





Enhanced  
**DIGITAL  
VERSION**  
Included

McDonald and Avery's

# DENTISTRY for the **CHILD** and **ADOLESCENT**

ELEVENTH EDITION



**JEFFREY A. DEAN**

ASSOCIATE EDITORS: Jones, Sanders, Vinson and Yepes



McDonald and Avery's

# DENTISTRY

for the **CHILD**  
and **ADOLESCENT**

ELEVENTH EDITION

## Jeffrey A. Dean, DDS, MSD, FFD(Hon)RCSI

Ralph E. McDonald Professor of Pediatric Dentistry  
Professor of Orthodontics and Dentofacial Orthopedics  
Indiana University School of Dentistry  
Riley Hospital for Children at IU Health  
Indianapolis, Indiana

### ASSOCIATE EDITORS:

#### James E. Jones, DMD, MSD, EdD, PhD

Paul E. Starkey Research Professor of Pediatric Dentistry  
Indiana University School of Dentistry  
Clinical Professor of Pediatrics  
Indiana University School of Medicine  
Riley Hospital for Children at IU Health  
Indianapolis, Indiana

#### Brian J. Sanders, DDS, MS

Sarah Jane McDonald Professor and Chair of Pediatric  
Dentistry  
Indiana University School of Dentistry  
Director, Department of Pediatric Dentistry  
Riley Hospital for Children at IU Health  
Indianapolis, Indiana

#### LaQuia A. Walker Vinson, DDS, MPH

Associate Professor and Graduate Program Director  
Department of Pediatric Dentistry  
Indiana University School of Dentistry  
Adjunct Clinical Faculty  
Indiana University School of Medicine  
Riley Hospital for Children at IU Health  
Indianapolis, Indiana

#### Juan Fernando Yepes, DDS, MD, MPH, MS, DrPH

Professor, Department of Pediatric Dentistry  
Indiana University School of Dentistry  
Riley Hospital for Children at IU Health  
Indianapolis, Indiana  
Adjunct Professor, CES University, Medellin, Colombia  
Adjunct Clinical Faculty, Department of Pediatric and  
Community Dentistry  
University at Buffalo, State University of New York

### VIDEO PRODUCER FOR ONLINE TEXT:

#### Allison C. Scully, DDS, MS

Clinical Assistant Professor  
Department of Pediatric Dentistry  
Indiana University School of Dentistry  
Riley Hospital for Children at IU Health  
Indianapolis, Indiana





Elsevier  
3251 Riverport Lane  
St. Louis, Missouri 63043

MCDONALD AND AVERY'S DENTISTRY FOR  
THE CHILD AND ADOLESCENT, ELEVENTH EDITION  
Copyright © 2022 by Elsevier, Inc. All rights reserved.

ISBN: 978-0-323-69820-7

No part of this publication may be reproduced or transmitted in any form or by any means, electronic or mechanical, including photocopying, recording, or any information storage and retrieval system, without permission in writing from the publisher. Details on how to seek permission, further information about the Publisher's permissions policies and our arrangements with organizations such as the Copyright Clearance Center and the Copyright Licensing Agency, can be found at our website: [www.elsevier.com/permissions](http://www.elsevier.com/permissions).

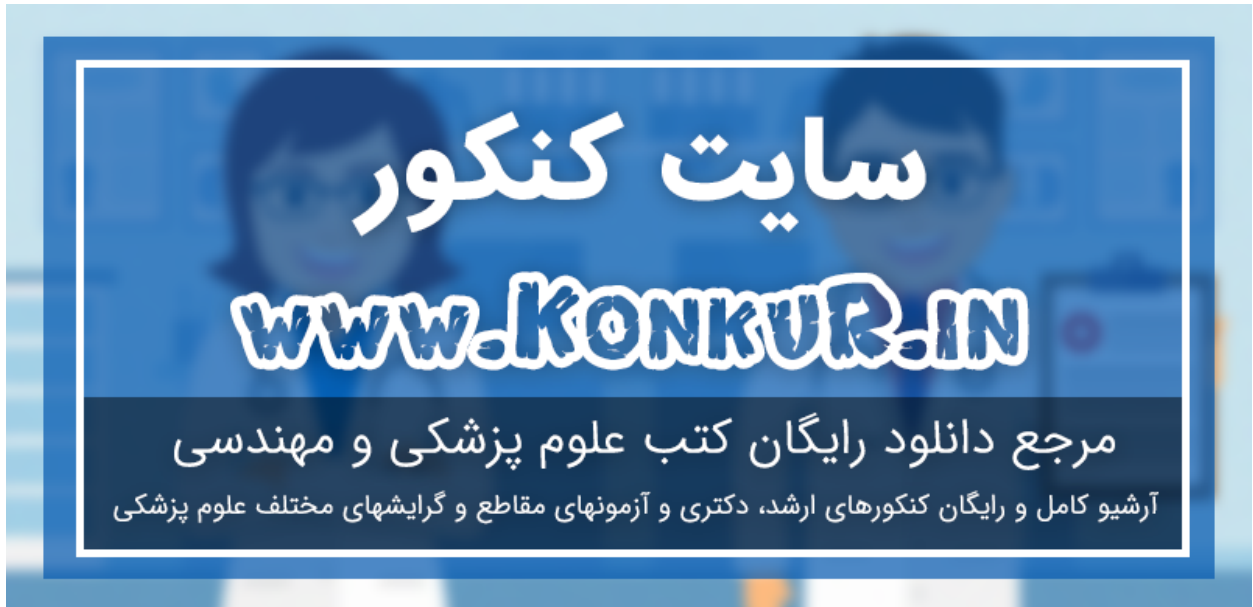This book and the individual contributions contained in it are protected under copyright by the Publisher (other than as may be noted herein).

#### Notices

Knowledge and best practice in this field are constantly changing. As new research and experience broaden our understanding, changes in research methods, professional practices, or medical treatment may become necessary. Practitioners and researchers must always rely on their own experience and knowledge in evaluating and using any information, methods, compounds or experiments described herein. Because of rapid advances in the medical sciences, in particular, independent verification of diagnoses and drug dosages should be made. To the fullest extent of the law, no responsibility is assumed by Elsevier, authors, editors or contributors for any injury and/or damage to persons or property as a matter of products liability, negligence or otherwise, or from any use or operation of any methods, products, instructions, or ideas contained in the material herein.

Previous editions copyrighted 2016, 2011, 2004, 1998, 1994, 1987, 1983, 1978, 1974, and 1969.

Library of Congress Control Number: 2020948301



Content Strategist: Joslyn Dumas  
Director, Content Development: Ellen Wurm-Cutter  
Senior Content Development Specialist: Kathleen Nahm  
Publishing Services Manager: Deepthi Unni  
Project Manager: Janish Ashwin Paul  
Design Direction: Renee Duenow

Printed in China

Last digit is the print number: 9 8 7 6 5 4 3 2 1



The associate editors of this edition, Jim Jones, Brian Sanders, LaQuia Vinson, Juan Yepes, and I would all like to affectionately dedicate this edition's labor of love to our spouses and children, and our many colleagues and students, both former and current. To our families, we all know the time away from you to work on this project can never be gained back, but your patience, love, and support throughout its production are so wonderfully appreciated by us all.

*"May the hinges of friendship never rust, nor the wings of love lose a feather."*

EDWARD B. RAMSAY, CIRCA 1857

***Jeffrey A. Dean***

# Contributors

## **Jeffrey D. Bennett, DMD**

Oral and Maxillofacial Surgery  
Indiana University School of Dentistry  
Roudebush VA Medical Center  
Indianapolis, Indiana

## **Mathew David Bojrab, DDS, MS, FACS**

Indiana Oral and Maxillofacial Surgery Associates  
Fishers, Indiana  
Oral and Maxillofacial Surgery  
Assistant Clinical Professor  
Oral and Maxillofacial Surgery  
Indiana University School of Dentistry  
Indianapolis, Indiana  
Chairman  
Oral and Maxillofacial Surgery and Hospital Dentistry  
Indiana University Health-Methodist Hospital  
Indianapolis, Indiana  
Chairman  
Oral and Maxillofacial Surgery and Hospital Dentistry  
Community Hospitals Indianapolis  
Indianapolis, Indiana

## **Judith Chin, DDS, MS**

Professor, Pediatric Dental Resident Program Director  
Department of Pediatric Dentistry  
Nova Southeastern University College of Dental  
Medicine  
Fort Lauderdale, Florida

## **Lilly Cortes-Pona**

Owner, CDMP  
LCP Dental Team Coaching  
AAPD Speaker's Bureau Member  
John Maxwell Leadership Coach  
Castle Rock, Colorado

## **Jeffrey A. Dean, DDS, MSD, FFD(Hon)RCSI**

Ralph E McDonald Professor of Pediatric Dentistry  
Professor of Orthodontics and Dentofacial Orthopedics  
Indiana University School of Dentistry  
Riley Hospital for Children at IU Health  
Indianapolis, Indiana

## **Kevin Donly, BS, DDS, MS**

Professor and Chair  
Department of Developmental Dentistry  
University of Texas Health Science Center at San Antonio  
San Antonio, Texas  
Professor  
Department of Pediatrics  
University of Texas Health Science Center at San Antonio  
San Antonio, Texas

## **Burton L. Edelstein, DDS, MPH**

Professor of Dental Medicine and Health Policy &  
Management  
Section of Growth and Development, Division of  
Pediatric Dentistry  
Columbia University Medical Center  
New York, New York  
Senior Policy Fellow and President Emeritus  
Children's Dental Health Project  
Washington, District of Columbia

## **John D. Emhardt, BSE, MD**

Associate Professor  
Anesthesia  
Indiana University School of Medicine  
Indianapolis, Indiana  
Medical Director  
Riley Outpatient Surgery Center  
Indianapolis, Indiana

## **Sabrina Feitosa, DDS, MSc, PhD**

Clinical Assistant Professor  
Biomedical Sciences and Comprehensive Care  
Indiana University School of Dentistry  
Indianapolis, Indiana

## **Donald J. Ferguson, DMD, MSD**

Professor of Orthodontics & Dean  
Orthodontics  
European University College  
Dubai  
United Arab Emirates

## **Elie M. Ferneini, DMD, MD, MHS, MBA, FACS**

Medical Director  
Beau Visage Med Spa  
Private Practice, Greater Waterbury OMS  
Cheshire, Connecticut  
Associate Clinical Professor  
Division of Oral and Maxillofacial Surgery  
University of Connecticut  
Farmington, Connecticut  
Associate Clinical Professor  
Department of Surgery  
Frank H Netter MD School of Medicine Quinnipiac  
University  
Hamden, Connecticut

## **Roberto Flores, MD**

Joseph G. McCarthy Associate Professor of Reconstructive  
Plastic Surgery  
Hansjorg Wyss Department of Plastic Surgery  
NYU Langone Health  
New York, New York

**Tasha Hall, DMD, MSD**

Director of Craniofacial Orthodontics  
Department of Orthodontics  
Indiana University  
Indianapolis, Indiana

**James Kennedy Hartsfield Jr., DMD, MS, MMSc, PhD**

Professor and E. Preston Hicks Endowed Chair in  
Orthodontics and Oral Health Research  
Oral Health Science  
University of Kentucky College of Dentistry  
Lexington, Kentucky  
Adjunct Professor  
Medical and Molecular Genetics  
Indiana University School of Medicine  
Indianapolis, Indiana  
Adjunct Professor  
Orthodontics and Oral Facial Genetics  
Indiana University School of Dentistry  
Indianapolis, Indiana  
Adjunct Clinical Professor  
Orthodontics  
University of Illinois at Chicago College of Dentistry  
Chicago, Illinois

**Kerry Hege, MD, MSc**

Assistant Professor  
Pediatric Hematology/Oncology  
Riley Hospital at IU Health  
Indiana University School of Medicine  
Indianapolis, Indiana

**Christopher V. Hughes, DMD, PhD**

Professor and Chair  
Pediatric Dentistry  
School of Dentistry, University of Mississippi Medical  
Center  
Jackson, Mississippi

**Vanchit John, DDS, MSD**

Chairperson and Tenured Professor  
Department of Periodontology  
Indiana University School of Dentistry  
Indianapolis, Indiana

**James Earl Jones, DMD, MSD, EdD, PhD**

Starkey Research Professor  
Department of Pediatric Dentistry  
Indiana University School of Dentistry  
Indianapolis, Indiana  
Clinical Professor  
Department of Pediatrics  
Indiana University School of Medicine  
Indianapolis, Indiana

**Mathew Thomas Kattadiyil, BDS, MDS, MS**

Professor and Director  
Advanced Specialty Education Program in  
Prosthodontics  
Loma Linda University School of Dentistry  
Loma Linda, California

**Carrie Klene, DDS**

Oral and Maxillofacial Surgeon  
Klene Center Oral & Facial Surgery  
Indiana University Health  
Carmel, Indiana

**Joan Elizabeth Kowolik, BDS, LDS, RCS Edin, Dip. Clin. Hyp.**

Director, Associate Professor  
Pediatric Dentistry  
Indiana University School of Dentistry  
Indianapolis, Indiana

**George Krull, DDS**

Private Practice, Pediatric Dentistry (Retired)  
Clarkston, Michigan

**John T. Krull, DDS**

Department of Pediatric Dentistry  
Indiana University School of Dentistry  
Indianapolis, Indiana

**John J. Manaloor, MD**

Assistant Professor of Clinical Pediatrics  
Ryan White Center for Pediatric Infectious Diseases  
Riley Hospital for Children, Indiana University School of  
Medicine  
Indianapolis, Indiana

**E. Angeles Martinez Mier, DDS, MSD, PHD**

Professor and Chair  
Cariology, Operative Dentistry and Dental Public Health  
Indiana University School of Dentistry  
Indianapolis, Indiana

**Hannah L. Maxey, PhD, MPH**

Associate Professor  
Family Medicine  
Indiana University School of Medicine  
Indianapolis, Indiana  
Director  
Bowen Center for Health Workforce Research and Policy  
at Indiana University School of Medicine  
Indianapolis, Indiana

**Lorri Ann Morford, PhD**

Assistant Professor  
Oral Health Science  
University of Kentucky  
Lexington, Kentucky

**Charles Nakar, MD**

Pediatric Hematologist  
Department of Pediatric  
Indiana Hemophilia and Thrombosis Center  
Indianapolis, Indiana

**Jeffrey A. Platt, DDS, MS**

Professor and Chair  
Biomedical Sciences and Comprehensive Care  
Indiana University  
Indianapolis, Indiana

**Laura Marie Romito, DDS, MS, MBA**

Professor  
Biomedical Sciences and Comprehensive Care  
Indiana University School of Dentistry  
Indianapolis, Indiana  
Assistant Dean  
IU Interprofessional Practice and Education Center  
Indiana University  
Indianapolis, Indiana

**Brian Sanders, DDS, MS**

Sarah Jane McDonald Professor and Chair  
Department of Pediatric Dentistry  
Indiana University School of Dentistry  
Riley Hospital for Children at IU Health  
Indianapolis, Indiana

**Mark Saxen, DDS, PhD**

Adjunct Clinical Associate Professor  
Oral Pathology, Medicine and Radiology  
Indiana University School of Dentistry  
Indianapolis, Indiana  
Dentist Anesthesiologist  
Indiana Office-Based Anesthesia  
Indianapolis, Indiana

**Allison Scully, DDS, MS**

Clinical Assistant Professor  
Department of Pediatric Dentistry  
Indiana University School of Dentistry Indianapolis  
Indianapolis, Indiana  
United States

**Amy D. Shapiro, MD**

Medical Director  
Pediatric Hematology  
Indiana Hemophilia & Thrombosis Center  
Indianapolis, Indiana  
Adjunct Senior Investigator  
Blood Research Institute  
Blood Center of Wisconsin  
Milwaukee, Wisconsin

**Daniel Shin, DDS, MSD**

Clinical Assistant Professor, Director Predoctoral  
Periodontology  
Department of Periodontology  
Indiana University School of Dentistry  
Indianapolis, Indiana

**Pooya Soltanzadeh, DDS, MS**

Assistant Professor  
Advanced Prosthodontics  
Loma Linda University School of Dentistry  
Loma Linda, California

**Kenneth J. Spolnik, DDS, MSD**

Chair and Program Director  
Endodontics  
Indiana University School of Dentistry  
Indianapolis, Indiana

**Jenny Stigers, DMD**

Associate Professor  
University of Kentucky College of Dentistry  
Lexington, Kentucky

**Dan Stoeckel, DDS, MS**

Program Director  
Graduate Pediatric Dentistry  
Saint Louis University  
Oral Pathologist  
Department of Pathology  
Saint Louis University  
St. Louis, Missouri  
Pediatric Dentist  
St. Louis Children's Hospital  
St. Louis, Missouri

**Shannon Thompson, MD**

Assistant Professor of Clinical Medicine  
IU Child Protection Programs  
Indiana University School of Medicine  
Indianapolis, Indiana

**Erwin G. Turner, DMD**

Associate Professor and Residency Director  
Pediatric Dentistry  
University of Kentucky College of Dentistry  
Lexington, Kentucky

**Jose Luis Ureña-Cirett, CD, MS**

Pediatric Dentistry  
Universidad Tecnológica de México, Mexico City  
CDMX  
Mexico

**LaQuia Walker Vinson, DDS, MPH**

Associate Professor, Pediatric Dentistry  
Graduate Program Director, Pediatric Dentistry Indiana  
University School of Dentistry Indianapolis  
Indianapolis, Indiana

**John Walsh, BDentSc, MSD (Ped), IUSD, MSD(Orth) UW, FFDRCSI**

Course Lead,  
Faculty of Dentistry  
Royal College of Surgeons  
Dublin  
Ireland

***Julie Weir, BS***

Founder  
Consultant  
Julie Weir & Associates  
Middleburg, Virginia

***Ghaeth Yassen, BDS, MSD, PhD***

Endodontist  
Department of Endodontics  
Case Western Reserve University  
Cleveland, Ohio

***Juan Fernando Yepes, DDS, MD, MPH, MS, DrPH***

Professor  
Pediatric Dentistry  
Indiana University School of Dentistry Indianapolis  
Indianapolis, Indiana  
Clinical Associate Professor  
Pediatric and Community Dentistry  
University at Buffalo School of Dental Medicine  
Buffalo, New York  
Visiting Professor  
Pediatric Dentistry  
CES University  
Medellin, Antioquia  
Colombia

# Reviewers

## ***Dorothy Lynne Cataldo, DMD***

Private Practice, Pediatric Dentist  
Pediatric Dentistry Faculty  
NYU Langone Advanced Education  
Tampa, Florida

## ***Brenda Bohaty, DDS, MSD, PhD***

Professor and Chair, Pediatric Dentistry - UMKC School of  
Dentistry  
Director, Residency Program in Pediatric Dentistry -  
Children's Mercy Hospital  
Kansas City, Missouri

## ***Farhad Yeroshalmi, DMD***

Professor of Dentistry  
Albert Einstein College of Medicine  
Chief & Residency Program Director  
Department of Pediatric Dentistry  
NYC Health + Hospitals/Jacobi  
Bronx, New York

## ***Cody Hughes, DMD, MSD***

Valley Pediatric Dental  
Mesquite/Logandale, Nevada  
Sunrise Children's Dentistry  
Las Vegas, Nevada

## ***Yuming Zhao, DDS, PhD***

Professor in the Department of Pediatric Dentistry  
Peking University School and Hospital of Stomatology  
Beijing, China

## ***Man Qin, BDS, PhD***

Professor of Department of Pediatric Dentistry  
Peking University School and Hospital of Stomatology  
President of Chinese Society of Pediatric Dentistry  
Beijing, China



# Foreword to the 11th edition of *McDonald and Avery's Dentistry for the Child and Adolescent: a historical review*



## **Ari Kupietzky, DMD, MSc**

Private practice, Jerusalem, Israel  
 Department of Pediatric Dentistry, Rutgers School of Dental  
 Medicine, Rutgers University, Newark, NJ  
 Department of Pediatric Dentistry, Hebrew University–  
 Hadassah School of Dental Medicine, Jerusalem, Israel

## **Stanley Gelbier, Hon FFPH, MA, PhD, FDSDDPH, DHMSA**

Honorary Professor in History of Dentistry, King's College  
 London, London, UK  
 Emeritus-Professor in Dental Public Health, University of  
 London, London, UK  
 Past President and National Secretary, British Paedodontic  
 Society, London, UK

## **Introduction**

In 1963, when Ralph McDonald wrote *Pedodontics*, dentistry for children was still in its infancy. McBride in 1952 wrote that children were sometimes described as being “temperamental and hysterical, notional and incorrigible.” Many practitioners saw them as small adults and offered little treatment. Nevertheless, there had been for a long time some enthusiastic dentists. One name to remember is Sam Harris, who qualified from Ann Arbor Dental School in 1924. Almost immediately, he enrolled at Boston's Forsyth Dental Infirmary for Children. He and his fellow students learned much about child dental care at a time

when many American dentists had notices in their offices that no children under the age of 12 years were accepted. Harris opened a practice specializing in pediatric dentistry in Detroit and decided a formal organization was needed to spread good care. In 1927, he and others founded the American Society for the Promotion of Children's Dentistry, which became the American Society of Dentistry for Children (ASDC) in 1940. In 1947, he was also influential in establishment of the American Academy of Pedodontics, renamed the American Academy of Pediatric Dentistry (AAPD) in 1984. In 1943, Harris was the founding editor of the *Review of Dentistry for Children*, precursor of the *Journal of Dentistry for Children*. In the 1930s, Harris began to formulate ideas on an international organization to bring together children's dentists from around the world. It was 1969 before his dream was fulfilled with establishment of the International Association of Dentistry for Children, which became the International Association of Paediatric Dentistry in 1991. This all began to put children's dentistry on a sounder footing, both at the general practitioner and specialist levels.

Walter E. McBride was the first president of ASDC. He and Harris devoted many hours to setting up the new organization. He was also a president of the American Academy of Pedodontics, the American Association of Dental Editors, and the Detroit District Dental Society. McBride was professor of pedodontics at the University of Detroit, so anything he wrote or said was listened to. In 1933, he told a meeting of the American Dental Association that when a general practice dentist refuses to treat children, he is disregarding a major factor in practice building. He quoted a new graduate who opened an office in a town of 2000 inhabitants where two dentists had practiced successfully for many years. They didn't like the idea of a newcomer with the audacity of a beginner, who installed beautiful new equipment and even employed an office assistant, potentially taking from their income. As he especially liked children, he suggested that they, not enjoying children's work, should refer them to him, and they agreed. The children came, liked the new dentist, gave favorable reports to their parents and their mothers came for treatment: a practice builder.

McBride published his *Juvenile Dentistry* in 1932, which probably remained the leading text until McDonald entered the field, although there were others. McBride said of his own book, “It was not scientific nor theoretical, but purely a résumé of practical procedures employed over ten years in a private practice devoted entirely to children.” It is not surprising that McBride's book was highly popular, but by

the end of the 1950s there was room for something new: a text based on scientific methodology.

We have to remember that when McDonald began his career in the 1940s, children suffered from massive dental caries, the prevalence being five times more than current (Bernabé & Sheiham, 2014). Prevention was needed. Following pressure from H. Trendley Dean, in 1945, Grand Rapids became the first city in the world to fluoridate its drinking water. Over 15 years, Dean researched decay in 30,000 schoolchildren and found that caries in children born after fluoridation was reduced by over 60 percent, revolutionizing dental care. For the first time, tooth decay became a preventable disease! Widespread use of fluoride toothpastes came way after McDonald's first book.

Ralph E. McDonald (1920-2015) commenced his career in 1944 with a DDS from Indiana University School of Dentistry. During his service as a naval dental officer, he observed much dental disease amongst young recruits and realized the need for good dentistry already in childhood. McDonald read every textbook and journal about children's dentistry that he could get his hands on. He continued to study once he returned home. Since a degree in pediatric dentistry had not yet been established, he earned a master's degree in microbiology. The year 1946 saw McDonald become an instructor in Indiana University's Children's Dental Clinic, where he pioneered the pediatric dentistry program (Fig. 1). Although he didn't realize it, whilst writing his lecture notes, they were a textbook waiting to happen. In 1952, McDonald became chair of the Children's Dentistry Department. During this period of time, much of the dental treatment for children was given by general practitioners, but some dentists trained as specialist pediatric dentists ("pedodontists" when the book was first published). It goes without saying that both groups needed good textbooks.

In 1963, McDonald published his book, *Pedodontics*, a 479-page compilation of material drawn from McDonald's lectures (Fig. 2). It contained eleven chapters and was highly successful as a textbook for graduate students. Interesting to note is the terminology used for Chapter 2, "Behavior guidance in the dental office." The AAPD only



Fig. 1 Dr. McDonald (right foreground) with patients and students in the school's pedodontic clinic in 1952.

recently changed its policy and guidelines from behavior management to behavior guidance as was proposed by McDonald over 50 years ago. *Pedodontics* was upgraded in 1969 as *Dentistry for the Child and Adolescent*, which contained his original 11 chapters from 1963 plus an additional 17 chapters written by 14 contributors. From the beginning, the editors and contributors of McDonald's *Dentistry for the Child and Adolescent* have been amongst the specialty's pioneers and top academicians, clinicians, and scientists. Early contributors included Maynard Hine, William Shafer, Ralph Phillips, Roland Dykema, James Roche, and Paul Starkey. Many of them had their own names on the cover of dental textbooks. The list of contributors was and remains tremendous, including esteemed colleagues such as Gerald Wright, Howard Needleman, and George Stookey. Amongst contemporary contributing pediatric dentist authors are Johon Aps, Ron Bell, Angus Cameron, Judith Chin, Kevin Donly, Burton Edelstein, Hala Henderson, Donald Huebener, Christopher Hughes, James Jones, Joan Kowolik, George Krull, Jasper Lewis, Brian Sanders, Jenny Stigers, Erwin Turner, John Walsh, James Weddell, LaQuia Vinson, and Juan Yepes.

Almost until he died, McDonald remained its author. However, in 1969, McDonald became dean of dentistry. This placed an added burden on his shoulders. And so, after completing the second edition in 1974, McDonald saw the need for a co-editor. He said: "I was getting further and further away from clinical dentistry. After producing two editions, I realized there were areas I could no longer cover by myself. I brought Dave in for his clinical expertise and research experience in dental materials." For the third




Fig. 2 Cover of *Pedodontics* published in 1963.

edition in 1978, McDonald guided David R. Avery through the whole process and gave him full credit. The fourth edition in 1983 “was very much a shared piece of work,” said Avery. In the sixth edition, a new author by the name of Jeffrey A. Dean was added, but it was not until the eighth edition that he would join the editorial team of McDonald and Avery. 2016 saw the book’s 50<sup>th</sup> anniversary 10<sup>th</sup> edition published. As they handed over the editorship to Dr. Dean, McDonald said: “As we entrust the continuing editions of this textbook to others, we reflect on the many rewards we have realized by our participation in the previous editions. There are rewards for students, colleagues who teach and/or practice pediatric dentistry and most importantly their patients.” He went on: “We wish Godspeed to Dr. Dean..., and all other future contributors as they proceed with this work of love. We have the utmost confidence in their abilities to carry on.”

*Dentistry for the Child and Adolescent* is internationally popular and has been considered a classic text for graduate programs worldwide. It has been translated from English into several foreign languages, including Chinese, Farsi, Japanese, Italian, Portuguese, Spanish, and Russian. The textbook is now the world’s longest-running children’s dentistry textbook (Fig. 3).

The specialty of pediatric dentistry has grown over the past century in popularity. For the 2020–21 academic year, the number of positions offered and residency positions filled surpasses all specialties and advanced education in general dentistry programs. *McDonald and Avery's Dentistry for the Child and Adolescent* has grown alongside, providing graduates and specialists with knowledge, science, and technique as envisioned by McDonald so many years ago.



**Fig. 3** The late Dr. Ralph E. McDonald (middle) with Dr. David R. Avery (left) and Dr. Jeffrey A. Dean (right), celebrating in 2000 the release of the 7<sup>th</sup> edition of the textbook. With that edition becoming the pediatric dentistry textbook with the most editions ever by surpassing Hogeboom’s total of 6 editions, Drs. Avery and Dean honored Dr. McDonald with a new world record gold medal and olive wreath.

## References

- Bernabé E, Sheiham A: Period and cohort trends in caries of permanent teeth in four developed countries, *Am J Public Health* 104:e115–e121, 2014. <https://doi.org/10.2105/AJPH.2014.301869>
- McBride, WC: Juvenile dentistry. 1952 (ed. 5), Lea & Febiger, Philadelphia.
- McBride, Walter C: The business phase of Children’s Dentistry *Journal of the American Dental Association*, 20(6):1003-1010, 1933.
- The health policy institute of the American Dental Association, <https://www.ada.org/en/science-research/health-policy-institute/data-center/dental-education>



# Preface and Acknowledgements

It is a great pleasure for me to introduce the next iteration of this long standing and successful textbook on the essence, foundation, and innovations in the science and practice of pediatric dentistry. After formally requesting and receiving fantastic feedback, compliments, and suggestions from a broad representation of notable academics and clinicians, as well as adding two new associate editors with specific expertise in their areas covered in the text, we analyzed, planned, and developed this edition to continue the nearly 60-year history of the book.

As I am writing this introduction, the world is mired in the Covid-19 pandemic and slowly learning how to adapt to the “new abnormal.” While impacting our care and practice, this remains an exciting time in dentistry and specifically pediatric dentistry, as new concepts, research,

techniques and philosophies continue to positively impact outcomes for our child and young adult patients. Increased emphasis on patient, centered care, parent and child consent and assent, continued public health and private practice improvements, advances in minimalist approaches to restorative care, new science on dental materials, pulp regeneration and revascularization, as well as a wide array of other advances, have enhanced our abilities to care for our patients and have been incorporated into these chapters.

Specifically, I am pleased to highlight a few additions and significant updates:

- Thirteen new authors have been added
- Complete update of the online video contribution with the expertise of a new video producer



**Front row, left to right: Jones, Dean**  
**Back row, left to right: Yepes, Vinson, Sanders**

- Rewrite of the community dentistry chapter with three critical components—dental workforce, dental delivery sites and organizations, and payment source
- Updates on preventive, interceptive, and early orthodontic treatment, including information on pediatric sleep apnea
- New emphasis on the use of silver diamine fluoride
- New author update of the oral pathology chapter
- New section on vaping and oral implications
- Updated pain management section related to opioid use and misuse
- New section on pediatric dental bleaching
- Information on coronavirus and Covid-19 in children
- Updated on Periodontal Classification for children
- Expert Consult website with fully searchable access to the text, videos and multiple-choice questions

All of these enhancements take the assistance and dedication of multiple people. In particular, I'd like to thank all the great support staff at the Indiana University School of

Dentistry, in particular Terry Wilson, Jr. and Caleb Clements for their excellent production and editing work on all of the new videos, Amy Edmunds, Joyce Marlatt and Jasmine Pence for their administrative support, Abby Morgan and Nicole Alderson in dental illustrations for their work, and Sean Stone for his guidance on the citation reference manager.

I'm proud of the dedication and work of our associate editors and authors for once again helping to maintain the tradition of excellence established by our mentors and predecessors, Drs. McDonald and Avery. We hope you enjoy this new edition, and as always, I look forward to your comments and constructive criticism as we continuously strive for improvement and the highest in quality. All the best to you, our colleagues, friends, and students.

***Jeffrey A. Dean***

## 1

# Examination of the Mouth and Other Relevant Structures

JUAN F. YEPES and JEFFREY A. DEAN

## CHAPTER OUTLINE

### Introduction

### Initial Parental Contact with the Dental Office

### The Diagnostic Method

### Preliminary Medical, Dental, Family, and Social History

### Clinical Examination

### Temporomandibular Evaluation

### Uniform Dental Recording

### Radiographic Examination

### Early Examination

### Infant Dental Care

### Detection of Substance Abuse

### Etiologic Factors in Substance Abuse

### Specific Substances and Frequency of use

### Vaping and Electronic Cigarettes

### Suicidal Tendencies in Children and Adolescents

### Infection Control in the Dental Office

### Biofilm

### Emergency Dental Treatment

## Introduction

A dentist is traditionally taught to perform a complete oral examination of the patient and to develop a treatment plan based on the examination findings. The dentist subsequently makes a case presentation to the patient or parents, outlining the recommended course of treatment. This process should include the development and presentation of a prevention plan that outlines an ongoing comprehensive oral health care program for the patient and establishment of the “dental home.”

The plan should include recommendations designed to correct the existing oral problems (or halt their progression) and to prevent anticipated future problems. It is essential to obtain all relevant patient and family information, to secure parental consent, and to perform a complete examination before embarking on this comprehensive oral health care program for pediatric patients. *Anticipatory guidance* is the term often used to describe the discussion and implementation of such a plan with the patient and/or parents. The American Academy of Pediatric Dentistry has published guidelines<sup>1</sup> concerning the periodicity of examination, preventive dental services, and oral treatment for children as summarized in [Table 1.1](#).

Each pediatric patient should be given an opportunity to receive complete dental care. The dentist should not attempt to decide what the child, the parents, or a third-party agent will accept or can afford. If parents reject a portion or all of the recommendations, the dentist has at least fulfilled the obligation of educating the child and the parents about the importance of the recommended

procedures. Parents with even moderate income usually find the means to have oral health care performed if the dentist explains that the child’s future oral health and even general health are related to the correction of the oral defects.

## Initial Parental Contact with the Dental Office

We most often think of parents’ first contact with the dental office as being by telephone or electronic contact formats (Instagram, Facebook, etc). This initial conversation between the parent and the office receptionist is very important. It provides the first opportunity for the receptionist to attend to the parents’ concerns by pleasantly and concisely responding to questions and by offering an office appointment. The receptionist must have a warm, friendly voice and the ability to communicate clearly. The receptionist’s responses should assure the parent that the well-being of the child is the chief concern.

The information recorded by the receptionist during this conversation constitutes the initial dental record for the patient. Filling out a patient information form is a convenient method of collecting the necessary initial information. Of course, most dental practices are moving toward online, website-driven information and completion of patient forms for use even before a parent calls an office for an appointment or schedules an appointment online. Practices need to make accommodations to their patient information systems to manage these very productive changes.

**TABLE 1.1** Recommendations for Pediatric Oral Health Assessment, Preventive Services, and Anticipatory Guidance/Counseling

Since each child is unique, these recommendations are designed for the care of children who have no contributing medical conditions and are developing normally. These recommendations will need to be modified for children with special health care needs or if disease or trauma manifests variations from normal. The American Academy of Pediatric Dentistry (AAPD) emphasizes the importance of very early professional intervention and the continuity of care based on the individualized needs of the child. Refer to the text of this guideline for supporting information and references. Refer to the text in the Guidelines on Periodicity of Examinations, Preventive Dental Services, Anticipatory Guidance, and Oral Treatment for Infants, Children, and Adolescents ([www.aapd.org/media/Policies\\_Guidelines/G\\_Periodicity.pdf](http://www.aapd.org/media/Policies_Guidelines/G_Periodicity.pdf)) for supporting information and references.

	AGE				
	6–12 months	12–24 months	2–6 years	6–12 years	≥12 years
Clinical oral examination <sup>1</sup>	•	•	•	•	•
Assesses oral growth and development <sup>2</sup>	•	•	•	•	•
Caries-risk assessment <sup>3</sup>	•	•	•	•	•
Radiographic assessment <sup>4</sup>	•	•	•	•	•
Prophylaxis and topical fluoride <sup>3,4</sup>	•	•	•	•	•
Fluoride supplementation <sup>5</sup>	•	•	•	•	•
Anticipatory guidance/counseling <sup>6</sup>	•	•	•	•	•
Oral hygiene counseling <sup>7</sup>	Parent	Parent	Patient/parent	Patient/parent	Patient
Dietary counseling <sup>8</sup>	•	•	•	•	•
Injury prevention counseling <sup>9</sup>	•	•	•	•	•
Counseling for nonnutritive habits <sup>10</sup>	•	•	•	•	•
Counseling for speech/language development	•	•	•	•	•
Assessment and treatment of developing malocclusion			•	•	•
Assessment for pit-and-fissure sealants <sup>11</sup>			•	•	•
Substance abuse counseling				•	•
Counseling for intraoral/perioral piercing				•	•
Assessment and/or removal of third molars					•
Transition to adult dental care					•

<sup>1</sup>First examination at the eruption of the first tooth and no later than 12 months. Repeat every 6 months or as indicated by child's risk status/susceptibility to disease. Includes assessment of pathology and injuries.

<sup>2</sup>By clinical examination.

<sup>3</sup>Must be repeated regularly and frequently to maximize effectiveness.

<sup>4</sup>Timing, selection, and frequency determined by child's history, clinical findings, and susceptibility to oral disease.

<sup>5</sup>Consider when systemic fluoride exposure is suboptimal. Up to at least 16 years of age or later in high-risk patients.

<sup>6</sup>Appropriate discussion and counseling should be an integral part of each visit for care.

<sup>7</sup>Initially, responsibility of parent; as child matures, jointly with parent; then, when indicated, only child.

<sup>8</sup>At every appointment; initially discuss appropriate feeding practices, followed by the role of refined carbohydrates and frequency of snacking in caries development and childhood obesity.

<sup>9</sup>Initially for play objects, pacifiers, car seats; then while learning to walk; and then with sports and routine playing, including the importance of mouthguards.

<sup>10</sup>At first, discuss the need for additional sucking: digits vs. pacifiers; then the need to wean from the habit before malocclusion or skeletal dysplasia occurs. For school-aged children and adolescent patients, counsel regarding any existing habits such as fingernail biting, clenching, or bruxism.

<sup>11</sup>For caries-susceptible primary molars, permanent molars, premolars, and anterior teeth with deep pits and fissures; placed as soon as possible after eruption.

## The Diagnostic Method

Before making a diagnosis and developing a treatment plan, the dentist must collect and evaluate the facts associated with the patient's or parents' chief concern and any other identified problems that may be unknown to the patient or parents. Some pathognomonic signs may lead to an almost immediate diagnosis. For example, obvious gingival swelling and drainage may be associated with a single, badly carious primary molar. Although these associated facts are collected and evaluated rapidly, they provide a diagnosis only for a single problem area. On the other hand, a comprehensive diagnosis of all of the patient's problems or potential problems may sometimes need to be postponed until more urgent conditions are resolved. For example, a patient with necrotizing ulcerative gingivitis or a

newly fractured crown needs immediate treatment, but the treatment will likely be only palliative, and further diagnostic and treatment procedures will be required later.

The importance of thorough collection and evaluation of the facts concerning a patient's condition cannot be over-emphasized. A thorough examination of the pediatric dental patient includes an assessment of the following:

- General growth and health
- Diet
- Chief complaint, such as pain
- Extraoral soft tissue and temporomandibular joint (TMJ) evaluation
- Intraoral soft tissue



- Oral hygiene and periodontal health
- Intraoral hard tissue
- Developing occlusion
- Caries risk
- Behavior

Additional diagnostic aids are often also required, such as radiographs, study models, photographs, pulp tests, and, infrequently, laboratory tests. In certain unusual cases, all of these diagnostic aids may be necessary before a comprehensive diagnosis can be made. Certainly, no oral diagnosis can be complete unless the diagnostician has evaluated the facts obtained by medical and dental history taking, inspection, palpation, exploration (if teeth are present), and often imaging (e.g., radiographs). For a more thorough review of evaluation of the dental patient, refer to the chapter by Glick et al.<sup>2</sup> in *Burket's Oral Medicine*.

## Preliminary Medical, Dental, Family, and Social History

It is important for the dentist to be familiar with the medical, dental, family, and social history of the pediatric patient. Familial history may also be relevant to the patient's oral condition and may provide important diagnostic information in some hereditary disorders. Before the physical examination is performed, the dentist can obtain sufficient information to provide with knowledge of the child's general health from the parent or the child's physician. Dental assistants as well as dental hygienists can start collecting information/pre-screening with the parents. The dentist will follow this initial contact and expand or explore in more detail issues with a clear repercussion in the treatment plan. The form illustrated in Fig. 1.1 can be completed by the parent. However, it is more effective for the dentist to ask the questions marked by the parents and obtain more critical details to have a better prospective of the patient. The questions included on the form will also provide information about any previous dental treatment.

Information regarding the child's social and psychological development is important. Accurate information reflecting a child's learning, behavioral, or communication problems is sometimes difficult to obtain initially, especially when the parents are aware of their child's developmental disorder but are reluctant to discuss it. Behavior problems in the dental office are often related to the child's inability to communicate with the dentist and to follow instructions. This inability may be attributable to a learning disorder. An indication of learning disorders can usually be obtained by the dentist when asking questions about the child's learning process; for example, asking a young school-aged child how he or she is doing in school is a good lead question. The questions should be age appropriate for the child.

If a young child was hospitalized previously for general anesthetic and surgical procedures, it should be noted. Hospitalization and procedures involving general anesthesia can be a traumatic psychological experience for a preschool child and may sensitize the youngster to procedures that will be encountered later in a dental office.<sup>3</sup> If the dentist is aware that a child was previously hospitalized or that the child fears strangers in clinic attire, the necessary time and

procedures can be planned to help the child overcome the fear and accept dental treatment.

Occasionally, when the parents report significant disorders, it is best for the dentist to meet privately. They are more likely to discuss the child's problems openly, and there is less chance for misunderstandings regarding the nature of the disorders. In addition, the dentist's personal involvement at this early time strengthens the parents' confidence. When an acute or chronic systemic disease or anomaly is indicated, the dentist should consult the child's physician to learn the status of the condition, the long-range prognosis, and the current drug therapy.

When a patient's medical and dental history is recorded, the presence of current illnesses or history of relevant disorders signals the need for special attention. In addition to consulting the child's physician, the dentist may decide to record additional data concerning the child's current physical condition, such as blood pressure, body temperature, heart sounds, height and weight, pulse, and respiration. Before any treatment is initiated, certain laboratory tests may be indicated and special precautions may be necessary. A decision to provide treatment in a hospital that possibly involves general anesthesia may be appropriate.

The dentist and the staff must also be alert to identify potentially communicable infectious conditions that threaten the health of the patient and others. Knowledge of the current recommended childhood immunization schedule is helpful. It is advisable to postpone nonemergency dental care for a patient exhibiting signs or symptoms of acute infectious disease until the patient recovers. Further discussions of management of dental patients with special medical, physical, or behavioral problems are presented in Parts III and V.

The pertinent facts of the medical history can be transferred to the oral examination record (Fig. 1.2) for easy reference by the dentist. A brief summary of important medical information serves as a convenient reminder to the dentist and the staff, who will refer to this chart at each treatment visit.

The patient's dental history should also be summarized on the examination chart. This should include a record of previous care in the dentist's office and the facts related by the patient and parent(s) regarding previous care, if any, in another office. Information concerning the patient's current oral hygiene habits and previous and current fluoride exposure helps the dentist develop an effective dental disease prevention program. For example, if the family drinks well water, a sample may be sent to a water analysis laboratory to determine the fluoride concentration.

## Clinical Examination

Most facts needed for a comprehensive oral diagnosis in the young patient are obtained by thorough clinical and radiographic examination. In addition to examining the oral cavity structures, the dentist may wish to note the patient's size, stature, gait, or involuntary movements in some cases. The first clue to malnutrition may come from observing a patient's abnormal size or stature. Similarly, the severity of a child's illness, even if oral in origin, may be recognized by observing a weak, unsteady gait or lethargy and malaise as the patient walks into the office. All relevant information should be noted on the oral examination record (Fig. 1.2), which becomes a permanent part of the patient's chart.

**UNIVERSITY PEDIATRIC DENTISTRY ASSOCIATES**

Riley Hospital for Children IU Health | ROC | Pediatric Dentistry  
 705 Riley Hospital Drive, Room #4205  
 Indianapolis, IN 46202-5109  
 317.944.3865 office | 317.944.9653 fax  
[www.pediatricdentistryassociates.org](http://www.pediatricdentistryassociates.org)



DOB: _____	EDR: _____
NA: _____	
LC: _____	DATE: _____

**MEDICAL / DENTAL HISTORY**

Patient Name: \_\_\_\_\_ Birth Date: \_\_\_\_\_ Gender:  Female  Male  
 City & State of Birth: \_\_\_\_\_ Race: \_\_\_\_\_ Height: \_\_\_\_\_ Weight: \_\_\_\_\_  
 Primary Care Physician: \_\_\_\_\_ Previous Dentist: \_\_\_\_\_  
 Physician Address: \_\_\_\_\_ Dentist Phone: \_\_\_\_\_  
 Physician Phone: \_\_\_\_\_ Last Dental Visit: \_\_\_\_\_  
 Date of Last Medical Exam: \_\_\_\_\_ Last Dental X-rays: \_\_\_\_\_

**Dental History:**

What is the primary reason for today's visit? \_\_\_\_\_  
 Is patient in pain?  YES  NO Explain: \_\_\_\_\_  
 Has patient had an injury to the mouth, teeth, or jaw?  YES  NO Explain: \_\_\_\_\_  
 What is patient's primary water source:  Private Well  City Water, City Name: \_\_\_\_\_  Other: \_\_\_\_\_  
 Was/is patient  Breastfed or  Bottle-fed Until what age? Breastfed: \_\_\_\_\_ Bottle-fed: \_\_\_\_\_  
 How often does patient brush teeth? \_\_\_\_\_  With Help  Without Help How often does patient floss? \_\_\_\_\_  
 Does patient...  

Yes / No	Yes / No	Yes / No
<input type="checkbox"/> <input type="checkbox"/> Suck Thumb/Fingers	<input type="checkbox"/> <input type="checkbox"/> Bite/Chew Finger Nails	<input type="checkbox"/> <input type="checkbox"/> Clench/Grind Teeth
<input type="checkbox"/> <input type="checkbox"/> Use Pacifier	<input type="checkbox"/> <input type="checkbox"/> Have Speech Issues	<input type="checkbox"/> <input type="checkbox"/> Mouth Breather

**Medical History:**

Is patient currently under the care of a doctor?  YES  NO Explain: \_\_\_\_\_  
 Does patient have allergies?  YES  NO Explain: \_\_\_\_\_  
 Is patient taking medications?  YES  NO Please list all medications and natural remedies. Additional items may be listed on the back

Medication Name:	Dose:	Frequency of Use:
_____	_____	_____
_____	_____	_____
_____	_____	_____
_____	_____	_____
_____	_____	_____

Has patient had surgery or been hospitalized?  YES  NO  
 Hospital Facility: \_\_\_\_\_ When: \_\_\_\_\_ Reason: \_\_\_\_\_  
 \_\_\_\_\_  
 \_\_\_\_\_

Does patient have / or had any of the following:

Yes / No	Yes / No	Yes / No
<input type="checkbox"/> <input type="checkbox"/> Congenital Heart Defect/Disease	<input type="checkbox"/> <input type="checkbox"/> Visual/Hearing Impairment	<input type="checkbox"/> <input type="checkbox"/> Failure to Thrive
<input type="checkbox"/> <input type="checkbox"/> Heart Surgery	<input type="checkbox"/> <input type="checkbox"/> Abnormal Bleeding Issues	<input type="checkbox"/> <input type="checkbox"/> Eating Disorders
<input type="checkbox"/> <input type="checkbox"/> Heart Murmur	<input type="checkbox"/> <input type="checkbox"/> Sickle Cell Trait/Disease	<input type="checkbox"/> <input type="checkbox"/> Born Prematurely
<input type="checkbox"/> <input type="checkbox"/> High Blood Pressure	<input type="checkbox"/> <input type="checkbox"/> Hemophilia	<input type="checkbox"/> <input type="checkbox"/> Immunizations
<input type="checkbox"/> <input type="checkbox"/> Rheumatic Fever	<input type="checkbox"/> <input type="checkbox"/> Anemia	<input type="checkbox"/> <input type="checkbox"/> Hepatitis A, B, C
<input type="checkbox"/> <input type="checkbox"/> Asthma/Breathing Issues	<input type="checkbox"/> <input type="checkbox"/> Kidney Problems	<input type="checkbox"/> <input type="checkbox"/> Blood/Blood Product Transfusion
<input type="checkbox"/> <input type="checkbox"/> Cerebral Palsy	<input type="checkbox"/> <input type="checkbox"/> Liver Problems	<input type="checkbox"/> <input type="checkbox"/> HIV/AIDS
<input type="checkbox"/> <input type="checkbox"/> Seizures/Convulsions/Epilepsy	<input type="checkbox"/> <input type="checkbox"/> Diabetes	<input type="checkbox"/> <input type="checkbox"/> Varicella Vaccine / Chicken Pox
<input type="checkbox"/> <input type="checkbox"/> Learning/Communication Problems	<input type="checkbox"/> <input type="checkbox"/> Muscle/Joint/Bone Problems	<input type="checkbox"/> <input type="checkbox"/> TB / Tuberculosis
<input type="checkbox"/> <input type="checkbox"/> Autism	<input type="checkbox"/> <input type="checkbox"/> Thyroid/Glandular Problems	<input type="checkbox"/> <input type="checkbox"/> MRSA
<input type="checkbox"/> <input type="checkbox"/> ADD/ADHD	<input type="checkbox"/> <input type="checkbox"/> Skin Problems / Hives / Cold Sores	<input type="checkbox"/> <input type="checkbox"/> Limited Mobility

I affirm that the information provided above is correct to the best of my knowledge. It will be held in confidence and it is my responsibility to inform this office if there is a change in the health history of this patient. I authorize the release of this information to additional healthcare providers as is necessary for the dental treatments of this patient.

Guardian Signature: \_\_\_\_\_ Relationship to Patient: \_\_\_\_\_  
 Resident Signature: \_\_\_\_\_ Date: \_\_\_\_\_ Time: \_\_\_\_\_



Fig. 1.1 Form used in completing the preliminary medical and dental history. (Printed with permission from Indiana University–University Pediatric Dentistry Associates.)



**UNIVERSITY PEDIATRIC DENTISTRY ASSOCIATES**  
 Riley Hospital for Children • Outpatient Center • Dental MSA  
 702 Barnhill Drive, Room #4205  
 Indianapolis, IN 46202-5200  
 (317) 274-3865 • (317) 274-9653 Fax

*Place Patient Label Here*

Patient Name: \_\_\_\_\_  
Last First MI  
 DOB \_\_\_\_\_ Record #: \_\_\_\_\_

## ORAL EXAMINATION RECORD

Address: Same  New  \_\_\_\_\_ Telephone: Same  New  \_\_\_\_\_  
 \*\*\*\* New address and/or phone number must be noted here and updated in practice software.

<b>MEDICAL HISTORY SUMMARY</b>	Last History Completed: _____ Update Due: _____ Weight: _____ Current Medication Status & Medication Usage: _____
<b>DENTAL HISTORY SUMMARY</b>	Date of Last Exam: _____ Last Radiographs: B.W.: _____ A.O.: _____ P.A.: _____ F.M.: _____ Appliances: _____ Last Cemented: _____ Last Replaced: _____ Description of Present Problem: _____ Summary of Prior Treatment: _____
<b>EXTRA-ORAL FINDINGS</b>	Head: _____ Neck: _____ Face: _____ Lips: _____ Hands: _____
<b>INTRA-ORAL FINDINGS</b>	Palate and Oropharynx: _____ Airway: I II III IV Tongue and Floor of Mouth: _____ Buccal Mucosa: _____ Frena: _____ Gingivae and Periodontium: _____
<b>OCCLUSION REVIEW</b>	Facial Profile: _____ <b>Molar Relationship:</b> PRIMARY (Terminal Plane): R L PERMANENT: R L Straight <input type="checkbox"/> <input type="checkbox"/> Molar <input type="checkbox"/> <input type="checkbox"/> Mes. Step <input type="checkbox"/> <input type="checkbox"/> End to End <input type="checkbox"/> <input type="checkbox"/> Dist. Step <input type="checkbox"/> <input type="checkbox"/> Class _____ Primate Space <input type="checkbox"/> <input type="checkbox"/> Canine _____ Canine Relationship _____ <b>Incisor Relationship:</b> Overjet _____mm Overbite _____% Openbite _____mm <b>Arch Length: (General Impression)</b> Maxilla Mandible Adequate <input type="checkbox"/> Adequate <input type="checkbox"/> Inadequate <input type="checkbox"/> Inadequate <input type="checkbox"/> <b>Eruption Sequence &amp; Timing:</b> Normal <input type="checkbox"/> Describe <input type="checkbox"/> _____ _____ <b>Midline:</b> Normal <input type="checkbox"/> Deviated <input type="checkbox"/> Maxilla _____mm R <input type="checkbox"/> L <input type="checkbox"/> Mandible _____mm R <input type="checkbox"/> L <input type="checkbox"/> <b>Mandibular:</b> Shift R <input type="checkbox"/> L <input type="checkbox"/> Ant. <input type="checkbox"/> _____mm
	<b>TMJ and Function:</b> Opening Path: Normal <input type="checkbox"/> Deviated <input type="checkbox"/> Closing Path: Normal <input type="checkbox"/> Deviated <input type="checkbox"/> Opening: _____mm Normal <input type="checkbox"/> Limited <input type="checkbox"/> Muscle Tenderness: _____ Tongue Function: _____ Crossbite: _____ Oral Habits: _____ Analysis Recommended: YES <input type="checkbox"/> NO <input type="checkbox"/> Joint Sounds: None Left Right Opening <input type="checkbox"/> <input type="checkbox"/> <input type="checkbox"/> Closing <input type="checkbox"/> <input type="checkbox"/> <input type="checkbox"/> Crepitus <input type="checkbox"/> <input type="checkbox"/> <input type="checkbox"/> Supernumerary Teeth/ Congenitally Missing Teeth: _____ Ectopic Eruption: _____ Other Anomalies: _____

Fig. 1.2 Chart used to record the oral findings and the treatment proposed for the pediatric patient. (Printed with permission from Indiana University–University Pediatric Dentistry Associates.)

University Pediatric Dentistry Associates 702 Barnhill Drive RM #4205 • Indianapolis IN 46202-5200 • (317) 274-3865 • (317) 274-9653 Fax

**ORAL EXAM RECORD**

Patient Name: \_\_\_\_\_

Date of Birth: \_\_\_\_\_ ACT#: \_\_\_\_\_

**HARD TISSUE EXAMINATION**

		Clinical	Radiographic			Clinical	Radiographic
	1			16			
	2			15			
	3			14			
A	4			J	13		
B	5			I	12		
C	6			H	11		
D	7			G	10		
E	8			F	9		
P	25			O	24		
Q	26			N	23		
R	27			M	22		
S	28			L	21		
T	29			K	20		
	30				19		
	31				18		
	32				17		

Plaque Score: A B C D F

Prior Score: \_\_\_\_\_

Fluoride Status: \_\_\_\_\_

Brushing / Flossing: \_\_\_\_\_

Habits: \_\_\_\_\_

Periodontal: \_\_\_\_\_

Periodontal Screening & Recording: \_\_\_\_\_

**DIAGNOSTIC SUMMARY**

Behavior: \_\_\_\_\_

Eruption sequence: \_\_\_\_\_

Occlusion: \_\_\_\_\_

Caries: \_\_\_\_\_

Caries Risk Assessment:  Low  Moderate  High

Upper Right

**TREATMENT PROPOSED**

Upper Left

Lower Right

Lower Left

Treatment sequence, additional notations:

- 1.
- 2.
- 3.
- 4.
- 5.

Instructions given:

\_\_\_\_\_  
Assistant

\_\_\_\_\_  
Resident

\_\_\_\_\_  
Faculty Instructor

Fig. 1.2—Cont'd



The clinical examination, whether the first examination or a regular recall examination, should be all inclusive. The dentist can gather useful information while getting acquainted with a new patient. Attention to the patient's hair, head, face, neck, and hands should be among the first observations made by the dentist after the patient is seated in the chair.

The patient's hands may reveal information pertinent to a comprehensive diagnosis. The dentist may first detect an elevated temperature by holding the patient's hand. Cold, clammy hands or bitten fingernails may be the first indication of abnormal anxiety in the child. A callused or unusually clean digit suggests a persistent sucking habit. Clubbing of the fingers or a bluish color in the nail beds suggests congenital heart disease, which may require special precautions during dental treatment.

Inspection and palpation of the patient's head and neck are also indicated. Unusual characteristics of the hair or skin should be noted. The dentist may observe signs of problems such as head lice (Fig. 1.3), ringworm (Fig. 1.4), impetigo (Fig. 1.5A,B), herpes labialis, or pink eye during the examination. Proper referral is indicated immediately because these conditions are contagious. After the child's physician has supervised treatment to control the condition, the child's dental appointment may be rescheduled. If a contagious condition is identified, but the child also has a dental emergency, the dentist and the staff must take appropriate precautions to prevent spread of the disease to others while the emergency is alleviated. Further treatment should be postponed until the contagious condition is controlled.

Variations in the size, shape, symmetry, or function of the head and neck structures should be recorded. Abnormalities of these structures may indicate various syndromes or conditions associated with oral abnormalities.

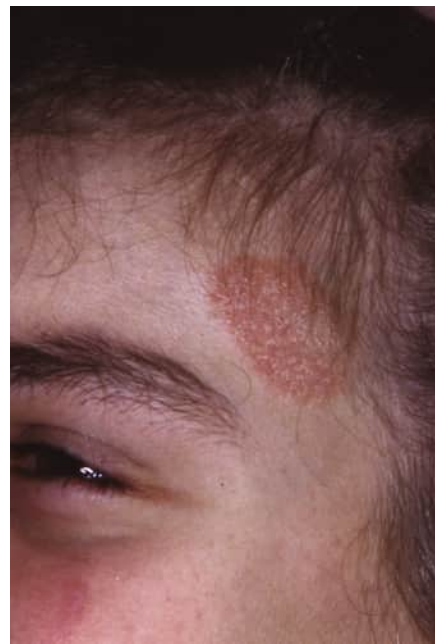## Temporomandibular Evaluation

A systematic review and meta-analysis published by da Silva et al.<sup>4</sup> assessed the prevalence of clinical signs of temporomandibular (TMJ) disorders in children and adolescents. One in six children and adolescents has clinical signs of disorders. Okeson<sup>5</sup> published a special report on TMJ disorders in children, indicating that although several studies included children aged 5–7 years, most observations have been made in young adolescents. Studies have placed the findings into the categories of symptoms or signs—those reported by the child or parents and those identified by the dentist during the examination. Prevalence of signs and symptoms increases with age and may occur in 30% of patients.

One should evaluate TMJ function by palpating the head of each mandibular condyle and by observing the patient while the mouth is closed (teeth clenched), at rest, and in various open positions (Fig. 1.6A–D). Movements of the condyles or jaw that do not flow smoothly or that deviate from the expected norm should be noted. Similarly, any crepitus that may be heard or identified by palpation as well as any other abnormal sounds should be noted. Sore masticatory muscles may also signal TMJ dysfunction. Such deviations from normal TMJ function may require further evaluation and treatment. There is a consensus



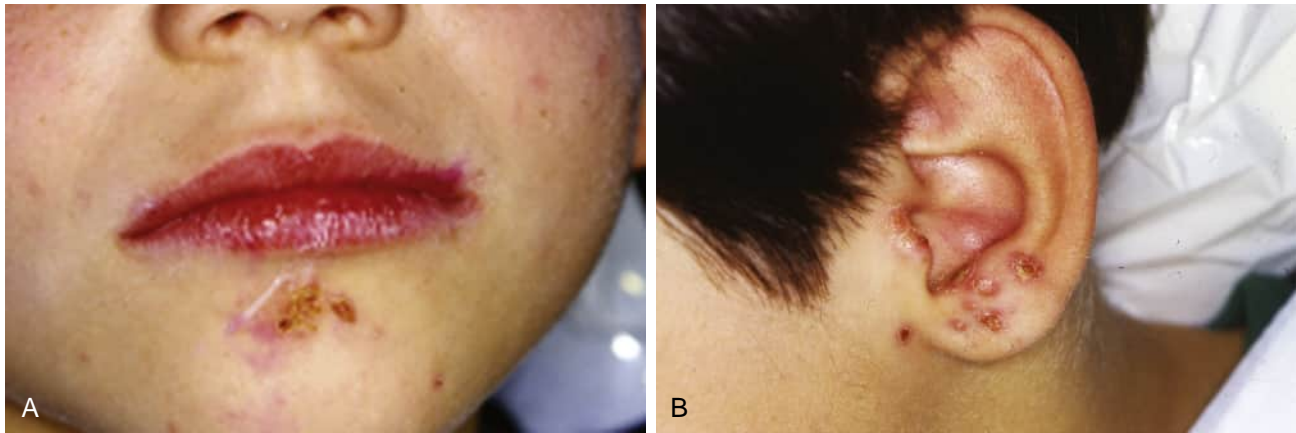
**Fig. 1.3** Evidence of head lice infestation. Usually the insects are not seen, but their eggs or nits cling to hair filaments until they hatch. (Courtesy Dr. Hala Henderson.)



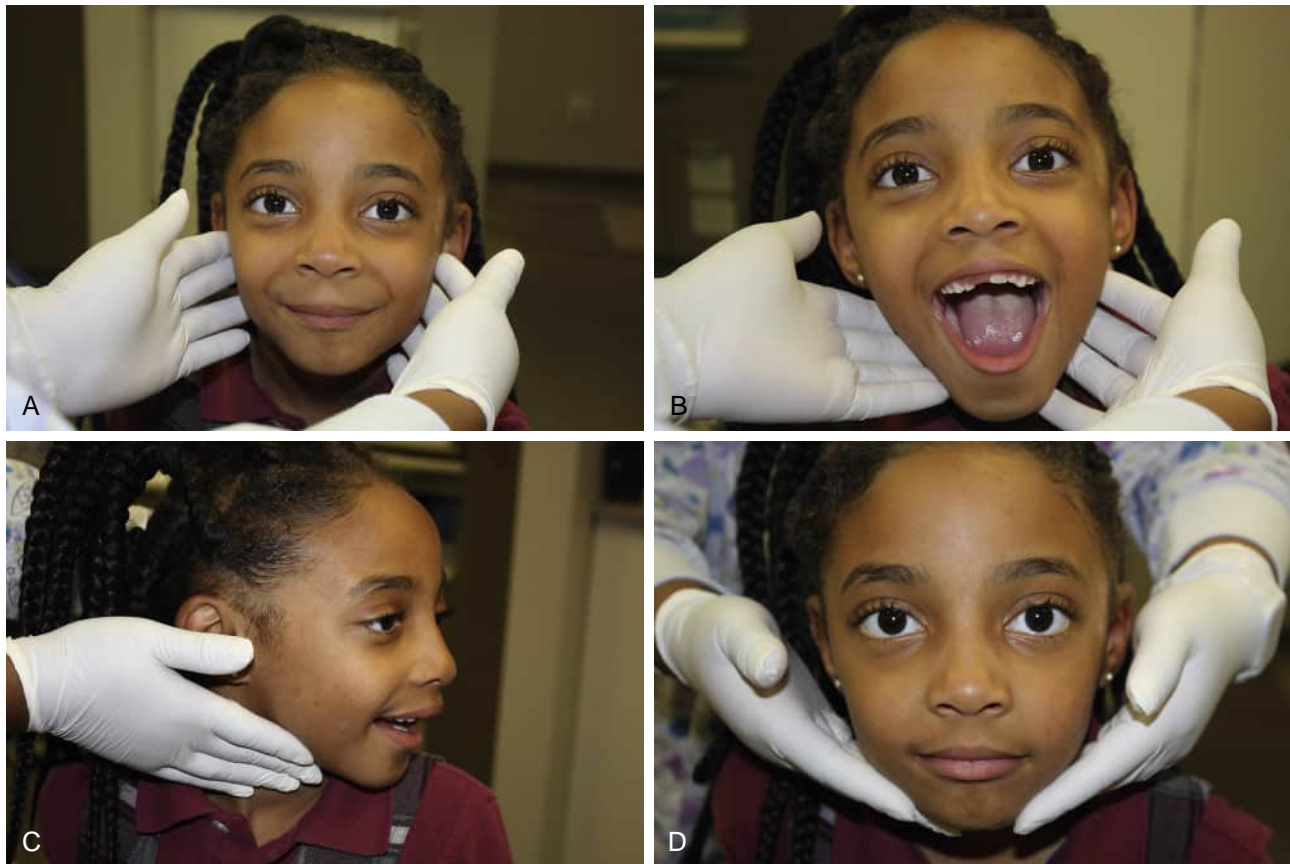**Fig. 1.4** Lesion on the forehead above the left eyebrow is caused by ringworm infection. Several fungal species may cause lesions on various areas of the body. The dentist may identify lesions on the head, face, or neck of a patient during a routine clinical examination. (Courtesy Dr. Hala Henderson.)

that temporomandibular disorders in children can be managed effectively by the following conservative and reversible therapies: patient education, mild physical therapy, behavioral therapy, medications, and occlusal splints.<sup>6</sup> Discussion of the diagnosis and treatment of complex TMJ disorders is available from many sources; we suggest Okeson's *Management of Temporomandibular Disorders and Occlusion* (2020).<sup>7</sup>

The extraoral examination continues with palpation of the patient's neck and submandibular area (Fig. 1.6C and D). Again, deviations from normal, such as unusual tenderness or enlargement, should be noted and follow-up tests performed or referrals made as indicated.



**Fig. 1.5** Characteristic lesions of impetigo on the (A) lower face and (B) left ear. These lesions occur on various skin surfaces, but the dentist is most likely to encounter them on upper body areas. The infections are of bacterial (usually streptococcal) origin and generally require antibiotic therapy for control. The child often spreads the infection by scratching the lesions. (Courtesy Dr. Hala Henderson.)



**Fig. 1.6** (A) and (B) Observation and palpation of the temporomandibular joint function. (C) and (D) Palpation of the neck and submandibular areas.

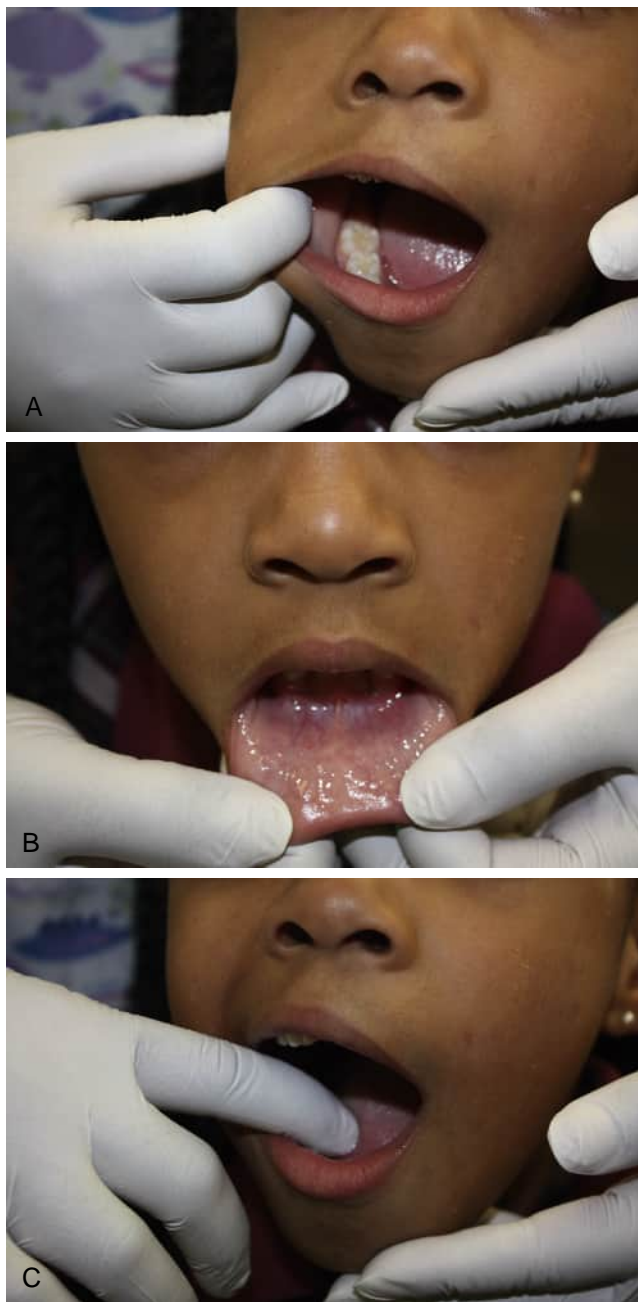
If the child is old enough to talk, speech should be evaluated. The positions of the tongue, lips, and perioral musculature during speech, while swallowing, and at rest may provide useful diagnostic information.

The intraoral examination of a pediatric patient should be comprehensive. There is a temptation to look first for obvious carious lesions. Although controlling carious lesions is important, the dentist should first evaluate the condition of the oral soft tissues and the status of

the developing occlusion. If the soft tissues and the occlusion are not observed early in the examination, the dentist may become so engrossed in charting carious lesions and in planning for their restoration that other important anomalies in the mouth are overlooked. Furthermore, any unusual breath odors and abnormal quantity or consistency of saliva should also be noted.

The buccal tissues, lips, floor of the mouth, palate, and gingivae should be carefully inspected and palpated (Fig. 1.7A–C).





**Fig. 1.7** Inspection and palpation of the (A) buccal tissues, (B) lips, and (C) floor of the mouth.

The use of the periodontal screening and recording program (PSR) is often a helpful adjunct when working with children. PSR is designed to facilitate early detection of periodontal diseases with a simplified probing technique and minimal documentation. Clerehugh and Tugnait<sup>8</sup> recommend initiation of periodontal screening in children following eruption of the permanent incisors and first molars. They suggest routine screening in these children at the child's first appointment and at regular recare appointments so that periodontal problems are detected early and treated appropriately. Immunodeficient children are especially vulnerable to early loss of bone support.

A more detailed periodontal evaluation is occasionally indicated, even in young children. Periodontal disorders of children are discussed further in [Chapter 15](#).

The tongue and oropharynx should be closely inspected. Enlarged tonsils accompanied by purulent exudate may be the initial sign of a streptococcal infection, which can lead to rheumatic fever. When streptococcal throat infection is suspected, immediate referral to the child's physician is indicated. In some cases, it may be helpful to the physician and convenient for the dentist to obtain a throat culture specimen while the child is still in the dental office, which contributes to an earlier definitive diagnosis of the infection. The diagnosis and treatment of soft tissue problems are discussed throughout this book (see [Chapters 5, 26, and 27](#).)

After thoroughly examining the oral soft tissues, the dentist should inspect the occlusion and note any dental or skeletal irregularities. The dentition and resulting occlusion may undergo considerable change during childhood and early adolescence. This dynamic developmental process occurs in all three planes of space, and with periodic evaluation the dentist can intercept and favorably influence undesirable changes. The patient's facial profile and symmetry; molar, canine, and anterior segment relationships; dental midlines; and relation of arch length to tooth mass should be routinely monitored in the clinical examination. More detailed evaluation and analysis are indicated when significant discrepancies are found during critical stages of growth and development. Diagnostic casts and cephalometric analyses may be indicated relatively early in the mixed-dentition stage and sometimes in the primary dentition. Detailed discussions of analyses of developing occlusions and interceptive treatment recommendations are presented in [Chapters 21, 22, and 23](#).

Finally, the teeth should be inspected carefully for evidence of carious lesions and hereditary or acquired anomalies. The teeth should also be counted and identified individually to ensure that supernumerary or missing teeth are recognized. Identification of carious lesions is important in patients of all ages, but it is especially critical in young patients because the lesions may progress rapidly in early childhood if not controlled. Eliminating the etiology of the caries activity, preventive management of the caries process, and restoration of cavitated lesions will prevent pain and the spread of infection and will contribute to the stability of the developing occlusion.

Since it is preferable for the dentist to perform the clinical examination of a new pediatric patient before the radiographic and prophylaxis procedures, it may be necessary to correlate radiographic findings or other initially questionable findings with the findings of a second brief oral examination. This is especially true when the new patient has poor oral hygiene. Detailed inspection and exploration of the teeth and soft tissues cannot be performed adequately until the mouth is free of extraneous debris.

During the clinical examination for carious lesions, each tooth should be dried individually and inspected under a good light. A definite routine for the examination should be established. For example, a dentist may always start in the upper right quadrant, work around the maxillary arch, move down to the lower left quadrant, and end the examination in the lower right quadrant. Morphologic defects and incomplete coalescence of enamel at the bases of pits and fissures in molar teeth can often be detected readily by visual and explorer examination after the teeth have been cleaned and dried. The decision whether to place a sealant



or to restore a defect depends on the patient's history of dental caries, the parents' or patient's acceptance of a comprehensive preventive dentistry program (including dietary and oral hygiene control), and the patient's dependability in returning for recare appointments.

In patients with severe dental caries, caries activity tests and diet analysis may contribute to the diagnostic process by helping define specific etiologic factors. These procedures probably have an even greater value in helping the patient and/or parents understand the dental caries disease process and in motivating them to make the behavioral changes needed to control the disease. The information provided to them should include instructions in plaque control and the appropriate recommendations for fluoride exposure. Dental caries susceptibility, caries disease process, caries activity tests, diet analysis, and caries control are discussed in [Chapter 10](#). Plaque control procedures and instructions are detailed in [Chapter 8](#).

The dentist's comprehensive diagnosis depends on the completion of numerous procedures but requires a thorough, systematic, and critical clinical examination. Any deviation from the expected or desired size, shape, color, and consistency of soft or hard tissues should be described in detail. The severity of associated problems and their causes must be clearly identified to the patient or parents before a comprehensive oral health care program can be expected to succeed.

During the initial examination and at subsequent appointments, the dentist and auxiliary staff members should be alert to signs and symptoms of child abuse and neglect. These problems are increasing in prevalence, and the dentist can play an important role in detecting their signs and symptoms; this subject is thoroughly covered in [Chapter 7](#).

## Uniform Dental Recording

Many different tooth-charting systems are currently in use, including the universal system illustrated in the hard tissue examination section of [Fig. 1.2A and B](#). This system of marking permanent teeth uses the numbers 1 to 32, beginning with the upper right third molar (No. 1) and progressing around the arch to the upper left third molar (No. 16), down to the lower left third molar (No. 17), and around the arch to the lower right third molar (No. 32). The primary teeth are identified in the universal system by the first 20 letters of the alphabets, A through T. In case of a supernumerary tooth, in the permanent dentition the number 50 is added to the tooth number that is closest to the supernumerary tooth. In the primary dentition, the letter "S" is added to the tooth number that is the closest to the supernumerary tooth.<sup>9</sup>

The *Fédération Dentaire Internationale's* Special Committee on Uniform Dental Recording has specified the following basic requirements for a tooth-charting system:

1. Simple to understand and teach
2. Easy to pronounce in conversation and dictation
3. Easily communicable in writing and electronic format
4. Easy to translate into computer input
5. Easily adaptable to standard charts used in general practice

The committee found that only one system, the two-digit system, seems to comply with these requirements. According to this system, the first digit indicates the quadrant and the second digit the type of tooth within the quadrant. Quadrants are allotted the digits 1 to 4 for the permanent teeth and 5 to 8 for the primary teeth in a clockwise sequence, starting at the upper right side; teeth within the same quadrant are allotted the digits 1 to 8 (primary teeth, 1 to 5) from the midline backward. The digits should be pronounced separately; thus, the permanent canines are teeth one-three, two-three, three-three, and four-three.

In the "Treatment Proposed" section of the oral examination record ([Fig. 1.2B](#)), the individual teeth that require restorative procedures, endodontic therapy, or extraction are listed. Gingival areas requiring follow-up therapy are also noted. A checkmark can be placed beside each listed tooth and procedure as the treatment is completed. Additional notations concerning treatment procedures completed and the date are recorded on supplemental treatment record pages.

## Radiographic Examination

When indicated, radiographic examination for children must be completed before a comprehensive oral health care plan can be developed (but after the detail clinical examination), and subsequent radiographs are required periodically to enable detection of incipient carious lesions or other developing anomalies.

A child should be exposed to dental ionizing radiation only after the dentist has determined that radiography is necessary to make an adequate diagnosis for the individual child at the time of the appointment.

Obtaining isolated occlusal, periapical, or bitewing films is sometimes indicated in very young children (even infants) because of trauma, toothache, suspected developmental disturbances, or proximal caries. It should be remembered that carious lesions appear smaller on radiographs than they actually are.

As early as 1967, Blayney and Hill<sup>10</sup> recognized the importance of diagnosing incipient proximal carious lesions with the appropriate use of radiographs. If the pediatric patient can be motivated to adopt a routine of good oral hygiene supported by competent supervision, many of these initial lesions can be arrested. The dentist must be aware of other non-ionizing radiation techniques available for the detection of interproximal caries. Each technique (e.g., transillumination) comes with clear indications. The interpretation of the non-ionizing radiation techniques must be done carefully by the dentist.

Radiographic techniques for the pediatric patient are described in detail in [Chapter 2](#).

## Early Examination

Historically, dental care for children has been designed primarily to prevent oral pain and infection, occurrence and progression of dental caries, premature loss of primary teeth, loss of arch length, and development of an association

between fear and dental care. The dentist is responsible for guiding the child and parents, resolving oral disorders before they can affect health and dental alignment, and preventing an oral disease. The goals of pediatric dental care are, thus, primarily preventive. The dentist's opportunity to conduct an initial oral examination and parental consultation during the patient's infancy is a key element in achieving and maintaining these goals.

Some dentists, especially pediatric dentists, like to counsel expectant parents before their child is born. They consider it appropriate to discuss with expectant mothers the importance of good nutrition during pregnancy and practices that can influence the expected child's general and dental health.

It is also appropriate to inquire about medication that the expectant mother is taking. For example, prolonged ingestion of tetracyclines may result in discolored, pigmented, and even hypoplastic primary teeth.

The expectant mother should be encouraged to visit her dentist and to have all carious lesions restored. The presence of active dental caries and accompanying high levels of *Streptococcus mutans* can lead to transmission by the mother to the infant and may be responsible for the development of carious lesions at a very early age.

It is not intended that the pediatric dentist usurp the responsibility of the expectant mother's physician in recommending dietary practices; rather, the dentist should reinforce good nutritional recommendations provided by medical colleagues.

## Infant Dental Care

The infant oral health care visit should be seen as the foundation on which a lifetime of preventive education and dental care can be built to help ensure optimal oral health into childhood. Oral examination, anticipatory guidance including preventive education, and appropriate therapeutic intervention for the infant can enhance the opportunity for a lifetime of freedom from preventable oral disease. The 2018 American Academy of Pediatric Dentistry guidelines on Perinatal and Infant Oral Health Care<sup>1</sup> included the following recommendations:

1. All primary health care professionals who serve mothers and infants should provide parent/caregiver education on the etiology and prevention of early childhood caries (ECC).
2. The infectious and transmissible nature of bacteria that cause ECC and methods of oral health risk assessment (e.g., caries risk assessment tool), anticipatory guidance, and early intervention should be included in the curriculum of all medical, nursing, and allied health professional programs.
3. Every infant should receive an oral health risk assessment from his or her primary health care provider or qualified health care professional by 6 months of age.
4. Parents or caregivers should establish a dental home for infants by 12 months of age.
5. Health care professionals and all stakeholders in children's health should support the identification of a dental home for all infants at 12 months of age.

Thus it is appropriate for a dentist to perform an oral examination for an infant of any age, even a newborn, and an examination is recommended anytime the parent or physician calls with questions concerning the appearance of an infant's oral tissues. Even when there are no known problems, the child's first dental visit and oral examination should take place by at least 1 year of age. This early dental visit enables the dentist and parents to discuss ways to nurture excellent oral health before any serious problems have had an opportunity to develop. An adequate oral examination for an infant is generally simple and brief, but it may be the important first step toward a lifetime of excellent oral health.

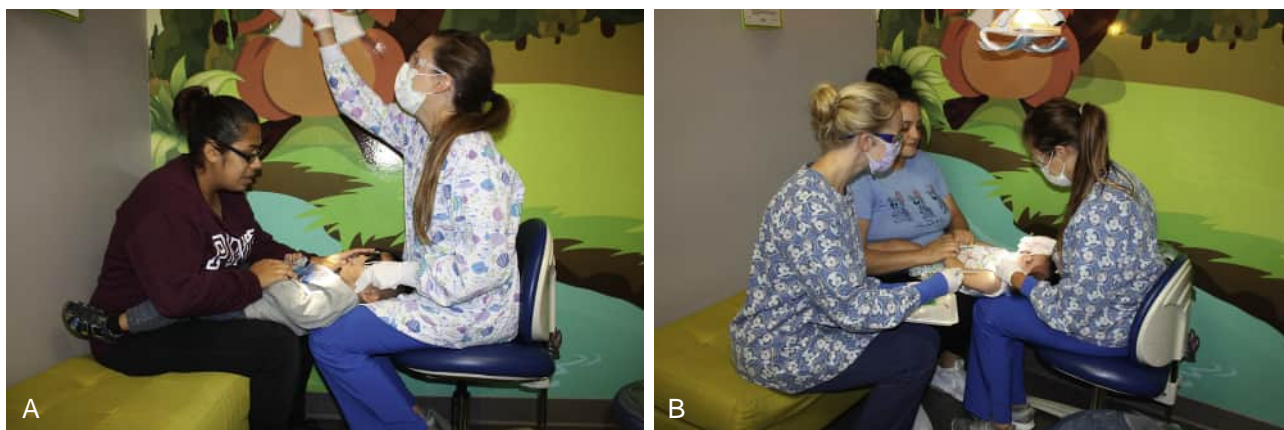
Some dentists may prefer to "preside" during the entire first session with the infant and parents. Others may wish to delegate some of the educational aspects of the session to auxiliary members of the office staff and then conduct the examination and answer any unresolved questions. In either case, it is sometimes necessary to have an assistant available to help hold the child's attention so that the parents can concentrate on the important information being provided.

It is not always necessary to conduct the infant oral examination in the dental operator, but it should take place where there is adequate light for a visual examination. The dentist may find it convenient to conduct the examination in the private consultation room during the initial meeting with the child and parents. The examination procedures may include only direct observation and digital palpation. However, if primary molars have erupted or if hand instruments may be needed, the examination should be performed in an area where instrument transfers between the dental assistant and the dentist can proceed smoothly.

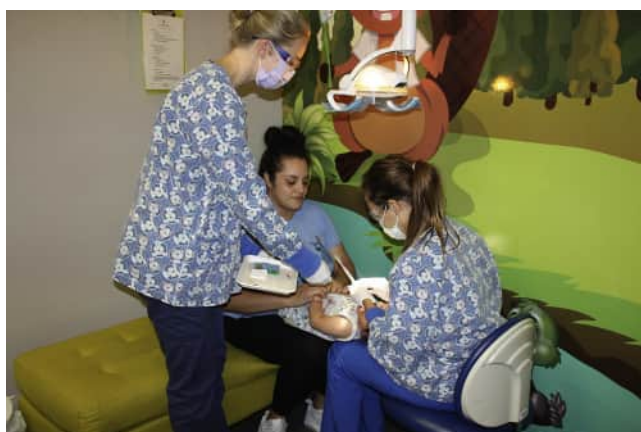The parents should be informed before the examination that it will be necessary to restrain the child gently and that it is normal for the child to cry during the procedure. The infant is held on the lap of a parent, usually the mother. This direct involvement of the parent provides emotional support to the child and allows the parent to help restrain the child. Both parents may participate or at least be present during the examination.

The dentist should make a brief attempt to get acquainted with the infant and to project warmth and caring. However, many infants and toddlers are not particularly interested in developing new friendships with strangers, and the dentist should not be discouraged if the infant shuns the friendly approach. Even if the child chooses to resist (which is common and normal), only negligible extra effort is necessary to perform the examination procedure. The dentist should not be flustered by the crying and resistant behavior and should proceed unhurriedly but efficiently with the examination. The dentist's voice should remain unstrained and pleasant during the examination. The dentist's behavior should reassure the child and alleviate the parents' anxiety concerning this first dental procedure.

One method of performing the examination in a private consultation area is illustrated in Fig. 1.8A. The dentist and the parent are seated face to face with their knees touching. Their upper legs form the "examination table" for the child. The child's legs straddle the parent's body, which allows the parent to restrain the child's legs and hands (Video 1.1). An assistant is present to record the



**Fig. 1.8** (A) One method of positioning a child for an oral examination in a small, private consultation area. The dental assistant is nearby to record findings. (B) If space allows three people to sit in a row, this method may make it easier for the dental assistant to hear the findings dictated by the dentist. The dental assistant also helps restrain the child's legs.



**Fig. 1.9** Oral examination for a very young child in the dental operator.

**Video 1.1** Oral Examination for Preschooler: knee-to-knee technique for an oral exam of a preschool aged child.

dentist's examination findings as they are dictated and to help restrain the child if needed. If adequate space is available in the consultation area, the approach illustrated in Fig. 1.8B may be useful. The dental assistant is seated at a desk or writing stand near the child's feet. The dental assistant and the parent are facing the same direction, side by side and at a right angle to the direction that the dentist is facing. The dental assistant is in a good position to hear and record the dentist's findings as they are dictated, even if the child is crying loudly. These positions (Fig. 1.8A and B) are also convenient for demonstrating oral hygiene procedures to the parents.

The positions of the dentist, parent, child, and dental assistant during the examination at the dental chair are illustrated in Fig. 1.9. The dental assistant is standing to permit good visibility and to better anticipate the dentist's needs. The assistant is also in a good position to hear and record the dentist's findings. The parent and the dental assistant restrain the child's arms and legs. The child's head is positioned in the bend of the parent's arm. The dentist establishes a chairside position so that not only the dentist's

hands but also the lower arms and abdomen may be available for supporting the child's head, if necessary.

The infant oral examination may often be performed by careful direct observation and digital palpation. The dentist may need only good lighting for visibility and gauze for drying or debriding tissues. Sometimes a tongue depressor and a soft-bristled toothbrush are useful. At other times, as previously mentioned, the dentist will want the complete operatory available. The examination should begin with a systematic and gentle digital exploration of the soft tissues without any instruments. The child may find this gentle palpation soothing, especially when alveolar ridges in teething areas are massaged. The digital examination may help relax the child and encourage less resistance. If hand instruments are needed, the dentist must be sure to have a stable finger rest before inserting an instrument into the child's mouth.

Although there is little effective communication between the dentist and patient, the child realizes at the conclusion of the examination that nothing "bad" happened and that the procedure was permitted by the parents, who were present and actually helped with the examination. The child will not hold a lasting grudge against anyone, and the experience will not have a detrimental effect on the child's future behavior as a dental patient. On the contrary, our experiences suggest that such early examinations followed by regular recall examinations often contribute to youngsters becoming excellent dental patients without fear at very young ages. These children's chances for enjoying excellent oral health throughout life are thus enhanced.

## Detection of Substance Abuse

It is within the scope of pediatric dentistry to be concerned with life-threatening habits and illnesses, such as alcoholism and drug addiction, which may occur in the older child.

Gigena et al.<sup>11</sup> and Marshall and Werb<sup>12</sup> have reported that abusers in the teen years and younger are as common as adult addicts. Drug abuse problems interact directly with the dental care of a patient. Oral health in teens who use drugs is statistically different and worse than that in teens who are not drug abusers. Obtaining and maintaining a



satisfactory history is important. The office health questionnaire, as presented in this chapter, must be worded to enable the patient or parent to give some indication of a drug problem. It is often difficult to detect addiction from casual observation. Therefore, input from the patient giving an indication of addiction is needed. At subsequent visits, the dentist must also consider changes in the general health history as well as answers to specific questions.

It is also important to know if the patient is taking drugs at the time of the dental visit because there could be an interaction with drugs, such as nitrous oxide, administered at the dental office. If the patient is under the influence of an abused substance, dental treatment should be postponed until a time when the patient is not “high.”

Symptoms of substance abuse may include depression, feelings of inadequacy, frustration, helplessness, immaturity, self-alienation, poor object relations, and major deficiencies in ego structure and functioning. Heavy drug users tend to have poor impulse control and frequently neglect hygiene in general and oral hygiene specifically. In addition, because a patient is taking drugs that affect normal thought processes, the pain from untreated dental conditions may be masked. This combination of factors results in a patient with very little dental interest who is practicing unsatisfactory prevention, leading to increased oral disease.

Identification of substance abusers is difficult, even for an experienced observer. There are specific clues, however. Abrupt changes in behavior are common, as are signs of depression and moodiness. Interest in the opposite sex often decreases. Without any apparent consumption of alcohol, a drug-addicted person can appear intoxicated. There may be a desperate need for money, as well as loss of weight and appetite. The presence of scars along the veins could indicate drug injection. Addicts frequently wear long-sleeved shirts, regardless of the weather, in an effort to cover identifying scars.

Fletcher et al.<sup>13</sup> state that the use of illegal drugs and volatile substances is common among young people in developed countries, such as the United States and the United Kingdom. In addition to presenting direct health risks, drug use is associated with accidental injury; self-harm; suicide; and other “problem” behaviors, such as alcohol misuse, unprotected sex, and antisocial behavior. Drug use at an early age is also associated with future use of particularly harmful drugs, such as heroin or cocaine. In turn, dependence on these drugs is associated with high rates of morbidity and mortality, social disadvantage, and crime. It is because of these health and social problems that reducing teenage drug use is a priority.

Their review of the literature, however, suggests that positive ethos and overall levels of strong school relationships and engagement are associated with lower rates of drug use, and that at the individual level, negative behaviors and attitudes relating to school are also associated with drug use.

MacDonald<sup>14</sup> reports that experimentation is a normal adolescent learning tool, but when combined with normal adolescent curiosity and fearlessness, it may be dangerous. Tobacco smoking is an example of a common teenage experiment. In a study by the National Survey on Drug Use and Health, 12% of adolescents of 12 to 17 years of age had smoked one or more cigarettes in the preceding month; and

of those who had never smoked, more than 22% were considered susceptible to start smoking.<sup>15</sup>

## ETIOLOGIC FACTORS IN SUBSTANCE ABUSE

Drug abuse in young people can be traced to many causes, the most important of which is considered to be rebellion against parents and society. Other factors may include a need to forget the pressures of daily living, a desire for pleasure, and a need to conform to a group with which the young people want to be associated.<sup>16</sup> Through drugs, young people obtain a momentary feeling of independence and power because they have disobeyed the rules of their parents and society. The satisfaction gained through rebelling against parents can give adolescents a reinforcing motive for persisting in drug abuse.

Children of wealthy parents are increasingly recognized as a high-risk group for the development of traits such as narcissism, poor impulse control, poor tolerance of frustration, depression, and poor coping ability. Therefore, it is not surprising that a large number of children within this group use drugs to cope with frustrations, boredom, anxiety, and depression.

In general, compared with youngsters who do not use drugs, drug users have been found to be less interested in formal education, less involved in organized activities such as athletics, and less likely to have well-defined goals. Adolescents who use drugs heavily have been described as manifesting more psychological problems than do nonusers. Significantly higher percentages of nonusers of drugs reported close relationships with their parents. Children involved in abusing drugs are more often found to have experienced the loss of a parent or to have parents who are divorced.

## SPECIFIC SUBSTANCES AND FREQUENCY OF USE

Since 1975, the University of Michigan’s Institute for Social Research, funded by the National Institute of Drug Abuse, has collected data on past month, past year, and lifetime drug use among 12th graders. It was expanded in 1991 to include 8th and 10th graders. The most recent report (<http://www.monitoringthefuture.org//pubs/monograph/s/mtf-overview2018.pdf>) says that in the early 21st century, young Americans reached extraordinarily high levels of illicit drug use. In 1975, majority of young people (55%) had used an illicit drug by the time they left high school. This rose to 66% in 1981, but declined to 41% by 1992—the low point. After 1992, in what the report calls the “relapse phase” of the epidemic, the proportion rose considerably to 55% in 1999 and gradually declined to 47% in 2009 before rising slightly to 50% by 2013 and keeping similar levels by 2018.

## VAPING AND ELECTRONIC CIGARETTES

Vaping, also known as JUULing, means using an electronic cigarette (e-cigarette) or another vaping device. Vaping is a relatively new trend with a dramatic increase in use by adolescents in the last 10 years. Liquid nicotine is involved in most vaping and is a highly addictive substance. The liquid comes in flavors, such as mint, fruit, and bubble gum,

which appeal to adolescents. The use of nicotine is associated with learning and attention difficulties in adolescents, and can lead to addiction. Furthermore, some sweet flavors may increase the risk for dental caries. In a study, Kim et al.<sup>17</sup> evaluated that the sugary, gelatinous aerosols in the flavors interact with the enamel, thereby changing the surface characteristics and increasing the risk for demineralization and subsequent development of caries.

Suppose the dentist identifies a person who needs help. What can be done? Unless the dentist is exceptionally qualified to handle addiction problems, the answer is direct or indirect referral to a treatment center. If the person expresses a need, the dentist may directly inform that person or the parents about area agencies that provide assistance. However, addicts may react defensively, even with hostility, if a direct approach is used. As with any problem related to general or dental health, preventive efforts must begin with the young. Children at a very young age need to be helped to develop a positive self-image, a sense of self-worth, and a separate identity.

## Suicidal Tendencies in Children and Adolescents

During the examination of the child, the pediatric dentist should be alert to signs and symptoms of suicidal tendencies. How prevalent is suicide in the young child and adolescent? According to the American Academy of Child and Adolescent Psychiatry (<http://www.aacap.org>), thousands of teenagers commit suicide each year. It is the sixth leading cause of death in 5- to 14-year-olds and the third leading cause in 15- to 24-year-olds. Suicidal tendencies follow a pattern and background that can be observed by the astute professional or parent. The following excerpt is from the

*American Academy of Child and Adolescent Psychiatry*<sup>18</sup>:  
*Teenagers experience strong feelings of stress, confusion, self-doubt, pressure to succeed, financial uncertainty, and other fears while growing up. For some teenagers, divorce, the formation of a new family with step-parents and step-siblings, or moving to a new community can be unsettling and can intensify self-doubts. For some teens, suicide may appear to be a solution to their problems and stress.*

Depression and suicidal feelings are treatable mental disorders. The child or adolescent needs to have his or her illness recognized and diagnosed, and appropriate treatment plans developed. When parents are in doubt as to whether their child has a serious problem, a psychiatric examination can be helpful. Many of the signs and symptoms of suicidal feelings are similar to those of depression.

Parents should be aware of the following signs from adolescents who may attempt suicide:

- Changes in eating and sleeping habits
- Withdrawal from friends, family, and regular activities
- Violent actions, rebellious behavior, or running away
- Drug and alcohol use
- Unusual neglect of personal appearance
- Marked personality change
- Persistent boredom, difficulty concentrating, or a decline in the quality of schoolwork

- Frequent complaints about physical symptoms, often related to emotions, such as stomach aches, headaches, or fatigue
- Loss of interest in pleasurable activities
- Not tolerating praise or rewards

A teenager who is planning to commit suicide may also exhibit the following signs:

- Complain of being a bad person or “feeling rotten” inside
- Give verbal hints with statements such as, “I won’t be a problem for you much longer,” “Nothing matters,” “It’s no use,” and “I won’t see you again”
- Put his or her affairs in order; for example, give away favorite possessions, clean his or her room, or throw away important belongings
- Become suddenly cheerful after a period of depression
- Have signs of psychosis (hallucinations or bizarre thoughts)

Children who say they want to kill themselves should not be ignored, and further expressions of concern and discussion with the child are important. Moreover, assistance from a mental health professional should be actively sought. With appropriate counseling and family support, intervention can be successful.

It should be recognized that the pediatric dentist and the orthodontist are in a unique position to recognize early warning signs of adolescent suicide. Loochtan and Cole<sup>19</sup> surveyed 1000 practicing orthodontists and 54 department chairs of postdoctoral programs. Of those surveyed, 50% had at least one patient who had attempted suicide and 25% had at least one young patient who actually did commit suicide.

## Infection Control in the Dental Office

The dental team is exposed to a wide variety of microorganisms in the saliva and blood of their patients. These may include hepatitis B and C, herpes viruses, cytomegalovirus, measles virus, mumps virus, chickenpox virus, human immunodeficiency virus, *Mycobacterium tuberculosis*, streptococci, staphylococci, and other non-vaccine-preventable infections. Because it is impossible to identify all of those patients who may harbor dangerous microorganisms, it is necessary to use standard precautions and practice infection control procedures routinely to avoid spread of disease. The following infection control procedures as described by Miller and Palenik<sup>20</sup> and Miller<sup>21</sup> are based on those recommended for dentistry by the Centers for Disease Control and Prevention in the Public Health Service of the U.S. Department of Health and Human Services:<sup>22</sup>

- Always obtain (and update) a thorough medical history (as discussed previously in this chapter) and include questions about medications, current illnesses, hepatitis, unintentional weight loss, lymphadenopathy, oral soft tissue lesions, or other infections.
- Clean all reusable instruments in an ultrasonic cleaner or washer/disinfector, and minimize the amount of hand scrubbing. Wear heavy rubber gloves, mask, and

protective clothing and eyewear to protect against puncture injuries and splashing.

- Sterilize all reusable instruments that penetrate or come into contact with oral tissues or that become contaminated with saliva or blood. Metal or heat-stable instruments should be sterilized in a steam autoclave, a dry heat oven, or an unsaturated chemical vapor sterilizer. Heat-sensitive items may require up to 10 hours of exposure time for sterilization in a liquid chemical agent approved by the U.S. Food and Drug Administration as a disinfectant/sterilant, followed by rinsing with sterile water. High-level disinfection may be accomplished by submersion in the disinfectant/sterilant chemical for the exposure time recommended on the product label, followed by rinsing with water.
- Monitoring of sterilization procedures should include a combination of process parameters, including mechanical, chemical, and biological. These parameters evaluate both the sterilizing conditions and the procedure's effectiveness. Biological monitoring must occur weekly.
- Dental instruments must be wrapped before sterilization. Unwrapped instruments have no shelf life and must be used immediately after being processed.
- Personal protective equipment (gloves, masks, protective eyewear, and clinical attire) should be worn when treating patients.
- Contamination of clinical contact surfaces with patient materials can occur by direct spray or spatter generated either during dental procedures or by contact with gloved hands. Barrier protection of surfaces and equipment can prevent contamination of clinical contact surfaces, but is particularly effective for those that are difficult to clean. Barriers include clear plastic wrap, bags, sheets, tubing, and plastic-backed paper or other materials impervious to moisture. If barriers are not used, cleaning and disinfection of surfaces between patients should involve use of an EPA-registered hospital disinfectant with a tuberculocidal claim (i.e., intermediate-level disinfectant).
- Hand hygiene (e.g., handwashing, hand antisepsis, or surgical hand antisepsis) substantially reduces potential pathogens on the hands. Evidence indicates that proper hand hygiene is the single most critical measure for reducing the risk of the transmission of organisms. For routine dental examinations and nonsurgical procedures, handwashing and hand antisepsis is achieved by using plain or antimicrobial soap and water. If the hands are not visibly soiled, an alcohol-based hand rub is adequate.
- Regulated medical waste is only a limited subset of waste, constituting 9% to 15% of total waste in hospitals and 1% to 2% of total waste in dental offices. Regulated medical waste requires special storage, handling, neutralization, and disposal and is covered by federal, state, and local rules and regulations. Examples of regulated waste found in dental practice settings are solid waste materials soaked or saturated with blood or saliva (e.g., gauze saturated with blood after surgery), extracted teeth, surgically removed hard and soft tissues, and contaminated sharp items (e.g., needles, scalpel blades, and wires).
- Dental prostheses, appliances, and items used in their fabrication (e.g., impressions, occlusal rims, and bite registrations) are potential sources for cross-contamination and require handling in a manner that prevents exposure of both practitioners and patients.

## BIOFILM

The goal of infection control in dentistry is to reduce or eliminate exposure of patients and dental team members to microorganisms. Potential pathogens can usually come from patients and practitioners. Another source, however, could be from the environment, such as via air or water.

Dental unit water lines contain relatively small amounts of water, much of which is in continuous contact with the inner surfaces of the tubing. The water is not in constant motion, with extended dormant periods. Movement of water varies, with greatest flow being in the middle of the tubing. Dental unit water lines readily become colonized by a variety of microorganisms, including bacteria, viruses, and protozoa. Water entering dental units usually contains few microorganisms. However, water coming out of the unit is often highly contaminated. Proliferation of microorganisms occurs within biofilms that adhere to internal surfaces of dental unit water lines.

Current guidelines<sup>22</sup> for proper treatment of dental unit water lines include the following:

1. Dental unit water lines should contain <500 colony-forming units per mL (CFU/mL).
2. For surgical procedures, use sterile or saline water from a single-use source.
3. Start each day by purging all lines by flushing thoroughly with water.
4. Purge all air and water from high-speed handpieces for 20–30 seconds after each patient.
5. Consider separate reservoirs, chemical treatment protocols, and sterile water delivery systems.
6. Use antiretraction valves and terminal flush devices into the dental unit.
7. Drain the water lines at the end of the day.
8. Disinfect dental units attached to hospital main water supplies every 4 months with 500 ppm chlorinated water.

## Emergency Dental Treatment

A patient's initial dental appointment is often prompted by an emergency situation. The diagnostic procedures necessary for an emergency dental appointment were outlined in this chapter previously, but the emergency appointment tends to focus on and resolve a single problem or a single set of related problems rather than provide a comprehensive oral diagnosis and management plan. Once the emergency problem is under control, the dentist should offer comprehensive services to the patient or parents.

The remainder of this book presents information for dentists and dental students to augment their diagnostic and management skills in providing oral health care services to children and adolescents during both emergency and preplanned dental visits.

## References

1. Guideline on periodicity of examination, preventive dental services, anticipatory guidance/counseling, and oral treatment for infants, children, and adolescents. In *Reference manual*. Chicago, IL, 2018. American Academy of Pediatric Dentistry, pp 194–203.
2. Glick M: *Burket's oral medicine*, ed 12, xv. Shelton, Connecticut, 2015. People's Medical Publishing House USA, p 716.
3. Fuhrer III CT, Weddell JA, Sanders BJ, Jones JE, Dean JA, Tomlin A: Effect on behavior of dental treatment rendered under conscious



- sedation and general anesthesia in pediatric patients, *Pediatr Dent* 31(7):492–497, 2009.
4. da Silva CG, Pachêco-Pereira C, Porporatti AL, et al.: Prevalence of clinical signs of intra-articular temporomandibular disorders in children and adolescents: a systematic review and meta-analysis. *J Am Dent Assoc* 147(1):10–18.e8, 2016.
  5. Okeson JP: Temporomandibular disorders in children, *Pediatr Dent* 11(4):325–329, 1989.
  6. Guideline on acquired temporomandibular disorders in infants, children, and adolescents. In *Reference manual*, Chicago, IL, 2018, American Academy of Pediatric Dentistry, pp 366–372.
  7. Okeson JP: *Management of temporomandibular disorders and occlusion*, ed 8, St. Louis, 2020, Elsevier.
  8. Clerehugh V, Tugnait A: Periodontal diseases in children and adolescents: I. Aetiology and diagnosis, *Dent Update* 28(5):222–230, 2001, 232.
  9. American Dental Association: *CDT 2020: dental procedures codes*, Chicago, IL, 2019, American Dental Association.
  10. Blayney JR, Hill IN: Fluorine and dental caries, *J Am Dent Assoc* 74(2):225–302, 1967.
  11. Gigena PC, Cornejo LS, Lescano-de-Ferrer A: Oral health in drug addict adolescents and non psychoactive substance users, *Acta Odontol Latinoam* 28(1):48–57, 2015.
  12. Marshall BD, Werb D: Health outcomes associated with methamphetamine use among young people: a systematic review, *Addiction* 105(6):991–1002, 2010.
  13. Fletcher A, Bonell C, Hargreaves J: School effects on young people's drug use: a systematic review of intervention and observational studies, *J Adolesc Health* 42(3):209–220, 2008.
  14. Macdonald DI: Drugs, drinking, and adolescence, *Am J Dis Child* 138(2):117–125, 1984.
  15. Groerer J, Caraballo R: Report on racial and ethnic differences among youths in cigarette smoking and susceptibility to start smoking—United States, 2002–2004, *MMWR* 55:1275–1277, 2006.
  16. Gopiram P, Kishore MT: Psychosocial attributes of substance abuse among adolescents and young adults: a comparative study of users and non-users, *Indian J Psychol Med* 36(1):58–61, 2014.
  17. Kim SA, Smith S, Beauchamp C, et al.: Cariogenic potential of sweet flavors in electronic-cigarette liquids, *PLoS One* 13(9):e0203717, 2018.
  18. American Academy of Child and Adolescent Psychiatry: AACAP official action. Summary of the practice parameters for the assessment and treatment of children and adolescents with schizophrenia. American Academy of Child and Adolescent Psychiatry, *J Am Acad Child Adolesc Psychiatry* 39(12):1580–1582, 2019. Available at: <https://www.ncbi.nlm.nih.gov/pubmed/11128338>.
  19. Loochtan RM, Cole RM: Adolescent suicide in orthodontics: results of a survey, *Am J Orthod Dentofacial Orthop* 100(2):180–187, 1991.
  20. Miller CH, Palenik CJ: *Infection control and management of hazardous materials for the dental team*, ed 3, xi. St. Louis, MO, 2005, Elsevier Mosby, p 515.
  21. Miller CH: *Infection control and management of hazardous materials for the dental team*, ed 6, xiii. St. Louis, Missouri, 2018, Elsevier, p 320.
  22. Centers for Disease Control and Prevention: *Summary of infection prevention practices in dental settings: basic expectations for safe care*, Atlanta, GA, October 2016, Centers for Disease Control and Prevention, US Dept of Health and Human Services. Available at: <https://www.cdc.gov/oralhealth/infectioncontrol/pdf/safe-care2.pdf>.



## 2

# Radiographic Techniques

JUAN F. YEPES

**CHAPTER OUTLINE****Radiation Safety and Protection**

Basics of Radiation Protection  
Protection of the Dental Staff  
Protection of the Patient

**Radiographic Image Receptors**

Analog Film  
Digital Film  
Image Viewing Conditions

**Radiographic Techniques**

Intraoral Radiography

**Extraoral Radiography****Selection Criteria and Radiographic Examinations**

Criteria for Exposing Children to Ionizing Radiation

Radiographic Exposures in Cases of Dentoalveolar Trauma

Radiographic Exposures in Patients with Special Needs

**Interpretation of Radiographs**

Wilhelm Conrad Roentgen's discovery of x-rays on November 8, 1895, initiated the first dental radiographs ever taken by Otto Walkhoff in January 1896. A new era was born, and ever since, dental radiographs have proved to be significant in dental and maxillofacial diagnosis. For many years, two-dimensional intraoral and extraoral radiography were the only radiographic options; but a little more than two decades ago, three-dimensional imaging in dentistry (cone beam computed tomography [CBCT]) became much more readily available. In addition, other advanced imaging modalities, such as multi-slice computed tomography (MSCT), magnetic resonance imaging (MRI), and ultrasound imaging, are also available.

This chapter provides a general overview of the techniques currently used in pediatric dental and maxillofacial radiology and will provide a clear overview of the image receptors, specialized techniques, and the indications and justifications for exposing pediatric patients to ionizing radiation or other imaging modalities.

## Radiation Safety and Protection

### BASICS OF RADIATION PROTECTION

The three basic principles of radiation protection are as follows:

#### The Justification Principle

This principle states that one should expose patients to ionizing radiation only if there is no other way to obtain the diagnostic information or if this exposure will positively influence the diagnosis, the treatment, and the patient's health. Justification applies only after a detailed oral examination and requires that one should attempt to obtain previously taken images because these contain important information and may negate the need for new radiographs. Special-needs patients and children may not always cope well with radiographic procedures. If the cooperation of

the patient is unlikely to result in a good-quality image, one should refrain from exposing the patient to ionizing radiation and explore other nonionizing imaging techniques such as transillumination, laser fluorescence, and photothermal radiometry and modulated luminescence.

#### The Limitation Principle

This principle states that one should always try to keep the radiation dose as low as reasonably achievable (ALARA). Current selection criteria will assist the clinician in addressing the principle of dose limitation.<sup>1</sup>

#### The Optimization Principle

Optimization means that one should obtain the best quality images possible, with both previous principles in mind. This can, however, imply the use of a technique that exposes the patient to a higher radiation dose, which can be justified only if the technique offers the greatest benefit for the patient and his/her health outcome.

The purpose for adhering to the above three principles is that x-rays can impart energy to the matter they traverse; if that matter is living tissue, then some biological injury may occur. Although much information is available regarding high levels of radiation (e.g., from cancer radiation treatments and nuclear accidents) and subsequent damage, little is known about the effects of low-energy ionizing radiation (as used in diagnostic radiology and dentistry in particular) on biological systems. However, animal studies indicate that acute or chronic low-dose ionizing radiation exposure may be harmful. It induces genetic changes and is associated with a range of physiological disruptions, including altered immune system, abnormal brain development, abnormal embryonic development, premature menopause in female animals, carcinogenesis, and shortened life expectancy.<sup>2</sup> Our assumptions of damage are based on extrapolation of data from high to lower levels of radiation. Therefore, two models have been devised to explain these effects: the non threshold (stochastic) and threshold models. The non-threshold model suggests that any dose of x-rays can cause

**TABLE 2.1** The Tissue Weighting Factors (WT) as Suggested by the International Commission (Higher WT Equals More Radiation Sensitivity) on Radiological Protection (ICRP, 2007)

Tissue	WT (2007)
Bone marrow	0.12
Breast	0.12
Colon	0.12
Lung	0.12
Stomach	0.12
Bladder	0.04
Esophagus	0.04
Gonads	0.08
Liver	0.04
Thyroid	0.04
Bone surface	0.01
Brain	0.01
Kidneys	0.01
Salivary glands	0.01
Skin	0.01
Remaining tissues	0.10

biological damage, whereas the threshold model suggests that no detrimental effects of ionizing radiation occur below a particular level or “threshold” of x-ray exposure. In 2018, Mallya and White<sup>3</sup> reported that until low-energy ionizing radiation is proven to be risk-free, dental health professionals should protect patients accordingly.

Dental health professionals must be concerned about any risk that the patient may encounter during therapy, with focus on three primary biological effects of low-level radiation: (1) carcinogenesis, (2) teratogenesis (malformations), and (3) mutagenesis. Carcinogenesis and malformations are responses of somatic tissues and, in most instances, are believed to have a threshold response (deterministic effect); that is, a certain amount of radiation is necessary before the response can be seen. Mutations may occur as a response of genetic tissue (gonads) to ionizing radiation and are believed to have no threshold (stochastic effects). In general, younger tissues and organs are more sensitive to ionizing radiation, with the sensitivity decreasing from the period before birth until maturity. Furthermore, far higher doses of radiation can be withstood by localized areas than by the whole body. There is a considerable variation in background radiation exposure depending of the geographical location; the global average is 2.4 mSv/year and the typical global range is 1–13 mSv/year.<sup>3</sup> Of this, about 15%–20% on an average is estimated to result from medical and dental diagnostic imaging. Later in this chapter, radiation doses will be discussed from the perspective of this annual background radiation. This information is important when discussing the potential impact of diagnostic x-ray imaging exposure with patients and parents.

To facilitate the calculation of effective radiation doses from certain diagnostic exposures, the International Commission on Radiological Protection has provided tissue weighting factors for human tissues<sup>4</sup> (Table 2.1). Some tissues are more vulnerable and susceptible to the effects of ionizing radiation. Table 2.2 shows the estimated risks for the development of a fatal cancer from exposure to diagnostic radiation. It is clear that the use of certain imaging modalities must be well justified. Table 2.3 shows the multiplication factors per age category, highlighting children’s increased sensitivity to x-rays.

**TABLE 2.2** Estimated Fatal Cancer Risks from Several Radiographic Examinations (Data from Ludlow et al., 2008, JADA).

X-ray diagnostic investigation	Estimated risk of a fatal cancer (adult)
Full-mouth x-rays with phosphor storage plates or F-speed analog film and rectangular collimation	2 in 1 million
Full-mouth x-rays with phosphor storage plates or F-speed analog film and circular collimation	9 in 1 million
Full-mouth x-rays with D-speed analog film and circular collimation	21 in 1 million
Two bitewing radiographs with phosphor storage plates or F-speed analog film and rectangular collimation	0.3 in 1 million
Dental panoramic radiograph (solid-state sensor)	0.8 to 1.3 in 1 million
Skull frontal radiograph (phosphor storage plate)	0.3 in 1 million
Lateral skull radiograph (phosphor storage plate)	0.3 in 1 million

**TABLE 2.3** Multiplication Factors per Age Category for the Estimated Risks of Developing a Fatal Cancer as a Result of Diagnostic Radiographs\*.

Age category	Multiplication factor
<10 years	×3
10–20 years	×2
20–30 years	×1.5
30–50 years	×0.5
50–80 years	×0.3
>80 years	×0

\*Whaites E: *Essentials of dental radiography and radiology*, Edinburgh, Churchill Livingstone, 2007.

## PROTECTION OF THE DENTAL STAFF

The best method for protecting dental staff from ionizing radiation is the use of shielding. Solid walls (preferably with a lead glass window) are the best protection one can achieve. However, some offices lack such walls, and the radiographer must maintain a safe distance from the x-ray source (Fig. 2.1). Once the x-ray machine is engaged, the patient is to be considered the source of radiation. The radiographer should stand either at 90 degrees to or behind the radiation source; at least 6 feet (2 m) from the radiation source is safe. One should never stand in the path of the primary radiation beam, or hold the image receptor or the wall-mounted x-ray machine. If, for whatever reason, insufficient distance is maintained, one should wear a lead or lead-free apron with thyroid shielding and stand in the appropriate position relative to the radiation source. The 6-foot rule also applies to panoramic and cephalometric imaging.

For the use of handheld x-rays devices, the operator should wear a lead or lead-free apron with thyroid shielding.<sup>5</sup>

For CBCT imaging, one should always stand behind a radioprotective barrier.

## PROTECTION OF THE PATIENT

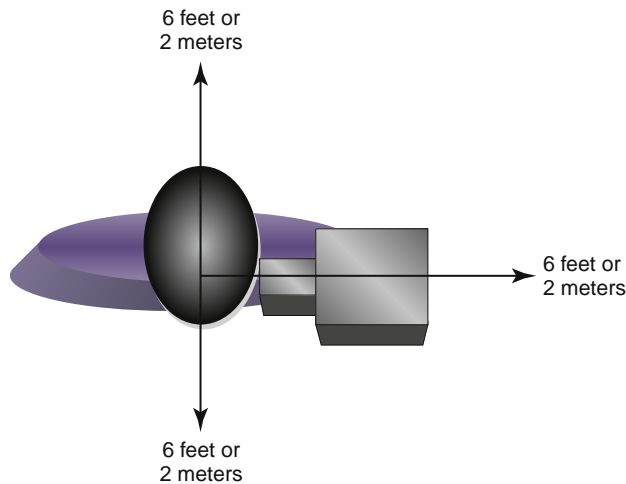
In addition to the three basic principles of radiation protection (justification, limitation, and optimization), one can

apply the following additional techniques to reduce the radiation burden to the patient:

- Rectangular collimation of the x-ray beam
- Correct focus-to-skin distance
- Lead or lead-free apron with thyroid collar
- More radiation-sensitive image receptors

The use of rectangular collimation limits the surface being irradiated to the size of the image receptor, reducing the radiation dose by about 50%, compared with that achieved with a 2.75-inch-diameter (6 cm) circular collimator (Fig. 2.2). According to the National Commission of Radiation Protection (NCRP), rectangular collimation must be routinely used for intraoral radiographs.<sup>6</sup> Rectangular collimators are available from different vendors. They are either attached to the tube head or are included in the image receptor holding device. Rectangular collimation also decreases the amount of scatter in the patient's tissues, which in turn results in better image quality.<sup>7-9</sup>

The focus-to-skin distance is the distance between the x-ray machine's anode (where x-rays are created) and the



**Fig. 2.1** Safe locations for the radiographer when obtaining an intraoral radiograph. Bird's-eye view of a patient being exposed for a bitewing radiograph. The arrows indicate the safest place for the radiographer to stand: at least 6 feet or 2 m from the patient.

skin of the patient's cheek or lip. Ideally, this should be a minimum of 8 inches (20 cm) to reduce the amount of low-energy x-radiation reaching the patient. Many manufacturers recess the x-ray tube to increase the focus-to-skin distance without increasing the overall length of the tube head.

The utility of a lead or lead-free apron (Fig. 2.3) as opposed to a thyroid collar has been extensively discussed. NCRP guidelines suggest that the use of a lead or lead-free apron is not necessary with rectangular collimation, short exposure times, adequate x-ray energies, and fast image receptors. Several studies have shown that with rectangular collimation, the patient is afforded protection from scatter radiation similar to that achieved with a lead or lead-free apron.<sup>9</sup> However, even with the existing evidence in favor of not using an apron, the recommendation is for it to always be used, especially in the young patient.

Fast image receptors, which require less exposure time, are advised since their use will enable the lowest possible radiation dose to be absorbed by the patient. If direct exposure film is used, either E- or F-speed film is strongly recommended. D-speed film requires at least twice the exposure of E-speed film and approximately 70% more exposure than F-speed film. Digital image receptors, either photostimulable phosphor plates (PSPs) or solid-state sensors, require much less exposure than D-speed film. Thus, digital image receptors and E- or F-speed film are considered to achieve similar lower radiation doses for patients.

When an apron is used with patients undergoing panoramic imaging, the apron must be placed high in the front, low in the back of the neck, and low over the shoulders. With correct positioning, the apron will not be captured in the panoramic images.

Correct positioning of the patient, image receptor, and tube head as well as appropriate exposure factors will decrease the need for retakes and will help keep the patient's dose ALARA. Darkroom quality assurance is essential if the radiographic imaging is film-based. Adequacy of safe lights, processing chemistry, and equipment maintenance and cleaning should be continuously monitored to maintain the quality and longevity of the film-based image.

Thus, it is clear that there are several actions one can take to minimize absorbed radiation doses and optimize image quality. For more information about protecting the patient



**Fig. 2.2** Examples of rectangular collimators. The rectangular end of the beam-indicating device decreases the exposed surface by more than 50% compared with a 2.75-inch-diameter round collimation. (A) A non removable rectangular collimator mounted on an intraoral x-ray machine. (B) A removable rectangular collimator (DENTSPLY® Universal Collimator) mounted on the circular open-ended beam-indicating device.

from radiation, Image Gently ([www.imagegently.org](http://www.imagegently.org)) is an excellent source for parents and health professionals to improve and increase the awareness in radiation safety protection for the young patient.

## Radiographic Image Receptors

### ANALOG FILM

Analog film is still used by a significant number of clinicians in the United States. Some dental professionals have not yet switched to digital radiography or have made only a partial switch (e.g., film for intraoral radiographs and digital for panoramic).

#### Direct Film

Direct analog film is the film of choice for intraoral radiography. It is called direct because of its high sensitivity to x-rays. Only E- or F-speed film should be used because these require shorter radiation exposure times and therefore contribute to a lower radiation burden for the patient. The exposure times needed for E- and F-films are comparable with those for digital image receptors. Direct analog film comes in different sizes (Table 2.4), making it suitable for different patients and tasks. The smallest size is 22 × 35 mm (International Organization for Standardization [ISO] format 0), which can be used for bitewing radiographs in the primary dentition and for periapical images of individual

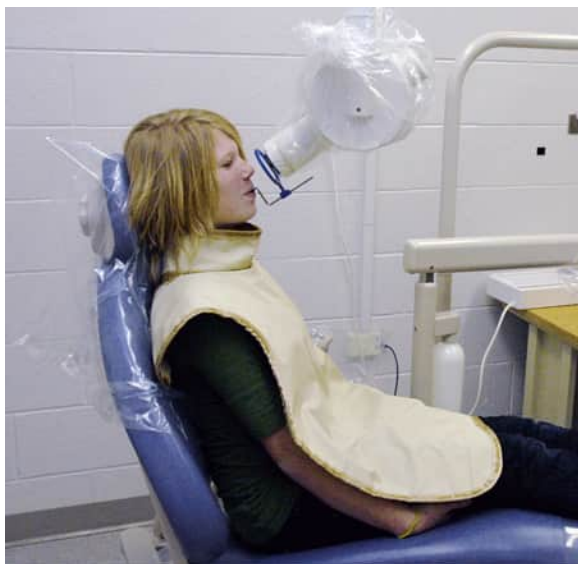

Fig. 2.3 An apron containing lead or a material equivalent to lead for dental use.

**TABLE 2.4** International Organization for Standardization (ISO) Formats of Intraoral Analog Film and Phosphor Storage Plates and their Dimensions.

ISO format	Dimensions (mm)
0	22 × 35
1	24 × 40
2	21 × 41
3	27 × 54
4	57 × 76

maxillary or mandibular incisors. Such film is often called “pedo-size” or “child-size” film. The ISO format 1 size is 24 × 40 mm and can be used for the same purposes as described for size 0. The ISO format 2 size is 31 × 41 mm and is probably the most common size used. It can be used for bitewing images, periapical images in children in a transitional dentition, in adolescents and adults, as well as for occlusal radiographs in the primary dentition. The ISO format 3 size is 27 × 54 mm, which is used only for bitewing images in the transitional or permanent dentition. The largest size is 57 × 76 mm (ISO format 4), typically used for occlusal radiographs of the mandible or maxilla in the mixed and permanent dentition. Film packages contain either single or double film. Since analog film is single use, packages can be bent if necessary; however, this should be minimized to reduce the likelihood of image distortion. Disadvantages of analog film include double exposures, difficulty sharing the films with colleagues and insurance companies, and need for sufficient office space to store chemicals, processor, and radiographs.

#### Indirect Film

Indirect analog film is more sensitive to light than it is to x-rays and should be used only in a cassette with an intensifying screen (Fig. 2.4). Indirect film is usually 15 × 30 cm or 18 × 24 cm, depending on its application. The intensifying screen converts the x-ray energy into light, which reaches the film and forms the latent image. In dentistry, this type of film is used in panoramic imaging and cephalometric radiography. The use of intensifying screens in cassettes keeps the exposure time as short as possible, but the images are less sharp than those obtained with direct analog film. The cassette should be checked regularly for light-tightness to ensure that no light can cause fogging of the film. The intensifying screens should be kept clean since dust or other particles can cause radiopaque artifacts in the image. One should use only the manufacturer’s recommended cleansing agent to clean the intensifying screens.

### DIGITAL FILM

#### Photostimulable Phosphor Storage Plates

The PSPPs (Fig. 2.5) appear very similar to analog film. This technique is also referred to as indirect digital imaging



Fig. 2.4 An opened panoramic cassette (15 × 30 mm) with intensifying screens on both sides (white surfaces) and analog film (blue-purple). A similar cassette, but without intensifying screens, is used for phosphor storage plates.






Fig. 2.5 The physical appearance of (A) a phosphor storage plate looks very similar to that of (B) analog film. The ISO format 2 is shown here.

because the image is captured in an analog format and converted to a digital image when scanned and is not displayed immediately when the radiographic image is captured. The phosphor layer is comprised of europium-activated barium fluorohalide, which will capture a latent image when exposed to x-rays. The phosphor plate emits a blue fluorescent light when exposed to a red helium laser light inside the PSPP scanner. The blue emissions captured by a photomultiplier are subsequently converted into a visible image. Once the image is generated, the scanner will expose PSPPs to white light to erase the latent image. Because PSPPs are sensitive to white light, the scanner cannot be placed in a brightly lit area since this will degrade the image once the phosphor plates are freed from the light-tight barrier. PSPPs come in different sizes and can be used for either intraoral or extraoral applications. When used for intraoral radiography, they should be wrapped in a single-use plastic light-tight barrier to avoid both cross-contamination and the toxicity of the phosphor layer. When PSPP is used in a cassette for extraoral radiography, there is no need for it to be wrapped in a plastic barrier. The cassette, however, should be light-tight and should not contain intensifying screens, as is the case with analog indirect film. Because of the various sizes and flexibility of PSPPs, it is acceptable for intraoral radiography in pediatric patients and patients with special needs. The biggest disadvantage of PSPPs is their susceptibility to scratches, bite marks, and creasing, which could damage the phosphor layer (Fig. 2.6). This damage is irreversible and will always be visible as a radiopacity in the image. Just as with analog film, double exposures are possible with this technology.

### Solid-State Sensors

Solid-state sensors (Fig. 2.7) are also known as direct digital receptors because they display the radiographic image instantaneously following exposure. There are two different types of solid-state sensors: charged coupled devices (CCDs) and complementary metal oxide semiconductors (CMOSs). These sensors differ in how the image is captured but appear similar in both external appearance and image output. Both CCD and CMOS sensors use a scintillation screen (usually gadolinium oxysulfide or cesium iodide) to transform the x-ray energy into visible green light, which is then converted into a visible image. Direct digital sensors are available in sizes 0, 1, and 2. The primary disadvantage of these

sensors is that they are relatively bulky and not always easy to position in the patient's mouth (Video 2.1). The majority of direct digital sensors are attached to a computer by a shielded wire cable, which can be damaged by repeated biting. The solid-state sensors are also incorporated into extraoral radiography devices, such as panoramic machines and cephalometric units. The sensors are arranged in a vertical array and capture the x-rays while the panoramic or cephalometric machine scans. The image is formed by vertical lines or columns of pixels. Some manufacturers use a lens in front of the solid-state sensor so that the image from a cephalometric unit can be obtained in one exposure, instead of via a scanning motion from anterior to posterior. This saves time and radiation dose and helps reduce motion artifacts.

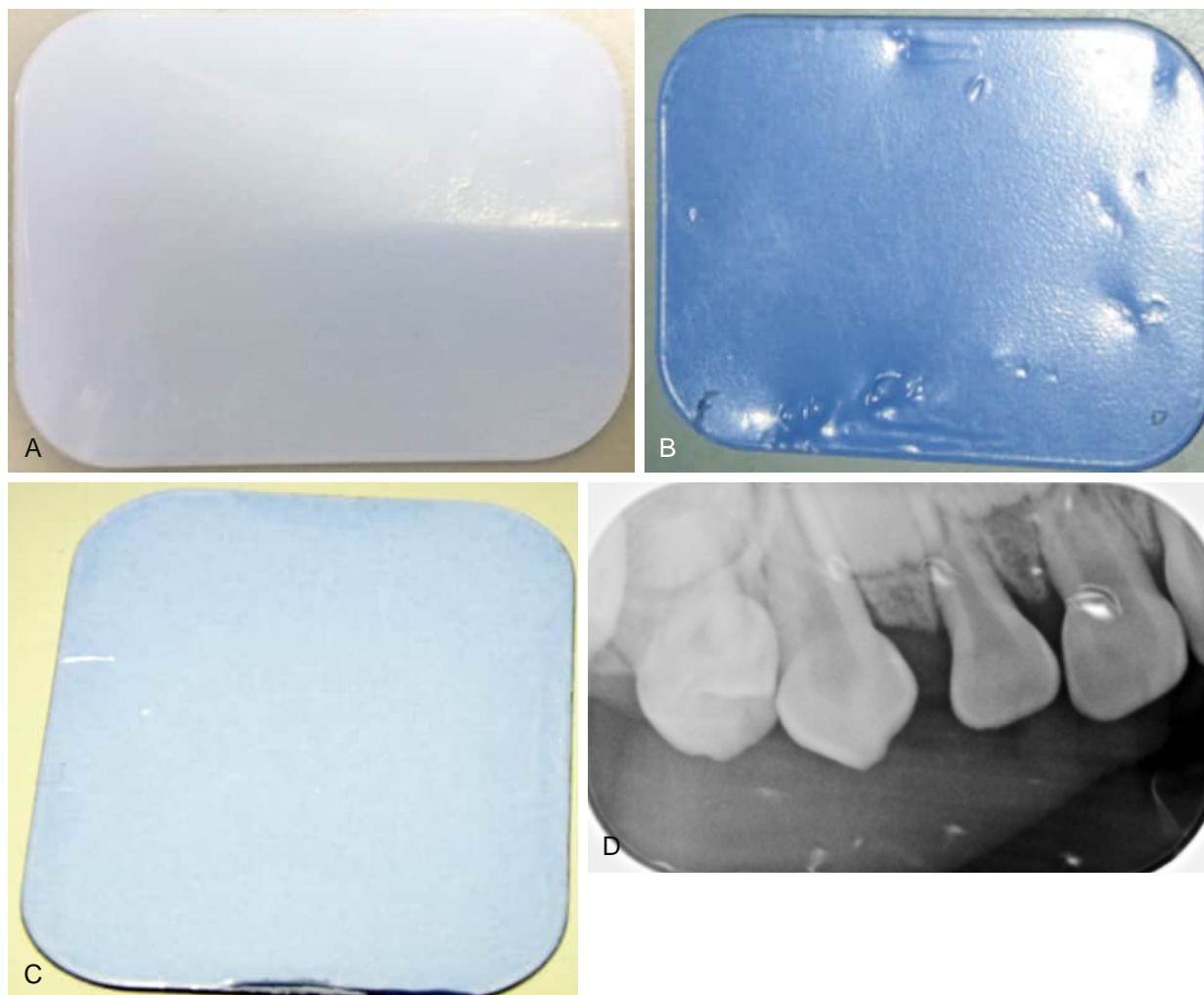
**Video 2.1** Radiographic Technique: phosphor storage plate intraoral placement and tube-head angulation for common pediatric radiographs.

*This video was made in conjunction with Dr. Tawana Ware and Professor Twyla Rader, Indiana University.*

### IMAGE VIEWING CONDITIONS

Analog film should be viewed on a clean and bright view box, with a clean viewing surface and a properly functioning light source. Optimal viewing conditions should allow one to collimate the light, so the light area is restricted to the size of the film. The viewer's eyes should be blocked to surrounding light to ameliorate the perception of details. Furthermore, the ambient light in the room should be dimmed so that more details in the radiographic image can be seen. This is not always feasible in a dental office setting, but efforts should be made to place the view box in a dimmed area of the office.

Digital images are viewed on a computer monitor or screen. Ideally, ambient light should be subdued and the monitor calibrated. Some viewing software programs allow for calibration of the computer screen. If they do not, a "monitor calibration screen" can easily be downloaded from the Internet (Fig. 2.8). Monitor performance should be evaluated periodically. The monitor should be positioned in an area of subdued lighting away from a window or bright light. Touchscreen monitors should not be used as fingerprints can cause image quality to deteriorate. According to the literature, most computer monitors provide sufficient resolution and contrast for the vast majority of dental diagnostic needs.



**Fig. 2.6** (A) Phosphor plate that has been bent. (B) Phosphor plate that has been bitten. (C) Phosphor plate with curling of the phosphor layer on the edge of the short side of the plate. (D) Phosphor plate image taken with a phosphor plate ISO format 0, with several bite marks and scratches. The latter will appear on every image that will be taken with this phosphor storage plate.



**Fig. 2.7** Solid-state sensors, sizes 0, 1, and 2. (Courtesy SIRONA DENTAL SYSTEMS, INC.)

A wide range of image receptors can be used in pediatric and special-needs dentistry. It is up to the dental professional to choose the system that works best in his or her practice as technology changes rapidly and image receptors will also change. Perhaps in the near future, technology will be available that makes image capture easier for both the clinician and the patient. Digital image receptors offer the opportunity for the captured image to be enhanced. Common enhancements include density and contrast, magnification, and edge sharpening. [Fig. 2.9](#) demonstrates the effects of density and contrast enhancements.

## Radiographic Techniques

Multiple radiographic techniques must be used to manage the wide range of pediatric and special-needs dental patients. The patient's size and ability to cooperate must be considered when a radiographic technique is selected.



Fig. 2.8 Example of monitor calibration screens.

## INTRAORAL RADIOGRAPHY

Intraoral tube heads and portable handheld devices should generate 60–70 kVp to produce adequate diagnostic images. The timer must be accurate to allow for short exposure times. Radiation-sensitive (rapid) image receptors should be used at all times.

Rectangular collimation of the radiation beam is advised to reduce the irradiated surface area to the size of the image receptor. The use of film positioning devices or image receptor holder is strongly recommended. There are several types of intraoral radiographs, each of which has specific indications and limitations.

### Periapical Radiography

Periapical radiographs should show the crown of the tooth and at least 3 mm beyond the apex of the tooth. To achieve this coverage, one can use either the paralleling technique or the bisecting angle technique. The paralleling technique is preferred because of its accuracy.

**Paralleling Technique.** This is the most accurate technique for taking intraoral radiographs. The image receptor should be positioned parallel to the long axis of the teeth, while the x-ray beam is directed perpendicular to the image receptor. Ideally, image receptor holders that enable one to aim easily and correctly should be used (Fig. 2.10). This

means that the aiming device must firmly grip the image receptor and that there is an extraoral component that allows the x-ray beam to be positioned correctly in both the vertical and horizontal planes. Other holders such as those displayed in Fig. 2.11 do not provide this extraoral component, and can produce either elongation or foreshortening of the image if the vertical angulation is incorrect or overlapping of proximal surfaces if the horizontal angulation is incorrect. Both angulation errors can result in the need for a retake.

**Bisecting Angle Technique.** In the bisecting angle technique, the image receptor is placed as close to the teeth as possible, and the central x-ray is directed perpendicular to a line that bisects the angle created by the tooth and image receptor (Fig. 2.12). This technique is obviously more prone to geometric errors and should not be regarded as the preferred technique. Elongation or foreshortening (vertical angulation errors) of the image or interproximal overlap (horizontal angulation errors) of the image is often the result of inaccurate aiming.

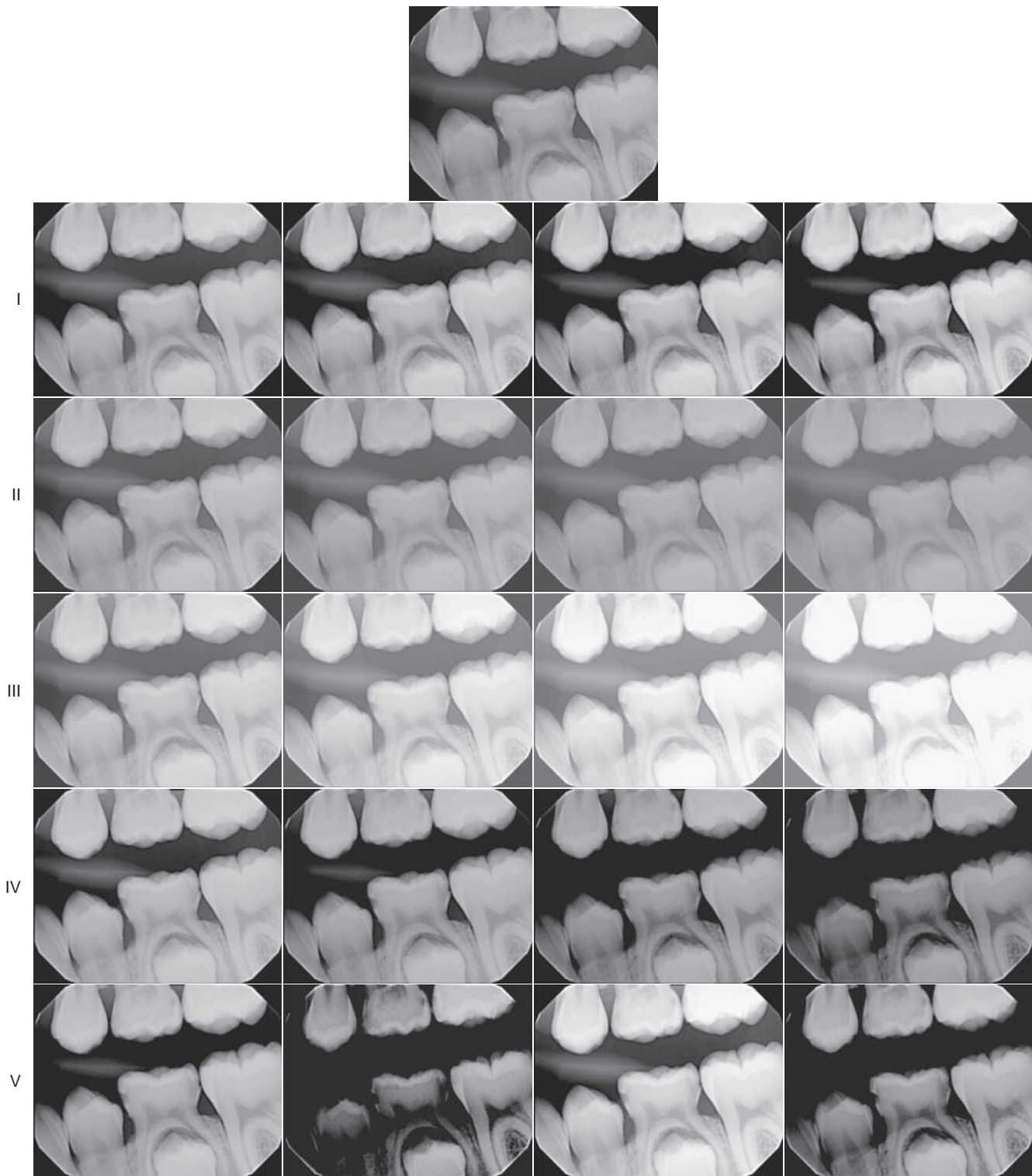
### Bitewing Radiography

Bitewing radiographs are intended to assess interproximal caries and interproximal bone height. Bitewing geometry is based on the paralleling technique, where the image receptor is placed parallel to the teeth and the x-ray beam is aimed perpendicular to the receptor. Overlap of proximal surfaces is minimal with the proper image receptor holders, which assist in directing the x-ray beam through the proximal contacts. However, it is the clinician's evaluation of the receptor placement that determines the accuracy of the image rather than the receptor holder (Fig. 2.13). Paper tabs, styrofoam tabs, or a device such as the Ezee Grip to hold the image receptor in the mouth does not offer extraoral guidance to aim the central x-ray through the proximal contacts.

**Anterior Maxillary Occlusal Technique.** In the anterior maxillary occlusal technique, the patient's occlusal plane should be parallel to the floor and the sagittal plane should be perpendicular to the floor (Fig. 2.14). A size 2 image receptor is placed in the patient's mouth so that the long axis of the film runs from left to right, rather than anteroposteriorly, and the midsagittal plane bisects the film. The patient is instructed to bite lightly to hold the receptor; a tongue blade can be attached to PSP or film receptors (Fig. 2.15), and rigid receptors should be wrapped in gauze to protect the sensor when the patient bites on it. The anterior edge of the receptor should extend approximately 2 mm in front of the incisal edge of the central incisors. The central x-ray is directed to the apices of the central incisors and 1 cm (0.5 inch) above the tip of the nose and through the midline. The vertical angle is +60 degrees. This receptor is exposed at the usual setting for maxillary incisor periapical films.


**Posterior Maxillary Occlusal Technique.** In the posterior maxillary occlusal technique, the patient's occlusal plane should be parallel to the floor and the sagittal plane should be perpendicular to the floor. A size 2 image receptor is placed in the patient's mouth so that the long axis






**Fig. 2.9** This figure shows how adjustments in contrast and density can alter the information in the image that one sees on the screen. The image at the top is the original image displayed by the software. The images in the first line have increasing contrast, and those in the second line have decreasing contrast. The images in the third line have decreasing density, and those in the fourth line have increasing density. The bottom line is a combination of changed contrast and density.

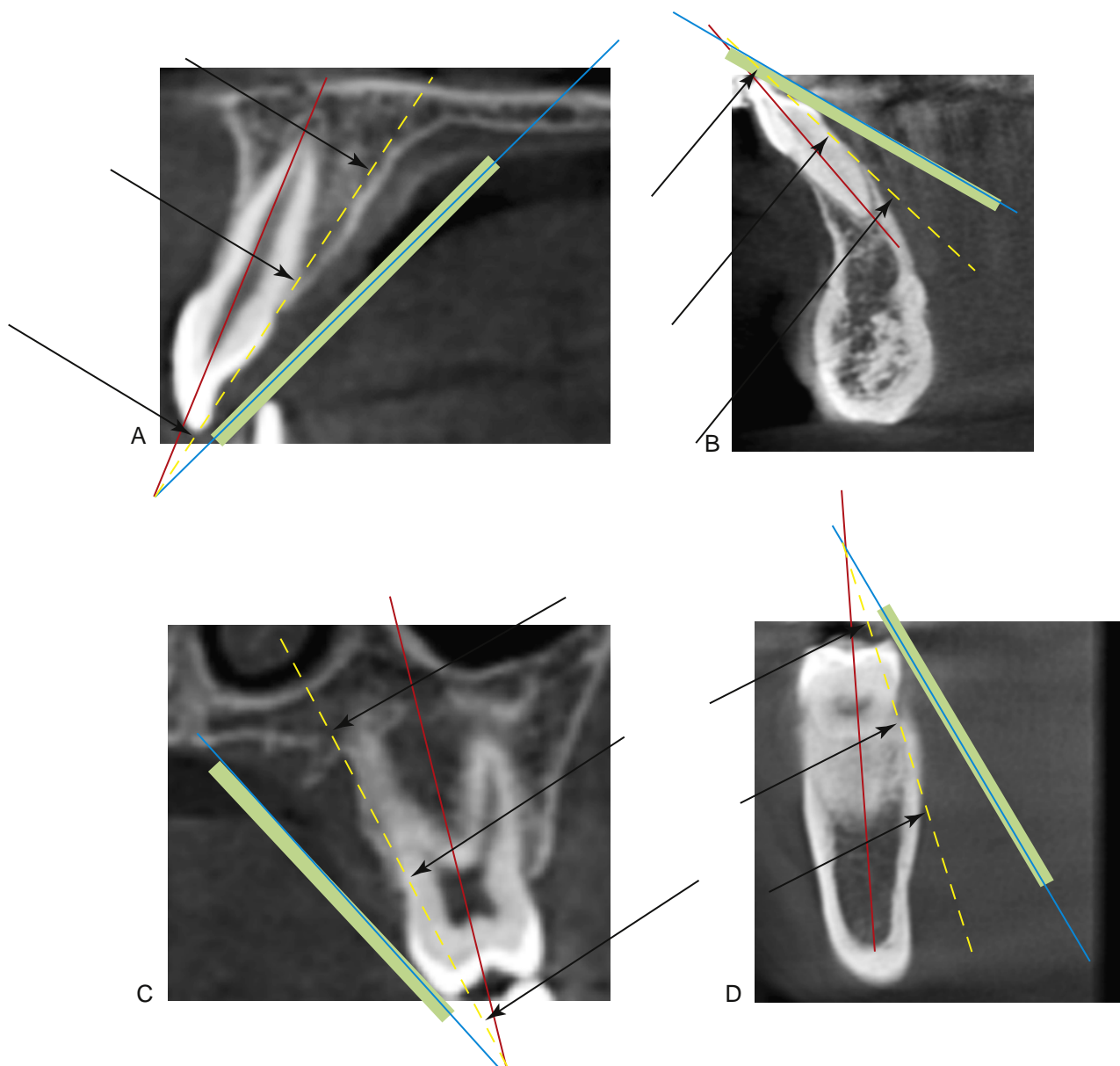




**Fig. 2.10** Illustration of the Rinn® paralleling technique beam-aiming and image receptor holding device. (A) The bite block holds the image receptor firmly and allows for ideal positioning in the patient's mouth. It also allows for the attachment of a metal rod that aids in correct horizontal and vertical aiming of the x-ray beam. (B) The plastic ring (yellow) demonstrates rectangular cutouts that allow the rectangular collimator/beam-aiming device to be aimed perpendicular to the image receptor. (C) and (D) Other examples of acceptable image receptor holders/aiming devices.



**Fig. 2.11** (A) and (B) Image receptor holders without extraoral aids. It is obvious that these are not ideal for aiming perfectly perpendicular to the image receptor.



**Fig. 2.12** The bisecting angle technique illustrated for (A) and (B) maxillary and mandibular incisors and for (C) and (D) mandibular and maxillary molars. The x-ray beam (black arrows) must be aimed perpendicular to the imaginary bisecting angle (interrupted yellow line) between the long axis of the tooth (red line) and the long axis of the image receptor (blue line).

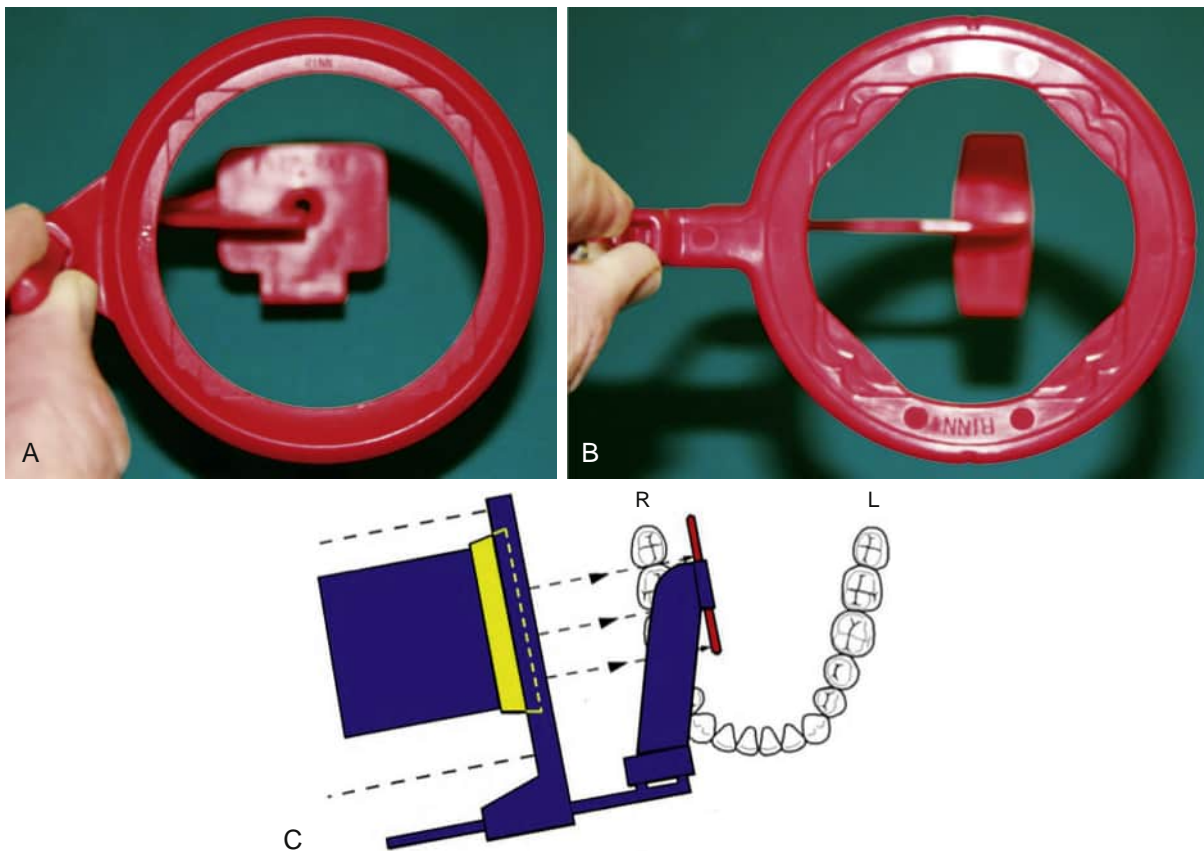
of the film is parallel to the floor. The anterior edge of the receptor should extend just mesial to the canine. The outer buccal edge of the receptor should extend approximately 2 mm beyond the primary molar crowns. The patient is instructed to bite lightly to hold the receptor. The central x-ray is directed toward the apices of the primary molars as well as interproximally. The vertical angle is +50 degrees. The receptor is exposed at the usual setting for maxillary premolar periapical projection.

**Anterior Mandibular Occlusal Technique.** The film placement for the anterior mandibular occlusal technique is identical to that for the anterior maxillary occlusal technique, except that the receptor must be placed so that the tube side faces the x-ray source (Fig. 2.16).

Furthermore, when the patient bites on the receptor, the anterior edge of the receptor is 2 mm beyond the incisal edge of the lower incisors. The patient's head is positioned so that the occlusal plane is at an angle of 45 degrees. The cone is then aligned at a -15-degree vertical angle, and the central x-ray is directed through the symphysis.

### Localization Techniques

One method of localizing embedded or unerupted teeth involves the buccal object rule (also referred to as the parallax technique or the "same lingual opposite buccal," i.e., SLOB rule), which states that the image of any buccally oriented object appears to move in the opposite direction from a moving x-ray source. Conversely, the image of any



**Fig. 2.13** (A) and (B) Bitewing holders with extraoral aids that allow for proper perpendicular aiming at the image receptor and the teeth. (C) The bottom image represents a schematic view of how a bitewing image should be taken and how the image receptor holder/aiming device (e.g., Rinn®) should be used.

lingually oriented object appears to move in the same direction as a moving x-ray source (Fig. 2.17).

Using this principle for localization, the practitioner makes two radiographs of the unerupted tooth. The technique consists of positioning the patient's head so that the sagittal plane is perpendicular to the floor and the alartragus line is parallel to the floor. An intraoral periapical film is placed in the mouth and then exposed by the paralleling technique. Subsequently, a second film is placed in the mouth in the same position as the first film, with the patient's head position remaining the same, but with the horizontal angle shifted either anteriorly or posteriorly depending on the site. The object in the projection that moved in the direction opposite to that in which the x-ray machine was moved is located more buccally, relative to the object(s) that moved in the same direction as the x-ray machine.

## EXTRAORAL RADIOGRAPHY

### Panoramic Imaging

The panoramic image is obtained through tomography. This means that only the structures located in the focal trough are captured in focus. Objects or structures outside the focal trough should be interpreted with care. Because of the projection geometry, panoramic images are magnified (by a factor of around 1.3) and therefore

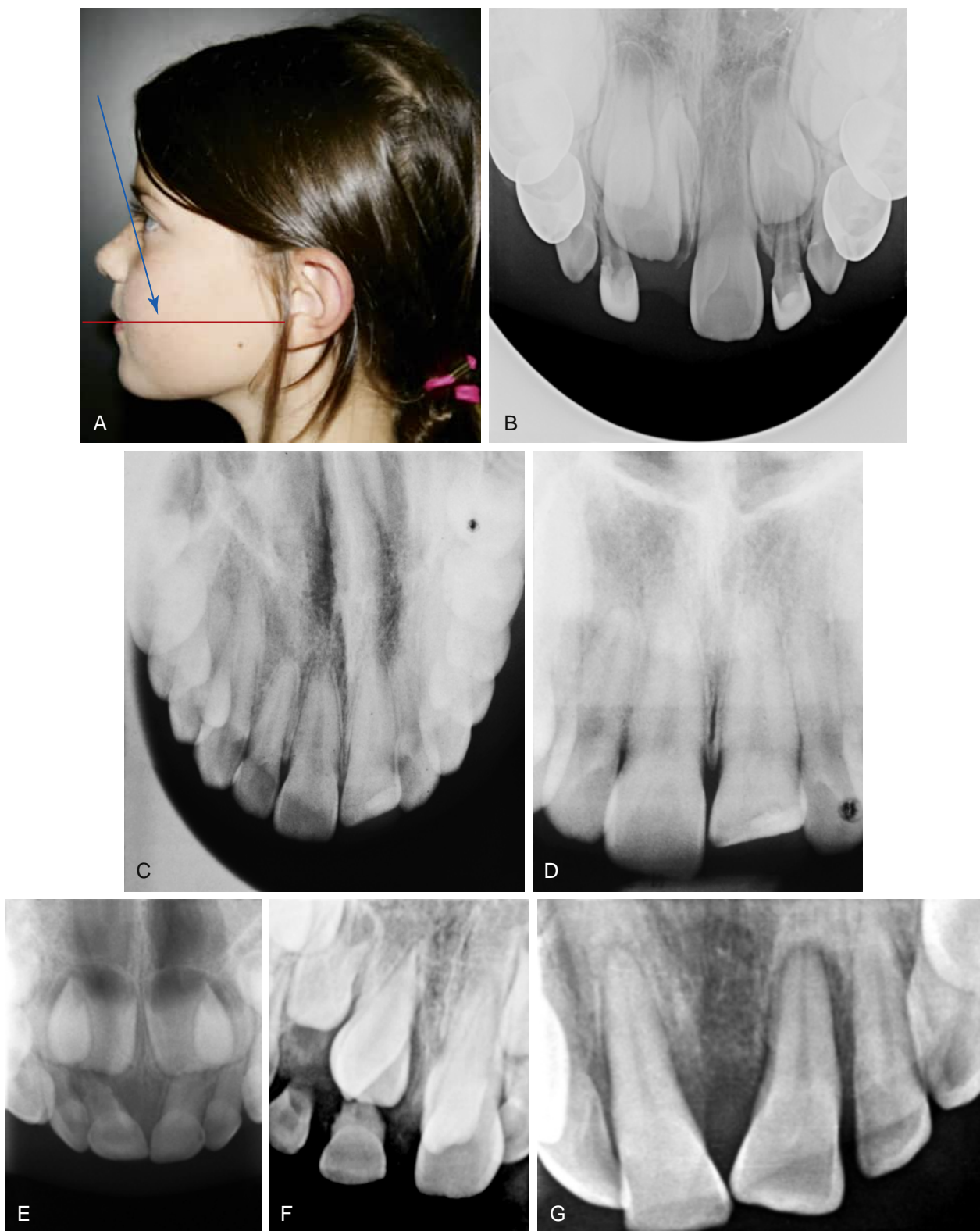
measurements taken from a panoramic image will also be magnified.

Most current panoramic machines enable one to take bitewing look-alike images (Fig. 2.18). These images should be interpreted with caution since a standard bitewing projection requires that the image receptor be placed parallel to the teeth, with the x-ray beam directed perpendicular to the receptor. The panoramic bitewing is re-created from the existing panoramic image; nevertheless, it is a very useful alternative when a patient cannot tolerate the intraoral image receptor. However, it should not be used as a standard bitewing projection. Panoramic machines are available with solid-state sensors or with a cassette system. Film-based panoramic cassettes contain intensifying screens that convert x-radiation to visible light. Phosphor plate panoramic cassettes do not contain intensifying screens.

### Cephalometric Imaging

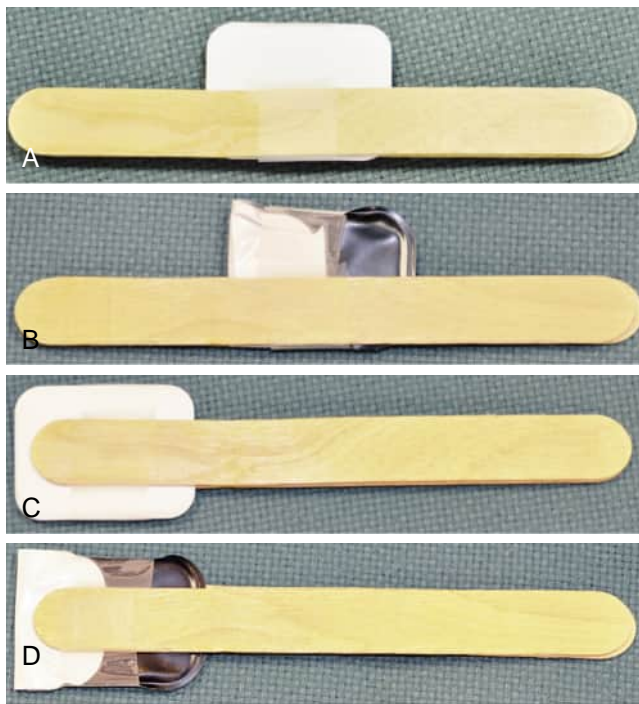
This technique is usually used in orthodontics and orthognathic surgery. Some machines will use a single exposure, which minimizes motion errors. In the scanning machines, the exposure takes longer; therefore, there is a higher risk for motion artifacts in these images. Positioning of the patient in the cephalostat is very important. Remember that digital imaging does not correct or compensate for improper patient positioning.





**Fig. 2.14** (A) An occlusal radiograph in the maxilla should be taken with the patient in an upright position in the chair, with the occlusal plane (red line) horizontal to the floor and the x-ray beam (blue arrow) aimed at 60 to 65 degrees through the bridge of the nose. (B) The radiograph shows the type of image obtained with this technique. (C) and (D) The images illustrate that this technique does not necessitate the use of size 4 film or phosphor storage plates, but that size 2 will suffice (both images are from the same patient, but taken at different times). (E), (F), and (G) These images illustrate the use of this technique in younger patients in the primary dentition and the mixed dentition, and in a (G) special-needs patient with a dentoalveolar trauma.





**Fig. 2.15** Illustration of wooden tongue depressors used to protect the film or phosphor plate from being bitten during positioning and/or exposure. (A) and (B) Anterior use. (C) and (D) Posterior use. The image receptor is taped between two tongue depressors. The patient can bite down on them to avoid permanent damage to a phosphor plate. The tongue depressors provide guidance to the radiographer to assess the level of the occlusal plane or can provide assistance to the caregiver who assists during the radiographic procedure.

### Cone Beam Computed Tomography

This technology has become very popular since 2002 and has found its way into many private practices. This modality is ideal for imaging hard tissues, including bone and teeth. CBCT delivers higher radiation than traditional radiographic techniques.<sup>10,11</sup> However, it provides detailed and critical information in very specific situations. Indications for the use of CBCT includes localization of impacted canines and third molars, visualization of maxillofacial pathologies for assessing extension or surgery planning, visualization of the condyles and glenoid fossa, visualization of the maxillary sinuses, and so on. As for conventional radiographic techniques, justification must be the driving force in the decision of ordering a CBCT in the young patient (Fig. 2.19A–C). Artifacts due to beam hardening and motion artifacts are to be avoided (Fig. 2.20). The radiation dose from CBCT is considerably higher than that from a periapical radiograph. It is also very difficult to determine the radiation dose in general from CBCT since it depends on exposure settings (kVp, mA, and exposure time), field of view (the size of the volume, which is determined by the size of the cone-shaped x-ray beam), and the resolution of the image (the details).<sup>12,13</sup> Again, justification to expose pediatric patients to CBCT should not be taken lightly.<sup>14</sup> The effective dose from diagnostic radiology techniques compared with CBCT is presented in Table 2.5.

### Medical Computed Tomography

Medical CT is responsible for the highest radiation doses a patient can receive from diagnostic imaging. The fan-shaped beam rotates around the patient's body (part) in a helical motion. The space between two rotations of the beam (pitch) determines the resolution of the image and hence the radiation dose. Medical CT, also called MSCT, is useful for the imaging of hard and soft tissues and provides the clinician with the ability to detect very small differences in density in the image (contrast resolution). The technique is usually used to identify malignancies, tumors, and other symptoms of pathology, with or without the use of contrast medium.

### Ultrasound Imaging

Most people associate ultrasound imaging with pregnancy, but this technique is also excellent for investigation of soft tissues, such as the floor of the mouth, salivary glands, and lymph nodes in the head and neck region. As the technique does not involve ionizing radiation, it can be repeated as many times as necessary, without exposing the patient to any risks. Fig. 2.21 displays an ultrasonogram of the floor of the mouth as an illustration of an investigation to evaluate swelling or foreign objects in the soft tissues in this region. Moreover, this technique is appropriate when fine-needle aspirations are required.

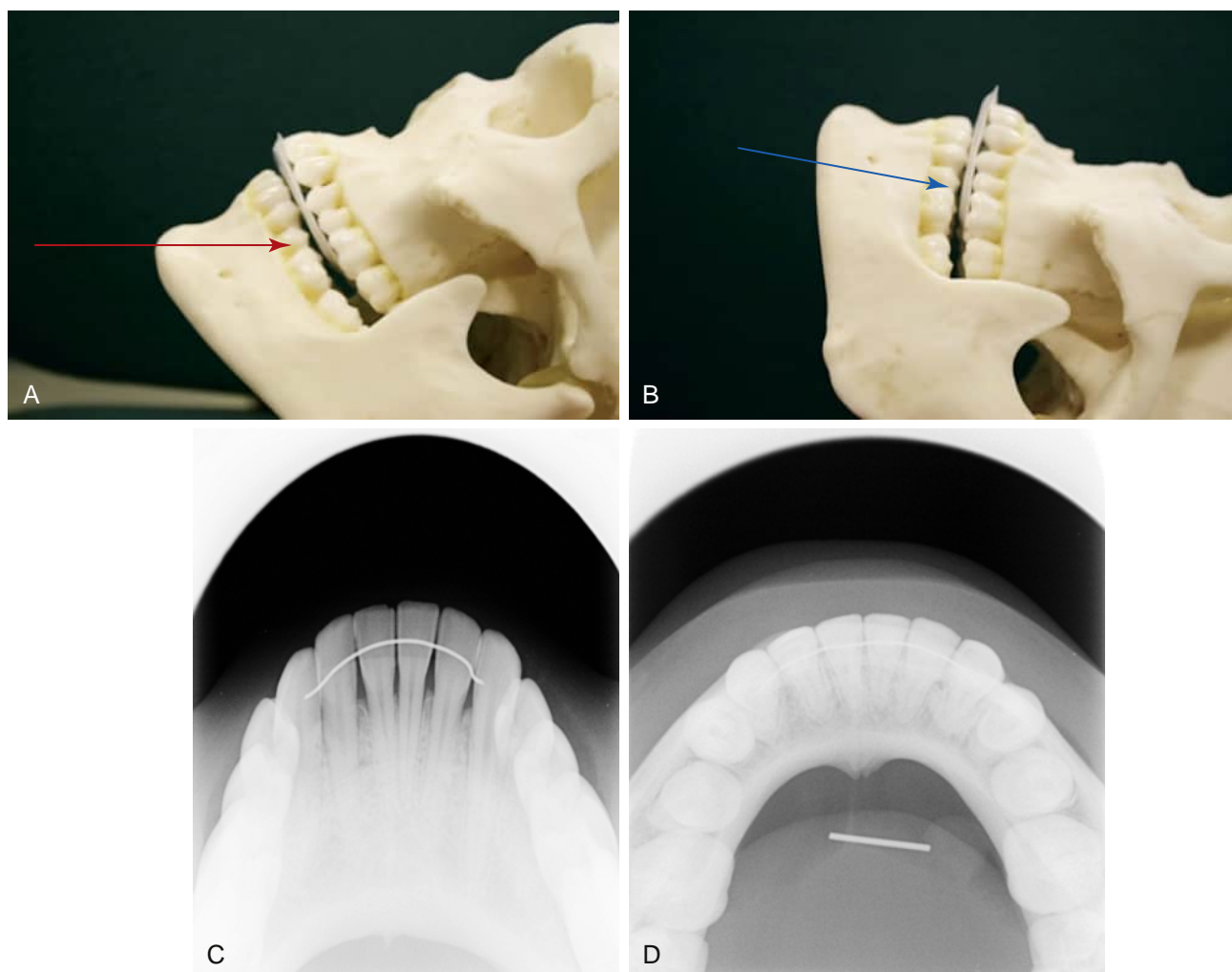
### Magnetic Resonance Imaging

The MRI evaluates the hydrogen content of tissues and uses a magnetic field to differentiate among different tissue types. As there are more hydrogen atoms in soft tissues than in cortical bone, this technique is especially useful with soft tissue. Contraindications for MRI include claustrophobia and the presence of metallic clips or metallic foreign bodies. The most common dental indication for the use of MRI is for imaging the soft tissues of the temporomandibular joint (Fig. 2.22).

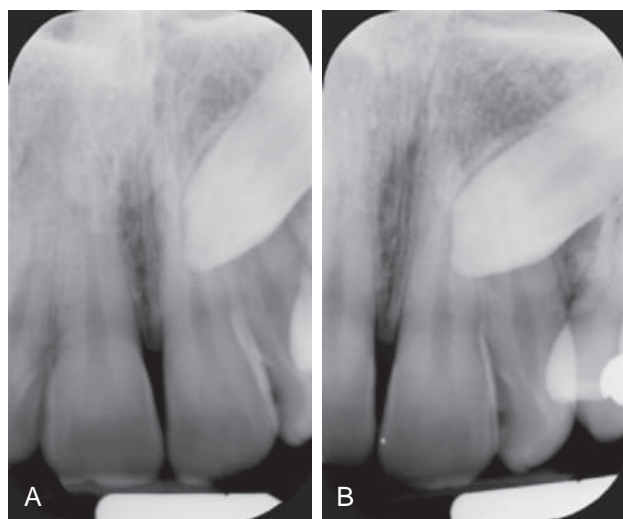
## Selection Criteria and Radiographic Examinations

### CRITERIA FOR EXPOSING CHILDREN TO IONIZING RADIATION

For all radiographic examinations, the same basic rules apply: justification and professional judgment on an individual patient basis. There are no guidelines per age group, gender, or dentition stage. The American Dental Association,<sup>15</sup> the American Academy for Pediatric Dentistry,<sup>15</sup> the European Academy for Pediatric Dentistry,<sup>16</sup> and other organizations have published criteria that are meant to guide the dental professionals in decision making regarding appropriate radiographic imaging (Table 2.6). These guidelines clearly state that if the patient cannot cope with the procedure, one should attempt other strategies to handle the situation. All the guidelines acknowledge that radiographs are not possible in some cases; in such cases, one should balance the benefit against the risk even more carefully. Sometimes it is better to postpone the radiographic exposure until the patient is older or better conditioned. The guidelines also clearly state that if there are no clinical signs



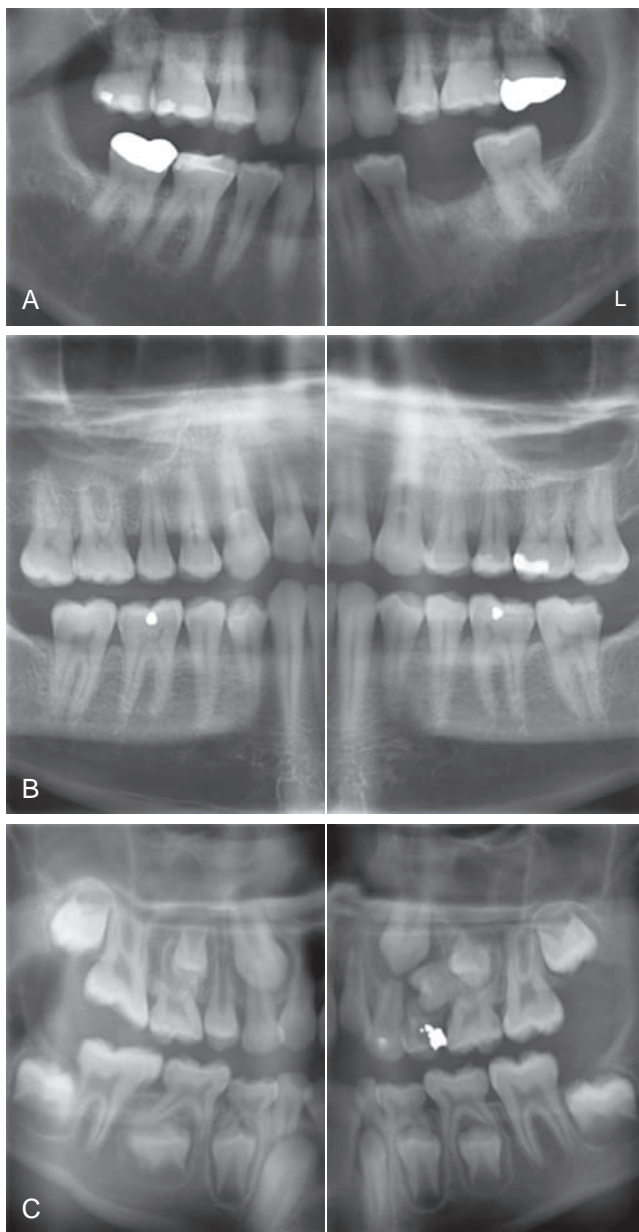
**Fig. 2.16** (A) The position of the x-ray source (red arrow) 45 degrees occlusal to the mandible. (C) An example of this projection. (B) The position of the x-ray source (blue arrow) 90 degrees occlusal to the mandible. (D) An example of this projection (patient with a small piece of a metal rod in the floor of the mouth).



**Fig. 2.17** The buccal object rule or parallax technique is illustrated to determine the position of an impacted maxillary canine. (A) The radiograph shows that the tip of the canine coincides with the mesial wall of the pulp canal of the left central incisor, whereas in (B), it coincides with the distal wall. From the latter, one can conclude that the canine is lingually impacted since it moved in the same direction as the x-ray source.

of pathology, the need for a radiographic assessment is up to the professional's judgment, and that these decisions have to be made on an individual patient basis. Radiographs are never to be used for economic and screening reasons because they involve a potential health risk for the patient.

Here are some examples of how the guidelines can be interpreted and implemented. A 3-year-old with a sound dentition and open proximal contacts does not need a radiographic assessment. Conversely, for a 3-year-old with only 10 teeth visible in the mouth and no history of dental treatment, the dental professional should make a radiographic assessment. If a 4-year-old shows rampant decay, a radiographic assessment is certainly justifiable and indicated. A 7-year-old with a normal transitional dentition and no caries history, and for whom bitewing images had been taken 12 months prior, does not need a panoramic radiograph. The same 7-year-old, with a complete primary dentition and no clinical signs of tooth mobility, might require a panoramic radiographic assessment. [Table 2.6](#) does not address the use of CBCT or MSCT, but it is obvious that justification and common sense should prevail when these examinations are prescribed for or performed on pediatric patients or patients with special needs.



**Fig. 2.18** Examples of bitewing radiographs taken with a panoramic machine (A) Planmeca ProOne; (B) Planmeca S2 Pan; (C) Planmeca S3 Promax.

### RADIOGRAPHIC EXPOSURES IN CASES OF DENTOALVEOLAR TRAUMA

Dentoalveolar trauma can occur in the primary, mixed, and permanent dentition. Both clinical evaluation and radiographic examination are necessary. Contusions, crown fractures, root fractures, and avulsions are among the many injuries that require radiographic assessment. The number and frequency of radiographs needed, however, are not entirely clear from the literature. Since most accidents involve the maxillary incisors, periapical and occlusal radiographs are likely to be part of the radiographic assessment. This means that x-rays are being aimed at the thyroid gland, which is a radiosensitive organ and should be avoided as much as possible.<sup>17</sup> CBCT is not often needed because periapical radiographs, taken

from two different angles, can often provide enough information for a proper diagnosis.<sup>18</sup> However, if a root fracture is suspected, a cone beam image at sufficient resolution (200  $\mu\text{m}$ ) can be useful. The potential for motion artifacts in CBCT imaging of pediatric patients must be considered when selecting a radiographic technique. When mandibular fracture is suspected, panoramic radiography is the technique of choice; CBCT might also be worth considering.

### RADIOGRAPHIC EXPOSURES IN PATIENTS WITH SPECIAL NEEDS

This group of patients should not be exempted from radiographic assessment. The same selection criteria apply, but the clinician must assess the ability of the patient to cooperate before performing any imaging. Lateral oblique or oblique lateral radiographs and (oblique) occlusal radiographs may prove to be very useful in this patient population. Nevertheless, if the patient cannot tolerate or cope with the technique required to obtain good-quality images, the clinician may have to pursue an alternative treatment plan and postpone the taking of radiographs until a more suitable moment (e.g., when the patient is under general anesthesia for a medical procedure).

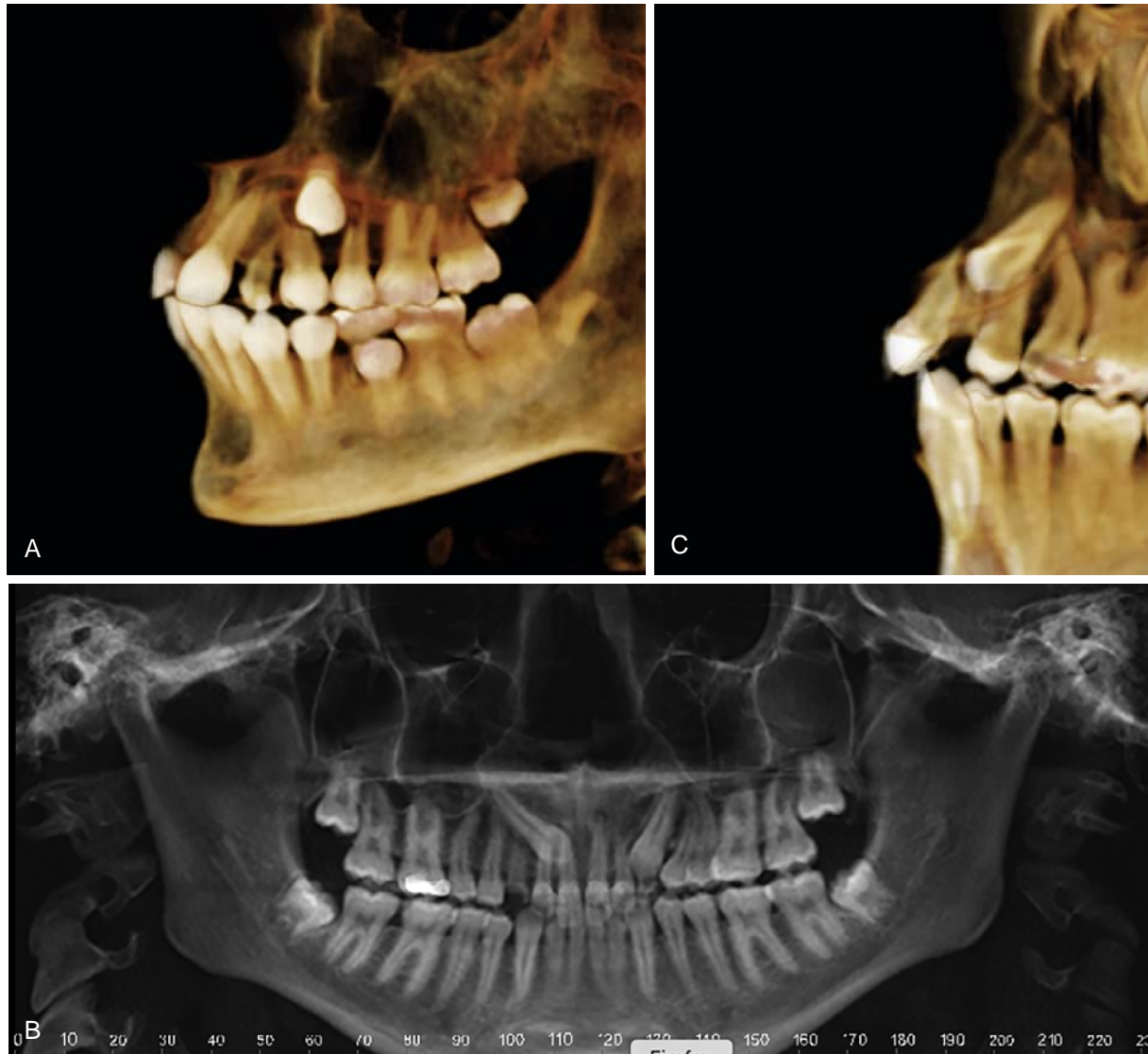
### Interpretation of Radiographs

Radiographs should be evaluated under ideal conditions. View boxes or monitors should be clean and positioned in an area of diminished ambient light. Density and contrast enhancements are essential tools for the assessment of digital images. These should be readily accessible so that the clinician can enhance different areas of the image with different enhancement tools. The clinician's ability to enhance the radiographic image dynamically and differentially is a significant advantage over analog film. Software filters can also assist in obtaining better images, but one should never overlook the fact that filtering means loss of information. It is, therefore, paramount to use all the information contained in the digital image, which should be considered as a database and not merely as an image displayed on the monitor.

As previously mentioned, assessing radiographs in a brightly lit dental operator clearly increases the clinician's potential to miss diagnostically useful information contained in a radiographic image. Despite the fact that the parents and patients appreciate viewing the radiographic images in the operator, the initial diagnosis should not be made at the chairside monitor, but rather in an area of the office where the light is dimmed.

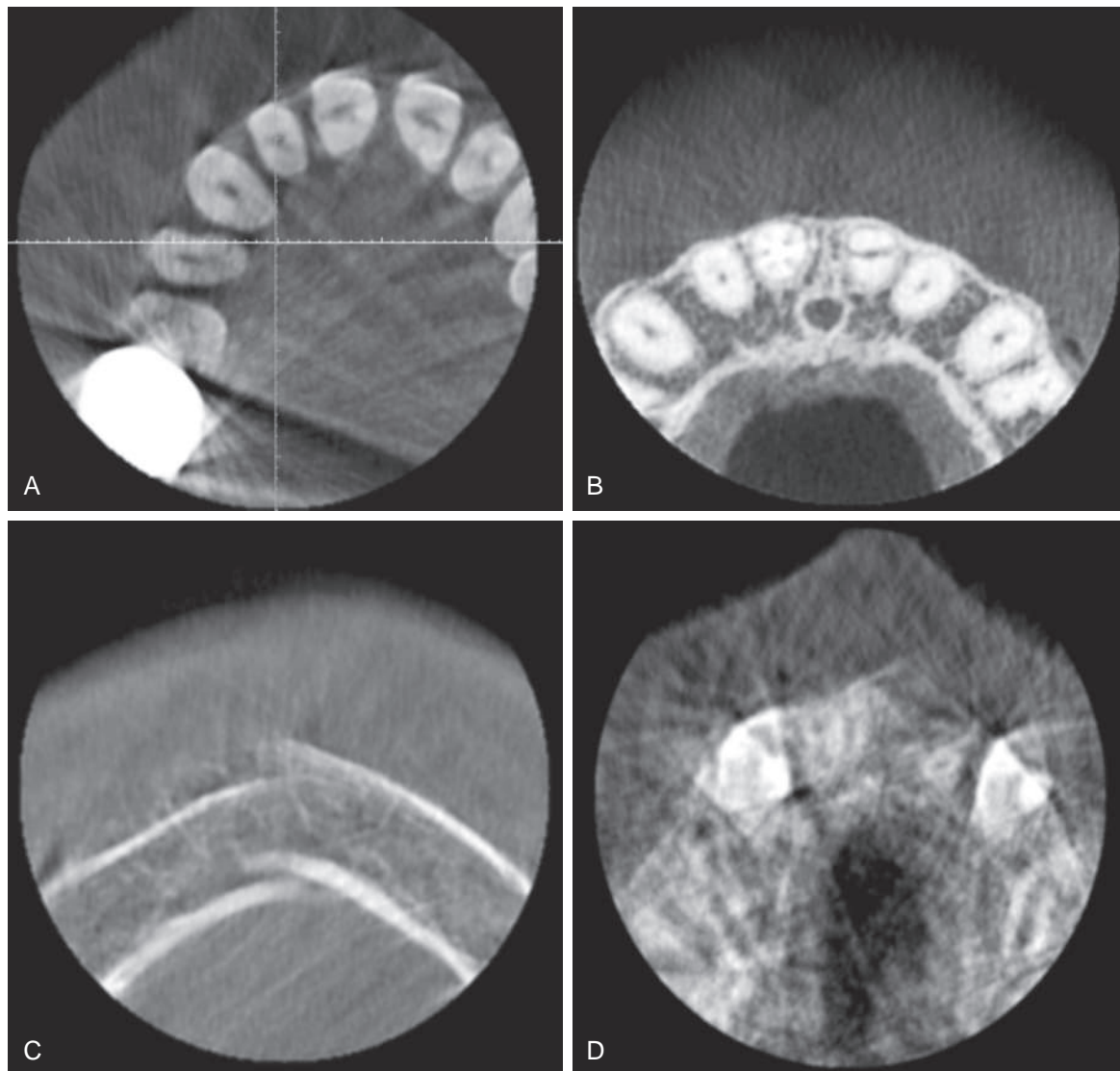
In case one has an image that cannot be diagnosed, the assistance of an oral and maxillofacial radiologist may be advisable. These professionals are well trained and can spend more time evaluating the image. The radiologist's report can subsequently be used by the clinician and/or the pathologist and can be of assistance in developing the treatment or follow-up plan for the patient. Oral and maxillofacial radiologists can make recommendations on the need for additional imaging as well as the imaging techniques that should be used.





**Fig. 2.19** (A) Three-dimensional reconstruction cone beam computed tomography (CBCT), impacted canine causing resorption of the apical third of the lateral incisor. (B) Reconstructed panoramic film CBCT, ectopic eruption of both permanent canines. (C) Three-dimensional reconstruction CBCT (same patient Fig. 2.20B), impacted canine causing resorption of the apical third of the lateral incisor.





**Fig. 2.20** Cone beam computed tomography images. (A) and (B) Illustration of beam-hardening artifacts. Notice the black lines that cross the image and the white streaks near the radiopaque material. (C) and (D) Illustration of patient movement. (C) Notice the apparent broken bone and (D) the non-diagnostic image caused by the patient moving his legs during the exposure.

**TABLE 2.5** Effective Dose from Diagnostic Radiology and Equivalent Background

Examination	Effective dose (mSv)	Equivalent background radiation (days)
<b>INTRAORAL</b>		
Posterior BW (F-speed) (rectangular collimation)	0.005	0.6
FMX (rectangular collimation)	0.035	4
FMX (round collimation)	0.171	21
<b>EXTRAORAL</b>		
Panoramic	0.006–0.026	1–3
Cephalometric	0.002–0.066	0.5–1
CBCT I-CAT® (extended view: 16 × 13 cm) 10 y.o.	0.134	13
CBCT Accuitomo® 170 (small view: <40 cm <sup>2</sup> ) 10 y.o.	0.028	2.8
CBCT Kodak 9000 3D (small view: <40cm <sup>2</sup> ) 10 y.o.	0.016	1.6
CBCT I-CAT® Next generation (medium view) 10. y.o	0.063	6.3
CT Head	2	243

*mSv*, millisievert; *BW*, Bitewing; *FMX*, Full mouth radiographic examination; *CBCT*, Cone Beam computed tomography; *CT*, Computed tomography.

Background radiation: 3.1 mSv/year

Mallya and S.C. White, *Oral radiology: principles and interpretation*. 8 ed. 2018, St. Louis: Mosby. xiv, 735 p.

**TABLE 2.6** Guidelines for Prescribing Dental Radiographs<sup>a</sup>**PATIENT AGE AND DENTAL DEVELOPMENTAL STAGE**

Type of encounter	Child with primary dentition (prior to eruption of first permanent tooth)	Child with transitional dentition (after eruption of first permanent tooth)	Adolescent with permanent dentition (prior to eruption of third molars)	Adult, dentate or partially edentulous	Adult, edentulous
New patient* being evaluated for dental diseases and dental development	Individualized radiographic examination consisting of selected periapical/occlusal views and/or posterior bitewings if proximal surfaces cannot be visualized or probed. Patients without evidence of disease and with open proximal contacts may not require a radiographic examination at this time.	Individualized radiographic examination consisting of posterior bitewings with panoramic examination or posterior bitewings and selected periapical images	Individualized radiographic examination consisting of posterior bitewings with panoramic exam or posterior bitewings and selected periapical images. A full mouth intraoral radiographic examination is preferred when the patient has clinical evidence of generalized dental disease or a history of extensive dental treatment.		Individualized radiographic examination based on clinical signs and symptoms
Recall patient* with clinical caries or at increased risk for caries**	Posterior bitewing examination at 6–12-month intervals if proximal surfaces cannot be examined visually or with a probe.			Posterior bitewing examination at 6–18-month intervals	Not applicable
Recall patient* with no clinical caries and not at increased risk for caries**	Posterior bitewing examination at 12–24-month intervals if proximal surfaces cannot be examined visually or with a probe		Posterior bitewing examination at 18–36-month intervals	Posterior bitewing examination at 24–36-month intervals	Not applicable
Recall patient* with periodontal disease	Clinical judgment as to the need for and type of radiographic images for the evaluation of periodontal disease. Imaging may consist of, but is not limited to, selected bitewing and/or periapical images of areas where periodontal disease (other than nonspecific gingivitis) can be identified clinically.				Not applicable
Patient for monitoring of growth and development	Clinical judgment as to need for and type of radiographic images for evaluation and/or monitoring of dentofacial growth and development		Clinical judgment as to need for and type of radiographic images for evaluation and/or monitoring of dentofacial growth and development. Panoramic or periapical examination to assess developing third molars.	Usually not indicated	
Patient with other circumstances including, but not limited to, proposed or existing implants, pathology, restorative/ endodontic needs, treated periodontal disease, and caries remineralization	Clinical judgment as to need for and type of radiographic images for evaluation and/or monitoring in these circumstances				

<sup>a</sup>Data from: American Academy of Pediatric Dentistry: Guideline on prescribing dental radiographs for infants, children, adolescents, and persons with special health care needs. *Pediatr Dent*. 2012;34(5):189–191. Ad Hoc Committee on Pedodontic Radiology. American Academy of Pediatric Dentistry, reference manual, 2012. The selection of patients for dental radiograph examination, American Dental Association and US Food and Drug Administration, *JADA*. 2006;137(9):1304–1312.

**\*Clinical situations for which radiographs may be indicated include but are not limited to:**

**A. Positive Historical Findings**

1. Previous periodontal or endodontic treatment
2. History of pain or trauma
3. Familial history of dental anomalies
4. Postoperative evaluation of healing
5. Remineralization monitoring
6. Presence of implants or evaluation for implant placement

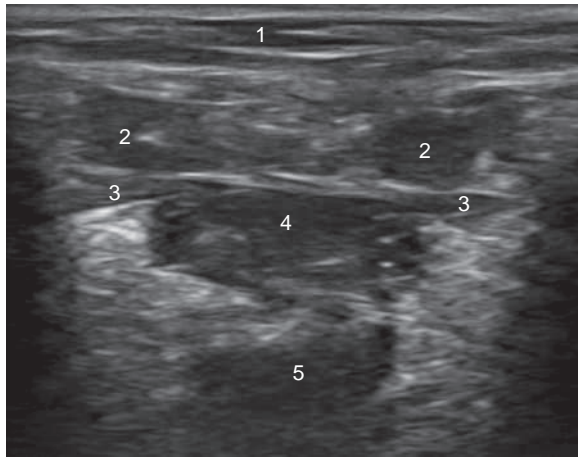
**B. Positive Clinical Signs/Symptoms**

1. Clinical evidence of periodontal disease
2. Large or deep restorations
3. Deep carious lesions
4. Malposed or clinically impacted teeth
5. Swelling
6. Evidence of dental/facial trauma
7. Mobility of teeth
8. Sinus tract ("fistula")
9. Clinically suspected sinus pathology
10. Growth abnormalities
11. Oral involvement in known or suspected systemic disease
12. Positive neurologic findings in the head and neck
13. Evidence of foreign objects
14. Pain and/or dysfunction of the temporomandibular joint
15. Facial asymmetry
16. Abutment teeth for fixed or removable partial prosthesis

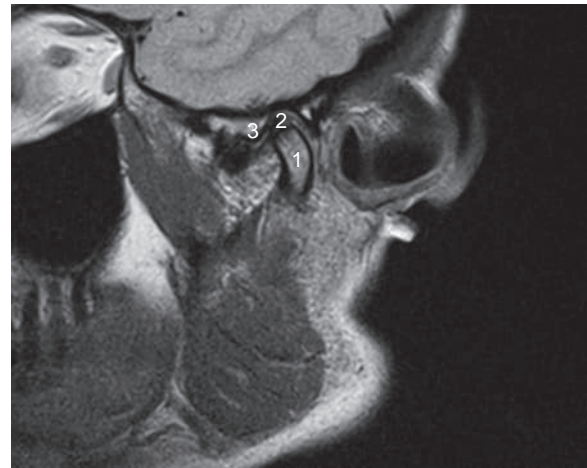
17. Unexplained bleeding
18. Unexplained sensitivity of teeth
19. Unusual eruption, spacing, or migration of teeth
20. Unusual tooth morphology, calcification, or color
21. Unexplained absence of teeth
22. Clinical erosion

**\*\*Factors increasing risk for caries may include but are not limited to:**

1. High level of caries experience or demineralization
2. History of recurrent caries
3. High titers of cariogenic bacteria
4. Existing restoration(s) of poor quality
5. Poor oral hygiene
6. Inadequate fluoride exposure
7. Prolonged nursing (bottle or breast)
8. Frequent high sucrose content in diet
9. Poor family dental health
10. Developmental or acquired enamel defects
11. Developmental or acquired disability
12. Xerostomia
13. Genetic abnormality of teeth
14. Many multisurface restorations
15. Chemo/radiation therapy
16. Eating disorders
17. Drug/alcohol abuse
18. Irregular dental care



**Fig. 2.21** Ultrasound image of the floor of the mouth. The top of the image is the skin under the floor of the mouth, and the bottom of the image is the tongue. (1) Skin and platysma; (2) anterior belly of both digastric muscles; (3) mylohyoid muscle; (4) genioglossus and geniohyoid muscles; (5) tongue.



**Fig. 2.22** Magnetic resonance imaging of the temporomandibular joint: (1) cancellous bone of the condyle (surrounded by a black line, which is the cortical bone); (2) disc of the joint; and (3) articular eminence with the dark line representing the cortical bone, while the white line inferior to that is the fibrous tissue anterior to the articular disc.

## References

- Dental Radiographic Examination: Recommendations for Patient Selection and Limiting Radiation Exposure. ADA Council of Scientific Affairs and US Department of Health and Human Services, Public Health Service, Food and Drug Administration. Revised 2012.
- Tang FR, Loke WK, Khoo BC: Low-dose or low-dose-rate ionizing radiation-induced bioeffects in animal models, *J Radiat Res* 58(2):165–182, 2017.
- Mallya S, Lam E: Oral radiology: principles and interpretation, ed 8, xiv. St. Louis, 2019, Mosby, p 27.
- Ludlow JB, Davies-Ludlow LE, White SC: Patient risk related to common dental radiographic examinations: the impact of 2007 international commission on radiological protection recommendations regarding dose calculation, *J Am Dent Assoc* 139(9):1237–1243, 2008.
- Danforth RA, Herschaft EE, Leonowich JA: Operator exposure to scatter radiation from a portable hand-held dental radiation emitting device (Aribex NOMAD) while making 915 intraoral dental radiographs, *J Forensic Sci* 54(2):415–421, 2009.
- National Council on Radiation Protection and Measurements: *radiation protection in dentistry: recommendations of the national council on radiation protection and measurements. NCRP report*, Bethesda, MD, 2003, National Council on Radiation Protection and Measurements, p 191, ix.
- Yepes JF: Radiation safety and protection in pediatric dentistry: rectangular collimation, *J Indiana Dent Assoc* 95(2):24–27, 2016.
- Parrott LA, Ng SY: A comparison between bitewing radiographs taken with rectangular and circular collimators in UK military dental practices: a retrospective study, *Dentomaxillofac Radiol* 40(2):102–109, 2011.
- Zhang W, Abramovitch K, Thames W, et al.: Comparison of the efficacy and technical accuracy of different rectangular collimators for intraoral radiography, *Oral Surg Oral Med Oral Pathol Oral Radiol Endod* 108(1):e22–e28, 2009.
- Aps JK: Three-dimensional imaging in paediatric dentistry: a must-have or you're not up-to-date? *Eur Arch Paediatr Dent* 14(3):129–130, 2013.
- Aps JK: Cone beam computed tomography in paediatric dentistry: overview of recent literature, *Eur Arch Paediatr Dent* 14(3):131–140, 2013.
- Yepes JF, Booe MR, Sanders BJ, et al.: Pediatric phantom dosimetry of Kodak 9000 cone-beam computed tomography, *Pediatr Dent* 39(3):229–232, 2017.
- Ludlow JB: Regarding "Influence of CBCT exposure conditions on radiation dose", *Oral Surg Oral Med Oral Pathol Oral Radiol Endod* 106(5):627–628, 2008; author reply 628–629.
- American Dental Association Council on Scientific Affairs: The use of cone-beam computed tomography in dentistry: an advisory statement from the American Dental Association Council on Scientific Affairs, *J Am Dent Assoc* 143(8):899–902, 2012.
- American Academy of Pediatric Dentistry: Ad hoc committee on pedodontic radiology. Guideline on prescribing dental radiographs for infants, children, adolescents, and persons with special health care needs, *Pediatr Dent* 34(5):189–191, 2012.
- Espelid I, Mejåre I, Weerheijm K: EAPD guidelines for use of radiographs in children, *Eur J Paediatr Dent* 4(1):40–48, 2003.
- Memon A, Godward S, Williams D, et al.: Dental x-rays and the risk of thyroid cancer: a case-control study, *Acta Oncol* 49(4):447–453, 2010.
- Kullman L, Sane MA: Guidelines for dental radiography immediately after a dento-alveolar trauma, a systematic literature review, *Dent Traumatol* 28(3):193–199, 2012.

## 3

# Acquired and Developmental Disturbances of the Teeth and Associated Oral Structures

JAMES K. HARTSFIELD JR. and LORRI ANN MORFORD

## CHAPTER OUTLINE

### Common Disturbances in Children

#### Dentoalveolar Abscess

#### Cellulitis

### Developmental Anomalies of the Teeth

#### Fusion of the Teeth

#### Concrescence

#### Gemination and Twinning

#### Dens Invaginatus (Dens in Dente)

#### Dens Evaginatus and Talon Cusp

#### Globodontia

### Early Exfoliation of Teeth

#### Hypophosphatasia

#### Cherubism (Familial Fibrous Dysplasia)

#### Gnathodiaphyseal Dysplasia

#### Acrodynia

#### Hypophosphatemia (Familial or X-Linked Hypophosphatemic Rickets or Vitamin D-Resistant Rickets)

#### Cyclic Neutropenia (Cyclic Hematopoiesis)

#### Other Disorders

### Enamel Hypoplasia

#### Hypoplasia Resulting From Nutritional Deficiencies

#### Hypoplasia Related to Brain Injury and Neurologic Defects

#### Hypoplasia Associated With Nephrotic Syndrome

#### Hypoplasia Associated With Allergies

#### Hypoplasia Associated With Lead Poisoning (Plumbism)

#### Hypoplasia Caused by Local Infection and Trauma

#### Hypoplasia Associated with Cleft Lip and Palate

#### Hypoplasia Caused by Ionizing Radiation and Chemotherapy

#### Hypoplasia Resulting from Rubella Embryopathy

#### Molar-Incisor Hypomineralization

#### Treatment of Hypoplastic Teeth

#### Hypoplasia Caused by Fluoride (Dental Fluorosis)

#### Enamel Microabrasion to Remove Superficial Enamel Discolorations

### Pre-Eruptive "Caries" (Pre-eruptive coronal resorption of the pre-eruptive intracoronary radiolucency)

### Taurodontism

### Inherited Defects of Dentin

#### Dentinogenesis Imperfecta (Hereditary Opalescent Dentin)

#### Dentin Dysplasia

### Amelogenesis Imperfecta

### Enamel and Dentin Aplasia

### Supernumerary Teeth (Hyperdontia)

### Agensis of Teeth

#### Anodontia

#### Hypodontia (Oligodontia)

#### Palatally Displaced Canines (PDCs)

#### Dental Agensis and Cancer

#### Ectodermal Dysplasias

#### Dental Treatment in Ectodermal Dysplasias

### Intrinsic Discoloration of Teeth (Pigmentation of Teeth)

#### Discoloration in Hyperbilirubinemia

#### Discoloration in Porphyrin

#### Discoloration in Cystic Fibrosis

#### Discoloration in Tetracycline Therapy

#### Bleaching of Intrinsic Tooth Discoloration

### Micrognathia (Robin Sequence)

### Anomalies of the Tongue

#### Macroglossia

#### Ankyloglossia (Tongue-Tie)

#### Fissured Tongue and Geographic Tongue (Benign Migratory Glossitis)

#### Coated Tongue

#### White Strawberry Tongue

#### Black Hairy Tongue

#### Indentation of the Tongue Margin (Crenation)

#### Median Rhomboid Glossitis (Central Papillary Atrophy of the Tongue)

#### Trauma to the Tongue, Teeth, and Oral Tissues, With Emphasis on Tongue Piercing

### Abnormal Labial Frenum

#### Frenectomy



## Common Disturbances in Children

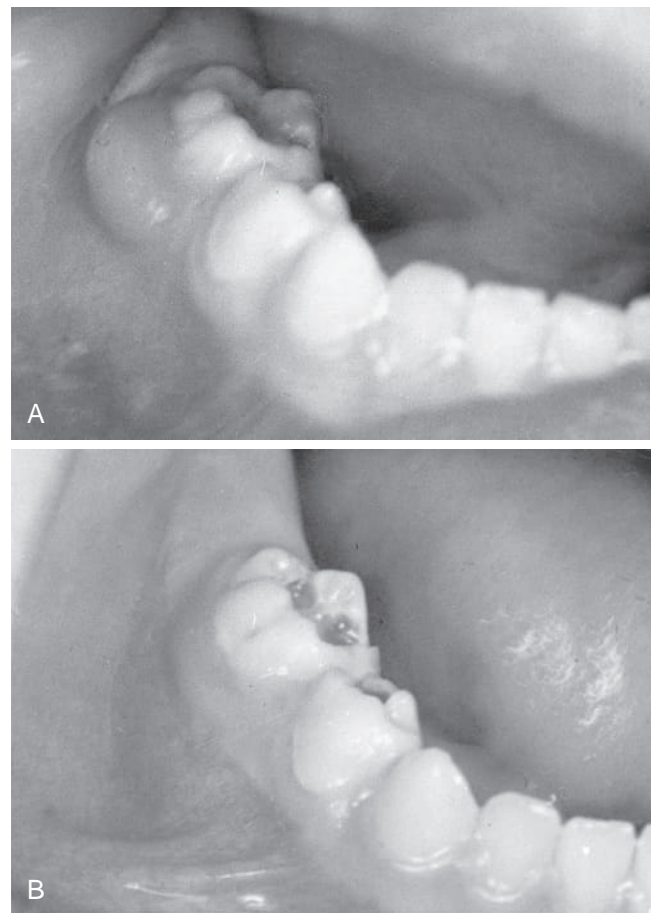
Over the past half century, dental care for children has become more readily available. Caries preventive programs have become increasingly effective, and there has been a steady decline in the incidence and prevalence of dental caries in both primary and permanent teeth among children worldwide (Chapter 10). However, according to the first US Surgeon General's report on oral health in America, published in May 2000, dental caries remains the single most common chronic childhood disease.<sup>1</sup> Moreover, follow-up data gathered on the National Health and Nutrition Examination Survey (2011–2012) has documented how race and ethnic disparities continue to persist when it comes to caries prevention and treatment a decade later in the United States.<sup>2</sup> Periodontal disease is also common; however, this is usually limited to the mild gingivitis experienced by most children. The severe forms of periodontal disease involving bone loss are rare in children and may involve an altered immune function or other mechanism. Both caries and periodontal disease are, for the most part, acquired and preventable diseases of the teeth and jaws. Other chapters of this book are devoted to a more in-depth discussion of the cause, prevention, and management of dental caries (see Chapters 8, 10, 11, 12, and 14) and periodontal disease (see Chapter 15). Another large category of acquired disturbances is injury to the teeth and supporting tissues (see Chapter 28).

Many children have orthodontic conditions that justify corrective treatment, and for some of them the condition is serious enough to be categorized as deforming or even as a disability. Approximately 1 in 1000 children in the United States is born with a cleft lip or palate. These conditions are primarily developmental disturbances and are discussed in greater detail in Chapters 6 and 24.

## Dentoalveolar Abscess

A dentoalveolar abscess may be categorized as acute or chronic and is associated with pulpal necrosis due to infection. In the permanent dentition, this condition usually appears as a well-localized periapical lesion surrounded by a fibrous capsule that is produced by differentiated fibroblasts from the periodontal membrane. The primary tooth abscess is usually evident as a more diffuse infection, and the surrounding tissue is less able to isolate or “wall off” the process. The virulence of the microorganisms and the ability of the host to react to the infection likely determine whether the infection will be acute or chronic.

In the early stages of infection, the acute alveolar abscess may be diagnosed based on radiographic signs of the periodontal ligament/apical space widening. The affected tooth may be sensitive to percussion, movement and/or temperature, and the patient may be febrile, experience migraine pain, and/or encounter a general sensation of unwellness. Accompanying symptoms may also include swelling of the localized gum tissue, lymph nodes, and/or the affected jaw. These symptoms can be alleviated by antibiotic therapy; however, the main tenet of treatment involves removal of the cause of the infection, namely, the necrotic pulp tissue.



**Fig. 3.1** (A) Acute alveolar abscess associated with a pulpless second primary molar. (B) Removal of the roof of the pulp chamber to allow for drainage resulted in immediate relief of pain. After the swelling is reduced, one can decide whether the tooth is to be treated or extracted.

Relief of the symptoms will be more effective if drainage is established (Fig. 3.1A and B) either through the pulp chamber of the tooth (especially in the case of a permanent tooth), by means of the associated gingiva, and/or with the extraction of the tooth. If extraction is selected as the best mode of treatment at the emergency appointment and the patient has an unremarkable medical history, concomitant antibiotic therapy is not always necessary. During this acute infection phase, however, it is often difficult or impossible to establish effective anesthesia for tooth extraction. Since injection of local anesthetic solution into inflamed and infected tissue is likely to be markedly uncomfortable and ineffective, general anesthesia may be required in severe cases. A significant collection of pus, especially with a spreading infection involving the floor of the mouth, or posterior spread that might involve the orbit and cavernous sinus, should be regarded as potentially life-threatening emergencies requiring surgery.

Drainage through the pulp chamber of a primary tooth is almost impossible if subperiosteal pus is present. Drainage through the pulp chamber of a permanent tooth can be established by creating a normal but complete, traditional access cavity and instrumenting the canals to permit drainage of the exudate. The endodontic instrument should not pass the root apex. After initial debridement and irrigation, the opening to

the chamber should be closed unless exudate continues to drain. If pain occurs during the excavation of tooth structure to establish drainage, the discomfort can be lessened if the tooth is stabilized by the dentist's fingers (Fig. 3.1).

A chronic alveolar abscess is less painful and is defined by a more distinct radiographic lesion. Patients who are systemically unwell will also have lymphadenopathy. Draining fistulas are frequently associated with chronic alveolar abscesses. Usually, antibiotic therapy is unnecessary except in patients with an overriding systemic comorbidity (e.g., those patients with organ transplants or who are immunodeficient). Again, drainage and removal of the cause of the infection are necessary through root canal therapy or extraction. If the lesion has only recently passed the acute stage, there may be an indicative soft-tissue abscess with an accumulation of purulent material. In this situation, incision and drainage may be indicated in addition to opening the tooth, especially if the tooth is to be treated endodontically. If the lesion is in an advanced chronic stage, drainage may already be established through a fistula as a natural reaction (Fig. 3.2).

## Cellulitis

Cellulitis is a diffuse infection of the soft tissues that occurs more frequently in younger children. It is caused by primary or permanent pulpal necrosis and is characterized by considerable swelling of the face or neck due to collateral edema and a spreading fascial space infection, causing the tissue to appear dark and brawny.

Cellulitis can be serious and even life threatening. It is usually a result of severe untreated caries in patients who receive irregular, symptomatic dental care or in individuals who may have had dental care only for the treatment of dental emergencies. Such children commonly come to the hospital emergency department, where they appear acutely ill and may have a high fever (greater than 40°C/104°F) with malaise and lethargy. If a maxillary tooth is involved, the swelling and redness may involve the eye (Fig. 3.3A) and, if untreated, may spread posteriorly to involve the brain with an abscess or cavernous sinus thrombosis. Cellulitis resulting from an infected mandibular tooth will spread to the floor of the mouth along the fascial planes. A rapidly progressive form of cellulitis involving submandibular, sublingual, and submental spaces is termed *Ludwig's angina* (Fig. 3.4). Ludwig's angina is a serious condition which requires early airway management since the tongue and floor of the mouth become elevated to the extent that the patient's airway can become obstructed, making breathing and swallowing nearly impossible. Signs that a patient's airway could be compromised include drooling, a muffled or hoarse voice, and/or a high-pitched wheezing due to disrupted airflow (stridor). This condition can be fatal, with mortality being observed in 8%–17% of cases in spite of antibiotic therapy<sup>3–6</sup>; often due to sudden asphyxiation caused by empyema, mediastinitis, pneumonia, airway obstruction, and/or multiorgan failure resulting from sepsis.<sup>3,5</sup> Dental disease of the mandibular second or third molars is a common cause for this condition<sup>3,4</sup>, other triggers may include a floor of the mouth injury or laceration, fractures of the mandible, tongue injury, oral piercing, osteomyelitis,

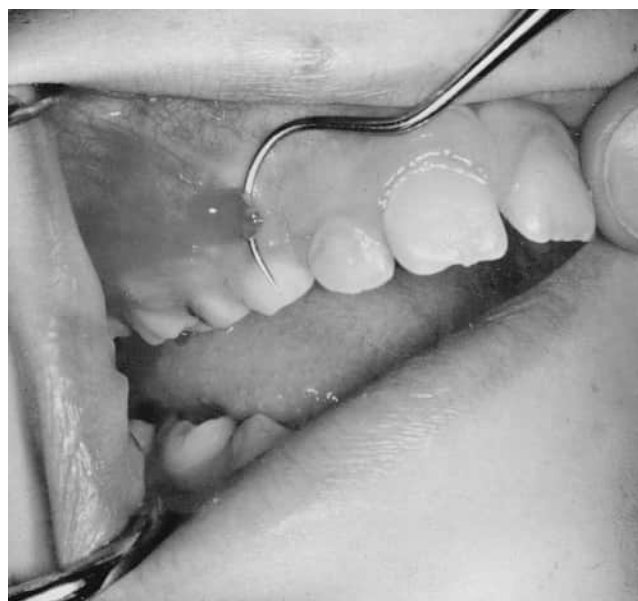

Fig. 3.2 A pedunculated granulomatous lesion overlying the canine but associated with a chronic draining alveolar abscess of the maxillary right first primary molar.

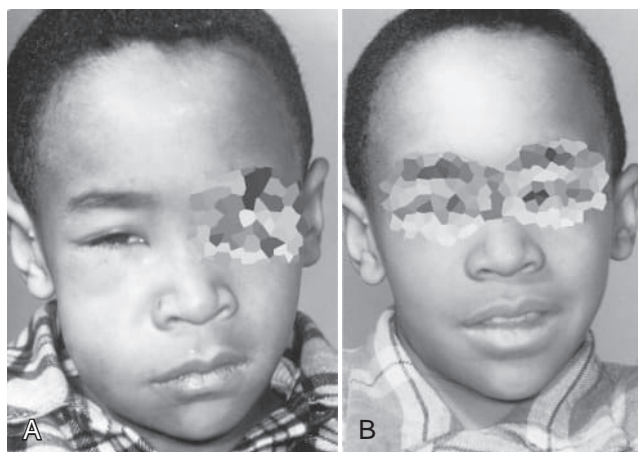
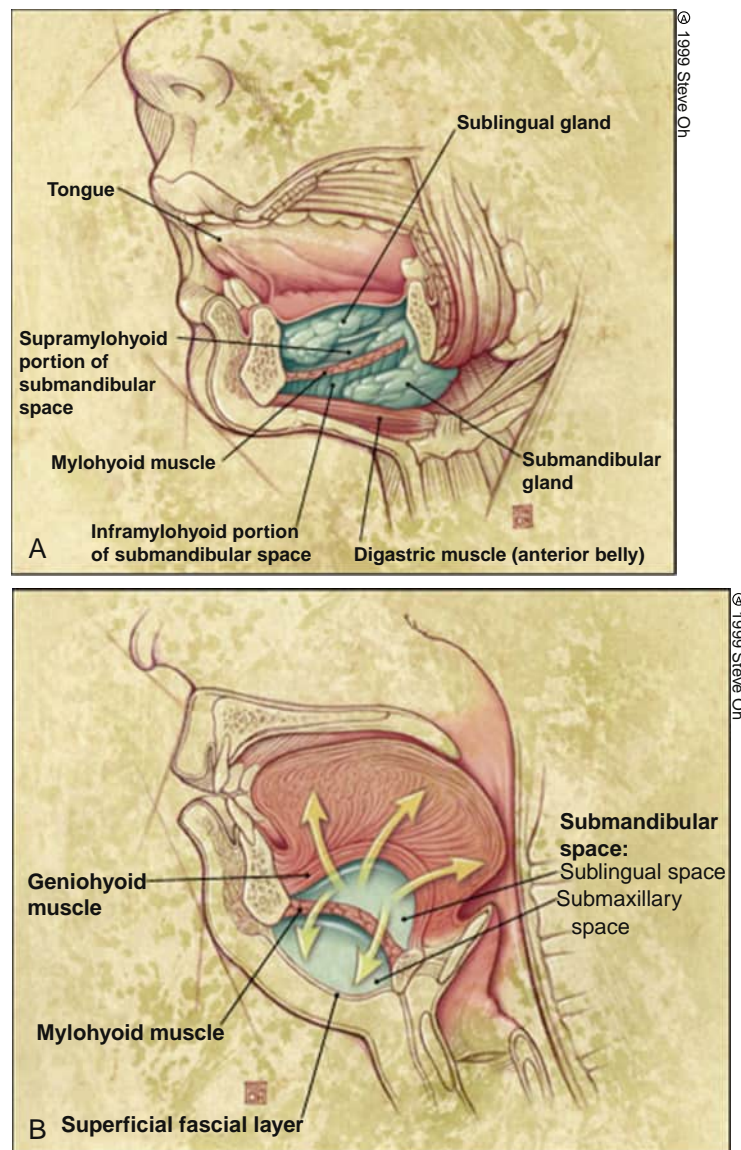


Fig. 3.3 (A) Patient appears to be acutely ill because of an infected permanent molar and resultant cellulitis. (B) Use of broad-spectrum antibiotics reduced the acute symptoms of the disease and prevented extraoral drainage.

traumatic intubation, peritonsillar abscess, submandibular sialadenitis, and infected thyroglossal cysts.<sup>7</sup> Factors that may predispose a patient to this serious condition include diabetes, oral malignancy, dental caries, alcoholism, malnutrition, and an immunocompromised status<sup>7</sup> (e.g., organ transplant patient or individual diagnosed with HIV).

Cases of cellulitis usually require extraction of the primary tooth or the establishment of drainage in permanent teeth, when possible, by opening the pulp chamber of the affected tooth. Some children, however, may have difficulty opening their mouth to permit the procedure due to swelling and discomfort. Incision of soft tissue to establish drainage is generally not indicated in the early stages of cellulitis because of the diffuse, poorly localized nature of the infection. Hence, antibiotics are usually indicated for children in these circumstances.





**Fig. 3.4** Impact of Ludwig's angina on a child's oral cavity. (A) Illustration of the anatomical positioning of the sublingual space above the mylohyoid muscle, and the submandibular space below the mylohyoid muscle. (B) Spread of process superiorly and posteriorly elevates the floor of mouth and tongue. A "bull neck" appearance occurs with anterior spread, as the myoid bone limits spread inferiorly. (Illustration by Steve Oh (Copyright 1999).)

The cultures isolated from these dental infections usually contain mixed flora predominantly comprising gram-positive facultative anaerobic microorganisms (*Streptococcus*, *Staphylococcus*, and *Actinomyces*), various anaerobic, gram-negative microorganisms (*Fusobacterium* and *Bacteroides*), and gram-negative rods/mini-rods (*Pseudomonas aeruginosa*, *Haemophilus influenzae*, and *Moraxella catarrhalis*, previously termed *Branhamella catarrhalis*).<sup>3,8,9</sup> Several of these microorganisms, such as certain *Streptococcus* and *Staphylococcus* species, are capable of producing hyaluronidase and/or fibrinolysins that break down the intercellular cementing substance (hyaluronic acid) and fibrin, thus permitting rapid spread of the infection.<sup>10,11</sup> A broad-spectrum antibiotic should be prescribed early to reduce the possibility of the infection localizing and draining on the outer surface of the face (Fig. 3.3B). A penicillin remains the drug of first choice in nonallergic patients. It should be emphasized to the patient and/or parents that antibiotics will not heal

the condition completely and that follow-up treatment of the tooth is essential.

In cases with severe infection, pus or exudate must be taken for culture. Be aware that many anaerobic microorganisms will not be identified in such cultures unless specific tests are performed. Because abscess formation and lymphadenopathy are not commonly observed with Ludwig's angina, it may be challenging to gather samples for bacterial culture. Nonetheless, if the infection does not respond to the initial antibiotic therapy, a second, more appropriate antibiotic, may be selected after the causative organisms have been identified. Molinari<sup>12</sup> has emphasized the continuing emergence of antibiotic-resistant bacterial strains that render many common antimicrobial agents ineffective.

Hospitalization is required for children with severe cellulitis who are not systemically well, those in whom the clinical signs or symptoms warrant close monitoring, or if there is any question as to whether the patient or parents

will follow through with the prescribed treatment. Hospitalization is also essential in any case involving a spreading infection of the floor of the mouth, such as Ludwig's angina, because maintenance of a patent airway may require the assistance of medical personnel. In these severe cases, parenteral administration of antibiotics is recommended.

## Developmental Anomalies of the Teeth

### FUSION OF THE TEETH

*Fusion* (or syndontia) describes the joining of two (or more) independently developing primary or permanent teeth that began from their own unique tooth germs. Fusion leads to the formation of a single large tooth and reduces the total number of visible teeth in the affected arch by one (or more). At the radiographic level, fusion usually affects the length of the teeth from the crowns (enamel/dentin) to the roots (cementum) in such a manner that the fused teeth maintain independent pulp chambers and root canals (Fig. 3.5). When a joining affects only the roots (cementum) of neighboring teeth, the condition is specifically termed *concrecence* (see the corresponding section). Fusions can occur in both the primary and permanent dentitions. Prevalence within the primary dentition varies by ethnicity, with the mean occurrence of 0.53% in Europeans, 1.5% in individuals from Western Indians, and 3.53% in Asian populations.<sup>13</sup> Dental fusion is usually localized to the anterior of the mouth, with the maxillary central and lateral incisors being the most frequently affected teeth. Fusions can occur within families, suggesting a hereditary pattern of occurrence. In rare circumstances, bilateral fusions and triplicate fusions of primary teeth have been observed.<sup>14-18</sup>

Fused teeth are at higher risk of developing dental caries along the line of crown fusion, necessitating the placement of a restoration. Furthermore, a frequent finding when two primary teeth fuse is the developmental absence of one of the corresponding permanent teeth. Consequently, patients with fused teeth often require a multidisciplinary approach for their dental care involving pediatric dentistry, endodontics, surgery, restorative dentistry, and orthodontics. Surgical sectioning and separation of fused teeth may be possible,

and although dentin is exposed, such teeth are easily moved orthodontically without the risk of ankylosis. Although diagnosis may be difficult using traditional radiographic techniques due to the superimposition of adjacent structures or other teeth, cone beam computed tomography is useful in determining the extent and exact location of the fusion.

### CONCRESCENCE

Like "*dental fusions*," *conrescent* teeth grow together after beginning to develop from separate tooth germs. In contrast to "*fusions*" however, *conrescent* teeth only coalesce at the root level (involving solely the cementum) (Fig. 3.6). *Concrecence* typically involves two teeth, and results in

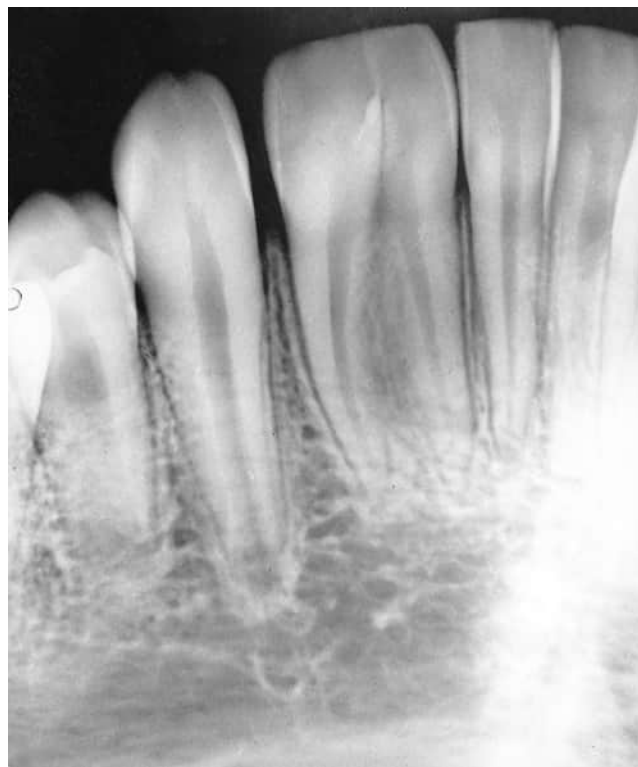


Fig. 3.5 Fusion of a permanent central and lateral incisor.

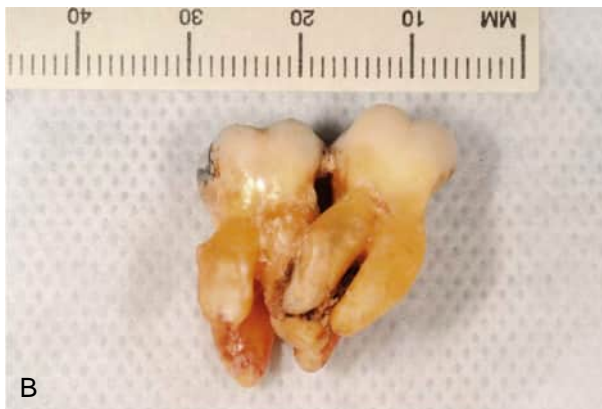
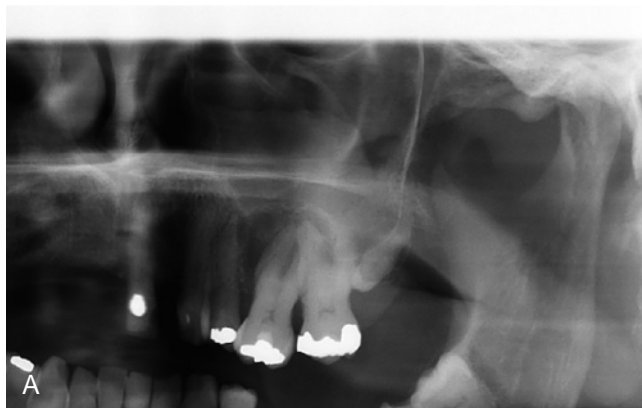
Fig. 3.6 Concrecence illustrated in (A) Cropped panoramic film left maxilla. Noted concrecent of first and second molars and (B) Concrecent left maxillary first and second molars. (Photo post extraction. Palermo D, Davies-House A. Unusual finding of concrecence. Case Reports 2016; 2016: bcr2016214597.)



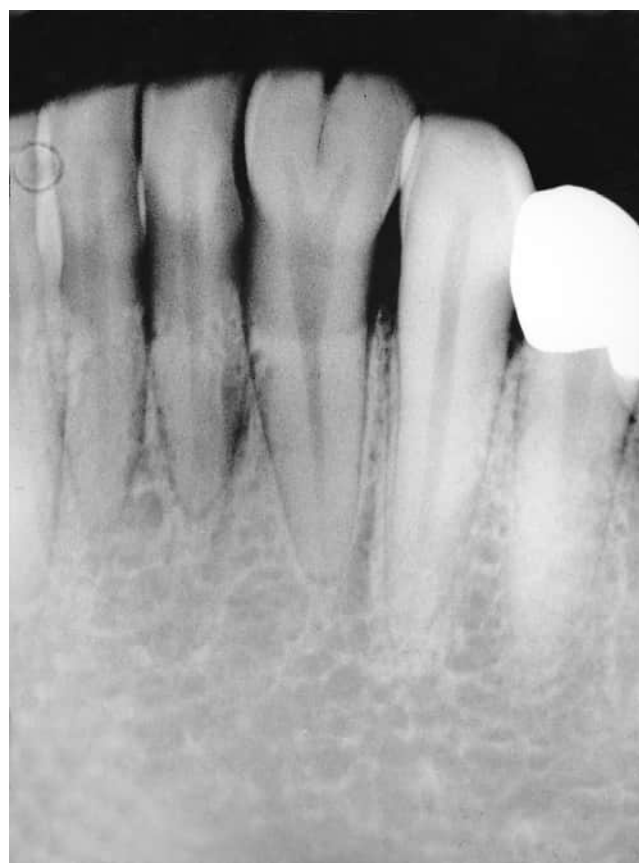the preservation of two clinical crowns each with their own pulp chamber. As such, this condition results in a normal number of crowns being visible in the arch. The most commonly affected teeth are the maxillary molars, with the joining of a second and third molar, or a third molar joining with a supernumerary tooth, although it has also been reported in the mandible.<sup>19–21</sup> Although concrescence typically impacts the development of only two teeth, there have been rare cases noted of triples.<sup>17,18,22</sup>

The exact etiology of this condition is unknown. It has been speculated that localized trauma, excessive occlusal force, restriction of space to grow during dental follicle development, and/or localized infection during and/or after development may play a role.<sup>20</sup> Indications that concrescence may be present include incomplete (or difficulty with) tooth eruption, associated occlusion problems leading to cheek biting and/or the formation of traumatic ulcers in the region, localized periodontal inflammation, and fracture of the maxillary tuberosity and/or the maxillary sinus floor.<sup>20</sup> The presence of concrescent teeth may influence surgical procedures along with periodontal, endodontic diagnosis and treatment. To reduce the risk of complications associated with concrescence, it should be identified with alternation of the treatment plan as indicated.

### GEMINATION AND TWINNING

A geminated tooth must be distinguished from fused or concrescent teeth. Gemination (or “schizodontism”) represents an attempted, but incomplete, division of a single tooth germ by invagination occurring during development. The geminated tooth appears clinically as a bifid crown (having two lobes or parts) on a single root that contains one enlarged or partially divided pulp chamber (Fig. 3.7). The crown is usually wider than normal, with a shallow groove extending from the incisal edge to the cervical region. The prevalence of gemination is variable, generally ranging from 0.1% to 1%.<sup>23–25</sup> This dental anomaly frequently occurs in a unilateral fashion within the anterior portion of the mouth and can be seen in both primary and permanent dentitions; however, it probably appears more frequently in primary dentition.<sup>24</sup> Bilateral gemination is very rare, with a reported prevalence of 0.01%–0.04% and 0.02%–0.05% in the primary and permanent dentitions, respectively.<sup>23,25–28</sup> Like fusions (see the corresponding section), geminations can show a familial tendency but are also likely to be influenced by environmental factors.<sup>24,29,30</sup> In contrast to gemination, “*twinning*” occurs when there is a complete division of a single tooth germ during the proliferation stage which leads to the development of two separate teeth from a single tooth bud, thereby creating an extra tooth within the affected arch.

Some of the clinical challenges that may arise due to gemination many include poor esthetics, dental crowding, a heightened risk of caries, and periodontal problems. The treatment of a permanent anterior geminated tooth may involve reduction of the mesiodistal width of the tooth to allow for normal development of the occlusion. Periodic “*disking*” of the tooth is recommended when the crown is not excessively large, as is eventual preparation of the tooth for restoration if dentin is exposed. However, if the crown is extremely large, the tooth size may be unable to be masked,



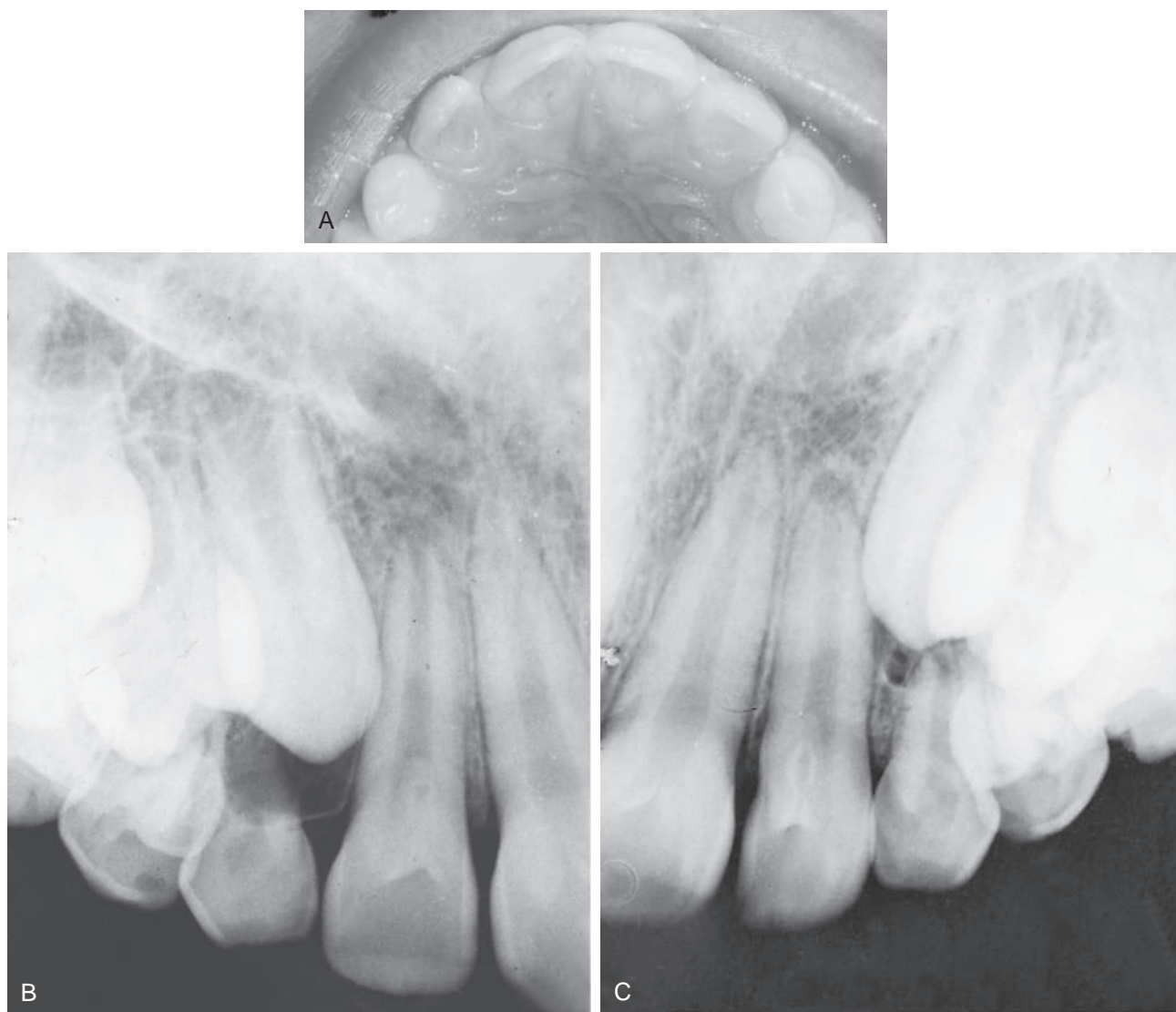
**Fig. 3.7** Gemination of a mandibular lateral incisor. The crown has a groove on the labial surface and is wider than normal.

necessitating removal and a combined orthodontic and prosthodontic approach to rehabilitation.

### DENS INVAGINATUS (DENS IN DENTE)

Dens invaginatus is a developmental irregularity where the enamel organ invaginates into the dental papilla prior to the mineralization of the tooth. This enfolding of a portion of the enamel and dentine layers into the tooth structure creates the appearance of a “tooth within a tooth” (Dens in Dente) radiographically. The invagination is thus lined with enamel and a foramen cecum, with the probability of communication or proximity between the cavity of the invagination and the pulp chamber (Fig. 3.8). This developmental anomaly can occur in both primary and permanent dentitions, with the prevalence estimated at approximately 0.17%–10%.<sup>31,32</sup> Although a greater incidence in males has been reported for the primary dentition,<sup>31</sup> females have been reported to be more commonly affected in the permanent dentition,<sup>33</sup> or that there is no gender difference.<sup>34</sup>

When present, dens invaginatus is observed 80%–90% of the time in the permanent maxillary lateral incisors, followed by maxillary canines or other posterior maxillary teeth, and rarely in mandibular teeth.<sup>31,32,35</sup> The presence of deep lingual pits should arouse suspicion of dens invaginatus, and may be a minimal expression of the developmental anomaly. For example, in a study of 58 families, more than one-third of the parents of children with dens invaginatus had dens invaginatus or deep lingual pits,<sup>36</sup>



**Fig. 3.8** (A) Small, “nonsticky” pits on the lingual surfaces of the maxillary lateral incisors are the only clues to the dens in dente condition of the teeth revealed radiographically in (B) and (C).

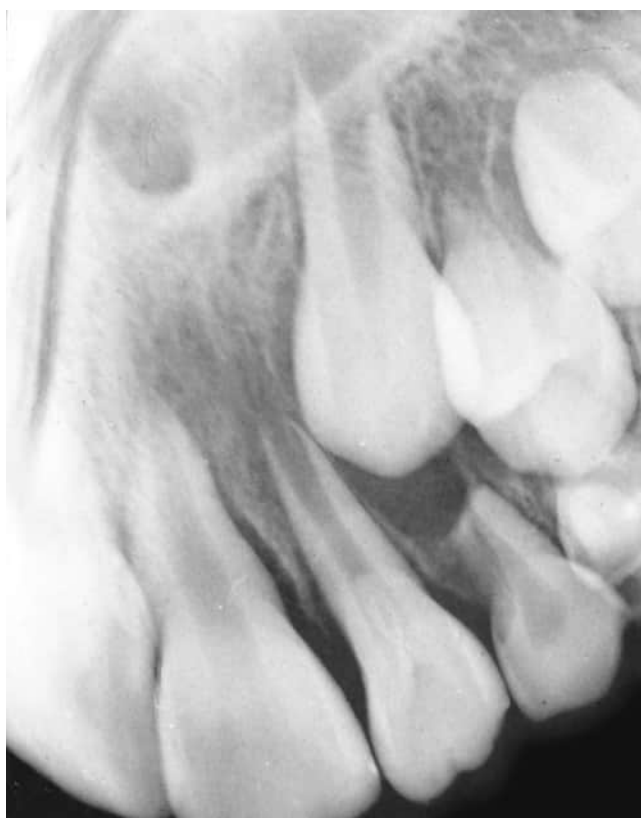indicating autosomal dominant inheritance with variable expressivity and possibly incomplete penetrance (see [Chapter 6](#) for definitions). Although usually a nonsyndromic trait, dens invaginatus has been associated with Williams syndrome in one case<sup>37</sup> (although a study of 45 cases found a variety of dental findings,<sup>38</sup> dens invaginatus was not mentioned), “suspected” in Nance-Horan syndrome (due to an affected female developing two spontaneous abscesses of her noncarious maxillary incisors)<sup>39</sup> and confirmed in a male case,<sup>40</sup> and Ekman-Westborg-Julin syndrome (variable expression of macrodontia in primary/permanent dentition, dental crowding, dens evaginatus, dental impactions, and other anomalies).<sup>41</sup> Recently missense pathogenic variants in the Kinesin Family Member 4A (*KIF4A*) gene have been found in subjects with X-linked taurodontism, microdontia, and dens invaginatus.<sup>42</sup> Unusual cases of dens invaginatus have been reported in a mandibular primary canine, a maxillary primary central incisor, and a mandibular second primary molar. Anterior teeth with dens invaginatus are usually of normal shape

and size. In other areas of the mouth, however, the tooth can have an anomalous appearance. Oehlers’ classification is frequently used to describe variations in the presentation of den invaginatus.<sup>43</sup>

Application of a sealant or a restoration in the opening of the invagination is the recommended treatment to prevent pulpal involvement. If the condition is detected before complete eruption of the tooth, gingival tissue must be removed to facilitate cavity preparation and restoration. A common presentation may be tooth necrosis, and the child may have an acute abscess. The prognosis of such teeth depends on pulp morphology and restorability of the crown ([Fig. 3.9](#)).

### DENS EVAGINATUS AND TALON CUSP

Dens evaginatus is a dental anomaly in which an accessory cusp forms on the occlusal surface on teeth in the posterior ([Fig. 3.10](#)).<sup>44</sup> A dens evaginatus that develops on an anterior tooth is termed a *talon cusp* due to its typical shape resembling the talon of an eagle’s claw ([Fig. 3.11](#)).<sup>44</sup> Up



**Fig. 3.9** Dens in dente in a maxillary lateral incisor. A communication between the invagination and the pulp chamber apparently caused pulpal necrosis.

to 15% of Native Alaskan Eskimos and North American Indians present with dens evaginatus.<sup>45,46</sup> People of Asian descent (including Chinese, Malay, Thai, Japanese, Filipino, and Indian populations) also have a high incidence of dens evaginatus/talon cusp (0.5%–4.3%).<sup>44,47</sup> Dens evaginatus and talon cusps can form in either the primary or permanent dentitions. Talon cusps develop on the lingual (or buccal) tooth surfaces of the anterior portion of the maxilla more often than the mandible, tend to form near the cemento-enamel junction, and comprise enamel, dentine, and pulp (Fig. 3.12).<sup>48</sup>

Concerning the less frequent mandibular talon cusps, males develop these anomalies more often than females.<sup>47</sup> The majority of mandibular talon cusps (over 90%) appear in the permanent dentition.<sup>47</sup> Talon cusps developing in the adult dentition on the lingual tooth surface(s) (about 68%) are more common than those forming on the buccal/facial surface (30%). Although rare, it has been documented that talon cusps form on both the lingual and buccal sides of a single tooth.<sup>47</sup> While unilateral talon cusps occur with the greatest frequency in the mandible, approximately one-fifth of all cases are bilateral.<sup>47</sup> “Double teeth” occur concurrently with mandibular talon cusps approximately half of the time.<sup>47</sup>

The presence of dens evaginatus may be unaesthetic and interfere with occlusion. This may lead to malocclusion, atypical wear on the occlusal surface of the tooth, and/or fracture in the region of the accessory cusp. If unerupted, it may resemble a compound odontoma or a supernumerary tooth and lead to unnecessary surgery. If the grooves

between the talon cusp and the rest of the tooth are deep, they should be sealed and monitored for caries development. The extra cusp may be gradually reduced periodically with topical fluoride application, with a necessity of endodontic treatment a possibility.<sup>49</sup> Orthodontic treatment may be considered when the extra cusp displaces a tooth or otherwise results in malalignment or infraocclusion of opposing teeth.<sup>47</sup> Ironically, the presence of extra cusps may make an ideal orthodontic correction impossible unless the extra cusp or opposing tooth surface is reduced to allow maximum intercuspation in the posterior or ideal overjet and overbite in the anterior.

## GLOBODONTIA

Globodontia is a trait that affects teeth in the molar and canine fields. Affected posterior teeth are enlarged and have a globular or bulbous appearance often lacking any discernable cusps or major occlusal grooves. Affected canines can also exhibit hypoplastic enamel. Incisors appear to be unaffected by this condition. While this trait can occur in both the primary and permanent dentitions, the primary dentition tends to be more seriously affected. In addition, globodontia has been associated with enflamed or enlarged gingiva and delay in tooth eruption (Fig. 3.13).

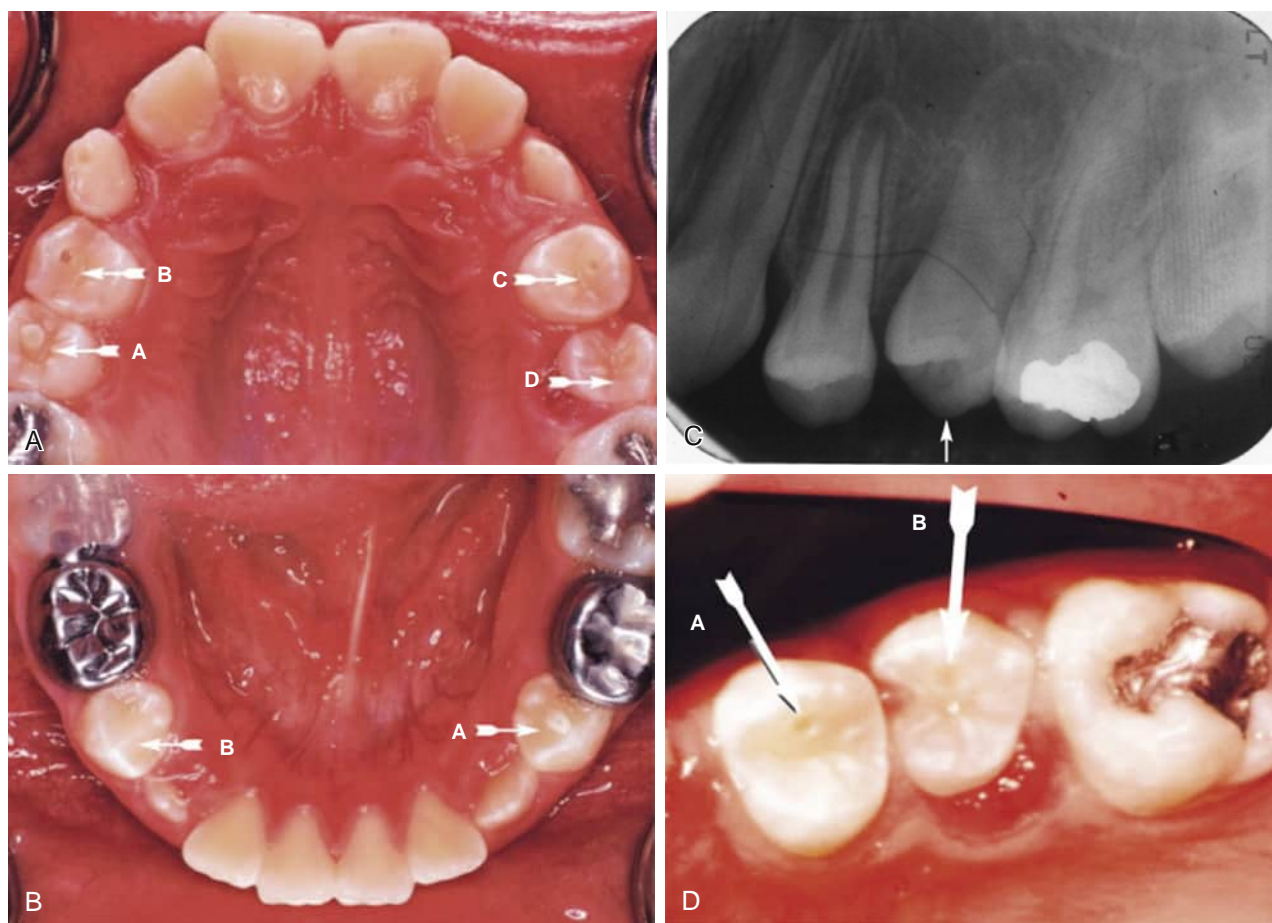
Globodontia is a hallmark feature of a condition called otodontal syndrome (also termed otodontal dysplasia, OMIM # 166750; [www.omim.org](http://www.omim.org)). Otodontal syndrome is a rare autosomal dominant disorder presenting with tooth shape and size irregularities in the posterior dentition (bulbous, pumpkin-shaped teeth), and high-frequency sensorineural hearing loss.

## Early Exfoliation of Teeth

Variations in both the time of eruption and the time of exfoliation of the primary teeth are frequently observed in pediatric patients. A variation of as much as 18 months in the exfoliation time of primary teeth may be considered normal. However, this pattern must be consistent with other aspects of dental development. Exfoliation of teeth in the absence of trauma in children younger than 5 years of age merits special attention because it can be related to local or systemic pathology.<sup>50</sup>

Early exfoliation of primary teeth due to periodontitis is uncommon and demands investigation (see [Chapters 5 and 15](#)); along with hypophosphatasia, it appears to be the most common cause of premature exfoliation of the primary teeth. Based on the 2017 World Workshop for the Classification of Periodontal and Peri-Implant Diseases and Conditions, most cases that were previously defined as “localized aggressive periodontitis” (also termed “early-onset,” “prepubertal,” and “juvenile” periodontitis)<sup>51</sup> will now be classified as stage III grade C periodontitis (Figs. 3.14–3.16).<sup>52,53</sup> Although this new III.C designation describes a severe disease state with a rapid rate of disease progression, be aware that the same designation applies to a diverse group of high-risk periodontal disease conditions such as patients diagnosed with diabetes and/or heavy smokers. Therefore it is important to clinically document the rapid disease progression, early onset in life, and the





**Fig. 3.10** Dens evaginatus observed in the dentition of a female Hispanic patient (9 years and 4 months old). (A) Photographic evidence of dens evaginatus on tooth no. 4 (arrow at A), intraoral appearance of occlusal caries on teeth nos. 5 and 12 at the site of fractured tubercle (arrows at B and C), and white halo on tooth no. 13 (arrow at D). (B) Dens evaginatus presenting as an exaggerated enlargement of the transverse ridge on tooth no. 21 (arrow at A) and a slight enlargement of the transverse ridge on tooth no. 28 (arrow at B). (C) Periapical radiograph of tooth no. 13 (arrow) revealing abnormal root development and periodontal defect on the mesial aspect. (D) The site of occlusal caries (arrow at A) on tooth no. 12 left after the tubercle fractured and the white halo (arrow at B) on tooth no. 13 representing the site of the fractured tubercle. (Reproduced from *The Journal of the American Dental Association*, Vol 133 (Issue 2), Shelly Stecker and Anthony J. DiAngelis, *Dens evaginatus: A diagnostic and treatment challenge*, pages 190-193, Copyright (February 2002) with permission from Elsevier.)

molar/incisor pattern in the patient-specific diagnostic records to facilitate the use of appropriate diagnosis driven treatment planning and interventions. Sub-Saharan Africans and African Americans have a greater incidence, and often familial aggregation. Genetic factors seem to play a role and appear to be heterogeneous.<sup>54-57</sup> More information on aggressive periodontitis, genetics, and epigenetics may be found in [Chapter 6](#).

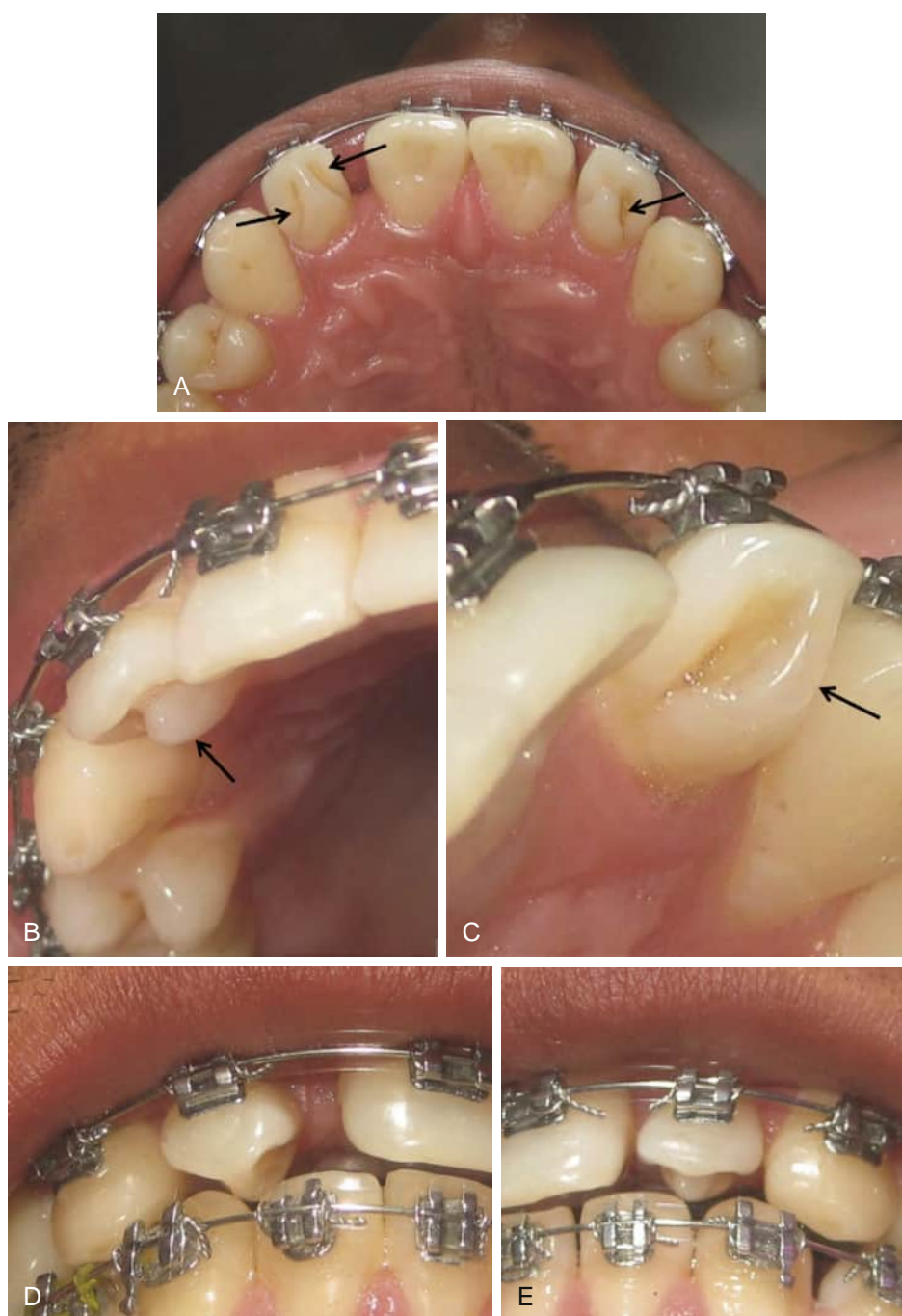
## HYPOPHOSPHATASIA

Hypophosphatasia is a metabolic disorder characterized by improper mineralization of bone due to the absence of enough functional tissue-nonspecific alkaline phosphatase enzyme (ALPL) in the serum, liver, bone, and kidney. Germline DNA variants of pathological significance within the *ALPL* gene are responsible for this enzymatic deficiency. Accordingly, while ALPL plays a vital role in tissue mineralization in healthy individuals, patients diagnosed with hypophosphatasia generate a build-up of phosphoethanolamine, phridoxal 5'-phosphate (vitamin B6) and inorganic pyrophosphate (PPi) levels in both their blood and urine.

This accumulation of extracellular PPi ultimately leads to the incomplete calcification of bones in infants and children (rickets) and osteomalacia in adults. A chief dental finding for children diagnosed with hypophosphatasia is the premature exfoliation of the anterior primary teeth associated with deficient cementum. The loss of teeth in the young child may be spontaneous or may result from a minimal trauma in the absence of gingival inflammation. The loss of alveolar bone may be limited to the anterior region.

The classification of hypophosphatasia includes the usually lethal autosomal recessive infantile type (OMIM #241500, [www.omim.org](http://www.omim.org)), the autosomal recessive milder juvenile type (OMIM #241510, [www.omim.org](http://www.omim.org)), and the autosomal dominant or autosomal recessive adult type (OMIM #146300, [www.omim.org](http://www.omim.org)). These are all due to different variants of pathological significance and heterozygosity versus homozygosity in the *ALPL* gene. Hu et al.<sup>58</sup> state that, as a general rule, the earlier the appearance of the disease, the greater its severity. Early exfoliation of the primary teeth is usually associated with the juvenile type, although loss of permanent teeth along with enlarged pulp chambers and severe dental caries may also be present in



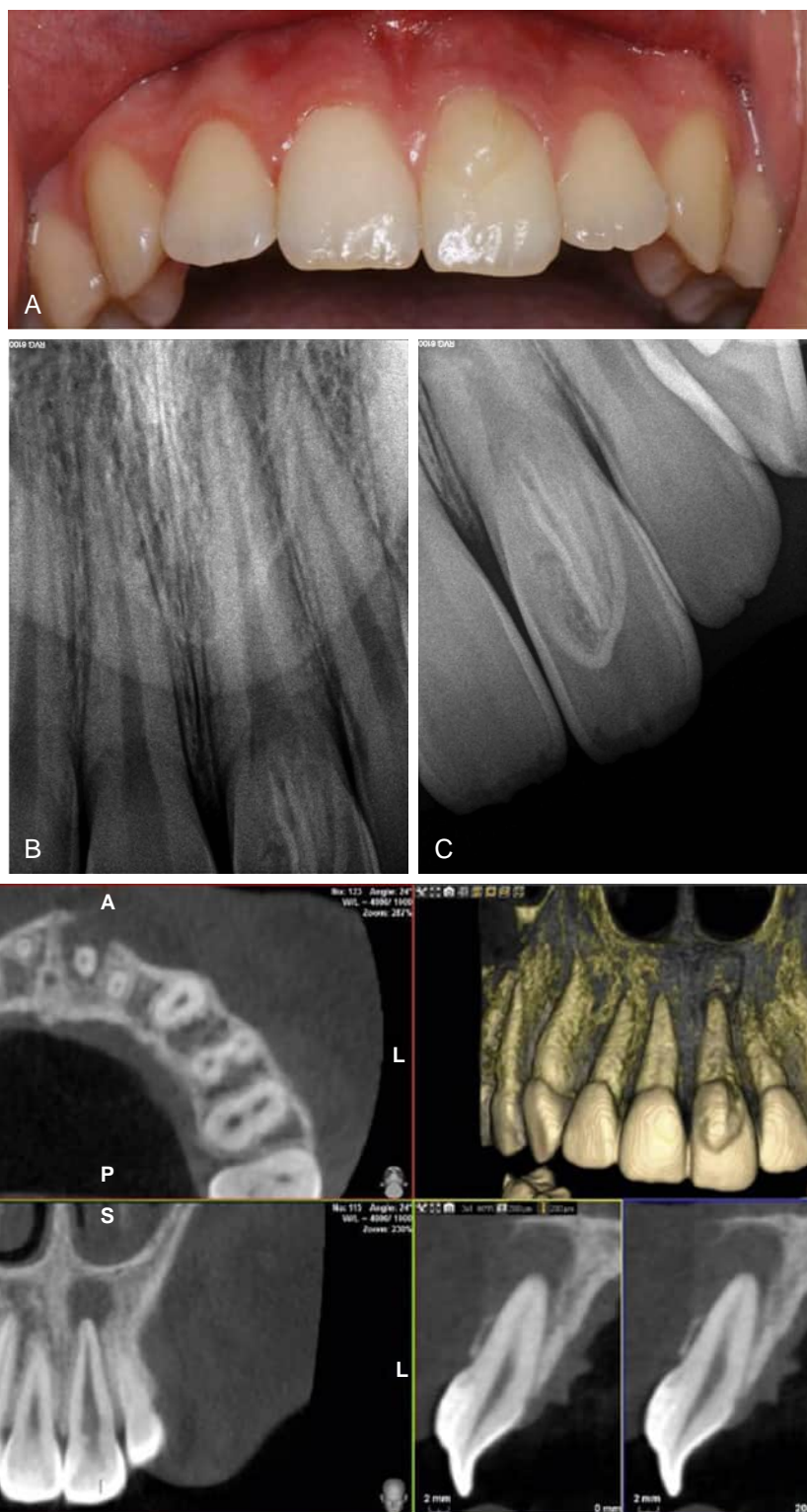


**Fig. 3.11** "Talon cusps" are a subtype of dens evaginatus which received their name based on the resemblance in shape to an eagle's talons. (A–C) Presence of complete talon cusp (black arrows). (D–E) Incisal view showing the contact of talon cusp with the lower anterior teeth. (Reproduced from *Case Reports in Dentistry*, Volume 2016, Article ID 5843231, Ankit Arora, Padmaja Sharma, and Surendra Lodha, Case Report - Comprehensive and Conservative Management of Talon Cusp: A New Technique., <https://doi.org/10.1155/2016/5843231>, (Copyright 2016), with permission Ankit Arora et al.)

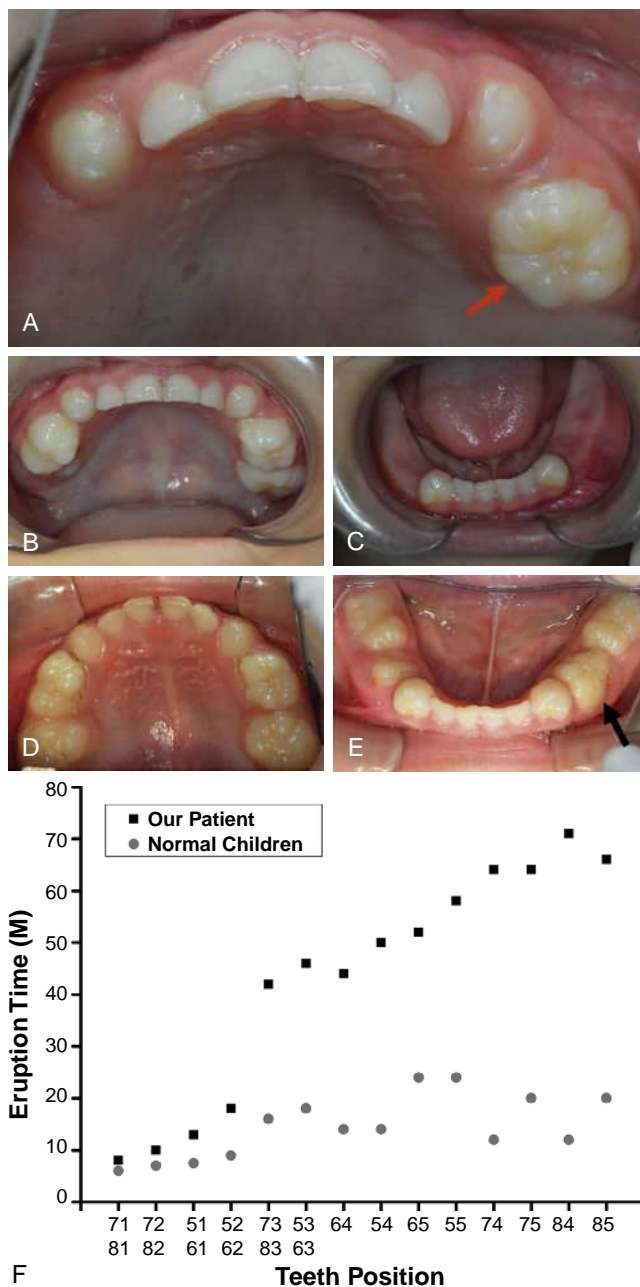
the adult type.<sup>58</sup> In addition, the condition may be non-penetrant in the adult type. Odontohypophosphatasia is also associated with variants of pathological significance in the *ALPL* gene although the phenotype involves the dentition and not the skeleton.<sup>59</sup> Odontohypophosphatasia and hypophosphatasia may occur in the same family.<sup>60</sup> Diagnostic tests should include the determination of serum alkaline phosphatase levels in the patient and family members related by blood. It is important to mention that the measure

of serum alkaline phosphatase in blood must be adjusted to the normal values according to the patient age and gender. The normal values are not the same for a 3-year-old girl as for a 7-year-old boy.

Pseudohypophosphatasia, first described by Scriver and Cameron,<sup>61</sup> is a rare disorder in which the child has the phenotype of juvenile hypophosphatasia and elevated levels of urinary phosphoethanolamine, but plasma alkaline phosphatase activity is normal. However, the clinical findings are



**Fig. 3.12** Dens evaginatus (talon cusp) presenting on the buccal surface of the central incisor of a 16-year-old Caucasian female. (A) Visual examination. (B and C) Intraoral periapical radiograph of dens evaginatus on the incisor. (D) Cone beam computed tomographic (CBCT) sagittal cross-section shows a periapical lesion and the presence of the dens evaginatus. A, Buccal; I, incisal; mm, millimeter; P, palatal; S, apical. (Reproduced from *Journal of Esthetic and Restorative Dentistry*, Vol. 29, Mena-Alvarez J, Rico-Romano C, Lobo-Galindo AB, Zubizarreta-Macho A., Endodontic treatment of dens evaginatus by performing a splint guided access cavity., pages 396–402, (Copyright 2017), <https://doi.org/10.1111/jerd.12314>; with permission from John Wiley and Sons Publisher.)



**Fig. 3.13** Globodontia (with otodontal syndrome): (A) Intraoral views showed abnormal canines and molars at 4 years, (B and C) at 5 years, and (D and E) at 6 years of age. The left maxillary first molar was enlarged like a pumpkin (red arrow). The left mandibular first primary molar (#74) was a little mobile with the accumulation of dental plaque on the buccal and lingual gingival margin, and inflamed and enlarged gingiva (black arrow). (F) Eruption time of primary teeth in the patient with otodontal syndrome compared to that in a normal child. In our patient, delayed eruption of primary canines and molars was observed. M, months. (Reproduced from the original as a two-panel image with permission from *BMC Oral Health* Volume 19, 164, by Su, J., Zeng, S., Ye, X. et al., "Three years of follow-up of otodontal syndrome in 3-year-old Chinese boy: a rare case report," (Copyright 2019), <https://doi.org/10.1186/s12903-019-0860-z>, (<http://creativecommons.org/licenses/by/4.0/>))

similar to those of juvenile hypophosphatasia. Pseudohypophosphatasia occurs when there is alkaline phosphatase activity toward artificial substrates, with a lack of activity toward endogenous substrates, resulting in a clinical picture indistinguishable from that of classic hypophosphatasia.

### CHERUBISM (FAMILIAL FIBROUS DYSPLASIA)

Cherubism (OMIM #118400, [www.omim.org](http://www.omim.org)) is a rare childhood disease affecting jaw development. The children have "chubby" facies and upturned eyes, giving the condition its name. Cherubism is usually inherited as an autosomal dominant trait, with somewhat reduced penetrance in females. The expression may be so variable that a parent who appears to be clinically normal may have a history of prominent facial swellings or radiographic evidence of an abnormal bone pattern in the mandible (Fig. 3.17). Although disease progression is expected to stabilize or even regress after puberty, a few very aggressive cases, sometimes producing morbid results, have been reported.<sup>62</sup> At least four cases of nonfamilial cherubism have been reported, suggesting occasional sporadic occurrences from spontaneous mutations. Cherubism may also be associated with the rare, apparently autosomal recessive, Ramon syndrome (cherubism, eye anomalies, epilepsy, mental deficiency, hypertrichosis, lack of growth, juvenile rheumatoid arthritis, and gingival fibromatosis; OMIM #266270, [www.omim.org](http://www.omim.org)).<sup>63</sup>

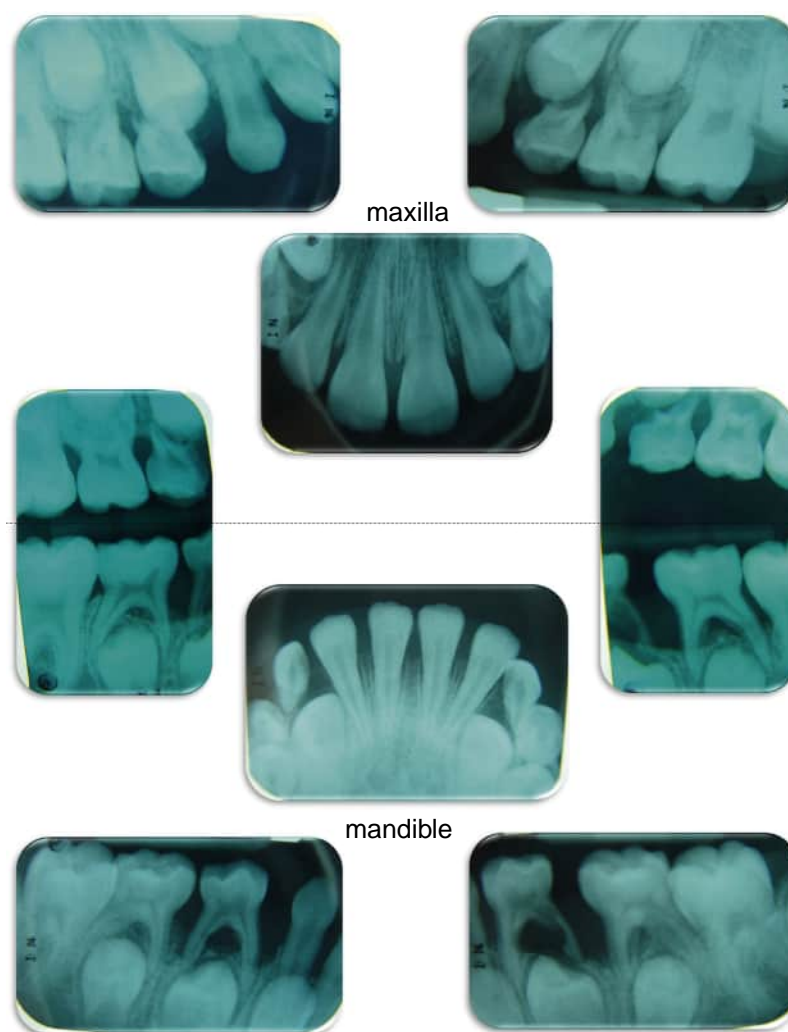
Variants of pathological significance of the SH3 domain-binding protein 2 (*SH3BP2*) gene in patients with cherubism probably result in a gain-of-function or dominant-negative effect that potentiates tumor necrosis factor- $\alpha$  (TNF- $\alpha$ )-induced osteoclastogenesis via nuclear factor of activated T cells 1 (NFATc1) and TNF- $\alpha$ -mediated inflammatory bone loss.<sup>64–66</sup> Characteristically, there is a symmetric enlargement of the jaws that may be noted at an early age. Radiographically, the condition presents multilocular areas of bone destruction (soap-bubble lesions) and thinning of the cortical plate (Fig. 3.18). Teeth in the involved area may exfoliate prematurely because of the loss of support or root resorption or, in permanent teeth, because of interference in the development of roots. Spontaneous loss of teeth may occur, or the child may pull the teeth from the soft tissue. Developing permanent teeth are usually ectopic, being displaced by the growing lesion.

McDonald and Shafer<sup>67</sup> reported a case in which the mandible and maxilla of a 5-year-old girl were symmetrically enlarged. Radiographs showed multilocular cystic involvement of both mandible and maxilla. A complete skeletal survey failed to reveal similar lesions in other bones. Microscopic examination of a segment of bone showed a large number of multinucleated giant cells scattered diffusely throughout a cellular stroma. The giant cells were large and irregular in shape and contained 30–40 nuclei. During a 10-year observation period, the bony lesions had not progressed appreciably.

The patient illustrated in Fig. 3.18 was followed into adulthood, and her mouth was restored satisfactorily. A comparison of the full-face photographs in Fig. 3.18A–I illustrates that as the face increases in height, the "cherubic" appearance caused by the bilateral bulging of the bone of the mandible is less apparent. Seven permanent teeth in the upper and lower arches were retained and prepared for Baker attachments. Complete dentures were constructed to restore function and improve appearance.

Pierce et al.<sup>68</sup> have reported regarding their 15-year dental management of a mother and two daughters with inherited craniofacial fibrous dysplasia. The daughters exhibited





**Fig. 3.14** Images of the severe bone loss around the primary molars of a 9-year-old African American female diagnosed with stage III grade C molar/incisor-pattern periodontitis (previously termed localized aggressive periodontitis or prepubertal periodontitis) in the primary dentition. (Courtesy Dr. Luciana Shaddox.)

clinical and radiographic appearances similar to those of the patient just described, but the authors consider fibrous dysplasia and cherubism to be separate entities. Their treatment of the daughters, though more aggressive, resulted in nearly complete dentitions. Treatment included surgical autotransplantation of several teeth and bony recontouring. Orthodontic therapy was also provided for one child. Orthodontics was recommended for the other child but was declined; her dental alignment was acceptable 3 years after surgery. von Wowern<sup>69</sup> published an extensive review of the literature and a 36-year follow-up of families with cherubism.

### GNATHODIAPHYSEAL DYSPLASIA

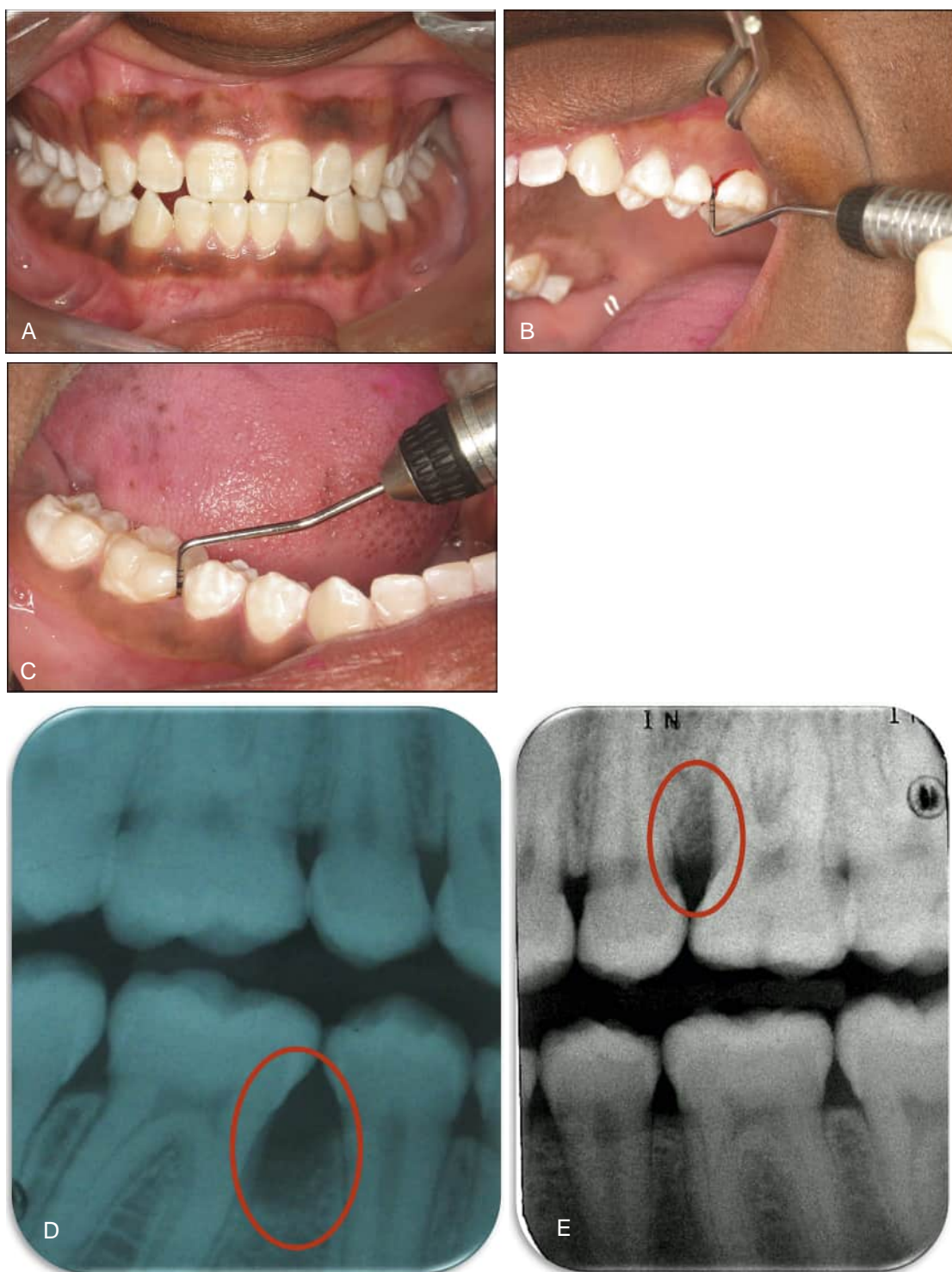
Facial deformity due to enlargement with cemento-osseous lesions and osteomyelitis of the jaws is also associated with gnathodiaphyseal dysplasia (OMIM #166260, [www.omim.org](http://www.omim.org)), an unusual type of osteogenesis imperfecta with autosomal dominant inheritance. The onset is in the first or second decade of life. This condition is related to genetic variants of pathological significance in the anoctamin 5 (*ANO5*) gene.<sup>70</sup>

### ACRODYNIA

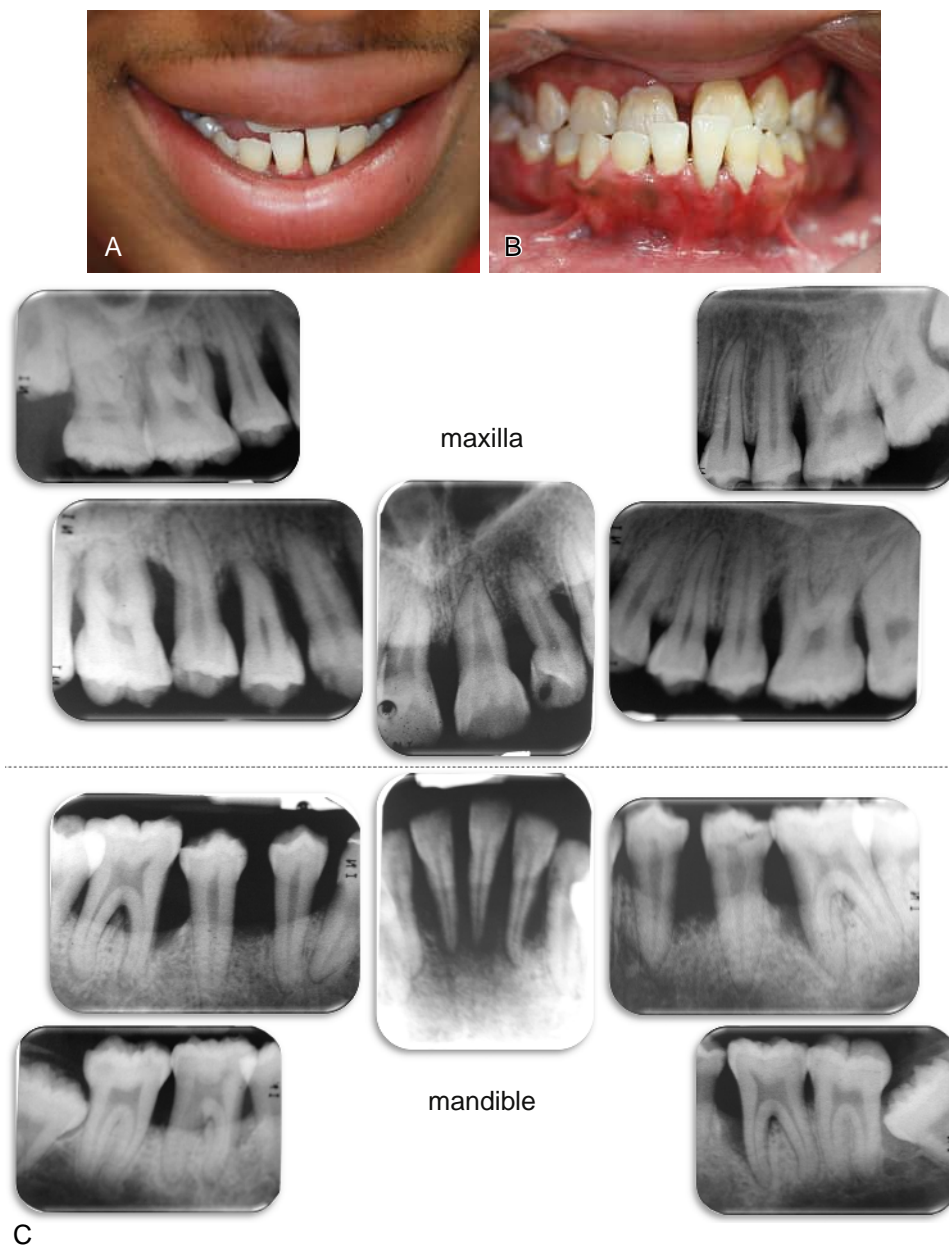
Acrodynia or pink disease results from the exposure of young children to minute amounts of mercury; ointments and medications are the usual sources of the mercury. Weinstein and Bernstein<sup>71</sup> reported on 20-month-old twin girls who came to hospital with the classic signs and symptoms of acrodynia. Further investigation revealed that the girls had been receiving once- or twice-weekly doses of a mercury-containing teething powder during the preceding 4 months. Apparently, such preparations are still available in some countries. Horowitz et al.<sup>72</sup> reported on two young brothers who received a diagnosis of acrodynia after playing repeatedly with a broken sphygmomanometer. Dental amalgam restorations do not cause acrodynia.

Clinical features of the disease include fever, anorexia, desquamation of the soles and palms (causing them to be pink), sweating, tachycardia, gastrointestinal disturbance, and hypotonia. The oral findings include inflammation and ulceration of the mucous membrane, excessive salivation, loss of alveolar bone, and premature exfoliation of teeth.





**Fig. 3.15** Images of a 15-year-old African American male diagnosed with stage III grade C molar/incisor-pattern periodontitis (previously termed localized aggressive periodontitis, or juvenile periodontitis) in the permanent dentition. (A) View of the patient's smile and apparent clinically healthy gingival tissue. (B) Probing of mesial of upper left first molar showing pocket depth of 8 mm with severe attachment loss and bleeding. (C) Probing of mesial of lower right first molar showing pocket depth of 8 mm with severe attachment loss and bleeding. (D) Radiographic findings revealed a U-shaped pattern (circled) of bone loss adjacent to the lower right first molar. (E) Radiographic findings revealed a vertical (circled) bone loss defect adjacent to the upper left first molar. (Courtesy Dr. Luciana Shaddox)



**Fig. 3.16** Images of a 19-year-old African American male diagnosed with stage IV grade C generalized periodontitis (previously termed generalized aggressive periodontitis or early-onset periodontitis) within the permanent dentition. (A) Patient's smile. (B) Patient in occlusion, anterior view. (C) Intraoral periapical series of all teeth showing generalized severe bone loss of most teeth. (Courtesy of Dr. Luciana Shaddox)

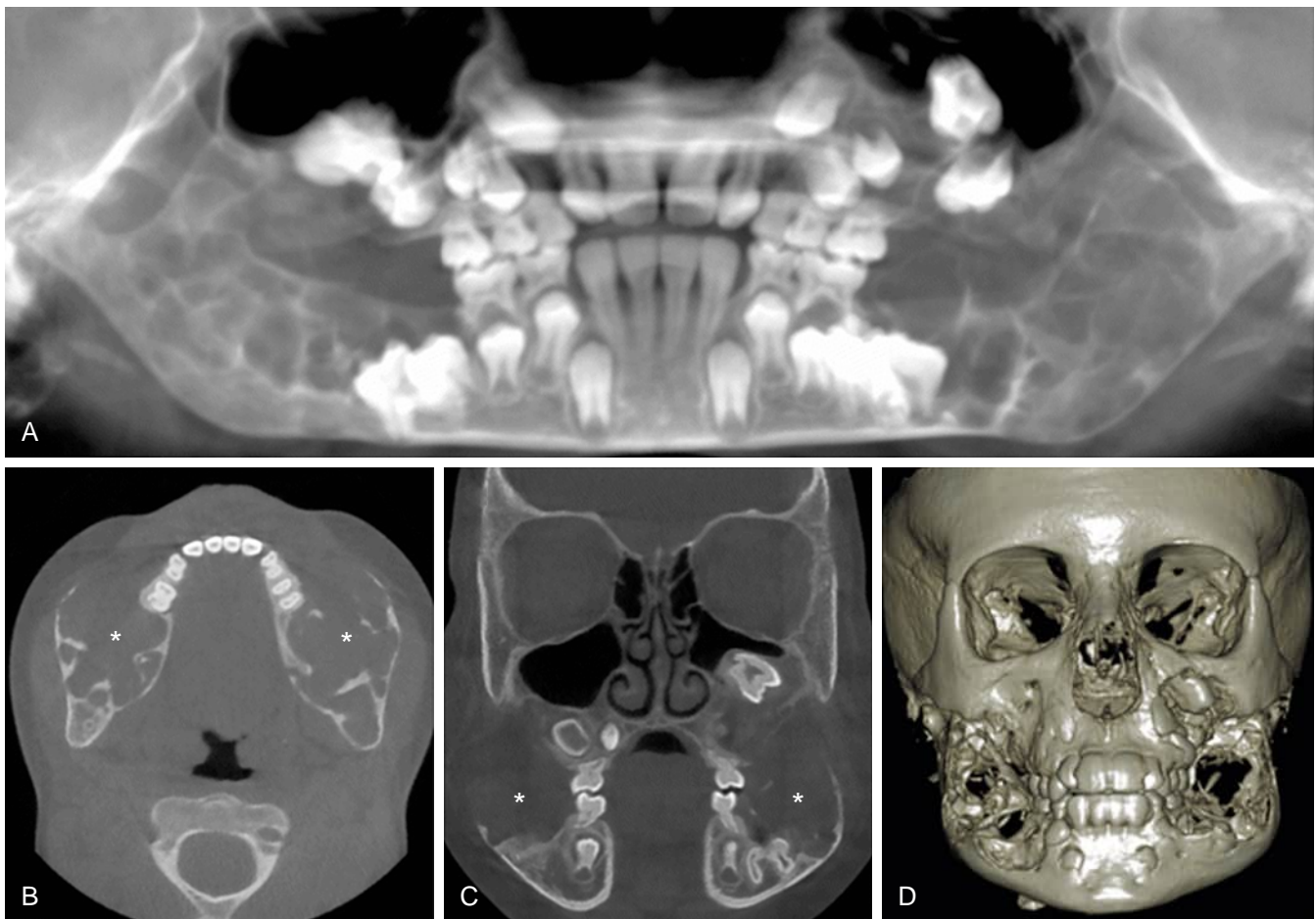
### **HYPOPHOSPHATEMIA (FAMILIAL OR X-LINKED HYPOPHOSPHATEMIC RICKETS OR VITAMIN D-RESISTANT RICKETS)**

Hypophosphatemia (hypophosphatemic rickets) is caused by clinically variable disorders of vitamin D metabolism or action. There is genetic heterogeneity of hypophosphatemia with various autosomal recessive, X-linked dominant, and X-linked recessive forms. Clinical features become evident in the second year of life and include short stature and bowing of the lower extremities in affected boys. Premature tooth exfoliation is sometimes also a feature.<sup>50</sup> The types associated with dental findings have autosomal dominant (OMIM #193100, [www.omim.org](http://www.omim.org)) inheritance involving the *FGF23* gene,<sup>73</sup> or usually X-linked dominant

inheritance (OMIM #307800, [www.omim.org](http://www.omim.org)) involving the phosphate regulating endopeptidase homolog X-linked (*PHEX*) gene on the X chromosome.<sup>74</sup> The incidence is twice as common in females as in males in the X-linked dominant type.

Dental manifestations often include periapical radiolucencies, abscesses, and fistulas associated with pulp exposures in the primary and permanent teeth. Pulpal necrosis is caused by abrasion of the thin, hypomineralized enamel, exposing the pulp horns that extend to the dentinoenamel junction or even to the external surface of the tooth. Dental radiographs show rickety bone trabeculations and absent or abnormal lamina dura.

McWhorter and Seale<sup>75</sup> found that 25% of their patients with vitamin D-resistant rickets (VDRR) were affected with



**Fig. 3.17** An 8-year-old boy with progressive painless and symmetric bilateral facial enlargement. (A) Translucent cone beam computed tomography (CBCT) thick-slab reconstruction shows well-defined bilateral multilocular radiolucencies with deformation and symmetric bilateral enlargement of the mandible and maxilla, and dental abnormalities (displaced permanent teeth and unerupted first molars). (B) Axial and (C) coronal CBCT images show multilocular pseudocystic osteolytic lesions with a few irregular bony septa (*asterisks*), no periosteal reaction, teeth displacement, and inferior alveolar nerve canal invasion. (D) Hypertrophic osteolytic mandibular and maxillary lesions typical of cherub face as seen on the three-dimensional CBCT reconstruction. (Reproduced from the original with permission from *Insights Imaging*, Volume 9, pages 571–589, by Salvatore Stefanelli, Pravin Mundada, et al., "Masses of developmental and genetic origin affecting the paediatric craniofacial skeleton," (Copyright 2018), Springer Nature Publisher, (<http://creativecommons.org/licenses/by/4.0/>))

abscesses in primary teeth. The results of their study indicated that the presence of one abscess is a predictor of future abscesses in the same patient. The authors suggested that early prophylactic treatment of all posterior primary teeth with pulpotomies and stainless-steel crown placement may be the most conservative therapy for a patient with VDRR who develops a spontaneous abscess. However, a follow-up retrospective study by Shroff et al.<sup>76</sup> found the success rate for prophylactic pulpotomies in these patients to be only 44%. They concluded that prophylactic pulpotomy therapy cannot be recommended for patients with VDRR. They suggested that a more aggressive approach involving prophylactic pulpectomy, as previously advocated by Rakocz et al.,<sup>77</sup> may be indicated in these patients and encouraged further investigation in this area.

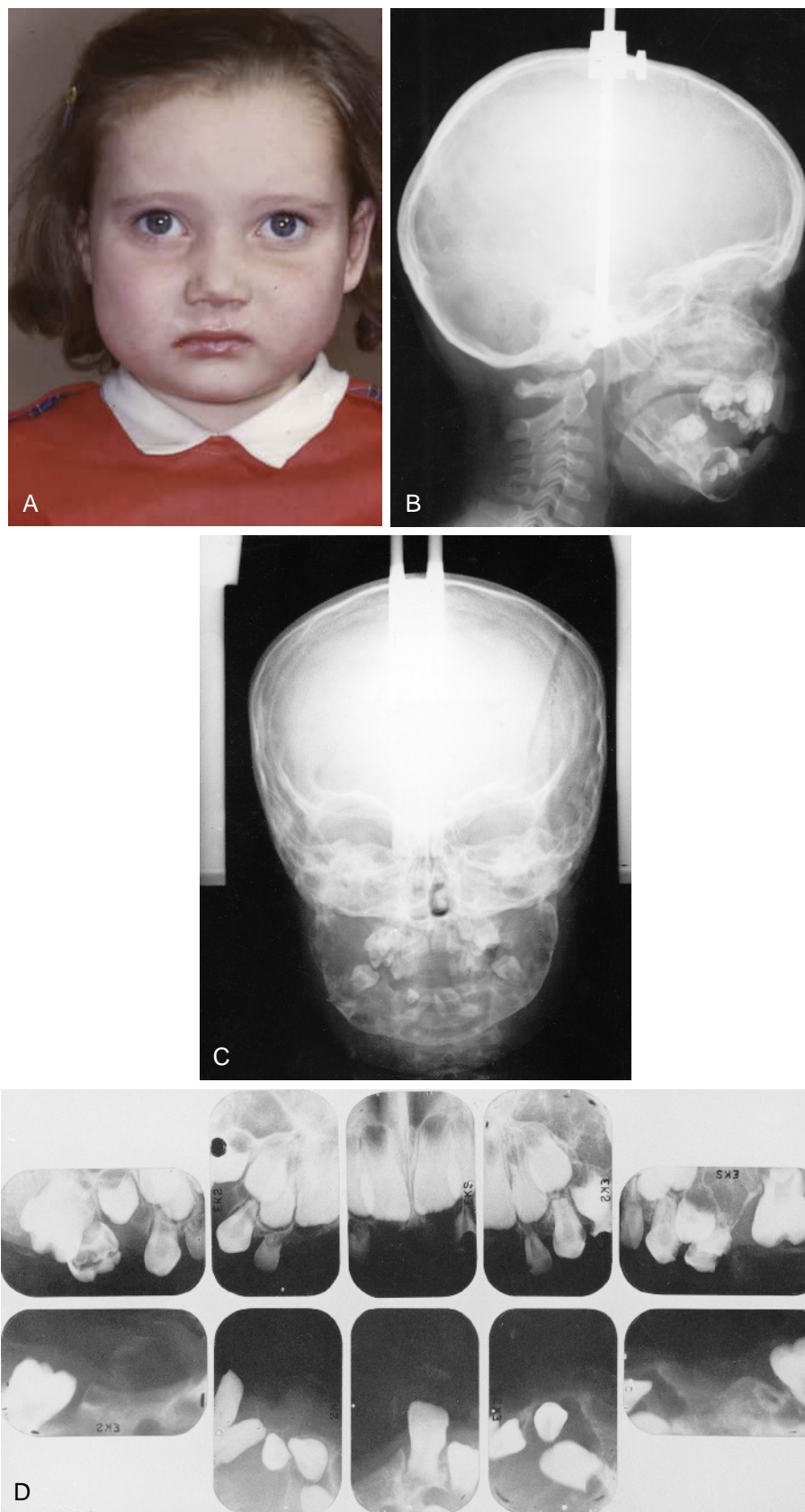
### CYCLIC NEUTROPENIA (CYCLIC HEMATOPOIESIS)

Cyclic neutropenia is an autosomal dominant condition in which affected individuals are at risk for opportunistic infection during intervals of neutropenia that occur in a

21-day cycle concomitant with oscillation in bone marrow blood cell production. Levels of monocytes, platelets, lymphocytes, and reticulocytes also cycle with the same frequency. Although classically the cycle has been reported to be 21 days long, it has also been reported to occur every 15–35 days in 20 cases from five families.<sup>78</sup> Thus the periodicity of the neutropenia and associated oral ulcerations may be of greater diagnostic significance than the actual length of time between manifestations. Horwitz et al.<sup>79</sup> found several different single-base substitutions in the *ELA2* gene encoding neutrophil elastase (also known as leukocyte elastase, elastase 2, and medullasin) in affected individuals and hypothesized that a perturbed interaction between neutrophil elastase and serpins or other substrates may regulate mechanisms governing the clocklike timing of hematopoiesis.

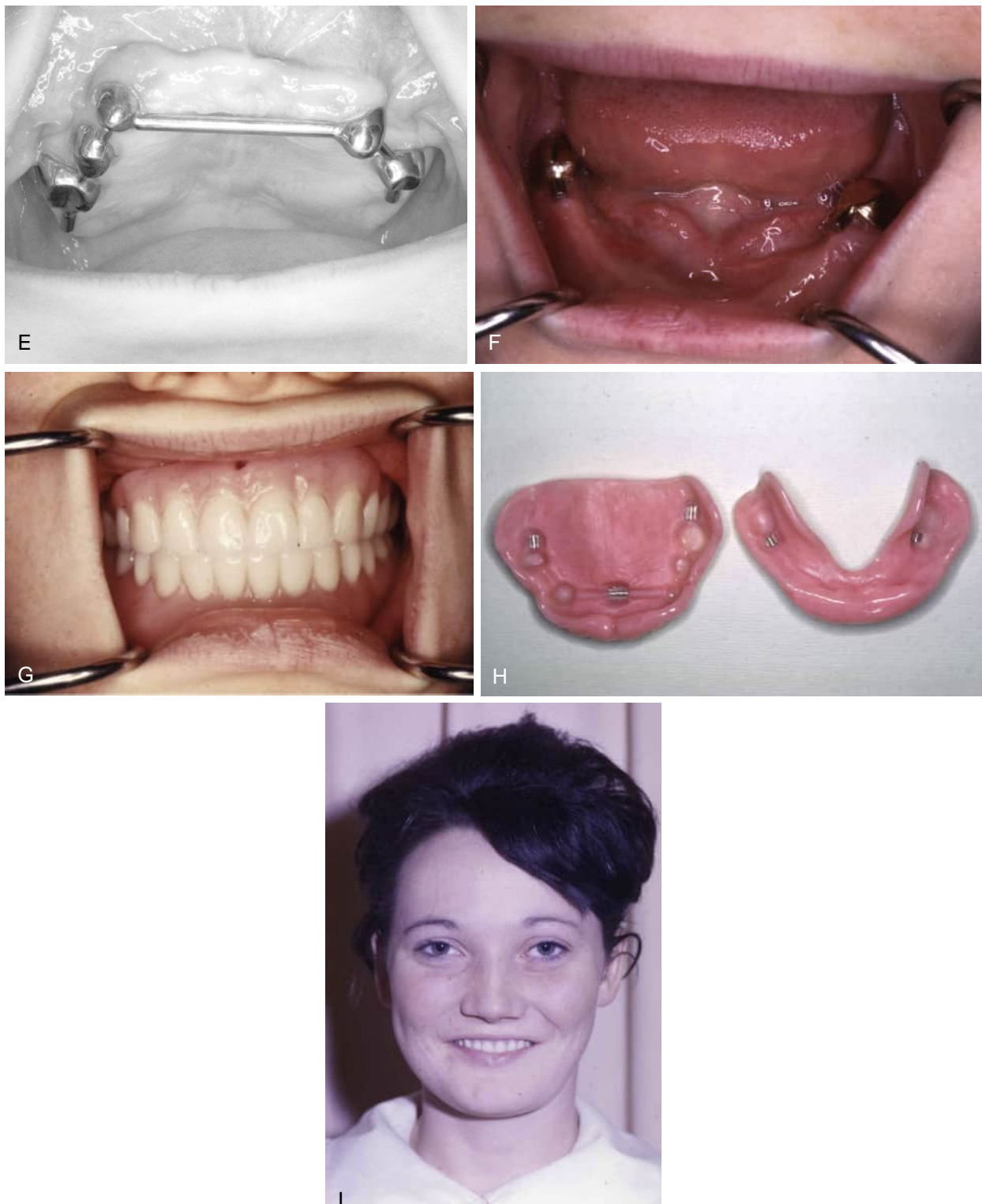
The condition may appear at any age, and numerous cases in children have been reported. The patients have fever, malaise, sore throat, stomatitis, and regional lymphadenopathy as well as headache, cutaneous infection, and conjunctivitis accompanying the neutropenia. Children exhibit severe gingivitis with ulceration. When the





**Fig. 3.18** (A) Enlargement of the cheeks caused by bilateral bulging of the bone of the mandible. (B and C) Lateral and anteroposterior cephalometric radiographs. Notice the displacement of the mandibular anterior teeth in a large area of bone destruction, the locular cystic involvement of the mandible and maxillae, and the number of missing teeth. (D) Full-mouth radiographs demonstrating large areas of bone destruction and several missing teeth.





**Fig. 3.18, cont'd** (E-H) When the patient was 18 years of age, the permanent teeth with good support were prepared for Baker attachments, and complete dentures were constructed. (I) The restored mouth and improved appearance of the adult.

neutrophil count returns to normal, the gingiva may return to a nearly normal clinical appearance. Children experiencing repeated insults from the condition have a considerable loss of supporting bone around the teeth. A case report by da Fonseca and Fontes<sup>80</sup> describes a young woman who had suffered from poor oral health throughout her lifetime, and as she approached 21 years of age, all her remaining permanent teeth were finally removed. Soon after the extractions, her blood counts improved to levels not previously seen by her hematologist. In some children, the condition may disappear during adolescence.

## OTHER DISORDERS

Premature exfoliation due to periodontal disease may be caused by quantitative neutrophil disorders or qualitative disorders, including acatalasia, Chédiak-Higashi syndrome, or leukocyte adhesion defect. Early loss of primary teeth is seen in other systemic conditions, such as Coffin-Lowry syndrome, Down syndrome, Ehlers-Danlos syndrome types IV and VIII, Hajdu-Cheney syndrome, hyperpituitarism, hyperthyroidism, juvenile diabetes, Papillon-Lefèvre syndrome, progeria, Singleton-Merten syndrome, Langerhans' cell histiocytosis (see [Chapter 26](#)), and the leukemias (see [Chapter 27](#)).<sup>50</sup>

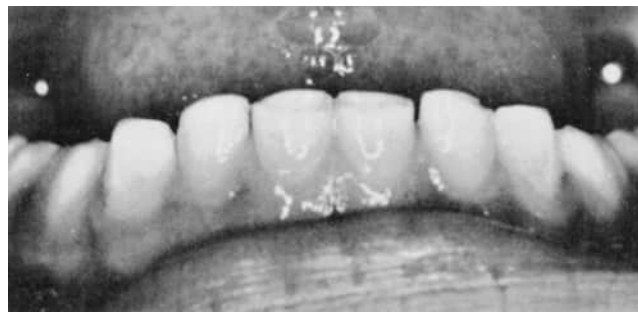## Enamel Hypoplasia

Amelogenesis occurs in three stages. In the first stage, the enamel matrix is secreted by ameloblasts and in the second stage, it undergoes calcification; a final stage of enamel maturation, with crystal growth and removal of water and protein, continues until eruption. Local or systemic factors that interfere with normal matrix formation cause disorders of tooth quantity with enamel surface defects and irregularities termed *enamel hypoplasia*. Factors that interfere with calcification and maturation of the enamel and are disorders of quality are termed *enamel hypocalcification*.

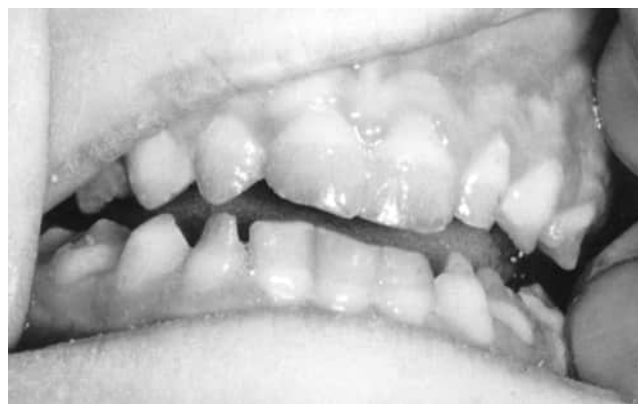Enamel hypoplasia may be mild and may result in a pitting of the enamel surface or in the development of a horizontal line across the enamel of the crown. If ameloblastic activity has been disrupted for a long period, gross areas of irregular or imperfect enamel formation occur. Generalized enamel hypoplasia is often seen as a component of many syndromes. An overview of the types of amelogenesis imperfecta has been provided in [Chapter 6](#).

Postnatal hypoplasia of the primary teeth is probably as common as hypoplasia of the permanent teeth, although the former usually does not occur in as severe a form. The hypoplasia of the primary enamel that occurs prior to birth is less common and usually arises from complications of premature birth ([Fig. 3.19](#)). In its mildest form, a prenatal disturbance is reflected as an accentuated neonatal ring in the primary tooth. In the severe type of neonatal disturbance, enamel formation is sometimes arrested at birth or during the neonatal period ([Fig. 3.20](#)). Postnatal amelogenesis is confined to the portion of the crown located cervically from the enamel area present at birth ([Fig. 3.21](#)).

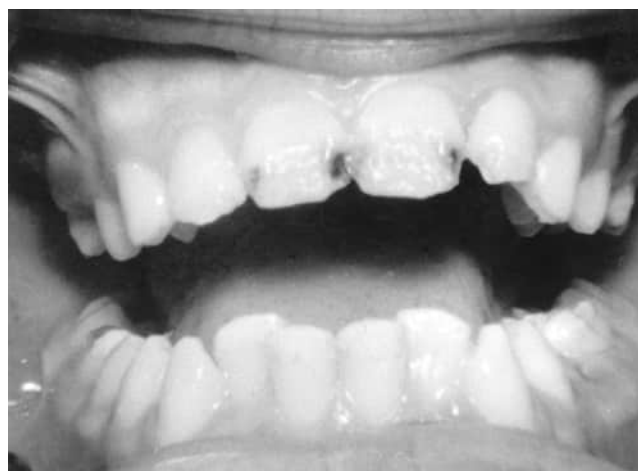Seow et al.<sup>81</sup> have observed that enamel hypoplasia of the primary teeth is common in prematurely born, very low-birthweight children; its pathogenesis is not understood



**Fig. 3.19** Prenatal enamel hypoplasia. The medical history revealed that the patient suffered from cerebral palsy as a result of premature birth (gestation, 6 months; birth weight, 2 lb, 5 oz). (Courtesy Dr. Stanley C. Herman.)

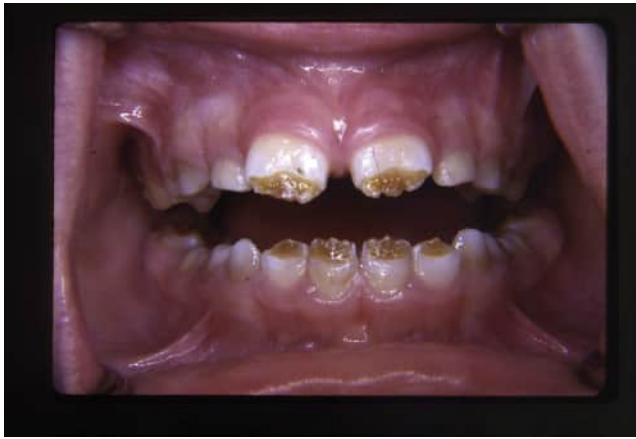

**Fig. 3.20** Neonatal enamel hypoplasia. Only the most cervical parts of the intrinsically stained areas are hypoplastic. The child experienced severe nutritional deficiency during the first month of extrauterine life. (Courtesy Dr. Stanley C. Herman.)



**Fig. 3.21** Enamel hypoplasia that occurred during infancy. A wide band of pitted enamel is evident on the maxillary and mandibular permanent incisors and first permanent molars. The child was severely affected with pneumonia at 6 months of age. (Courtesy Dr. Stanley C. Herman.)

clearly, but it is likely to occur due to neonatal hypocalcemia or hypoxia. An important local factor is trauma from laryngoscopy and endotracheal intubation, which usually results in localized enamel hypoplasia involving only the left maxillary anterior teeth. Slayton et al.<sup>82</sup> examined



**Fig. 3.22** Enamel hypoplasia that developed as the result of a nutritional deficiency during infancy. The first permanent molars, maxillary central incisors, and mandibular incisors show hypoplastic enamel and dentin.

698 well-nourished and healthy children from 4 to 5 years of age and found that 6% had at least one primary tooth with enamel hypoplasia.

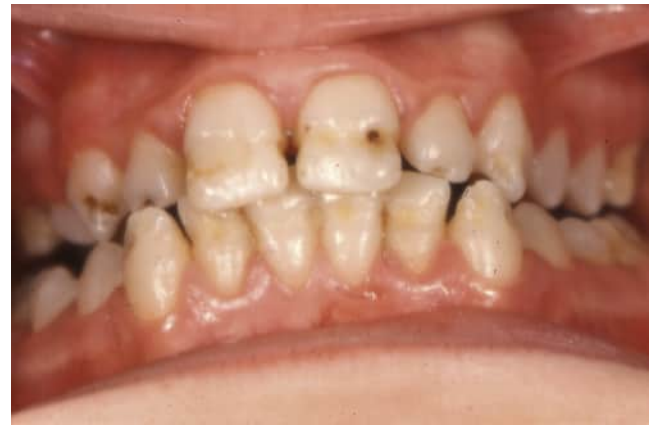### HYPOPLASIA RESULTING FROM NUTRITIONAL DEFICIENCIES

Many clinical investigations have been undertaken to determine the relationship between hypoplastic defects of enamel and systemic disabilities. Relatively little importance has been placed on exanthematous fevers, but deficiency states, particularly those related to deficiencies in vitamins A, C, and D, calcium, and phosphorus, can often be related to the occurrence of enamel hypoplasia.

Sarnat and Schour<sup>83</sup> observed that, in a group of 60 children who had adequate medical histories, two-thirds of the hypoplastic disturbances occurred during infancy (from birth to the end of the first year) (Fig. 3.22). Approximately one-third of enamel hypoplasia was found in the portion of teeth formed during early childhood (13–34 months) (Fig. 3.23). Less than 2% of enamel defects found originated in late childhood (35–80 months).

Sheldon et al.<sup>84</sup> sought to determine whether the defects in enamel were related to the occurrence of systemic ailments. They examined ground sections of 95 teeth from 34 patients for whom detailed medical histories were available. In more than 70% of the individuals, a positive correlation was established between the time of formation of a band of defective enamel and the existence of some systemic disability. However, defects in enamel occurred in 23% of patients who had no history of systemic conditions that might have produced enamel defects. No enamel changes occurred in 6% of patients who had histories of disabilities that had produced enamel changes in other patients. Deficiencies of vitamins A, C, and D, calcium, and phosphorus were the most common causes of defective enamel formation.

In a study of 112 infants with neonatal tetany, Purvis et al.<sup>85</sup> observed that 63 (56%) infants later showed severe enamel hypoplasia of the primary teeth. Histologic examinations revealed a prolonged disturbance of enamel formation in the 3 months before birth. An inverse relationship



**Fig. 3.23** Enamel hypoplasia occurred during early childhood. Enamel formation on the incisal third of the lower incisors and the maxillary central incisors is normal.

was demonstrated between the mean daily hours of bright sunshine in each calendar month and the incidence of neonatal tetany 3 months later. This observation suggested that enamel hypoplasia and neonatal tetany can be manifestations of vitamin D deficiency during pregnancy and are most likely the result of secondary hyperparathyroidism in the mother. A significantly higher mean maternal age and a preponderance of lower social class were also seen in the mothers of those in the tetany group.

In some children, a mild deficiency state or systemic condition without clinical symptoms can apparently interfere with ameloblastic activity and can produce a permanent defect in the developing enamel.

### HYPOPLASIA RELATED TO BRAIN INJURY AND NEUROLOGIC DEFECTS

Herman and McDonald<sup>86</sup> studied 120 children with cerebral palsy between 2.5 and 10.5 years of age (for whom complete medical records were available) to determine the prevalence of dental hypoplasia, and compared them with 117 age-matched healthy children. They observed enamel hypoplasia in 36% of children with cerebral palsy and in 6% of healthy children. A definite relationship between the time of occurrence of the possible factors that could have caused brain damage and the apparent time of origination of the enamel defect (based on its location in the enamel on the crown of the tooth) was established for 70% of the affected teeth of children with cerebral palsy (Fig. 3.19). Evidence of enamel hypoplasia is an aid to the clinician and the research worker in determining when brain injury occurred in patients in whom the cause is not clearly defined.

Cohen and Diner<sup>87</sup> observed that enamel defects occurred with greatest frequency in children with low intelligence quotients and a high incidence of neurologic defects. They found that chronologically distributed enamel defects were a valuable aid in neurologic diagnosis because they occur commonly in children with brain damage. In addition, the defects indicate the time of insult to the developing fetus or infant, even when the history is reportedly negative. Martinez et al.<sup>88</sup> examined 170 children between 4 and 17 years



of age (mean age, 12.03 years) with mental retardation and no history of dental trauma. They found that 37% of these children had dental enamel defects.

### HYPOPLASIA ASSOCIATED WITH NEPHROTIC SYNDROME

Oliver et al.<sup>89</sup> observed enamel hypoplasia in the permanent dentition in a high percentage of children with nephrotic syndrome and found a correlation between the time of severe renal disease and the estimated time at which the defective enamel formation occurred. Similarly, Koch et al.<sup>90</sup> found a high incidence of enamel defects in the primary dentition of children diagnosed with chronic renal failure early in infancy.

### HYPOPLASIA ASSOCIATED WITH ALLERGIES

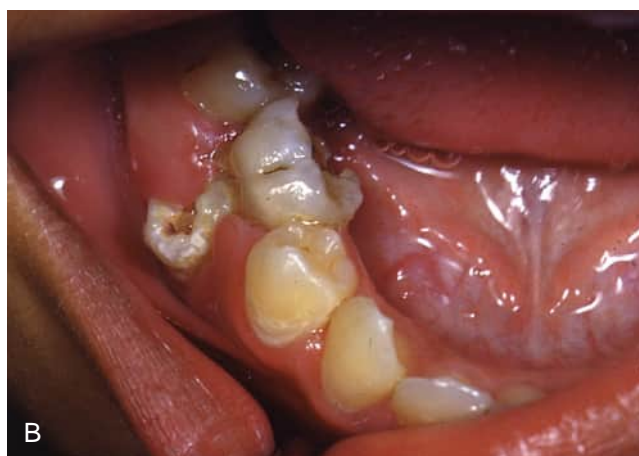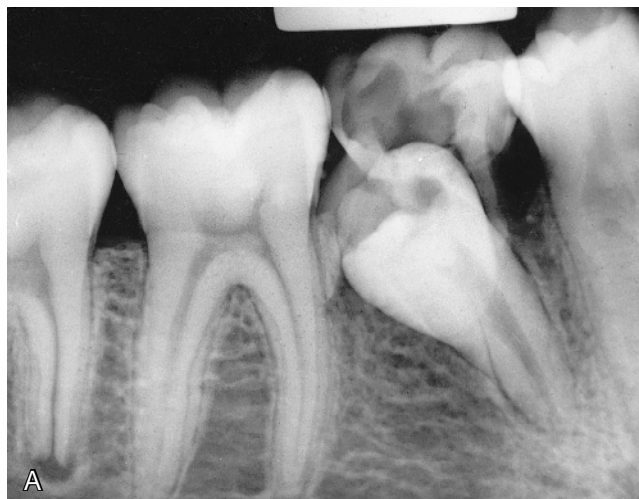Rattner and Myers<sup>91</sup> discovered a correlation between enamel defects of the primary dentition and the presence of severe allergic reactions. Enamel defects were present in 26 of 45 children with congenital allergies. The enamel lesions were localized in the occlusal third of the primary canines and first molars.

### HYPOPLASIA ASSOCIATED WITH LEAD POISONING (PLUMBISM)

In areas of Charleston, South Carolina, where there are very old frame buildings, Lawson et al.<sup>92</sup> observed that the incidence of pitting hypoplasia was approximately 100% greater than published standards or the incidence in their control group of children. They suggested that dentists treating children with unexplained pitting hypoplasia should consider previous exposure to lead as a part of their health evaluation, particularly if the child is from a family of a low economic stratum.

Pearl and Roland<sup>93</sup> have pointed out that the fetus of a mother with lead poisoning can be affected because lead readily crosses the placenta during pregnancy. They observed significant delays in development and eruption of the primary teeth in the child of such a mother. They also listed pica (ingestion of unusual objects to satisfy an abnormal craving) as a common sign of plumbism in children from 1 to 6 years old as well as in their mothers. One mother admitted eating plaster from her apartment walls during several months of pregnancy.

The association between blood lead level and dental caries was evaluated in cross-sectional analyses of baseline data for 543 children 6–10 years old screened for enrollment in the Children's Amalgam Trial. Approximately half of the children were recruited from an urban setting (Boston/Cambridge, MA, USA) and approximately half from a rural setting (Farmington, ME, USA). The mean blood lead level and the mean number of carious tooth surfaces were significantly greater among the urban subgroup members. This association was stronger in the primary than in the permanent dentition and stronger for occlusal, lingual, and buccal tooth surfaces than for mesial or distal surfaces. Interestingly, the blood lead level was not associated with caries in the rural subgroup. This difference might reflect the presence of confounding factors in the urban setting



**Fig. 3.24** (A) Infected mandibular second primary molar has caused hypoplasia of the second premolar and delayed eruption of the tooth. (B) Hypoplasia is evident in the occlusal third of the second premolar.

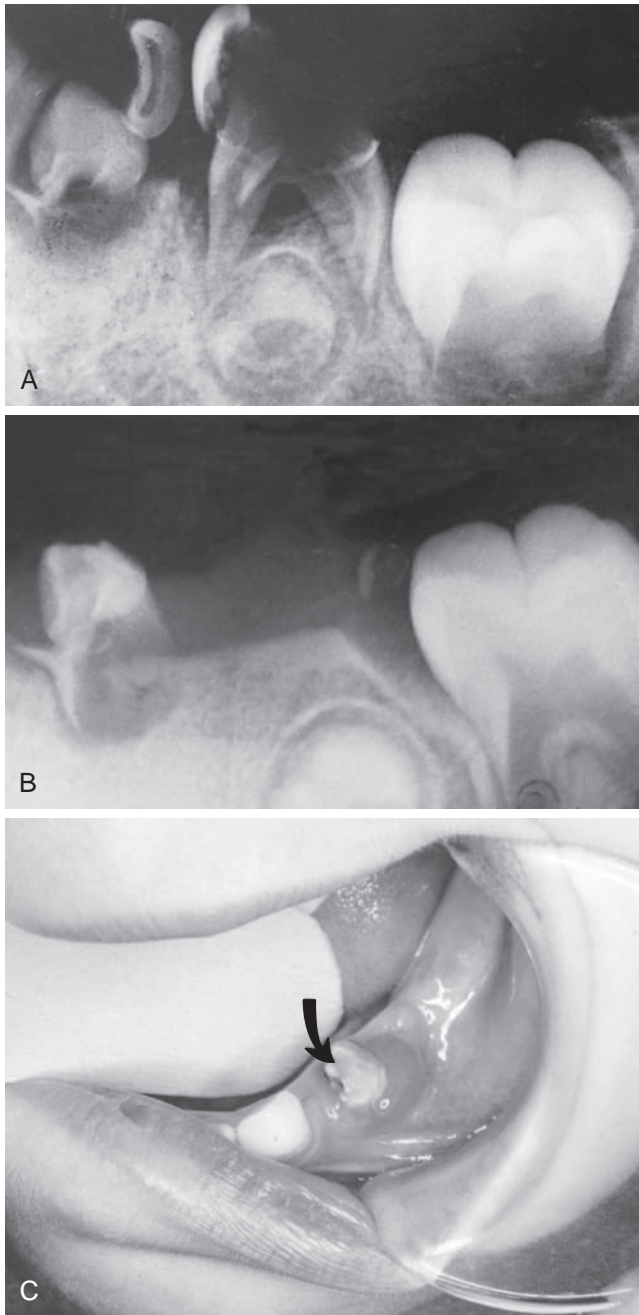
and the presence of greater variability of important caries risk factors (e.g., fluoride exposure) or greater exposure misclassification in the rural setting. These findings add to the evidence supporting a weak association between children's lead exposure and caries prevalence.<sup>94</sup>

### HYPOPLASIA CAUSED BY LOCAL INFECTION AND TRAUMA

Enamel hypoplasia resulting from a deficiency state or a systemic condition will be evident on all the teeth that were undergoing matrix formation and calcification at the time of the insult. The hypoplasia will follow a definite pattern. Individual permanent teeth often have hypoplastic or hypocalcified areas on the crown that result from infection or trauma (Figs. 3.24 and 3.25).

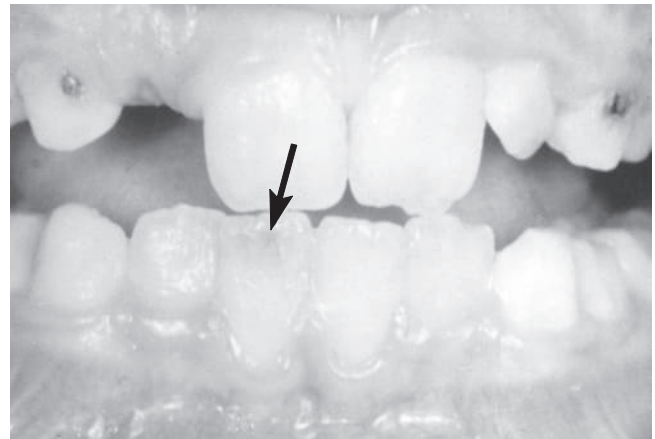
Turner<sup>95</sup> first described this localized type of hypoplasia. He noted defects in the enamel of two premolars and traced the defects to apical infection of the nearest primary molar. Enamel hypoplasia resulting from local infection is called *Turner tooth*.

From a study of autopsy material, Bauer<sup>96</sup> concluded that the periapical inflammatory processes of primary teeth extend toward the buds of the pertinent permanent teeth



**Fig. 3.25** (A) Only a root fragment remains as evidence of a pulpless first primary molar. The infection has affected the development of the first premolar. (B) The second primary molar has been exfoliated prematurely. The first premolar is malformed as a result of the infection in the area. (C) The malformed calcified mass (*arrow*) is surrounded by inflamed tissue.

and affect them during their pre-functional stage of eruption. The infection fails to stimulate the development of a fibrous wall that would localize the lesion. Instead, the infection spreads diffusely through the bone around the buds of the successors and thereby affects the important protective layer of the young enamel, the united enamel epithelium. Bauer found that the united enamel epithelium was destroyed in some cases, and the enamel was exposed to inflammatory edema and to granulation tissue. The granulation tissue later eroded the enamel and deposited a



**Fig. 3.26** Hypoplastic defect on the labial surface of a mandibular permanent central incisor (*arrow*). There was a history of trauma to the primary tooth.

well-calcified, metaplastic, cementum-like substance on the surface of the deep excavation.

A traumatic blow to an anterior primary tooth that causes its apical displacement can interfere with matrix formation or calcification of the underlying permanent tooth. The trauma or subsequent periapical infection frequently produces defects on the labial surface of the permanent incisor (Fig. 3.26). The retention of infected primary teeth, even if they are asymptomatic, is unjustifiable. The development of hypoplastic defects on the permanent tooth, its deflection from the normal path of eruption, and even death of the developing tooth may result.

#### **HYPOPLASIA ASSOCIATED WITH CLEFT LIP AND PALATE**

Mink<sup>97</sup> studied the incidence of enamel hypoplasia of the maxillary anterior teeth in 98 patients with repaired bilateral and unilateral complete cleft lip and palate; the age of the individuals ranged from 1.5 to 18 years. Among them, 66% with maxillary anterior primary teeth had one or more primary teeth affected with enamel hypoplasia and 92% with erupted maxillary anterior permanent teeth had one or more permanent teeth affected with enamel hypoplasia. Mink concluded that the permanent teeth are in earlier stages of development at the time of the surgical procedure and are more subject to damage. However, Vichi and Franchi<sup>98</sup> suggested that dental anomalies, including hypoplasia, probably result from multiple causes. They emphasized the difficulty in understanding the role played by genetic factors, postnatal environment, nutrition, and surgical influences in the development of dental anomalies.

#### **HYPOPLASIA CAUSED BY IONIZING RADIATION AND CHEMOTHERAPY**

Numerous dental abnormalities may result in surviving children who receive high-dose radiotherapy and chemotherapy during the formation of their teeth. Kaste et al.<sup>99</sup> reviewed clinical and radiographic records of 423 survivors of acute lymphoblastic leukemia (ALL). Among these patients, they observed root stunting in 24.4%, microdontia



in 18.9%, hypodontia in 8.5%, taurodontism in 5.9%, and over-retention of primary teeth in 4%. Patients aged younger than 8 years at diagnosis or who received cranial irradiation (in addition to chemotherapy) developed more dental abnormalities than those aged older than 8 years at diagnosis and those who did not receive cranial irradiation. They also noted that the resulting dental defects could affect the survivors' quality of life. The advent of intrathecal chemotherapy has almost eliminated cranial relapse in children with ALL and has reduced the need for cranial irradiation.

Maguire and Welbury<sup>100</sup> point out that, as survival rates for children with cancer improve, the emphasis in therapy has moved from saving children at all costs to saving children at the least cost to the child, and therapy protocols are continually reviewed with this goal in mind.

Children who receive high-dose radiotherapy for the treatment of a malignancy are at risk for developing rampant caries in the irradiated area. The main cause is due to reduced or destroyed major salivary gland function.

Ameloblasts are somewhat resistant to x-radiation. However, a line of hypoplastic enamel that corresponds to the stage of development at the time of therapy may be seen (Fig. 3.27). Radiotherapy will have a more severe effect on the development of the dentin, and root formation will be stunted. Occasionally the development of the permanent teeth will be arrested (Fig. 3.28).

### HYPOPLASIA RESULTING FROM RUBELLA EMBRYOPATHY

Musselman<sup>101</sup> examined 50 children (average age, 2.5 years) with congenital anomalies attributed to *in utero* infection with rubella. Enamel hypoplasia was found in 90% of the affected children compared with only 13% of the unaffected children. Tapered teeth also occurred in 78% of the children with a history of rubella (Fig. 3.29). Notched teeth were present in nine of the affected children and none of the unaffected children.

### MOLAR-INCISOR HYPOMINERALIZATION

It should be noted that interference with dental development at birth, or while the enamel of the permanent first molars and permanent incisors is forming, may result in a qualitative effect on the mineralization of one to four of the first permanent molars with or without involvement of the maxillary and mandibular permanent incisors. This has been referred to as molar-incisor hypomineralization. Although the mechanism(s) remain unclear, possible causes have been reported to include asthma, pneumonia, upper respiratory tract infections, otitis media, antibiotics, dioxins in mother's milk, tonsillitis and tonsillectomy, and exanthematous fevers of childhood.<sup>102</sup>

### TREATMENT OF HYPOPLASTIC TEETH

The contention that hypoplastic teeth are more susceptible to dental caries than are normal teeth has little supporting evidence. Carious lesions do develop, however, in the enamel defects and in areas of the clinical crown where dentin is exposed. Small carious and pre-carious areas may

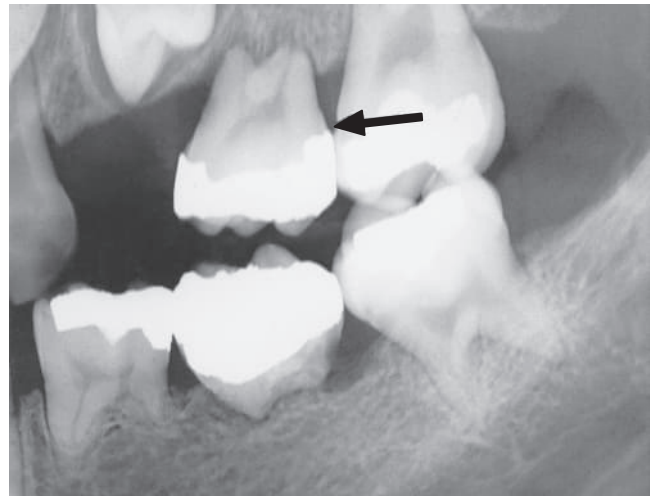


Fig. 3.27 X-radiation caused hypoplastic defect on the crown of the first permanent molar (arrow) and stunting of root development.



Fig. 3.28 Absence of developing premolars and the malformed second permanent molar were caused by excessive x-radiation.

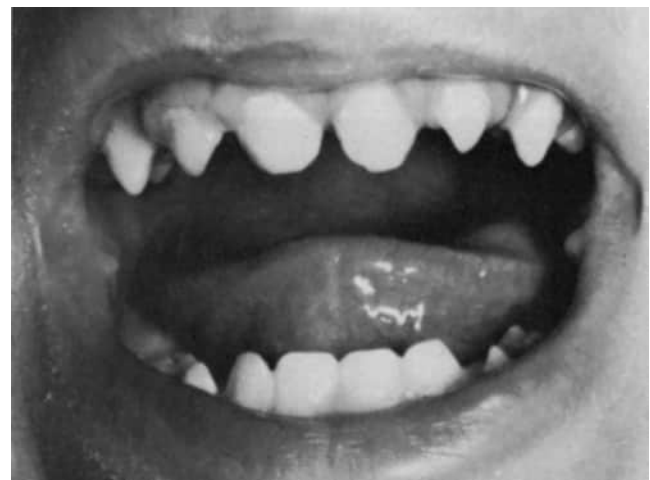

Fig. 3.29 The mother of this child had rubella in the eighth week of pregnancy. The primary teeth were tapered and had a rough hypoplastic surface. The child had a patent ductus arteriosus, pulmonary stenosis, and a cognitive disability. There was also a history of difficult feeding and dehydration at 2 months of age. (Courtesy Dr. Robert Musselman.)



be restored with composite resin or a glass ionomer. The restoration is usually confined to the area of involvement. The occlusal third of the first permanent molar often shows gross evidence of hypoplasia, and treatment is necessary before the tooth fully erupts. The most successful restorations for young children are those involving full coverage, namely, stainless-steel crowns.

Hypoplastic primary and permanent teeth with large areas of defective enamel and exposed dentin may be sensitive as soon as they erupt. Satisfactory restoration may not be practical at this time. The topical application of fluoride has been found to decrease tooth sensitivity. The application should be repeated as often as necessary to reduce sensitivity to thermal change and acidic foods.

### HYPOPLASIA CAUSED BY FLUORIDE (DENTAL FLOUROSIS)

Excess ingestion of fluoride can affect ameloblasts during the appositional, calcification, and maturation stages of tooth development, causing a clinical entity called dental fluorosis or mottled enamel. The appearance of enamel affected by excessive fluoride during formation varies considerably. Although the more severe cases of dental fluorosis are associated with a high level of fluoride consumption, there is apparently considerable individual variation. The affected enamel is often limited superficially to the outer 100- to 200- $\mu\text{m}$  layer, with appearance ranging from fine white flecks to brown opaque lesions and/or pitting.

Dental fluorosis is seen most often in permanent teeth, but it has also been observed in primary teeth. Levy et al.<sup>103</sup> observed fluorosis of primary teeth in 12.1% of 504 children, most often on second primary molars. Based on their estimates of fluoride ingested prenatally and during the first year of life in these children, the middle of the first year of life seemed to be the most important time with regard to the development of fluorosis in the primary dentition. Otherwise, in relation to permanent incisor fluorosis, the exposure to excess fluoride between 18 months and 3 years of age, when the enamel is maturing, is most important. It should be noted that the opacities present are areas of hypomineralization and porosity in the enamel. The surface of newly erupted enamel is subject to abrasion causing pits and stains and is termed posteruptive breakdown.

The existence of a genetic influence on the development of fluorosis is supported by the finding that some inbred strains of mice are much more susceptible to fluorosis than are other strains that receive the same fluoride dosage under identical conditions. Studies of these differing mouse strains should identify candidate genes for study in human cases of dental and skeletal fluorosis.<sup>104</sup>

### ENAMEL MICROABRASION TO REMOVE SUPERFICIAL ENAMEL DISCOLORATIONS

For many years, some dentists have advocated the application of hydrochloric acid as an effective method for destaining mottled enamel. McCloskey<sup>105</sup> described a technique, originally advocated by Kane, that used 18% hydrochloric acid on the affected enamel surfaces. Croll<sup>106</sup> proposed a modified procedure called *enamel microabrasion* in which

a specially prepared abrasive compound (Prema; Premier Dental Products, King of Prussia, Pennsylvania) is applied to the discolored enamel areas, similarly to prophylaxis paste, using a synthetic rubber applicator in a 10:1 gear-reduction handpiece. Frequent rinsing with water and re-evaluation of the tooth for color correction are required. The instrumentation is continued until the undesirable coloration is removed or until a noticeable amount of enamel is being removed when the tooth is viewed incisally. Finally, the abraded teeth are polished with a fine fluoridated prophylactic paste and given a 4-minute fluoride treatment (Fig. 3.30).

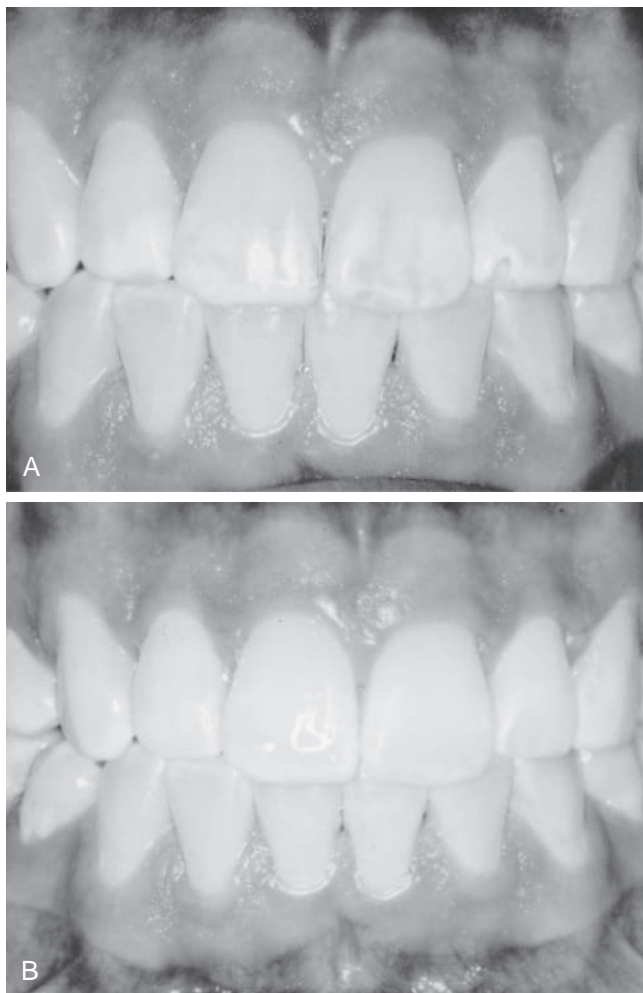
Croll and Helpin<sup>107</sup> introduced a delivery system for the microabrasion procedure. A viscous, water-soluble abrasion slurry containing hydrochloric acid and silicon carbide microparticles (Opalustre; Ultradent Products, South Jordan, Utah) is conveniently applied to the tooth surface using a syringe. Bleaching of vital teeth may be used in combination with enamel microabrasion to help remove deeper intrinsic discolorations. (Bleaching is discussed later in this chapter.) Microabrasion may also be achieved by judicious polishing of the tooth surface with multifluted tungsten carbide burs.

### Pre-Eruptive “Caries” (Pre-eruptive coronal resorption of the pre-eruptive intracoronal radiolucency)

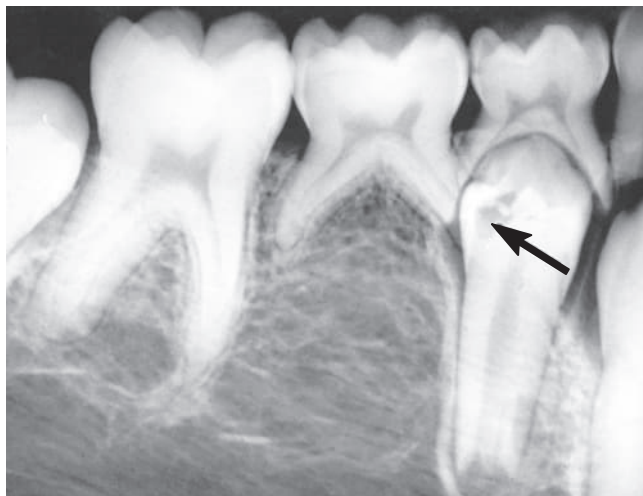
Occasionally, the defects on the crowns of developing permanent teeth are evident radiographically, even though no infection of the primary tooth or surrounding area is apparent (Fig. 3.31). Muhler<sup>108</sup> referred to this condition as pre-eruptive “caries.” Such a lesion often does resemble caries when it is observed clinically, and the destructive lesion progresses if it is not restored. As soon as the lesion is reasonably accessible, the tooth should be uncovered by removal of the overlying primary tooth or by surgical exposure. The caries-like dentin is then excavated, and the tooth is restored with a durable temporary or permanent restorative material. In some cases, the lesion may be so extensive that indirect pulp therapy is justified (Fig. 3.32).

Mueller et al.<sup>109</sup> reported caries-like, bilateral intracoronal radiolucencies in mandibular permanent second molars of a 12-year-old patient. Both lesions were successfully treated in a manner similar to the treatment illustrated in Fig. 3.32. Holan et al.<sup>110</sup> reported three cases in which similar management of pre-eruptive tooth defects was successfully performed. Their experience and a review of other reported cases suggest that impacted teeth or teeth delayed in eruption may be at higher risk for developing such lesions.

Seow et al.<sup>111,112</sup> determined the prevalence of pre-eruptive dentin radiolucencies in permanent teeth to be 2% (in 6% of the study population) using bitewing radiographs and 0.5% (in 3% of the study population) using panoramic radiographs. The authors emphasized the importance of careful study of radiographic images of unerupted teeth so that early detection and treatment are possible.



**Fig. 3.30** (A) Mottled enamel. Because the brown pigmentation and white splotchy areas were objectionable, the teeth were treated by enamel microabrasion. (B) Much of the pigment has been removed by enamel microabrasion.



**Fig. 3.31** Pre-eruptive "caries" on the crown of an unerupted first premolar (arrow).

## Taurodontism

Lysell<sup>113</sup> credits Keith with giving the name to the phenomenon known as *taurodontism*. This anomaly is characterized by a tendency for the body of the tooth to enlarge at the expense of the roots. The pulp chamber is elongated and extends deeply into the region of the roots (Fig. 3.33). A similar condition is seen in the teeth of cud-chewing animals such as the bull (Latin, *taurus*).

Taurodontism was identified in 15% of French patients seeking orthodontics.<sup>114</sup> Jaspers and Witkop<sup>115</sup> noted that taurodontism is found in about 2.5% of Caucasian adults as an isolated trait as well as in individuals with syndromes such as tricho-dento-osseous (TDO) syndrome (OMIM 190320; [www.omim.org](http://www.omim.org)), otodental dysplasia (OMIM 166750; [www.omim.org](http://www.omim.org)), and X-chromosome aneuploidies. Mena<sup>116</sup> observed a mother and seven children, four of whom showed evidence of taurodontism in the permanent and/or primary teeth. This was probably the first report of taurodontism of the primary dentition as a definite family trait in children of African heritage. Gedik and Cimen<sup>117</sup> reported taurodontism of six primary molars of a 7-year-old boy who had no syndromes or systemic disease. Other pedigrees have been consistent with autosomal dominant or autosomal recessive inheritance. The inheritance may also be polygenic. The clinical significance of the condition becomes apparent only if vital pulp therapy or root canal therapy is necessary.

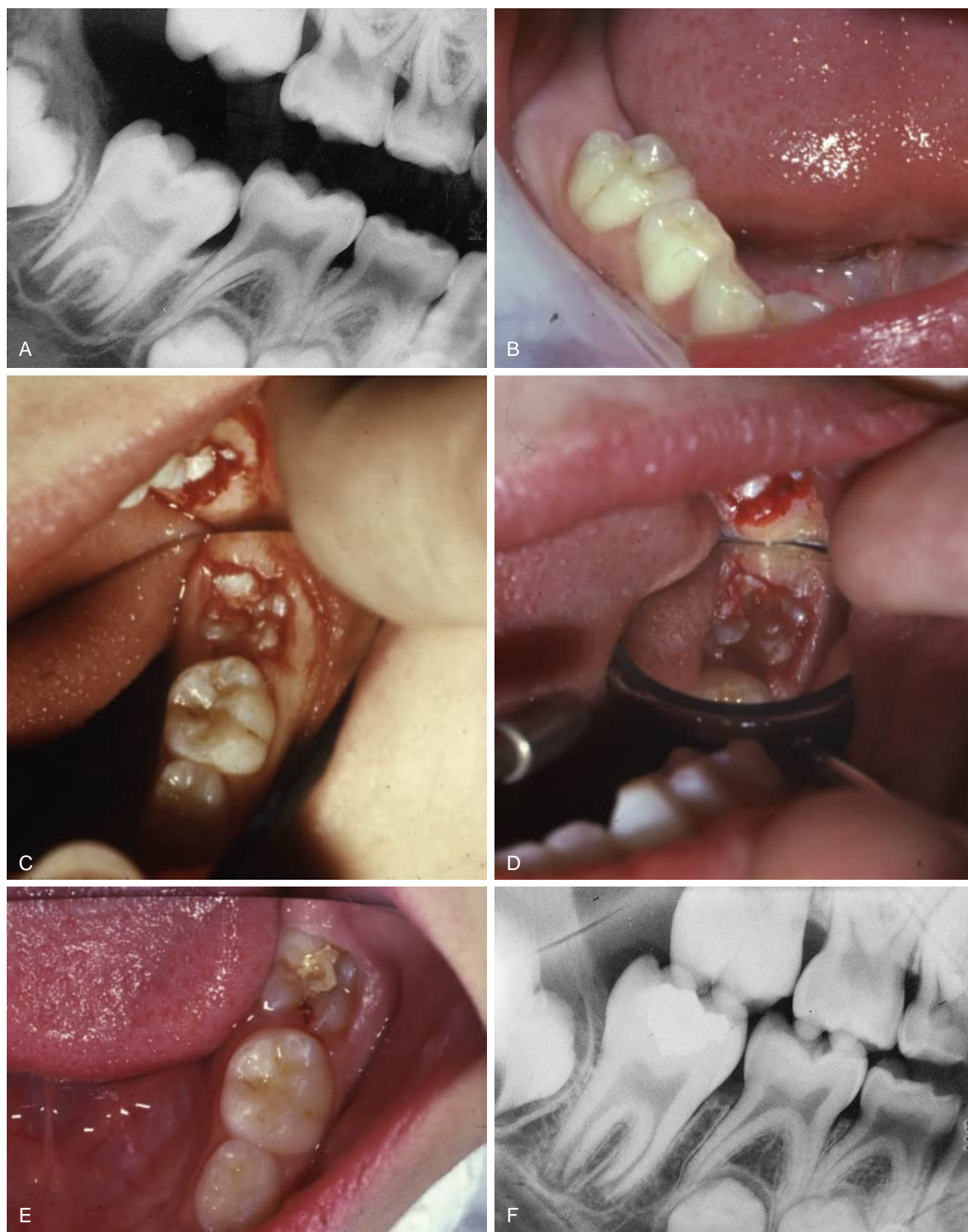
## Inherited Defects of Dentin

Two broad categories of heritable dentin defects, dentinogenesis imperfecta and dentin dysplasia, are identifiable, each with distinct subtypes.

### DENTINOGENESIS IMPERFECTA (HEREDITARY OPALESCENT DENTIN)

Dentinogenesis imperfecta is inherited as an isolated autosomal dominant trait ("isolated" in this use means that it occurs without other anomalies). Bixler et al.<sup>118</sup> observed this pattern in a six-generation family in which 34 members were studied. There was 100% penetrance and consistent gene expression within a sibship. In a survey of 96,000 Michigan children, Witkop<sup>119</sup> reported a prevalence of 1 in 8000 with the trait. The anomaly may be seen with osteogenesis imperfecta (Fig. 3.34). A decade later, Witkop<sup>120</sup> suggested that there are two distinct diseases and recommended the terms *dentinogenesis imperfecta* for the disease that occurs in conjunction with osteogenesis imperfecta and *hereditary opalescent dentin* for the disease that occurs as an isolated trait. Shields et al.<sup>121</sup> proposed a new classification: (Shields) *type I dentinogenesis imperfecta* and (Shields) *type II dentinogenesis imperfecta*, respectively. In addition, the dentin defects seen in the isolated Brandywine triracial population in southern Maryland were termed (Shields) *type III dentinogenesis imperfecta*. These latter defects consisted of variable expression of the features of (Shields) type I (without osteogenesis imperfecta) and type II, shell-like teeth, and multiple pulp exposures (Fig. 3.35). In this condition,





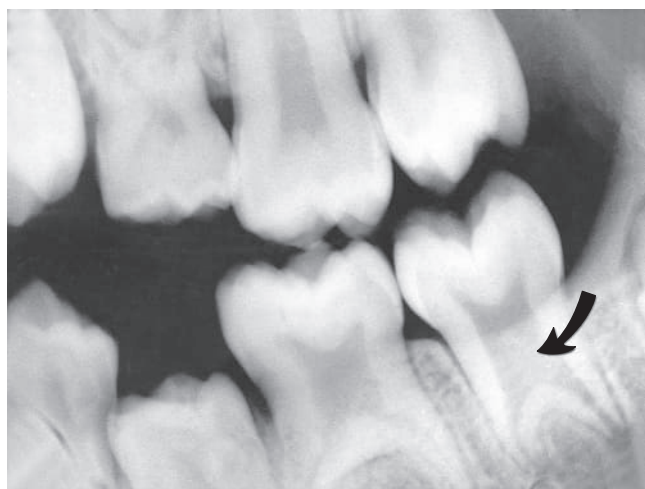
**Fig. 3.32** (A and B) Pre-eruptive “caries” in a mandibular right first permanent molar that is still unerupted. (C) Mirror view of the lesion on the occlusal surface of the unerupted tooth. (D) Mirror view of excavated cavity after gross caries removal. (E) Mirror view of temporary restoration 1 week postoperatively (dark spot on mesial marginal ridge area is an artifact). (F) Nine months postoperatively, patient had continued normal root development and eruption of the tooth. The temporary restoration remained 3 months before the tooth was re-entered and restored with amalgam. (Courtesy Drs. George E. Krull and James R. Roche.)



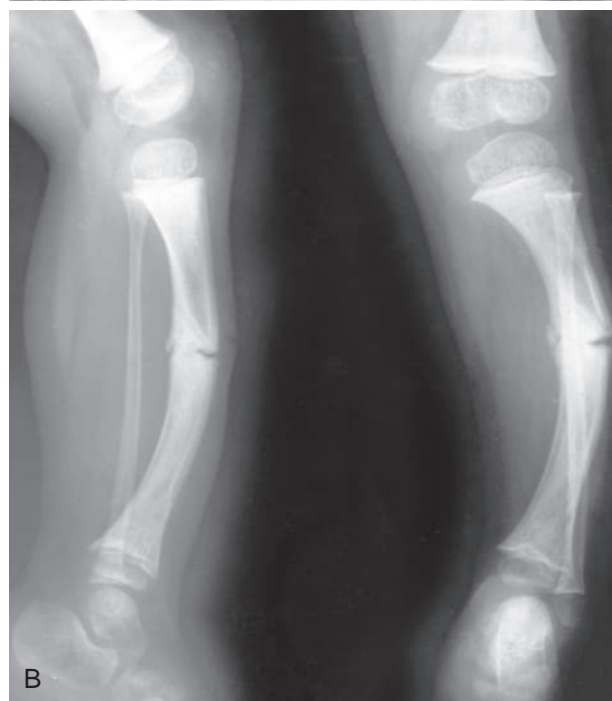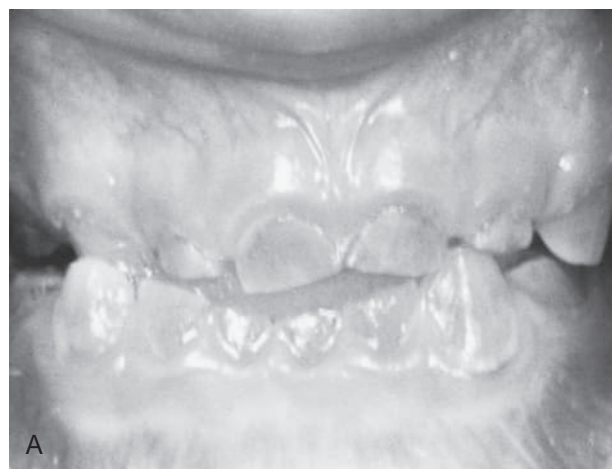normal dentin formation is confined to a thin layer next to the enamel and cementum, followed by a layer of disorderly dentin containing a few tubules. The roots of shell teeth are short, and the primary teeth may be exfoliated prematurely.

Xiao et al.<sup>122</sup> and Zhang et al.<sup>123</sup> have found mutations in the *DSPP* gene, which codes for the two major noncollagenous dentin matrix proteins dentin sialoprotein (DSP) and dentin phosphoprotein (also known as phosphophorin), in patients with (Shields) type II dentinogenesis imperfecta. In the *Dspp* knockout mouse, Sreenath et al.<sup>124</sup> noted that the teeth have a widened predentin zone and develop defective dentin mineralization similar in phenotype to that in human (Shields) type III dentinogenesis imperfecta; these findings imply that *Dspp* may also be involved in the latter condition.

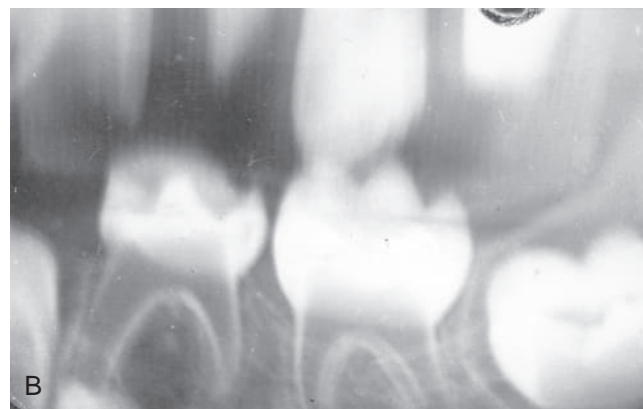
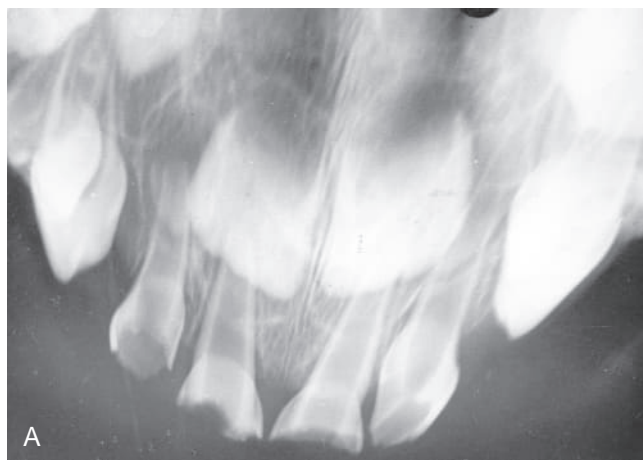
The clinical picture of dentinogenesis imperfecta is one in which the primary and permanent teeth are a characteristic reddish-brown to blue-gray opalescent color. Soon after the primary dentition is complete, enamel is worn and often breaks away from the incisal edges of anterior teeth and the occlusal surfaces of posterior teeth. The exposed soft dentin abrades rapidly, occasionally to the extent that



**Fig. 3.33** Taurodontism. Notice the elongated pulp chamber and short root canals (arrow).



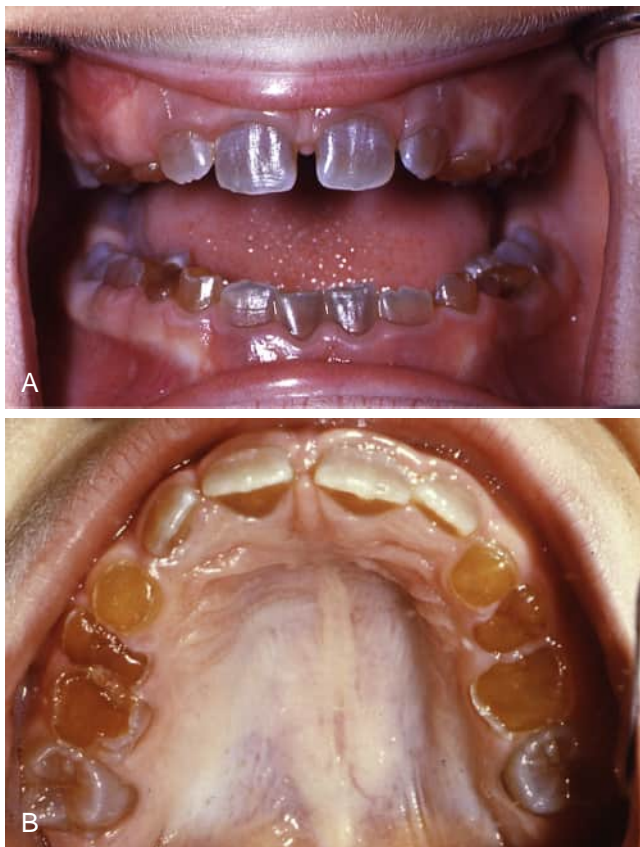**Fig. 3.34** (A) A 5-year-old girl with dentinogenesis imperfecta and osteogenesis imperfecta. The child had sustained numerous fractures of the long bones. (B) A fracture of the tibia is evident in the radiograph.



**Fig. 3.35** Shell teeth. The large size of the pulp cavities indicates the nonexistence of secondary dentin.

the smooth, polished dentin surface is continuous with the gingival tissue (Fig. 3.36). Radiographs show slender roots and bulbous crowns. The pulp chamber is large initially and undergoes obliteration (Fig. 3.37). Periapical rarefaction in the primary dentition is observed only occasionally. However, no satisfactory explanation has been offered because the condition apparently is not related to pulp exposures and pulpal necrosis. Multiple root fractures are often seen, particularly in older patients. Crowns of the permanent teeth often seem to be of better quality and have less destruction. Occasionally they appear clinically normal (Fig. 3.38). There is some evidence of a genotype-phenotype correlation, with Malmgren et al.<sup>125</sup> showing one *DSPP* missense variant of pathological significance being associated with a more severe phenotype in one family than that seen in another affected family with a different *DSPP* missense variant of pathological significance.

The treatment of dentinogenesis imperfecta is difficult in both primary and permanent dentitions. The placement of stainless-steel crowns on primary posterior teeth may be considered as a means of preventing gross abrasion of the tooth structure. Full-coverage restorations may be placed on the permanent teeth if the crowns need protection in late adolescence or young adulthood. Bonded veneer restorations on anterior teeth have also been used successfully for aesthetic improvement in patients with dentinogenesis imperfecta when full-coverage restorations are unnecessary. Unfortunately, the long-term prognosis of these teeth



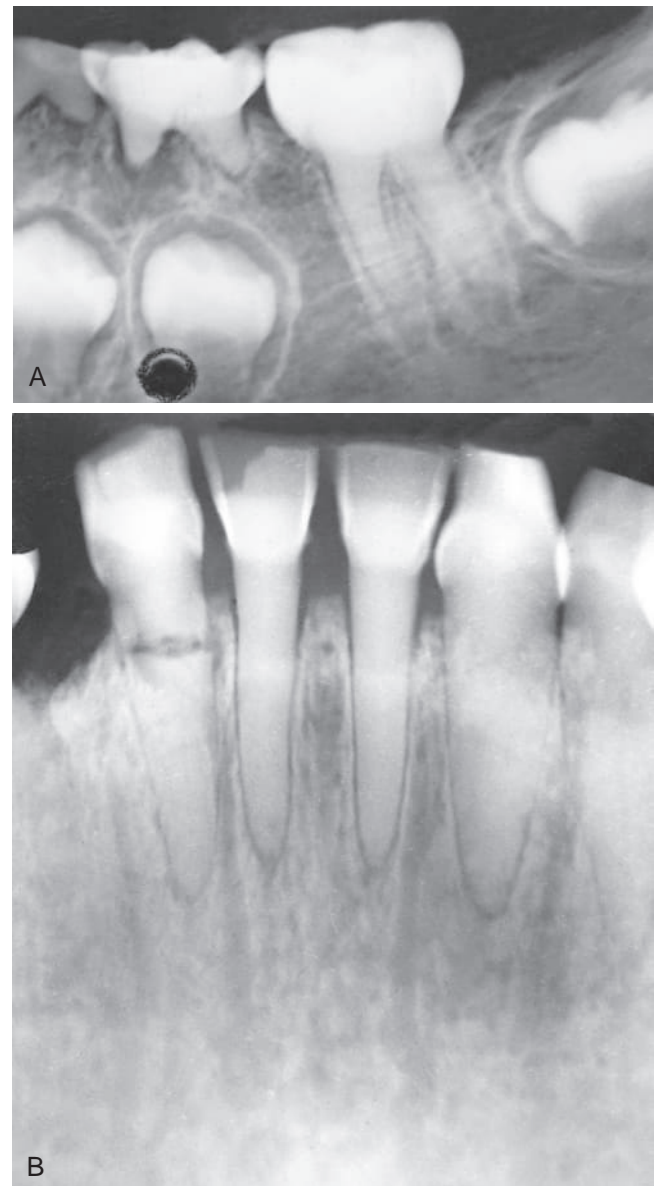
**Fig. 3.36** Dentinogenesis imperfecta. The primary teeth are severely abraded. Enamel is breaking away from the incisal edge of the lower permanent central incisors.

is poor; despite best efforts, they are usually lost in early adulthood. A pragmatic approach to treatment planning is required, especially in those patients with osteogenesis imperfecta.

Teeth with periapical rarefaction and root fracture should be removed. Extraction of such teeth is difficult because of the brittleness of the dentin.

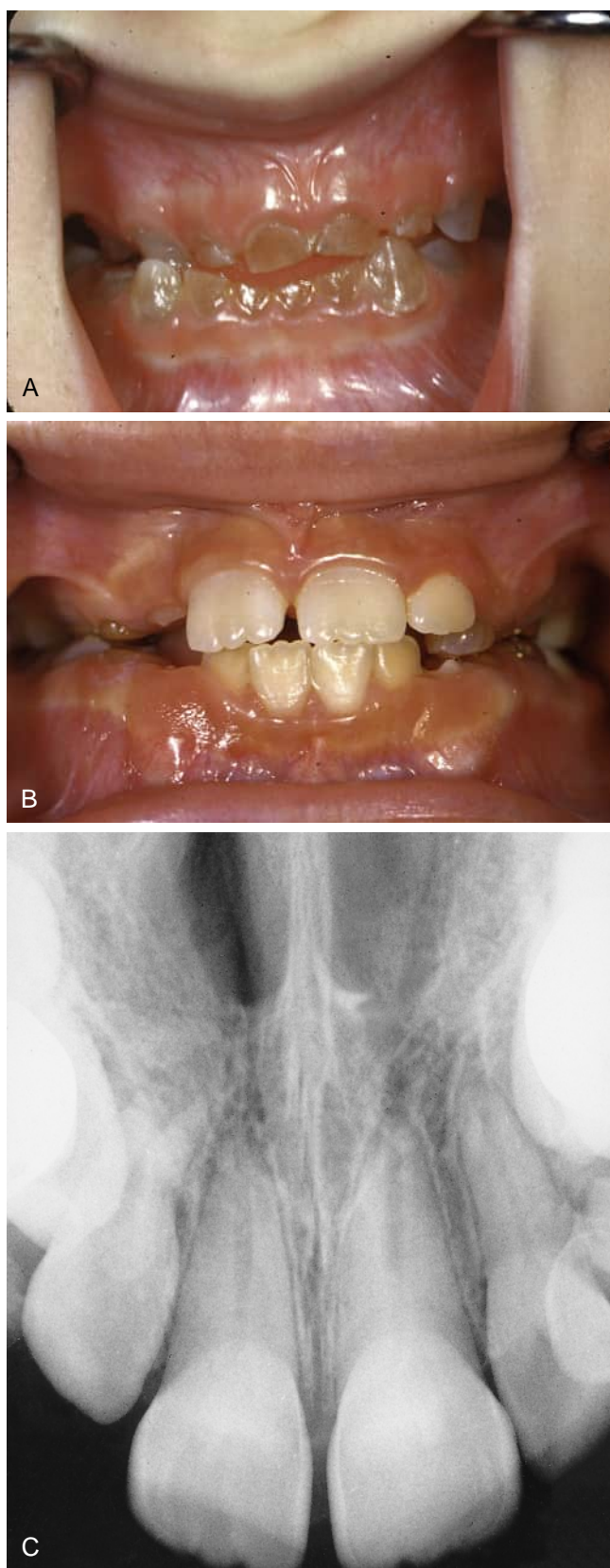
## DENTIN DYSPLASIA

Dentin dysplasia is a rare disturbance of dentin formation that Shields et al.<sup>121</sup> categorized into two types: radicular dentin dysplasia (type I) and coronal dentin dysplasia (type II). Both primary and secondary dentitions are affected in dentin dysplasia type I, which is inherited as an autosomal dominant trait. Radiographically, the roots are short and



**Fig. 3.37** (A) Slender roots with ribbon-like pulp canals and bulbous crowns are characteristic of dentinogenesis imperfecta. The primary molars show periapical rarefaction. (B) Root fractures are common in older patients.





**Fig. 3.38** (A) Four-year-old child with dentinogenesis imperfecta. (B) The permanent teeth, in contrast to the primary teeth, are normal in color. (C) The radiograph shows typical dentinogenesis imperfecta.

may be more pointed than normal. Usually, the root canals and pulp chambers are absent except for a chevron-shaped remnant in the crown. The color and general morphology of the crowns of the teeth are usually normal, but they may be slightly opalescent and blue or brown. Periapical radiolucencies may be present at the apices of affected teeth. Investigation of individuals with dentin dysplasia type I associated with extreme microdontia and aberrant crown morphology disclosed homozygosity for a splice-site mutation in the *SMOC2* gene. Since parents and siblings heterozygous for the mutation were not affected, the *SMOC2* gene may not be involved in dentin dysplasia type I without microdontia and aberrant crown morphology.<sup>126</sup> However, it may be involved in the developmental pathway that, with some other alteration, may result in dentin dysplasia type I.

Dentin dysplasia type II is inherited as an autosomal dominant trait in which the primary dentition appears opalescent and radiographically shows obliterated pulp chambers similar to those in dentinogenesis imperfecta. Unlike dentinogenesis imperfecta, however, in dentin dysplasia type II, the permanent dentition has normal color and radiographically exhibits a thistle tube pulp configuration with pulp stones.

On noting the phenotypic similarity of Shields type II dentinogenesis imperfecta to that in the primary dentition in dentin dysplasia type II, Dean et al.<sup>127</sup> hypothesized that these conditions may be due to different alleles of the same gene. Investigation of a family with 10 of 24 members affected in three generations showed that the candidate region for the dentin dysplasia type II gene overlaps the likely location of the gene for Shields type II dentinogenesis imperfecta. They suggested that a candidate gene for Shields type II and/or III dentinogenesis imperfecta should also be a candidate gene for dentin dysplasia type II. Subsequently, Rajpar et al.<sup>128</sup> showed that a *DSPP* missense mutation was present in a family with dentin dysplasia type II, thereby confirming the hypothesis of Dean et al. Further analysis of the *DSPP* gene in patients with Shields type II dentinogenesis imperfecta or dentin dysplasia type II suggests that these dominant phenotypes result from the disruption of signal peptide processing and/or related biochemical events that interfere with protein processing.<sup>129</sup> This is consistent with the assertion that dentin dysplasia type II and Shields type II dentinogenesis imperfecta are milder and more severe forms, respectively, of the same developmental disease.<sup>130</sup>

## Amelogenesis Imperfecta

As noted in [Chapter 6](#), amelogenesis imperfecta is a developmental defect with a heterogeneous etiology that affects the enamel of both primary and permanent dentition. The anomaly occurs in the general population with an incidence of 1 in 14,000 to 1 in 16,000. Amelogenesis imperfecta has a wide range of clinical appearances, with three broad categories observed clinically: the hypocalcified type, the hypomaturation type, and the hypoplastic type. Although amelogenesis imperfecta can occur as part of several syndromes, Cartwright et al.<sup>131</sup> confirmed that the trait itself could also be associated with a skeletal anterior open bite; however, the pathophysiologic relationship between amelogenesis imperfecta and open bite remains unclear.<sup>132</sup>



Progress has been made in unraveling the molecular basis of the myriad clinical forms of amelogenesis imperfecta. Aldred and Crawford<sup>133</sup> discussed the limitations of the existing classification systems and proposed an alternative classification based on the molecular defect, biochemical result, mode of inheritance, and phenotype. They proposed two separate phenotypes, namely enamel that is predominantly hypoplastic (i.e., enamel that is either uniformly thin, with spacing between adjacent teeth, or irregular, giving rise to pits or grooves) or predominantly hypomineralized (i.e., with soft, poorly formed enamel with altered color and translucency). Hart et al.<sup>134,135</sup> recommended a standardized nomenclature for describing amelogenesis imperfecta that causes alterations at the genomic, complementary DNA, and protein levels. Two clinically distinct forms of autosomal dominant amelogenesis imperfecta—smooth hypoplastic amelogenesis imperfecta and local hypoplastic amelogenesis imperfecta—are associated with mutations in the enamelin (*ENAM*) gene located at 4q21. In addition, autosomal dominant amelogenesis imperfecta can be associated with mutation in the Kallikrein-4 (*KLK4*) gene, and autosomal recessive pigmented hypomaturational amelogenesis imperfecta with an enamelysin (also termed Matrix Metalloproteinase-20, *MMP-20*) gene mutation, illustrating the heterogeneity of the condition. An X-linked form (AIH1) has been found to be associated with as many as 14 mutations in the Amelogenin X-Linked (*AMELX*) gene located at Xp21.<sup>136</sup> However, at least one family has had the trait linked to another location on chromosome Xq22-q28.<sup>137</sup>

The defective tooth structure is limited to the enamel. On radiographic examination, the pulpal outline appears to be normal, and the root morphology is that of normal teeth. The difference in the appearance and quality of the enamel is thought to be attributable to the state of enamel development when the defect occurs. In the hypoplastic type, the enamel matrix appears to be imperfectly formed; although calcification subsequently occurs in the matrix and the enamel is hard, it is defective in amount and has a roughened, pitted surface (Fig. 3.39). In the hypocalcified type, matrix formation appears to be of normal thickness, but calcification is deficient, and the enamel is soft (Fig. 3.40). In both of these more common types of the defect, the enamel becomes stained because of the roughness of the surface and increased permeability.

In still another variant of amelogenesis imperfecta, a thin, smooth covering of brownish-yellow enamel is present. In this type, the enamel does not seem excessively susceptible to abrasion or caries (Figs. 3.41 and 3.42).

Congleton and Burkes<sup>138</sup> reported three cases of amelogenesis imperfecta in which the patients also demonstrated taurodontism. Others have identified cases with the clinical appearance of amelogenesis imperfecta and taurodontism along with strikingly curly hair and increased bone density (especially of the skull) which has been identified as TDO syndrome. Seow<sup>139</sup> has suggested that some cases reported as amelogenesis imperfecta with taurodontism were actually cases of TDO syndrome. Price et al.<sup>140</sup> found that this autosomal dominant condition is caused by a mutation in the distal-less homeobox gene *DLX3*.<sup>140</sup> Even though the taurodontism and amelogenesis imperfecta traits in this condition are fully penetrant in affected individuals,

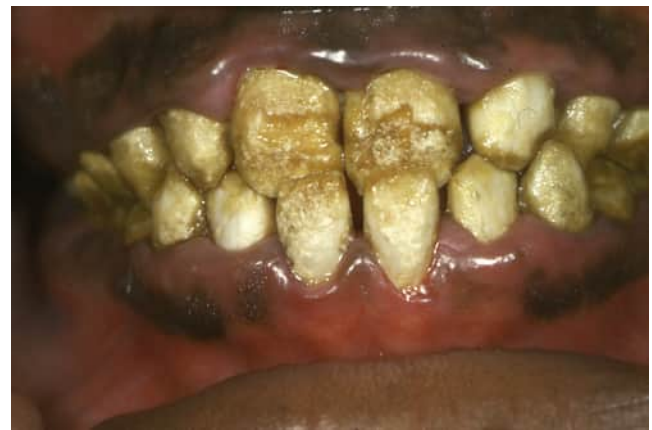

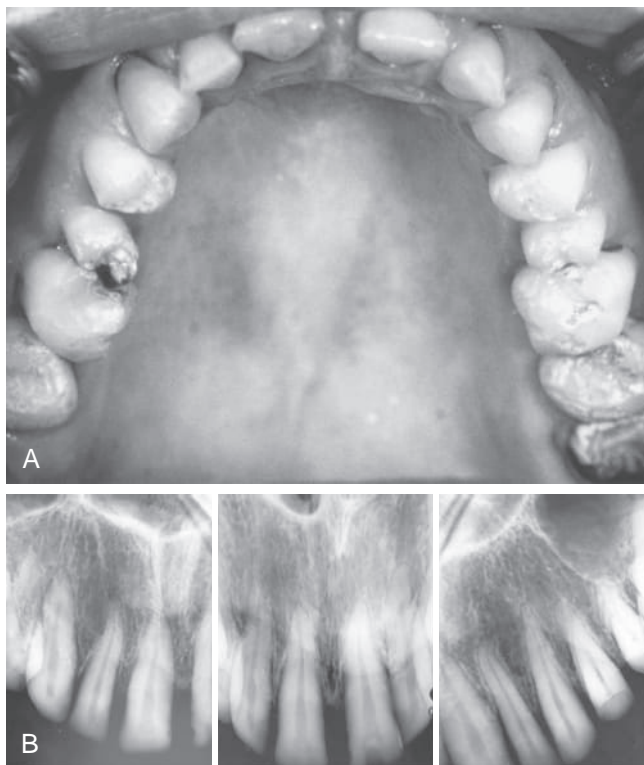
Fig. 3.39 Both the primary and permanent teeth are affected by the hereditary anomaly amelogenesis imperfecta. The enamel is pitted but hard.

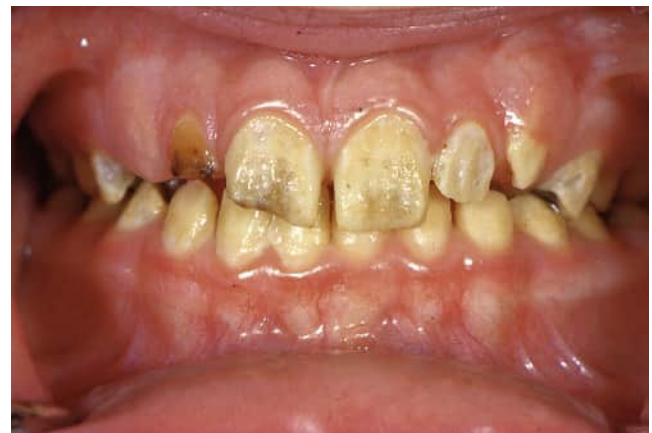

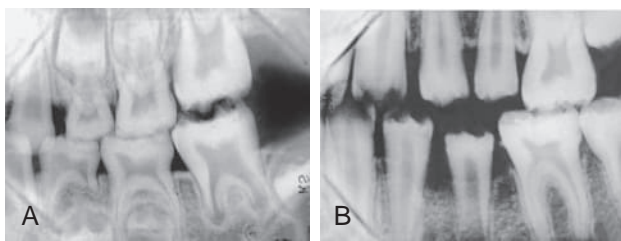
Fig. 3.40 Hypocalcification type of amelogenesis imperfecta. The primary teeth were similarly affected. The enamel surface is soft.

the osseous and hair features are variably expressed even when the same deletion is present in a family, indicating that the variable expression is influenced by other genes and/or environmental factors; however, further studies by Price et al.<sup>141</sup> indicated that TDO syndrome and amelogenesis imperfecta of the hypomaturational-hypoplastic type with taurodontism are two genetically distinct conditions. Dong et al.<sup>142</sup> found that a mutation within the *DLX3* gene homeodomain is associated with amelogenesis imperfecta (hypoplastic-hypomaturational type) with taurodontism (AIHHT). Because a *DLX3* mutation outside the homeodomain is associated with TDO syndrome, they suggested that TDO and some forms of AIHHT are allelic.

Amelogenesis imperfecta may also be associated with nephrocalcinosis syndrome, also called enamel-renal syndrome or Lubinsky syndrome. Inheritance appears to be autosomal recessive. In addition to hypoplastic enamel, the teeth often fail to erupt and undergo resorption due to the disappearance of the reduced enamel epithelium. Histopathology of the gingiva, which may be enlarged, reveals islands of odontogenic calcification.<sup>143,144</sup> Nephrocalcinosis may be the cause of renal impairment but only rarely end-stage renal failure, unless complicated by renal stones and recurrent infections.<sup>145</sup>



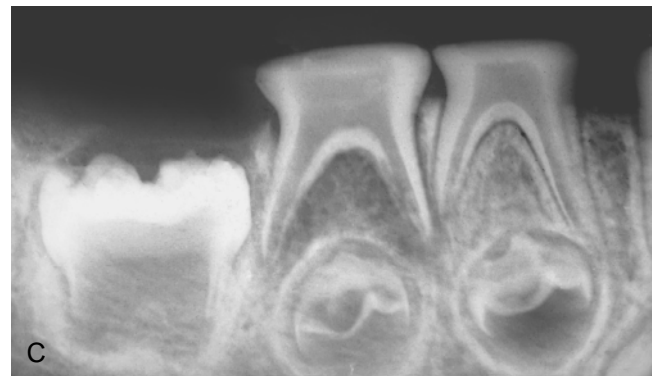
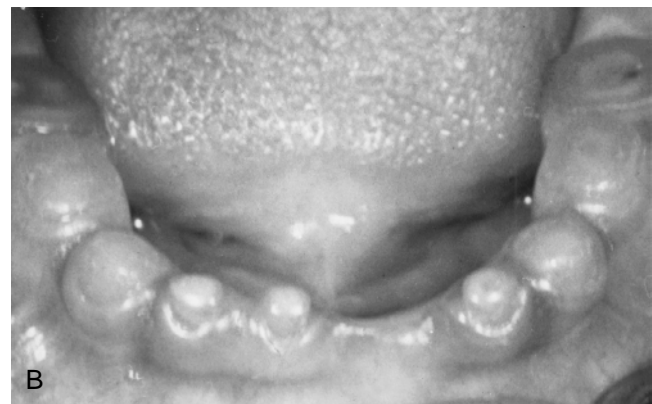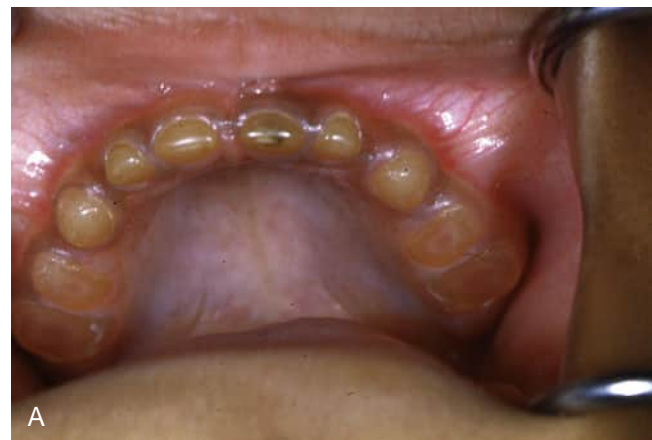**Fig. 3.41** (A) Case diagnosed as amelogenesis imperfecta. The permanent teeth have a thin covering of pigmented enamel. (B) The radiographs show essentially normal root morphology. The crowns have a thin covering of enamel.



**Fig. 3.42** (A and B) Left bite wing radiographs of a patient with amelogenesis imperfecta. Radiograph in B was made 6 years after radiograph in A and demonstrates the maintenance of a caries-free dentition despite the thin enamel.

Since nephrocalcinosis is often asymptomatic and can be associated with impaired renal function, dentists who see children with generalized and thin hypoplastic amelogenesis imperfecta should consider a renal ultrasound scan and referral to a nephrologist, if appropriate. Conversely, children with nephrocalcinosis should also be considered for a dental referral.<sup>144</sup>

The treatment of teeth with amelogenesis imperfecta-like defects depends on the severity of the condition and the demands for aesthetic improvement. When indicated, the teeth can be prepared for full-coverage restorations. For some cases of the hypoplastic types, bonded veneer restorations may offer a more conservative alternative for the management of the aesthetic problem of the anterior teeth. Patel et al.<sup>146</sup> have reported successful treatment with porcelain laminate veneer restorations.



**Fig. 3.43** (A and B) Severely abraded teeth are almost entirely devoid of enamel. The outline of a large pulp chamber can be seen through a thin covering of dentin. The mandibular second primary molars have pulp exposure. (C) Radiograph shows large pulp canals and large pulp chambers. Apical rarefaction is associated with pulp exposure of the second primary molar.

## Enamel and Dentin Aplasia

Teeth with characteristics of both dentinogenesis imperfecta and amelogenesis imperfecta have been reported. Chaudhry et al.<sup>147</sup> reported such a case and called the condition *odontogenesis imperfecta*. Schimmelpfennig and McDonald<sup>148</sup> observed a similar dentition and termed it *enamel and dentin aplasia*. The primary teeth were essentially devoid of enamel, and the smooth, severely abraded dentin was reddish-brown. Radiographs showed normal alveolar bone around the roots of the teeth. Two teeth had pulp exposure and pulpal degeneration (Fig. 3.43). Radiolucent areas were present at the apices of the two primary teeth,



with exposed and degenerated pulps. The pulp chambers and canals in all the primary teeth were extremely large, with no evidence of becoming obliterated. In ground sections of the primary teeth, the dentinal tubules showed little evidence of a normal growth pattern. They were few and irregular, with a tendency toward branching. The cementum appeared normal and was acellular. No evidence of secondary dentin formation was found. A few fragments of enamel adhering to the dentin appeared thinner than normal, and few normal morphologic characteristics were present. The dentino-enamel junction was atypical in that it lacked the characteristic scalloping.

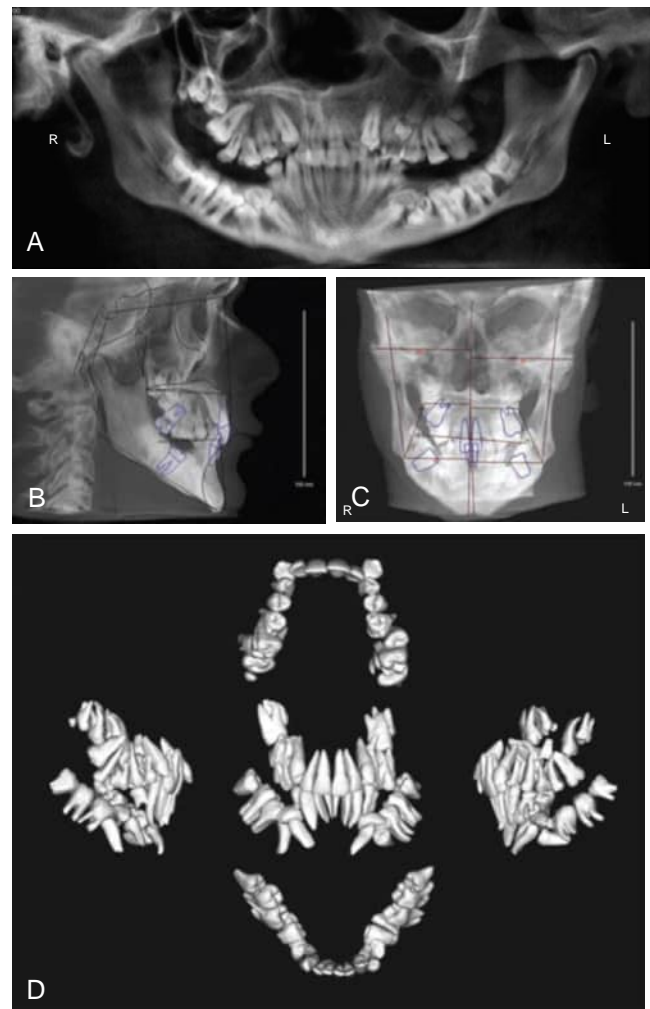
The permanent teeth, when they erupted, were partially covered with a thin, gray, poorly coalesced coating of enamel. Brown dentin could be seen on the labial aspect of the central incisors and at the bases of the fissures of the first permanent molars. Stainless-steel crown restorations were placed even before complete eruption to protect the teeth from continued abrasion.

## Supernumerary Teeth (Hyperdontia)

Supernumerary teeth, also termed hyperdontia, is a condition where more than the normal number of teeth are formed in the primary or permanent dentitions. The reported prevalence of nonsyndromic multiple supernumerary teeth (NSMST) in the oral cavity varies with definition (two or more, or more commonly either five or more supernumerary teeth or with supernumerary teeth forming in more than one dental series/field, as well as with population). It has been reported to vary between 1% and 11%, but most studies indicate that it is in the lower percentage range.<sup>149</sup> In addition, the stage of development (primary or permanent dentition), tooth type affected, arch location, tooth series, and morphology are highly variable.<sup>149,150</sup>

Diagnosis of NSMST occurs most frequently during the teenage years.<sup>149</sup> Many NSMST patients diagnosed with supernumerary teeth have them present in both jaws.<sup>149</sup> In these individuals, teeth in the canine and premolar fields are affected overall more frequently than the incisor and molar fields, with the premolar field most frequently affected in the mandible and the incisor/molar fields most frequently affected in the maxilla.<sup>149</sup> The majority of NSMST patients diagnosed with canine-premolar field supernumerary teeth present in a bilateral fashion.<sup>149</sup> Although males are affected more frequently with NSMST than females (2:1), there are no sex differences for affected individuals in terms of the number or location of the supernumerary teeth that form.<sup>149</sup>

It is rare to find multiple supernumeraries in individuals with no other associated disease or syndrome, although some individual cases have been reported.<sup>151</sup> Genetic disorders that may have supernumerary teeth include: Gardner syndrome/familial adenomatous polyposis/adenomatous polyposis coli (OMIM 175100; [www.omim.org](http://www.omim.org)), cleidocranial dysostosis (dysplasia) (OMIM 119600; [www.omim.org](http://www.omim.org)), Nance-Horan syndrome (OMIM 302350; [www.omim.org](http://www.omim.org)),<sup>152</sup> trichorhinophalangeal syndrome types I and III (OMIM 190350 and 190351 respectively; [www.omim.org](http://www.omim.org)) (Fig. 3.44),<sup>153</sup> Opitz BBB/G syndrome



**Fig. 3.44** A 17-year-old Caucasian male diagnosed with trichorhinophalangeal syndrome, type I. (A) Panoramic radiograph showing multiple retained supernumerary and impacted teeth with long, well-developed root structure in both maxillary and mandibular arches. (B and C) Lateral and posteroanterior cephalograms showing prominent chin button, mild class II skeletal relationship, lingually inclined maxillary and mandibular incisors, steeply inclined lower border of the mandible, obtuse gonial angle, and shortened posterior facial height with short mandibular ramus. (D) Virtual models showing development of roots and multiple impacted teeth. (Reprinted from *Journal of Orthodontics*, Volume 40, Issue 1, pages 47-52, by Ahmed Ghoneima, Kanwar Sachdeva, James Hartsfield, David Weaver & Katherine Kula, *The use of cone beam computed tomography for the assessment of trichorhinophalangeal syndrome, type I – a case report* (Copyright 2013) with permission from Sage Publisher.)

(OMIM 300000; [www.omim.org](http://www.omim.org)), Rubinstein-Taybi syndrome types I and II (OMIM 180849 and 613684 respectively; [www.omim.org](http://www.omim.org)), oculofaciocardiodental syndrome (OMIM 300166; [www.omim.org](http://www.omim.org)), and Robinow syndrome type I (OMIM 180700; [www.omim.org](http://www.omim.org)).<sup>154,155</sup>

The diagnosis of the presence of supernumerary teeth may be an important indication to refer for the evaluation of undiagnosed condition in the individual, especially Gardner syndrome/familial adenomatous polyposis, since the development of supernumerary teeth precedes the possible development of colon carcinoma.<sup>156</sup> Furthermore, the development of Gardner syndrome-associated osteomas occur most commonly in the skull, mandible, facial bones, and paranasal sinuses.<sup>157,158</sup> As with supernumerary



teeth, the early detection of osteomas is critical as they always precede the presentation of intestinal polyps, which may transform into colorectal cancers.<sup>159,160</sup> The presence of multiple supernumerary teeth is a strong indication for further diagnostic evaluation, especially if any other anomalies are present.

## Agenesis of Teeth

### ANODONTIA

Anodontia (i.e., complete failure of the teeth to develop) is rare. Although agenesis of primary and/or permanent teeth is often referred to as *congenital absence*, such teeth would not of course be expected in the oral cavity at birth unless they are natal teeth. Thus the term “congenital absence” of teeth is not accurate, although used commonly. Gorlin et al.<sup>161</sup> noted that when anodontia of the permanent dentition occurs as an isolated (nonsyndromic) trait, the primary dentition is not affected, and the inheritance is autosomal recessive. Although dental anomalies, including hypodontia and oligodontia, can occur in many types of ectodermal dysplasia,<sup>162</sup> anodontia is unusual in them. However, anodontia or oligodontia may be a part of the ectodermal dysplasia also affecting the skin, hair, and nails, called odonto-onycho-dermal dysplasia (OMIM 257980, [www.omim.org](http://www.omim.org)), which can be caused by homozygous or compound heterozygous mutations in the *WNT10A* gene.<sup>163,164</sup> Mutations in *WNT10A* are also a significant cause of isolated (nonsyndromic) hypodontia.<sup>165</sup> Thus other factors and/or differences in the specific mutation of the gene can result in syndromic or nonsyndromic selective or complete dental agenesis.

Swallow<sup>166</sup> reported regarding an 11-year-old boy who had a complete primary dentition but no permanent dentition. Schneider<sup>167</sup> also observed a 7-year-old white female with primary teeth but missing permanent teeth. As is usually the case with presumed autosomal recessive inheritance, the hereditary background included no known consanguinity in the family or history of anodontia or ectodermal dysplasia in either the maternal or paternal lineage. Although consanguinity increases the likelihood that recessive traits or conditions will be expressed, most affected individuals do not have a family history of inbreeding. An overlay denture, which is often the treatment of choice, was constructed for the patient. A comparable situation is shown in Fig. 3.45. Laird<sup>168</sup> reported regarding a similar patient in whom a complete primary dentition was present, but the only permanent teeth were maxillary first permanent molars. Witkop<sup>169</sup> studied two families in which both parents had peg-shaped or missing maxillary lateral incisors, which is an autosomal dominant trait with incomplete penetrance and variable expressivity, and concluded that agenesis of the permanent teeth can be an expression of the homozygous state of that gene. This hypothesis is also supported by the findings reported by Hoo.<sup>170</sup>

### HYPODONTIA (OLIGODONTIA)

Agenesis of fewer than six permanent teeth (not including the third molars) is referred to as *hypodontia*, whereas the

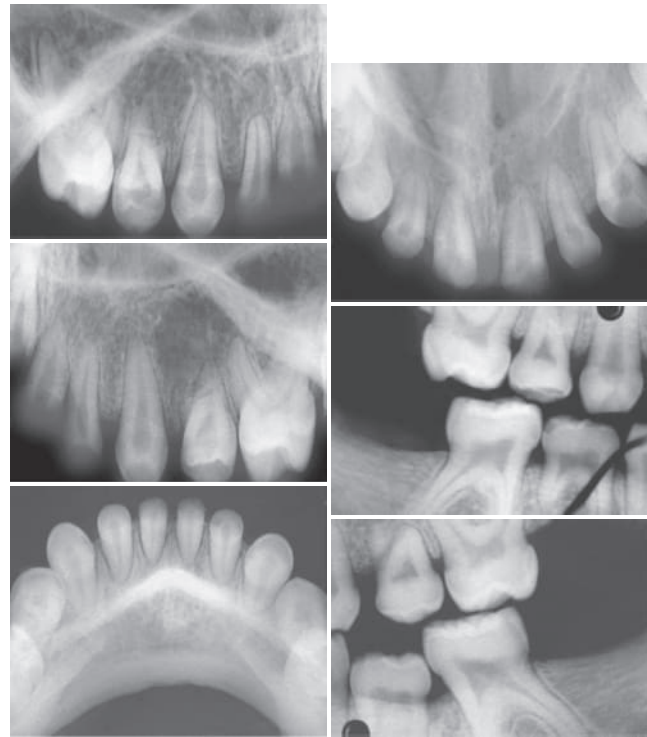

Fig. 3.45 A complete primary dentition without evidence of permanent teeth in a 14-year-old girl.

term *oligodontia* is used to describe conditions when more than six permanent teeth do not develop. The terminology *partial anodontia* should not be used in either of these cases. Hypodontia is usually familial, although it can occur sporadically (without a family history of hypodontia). It may also be identified as part of a syndrome, especially in one of the ectodermal dysplasias, although it usually occurs alone (isolated). Note that *isolated* in this usage means not occurring as part of a syndrome; it may still be familial.

Although any of the 32 permanent teeth may not form properly, there is a higher propensity for the last tooth in each dental series to be absent, namely third molars, mandibular second premolars, maxillary lateral incisors, and maxillary second premolars. The mandibular central incisors versus the lateral incisors are an exception. This order of frequency has been confirmed in studies by both Glenn<sup>171</sup> and Grahnen.<sup>172</sup> The absence of teeth may be unilateral or bilateral. During an examination of 1702 children, Glenn observed<sup>171</sup> that 5% children had a missing permanent tooth other than a third molar. In 97% of the children, the formation of the second premolar could be detected radiographically at 5.5 years of age and that of the lateral incisor at 3.5 years of age. The most preserved permanent teeth are the maxillary central incisors (with the notable exception of solitary median maxillary central incisor syndrome as reviewed earlier in this chapter), the first molars, and the canines.

For an excellent review of the genetic etiology of human dental agenesis, see the open access paper by Williams and Letra.<sup>173</sup> Dental agenesis may be associated with other dental anomalies, such as small and short crowns and roots of the teeth that are present, conical crowns, enamel hypoplasia, taurodontism, delayed eruption, prolonged retention

of primary teeth, infraocclusion of primary teeth, ectopic eruption, transposition, lack of alveolar bone, reduced vertical dimensions, increased overbite, and tooth impaction (particularly palatally displaced canines[PDCs]).<sup>78,174</sup> For example, autosomal recessive variants of pathological significance in the latent transforming growth factor-beta binding protein 3 (*LTBP3*) gene have been associated with dental anomalies, including dental agenesis as severe as anodontia, and short stature (DASS, OMIM 601216, [www.omim.org](http://www.omim.org); which had previously been designated STHAG6).<sup>175</sup>

### PALATALLY DISPLACED CANINES (PDCS)

An impacted tooth is one that fails to erupt after the usual development pattern is complete.<sup>176</sup> Maxillary canine impaction in the general population varies from 0.27% in a Japanese sample,<sup>177</sup> 2.4% in an Italian sample,<sup>178</sup> to as much as 3.6% in a Turkish sample. The prevalence in most orthodontic and other specialty offices is higher as a result of evaluation and referral. Interestingly, perhaps due in part to female dental development generally occurring at an earlier age than in males, the occurrence is 2.3 to 3 times more common in females than in males.<sup>178-180</sup>

When a permanent maxillary canine does not erupt according to the normal developmental sequel, 85% of the time, the canine will be displaced and/or impacted to the palatal region compared with 15% which are located “ectopically” (to the buccal). Although PDCs are not typically associated with dental crowding, they are frequently associated with other anomalies within the adult dentition. These anomalies include small, peg-shaped or missing maxillary lateral incisors, hypodontia involving other teeth, dentition spacing, and dentitions with delayed development, suggesting a common genetic influence.<sup>181</sup> There is greater likelihood of a PDC on the same side of a missing or small maxillary lateral incisor, emphasizing the possibility of a local environmental effect.<sup>182</sup>

There are also cases in which a canine is palatally displaced without an apparent anomaly of the maxillary lateral incisors, and cases in which there are missing lateral incisors without palatal displacement of a canine. Adding to the complexity is the heterogeneity found in studies of cases of both buccally displaced canines<sup>183</sup> and PDCs.<sup>182</sup> Whereas the canine eruption theory of guidance by the lateral incisor root cannot explain all instances of PDCs, it does seem to play a role in some cases.<sup>184</sup>

Maxillary canine impaction or displacement is labial/buccal to the arch in 15% of cases of maxillary canine impaction and, in contrast to palatal displacement being associated with small maxillary teeth,<sup>185</sup> ectopic canines are often associated with dental crowding. Because there are various degrees of genetic influence on these anomalies, there has been some discussion about PDCs themselves also being influenced by genetic factors to some degree. With apparent genetic and environmental factors playing various roles in these cases, the etiology appears to be multifactorial.<sup>186</sup> This is supported by the occurrence of PDCs occurring in a higher percentage within families than in the general population.

Generally, the phenotype is the result of some genetic influences (either or both directly or indirectly as part of

a developmental “sequence,” such as through a primary effect on development of some or all of the rest of the dentition) interacting with environmental factors and having an effect on subsequent development.<sup>187</sup> Some of these cases may be examples of how primary genetic influences (which still interact with other genes and environmental factors) affect a phenotypic expression that is a variation in a local environment, such as the physical structure of the lateral incisor in relation to the developing canine.

### DENTAL AGENESIS AND CANCER

The tumor suppressor gene, adenomatous polyposis coli (*APC*), and its protein product play an important role in WNT/ $\beta$ -catenin intracellular signaling along with the protein products of the *AXIN1*, *AXIN2* and glycogen synthase kinase 3 (*GSK3 $\alpha\beta$*  genes). WNT/ $\beta$ -catenin signaling is central to proper tooth development as demonstrated by gene overexpression and mutational studies in mouse models. This has been supported in human hypodontia/oligodontia studies of variations of pathological significance in genes such as *WNT10A*, *AXIN1*, and *AXIN2*.<sup>188-190</sup> As already noted, variations of pathological significance in the *APC* gene can lead to the formation of extra teeth.<sup>191-193</sup> Although there are often variations of pathological significance in the *APC* gene in colorectal and other types cancer, it is interesting to note that *AXIN2* variants of pathological significance have been reported in subset of colorectal cancer cases that also presented clinically with oligodontia.

A striking example of this was reported in a Finnish family in which oligodontia and colorectal cancer were inherited together in an autosomal dominant pattern.<sup>191</sup> The oligodontia and cancer predisposition were caused by a nonsense variant of pathological significance in the *AXIN2* gene, a negative regulator of Wnt signaling. Colorectal cancer or precancerous lesions in the family were found only in association with oligodontia and the exon 7 *AXIN2* variant of pathological significance (1966C>T, R656X) and affected all those of the oldest generation who had the variant of pathological significance.

In the same report, another *de novo* variant of pathological significance (1994-1995insG creating a frameshift and stop at p.706) in exon 7 of the *AXIN2* gene was found in an unrelated young patient with oligodontia who may have been too young to manifest the cancer. Both variants of pathological significance are expected to inactivate the *AXIN2* protein function, leading to an increase in Wnt signaling, which may lead to cancer development as well as a lack of dental development.<sup>191</sup>

Another publication found a heterozygous nonsense variant of pathological significance in exon 7 of *AXIN2* (c.1989G>A, p.Trp663stop) in a three-generation family with autosomal dominant oligodontia variably associated with colon or gastric polyps, early-onset colorectal and/or breast cancer, and a mild ectodermal dysplasia presenting with sparse hair and eyebrows.<sup>192</sup> Both of these studies describe a co-segregation of *AXIN2* exon 7 gene variants of pathological significance with oligodontia and early-onset cancer in an autosomal dominant pattern of inheritance, illustrating how changes in the protein products of genes can have pleiotropic effects on different parts of the body



at different times. There is a high concentration of known *AXIN2* exon 7 frameshift variants of pathological significance in gastrointestinal cancers.<sup>193</sup>

Further support for the proposition that dental agenesis can be developmentally associated with cancer comes from a University of Kentucky report that women with epithelial ovarian cancer (EOC) are 8.1 times more likely to have hypodontia than are women without EOC.<sup>194</sup> In contrast to the oligodontia reported with the specific mutations in the *AXIN2* gene, the severity of hypodontia was similar between the two groups (affected and nonaffected) in the Kentucky study, with one or two teeth being agenic. Maxillary lateral incisors followed by second premolars were the most frequently affected.<sup>194</sup> Moreover, a similar study of 120 women from Slovenia found a prevalence of hypodontia of 19.2% in women with EOC and 6.7% in women in the control group ( $P = .004$ ).<sup>195</sup>

The most frequently missing teeth in women with EOC were the maxillary second premolars, followed by the maxillary lateral incisors, mandibular second premolars, and mandibular central incisors. Conversely, the most frequently missing teeth in the control group individuals were the maxillary lateral incisors, followed by the mandibular second premolars.<sup>195</sup> In addition from this sample, bilateral occurrence of EOC was more common than unilateral occurrence in women with hypodontia ( $P = .021$ ; odds ratio [OR] = 2.9; confidence interval [CI] = 1.15–7.36). There was also a statistically significant difference between the EOC group and control group regarding the presence of other malignant tumors ( $P < .001$ ).

A study of self-reported family cancer history and analysis of 14 DNA markers in the *AXIN2*, *FGF3*, *FGF10*, and *FGFR2* genes in Brazilian individuals with dental agenesis found statistical associations between the genes and tooth agenesis. Further supporting the concept of genetic associations for dental agenesis also being involved in familial predisposition towards developing cancer, the individuals who had dental agenesis had an increased risk of having a family history of cancer ( $P = .00006$ ; OR = 2.7; 95% CI = 1.6–4.4).<sup>196</sup> It should be noted that although the conglomerate self-reported family history of cancer was significant, a breakdown of types of cancer by “type” (organ or body location) found only the brain and nervous system, breast, and prostate to be significant for probands with hypodontia.<sup>196</sup>

Future studies of the family history and genotypes of individuals with hypodontia will help illustrate the potential relative risk of cancer development in individuals or family members with hypodontia compared with that in the general population. Currently, there is a great deal to learn regarding potential connections between dental agenesis and cancer. As such, one should use extreme caution when/if mentioning these findings to a young patient. It is recommended that discussion of these types of genetic connections between dental agenesis and cancer are only warranted with a patient (and their family) after an extensive family history is gathered to determine whether sufficient evidence exists to support a genetic connection between the two phenotypes within the family line. If a connection appears to exist, a referral for genetic testing and counseling may be in order.

## ECTODERMAL DYSPLASIAS

Developmental agenesis of primary teeth is relatively rare. When several primary teeth fail to develop, other ectodermal deficiencies are usually evident. There are more than 170 types of ectodermal dysplasia with various anomalies of ectodermal derivatives, including both primary and permanent teeth, hair, nails, and skin. Children with missing primary and permanent teeth may have some or all of the signs of a type of ectodermal dysplasia and should undergo further evaluation.<sup>162</sup>

One of the more common types of ectodermal dysplasia, X-linked recessive hypohidrotic ectodermal dysplasia (XLHED, OMIM 305100, [www.omim.org](http://www.omim.org)) has already been mentioned in this chapter. This condition is also called anhidrotic ectodermal dysplasia (since there is usually at least minimal ability to perspire, the “anhidrotic” term is not recommended) and Christ-Siemens-Touraine syndrome. Hypodontia and dental hypoplasia, as well as hypotrichosis, hypohidrosis, and asteatosis, are characteristic of XLHED. Secondary characteristics include a deficiency in salivary flow, protuberant lips, and a saddle-nose appearance. The skin is often dry and scaly, and there is fissuring at the corners of the mouth. Animal models of X-linked hypohidrotic ectodermal dysplasia secondary to ectodysplasin A (*EDA*) variants of pathological significance, including canine models, have shown that postnatal intravenous administration of soluble recombinant *EDA* significantly corrected the development of the adult teeth and positively affected other components of the condition.<sup>197</sup>

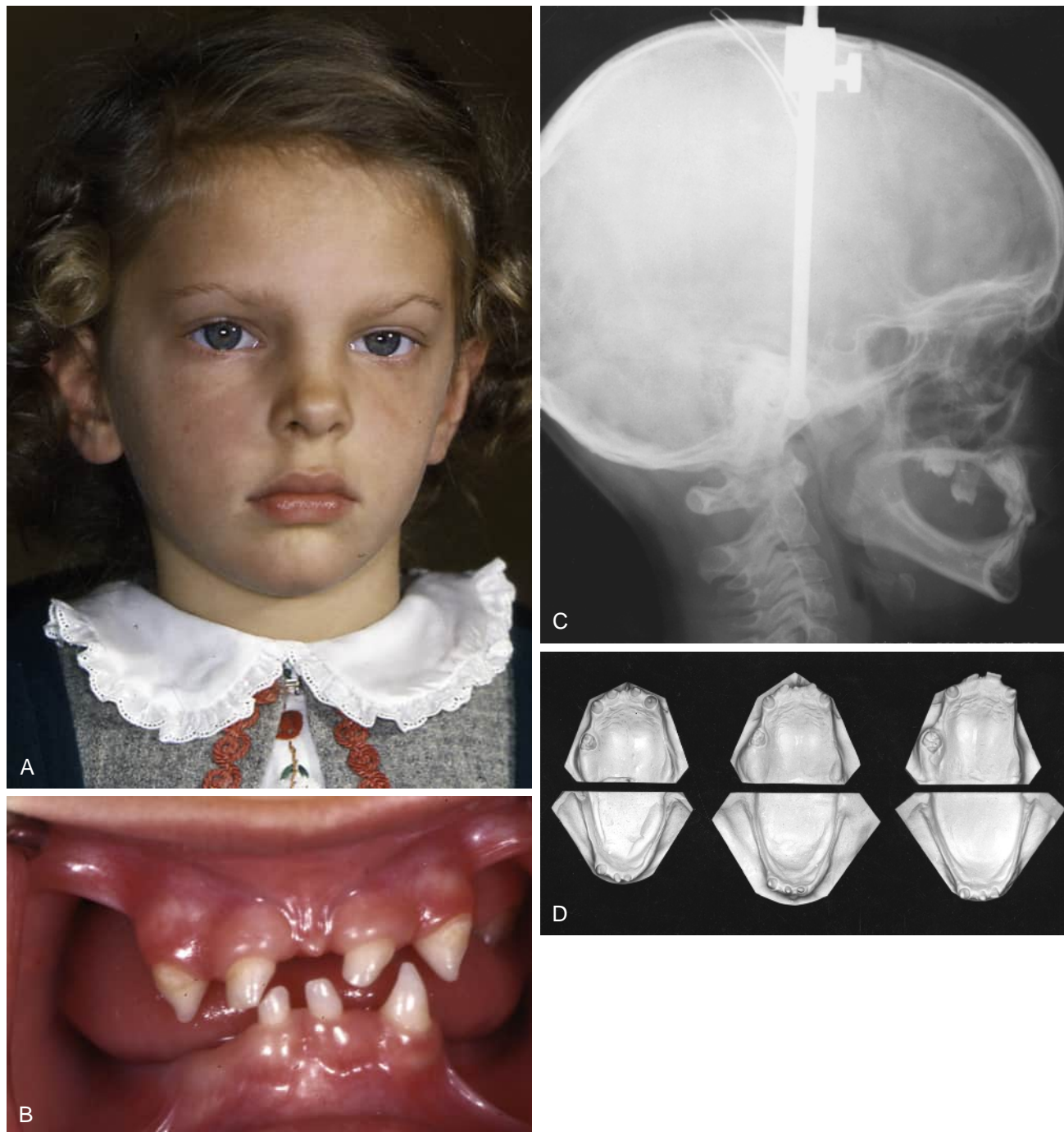
Subsequently, the recombinant fusion protein Fc-*EDA* comprising the receptor-binding domain of *EDA* and the Fc domain of human IgG1 was administered at 26 and 31 weeks of gestation into the amniotic sacs of a pair of mono-chorionic, diamniotic twin male fetuses diagnosed prenatally with XLHED based on lack of tooth germs and because they had an affected older brother who was hemizygous for a missense mutation in the *EDA* gene (Y304C). The recombinant protein was also injected into the amnion of a single affected human fetus at gestational week 26. All three children were able to perspire and had evidence of developing initial tooth buds at 14–22 months of age.<sup>198</sup> These children will be followed to see if this corrected phenotype persists and to what extent. This shows the potential for recombinant protein therapy in certain genetic disorders involving dental development.

There are rare autosomal recessive (e.g., ECTD11B, OMIM 614941 and ECTD10B, OMIM 224900, [www.omim.org](http://www.omim.org)) and an autosomal dominant form (ECTD10A, OMIM 129490, [www.omim.org](http://www.omim.org)) of hidrotic ectodermal dysplasia that maybe similar to, or clinically indistinguishable from, XLHED. Since these types are not due to a deficiency of *EDA*, an accurate genetic diagnosis to distinguish the X-linked form, the dominant or recessive types, will be necessary if recombinant *EDA* therapy is to be employed in the future.

## DENTAL TREATMENT IN ECTODERMAL DYSPLASIAS

Because the absence of teeth predisposes the child to a lack of alveolar process growth, the construction of dentures,





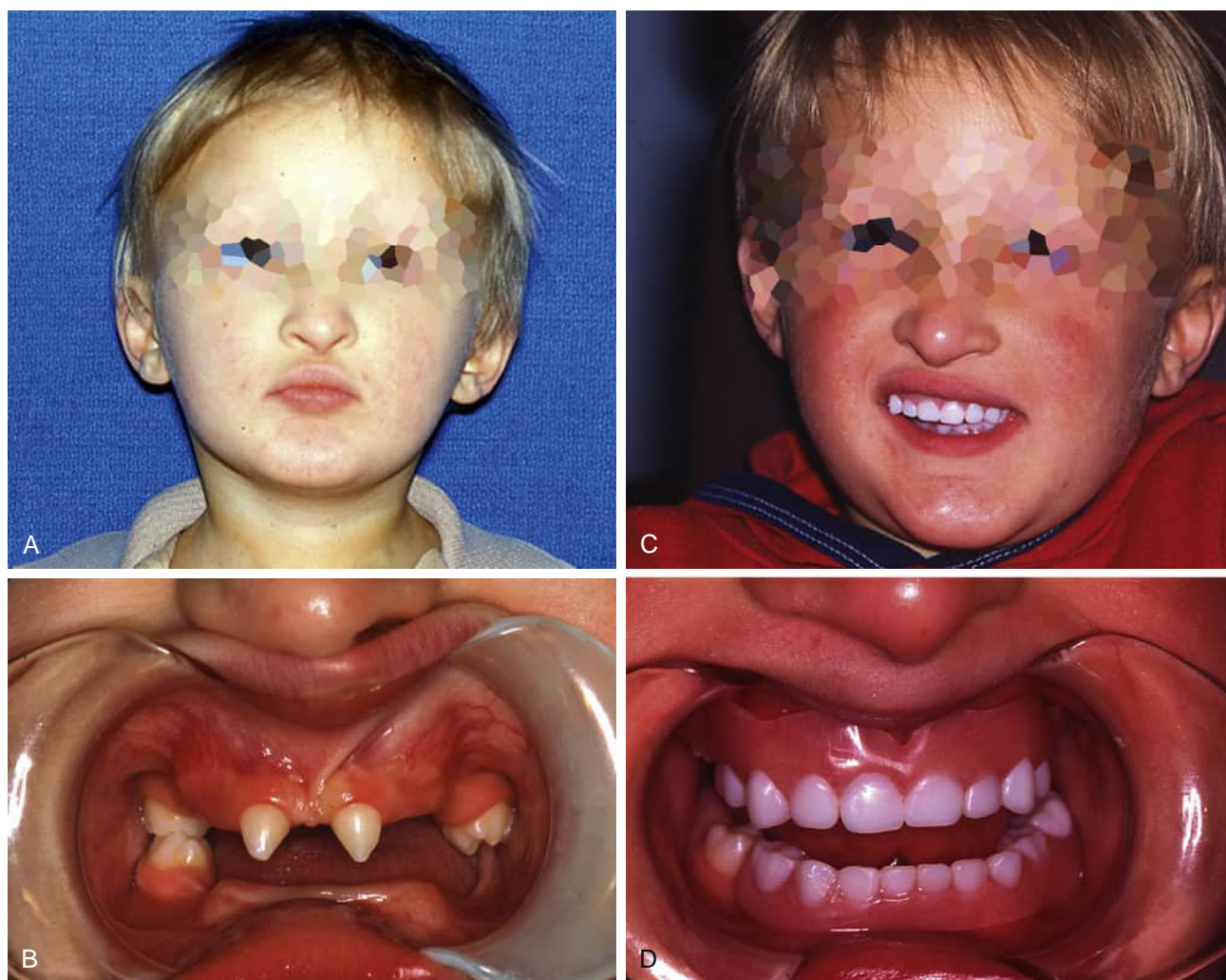**Fig. 3.46** (A) A 4-year-old girl with many features of ectodermal dysplasia. There was a history of consanguinity. (B) The anterior teeth were small and conical. The lack of development of the alveolar process is evident. (C) The facial pattern was good, even though many primary and permanent teeth were missing. (D) Partial dentures were constructed, modified, and remade as additional teeth erupted. The models show how growth has occurred in the mandible and maxilla.

partial dentures, or overdentures is complicated. Serial lateral cephalograms obtained during childhood and adolescence have shown that the sagittal development of the mandible is essentially normal in hypohidrotic ectodermal dysplasia. A deficiency in sweat glands predisposes to increased body temperature, and children with hypohidrosis are extremely uncomfortable during hot weather. Many of them must reside in cool climates. Children with most of the common types of ectodermal dysplasia usually have normal mental capacity and a normal life expectancy.

Consanguinity increases the likelihood of expression of an inherited recessive trait or condition (Fig. 3.46).

The primary and permanent teeth that are present may be normal or reduced in size. The anterior teeth are often conical, which is characteristic of oligodontia associated with many types of ectodermal dysplasia. The primary molars without permanent successors tend to become ankylosed and develop infraocclusion.

Many types of ectodermal dysplasia with different modes of inheritance can be illustrated by describing a “tooth



**Fig. 3.47** (A) A 4-year-old boy with characteristics of ectodermal dysplasia. Many primary and permanent teeth are congenitally missing. The skin is dry and the hair is sparse. (B) The anterior primary teeth are typically conical. (C and D) A full maxillary overdenture and a partial mandibular denture were constructed.

and nail” type of autosomal dominant ectodermal dysplasia (ECTD3 OMIM 189500, [www.omim.org](http://www.omim.org)), also called *Witkop syndrome*, reported by Giansanti et al.<sup>199</sup> This ectodermal dysplasia is characterized by hypoplastic nails and hypodontia. Similar to the association of variants of pathological significance in the *EDA* gene with both isolated (nonsyndromic) hypodontia and syndrome(s) with hypodontia, variants in the *MSX1* gene different from that found when only hypodontia is present have been reported by Jumlongras et al.<sup>200</sup> in a family with tooth and nail syndrome. In contrast to most nonsyndromic hypodontias in which premolars and maxillary lateral incisors (excluding third molars) are most often missing, the mandibular incisors, second molars, and maxillary canines are most frequently absent. Overall, the teeth are generally not affected to the extent seen in XLHED, and there is little involvement of the hair and sweat glands.<sup>201</sup>

For children with many missing primary teeth, partial dentures can be constructed at an early age; 2- and 3-year-old children have successfully worn partial dentures. Their ability to masticate food increases, and their nutritional

status may improve. A partial denture can be adjusted or remade at intervals to allow for the eruption of permanent teeth. Denture construction at an early age may also reduce the psychological problem of the child’s feeling “different” (Fig. 3.47).

If the permanent teeth erupt in good position and in favorable relationship to each other, partial dentures may serve until the child is old enough for implants or a fixed partial denture (described in Chapter 25). However, orthodontic and surgical procedures may be necessary before the prosthodontic treatment.

Bonding techniques have improved clinicians’ ability to provide aesthetic interim restorations and greater function for patients with conical teeth with or without oligodontia or hypodontia. In 2003, Nunn et al. published a series of five papers that outline the management of patients with hypodontia by a coordinated interdisciplinary team of dentists and demonstrate the advantages of this approach.<sup>202–206</sup> Several dental specialties are represented on the team. Ideally, the initial responsibility for oversight and coordination of the patient’s care begins in infancy



with the services of a pediatric dentist. As the patient grows and develops through puberty, a general family practitioner may assume the oversight and coordination responsibilities.

When maxillary lateral incisors are missing, the clinician must analyze the occlusion and arches carefully to determine whether there is sufficient room within the arch to maintain space and to provide a fixed partial denture. If space for a normal sized lateral incisor replacement is insufficient, the clinician may sometimes choose to move the canine forward into the lateral position and reshape it to appear more like a permanent lateral incisor.

## Intrinsic Discoloration of Teeth (Pigmentation of Teeth)

The primary teeth occasionally have unusual pigmentation. Certain conditions arising from the pulp can cause the entire tooth to appear discolored. Factors causing these conditions include blood-borne pigment, blood decomposition within the pulp, and drugs used in procedures such as root canal therapy. (Color changes in relation to trauma are discussed in [Chapter 28](#).)

### DISCOLORATION IN HYPERBILIRUBINEMIA

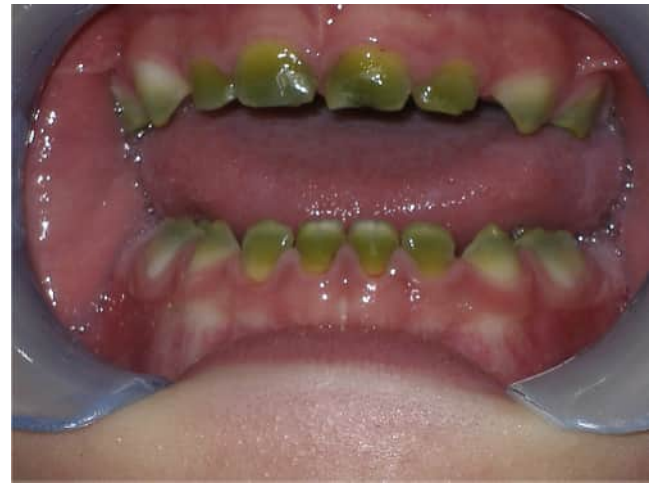In several conditions, excess levels of bilirubin are released into the circulating blood.<sup>207</sup> If teeth are developing during periods of hyperbilirubinemia, they may become intrinsically stained. The two most common disorders that cause this intrinsic staining are erythroblastosis fetalis and biliary atresia. Other less common causes are premature birth, ABO blood type incompatibility, neonatal respiratory distress, significant internal hemorrhage, congenital hypothyroidism, biliary hypoplasia, tyrosinemia,  $\alpha$ 1-antitrypsin deficiency, and neonatal hepatitis.

Erythroblastosis fetalis results from the transplacental passage of maternal antibodies against red blood cell antigens of the infant, which leads to an increased rate of red blood cell destruction.<sup>208</sup> Cullen<sup>209</sup> reported regarding the occurrence of erythroblastosis fetalis produced by Kell immunization. *In utero*, the maternal antibodies coat the fetal red blood cells and cause hemolysis. The fetus develops anemia with a resultant increase in the bilirubin content of the amniotic fluid. The newborn appears pale and anemic. Shortly after birth, jaundice occurs as a result of the high bilirubin levels. Despite the development of a method of prevention of maternal isoimmunization by Rh antigens, it remains a significant cause of anemia and jaundice in newborn infants. However, an infant from Rh-negative mother's first pregnancy rarely develops this disease.

If an infant has had severe, persistent jaundice during the neonatal period, the primary teeth may have a characteristic blue-green color; in a few instances, brown teeth have also been observed ([Fig. 3.48](#)). The color of the pigmented tooth is gradually reduced. The fading in color is particularly noticeable in the anterior teeth.

### DISCOLORATION IN PORPHYRIA

The porphyrias are inherited (in an autosomal dominant mode usually, although congenital erythropoietic



**Fig. 3.48** Characteristic blue-green discoloration of the primary teeth in an infant who suffered from persistent jaundice in the neonatal period.

porphyria [CEP], OMIM 263700, [www.omim.org](http://www.omim.org), is autosomal recessive) and acquired disorders in which the activities of the enzymes of the heme biosynthetic pathway are partially or almost completely deficient.<sup>210</sup> As a result, abnormally elevated levels of porphyrins and/or their precursors are produced, which accumulate in tissues and are excreted.

Children with CEP have red-colored urine, are hypersensitive to light, and develop subepidermal bullous lesions when their skin is exposed to sunlight. Their primary teeth are purplish-brown as a result of the deposition of porphyrin in the developing structures (erythrodontia). The permanent teeth also show evidence of intrinsic staining but to a lesser degree.

### DISCOLORATION IN CYSTIC FIBROSIS

Cystic fibrosis (OMIM 219700, [www.omim.org](http://www.omim.org)) is an autosomal recessive, chronic, multisystem, life-shortening disorder characterized primarily by poor digestion and obstruction and infection of the airways. It is caused by variants of pathological significance in both copies of the cystic fibrosis transmembrane regulator gene (*CFTR*). Zegarelli et al.<sup>211</sup> have suggested that tooth discoloration in persons with cystic fibrosis is a result of either the disease alone or therapeutic agents, especially tetracyclines, or a combination of the two factors. The possibility that there is, at least in part, an intrinsic developmental enamel abnormality secondary to the disease is supported by the investigations of Wright et al.<sup>212</sup> who found abnormal enamel in the incisors of homozygous *CFTR* knockout mice. Further studies by Arquitt et al.<sup>213</sup> also strongly suggest that *CFTR* plays an important role in enamel formation.

Although many patients with cystic fibrosis who lived during the latter half of the 20th century endured unsightly discolorations of their teeth because they received tetracycline therapy during a period when their tooth crowns were forming, modern physicians rarely, if ever, prescribe tetracyclines for patients during their tooth-forming years. During the era when tetracycline therapy for children was common, Primosch<sup>214</sup> reported regarding tetracycline



tooth discolorations, enamel defects, and dental caries in 86 young patients with cystic fibrosis. The incidence of dental caries in these patients was compared with that in control individuals matched for gender, race, exposure to optimally fluoridated water, chronologic age, and dental age. The findings indicated a high prevalence of tooth discolorations and enamel defects but a significantly reduced caries experience in the patients with cystic fibrosis who had received tetracycline drugs.

### DISCOLORATION IN TETRACYCLINE THERAPY

Dentists and physicians have observed that children who receive tetracycline therapy during the period of calcification of the primary or permanent teeth show a degree of pigmentation of the clinical crowns of the teeth. As van der Bijl and Pitigoi-Aron<sup>215</sup> pointed out, because the tetracyclines chelate calcium salts, the drugs are incorporated into the bones and teeth during calcification. The crowns of the affected teeth are discolored, ranging from yellow to brown and from gray to black (Fig. 3.49). Currently most, if not all, infections in children can be treated effectively with antibiotics that do not cause tooth discoloration. Consequently, this previously common problem is now rare.

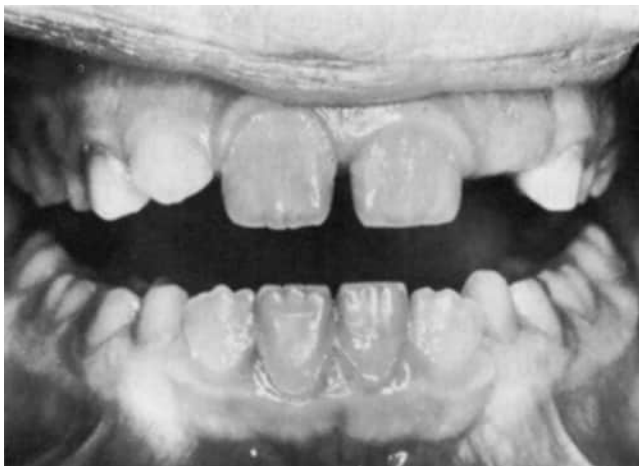

Fig. 3.49 Pigmentation in tetracycline therapy. The permanent incisors that have erupted appear yellowish-brown.

Tetracycline is deposited in the dentin and, to a lesser extent, in the enamel of teeth that are calcifying during the time the drug is administered. The location of the pigment in the tooth can be correlated with the development stage of the tooth and the time and duration of drug administration. The tetracyclines, which are yellow, fluoresce under ultraviolet light. When tetracyclines in the dental structures darken from yellow to brown, the fluorescence diminishes because of the destruction of the fluorophores.

The exposure of the teeth to light results in slow oxidation, with a change in color of the pigment from yellow to brown. The larger the dose of drug relative to body weight, the deeper the pigmentation. The duration of exposure to the drug may be less important than the total dose relative to body weight.

Because tetracyclines can be transferred through the placenta, the crowns of the primary teeth may also show noticeable discoloration if tetracyclines are administered during pregnancy. Moffitt et al.<sup>216</sup> have observed that the critical period for tetracycline-related discoloration in the primary dentition is 4 months *in utero* to 3 months postpartum for maxillary and mandibular incisors and 5 months *in utero* to 9 months postpartum for maxillary and mandibular canines.

The sensitive period for tetracycline-induced discoloration in the permanent maxillary and mandibular incisors and canines is approximately 3 months to 7 years of age. The maxillary lateral incisors are an exception because they begin to calcify at 10–12 months postpartum.

In addition to fluoride and tetracyclines (including minocycline), ciprofloxacin has been associated with intrinsic staining. Medications that have been reported to cause extrinsic staining include chlorhexidine, oral iron salts, co-amoxiclav, and essential oils.<sup>217</sup>

### BLEACHING OF INTRINSIC TOOTH DISCOLORATION

Vital bleaching of intrinsically discolored teeth became a popular dental cosmetic procedure during the late 20th century (Fig. 3.50); several safe techniques are available. The accepted procedures incorporate the use of a peroxide compound placed on the tooth surface that bleaches the intrinsic tooth pigments to a lighter hue. Adding energy to

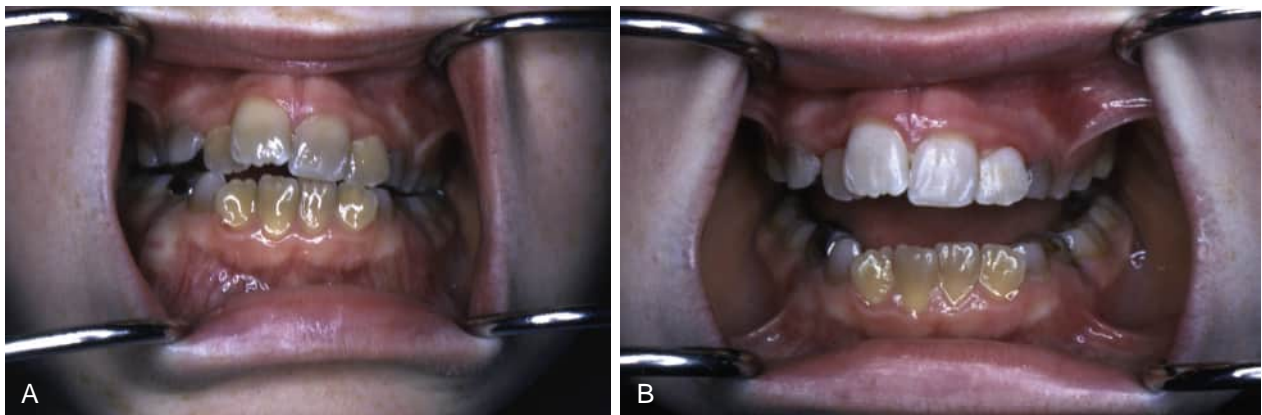


Fig. 3.50 (A) Tetracycline-pigmented teeth. (B) The maxillary incisors have been bleached; the lower mandibular incisors are untreated.

the peroxide compound in the form of heat, light, or laser radiation may accelerate this process.

Although many diluted tooth bleaching products are available over the counter, the most efficient and effective systems are provided or prescribed by a dentist. To be safe, bleaching procedures must be carefully performed and monitored. Although these procedures are usually performed on permanent teeth, Brantley et al.<sup>218</sup> reported successfully bleaching discolored primary teeth in a 4-year-old girl.

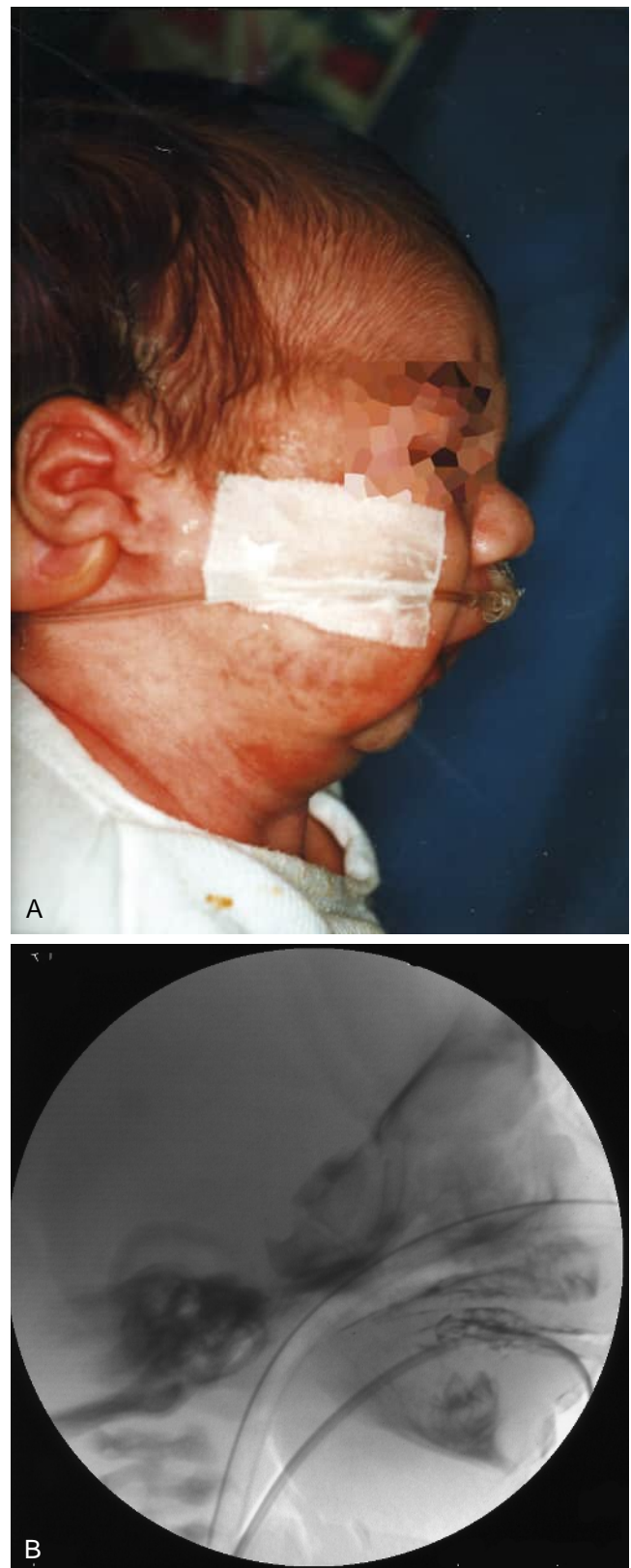
Refer to current textbooks on endodontics or cosmetic dentistry for more information on bleaching techniques. Another valuable resource with considerable detailed information is the Special Supplement of the *Journal of the American Dental Association*, volume 128, April 1997.<sup>219–232</sup> This supplement provides reports presented by numerous recognized bleaching experts during an international symposium about nonrestorative treatment of discolored teeth.

If the tooth discoloration is severe and bleaching does not adequately improve the condition, the dentist may consider masking the visible surfaces with bonded veneer restorations like those discussed in Chapter 12. Bleaching and enamel microabrasion may be used in combination for certain types of discoloration, and these procedures may also be used as adjunctive steps before placement of veneer restorations.

## Micrognathia (Robin Sequence)

Micrognathia (small mandible, particularly in the sagittal plane) is usually present at birth (congenital), but it may be acquired in later life (Fig. 3.51). The etiology of congenital micrognathia is heterogeneous. Deficient nutrition of the mother and intrauterine injury resulting from pressure or trauma have been suggested as possible causes. In addition, micrognathia may be part of the Pierre Robin, or just Robin, sequence (OMIM 261800, [www.omim.org](http://www.omim.org)), which also includes cleft palate (especially in the posterior with a rounded distal edge) and glossoptosis. The incidence of Robin sequence has been estimated to be one out of 8500–14,000.<sup>233</sup> Although this developmental sequence may be sporadic, it is often (on the order of 45% of cases)<sup>234</sup> the pleiotropic expression of a gene for a condition such as Stickler syndrome (OMIM 108300 [type I], or OMIM 604841 [type II], [www.omim.org](http://www.omim.org)) or velocardiofacial syndrome (OMIM 192430, [www.omim.org](http://www.omim.org)) and warrants a clinical genetic evaluation.<sup>156,235</sup> See Tan et al.<sup>233</sup> for a table of selected syndromes and chromosomal anomalies associated with Robin sequence.

Infants with mandibular micrognathia have difficulty breathing and experience episodes of cyanosis; they must be kept in a ventral position as much as possible. The anterior portion of the mandible is positioned so that the tongue has little if any support and can fall backward, causing an obstruction. Based on longitudinal growth studies, Pruzansky and Richmond<sup>236</sup> reported that in most instances of congenital micrognathia, the increment in mandibular growth relative to total facial growth during infancy and early childhood is sufficient to overcome the extreme deficiency of the chin at birth. This is often referred to as “catch-up growth.”



**Fig. 3.51** (A) Micrognathia in a 1-month-old girl. The chin is noticeably recessive. (B) The radiograph shows the extent of the development of the dentition at birth. When the patient was 1 year old, the micrognathia was less noticeable.

Daskalogiannakis et al.<sup>237</sup> performed 29 cephalometric measurements, taken at three different ages, on 96 patients with Robin sequence and compared them with similar measurements in 50 patients with isolated clefting of the palate (control group). They found that patients with Robin sequence had mandibles significantly smaller than those in the control group from approximately 5.5 to 17 years of age. This finding suggests that the mandibles of patients with Robin sequence do not really grow proportionately more than those in others not affected by the disorder. Although the size and position of the mandible growth may depend on the etiology or associated syndrome,<sup>238</sup> there appears to be no statistical difference between the syndromic and nonsyndromic Robin patients needing operative airway management.<sup>234</sup>

The nursing bottle may be used in the treatment of congenital micrognathia to help promote adequate function of the mandible. Because the infant should be made to reach for the nipple of the nursing bottle, the bottle should never be allowed to rest against the mandible. The parent is instructed to sit the infant on his or her lap in an upright position and place gentle forward pressure on the child's ramus with the thumb and fingers while offering the bottle. Thus the infant must extend the mandible to feed. Mandibular advancement by orthopedic force is sometimes recommended, as well as surgical mandibular reconstruction.

Hotz and Gnoinski<sup>239</sup> have described the use of a special palatal obturator appliance to help infants born with Robin sequence. In addition to providing coverage to seal the cleft palate, the appliance includes a posterior extension to simulate the missing soft palate structures, including the uvula. The appliance seems to stimulate the infant to maintain a more normal tongue position. The improved tongue position significantly reduces the tendency for the infant to experience life-threatening apneic episodes. Dean<sup>240</sup> also reported successful use of similar appliances in infants with Robin sequence, including 22 infants with severe airway obstruction. The results supported the use of the obturator but also indicated that further study of treatment with these appliances was needed.

Acquired micrognathia may develop gradually and may not be evident until children reach 4–6 years of age. Although this anomaly in growth is usually not related to trauma, ankylosis of the temporomandibular joint(s) caused by a birth injury or trauma in later life may result in an acquired type of micrognathia. Infection in the temporomandibular joint area can also cause arrested growth at the head of the condyle and lead to development of the acquired pattern of micrognathia. In cases of true ankylosis of the mandible, arthroplasty should be recommended.

## Anomalies of the Tongue

Pediatric patients with unremarkable medical histories rarely complain of symptomatic tongue lesions. However, the tongue should be inspected carefully during the examination. Several benign conditions may be evident and should be brought to the attention of the parents.

There are four main types of papillae of the tongue. About 10–15 large circumvallate papillae may be found on the posterior border of the dorsum. These papillae have a blood

supply and are the site of numerous taste buds. Fungiform (mushroom-shaped) papillae may be distributed over the entire dorsum of the tongue; however, they are present in greater numbers at the tip and toward the lateral margins of the tongue. Inflammatory and atrophic changes occurring on the dorsum of the tongue may involve the vascularized fungiform papillae. The most numerous papillae of the tongue are the filiform papillae, which are thin, hair like, and evenly distributed over the dorsal surface. The filiform papillae are without a vascular core, and their continuous growth is slight. The foliate papillae represent a fourth type and are arranged in folds along the lateral margins of the tongue; the taste sensation is associated with these papillae.

## MACROGLOSSIA

Macroglossia refers to a larger-than-normal tongue size and may be either congenital or acquired. Congenital macroglossia, which is caused by an overdevelopment of the lingual musculature or vascular tissues, becomes increasingly apparent as the child develops.

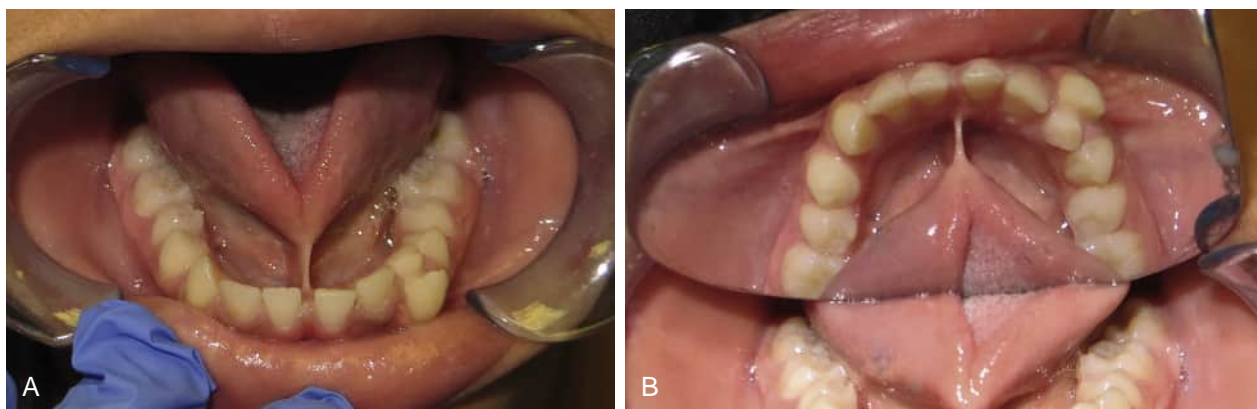
An abnormally large tongue is characteristic of hypothyroidism, in which case the tongue is fissured and may extend from the mouth. Macroglossia is also commonly observed with glycogen storage disease II (also known as Pompe disease, OMIM 232300, [www.omim.org](http://www.omim.org)), neurofibromatosis type 1 (OMIM 162200, [www.omim.org](http://www.omim.org)), and Beckwith-Wiedemann syndrome (OMIM 130650, [www.omim.org](http://www.omim.org)). It can be an isolated and sporadic (nonfamilial) trait or a familial (autosomal dominant) trait (OMIM 153630, [www.omim.org](http://www.omim.org)), as studied by Reynoso et al.<sup>241</sup> Macroglossia has also been cited as a characteristic of Down syndrome (OMIM 190685, [www.omim.org](http://www.omim.org)), although this may be, at least in part, due to the relative size of the oral cavity<sup>242</sup> and myotonia with “drooping” of the tongue out of the oral cavity in some individuals with Down syndrome.<sup>243</sup> These factors can also exacerbate obstructive sleep apnea in individuals with Down syndrome.<sup>243</sup> Occasionally an allergic reaction causes a transitory enlargement of the tongue (angioneurotic edema). Both allergic reaction and injury can cause such severe enlargement of the tongue that a tracheotomy is necessary to maintain a patent airway.

A disproportionately large tongue may cause both an abnormal growth pattern of the jaw and malocclusion. Proclination of the anterior teeth of the mandible or posterior or anterior open bites may also be the result of true or relative macroglossia (size of tongue versus space). The treatment of macroglossia depends on its cause and severity. Surgical reduction of a portion of the tongue is occasionally necessary.

## ANKYLOGLOSSIA (TONGUE-TIE)

In ankyloglossia, a short lingual frenum extending from the tip of the tongue to the floor of the mouth and onto the lingual gingival tissue limits movements of the tongue, which may cause speech difficulties (Fig. 3.52). It has been reported to have a newborn incidence of 4%.<sup>244</sup> Stripping of the lingual tissues may occur if the tongue-tie is not corrected. Surgical reduction of the abnormal lingual frenum is indicated if it interferes with the infant's nursing (lingual





**Fig. 3.52** (A) Ankyloglossia (tongue-tie). A short, heavy lingual frenum extends from the top of the tongue to the floor of the mouth and onto the lingual tissue. (B) A mirror view of the abnormal frenum.

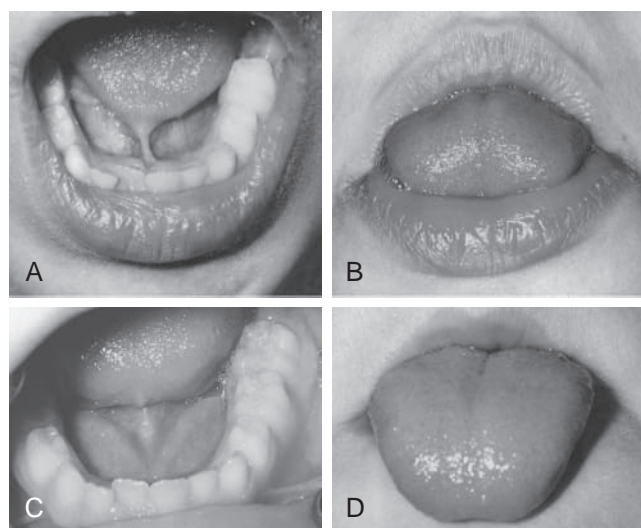
frenectomy, frenotomy, or frenuloplasty). In the older child, a reduction of the frenum should be recommended only if local conditions or speech problems warrant the treatment. Studies of nonsyndromic ankyloglossia have suggested both autosomal dominant (that may be associated with agenesis of mandibular incisors and rarely supernumerary teeth, OMIM 106280, [www.omim.org](http://www.omim.org)) and X-linked inheritance patterns; however, in one of the studies, 47% of those affected had no family history of ankyloglossia.<sup>244</sup> Familial cleft palate with or without ankyloglossia (OMIM 303400, [www.omim.org](http://www.omim.org)) is caused by variants of pathological significance in the T-box 22 transcription factor (*TBX22*) gene.<sup>245</sup>

Ayers and Hilton<sup>246</sup> reported a case of ankyloglossia in a 7-year-old boy who had been evaluated at his school for a speech problem. The patient had previously undergone routine dental examinations, but no treatment had been suggested by the dentist. Tongue mobility and speech patterns improved greatly after the frenum attachment was released surgically. The patient and parents reported very little postoperative discomfort. This history and the results are similar to those of the 6-year-old girl with ankyloglossia illustrated in Fig. 3.53. After studying 30 children with ankyloglossia of age 1–12 years, Messner and Lalakea<sup>247</sup> concluded that tongue mobility and speech improved significantly after frenuloplasty.

### FISSURED TONGUE AND GEOGRAPHIC TONGUE (BENIGN MIGRATORY GLOSSITIS)

A fissured tongue is seen in a small number of children and may be of no clinical significance, although it is sometimes associated with hypothyroidism and Down syndrome. The fissures on the dorsum of the tongue usually have a symmetric pattern and may be longitudinal or at right angles to the margin of the tongue. Vitamin B-complex deficiency may be associated with the fissuring. Treatment of the fissured tongue is generally unnecessary unless a mild inflammation develops at the base of the fissures from an accumulation of food debris. Brushing of the tongue and improved oral hygiene aid in reducing the inflammation and soreness.

A wandering type of lesion and probably the most common tongue anomaly is known as *geographic tongue*.

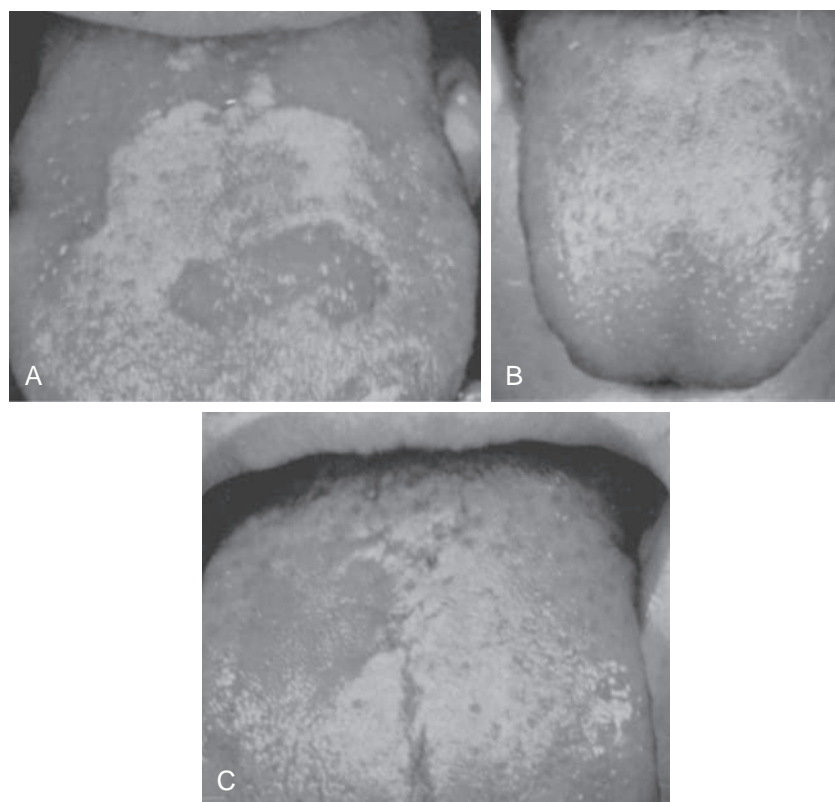


**Fig. 3.53** (A) Ankyloglossia in a 6-year-old girl. (B) Patient had limited tongue mobility and speech problems. (C) Two weeks after surgical release. (D) Tongue mobility and speech improved spontaneously.

Prevalence rates from 1% to as high as 14% have been reported. Kullaa-Mikkonen<sup>248</sup> studied the inheritance of fissured tongue in 31 families and concluded that fissured tongue with smooth-surfaced papillae is transmitted as an autosomal dominant trait with incomplete penetrance and is preceded by geographic tongue (OMIM 137400, [www.omim.org](http://www.omim.org)). The severity of fissured tongue increased with age. Tongue fissuring with normal-appearing filiform papillae was found not to be familial and was not associated with geographic tongue.

Geographic tongue is often detected during routine dental examination of pediatric patients who are unaware of the condition. Red, smooth areas devoid of filiform papillae appear on the dorsum of the tongue. The margins of the lesions are well developed and slightly raised. The involved areas enlarge and migrate by extension of the desquamation of the papillae at one margin of the lesion and regeneration at the other (Fig. 3.54). Every few days, a change can be noted in the pattern of the lesions. However, the condition is self-limiting and no treatment is necessary.

Bánóczy et al.<sup>249</sup> have indicated that gastrointestinal disturbances associated with anemia may be related to migratory glossitis. In addition, a psychosomatic disorder should



**Fig. 3.54** (A) Geographic tongue. The smooth areas are devoid of filiform papillae. (B) The pattern observed at the initial visit is indistinguishable 4 weeks later. (C) In 1 year, a new pattern is developing on the dorsum of the tongue.

be considered as a possible etiologic factor. Histologically, the process appears to be superficial, with desquamation of the keratin layers of papillae and inflammation of the corium.

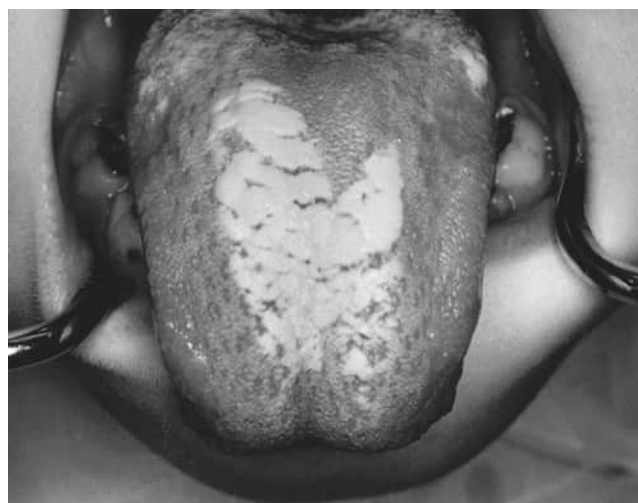### COATED TONGUE

A white coating of the tongue is usually associated with local factors. The amount of coating on the tongue varies with the time of day and is related to oral hygiene and the character of the diet. The coating consists of food debris, microorganisms, and keratinized epithelium found on and around the filiform papillae (Fig. 3.55).

Children who have a congenital or acquired deficiency in salivary flow may have a coated tongue, occasionally to the extent that a dry crust appears on the dorsum of the tongue. Frequent rinsing with artificial saliva palliates the condition. Systemic disease with associated fever and dehydration may also cause a coating, which is usually white but may become stained with foods or drugs. Increased ingestion of liquid is appropriate to alleviate this situation. Brushing the tongue with a toothbrush and dentifrice reduces the coating.

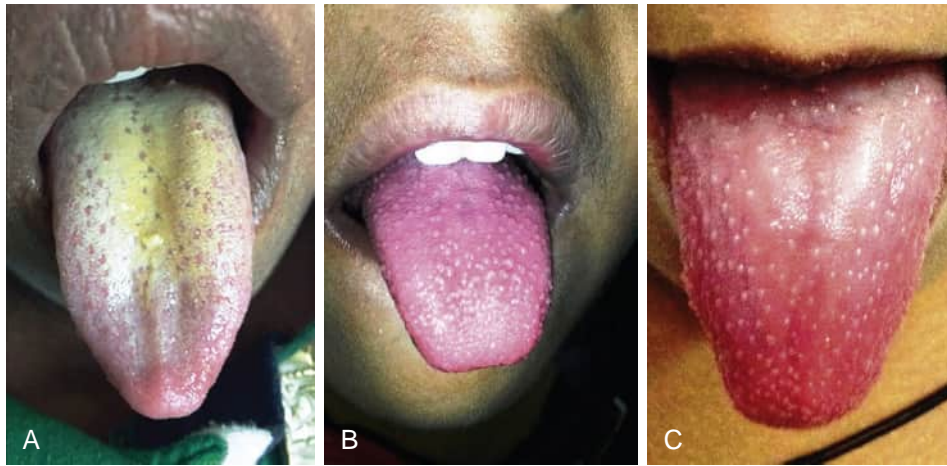
### WHITE STRAWBERRY TONGUE

An enlargement of the fungiform papillae extending above the level of the white desquamating filiform papillae gives the appearance of an unripe strawberry. The condition has been observed in cases of scarlet fever and Kawasaki disease

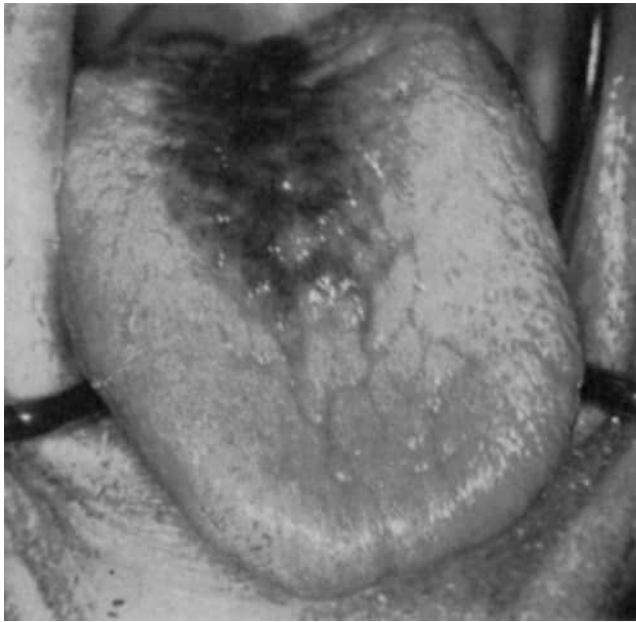


**Fig. 3.55** White coating of the tongue is usually associated with local factors.

(OMIM 611775, [www.omim.org](http://www.omim.org)) in young children. During the course of scarlet fever and other acute febrile conditions, the coating on the tongue disappears, and the enlarged red papillae extend above a smooth, denuded surface, which gives the appearance of a red strawberry or raspberry. The tongue returns to normal after recovery from the systemic condition (Fig. 3.56).



**Fig. 3.56** (A) White strawberry tongue (initial appearance with scarlet fever). (B) Red strawberry tongue in late scarlet fever stage. (C) Strawberry tongue in Kawasaki disease. (Reproduced as a composite 3-part image from *Indian J Dermatol Venereol Leprol*, Volume 84, Pages 500-505, by Adya KA, Inamadar AC, Palit A., *The strawberry tongue: What, how and where?* (Copyright 2018), <http://www.ijdv.com/text.asp?2018/84/4/500/229194>, with permission from Wolters Kluwer Medknow Publications.)



**Fig. 3.57** Black hairy tongue. This condition usually has no clinical significance.

### BLACK HAIRY TONGUE

Black hairy tongue is rarely seen in children but occurs in young adults and has been related to the oral and systemic intake of antibiotics, smoking, and excessive ingestion of dark drinks such as coffee and tea (Fig. 3.57). Accumulations of keratin on the filiform papillae in the middle third of the tongue become elongated into hair like processes, sometimes as long as 2.5 cm (1 inch). Neville et al.<sup>207</sup> note that the cause is uncertain, but that an apparent increase in keratin production or a decrease in normal keratin desquamation results.<sup>207</sup> It is a benign condition with no serious sequelae. Rigorous hygienic procedures such as brushing and scraping the tongue may help control it. When the condition appears during antibiotic therapy, it usually

disappears again without specific treatment after the antibiotics are discontinued.

### INDENTATION OF THE TONGUE MARGIN (CRENATION)

During the examination of the pediatric patient, the dentist may notice a scalloping or crenation along the lingual periphery. Careful examination will reveal the markings to be caused by the tongue's position against the lingual surfaces of the mandibular teeth. Although usually no significance can be attached to these crenations, they have been related to pressure habits, macroglossia, vitamin B-complex deficiency, and systemic disease that causes reduced muscle tone.

### MEDIAN RHOMBOID GLOSSITIS (CENTRAL PAPPILARY ATROPHY OF THE TONGUE)

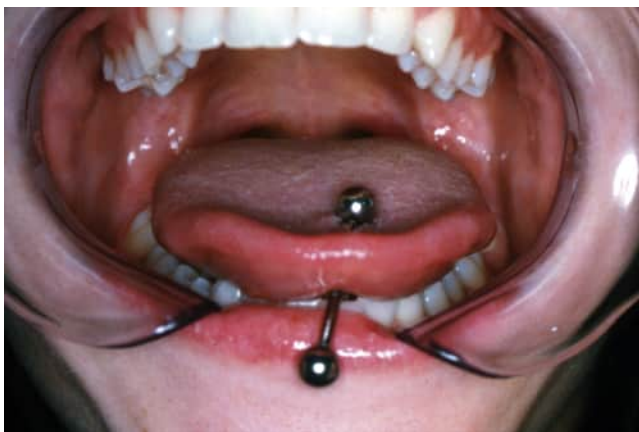Median rhomboid glossitis is an oval, rhomboid, or diamond-shaped reddish patch on the dorsal surface of the tongue immediately anterior to the circumvallate papillae. Flat, slightly raised, or nodular, it stands out distinctly from the rest of the tongue because it has no filiform papillae. This atrophic area is usually asymptomatic. Long believed to be a developmental anomaly, the condition is now recognized almost exclusively to represent a chronic, localized, and mild candidal infection, as proposed by Cooke.<sup>250</sup>

Although median rhomboid glossitis occurs more often in adults, it occurs sometimes in teenagers and even infrequently in younger children. Barasch et al.<sup>251</sup> have observed it with high prevalence in HIV-positive children. Treatment with topical antifungal agents is appropriate.

### TRAUMA TO THE TONGUE, TEETH, AND ORAL TISSUES, WITH EMPHASIS ON TONGUE PIERCING

A child may bite his or her tongue as a result of a traumatic blow or fall. The dentist may inadvertently traumatize the tongue with a cutting instrument during operative





**Fig. 3.58** Tongue ornaments are popular among teenagers and young adults.

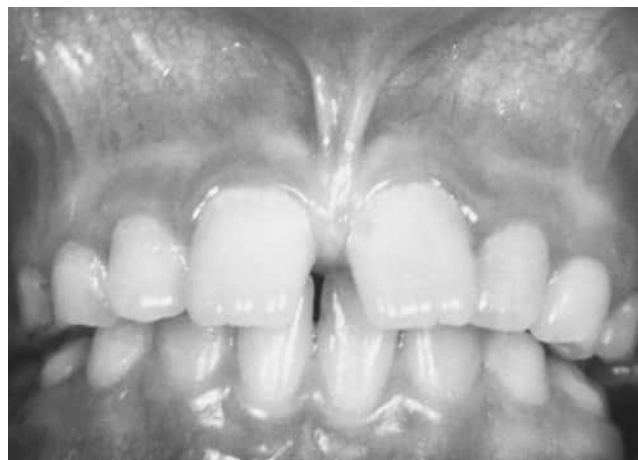procedures. Deep laceration of the tongue requires suturing to minimize scarring and to aid in hemorrhage control. In cases of severe injury, the tongue should be examined carefully for the detection of any enlargement that might interfere with the maintenance of an open airway.

Tongue piercing, a deliberate trauma, is one of the popular types of body piercing occurring in all parts of the world today, especially among teenagers and young adults (Fig. 3.58). Tongue piercing is of interest in dentistry because it carries a high risk of adverse intraoral sequelae and can have significant systemic effects. The scientific literature has grown extensively with documented cases of complications following piercing procedures. Fractured teeth, dental abrasion, and gingival recession are reported to be common sequelae. Other observed complications with life-threatening potential include brain abscess,<sup>252</sup> cephalic tetanus,<sup>253</sup> endocarditis,<sup>254</sup> Ludwig's angina,<sup>255</sup> and upper airway compromise.<sup>256</sup> Whenever appropriate, dentists should counsel their patients and other members of the community about the serious risks associated with this form of body art. If patients insist on wearing tongue ornaments and other body jewelry, they should be advised to remove them at least during athletic activities in which the risk of injury is high.

## Abnormal Labial Frenum

A maxillary midline diastema is frequently seen in preschool and mixed dentition stage children. It is important to determine whether the diastema is normal for that time of development or is related to an abnormal maxillary labial frenum. A midline diastema may be considered normal for many children during the time of eruption of the permanent maxillary central incisors. When the incisors first erupt, they may be separated by bone, and the crowns incline distally because of the crowding of the roots. With the eruption of the lateral incisors and the permanent canines, the midline diastema is reduced, and in most cases normal contact between the central incisors develops.

Insufficient tooth mass in the maxillary anterior region, the presence of peg-shaped lateral incisors, or agenesis of



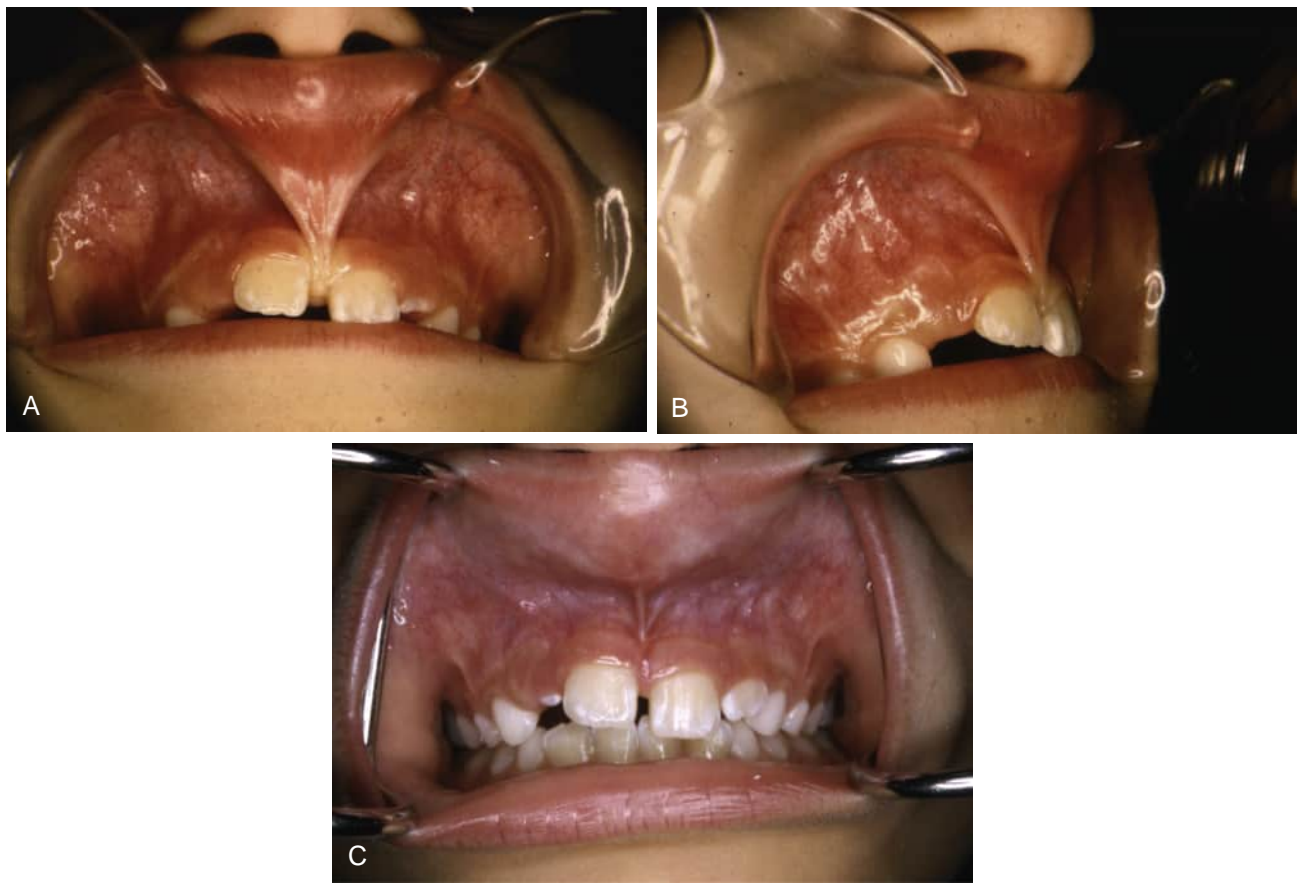
**Fig. 3.59** Abnormal labial frenum. There is blanching of the free marginal tissue between the central incisors and of the palatine papilla. A frenectomy is indicated.

lateral incisors may cause a diastema. Other factors and anomalies, including a midline supernumerary tooth, an oral habit, macroglossia, and abnormally large mandibular anterior teeth, should be considered as possible causes (in addition to an abnormal labial frenum) of the midline diastema.

The labial frenum is composed of two layers of epithelium enclosing a loose vascular connective tissue. Muscle fibers, if present, are derived from the orbicularis oris muscle. The origin of the maxillary frenum is at the midline on the inner surface of the lip. The origin is often wide, but the tissue of the frenum itself narrows in width and is inserted in the midline into the outer layer of periosteum and into the connective tissue of the internal maxillary suture and the alveolar process. The exact attachment site is variable. It can be several millimeters above the crest of the ridge or on the ridge, or the fibers may pass between the central incisors and attach to the palatine papilla.

Many dentists delay considering an abnormal labial frenum as the cause of a diastema until all the maxillary permanent anterior teeth, including the canines, have erupted. This approach may be considered generally correct. However, other diagnostic points should be kept in mind. One can perform a simple diagnostic test for an abnormal frenum during mid- to late-mixed dentition by observing the location of the alveolar attachment when intermittent pressure is exerted on the frenum. If a heavy band of tissue with a broad, fanlike base is attached to the palatine papilla and produces blanching of the papilla, it is safe to predict that the frenum will unfavorably influence the development of the anterior occlusion (Fig. 3.59).

The abnormal labial frenum, in addition to causing a midline diastema, can produce other undesirable clinical conditions. The heavy band of tissue and low attachment can interfere with toothbrushing by making it difficult to place the brush at the proper level in the vestibule to brush in the conventional manner. If fibers of the frenum attach to the free marginal tissue, stretching of the lip during mastication and speech may cause stripping of the tissue from the neck of the tooth. Such attachment may also cause the accumulation of food particles and eventual pocket



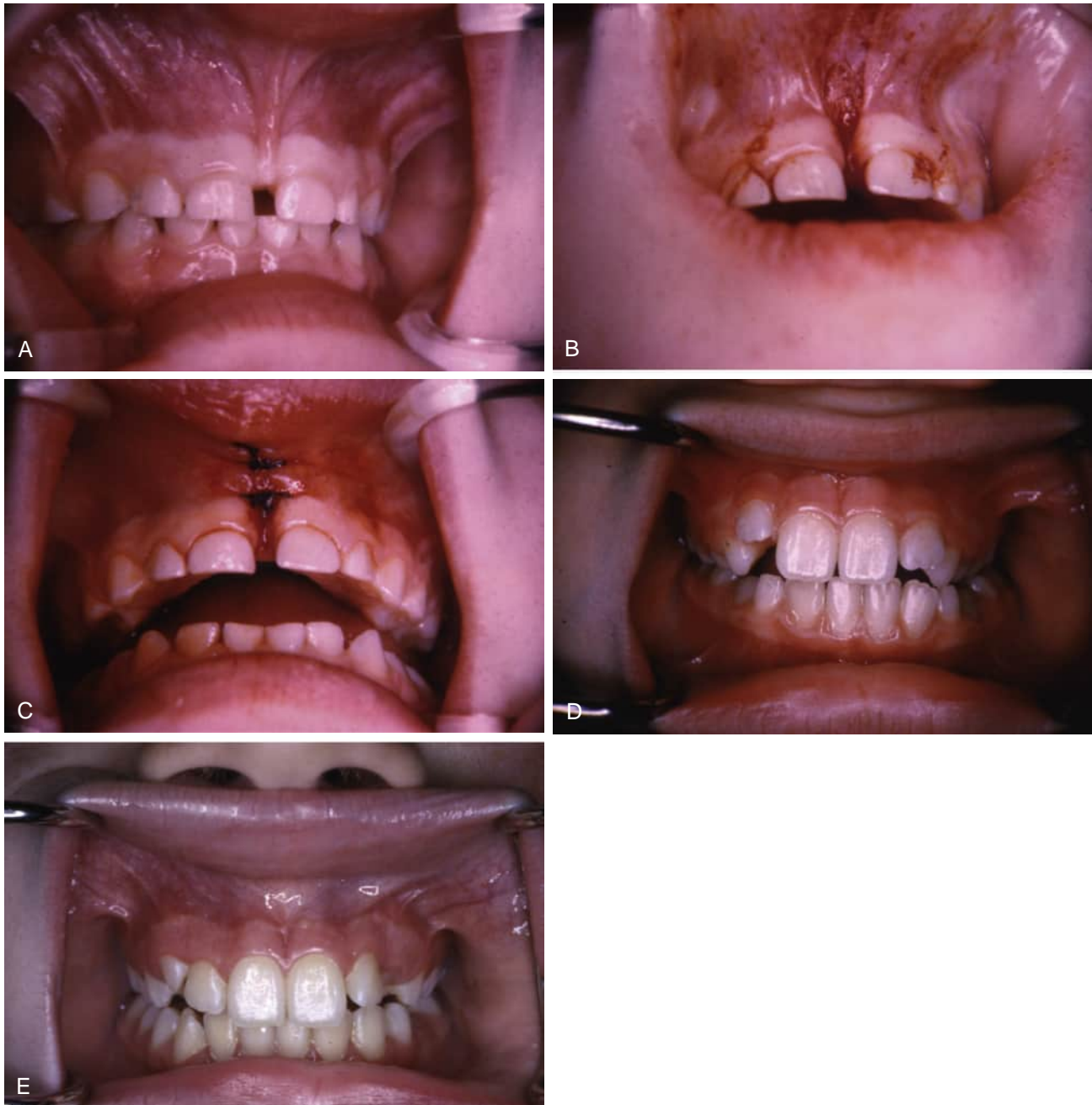
**Fig. 3.60** (A) Abnormal labial frenum in an 8-year-old child. The heavy, fan-shaped band of tissue interfered with speech and had an undesirable appearance. (B) An oblique view of the abnormal frenum. (C) A much more desirable appearance is observed 6 months after the frenectomy.

formation. The abnormal frenum may restrict movements of the lip, interfere with speech, and produce an undesirable cosmetic result (Fig. 3.60).

### FRENECTOMY

The decision regarding treatment of the labial frenum should be made only after a careful evaluation to determine whether the result will be undesirable if the condition is allowed to remain. In the surgical technique, a wedge-shaped section of the tissue is removed, including the tissue

between the central incisors and the tissue extending palatally to the nasal palatine papilla (Figs. 3.60 and 3.61). Lateral incisions are made on either side of the frenum to the depth of the underlying bone. The free marginal tissue on the mesial side of the central incisors should not be disturbed. The wedge of tissue can be picked up with tissue forceps and excised with tissue shears at an area close enough to the origin of the frenum to provide a desirable cosmetic effect. Sutures are placed inside the lip to approximate the free tissue margins. It is generally unnecessary to suture or pack the tissue between the incisors.



**Fig. 3.61** (A) Abnormal labial frenum observed in a preschool child is causing a diastema between the primary central incisors and is interfering with normal movement of the upper lip. (B) A wedge-shaped section of tissue, including the frenum, has been removed. (C) Two sutures have been placed to approximate the tissue margins. (D) The permanent incisors have erupted. No reattachment of the frenum fibers has occurred. (E) A desirable result of the frenectomy is evident 5 years after the surgical procedure.



## References

- United States Department of Health and Human Service: *Oral Health in America: a report of the surgeon general*, Rockville, MD, 2000, US Department of Health and Human Services, National Institute of Dental and Craniofacial Research, National Institutes of Health.
- Dye B, Thornton-Evans G, Li X, et al.: Dental caries and sealant prevalence in children and adolescents in the United States, 2011–2012, *NCHS Data Brief* (191)1–8, 2015.
- Britt JC, Josephson GD, Gross CW: Ludwig's angina in the pediatric population: report of a case and review of the literature, *Int J Pediatr Otorhinolaryngol* 52(1):79–87, 2000.
- Sethi DS, Stanley RE: Deep neck abscesses – changing trends, *J Laryngol Otol* 108(2):138–143, 1994.
- Moreland LW, Corey J, McKenzie R: Ludwig's Angina: report of a case and review of the literature, *Arch Intern Med* 148(2):461–466, 1988.
- Botha A, Jacobs F, Postma C: Retrospective analysis of etiology and comorbid diseases associated with Ludwig's angina, *Ann Maxillofac Surg* 5(2):168–173, 2015.
- An J, Madeo J, Singhal M: In *StatPearls [Internet]*, Treasure Island, FL, 2019, StatPearls Publishing. Available at: <https://www.ncbi.nlm.nih.gov/books/NBK482354/>.
- Bansal A, Miskoff J, Lis RJ: Otolaryngologic critical care, *Crit Care Clin* 19(1):55–72, 2003.
- Brook I: Microbiology and principles of antimicrobial therapy for head and neck infections, *Infect Dis Clin North Am* 21(2):355–391, 2007.
- Meyer K, Chaffee E, Hobby GL, Dawson MH: Hyaluronidases of bacterial and animal origin, *J Exp Med* 73(3):309–326, 1941.
- Hynes WL, Walton SL: Hyaluronidases of Gram-positive bacteria, *FEMS Microbiol Lett* 183(2):201–207, 2000.
- Molinari JA: Microbial disease trends and acquired antibiotic resistance: part 1, *Compend Contin Educ Dent* 18(2):106–108, 1997.
- Tasa GL, Lukas JR: The prevalence and expression of primary double teeth in Western India, *ASDC J Dent Child* 68(3):196–200, 2001.
- Tomizawa M, Shimizu A, Hayashi S, et al.: Bilateral maxillary fused primary incisors accompanied by succedaneous supernumerary teeth: report of a case, *Int J Paediatr Dent* 12(3):223–227, 2002.
- Shanthraj SL, Mallikarjun SB, Kiran S, et al.: 'Triplication' defect in deciduous teeth: an unusual odontogenic anomaly, *BMJ Case Rep* 2015:bcr2014205185, 2015.
- Mohapatra A, Prabhakar AR, Raju OS: An unusual triplication of primary teeth—a rare case report, *Quintessence Int* 41(10):815–820, 2010.
- Prabhakar AR, Marwah N, Raju OS: Triple teeth: case report of an unusual fusion of three teeth, *J Dent Child* 71(3):206–208, 2004.
- Shilpa G, Nuvvula S: Triple tooth in primary dentition: a proposed classification, *Contemp Clin Dent* 4(2):263–267, 2013.
- Gunduz K, Sumer M, Sumer A, Gunhan O: Concrescence of a mandibular third molar and a supernumerary fourth molar: report of a rare case, *Br Dent J* 200(3):141, 2006.
- Manoj S, Sanoj N: Concrescence of a maxillary third molar and second molar: report of a rare case, *IOSR J Dent Med Sci* 16(5):103–105, 2017.
- Shrestha A, Marla V, Shrestha S, et al.: Developmental anomalies affecting the morphology of teeth—a review, *Rev Sul-Bras Odontol* 12(1):68–78, 2015.
- Sharma U: Palatal ulceration: a local anesthetic complication, *Contemp Clin Dent* 4(1):94–96, 2013.
- Duncan WK, Helpin ML: Bilateral fusion and gemination: a literature analysis and case report, *Oral Surg Oral Med Oral Pathol* 64(1):82–87, 1987.
- Grover P, Lorton L: Gemination and twinning in the permanent dentition, *Oral Surg Oral Med Oral Pathol* 59(3):313–318, 1985.
- Aguilo L, Gandia J, Cibrian R, et al.: Primary double teeth. A retrospective clinical study of their morphological characteristics and associated anomalies, *Int J Paediatr Dent* 9(3):175–183, 1999.
- Rao P, Veena K, Chatra L, et al.: Twin tooth on either side: a case report of bilateral gemination, *Ann Med Health Sci Res* 3(2):271–273, 2013.
- Shokri A, Baharvand M, Mortazavi H: The largest bilateral gemination of permanent maxillary central incisors: report of a case, *J Clin Exp Dent* 5(5):e295–e297, 2013.
- Türktaş S, Gökçe HS, Dalkız M: Esthetic rehabilitation of bilateral geminated teeth: a case report, *Eur J Dent* 1(3):188, 2007.
- Tarım Ertaş E, Yırcalı Atıcı M, Arslan H, et al.: Endodontic treatment and esthetic management of a geminated central incisor bearing a talon cusp, *Case Rep Dent* 2014:123681, 2014.
- Gupta S, Tandon A, Chandra A, et al.: Syndontia with talon cusp, *J Oral Maxillofac Path* 16(2):266, 2012.
- Alani A, Bishop K: Dens invaginatus. Part 1: classification, prevalence and aetiology, *Int Endod J* 41(12):1123–1136, 2008.
- Colak H, Tan E, Aylıkçı BU, et al.: Radiographic study of the prevalence of dens invaginatus in a sample set of Turkish dental patients, *J Clin Imaging Sci* 2:34, 2012.
- Thongudomporn U, Freer TJ: Prevalence of dental anomalies in orthodontic patients, *Aust Dent J* 43(6):395–398, 1998.
- Hamasha A, Alomari Q: Prevalence of dens invaginatus in Jordanian adults, *Int Endod J* 37(5):307–310, 2004.
- Mupparapu M, Singer S: A rare presentation of dens invaginatus in a mandibular lateral incisor occurring concurrently with bilateral maxillary dens invaginatus: case report and review of literature, *Aust Dent J* 49(2):90–93, 2004.
- Grahn H, Lindahl B, Omnell KA: Dens invaginatus. I. A clinical, roentgenological and genetical study of permanent upper lateral incisors, *Odont Rev* 10:115, 1959.
- Oncag A, Gunbay S, Parlar A: Williams syndrome, *J Clin Pediatr Dent* 19(4):301–304, 1995.
- Hertzberg J, Nakisbendi L, Needleman H, et al.: Williams syndrome—oral presentation of 45 cases, *Pediatr Dent* 16:262–267, 1994.
- Hibbert S: A previously unreported association between Nance-Horan syndrome and spontaneous dental abscesses, *Oral Surg Oral Med Oral Pathol Oral Radiol Endod* 99(2):207–211, 2005.
- Walia PS, Kamal M, Kumar A: Nance-Horan syndrome—review and a case report, *Indian J Dent Sci* 8(1):102–105, 2016.
- Ritzau M, Carlsen O, Kreiborg S, et al.: The Ekman-Westborg-Julin syndrome: report of a case, *Oral Surg Oral Med Oral Pathol Oral Radiol Endod* 84(3):293–296, 1997.
- Gowans IJJ, Cameron-Christie S, Slayton RL, et al.: Missense pathogenic variants in KIF4A affect dental morphogenesis resulting in X-linked taurodontism, microdontia and dens-invaginatous, *Front Genet* 10:800, 2019.
- Oehlers FAC: Dens invaginatus (dilated composite odontome): I. Variations of the invagination process and associated anterior crown forms, *Oral Surg Oral Med Oral Pathol* 10(11):1204–1218, 1957.
- Levitan ME, Himel VT: Dens evaginatus: literature review, pathophysiology, and comprehensive treatment regimen, *J Endod* 32(1):1–9, 2006.
- Merrill RG: Occlusal anomalous tubercles on premolars of Alaskan Eskimos and Indians, *Oral Surg Oral Med Oral Pathol* 17(4):484–496, 1964.
- Curzon ME, Curzon JA, Poyton HG: Evaginated odontomes in the Keewatin Eskimo, *Br Dent J* 129(7):324–328, 1970.
- Mallineni SK, Panampally GK, Chen Y, et al.: Mandibular talon cusps: a systematic review and data analysis, *J Clin Exp Dent* 6(4):e408–e413, 2014.
- Mupparapu M, Singer S, Goodchild J: Dens evaginatus and dens invaginatus in a maxillary lateral incisor: report of a rare occurrence and review of literature, *Aust Dent J* 49(4):201–203, 2004.
- Tulunoglu O, Cankala D, Ozdemir R: Talon's cusp: report of four unusual cases, *J Indian Soc Pedod Prev Dent* 25(1):52, 2007.
- Hartsfield Jr JK: Premature exfoliation of teeth in childhood and adolescence, *Adv Pediatr* 41:453–470, 1994.
- Armitage GC: Development of a classification system for periodontal diseases and conditions, *Ann Periodontol* 4(1):1–6, 1999.
- Papapanou PN, Sanz M, Buduneli N, et al.: Periodontitis: consensus report of workgroup 2 of the 2017 world workshop on the classification of periodontal and peri-implant diseases and conditions, *J Periodontol* 89(Suppl 1):S173–S182, 2018.
- Papapanou PN, Sanz M, Buduneli N, et al.: Periodontitis: consensus report of workgroup 2 of the 2017 world workshop on the classification of periodontal and peri-implant diseases and conditions, *J Clin Periodontol* 45(Suppl 20):S162–S170, 2018.
- Vieira AR, Albandar JM: Role of genetic factors in the pathogenesis of aggressive periodontitis, *Periodontol* 2000 65(1):92–106, 2014.
- e Silva M, Moreira PR, da Costa GC, et al.: Association of CD28 and CTLA-4 gene polymorphisms with aggressive periodontitis in Brazilians, *Oral Dis* 19(6):568–576, 2013.
- Zhu XL, Meng HX, Zhang L, et al.: Association analysis between the –2518MCP-1(A/G) polymorphism and generalized aggressive periodontitis in a Chinese population, *J Periodontol Res* 47(3):286–292, 2012.

57. Albandar JM: Aggressive and acute periodontal diseases, *Periodontol* 2000 65(1):7–12, 2014.
58. Hu CC, King DL, Thomas HF, et al.: A clinical and research protocol for characterizing patients with hypophosphatasia, *Pediatr Dent* 18(1):17–23, 1996.
59. Herasse M, Spentchian M, Taillandier A, et al.: Molecular study of three cases of odontohypophosphatasia resulting from heterozygosity for mutations in the tissue non-specific alkaline phosphatase gene, *J Med Genet* 40(8):605–609, 2003.
60. Lia-Baldini A, Muller F, Taillandier A, et al.: A molecular approach to dominance in hypophosphatasia, *Hum Genet* 109(1):99–108, 2001.
61. Scriver CR, Cameron D: Pseudohypophosphatasia, *N Engl J Med* 281(11):604–606, 1969.
62. Kalantar Motamedi MH: Treatment of cherubism with locally aggressive behavior presenting in adulthood: report of four cases and a proposed new grading system, *J Oral Maxillofac Surg* 56(11):1336–1342, 1998.
63. Parkin B, Law C: Axenfeld anomaly and retinal changes in Ramon syndrome: follow-up of two sibs, *Am J Med Genet* 104(2):131–134, 2001.
64. Ueki Y, Tiziani V, Santanna C, et al.: Mutations in the gene encoding c-Abl-binding protein SH3BP2 cause cherubism, *Nat Genet* 28(2):125–126, 2001.
65. Reichenberger EJ, Levine MA, Olsen BR, et al.: The role of SH3BP2 in the pathophysiology of cherubism, *Orphanet J Rare Dis* 7(1):S5, 2012.
66. Mukai T, Ishida S, Ishikawa R, et al.: SH3BP2 cherubism mutation potentiates TNF- $\alpha$ -induced osteoclastogenesis via NFATc1 and TNF- $\alpha$ -mediated inflammatory bone loss, *J Bone Miner Res* 29(12):2618–2635, 2014.
67. McDonald RE, Shafer WG: Disseminated juvenile fibrous dysplasia of the jaws, *AMA Am J Dis Child* 89(3):354–358, 1955.
68. Pierce AM, Sampson WJ, Wilson DF, et al.: Fifteen-year follow-up of a family with inherited craniofacial fibrous dysplasia, *J Oral Maxillofac Surg* 54(6):780–788, 1996.
69. von Wowern N: Cherubism: a 36-year long-term follow-up of 2 generations in different families and review of the literature, *Oral Surg Oral Med Oral Pathol Oral Radiol Endod* 90(6):765–772, 2000.
70. Marconi C, Brunamonti Binello P, Badiali G, et al.: A novel missense mutation in ANO5/TMEM16E is causative for gnathodiaphyseal dysplasia in a large Italian pedigree, *Eur J Hum Genet* 21:613, 2012.
71. Weinstein M, Bernstein S: Pink ladies: mercury poisoning in twin girls, *Can Med Assoc J* 168(2):201, 2003.
72. Horowitz Y, Greenberg D, Ling G, et al.: Acro-dynia: a case report of two siblings, *Arch Dis Child* 86(6):453, 2002.
73. White KE, Carn G, Lorenz-Depiereux B, et al.: Autosomal-dominant hypophosphatemic rickets (ADHR) mutations stabilize FGF-23, *Kidney Int* 60(6):2079–2086, 2001.
74. Francis F, Hennig S, Korn B, et al.: A gene (PEX) with homologies to endopeptidases is mutated in patients with X-linked hypophosphatemic rickets, *Nat Genet* 11(2):130–136, 1995, <https://doi.org/10.1038/ng1095-130>.
75. McWhorter AG, Seale NS: Prevalence of dental abscess in a population of children with vitamin D-resistant rickets, *Pediatr Dent* 13(2):91–96, 1991.
76. Shroff DV, McWhorter AG, Seale NS: Evaluation of aggressive pulp therapy in a population of vitamin D-resistant rickets patients: a follow-up of 4 cases, *Pediatr Dent* 24(4):347–349, 2002.
77. Rakocz M, Keating III J, Johnson R: Management of the primary dentition in vitamin D-resistant rickets, *Oral Surg Oral Med Oral Pathol* 54(2):166–171, 1982.
78. Morley AA, Carew JP, Baikie AG: Familial cyclical neutropenia, *Br J Haematol* 13(5):719–738, 1967.
79. Horwitz M, Benson KF, Person RE, et al.: Mutations in ELA2, encoding neutrophil elastase, define a 21-day biological clock in cyclic haematopoiesis, *Nat Genet* 23(4):433–436, 1999.
80. da Fonseca MA, Fontes F: Early tooth loss due to cyclic neutropenia: long-term follow-up of one patient, *Spec Care Dentist* 20(5):187–190, 2000.
81. Seow WK, Masel JP, Weir C, et al.: Mineral deficiency in the pathogenesis of enamel hypoplasia in prematurely born, very low birth-weight children, *Pediatr Dent* 11(4):297–302, 1989.
82. Slayton RL, Warren JJ, Kanellis MJ, et al.: Prevalence of enamel hypoplasia and isolated opacities in the primary dentition, *Pediatr Dent* 23(1):32–36, 2001.
83. Sarnat BG, Schour I: Enamel hypoplasia (Chronologic Enamel Aplasia) in relation to systemic disease: a chronologic, morphologic and etiologic classification, *J Am Dent Assoc* 29(1):67–75, 1942.
84. Sheldon M, Bibby BG, Bales MS: The relationship between microscopic enamel defects and infantile debilities, *J Dent Res* 24(2):109–116, 1945.
85. Purvis RJ, Barrie WJ, MacKay GS, et al.: Enamel hypoplasia of the teeth associated with neonatal tetany: a manifestation of maternal vitamin-D deficiency, *Lancet* 2(7833):811–814, 1973.
86. Herman SC, McDonald RE: Enamel hypoplasia in cerebral palsied children, *J Dent Child* 30:46–3049, 1963.
87. Cohen HJ, Diner H: The significance of developmental dental enamel defects in neurological diagnosis, *Pediatrics* 46(5):737–747, 1970.
88. Martinez A, Cubillos P, Jiménez M, et al.: Prevalence of developmental enamel defects in mentally retarded children, *ASDC J Dent Child* 69(2):124, 151–155, 2002.
89. Oliver WJ, Owings CL, Brown WE, et al.: Hypoplastic enamel associated with the nephrotic syndrome, *Pediatrics* 32:399–406, 1963.
90. Koch MJ, Buhner R, Pioch T, et al.: Enamel hypoplasia of primary teeth in chronic renal failure, *Pediatr Nephrol* 13(1):68–72, 1999.
91. Rattner LJ, Myers HM: Occurrence of enamel hypoplasia in children with congenital allergies, *J Dent Res* 41:646–649, 1962.
92. Lawson BF, Stout FW, Ahern DE, et al.: The incidence of enamel hypoplasia associated with chronic pediatric lead poisoning, *S C Dent J* 29(11):5–10, 1971.
93. Pearl M, Roland NM: Delayed primary dentition in a case of congenital lead poisoning, *ASDC J Dent Child* 47(4):269–271, 1980.
94. Gemmel A, Tavares M, Alperin S, et al.: Blood lead level and dental caries in school-age children, *Environ Health Perspect* 110(10):A625–A630, 2002.
95. Turner JG: Two cases of hypoplasia of enamel, *Proc R Soc Med* 5(Odontol Sect):73–76, 1912.
96. Bauer WH: Effect of periapical processes of deciduous teeth on the buds of permanent teeth: pathological-clinical study, *Am J Orthod Oral Surg* 32:232–241, 1946.
97. Mink JR: *Relationship of enamel hypoplasia and trauma in repaired cleft lip and palate*. Masters of Science in Dentistry thesis, Indiana University-Purdue University Indianapolis (IUPUI), Indianapolis, 1961.
98. Vichi M, Franchi L: Abnormalities of the maxillary incisors in children with cleft lip and palate, *ASDC J Dent Child* 62(6):412–417, 1995.
99. Kaste SC, Hopkins KP, Jones D, et al.: Dental abnormalities in children treated for acute lymphoblastic leukemia, *Leukemia* 11(6):792–796, 1997.
100. Maguire A, Welbury RR: Long-term effects of antineoplastic chemotherapy and radiotherapy on dental development, *Dent Update* 23(5):188–194, 1996.
101. Musselman RJ: *Dental defects and rubella embryopathy: a clinical study of fifty children*. Masters of Science in Dentistry thesis, Indiana University-Purdue University Indianapolis (IUPUI), Indianapolis, 1968.
102. Willmott NS, Bryan RA, Duggal MS: Molar-incisor-hypomineralisation: a literature review, *Eur Arch Paediatr Dent* 9(4):172–179, 2008.
103. Levy SM, Hills SL, Warren JJ, et al.: Primary tooth fluorosis and fluoride intake during the first year of life, *Community Dent Oral Epidemiol* 30(4):286–295, 2002.
104. Everett ET, McHenry MA, Reynolds N, et al.: Dental fluorosis: variability among different inbred mouse strains, *J Dent Res* 81(11):794–798, 2002.
105. McCloskey RJ: A technique for removal of fluorosis stains, *J Am Dent Assoc* 109(1):63–64, 1984.
106. Croll TP: Enamel microabrasion: observations after 10 years, *J Am Dent Assoc* 128:45S–50S, 1997.
107. Croll TP, Helpin ML: Enamel microabrasion: a new approach, *J Esthet Dent* 12(2):64–71, 2000.
108. Muhler JC: The effect of apical inflammation of the primary teeth on dental caries in the permanent teeth, *J Dent Child* 24:209–210, 1957.
109. Mueller BH, Lichty GC, II, Tallerico ME, et al.: “Caries-like” resorption of unerupted permanent teeth, *J Pedod* 4(2):166–172, 1980.
110. Holan G, Eidelman E, Mass E: Pre-eruptive coronal resorption of permanent teeth: report of three cases and their treatments, *Pediatr Dent* 16(5):373–377, 1994.
111. Seow WK, Lu PC, McAllan LH: Prevalence of pre-eruptive intra-coronal dentin defects from panoramic radiographs, *Pediatr Dent* 21(6):332–339, 1999.



112. Seow WK, Wan A, McAllan LH: The prevalence of pre-eruptive dentin radiolucencies in the permanent dentition, *Pediatr Dent* 21(1):26–33, 1999.
113. Lysell L: Taurodontism: a case report and a survey of the literature, *Odontol Rev* 13(2):158–174, 1962.
114. Baron C, Houchmand-Cuny M, Enkel B, et al.: Prevalence of dental anomalies in French orthodontic patients: a retrospective study, *Arch Pediatr* 25(7):426–430, 2018.
115. Jaspers MT, Witkop Jr CJ: Taurodontism, an isolated trait associated with syndromes and X-chromosomal aneuploidy, *Am J Hum Genet* 32(3):396–413, 1980.
116. Mena CA: Taurodontism, *Oral Surg Oral Med Oral Pathol* 32(5):812–823, 1971.
117. Gedik R, Cimen M: Multiple taurodontism: report of case, *ASDC J Dent Child* 67(3):216–217, 2000.
118. Bixler D, Conneally PM, Christen AG: Dentinogenesis imperfecta: genetic variations in a six-generation family, *J Dent Res* 48(6):1196–1199, 1969.
119. Witkop Jr CJ: *Genetics and dental health*, McGraw-Hill, New York City, 1961.
120. Witkop Jr CJ: Manifestations of genetic diseases in the human pulp, *Oral Surg Oral Med Oral Pathol* 32(2):278–316, 1971.
121. Shields ED, Bixler D, el-Kafrawy AM: A proposed classification for heritable human dentine defects with a description of a new entity, *Arch Oral Biol* 18(4):543–553, 1973.
122. Xiao S, Yu C, Chou X, et al.: Dentinogenesis imperfecta 1 with or without progressive hearing loss is associated with distinct mutations in DSPP, *Nat Genet* 27(2):201–204, 2001, <https://doi.org/10.1038/84848>.
123. Zhang X, Zhao J, Li C, et al.: DSPP mutation in dentinogenesis imperfecta Shields type II, *Nat Genet* 27(2):151–152, 2001, <https://doi.org/10.1038/84765>.
124. Sreenath T, Thyagarajan T, Hall B, et al.: Dentin sialophosphoprotein knockout mouse teeth display widened predentin zone and develop defective dentin mineralization similar to human dentinogenesis imperfecta type III, *J Biol Chem* 278(27):24874–24880, 2003, <https://doi.org/10.1074/jbc.M303908200>.
125. Malmgren B, Lindskog S, Elgadi A, et al.: Clinical, histopathologic, and genetic investigation in two large families with dentinogenesis imperfecta type II, *Hum Genet* 114(5):491–498, 2004.
126. Bloch-Zupan A, Jamet X, Etard C, et al.: Homozygosity mapping and candidate prioritization identify mutations, missed by whole-exome sequencing, in SMOC2, causing major dental developmental defects, *Am J Hum Genet* 89(6):773–781, 2011.
127. Dean JA, Hartsfield Jr JK, Wright JT, et al.: Dentin dysplasia, type II linkage to chromosome 4q, *J Craniofac Genet Dev Biol* 17(4):172–177, 1997.
128. Rajpar MH, Koch MJ, Davies RM, et al.: Mutation of the signal peptide region of the bicistronic gene DSPP affects translocation to the endoplasmic reticulum and results in defective dentine biomineralization, *Hum Mol Genet* 11(21):2559–2565, 2002.
129. McKnight DA, Suzanne Hart P, Hart TC, et al.: A comprehensive analysis of normal variation and disease-causing mutations in the human DSPP gene, *Hum Mutat* 29(12):1392–1404, 2008.
130. Beattie ML, Kim JW, Gong SG, et al.: Phenotypic variation in dentinogenesis imperfecta/dentin dysplasia linked to 4q21, *J Dent Res* 85(4):329–333, 2006.
131. Cartwright AR, Kula K, Wright TJ: Craniofacial features associated with amelogenesis imperfecta, *J Craniofac Genet Dev Biol* 19(3):148–156, 1999.
132. Ravassipour DB, Powell CM, Phillips CL, et al.: Variation in dental and skeletal open bite malocclusion in humans with amelogenesis imperfecta, *Arch Oral Biol* 50(7):611–623, 2005.
133. Aldred MJ, Crawford PJ: Amelogenesis imperfecta—towards a new classification, *Oral Dis* 1(1):2–5, 1995.
134. Hart PS, Hart TC, Simmer JP, et al.: A nomenclature for X-linked amelogenesis imperfecta, *Arch Oral Biol* 47(4):255–260, 2002.
135. Hart PS, Michalec MD, Seow WK, et al.: Identification of the enamelin (g.8344delG) mutation in a new kindred and presentation of a standardized ENAM nomenclature, *Arch Oral Biol* 48(8):589–596, 2003.
136. Stephanopoulos G, Garefalaki ME, Lyroutida K: Genes and related proteins involved in amelogenesis imperfecta, *J Dent Res* 84(12):1117–1126, 2005.
137. Aldred MJ, Crawford PJ, Roberts E, et al.: Genetic heterogeneity in X-linked amelogenesis imperfecta, *Genomics* 14(3):567–573, 1992.
138. Congleton J, Burkes Jr EJ: Amelogenesis imperfecta with taurodontism, *Oral Surg Oral Med Oral Pathol* 48(6):540–544, 1979.
139. Seow WK: Taurodontism of the mandibular first permanent molar distinguishes between the tricho-dento-osseous (TDO) syndrome and amelogenesis imperfecta, *Clin Genet* 43(5):240–246, 1993.
140. Price JA, Wright JT, Kula K, et al.: A common DLX3 gene mutation is responsible for tricho-dento-osseous syndrome in Virginia and North Carolina families, *J Med Genet* 35(10):825–828, 1998.
141. Price JA, Wright JT, Walker SJ, et al.: Tricho-dento-osseous syndrome and amelogenesis imperfecta with taurodontism are genetically distinct conditions, *Clin Genet* 56(1):35–40, 1999.
142. Dong J, Amor D, Aldred MJ, et al.: DLX3 mutation associated with autosomal dominant amelogenesis imperfecta with taurodontism, *Am J Med Genet A* 133A(2):138–141, 2005.
143. Hall RK, Phakey P, Palamara J, et al.: Amelogenesis imperfecta and nephrocalcinosis syndrome. Case studies of clinical features and ultrastructure of tooth enamel in two siblings, *Oral Surg Oral Med Oral Pathol Oral Radiol Endod* 79(5):583–592, 1995.
144. Martelli-Júnior H, dos Santos Neto PE, de Aquino SN, et al.: Amelogenesis imperfecta and nephrocalcinosis syndrome: a case report and review of the literature, *Nephron Physiol* 118(3):p62–65, 2011.
145. Vervaeet BA, Verhulst A, D'Haese PC, et al.: Nephrocalcinosis: new insights into mechanisms and consequences, *Nephrol Dial Transplant* 24(7):2030–2035, 2009, <https://doi.org/10.1093/ndt/gfp115>.
146. Patel RR, Hovijitra S, Kafrawy AH, et al. X-linked (recessive) hypomaturation amelogenesis imperfecta: a prosthodontic, genetic, and histopathologic report, *J Prosthet Dent*. 1999;1:66(3):398-402.
147. Chaudhry AP, Wittich HC, Stickel FR, et al.: Odontogenesis imperfecta. Report of a case, *Oral Surg Oral Med Oral Pathol* 14:1099–1103, 1961.
148. Schimmelpfennig CB, McDonald RE: Enamel and dentine aplasia: report of a case, *Oral Surg Oral Med Oral Pathol* 6(12):1444–1449, 1953.
149. Alvira-González J, Gay-Escoda C: Non-syndromic multiple supernumerary teeth: meta-analysis, *J Oral Pathol Med* 41(5):361–366, 2012.
150. Lubinsky M, Kantaputra PN: Syndromes with supernumerary teeth, *Am J Med Genet A* 170(10):2611–2616, 2016, <https://doi.org/10.1002/ajmg.a.37763>.
151. Fleming P, Xavier G, DiBiase A, et al.: Revisiting the supernumerary: the epidemiological and molecular basis of extra teeth, *Br Dent J* 208(1):25, 2010.
152. Bixler D, Higgins M, Hartsfield Jr J: The Nance-Horan syndrome: a rare X-linked ocular-dental trait with expression in heterozygous females, *Clin Genet* 26(1):30–35, 1984.
153. Ghoneima A, Sachdeva K, Hartsfield J, et al.: The use of cone beam computed tomography for the assessment of trichorhinophalangeal syndrome, type I—a case report, *J Orthod* 40(1):47–52, 2013.
154. Subasioglu A, Savas S, Kucukyilmaz E, et al.: Genetic background of supernumerary teeth, *Eur J Dent* 9(1):153–158, 2015.
155. Cammarata-Scalisi F, Avendaño A, Callea M: Main genetic entities associated with supernumerary teeth, *Arch Argent Pediatr* 116(6):437–444, 2018.
156. Hartsfield Jr JK: The benefits of obtaining the opinion of a clinical geneticist regarding orthodontic patients. In Krishnan V, Davidovitch Z, editors: *Integrated clinical orthodontics*, West Sussex, UK, 2012, John Wiley & Sons, Ltd., pp 109–131.
157. Ishikawa T, Yashima S, Hasan H, et al.: Osteoma of the lateral pterygoid plate of the sphenoid bone, *Int J Oral Maxillofac Surg* 15(6):786–789, 1986.
158. Lew D, DeWitt A, Hicks RJ, et al.: Osteomas of the condyle associated with Gardner's syndrome causing limited mandibular movement, *J Oral Maxillofac Surg* 57(8):1004–1009, 1999.
159. Katou F, Motegi K, Baba S: Mandibular lesions in patients with adenomatosis coli, *J Cranio Maxill Surg* 17(8):354–358, 1989.
160. Nandakumar G, Morgan JA, Silverberg D, et al.: Familial polyposis coli: clinical manifestations, evaluation, management and treatment, *Mt Sinai J Med* 71(6):384–391, 2004.
161. Gorlin RJ, Herman NG, Moss SJ: Complete absence of the permanent dentition: an autosomal recessive disorder, *Am J Med Genet* 5(2):207–209, 1980.



162. Salinas CF, Jorgenson RJ, Wright JT, et al.: 2008 International conference on ectodermal dysplasias classification: conference report, *Am J Med Genet A* 149A(9):1958–1969, 2009.
163. Adaimy L, Chouery E, Megarbane H, et al.: Mutation in WNT10A is associated with an autosomal recessive ectodermal dysplasia: the odonto-onycho-dermal dysplasia, *Am J Hum Genet* 81(4):821–828, 2007.
164. Bohring A, Stamm T, Spaich C, et al.: WNT10A mutations are a frequent cause of a broad spectrum of ectodermal dysplasias with sex-biased manifestation pattern in heterozygotes, *Am J Hum Genet* 85(1):97–105, 2009.
165. van den Boogaard MJ, Créton M, Bronkhorst Y, et al.: Mutations in WNT10A are present in more than half of isolated hypodontia cases, *J Med Genet* 49(5):327–331, 2012.
166. Swallow J: Complete anodontia of the permanent dentition, *Br Dent J* 107:143–145, 1959.
167. Schneider PE: Complete anodontia of the permanent dentition: case report, *Pediatr Dent* 12(2):112–114, 1990.
168. Laird GS: Congenital anodontia, *J Am Dent Assoc* 51(6):722, 1955.
169. Witkop Jr CJ: Agenesis of succedaneous teeth: an expression of the homozygous state of the gene for the pegged or missing maxillary lateral incisor trait, *Am J Med Genet* 26(2):431–436, 1987.
170. Hoo JJ: Anodontia of permanent teeth (OMIM # 206780) and pegged/missing maxillary lateral incisors (OMIM # 150400) in the same family, *Am J Med Genet* 90(4):326–327, 2000.
171. Glenn FB: A consecutive six-year study of the prevalence of congenitally missing teeth in private pedodontic practice of two geographically separated areas, *J Dent Child* 31:264–270, 1964.
172. Grahnén H: Hypodontia in the permanent dentition, *Dent Abstr* 3:308–309, 1957.
173. Williams MA, Letra A: The changing landscape in the genetic etiology of human tooth agenesis, *Genes* 9(5):255, 2018.
174. Cobourne MT: Familial human hypodontia—is it all in the genes? *Br Dent J* 203(4):203–208, 2007.
175. Noor A, Windpassinger C, Vitcu I, et al.: Oligodontia is caused by mutation in LTBP3, the gene encoding latent TGF-beta binding protein 3, *Am J Hum Genet* 84(4):519–523, 2009.
176. Hamada Y, Timotheus CJC, Shin D, et al.: Canine impaction—a review of the prevalence, etiology, diagnosis and treatment, *Semin Orthod* 25(2):117–123, 2019.
177. Takahama Y, Aiyama Y: Maxillary canine impaction as a possible microform of cleft lip and palate, *Eur J Orthod* 4(4):275–277, 1982.
178. Sacerdoti R, Baccetti T: Dentoskeletal features associated with unilateral or bilateral palatal displacement of maxillary canines, *Angle Orthod* 74(6):725–732, 2004.
179. Becker A, Smith P, Behar R: The incidence of anomalous maxillary lateral incisors in relation to palatally-displaced cuspids, *Angle Orthod* 51(1):24–29, 1981.
180. Johnston WD: Treatment of palatally impacted canine teeth, *Am J Orthod* 56(6):589–596, 1969.
181. Becker A, Sharabi S, Chaushu S: Maxillary tooth size variation in dentitions with palatal canine displacement, *Eur J Orthod* 24(3):313–318, 2002.
182. Becker A, Gillis I, Shpack N: The etiology of palatal displacement of maxillary canines, *Clin Orthod Res* 2(2):62–66, 1999.
183. Chaushu S, Sharabi S, Becker A: Tooth size in dentitions with buccal canine ectopia, *Eur J Orthod* 25(5):485–491, 2003.
184. Becker A: In defense of the guidance theory of palatal canine displacement, *Angle Orthod* 65(2):95–98, 1995.
185. Paschos E, Huth KC, Fassler H, et al.: Investigation of maxillary tooth sizes in patients with palatal canine displacement, *J Orofac Orthop* 66(4):288–298, 2005.
186. Peck S, Peck L, Kataja M: The palatally displaced canine as a dental anomaly of genetic origin, *Angle Orthod* 64(4):249–256, 1994.
187. Rutledge MS, Hartsfield Jr JK. In *Seminars in orthodontics*. 16(3): 165–171 (Elsevier), September 2010.
188. Tamura M, Nemoto E: Role of the Wnt signaling molecules in the tooth, *Jpn Dent Sci Rev* 52(4):75–83, 2016.
189. Xiong Y, Fang Y, Qian Y, et al.: Wnt production in dental epithelium is crucial for tooth differentiation, *J Dent Res* 98(5):580–588, 2019.
190. Järvinen E, Shimomura-Kuroki J, Balic A, et al.: Mesenchymal Wnt/ $\beta$ -catenin signaling limits tooth number, *Development* 145(4):dev158048, 2018.
191. Lammi L, Arte S, Somer M, et al.: Mutations in AXIN2 cause familial tooth agenesis and predispose to colorectal cancer, *Am J Hum Genet* 74(5):1043–1050, 2004.
192. Marvin ML, Mazzoni SM, Herron CM, et al.: AXIN2-associated autosomal dominant ectodermal dysplasia and neoplastic syndrome, *Am J Med Genet A* 155A(4):898–902, 2011.
193. Mazzoni SM, Fearon ER: AXIN1 and AXIN2 variants in gastrointestinal cancers, *Cancer Lett* 355(1):1–8, 2014.
194. Chalothorn LA, Beeman CS, Ebersole JL, et al.: Hypodontia as a risk marker for epithelial ovarian cancer: a case-controlled study, *J Am Dent Assoc* 139(2):163–169, 2008.
195. Fekonja A, Cretnik A, Takac I: Hypodontia prevalence and pattern in women with epithelial ovarian cancer, *Angle Orthod* 84(5):810–814, 2014.
196. Kuchler EC, Lips A, Tannure PN, et al.: Tooth agenesis association with self-reported family history of cancer, *J Dent Res* 92(2):149–155, 2013.
197. Casal ML, Lewis JR, Mauldin EA, et al.: Significant correction of disease after postnatal administration of recombinant ectodysplasin A in canine X-linked ectodermal dysplasia, *Am J Hum Genet* 81(5):1050–1056, 2007.
198. Schneider H, Faschingbauer F, Schuepbach-Mallepell S, et al.: Prenatal correction of X-linked hypohidrotic ectodermal dysplasia, *N Engl J Med* 378(17):1604–1610, 2018.
199. Giansanti JS, Long SM, Rankin JL: The “tooth and nail” type of autosomal dominant ectodermal dysplasia, *Oral Surg Oral Med Oral Pathol* 37(4):576–582, 1974.
200. Jumlongras D, Bei M, Stimson JM, et al.: A nonsense mutation in MSX1 causes Witkop syndrome, *Am J Hum Genet* 69(1):67–74, 2001.
201. Hudson CD, Witkop CJ: Autosomal dominant hypodontia with nail dysgenesis. Report of twenty-nine cases in six families, *Oral Surg Oral Med Oral Pathol* 39(3):409–423, 1975.
202. Nunn JH, Carter NE, Gillgrass TJ, et al.: The interdisciplinary management of hypodontia: background and role of paediatric dentistry, *Br Dent J* 194(5):245–251, 2003.
203. Carter NE, Gillgrass TJ, Hobson RS, et al.: The interdisciplinary management of hypodontia: orthodontics, *Br Dent J* 194(7):361–366, 2003.
204. Hobson RS, Carter NE, Gillgrass TJ, et al.: The interdisciplinary management of hypodontia: the relationship between an interdisciplinary team and the general dental practitioner, *Br Dent J* 194(9):479–482, 2003.
205. Jepson NJ, Nohl FS, Carter NE, et al.: The interdisciplinary management of hypodontia: restorative dentistry, *Br Dent J* 194(6):299–304, 2003.
206. Meechan JG, Carter NE, Gillgrass TJ, et al.: Interdisciplinary management of hypodontia: oral surgery, *Br Dent J* 194(8):423–427, 2003.
207. Neville BW, Damm Carl Allen DD, Bouquot J, et al.: In Neville BW, Damm DD, Allen CM, Bouquot JE, editors: *Oral and maxillofacial pathology*, ed 2, Philadelphia, 2002, WB Saunders.
208. Stoll BJ, Kliegman RM: Hemolytic disease of the newborn (erythroblastosis fetalis). In Behrman RE, Kliegman RM, Jenson HB, editors: *Nelson textbook of pediatrics*, Philadelphia, 2004, WB Saunders.
209. Cullen CL: Erythroblastosis fetalis produced by Kell immunization: dental findings, *Pediatr Dent* 12(6):393–396, 1990.
210. Sassa S: The porphyrias. In Behrman RE, Kliegman RM, Jenson HB, editors: *Nelson textbook of pediatrics*, Philadelphia, 2004, WB Saunders.
211. Zegarelli EV, Kutscher AH, Denning CR, et al.: Discoloration of the teeth in a 24-year-old patient with cystic fibrosis of the pancreas not primarily associated with tetracycline therapy. Report of a case, *Oral Surg Oral Med Oral Pathol* 24(1):62–64, 1967.
212. Wright JT, Hall KI, Grubb BR: Enamel mineral composition of normal and cystic fibrosis transgenic mice, *Adv Dent Res* 10(2):270–274, 1996; discussion 275.
213. Arquitt CK, Boyd C, Wright JT: Cystic fibrosis transmembrane regulator gene (CFTR) is associated with abnormal enamel formation, *J Dent Res* 81(7):492–496, 2002.
214. Primosch RE: Tetracycline discoloration, enamel defects, and dental caries in patients with cystic fibrosis, *Oral Surg Oral Med Oral Pathol* 50(4):301–308, 1980.
215. van der Bijl P, Pitigoi-Aron G: Tetracyclines and calcified tissues, *Ann Dent* 54(1-2):69–72, 1995.
216. Moffitt JM, Cooley RO, Olsen NH, et al.: Prediction of tetracycline-induced tooth discoloration, *J Am Dent Assoc* 88(3):547–552, 1974.
217. Tredwin CJ, Scully C, Bagan-Sebastian JV: Drug-induced disorders of teeth, *J Dent Res* 84(7):596–602, 2005.

218. Brantley DH, Barnes KP, Haywood VB: Bleaching primary teeth with 10% carbamide peroxide, *Pediatr Dent* 23(6):514–516, 2001.
219. Burrell KH: ADA supports vital tooth bleaching—but look for the seal, *J Am Dent Assoc* 128:3S–5S, 1997.
220. Christensen GJ: Bleaching teeth: practitioner trends, *J Am Dent Assoc* 128:16S–18S, 1997.
221. Croll TP: Enamel microabrasion: observations after 10 years, *J Am Dent Assoc* 128:45S–50S, 1997.
222. Floyd RA: The effect of peroxides and free radicals on body tissues, *J Am Dent Assoc* 128:37S–40S, 1997.
223. Friedman S: Internal bleaching: long-term outcomes and complications, *J Am Dent Assoc* 128:51S–55S, 1997.
224. Garber DA: Dentist-monitored bleaching: a discussion of combination and laser bleaching, *J Am Dent Assoc* 128:26S–30S, 1997.
225. Goldstein RE: In-office bleaching: where we came from, where we are today, *J Am Dent Assoc* 128:11S–15S, 1997.
226. Haywood VB: Nightguard vital bleaching: current concepts and research, *J Am Dent Assoc* 128:19S–25S, 1997.
227. Heymann HO: Introduction: nonrestorative treatment of discolored teeth: reports from an international symposium, *J Am Dent Assoc* 128:i–ii, 1997.
228. Li Y: Toxicological considerations of tooth bleaching using peroxide-containing agents, *J Am Dent Assoc* 128:31S–36S, 1997.
229. Nathanson DAN: Vital tooth bleaching: sensitivity and pulpal considerations, *J Am Dent Assoc* 128:41S–44S, 1997.
230. Nathoo SA: The chemistry and mechanisms of extrinsic and intrinsic discoloration, *J Am Dent Assoc* 128:6S–10S, 1997.
231. Swift EJJ: Restorative considerations with vitae tooth bleaching, *J Am Dent Assoc* 128:60S–64S, 1997.
232. Trope M: Cervical root resorption, *J Am Dent Assoc* 128:56S–59S, 1997.
233. Tan, TY, Kilpatrick, N, Farlie, PG. Developmental and genetic perspectives on Pierre Robin sequence. *Am J Med Genet Part C Semin Med Genet* 163C:295–305, 2013.
234. Evans AK, Rahbar R, Rogers GF, et al.: Robin sequence: a retrospective review of 115 patients, *Int J Pediatr Otorhinolaryngol* 70(6):973–980, 2006.
235. Gorlin RJ, Cohen MM, Hennekam RCM: *Syndromes of the head and neck*, ed 4, Oxford University Press, Oxford, England, 2001, p 1344.
236. Pruzansky S, Richmond JB: Growth of mandible in infants with micrognathia; clinical implications, *AMA Am J Dis Child* 88(1):29–42, 1954.
237. Daskalogiannakis J, Ross RB, Tompson BD: The mandibular catch-up growth controversy in Pierre Robin sequence, *Am J Orthod Dentofacial Orthop* 120(3):280–285, 2001.
238. Rogers G, Lim AA, Mulliken JB, et al.: Effect of a syndromic diagnosis on mandibular size and sagittal position in Robin sequence, *J Oral Maxillofac Surg* 67(11):2323–2331, 2009.
239. Hotz M, Gnoinski W: Clefts of the secondary palate associated with the “Pierre Robin syndrome.” Management by early maxillary orthopaedics, *Swed Dent J* 15:89–98, 1982.
240. Dean JA: Prevention of airway obstruction in Pierre Robin sequence via obturator use, *Pediatr Dent* 24:173–174, 2002.
241. Reynoso MC, Hernández A, Lizcano-Gil LA, et al.: Autosomal dominant congenital macroglossia: further delineation of the syndrome, *Genet Couns* 5(2):151–154, 1994.
242. Guimaraes CV, Donnelly LF, Shott SR, et al.: Relative rather than absolute macroglossia in patients with Down syndrome: implications for treatment of obstructive sleep apnea, *Pediatr Radiol* 38(10):1062, 2008.
243. Chin CJ, Khami MM, Husein M: A general review of the otolaryngologic manifestations of Down Syndrome, *Int J Pediatr Otorhinolaryngol* 78(6):899–904, 2014.
244. Klockars T, Pitkäranta A: Inheritance of ankyloglossia (tongue-tie), *Clin Genet* 75(1):98–99, 2009.
245. Braybrook C, Doudney K, Marçano AC, et al.: The T-box transcription factor gene TBX22 is mutated in X-linked cleft palate and ankyloglossia, *Nat Genet* 29(2):179–183, 2001, <https://doi.org/10.1038/ng730>.
246. Ayers FJ, Hilton LM: Treatment of ankyloglossia: report of case, *ASDC J Dent Child* 44(3):237–239, 1977.
247. Messner AH, Lalakea ML: The effect of ankyloglossia on speech in children, *Otolaryngol Head Neck Surg* 127(6):539–545, 2002.
248. Kullaa-Mikkonen A: Familial study of fissured tongue, *Scand J Dent Res* 96(4):366–375, 1988.
249. Bánóczy J, Szabó L, Csiba A: Migratory glossitis. A clinical-histologic review of seventy cases, *Oral Surg Oral Med Oral Pathol* 39(1):113–121, 1975.
250. Cooke BE: Median rhomboid glossitis. Candidiasis and not a developmental anomaly, *Br J Dermatol* 93(4):399–405, 1975, <https://doi.org/10.1111/j.1365-2133.1975.tb06513.x>.
251. Barasch A, Safford MM, Catalanotto FA, et al.: Oral soft tissue manifestations in HIV-positive vs. HIV-negative children from an inner city population: a two-year observational study, *Pediatr Dent* 22(3):215–220, 2000.
252. Martinello RA, Cooney EL: Cerebellar brain abscess associated with tongue piercing, *Clin Infect Dis* 36(2):e32–e34, 2003, <https://doi.org/10.1086/345755>.
253. Dyce O, Bruno JR, Hong D, et al.: Tongue piercing. The new “rusty nail”? *Head & Neck* 22(7):728–732, 2000.
254. Akhondi H, Rahimi AR: Haemophilus aphrophilus endocarditis after tongue piercing, *Emerg Infect Dis* 8(8):850–851, 2002.
255. Perkins CS, Meisner J, Harrison JM: A complication of tongue piercing, *Br Dent J* 182(4):147–148, 1997.
256. Keogh IJ, O’Leary G: Serious complication of tongue piercing, *J Laryngol Otol* 115(3):233–234, 2001.

## 4

# Development and Morphology of the Primary Teeth

ERWIN G. TURNER and JEFFREY A. DEAN

## CHAPTER OUTLINE

### Life Cycle of the Tooth

Initiation (bud Stage)

Proliferation (Cap Stage)

Histodifferentiation and Morphodifferentiation (Bell Stage)

Apposition

Calcification

### Early Development and Calcification of the Anterior Primary Teeth

### Early Development and Calcification of the Posterior Primary Teeth and the First Permanent Molar

### Morphology of Individual Primary Teeth

Maxillary Central Incisor

Maxillary Lateral Incisor

Maxillary Canine

Mandibular Central Incisor

Mandibular Lateral Incisor

Mandibular Canine

Maxillary First Molar

Maxillary Second Molar

Mandibular First Molar

Mandibular Second Molar

### Morphologic Differences Between Primary and Permanent Teeth

### Size and Morphology of the Primary Tooth Pulp Chamber and Canals

This chapter presents a brief review of the development of the teeth. An accurate chronology of primary tooth calcification is of clinical significance to the dentist. It is often necessary to explain to parents the time sequence of calcification in utero and during infancy. The common observations of tetracycline pigmentation, developmental enamel defects, and generalized hereditary anomalies can be explained if the calcification schedule is known. A brief discussion of the morphology of the primary teeth is also appropriate before restorative procedures are considered for children.

A complete review is available in the reference texts on oral histology, dental anatomy, and developmental anatomy listed at the end of the chapter. Furthermore, contemporary scientists are rapidly gaining knowledge of tooth development at the molecular level. We suggest that readers with a special interest in the molecular events of tooth development study the listed references by Smith<sup>1</sup> and by Miletich and Sharpe.<sup>2</sup>

## Life Cycle of the Tooth

### INITIATION (BUD STAGE)

Evidence of development of the human tooth can be observed as early as the sixth week of embryonic life. Cells in the basal layer of the oral epithelium proliferate at a more rapid rate than do the adjacent cells. The result is an epithelial thickening in the region of the future dental arch that extends along the entire free margin of the jaws. This thickening is called the *primordium* of the ectodermal portion of

the teeth and what results is called the *dental lamina*. Simultaneously, 10 round or ovoid swellings occur in each jaw in the position to be occupied by the primary teeth.

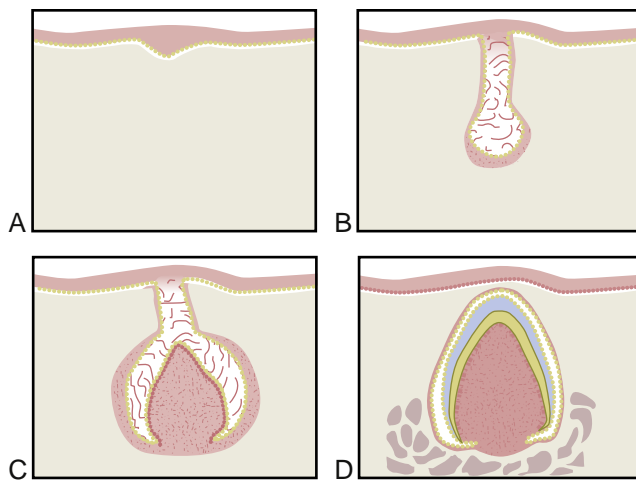
Certain cells of the basal layer begin to proliferate at a more rapid rate than do the adjacent cells (Fig. 4.1A). These proliferating cells contain the entire growth potential of the teeth. The permanent molars, like the primary teeth, arise from the dental lamina. The permanent incisors, canines, and premolars develop from the buds of their primary predecessors. The congenital absence of a tooth is the result of a lack of initiation or an arrest in the proliferation of cells. The presence of supernumerary teeth is the result of continued budding of the enamel organ.

### PROLIFERATION (CAP STAGE)

Proliferation of the cells continues during the cap stage. As a result of unequal growth in the different parts of the bud, a cap is formed (Fig. 4.1B). A shallow invagination appears on the deep surface of the bud. The peripheral cells of the cap later form the outer and inner enamel epithelium.

As with a deficiency in initiation, a deficiency in proliferation results in failure of the tooth germ to develop and in fewer than the normal numbers of teeth. Excessive proliferation of cells may result in epithelial rests. These rests may remain inactive or become activated due to an irritation or stimulus. If the cells become partially differentiated or detached from the enamel organ in their partially differentiated state, they assume the secretory functions common to all epithelial cells, and a cyst develops. If the cells become





**Fig. 4.1** Life cycle of the tooth. (A) Initiation (Bud stage). (B) Proliferation (Cap stage). (C) Histodifferentiation and morphodifferentiation (bell stage). (D) Apposition and calcification. (Adapted from Bath-Balogh M, Fehrenbach MJ: *Illustrated dental embryology, histology, and anatomy*, ed 2, Philadelphia, 2006, Saunders.)

more fully differentiated or detached from the enamel organ, they produce enamel and dentin, resulting in an odontoma or a supernumerary tooth. The degree of differentiation of the cells determines whether a cyst, an odontoma, or a supernumerary tooth develops (Fig. 23.53).

### HISTODIFFERENTIATION AND MORPHODIFFERENTIATION (BELL STAGE)

The epithelium continues to invaginate and deepen until the enamel organ takes on the shape of a bell (Fig. 4.1C). During this stage, the cells of the dental papilla differentiate into odontoblasts and cells of the inner enamel epithelium differentiate into ameloblasts.

Histodifferentiation marks the end of the proliferative stage as the cells lose their ability to multiply. This stage is the forerunner of appositional activity. Disturbances in the differentiation of the formative cells of the tooth germ result in abnormal structure of the dentin or enamel. One clinical example of the failure of ameloblasts to differentiate properly is amelogenesis imperfecta (Figs. 3.42 and 3.43). The failure of the odontoblasts to differentiate properly, with the resultant abnormal dentin structure, results in dentinogenesis imperfecta (Fig. 3.41).

In the morphodifferentiation stage, the formative cells are arranged to outline the form and size of the tooth. This process occurs before matrix deposition. The morphologic pattern of the tooth becomes established when the inner enamel epithelium is arranged so that the boundary between it and the odontoblasts outlines the future dentino-enamel junction. Disturbances and aberrations in morphodifferentiation lead to abnormal forms and sizes of teeth, resulting in conditions such as peg teeth, other types of microdontia, and macrodontia.

### APPOSITION

Appositional growth is the result of a layer-like deposition of a nonvital extracellular secretion in the form of a tissue matrix. This matrix is deposited by the formative cells, ameloblasts, and odontoblasts, which line up along the future

dentino-enamel and dentinocemental junction at the stage of morphodifferentiation. These cells deposit the enamel and dentin matrix in a definite pattern and at a definite rate. The formative cells begin their work at specific sites that are referred to as *growth centers* as soon as the blueprint, the dentino-enamel junction, is completed (Fig. 4.1D).

Any systemic disturbance or local trauma that injures the ameloblasts during enamel formation can cause an interruption or an arrest in matrix apposition, leading to enamel hypoplasia (Fig. 3.14). Hypoplasia of the dentin is less common than enamel hypoplasia and occurs only after severe systemic disturbances.

### CALCIFICATION

Calcification (mineralization) takes place following matrix deposition and involves the precipitation of inorganic calcium salts within the deposited matrix. The process begins with the precipitation of a small nidus, and further precipitation occurs around it. The original nidus increases in size by the addition of concentric laminations. There is an eventual approximation and fusion of these individual calcospherites into a homogeneously mineralized layer of tissue matrix. If the calcification process is disturbed, there is a lack of fusion of the calcospherites. These deficiencies are not readily identified in the enamel, but in the dentin they are evident microscopically and are referred to as interglobular dentin.

## Early Development and Calcification of the Anterior Primary Teeth

Kraus and Jordan<sup>3</sup> found that the first macroscopic indication of morphologic development occurs at approximately 11 weeks in utero. The maxillary and mandibular central incisor crowns appear identical at this early stage as tiny, hemispheric, mound-like structures.

The lateral incisors begin to develop morphologic characteristics between 13 and 14 weeks. There is evidence of the developing canines between 14 and 16 weeks. Calcification of the central incisor begins at approximately 14 weeks in utero, with the maxillary central incisor slightly preceding the mandibular central incisor. The initial calcification of the lateral incisor occurs at 16 weeks and that of the canine occurs at 17 weeks.

The developmental dates listed precede by 3 to 4 weeks the dates that appear in the chronology of the human dentition as developed by Logan and Kronfeld.<sup>4</sup> This observation has been confirmed by Lunt and Law.<sup>5</sup>

## Early Development and Calcification of the Posterior Primary Teeth and the First Permanent Molar

The maxillary first primary molar appears macroscopically at 12½ weeks in utero. Kraus and Jordan<sup>3</sup> observed that as early as 15½ weeks, the apex of the mesiobuccal cusp

may undergo calcification. At approximately 34 weeks, the entire occlusal surface is covered by calcified tissue. At birth, calcification includes roughly three-fourths of the occlusal gingival height of the crown.

The maxillary second primary molar also appears macroscopically at about 12½ weeks in utero. There is evidence of calcification of the mesiobuccal cusp as early as 19 weeks. At birth, calcification extends occlusogingivally to include approximately one-fourth of the height of the crown.

The mandibular first primary molar initially becomes evident macroscopically at about 12 weeks in utero. Calcification may be observed as early as 15½ weeks at the apex of the mesiobuccal cusp. At birth, a completely calcified cap covers the occlusal surface.

The mandibular second primary molar also becomes evident macroscopically at 12½ weeks in utero. According to Kraus and Jordan,<sup>3</sup> calcification may begin at 18 weeks. At birth, the five centers coalesce, and only a small area of uncalcified tissue remains in the middle of the occlusal surface. There are sharp conical cusps, angular ridges, and a smooth occlusal surface, all of which indicate that calcification of these areas is incomplete at birth. Thus there is a calcification sequence of central incisor, first molar, lateral incisor, canine, and second molar.

The work of Kraus and Jordan<sup>3</sup> indicates that the adjacent second primary and the first permanent molars undergo identical patterns of morphodifferentiation but at different times, and the initial development of the first permanent molar occurs slightly later. Their research has also shown that the first permanent molars are uncalcified before 28 weeks of age; calcification may begin at any time thereafter. Some degree of calcification is always present at birth. Using first permanent and second primary molars, Morita et al.<sup>6</sup> additionally reported that their patterns of cusp shape variability differ from each other and that temporal factors contribute to the patterns of size variability, whereas topographic factors contribute to the patterns of shape variability.

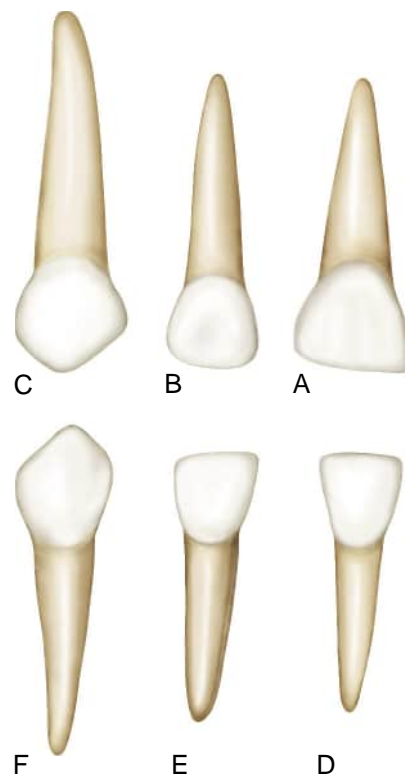
## Morphology of Individual Primary Teeth

### MAXILLARY CENTRAL INCISOR

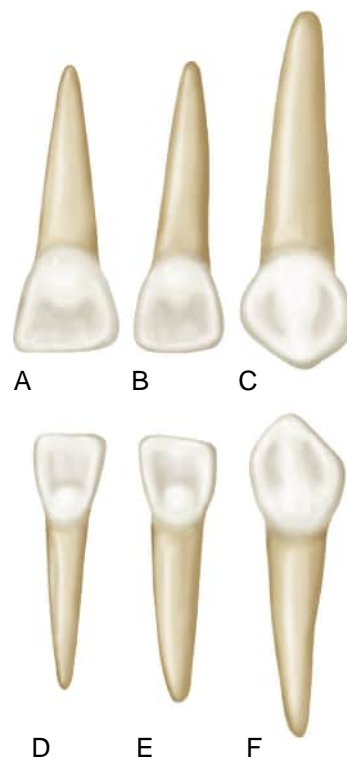
The mesiodistal width of the crown of the maxillary central incisor is greater than the cervico-incisal length. Developmental lines are usually not evident in the crown; thus the labial surface is smooth. The incisal edge is nearly straight even before abrasion becomes evident. There are well-developed marginal ridges on the lingual surface and a distinctly developed cingulum (Figs. 4.2 and 4.3). The root of the incisor is conical with tapered sides.

### MAXILLARY LATERAL INCISOR

The outline of the maxillary lateral incisor is similar to that of the central incisor, but the crown is smaller in all dimensions. The length of the crown from the cervical to the incisal edge is greater than the mesiodistal width. The root outline is similar to that of the central incisor but is longer in proportion to the crown.



**Fig. 4.2** Primary right anterior teeth, labial aspect. (A) Maxillary central incisor. (B) Maxillary lateral incisor. (C) Maxillary canine. (D) Mandibular central incisor. (E) Mandibular lateral incisor. (F) Mandibular canine. (From Nelson SJ: *Wheeler's dental anatomy, physiology, and occlusion*, ed 9, Philadelphia, 2010, WB Saunders.)



**Fig. 4.3** Primary right anterior teeth, lingual aspect. (A) Maxillary central incisor. (B) Maxillary lateral incisor. (C) Maxillary canine. (D) Mandibular central incisor. (E) Mandibular lateral incisor. (F) Mandibular canine. (From Nelson SJ: *Wheeler's dental anatomy, physiology, and occlusion*, ed 9, Philadelphia, 2010, WB Saunders.)

### MAXILLARY CANINE

The crown of the maxillary canine is more constricted at the cervical region than that of the incisors, and the incisal and distal surfaces are more convex. There is a well-developed sharp cusp rather than a relatively straight incisal edge. The canine has a long, slender, tapering root that is more than twice the length of the crown. The root is usually inclined distally, apical to the middle third.

### MANDIBULAR CENTRAL INCISOR

The mandibular central incisor is smaller than the maxillary central incisor, but its labiolingual measurement is usually only 1 mm less. The labial aspect presents a flat surface without developmental grooves. The lingual surface presents marginal ridges and a cingulum. The middle third and the incisal third on the lingual surface may have a flattened surface level with the marginal ridges, or there may be a slight concavity. The incisal edge is straight and bisects the crown labiolingually. The root is approximately twice the length of the crown.

### MANDIBULAR LATERAL INCISOR

The outline of the mandibular lateral incisor is similar to that of the central incisor, but somewhat larger in all dimensions except labiolingually. The lingual surface may have greater concavity between the marginal ridges. The incisal edge slopes toward the distal aspect of the tooth.

### MANDIBULAR CANINE

The form of the mandibular canine is similar to that of the maxillary canine, with a few exceptions. The crown is slightly shorter, and the root may be as much as 2 mm shorter than that of the maxillary canine. The mandibular canine is not as large labiolingually as its maxillary counterpart.

### MAXILLARY FIRST MOLAR

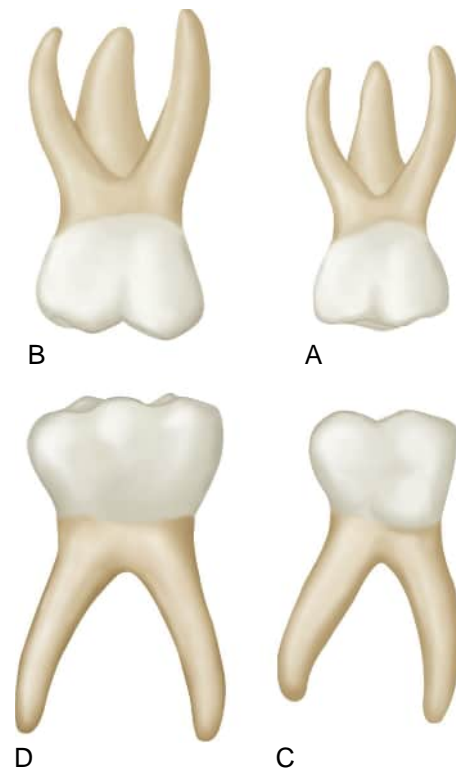
The greatest dimension of the crown of the maxillary first molar is at the mesiodistal contact areas, and from these areas the crown converges toward the cervical region (Figs. 4.4–4.6).

The mesiolingual cusp is the largest and sharpest. The distolingual cusp is poorly defined, small, and rounded. The buccal surface is smooth, with little evidence of developmental grooves. The three roots are long, slender, and widely spread.

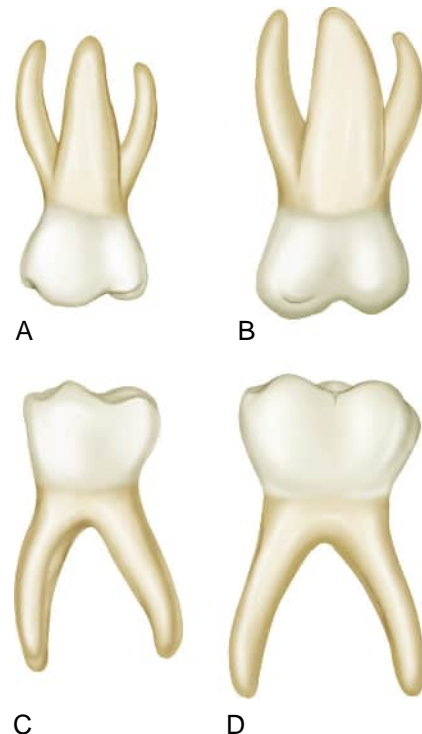
### MAXILLARY SECOND MOLAR

There is a considerable resemblance between the maxillary second primary molar and the maxillary first permanent molar. There are two well-defined buccal cusps, with a developmental groove between them. The crown of the second molar is considerably larger than that of the first molar.

The bifurcation between the buccal roots is close to the cervical region. The roots are longer and heavier than those of the first primary molar, and the lingual root is larger and thicker than the other roots (Figs. 4.4 and 4.5).

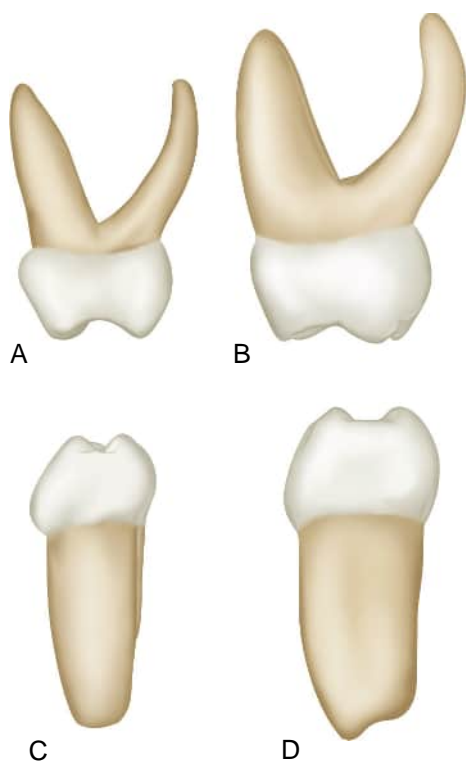


**Fig. 4.4** Primary right molars, buccal aspect. (A) Maxillary first molar. (B) Maxillary second molar. (C) Mandibular first molar. (D) Mandibular second molar. (From Nelson SJ: *Wheeler's dental anatomy, physiology, and occlusion*, ed 9, Philadelphia, 2010, WB Saunders.)



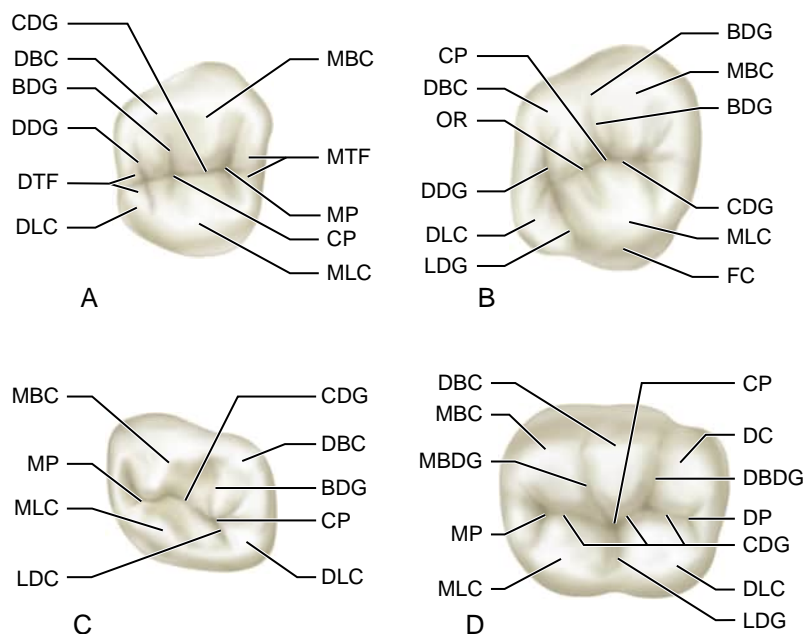
**Fig. 4.5** Primary right molars, lingual aspect. (A) Maxillary first molar. (B) Maxillary second molar. (C) Mandibular first molar. (D) Mandibular second molar. (From Nelson SJ: *Wheeler's dental anatomy, physiology, and occlusion*, ed 9, Philadelphia, 2010, WB Saunders.)





**Fig. 4.6** Primary right molars, mesial aspect. (A) Maxillary first molar. (B) Maxillary second molar. (C) Mandibular first molar. (D) Mandibular second molar. (From Nelson SJ: *Wheeler's dental anatomy, physiology, and occlusion*, ed 9, Philadelphia, 2010, WB Saunders.)

The lingual surface has three cusps: a mesiolingual cusp that is large and well developed; a distolingual cusp; and a third and smaller supplemental cusp (the cusp of Carabelli).



**Fig. 4.7** Primary right molars, occlusal aspect. (A) Maxillary first molar. (B) Maxillary second molar. (C) Mandibular first molar. (D) Mandibular second molar. *BDG*, Buccal developmental groove; *CDG*, central developmental groove; *CP*, central pit; *DBC*, distobuccal cusp; *DBDG*, distobuccal developmental groove; *DC*, distal cusp; *DDG*, distal developmental groove; *DLC*, distolingual cusp; *DP*, distal pit; *DTF*, distal triangular fossa; *FC*, fifth cusp; *LDG*, lingual developmental groove; *MBC*, mesiobuccal cusp; *MBDG*, mesiobuccal developmental groove; *MLC*, mesiolingual cusp; *MP*, mesial pit; *MTF*, mesial triangular fossa; *OR*, oblique ridge. (From Nelson SJ: *Wheeler's dental anatomy, physiology, and occlusion*, ed 9, Philadelphia, 2010, WB Saunders.)

A well-defined groove separates the mesiolingual cusp from the distolingual cusp. On the occlusal surface, a prominent oblique ridge connects the mesiolingual cusp with the distobuccal cusp (Fig. 4.7).

### MANDIBULAR FIRST MOLAR

Unlike the other primary teeth, the first primary molar does not resemble any of the permanent teeth. The mesial outline of the tooth, when viewed from the buccal aspect, is almost straight from the contact area to the cervical region. The distal area of the tooth is shorter than the mesial area.

The two distinct buccal cusps have no evidence of a distinct developmental groove between them; the mesial cusp is the larger of the two.

There is a pronounced lingual convergence of the crown on the mesial aspect, with a rhomboid outline present on the distal aspect. The mesiolingual cusp is long and sharp at the tip; a developmental groove separates this cusp from the distolingual cusp, which is rounded and well developed. The mesial marginal ridge is well developed, to the extent that it appears as another small cusp lingually. When the tooth is viewed from the mesial aspect, there is an extreme curvature buccally at the cervical third. The crown length is greater in the mesiobuccal area than in the mesiolingual area; thus the cervical line slants upward from the buccal to the lingual surface.

The longer slender roots spread considerably at the apical third, extending beyond the outline of the crown. The mesial root, when viewed from the mesial aspect, does not resemble any other primary root. The buccal and lingual outlines of the root drop straight down from the crown, being essentially parallel for more than half their length. The end of the root is flat and almost square.

## MANDIBULAR SECOND MOLAR

The mandibular second molar resembles the mandibular first permanent molar, except that the primary tooth is smaller in all its dimensions. The buccal surface is divided into three cusps that are separated by mesiobuccal and distobuccal developmental grooves. The cusps are almost equal in size. Two cusps of almost equal size are evident on the lingual surface and are divided by a short lingual groove.

The primary second molar, when viewed from the occlusal surface, appears rectangular with a slight distal convergence of the crown. The mesial marginal ridge is developed to a greater extent than the distal marginal ridge.

One difference between the crown of the primary molar and that of the first permanent molar is in the distobuccal cusp; the distal cusp of the permanent molar is smaller than the other two buccal cusps.

The roots of the primary second molar are long and slender, with a characteristic flare mesiodistally in the middle and apical thirds.

## Morphologic Differences Between Primary and Permanent Teeth

Cleghorn et al.<sup>7</sup> state that the morphology of the primary dentition is different in many respects from that of the permanent dentition, and not only in the sizes of the crowns

and roots. They have outlined these morphologic differences (Box 4.1).

## Size and Morphology of the Primary Tooth Pulp Chamber and Canals

Considerable individual variation exists in the sizes of the pulp chambers and pulp canals of the primary teeth. Immediately after tooth eruption, the pulp chambers are large and generally follow the outline of the crown. They decrease in size as age increases and under the influence of both function and abrasion of the occlusal and incisal surfaces of the teeth.

No attempt is made here to describe in detail each pulp chamber outline; rather, it is suggested that the dentist examine critically the bitewing radiographs of the child before undertaking operative procedures. Just as there are individual differences in the calcification and eruption times of teeth, so are there individual differences in the morphology of the crowns and the size of the pulp chamber. However, radiographs do not completely demonstrate the extent of the pulp horn into the cuspal area. An interesting article by Ahmed et al. (Ahmed, Musale, Alshahawy, & Dummer, 2019) presents a system for classifying the root and canal morphology of primary teeth since "...the bizarre and tortuous canals encased in roots programmed for physiological

### Box 4.1 Characteristics of teeth in the primary dentition

#### Crowns

The crowns in the primary dentition are shorter relative to the length of the root (i.e., smaller crown: root ratio).  
The occlusal tables of primary molars are constricted buccolingually and much narrower mesiodistally when compared with those of the permanent molars.  
Enamel and dentin of primary teeth are thinner than those of permanent teeth.  
The thickness of the enamel and dentin of primary teeth is approximately half that of permanent teeth.  
The enamel rod direction in the cervical area is angled occlusally compared with the apical direction in permanent teeth.  
Crowns of primary teeth are characterized by significant cervical constriction in both the mesiodistal and faciolingual dimensions.  
The primary molars have a pronounced buccal cervical bulge.  
The contact areas of primary molars are flat and very broad buccolingually compared with those of the permanent molars.  
The crown color of the primary teeth is whiter and a lighter shade.

#### Roots

The roots of the primary molars have a greater flare, which accommodates the developing crowns of the succedaneous

permanent premolars of the permanent dentition.

The mesiodistal width of the roots of primary anterior teeth is much narrower than the crown when compared with those of the permanent anterior teeth.

The primary molar roots are relatively longer and more slender, i.e., mandibular molar roots are narrower mesiodistally, maxillary mesiobuccal and distobuccal roots are narrower mesiodistally, and maxillary palatal roots are narrower buccolingually.

#### Pulp and Root Canal Systems

The size of the pulp relative to the crown is larger in the primary teeth.

Pulp horns are higher in proportion and are located closer to the dentino-enamel junction and to the outer surface of the crown.

Mesial pulp horns are higher than distal pulp horns.

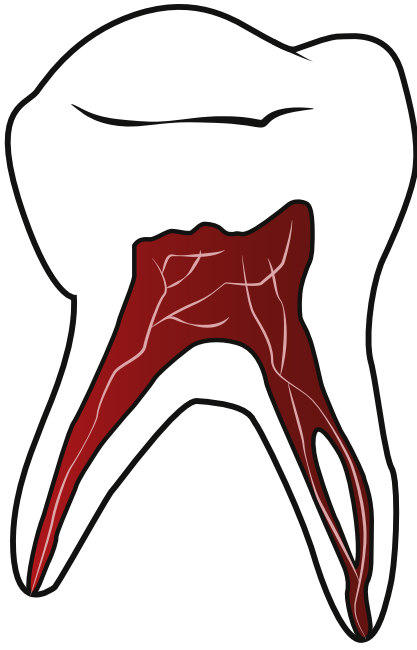
Pulp chambers are shaped comparably with the shape of the outline of the crown from an occlusal view.

Pulp horns are present under each cusp of the primary molars.

The pulp chambers of primary mandibular molar teeth are normally larger than the pulp chambers of primary maxillary molars.

The root canal system of fully developed primary molars is extremely tortuous and complex.

Used with permission from Cleghorn BM, Boorberg NB, Christie WH. Primary human teeth and their root canal systems, *Endodontic Topics* 23:6–33, 2010.  
Ahmed HM, Musale PK, El Shahawy OI, et al. Application of a new system for classifying tooth, root and canal morphology in the primary dentition. *Int Endod J*. 2019;1(53):27–35. Retrieved from <https://onlinelibrary.wiley.com/doi/pdf/10.1111/iej.13199>. <https://doi.org/10.1111/iej.13199>  
Makiguchi T, Imai H, Arakawa A, et al. Development of jaw and deciduous teeth in Japanese children -comparing size of crown and alveolar area between today and 40 years ago. *Bull Tokyo Dent Coll*. 2018;59(3):171–181. Retrieved from [https://www.jstage.jst.go.jp/article/tdcpublication/59/3/59\\_2017-0033/\\_pdf](https://www.jstage.jst.go.jp/article/tdcpublication/59/3/59_2017-0033/_pdf). <https://doi.org/10.2209/tdcpublication.2017-0033>



**Fig. 4.8** Canal configuration in a mandibular primary molar with notation as “ $^{2}74 M^{1-2-1}D^1$ ” connoting that this left mandibular first primary molar (FDI tooth #74) has two canals “ $^{2}74$ ”. The Mesial root starts from the pulp chamber with 1 canal that separates into 2 canals and then rejoins towards the apex into 1 canal,  $M^{1-2-1}$ , and the Distal root has 1 canal,  $D^1$ . (Adapted from: Ahmed, H. M. A., Musale, P., Alshahawy, O. I., & Dummer, P. M. H. (2019). Application of a new system for classifying tooth, root and canal morphology in the primary dentition. *Int Endod J*)

resorption are a unique challenge for dental practitioners.” This system provides detailed information on tooth notation, number of roots and canal configuration, as well as accessory canals and tooth anomalies (Fig. 4.8).

In addition, the cemento-enamel junction of primary teeth presents three interesting morphologic relationships, in which

the cementum is over enamel, the cementum and enamel are edge to edge, or there is a gap between the cementum and enamel with dentin exposure. This irregularity in the cemento-enamel junction may indicate the need for care during restorative and other procedures to avoid damage.<sup>8</sup> Finally, a brief note about trends in the size of primary teeth has been reported by Makiguchi et al. (Makiguchi et al., 2018). They studied the mesiodistal width of the primary teeth and size of the jaws in Japanese children born between 1968 and 1974 versus 2007 and 2009. While the widths had not changed statistically over the 40-year time frame, the tooth size-arch length discrepancy had decreased, especially in boys.

### References

1. Smith CE: Cellular and chemical events during enamel maturation. *Crit Rev Oral Biol Med* 9(2):128–161, 1998.
2. Miletich I, Sharpe PT: Normal and abnormal dental development. *Hum Mol Genet* 12:R69–R73, 2003.
3. Kraus BS, Jordan RE: *The human dentition before birth*. Philadelphia, Lea & Febiger, 1965.
4. Logan WH, Kronfeld R: Development of the human jaws and surrounding structures from birth to the age of fifteen years. *J Am Dent Assoc* 20(3):379–428, 1933.
5. Lunt RC, Law DB: A review of the chronology of calcification of deciduous teeth. *J Am Dent Assoc* 89(3):599–606, 1974.
6. Morita W, Yano W, Nagaoka T, et al.: Size and shape variability in human molars during odontogenesis. *J Dent Res* 93(3):275–280, 2014.
7. Cleghorn BM, Boorberg NB, Christie WH: Primary human teeth and their root canal systems. *Endodontic Topics* 23(1):6–33, 2012.
8. Francischone LA, Consolaro A: Morphology of the cemento-enamel junction of primary teeth. *J Dent Child* 75(3):252–259, 2008.

### Suggested Readings

- Chiego D: *Essentials of oral histology and embryology*, ed 5. St Louis, 2018, Elsevier.
- Nanci A: *Ten Cate's oral histology*, ed 9. St Louis, 2017, Elsevier.
- Nelson SJ: *Wheeler's dental anatomy, physiology, and occlusion*, ed 11. St Louis, 2020, Elsevier.
- Schour I, Massler M: Studies in tooth development: the growth pattern of human teeth. *J Am Dent Assoc* 27:1778–1793, 1940.



## 5

# Oral Pathology of the Child and Adolescent

JUAN F. YEPES and DAN STOECKEL

## CHAPTER OUTLINE

### Introduction

#### Epithelial Lesions

##### Fibroma

##### Localized Gingival Swellings

Pyogenic Granuloma

Peripheral Giant Cell Granuloma

Peripheral Ossifying Fibroma

##### Congenital Epulis

##### Localized Juvenile Spongiotic Gingival Hyperplasia

##### Gingival and Palatal Cysts of the Newborn

##### Mucocele

##### Vascular Malformations

##### Lymphangioma

##### Benign Neoplasms

Neurofibroma

Pleomorphic Adenoma

### Benign Lesions of Bone

Benign Non-Odontogenic Lesions of Bone

Benign Fibro-Osseous Lesions of the Jaws

Juvenile Ossifying Fibroma

Central Giant Cell Granuloma

Cherubism

Melanotic Neuroectodermal Tumor of Infancy

Odontogenic Cyst

Odontogenic Tumors

### Malignant Tumors

Fibroblastic Tumors and Fibrosarcoma in Infancy and Childhood

Rhabdomyosarcoma

Osteogenic Sarcoma

Ewing's Sarcoma

Langerhans Cell Histiocytosis (Histiocytosis X)

► For additional resources, please visit the website.

## Introduction

Oral pathology is an area of dentistry that is often overlooked. This is especially true in children. A thorough soft tissue examination, what we think of as an oral cancer screening in an adult, is often difficult to perform consistently in a busy pediatric dentistry practice, particularly when the child is uncooperative. Oral soft tissue lesions in children are most often benign. Malignant lesions, although rare, do occur in children. The dentist treating children is often the only health care provider examining the oral cavity. Therefore, it is important that the dentist performs an oral soft tissue examination regularly on each patient. The dentist must be familiar with common oral pathologic lesions and must be able to distinguish between what is likely a benign lesion and what is potentially malignant.

According to a review published in 2017, the most common soft tissue lesions in children that are biopsied include mucoceles, fibromas, and pyogenic granulomas. Mucosal diseases such as aphthous ulcers and trauma-related lesions are more common, but covered elsewhere in this text. Malignant lesions, although rare, are also noted in the review. The most common oral soft tissue malignancy in children is rhabdomyosarcoma. Manifestations of

hematopoietic disorders, such as leukemia, are also important considerations in children and are covered elsewhere in this text book.<sup>1</sup>

Distinguishing clinically between lesions that are likely benign and lesions that are potentially malignant is a very important skill for the general and pediatric dentist (see [Box 5.1](#)). Benign soft tissue lesions tend to be symmetrical and well circumscribed. The borders of a well-circumscribed lesion can be easily distinguished from the surrounding normal tissues. Benign lesions grow slowly over a period of several months to several years before they are brought to the attention of a health care provider. The surface of a benign lesion that develops from the deep soft tissues is smooth and non-ulcerated. The surface of a benign lesion that develops from the epithelium is often hyperkeratotic and may have a pebbly surface. Hyperkeratotic lesions appear white clinically.<sup>2</sup>

Malignant lesions of the oral soft tissues generally grow more quickly than benign lesions. They tend to grow over a period of several weeks to about 2 months before being brought to the attention of a health care provider. This has been described as a moderately rapid growth pattern. This distinguishes the potentially malignant lesion from a reactive lesion, such as an abscess, that enlarges over a period of several hours to several days. The malignant lesion is most often poorly circumscribed, meaning the borders blend into the surrounding tissue, making it difficult to distinguish

### Box 5.1 Typical distinguishing features between benign and malignant lesions

#### Benign Lesions

- Tend to be symmetrical and well circumscribed
- Well-circumscribed borders easily distinguished from surrounding normal tissue
- Grow slowly over several months to years
- Surface that develop from deep soft tissues is smooth and non-ulcerated
- Surface developed from epithelium is often hyperkeratotic and may have pebbly surface
- Hyperkeratotic lesions appear white clinically

#### Malignant Lesions

- Generally grow more quickly over several weeks to about 2 months
- Poorly circumscribed, blending into surrounding tissue so difficult to distinguish where lesion ends and normal tissue begins
- Overlying tissue in soft tissue lesion is often ulcerated

where the lesion ends and normal surrounding tissue begins. The tissue overlying a malignant soft tissue lesion is often ulcerated.<sup>2</sup> It should be emphasized that these features indicate that a lesion is potentially malignant. It serves as a guide for the dentist to advise the patient and parents and to recommend appropriate management. A malignant lesion can only be definitively diagnosed by examination of the tissue by a pathologist.

This chapter provides an overview of soft and bone lesions of the oral cavity that may be seen in a pediatric patient. It is not intended to be all inclusive, but will hopefully give a lead to the general or pediatric dentist when evaluating a patient with a potential pathology.

## Epithelial Lesions

Lesions arising from the epithelium often have a rough or pebbly surface and are most often more pale or even white compared to the surrounding oral mucosa. In children, most lesions arising from the epithelium are related to the human papilloma virus (HPV). These lesions include the squamous papilloma, verruca vulgaris, condyloma acuminatum, and multifocal epithelial hyperplasia. All of these lesions exhibit an exophytic growth pattern, meaning that they arise from the surface of the oral soft tissues and grow outward. The squamous papilloma (Fig. 5.1) is more common in the oral cavity than is verruca vulgaris, which usually occurs on the skin. It is associated with low-risk HPV subtypes HPV-6 and HPV-11. The squamous papilloma is most often a solitary rough-surfaced lesion that is pedunculated or on a stalk. It can vary between a pebbly, pink appearance to a white lesion with frond like projections.<sup>3,4</sup>

Verruca vulgaris is uncommon in the oral cavity, but is a very common skin lesion particularly in adolescents and young adults with peak incidence between 12 and 16 years of age. The virus is thought to infect the oral epithelium when a child bites a wart or sucks on their finger or thumb, a process called autoinoculation. Verrucas are associated with HPV-2 and HPV-4. Verruca vulgaris presents most

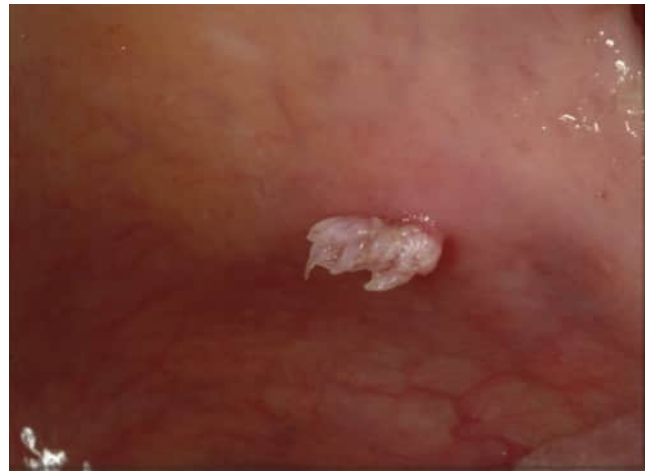

Fig. 5.1 Squamous papilloma in a 4-year-old.

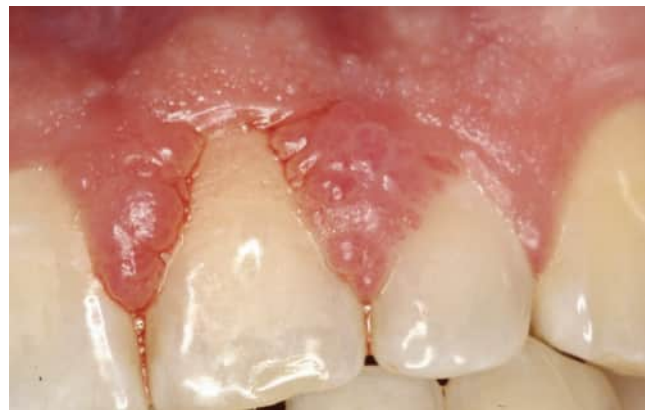
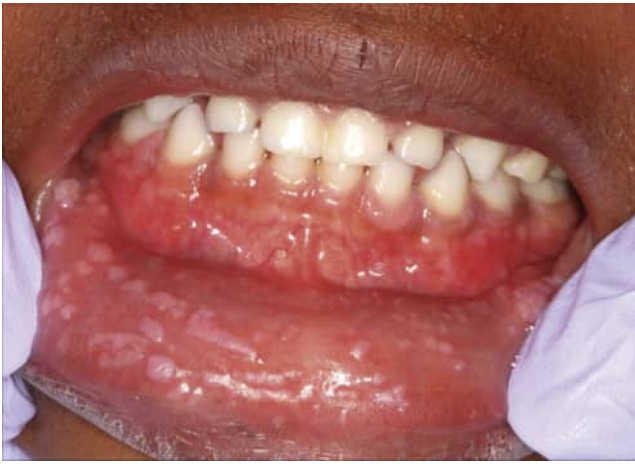
Fig. 5.2 Condyloma in a 17-year-old between teeth #8-9 and 10, extending into the palate.

often as a solitary, sessile lesion most commonly found on the palate and the labial mucosa. Sessile means that the lesion has a broad base rather than a stalk. The lesion is usually less than 1.0 cm in diameter with a pink to white rough surface.<sup>5,6</sup>

Condyloma acuminatum most commonly presents as anogenital warts and is a commonly reported sexually transmitted disease. It is uncommon in the oral cavity and the presence of the lesion in the mouth does not necessarily indicate sexual contact. Other modes of transmission, such as through fomites, may be possible.<sup>7</sup> Like the squamous papilloma, condyloma acuminatum is associated with HPV-6 and HPV-11. Because of the similar clinical presentation and the association with the same subtypes of HPV, some authors argue that squamous papilloma and condyloma acuminatum should be considered as the same lesion. Condyloma may present as a solitary lesion (Fig. 5.2), but more often presents as multiple lesions that may coalesce to form a larger growth. The lesions have a pink to white surface and are usually sessile, but may be pedunculated as well. In the oral cavity, condyloma are most often seen on the tongue and labial mucosa.<sup>6,8</sup>

Multifocal epithelial hyperplasia, also known as Heck's disease, is most commonly seen in children and is also caused by HPV. The disorder was originally thought to



**Fig. 5.3** A 5-year-old, recent immigrant to the United States. Sister also presented with similar lesions.

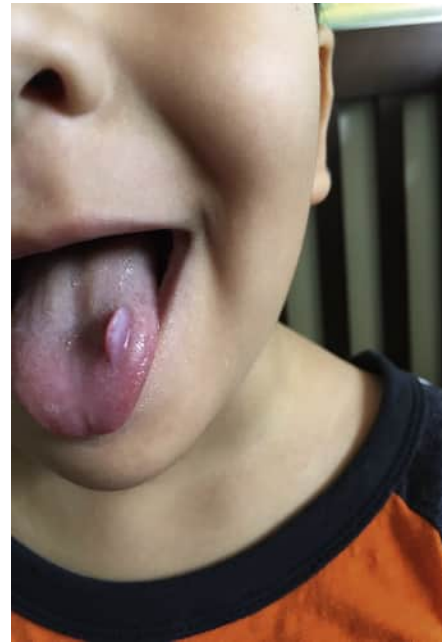affect primarily Native American populations, but has since been described worldwide. Multifocal epithelial hyperplasia is clinically distinct from the other HPV lesions in that it presents as multiple lesions in a generalized pattern covering portions of the oral mucosa (Fig. 5.3). There are two recognized clinical patterns. The papulonodular variant occurs most often on the buccal and labial mucosa. This is the more common of the two variants, and the lesions present as flat and mucosa colored. The less common papillomatous variant is seen on the gingiva and tongue, with lesions described as white with a pebbly surface. The individual lesions of both variants measure between 1 mm and 10 mm in diameter.<sup>6,9</sup>

Squamous papilloma, verruca vulgaris, condyloma acuminatum, and multifocal epithelial hyperplasia are all benign lesions and their presence in the oral cavity does not imply that the patient is at a higher risk of HPV-related malignancies. Although oropharyngeal cancer in adults is associated with HPV, the proteins of the HPV subtypes are different and allow the subtypes to be characterized as high risk or low risk for malignancies. The subtypes of the viruses that cause HPV-associated lesions commonly in childhood are low-risk variants; they neither have the potential to develop into a malignant lesion nor does their presence imply that the child is infected with a high-risk variant, putting them at risk for oropharyngeal carcinoma in the future.<sup>6</sup>

The treatment of HPV-related lesions of the oral cavity in childhood is generally surgical excision. They are removed to eliminate unsightly lesions if in visible areas of the oral cavity and to decrease the chance of autoinoculation and spread of the infection. The newer HPV vaccines, both the quadrivalent (4vHPV) and the 9-valent (9vHPV), protect against HPV-6 and HPV-11 in addition to high-risk variants. Widespread administration of these vaccines will likely reduce the incidence of these lesions in the future.<sup>6</sup>

## Fibroma

The fibroma is the most common benign soft tissue lesion found in the oral cavity (Fig. 5.4). Unlike lesions arising from the epithelium, the fibroma occurs in the submucosa,



**Fig. 5.4** Fibroma in a 9-year-old associated with trauma.

the connective tissue beneath the epithelial layer. Because the fibroma occurs in the submucosa, it is characteristically a dome-shaped lesion with a sessile base and a smooth surface that is usually the color of the surrounding mucosa. It may vary from firm to flaccid in texture and most commonly occurs in sites predisposed to irritation or trauma, such as the buccal mucosa, lip, tongue, gingiva, and hard palate. It is more common in adults, but may occur at any age. Often called focal fibrous hyperplasia, irritation fibroma, or traumatic fibroma, a fibroma occurring in the oral cavity is not a true neoplasm but a reactive lesion forming in response to chronic irritation. Fibromas on the gingiva may represent a pyogenic granuloma that has undergone sclerosis.<sup>8,10</sup>

Treatment of the fibroma consists of simple surgical excision. The excised fibroma should be submitted for microscopic examination as other soft tissue lesions may appear clinically similar to a fibroma. Once removed, the fibroma is unlikely to recur.

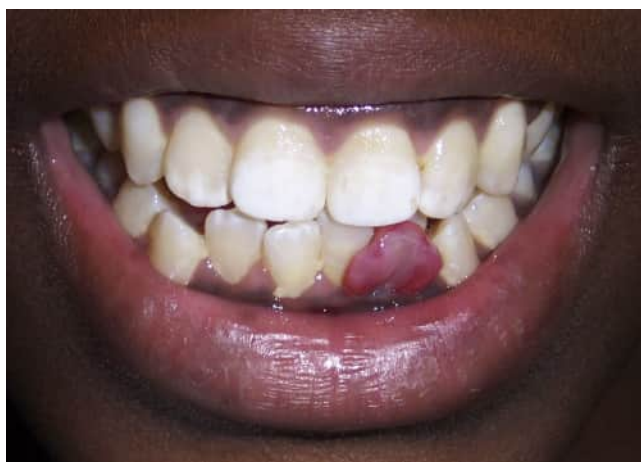## Localized Gingival Swellings

There are several lesions that characteristically present as localized enlargements on the gingiva. Although other soft tissue tumors may present in this way, this presentation is classic for three lesions in particular; they make up the differential diagnosis for a localized gingival swelling, particularly in an adolescent or young adult. These lesions are often described as the “three Ps”: pyogenic granuloma, peripheral ossifying fibroma, and peripheral giant cell granuloma.

### PYOGENIC GRANULOMA

Pyogenic granuloma is a relatively common soft tissue enlargement that arises from the fibrous connective tissue of the skin or mucous membranes (Fig. 5.5). The pyogenic





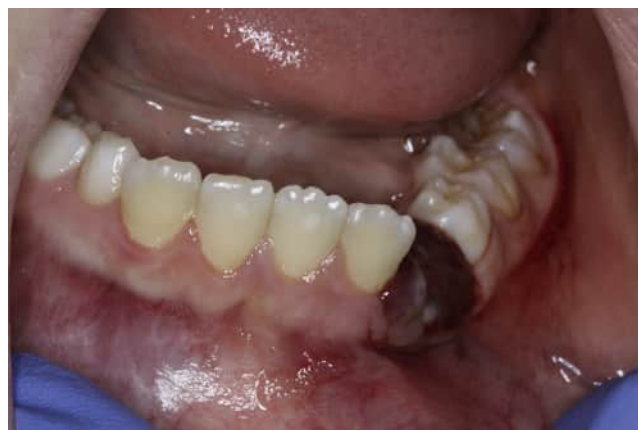**Fig. 5.5** Pyogenic granuloma arising from the interdental papilla between the mandibular incisors. The surface is lobulated. There was poor oral hygiene with heavy accumulation of plaque on the lingual surfaces of the teeth.

granuloma is a reactive inflammatory process in which an exuberant fibrovascular proliferation of the connective tissue occurs secondary to a low-grade, chronic irritation. When present on the gingiva, the source of this irritation may be dental plaque and calculus. Although the lesion can occur at any age and on any location, the mucosa or skin, it is characteristically seen on the gingiva of adolescents and pregnant women. When present in pregnant women, it may be referred to as a pregnancy tumor. A review of pyogenic granulomas of the oral cavity revealed a 65% to 70% incidence of occurrence on the gingiva, most commonly the maxillary anterior labial gingiva, followed by the lips, tongue, buccal mucosa, palate, mucolabial or mucobuccal fold, and alveolar mucosa of edentulous areas. In this series, 27% of 46 patients were younger than 20 years of age.<sup>11</sup> Another review of 38 cases reported an age range of 5–75 years (mean age, 33 years), with the most frequent site of occurrence also being on the gingiva (74%).<sup>12</sup>

Clinically, the pyogenic granuloma is a raised lesion on either a sessile or a pedunculated base. Its surface is smooth or lobulated and characteristically ulcerated. The remainder of the lesion is often brightly erythematous. The pyogenic granuloma often has a rapid growth rate, enlarging over a period of a few weeks to several months. Depending on the age of the lesion, the texture varies from soft to firm and is suggestive of an ulcerated fibroma. Because of the pronounced vascularity of these lesions, they bleed easily when probed. Although the pyogenic granuloma is a reactive process, its clinical presentation as a rapidly growing, ulcerated lesion is similar to that of malignant soft tissue tumor. Consequently, treatment consists of surgical excision with microscopic examination to rule out other more serious lesions. Some authors recommend scaling the teeth in the area of the lesion in an attempt to remove the source of irritation. About 16% of pyogenic granulomas recur following excision. The recurrence rate is higher in pregnant females.<sup>13</sup>

### PERIPHERAL GIANT CELL GRANULOMA

Peripheral giant cell granuloma (Fig. 5.6) is a reactive lesion that has a clinical presentation similar to the



**Fig. 5.6** Peripheral giant cell granuloma in an 8-year-old girl. Tooth #M exfoliated spontaneously.

pyogenic granuloma. Unlike the pyogenic granuloma, the peripheral giant cell granuloma is found exclusively on the gingiva. It presents as a pedunculated or sessile gingival enlargement that is usually less than 2 cm in diameter. The surface is smooth and may be ulcerated. The peripheral giant cell granuloma is vascular, like the pyogenic granuloma; however, it is more likely to be blue or purple, unlike the pyogenic granuloma which is bright red. With that said, it is only truly distinguishable from pyogenic granuloma and peripheral ossifying fibroma on the basis of its microscopic appearance, which is essentially identical to that of central giant cell granuloma (discussed later in this chapter). In a review of 720 cases, 33% were seen in patients younger than 20 years of age, which concurs with the findings of another study in which 33 of 97 cases (34%) occurred in individuals between 5 and 15 years of age. There is a nearly 2:1 predilection of females to males, with the mandible being involved more often than the maxilla. Although it develops in soft tissue, resorption of the adjacent alveolar bone may occur. While rare, cervical root resorption may also be seen in association with a peripheral giant cell granuloma.

The peripheral giant cell granuloma is best treated by complete surgical excision, with care taken to excise it at its base. A recurrence rate similar to that of a pyogenic granuloma is reported. Scaling of the adjacent tooth is recommended for peripheral giant cell granuloma to minimize the risk of recurrence.

### PERIPHERAL OSSIFYING FIBROMA

The third lesion of the “three Ps” that characteristically presents on the gingiva is the peripheral ossifying fibroma. Peripheral ossifying fibroma is a benign reactive lesion believed to be of periodontal ligament origin that occurs, like the peripheral giant cell granuloma, exclusively on the gingiva. Despite the similarity in the name, it does not represent the soft tissue counterpart of the central ossifying fibroma, a true benign neoplasm of bone. Clinically, the peripheral ossifying fibroma is similar in appearance to the pyogenic granuloma or the peripheral giant cell granuloma, but is more likely to be pink and firm compared to the other two highly vascular lesions.<sup>14</sup> In the largest series of cases, 50% of the lesions were noted to occur in individuals

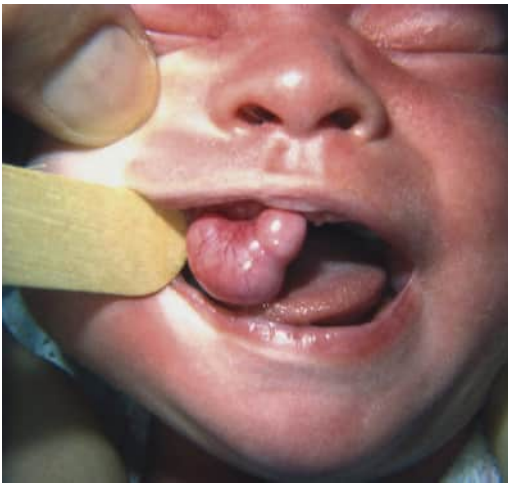

Fig. 5.7 Congenital epulis of the newborn.

between 5 and 25 years of age, with the peak incidence at 13 years. The lesions were almost equally divided between maxilla and mandible, with more than 80% of the lesions in both jaws occurring anterior to the molar area.

Simple surgical excision is the treatment of choice. Like the pyogenic granuloma and the peripheral giant cell granuloma, recurrences are not uncommon and were reported in two studies in 16% and 20% of cases, respectively.<sup>15</sup> This rate is similar to the other two lesions.

## Congenital Epulis

Several other lesions characteristically occur on the gingiva in children and should be noted. The first is the congenital epulis of the newborn. Congenital epulis of the newborn is a rare lesion of uncertain origin that occurs exclusively on the gingiva in newborn infants. It is most often found on the maxillary anterior alveolar ridge and less commonly on the mandibular anterior alveolar ridge. Although usually solitary lesions, they may be multiple, most often affecting both the maxilla and mandible. Rare simultaneous occurrence of lesions on the maxillary anterior alveolar ridge and tongue have been reported. Clinically, the lesion presents at birth as a pink, smooth to lobulated, pedunculated mass that may vary in size from a few millimeters to >7 cm in diameter. More than 90% of cases occur in girls (Fig. 5.7).<sup>16,17</sup>

Under the microscope, the congenital epulis looks similar to a granular cell tumor seen in older persons. Special stains indicate that it is not likely related to the granular cell tumor and may derive from primitive nerve cells. However, the histogenesis of the congenital epulis remains uncertain.<sup>18</sup>

Although the clinical presence of congenital epulis in a newborn baby may alarm the parents, it ceases to grow following birth and is benign, with some cases undergoing spontaneous involution. The treatment is simple surgical excision, with care taken not to interfere with the developing dentition. Since there are reports of spontaneous regression, lesions measuring <2 cm, where there is no interference with respiration or feeding, can be allowed time to regress in an effort to avoid general anesthesia in a

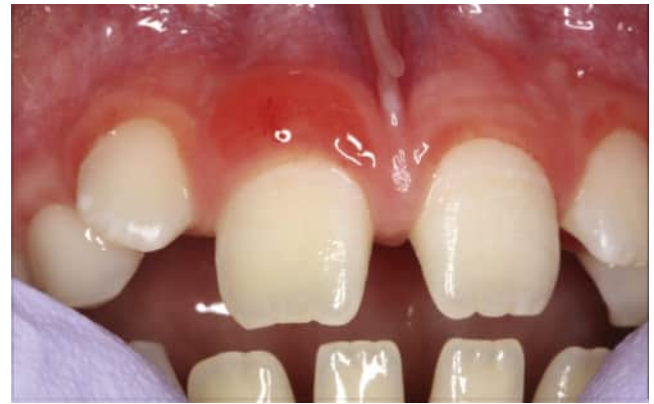

Fig. 5.8 Localized juvenile spongiotic gingival hyperplasia in a 9-year-old girl with otherwise excellent hygiene.

neonate. There is no propensity for recurrence with excision, even in those cases in which the lesion is incompletely removed.<sup>16</sup>

## Localized Juvenile Spongiotic Gingival Hyperplasia

Localized juvenile spongiotic gingival hyperplasia (LJSGH) is a recently described entity that characteristically occurs on the anterior gingiva in children and adolescents. First described in 2007, LJSGH is a distinct form of inflammatory hyperplasia. The LJSGH presents as a solitary, asymptomatic, brightly erythematous, slightly raised papillary area on the anterior maxillary gingiva. The surface of the lesion is sometimes described as having a velvety appearance. It is most often noted on the gingiva centered over the root of a tooth, although some cases involve the interdental papilla. Multifocal lesions and lesions affecting the mandibular anterior gingiva have been reported. The lesion is seen more often in females and the average age of patients is 12 years. LJSGH tends to bleed on probing or during oral hygiene procedures and does not resolve following oral hygiene. Clinically, the lesion appears most similar to a small pyogenic granuloma or inflamed squamous papilloma (Fig. 5.8). The word spongiotic in the name describes the edema in the epithelial layer seen microscopically that is characteristic of this lesion.<sup>19,20</sup>

Surgical excision is currently recommended as the treatment of choice by most authors. Although cases have been reported in older individuals, the fact that the lesion is seen predominantly in children and adolescents implies that the lesion may resolve spontaneously over time. Certainly, lesions where the diagnosis is in doubt, have an atypical presentation, or are a cosmetic concern for the patient should be surgically excised and submitted for biopsy.<sup>19,21</sup> Approximately 10% of lesions recur following excision.

## Gingival and Palatal Cysts of the Newborn

Another lesion that is noted on the gingiva in children are gingival cysts of the newborn. These have a clinical appearance distinct from the previous gingival lesions discussed.

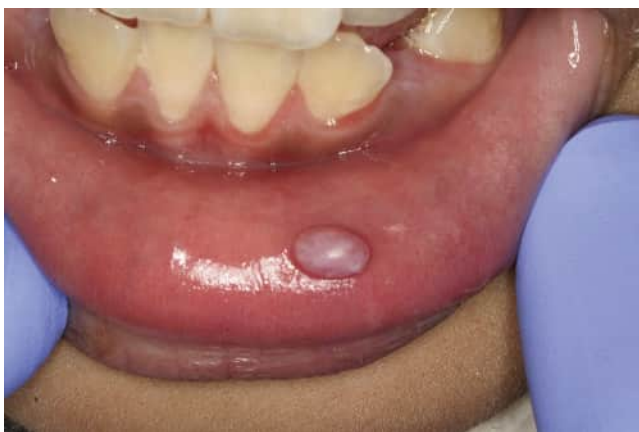

Fig. 5.9 Mucocoele on the lower lip.

These cysts are thought to arise from the remnants of the dental lamina. These lesions present as small white nodules on the gingiva and are usually present at birth. They often present as multiple cysts and are more common on the maxilla than on the mandible. These small developmental cysts resolve spontaneously and are rarely seen after 3 months of age.

Similar lesions are seen on the hard palate and are referred to as palatal cysts of the newborn. Some of these cysts may arise from the epithelium trapped during the meeting of the palatal shelves *in utero*. Other cysts are thought to arise from the development of the minor salivary glands. Cysts present on the midline of the palate are traditionally referred to as Epstein's pearls and those scattered across the palate are called Bohn's nodules. Like the gingival cysts of the newborn, these cysts spontaneously resolve.<sup>22</sup> The distinction between Bohn's nodules and Epstein's pearls is academic and serves no clinically relevant purpose.

## Mucocoele

The mucocoele is the most common salivary gland lesion in all age groups including children. Several studies have shown that one-half to two-thirds of mucocoeles occur in patients under 17 years of age.<sup>23</sup> The mucocoele is a reactive lesion of the salivary glands that is the result of saliva "leaking" from a gland or duct into the surrounding connective tissue. The extravasation of mucus into the fibrous connective tissue produces a cyst like cavity. Unlike a true cyst, the wall of the mucocoele is not lined by epithelium, but by granulation tissue. Since the extravasated saliva collects in the connective tissue beneath the epithelial layer, the mucocoele, like other lesions occurring in the submucosa, has a smooth surface.

Mucocoeles are noted to occur most commonly on the lower lip, with the floor of the mouth and buccal mucosa being the next most frequent sites of involvement. Mucocoeles are only rarely seen on the upper lip, retromolar pad, or palate. Although they may occur at any age, including at birth, they tend to be noted most frequently in the second and third decades of life. No obvious gender predilection is noted.

A mucocoele may be located either in the superficial mucosa, where it is presents as a fluid-filled vesicle or blister that often has a bluish hue (Fig. 5.9), or deep within the

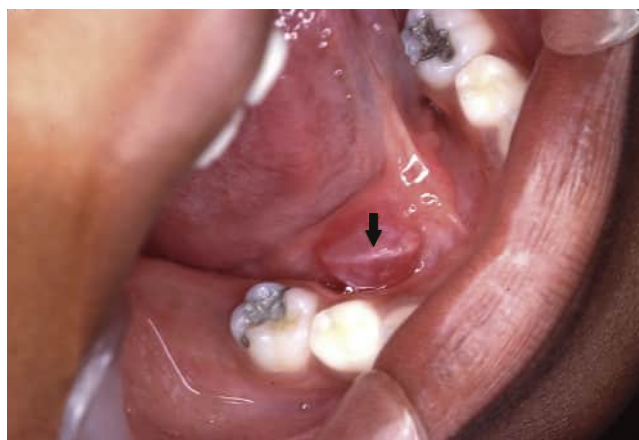

Fig. 5.10 Ranula on the floor of the mouth (arrow).

connective tissue, where it is seen as a fluctuant nodule that is similar in color to the surrounding mucosa. Unlike a true neoplasm, which will enlarge or remain stable in size, the mucocoele often appears to increase and decrease in size. There may be spontaneous drainage of the mucus within the lesion resulting in a decrease in size or even temporary resolution, especially in superficial lesions. The lesion then enlarges again as saliva continues to drain into the connective tissue at the site of the torn duct.

Occasionally, the mucocoele will rupture and heal spontaneously. This is especially true of lesions that are of short duration. For lesions that do not resolve on their own over a period of a few weeks or months, treatment is by surgical excision. Removal of the nearby minor salivary glands when excising the lesion is recommended to prevent recurrence.

Ranula is the clinical term for a mucocoele occurring on the floor of the mouth when saliva leaks from the sublingual glands. Ranulas are typically slowly enlarging, fluctuant swellings occurring on one side of the midline of the floor of the mouth and are so named because of their resemblance to the bloated underside of a frog's belly (Fig. 5.10). The clinical term plunging ranula is used when extravasated mucus dissects through the mylohyoid muscle and along the fascial planes of the neck, producing a swelling evident in the floor of the mouth.

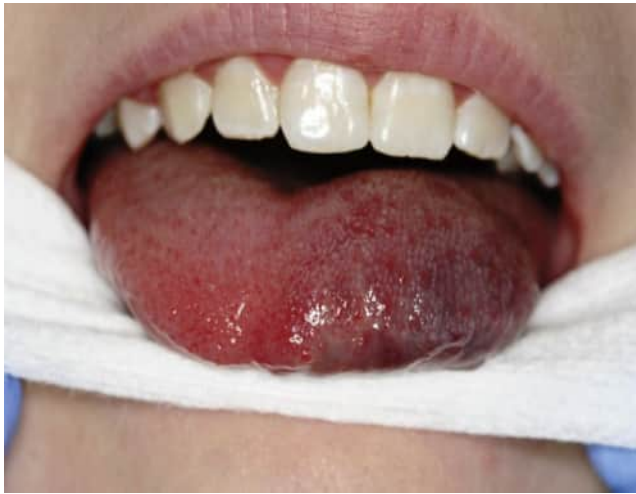For small ranulas, treatment by marsupialization can be attempted. Marsupialization is the removal of the superficial intraoral surface of the lesion. Although less invasive, marsupialization is often ineffective in preventing recurrence of the lesion. Larger examples, or lesions that recur, require the removal of the offending sublingual gland.<sup>23</sup>

## Vascular Malformations

Several soft tissue lesions may present in children that are the result of developmental anomalies of the vasculature. The term vascular anomaly is now used to classify lesions that include hemangiomas and vascular malformations (venous, capillary, arteriovenous, and lymphatic).<sup>24</sup>

Vascular anomalies are commonly encountered lesions of childhood and may be divided into hemangiomas and vascular malformations.<sup>25</sup> Hemangiomas are differentiated from vascular malformations since they are considered





**Fig. 5.11** Hemangioma of the left side of the tongue. The lesion developed within the first 4 weeks of life.

benign tumors that demonstrate proliferative activity of the endothelial cells, whereas vascular malformations are a structural anomaly of the vessels with normal endothelial cell turnover. The hemangioma is a common, benign vasoformative tumor that frequently occurs in the head and neck in children. Hemangiomas of infancy are generally not present at birth but develop within the first few weeks of life. On the superficial skin, these tumors appear bright red and may be either smooth or bosselated. A bosselated surface is one that is covered with many broad folds or protuberances. Deeper skin lesions present as smooth lesions with a bluish hue.<sup>26</sup>

Hemangiomas arising in the oral soft tissues most commonly affect the tongue (Fig. 5.11), lips, and buccal mucosa. Clinically, they may be flat or raised and may vary from deep red to blue. Their histologic classification is based on the size of the vascular spaces. A capillary hemangioma is the most common type and is composed of many tiny capillaries with a pronounced endothelial cell proliferation. The cellular or juvenile hemangioma principally consists of a proliferation of endothelial cells with only small numbers of discernible capillaries. A cavernous hemangioma is characterized by large, blood-filled sinusoidal spaces lined by endothelial cells and supported by a fibrous stroma. Hemangiomas may also occur centrally within the mandible or maxilla.

Vascular malformations are present at birth and persist throughout life.<sup>24</sup> They may be categorized as high-flow lesions and low-flow lesions. Arteriovenous malformations are high-flow lesions (Fig. 5.12A and B). These lesions result from a direct connection between the arterial and venous blood supply. These lesions often cause a dusky red appearance of the overlying soft tissue and may present with pain, bleeding, or ulcerations of the overlying surface. Although present at birth, they may not come to attention until they grow larger as the child grows.<sup>27</sup> When examining high-flow lesions, the clinician may be able to detect the rapid flow of blood through the lesion by palpation, where they feel a thrill or the vibration of the rapid blood flow, or by auscultation, where they hear a bruit, or the sound of the blood flowing through the lesion. Low-flow lesions include capillary, lymphatic, and venous malformations. These lesions

present as a small, red, blue, or purple compressible lesion that lacks the thrill and bruit of the high-flow lesion. These lesions may blanch or lose their color when gentle pressure is applied. This is the result of the blood being pushed out of the lesion. Not all vascular malformations will blanch on pressure, so this sign is useful when present; however, the lack of blanching cannot rule out a vascular malformation.

Vascular malformations may also occur centrally or within bone. They are more common in the mandible than in the maxilla. A high-flow lesion is potentially dangerous in that a biopsy or simple event such as a tooth extraction may lead to a catastrophic hemorrhage, possibly leading to death.<sup>28</sup> These lesions may be asymptomatic, picked up only as incidental radiographic findings, or they may cause pain and swelling. They are typically well-circumscribed, radiolucent lesions that are indistinguishable from odontogenic or other lesions of bone. Occasionally, loose or displaced teeth may be seen. It is advisable to aspirate such lesions with a needle before surgery or dental extraction to avoid the possibility of severe blood loss or exsanguination caused by the inability to control the resultant profuse bleeding.

The treatment for vascular anomalies varies with the type, location, and size of the lesion involved. Many lesions spontaneously involute with age, especially those that are noted early and cease growing during the first year of life. Others require no treatment because of their small size and innocuous nature.

## Lymphangioma

Lymphangiomas are relatively rare type of vascular malformation that merit separate consideration because of its distinct clinical presentation. Even though the embryologic events leading to their development remain unclear, they are thought to arise as a benign hamartomatous proliferation of sequestered lymphatic rests. The head and neck region is most commonly involved, with up to two-third of cases being present at birth and as many as 90% being present by the second year of life. A small number of lymphangiomas may not manifest until the child is older.<sup>29</sup>

Lymphangiomas of the oral soft tissues may occur on the lips and buccal mucosa, but the most common location is the tongue causing macroglossia. Superficial lesions are elevated and nodular in appearance, often described as appearing similar to frog's eggs. They may have the same color as the surrounding mucosa, but some area of the lesion may also have a red or purple color due to hemorrhage in the lymphatic vessels. Deeper lesions cause enlargement of the tissue without the nodular surface. Treatment is generally not indicated for small oral mucosal lymphangiomas. Partial or complete spontaneous involution is occasionally noted.<sup>29</sup>

Cystic hygromas are lymphangiomas containing large cyst like (macrocytic) spaces. Cystic hygromas may be found in the oral cavity in sites such as the tongue, but they most frequently appear as a mass in the neck, occasionally extending into the mediastinum. Cystic hygroma most commonly present as a slow-growing asymptomatic soft tissue mass; however, they may undergo sudden enlargement in the presence of trauma, inflammation, internal hemorrhage, or respiratory tract infection. Large cystic hygromas

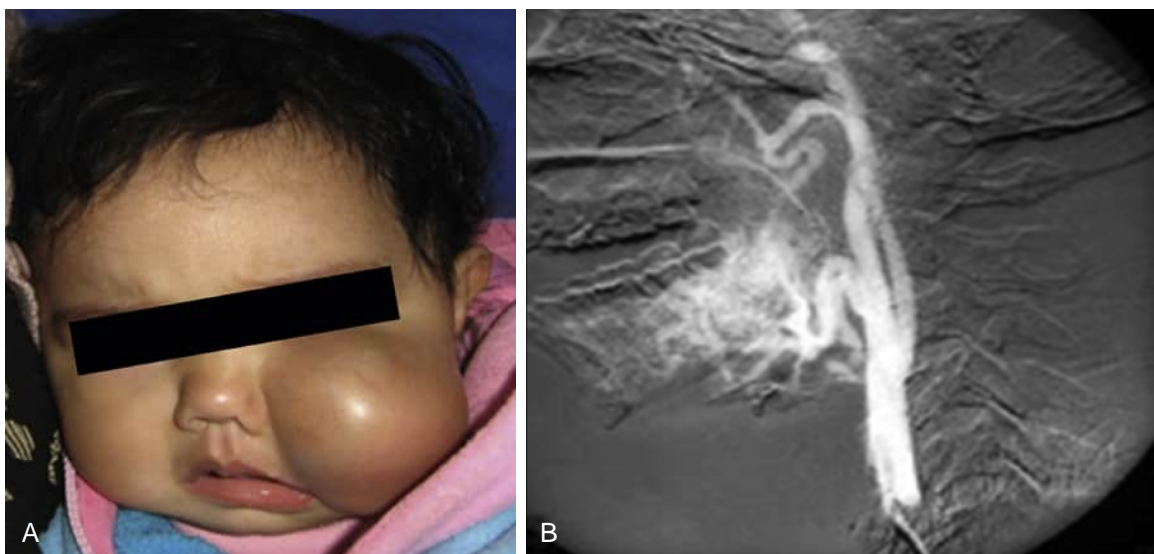


Fig. 5.12 (A) Vascular malformation (arteriovenous) in a 4-year-old girl. (B) Arteriography of the same lesion.

may encroach on the airway and esophagus, leading to difficulty in swallowing and even airway obstruction.<sup>30</sup>

Treatment of lymphatic lesions depends on the size and location. Lesions that are not associated with a function or cosmetic problem are often left alone. Surgical excision is a consideration for some lesions but is associated with a high recurrence rate, particularly in cystic hygromas. Sclerotherapy is attempted in some lesions as well. This is most successful in macrocystic lesions, but may prove effective for lesions comprising smaller lymphatic vessels as well.<sup>29,30</sup>

## Benign Neoplasms

Benign oral soft tissue and salivary gland neoplasms, although rare in pediatric patients, do occur from time to time. As discussed at the beginning of the chapter, these lesions often have a similar clinical presentation. They present as a swelling that grows over a period of months to years. These swellings are smooth surfaced, non-ulcerated, and of the same color as the surrounding mucosa. Microscopic examination of the biopsy specimen is generally required to make a definitive diagnosis. Two examples of soft tissue lesions that present in children are discussed.

### NEUROFIBROMA

Neurofibroma is a benign neural neoplasm of Schwann cell origin. Several clinical forms of neurofibroma are recognized. The solitary neurofibroma may present in the skin or oral mucous membranes as a soft tumor with a sessile or pedunculated base. Intraorally, neurofibromas may present in several ways. They may present as nodular lesions on either a sessile or pedunculated base, often with a normal, pink mucosal color (Fig. 5.13), as a diffuse, ill-defined swelling with a firm to doughy consistency, or as a diffuse, non-compressible mass. They are most frequently found on the tongue and buccal mucosa but occasionally present as intraosseous lesions, which occur most commonly in the

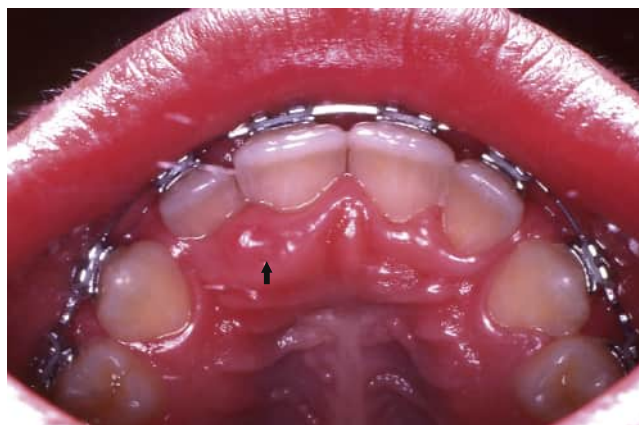

Fig. 5.13 A 14-year-old boy undergoing orthodontic therapy was referred for evaluation of gingival hyperplasia on the lingual surfaces of the maxillary incisors and a firm swelling on the palatal side of tooth #9 (arrow) that was found after biopsy to be a neurofibroma.

posterior mandible. The presence of a neurofibroma may be part of neurofibromatosis; however, the presence of either a solitary or diffuse neurofibroma does not in itself herald the diagnosis of neurofibromatosis.<sup>31</sup>

There are three recognized forms of neurofibromatosis—neurofibromatosis type 1 (NF1), neurofibromatosis type 2 (NF2), and schwannomatosis—with the most prominent common denominator of all three being the appearance of Schwann cell-initiated tumorigenesis of the peripheral nervous system. Because of its frequency of occurrence and frequency of oral and cutaneous manifestations evident to the dental practitioner, only NF-1 will be discussed in this chapter. NF1, also known as von Recklinghausen disease, is a relatively common disorder showing autosomal dominant inheritance with complete penetrance, variable clinical expressivity and pleiotropy, and age-dependent expression of clinical manifestations. It occurs in approximately 1 in 3000 live births, with an equal gender predilection. The *NF1* gene is carried on chromosome 17 and has tumor-suppressor function, with the tumor-suppressing properties of neurofibromin (the NF1 gene product) being



impaired or lost due to mutation in the gene. It is said to be the most common single-gene disorder to affect the human nervous system. The criterion for diagnosis is the presence of two or more of the following features: six or more café-au-lait spots ( $\geq 1.5$  cm in postpubertal individuals,  $\geq 0.5$  cm in prepubertal individuals), two or more neurofibromas of any type or one or more plexiform neurofibromas, freckling in the axillary or inguinal region, optic glioma, two or more pigmented iris hamartomas or Lisch nodules, dysplasia of the sphenoid bone or dysplasia or thinning of long bone cortex with or without pseudoarthrosis, and a first-degree relative with NF1.<sup>32</sup>

## PLEOMORPHIC ADENOMA

The most common benign tumor of the salivary gland is the pleomorphic adenoma, comprising about 90% of all salivary gland tumors seen in children. The pleomorphic adenoma most often presents as an asymptomatic enlargement in the parotid gland. When affecting the minor salivary glands, it presents with an appearance similar to other benign soft tissue tumors. It is a slow-growing, well-circumscribed lesion surfaced by normal mucosa. The minor salivary glands of the posterior hard palate and soft palate is the most common intraoral location, but it can be seen anywhere where there are minor salivary glands, including the floor of the mouth where it may affect the submandibular gland or sublingual gland as well. The pleomorphic adenoma is treated by excision.<sup>23</sup>

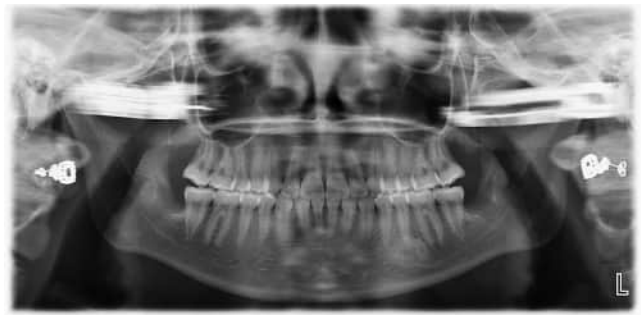
## Benign Lesions of Bone

Lesions found in the maxilla and mandible are classified as either odontogenic, arising from the epithelium and connective tissue that forms the teeth, or non-odontogenic, arising from the bone, cartilage, or soft tissue. Benign lesions of bone share characteristics with the benign soft tissue lesions discussed earlier. They tend to grow slowly, over a period of months to years, and are generally well circumscribed, meaning the borders of the lesion are easily demarcated from the surrounding bone. Moreover, benign lesions of bone tend to displace the teeth and expand the bone without perforating the cortical plates. By contrast, malignant lesions of bone tend to grow rapidly causing teeth to become mobile and appear to “stand in space” rather than being displaced. Malignant lesions are often poorly circumscribed and perforate the cortical plate.

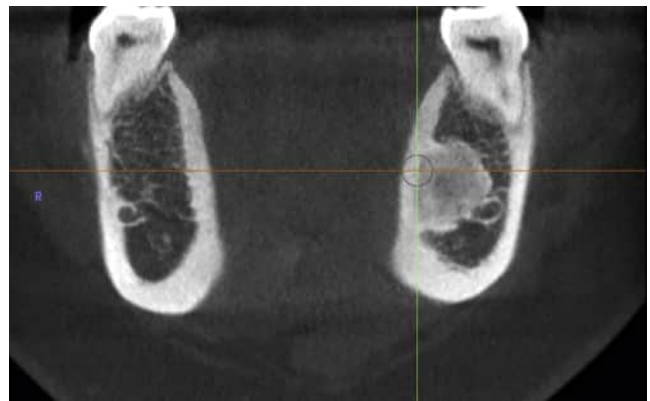
### BENIGN NON-ODONTOGENIC LESIONS OF BONE

#### Idiopathic Bone Sclerosis (Osteosclerosis)

Idiopathic bone sclerosis (osteosclerosis) or enostosis is not a neoplasm, but an area of sclerotic bone of unknown cause (Figs. 5.14 and 5.15). These are very common in adolescents and young adults and are most often seen in the first molar region of the mandible. Idiopathic osteosclerosis presents as a well-defined radiopaque area in the bone, not associated with the apex of the tooth. The area is asymptomatic and does not cause expansion of the mandible. The lesion may slowly increase in size when noted in children and adolescents, but remain stable in size after the patient



**Fig. 5.14** A 16-year-old boy undergoing orthodontic therapy. A panoramic film revealed a radiopaque area at the apex of tooth #20. Idiopathic bone sclerosis.



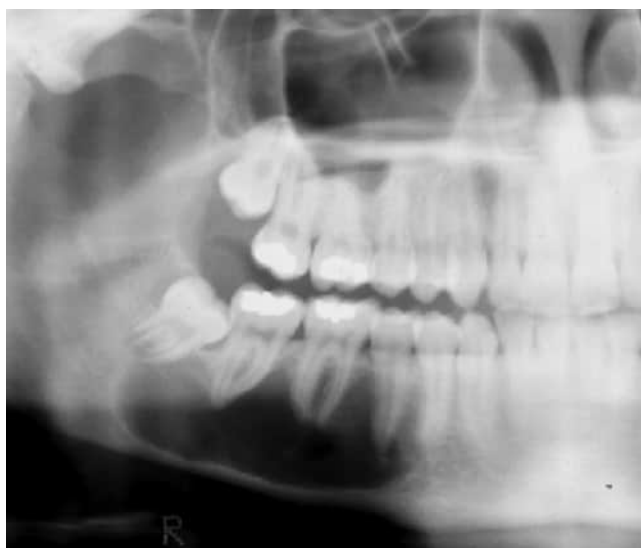**Fig. 5.15** CBCT, coronal view (same patient to this. Fig. 5.14). Notice also no expansion.

stops growing. Most patients only have one sclerotic area, although some people may have multiple lesions. If the sclerotic area is associated with the apex of a carious tooth, it may indicate irreversible pulpitis or a necrotic pulp and is more appropriately diagnosed as condensing osteitis. An idiopathic osteosclerosis does not require treatment, although follow-up is recommended until the lesion stops growing in adulthood.

#### Idiopathic Bone Cavity

As the name implies, the idiopathic bone cavity (Fig. 5.16) is a cavity in the bone of uncertain origin. It is also commonly referred to as a simple bone cyst or a traumatic bone cyst, although both of these are misnomers. The lesion is not a cyst as the space does not contain a connective tissue wall lined by epithelium, nor is there a clear association with acute injury, although trauma was proposed as a possible cause in the past. The idiopathic bone cavity most often occurs in children and adolescents, with peak incidence in the second decade. Lesions occurring in older individuals are most often associated with cemento-osseous dysplasia. Lesions of the jaws are noted with equal frequency in males and females and the majority of cases occur in the mandible. The idiopathic bone cavity often presents as a well-defined, unilocular radiolucency of the bone that can be between 1 cm and 10 cm in greatest dimension. A recent study showed an average size of 2.3 cm.<sup>33</sup> The idiopathic bone cavity may appear to scallop in between the roots of the teeth, particularly in larger lesions. When this feature is noted, it is highly suggestive of idiopathic bone cavity, although not diagnostic.





**Fig. 5.16** A 17-year-old asymptomatic. Incidental finding. Idiopathic bone cavity.

The lesion is generally asymptomatic and a minority of cases causes expansion of the bone, although some lesions may cause thinning of the cortical plates. As this is a cavity in the bone, it does not displace teeth like other benign cysts or tumors are expected to do. The teeth in the area are vital although some resorption of the roots may be noted.

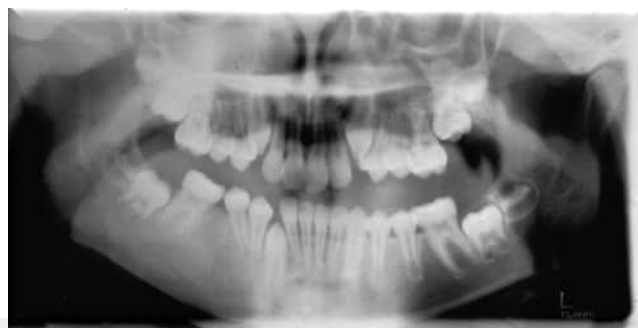Although the idiopathic bone cavity in the long bones is often treated aggressively, lesions in the jaws are managed by surgically entering the space and curettage of the walls. This induces regeneration of the bone, and normal radiographic findings are noted 12–18 months following surgery. Some studies indicate that lesions may persist following surgical exploration. Despite this, the prognosis is excellent and observation is recommended once the diagnosis is established.<sup>33</sup>

## BENIGN FIBRO-OSSEOUS LESIONS OF THE JAWS

Benign fibro-osseous lesions of the jaws comprise a diverse group of lesions sharing similar microscopic appearance of fibrous connective tissue containing mineralized product. The mineralized product consists of varying amounts of woven bone, lamellar bone, and curvilinear trabeculae or spherical calcifications. The mineralized material may histologically resemble bone and/or cementum. Because of the similar microscopic appearance of these lesions, the clinical and radiographic features together with the microscopic features are necessary to establish the correct diagnosis. Many times, consideration of the intraoperative findings and the gross tissue evaluation are important in diagnosis as well. This group of lesions includes fibrous dysplasia (considered a developmental process), reactive or dysplastic processes grouped under the collective term cemento-osseous dysplasia, and cemento-ossifying fibroma, which is a benign neoplasm.<sup>34</sup> Because cemento-osseous dysplasia is very rare in children, we will only discuss fibrous dysplasia and cemento-osseous fibroma in this chapter.

### Fibrous Dysplasia

Fibrous dysplasia (Fig. 5.17) is a skeletal condition that may affect the jaws. It is considered a non-neoplastic



**Fig. 5.17** A 14-year-old asymptomatic. Incidental finding. Fibrous dysplasia. Notice the teeth displacement and the “orange peel appearance”

developmental lesion in which normal bone is replaced by poorly organized bone and fibrous tissue. One of the disease entities included in the category of benign fibro-osseous lesions of the jaws, it is distinguished from the others by its clinical and radiographic features. Fibrous dysplasia is caused by a somatic activating mutation of the alpha subunit of the G protein receptor (Gs-alpha) that ultimately results in abnormalities of osteoblast differentiation and abnormal bone formation.<sup>35,36</sup>

Fibrous dysplasia may affect one bone, monostotic fibrous dysplasia, or multiple bones, polyostotic fibrous dysplasia. A form of polyostotic fibrous dysplasia called McCune-Albright syndrome is associated with café-au-lait macules on the skin and various endocrine disorders, most commonly precocious puberty, but also including Cushing’s syndrome, hyperthyroidism, and growth hormone excess.

Monostotic fibrous dysplasia tends to develop early in life, with lesions being detected late in the first or early in the second decade of life. It is seen with approximately equal frequency in males and females, with the maxilla being involved more frequently than the mandible. Maxillary involvement can be an especially serious form of the disease, frequently involving contiguous bones across suture lines, including the maxillary sinus, floor of the orbit, sphenoid bone, base of the skull, and occiput. This form of the disease has been called craniofacial fibrous dysplasia and is not truly monostotic in its nature.

The most common clinical manifestation is a painless swelling of the jaws characterized by a smooth, uniform, fusiform expansion of the involved alveolar ridge. Obliteration of the mucobuccal or mucolabial fold is a common feature, with the overlying mucosa being normal in appearance. When the maxilla is involved, elevation of the eye may be noted.

Radiographically, fibrous dysplasia presents as a poorly defined lesion of bone that is characteristically sclerotic, but may vary from radiolucent to radiopaque depending on the maturity of the lesion. The radiographic appearance of the lesional bone on a radiograph is commonly referred to as having a ground-glass or orange peel appearance. Their borders are typically poorly defined, except for the anterior portion of some maxillary lesions, which may appear to be well circumscribed. Although significant tooth displacement and root resorption are not common features of fibrous dysplasia, divergence of roots may be noted. In children with developing permanent teeth, the teeth may be displaced and/or fail to erupt (Fig. 5.17). Other potential

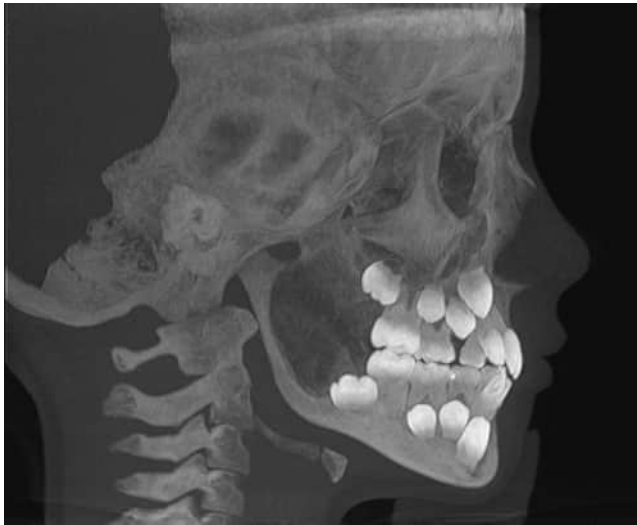

Fig. 5.18 A 9-year-old boy. CBCT, 3D reconstruction, sagittal view.

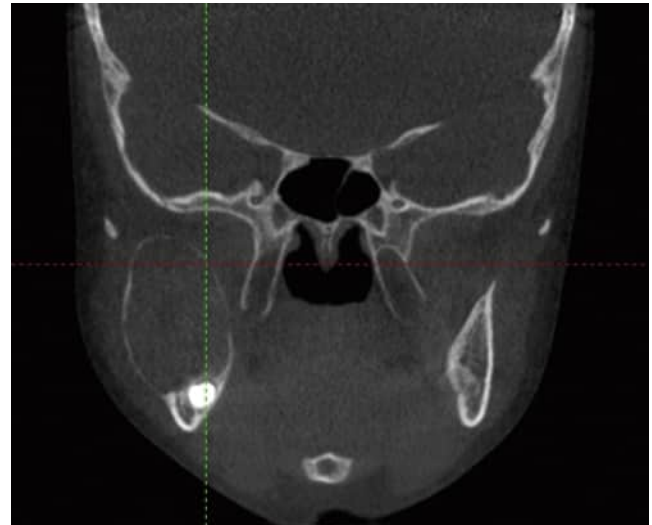


Fig. 5.19 A 9-year-old boy. CBCT, coronal view. Note the buccal expansion of the lesion.

distinguishing radiographic findings include superior displacement of the mandibular canal, displacement of the maxillary sinus cortex, alteration of the lamina dura because of the abnormal bone pattern, and narrowing of the periodontal ligament space.

Monostotic fibrous dysplasia of the jaws is typically a slow-growing, painless, progressive enlargement of bone whose growth pattern often stabilizes with time as maturation in skeletal growth is reached. Conservative therapy is indicated because of the benign nature of this lesion and because surgically the margins are ill defined and blend into the surrounding normal bone. Surgery, chiefly in the form of osseous recontouring, should be considered only when there is functional or significant cosmetic deformity and then usually only after stabilization of the disease process. Radiation therapy is contraindicated because of the possibility of a post-radiation sarcoma in the area. In symptomatic cases in which pain control and disease stabilization are needed, bisphosphonates have been used, resulting in pain relief and, in a number of patients, disease stabilization as well. Little, however, is known about the long-term skeletal effects of childhood bisphosphonate use, and it has been recommended that its use be limited to experienced pediatric units.<sup>34</sup>

### Cemento-Ossifying Fibroma

Cemento-ossifying fibroma, often referred to simply as ossifying fibroma, is a benign neoplasm of bone (Figs. 5.18 and 5.19). Although it was traditionally considered to be an odontogenic neoplasm of periodontal ligament origin affecting the tooth-bearing areas of the jaws, the occurrence of histologically identical neoplasms in the temporal, frontal, ethmoid, and sphenoid bones leave this concept in doubt. Although there is a predilection for occurrence in the third and fourth decades of life, cemento-ossifying fibroma is found with some frequency in patients younger than 20 years of age. The mandible is involved more often than the maxilla, with the molar and premolar regions of the mandible being the most common sites of occurrence.

Cemento-ossifying fibroma may be asymptomatic, being discovered on routine radiographic examination, or may present as a painless expansion of bone. Radiographically,

it is a well-circumscribed lesion, often with a well-demarcated sclerotic border. Beyond this, the radiographic features are quite variable. It most frequently presents as a unilocular radiolucency with or without radiopaque foci, which may be superimposed over teeth, be interposed between contiguous teeth, or reside in edentulous regions. Aggressively expansile lesions, with or without radiopaque foci, and multilocular expansile lesions may also be noted. Tooth displacement or divergence of roots of teeth and/or root resorption may be seen with varying degrees of frequency. Cortical thinning and bony expansion with clinical deformity have been reported in a majority of cases. Initial treatment is by enucleation or curettage where possible. Recurrence is considered uncommon.<sup>37,34</sup>

### JUVENILE OSSIFYING FIBROMA

The term *juvenile ossifying fibroma* (JOF), also known as juvenile active ossifying fibroma and juvenile aggressive ossifying fibroma, encompasses two distinct variants of ossifying fibroma involving the craniofacial bones: trabecular JOF (TrJOF) and psammomatoid JOF (PsJOF).

The majority of cases of TrJOF occur in children and adolescents. Both the maxilla and mandible may be involved, with the maxilla involved slightly more frequently. Occurrence in extragnathic locations is extremely rare. The reported mean age ranges from 8.5 to 12 years (range, 2–12 years). The growth of TrJOF has been characterized as painless, progressive, and sometimes rapid expansion of the affected area. Radiographically, they may show a mixed radiolucent radiopaque appearance and are expansile, fairly well defined, and may present with cortical thinning and perforation.

PsJOF occurs predominantly in the sinonasal and orbital bones in children, with a mean age range of 16 to 33 years (range, 3 months to 72 years). Clinically, it presents as bony expansion of the orbital or nasal bones or sinuses, and radiographically, it is seen as a round, well-defined, sometimes corticated, osteolytic lesion with cystic appearance.

Aggressive growth was noted to occur in both types of JOF, with a high recurrence rate after excision (30%–56%). This has been postulated as likely due to incomplete excision caused by the infiltrative nature of the tumor borders. Even with this, it has been proposed that, despite their similarities in biologic behavior, differences in histologic and clinical presentation as well as sites of occurrence between PsJOF and TrJOF warrant their separation into two distinct entities.<sup>38</sup>

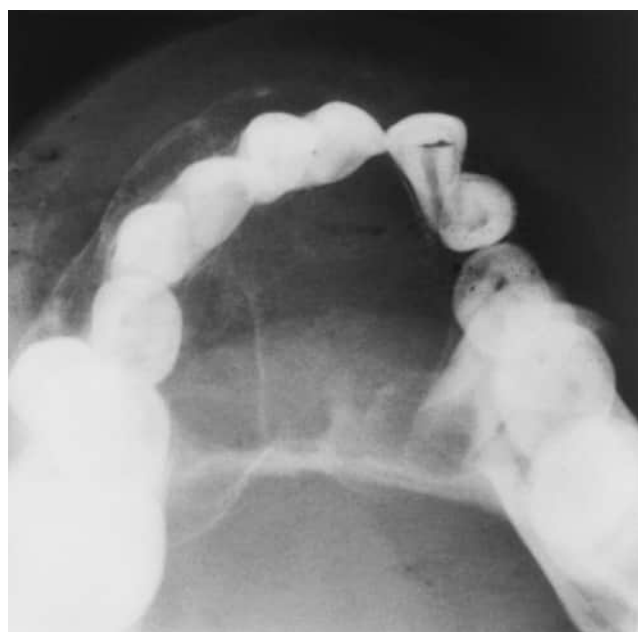### CENTRAL GIANT CELL GRANULOMA

First described in 1953 as giant cell reparative granuloma, the central giant cell granuloma (CGCG) of the jaws is a relatively uncommon benign lesion of bone. It occurs most commonly during the first 30 years of life, with more than 60% of lesions noted before 20 years of age and nearly 50% occurring in patients younger than 16 years of age. CGCG occurs more often in females than in males. It may be found in either jaw, but the mandible is involved twice as often as the maxilla. Although it was traditionally accepted that the majority of lesions occur anterior to the first permanent molar, a study of 80 cases of CGCG found that nearly 50% of cases occurred in the molar, ramus, and tuberosity regions.<sup>39</sup>

Most CGCG present as asymptomatic lesions that are first noted on routine radiographs or present as a painless expansion of the jaw. The lesion was originally reported as an indolent process that yielded readily to therapy, with the therapeutic procedure of choice being surgical curettage. It was subsequently reported that there is a range of biologic behavior of CGCGs, from indolent to aggressive, expansile lesions. Lesions in CGCG have since been classified as nonaggressive and aggressive based on their clinical presentation. Nonaggressive lesions have a slow, asymptomatic growth without perforation of the cortical plate of bone. Radiographically, nonaggressive lesions present as a unilocular radiolucency of bone. Features of aggressive lesions may include rapid growth, pain, expansion, and/or perforation of the cortical plate of bone with soft tissue extension. Aggressive lesions present radiographically as a multilocular, expansile lesion with displacement and impaction of teeth, root resorption, and cortical perforation. It has been suggested that younger age at presentation may be associated with more aggressive behavior (Fig. 5.20).<sup>40</sup>

The pathogenesis of CGCG of the jaws remains unknown, with lesions, as a group, exhibiting features of both reactive and neoplastic disease. There is also considerable discussion in the literature as to its relationship to giant cell tumor of bone. It has been suggested by several authors that CGCG and giant cell tumor of other bones represent a spectrum of a single disease process, with the differences in clinical behavior partially accounted for by differences in age distribution and by the site of occurrence, among other factors.<sup>41</sup>

While surgical curettage is the most commonly used therapy for CGCG, resection may be indicated in aggressive cases. Although alternative treatments to surgical curettage have been suggested, including injections of corticosteroid, calcitonin, and interferon (IFN- $\alpha$ ) as well as some others, a Cochrane review did not identify evidence from randomized controlled trials to support their use. The microscopic appearance of CGCG looks identical to several



**Fig. 5.20** Central giant cell granuloma involving the anterior mandible presenting radiographically as a multilocular, radiolucent lesion with expansion and thinning of the cortical plates. Notice also the faint trabeculation within the lesion.

other entities, including cherubism and a brown tumor of hyperparathyroidism. Although most cases of hyperparathyroidism occur in older individuals, all patients diagnosed with CGCG should be referred to their physician to rule out hyperparathyroidism.

### CHERUBISM

Cherubism is a rare developmental disorder of bone growth that is mentioned in this chapter because it has a microscopic appearance similar to that of a CGCG and is exclusively seen in children. Cherubism is inherited in an autosomal dominant manner, although there are cases of *de novo* mutations. A *de novo* mutation is one that occurs “from new” or for the first time in that patient. These patients will lack a family history of the disorder.

Cherubism develops in children under the age of 6 years as a painless expansion of the jaw in multiple quadrants. Mild cases may not be recognized until the child is 10–12 years of age. The mandible is most commonly affected, but maxillary involvement is not uncommon. In some patients, all four quadrants are involved. When the maxilla is involved, the expansion creates the characteristic “eyes tuned toward heaven” appearance that is reminiscent of the cherubs in Renaissance paintings and gives the disorder its name. Intraorally, there may be widening of the jaws with loss of the buccal sulcus. The teeth may be displaced with premature loss of the primary dentition and root resorption of the permanent teeth. The lesions may be associated with cervical lymphadenopathy. Radiographically, the lesions of cherubism present as multilocular radiolucencies, often described as having a soap-bubble appearance.<sup>42</sup>

The enlargement of the jaws usually stops by late childhood and the lesions may begin to regress as the child enters puberty. The lesions are often completely remodeled by age



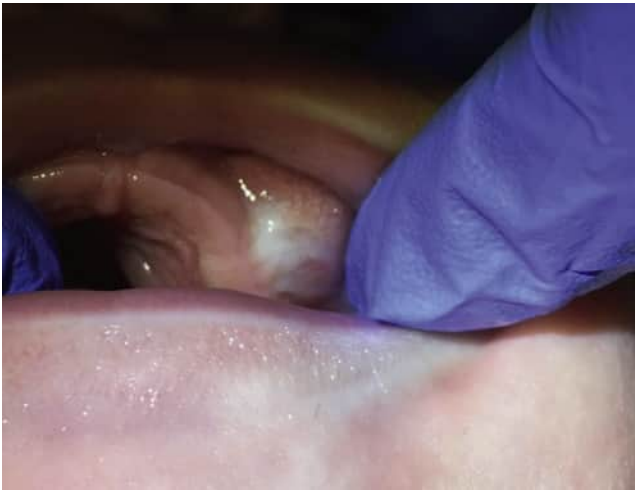

Fig. 5.21 Melanotic neuroectodermal tumor of the infancy in a 2-month-old baby.

40. Some lesions, unfortunately, persist into adulthood. Given the tendency of the lesions to regress on their own over time, treatment is generally conservative, with surgical recontouring performed only for residual cosmetic defects after the lesions have regressed. Surgery may be considered when there are functional or psychologic concerns.<sup>43</sup>

### MELANOTIC NEUROECTODERMAL TUMOR OF INFANCY

The melanotic neuroectodermal tumor of infancy (MNTI) is a rare tumor, but is mentioned here because it is nearly always seen in the oral region of children less than 1 year old (Figs. 5.21–5.23). In 90% cases, the tumor occurs in the head and neck and is slightly more common in males. The MNTI is a benign lesion thought to be of neural crest origin. Although benign, the lesion may exhibit aggressive behavior. The lesion is most commonly reported in the maxilla, accounting for nearly 90% of cases in a recently published review of the literature.<sup>44</sup> MNTI is reported in the mandible, but this accounts for less than 10% of cases. Rarely, the tumor has been reported in the skull, brain, and testes.

The MNTI generally presents as a painless, rapidly growing radiolucency of the anterior maxilla that displaces the primary teeth. The average age of patients presenting with MNTI is less than 6 months. The lesion is present at birth in as many as 10% of patients. Most cases are reported as a unilocular lesion, but MNTI can be multilocular. A majority of lesions perforate the cortical plate, creating a soft tissue component that appears as a rapidly expanding, bluish-black mass on the anterior palate or maxillary alveolar ridge.

Treatment of MNTI is primarily surgical. Curettage of the lesion alone is associated with a higher recurrence rate. Surgical enucleation or resection is considered the treatment of choice. The recurrence rate is approximately 20%.<sup>44,45</sup>

### ODONTOGENIC CYST

Odontogenic cysts are so named because they are considered to be derived from the epithelium that arose from the dental lamina during odontogenesis. They may be developmental

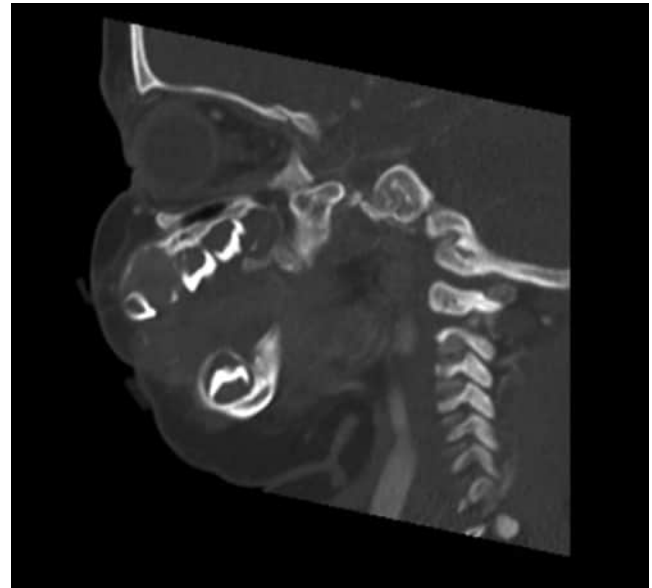

Fig. 5.22 Melanotic neuroectodermal tumor of the infancy in a 2-month-old baby (same patient Fig. 5.21). Computed tomography, sagittal view. Notice lesion on the anterior maxilla.

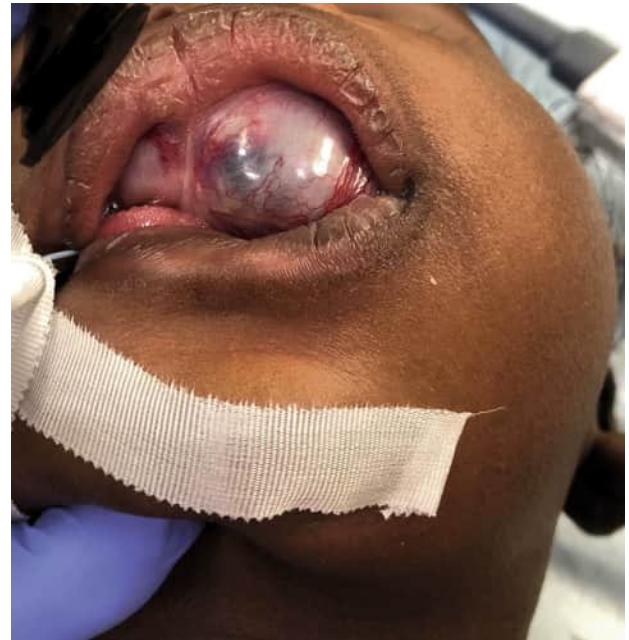

Fig. 5.23 Melanotic neuroectodermal tumor of the infancy in a 4-month-old baby. (Photo courtesy of Dr Tyler Mesa.)

or inflammatory in origin. Even though the pathogenesis of the developmental types of odontogenic cysts is not clearly understood, it is known that inflammatory cysts such as the periapical cyst (apical periodontal cyst, radicular cyst) result from proliferation of epithelial rests of Malassez secondary to inflammation from pulpal necrosis of an associated tooth.<sup>46–48</sup>

Because of their relative potential for occurrence in the pediatric dental population, four types of developmental odontogenic cysts—primordial cyst, dentigerous cyst, eruption cyst, and odontogenic keratocyst (OKC, aka keratocystic odontogenic tumor or KOT)—are discussed in this

chapter. OKC/KOT is also discussed in relation to the nevoid basal cell carcinoma syndrome (Gorlin syndrome).

### Primordial Cyst

Traditionally, primordial cyst was considered to be an uncommon type of odontogenic cyst, formed by cystic degeneration of the enamel organ (primordium) before the formation of enamel or dentin. Primordial cysts are usually asymptomatic and are most likely to be found on routine radiographic examination. Although they begin to evolve when the enamel organ is developing before the formation of the enamel or dentin, they may not be noticed or become clinically evident for many years.

Radiographically, the primordial cyst may be a well-circumscribed, unilocular or multilocular-appearing radiolucent lesion in a location where a permanent tooth failed to develop and where none has been extracted. Such cysts are more commonly found in the third molar region, but they may occur in any location where a permanent tooth would have formed.

Although more typically lined by non-keratinizing, stratified squamous odontogenic cyst-lining epithelium with a fibrous connective tissue wall, primordial cyst may present as a histologically distinct type of odontogenic cyst, the OKC. In one large case series, 60 of 135 (44.4%) primordial cysts were histologically OKCs.<sup>49</sup> Some authors have concluded that all primordial cysts are OKCs and use the two terms synonymously. However, if one takes into consideration that in the study cited here, in which greater than 55% of cysts that clinically and radiographically fit the traditional criteria for a primordial cyst were not histologically OKCs, the concept that the two terms are synonymous ignores the histologic evidence to the contrary.

Appropriate treatment for the primordial cyst is surgical removal unless an extremely large bone-destructive lesion is present, in which case cystotomy with placement of a polyethylene drain followed by cystectomy when the cyst has reached a manageable size is the treatment of choice. If the lesion is found histologically to be an OKC, the chance for recurrence is high (see later in this chapter).

### Radicular Cyst

Radicular cyst (RC) is the most common inflammatory cyst and arises from the epithelial residues in the periodontal ligament as a result of pulpal chronic inflammatory process. The majority of RCs are found at the apex of a non-vital tooth. In some cases, the location is lateral because of accessory canals. RC is usually asymptomatic unless an acute inflammatory process is present. The majority of RCs develop slowly. Over the years, RC may regress, remain static, or grow in size. RC constitutes about 17% of all the tissue specimens submitted to oral pathology for biopsy. RC is the most common odontogenic cyst. From the radiographic perspective, RCs are radiolucent, well defined, and well corticated (Fig. 5.24). In some cases, RC is associated with teeth displacement and root resorption. The choice of treatment is determined on the basis of different factors such as extension of the lesion, relation with anatomical structures, clinical characteristics of the lesion, age of the patient, and systemic compromised condition. Conservative treatment is an option and consists of root canal treatment. In large cases, the root canal treatment is not efficient;

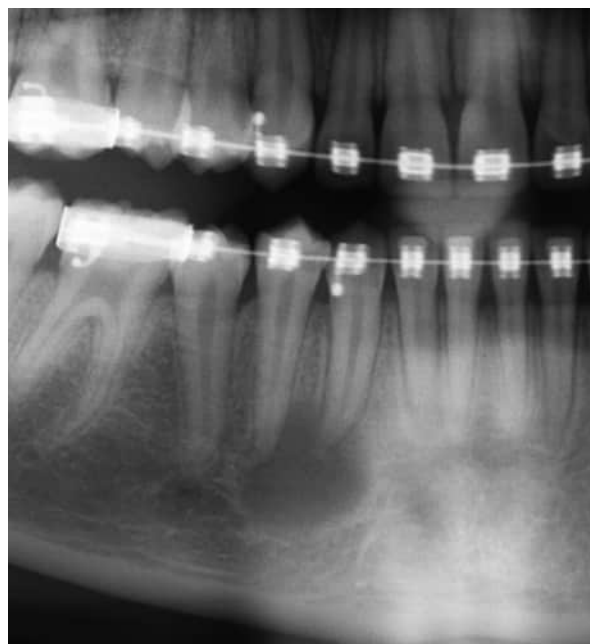


Fig. 5.24 Radicular cyst in an 18-year-old boy. Tooth #28: negative vitality.

surgical decompression or marsupialization are treatment options.<sup>2</sup>

### Buccal Bifurcation Cyst

Buccal bifurcation cyst (BBC) is an uncommon inflammatory odontogenic cyst that usually occurs at the buccal region of the first or second primary mandibular molars. Several names are used to describe this condition including the term juvenile paradental cyst. According to the World Health Organization, BBC is listed under the category of “paradental cyst” and named “mandibular infected buccal cyst.” BBC occurs in children between 5 and 13 years of age. The differential diagnosis of this lesion includes eosinophilic granuloma, lateral periodontal cyst, simple bone cyst, and periostitis ossificans. Usually, the clinical and radiographic features distinguish the BBC from other conditions. It commonly affects the second primary molar. Delayed tooth eruption and swelling at the affected area is commonly observed. In some cases, partial tooth eruption with crown buccal tilting and deep periodontal pockets is observed. Radiographically, the BBC is characterized by a well-defined radiolucent area, often corticated around the roots of the involved teeth (Fig. 5.25). Usually the lamina dura is not affected. Surgical excision of the lesion is the treatment of choice.<sup>50</sup>

### Dentigerous Cyst

Dentigerous cyst (Figs. 5.26–5.28), the most common type of odontogenic cyst, is found in association with the crown of an impacted, embedded, or otherwise unerupted tooth. The incidence of dentigerous cysts is reportedly 1.44 per 100 unerupted teeth.<sup>51,52</sup> Even though the dentigerous cyst is considered to be a developmental type of odontogenic cyst, it has been speculated that some may have an inflammatory origin from a source such as periapical inflammation from a nonvital deciduous tooth.<sup>53</sup> Typically, dentigerous cysts are asymptomatic and found on routine

radiographic examination, appearing as a well-defined unilocular or multilocular radiolucent lesion. The lesion may vary in size from one in which the differentiation from an enlarged dental follicle is somewhat arbitrary (a pericoronal radiolucency of 2.5 mm or greater from the crown of the tooth has been generally accepted as differentiating a dentigerous cyst from a dental follicle)<sup>48</sup> to a large, bone-destructive lesion that may resorb the roots of primary teeth, cause the divergence of or completely displace permanent teeth, and produce large areas of bone destruction in either the mandible or the maxilla.

In addition to its potential for bone destruction and because of the multipotential nature of this epithelium derived from the dental lamina, several entities may arise in or be associated with the wall of a dentigerous cyst. For example, 8.5% of cysts that clinically appear as dentigerous cysts have been found histologically to be OKC.<sup>49</sup> Although relatively uncommon in children and adolescents, it is believed that the majority of ameloblastomas in this age group are associated with dentigerous cysts, with 50% to 80% of cases of cystic ameloblastoma appearing radiographically as dentigerous cysts.<sup>54–56</sup> Based on histopathologic features, it has been concluded that these ameloblastomatous changes occurred in a preexisting cyst rather than representing cystic degeneration of a solid tumor.<sup>55</sup> Mucus-secreting cells and, more significantly, mucoepidermoid carcinoma may also arise in the wall of a dentigerous cyst.

The treatment of choice for dentigerous cysts is surgical removal. Large bone-destructive lesions, however, are

best treated initially by cystotomy and the placement of a polyethylene drain in the lesion, which facilitates shrinkage with healing around the periphery to the point where the lesion becomes amenable to more simple surgical removal. Because of the potential for occurrence of an OKC or the development of an ameloblastoma or, more rarely, mucoepidermoid carcinoma, all such lesions, when removed, should be submitted for histopathologic evaluation.

### Eruption Cyst or Eruption Hematoma

An eruption cyst or eruption hematoma is a type of dentigerous cyst associated with an erupting primary or permanent tooth in its soft tissue phase after erupting through bone. The lesion is usually a translucent, smooth, painless swelling over the erupting tooth. If bleeding occurs into the cystic space, it may appear blue to blue-black and is then called an *eruption hematoma*. In most cases, no treatment is indicated because the tooth usually erupts into the oral cavity undelayed and in a normal fashion.

### Odontogenic Keratocyst (Keratocystic Odontogenic Tumor)

The OKC is a distinct clinicopathologic entity with a clearly identifiable histologic appearance. Clinically, it is characterized by a high rate of recurrence after treatment and by the potential to become an aggressive, bone-destructive lesion. In a review of 312 cases, the peak incidence was found to be in the second and third decades of life, with 17% cases occurring before 20 years of age.<sup>49</sup> The mandible is involved twice as frequently as the maxilla, with the most common site of origin being the mandibular third molar region and ramus of the mandible, followed by the maxillary third molar region, mandibular first and second molar area, maxillary canine area, and mandibular premolar region. Half of the patients were symptomatic, with swelling and drainage being the most common clinical findings.

Radiographically, OKC may be a unilocular or multilocular lesion, almost always with a well-defined sclerotic border (Figs. 5.29–5.31). Tooth displacement, particularly of unerupted teeth, root resorption, root divergence, and extrusion of erupted teeth may be seen. Although radiographic evaluation typically includes a panoramic radiograph, in the case of large lesions, especially those in the maxilla, computed tomography studies should be performed preoperatively to accurately define margins and soft tissue extension that may be present.

The histologic appearance is pathognomonic. The lesion has a thin, generally uniform lining epithelium, usually

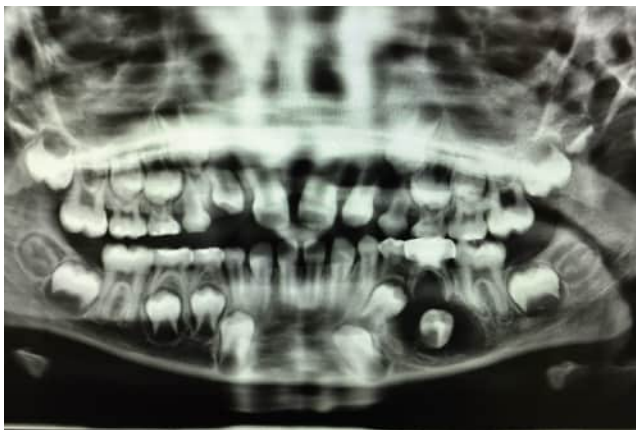


Fig. 5.25 Buccal bifurcation cyst. Notice the radiolucency around tooth #20 associated with displacement of tooth #21.

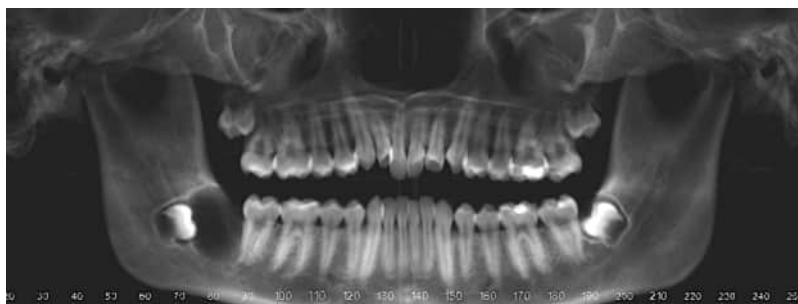


Fig. 5.26 CBCT reconstructed panoramic film. Dentigerous cyst associated with unerupted tooth #32.



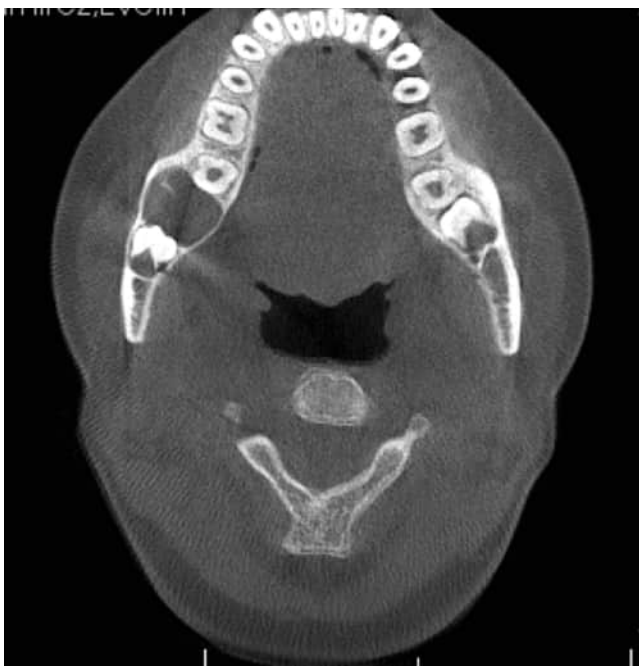

Fig. 5.27 CBCT, axial view (Fig. 5.26). Note the moderate expansion buccal-lingual.

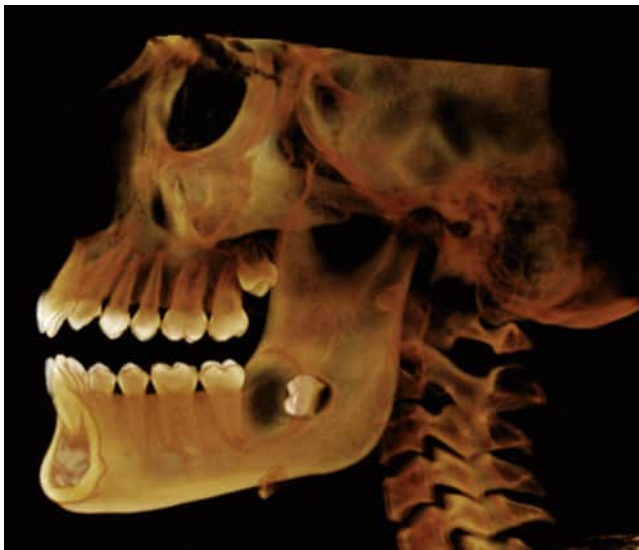

Fig. 5.28 CBCT, 3D reconstruction, lingual view (same patient Fig. 5.26).

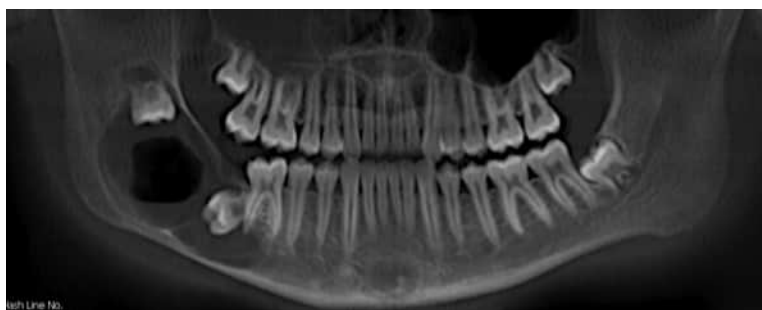

Fig. 5.29 CBCT reconstructed panoramic film. Odontogenic keratocyst associated with unerupted tooth #31 and 32.

6–10 cells thick, with palisading and hyperchromasia of the basal layer of cells and a corrugated parakeratin layer. Often parakeratotic squames are shed into the lumen of the cyst cavity.

Occasionally, a cyst is lined by orthokeratin with a sub-jacent granular cell layer. These cysts have been termed *orthokeratinized odontogenic cysts* and should be differentiated clinically from OKC because orthokeratinized odontogenic cysts show little clinical aggressiveness and rarely recur.<sup>57</sup>

There is no uniform agreement as to the most appropriate method of treatment of OKCs. Recommendations vary from enucleation, with or without adjunctive therapy such as application of Carnoy solution, to marsupialization or decompression, to marginal or segmental resection. This is partly because of their variable clinical presentation, which includes differences in size and the multilocular nature of many OKCs, and partly because of their benign nature coupled with the high frequency of recurrence. A review of 22 reports citing 1592 cases of OKCs revealed a recurrence rate varying from 3% to 62% and an average rate of recurrence of 30.8%.<sup>58</sup> Moreover, 70% recurrences have been shown to occur within 5 years of treatment.<sup>46,47</sup> Although these lesions should be surgically excised, enucleation is difficult because the cyst lining is often extremely thin and friable, and disruption of the epithelial lining in the resected specimen may be a primary determinant of recurrence.<sup>59</sup> OKCs that are completely enucleated recur significantly less often than those removed piecemeal.<sup>60</sup> Enucleation followed by the application of Carnoy solution and decompression followed by enucleation have been associated with low recurrence rates and resulted in significantly less morbidity than resection.<sup>61</sup> Alternatively, the radiograph in Fig. 5.32A and B shows a large OKC in which decompression was performed with placement of a polyethylene drain, followed by cystectomy as the lesion became more surgically manageable.

Therefore, as pointed out in a recent systematic review of the recurrence rate for OKCs as related to treatment modalities, there is currently no high-quality evidence available to evaluate recurrence rates relative to treatment types, leaving the most optimal treatment type in doubt.<sup>62</sup>

Patients with documented or suspected nevoid basal cell carcinoma syndrome have a higher rate of recurrence than patients without the syndrome.<sup>63</sup>

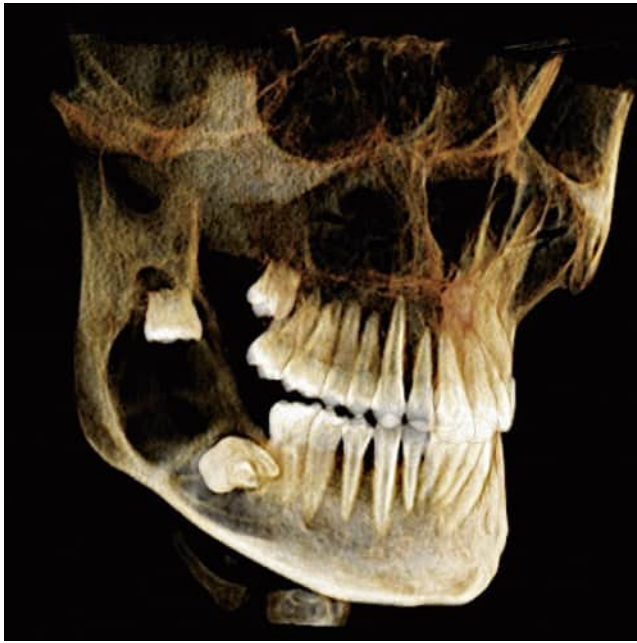

Fig. 5.30 CBCT, 3D reconstruction (same patient Fig. 5.29).

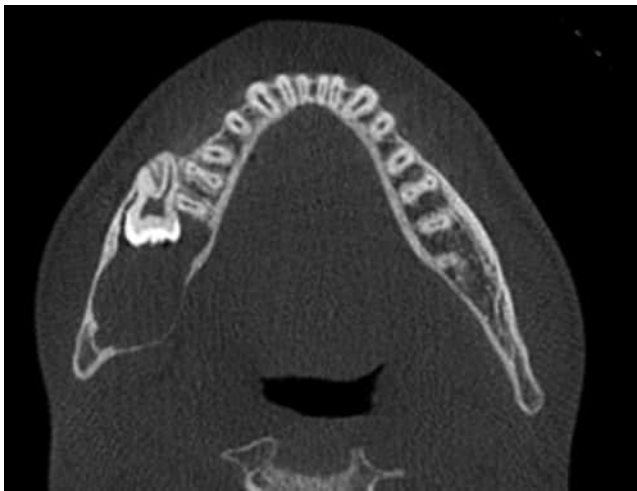

Fig. 5.31 CBCT, axial view (same patient Fig. 5.29). Notice displacement of tooth #31.

### Nevoid Basal Carcinoma (Gorlin) Syndrome

Nevoid basal carcinoma syndrome is a trait with autosomal dominant inheritance with complete penetrance and remarkably variable expressivity.<sup>64</sup> It is caused by a mutation of the patched (*PTCH1*) gene, which is thought to be crucial for proper embryonic development and tumor suppression. Traditionally characterized by a symptom complex of multiple basal cell carcinomas of the skin, OKCs (Fig. 5.33), and rib abnormalities (bifid, fused, or splayed ribs), various other abnormalities may accompany this disorder. Patients may have characteristic facies with cranial enlargement, frontal and parietal bossing with overdevelopment of the supraorbital ridges, hypertelorism, and a broad nasal root and mild mandibular prognathism. Calcification of the falx cerebri (Fig. 5.34) is evident radiographically in the majority of adult patients. In addition to the basal

cell carcinomas, palmar and plantar pits and epidermal cysts of the skin are commonly seen. Congenital malformations such as cleft lip and cleft palate and polydactyly or syndactyly may be present. Spina bifida occulta of the cervical or thoracic vertebrae may occur, and marfanoid habitus may be seen. A variety of benign and malignant neoplasms have been reported to occur, including medulloblastoma, meningioma, ovarian fibroma, and fetal rhabdomyoma.<sup>65</sup> Neurologic abnormalities, including cognitive disabilities, may be noted, and some patients may be hyporesponsive to parathyroid hormone. Because of the association of the OKC with the basal cell nevus syndrome, all patients with single or multiple OKCs should be evaluated medically with this condition in mind. This is especially true when an OKC is found in a young patient because the median age of appearance is younger in syndromic than in nonsyndromic patients.<sup>64</sup> Also, as previously stated, there is an apparent increase in the rate of recurrence of OKCs in patients with the syndrome.

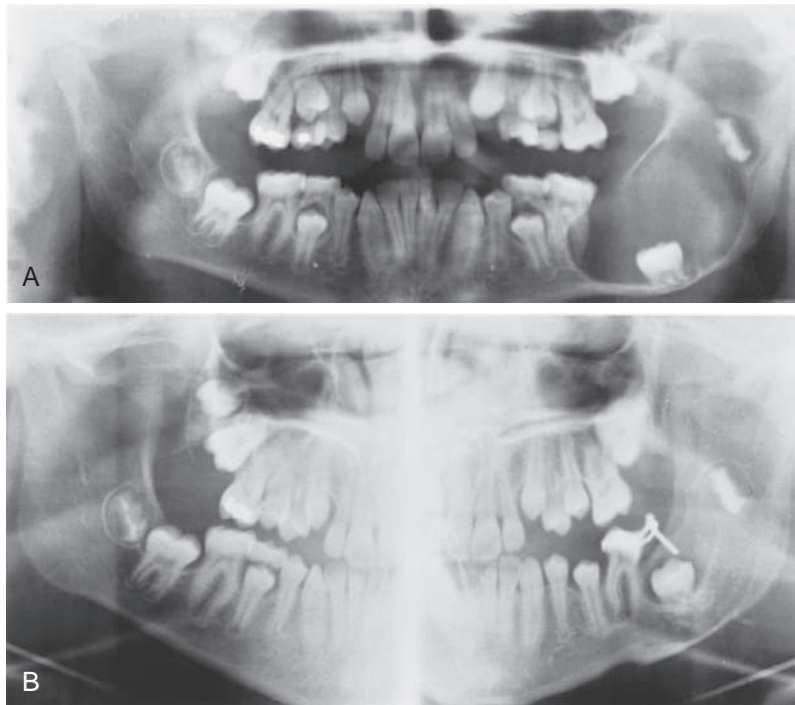
### ODONTOGENIC TUMORS

The odontogenic tumors are so named because of their presumed origin from the tissues derived from the developing odontogenic elements—that is, epithelium ultimately derived developmentally from the dental lamina and/or ectomesenchymally derived mesenchymal cells. The word tumor is used in its broadest sense here, which includes neoplastic and hamartomatous processes.

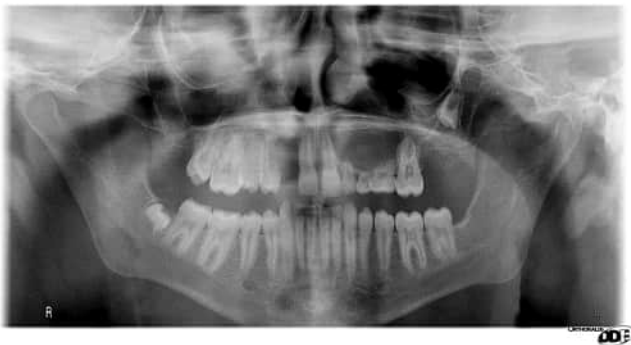#### Ameloblastoma

Ameloblastoma, the most common odontogenic neoplasm, is an aggressive, benign odontogenic neoplasm of ectodermal origin. Usually an asymptomatic lesion, its initial presentation may be facial swelling. It may present with symptoms of pain and occasionally with lip/facial numbness. Ameloblastoma may be discovered on routine radiographic evaluation or may show features such as bony expansion, mobility, or divergence of teeth. The average age of patients with ameloblastoma is approximately 36 years, with more than 80% of the lesions occurring in the mandible and more than 70% occurring in the molar-ramus area.

At first glance, with the average age of occurrence of ameloblastomas in the fourth decade of life, the discussion of this entity in a pediatric context would not appear to be particularly relevant to this chapter. In 1977, however, the unicystic ameloblastoma was described, which was thought to be a prognostically distinct entity.<sup>65</sup> In the 20 patients studied, the average age was 21 years, with half of patients being younger than 20 years. Clinically and radiographically, the lesions were described as having the features of a non-neoplastic cyst, with the majority mimicking dentigerous cysts. A critical review of 193 cases of unicystic ameloblastoma in the literature found that the mean age during the diagnosis of unicystic ameloblastoma was most closely related to one clinical feature—the presence of an impacted tooth. Cases associated with an impacted tooth have been termed the dentigerous type and those not associated with an impacted tooth have been termed the non-dentigerous type. The mean age at diagnosis of the dentigerous variant was 16.5 years, whereas that of the nondentigerous type was 35.2 years.<sup>66</sup> A review of the literature of ameloblastoma in children in Western societies from 1970, when the histologic criteria for ameloblastoma were well defined,<sup>67</sup> through



**Fig. 5.32** (A) An odontogenic keratocyst in a 9-year-old girl involving the angle and ramus of the left mandible with displacement of the developing second and third molar teeth. (Courtesy Dr. Steven Reubel.) (B) Same patient, 9 months after marsupialization and placement of a drain. Notice the shrinkage of the cyst with bone fill in the area. Notice also inferior displacement of the inferior alveolar nerve. (Courtesy Dr. Steven Reubel.)



**Fig. 5.33** A 16-year-old boy with multiple odontogenic keratocysts.

2001 revealed the average age of occurrence to be 14.3 years.<sup>68</sup> There is a strong predilection for mandibular involvement, particularly in the molar-ramus region.<sup>68–70</sup> Interestingly, when literature from Africa was reviewed, the average ages (i.e., 14.7 years) were essentially identical to those in Western countries; however, unicystic ameloblastoma accounted for only 19.5% of cases, and there was an increased frequency of occurrence in the mandibular symphysis (44.2%). A similar trend has been reported in children and adolescents in one report from China; the average age of occurrence (14.8 years) was again essentially identical, with a strong predilection for occurrence in the mandible (96.6%), and historically, the solid type predominated over the unicystic type (63% versus 37%).<sup>71</sup>

Radiographically, ameloblastomas may present as either unilocular or multilocular radiolucent lesions, with or without bony expansion (Fig. 5.35). Cystic-appearing spaces may be compartmentalized by separate, distinct septa of bone. Unicystic ameloblastoma occurs almost exclusively in the mandible, predominantly in the posterior part.

Although most commonly found in association with the crowns of impacted teeth, unicystic ameloblastomas may be seen in interradicular, periapical, or edentulous regions.

Histologically, they are distinguished by their resemblance to the enamel organ. Regardless of age or location, ameloblastomas demonstrate a variety of distinct histologic patterns singly or in combination. They are frequently characterized by discrete islands of neoplastic odontogenic epithelium with a peripheral layer of columnar to cuboidal epithelial cells that are palisaded in their appearance, with polarization of the nuclei away from the basement membrane. The central portions of these islands of neoplastic odontogenic epithelium are composed of cells that resemble the stellate reticulum. In some lesions, these central areas may take on an acanthomatous or granular appearance. The plexiform pattern is most frequently encountered in the pediatric age group, with arrangement of tumor cells as a network of interconnecting strands of cells. An important histologic finding in the unicystic form, other than the observation of ameloblastic change in the cyst lining itself, is the presence of a significant luminal and/or mural component characterized by a proliferation of ameloblastic odontogenic epithelium into the lumen of the cyst, the fibrous cyst wall, or both. Mural invasion of the cyst wall portends a higher risk of recurrence for this lesion.

Therapy is by surgical removal, the method of which varies according to the location and clinical and radiographic extent of the lesion. Although a recurrence rate of 55% to 90% has been found for ameloblastomas of all types that have been treated by curettage, the cystic form, the type found most commonly in children, potentially carried a lower potential for recurrence.<sup>56,69</sup> More recent studies, however, have shown significant potential for recurrence



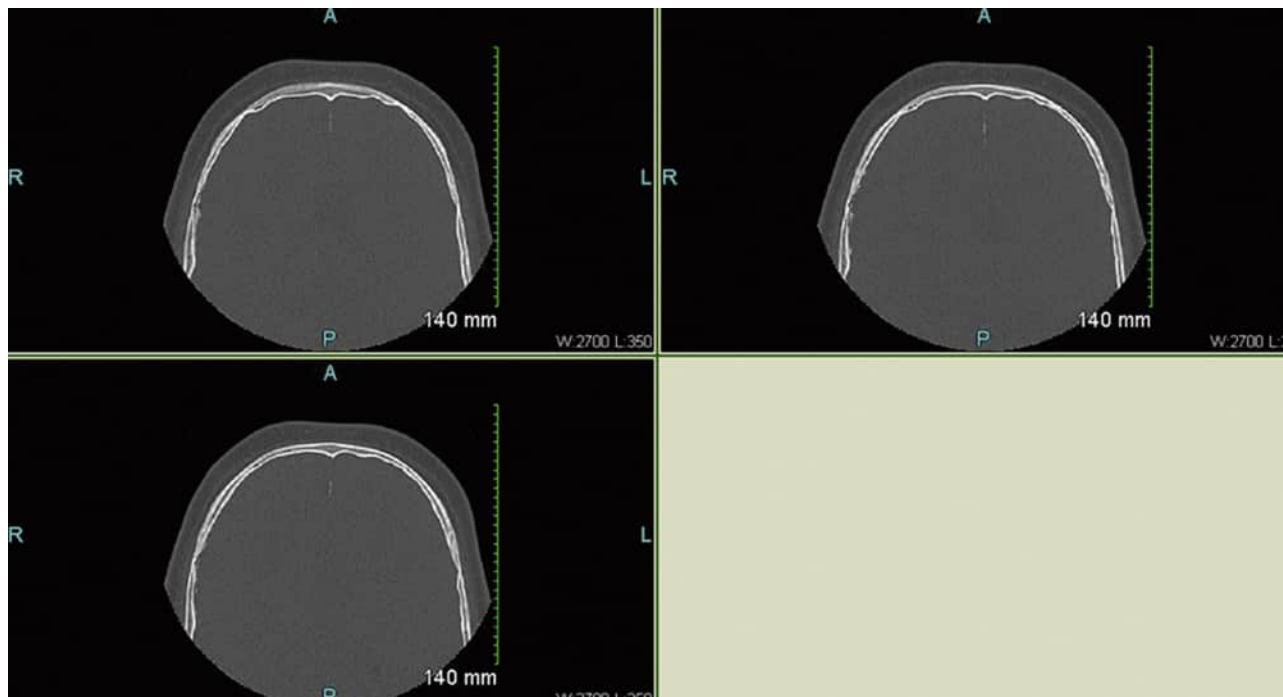


Fig. 5.34 CBCT, axial view (same patient Fig. 5.33). Calcification of the falx cerebri.

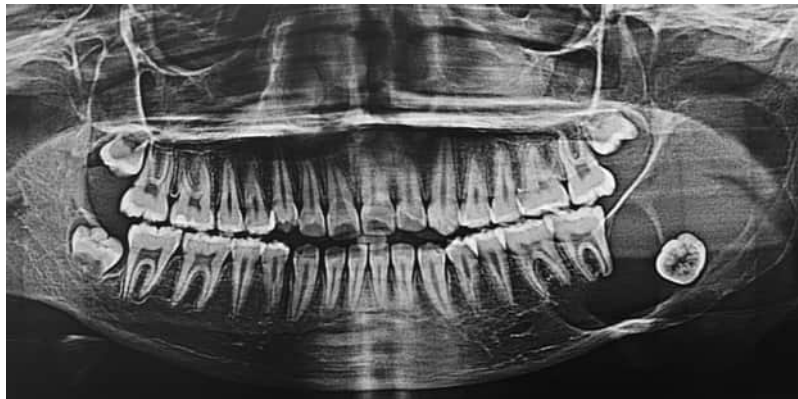

Fig. 5.35 A 16-year-old girl. Mild pain and swelling over the left mandible. Ameloblastoma left mandible. Notice severe displacement of tooth #17.

after conservative treatment, not dissimilar to that of conventional ameloblastoma, with the recommendation being made for more aggressive therapy than has been recommended in the past.<sup>72</sup>

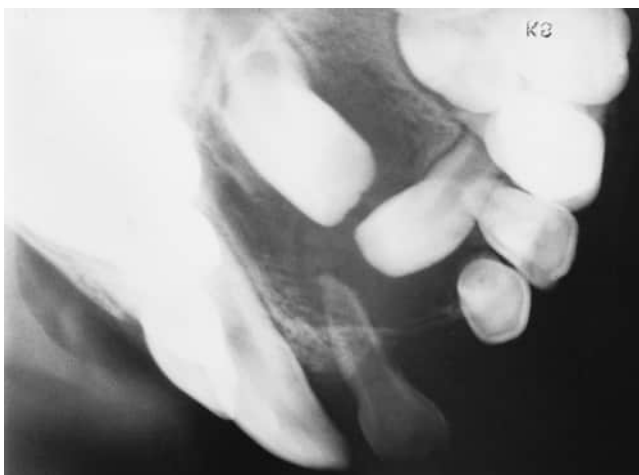### Adenomatoid Odontogenic Tumor

Adenomatoid odontogenic tumor (AOT) is a benign, probably hamartomatous, epithelial tumor that occurs in two intraosseous forms (follicular and extrafollicular) as well as a peripheral variant. It is also known as adenoameloblastoma, which is misleading because it behaves clinically in a distinctly different manner than ameloblastoma.

Several large clinical and epidemiologic reviews of AOT have been reported.<sup>73–75</sup> AOT can be subclassified into three variants based on clinical and radiologic findings. Two of these are central or intraosseous variants. The first is the follicular (dentigerous) type, in which the tumor is found in association with the crown of an impacted tooth, with the

most likely provisional diagnosis being that of a dentigerous cyst. The second and less commonly reported intraosseous variant is the extrafollicular type, in which there is no association with the crown of an impacted tooth, with the most likely provisional diagnosis being that of a residual, radicular, globulomaxillary, or lateral periodontal cyst depending upon its location. The third variant is the peripheral or extraosseous variant, which may appear clinically as a fibroma. Approximately 98% of AOTs are reported as being the intrabony or central type, with the follicular variant accounting for 71%. Although most often asymptomatic, the tumor frequently causes a painless swelling exhibiting slow but progressive growth.

AOTs occur most commonly in the second decade of life. Nearly 70% of patients are younger than 20 years of age, and more than 50% of cases occur in the teenage years. Females are involved twice as often as males, and the intraosseous lesions have been noted to occur nearly



**Fig. 5.36** Adenomatoid odontogenic tumor in a 12-year-old girl presenting as an expansile radiolucent lesion in the right maxilla associated with the lateral incisor. The lesion was curetted, and the lateral incisor was allowed to erupt and was orthodontically moved into proper alignment. (Courtesy Dr. Dan J. Crocker.)

twice as frequently in the maxilla as in the mandible, with a noticeable predilection for occurrence in the canine and incisor regions. The rare peripheral type is found almost entirely in the anterior maxillary region. While it presents as a peripheral lesion, there has been agreement from the beginning that it is an erupted AOT, forming when an associated tooth erupts into the gingiva, allowing for its soft tissue presentation.<sup>76,77</sup>

The most common radiographic finding is that of a unilocular radiolucent lesion, which, as previously stated, may appear radiographically as a dentigerous cyst (Fig. 5.36) or as a residual, radicular, globulomaxillary, or lateral periodontal cyst depending on its location. Radiopacities of varying size and density are often present. Because these are space-occupying lesions, divergence of roots and displacement of teeth may be noted.

Histologically, AOT is composed of neoplastic odontogenic epithelium with a distinct histologic appearance: an encapsulated proliferation of swirling strands of spindle-shaped or polygonal epithelial cells within which are nodules of duct like or rosette-like structures composed of a row of definite cuboidal to columnar epithelial cells; these may be empty or may contain variable amounts of an amorphous eosinophilic material, which may become calcified in some areas.

Because these lesions are, in almost all cases, well encapsulated and show an identical benign biologic behavior, conservative surgical enucleation and curettage is the treatment of choice. There is no propensity for recurrence.

### Odontogenic Myxoma

Odontogenic myxoma is an uncommon benign mesodermal neoplasm of the jaws, which is thought to arise from odontogenic ectomesenchyme or undifferentiated mesenchymal cells in the periodontal ligament. In one large review,<sup>78</sup> two-third cases involved the mandible and one-third involved the maxilla, with the molar and premolar region being the most common site of occurrence. Although the majority of cases were diagnosed in the second to fourth decades of life, 33% of the cases were in patients aged 20 years or younger

(7% in patients younger than 10 years and 26% in the second decade of life).

Clinically, odontogenic myxomas are usually painless, slow-growing lesions that can attain considerable size before manifesting noticeable signs and symptoms such as swelling or mobility and divergence of teeth. Several cases have been reported as occurring in association with impacted or missing teeth, whereas some cases have been noted to occur in non-tooth-bearing areas, such as the ramus and condyle.

Radiographically, odontogenic myxomas may be unilocular or multilocular lesions that may cause expansion, thinning, and destruction of the cortical plates of bone and displacement of teeth. Multilocular lesions often exhibit a mottled, soap-bubble, or honeycomb appearance. There is no universal agreement regarding the relative frequency of presentation as a unilocular versus a multilocular radiographic appearance. In an analysis of 10 cases of odontogenic myxoma in childhood, the most frequent radiographic finding was a unilocular lesion with cortical expansion and tooth displacement.<sup>78</sup> In a review of cases from all age groups, a multilocular appearance was noted in 55% of cases, with a significant correlation between the size of the lesion and its locularity being noted.<sup>78</sup> Perhaps the frequency of unilocular lesions in pediatric cases can be accounted for based on a smaller lesional size in childhood cases, with larger lesions more likely being multilocular.<sup>78</sup> Because of the variable nature of the radiographic appearance of odontogenic myxomas, the differential diagnosis should include odontogenic lesions such as dentigerous cyst, OKC, and ameloblastoma, as well as nonodontogenic lesions such as CGCG, central hemangioma, traumatic bone cyst, and aneurysmal bone cyst.

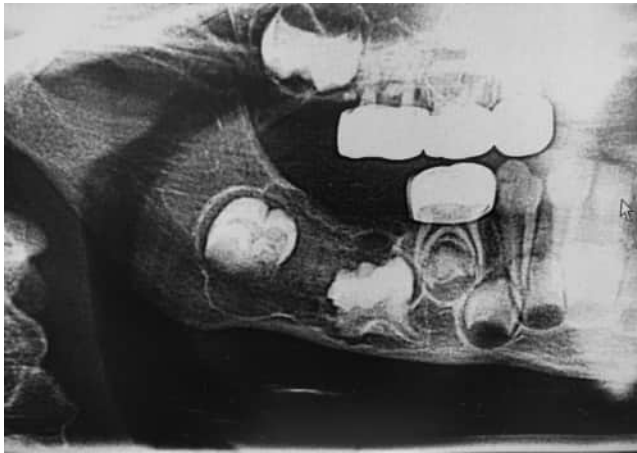
Histologically, odontogenic myxoma is made up of stellate to spindle-shaped cells with delicate fibrillar interlacing processes, which produce a loose myxoid appearance. Occasional nests of inactive odontogenic epithelium may be noted, interspersed within this fibromyxoid stroma.

A potentially major diagnostic pitfall lies in the fact that the dental papilla from a developing tooth appears nearly identical histologically to the stroma of an odontogenic myxoma, and the two can be confused, causing misdiagnosis. One distinguishing characteristic is the presence of the peripheral layer of odontoblasts in the dental papilla, if visible in the tissue sections available on the slide.

The appropriate treatment for odontogenic myxoma is still a matter of debate and is certainly dependent on its size and location. The preferred treatment is complete surgical excision, which may prove difficult because of infiltration and expansion of the tumor into bone and the absence of a true capsule. Treatment is complicated by the understandable reluctance to perform wide surgical excision of a benign lesion, especially in a child. Periodic follow-up to check for recurrence is important. In the series of 10 cases of childhood odontogenic myxoma previously discussed, two patients experienced recurrence within the first year after surgery.<sup>79</sup>

### Ameloblastic Fibroma

Ameloblastic fibroma is a true mixed neoplasm of odontogenic origin characterized by the proliferation of both odontogenic epithelium and mesenchymal tissue without



**Fig. 5.37** Ameloblastic fibroma in a 5-year-old boy. Notice displacement of tooth #30 and tooth #T.

the formation of enamel or dentin. It is generally believed to be less aggressive than ameloblastoma. In a review of the largest series of cases to date, the average age of occurrence was shown to be 15.9 years, with a male-to-female ratio of 1.26:1.<sup>80,81</sup>

The lesion occurs in the mandible in approximately 75% of cases, with a predilection for the mandibular second primary molar or second premolar-first molar region. Its initial clinical presentation is most often swelling; however, it is not uncommonly asymptomatic and found on routine radiographic examination. Radiographically, it may be a unilocular or multilocular radiolucent lesion, usually with well-defined, often sclerotic borders, and may be found in association with unerupted or displaced teeth (Fig. 5.37).

Ameloblastic fibroma has a characteristic histologic appearance, with strands of cuboidal to columnar epithelial cells and islands with peripheral columnar epithelial cells surrounding loosely arranged epithelial cells resembling stellate reticulum, which proliferate along with a primitive-appearing mesenchymal component that resembles the developing dental papilla.

There is a rare peripheral ameloblastic fibroma.<sup>82</sup> Also, malignant transformation of ameloblastic fibroma into ameloblastic fibrosarcoma has been reported and reviewed.<sup>83</sup>

Treatment is by surgical removal that is complete but conservative compared with that advocated for ameloblastoma. At one time, simple surgical excision was advocated because there was believed to be little chance for recurrence. Recent evidence, however, indicates that the recurrence rate is higher than originally suspected. In a recent review of published studies with well-documented follow-up data, an overall recurrence rate of 33.3% was noted.<sup>83</sup> Hence, somewhat more aggressive surgical therapy with long-term clinical follow-up is indicated than was previously recommended.

### Ameloblastic Fibro-Odontoma

Ameloblastic fibro-odontoma (AFO) has been defined as "a lesion similar to ameloblastic fibroma, but also showing inductive changes that lead to the formation of both dentin and enamel."<sup>84</sup> It should be stressed, however, that they are separate tumors and that ameloblastic fibromas do not develop into AFOs or that the latter will arise in the

former.<sup>85</sup> The average age of occurrence has been reported as 9.4 years, with the majority of cases occurring in the mandible (59.5%).<sup>86</sup> Although typically described as a painless, slow-growing, and expanding lesion, it can show rapid growth.<sup>86</sup> It most often presents radiographically as a well-circumscribed, unilocular, mixed-density, radiolucent-radiopaque lesion associated with displaced or unerupted teeth, the clinical manifestations of which commonly lead to its diagnosis.<sup>84,86</sup> Size may vary from lesions evident only microscopically to a large mass of up to 6 cm or more in its greatest dimension.

Histologically, the epithelial and mesenchymal components are those of an ameloblastic fibroma, with the formation of osteodentin or dentin-like material and enamel matrix.

While it is generally agreed that AFO is a hamartomatous lesion that is a stage preceding the development of a complex odontoma,<sup>84,86,87</sup> it has been argued that AFO should be classified as a neoplasm from a purely clinical standpoint. This is because of, among other reasons, its potential for continued and even rapid growth with potential for local destruction, as well as the fact that malignant transformation of an AFO to an ameloblastic fibro-odontosarcoma has been reported.<sup>86</sup> While the overall biologic behavior of AFOs has been shown over time to be fairly innocuous, the largest review to date has shown a recurrence rate of 7.4%, with these recurrences attributed to inadequate surgical removal at the time of the initial treatment.<sup>86</sup> Hence, conservative surgical removal with extraction of associated teeth has been recommended.

### Odontoma

Odontomas are mixed odontogenic tumors in which both the epithelial and mesenchymal components have undergone functional differentiation to the point that both enamel and dentin are formed. Odontomas, the most common of the odontogenic tumors, are believed to be hamartomatous rather than neoplastic. WHO has classified odontomas into two types depending on their degree of morphodifferentiation. The *compound odontoma* (Fig. 5.38) is a lesion in which all the dental tissues are represented in an orderly fashion so that there is at least superficial anatomic resemblance to teeth. In a *complex odontoma* (Fig. 5.39), on the other hand, although all the dental tissues are represented, they are formed in such a rudimentary fashion that there is little or no morphologic similarity to normal tooth formation.

A review of 149 cases indicated that compound odontomas have a propensity for occurrence in the canine and incisor region, being found more often in the maxilla than in the mandible, whereas complex odontomas show a predilection for occurrence in the posterior jaws.<sup>88</sup> Compound odontomas have been reported as having a mean age of occurrence of 14.8 years compared with 20.3 years for complex odontomas, possibly because the odontogenic tissue in the anterior jaws, where the compound odontoma predominantly occurs, has finished its differentiation earlier than tissues in the posterior part of the jaw.<sup>87</sup>

It has been argued that, because the radiographic and histologic distinction between the compound and complex odontomas is poorly defined and because no appreciable clinical difference separates them, differentiation between these two types cannot be justified given the obliquity of the



diagnostic criteria.<sup>89</sup> Others take exception to this concept, holding the view that complex and compound odontomas are pathogenetically different.<sup>84</sup> Those who take exception argue that complex odontomas are the terminal stage in the series of hamartomatous lesions (termed the developing complex odontoma line), including ameloblastic fibrodentinoma, AFO, and the hamartomatous type of ameloblastic fibroma. They also argue that ameloblastic fibromas occurring after the age of 20 years represent a benign neoplasm, whereas those occurring during childhood (i.e., during the tooth development period) are likely to be non-neoplastic hamartomatous lesions. They believe that compound odontoma represents a malformation with a high degree of histomorphologic differentiation, similar to the process producing supernumerary teeth, “multiple schizodontia,” or locally conditioned hyperactivity of the dental lamina.

Although odontomas are usually asymptomatic, they may be the cause of noneruption or impaction of teeth and retained primary teeth. In one study, for instance, odontomas were found to be in association with an unerupted

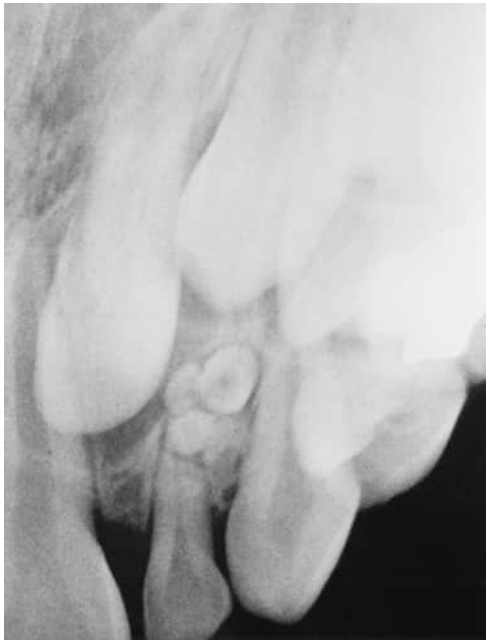

Fig. 5.38 Compound odontoma.

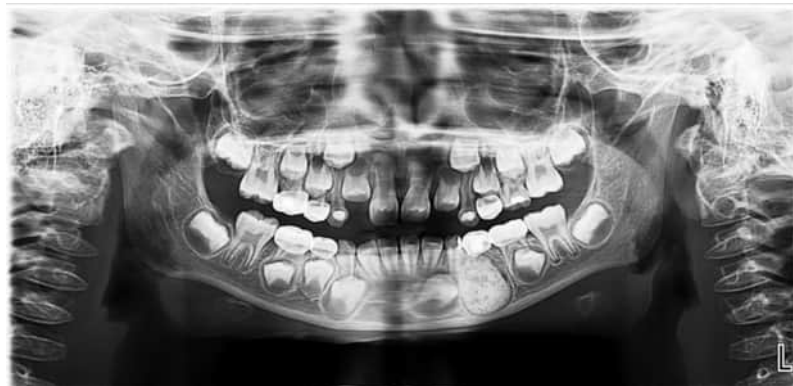

Fig. 5.39 Complex odontoma.

tooth in 48% of cases and in conjunction with a dentigerous cyst in 28% of cases.<sup>89</sup>

Odontomas are most commonly found on routine radiographic examination, presenting as an irregular radiopaque mass or as small, tooth like structures, with the most frequent presenting symptom being lack of eruption of a permanent tooth or bony expansion or swelling. The recommended treatment for an odontoma is conservative surgical excision, with care taken to remove the surrounding soft tissue. No propensity for recurrence has been noted.

Finally, the occurrence of the albeit rare ameloblastic odontoma (odontoameloblastoma) should be mentioned. These are reported to occur in an age range similar to that of standard odontomas, with the location, clinically aggressive growth, and recurrence rate seen for conventional ameloblastomas.<sup>89</sup>

## Malignant Tumors

### FIBROBLASTIC TUMORS AND FIBROSARCOMA IN INFANCY AND CHILDHOOD

#### Desmoid-Type Fibromatosis

Desmoid-type fibromatosis (DF), also known as aggressive fibromatosis or desmoid tumors, are fibroblastic-myofibroblastic tumors of intermediate prognosis that are locally aggressive in behavior with a tendency for recurrence; although they do not metastasize, they can kill by local infiltration and extension into vital structures. The head and neck region has been reported as a common site of involvement for these lesions, with DFs occurring there known as fibromatosis, extra-abdominal fibromatoses, or extra-abdominal desmoid tumors. They most commonly present as a painless mass involving the cheek, tongue, or submandibular region, with erosion of bone being a frequent finding in lesions arising in soft tissue adjacent to the jaws.<sup>91</sup> In one large study of DF occurring in the oral and paraoral region, 74% of cases occurred in the first decade of life.<sup>86,90</sup>

Histologically, DF is characterized by a proliferation of spindle-shaped or oval bland and uniform cells that are arranged in streaming fascicles with varying amounts of collagen. Cellular pleomorphism and nuclear hyperchromatism are not noted, and mitoses are essentially absent. Immunostaining confirms their fibroblastic-myofibroblastic nature.

When DFs occur in bone, they are still termed desmoplastic fibromas or aggressive fibromatosis, with the mandible being the most common site of involvement.<sup>91</sup> Microscopically, there is nothing to differentiate desmoplastic fibroma of bone from DF occurring in the soft tissues. The radiographic findings are variable, ranging from unilocular to multilocular with ill-defined to well-demarcated borders. Whereas magnetic resonance imaging may be valuable in surgical planning, computed tomography is best for demonstrating perforation of the cortical plate.<sup>91</sup> Because of the locally aggressive nature of DF, complete surgical excision with a generous margin of normal tissue has been reported as the treatment of choice, with recurrence being dependent on the adequacy of initial treatment.

Relative to treatment of DF occurring in the soft tissues, aggressive surgery has traditionally been the mainstay of therapy, with procedures producing significant loss of function and morbidity without being curative in many cases.<sup>92</sup> This is reported to have led to more recent strategies that have included various systemic therapies and even a “wait and see” strategy following clinical and radiological assessment.<sup>92</sup>

### Fibrosarcoma

Fibrosarcoma is a malignant neoplasm of fibroblastic and myofibroblastic differentiation. Congenital and infantile fibrosarcoma (IFS) is a relatively rare tumor that usually manifests in the first year of life, especially in the first 3 months, and almost always before 4 years of age.<sup>93</sup> Compared with DF, it is generally more cellular in appearance, with increased mitotic activity, and radiographically, it may be more destructively expansile.<sup>93</sup> As with DF, IFS is classified among soft part tumors of intermediate prognosis.<sup>92</sup> It rarely metastasizes and has a very good prognosis. While surgery has been the traditional mainstay of treatment for IFS, currently, after initial biopsy, neoadjuvant chemotherapy is used, after which delayed conservative resection may be performed. If complete remission is noted following chemotherapy, then the patient may be spared surgery.<sup>94</sup> Due to the young age of the patients, radiation is not an option.<sup>92</sup>

### RHABDOMYOSARCOMA

Rhabdomyosarcoma (RMS) is a malignant neoplasm derived from primitive mesenchymal tissue destined to form striated skeletal muscle.<sup>95,96</sup> It is the most common soft tissue sarcoma in children, accounting for more than half of all such lesions occurring in childhood. It is one of the small, round, blue-cell tumors of childhood, which include neoplasms such as neuroblastoma, Ewing's sarcoma, and lymphoma.<sup>95</sup> There are two key age ranges for the occurrence of RMS in children—from 2 to 6 years of age and in adolescence—with the early peak primarily due to occurrences in the head and neck region and genitourinary tract and the peak during adolescence due to tumors of the testes and adjacent structures.<sup>97</sup>

Three general histologic subtypes of RMS are recognized: embryonal and its botryoid variant, alveolar, and pleomorphic. The embryonal subtype accounts for most cases of RMS in infancy and childhood.<sup>95</sup> The most common clinical finding is a mass occurring in any region of the head and

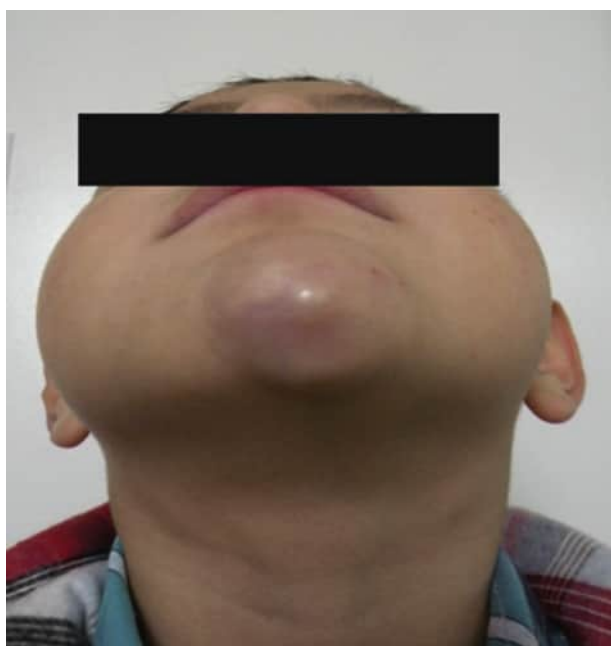neck where striated muscle or its mesenchymal progenitor cells exist. There are three primary sites of involvement for RMS in the head and neck in children: the eyelid and orbit, parameningeal sites, and remaining head and neck sites, including the oral cavity.<sup>98</sup> The parameningeal sites include the pterygopalatine and infratemporal fossas, nasal cavity, nasopharynx, paranasal sinuses, and middle ear and mastoid. Although there is not good consensus about site predilection within the oral cavity, the soft palate and tonsillar region, tongue, and cheek seem to be most frequently involved, with the gingiva and floor of mouth being unusual locations.<sup>99,100</sup> Typically, a rapidly growing, often non-ulcerated soft tissue mass, RMS typically metastasizes by hematogenous routes to the lungs, bone, and brain but may also disseminate via the lymphatics or direct extension (Figs. 5.40–5.42).

RMS arising in the head and neck region are characterized by a wide variation in survival rate, which is dependent on the site, with orbital lesions having the highest survival rates of any site in the body and parameningeal tumors having a worse prognosis.<sup>101</sup> The high survival rate in patients with orbital lesions is likely because they present with less advanced disease compared with the insidious presentation of parameningeal primaries, which more typically present with advanced-stage disease.<sup>101</sup> Even though age, anatomic subsite, and resectability were not shown to correlate with survival, the extent of disease, including tumor size, invasiveness, nodal metastases, and distant disease at presentation, was significantly associated with mortality.<sup>101</sup> Children 11 years of age or younger with a tumor measuring  $\leq 5$  cm have been shown to have the best survival, whereas patients over 11 years with a tumor measuring  $> 5$  cm had the worst survival outcome.<sup>102</sup> Treatment considerations include risk-guided therapy based on the chance of a cure with a specific treatment approach and taking into consideration both near- and long-term side effects of the various therapeutic modalities. In general, then, all patients will likely receive chemotherapy along with a local treatment strategy such as surgery, radiation therapy, or both.<sup>95,102</sup>

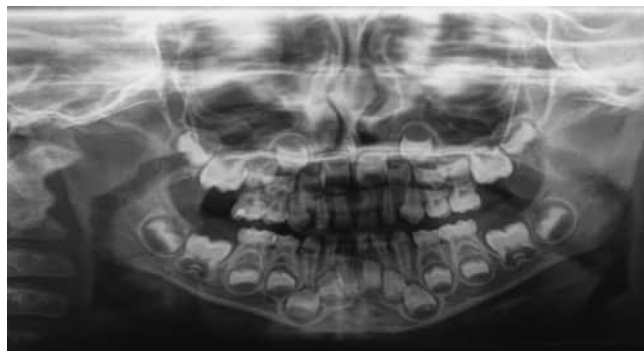### OSTEOGENIC SARCOMA

Osteogenic sarcoma (OS) is an uncommon, highly malignant primary neoplasm of bone with a soft tissue counterpart with a similar histomorphology. Its peak age of occurrence is the second decade of life, with the modal age of incidence being 16 years for girls and 18 for boys.<sup>103</sup> The most common site of involvement is the distal femur, followed by the proximal tibia and proximal humerus.

Osteogenic sarcoma of the jaws (OSJ) accounts for approximately 6.5% of all cases of OS, with the average age of onset being 10–20 years later than that for skeletal lesions.<sup>104</sup> The mandible seems to be involved more often than the maxilla.<sup>104,105</sup> Swelling with or without pain is the most frequently described early symptom, although paresthesia/anesthesia and loosening of the teeth may be noted. In a clinicopathologic study of 22 cases of OS of the head and neck in a pediatric population ranging from 1 to 18 years (mean age, 12.2 years), the primary symptoms were painless swelling occasionally associated with pain or tenderness. In a few cases, there was associated malocclusion



**Fig. 5.40** A 5-year-old boy with mild pain and swelling over the anterior mandible.



**Fig. 5.41** Panoramic film (same patient Fig. 5.40). Notice the lesion over anterior mandible.

and loosening or loss of teeth.<sup>106</sup> The average duration of symptoms was 5.9 months. Nineteen cases (86%) occurred in the mandible, two cases in the sphenoid sinus, and one in the maxilla.

The radiographic findings are typically those of a poorly defined, bone-destructive lesion suggestive of malignancy. Radiographically, it may be osteoblastic or osteolytic or may have a mixed radiographic appearance. One study reported that most of the lesions on the maxilla were osteoblastic, whereas most of those on the mandible were osteolytic.<sup>107</sup> A frequently described radiographic feature is a “sun-ray” appearance, with delicate, hair like osteophytes radiating in a sunburst manner away from the peripheral surface of the lesion. This has been reported to occur in as few as 10% and as many as 55% of cases.<sup>108,109</sup> An additional radiographic finding in early OSJ is symmetric widening of the periodontal ligament space around one or more of the teeth in the area of the lesion.

Histologically, OS is characterized by the production of tumor osteoid forming a malignant stroma that often

appears fibroblastic. These tumors are typically classified histologically into osteoblastic, chondroblastic, or fibroblastic subtypes according to the dominant histologic pattern. There is no agreement, however, as to whether the histologic subtype has any significant bearing on the patient’s prognosis.

The primary treatment modality for OSJ should always be radical surgery, with the single most important factor in curative therapy being its amenability to radical resection with clear margins.<sup>104</sup> Overall, chemotherapy has not been shown to be as effective in OSJ as in extragnathic sites for two reasons. First, even though almost all patients with OS of the long bones have at least microscopic metastatic disease at the time of diagnosis, the incidence of metastatic disease at the time of diagnosis for OSJ in all age groups is reported to be no higher than 18%<sup>97</sup>; and second, OSJs tend to be better differentiated than those involving the long bones, which may be partially responsible for the better prognosis for patients with osteosarcoma of the jaws.<sup>107,110</sup> Even so, it is still recommended that patients with primary osteosarcoma of the jaws should be treated with multiagent chemotherapy in addition to complete surgical excision, with free surgical margins being absolutely essential.<sup>111</sup>

## EWING’S SARCOMA

After osteosarcoma, the Ewing’s sarcoma (ES) family of tumors (ES), along with peripheral primitive neuroectodermal tumor (pPNET) is the second most common primary malignancy of bone in children and adolescents. ES of bone and soft tissue, as well as pPNET, are small round-cell tumors, the genetic hallmarks of which are a translocation of chromosomes 11 and 22,  $t(11;22)(q24;q12)$ ,<sup>112,113</sup> and, in most cases, overexpression of the *MIC2* gene surface marker,<sup>99</sup> which differentiates them from the majority of other small round-cell tumors.

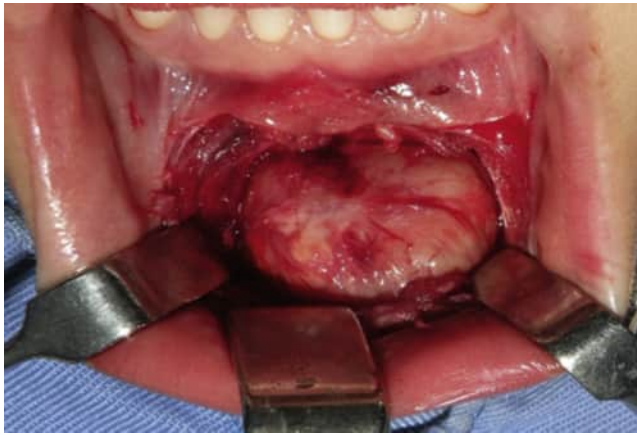
The histologic and electron microscopic features of ES and pPNET, as well as expression of the antigen of the *MIC2* gene, provide the basis for characterizing them as neuroectodermally derived neoplasms.<sup>114</sup>

Approximately 4% of primary cases of ES arising in bone arise in the bones of the head and neck, with the skull being the most frequent site of involvement and the mandible being the most commonly involved gnathic bone.<sup>115</sup> A review of 105 cases showed the average age at diagnosis to be 15.9 years, with an age range of 2–44 years at presentation.<sup>116</sup> There was a slight predilection for occurrence in males, with a male-to-female ratio of 1.5:1. The mandible was involved more than twice as often as the maxilla, with a predilection of 4:1 for occurrence in the posterior aspect of the jaws over other regions.

A histopathologically identical extraskeletal form of ES has been identified.<sup>117</sup> In a series of 130 patients with ES of soft tissue in childhood, 18% of cases involved the head and neck. Patients with soft tissue or extraskeletal ES were compared with patients with pPNET.<sup>118</sup> There were no significant differences in patient age, gender, tumor location, or stage at presentation between patients with ES and those with pPNET of the soft tissue.

Localized swelling and pain are the most frequent complaints at presentation, although paresthesia and tooth mobility may also be presenting symptoms. The soft tissue





**Fig. 5.42** Surgical enucleation (same patient Fig. 5.40) of the rhabdomyosarcoma.

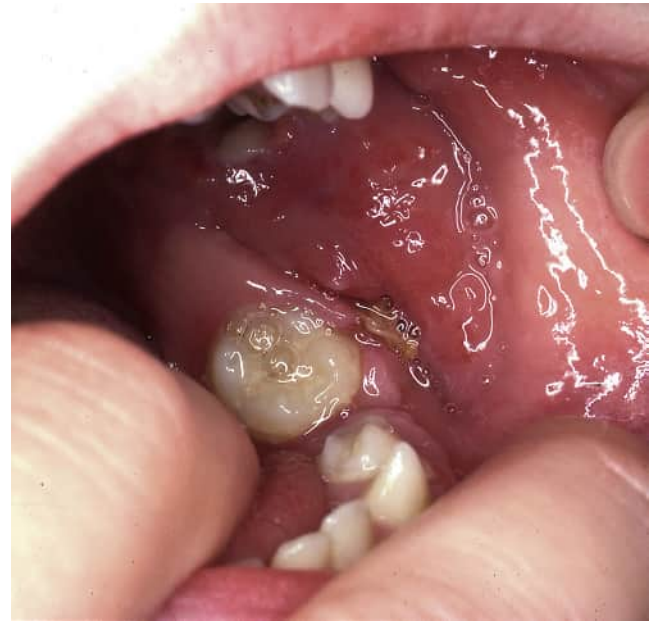overlying the lesion may be erythematous and warm to the touch, and thus more suggestive of an inflammatory process than of a neoplasm (Fig. 5.43). In addition, the patient may have fever, elevated erythrocyte sedimentation rate, increased serum lactic dehydrogenase level, anemia, and leukocytosis.

The radiographic features are those of a diffuse bone-destructive lesion, appearing as an irregular, somewhat mottled, radiolucent lesion that may resemble an osteomyelitis (Fig. 5.44). Although reduplication or lamination of the periosteum has been considered a common radiologic sign of ES of long bones, this has been shown not to be a common feature of this disease in the jaw bones; however, sun-ray spicules of periosteal bone may be seen as previously described for OS.<sup>116</sup> Computed tomography and, in particular, magnetic resonance imaging are invaluable in further delineating the extent of disease not readily visible on plain radiographs.<sup>119,120</sup>

Histologically, ES appears as sheets of cells with small, dark-staining nuclei and poorly defined cytoplasmic outlines. Mitotic figures are prominent, and necrosis is a common feature. Sheets of cells may be separated by vascular connective tissue septa. The presence of intracytoplasmic glycogen and positive results on periodic acid–Schiff staining are essential findings unless there is documented glycogen content on electron microscopy. Detection of MIC2 antigen along with the use of molecular techniques to detect the t(11;22) (q24;q12) translocation have generally improved the clinician's ability to diagnose these tumors.

In the past, ES as a whole has been associated with an almost uniformly poor prognosis, with nearly all patients having micrometastatic disease at the time of diagnosis. The prognosis for ES in the head and neck, however, has been noted to be significantly better than that for ES overall.<sup>115</sup> In a report by the Intergroup Ewing's Sarcoma Study of patients who were followed in the study for more than 3 years, 80% were alive and well without known progressive, recurrent or metastatic disease. Of the 10 patients who had survived  $\geq 5$  years, none had subsequently died, and of the 5 patients who had died, none had gnathic involvement.

Chemotherapy is the cornerstone of treatment for ES and is usually applied in a neoadjuvant fashion.<sup>119</sup> Therapy consists of systemic multiagent chemotherapy along with



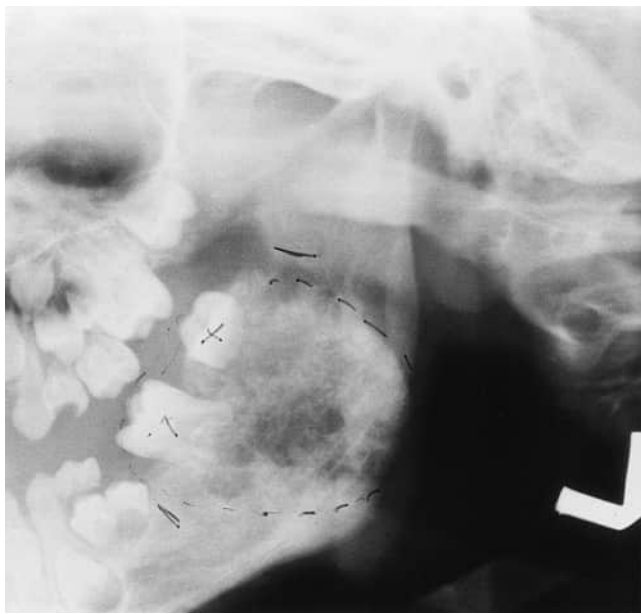
**Fig. 5.43** Photograph of a 6-year-old boy with Ewing's sarcoma who had a 1-month history of swelling on the left side of his face. Clinically, there was swelling with mucosal ulceration in the muco buccal fold in the first molar area. (Courtesy Drs. Richard L. Miller and William Epstein.)

local control, which may consist of surgery, radiation therapy, or a combination of the two, depending on the age of the patient, location of the primary tumor, and functional consequences of therapy. When surgery is employed, the goal should be complete tumor removal, avoiding marginal resection.<sup>119</sup> Because of the potential for post-radiation sarcomas, particularly bone sarcoma in the field of radiation treatment, the importance of local control of the disease with surgery and safe local control with radiation is now emphasized. Patients with clinically detectable metastases at the time of diagnosis and those with relapse after initial therapy have a significantly poorer prognosis.

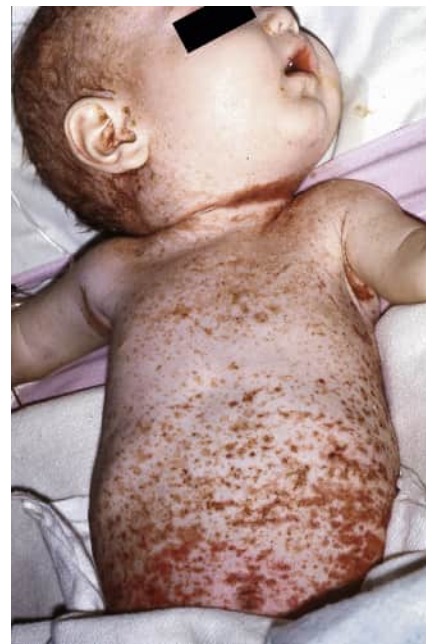### LANGERHANS CELL HISTIOCYTOSIS (HISTIOCYTOSIS X)

Langerhans cell histiocytosis (LCH) is the current designation replacing the term histiocytosis X that was introduced by Lichtenstein in 1953 as a unifying designation for several previous eponyms, including Letterer-Siwe disease, Hand-Schüller-Christian disease, and eosinophilic granuloma (LCH of bone).<sup>121</sup> Prior to this, the three clinical entities that comprise this nosologic category were described and categorized over a period of nearly 50 years.<sup>122</sup> Histiocytosis X was renamed LCH in 1987.<sup>123</sup> While its etiology and pathogenesis remain obscure, the one common denominator is the Langerhans cell, a bone marrow–derived, antigen-presenting dendritic cell. Langerhans cells reside in the skin, thymus, and mucosal epithelium, including the oropharynx and nasopharynx, esophagus, bronchi, and cervix, and are said to be the most potent antigen-presenting cells in the body.<sup>124–126</sup>

Histologically, LCH is characterized by the presence of uniform sheets of large, round Langerhans histiocytes, which have been shown to be immature dendritic cells and not histiocytes at all, with a homogenous pink cytoplasm



**Fig. 5.44** Radiograph of the same patient as in Fig. 5.43 with Ewing's sarcoma involving the left angle of the mandible. Notice the mottled radiolucent appearance. (Courtesy Drs. Richard L. Miller and William Epstein.)

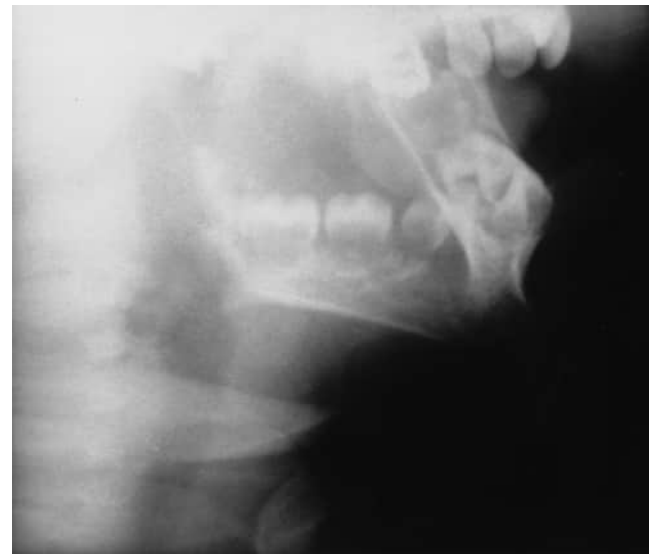

**Fig. 5.45** Characteristic erythematous, scaly skin rash in a 5½-month-old infant with Letterer-Siwe disease.

when stained with hematoxylin and eosin. These Langerhans cell histiocytes are interspersed with variable numbers of eosinophils, lymphocytes, plasma cells, and multinucleated giant cells, particularly in lesions of bone. Langerhans cells are characterized ultrastructurally by the presence of Langerhans or Birbeck granules, rod-shaped organelles that may have a vesicular portion imparting the so-called “tennis racquet appearance” under the electron microscope. LCH can now be identified on the basis of immunoreactivity to cell-surface markers such as CD-1a and, more specifically, CD-207 (Langerin), which differentiates it from other dendritic disorders.<sup>127,128</sup>

The clinical manifestations of LCH are variable and, as previously noted, were historically divided into distinct entities. The term Letterer-Siwe disease (now better termed *acute disseminated histiocytosis*) has been used as a moniker for an acute fulminating proliferative disorder involving Langerhans histiocytes that chiefly affects infants and children younger than 3 years of age. It is often characterized by the development of a scaly, erythematous skin rash, initially most prominent on the trunk but progressing to involve the scalp and extremities (Fig. 5.45). This is accompanied by a persistent low-grade fever, anemia, thrombocytopenia, hepatosplenomegaly, and lymphadenopathy.

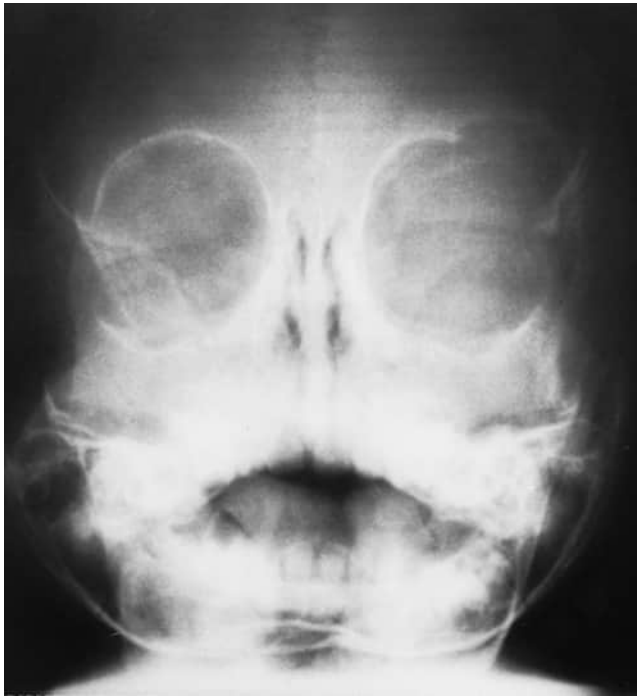Bony involvement, indistinguishable from that found in chronic disseminated histiocytosis (Hand-Schüller-Christian disease) and eosinophilic granuloma of bone, may be noted (Fig. 5.46). Oral lesions with swelling, pain, ulceration, gingival inflammation and necrosis, and destruction of alveolar bone with premature exfoliation of the teeth may be an early manifestation of this form of the disease. Although multiagent chemotherapy may result in regression of the disease in some cases, patients with this form of the disease have a relatively poor prognosis.



**Fig. 5.46** Diffuse destruction of maxillary and mandibular alveolar bone around the developing primary teeth in the same patient as in Fig. 5.47. Notice also destruction of the left angle and ramus of the mandible.

Hand-Schüller-Christian disease (now better termed *chronic disseminated histiocytosis*) has been used to describe the chronic disseminated form of LCH, which is characterized by the development of multifocal eosinophilic granulomas of bone, lymphadenopathy, and visceral involvement, especially hepatosplenomegaly (Fig. 5.47). The classic clinical triad that has often been described for this disease is the occurrence of radiolucent defects appearing as punched-out lesions in membranous bones, exophthalmos, and diabetes insipidus. Chronic otitis media is also a frequent finding. Although usually diagnosed early in the first





**Fig. 5.47** Radiograph of a 12-month-old girl with Hand-Schüller-Christian disease. There is an expansile radiolucent lesion in the right body of the mandible as well as destruction of the greater wing of the sphenoid and supraorbital rim on the left.

decade of life, chronic disseminated histiocytosis has been reported to occur as late as the sixth decade.<sup>129</sup> The treatment varies according to the extent of the disease, with surgical curettage or radiation therapy being used to treat the focal disease. Multiagent chemotherapy has been relatively successful in long-term control of disseminated disease.

Eosinophilic granuloma (LCH of bone) is the most common and also least severe form of LCH. It is characterized by single or multiple usually well-defined radiolucent bony lesions, most often accompanied by pain and swelling. Older children and young adults most commonly display this form of the disease. In addition to the mandible and skull, the femur, humerus, ribs, and pelvis are also frequently involved. The maxilla is involved less frequently than the mandible, with the midposterior mandible being the most common site of occurrence. Skin and visceral involvement such as that described for the acute and chronic disseminated forms of the disease are absent. Several options exist for patients with eosinophilic granuloma. After confirmation of the diagnosis by biopsy, the lesion may be left alone for observation, it may be surgically curetted or excised, intralesional injections of corticosteroids may be given, or low-dose radiotherapy may be used. In one series of 41 lesions in 25 patients, treatment varied from excisional biopsy to curettage and peripheral ostectomy as the only surgical treatment, followed by low-dose radiotherapy. Three lesions (7.3%) in three patients (12%) recurred.<sup>130</sup>

## References

- Hong CHL, Dean DR, Hull K, et al.: World workshop on oral medicine VII: relative frequency of oral mucosal lesions in children, a scoping review, *Oral Dis* 25(Suppl 1):193–203, 2019.
- Wood NK, Goaz PW, Wood NK: *Differential diagnosis of oral and maxillofacial lesions*, ed 5, St. Louis, 1997, Mosby, p 656, xii.
- Orenuga OO, Oluwakuyide RT, Olawuyi AB, et al.: Recurrent oral squamous papilloma in a pediatric patient: case report and review of the literature, *Niger J Clin Pract* 21(12):1674–1677, 2018.
- Abbey LM, Page DG, Sawyer DR: The clinical and histopathologic features of a series of 464 oral squamous cell papillomas, *Oral Surg Oral Med Oral Pathol* 49(5):419–428, 1980.
- Rautava J, Syrjanen S: Human papillomavirus infections in the oral mucosa, *J Am Dent Assoc* 142(8):905–914, 2011.
- Betz SJ: HPV-related papillary lesions of the oral mucosa: a review, *Head Neck Pathol* 13(1):80–90, 2019.
- Syrjanen S: Current concepts on human papillomavirus infections in children, *APMIS* 118(6-7):494–509, 2010.
- Neville BW, Damm DD, White DK: *Color Atlas of Clinical oral pathology*, ed 2, Baltimore, 1999, Williams & Wilkins, p 488, xi.
- Damm DD: Oral pathology, *Oral Surg Oral Med Oral Pathol* 77(1):4–5, 1994.
- Mays JW, Carey BP, Posey R, et al.: World workshop of oral medicine VII: a systematic review of immunobiologic therapy for oral manifestations of pemphigoid and pemphigus, *Oral Dis* 25(Suppl 1):111–121, 2019.
- Angelopoulos AP: Pyogenic granuloma of the oral cavity: statistical analysis of its clinical features, *J Oral Surg* 29(12):840–847, 1971.
- Lawoyin JO, Arotiba JT, Dosumu OO: Oral pyogenic granuloma: a review of 38 cases from Ibadan, Nigeria, *Br J Oral Maxillofac Surg* 35(3):185–189, 1997.
- Thompson LD: Lobular capillary hemangioma (pyogenic granuloma) of the oral cavity, *Ear Nose Throat J* 96(7):240, 2017.
- Cuisia ZE, Brannon RB: Peripheral ossifying fibroma—a clinical evaluation of 134 pediatric cases, *Pediatr Dent* 23(3):245–248, 2001.
- Eversole LR, Rovin S: Reactive lesions of the gingiva, *J Oral Pathol* 1(1):30–38, 1972.
- Ritwik P, Brannon RB, Musselman RJ: Spontaneous regression of congenital epulis: a case report and review of the literature, *J Med Case Rep* 4:331, 2010.
- Wong DK, Ramli R, Muhaizan WM, et al.: Congenital epulis: a rare benign tumour, *Med J Malaysia* 71(5):300–301, 2016.
- Kaiserling E, Ruck P, Xiao JC: Congenital epulis and granular cell tumor: a histologic and immunohistochemical study, *Oral Surg Oral Med Oral Pathol Oral Radiol Endod* 80(6):687–697, 1995.
- Solomon LW, Trahan WR, Snow JE: Localized juvenile spongiotic gingival hyperplasia: a report of 3 cases, *Pediatr Dent* 35(4):360–363, 2013.
- Chang JY, Kessler HP, Wright JM: Localized juvenile spongiotic gingival hyperplasia, *Oral Surg Oral Med Oral Pathol Oral Radiol Endod* 106(3):411–418, 2008.
- Vargo RJ, Bilodeau EA: Reappraising localized juvenile spongiotic gingival hyperplasia, *J Am Dent Assoc* 150(2):147–153, e2, 2019.
- Neville BW: Update on current trends in oral and maxillofacial pathology, *Head Neck Pathol* 1(1):75–80, 2007.
- Carlson ER, Ord RA: Benign pediatric salivary gland lesions, *Oral Maxillofac Surg Clin North Am* 28(1):67–81, 2016.
- Wassef M, Blei F, Adams D, et al.: Vascular anomalies classification: recommendations from the international society for the study of vascular anomalies, *Pediatrics* 136(1):e203–e214, 2015.
- Robertson RL, Robson CD, Barnes PD, et al.: Head and neck vascular anomalies of childhood, *Neuroimaging Clin N Am* 9(1):115–132, 1999.
- Neville B, Damm DD, Allen C, Bouquot J: *Oral and maxillofacial pathology*, ed 3, China, 2009, Elsevier, p 920.
- Arneja JS, Gosain AK: Vascular malformations, *Plast Reconstr Surg* 121(4):195e–206e, 2008.
- Lamberg MA, Tasanen A, Jaaskelainen J: Fatality from central hemangioma of the mandible, *J Oral Surg* 37(8):578–584, 1979.
- Bhayya H, Pavani D, Avinash Tejasvi ML, et al.: Oral lymphangioma: a rare case report, *Contemp Clin Dent* 6(4):584–587, 2015.
- Damaskos C, Garpis N, Manousi M, et al.: Cystic hygroma of the neck: single center experience and literature review, *Eur Rev Med Pharmacol Sci* 21(21):4918–4923, 2017.
- Javed F, Ramalingam S, Ahmed HB, et al.: Oral manifestations in patients with neurofibromatosis type-1: a comprehensive literature review, *Crit Rev Oncol Hematol* 91(2):123–129, 2014.
- McClatchey AI: Neurofibromatosis, *Annu Rev Pathol* 2:191–216, 2007.



33. Resnick CM, Dentino KM, Garza R, et al.: A management strategy for idiopathic bone cavities of the jaws, *J Oral Maxillofac Surg* 74(6):1153–1158, 2016.
34. Eversole R, Su L, El Mofty S: Benign fibro-osseous lesions of the craniofacial complex. A review, *Head Neck Pathol* 2(3):177–202, 2008.
35. Nelson BL, Thompson LD: Fibrous dysplasia of bone, *Ear Nose Throat J* 82(4):259, 2003.
36. Nelson JF, Berringer RD, Theisen FC: Fibrous dysplasia of the mandible and sphenoid bones: report of case, *J Oral Surg* 35(11):924–928, 1977.
37. Nelson BL, Folk GS: Ameloblastic fibroma, *Head Neck Pathol* 3(1):51–53, 2009.
38. El-Mofty S: Psammomatoid and trabecular juvenile ossifying fibroma of the craniofacial skeleton: two distinct clinicopathologic entities, *Oral Surg Oral Med Oral Pathol Oral Radiol Endod* 93(3):296–304, 2002.
39. Kaffe I, Ardekian L, Taicher S, et al.: Radiologic features of central giant cell granuloma of the jaws, *Oral Surg Oral Med Oral Pathol Oral Radiol Endod* 81(6):720–726, 1996.
40. Whitaker SB, Waldron CA: Central giant cell lesions of the jaws. a clinical, radiologic, and histopathologic study, *Oral Surg Oral Med Oral Pathol* 75(2):199–208, 1993.
41. Triantafyllidou K, Grigoris V, George K, et al.: Central giant cell granuloma of the jaws: a clinical study of 17 cases and a review of the literature, *Ann Otol Rhinol Laryngol* 120(3):167–174, 2011.
42. Komerik N, Tas B, Onal L: Cherubism, *Head Neck Pathol* 8(2):164–167, 2014.
43. Tsodoulos S, Ilija A, Antoniadis K, et al.: Cherubism: a case report of a three-generation inheritance and literature review, *J Oral Maxillofac Surg* 72(2):405.e1–e9, 2014.
44. Chrcanovic BR, Gomez RS: Melanotic neuroectodermal tumour of infancy of the jaws: an analysis of diagnostic features and treatment, *Int J Oral Maxillofac Surg* 48(1):1–8, 2019.
45. Moreau A, Galmiche L, Minard-Colin V, et al.: Melanotic neuroectodermal tumor of infancy (MNTI) of the head and neck: A French multicenter study, *J Craniomaxillofac Surg* 46(2):201–206, 2018.
46. Woolgar JA, Rippin JW, Browne RM: The odontogenic keratocyst and its occurrence in the nevusoid basal cell carcinoma syndrome, *Oral Surg Oral Med Oral Pathol* 64(6):727–730, 1987.
47. Woolgar JA, Rippin JW, Browne RM: A comparative study of the clinical and histological features of recurrent and non-recurrent odontogenic keratocysts, *J Oral Pathol* 16(3):124–128, 1987.
48. Browne RM: The pathogenesis of odontogenic cysts: a review, *J Oral Pathol* 4(1):31–46, 1975.
49. Brannon RB: The odontogenic keratocyst. A clinicopathologic study of 312 cases. Part I. Clinical features, *Oral Surg Oral Med Oral Pathol* 42(1):54–72, 1976.
50. Kim HR, Nam SH, Kim HJ, et al.: Buccal bifurcation cyst: two case reports and a literature review, *J Clin Pediatr Dent* 42(3):221–224, 2018.
51. Mourshed F: A Roentgenographic study of dentigerous cysts. 3. Analysis of 180 cases, *Oral Surg Oral Med Oral Pathol* 18:466–473, 1964.
52. Mourshed F: A roentgenographic study of dentigerous cysts. II. Role of roentgenograms in detecting dentigerous cyst in the early stages, *Oral Surg Oral Med Oral Pathol* 18:54–61, 1964.
53. Benn A, Altini M: Dentigerous cysts of inflammatory origin. a clinicopathologic study, *Oral Surg Oral Med Oral Pathol Oral Radiol Endod* 81(2):203–209, 1996.
54. McMillan MD, Smillie AC: Ameloblastomas associated with dentigerous cysts, *Oral Surg Oral Med Oral Pathol* 51(5):489–496, 1981.
55. Leider AS, Eversole LR, Barkin ME: Cystic ameloblastoma. A clinicopathologic analysis, *Oral Surg Oral Med Oral Pathol* 60(6):624–630, 1985.
56. Gardner DG, Corio RL: Plexiform unicystic ameloblastoma. A variant of ameloblastoma with a low-recurrence rate after enucleation, *Cancer* 53(8):1730–1735, 1984.
57. Wright JM: The odontogenic keratocyst: orthokeratinized variant, *Oral Surg Oral Med Oral Pathol* 51(6):609–618, 1981.
58. Eyre J, Zakrzewska JM: The conservative management of large odontogenic keratocysts, *Br J Oral Maxillofac Surg* 23(3):195–203, 1985.
59. Anand VK, Arrowood Jr JP, Krolls SO: Malignant potential of the odontogenic keratocyst, *Otolaryngol Head Neck Surg* 111(1):124–129, 1994.
60. Forssell K, Forssell H, Kahnberg KE: Recurrence of keratocysts. A long-term follow-up study, *Int J Oral Maxillofac Surg* 17(1):25–28, 1988.
61. Blanas N, Freund B, Schwartz M, et al.: Systematic review of the treatment and prognosis of the odontogenic keratocyst, *Oral Surg Oral Med Oral Pathol Oral Radiol Endod* 90(5):553–558, 2000.
62. Kaczmarzyk T, Mojsa I, Stypulkowska J: A systematic review of the recurrence rate for keratocystic odontogenic tumour in relation to treatment modalities, *Int J Oral Maxillofac Surg* 41(6):756–767, 2012.
63. Meara JG, Shah S, Li KK, et al.: The odontogenic keratocyst: a 20-year clinicopathologic review, *Laryngoscope* 108(2):280–283, 1998.
64. Hasan A, Akintola D: An update of Gorlin-Goltz syndrome, *Prim Dent J* 7(3):38–41, 2018.
65. Sanghera R, Grewal P: Gorlin syndrome presentation and the importance of differential diagnosis of skin cancer: A case report, *J Pharm Pharm Sci* 21(1s):222s–224s, 2018.
66. Philipsen HP, Reichart PA: Unicystic ameloblastoma. A review of 193 cases from the literature, *Oral Oncol* 34(5):317–325, 1998.
67. Vickers RA, Gorlin RJ: Ameloblastoma: delineation of early histopathologic features of neoplasia, *Cancer* 26(3):699–710, 1970.
68. Ord RA, Blanchaert Jr RH, Nikitakis NG, et al.: Ameloblastoma in children, *J Oral Maxillofac Surg* 60(7):762–770, 2002; discussion, 770–771.
69. Kahn MA: Ameloblastoma in young persons: a clinicopathologic analysis and etiologic investigation, *Oral Surg Oral Med Oral Pathol* 67(6):706–715, 1989.
70. Rosenstein T, Pogrel MA, Smith RA, et al.: Cystic ameloblastoma—behavior and treatment of 21 cases, *J Oral Maxillofac Surg* 59(11):1311–1316, 2001; discussion 1316–1318.
71. Zhang J, Gu Z, Jiang L, et al.: Ameloblastoma in children and adolescents, *Br J Oral Maxillofac Surg* 48(7):549–554, 2010.
72. Ghandhi D, Ayoub AF, Pogrel MA, et al.: Ameloblastoma: a surgeon's dilemma, *J Oral Maxillofac Surg* 64(7):1010–1014, 2006.
73. Philipsen HP, Reichart PA: Classification of odontogenic tumours. A historical review, *J Oral Pathol Med* 35(9):525–529, 2006.
74. Philipsen HP, Reichart PA: Adenomatoid odontogenic tumour: facts and figures, *Oral Oncol* 35(2):125–131, 1999.
75. Philipsen HP, Reichart PA: The adenomatoid odontogenic tumour: ultrastructure of tumour cells and non-calcified amorphous masses, *J Oral Pathol Med* 25(9):491–496, 1996.
76. Abrams AM, Melrose RJ, Howell FV: Adenoameloblastoma. A clinical pathologic study of ten new cases, *Cancer* 22(1):175–185, 1968.
77. Courtney RM, Kerr DA: The odontogenic adenomatoid tumor. A comprehensive study of twenty new cases, *Oral Surg Oral Med Oral Pathol* 39(3):424–435, 1975.
78. Chrcanovic BR, Gomez RS: Odontogenic myxoma: an updated analysis of 1,692 cases reported in the literature, *Oral Dis* 25(3):676–683, 2019.
79. Oliveira SV, Rocha AC, Cecchetti MM, et al.: Odontogenic myxoma in a child treated with enucleation and curettage, *Autops Case Rep* 8(3):e2018042, 2018.
80. Huang P, Bell C, Wallace V, et al.: Mixed odontogenic tumors in four young dogs: ameloblastic fibroma and ameloblastic fibro-odontoma, *J Vet Diagn Invest* 31(1):98–102, 2019.
81. Corte AF, Moura CP, I, Filipe JP, et al.: Ameloblastic fibroma with an unusual location, *Otol Neurotol* 39(10):e1176–e1178, 2018.
82. Ide F, Mishima K, Kikuchi K, et al.: Development and growth of adenomatoid odontogenic tumor related to formation and eruption of teeth, *Head Neck Pathol* 5(2):123–132, 2011.
83. Chen Y, Wang JM, Li TJ: Ameloblastic fibroma: a review of published studies with special reference to its nature and biological behavior, *Oral Oncol* 43(10):960–969, 2007.
84. Philipsen HP, Reichart PA, Praetorius F: Mixed odontogenic tumours and odontomas. Considerations on interrelationship. Review of the literature and presentation of 134 new cases of odontomas, *Oral Oncol* 33(2):86–99, 1997.
85. Tomich CE: Benign mixed odontogenic tumors, *Semin Diagn Pathol* 16(4):308–316, 1999.
86. Boxberger NR, Brannon RB, Fowler CB: Ameloblastic fibro-odontoma: a clinicopathologic study of 12 cases, *J Clin Pediatr Dent* 35(4):397–403, 2011.
87. Slootweg PJ: An analysis of the interrelationship of the mixed odontogenic tumors—ameloblastic fibroma, ameloblastic fibro-odontoma,

- and the odontomas, *Oral Surg Oral Med Oral Pathol* 51(3):266–276, 1981.
88. Budnick SD: Compound and complex odontomas, *Oral Surg Oral Med Oral Pathol* 42(4):501–506, 1976.
  89. Kaugars GE, Miller ME, Abbey LM: Odontomas, *Oral Surg Oral Med Oral Pathol* 67(2):172–176, 1989.
  90. Fowler CB, Hartman KS, Brannon RB: Fibromatosis of the oral and paraoral region, *Oral Surg Oral Med Oral Pathol* 77(4):373–386, 1994.
  91. Said-Al-Naief N, Fernandes R, Louis P, et al.: Desmoplastic fibroma of the jaw: a case report and review of literature, *Oral Surg Oral Med Oral Pathol Oral Radiol Endod* 101(1):82–94, 2006.
  92. Ferrari A, Alaggio R, Meazza C, et al.: Fibroblastic tumors of intermediate malignancy in childhood, *Expert Rev Anticancer Ther* 13(2):225–236, 2013.
  93. Fisher C: Fibromatosis and fibrosarcoma in infancy and childhood, *Eur J Cancer* 32A(12):2094–2100, 1996.
  94. Orbach D, Rey A, Cecchetto G, et al.: Infantile fibrosarcoma: management based on the European experience, *J Clin Oncol* 28(2):318–323, 2010.
  95. Paulino AC, Okcu MF: Rhabdomyosarcoma, *Curr Probl Cancer* 32(1):7–34, 2008.
  96. Hicks J, Flaitz C: Rhabdomyosarcoma of the head and neck in children, *Oral Oncol* 38(5):450–459, 2002.
  97. Miller RW, Dalager NA: Fatal rhabdomyosarcoma among children in the United States, 1960–69, *Cancer* 34(6):1897–1900, 1974.
  98. Takeda Y: Ameloblastic fibroma and related lesions: current pathologic concept, *Oral Oncol* 35(6):535–540, 1999.
  99. Bras J, Batsakis JG, Luna MA: Rhabdomyosarcoma of the oral soft tissues, *Oral Surg Oral Med Oral Pathol* 64(5):585–596, 1987.
  100. Peters E, Cohen M, Altini M, et al.: Rhabdomyosarcoma of the oral and paraoral region, *Cancer* 63(5):963–966, 1989.
  101. Kraus DH, Saenz NC, Gollamudi S, et al.: Pediatric rhabdomyosarcoma of the head and neck, *Am J Surg* 174(5):556–560, 1997.
  102. Simon JH, Paulino AC, Smith RB, et al.: Prognostic factors in head and neck rhabdomyosarcoma, *Head Neck* 24(5):468–473, 2002.
  103. Meyers PA, Gorlick R: Osteosarcoma, *Pediatr Clin North Am* 44(4):973–989, 1997.
  104. Mendenhall WM, Fernandes R, Werning JW, et al.: Head and neck osteosarcoma, *Am J Otolaryngol* 32(6):597–600, 2011.
  105. Garrington GE, Scofield HH, Cornyn J, et al.: Osteosarcoma of the jaws. analysis of 56 cases, *Cancer* 20(3):377–391, 1967.
  106. Gadwal SR, Gannon FH, Fanburg-Smith JC, et al.: Primary osteosarcoma of the head and neck in pediatric patients: a clinicopathologic study of 22 cases with a review of the literature, *Cancer* 91(3):598–605, 2001.
  107. Clark JL, Unni KK, Dahlin DC, et al.: Osteosarcoma of the jaw, *Cancer* 51(12):2311–2316, 1983.
  108. Fernandes GL, Natal MRC, da Cruz CLP, et al.: Primary osteosarcoma of the cranial vault, *Radiol Bras* 50(4):263–265, 2017.
  109. August M, Magennis P, Dewitt D: Osteogenic sarcoma of the jaws: factors influencing prognosis, *Int J Oral Maxillofac Surg* 26(3):198–204, 1997.
  110. Mardinger O, Givol N, Talmi YP, et al.: Osteosarcoma of the jaw. the Chaim Sheba Medical Center experience, *Oral Surg Oral Med Oral Pathol Oral Radiol Endod* 91(4):445–451, 2001.
  111. Thiele OC, Freier K, Bacon C, et al.: Interdisciplinary combined treatment of craniofacial osteosarcoma with neoadjuvant and adjuvant chemotherapy and excision of the tumour: a retrospective study, *Br J Oral Maxillofac Surg* 46(7):533–536, 2008.
  112. Whang-Peng J, Triche TJ, Knutsen T, et al.: Chromosome translocation in peripheral neuroepithelioma, *N Engl J Med* 311(9):584–585, 1984.
  113. Turc-Carel C, Philip I, Berger MP, et al.: [Chromosomal translocation (11; 22) in cell lines of Ewing's sarcoma], *C R Seances Acad Sci III* 296(23):1101–1103, 1983.
  114. Ambros IM, Ambros PF, Strehl S, et al.: MIC2 is a specific marker for Ewing's sarcoma and peripheral primitive neuroectodermal tumors. evidence for a common histogenesis of ewing's sarcoma and peripheral primitive neuroectodermal tumors from MIC2 expression and specific chromosome aberration, *Cancer* 67(7):1886–1893, 1991.
  115. Siegal GP, Oliver WR, Reinus WR, et al.: Primary Ewing's sarcoma involving the bones of the head and neck, *Cancer* 60(11):2829–2840, 1987.
  116. Wood RE, Yacobi R, Pharoah M, et al.: Ewing's tumor of the jaw, *Oral Surg Oral Med Oral Pathol* 69(1):120–127, 1990.
  117. Raney RB, Anderson JR, Barr FG, et al.: Ewing's sarcoma of soft tissues in childhood: a report from the Intergroup Rhabdomyosarcoma Study, 1972 to 1991, *J Clin Oncol* 15(2):574–582, 1997.
  118. Siebenrock KA, Nascimento AG, Rock MG: Comparison of soft tissue Ewing's sarcoma and peripheral neuroectodermal tumor, *Clin Orthop Relat Res* 329:288–299, 1996.
  119. Bielack SS, Carrle D: State-of-the-art approach in selective curable tumors: bone sarcoma, *Ann Oncol* 19(Suppl 7):vii155–v160, 2008.
  120. Eggli KD, Quiogue T, Moser Jr RP: Ewing's sarcoma, *Radiol Clin North Am* 31(2):325–337, 1993.
  121. Lichtenstein L: Histiocytosis X; integration of eosinophilic granuloma of bone, Letterer-Siwe disease, and Schuller-Christian disease as related manifestations of a single nosologic entity, *AMA Arch Pathol* 56(1):84–102, 1953.
  122. Badalian-Very G, Vergilio JA, Fleming M, et al.: Pathogenesis of Langerhans cell histiocytosis, *Annu Rev Pathol* 8:1–20, 2013.
  123. Jezierska M, Stefanowicz J, Romanowicz G, et al.: Langerhans cell histiocytosis in children - a disease with many faces. Recent advances in pathogenesis, diagnostic examinations and treatment, *Postepy Dermatol Alergol* 35(1):6–17, 2018.
  124. Halperson E, Weintraub M: Oral Langerhans cell histiocytosis in an infant, *J Dent Child (Chic)* 85(2):75–78, 2018.
  125. Kobayashi M, Tojo A: Langerhans cell histiocytosis in adults: advances in pathophysiology and treatment, *Cancer Sci* 109(12):3707–3713, 2018.
  126. Krooks J, Minkov M, Weatherall AG: Langerhans cell histiocytosis in children: diagnosis, differential diagnosis, treatment, sequelae, and standardized follow-up, *J Am Acad Dermatol* 78(6):1047–1056, 2018.
  127. Hicks J, Flaitz CM: Langerhans cell histiocytosis: current insights in a molecular age with emphasis on clinical oral and maxillofacial pathology practice, *Oral Surg Oral Med Oral Pathol Oral Radiol Endod* 100(Suppl 2):S42–S66, 2005.
  128. Valladeau J, Ravel Odile, Moore Kevin, et al.: Langerin, a novel C-type lectin specific to Langerhans cells, is an endocytic receptor that induces the formation of Birbeck granules, *Immunity* 12(1):71–81, 2000.
  129. McDonald JS, Miller RL, Bernstein ML, et al.: Histiocytosis X: a clinical presentation, *J Oral Pathol* 9(6):342–349, 1980.
  130. Ardekian L, Peled M, Rosen D, et al.: Clinical and radiographic features of eosinophilic granuloma in the jaws: review of 41 lesions treated by surgery and low-dose radiotherapy, *Oral Surg Oral Med Oral Pathol Oral Radiol Endod* 87(2):238–242, 1999.

## 6

# Clinical Genetics for the Dental Practitioner

JAMES K. HARTSFIELD JR. and LORRI ANN MORFORD

## CHAPTER OUTLINE

### Review of Genetic Principles

#### Cell Differentiation and Developmental Biology

#### Chromosomal Abnormalities

#### Hereditary Traits in Families

#### Developmental Biology of Enamel

#### Autosomal Dominant (AD) Inheritance

#### Autosomal Recessive (AR) Inheritance

#### X-Linked of Sex-Linked Inheritance

#### X-Linked Dominant (XLD)

#### X-Linked Recessive (XLR)

#### Variation in Gene Expression

#### Penetrance

#### Expressivity

#### Epigenetics

#### Complex/Multifactorial Inheritance

#### Influence of Genetic Factors on Major Cranofacial, Oral, and Dental Conditions

#### Genetics and Dental Caries

#### Genetics and Periodontal Disease

#### Aggressive Periodontitis (Stage III Grade C, Rapid Rate of Progression)

#### Genetics of Malocclusion

#### External Apical Root Resorption

#### Genetics of Cleft Lip and Palate

For additional resources, please visit the website.

## Review of Genetic Principles

The term *genome* is used to describe a single, complete copy of the genetic information contained within a cell or an organism (i.e., the DNA code). In humans, our genetic information is organized into a complement of 46 chromosomes comprising 22 autosomal pairs of chromosomes plus two sex chromosomes (XX or XY). Within a genome, structures termed *genes* represent the smallest physical and functional units of inheritance. Within the genome, each gene resides at a specific location termed as a *locus* (e.g., *locus* describes a single location, whereas the term *loci* refers to more than one location; Fig. 6.1). A *gene* is typically composed of regulatory information (e.g., a promoter), exons which contain the coding information needed to generate functional RNA and/or protein products, and introns which are segments of the DNA that separate the exons. The term *genotype* generally refers to the set of genes that an individual has inherited, and in particular can refer to the specific pair of alleles (i.e., alternative forms of a gene which contain some difference(s) in their DNA sequence) that a person has inherited at a given location (locus) within their *genome*. In contrast, a *phenotype* is the measurable or observable properties and physical characteristics of an individual, which can be due to a single *trait* or *collection of traits* as determined by the individual's genotype and the environment in which the individual develops over time.<sup>1,2</sup>

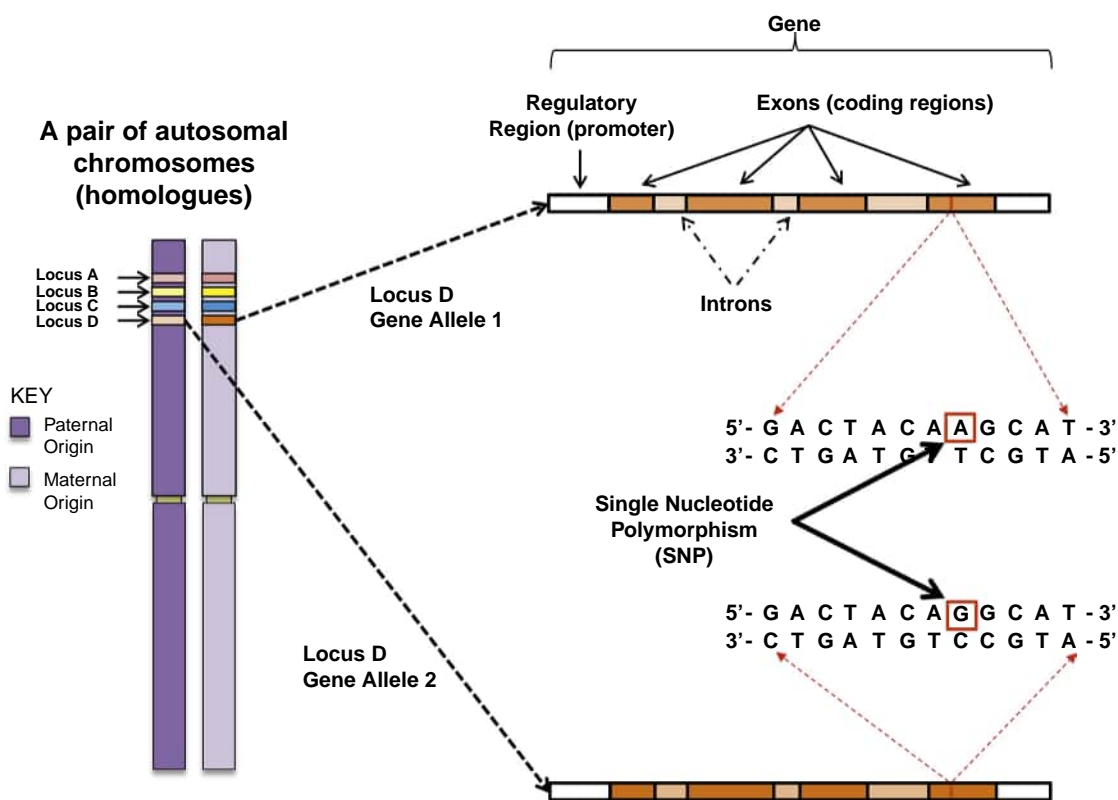
The Human Genome Project (HGP), which was a significant scientific achievement that provided valuable insights into the code of the entire human genome, made

extraordinary steps towards the future of what we term personalized or precision medicine.<sup>3-5</sup> Based on the findings of the HGP, it has been estimated that humans have only 20,000 to 25,000 genes, far fewer than many scientists had previously estimated; a finding supporting the idea that interactions between inherited genetic codes and environmental/epigenetic regulators are vital to the generation of the vast phenotypic diversity that we observe among different individuals and groups.<sup>6,7</sup>

We often think of a gene as the entire DNA sequence necessary for the synthesis of a functional polypeptide molecule (production of a protein via a messenger RNA [mRNA] intermediate) or RNA molecule (transfer RNA [tRNA] and ribosomal RNA [rRNA]). However, only about 1% of our DNA is made of protein-coding genes, and many of our genes do not code for proteins. While certain regions of DNA that were identified did not code for a protein and were initially labelled "junk DNA," it is now well understood that these portions of DNA play very important roles, particularly in the regulation of gene expression. While some of these non-protein coding areas contain enhancer and silencer elements used to regulate transcription, still other areas contain instructions for the generation of regulatory RNAs in addition to the mRNA, tRNA, and rRNA types. Regulatory RNAs include, but are not limited to, microRNAs (miRNAs) and long noncoding RNAs (lncRNAs) which help to control gene activity often by influencing or interfering with protein production.<sup>7</sup>

Remarkable advances in the biochemical techniques used to study cellular and molecular biology and DNA codes have taken researchers to the threshold of understanding the regulation of many key cell functions. To illustrate this principle, not so long ago, DNA analyses could only be





**Fig. 6.1** Illustration of a pair of autologous chromosomes, which can also be referred to as homologues. The location of four different gene loci (Locus A, B, C and D) are indicated on each homologue in the pair. Gene locus D is enlarged to the right in the diagram to highlight the specific elements of both allele 1 and allele 2 of this gene, including the gene regulatory region (or promoter), introns, exons, and the location of a single nucleotide polymorphism within the gene coding region of each homologous chromosome copy.

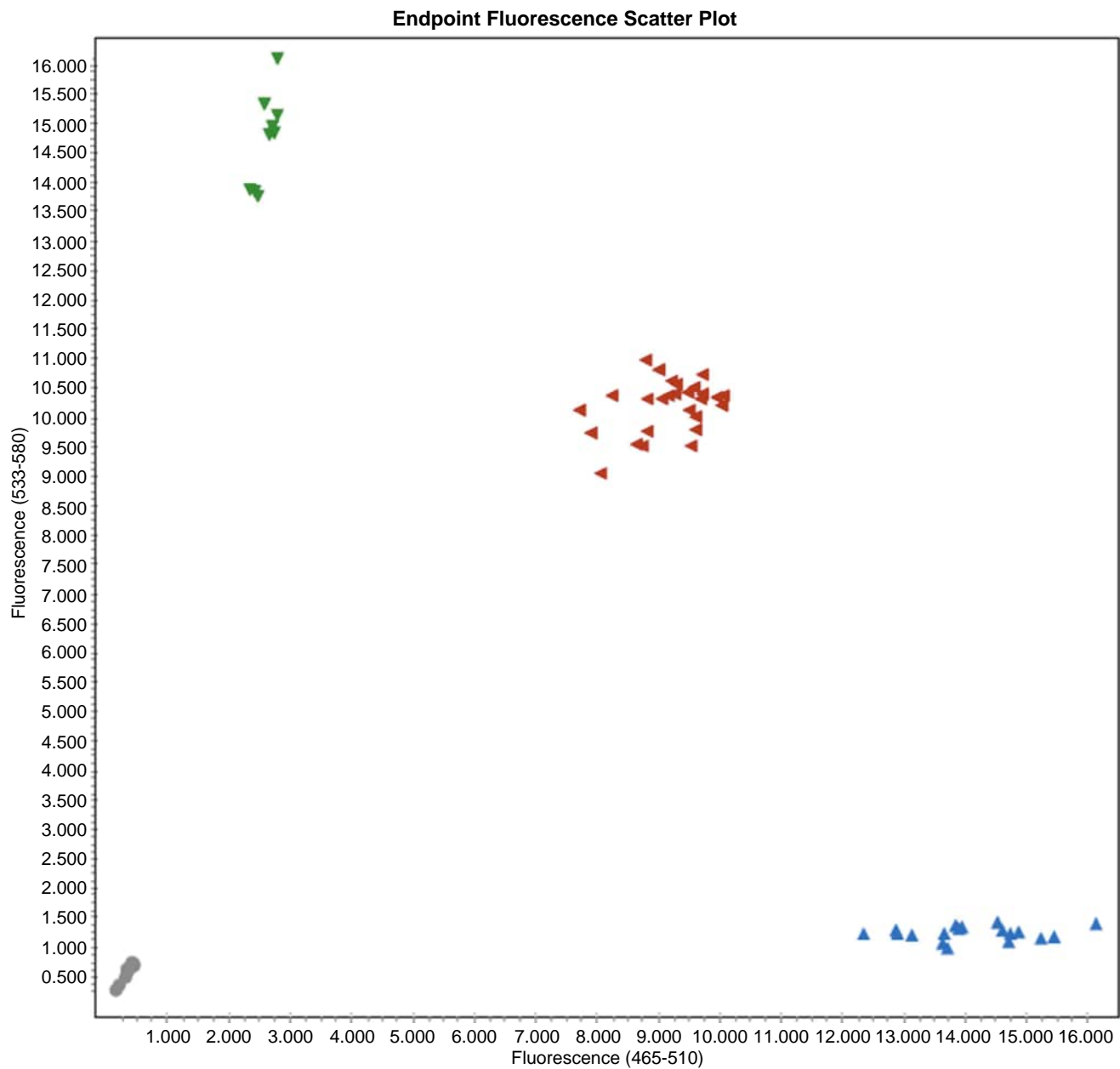
performed on minute amounts of DNA (picograms) because only these small quantities of DNA were available for study. However, when investigators discovered a DNA polymerase enzyme (termed Taq polymerase) which could be used to replicate DNA through a process called polymerase chain reaction amplification, DNA regions could be synthesized by the gram and the problem of “minimal sample size” disappeared.<sup>8</sup> This advance was instrumental for the completion of the HGP, which resulted in not only the definition of a single human genome sequence composed of overlapping parts from several people, but also an expanding catalogue of more than one million sites of variation in the human genome sequence.<sup>3,9</sup> These variations (or polymorphisms) can be used as markers for genetic analysis (including analysis of genetic–environmental interaction) in humans.<sup>10</sup> The genome varies from one individual to the next, most often in terms of single base changes of DNA, called *single nucleotide polymorphisms* (SNPs, pronounced “snips”). The main use of this human SNP map is to determine the contributions of genes to diseases (or non-disease phenotypes) that have complex, multifactorial bases (Fig. 6.2).<sup>11,12</sup>

The amount of genetic information that is currently available to study how genes influence clinical questions is continuing to grow exponentially due to what is referred to as next-generation or “deep” sequencing.<sup>13</sup> Compared with the methods used in the HGP nearly 20 years ago, modern sequencers are 50,000-fold faster, and therefore proportionately cheaper (Fig. 6.3). Hence, in spite of the fact that sequencing costs have sharply decreased with time and advancing technology, generating high-quality

sequencing coverage across an entire genome (referred to as whole genome sequencing, or WGS) can still be quite cost prohibitive, particularly for research purposes. Therefore, an alternative approach to WGS has been established that uses hybridization capture (also termed whole “exome” capture) to enrich DNA samples for only the exon sequences contained within the genome (i.e., which only make up ~1% of the entire human genome), allowing professionals to conduct whole exome sequencing (WES) in a much more cost-effective manner.<sup>14</sup> Determination of the genes responsible for still-unknown Mendelian (“single-gene”) and complex diseases and traits presents an immediate opportunity for this technology to be used to move away from methodologies that were based on only partial information (genetic linkage and/or genome-wide association studies, GWAS with SNP or microsatellite arrays) to complete analyses of the relationship between genomic variation and phenotype.<sup>15,16</sup>

## Cell Differentiation and Developmental Biology

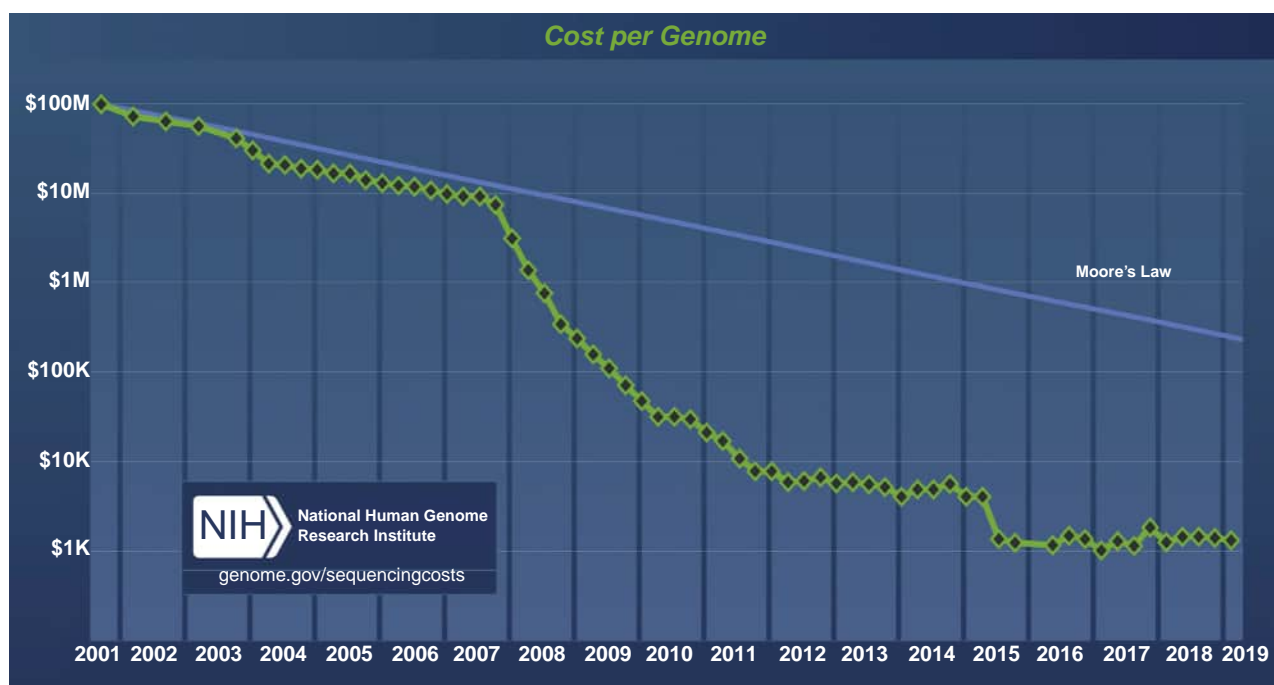
It is fascinating that a single fertilized ovum contains within itself the full potential needed for the development of the incredibly complicated human being. Cellular differentiation is a critical component of this developmental process; aside from a few unique examples largely within immune cells to eliminate portions of DNA code during the generation of both T-cell receptor and antibody diversity, typical



**Fig. 6.2** Single nucleotide polymorphism (SNP) genotyping as illustrated by an Endpoint fluorescence scatter plot. During an Endpoint genotyping experiment, DNA from different individuals is amplified in separate wells to generate millions of copies of the portion of DNA that contains the SNP of interest using polymerase chain reaction methodology. During this amplification process, one- or two-colored fluorescent signal(s) accumulate in each well based on whether an individual being studied has inherited two identical copies of the SNP allele (homozygous; only one color accumulates in the well) or two different SNP alleles (heterozygous; two colors accumulate in the well) for the SNP being tested. Each triangle on the plot represents one individual being tested and the individual's genotype is determined based on the location of the symbol for that person on the scatter plot. For example, this is a plot for the catechol *O*-methyltransferase gene SNP, rs6269, which is important in pain perception. The genotype for individuals indicated by the green triangles is GG, the genotype for the individuals marked by the red triangles is AG, and the genotype for the individuals represented by the blue triangles is AA. The gray samples in the lower left corner of the plot are control samples that contained the genotyping reagents without DNA to check for contamination of the assay components. (From Hartsfield JK Jr et al: Pain perception following orthodontic separator placement and COMT haplotype. *J Dent Res* 93(Spec Iss B): abstract number 1674, 2014 ([www.dentalresearch.org](http://www.dentalresearch.org)).

cellular differentiation occurs completely in the absence of genetic rearrangement or mutation. Simply stated, nearly every cell within the human body contains a complete copy of the genome and therefore, different cell types and tissues within the body (e.g., bone, heart, lung, liver) take on their specific characteristics due to the expression of a particular subset of the 20,000 to 25,000 genes present within each cell. Some of the types of polypeptides that a cell

may synthesize during the process of lineage determination and the establishment of specialized cellular function(s) include: enzymes, which catalyze various activities of cellular metabolism and homeostasis; structural proteins, which form the intracellular and extracellular scaffolding or cellular matrix; and regulatory proteins, which convey signals from the outside of the cell to the nucleus and modulate or control specific gene expression. In a developing



**Fig. 6.3** Genome sequencing cost in USD as estimated by the National Human Genome Research Institute. In comparison with hypothetical data reflecting Moore's law, which describes a long-term trend in the computer hardware industry that involves the doubling of "computer power" every 2 years, the progress in decreasing the costs of genomic sequencing has been spectacular. [Graph provided courtesy of The National Human Genome Research Institute; <https://www.genome.gov/about-genomics/fact-sheets/DNA-Sequencing-Costs-Data>; Accessed 9-23-2019].

embryo, cells reside in a three-dimensional environment and respond to signals from themselves (autocrine), from nearby sources (paracrine), and from anatomically distant sources (endocrine). Many of these signals are mediated by soluble molecules (either peptide or nonpeptide in origin) that bind to specific receptors (proteins) present on the surface or on the inside of cells. In addition to signals from soluble factors, cells can respond to cell-to-cell or cell-to-extracellular matrix signals.<sup>17</sup>

The action of "turning on" or "turning off" specific genes, referred to as *regulation of gene expression*, is carefully orchestrated and remains a critical element in the determination of cell specificity and tissue morphogenesis. In addition to the epigenetic regulation of a gene locus (via changes in DNA methylation status and histone modifications), specific transcription factor proteins can bind to regulatory DNA elements upstream of a gene locus to either facilitate or suppress the initiation of gene transcription. Hence, the regions upstream of a gene represent a common control point of gene expression. In the development of the craniofacial complex, there is increasing evidence regarding the role of homeobox-containing gene families that encode transcription factors. These homeodomain proteins are critical for the control of complex interactions between and among genes which are expressed relatively early in development to define such things as structural orientation (anterior-posterior axis/dorsal-ventral axis) and cell maturation.<sup>18</sup>

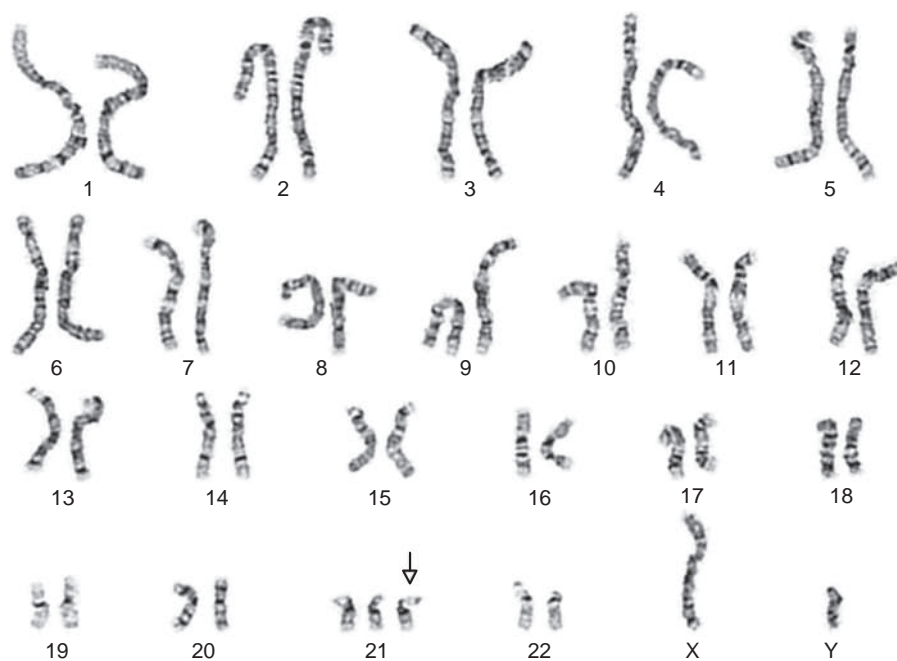
In summary:

1. The genetic instructions lie in the DNA code itself, which is transmitted from cell generation to cell generation when these DNA molecules are replicated.
2. A given cell type and/or function are defined by the specific RNA molecules made from the DNA master (i.e., mRNA, tRNA, rRNA, miRNA, and lncRNA). These RNA copies direct protein synthesis in the cell.
3. Transcription factors help to determine which genes are expressed through the production of the RNA and subsequent protein.
4. Environmental factors can influence gene expression through epigenetic mechanisms which add or remove chemical moieties from the regulatory regions of genes (such as methylation or demethylation of DNA) and/or via modification of the DNA packaging structures (i.e., histone acetylation or deacetylation). When these epigenetic markers are present in the germline DNA, they can be inherited along with the DNA sequence and may confer short- or long-term effects on gene expression.
5. Development also occurs through the action of specific transcription factors and other regulators of protein production (i.e., miRNA) on specific genes and/or their gene products which need to be expressed within a time- and/or location-specific manner.

## Chromosomal Abnormalities

As previously mentioned, DNA is grouped into units called *chromosomes*. Humans have 46 chromosomes that contain an estimated 20,000–25,000 genes, including numerous duplicates. Of the 46 chromosomes, the *sex chromosomes* are X and Y and the remaining 44 chromosomes are referred to as *autosomes*. In 1959, Lejeune and colleagues<sup>19</sup> demonstrated that the fundamental cause of Down syndrome





**Fig. 6.4** Banded karyotype of a male with trisomy of chromosome 21 (Down syndrome). (Courtesy Cytogenetic Laboratories, Indiana University School of Medicine, Indianapolis.)

is the presence of an extra copy of a specific chromosome (number 21) in the affected individual's cells. When an entire extra chromosome is present, the condition is called a *trisomy* of the chromosome in question; for example, trisomy 21 for Down syndrome. Fig. 6.4 shows the karyotype of a man who has Down syndrome. The extra chromosome in the group of number 21 is readily apparent.

Since this report in 1959, many disease states have been shown to be associated with an incorrect chromosome complement, and therefore, an incorrect number of genes. By using first the microscopic study of chromosome structure in karyotyping, and now chromosomal microarray analysis and low-pass genome sequencing, alterations in the fine structure of chromosomes can be detected in much higher resolution, as well as the number of total chromosomes that are present.<sup>20</sup> Monosomy of an autosome (i.e., the absence of one autosomal chromosome) was initially not believed to be compatible with life, but several monosomies in live-born children have now been reported. Monosomy of the sex chromosomes can be compatible with life and typically affects development of both internal and external sex organs of the individuals. The best known example of this is Turner syndrome, which occurs in approximately 1 in every 5000 live female births. These persons are phenotypic females who are usually missing one of the X chromosomes and are chromosomally designated as 45,X. Other aberrations of the X chromosome, besides complete loss, may also cause Turner syndrome. Affected individuals typically have short stature, lack secondary gender characteristics, and are sterile. Table 6.1 lists common chromosomal aberrations that produce clinical disease, including examples of translocations (the attachment of a broken piece from one chromosome to another, but not homologous, chromosome) and deletions (the absence of a piece of a chromosome).

**TABLE 6.1** Common Chromosomal Aberrations

Type	Specific Alteration	Clinical Result
Aneuploidy	Trisomy 21 Trisomy 18 Trisomy 13 Extra X chromosomes	Down syndrome Edwards syndrome Patau syndrome In females: XXX, XXXX, XXXXX syndromes In males: Klinefelter syndrome—XXY, XXXY, and XXXXY
	Monosomy, autosomal Monosomy, X chromosome	Usually nonviable In females: Turner syndrome, 45, X In males: nonviable, 45, Y
Translocation	14/21, 21/21 or 21/22	Translocation carrier (normal phenotype) or Down syndrome
Deletion	Ring chromosome	Variable
	Short arm chromosome No. 5 Philadelphia chromosome (No. 22)	Cri du chat syndrome Chronic myeloid leukemia

Chromosome abnormalities are an important cause of spontaneous abortion. About 15% of all recognized pregnancies end in spontaneous abortion (miscarriage), and the incidence of chromosome abnormalities in these is greater than 50%. Only 0.3% to 0.5% of all live-born infants have a chromosome abnormality that is detectable with microscopic karyotyping. Microdeletions and microduplications of DNA, not visible by microscopic chromosome karyotype analysis, are a major cause of human malformation and cognitive delay. A complementary analysis called *comparative genomic hybridization* (CGH) or *chromosomal microarray* (CMA) can improve the diagnostic detection rate of these small chromosomal abnormalities.<sup>21,22</sup> The technology has advanced so

far that CMA is now the American College of Medical Genetics and Genomics recommended first-tier diagnostic test for individuals with multiple congenital anomalies, developmental delay/intellectual disability, and autism spectrum disorders.<sup>23</sup> Although CMA has been extensively shown to provide a higher diagnostic yield than microscopic cytogenetic methods, initially some health insurers refused to provide coverage for this test, claiming that it was experimental and did not affect patients' clinical management. In contrast to this claim, there are data demonstrating the clinical utility of CMA.<sup>24</sup>

## Hereditary Traits in Families

Heritability is an estimate of the proportion of the total phenotypic variance within a population sample that occurs with genetic variance. A trait with a heritability of 1 is said to be expressed in the sample without any environmental influence, whereas a trait with a heritability of 0.5 has half its variability (from individual to individual in a sample) influenced by environmental factors and half by genotypic factors. Values greater than 1 may occur because the methodology provides an estimate of heritability under several simplifying assumptions that may be incorrect.<sup>25</sup> However, care should be taken not to read too much into what an estimate of heritability for any trait means. For example, on an individual basis for a binary trait (i.e., a disease or trait that an individual either has or does not have), heritability is not the proportion of disease or the trait attributable to, or caused by, genetic factors. For a quantitative trait, heritability is not a measure of the proportion of an individual's measurement attributable to genetic factors.

There is the common perception that knowing a trait's heritability will somehow affect how a patient should be treated (e.g., for malocclusion) or that it will define the limits of tooth movement or the manipulation of jaw growth. This is not true. The ability of the patient to respond to changes in the environment (including treatment), which has nothing to do with heritability, defines these limits. This does not mean that genetic factors do not play a role, but heritability estimates imply nothing about trait size or treatment limits based on a presumed genetic "predetermination."<sup>25</sup> Even so, the estimation of heritability can provide an indication of the relative importance of genetic factors on a trait in a population/group at the time of assessment. Confirming there is a certain degree of genetic influence on a trait may indicate it would be worthwhile to perform further genetic studies to determine areas of the genome that appear to be associated with the characteristics of a given trait.<sup>26</sup>

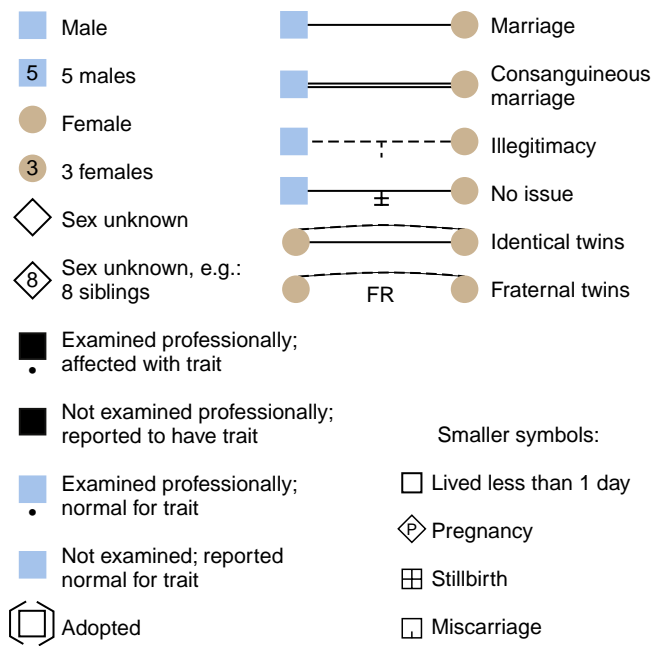
It is convenient to think of three classes of genetically influenced traits: (1) monogenic (Mendelian), (2) polygenic, and (3) multifactorial. Recently, the polygenic and multifactorial classes have often been combined into what are referred to as *complex traits*.<sup>27</sup> Monogenic traits are produced and regulated by a single-gene locus. Usually they are relatively rare in the general population (fewer than 1 per 1000 individuals). However, if the appearance of an affected person is striking, there may be instant recognition of the disease, as with patients having albinism, achondroplasia, or neurofibromatosis. Monogenetic conditions often occur in families and show transmission characteristics of Mendelian (dominant or recessive) inheritance.

Polygenic traits are also hereditary and typically exert influence over common characteristics such as height, skin pigmentation, and intelligence. This influence takes place through many gene loci collectively asserting their influence on the trait. Although each gene involved has a minimal effect by itself, the effect of all the genes involved is "additive." The associated phenotype is rarely discrete (i.e., present or absent) and is most commonly continuous or quantitative. Because these traits show a quantitative distribution of their phenotypes in a population, they do not show Mendelian inheritance patterns. It is important to note that the very nature of their influence (multiple genes, each with a relatively small additive effect) dictates that environment factors may readily influence them. For example, one can easily think of environmental factors known to influence height and intelligence quotient. In contrast, the presence of a monogenic trait is not readily amenable to large-scale environmental modification, although there can be variations, presumably secondary to other genetic and environmental/epigenetic factors.

Finally, multifactorial traits or conditions are influenced by multiple genes but differ significantly from polygenic traits in that the influence is achieved through an interaction of multiple genes and environmental factors and occurs when a liability threshold is exceeded. Although typically the number of genes involved is many, occasionally a few genes, sometimes only two or three will have the greatest influence on the trait. The effect of these genes on a phenotype trait is therefore a net effect, not necessarily a simple additive effect. Furthermore, phenotypic expression approaches that of a discrete Mendelian trait and, therefore, cannot be readily classed as a quantitative trait. Likewise, the effect of a gene influencing the phenotype may not be as great as that of a gene associated with a monogenic trait, but the gene may be referred to as having a major effect. Among the well-known hereditary types of conditions designated as multifactorial are several nonsyndromic malformations such as cleft lip and palate (CLP), neural tube defects such as spina bifida, anencephaly, and hip dislocation.

The investigation of human heritable traits usually involves the observation of specific features that occur within a family and the study of that family's family tree, referred to and drawn as a pedigree. In a family pedigree, the affected individual who first brings that family to the attention of the geneticist is called the *proband* or *propositus*. This individual can also be referred to as the index case. Brothers and sisters of the proband are termed *siblings* or *sibs*. Thus, a "sibship" consists of all the brothers and sisters in a nuclear family unit (parents and their offspring).

In an earlier section, the point is made that the full human chromosome complement has 22 homologous pairs of autosomes and one pair of sex chromosomes. Because of homologue pairing (excluding the X and Y chromosomes in the male), there are at least two copies of each gene, one located at the same position (locus) on each member of the homologous pair (Fig. 6.1). Genes at the same locus on a pair of homologous chromosomes are *alleles*. When both members of a pair of alleles are identical, the individual is *homozygous* for that locus. When the two alleles at a specific locus are different, the individual is *heterozygous* for that locus.



EXAMPLE OF SYMBOL USE  
(Marriage and Sibship)

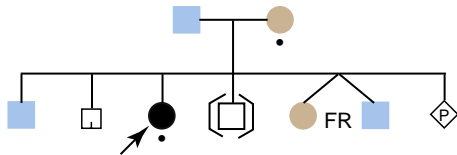


Fig. 6.5 Pedigree symbols used in family studies.

A gene allele that results in the expression of a phenotype in single dose/copy (i.e., heterozygous) is often referred to as a dominant gene allele. When the allele must be present in double dose (homozygous) to express the phenotype, it frequently can be referred to as a recessive gene allele. However, it is important to note that the *mode of inheritance* of the phenotype (and not the gene allele itself) is what is presenting as dominant or recessive. The terms *dominant gene* and *recessive gene*, though, are commonly used to describe these types of inherited traits in families.

Construction of a pedigree, which is a shorthand method of classifying the family data, conveniently summarizes these data for the study of inherited traits. The symbols used in constructing a pedigree are shown in Fig. 6.5. The observable inheritance patterns followed by such monogenic traits within families are determined by (1) whether the trait is dominant or recessive, (2) whether the gene is autosomal (on one of the autosomes) or X-linked (on the X chromosome), and (3) the chance distribution in the offspring of those genes passed from parents in their gametes (sperm and ova). Pedigree construction is a valuable tool for the clinician who is concerned with the diagnosis of and counseling regarding hereditary traits. Every dentist should be able to construct and interpret a pedigree because patients will certainly come to the dentist's office with heritable oral diseases that should be diagnosed before treatment can begin. Ideally a pedigree should go back three generations and include first-, second-, and third-degree

relatives of the proband. This may be done on a blank sheet of paper, on paper with three horizontal lines to guide the vertical spacing of the three generations, or made using software available online (e.g., the “Proband—Pedigrees Made Simple” app for iOS devices from The Children’s Hospital of Philadelphia).

The simple patterns of monogenic inheritance seen in families are described in the following discussion. Because all the Mendelian modes of inheritance can be found within spectrum of the amelogenesis imperfecta (AI) disorders, examples of different AI disorders are used in the sections that follow to illustrate basic genetic principles of inheritance.

## Developmental Biology of Enamel

Tucker and Sharpe<sup>28</sup> provided a review of how molecular biologists are studying the genetic factors involved in dental development. The two developmentally different cell layers involved in dentinogenesis, inner enamel epithelium (enamel) and neural crest (dentin), are separated by an extracellular matrix.<sup>29</sup> Specific tooth development is then mutually dependent on reciprocal cell-to-cell signaling between these two developmentally different cell layers.<sup>30</sup> The following is a discussion of genetic principles best exemplified by the heritable disorders of enamel. (Further discussion of the molecular basis of the heritable disorders of dentin and enamel is presented in Chapter 3.)

Based on clinical appearance, radiographic characteristics, and microscopic features, oral pathologists classically recognized three major types of inherited AI enamel defects: hypoplasia, hypocalcification, and hypomaturation.<sup>31</sup>

These terms also provide the general description of the disease phenotypes. For example, in the enamel hypoplasia phenotype, the enamel is hard and well calcified but defective in amount, so the teeth appear small. Two types of deficient enamel phenotypes are seen: generalized (all the enamel) and localized (pits and grooves in specific areas). A second phenotype shows hypocalcification in which the enamel matrix is so drastically altered that normal calcification cannot occur, resulting in soft enamel that easily wears away. A third phenotype is the result of hypomaturation, involving the process of maturation of the enamel crystal. This occurs after an essentially normal enamel matrix has been established. The enamel is of normal thickness (not hypoplastic) and relatively normal hardness (slightly hypocalcified) with reduced radiographic density and discoloration. One characteristic of most inherited dental defects is that both dentitions (primary and permanent) are affected. Occasionally, the defect is expressed differently in the two dentitions, as in the case of dentin dysplasia type II.<sup>32</sup> However, it is much more common to see the same clinical and radiographic picture in both dentitions. Both dentitions are typically affected to some degree in AI disorders.

A more extensive classification of different types of AI based on the phenotype, mode of inheritance and gene involved may be found by searching for AI on the “Online Mendelian Inheritance in Man” website ([www.omim.org](http://www.omim.org)), going to one of the types of AI, and then clicking on the “Phenotypic Series.” From this collection of enamel diseases, we can now select four examples of AI that illustrate



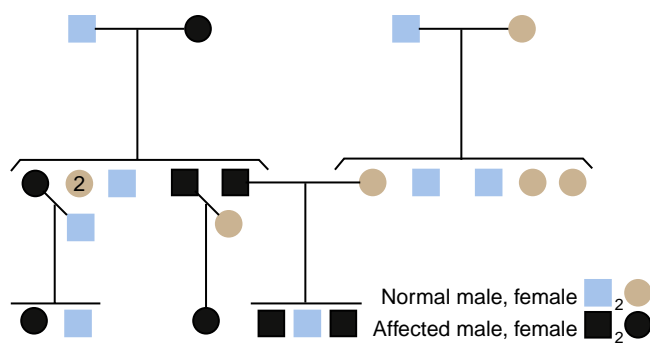


Fig. 6.6 Autosomal dominant inheritance in hypocalcified amelogenesis imperfecta.

the four major Mendelian modes of inheritance: autosomal dominant (AD), autosomal recessive (AR), X-linked dominant (XLD), and X-linked recessive (XLR).

## Autosomal Dominant (AD) Inheritance

From pedigrees such as that shown in Fig. 6.6, the following criteria for AD inheritance may be deduced:

1. The phenotype occurs in successive generations, that is, it shows vertical inheritance.
2. On average, 50% of the offspring of an affected parent will also be affected.
3. Normal parents have normal offspring. The following causes of exceptions to this rule are worth noting:
  - Nonpenetrance of the trait (defined later)
  - A mutation in either the sperm or egg
  - Germinal (gonadal) mosaicism

In this case, some of the gametes in a parent carry a DNA variation of pathological significance, but the rest do not. Chance determines which gamete cell line will be selected. However, as the molecular basis of genetic traits becomes evident, mutation analysis may show that a parent believed to be unaffected may have in some of their gametes the variation of pathological significance found in their affected child.

- Nonpaternity

Although this is not strictly a genetic problem, the illegitimacy rate in the US population is high enough to make this a possible explanation when a normal couple has a child affected with a completely penetrant dominant trait.

4. Males and females are equally likely to be affected.

The hypocalcification AI phenotype provides an example of AD inheritance. For diagnosis of this trait, several criteria are used. First, enamel matrix is susceptible to abrasion. The clinical picture is typical—gross accumulation of plaque on teeth that are hypersensitive because of the exposed dentin. Second, radiographs show enamel of various interproximal thicknesses but with a “Swiss cheese” appearance because of loss of mineral. Thus, severe abrasion of this soft enamel is common. In addition, an anterior open bite may occur in 60% of cases. Class III malocclusion may also be associated.

## Autosomal Recessive (AR) Inheritance

Recessively inherited traits require that both gene alleles at a given locus of a homologous chromosome harbor the code for producing defective proteins. Thus, of the two alleles at this genetic locus for AI, both must have variants of pathological significance to show the trait. The following three gene pairs are recognized: BB, normal; Bb, heterozygote, showing an unaffected phenotype; and bb, homozygous, affected phenotype. The most common genetic situation producing an affected child is that in which both unaffected parents are heterozygous at this genetic locus (Fig. 6.7).

The following significant points about recessive inheritance must be noted:

1. The concept of a gene carrier is used here. The carrier is heterozygous for a recessive trait because they only inherited one copy of the gene encoding the trait, and this single gene has only subtle, if any, expression by itself. Parents of an affected child are typically heterozygous (carriers) and are then interpreted as being normal. Sometimes the carrier state can be detected, as in the case of phenylketonuria or Tay-Sachs disease. In these conditions, a test is available for carrier identification to detect the presence of the single gene that has a variation of pathological significance. This greatly improves the precision of genetic counseling.
2. The rarer the gene allele that causes the recessive trait, the more likely it is that normal parents who have an affected child will be blood relatives. A mating between blood relatives is termed a *consanguineous mating*. Given that both parents who produce an AR-affected child are presumed to be heterozygotes ( $Bb \times B^*b^*$ ), only one of the four possible combinations of parents' genes (BB, Bb, bB, **bb**) result in the homozygous-affected genotype. Therefore, the recurrence risk for an affected child in this case is 25% for each pregnancy. Note that transmission of the phenotype in a pedigree is horizontal (typically present only in sibs) and not vertical as with a dominant trait.

Of several AR types of AI, the one chosen for discussion here is the pigmented hypomaturation form. In this instance, the problem probably lies in the protein needed in late tooth development to produce mature, hard, and dense enamel. The defective enamel that is present is softer than normal but not nearly as soft and easily abraded as in the hypocalcification defect. Remarkably, a brown pigment is found in these outer layers of enamel that are formed last, imparting a dark brown, unsightly appearance that necessitates restorative treatment. A pedigree illustrating AR inheritance of this hypomaturation defect is depicted in Fig. 6.7.

## X-Linked of Sex-Linked Inheritance

Genes on the sex chromosomes are unequally distributed to males and females. This inequality is the result of the following: (1) males have one X and one Y chromosome, whereas

females have two X chromosomes; and (2) the genes active on the Y chromosome are essentially concerned with the development of the male reproductive system. For these reasons, males are hemizygous for X-linked genes, meaning that they have only half (i.e., one copy) of the X-linked genes. Because females have two X chromosomes, they may be either homozygous or heterozygous for X-linked genes, just as with autosomal genes.

Interesting genetic combinations are made possible by the male hemizygous condition. Because only one gene locus of each kind in the X chromosome is represented in the male, all recessive genes in single dose express themselves phenotypically and thereby behave as though they were dominant genes. Conversely, XLR genes must be present in double dose (homozygous) in females to fully express themselves. Consequently, full expression of rare XLR diseases in practice is restricted to males and is seen infrequently in females.

To this point, we have considered heritable defects in two of the three major types of enamel disorders. The third type—AI, hypoplastic type—shows both autosomal and X-linked modes of inheritance, but only one X-linked type is described here.

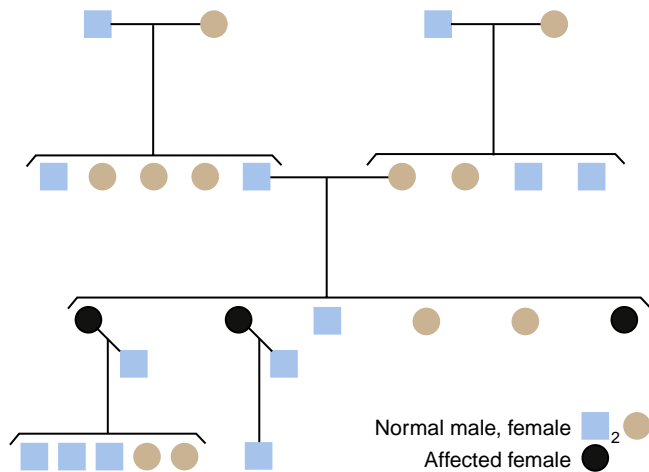


Fig. 6.7 Autosomal recessive inheritance in pigmented amelogenesis imperfecta.

### X-LINKED DOMINANT (XLD)

A pedigree of a family with the XLD form of AI, hypoplastic type, is shown in Fig. 6.8.<sup>33</sup> The clinical features are diagnostic and in some females can be quite striking. Once again, both primary and permanent dentitions are affected similarly. The surface defect is granular, lobular, or even pitted. Conceivably, all these different forms of expression are the result of the action of a single gene (or at least its alleles). The enamel is hard, but it is more susceptible to fracture and abnormal wear because of its thinness. Under appropriate conditions, this trait resembles a hypocalcification defect. However, radiographs quickly resolve this diagnostic problem and show enamel of normal density but with greatly reduced thickness. Anterior open bite may also be a common feature, as in some other types of AI.

### X-LINKED RECESSIVE (XLR)

A pedigree of a family with the XLR form of AI, enamel hypomaturational type, is shown in Fig. 6.9. The genetic criteria for diagnosing an XLR trait are summarized as follows:

1. Because the gene cannot be passed from father to son, affected fathers almost never have affected sons. A son

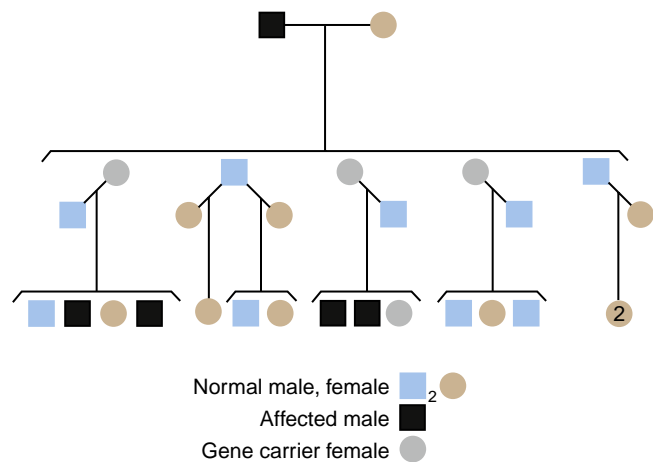


Fig. 6.9 X-linked recessive inheritance in hypomaturational amelogenesis imperfecta.

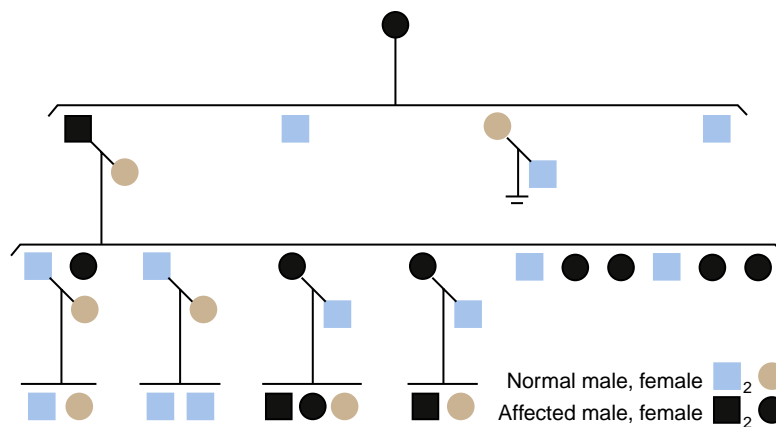


Fig. 6.8 X-linked dominant inheritance in hypoplastic amelogenesis imperfecta.

could be affected if the mother is a carrier of the XLR trait.

2. All daughters of an affected male receive his X-linked genes, making them carriers. Therefore, affected males transmit the trait to their grandsons if they are affected through their daughters.
3. The incidence of the trait is much higher in males than in females. This is typified by the disease hemophilia, which is also caused by an XLR gene.

The clinical features of XLR form of AI, hypomaturation type, are striking. The enamel has a somewhat reduced hardness but is not soft. However, the crowns of the teeth look like mountains with snow on them, hence the name “snow-capped teeth.” Radiologically, the enamel is hypomature, showing a lack of contrast between enamel and dentin even though the enamel is of normal thickness.<sup>34</sup>

It should be noted that heterozygous females occasionally show significant clinical expression of a single XLR gene. The reason for this apparent contradiction is the process of X inactivation, termed *lyonization*, after geneticist Dr. Mary Francis Lyon. This occurs only in females. All normal female cells have two X chromosomes, but most of the genes on one of the two X chromosomes are inactivated at approximately the blastula stage of development. This has the effect of making the total number of active, X-linked genes about the same in both males and females. If the female is heterozygous for an X-linked trait, two populations of cells result. One cell population has genes on one X chromosome that are active, while the other cell population has genes on the other X chromosome that are active. When by chance the X chromosome with the deleterious gene is active in a significant proportion of the cells, its expression may be observed in that female. Chance dictates that this imbalance does not occur frequently, but because all females are, by mechanism of lyonization, mosaic with regard to X-linked traits, phenotypic expression of heterozygous genes may occur in them.

The previous statements concerning the distribution of XLR genes in males and females apply equally as well to XLD genes. The principal difference lies in the fact that when the gene is dominant, more females than males will show the trait (see pedigree in Fig. 6.9). Because all XLR genes behave as dominant genes in males, no new criteria are made for their inheritance in males. The following criteria distinguish an XLD trait in families:

1. Affected males must transmit the trait to all their daughters (as with XLR traits), and all of them are affected because fathers give their X chromosome to their daughters and their Y chromosome to their sons.
2. Affected males cannot transmit the trait to their sons (just as with XLR traits).
3. Heterozygous females transmit the trait to, on average, 50% of their children of both genders, whereas affected homozygous females will have only affected children. The latter situation is exceptionally rare for a dominant trait and is practically never observed. Thus, all females affected with a dominantly inherited X-linked trait are considered to be heterozygotes until proven otherwise.

Two important points must be emphasized here. First, transmission of XLD genes by females follows a pattern

indistinguishable from that of AD transmission. Thus, these types of dominant inheritance can be differentiated only by observation of the offspring of affected males. Second, it was noted that XLR disorders are much less common in females than in males. The reverse is true for XLD traits. An XLD trait should appear about twice as often in females as in males because females have twice as many X chromosomes as males.

### AI and Nephrocalcinosis Syndrome

Although AI usually occurs as an isolated trait and not as part of a syndrome, many syndromes include AI as part of their pattern of anomalies.<sup>35</sup> One that is rare, but of clinical importance due to its potential medical significance, is AI with nephrocalcinosis, also called enamel renal syndrome (OMIM #204690, [www.omim.org](http://www.omim.org)). AR form of AI type 1G (AI1G) in the OMIM classification shows the pleiotropic effect of a variant of pathological significance in the *golgi associated secretory pathway pseudokinase (FAM20A)* gene with not only hypoplastic discolored enamel and gingival fibromatosis but also kidney disease.<sup>36</sup>

In addition to the hypoplastic enamel, other dental findings include pulp stones, delayed or failed eruption of secondary dentition, and gingival overgrowth. Since nephrocalcinosis is often asymptomatic and can be associated with impaired renal function, dentists who see children with generalized and thin hypoplastic AI should consider referral to a nephrologist for a renal ultrasound scan. Likewise, children and adults with nephrocalcinosis should be referred to a dentist.<sup>37</sup> Follow-up may be indicated since blood chemistry analyses are typically normal, and the nephrocalcinosis may not appear on renal ultrasound until later in life.<sup>38</sup>

Another pleiotropic syndrome with AI with medical significance is AR cone-rod dystrophy and AI (Jalili syndrome, OMIM #217080, [www.omim.org](http://www.omim.org)).<sup>39</sup> Jalili proposed two phenotypes: an infancy-onset form with progressive macular lesions, and an early childhood-onset form with normal fundi.<sup>40</sup> Consideration should be given by the dentist to refer a young patient with AI, particularly if they have vision difficulty to a pediatric ophthalmologist.

## Variation in Gene Expression

The patterns of inheritance in a family with several affected by traits determined by genes at a single locus are usually easy to recognize. However, many factors may modify the development of the phenotype within a family in such a way that a typical monogenic pattern of inheritance is not discernible. Although this is referred to as variation in gene expression, it can result in a variation in the amount, location, or timing of protein production. Two concepts related to how this is observed clinically are discussed here: penetrance and expressivity.

### PENETRANCE

When a person with a given genotype fails to demonstrate the phenotype characteristic for the genotype, the gene is said to show non-penetrance. In a group of individuals who have the given genotype but do not show the phenotype,



this is referred to as reduced penetrance. This is a situation most commonly seen with dominant traits, but may be with AR traits as well.<sup>41</sup> Dentinogenesis imperfecta (OMIM #125490, [www.omim.org](http://www.omim.org)), an AD trait due to variation of pathological significance in the dentin sialophosphoprotein (DSPP) gene,<sup>42</sup> is practically 100% penetrant because all individuals who carry that gene show its phenotype. van der Woude syndrome, the most common oral clefting syndrome, has AD inheritance and is associated with variation of pathological significance in the interferon regulatory factor 6 gene (*IRF6*; OMIM #119300, [www.omim.org](http://www.omim.org)) and the grainyhead like transcription factor 3 gene (*GRHL3*; OMIM #606713, [www.omim.org](http://www.omim.org)). Although the severity of the phenotype can be variable with paramedian lower pits and/or sinuses, CLP, the condition has been reported to have a penetrance of 96.7%,<sup>43</sup> indicating that approximately 3% of those who have a genetic variation of pathological significance typically associated with van der Woude syndrome show no clinical sign of it, but yet they have a 50% chance of passing on the mutation to each of their children. Reduced penetrance is a possible explanation for when a trait or syndrome that typically has AD inheritance seems to “skip a generation.”

## EXPRESSIVITY

If a single-gene trait can show different degrees of phenotypic expression in the affected members of kindred, it shows variable expressivity. In addition to the example of variable expressivity in van der Woude syndrome described above, families with osteogenesis imperfecta also provide an illustration of variable gene expression. The cardinal signs of this disease are (1) multiple fractures, (2) blue sclera, (3) dentinogenesis imperfecta, and (4) otosclerosis, which results in a hearing deficit. Each affected individual in different families and even within a single family may not show all of these features, which illustrates the considerable variation in gene expression.<sup>44</sup> The minimum expression of the gene observed in a family might then be only a blue color to the sclera, which could be unnoticed by the clinician. In this case, highly variable gene expression may fade into non-penetrance.

Many craniosynostosis syndromes are AD traits associated with single-gene variations of pathological significance.<sup>45</sup> They also provide good examples of how the phenotype can vary markedly, even with the strong influence of a single gene. Although a particular mutation in a given gene was considered to always result in a specific syndrome, several identical mutations in the fibroblast growth factor receptor 2 (*FGFR2*) gene have been found in patients diagnosed with the three different clinical craniosynostosis syndrome entities of Crouzon, Pfeiffer, and Jackson-Weiss syndromes.<sup>46,47</sup>

Another example of variable expressivity observed with a single-gene AD phenotype was documented when two individuals in the same family were diagnosed with the classic phenotypes of Pfeiffer and Apert syndromes. Upon closer examination, seven other family members had unusually shaped heads and facial appearance reminiscent of Crouzon syndrome.<sup>48</sup> The phenotype may be so variable that the individual may appear to be clinically normal, yet have the same gene variation of pathological significance associated

with Crouzon syndrome in three of his children and two of his grandchildren. Only through the analysis of radiographic measurements was a minimal expression of features suggestive of Crouzon syndrome evident.<sup>49</sup>

## EPIGENETICS

The influence of one or more modifying genes through their protein products in reducing or enhancing the effect of another gene is referred to as *epistasis*. *Epigenetics* refers to changes in gene expression which are not caused by an alteration in the sequence of the gene. Examples of epigenetics include gene expression that is altered due to DNA methylation and/or histone acetylation, and by inhibition of mRNA translation by interfering RNA or miRNA binding.<sup>50</sup> Although monozygotic (identical) twins are epigenetically similar during the early years of life, older monozygous twins may exhibit remarkable differences in their overall content and genomic distribution of 5-methylcytosine DNA and histone acetylation, which can create differences in gene expression between the twin pairs.<sup>51</sup> These epigenetic factors can help explain the relationship between an individual's genetic background, the environment, diet, exercise, aging, and disease. It can do so because the epigenetic state varies among tissues and during a lifetime, and may be inherited if present in the sperm or ova, whereas the DNA sequence remains essentially the same. As cells adapt to a changing internal and external environment, epigenetic mechanisms can “remember” these changes in the programming and reprogramming of gene expression.<sup>52</sup> This is leading to a new way of thinking about how the genome and environment interact, with a tremendous impact on the study of developmental biology, cancer, and other diseases.

## Complex/Multifactorial Inheritance

The following features typify the inheritance of “complex” traits in contrast to monogenic inheritance: (1) multiple genes (polygenes) at different loci are involved in expressing the phenotype, and (2) the phenotype produced is a summation of the effects of polygenes interacting with their environment. The phenotypic result is often a continuously varying spectrum of that trait (e.g., height) rather than presentation as a discrete (trait present or absent) phenotype. As already mentioned, if the presentation is a discrete trait, such as overt cleft lip, then the complex trait is not expressed unless the etiological factors combine to exceed a threshold after which the trait is expressed (although an underlying susceptibility may be present in unaffected relatives).

Many common diseases, such as dental caries, have a continuous spectrum of variation with no sharp distinction between normal (average) and abnormal (extremes). However, there may be a specific measurable point beyond which that disease is arbitrarily regarded by the clinician as abnormal.

The inheritance of complex traits is difficult to analyze genetically; in fact, geneticists often arrive at a diagnosis of complex/multifactorial inheritance for a given trait only after the monogenic forms of inheritance have been

considered and found to be unlikely. Certain techniques for studying complex traits have been developed. The simplest method involves studying the resemblance between relatives, which states that the more closely related two individuals are, the more closely they resemble each other concerning the specific trait in question. However, it is important to stress on the continuous phenotypic variation that is characteristic of inheritance patterns resulting from many genes (polygenes).

This issue of continuous variation is emphasized because the most common diseases with which the dentist must deal (i.e., periodontal disease, dental caries, and malocclusion) are traits with a complex and heterogeneous etiology. Only the extremes of variation are readily apparent to the dentist, such as in the child with rampant caries or the adult who is caries-free. In this latter instance, if one did not understand the concept of complex traits, one might conclude that such individuals represent a discrete phenotype influenced by a single gene in a Mendelian manner. This is usually not the case.

The most important feature of traits produced by polygenes is that they are susceptible to environmental modification. A phenotype resulting from the concerted action of 100 genes is much more likely to be altered and modified by the existing environment than a trait strongly influenced by only one or even several genes. Even so, this does not mean that a trait resulting from only one or even several genes cannot be influenced by environmental/epigenetic factors. The change in phenotype depends on the individual's ability to respond to the environmental factor, which may be heavily influenced by the same gene(s) originally influencing the phenotype or by other genes.

An example of a polygenic trait that is markedly influenced by environmental factors is dental caries, which is the interaction product of three essential factors: a cariogenic diet, a caries-producing bacterial flora, and a susceptible tooth. These three factors encompass a variety of biologically complicated entities, such as saliva, plaque, immune response, tooth matrix formation, and crystallization. The development of these complex elements involves many genes. Environmental modification, such as properly timed systemic fluoride supplementation, produces a considerable alteration in the phenotype without changing the genome of the individual. The reader can probably think of additional environmental modifications that can produce a greatly altered dental caries experience without changing an individual's genome. Some conditions that are attributed to a complex/multifactorial inheritance because they tend to occur in families may be greatly influenced by a gene (or genes) that predispose to the condition, depending on the other genetic or environmental factors involved.

In contrast to so-called simple monogenic traits, whose characteristics have been summarized in preceding paragraphs, complex/multifactorial traits/diseases show the following characteristics:

1. Each person has a liability for a given trait, malformation, or disease, and that liability represents a sum of the genetic and environmental liabilities.
2. The multifactorial-threshold model is a mathematical way of expressing these liabilities. For polygenic traits, the model is illustrated as a Gaussian curve. As already

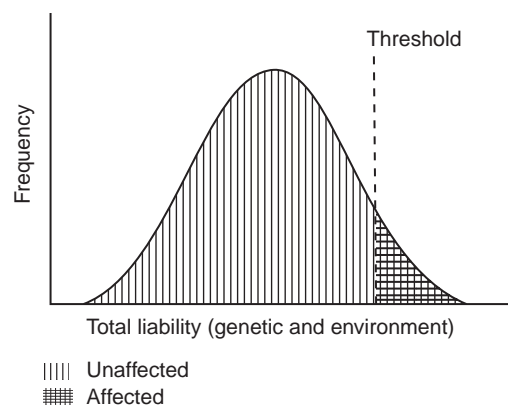


Fig. 6.10 Multifactorial model for inheritance of cleft lip and palate.

noted, for multifactorial traits, a threshold must be added to allow the continuous polygenic model to be used in describing noncontinuous or discrete traits. For many human malformations, a multifactorial model with threshold is appropriate for describing discrete traits such as CLP. Such a threshold means that all persons with sufficient gene dosage and environmental interaction will be above the threshold of expression and show the cleft lip, whereas those with less will not show the cleft lip. A graphic representation of this idea is shown in Fig. 6.10.

3. Because of the different dosages of polygenes in groups that show a specific phenotype (e.g., CLP), the overall incidence of this trait will vary in near-relatives of those affected. For example, a dominantly inherited trait has a gene dosage of one in two (50%). Assuming that several polygenes may be involved in CLP, this figure decreases at least 10-fold to about 1% to 5%. The incidence in a random population is even lower—about 1 per 1000. Therefore, increasing gene dosage for a multifactorial complex trait in a family is associated with an increased incidence of that trait in near-relatives of the affected individuals. The nature of this system with a threshold permits large numbers of persons at risk for showing that phenotype (CLP) to carry the liability for clefting without expressing it clinically.

Toward the end of the 19th century, Galton recognized that twins could be useful for evaluating the nature versus nurture argument (genetics-environment/upbringing) that was raging at that time. In the 20th century, the twin method for study of the relative importance of heredity and environment in humans became a mainstay. One explanation for this interest is that many human traits are complex and susceptible to environmental modification and are, therefore, difficult to study by conventional methods. The twin method allows such traits to be studied based on the principle that human twins are of two basic types: monozygotic (or identical) twins, resulting from a single ovum fertilized by a single sperm, and dizygotic (or fraternal) twins, resulting from fertilization of two ova by two sperms. It is self-evident that monozygotic twins have identical genotypes, whereas dizygotic twins are no more closely related to each other than they are to any two non-twin siblings.<sup>53</sup> It also follows that differences between monozygotic twins result from environmental/epigenetic differences, whereas

differences between dizygotic twins result from differences in both heredity and environment/epigenetics.

To use the twin method, one must distinguish between the two types of zygosity. If both twins are identical for the trait in question (regardless of their zygosity), they are described as *concordant*. If they are unlike for the trait, they are *discordant*. Such intrapair differences are usually expressed in percentage figures for a group of twins being evaluated. For example, monozygous twins show a 33% concordance for CLP, whereas dizygous twins show only a 5% concordance. The concept of estimating heritability comes from the study of the concordance of a trait in twins.

Another method to estimate the heritability of a trait and to evaluate the evidence of linkage of a phenotype with DNA polymorphisms is by sib-pair analysis. Heritability estimates can be generated from within- and between-sibship variance quantified by generalized linear models, with confounding factors controlled for where indicated. Polymorphic DNA markers may be tested for genetic linkage (proximity) to a gene influencing a phenotype by testing whether the magnitude of the phenotypic difference between two siblings is correlated with the alleles they share that are identical by descent (IBD). An allele is IBD if both members of a sibling pair inherited the same marker allele from the same parent. If a marker is linked to a gene contributing to the phenotype in question, then siblings with a similar (if quantitative) or the same (if discrete) phenotype would be expected to share more alleles IBD, whereas siblings with widely differing phenotypes would be expected to share few, if any, alleles IBD near any gene(s) influencing the phenotype.<sup>54</sup> In addition, another method of looking for DNA markers is by linkage disequilibrium or association analysis. In its simplest terms, this refers to a nonrandom association of alleles at two or more loci (i.e., they travel together in the genome). It was found that some sections of DNA do not tend to change through generations, in what are called *haplotype blocks*. Therefore, testing one SNP within each block for significant association with a disease or trait is possible when an influencing locus for that disease or trait is located in or at least close to that haplotype block.<sup>55</sup> Partly because these haplotype blocks occur in populations, these analyses can be performed on unrelated individuals (affected and controls) as opposed to linkage analyses in related individuals.

However, if the control individuals are from a different genetic background than the affected individuals, there may be a bias. One way to deal with that problem is to use the quantitative transmission disequilibrium test (TDT). This analysis calculates the difference between the value of the quantitative trait in the offspring and the average value of the quantitative trait in all offspring in all families studied, while simultaneously considering the allele transmission from parent to offspring.<sup>56</sup> Thus, the sib-pair linkage analysis involves two or more siblings, and the quantitative TDT involves trios of parents and one or more siblings.

As mentioned previously, there is now a shift towards investigating familial traits by performing WGS, or sequencing of only the parts of the genome that codes for proteins and regulatory RNAs (WES) of DNA from the affected and unaffected family members.<sup>14</sup> With the development of increasingly sophisticated statistical analysis and bioinformatics based upon biological databases and clinical insight, significant findings may even be identified in an individual

who is not studied in the context of their family.<sup>57</sup> This application of WES and big data analytics will advance the field of personalized (precision) healthcare.<sup>58</sup>

## Influence of Genetic Factors on Major Cranofacial, Oral, and Dental Conditions

### GENETICS AND DENTAL CARIES

Based on several dietary studies, variation in susceptibility to dental caries clearly exists even under identical, controlled conditions.<sup>59</sup> This implies that, because of genetic differences, certain environmental factors are potentially more cariogenic for some people than for others. This is not to say that dental caries is an inherited disease; rather, genetic influences may modify the overt expression of this disease in the individual.

About 50 years ago, dental caries was presented to dental students as a disease that was so common that more than 99% of the general population was afflicted with it. Although it is still recognized as a common disease, the use of systemic and topical fluorides and persistence by organized dentistry to bring about changes in dietary habits and oral hygiene practices have significantly contributed to the remarkable decrease in the prevalence of this disorder, especially in children. Currently, it is not unusual for a prepubertal child to be caries-free. Yet, there remains individual variations in caries that are not fully explained by hygiene or fluoride exposure.

Three essential interacting elements comprise the model system for dental caries that is most commonly used to discuss its etiology: microorganisms, substrate (fermentable carbohydrates), and host factors such as tooth anatomy, salivary composition, and immune response. It is in the last area—host factors—that genetics exerts a major influence on dental caries initiation.

Several investigators have studied the genetic aspects of dental caries in humans using twin, family pedigree, and population approaches. Because dental caries is an age-dependent process, much of the reported data cannot be compared because of age differences in the various population groups studied. Nevertheless, the family observations by Klein and Palmer<sup>60</sup> and Klein<sup>61</sup> are worth noting. Their findings indicated that children have a caries experience remarkably similar to that of their parents when the susceptibility of both parents is the same (either high or low). However, when caries susceptibility of the two parents is dissimilar, the children's susceptibility tends to be more like that of the mother than that of the father. This finding was particularly evident in daughters.

Because dental caries is an infectious communicable disease, familial clustering may, to some degree, reflect familial environmental contact, with transmission of cariogenic bacteria to children at certain ages. Li and Caufield<sup>62</sup> found that mothers are the principal source of *mutans streptococci* in their infants, with a greater rate of transmission to female than male infants. Furthermore, the association of maternal salivary bacterial challenge (*mutans streptococci* and *lactobacilli*) from pregnancy through 24 months postpartum



is associated with not only oral infection among children but also their caries incidence (one or more cavitated or restored teeth) at 36 months.<sup>63</sup> The more common a trait is, the more difficult it is to demonstrate its genetic character if present. Several authors have attempted to do this for dental caries by studying twins. Book<sup>64</sup> attempted to maximize differences in caries experience within families by selecting caries-free 20-year-old men and comparing caries experience within their families.<sup>64</sup> Results showed that parents and siblings of caries-free propositi had significantly lower rates of decayed, missing, and filled teeth than did the control families. The authors concluded that the observed differences are hereditary, which is most likely polygenic in nature.

Studies of twins conducted by Dahlberg and Dahlberg,<sup>65</sup> Mansbridge,<sup>66</sup> Horowitz et al.,<sup>67</sup> Caldwell and Finn,<sup>68</sup> and Bretz et al.<sup>69</sup> indicated that genetic factors make a significant contribution to individual differences in caries susceptibility. However, most authors agree that this genetic component of dental caries is overshadowed by the overall effect of environmental factors in most individuals. Although it appears that genetic factors significantly contribute to the colonization of specific oral bacteria,<sup>70</sup> or to the levels of *Streptococcus mutans* specifically,<sup>70</sup> the conclusion from clinical twin and familial correlation studies and estimations from heritability studies regarding the degree of genetic influence on caries may be confounded by familial factors such as oral hygiene habits, diet, and the already-mentioned transmission of cariogenic bacteria within the family.

The foundation for seeking different individual susceptibilities to caries is based on animal studies. Hunt et al.<sup>71</sup> succeeded in establishing caries-resistant and caries-susceptible strains of rats using inbreeding techniques. Although the resistant strain was challenged by oral inoculation of cariogenic bacteria, the resistant phenotype was maintained. These were the first studies to confirm the presence of important genetic elements influencing dental caries susceptibility.

A review of inherited risks for susceptibility to caries found evidence of an association between altered dental enamel development in defined populations and an increased risk of caries, as well as a relationship between host immune complex genes and different levels of cariogenic bacteria and enamel defects.<sup>72</sup> This was further supported by the finding of a significant interaction between tuftelin (*TUFT1*) SNP genotypes and *S. mutans* levels,<sup>73</sup> and by variation in the amelogenin (*AMELX*) gene and caries susceptibility.<sup>74</sup> Thus the individual's genotype may influence the likelihood of intraoral colonization of cariogenic bacteria, which further exemplifies the complexity of caries development. Genetic studies on well-characterized populations with clearly defined caries experience will help define those host factors with the greatest influence on the incidence of caries.<sup>64</sup>

For example, GWAS for dental caries focused on the primary dentition in children aged 3–12 years and implicated several novel genes: actinin alpha 2 (*ACTN2*), EDAR-associated death domain (*EDARADD*), EPH receptor A7 (*EPHA7*), lactoperoxidase (*LPO*), metallophosphoesterase domain containing 2 (*MPPED2*), 5-methyltetrahydrofolate-homocysteine methyltransferase (*MTR*), and zinc metallopeptidase STE24 (*ZMPSTE24*).<sup>75</sup> Subsequent investigation has corroborated the influence of the *MPPED2* and

*ACTN2* genes on caries risk. The role of *ACTN2* in organizing ameloblasts during amelogenesis supports the hypothesis of its involvement in caries risk.<sup>76</sup> The enamel gene (*ENAM*) has also been implicated as a factor in caries susceptibility.<sup>77</sup> An indication that different genes may influence caries activities across the surfaces of the permanent dentition was found by a GWAS suggesting *BCL6* corepressor (*BCOR*) and inhibin subunit beta A (*INHBA*) to be factors in pit-and-fissure caries, while *BCL6* corepressor like 1 (*BCORL1*), C-X-C motif chemokine receptor 1 (*CXCR1*), and C-X-C motif chemokine receptor 2 (*CXCR2*) are factors in smooth surface caries.<sup>78</sup> Further studies to define the genes involved, which may be related, for example, to salivary flow, plaque formation, and diet preferences, are in progress. Bretz et al.<sup>79</sup> found that genetic factors contributed independently to both dental caries and sucrose sweetness preference,<sup>79</sup> although it is likely that an increased preference for sweets would affect the caries rate.

Further examples of the complexity of the genetic influences on dental caries can be found in a systemic review of host genetic factors in the pathogenesis of caries and periodontal disease,<sup>80</sup> and a genome-wide analysis of dental caries and periodontitis combining clinical and self-reported data that identified 47 novel and conditionally independent risk loci for dental caries. Interestingly, a study conducted later found evidence suggesting that processes contributing to dental caries may have undesirable downstream effects on health.<sup>81</sup>

In summary, susceptibility to human dental caries is influenced to a significant, but variable, degree by genetic factors in most individuals.<sup>82</sup> This genetic influence is undoubtedly complex and strongly implies considerable environmental influence. However, there are likely individuals in whom the genetic susceptibility is markedly greater than that in most of the population. Specific types of dental caries susceptibility representing the extreme variations of this trait may ultimately prove to be monogenic or major gene traits, but currently the evidence is insufficient for a clear statement of such inheritance.

## Genetics and Periodontal Disease

The periodontal disease state is often described as a local inflammatory disease with possible underlying systemic factors. One might visualize a continuum of disease expression ranging from localized gingivitis to generalized periodontitis with severe bone and tooth loss. Such a complex disease shows both inflammatory and degenerative pathologic features. Forms of the disease previously recognized as “chronic” or “aggressive” are now referred to as periodontitis with a staging and grading system. The staging (I to IV) is largely dependent upon the severity of disease at its presentation as well as on the complexity of disease management. Grading provides supplemental information about biological features of the disease. These include a history-based analysis of the rate of disease progression (A slow, B moderate, C rapid), and the presence of modifiers such as diabetes and smoking.<sup>83</sup>

A carefully designed study of twins with periodontal disease was reported by Ciancio et al. (1969).<sup>84</sup> Using the Ramfjord index, which evaluates gingival inflammation,

calculus formation, tooth mobility, and tooth loss in all four quadrants of the mouth, the authors examined 7 monozygotic and 12 dizygotic pairs of teenaged twins. They concluded that there was no evidence in these twins for significant heritability of any of these dental parameters.

Alternatively, Michalowicz et al.<sup>85</sup> published a large study (63 monozygotic and 33 dizygotic pairs) of adult twins (mean age, 40 years). Using elements of the Ramfjord index as criteria for diagnosis, they calculated heritability estimates. The authors state that 38%–82% of the periodontal disease identified in these twins was attributable to genetic factors.

Investigation by Kornman et al.<sup>86</sup> into the association of different polymorphisms of inflammation mediating genes and periodontal disease in adult nonsmokers indicated that interleukin 1 $\alpha$  and 1 $\beta$  (IL-1 $\alpha$  and IL-1 $\beta$ ) genotypes may be a risk factor.<sup>86</sup> The IL-1 $\beta$  polymorphism was IL-1 $\beta$  + 3953, originally IL-1 $\beta$  + 3954 (SNP identifier rs1143634) and the IL-1 $\alpha$  polymorphism was IL-1 $\alpha$  -889. Nonsmokers aged 40–60 years carrying the “2” allele (in either the homozygous or the heterozygous state) at both loci were observed to have nearly 19 times the risk of developing severe periodontitis as did those homozygous for the “1” allele at either or both of these loci. However, this association has been seen in other,<sup>87</sup> but not all, populations.<sup>87–90</sup> Greenstein and Hart<sup>91</sup> noted that the relationship of specific IL-1 genotypes and the level of crevicular fluid IL-1 $\beta$  is not clear, and that the ability of the genetic susceptibility test for severe chronic periodontitis, based on the findings of Kornman et al.,<sup>86</sup> to predict which patients will develop increased bleeding on probing, periodontitis, loss of teeth, or need for dental implants is ambiguous. Later the application of IL-1 genotype, the presence of diabetes, and a history of smoking were proposed as factors to predict the risk of tooth loss as a guide for the scheduling of preventive care.<sup>92</sup> However, subsequent analysis questioned the validity of this method to inform the clinical treatment of patients.<sup>93,94</sup> This illustrates the complexity of genetic association studies and questions the validity of when genetic counseling is based on a marker that accounts for only a portion of phenotypic variation.<sup>95,96</sup>

A genome-wide scan for chronic periodontitis found suggestive evidence of association for six genes, including nin-ein (*NIN*), neuropeptide Y (*NPY*), and Wnt family member 5A (*WNT5A*) for severe chronic periodontitis, and natural cytotoxicity triggering receptor 2 (*NCR2*), adhesion G protein-coupled receptor E1 (originally termed *EMR1* renamed *ADGRE1*), and chromosome location 10p15 for moderate chronic periodontitis. Inclusion of smoking data along with the genetic analysis increased the heritable variance in severe chronic periodontitis from 18% to 52%, confirming smoking as an environmental causative factor that may act in addition to inherited susceptibility genes.<sup>97</sup>

Progress has been made in the study of rare genetic conditions or syndromes that can predispose to periodontal disease or have periodontal disease as a relatively consistent component of their pleiotropic effect. For example, leukocyte adhesion deficiency (LAD), type I and type II, are AR disorders of the leukocyte adhesion cascade.<sup>98</sup> LAD type I has abnormalities in the integrin receptors of leukocytes resulting from mutations in the  $\beta 2$  integrin chain

(*ITG $\beta 2$* ) gene, leading to impaired adhesion and chemotaxis, which result in increased susceptibility for severe infections and early-onset periodontitis.<sup>99,100</sup> LAD type II is also an AR disorder secondary to mutation in the solute carrier family 35 member C1 (*SLC35C1*) gene encoding a GDP-fucose transmembrane transporter (FucT1) located in the Golgi apparatus. The infectious episodes and the severity are much milder than those observed in LAD type I, and the only persistent clinical symptom is chronic severe periodontitis. The exact defect in the system is absence of the sialyl Lewis x (SleX) structure antigens, which are important ligands for selectin on the leukocyte, leading to a profound defect in leukocyte rolling, the first step in the adhesion cascade. This causes a marked decrease in chemotaxis, accompanied by pronounced neutrophilia. Apart from the leukocyte defect, these patients suffer from severe growth and cognitive delay and exhibit the rare Bombay blood group type.<sup>98</sup>

Ehlers-Danlos syndrome (EDS) is a collection of connective tissue disorders which are divided into 10 types distinguished on the basis of clinical symptoms and inheritance patterns. In addition to consistent early-onset periodontal disease, patients with EDS type VIII have variable hyperextensibility of the skin, ecchymotic pretibial lesions, minimal bruising, minimal to moderate joint hypermobility of the digits, and “cigarette paper” scars. Inheritance is AD. Early-onset periodontal disease may also be found in patients with EDS type IV (vascular type). These individuals are usually characterized by type III collagen abnormalities with hyperextensibility of the skin, ecchymotic pretibial lesions, easy bruisability, cigarette paper scars, joint hypermobility of digits, pes planus, and, of greatest concern, arterial and intestinal ruptures. Individuals with type IV, like those with type VIII, also have AD inheritance.<sup>101</sup> Although there is considerable overlap in phenotype of these two types (IV vascular and VIII periodontal),<sup>102</sup> mutations in collagen type III alpha 1 chain (*COL3A1*) gene are found in the vascular type consistent with the abnormal collagen type III biochemical findings,<sup>103</sup> whereas mutations in the complement C1r (*C1R*) and complement C1s (*C1S*) genes that encode subcomponents C1r and C1s of complement have been found in the periodontal type 1 and periodontal type 2, respectively.<sup>104</sup>

Chédiak-Higashi syndrome has frequently been linked with severe periodontitis.<sup>100</sup> This rare AR disorder is characterized by oculocutaneous hypopigmentation, severe immunologic deficiency with neutropenia and lack of natural killer cells, a bleeding tendency, and neurologic abnormalities. It is caused by mutations in the lysosomal trafficking regulator (*CHS1/LYST*) gene.<sup>105</sup>

Papillon-Lefèvre syndrome and Haim-Munk syndrome are two of the several different types of palmoplantar keratoderma, differing from the others by the occurrence of severe early-onset periodontitis with premature loss of the primary and permanent dentition. Moreover, Haim-Munk syndrome is characterized by arachnodactyly, acroosteolysis, and onychogryphosis.<sup>106</sup> Hart et al.<sup>107</sup> have shown that both of these AR syndromes are due to different mutations in the cathepsin C (*CTSC*) gene. In addition, aggressive periodontitis-1 is caused by a homozygous mutation in *CTSC*.<sup>108,109</sup>

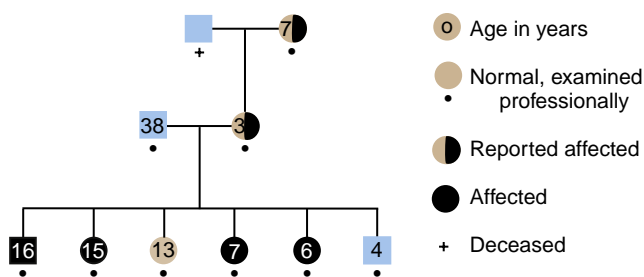


Fig. 6.11 Pedigree of family with localized aggressive periodontitis.

### AGGRESSIVE PERIODONTITIS (STAGE III GRADE C, RAPID RATE OF PROGRESSION)

Aggressive periodontitis has been documented in the primary dentition, may develop during puberty affecting the permanent dentition (has been referred to as prepubertal periodontitis), and is characterized by exceedingly rapid loss of alveolar bone. Along with hypophosphatasia, aggressive periodontitis appears to be the most commonly encountered cause of premature exfoliation of the primary teeth and may also result in the loss of permanent teeth (Fig. 6.11).<sup>101</sup>

Aggressive periodontitis has the following features:

1. An early onset of the breakdown of periodontal bone.  
This bone loss is of two types: usually a localized form in which the molar or incisor regions of bone are the most severely affected, or a generalized form affecting any dental area.
2. Bone destruction that is rapid and vertical, with specific microorganisms associated with the periodontal lesion.
3. Familial aggregation, especially in the localized form.  
It may be that the generalized and localized types represent two different aspects of the same disorder. The localized aggressive periodontitis shows a characteristic molar/incisor pattern.
4. Increased incidence in African Americans.

Because several forms of what was termed early-onset periodontitis (aggressive periodontitis) can be found in the same family, the expression of the underlying genetic etiology appears to have the potential to be influenced by other genetic and or environmental factors.<sup>110</sup>

Evaluation of the same IL-1 $\alpha$  and IL-1 $\beta$  polymorphisms found by Kornman et al.<sup>86</sup> to be associated with periodontitis in adult nonsmokers was performed by Diehl et al.<sup>111</sup> in African American and Caucasian families with two or more members affected with early-onset periodontitis. Interestingly, they found the IL-1 alleles associated with high risk of early-onset periodontitis to be the ones suggested previously to be correlated with low risk for severe adult periodontitis. They concluded that “early-onset periodontitis” is a complex, oligogenic disorder (i.e., involving a small number of genes), with IL-1 genetic variation having an important but not exclusive influence on disease risk. As previously noted, aggressive periodontitis-1 (OMIM #170650, [www.omim.org](http://www.omim.org)) is caused by a variation of pathological significance in the cathepsin C gene (*CTSC*; chromosome 11q14.2), which is also involved in Papillon-Lefèvre syndrome and Haim-Munk syndrome, while aggressive periodontitis-2 (OMIM #608526, [www.omim.org](http://www.omim.org)) has been mapped to a different chromosomal location

(1q25).<sup>107,112,113</sup> GWAS found that the rs4284742 SNP located at chromosome19q13.41 in the sialic acid binding Ig like lectin 5 (*SIGLEC5*) gene is associated with aggressive periodontitis, and both the defensin alpha 1 and alpha 3, variable copy number locus (*DEFA1A3*) and *SIGLEC5* genes were associated at a genome-wide significance level in pooled aggressive periodontitis and chronic periodontitis data, suggesting that although heterogeneity exists, there may be some common genetic factors between the two clinical designations.<sup>114</sup> The separation of aggressive and chronic periodontitis as two separate diseases is not supported by current studies; however, the wide variation in clinical presentation in regard to extent and severity regardless of age suggests that there are groups with distinct disease trajectories due to differences in exposure and or susceptibility.<sup>83</sup> Interestingly, siglecs may be important for recognizing “self” tissues in the form of sialic acid and inhibiting activation of the natural immune system.<sup>115</sup> The association of the *SIGLEC5* gene (rs12461706) with a periodontitis/loose teeth phenotype was also supported by a report on a larger data set.<sup>81</sup>

### Genetics of Malocclusion

The study of occlusion pertains to relationships between teeth in the same dental arch as well as between the two dental arches when the teeth come together. Many factors are involved in the definition of normal occlusion. Some of the most important orofacial parameters of occlusion are airway function, soft tissue anatomy and function, size of the maxilla, size of the mandible (both rami and body), arch form, anatomy of teeth (including malformation), agenesis of teeth, and rotation of teeth. All these important elements must be included in the concept of occlusion.

Malocclusion is perhaps somewhat easier to define. One may simply say that malocclusion is a significant deviation from normal occlusion. However, this description is useful only if one considers the multiple aspects implicit in such a definition. Normal occlusion and malocclusion are dynamic concepts that involve the interrelationships of many factors, not a few of which have been shown to be influenced by genetic factors. Genetic influences on each occlusal trait are rarely due to only a single gene, which would be necessary for malocclusion to be due to the simple inheritance of discrete skeletal and dental characteristics. Instead, malocclusions are often polygenic with the potential for environmental influence and are therefore complex traits. Even though we will focus on genetic factors, it should always be remembered that malocclusion can be greatly or even predominantly influenced by environmental factors, particularly for occlusal variables. It has been suggested that the rapid increase in malocclusion in indigenous Australian people was produced by dietary factors concurrent with industrialization, emphasizing the importance of environmental influences on occlusal variation and the variability of apparent genetic determinants with respect to the environment or population in which they are measured.<sup>116–118</sup> Likewise Kawala et al.,<sup>119</sup> after studying the concordance of malocclusion in twins, showed that the distribution of within-pair malocclusions depended upon the gender of



the individuals, and supported the impact of environmental factors.

Theoretically, there are two general ways in which predisposing or causative factors for malocclusion could be due to heritable characteristics.<sup>120</sup> One would be inheritance of a disproportion between the size of the teeth and the jaws, resulting in crowding or spacing issues. Posterior and/or anterior Bolton discrepancies are defined as a disproportion among the sizes of individual teeth between the two arches. To achieve good occlusion with the ideal overbite and overjet, the maxillary and mandibular teeth must be proportional in their mesial-distal dimensions. If some teeth are not proportional, there could be crowding, spacing issues, and/or an effect on overbite and/or overjet even if the arches are in a favorable relationship. Certainly, hypodontia as well as the often-associated smaller size of teeth that are often agenetic or other teeth can contribute to malocclusion. This is particularly evident in patients with hypodontia or even oligodontia, which may occur spontaneously or be part of a syndrome such as hypohidrotic ectodermal dysplasia, which can be caused by mutations in the *EDA* gene. Other mutations in the same gene may cause non-syndromic dental agenesis; in a Hong Kong Chinese Class I malocclusion sample, variations in the *EDA* gene and the gene for its receptor, *XEDAR*, have been associated with dental crowding greater than 5 mm.<sup>121</sup> Several other genes in addition to *EDA* and *XEDAR*, associated with syndromic or nonsyndromic hypodontia/oligodontia, including *msh* homeobox 1 (*MSX1*), paired box 9 (*PAX9*), *AXIN2*, Wnt family member 10A (*WNT10A*), and latent transforming growth factor beta binding protein 3 (*LTBP3*) (see [Chapter 3](#)), could also contribute to variations in tooth size in general or for specific teeth.

The other general way in which predisposing or causative factors for malocclusion could be due to heritable characteristics would be inheritance of a disproportion in the position, size, or shape of the mandible and maxilla. Note that the influence on bony morphology could be secondary to heritable effects, including those on the cartilage, collagen, muscle fibers, other connective tissue components, and growth factors. For example, in a study conducted by Yamaguchi et al.<sup>122</sup> on the association of the Pro561Thr (P56IT) variant in the growth hormone receptor (*GHR*) gene with craniofacial measurements on lateral cephalometric radiographs, it was found that individuals without the *GHR* P56IT allele had a significantly greater mandibular ramus length (condylion-gonion) than those with the *GHR* P56IT allele in a normal Japanese sample of 50 men and 50 women. The average mandibular ramus height in those with the *GHR* P56IT allele was 4.65 mm shorter than that in those without the *GHR* P56IT allele. This significant correlation between the *GHR* P56IT allele and shorter mandibular ramus height was confirmed in an additional 80 women.

Class III malocclusion morphology is heterogeneous, with various degrees of incidence among different ethnic groups, and various facial patterns may, as a composite, result in the condition.<sup>123,124</sup> There is a strong heritable component in Class III malocclusion in general, with modes of inheritance being reported to be polygenic,<sup>125</sup> AD in a Libyan sample,<sup>126</sup> and AD with incomplete penetrance with a multifactorial component in a Brazilian sample.<sup>127</sup>

The variations in ethnic incidence as well as variations in morphology that we lump together into the category of Class III malocclusion may also reflect variations in genes involved in “different” Class III malocclusions. This concept of genetic heterogeneity influencing the range of subphenotypes or subtypes in what we call a Class III malocclusion is supported by genetic linkage and association studies finding several different genes or genetic markers to be significant for Class III malocclusion among different ethnic groups, with some genes or genetic markers appearing to be different among the ethnic groups and other Class III malocclusion genes or markers possibly being common among the groups. Until recently, the vast majority of Class III malocclusion genetics studies had been completed in Asian populations and implicated multiple chromosomal regions including 1p35, 1p36, 4p16.1, 6q25, 12q13, 14q24.3, and 19p13.2.<sup>128–133</sup> A study of Class III malocclusion in Colombia yielded significant genetic linkage to 1p22.1, 3q26.2, 11q22, 12q13.13, and 12q23 in patients primarily with maxillary hypoplasia.<sup>134</sup> Another study of Class III malocclusion in Colombian and Brazilian families, primarily with mandibular prognathism in the presence or absence of maxillary hypoplasia, found linkage to chromosome 7.<sup>135</sup> Another genetic association study of a sample of Class III malocclusion patients from the United States, consisting mostly of Caucasian individuals, was race-, age-, and gender-matched with Class I/orthognathic control individuals, with genetic markers used for a set of candidate genes. There was a significant ( $P = 0.02$ ) association of the Class III malocclusion with the marker rs10850110 located upstream of the myosin 1H gene (*MYO1H*) on chromosome 12q24.11.<sup>136</sup>

The influence of muscle on skeletal morphology is further supported by research in myosin gene expression, muscle fiber type differences, and skeletal malocclusions. Gene expression evaluation in masseter muscle from individuals undergoing orthognathic surgery for skeleton-based malocclusions found a trend for increased *MYO1H* and myosin IC (*MYOIC*) expression in Class III malocclusion compared with Class II malocclusion. There were significant correlations ( $P < 0.05$ ) between *MYOIC* expression and fiber-type percent occupancy in masseter muscle from individuals with normal and deep-bite malocclusions. Significant correlations were also identified between *MYOIC* and *MHC* (myosin heavy chain) gene expression. The mechanism of how the *MYO1H* and *MYOIC* genes and their protein products influence the Class III phenotype, however, remains unknown. It has been postulated that altered glucose transport during condylar cartilage growth may be one of the cellular mechanisms that promotes mandibular prognathism, as well as development of open and deep-bite skeletal malocclusions through masseter muscle fiber-type differences.<sup>137</sup> Analysis of the DNA sequences from an Estonian family recently uncovered a rare heterozygous missense mutation associated with Class III skeletal malocclusion in the dual-specificity phosphatase 6 (*DUSP6*) gene (c.545C>T; p.Ser182Phe; rs139318648). Affected individuals in this family were largely characterized as having a straight profile with maxillary deficiency. This rare variant cosegregated with the disease and followed an AD pattern of inheritance with incomplete penetrance. The *DUSP6* gene encodes a cytoplasmic dual-specificity phosphatase that

acts as a negative regulator of the MAP kinases, ERK1/2. This protein is involved in some fundamental signaling processes that occur at the early stages of skeletal development, and can be transcriptionally upregulated via the fibroblast growth factor (FGF)/FGF receptor signaling pathway.<sup>138</sup> Further genetic studies on skeletal variation in malocclusion are yielding data about the association of sagittal and vertical aspects of malocclusion with genetic markers emphasizing the complexity of facial growth.<sup>139,140</sup> One of the many interesting findings is that SNPs in the *FGFR2* gene were associated with increased risk of Classes II and III skeletal malocclusion, indicating that these SNPs may influence the risk for abnormal maxillomandibular discrepancies in general.<sup>139</sup> The list of Class III malocclusion-related genes continues to grow with fibroblast growth factor 23 (*FGF23*),<sup>141</sup> ADAM metalloproteinase with thrombospondin type 1 motif 1 (*ADAMTS1*),<sup>142</sup> ADAMTS like 1 (*ADAMTSL1*),<sup>143</sup> Rho GTPase activating protein 21 (*ARHGAP21*)<sup>144</sup> and bestrophin 3 (*BEST3*),<sup>145</sup> and more certain to follow. The ongoing research into genetic factors associated with Class III malocclusion is necessary if a “gene panel” for this developmental variation is to be developed for the study of genotype-phenotype correlations and treatment efficacy.<sup>146</sup> For a review on the challenges in treating Class III malocclusion in children and adolescents and a review of the genetics of Class III malocclusion, see “The Quest and Reality of Personalized Treatment for the Skeletal Class III Patient.”<sup>146</sup>

In addition to studies in which cephalometric data was analyzed by genotype, the use of three-dimensional facial scanning has enabled the investigation of facial morphology using GWAS, resulting in some interesting association of genes with some facial variation that may be useful in future research and clinical studies of malocclusion, facial clefting, asymmetry, and other developmental disorders.<sup>147</sup>

The studies previously mentioned dealt with differences in jaw/facial morphology. What about differences in growth velocity during puberty? Certainly, increased accuracy in the estimation of pubertal facial growth would be of great benefit prior to the utilization of different therapeutic modalities including orthodontics, orthopedic growth modification, and surgery. The pubertal growth spurt response is mediated by the combination of sex steroids; growth hormone; insulin-like growth factor (IGF-I); and other endocrine, paracrine, and autocrine factors. Testosterone and estradiol in mice have a direct, gender-specific stimulatory activity on male- and female-derived chondroprogenitor cell proliferation. Testosterone stimulated growth and local production of IGF-I and IGF-I-R in chondrocyte cell layers of an isolated organ culture of the mouse mandibular condyle.<sup>148</sup> Administration of low doses of testosterone in boys with delayed puberty accelerates not only their staturnal growth rate but also their craniofacial growth rate.<sup>149</sup> Estrogens are a group of hormones involved in growth and development.<sup>150</sup>

Aromatase (also known as estrogen synthetase, encoded by the cytochrome P450 family 19 subfamily A member 1 gene (*CYP19A1*)) is a key cytochrome P450 enzyme involved in estrogen biosynthesis.<sup>151</sup> This steroidogenic enzyme catalyzes the final step of estrogen biosynthesis by converting testosterone and androstenedione to estradiol and estrone, respectively.<sup>152</sup> Regulation of this gene’s

transcription is critical for the testosterone/estrogen (T/E) ratio in the body since aromatase plays an important role in the conversion of androgens to estrogens. Some studies have shown that the T/E ratio is critical in the development of gender-indexed facial characteristics such as the growth of cheekbones, the mandible, and chin; the prominence of eyebrow ridges; and the lengthening of the lower face.<sup>153,154</sup> The difference in the average sagittal jaw growth between two groups of Caucasian males with different *CYP19A1* alleles with the greatest differences in growth per year was just over 1.5 mm per year during treatment for the maxilla and 2.5 mm per year for the mandible. There was no statistically significant difference for the particular *CYP19A1* alleles in females. It is particularly interesting that at the beginning of treatment there was no statistically significant difference among the males based on the *CYP19A1* genotype. The difference expressed itself only over the time of treatment during the cervical vertebral stage associated with increased growth velocity.<sup>155</sup> Interestingly, the same result was found in a group of Chinese males and females, strongly suggesting that this variation in the *CYP19A1* gene may be a multiethnic marker for sagittal facial growth.<sup>156</sup> Although the difference in average annual sagittal mandibular and maxillary growth based on this *CYP19A1* genotype was significant, as one factor in a complex trait (sagittal jaw growth), it accounts for only part of the variation seen, and therefore, by itself, has little predictive power.<sup>157</sup> King et al.<sup>158</sup> noted that many studies estimating the heritability of craniofacial structures may have a bias because they have generally involved individuals who had not undergone orthodontic treatment, and that those judged to have an extreme malocclusion were often excluded. In contrast to the relatively high heritability of cephalometric variables and low heritability of occlusal variables in individuals with naturally occurring good occlusion, they found that the heritability estimates for craniofacial skeletal variables in those with overt malocclusions were significantly lower and the heritability estimates for occlusal variations were significantly higher. This observation supports the idea that everyone does not react to specific environmental factors in the same manner, although those who are related are more likely to react similarly. To quote King et al.<sup>158</sup>:

*We propose that the substantive measures of intersib similarity for occlusal traits reflect similar responses to environmental factors common to both siblings. That is, given genetically influenced facial types and growth patterns, siblings are likely to respond to environmental factors (e.g., reduced masticatory stress, chronic mouth breathing) in similar fashions. Malocclusions appear to be acquired, but the fundamental genetic control of craniofacial form often diverts siblings into comparable physiologic responses leading to development of similar malocclusions.*

Although we have some information about genetic influence on specific traits (e.g., missing teeth, occlusal patterns, tooth morphology, and even mandibular prognathism), these cases are exceptions; we do not have sufficient information to make accurate predictions about the development of occlusion simply by studying the frequency of its occurrence in parents or even siblings. Admittedly, family

patterns of resemblance are frequently obvious, but predictions must be made cautiously because of the genetic and environmental variables and their interaction, which are unknown and difficult to evaluate.

Currently the results of studies regarding the genetic and environmental factors that influence the development of malocclusion are representative of the samples studied, not necessarily of any individual. In addition, the extent to which a particular trait is influenced by genetic factors may have little, if any, effect on the success of environmental (treatment) intervention. Even so, it may be that genetic factors that influenced a trait will also influence the response to intervention to alter that trait, or other genetic factors may be involved in the response. Therefore, the possibility of altering the environment to gain a more favorable occlusion theoretically exists, even in individuals in whom the malocclusion has a relatively high genetic influence. However, the question of how environmental and genetic factors interact is most relevant to clinical practice because it may explain why a particular alteration of the environment (treatment) may be successful in one compliant patient and not in another.<sup>159</sup>

Multiple factors and processes contribute to individual responses to treatment. Some patients exhibit unusual untreated growth patterns, treatment outcomes, or reactions to medications linked to polymorphic genes. Analysis of overall treatment response requires a systems analysis based on informatics for integration of all relevant information. The influence of genetic factors on treatment outcome must be studied and understood in quantitative terms for it to be applied effectively for each patient. Conclusions from retrospective studies must be evaluated by prospective testing for a true evaluation of their value in practice. Genetic studies are necessary to advance the evidence base for practice. Only then will we begin to truly understand how nature (genetic factors) and nurture (environmental factors, including treatment) together affect treatment of our patients.<sup>2</sup>

## External Apical Root Resorption

Basic descriptors of root resorption are based on the anatomic region of occurrence; that is, designations are *internal root resorption* and *external root resorption* (cervical root resorption and external apical root resorption [EARR]). EARR is a frequent iatrogenic outcome associated with orthodontic treatment and may also occur in the absence of orthodontic treatment.<sup>160,161</sup> Although orthodontic treatment is associated with some maxillary central incisor EARR in most patients, and more than one-third of those treated experience greater than 3 mm of loss, severe EARR (>5 mm) occurs in 2% to 5% of cases.<sup>162,163</sup>

Currently, there are no reliable markers to predict either who will develop EARR or its severity following orthodontic tooth movement,<sup>164</sup> although the shape of the root has been associated with the likelihood of EARR and is best examined on periapical rather than panoramic radiographs.<sup>165</sup> Even when duration of treatment is a factor, along with several significant dentofacial structural measurements (e.g., overjet), it does not account for enough of the observed variability to be useful as a predictor of EARR.<sup>163</sup>

Although orthodontic tooth movement, or *biomechanics*, has been found to account for approximately one-tenth to one-third of the total variation in EARR,<sup>166–168</sup> Owman-Moll et al.<sup>169</sup> showed that individual variation overshadowed the force magnitude and the force type in defining the susceptibility to histologic root resorption associated with orthodontic force. Individual variations were considerable regarding both extension and depth of histologic root resorption within individuals, and these were not correlated to the magnitude of tooth movement achieved.<sup>170</sup>

The degree and severity of EARR associated with orthodontic treatment are multifactorial involving host and environmental factors,<sup>171</sup> with genetic factors accounting for at least 50% of the variation overall and approximately two-thirds of the variation seen in maxillary central incisor EARR.<sup>172,173</sup> In addition, studies in a panel of different inbred mice also supported a genetic component involving multiple genes in histologic root resorption.<sup>174,175</sup>

The potential for IL-1 $\beta$  to have an effect on root resorption was supported by the increase in orthodontically induced histologic root resorption in the absence of the IL-1 $\beta$  cytokine in a knockout mouse model<sup>176,177</sup> and a P2rx7 knockout mouse model<sup>178,179</sup> because a lack of the P2rx7 receptor results in a lack of IL-1 $\beta$ . In both models, there was no difference at baseline between the histologic root resorption in wild-type (“normal”) and knockout mice, whereas the application of force resulted in a significant increase in histologic root resorption in the wild-type mice. In addition, there was a significant ( $P < 0.02$ ) increase in histologic root resorption in both types of knockout mice compared with the respective wild-type mice when the same force was applied in all the mice. Thus, there was a significant interaction between the genotype and environment (orthodontic force) in histologic root resorption.

There have been at least seven clinical studies determining whether the +3953/4 (G/A) SNP rs1143634 DNA marker variation in the *IL-1B* gene is associated with variation in EARR concurrent with orthodontia. Three studies of cohorts from the United States (Caucasian),<sup>180</sup> Brazil,<sup>181</sup> and Spain<sup>182</sup> found a significant association, whereas four others, from Japan,<sup>183</sup> Germany,<sup>184</sup> Portugal,<sup>185</sup> and the Czech Republic,<sup>186</sup> did not find a significant association. In addition, a meta-analysis of studies investigating the IL-1B +3953/4 polymorphism and EARR concurrent with orthodontic treatment found no publication bias or association.<sup>187</sup> Other DNA markers for other genes have been investigated as well, with some finding a significant association and others none.<sup>1</sup> Most of these studies investigated only one or possibly two genetic markers, and sometimes clinical factors such as length of treatment and extraction of premolars are also included in the analysis. Since from the beginning of these studies it was appreciated that EARR concurrent with orthodontia is a complex trait, future studies should endeavor to study as many genetic and treatment factors as possible in as many orthodontic patients as possible to gain a better understanding of this phenomenon.

## Genetics of Cleft Lip and Palate

Studies of the CLP phenotype in twins indicate that monozygous twins have a 35% concordance rate, whereas dizygous



twins show less than 5% concordance.<sup>188</sup> Information from two sources (families and twins) establishes a genetic basis for CLP, but despite many extensive investigations, no simple pattern of inheritance has been demonstrated. This has led to proposals for a variety of genetic modes of inheritance for CLP, including dominance, recessiveness, and sex linkage, and has ultimately led to the documentation of modifying conditions that may be present, such as incomplete penetrance and variable gene expressivity.<sup>189</sup> There are three important reasons for the failure to resolve the question of a hereditary basis for clefts: (1) some clefts are of a nongenetic origin and should not be included in a genetic analysis (such cases are seldom recognized and are difficult to prove); (2) individuals who have increased genetic liability for having a child with CLP often fail to be recognized, but because they do not have CLP themselves, they cannot be identified with certainty (this latter situation defines the problem of nonpenetrance for genes that control CLP)<sup>190</sup>; and (3) CLP, although sometimes appearing to be relatively simple in origin, is undoubtedly a complex of diseases with different etiologies lumped together because of clinical disease resemblance (they all show clefting).

There are two clearly recognized groups of etiologically different clefts: cleft lip either with or without cleft palate, CL(P), and isolated cleft palate (cleft palate only, CPO). These two entities, CL(P) and CPO, can occur as both single and multiple cases in a family. In the former they are called *sporadic* and in the latter they are called *familial* or *multiplex*. Some researchers refer to multiplex cases as those individuals with findings in addition to an oral cleft, even if a specific syndrome is not recognized. It should also be noted that CPO that occurs without a cleft of the lip is different from the palatal cleft that occurs as a part of CL(P). The embryology and developmental timing are different, and CPO is more commonly part of a syndrome than is CL(P). CPO is less common, with a prevalence of approximately 1 per 1500 to 2000 births in Caucasians, whereas CL(P) is more common, with 1 or 2 per 1000 births. The prevalence of CPO does not vary in different racial backgrounds, but the prevalence of CL(P) varies considerably, with Asians and Native Americans having the highest rate and Africans the lowest. There are also gender ratio differences, with more males having CL(P) and more females having CPO. Except in a small number of syndromes such as van der Woude syndrome, families with one type of clefting segregating in the family do not have the other cleft type occurring at a rate higher than the population prevalence.

When all potential study groups for CL(P) and CPO are considered, the minimum number is six: three subgroups for CL(P) and three for CPO. These three for each type of cleft are the sporadic and the familial groups, and a group of syndromes that feature CL(P) and/or CPO. Approximately 30% of CL(P) and 50% of CPO patients have one of the more than 400 syndromes described.<sup>191</sup>

As noted earlier, minor and subtle facial changes are perhaps more likely to produce the best-correlated phenotype needed to pinpoint the cleft genotype. Part of the reason for this view is the suspicion that certain facial shapes are more predisposed to developing CL(P) than others,<sup>192,193</sup> and that subepithelial defects of the upper lip musculature are part of the phenotypic spectrum of oral clefts and may represent an occult, subclinical manifestation of the

anomaly.<sup>194</sup> Although this approach seems best for producing an accurately generated clefting phenotype, further study of the developmental anatomy of the head and face is needed and ongoing.

The published data on nonsyndromic cleft populations come from around the world (Japan, China, Hawaii, Denmark, Sweden, the United Kingdom, and North America). These studies make it clear that both CL(P) and CPO are heterogeneous diseases, that is, there are multiple causes for the single phenotypes. The generally accepted hereditary basis for CL(P) and CPO can be summarized as follows: single, nonsyndromic cases of CL(P) and CP, or sporadic clefts, are believed to be the result of a complex interaction between multiple genetic and environmental factors. Therefore, their etiology is multifactorial in the true sense of the word, and the chance that these multiple factors would interact to produce a cleft phenotype in relatives is small, probably less than 1%.

The other nonsyndromic group consists of multiple cases of clefts that occur in a single family. These are called familial (or multiplex) and have been viewed by researchers as the “true” genetic cases. Familial occurrences of CL(P) and CPO seem most likely to be attributed to the action of a single major gene, but the influence of multifactorial (complex) trait factors is difficult to rule out. Thus, we are left with the idea that both multifactorial and single major gene elements may have a role in producing sporadic and familial cases of CL(P) and CPO. (For an overview of genetic and other factors in orofacial clefting, the reader is referred to the paper by Leslie and Marazita.<sup>195</sup>)

An example of an environmental (dietary) factor associated with a decrease in neural tube defects such as spina bifida, as well as orofacial clefting, is the maternal intake of folate (folic acid), now a common component in prenatal vitamins. To be effective, such vitamins or other dietary supplements must be used at least around the time of conception because of the embryologic timing of neural tube closure, and lip and palate formation. Because of the public health importance and critical need before a woman may realize that she is pregnant, folic acid fortification of grains in the United States became mandatory since January 1, 1998, specifically to reduce the occurrence of neural tube defects, which has been successful. This has also, to a lesser degree, reduced the occurrence of orofacial clefting. Interestingly, however, it did not decrease the occurrence of orofacial clefting in children whose mothers smoke cigarettes.<sup>196</sup>

Although some genetic and environmental risk factors for CL(P) have been identified, many nonsyndromic clefts are not linked to any of these factors. Furthermore, there is a paucity of information available on the long-term consequences for children born with CL(P) or CPO. To address these concerns, the National Center on Birth Defects and Developmental Disabilities at the Centers for Disease Control and Prevention conducted a workshop entitled “Prioritizing a Research Agenda for Orofacial Clefts.” Experts in the fields of epidemiology, public health, genetics, psychology, speech pathology, dentistry, health economics, and others participated in this workshop to review the state of knowledge on orofacial clefts, identify knowledge gaps that need additional public health research, and create a prioritized public health research agenda based on these gaps. Their

report is recommended to the reader as an excellent summary of the current knowledge and future research priorities for orofacial clefting.<sup>197</sup>

## References

- Hartsfield Jr JK, Morford LA: In Graber LW, Vanarsdall Robert LL, Katherine W, editors: *Orthodontics: Current Principles and Techniques*, Elsevier Mosby, 2016. (Vig) Ch. 2.
- Hartsfield J, James K: In *Sem Orthod*, 14. Elsevier, 2008, pp 166–171.
- Venter JC, Adams MD, Myers EW, et al.: The sequence of the human genome, *Science* 291(5507):1304–1351, 2001.
- Lander ES, Linton LM, Birren B, et al.: Initial sequencing and analysis of the human genome, *Nature* 409(6822):860–921, 2001.
- Collins FS, Morgan M, Patrinos A: The human genome project: lessons from large-scale biology, *Science* 300(5617):286–290, 2003.
- Baltimore D: Our genome unveiled, *Nature* 409(6822):814–816, 2001.
- NIH: *Department of Health & Human Services, Lister Hill National Center for Biomedical Communications*, U.S. National Library of Medicine, National Institutes of Health, 2019. <https://ghr.nlm.nih.gov>.
- Mullis K, et al.: In *Cold Spring Harb Symp Quant Biol*, 51. Cold Spring Harbor Laboratory Press, 1986, pp 263–273.
- Genome International Sequencing Consortium: Initial sequencing and analysis of the human genome, *Nature* 409(6822):860–921, 2001.
- Pemberton TJ, Gee J, Patel PI: Gene discovery for dental anomalies, *J Am Dent Assoc* 137(6):743–752, 2006.
- Chakravarti A: Single nucleotide polymorphisms:... to a future of genetic medicine, *Nature* 409(6822):822–823, 2001.
- Shastry BS: SNPs: impact on gene function and phenotype, *Methods Mol Biol* 578:3–22, 2009.
- Morozova O, Marra MA: Applications of next-generation sequencing technologies in functional genomics, *Genomics* 92(5):255–264, 2008.
- Bamshad MJ, Ng SB, Bigham AW, et al.: Exome sequencing as a tool for mendelian disease gene discovery, *Nat Rev Genet* 12(11):745–755, 2011.
- Kilpinen H, Barrett JC: How next-generation sequencing is transforming complex disease genetics, *Trends Genet* 29(1):23–30, 2013.
- Adams DR, Eng CM: Next-generation sequencing to diagnose suspected genetic disorders, *New Eng J Med* 379(14):1353–1362, 2018.
- Everett E, Hartsfield Jr J: In Davidovitch Z, Mah J, editors: *Biological Mechanisms of Tooth Movement and Craniofacial Adaptation*, Harvard Society for the Advancement of Orthodontics, 2000, pp 287–298.
- Cobourne MT: Construction for the modern head: current concepts in craniofacial development, *J Orthod* 27(4):307–314, 2000.
- Lejeune JT, Turpin R, Gautier M: Le mongolisme, premier exemple d'aberration autosomique humaine, *Ann Genet* 1(4):1–49, 1959.
- Wang H, Dong Z, Zhang R, et al.: Low-pass genome sequencing versus chromosomal microarray analysis: implementation in prenatal diagnosis, *Genet Med* 22(3):500–510, 2020.
- Slavotinek AM: Novel microdeletion syndromes detected by chromosome microarrays, *Hum Genet* 124(1):1–17, 2008.
- Vissers LE, de Vries BB, Osoegawa K, et al.: Array-based comparative genomic hybridization for the genomewide detection of submicroscopic chromosomal abnormalities, *Am J Hum Genet* 73(6):1261–1270, 2003.
- Manning M, Hudgins L: Array-based technology and recommendations for utilization in medical genetics practice for detection of chromosomal abnormalities, *Genet Med* 12(11):742–745, 2010.
- Henderson LB, Applegate CD, Wohler E, et al.: The impact of chromosomal microarray on clinical management: a retrospective analysis, *Genet Med* 16(9):657–664, 2014.
- Harris EF: In *Sem Orthod*, 14. Elsevier, 2008, pp 125–134.
- LaBuda MC, Gottesman II, Pauls DL: Usefulness of twin studies for exploring the etiology of childhood and adolescent psychiatric disorders, *Am J Med Genet* 48(1):47–59, 1993. <https://doi.org/10.1002/ajmg.1320480111>.
- Abass SK, Hartsfield Jr JK: Investigation of genetic factors affecting complex traits using external apical root resorption as a model, *Sem Orthod* 14(2):115–124, 2008.
- Tucker A, Sharpe P: The cutting-edge of mammalian development: how the embryo makes teeth, *Nat Rev Genet* 5(7):499–508, 2004.
- Croissant R, Guenther H, Slavkin H: In *Extracellular Matrix Influences on Gene Expression*, Elsevier, 1975, pp 515–521.
- Sharpe PT: Neural crest and tooth morphogenesis, *Adv Dent Res* 15(1):4–7, 2001.
- Witkop C, Sauk J: In Stewart RE, Prescott GH, editors: *Oral Facial Genetics*, Mosby, 1976, pp 151–226.
- Dean JA, Hartsfield Jr JK, Wright JT, et al.: Dentin dysplasia, type II linkage to chromosome 4q, *J Craniofac Genet Develop Biol* 17(4):172–177, 1997.
- Schultze C, Lenz FR: Ueber Zahnschmelzhypoplasie von unvollständig dominiertem geschlechtsgebundenen Egrgang, *Z Mensch Vererb Kops* 31:104–114, 1952.
- Escobar VH, Goldblatt LI, Bixler D: A clinical, genetic, and ultrastructural study of snow-capped teeth: amelogenesis imperfecta, hypomaturation type, *Oral Surg Oral Med Oral Path* 52(6):607–614, 1981.
- Hartsfield JK: In *Integrated Clinical Orthodontics*, 2012, pp 109–131.
- Jaureguiberry G, De la Dure-Molla M, Parry D, et al.: Nephrocalcinosis (enamel renal syndrome) caused by autosomal recessive FAM20A mutations, *Nephron Physiol* 122(1–2):1–6, 2012. <https://doi.org/10.1159/000349989>.
- Martelli-Júnior H, Neto PE, Aquino SN, et al.: Amelogenesis imperfecta and nephrocalcinosis syndrome: a case report and review of the literature, *Nephron Physiol* 118(3):p62–p65, 2011.
- Wang SK, Aref P, Hu Y, et al.: FAM20A mutations can cause enamel-renal syndrome (ERS), *PLoS Genet* 9(2), 2013. e1003302.
- Hirji N, Bradley PD, Li S, et al.: Jalili syndrome: cross-sectional and longitudinal features of seven patients with cone-rod dystrophy and amelogenesis imperfecta, *Am J Ophthalmol* 188:123–130, 2018.
- Jalili IK: Cone-rod dystrophy and amelogenesis imperfecta (Jalili syndrome): phenotypes and environs, *Eye* 24(11):1659–1668, 2010.
- Cooper DN, Krawczak M, Polychronakos C, et al.: Where genotype is not predictive of phenotype: towards an understanding of the molecular basis of reduced penetrance in human inherited disease, *Hum Genet* 132(10):1077–1130, 2013.
- Zhang X, Zhao J, Li C, et al.: DSPP mutation in dentinogenesis imperfecta Shields type II, *Nat Genet* 27(2):151–152, 2001.
- Janku P, Robinow M, Kelly T, et al.: The van der Woude syndrome in a large kindred: variability, penetrance, genetic risks, *Am J Med Genet* 5(2):117–123, 1980.
- Shapiro JR: In Shapiro Jay R, Byers Peter H, Glorieux Francis H, Sponseller Paul D, editors: *Osteogenesis Imperfecta: a Translational Approach to Brittle Bone Disease*, Academic Press, is an imprint of Elsevier, 2014, pp 15–22.
- Johnson D, Wilkie AO: Craniosynostosis, *Eur J Hum Genet* 19(4):369–376, 2011.
- Mulvihill JJ: Craniofacial syndromes: no such thing as a single gene disease, *Nat Genet* 9(2):101, 1995.
- Park WJ, Bellus GA, Jabs EW: Mutations in fibroblast growth factor receptors: phenotypic consequences during eukaryotic development, *Am J Hum Genet* 57(4):748, 1995.
- Escobar V, Bixler D: On the classification of the acrocephalysyndactyly syndromes, *Clin Genet* 12(3):169–178, 1977.
- Everett ET, Britto DA, Ward RE, et al.: A novel FGFR2 gene mutation in Crouzon syndrome associated with apparent nonpenetrance, *Cleft Palate-Cran J* 36(6):533–541, 1999.
- Rosenberg RN, Stüve O, Eagar T: 200 years after Darwin, *Arch Neurol* 66(2):153–155, 2009, 200.
- Fraga MF, Ballestar E, Paz MF, et al.: Epigenetic differences arise during the lifetime of monozygotic twins, *P Natl Acad Sci* 102(30):10604–11060, 2005.
- Feinberg AP: Epigenetics at the epicenter of modern medicine, *J Am Med Assoc* 299(11):1345–1350, 2008.
- Smith SM, Penrose LS: Monozygotic and dizygotic twin diagnosis, *Ann Hum Genet* 19(4):273–289, 1955.
- Kruglyak L, Lander ES: Complete multipoint sib-pair analysis of qualitative and quantitative traits, *Am J Hum Genet* 57(2):439, 1995.
- Slatkin M: Linkage disequilibrium—understanding the evolutionary past and mapping the medical future, *Nat Rev Genet* 9(6):477–485, 2008.
- Abecasis GR, Cardon LR, Cookson WO: A general test of association for quantitative traits in nuclear families, *Am J Hum Genet* 66(1):279–292, 2000.
- Bruel AL, Nambot S, Quéré V, et al.: Increased diagnostic and new genes identification outcome using research reanalysis of singleton exome sequencing, *Eur J Hum Genet* 27(10):1519–1531, 2019.

58. Suwinski P, Ong C, Ling MH, et al.: Advancing personalized medicine through the application of whole exome sequencing and big data analytics, *Front Genet* 10:49, 2019.
59. Gustafsson BE, Quensel CE, Lanke LS, et al.: The effect of different levels of carbohydrate intake on caries activity in 436 individuals observed for five years, *Acta Odontol Scand* 11(3-4):232-364, 1953.
60. Klein H, Palmer CE, Knutson JW: Studies on dental caries: v. Familial resemblance in the caries experience of siblings, *Public Health Rep* 1353-1364, 1938.
61. Klein H: The family and dental disease. IV: Dental disease (DMF) experience in parents and offspring, *J Am Dent Assoc* 33(11):735-743, 1946.
62. Li Y, Caufield P: The fidelity of initial acquisition of mutans streptococci by infants from their mothers, *J Dent Res* 74(2):681-685, 1995.
63. Chaffee BW, Gansky SA, Weintraub JA, et al.: Maternal oral bacterial levels predict early childhood caries development, *J Dent Res* 93(3):238-244, 2014.
64. Book JA: Clinical and genetical studies of dental caries. II. Parents and sibs of adult highly resistant (caries-free) propositi, *Odontol Rev* 4:1-53, 1953.
65. Dahlberg G, Dahlberg B: Uber karies und andere zahnveranderungen bei zwillingen, *Uppsala LakforForth* 47:395-416, 1942.
66. Mansbridge JN: Heredity and dental caries, *J Dent Res* 38(2):337-347, 1959.
67. Horowitz SL, Osborne RH, DeGeorge FV: Caries experience in twins, *Science* 128:300-301, 1958.
68. Caldwell RC, Finn SB: Comparisons of the caries experience between identical and fraternal twins and unrelated children, *J Dent Res* 39:693-694, 1960.
69. Bretz WA, Corby PM, Hart TC, et al.: Dental caries and microbial acid production in twins, *Caries Res* 39(3):168-172, 2005.
70. Corby PM, Bretz WA, Hart TC, et al.: Heritability of oral microbial species in caries-active and caries-free twins, *Twin Res Hum Genet* 10(6):821-828, 2007.
71. Hunt HR, Hoppert CA, Rosen S: In Sognaes Reidar F, editor: *Advances in experimental caries research*, American Association for the Advancement of Science, 1955.
72. Shuler CF: Inherited risks for susceptibility to dental caries, *J Dent Educ* 65(10):1038-1045, 2001.
73. Slayton RL, Cooper ME, Marazita ML: Tuftelin, mutans streptococci, and dental caries susceptibility, *J Dent Res* 84(8):711-714, 2005.
74. Deeley K, Letra A, Rose EK, et al.: Possible association of amelogenin to high caries experience in a Guatemalan-Mayan population, *Caries Res* 42(1):8-13, 2008.
75. Shaffer JR, Wang X, Feingold E, et al.: Genome-wide association scan for childhood caries implicates novel genes, *J Dent Res* 90(12):1457-1462, 2011.
76. Stanley BO, Feingold E, Cooper M, et al.: Genetic association of MPPED2 and ACTN2 with dental caries, *J Dent Res* 93(7):626-632, 2014.
77. Chaussain C, Bouazza N, Gasse B, et al.: Dental caries and enamel haplotype, *J Dent Res* 93(4):360-365, 2014.
78. Zeng Z, Shaffer JR, Wang X, et al.: Genome-wide association studies of pit-and-fissure-and smooth-surface caries in permanent dentition, *J Dent Res* 92(5):432-437, 2013.
79. Bretz WA, Corby PM, Melo MR, et al.: Heritability estimates for dental caries and sucrose sweetness preference, *Arch Oral Biol* 51(12):1156-1160, 2006.
80. Nibali L, Di Iorio A, Tu YK, et al.: Host genetics role in the pathogenesis of periodontal disease and caries, *J Clin Periodontol* 44:S52-S78, 2017.
81. Shungin D, Haworth S, Divaris K, et al.: Genome-wide analysis of dental caries and periodontitis combining clinical and self-reported data, *Nat Commun* 10(1):1-13, 2019.
82. Dawson DV: Genetic factors appear to contribute substantially to dental caries susceptibility, and may also independently mediate sucrose sweetness preference, *J Evid Based Dent Pract* 8(1):37-39, 2008.
83. Papananou PN, Sanz M, Buduneli N, et al.: Periodontitis: Consensus report of workgroup 2 of the 2017 World Workshop on the Classification of Periodontal and Peri-Implant Diseases and Conditions, *J Periodontol* 89:S173-S182, 2018.
84. Ciancio SG, Hazen SP, Cunat JJ: Periodontal observations in twins, *J Periodontol Res* 4(1):42-45, 1969.
85. Michalowicz BS, Aeppli D, Virag JG, et al.: Periodontal findings in adult twins, *J Periodontol* 62(5):293-299, 1991.
86. Kornman KS, Crane A, Wang HY, et al.: The interleukin-1 genotype as a severity factor in adult periodontal disease, *J Clin Periodontol* 24(1):72-77, 1997.
87. Wagner J, Kaminski WE, Aslanidis C, et al.: Prevalence of OPG and IL-1 gene polymorphisms in chronic periodontitis, *J Clin Periodontol* 34(10):823-827, 2007.
88. Fiebig A, Jepsen S, Loos BG, et al.: Polymorphisms in the interleukin-1 (IL1) gene cluster are not associated with aggressive periodontitis in a large Caucasian population, *Genomics* 92(5):309-315, 2008.
89. Nikolopoulos GK, Dimou NL, Hamodrakas SJ, et al.: Cytokine gene polymorphisms in periodontal disease: a meta-analysis of 53 studies including 4178 cases and 4590 controls, *J Clin Periodontol* 35(9):754-767, 2008.
90. Sakellari D, Katsares V, Georgiadou M, et al.: No correlation of five gene polymorphisms with periodontal conditions in a Greek population, *J Clin Periodontol* 33(11):765-770, 2006.
91. Greenstein G, Hart TC: Clinical utility of a genetic susceptibility test for severe chronic periodontitis: a critical evaluation, *J Am Dent Assoc* 133(4):452-459, 2002.
92. Giannobile WV, Braun TM, Caplis AK, et al.: Patient stratification for preventive care in dentistry, *J Dent Res* 92(8):694-701, 2013.
93. Diehl SR, Kuo F, Hart TC: Interleukin 1 genetic tests provide no support for reduction of preventive dental care, *J Am Dent Assoc* 146(3):164-173, 2015.
94. Ioannidis JP: Preventing tooth loss with biannual dental visits and genetic testing: does it work? *J Am Dent Assoc* 146(3):141-143, 2015.
95. Kinane D, Hart T: Genes and gene polymorphisms associated with periodontal disease, *Crit Rev Oral Biol Med* 14(6):430-449, 2003.
96. Kinane DF, Shiba H, Hart TC: The genetic basis of periodontitis, *Periodontol* 39(1):91-117, 2005, 2000.
97. Divaris K, Monda KL, North KE, et al.: Exploring the genetic basis of chronic periodontitis: a genome-wide association study, *Hum Mol Genet* 22(11):2312-2324, 2013.
98. Etzioni A, Tonetti M: Leukocyte adhesion deficiency II—from A to almost Z, *Immunol Rev* 178(1):138-147, 2000.
99. Arnaout MA, Dana N, Gupta SK, et al.: Point mutations impairing cell surface expression of the common beta subunit (CD18) in a patient with leukocyte adhesion molecule (Leu-CAM) deficiency, *J Clin Inv* 85(3):977-981, 1990.
100. Meyle J, Gonzales JR: Influences of systemic diseases on periodontitis in children and adolescents, *Periodontol* 26(1):92-112, 2001, 2000.
101. Hartsfield Jr JK: Premature exfoliation of teeth in childhood and adolescence, *Adv Pediatr* 41:453, 1994.
102. Hartsfield Jr JK, Kousseff BG: Phenotypic overlap of Ehlers-Danlos syndrome types IV and VIII, *Am J Med Genet* 37(4):465-470, 1990.
103. Superti-Furga A, Gugler E, Gitzelmann R, et al.: Ehlers-Danlos syndrome type IV: a multi-exon deletion in one of the two COL3A1 alleles affecting structure, stability, and processing of type III procollagen, *J Biol Chem* 263(13):6226-6232, 1988.
104. Kapferer-Seebacher I, Pepin M, Werner R, et al.: Periodontal Ehlers-Danlos syndrome is caused by mutations in C1R and C1S, which encode subcomponents C1r and C1s of complement, *Am J Hum Genet* 99(5):1005-1014, 2016.
105. Nagle DL, Karim MA, Woolf EA, et al.: Identification and mutation analysis of the complete gene for Chediak-Higashi syndrome, *Nat Genet* 14(3):307-311, 1996.
106. Hart TC, Stabholz A, Meyle J, et al.: Genetic studies of syndromes with severe periodontitis and palmoplantar hyperkeratosis, *J Periodontol Res* 32(1):81-89, 1997.
107. Hart TC, Hart PS, Michalec MD, et al.: Haim-Munk syndrome and Papillon-Lefevre syndrome are allelic mutations in cathepsin C, *J Med Genet* 37(2):88-94, 2000.
108. Noack B, Görgens H, Lorenz K, et al.: Cathepsin C gene variants in aggressive periodontitis, *J Dent Res* 87(10):958-963, 2008.
109. Hart TC, Hart PS, Michalec MD, et al.: Localisation of a gene for prepubertal periodontitis to chromosome 11q14 and identification of a cathepsin C gene mutation, *J Med Genet* 37(2):95-101, 2000.
110. Schenkein H: Inheritance as a determinant of susceptibility for periodontitis, *J Dent Educ* 62(10):840-851, 1998.
111. Diehl SR, Wang Y, Brooks CN, et al.: Linkage disequilibrium of interleukin-1 genetic polymorphisms with early-onset periodontitis, *J Periodontol* 70(4):418-430, 1999.



112. Hewitt C, McCormick D, Linden G, et al.: The role of cathepsin C in Papillon-Lefèvre syndrome, prepubertal periodontitis, and aggressive periodontitis, *Hum Mutat* 23(3):222–228, 2004.
113. Li Y, Xu L, Hasturk H, et al.: Localized aggressive periodontitis is linked to human chromosome 1q25, *Hum Genet* 114(3):291–297, 2004.
114. Munz M, Willenborg C, Richter GM, et al.: A genome-wide association study identifies nucleotide variants at SIGLEC5 and DEFA1A3 as risk loci for periodontitis, *Hum Mol Genet* 26(13):2577–2588, 2017.
115. Chow DA: In Bertók Lóránd, Chow Donna A, editors: *NeuroImmune Biol*, vol. 5. Elsevier, 2005, pp 123–150.
116. Corruccini RS: An epidemiologic transition in dental occlusion in world populations, *Am J Orthod* 86(5):419–426, 1984.
117. Corruccini RS: Australian aboriginal tooth succession, interproximal attrition, and Begg's theory, *Am J Orthod Dentofacial Orthop* 97(4):349–357, 1990.
118. Corruccini RS, Townsend GC, Richards LC, et al.: Genetic and environmental determinants of dental occlusal variation in twins of different nationalities, *Hum Biol* 62(3):353–367, 1990.
119. Kawala B, Antoszewska J, Nečka A: Genetics or environment? A twin-method study of malocclusions, *World J Orthod* 8(4), 2007.
120. Proffit WR: *Contemporary Orthodontics*, 4th ed. Mosby Inc., 2007, pp 6–14.
121. Ting TY, Wong RW, Rabie AB: Analysis of genetic polymorphisms in skeletal Class I crowding, *Am J Orthod Dentofacial Orthop* 140(1):e9–e15, 2011.
122. Yamaguchi T, Maki K, Shibasaki Y: Growth hormone receptor gene variant and mandibular height in the normal Japanese population, *Am J Orthod Dentofacial Orthop* 119(6):650–653, 2001.
123. Bui C, King T, Proffit W, et al.: Phenotypic characterization of Class III patients, *Angle Orthod* 76(4):564–569, 2006, [https://doi.org/10.1043/0003-3219\(2006\)076\[0564:PCOCIP\]2.0.CO;2](https://doi.org/10.1043/0003-3219(2006)076[0564:PCOCIP]2.0.CO;2).
124. Singh GD: Morphologic determinants in the etiology of class III malocclusions: a review, *Clin Anat* 12(5):382–405, 1999, [https://doi.org/10.1002/\(SICI\)1098-2353\(1999\)12:5<382::AID-CA9>3.0.CO;2-0](https://doi.org/10.1002/(SICI)1098-2353(1999)12:5<382::AID-CA9>3.0.CO;2-0).
125. Litton SF, Ackermann LV, Isaacson RJ, et al.: A genetic study of Class 3 malocclusion, *Am J Orthod* 58(6):565–577, 1970.
126. El-Gheriani AA, Maher BS, El-Gheriani AS, et al.: Segregation analysis of mandibular prognathism in Libya, *J Dent Res* 82(7):523–527, 2003.
127. Cruz RM, Krieger H, Ferreira R, et al.: Major gene and multifactorial inheritance of mandibular prognathism, *Am J Med Genet A* 146A(1):71–77, 2008, <https://doi.org/10.1002/ajmg.a.32062>.
128. Yamaguchi T, Park SB, Narita A, et al.: Genome-wide linkage analysis of mandibular prognathism in Korean and Japanese patients, *J Dent Res* 84(3):255–259, 2005.
129. Jang J, Park EK, Ryou HM, et al.: Polymorphisms in the Matrilin-1 gene and risk of mandibular prognathism in Koreans, *J Dent Res* 89(11):1203–1207, 2010.
130. Xue F, Wong RW, Rabie AB: Genes, genetics, and Class III malocclusion, *Orthod Craniofac Res* 13(2):69–74, 2010.
131. Li Q, Li X, Zhang F, et al.: The identification of a novel locus for mandibular prognathism in the Han Chinese population, *J Dent Res* 90(1):53–57, 2011.
132. Li Q, Zhang F, Li X, et al.: Genome scan for locus involved in mandibular prognathism in pedigrees from China, *PLoS One* 5(9), 2010, e12678.
133. Xue F, Rabie AB, Luo G: Analysis of the association of COL 2 A 1 and IGF-1 with mandibular prognathism in a Chinese population, *Orthod Craniofac Res* 17(3):144–149, 2014.
134. Frazier-Bowers S, Rincon-Rodriguez R, Zhou J, et al.: Evidence of linkage in a Hispanic cohort with a Class III dentofacial phenotype, *J Dent Res* 88(1):56–60, 2009.
135. Falcão-Alencar G, Otero L, Cruz RM, et al.: Evidence for genetic linkage of the class III craniofacial phenotype with human chromosome 7 in 36 South American families, *Am J Hum Genet* 3:2010, 2010.
136. Tassopoulou-Fishell M, Deeley K, Harvey EM, et al.: Genetic variation in myosin 1H contributes to mandibular prognathism, *Am J Orthod Dentofacial Orthop* 141(1):51–59, 2012.
137. Raoul G, Desh H, Gray SL, et al.: Expression of unconventional type-1 myosins (1H/1C) in masseter muscle influence the development of skeletal malocclusion in orthognathic surgery subjects, *Int J Oral Maxillofac Surg* 42(10):1335, 2013.
138. Nikopentius T, Saag M, Jagomägi T, et al.: A missense mutation in DUSP6 is associated with Class III malocclusion, *J Dent Res* 92(10):893–898, 2013.
139. da Fontoura CG, Miller SF, Wehby GL, et al.: Candidate gene analyses of skeletal variation in malocclusion, *J Dent Res* 94(7):913–920, 2015.
140. Cruz CV, Mattos CT, Maia JC, et al.: Genetic polymorphisms underlying the skeletal Class III phenotype, *Am J Orthod Dentofacial Orthop* 151(4):700–707, 2017.
141. Chen F, Li Q, Gu M, et al.: Identification of a mutation in FGF23 involved in mandibular prognathism, *Sci Rep* 5:11250, 2015.
142. Guan X, Song Y, Ott J, et al.: The ADAMTS1 gene is associated with familial mandibular prognathism, *J Dent Res* 94(9):1196–1201, 2015.
143. Kantaputra PN, Pruksametan A, Phondee N, et al.: ADAMTSL1 and mandibular prognathism, *Clin Genet* 95(4):507–515, 2019.
144. Perillo L, Monsurrò A, Bonci E, et al.: Genetic association of ARHGAP21 gene variant with mandibular prognathism, *J Dent Res* 94(4):569–576, 2015.
145. Kajii TS, Oka A, Saito F, et al.: Whole-exome sequencing in a Japanese pedigree implicates a rare non-synonymous single-nucleotide variant in BEST3 as a candidate for mandibular prognathism, *Bone* 122:193–198, 2019.
146. Klumper GT, LA Morford LA, Hartsfield J, James Kennedy: In Kimberman Hera, Franchi Lorenzo, Ruellas Antonio, editors: *Effective, Efficient and Personalized Orthodontics: Patient-Centered Approaches And Innovations*, vol. 55, The University of Michigan Craniofacial Growth Series, 2019, pp 127–149.
147. Claes P, Roosenboom J, White JD, et al.: Genome-wide mapping of global-to-local genetic effects on human facial shape, *Nat Genet* 50(3):414, 2018.
148. Maor G, Segev Y, Phillip M: Testosterone stimulates insulin-like growth factor-I and insulin-like growth factor-I-receptor gene expression in the mandibular condyle—a model of endochondral ossification, *Endocrinology* 140(4):1901–1910, 1999.
149. Verdonck A, Gaethofs M, Carels C, et al.: Effect of low-dose testosterone treatment on craniofacial growth in boys with delayed puberty, *Eur J Orthod* 21(2):137–143, 1999.
150. Honjo H, Tamura T, Matsumoto Y, et al.: Estrogen as a growth factor to central nervous cells: Estrogen treatment promotes development of acetylcholinesterase-positive basal forebrain neurons transplanted in the anterior eye chamber, *J Steroid Biochem Mol Biol* 41(3–8):633–635, 1992.
151. Bulun SE, Sebastian S, Takayama K, et al.: The human CYP19 (aromatase P450) gene: update on physiologic roles and genomic organization of promoters, *J Steroid Biochem Mol Biol* 86(3–5):219–224, 2003.
152. Guo Y, Xiong DH, Yang TL, et al.: Polymorphisms of estrogen-biosynthesis genes CYP17 and CYP19 may influence age at menarche: a genetic association study in Caucasian females, *Hum Mol Genet* 15(16):2401–2408, 2006.
153. Schaefer K, Fink B, Grammer K, et al.: Female appearance: facial and bodily attractiveness as shape, *Psychol Sci* 48(2):187–204, 2006.
154. Schaefer K, Fink B, Mitteroecker P, et al.: Visualizing facial shape regression upon 2nd to 4th digit ratio and testosterone, *Coll Antropol* 29(2):415–419, 2005.
155. Hartsfield Jr JK, Zhou J, Chen S: The importance of analyzing specific genetic factors in facial growth for diagnosis and treatment planning, *Surgical Enhancement of Orthodontic Treatment*, Ann Arbor, 2010, University of Michigan, pp 267–281.
156. He S, Hartsfield Jr JK, Guo Y, et al.: Association between CYP19A1 genotype and pubertal sagittal jaw growth, *Am J Orthod Dentofacial Orthop* 142(5):662–670, 2012.
157. Hartsfield Jr JK, Morford LA, Otero LM: In Tech Rijeka, editor: *Genetic factors affecting facial growth. Orthodontics—Basic Aspects and Clinical Considerations*, 2012.
158. King L, Harris EF, Tolley EA: Heritability of cephalometric and occlusal variables as assessed from siblings with overt malocclusions, *Am J Orthod Dentofacial Orthop* 104(2):121–131, 1993.
159. Harris JE: Genetic factors in the growth of the head. Inheritance of the craniofacial complex and malocclusion, *Dent Clin North Am* 19(1):151–160, 1975.
160. Harris EF, Butler ML: Patterns of incisor root resorption before and after orthodontic correction in cases with anterior open bites, *Am J Orthod Dentofacial Orthop* 101(2):112–119, 1992.

161. Harris EF, Robinson QC, Woods MA: An analysis of causes of apical root resorption in patients not treated orthodontically, *Quintessence Int* 24(6), 1993.
162. Killiany DM: In *Sem Orthod*, 5. Elsevier, 1999, pp 128–133.
163. Taithongchai R, Sookkorn K, Killiany DM: Facial and dentoalveolar structure and the prediction of apical root shortening, *Am J Orthod Dentofacial Orthop* 110(3):296–302, 1996.
164. Iglesias-Linares A, Hartsfield J: Cellular and molecular pathways leading to external root resorption, *J Dent Res* 96(2):145–152, 2017.
165. Sameshima GT, Sinclair PM: Predicting and preventing root resorption: Part I. Diagnostic factors, *Am J Orthod Dentofacial Orthop* 119(5):505–510, 2001.
166. Baumrind S, Korn EL, Boyd RL: Apical root resorption in orthodontically treated adults, *Am J Orthod Dentofacial Orthop* 110(3):311–320, 1996.
167. Horiuchi A, Hotokezaka H, Kobayashi K: Correlation between cortical plate proximity and apical root resorption, *Am J Orthod Dentofacial Orthop* 114(3):311–318, 1998.
168. Linge L, Linge BO: Patient characteristics and treatment variables associated with apical root resorption during orthodontic treatment, *Am J Orthod Dentofacial Orthop* 99(1):35–43, 1991.
169. Owman-Moll P, Kurol J, Lundgren D: Continuous versus interrupted continuous orthodontic force related to early tooth movement and root resorption, *Angle Orthod* 65(6):395–401, 1995.
170. Kurol J, Owman-Moll P, Lundgren D: Time-related root resorption after application of a controlled continuous orthodontic force, *Am J Orthod Dentofacial Orthop* 110(3):303–310, 1996.
171. Ngan DC: *The Genetic Contribution to Orthodontic Root Resorption: a Retrospective Twin Study*. University of Sydney, 2003.
172. Harris EF, Kineret SE, Tolley EA: A heritable component for external apical root resorption in patients treated orthodontically, *Am J Orthod Dentofacial Orthop* 111(3):301–309, 1997.
173. Hartsfield Jr JK, Everett ET, Al-Qawasmi RA: Genetic factors in external apical root resorption and orthodontic treatment, *Crit Rev Oral Biol Med* 15(2):115–122, 2004.
174. Abass SK, Hartsfield Jr JK, Al-Qawasmi RA, et al.: Inheritance of susceptibility to root resorption associated with orthodontic force in mice, *Am J Orthod Dentofacial Orthop* 134(6):742–750, 2008.
175. Al-Qawasmi RA, Hartsfield Jr JK, Everett ET, et al.: Root resorption associated with orthodontic force in inbred mice: genetic contributions, *Eur J Orthod* 28(1):13–19, 2006.
176. Al-Qawasmi RA, Hartsfield JK, Everett ET, et al.: Root resorption associated with orthodontic force in IL-1B knockout mouse, *J Musculoskelet Neuronal Interact* 4(4):383, 2004.
177. Hartsfield Jr J: Pathways in external apical root resorption associated with orthodontia, *Orthod Craniofac Res* 12(3):236–242, 2009.
178. Vecilli RF, Katona TR, Chen J, et al.: Three-dimensional mechanical environment of orthodontic tooth movement and root resorption, *Am J Orthod Dentofacial Orthop* 133(6), 2008. 791–e11.
179. Vecilli RF, Katona TR, Chen J, et al.: Orthodontic mechanotransduction and the role of the P2X7 receptor, *Am J Orthod Dentofacial Orthop* 135(6), 2009. 694–e1.
180. Al-Qawasmi RA, Hartsfield Jr JK, Everett ET, et al.: Genetic predisposition to external apical root resorption, *Am J Orthod Dentofacial Orthop* 123(3):242–252, 2003.
181. Lages EM, Drummond AF, Pretti H, et al.: Association of functional gene polymorphism IL-1beta in patients with external apical root resorption, *Am J Orthod Dentofacial Orthop* 136(4):542–546, 2009.
182. Iglesias-Linares A, Yañez-Vico R, Ballesta-Mudarra S, et al.: Post-orthodontic external root resorption is associated with IL1 receptor antagonist gene variations, *Oral Dis* 18(2):198–205, 2012.
183. Tomoyasu Y, Yamaguchi T, Tajima A, et al.: External apical root resorption and the interleukin-1B gene polymorphism in the Japanese population, *Orthod Waves* 68(4):152–157, 2009.
184. Gülden N, Eggermann T, Zerres K, et al.: Interleukin-1 polymorphisms in relation to external apical root resorption (EARR), *J Orofac Orthop* 70(1):20–38, 2009.
185. Pereira S, Lavado N, Nogueira L, et al.: Polymorphisms of genes encoding P2X7R, IL-1 B, OPG and RANK in orthodontic-induced apical root resorption, *Oral Dis* 20(7):659–667, 2014.
186. Linhartova P, Cernochova P, Izakovcova Holla L: IL1 gene polymorphisms in relation to external apical root resorption concurrent with orthodontia, *Oral Dis* 19(3):262–270, 2013.
187. Wu FL, Wang LY, Huang YQ, et al.: Interleukin-1β+ 3954 polymorphisms and risk of external apical root resorption in orthodontic treatment: A meta-analysis, *Genet Mol Res* 12(4):4678–4686, 2012.
188. Shields ED, Bixler D, Fogh-Andersen P: Facial clefts in Danish twins, *Cleft Palate J* 16(1):1–6, 1979.
189. Fogh-Andersen P, Aagesen E: Inheritance of harelip and cleft palate: contribution to the elucidation of the etiology of the congenital clefts of the face, 1942. Copenhagen..
190. Metrakos J, Metrakos K, Baxter H: Clefts of the lip and palate in twins: including a discordant pair whose monozygosity was confirmed by skin transplants, *Plast Reconstr Surg* 22(2):109–122, 1958.
191. Lidral AC, Moreno LM, Bullard SA: In *Sem Orthod*, 14. Elsevier, 2008, pp 103–114.
192. Ward R, Moore E, Hartsfield Jr J: In Wyszynski Diego F, editor: *Cleft lip and palate: from origin to treatment*, Oxford University Press, 2002.
193. Weinberg SM, Neiswanger K, Richtsmeier JT, et al.: Three-dimensional morphometric analysis of craniofacial shape in the unaffected relatives of individuals with nonsyndromic orofacial clefts: a possible marker for genetic susceptibility, *Am J Med Genet A* 146(4):409–420, 2008.
194. Weinberg SM, Brandon CA, McHenry TH, et al.: Rethinking isolated cleft palate: evidence of occult lip defects in a subset of cases, *Am J Med Genet A* 146(13):1670–1675, 2008.
195. Leslie EJ, Marazita ML: In *Am J Med Genet C*, 163. Wiley Online Library, 2013, pp 246–258.
196. Yazdy MM, Honein MA, Xing J: Reduction in orofacial clefts following folic acid fortification of the US grain supply, *Birth Defects Res A Clin Mol Teratol* 79(1):16–23, 2007.
197. Yazdy MM, Honein MA, Rasmussen SA, et al.: Priorities for future public health research in orofacial clefts, *Cleft Palate-Cran J* 44(4):351–357, 2007.

## 7

# Child Abuse and Neglect

SHANNON L. THOMPSON and BRIAN J. SANDERS

**CHAPTER OUTLINE****Defining Child Abuse**

Physical Abuse

Sexual Abuse

Neglect

Emotional or Psychological Abuse

Medical Child Abuse

Human Trafficking

**The Victims of Abuse****Possible Indicators of Child Abuse**

Physical Indicators

Behavioral Indicators

**Evaluating Suspected Cases of Child Abuse**

History-Taking

Communication With the Patient

Physical Examination

**Managing Suspected Cases of Child Abuse**

Treatment

Documentation

Reporting

Parental Concerns

**Understanding the Legal Requirements**

Obligation of the Dentist

**Conclusion**

Child abuse and neglect affect millions of children in the United States each year and are found in all ethnic, cultural, and socioeconomic sections of our society. The long-term effects resulting from child maltreatment are deleterious and often involve physical, cognitive, and emotional impairments in childhood that clearly correlate with morbidity in adulthood. Orofacial trauma is present in approximately 50%–75% of all reported cases of physical abuse.<sup>1</sup> Oral health issues are also commonly seen in human trafficking victims.<sup>2</sup> Many of the injuries common to abuse in children are thus within the scope of dentistry and are easily observed by the dental professional.<sup>1</sup> This places dental professionals in a unique position to identify victims of child maltreatment. Dentists must, therefore, be knowledgeable of their responsibilities in the recognition, documentation, treatment, and reporting of suspected child abuse cases. To ensure appropriate intervention, dental professionals must first be willing to consider the possibility of abuse or neglect when faced with unusual injuries.<sup>3</sup> “The public and the profession are best served by dentists who are familiar with identifying the signs of abuse and neglect and knowledgeable about the appropriate intervention resources ...” (statement by ADA’s Council on Ethics, Bylaws, and Judicial Affairs, April 2000). This chapter includes a discussion of the types of child maltreatment frequently encountered, the clinical presentation and management of suspected child abuse, and the documentation and reporting required in these cases.

## Defining Child Abuse

Child abuse and neglect encompass a variety of experiences that are threatening or harmful to the child and are the result of acts of commission or omission on the part of a responsible caregiver. Child maltreatment can present in many forms and may be divided into the categories of physical abuse, sexual abuse, emotional or psychological abuse, and neglect (Table 7.1).<sup>4</sup> Although maltreatment is not always willful, meaning that the harm or injury inflicted is not always intended, it can nonetheless result in significant damage to the child and, in many cases, even death. Professionals from multidisciplinary backgrounds working together are in the best position to identify, treat, and intervene on the behalf of this vulnerable population. Dental professionals also have an opportunity to play a proactive role in helping these victims by recognizing child abuse in its many forms.

### PHYSICAL ABUSE

Physical abuse can be defined as a nonaccidental inflicted physical injury (ranging from minor bruises to severe fractures or death) that occurs as a result of harming a child by a parent, caregiver, or other person who has responsibility for the child.<sup>5</sup> It is often the most easily recognized form of child maltreatment. The *battered child syndrome* was initially



**TABLE 7.1** Types of Child Maltreatment<sup>4</sup>

Types of Abuse	Description
Physical abuse	Any nonaccidental injury or trauma to the body of a child by a parent or caregiver.
Sexual abuse	Any sexual behavior or activity with a minor or the exploitation of a minor, by an adult, for the sexual pleasure of someone else.
Neglect	Occurs when an adult knowingly permits a child to endure pain or suffering or fails to provide the basic needs for proper development. Categorized as physical, medical, educational, and emotional.
Emotional abuse	A pattern of behavior that impedes a child's development and self-esteem by constant criticizing or belittling or failing to provide love and/or appropriate guidance.

described by Kempe et al. in 1962 and was further elaborated by Kempe and Helfer in 1972, as the clinical picture of physical trauma in which the explanation of injury was not consistent with the severity and type of injury observed.<sup>6,7</sup> Physical abuse is usually recognized by the pattern of injury and/or its inconsistency with the related history. Bruises, welts, fractures, burns, and lacerations are examples of commonly inflicted physical injuries. Studies have consistently shown that head, face, and neck injuries that can easily be recognized by the dentist occur in more than half the cases of child abuse,<sup>8</sup> and 25% of physical abuse injuries occur in or around the mouth.

## SEXUAL ABUSE

Sexual abuse is defined by the Federal Child Abuse Prevention and Treatment Act as “the employment, use, persuasion, inducement, enticement, or coercion of any child to engage in, or assist any other person to engage in, any sexually explicit conduct or simulation of such conduct for the purpose of producing a visual depiction of such conduct; or the rape, and in cases of caregiver or interfamilial relationships, statutory rape, molestation, prostitution, or other form of sexual exploitation of children, or incest with children.”<sup>5</sup> Sexual abuse essentially includes any sexually stimulating activity that is inappropriate for the child's age, level of cognitive development, or role within the family. Sexually abusive acts can include activities such as exhibitionism, kissing, fondling, intercourse, child pornography, child prostitution, and rape. Oral findings of trauma to the mouth from sexual contact or lesions from sexually transmitted infections can readily be identified by dentists who maintain a high index of suspicion when faced with these findings. Some states include age criteria or an age differential in their statutes defining some forms of sexual abuse. Practitioners should be aware that there are differences in state definitions.

## NEGLECT

Neglect is the failure of a parent, guardian, or other caregiver to provide for a child's basic needs. It can be further categorized as physical (e.g., failure to provide necessary food or shelter, lack of appropriate supervision), medical (e.g., failure to provide necessary medical or mental health

treatment), educational (e.g., failure to educate a child or attend to special education needs), or emotional (e.g., inattention to a child's emotional needs, failure to provide psychological care, or permitting the child to use alcohol or other drugs).<sup>5</sup> Whereas physical abuse tends to be episodic, neglect tends to be chronic and more insidious and may present through failure to take the child for appropriate dental care, which may be just one manifestation of a larger picture of neglect.<sup>9</sup> The American Academy of Pediatric Dentistry defines dental neglect as the “willful failure of a parent or guardian to seek and follow through with treatment necessary to ensure a level of oral health essential for adequate function and freedom from pain and infection,”<sup>10</sup> and is the most frequent type of abuse seen by dentists.<sup>11</sup> Factors that can play a role in failure to seek adequate dental care can include family isolation, lack of finances, parental ignorance, or lack of perceived value of oral health.<sup>8</sup> Dentists should be aware of these factors and attempt to assist families in overcoming these barriers when possible. The level of medical and dental care, adequate nutrition, and adequate food and clothing must be considered in light of cultural and religious differences, poverty, and community requirements and standards, and the impact of such neglect on the physical well-being of the child.

## EMOTIONAL OR PSYCHOLOGICAL ABUSE

Emotional abuse can be defined as a pattern of behavior that impairs a child's emotional development or sense of self-worth, which may include constant criticism, threats, or rejection, as well as the withholding of love, support, or guidance.<sup>5</sup> It has been a concern for many years, but standards for identifying and proving such abuse have been extremely difficult to establish. Demonstrating the direct or causal link between the emotional and verbal abuse and the harm to the child can be difficult. Harm to the child generally occurs in various ways over a prolonged period of time and usually manifests as abnormal behaviors, high risk-taking behaviors, or mental health problems that are multifactorial in origin. Continuous isolation, rejection, degradation, terrorization, corruption, exploitation, and denial of affection are examples of behaviors that frequently have significant damaging effects on the child.

## MEDICAL CHILD ABUSE

Perhaps the most difficult form of child maltreatment to identify and treat is a fictitious disorder. Initially called *Munchausen syndrome by proxy*, and then *pediatric condition falsification*, the problem is one of child abuse in the medical setting. It occurs when a perpetrator (usually the mother) fabricates or exaggerates signs and/or symptoms of illness, or induces illness or signs and/or symptoms of illnesses in the child, causing unnecessary and harmful or potentially harmful testing, procedures, and treatments to be performed on the child. This form of abuse is different from all other forms of child maltreatment in that the medical community is unwittingly a part of the abuse. Because health care providers are often dependent on the parental history of the child's illness, it takes some time for the practitioner to realize the inconsistencies and possibly fabricated or exaggerated nature of the complaints. These children often

present with persistent and recurrent illnesses that cannot be explained and signs and symptoms that do not clinically make sense. The motivation of the perpetrators of this form of abuse can be multifactorial (e.g., to gain medical attention as a result of parental psychosis, or to obtain services or monetary benefit) but is not considered in the making of a diagnosis of medical child abuse. The bizarre nature of many of these cases makes them almost unbelievable even to the professionals involved, which can unfortunately lead to failure to protect the child.

## HUMAN TRAFFICKING

Human trafficking, as defined by the US Department of State is “the recruitment, harboring, transportation, provision, or obtaining of a person for labor or services through the use of force, fraud, or coercion for the purpose of subjection to involuntary servitude, peonage, debt bondage, or slavery.”<sup>12</sup> It is a serious child health concern that is only just beginning to be addressed in the United States. Medical providers, including dentists, need to be aware of the risk factors of this form of abuse as well as become familiar with resources available to help this vulnerable population, as they often present with dental problems either from oral trauma or stemming from malnutrition which can result in poorly formed teeth, dental caries, infections, and tooth loss.<sup>2</sup>

## The Victims of Abuse

Children from all walks of life can be victims of child abuse or neglect—no age, race, gender, or socioeconomic level is spared. Each year, millions of children are reported to children’s protective services or law enforcement authorities as suspected victims of abuse.<sup>2</sup> According to the National Child Abuse and Neglect Data System (NCANDS), child protective service agencies received an estimated 4.1 million referrals involving approximately 7.5 million children in the Federal Fiscal Year 2017.<sup>13</sup> Statistics on child abuse reflect only those cases known or suspected, and all studies struggle with the component of the unknown. The Child Maltreatment 2017 report (NCANDS) noted that, of the victims reported, 74.9% suffered neglect, 18.3% suffered physical abuse, and 8.6% suffered sexual abuse.<sup>13</sup> As is often the case, children may be the victim of more than one type of maltreatment. These statistics reflect a child counted once for each maltreatment type.

Sociodemographic characteristics of maltreated children vary somewhat by the type of abuse or neglect. According to the Child Maltreatment 2017 report, victims in their first year of life had the highest rate of victimization, at 25.3 per 1000 children of the same age in the national population. Boys accounted for 48.6% and girls accounted for 51% of victims, and the majority of victims consisted of three races or ethnicities—White (44.6%), Hispanic (22.3%), and African American (20.7%).<sup>13</sup> Child fatalities are clearly the most tragic consequence of maltreatment. Based on NCANDS 2017 data, a nationally estimated 1720 children died from abuse and neglect, an 11% increase from the 2013 national estimate of 1550 children. Again, the youngest children represented the largest percentage of fatalities as 71.8%

of all child fatalities were younger than 3 years and nearly one-half were younger than 1 year old. Just over 88% were of the three aforementioned ethnicities—White (41.9%), African American (31.5%), and Hispanic (15.1%).<sup>13</sup>

Most episodes of child abuse and neglect occur within the child’s family and are symptomatic of the family’s dysfunction.<sup>4</sup> Characteristics that are overrepresented among families of maltreated children and therefore considered risk factors include the presence of multiple children at home, lower socioeconomic status, interpartner violence, substance abuse, illness, and financial stress. Children living in violent homes are increasingly recognized as victims of maltreatment. Infants and young children are more likely to be abused because of their defenselessness, physical fragility, and inability to escape an angry parent or caregiver, whereas adolescents often trigger violent responses from their caregivers by challenging parental authority.<sup>14</sup> Risk factors certainly play a role, but ultimately, every child is a potential victim.

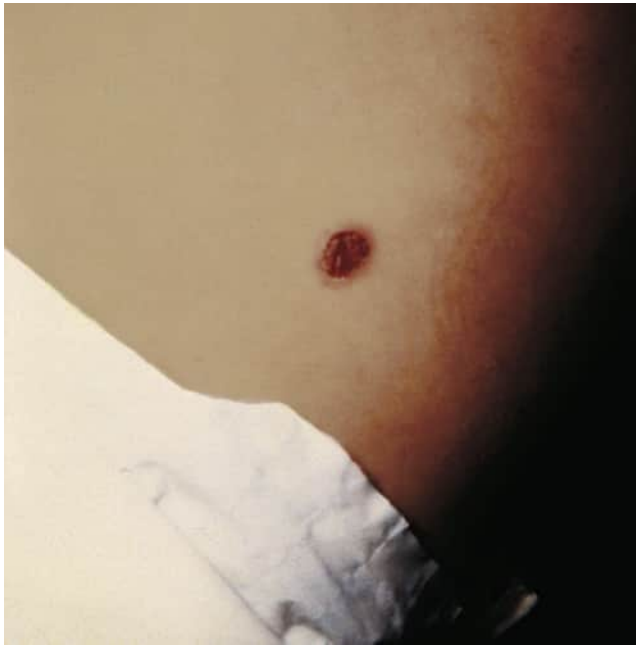## Possible Indicators of Child Abuse

As stated earlier, child abuse and neglect cannot be identified if it is not considered a diagnostic possibility. The dental professional must be willing to consider the diagnosis of abuse to make the diagnosis. Dentists who have been educated to recognize the signs of child maltreatment are five times more likely to make a report than dentists who have not.<sup>15</sup> Indicators of child abuse and neglect are those signs or symptoms that should raise one’s suspicions to the possibility of child maltreatment. The presence of such indicators is not diagnostic of maltreatment but should lead dentists to be more thoughtful in their consideration when faced with concerning injuries/illnesses. Many of the signs and symptoms are nonspecific and may be present for a variety of reasons. Child abuse should be included in the differential diagnosis. Indicators of abuse and neglect often depend on the child’s age and developmental level and may vary with the child’s experiences and resiliency.

## PHYSICAL INDICATORS

There are numerous common physical signs that should alert one to the possibility of physical abuse and/or neglect. Some physical indicators of physical abuse include unexplained bruises, fractures, burns, lacerations, and abrasions. Although many injuries are accidental, dental professionals should always maintain a high index of suspicion for any traumatic injury, especially those in which there is either no explanation given or the explanation is not consistent with or plausible for the injury seen.

Unexplained bruises, abrasions, welts, or lacerations in places not routinely subject to a child’s active lifestyle are among those that should be considered suspicious for abusive injury. For example, bruises on the shins and forehead or overlying bony prominences are expected in normal healthy active children, whereas those seen on the neck, upper arms, or abdomen are not. Bruising in any infant who is not yet ambulating or cruising is suspicious. Unexplained injuries on the face, especially the cheeks; clusters of bruises or bruises that appear patterned, reflecting the shape of an article; and



**Fig. 7.1** Intentional cigarette burn. (From Zitelli BJ, Davis HW: *Atlas of pediatric physical diagnosis*, ed 5, Philadelphia, 2008, Mosby.)

scattered significant bruises on different surface areas are all suspicious. The study by Pierce et al.<sup>15</sup> on bruising characteristics of abused children versus accidental injuries found clear evidence that the following should be considered a red flag and serve as an indication for possible physical abuse: bruising without a clear confirmatory history for any infant not cruising, and bruising to the torso-ear-neck-frenulum, angle of jaw, cheek, eyelid, subconjunctival hemorrhage (TEN FACES) region of a child younger than 4 years old (TEN-4 FACES clinical decision rule). Trauma resulting in injuries to the teeth, mouth, lips, tongue, or cheeks inconsistent with an accident is an indicator that should be readily identified by the dental professional.<sup>1</sup> Any unexplained fracture, especially in children younger than 2 years old, multiple fractures in various stages of healing, or injuries to the growth centers of bones should raise real concern. While all such injuries can be accidental, a clear and plausible explanation must be sought. For example, a simple linear skull fracture may result from a short-height fall (less than 3–4 feet). However, accompanying injury including significant intracranial hemorrhage with brain injury and severe multilayer retinal hemorrhages would not be expected from this history and thus highly suspicious for abusive head trauma. Burns are another form of recognizable child abuse. Intentional cigarette (Fig. 7.1) and immersion burns are readily distinguishable from accidental splash burns in that they typically have a uniform depth, clear lines of demarcation, and can often be symmetric. Suspicious burn patterns require a careful history and scene investigation to help ascertain the plausibility of any reported history. Another physical indicator of physical abuse is evidence of delayed or inappropriate treatment of injuries. Physical indicators of neglect can include abandonment, consistent lack of appropriate supervision, unattended medical or dental needs, an emaciated appearance, poor hygiene, or being inappropriately or inadequately dressed for conditions. Indicators of dental neglect include untreated extensive caries that could easily be

detected by a layperson; untreated pain, infection, bleeding, or trauma affecting the orofacial region; or lack of continuity of care in the presence of identified dental disease.<sup>4</sup>

## BEHAVIORAL INDICATORS

Significant behavioral changes often linked to the various forms of child maltreatment include withdrawal, depression, poor school performance, regression in developmentally appropriate behavior, acting out, clinginess, and somatic complaints. Young maltreated children may show inappropriate affection toward others or may be extremely wary and distant in social interactions. Many abused children will still demonstrate affection toward an abusive parent, which should not be construed as evidence against maltreatment. Children who express fear of going home, appear frightened by their parents, show a lack of spontaneous smiling, or avoid eye contact with their parents may be displaying known behavioral indicators for maltreatment. Any child who reports injury by caregivers should be taken seriously. While there are extensive lists of signs that purport to describe behavioral indicators of possible maltreatment, they should be considered in context of the child's entire clinical history and presentation and not in isolation. When other explanations for such behaviors are not found, maltreatment is an appropriate consideration.

Behavioral indicators for physical abuse may also be present in caregivers. These include both a lack of concern and inappropriately high levels of concern in relation to the severity of the child's injury, defensiveness or hostility when questioned, and refusal of recommended further evaluation and care for the child. Other behavioral indicators include an explanation that is inconsistent with the pattern of injury or the child's abilities or an explanation that changes when the perpetrator realizes that the first story was not believed. Poor judgment, jealousy or extreme protectiveness, excessive watchfulness or vigilance, child abandonment, violent behavior, and erratic behavior (suggesting substance abuse or mental illness) are other clues to possible maltreatment by caregivers. Indications of possible medical child abuse can include doctor or emergency department "shopping" or excessive use of medical care for an apparently well child. A child who is seen for repeated ingestions of harmful substances or has repeated hospitalizations for the same or similar constellation of symptoms with largely negative diagnostic testing is also concerning.

Like pediatricians, dental professionals have a continuing relationship with their pediatric patients and their families because it is often necessary for a patient to be seen several times a month.<sup>9</sup> This provides the dental professional with ample opportunity to recognize any concerning physical and behavioral indicators of physical abuse and neglect and to intervene when necessary to protect potential victims of abuse.

## Evaluating Suspected Cases of Child Abuse

Trauma to the orofacial structures is a frequent manifestation of child abuse and is present in as many as 50% to 75% of all reported cases of child physical abuse.<sup>1</sup> Because abusive



parents do not always show the same caution when visiting the dentist as when visiting the physician, the dental practitioner may be the first person to identify the abused child. The dentist must, therefore, learn to screen for maltreatment as a basic part of any clinical examination performed on a child<sup>16</sup> and complete a thorough history as well as a thorough dental and directed physical examination. The dentist must learn to recognize an abused child and make the appropriate referrals.<sup>17</sup>

## HISTORY-TAKING

A certain combination of information is what influences or creates the suspicion of possible child maltreatment. Historical information should include a complete dental and medical history. Details regarding any trauma should be complete and obtained separately from more than one source (e.g., parent and child), if possible, and in the presence of another staff member to act as a witness.<sup>16</sup> The use of open-ended questions is favored, and “yes” or “no” questions should be avoided. Often, the best question is, “What happened?” The dentist need ask only for a level of detail that would be indicative of a suspicion for reportable abuse or neglect. Such details might include who witnessed the injury and who was with the child at the time of the injury; where the child and supervising adults were at the time of the injury; and details about what, how, and when the incident occurred. A description of present and past injuries as well as the child’s developmental abilities is always helpful. Situations raising the strongest suspicions are those in which the pattern of injury is not consistent with the account offered to explain it. The history should be consistent with the injury as it relates to the mechanism and timing of the injury and the developmental level of the child. For example, a 6-month-old infant cannot sustain a frenulum tear from sucking on a pacifier. A bruise in the shape of a handprint on the cheek does not result from a fall at the park. (Fig. 7.2). Conflicting accounts from two or more individuals (e.g., parents or a parent and child) or historical accounts that change over time should raise concerns. Additionally, any significant injury that is reportedly “unwitnessed” can be a reasonable cause for suspicion.

## COMMUNICATION WITH THE PATIENT

In most circumstances, professionals who are identifying and reporting suspected child maltreatment will have to talk to children to clarify a possible suspicion. They should not, however, be conducting investigative interviews of children to learn explicit details or sort out the truthfulness of comments. The goal of questioning should be limited to obtaining the information needed to care appropriately for the child and help inform opinions about suspicions of child maltreatment. Based on this information including one’s own knowledge and experience, if there is reason to believe that the child may have been abused or neglected, a report should be made to the appropriate child protection agency, whose job is to investigate such concerns. It is appropriate to listen to and provide support for the child who is talking and wants to disclose more.

## PHYSICAL EXAMINATION

The examination of the patient by a dentist should include a careful and thorough intraoral and perioral examination

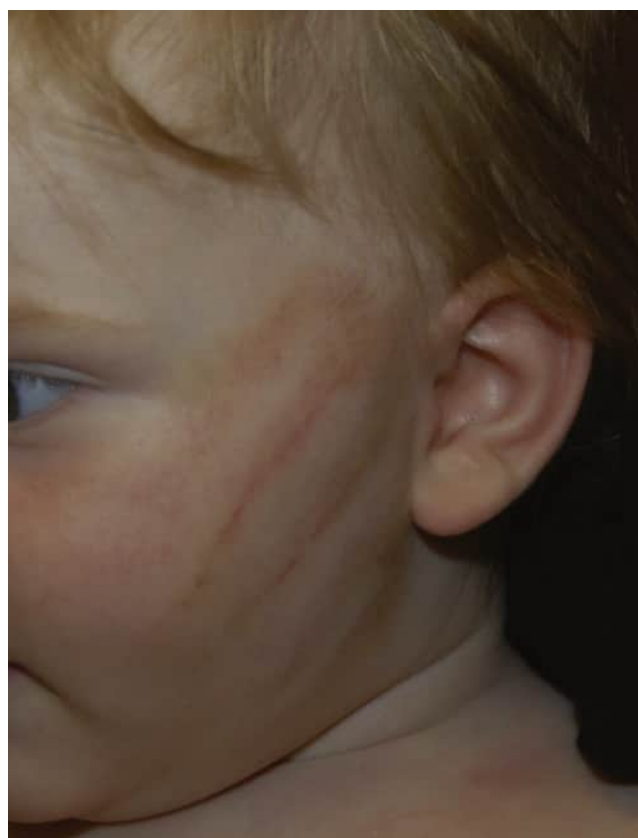
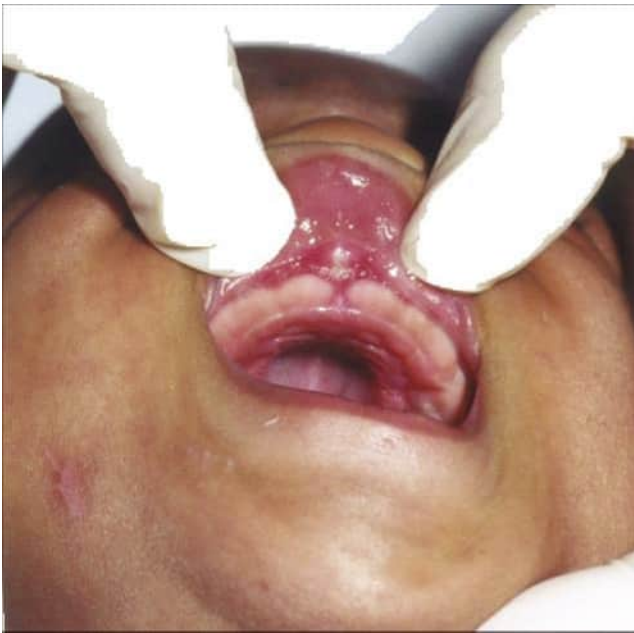
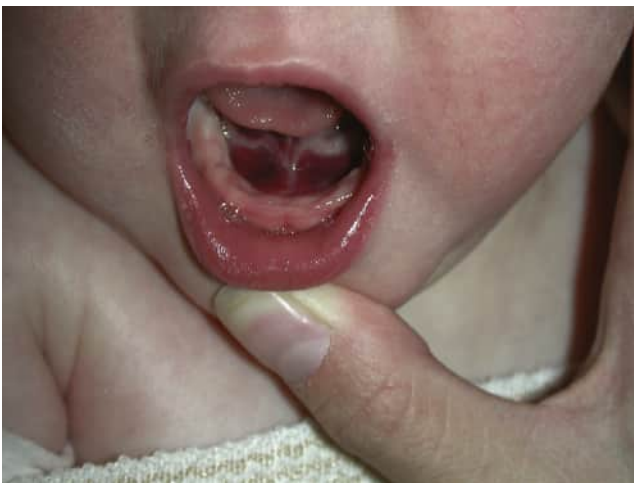Fig. 7.2 Bruise in the shape of a handprint on the cheek.

in addition to exposed areas of the body that can be examined without undressing the child. The examination should be completed before any treatment is initiated. Observations should be assessed in the context of the age, developmental level, and known history of the child, and should include the patient’s posture, gait, and clothing. Dental staff should also be trained in recognizing abuse and neglect so that they may alert the dentist if they have concerns. Inappropriate interaction between a child and a caregiver may be cause for concern. For example, a parent’s rough handling a child in the waiting room may be indicative of a history of physical abuse.

The physical examination should start at the top, beginning with careful visual examination and palpation of the head, including the hair, scalp, facial bones, and mouth, and systematically work down. Findings that may be of concern include alopecia, which without an underlying medical cause may be an indicator of malnutrition or hair pulling. Subgaleal hematoma can be the result of trauma to the scalp from direct trauma or violent hair pulling. Periorbital ecchymosis, subconjunctival hemorrhages, ptosis, and deviated or unequal pupils may indicate significant facial trauma. A nasal fracture, deviated septum, and clotted blood are nasal findings that may be of concern and indicate previous trauma. Bruising inside and behind the ears is worrisome for inflicted trauma. Other common orofacial injuries include lacerations, burns, abrasions, or bruises to the lips or corners of the mouth; labial (maxillary) or lingual frenum tears; burns or lacerations of the gingiva, tongue, palate, or floor of the mouth; and past or present fractures to the facial bones, condyles, ramus, or symphysis of the mandible, which can result in malocclusion.<sup>4</sup> Burns

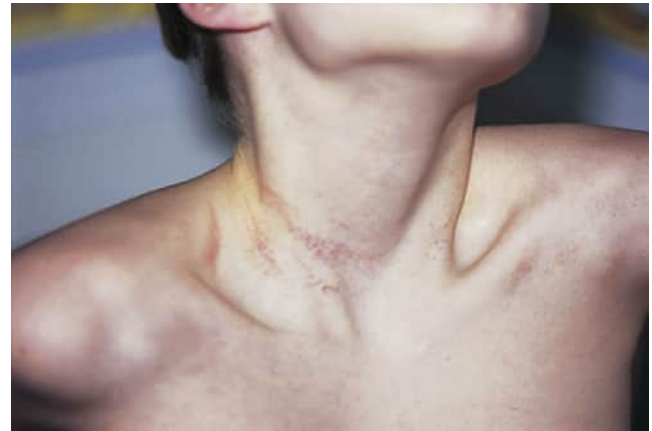

**Fig. 7.3** Torn frenulum from blunt force trauma to the mouth. Upon further investigation, this child was found to have 17 fractures.

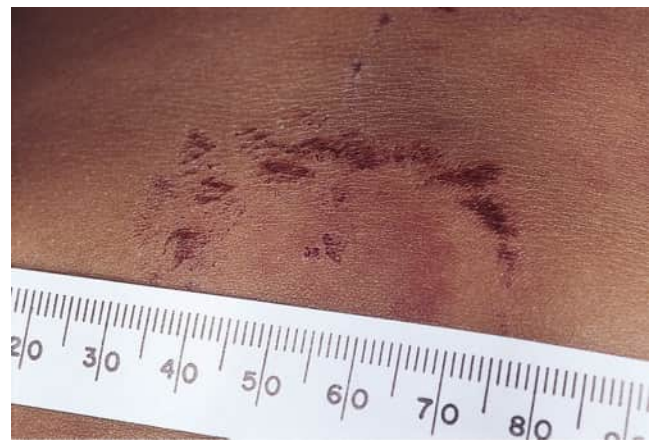

**Fig. 7.4** Sublingual hemorrhage in an infant with signs of genital and abdominal trauma.

can be the result of forced ingestion of hot or caustic substances. A torn maxillary frenum especially on a child who is not mobile may indicate blunt force trauma to the mouth (e.g., slap, fist blow, or forced feeding). Similarly, a torn lingual frenum could indicate blunt trauma from sexual abuse or forced feeding (Figs. 7.3 and 7.4). The mandible should be examined for any deviation on opening, range of motion, trismus, and occlusion at rest. The maxilla should also be examined for any mobility indicating a facial fracture. Bleeding under the tongue may indicate a fracture of the body of the mandible. Examination of the teeth and their supporting structures may also reveal concerns for abusive injury and may be present in the form of missing teeth or previously traumatized teeth (avulsions, luxations, intrusions, or fractures). Physical examination findings of a child with dental neglect may reveal a child with extensive untreated dental caries, untreated infection, or dental pain.



**Fig. 7.5** Attempted strangulation marks on the neck of an adolescent. (From Hobbs CJ, Wynne JM: *Physical signs of child abuse: a colour atlas*, ed 2, London, 2001, WB Saunders/Harcourt Publishers.)



**Fig. 7.6** The presence of an adult bite mark may be a sign of physical or sexual abuse or neglect. (From Shah BR, Laude TA: *Atlas of pediatric clinical diagnosis*, Philadelphia, 2000, WB Saunders.)

Any bruise in the shape of an object, such as a belt, looped cord, handprint, or hanger, should alert the practitioner to inflicted trauma. Bruising cannot be aged by its appearance, as various colors may be present over the course of their resolution. The neck should be examined for evidence of ligature marks or bruises (Fig. 7.5) with associated facial petechiae that may indicate attempted strangulation. Physical trauma to the child's chest or ribs may elicit a painful response from the child if a lifting motion is used to slide the child up to the top of the dental chair and may warrant further examination.

Bite marks should be suspected when bruising, abrasions, or lacerations are found in an elliptical or ovoid pattern.<sup>8</sup> Bite marks can occur anywhere, but most commonly are found on the facial cheeks, back, sides, arms, buttocks, and genitalia.<sup>4</sup> Human bites tend to compress flesh, whereas animal bites typically result in tears and avulsions of the flesh.<sup>8</sup> The presence of adult bite marks (Fig. 7.6) is usually associated with physical or sexual abuse.<sup>4</sup> In general, an intercanine distance (linear distance between the central points of the cuspid tips) measuring more than 3.0 cm is suspicious for an adult bite.<sup>8</sup> Identifying potential perpetrators through bite mark analysis is a complicated and inexact science and should be used with caution, as much



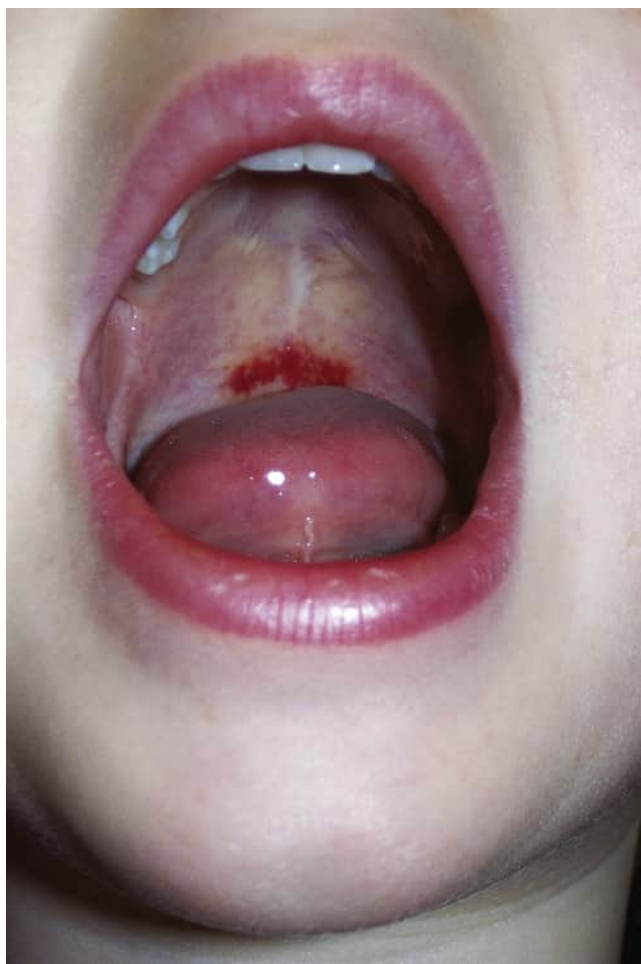

Fig. 7.7 Palatal hemorrhage from oral-genital contact.

more high quality research is needed.<sup>18</sup> The American Board of Forensic Odontology (ABFO) is currently continuing to research this subject in order to improve the quality and reliability of bite mark analysis.<sup>18</sup> It may be prudent to consult a forensic odontologist or pathologist when needed in cases where there is considerable suspicion for adult bites. Bite mark injuries should be clearly documented with detailed information regarding their pattern, size, contour, and color. They should be photographed, if possible, when they are first observed because they tend to fade rapidly. Photographs should include a patient identification tag and a scale marker and taken such that the angle of the camera lens is directly over the bite and perpendicular to the plane of the bite to avoid distortion.<sup>8</sup> The ABFO has developed a special photographic scale for this purpose, which can also be used in the documentation of other injuries (ABFO No. 2 reference scale, Lightning Powder Company Inc., Salem, OR, USA).<sup>8</sup> Most law enforcement agencies will dispatch a photographer if requested in child abuse cases.

Dentists are not as involved as other health professionals in the diagnosis of sexual abuse; however, there are certain signs and symptoms for which they should remain alert.<sup>4</sup> Bruising, erythema, or petechiae at the junction of the soft and hard palates may indicate forced oral penetration (Fig. 7.7). Oral manifestations of sexually transmitted infections can be apparent in sexually abused children. Gonorrhea

may appear symptomatically as anything from erythema to ulcerations and from vesiculopustular to pseudomembranous lesions on the lips, tongue, palate, and/or pharynx.<sup>4</sup> Syphilis may manifest as a papule on the lip or skin at the site of inoculation, which later ulcerates to form the classic chancre in primary syphilis, and as a generalized maculopapular rash in secondary syphilis.<sup>4</sup> Condylomata acuminata (human papilloma virus [HPV]) can appear as single or multiple raised pedunculated, cauliflower-like lesions in the oral cavity as well as genital and anal areas.<sup>4</sup> Herpes simplex virus (HSV) presents as oral or perioral painful erythematous eruptions with grape like clusters of vesicles that rupture to form crusted-over lesions. Notably, HPV and HSV may not indicate sexual abuse as they have both vertical (mother-to-child transmission in utero or during birth) and horizontal (person-to-person or to self-transmission via direct physical contact, airborne, or environmental contact) modes of transmission. Depending on the circumstances, their presence should raise the consideration of sexual abuse. The presence of gonorrhea or syphilis, however, are both diagnostic of sexual abuse in an otherwise healthy child. Pregnancy in a child under the age of sexual consent (varies by state, but generally 12–13 years) is also diagnostic of sexual abuse and should be reported. It is the combination of a complete history and physical examination that should form one's basis for the suspicion of child maltreatment, all while considering the differential diagnosis. The primary goal of detection is to prevent further injury to the child.

## Managing Suspected Cases of Child Abuse

Clinical and medicolegal management of suspected child abuse and neglect involves several basic steps: appropriate medical and dental treatment, complete and objective documentation (including photographs), and reporting. There are numerous reports in the dental literature in which dentists initially suspected abuse-based orofacial injuries, many of which were instances of severe child abuse resulting in hospitalization or death.<sup>19</sup> As health care professionals, dentists should be especially sensitive to the need for protecting children from abuse and neglect and should adopt routine protocols for the management of these cases when suspicion exists.

### TREATMENT

Any medical or dental treatment that is indicated by the child's condition should be provided. The dentist can ensure that a child receives the immediate necessary attention. In cases of child abuse or neglect, if the dentist feels competent and the problem or injury is restricted to the mouth, definitive dental/medical care should be initiated. More extensive trauma (e.g., fractures, lacerations, serious injuries to the head) should be referred to the appropriate medical and dental specialists.<sup>4</sup> For example, a maxillofacial surgeon may be best qualified to provide treatment for instances of severe trauma to the jaw, alveoli, or intraoral soft tissues.<sup>19</sup> A plastic surgeon may be best qualified to treat facial lacerations requiring extensive suturing.<sup>19</sup> In cases of suspected



head trauma, the child should be referred to a pediatrician or neurosurgeon familiar with child abuse as soon as possible. Referral to a local emergency room (ER)/hospital may be indicated for other trauma involving the body, head, or extremities. Additionally, some cases may require referral to the child's primary care provider or a child abuse pediatrician who can assist in considering the complete differential diagnosis, identify medical conditions that can mimic or be confused with child abuse, and perform any additional medical evaluation necessary.<sup>20</sup> The dentist should always notify the specialist or hospital/ER regarding his/her concern of maltreatment so that these individuals may also be sensitive and helpful in assessing the possibility of abuse.<sup>4,19</sup> Referral to a physician does not eliminate the dentist's obligation to make a report to authorities if maltreatment is suspected. If the treatment is within the scope of the dentist's mandate, definitive care should be given, followed by a discussion with the caregiver regarding the treatment provided, the prognosis, and any necessary follow-up care prior to any discussion of the suspicion of child abuse.<sup>19</sup>

## DOCUMENTATION

All data collected in the medical history and physical examination must be documented in a complete and objective manner. Pertinent positive and negative findings should be included. Findings should be documented with a detailed description of the injuries and the history obtained for how they occurred. Actual comments in quotations should be recorded whenever possible. Behaviors should also be objectively noted, and opinions about those behaviors should be avoided. If possible, photographs of any visible injuries should be obtained, with the child's name and date of the photograph included in the picture. Most law enforcement officials will take photographs if requested to do so when suspected child abuse is reported. Furthermore, document the reason why maltreatment is suspected. When suspected maltreatment is reported to authorities, the time, date, and method of reporting (telephone or written report) should also be documented in the medical and dental record.

## REPORTING

Dentists must be informed about their responsibilities in relation to child maltreatment as outlined by the American Dental Association. The dentist is obligated by law to report suspected findings of child abuse to child protective service agencies and/or law enforcement officials. Reports of suspected child maltreatment to local authorities mandated to investigate allegations are allowable without parental consent under Health Insurance Portability and Accountability Act regulations. Underreporting is a concern among all health professionals and is not unique to dentists.<sup>21</sup> Health care professionals are likely to underreport cases of suspected abuse because of their own values and attitudes toward abuse,<sup>21</sup> concerns about making false accusations,<sup>1</sup> or lack of adequate training or education in the recognition of child maltreatment.<sup>19</sup> With increased public awareness and the inclusion of courses on child abuse in the dental curriculum, ignorance of the laws regarding child abuse is not an acceptable excuse. Health professionals who fail to report reasonable suspicions of abuse may be subject to civil

or criminal charges. Those who report in good faith are protected from civil and criminal liability.

Reporting is initiated simply with a telephone call to the appropriate child protective service or law enforcement agency, depending on local statutes. The telephone call initiates a response by professionals trained in investigating and recognizing child abuse. The reasons for the suspicion, with supporting documentation, should be communicated both verbally and in writing. Dentists are mandated to report based on "reasonable suspicion" and are not responsible for any further investigation. If the concern is dental neglect, the dentist must work with the authorities to educate them on the diagnosis and need for care and then establish and follow through on a plan of treatment. While it is possible to report suspected child abuse anonymously in most states, it is preferred that one provide contact information to help the agency understand the concerns. There should be no reluctance on the part of the dentist to report suspected child abuse due to concerns that it will require a great deal of time. In most cases once the initial report has been filed, no further involvement is necessary on the part of the dentist, and few cases require a court appearance. Detailed documentation in the dental record may reduce the likelihood of the need for a personal appearance.

## PARENTAL CONCERNS

In most situations, parents should be told about concerns of possible child abuse or neglect and the legal requirement to report it to local authorities. This can help maintain the relationship with the patient and family. It can also be helpful to ask the parent if there has ever been a concern that someone might have hurt the child. Health care professionals should be careful not to make any accusations about who may have caused the harm. One may consider using the following simple and direct statement: "Because of an injury like this in a child of this age, we have to think about all of the possible causes. Whenever we are faced with this, I am required by law to make a report to Child Protective Services." When the dentist's action is presented to parents as motivated by concern for the child and by an attitude of partnership in an effort to determine what has happened, many parents are eventually appreciative and will continue to seek support and care from the reporting professional.

In situations in which a child is suspected to have been significantly harmed in the home, in which the parent is expected to be violent, or in which possible retribution against the child for having made a disclosure about abuse is a concern, it may be more prudent to contact the authorities first and have them present to protect the child before parents are informed about suspicions of abuse. Discussion about the severity of the situation with the authorities will aid in determining a plan about the disposition of the child (e.g., whether you should release the child from the office or await the arrival of the authorities). The dental professional has no legal obligation to inform parents that abuse or neglect is suspected or will be reported. Decisions about this should be tailored to the specific situation. The welfare of the patient should be at the forefront of all decision making, and any concerns about losing a patient from a practice should be secondary.

## Understanding the Legal Requirements

There are mandates in all 50 states requiring that suspected child abuse and neglect be reported to proper state authorities by dental professionals.<sup>21</sup> These statutes may vary somewhat from state to state regarding detailed definitions of child abuse and neglect, but there is no variance in the identification of all health care professionals as mandated reporters. It is important to emphasize that one is required to report reasonable suspicions of child maltreatment, not proven allegations of abuse. Once suspicions have been reported, it is the responsibility of social and legal authorities to determine the needs of the child and family, whether maltreatment has occurred, and what intervention or service is legally allowable or necessary.

### OBLIGATION OF THE DENTIST

Dental professionals are mandated reporters under state law and may face criminal sanctions for failing to report cases. They also have a defined ethical duty to report and may be subject to private civil malpractice lawsuits if they fail to notify state child protection agencies when appropriate.<sup>21</sup> Some state statutes allow the mandated reporter to be held liable for proximate damages caused by the failure to report. The privileged quality of communication between the caregivers or the patient and the practitioner is not grounds for excluding evidence in a judicial proceeding that either results from a report or results from failure to make a report as required by law. Strict confidentiality of records should always be maintained. Reports and any other information obtained in reference to a report are confidential and available only to persons authorized by the juvenile code to examine them.

Again, it must be understood that absolute proof is not required when making reports about suspicions of abuse. It is the responsibility of child protective service agencies and law enforcement officials to investigate suspicions and determine whether intervention is necessary. The health care professional can provide invaluable assistance by giving as much information as possible through communication and coordination. Investigating professionals cannot do their jobs if the health care professional does not share detailed information regarding why the suspicions exist. Health care professionals who are unhappy with the outcome of system intervention (e.g., nothing was done) are usually those who would not or did not provide the information available that would have assisted authorities in making the best-informed decisions. If the health care professional believes that a bad decision is being made, a follow-up telephone call to the assigned case worker or case worker's supervisor to clarify concerns and interventions is appropriate. Many misperceptions exist about what interventions are possible legally. Clear communication and coordination can improve everyone's knowledge and understanding about a child's needs and what can be done to meet them.

In cases of dental neglect, the dentist should determine whether the failure to provide dental care is willful or due to a lack of awareness, lack of finances, or lack of perceived value of health care prior to filing a report with proper

authorities. Taking a good medical and dental history and making repeated attempts to obtain appropriate treatment for the child can help resolve these issues. Dentists must be aware of these factors and attempt to assist families to overcome any identified barriers as well as provide clear explanations regarding the disease and its implications.<sup>8</sup> A report to a child protective service agency is indicated if repeated attempts to address the cause of the dental neglect are not met with success, since the manifestations of dental neglect (e.g., dental caries, periodontal disease) can cause significant pain, infection, and loss of oral function if left untreated. This can result in adverse effects on learning, communication, nutrition, and other activities necessary for normal growth and development.<sup>8</sup>

## Conclusion

Consequences of child abuse can be devastating, often manifesting in short- and long-term emotional and physical problems, cognitive impairments, and mental health disturbances.<sup>4</sup> Society is also adversely affected by child abuse through the substantial direct costs resulting from the investigation and prosecution, and resulting health care costs.<sup>4</sup> Of the abused children who are returned to the same environment without intervention, it is known that many will be seriously reinjured or killed. This same risk exists for all contact children in the same environment.<sup>22</sup> It is thus imperative that health care professionals appropriately recognize and report suspected victims of child maltreatment to prevent further injury and/or death to the child and any contact children/siblings. Dental professionals and offices can be instrumental in prevention efforts as well by facilitating community awareness of child abuse through the provision of resource materials in waiting rooms, participation in organizations concerned with ending violence, and ensuring that all office staff become familiar with the signs of abuse and be encouraged in the pursuit of continuing education on the subject.<sup>16</sup>

### References

1. Santos JF, Cavalcanti AL, Nunes KS, et al.: Primary identification of an abused child in dental office: a case report. *J Indian Soc Pedodont Prev Dent* 25(4):191–193, 2007.
2. Fisher-Owens SA, Lukefahr JL, Tate AR, et al.: Oral and dental aspects of child abuse and neglect. *Pediatrics* 140(2):e20171487, 2017
3. Jones R, Flaherty EG, Binns HJ, et al.: Clinicians' description of factors influencing their reporting of suspected child abuse: report of the child abuse reporting experience study research group. *Pediatrics* 112(2):259–266, 2008.
4. Jessee S, Deinard S. Child abuse and neglect: implications for the dental professional, Crest Oral-B at [dentalcare.com](http://dentalcare.com), Continuing Education Course, Revised March 31st 2015.
5. Child Information Gateway Factsheet: *What is child abuse and neglect? Recognizing the signs and symptoms*, [www.childwelfare.gov](http://www.childwelfare.gov). Accessed October 4, 2019.
6. Kempe CH, Silverman FN, Steele BF, et al.: The battered-child syndrome. *J Am Med Assoc* 181(1):17–24, 1962.
7. Kempe C, Helfer R. *Helping the battered child and his family*. JB Lippincott: Philadelphia.
8. American Academy of Pediatric Dentistry: *Guideline on oral and dental aspects of child abuse and neglect*, AAP Committee on Child Abuse and Neglect and AAPD, Adopted, 1999, Council on Clinical Affairs. Revised 2005, Reaffirmed 2010.
9. Kiran K, Kamala BK: Child abuse and the role of a dental professional – the Indian scenario. *Child Abuse Negl* 35(3):157–158, 2011.

10. American Academy of Pediatric Dentistry: Definition of dental neglect, *Pediatr Dent Reference Manual* 40(6):13, 2018-2019.
11. Kilpatrick NM, Scott J, Robinson S, et al.: Child protection: a survey of experience and knowledge within the dental profession of New South Wales, Australia, *Int J Ped Dent* 9(3):153–159, 1999.
12. US Department of State: *Trafficking in persons report*, 2007. Available at [www.state.gov/j/tip/rls/tiprpt/2007/](http://www.state.gov/j/tip/rls/tiprpt/2007/)
13. U.S. Department of Health and Human Services. Administration for Children and Families, Administration on Children, Youth and Families, Children's Bureau. Child maltreatment (2017). available from, <http://www.acf.hhs.gov/programs/cb/research-data-technology/statistics-research/child-maltreatment>. Accessed October 4, 2019.
14. da Fonseca MA, Feigal RJ, Ten Benschel RW, et al.: Dental aspects of 1248 cases of child maltreatment on file at a major county hospital, *Pediatr Dent* 14(3):152–157, 1992.
15. Pierce MC, Kaczor K, Aldridge S, et al.: Bruising characteristics discriminating physical child abuse from accidental trauma, *Pediatrics* 125(1):67–74, 2010.
16. Tsang A, Sweet D: Detecting child abuse and neglect—are dentists doing enough? *J Can Dent Assoc* 65:387–391, 1999.
17. Harris JC, Sidebotham PD, Welbury RR: Safeguarding children in dental practice, *Primary Care Dent* 34(8):508–517, 2007.
18. Hinchliffe J: Forensic odontology, part 4. Human bite marks, *BDJ* 210:363–368, 2011
19. Needleman HL: Orofacial trauma in child abuse: types, prevalence, management and the dental profession's involvement, *Pediatr Dent* 8(1):71–80, 1986.
20. Kellogg N: Oral and dental aspects of child abuse and neglect, *Pediatrics* 116(6):1565–1568, 2005.
21. Katner DR, Brown C: Mandatory reporting of oral injuries indicating possible child abuse, *J Am Dent Assoc* 143(10):1087–1091, 2012.
22. Lindberg DM, Shapiro RA, Laskey AL, et al.: Prevalence of abusive injuries in siblings and household contacts of physically abused children, *Pediatrics* 130(2):193–201, 2012.



**Case Clinical Vignette**

“Eric” is a 7-year-old boy presenting for his 6-month comprehensive dental examination on one of the hottest days on record. You are familiar with Eric’s mother and understand that she recently remarried. Eric presents today with his stepfather, who appears agitated and impatient. Eric makes very little eye contact with his stepfather and appears withdrawn. You immediately notice Eric is wearing a long-sleeved shirt and jeans despite the heat, whereas his stepfather is dressed appropriately in t-shirt and shorts. When Eric sits in the examination chair, you notice bruising to his both of his ears. You take Eric for x-rays while his stepfather waits in the examination room; at this point, you take the opportunity to ask Eric about his clothing on such a hot day. He is more quiet than you recall and shrugs his shoulders. When you help him up in the chair while gripping his arm, he visibly winces in pain. Having been Eric’s dentist since he was 3 years old, you ask him what happened. Eric tells you that his stepfather is mean and does not like him. He tells you that his stepfather is mean to his mom too and that is why she did not come today. Eric then gingerly lifts his sleeve revealing linear bruising around his arm with swelling and redness.

Questions:

1. What are some physical indicators of abuse in this scenario?
2. What are some behavioral indicators of abuse in this scenario?
3. What should you document in this scenario?
4. What is your role as mandated reporter in this scenario?
5. What are some things you should consider in ensuring Eric gets the treatment and evaluation he needs?

## 8

# Mechanical and Chemotherapeutic Home Oral Hygiene

CHRISTOPHER V. HUGHES and JEFFREY A. DEAN

## CHAPTER OUTLINE

### Microbial Aspects of Oral Hygiene and Plaque Formation

#### Mechanical Methods of Plaque Control

Manual Toothbrush

Floss

Powered Mechanical Plaque Removal

Dentifrices

Disclosing Agents

Other Adjuncts for Plaque Control

Techniques

Visual-Motor Skill Mastery

Time Considerations

### Chemotherapeutic Plaque Control

Antiseptic Agents

#### Age-Specific Home Oral Hygiene Instructions

Prenatal Counseling

Infants (Birth to 1 Year Old)

Toddlers (1 to 3 Years Old)

Preschoolers (3 to 6 Years Old)

School-Aged Children (6 to 12 Years Old)

Adolescents (12 to 19 Years Old)

In-Office Oral Hygiene Programs

## ► For additional resources, please visit the website.

As the technological level of health care increases, it is important not to lose sight of the basics of patient care. In dentistry, this means establishing and maintaining effective preventive habits in our patients. No matter how sophisticated our dental techniques and procedures have become, preventive dentistry is the foundation on which all oral health care must be built. In 1960, McDonald<sup>1</sup> discussed how pediatric medicine had changed in the previous 30 years (since 1930) from 90% treatment and 10% prevention to just the reverse. He stated that preventive measures for dentistry were available and remained to be applied, as they had been in pediatrics. With this preventive philosophy, dentistry, particularly dentistry for children, has come a long way toward reaching this ratio of 90% prevention to 10% treatment.

At the core of this preventive foundation are home oral hygiene and plaque control. The area of oral hygiene has undergone recent developments that have turned a mundane subject into a field of surprising growth and research. Modern biology has paved new inroads into the area of plaque control and will continue to exert a strong influence on how we look at oral hygiene and plaque in the future. Recently, this has led to a greater understanding of dental plaque as a biofilm and dental diseases as biofilm-mediated diseases.<sup>2</sup> The traditional focus of oral hygiene has been and will continue to be the control of the two most prevalent oral diseases: caries and periodontal disease. Although plaque control is essential to oral hygiene, unlike periodontal disease, no clear relationship exists between

plaque control and the prevention of caries. As discussed in [Chapter 10](#), the complex etiology of decay centers on the following factors: tooth susceptibility, bacterial plaque, refined carbohydrates, host genetic susceptibility, and time. Many other variables, such as oral sugar clearance, salivary flow, and pH and immune factors, add to the complexity of this process. This may help explain the difficulty in demonstrating a direct relationship between oral hygiene practices and caries prevention.

Despite this ambiguity, plaque control remains an essential element in oral health. Although Marsh<sup>2</sup> has shown that the natural oral microflora confers several benefits on the host, in the absence of oral hygiene, dental plaque accumulates, leading to shifts in bacterial populations away from those associated with health.<sup>3</sup> Treatment should, therefore, be designed to control rather than to eliminate dental plaque.

Not only have there been advances in biology, but the public's consciousness regarding home oral hygiene also has been raised to new levels by the advertising of home health care products. The global oral care market size is anticipated to reach USD 40.9 billion by 2025.<sup>4</sup> Health and cosmetic awareness by patients is possibly at an all-time high; the patients are willing to pay for the best in health products.

This chapter addresses the broad area of home oral hygiene for the child and adolescent from the biology of plaque development to plaque removal techniques and patient motivation. Dental health care professionals need to make home oral hygiene the core of their preventive foundation.

## Microbial Aspects of Oral Hygiene and Plaque Formation

Although Miller<sup>5</sup> proposed, in the late 19th century that microorganisms play a role in dental disease, definitive evidence of the microbial etiology of dental caries and periodontal diseases did not appear until three-fourths of a century later, with the work of Keyes<sup>6</sup> and Loe et al.<sup>7</sup> Since these seminal studies, a major focus of dental research has been to define the specific microorganisms in dental plaque that mediate these diseases. In the last decade, the heterogeneity of the microbiota associated with dental caries has been recognized and the infectious and transmissible nature of caries called into question.<sup>8</sup> Regardless of the specific microorganisms associated with dental caries, our primary tools for preventing dental diseases remain mechanical removal of plaque and promotion of the remineralization of the tooth surface. Therefore, the following brief review of the timing, mechanisms, and biology of plaque formation provides a scientific rationale for any clinical program of oral hygiene and prevention.

The development of anaerobic culturing techniques and, more recently, genetic techniques that allow for the detection of uncultivable species has identified more than 700 bacterial species and numerous distinct bacterial habitats in the mouth. Interestingly, only a limited number of species are found in high numbers in dental plaque.<sup>9–11</sup> These species are uniquely suited to this habitat. The formation of plaque on the tooth surface is characterized by progression from a limited number of pioneer species (mainly streptococci and other Gram-positive organisms) to the complex flora of mature dental plaque. This maturation involves initial adherence of bacteria to the salivary pellicle and subsequent formation of a complex multispecies biofilm. Most oral bacteria have evolved specific adherence mechanisms that enable them to colonize the tooth surface. In addition, bacteria undergo numerous phenotypic changes as they initiate the formation of a biofilm. The molecular mechanisms that underlie these processes have been intensively studied.<sup>9–11</sup> Although these mechanisms offer the possibility of new methods of plaque control, mechanical plaque removal with supplementation by chemotherapeutic agents currently offers the most practical method of controlling plaque.

Not only do microbial changes occur as plaque matures on the tooth surface, but also mature dental plaques associated with oral diseases appear to differ from those associated with oral health. Many studies have demonstrated that the pathogenicity of plaque in dental caries is related to the number of cariogenic species present, often but not always, the mutans streptococci.<sup>12,13</sup> The primacy of the mutans streptococci has recently been called into question.<sup>2</sup> In contrast, the plaques associated with gingival inflammation are characterized by a predominance of Gram-negative bacteria rather than the predominantly Gram-positive flora found in oral health. This transition seems to coincide with inflammatory changes that occur at the gingival margin. Culture-independent studies using genetic techniques have expanded the range of disease-associated bacteria in both dental caries and periodontal diseases.<sup>6</sup> Regardless, plaque control efforts should be

directed toward two goals: (1) limiting the numbers of cariogenic organisms, including the mutans streptococci, in dental plaques for the prevention of caries by mechanical elimination of supragingival plaque and limitation of dietary sucrose; and (2) maintaining the predominantly Gram-positive flora associated with gingival health by mechanical removal of plaque from the subgingival area on a regular basis. The use of chemotherapeutic agents, particularly chlorhexidine, can also play a role in the maintenance of gingival health. The incorporation of these methods into the daily routines of patients and their parents is perhaps the greatest challenge facing the dentist.

## Mechanical Methods of Plaque Control

Mechanical methods of plaque control are the most widely accepted techniques for plaque removal. Toothbrushing and flossing are the essential elements of these mechanical methods; adjuncts include disclosing agents, oral irrigators, and tongue scrapers.

### MANUAL TOOTHBRUSH

Toothbrushing is the most common method for removing plaque from the tooth surface. Several variables enter into the design and fabrication of toothbrushes, including the bristle material; length, diameter, and total number of fibers; length of brush head; trim design of brush head; number and arrangement of bristle tufts; angulation of brush head to handle; and handle design. Many features such as the use of neon colors or familiar cartoon caricatures are also designed to attract the attention of potential purchasers (Fig. 8.1).

Today most commercially available toothbrushes are manufactured with synthetic (nylon) bristles. Park et al.<sup>14</sup> have identified the bristle and head of the toothbrush as the most important part of the toothbrush, noting that the length of most bristles is 11 mm. Toothbrushes are classified as soft, medium, or hard based on the diameter of these bristles. Diameter ranges for these classifications are 0.16–0.22 mm for soft, 0.23–0.29 mm for medium, and  $\geq 0.30$  mm for hard. In addition to the bristle diameter, the bristle end has been studied to determine the most beneficial type for plaque control. Of the three types of bristle ends (Figs. 8.2A–C), coarse-cut, enlarged bulbous, and round, the round end is the bristle type of choice because it is associated with a



Fig. 8.1 Features such as neon colors or cartoon characters on toothbrushes are designed to attract the attention of purchasers.

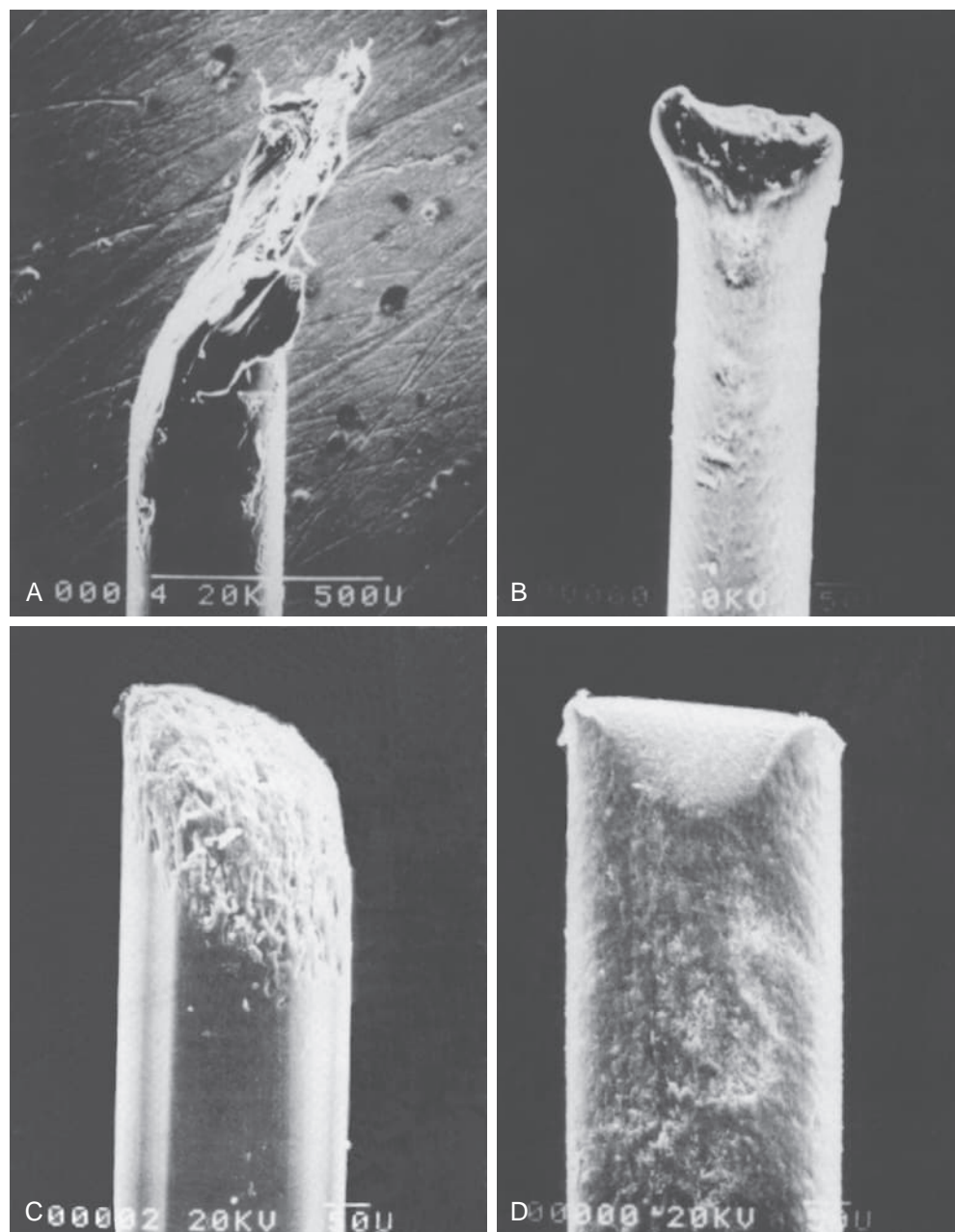


lower incidence of gingival tissue irritation. However, even the coarse-cut bristles round off eventually with normal use (see Fig. 8.2D).

The soft brush is preferable for most uses in pediatric dentistry because of the decreased likelihood of gingival tissue trauma and increased interproximal cleaning ability. In evaluating the best toothbrush head and handle for children, Updyke<sup>15</sup> recommended a toothbrush with a smaller head and a thicker handle than an adult-size toothbrush for better access to the oral cavity and to facilitate the child's grip of the handle. However, no single toothbrush design has been scientifically proven to be superior for the removal

of plaque,<sup>16-18</sup> although some evidence exists that an angled bristle tuft configuration is more effective.<sup>19,20</sup> Multiple variables influence a toothbrush's ability to remove plaque; therefore the practitioner should make recommendations only after assessing a patient's individual needs.

Wear rates of toothbrush bristles and their subsequent ability to remove plaque raise another concern. Numerous studies suggest that toothbrushes remain effective even after wear is noticeable to the patient.<sup>21</sup> Over time, of course, there is an inevitable decline in efficiency. Studies suggest that this occurs by the fourth month of continued use, especially at approximal sites.<sup>21</sup> The cleansing effectiveness of



**Fig. 8.2** Scanning electron micrographs of toothbrush bristles manufactured by different processes. (A) Coarse-cut bristle end, probably the result of an incomplete single-blade cut. (B) Slightly enlarged, bulbous nylon bristle end, resulting from a double-blade or scissors cut. (C) Tapered or round-end nylon toothbrush bristle produced by heat or a mechanical polishing process. (D) Scrubbing, mechanical action of a toothbrush wear machine has rounded off this bristle removed from a brush that was originally coarse-cut. (From Park KK, Matis BA, Christen AG: Choosing an effective toothbrush, *Clin Prev Dent* 7:5-10, 1985.)

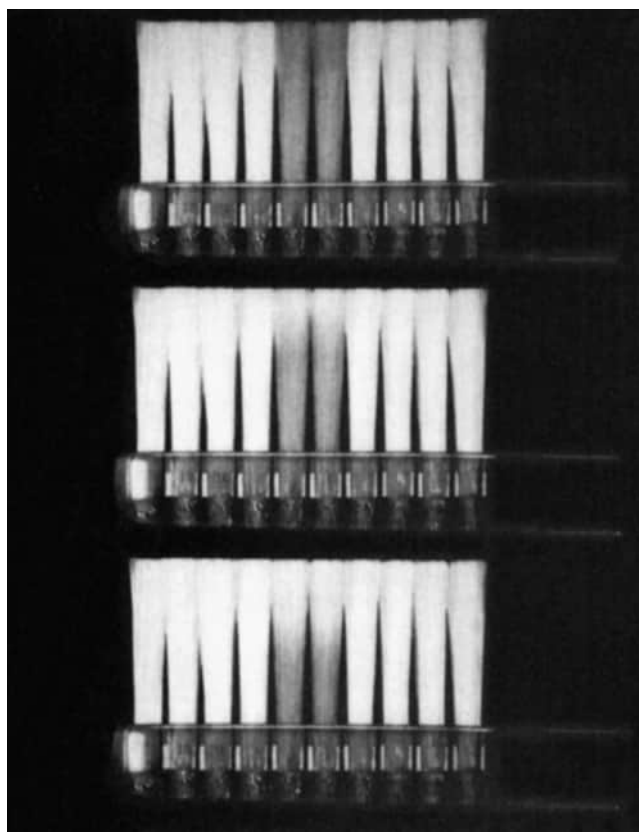
toothbrushes is maintained until pronounced toothbrush wear has occurred. This implies that patients are much more likely to dispose of a brush well before its clinical usefulness actually ends than to continue to use a toothbrush that no longer cleans effectively. In this regard, one manufacturer claims that its commercial toothbrush (Oral-B Indicator; Oral-B Laboratories, Inc., Belmont, California, United States) indicates when the brush should be replaced by means of centrally located tufts of bristles dyed with food colorant. When the blue band fades to halfway down the bristle, it is time to replace the brush (Fig. 8.3). The company states that this occurs, on average, after 3 months, but the time varies depending on the individual's brushing habits.

Parents frequently ask how often they should change a child's toothbrush. It is best to replace the toothbrush when it appears well worn. This can present some problems for parents because some children, especially toddlers, chew their brushes when brushing, which rapidly gives the bristles a well-worn appearance.

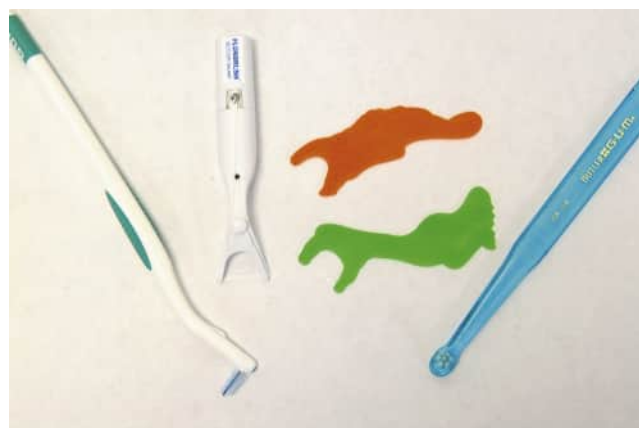## FLOSS

Although toothbrushing is the most widely used method of mechanical plaque control, toothbrushing alone cannot adequately remove plaque from all tooth surfaces. In particular, it is not efficient in removing interproximal plaque, which means that interproximal cleaning beyond brushing is necessary. Many studies have compared the short-term benefits of toothbrushing plus flossing with those of toothbrushing alone. Surprisingly, these studies show minimal or modest differences between the two groups in levels of gingival inflammation and new dental caries.<sup>22,23</sup> The short-term nature of most studies limits their ability to detect differences. However, Corby et al.<sup>24</sup> did find differences in the microbial composition of dental plaques following flossing. After a 2-week study period of 12- to 21-year-old well-matched twins, they found that tooth and tongue brushing plus flossing significantly decreased the abundance of microbial species associated with periodontal disease and dental caries.<sup>24</sup> Many devices have been suggested for the interproximal removal of plaque, such as interdental brushes, floss holders and floss, and end-tuft brushes (Fig. 8.4). A recent systematic review by Richards<sup>25</sup> suggests little difference in effectiveness between these devices. Other devices are more often recommended in certain unique circumstances; for example, the interdental brush may be recommended for orthodontic patients. Unfortunately, regular flossing does not occur daily in most households. Chen and Rubinson<sup>26</sup> demonstrated that daily flossing was practiced by only 20% of mothers, 12% of fathers, and 6% of children within families. In addition, 28% of mothers, 45% of fathers, and 48% of children never floss their teeth. Technical difficulties with flossing in children may account for low compliance.<sup>27</sup>

Several different types of floss are available: flavored and unflavored; waxed and unwaxed; and thin, tape, and mesh-work (Super Floss; Oral-B Laboratories, Inc., Belmont, California, United States) (Fig. 8.5). Almost all commercially available floss is made of nylon, although floss made of Teflon material (polytetrafluoroethylene) (Glide; W.L. Gore and Associates, Inc., Flagstaff, Arizona, United States) is



**Fig. 8.3** Blue dye in the center bristle tufts of this toothbrush fades down from the end with use. When the dye reaches the halfway point (bottom), the manufacturer suggests replacing the toothbrush.



**Fig. 8.4** Several different methods for interproximal cleaning. Left to right, interdental brush, Y-shaped floss holder, disposable floss holders, and end-tuft brush.

also available. The manufacturer claims that, because Teflon material has a lower coefficient of friction than nylon, this floss does not shred, slides easily between tight contacts, and minimizes snapping of the floss. Unwaxed nylon-filament floss has generally been considered the floss of choice because of the ease of passing the floss between tight contacts, the lack of a wax residue, the squeaking sound produced by moving the floss over a clean tooth, and the fiber spread, which results in increased surface contact and greater plaque removal.




Fig. 8.5 Dental floss. Thin (top), tape (middle), and meshwork (bottom).

However, more recent work clearly indicates that individual patient needs and preferences should be taken into account before floss selection recommendations are made. Clinical studies have shown little difference in cleaning efficacy, comfort of use, or ease of use among the available floss types.<sup>28,29</sup>

With these results in mind, it may help when making floss recommendations to parents for their children to consider both the parents' and the child's preferences and individual needs. From the perspective of patient acceptance, flavored waxed floss may be most effective. Furthermore, many parents complain that their fingers are too large for their child's mouth. Floss-holding devices (see Fig. 8.4) are an excellent alternative for parents when this complaint is voiced or when the dexterity of the parent or child prevents handholding of floss. For orthodontic patients, the use of Super Floss or a floss threader (Fig. 8.6) helps in negotiating the floss under the archwires to allow for interproximal cleaning. For orthodontic patients, flossing is a tedious process but is nonetheless essential to the maintenance of oral health.

### POWERED MECHANICAL PLAQUE REMOVAL

The use of powered or electric toothbrushes has received considerable attention since the 1960s. The rationale for using powered brushes is that many patients remove plaque poorly because they lack adequate manual dexterity to manipulate the brush. The powered brushes should decrease the need for dexterity by automatically including some movement of the toothbrush head. Numerous studies examining the plaque removal effectiveness of powered toothbrushes have failed to demonstrate greater efficacy for powered than for manual toothbrushes. Although improvement was seen initially, over time the level of cleaning achieved with powered toothbrushes declined to the same level as that obtained with manual toothbrushes.<sup>30</sup> Kerlinger<sup>31</sup> refers to this as the *Hawthorne effect*: almost any change or experimental manipulation will induce an improvement in behavior, apparently because of a novelty effect. It seems the introduction of powered toothbrushes causes an initial increase in use,




Fig. 8.6 Floss-threading device with segment of thin floss attached.

and therefore better plaque control. Over time, however, the results are comparable with those achieved with manual toothbrushes.

Use of the latest powered toothbrushes, such as the Sonicare (Philips Oral Healthcare, Inc., Snoqualmie, Washington, United States) or the Braun Oral-B Kids' Power Toothbrush (D10) (Oral-B Laboratories, Inc., Belmont, California, United States), however, may prove to be more beneficial than other toothbrushes.

The Sonicare brush uses sonic technology in the form of acoustic energy to improve the plaque removal ability of traditional toothbrush bristles. The brush has an electromagnetic device that drives the bristles' motions at 261 Hz, or 31,320 brush strokes per minute. Ho and Niederman<sup>32</sup> found that the Sonicare toothbrush was significantly more effective than the manual toothbrush in reducing the plaque index, gingival index, percentage of sites that bled when probed, pocket depth, and total Gram-negative bacteria in a subgingival plaque sample. Nowak et al.<sup>33</sup> demonstrated a 40% improvement in the debris index component of the Simplified Oral Hygiene Index in children aged 4–9 years who were using the Braun Oral-B Kids' Power Toothbrush. Studies by Grossman and Proskin<sup>34</sup> and by Jongenelis and Wiedemann<sup>35</sup> also compared the effectiveness of powered toothbrushes with that of manual toothbrushes when the toothbrushes were specifically designed for children. Both studies concluded that the powered toothbrushes removed significantly more plaque than the manual toothbrushes for children. Finally, Heanue et al.<sup>36</sup> performed a meta-analysis showing that powered toothbrushes with a rotation-oscillation action design removed more plaque and reduced gingivitis more effectively than manual brushes in both the short and the long term. No other powered toothbrush designs were consistently superior to manual toothbrushes. Subsequent meta-analyses have continued to demonstrate a modest superiority of the rotation-oscillation action design; however, its clinical significance is unclear.<sup>37–39</sup>

The Toothbrush Acceptance Program Guidelines of the American Dental Association (ADA) Council on Scientific Affairs list several requirements for both manual and powered toothbrushes.<sup>40</sup> Perhaps the main difference in requirements for the two is that powered toothbrushes must have been subjected to an examination by and met the requirements of an appropriate technical safety laboratory such as Underwriters Laboratories, Inc., because of their electrical power supply.



## DENTRIFICES

Dentifrices serve multiple functions in oral hygiene through the inclusion of a variety of agents. They act as plaque- and stain-removing agents through the use of abrasives and surfactants. Pleasant flavors and colors encourage their use. They have tartar control properties because of the addition of pyrophosphates. Finally, dentifrices have anticaries and desensitization properties through the action of fluoride and other agents. Recently, numerous toothpastes have been marketed that contain additional remineralizing agents such as casein phosphopeptide–amorphous calcium phosphate. A growing body of evidence supports their use, especially in high-risk patients.<sup>41,42</sup> A child's dentifrice should contain fluoride, rank low in abrasiveness, and carry the ADA seal of acceptance. In 2020, 49 different dentifrices containing fluoride were listed as accepted dental therapeutic products by the ADA Council on Scientific Affairs. Many of the 49 dentifrices are specifically designed and flavored to appeal to children.

These formulations are useful because a child is more likely to practice oral hygiene procedures if the tools to be used are pleasing. Although the caries-preventive efficacy of fluoride toothpastes in children has been well documented, the impact of dentifrices on children's total fluoride intake must be considered. Adair et al.<sup>43</sup> confirmed that children tend to use larger amounts of dentifrice, brush for a longer period, and rinse and expectorate less when using a children's dentifrice than when using an adult dentifrice. Levy and Zarei-M<sup>44</sup> studied toothbrushing habits and quantities of toothpaste used on toothbrushes in children from birth through 6 years of age (Fig. 8.7). This study did not quantify the amount of toothpaste, and therefore of fluoride, ingested from the use of a certain amount of toothpaste on the brush. However, the investigators suggest that ingestion was likely a substantial source of systemic fluoride for these children during the years when a risk of dental fluorosis is present. It is interesting to note that many toothpaste advertisements show children with large amounts of toothpaste on their brushes. Clearly, this is not the perception dentists want the public to have regarding the use of fluoridated toothpastes in young children.

In a study involving 12- to 24-month-old children, Simard et al.<sup>45</sup> concluded that 20% of the children ingested more than 0.25 mg of fluoride per day by toothbrushing alone. To reduce the chance of dental fluorosis in children secondary to toothpaste ingestion, they suggested that manufacturers market a low-fluoride dentifrice for infants or reduce the diameter of the tube orifice. More recently, the American Academy of Pediatric Dentistry (AAPD) recommendations have been modified to encourage fluoride toothpaste use in all children.<sup>46</sup> For children under the age of 2, parents should be instructed to apply a smear of toothpaste before brushing. A pea-sized portion of toothpaste can be used for children aged 2–4 years. These recommendations help limit the potential for fluoride ingestion but still provide the benefits of fluoride in these children. Pediatricians should take into consideration all sources of fluoride before prescribing supplements. However, recent reviews conclude that the relationship between the risk of fluorosis and toothpaste ingestion has been overestimated.<sup>47</sup> Given the benefits of fluoride, the judicious use of fluoridated toothpaste, even in young children, should be encouraged.<sup>47–49</sup>

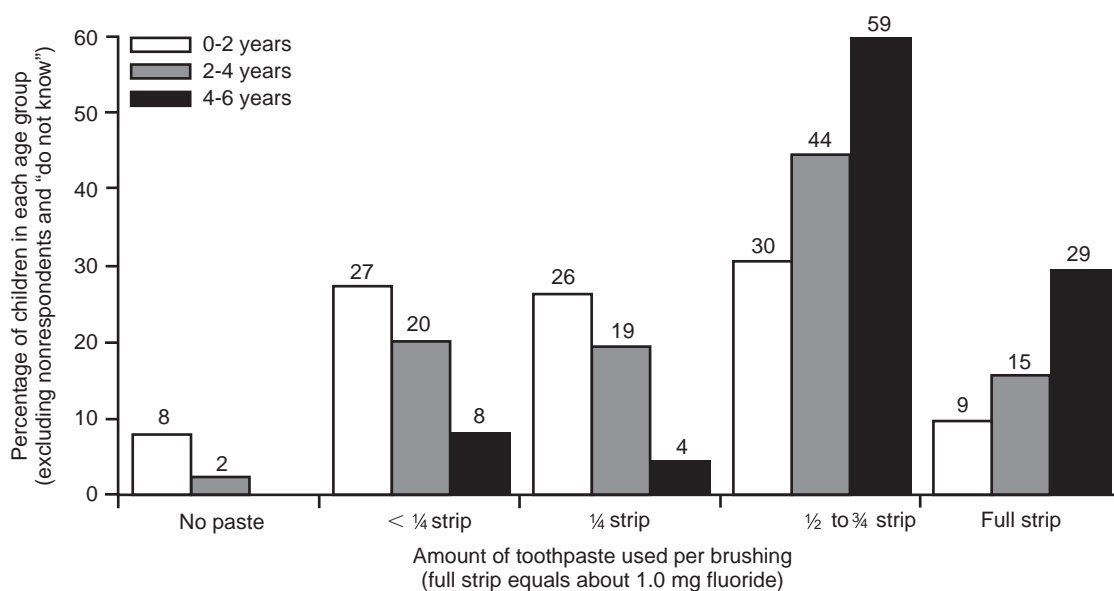
## DISCLOSING AGENTS

To increase the patient's ability to remove plaque, several agents have been developed to allow for patient visualization of plaque. These include iodine, gentian violet, erythrosin, basic fuchsin, fast green, food dyes, fluorescein, and a two-tone disclosing agent. Use of these agents is particularly helpful in teaching school-aged children toothbrushing techniques and educating them on the rationale for oral hygiene. FD&C Red No. 28 is a plaque disclosing agent commonly used either as a liquid to be dabbed onto the teeth with a cotton swab or in the form of a chewable tablet (Fig. 8.8). Unfortunately, this dye stains the oral soft tissues and dental pellicle, as well as the plaque, leaving an objectionable pink discoloration that lasts up to several hours after use. Most of the younger children do not appear to be bothered by the discoloration, but as children approach adolescence, it can become a problem. Fluorescein disclosing agents were developed to address this problem because fluorescein is not visible under normal light. However, their use requires special equipment.

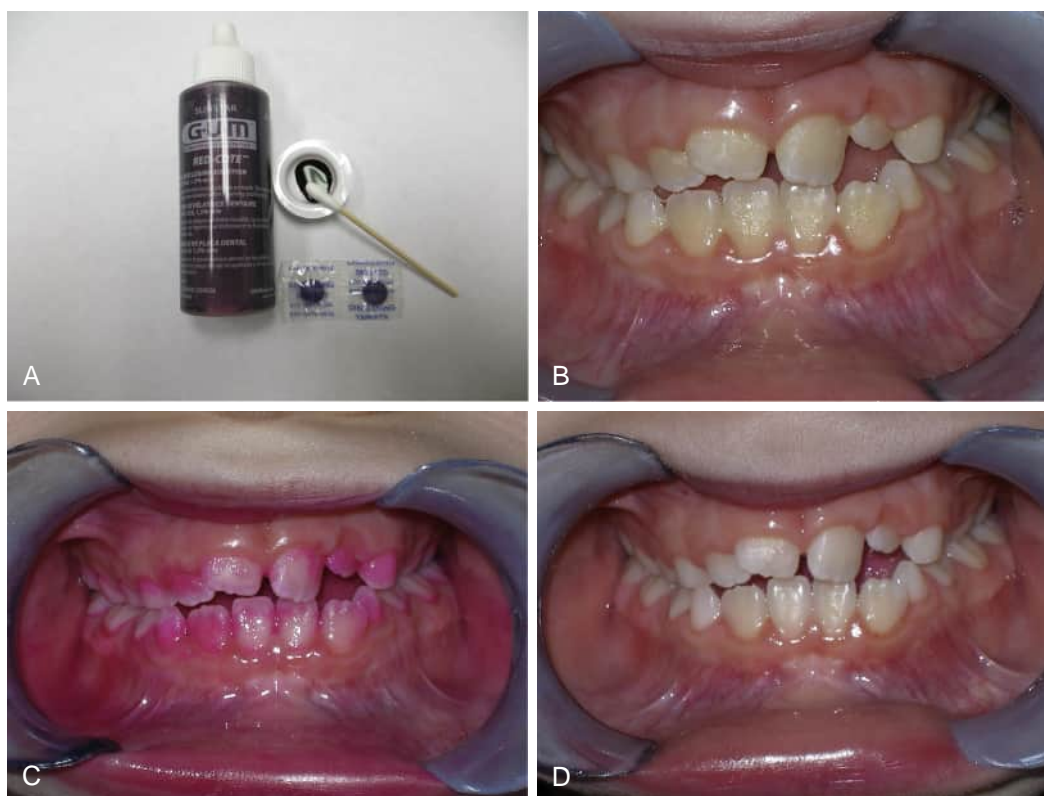In a study by Lim et al.,<sup>50</sup> four different techniques were compared for clinically detecting plaque in patients using different dietary regimens. Individuals in the study population, ranging in age from 18 to 27 years, had their plaque levels assessed using a caries probe, a plaque detection probe, erythrosin, and a two-tone disclosing agent at 3, 6, and 18 hours after their teeth had been thoroughly cleaned. Next, 38 patients were assigned to a sucrose-restricted (SR) diet in the first part of the study and 32 patients to a sucrose-supplemented (SS) diet in the second part of the study. At 3 hours, plaque was detectable on more than 12% of sites in those consuming the SR diet and up to 23% of sites in those consuming the SS diet. After 18 hours, the proportion of plaque-covered surfaces had increased to 52% (SR diet) and 73% (SS diet). For minimal amounts of plaque, the disclosing solutions were found to be the most sensitive assessment techniques. For moderate and abundant plaque deposits, however, the probe techniques were more sensitive. The clinical significance of these data is that, in measuring a patient's oral hygiene abilities, one must assess plaque deposits immediately after the patient has cleaned his or her teeth. Otherwise, allowances must be made for factors such as the time elapsed since the teeth were cleaned and the patient's diet. If a patient is seen several hours after the teeth have been cleaned, the quality of plaque control may be deemed unsatisfactory regardless of the quality of the patient's performance. Disclosing agents can be valuable adjuncts for both clinical and at-home use.

## OTHER ADJUNCTS FOR PLAQUE CONTROL

Several other devices, such as oral irrigators and tongue scrapers, have been suggested for routine oral hygiene. Oral irrigators use pulsed water or chemotherapeutic agents to dislodge plaque from the dentition. Tongue scrapers, which are flat, flexible plastic sticks, are used to remove bacterial and food deposits that accumulate within the rough dorsal surface of the tongue. In addition, gauze or special dental washcloths are useful in infants to massage the gums and to remove plaque on newly erupted teeth. Although these adjuncts add to our basic hygiene tools, toothbrushes and



**Fig. 8.7** Quantity of toothpaste used by children from birth to 6 years of age. (From Levy SM, Zarei-M Z: Evaluation of fluoride exposures in children, *J Dent Child* 58:467-473, 1991.)



**Fig. 8.8** Plaque disclosing procedure. (A) Two common forms of FD&C Red No. 28 disclosing agent: a liquid that is dabbed on with a cotton swab and a chewable tablet. (B) Mixed dentition in a patient before oral hygiene and use of a disclosing agent. (C) Patient before oral hygiene but after use of a disclosing agent. (D) Patient after oral hygiene and use of a disclosing agent.

floss remain the most effective means of mechanical plaque removal. Professional recommendation of these adjuncts should be to suggest them as supplements to and not substitutes for the basic tools and should take into consideration the patient's and caregiver's individual needs, abilities, and preferences.<sup>51</sup>

## TECHNIQUES

As with toothbrush design, several different types of toothbrushing techniques for children have been advocated over the years. The most well-known techniques are the roll method, the Charters method, the horizontal scrubbing method, and the modified Stillman method.<sup>46</sup> In a study

regarding the effectiveness of these four techniques in children of 11 to 14 years of age, Anaise<sup>52</sup> describes them as follows.

### Roll Method

The brush is placed in the vestibule, the bristle ends directed apically, with the sides of the bristles touching the gingival tissue. The patient exerts lateral pressure on the sides of the bristles, and the brush is moved occlusally. The brush is placed again high in the vestibule, and the rolling motion is repeated. The lingual surfaces are brushed in the same manner, with two teeth brushed simultaneously.

### Charters Method

The ends of the bristles are placed in contact with the enamel of the teeth and the gingiva, with the bristles pointed at about a 45-degree angle toward the plane of occlusion. A lateral and downward pressure is then placed on the brush, and the brush is vibrated gently back and forth (approximately 1mm).

### Horizontal Scrubbing Method

The brush is placed horizontally on buccal and lingual surfaces and moved back and forth with a scrubbing motion.

### Modified Stillman Method

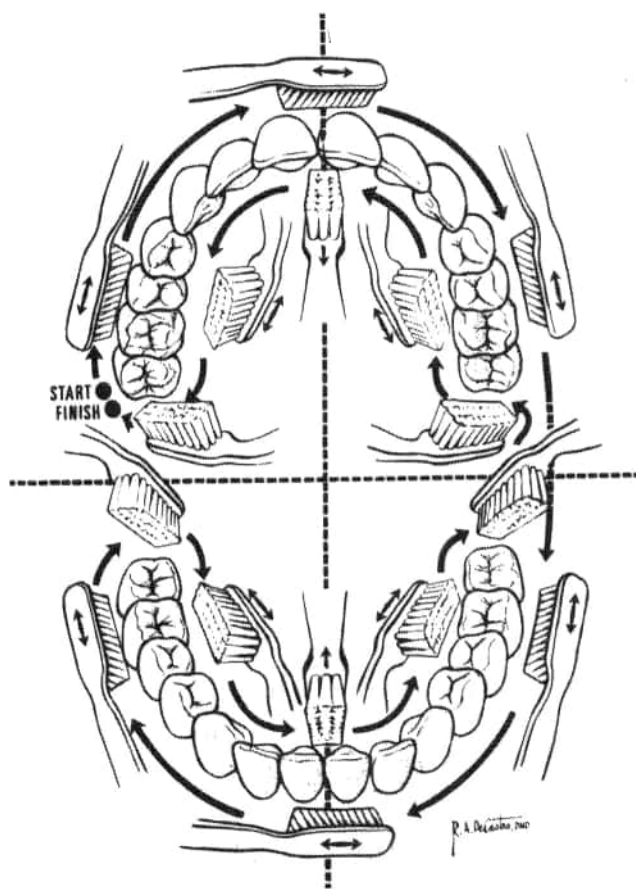
The modified Stillman method combines a vibratory action of the bristles with a stroke movement of the brush in the long axis of the teeth. The brush is placed at the mucogingival line, with the bristles pointed away from the crown, and moved with a stroking motion along the gingiva and the tooth surface. The handle is rotated toward the crown and vibrated as the brush is moved.

Anaise<sup>52</sup> concluded that the horizontal scrubbing method exhibited a more significant plaque-removing effect than the roll, Charters, and modified Stillman methods. This finding supports the work done by McClure<sup>53</sup> and by Sangnes et al.<sup>54</sup>

The horizontal scrub technique removes as much or more plaque than the other techniques, regardless of the child's age and whether the brushing is performed by the parent or the child. In addition, it is the technique most naturally adopted by children.<sup>55</sup> By following a systematic approach, as shown in Fig. 8.9, the child or parent can help ensure that all areas of the mouth are cleaned. Also, notice on this figure the positioning of the brush head on the lingual surfaces of the anterior teeth and on the distal aspect of the most posterior tooth in each quadrant.

For flossing, the following technique is recommended (Fig. 8.10):

1. A 46- to 61-cm (18- to 24-inch) length of floss is obtained, and the ends are wrapped around the patient's or parent's middle fingers. Floss should be long enough to allow the thumbs to touch each other when the hands are laid flat.
2. The thumbs and index fingers are used to guide the floss as it is gently "sawed" between the two teeth to be cleaned. Care must be taken not to snap the floss down through the interproximal contacts, to avoid gingival trauma.



**Fig. 8.9** Systematic approach to brushing the teeth begins with the buccal aspects of the teeth in the maxillary right quadrant and follows the arrows. Bristles are held at a 45-degree angle to the long axis of the teeth and are directed to the gum line. Short back-and-forth strokes are used, allowing bristles to remain in the same place. The handle of the brush is placed parallel to the biting surfaces except when one is brushing the lingual aspects of the anterior teeth and the posterior aspects of the last tooth in each quadrant, when a heel-toe direction of brushing is used. (Courtesy of Dr. Paul Starkey.)

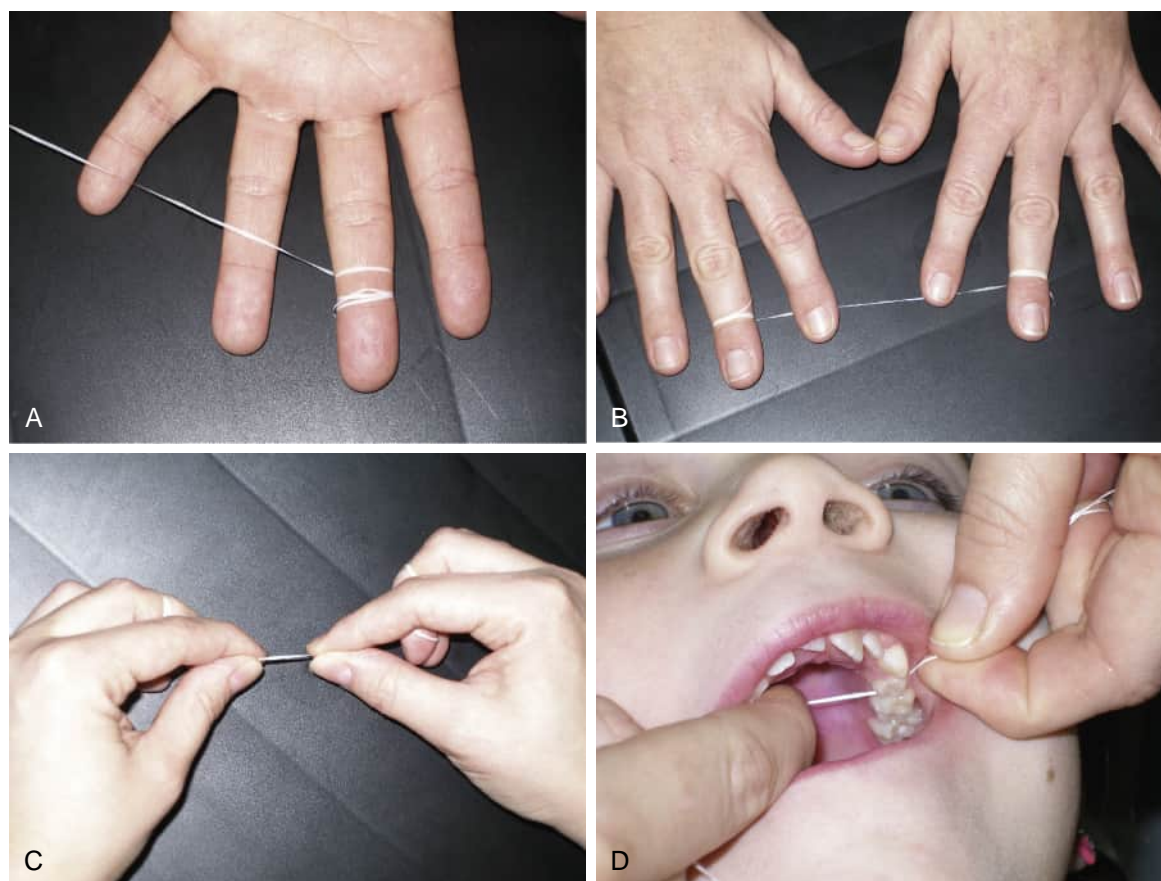
3. The floss is then manipulated into a C shape around each tooth and moved in a cervical-occlusal reciprocating motion until the plaque is removed. In between the cleaning of each pair of teeth, the floss is repositioned on the fingers so that fresh, unsoiled floss is used at each new location.

Learning a flossing technique is difficult and takes some practice. Some children and their parents prefer to make a loop of floss. Tying the two ends of the floss together, instead of wrapping it around their fingers, assists them in holding and controlling the floss. However, Rodrigues et al.<sup>56</sup> demonstrated that even when the looped floss technique is used, a training program is required for children from 6½ to 7½ years of age if a significant reduction is to be achieved in proximal surface dental plaque indices.

### VISUAL-MOTOR SKILL MASTERY

Several attempts have been made to develop specific recommendations for when children can begin performing oral hygiene procedures themselves with adequate effectiveness.





**Fig. 8.10** Flossing technique. (A) The length of floss is wrapped around the middle fingers of each hand. (B) Enough floss should be left between the middle fingers to allow the thumbs to touch when the hands are laid flat. (C) The index fingers and thumbs are used to manipulate the floss. (D) The floss is carefully placed in a C shape between the interproximal contacts and gently “sawed” up and down until each tooth surface is clean.

Terhune<sup>57</sup> stated that the variables of age, gender, and eye-hand coordination could not precisely predict when particular children were ready to learn an effective dental flossing technique. However, all 8- to 11-year-old children in his study learned how to use dental floss effectively within 10 days. Mescher et al.<sup>58</sup> found that hand function was an age-related factor in children’s ability to perform sulcular toothbrushing, but that hand function test scores were not accurate predictors of an individual’s toothbrushing ability.

Preisch,<sup>59</sup> however, using a visual-motor integration developmental test, did find a significant relationship between developmental age and oral hygiene scores. Significant correlations were shown between the children’s ability to copy geometric forms and their academic achievement and motor skill level. Higher levels of thinking and behavior require integration among sensory inputs and motor action. A child can have well-developed visual and motor skills but may be unable to coordinate the two. Although both chronologic and developmental ages were found to be predictors of plaque removal ability, only developmental age demonstrated statistically significant predictive power. Because of the complexity of this test, however, we are left without a practical method for making recommendations to parents as to when their child can begin brushing unsupervised. As Preisch<sup>59</sup> laments, many dentists use anecdotal accounts and tell parents to supervise their children’s brushing until the children can color within

the lines, tie their own shoelaces, or cut through a tough piece of meat. However, these may still be our best practical recommendations.

### TIME CONSIDERATIONS

Perhaps more important in determining the effectiveness of oral hygiene procedures than technique is the daily frequency and length of time spent brushing. How often and for how long should patients brush and floss their teeth? In discussing frequency of oral hygiene procedures, Løe<sup>60</sup> suggests that oral cleanliness should be regarded as a defined state in which all surfaces of all teeth are plaque-free. He states that it may not be surprising to find that complete removal of plaque once daily or every second day, or possibly even once every third day, is more valuable in preventing dental disease than performing two or three inadequate brushings per day. Indeed, Lang et al.<sup>61</sup> observed that completion of effective oral hygiene procedures at intervals of up to 48 hours is compatible with gingival health. Studies addressing the relation between the frequency of hygiene procedures and caries experience in children have yielded inconclusive results.<sup>62</sup>

In addition to optimal brushing frequency, the most efficacious length of brushing time has been investigated. In a study by Hodges et al.,<sup>63</sup> 84 children of age range 5 to 15 years brushed their teeth with a fluoridated dentifrice

for 30, 60, 120, or 180 seconds. The results of the study suggested that, statistically, a 1-minute brushing period provides the greatest plaque removal benefit of all time periods tested. Indeed, Honkala et al.<sup>64</sup> concluded that time spent brushing was more important than the frequency of brushing.

The following recommendations are made based on the preceding information. In children, thorough oral hygiene procedures should be performed at least once daily, preferably twice, with parental supervision. Teeth should be brushed for at least 1 minute with a fluoridated dentifrice; flossing and other plaque removal activities are added to this time. If oral hygiene is accomplished only once per day, it should be the last thing the child does before bedtime at night. Because the flow of saliva and its buffering capacity are reduced during sleep, it is advantageous to remove plaque before bedtime. To optimize the benefits of fluoride, rinsing at bedtime brushing should be discouraged. In addition, the development in children of a learned behavior performed at a specific time of day, each and every day, will be helpful throughout childhood and into adulthood.

## Chemotherapeutic Plaque Control

Although the use of mechanical therapy for plaque control can provide excellent results, many patients are unable, unwilling, or untrained to practice routine effective mechanotherapy. Furthermore, certain patients with dental diseases (e.g., periodontitis) or medical diseases (e.g., immunocompromised conditions) require additional assistance beyond mechanotherapy to maintain a normal state of oral health. Therefore, chemotherapeutic agents have been developed as adjuncts in plaque control.

Van der Ouderaa<sup>65</sup> has stated that the ideal chemotherapeutic plaque control agent should have the following characteristics:

- Specificity only for the pathogenic bacteria
- Substantivity—the ability to attach to and be retained by oral surfaces and then be released over time without loss of potency
- Chemical stability during storage
- Absence of adverse reactions, such as staining or mucosal interactions
- Toxicologic safety
- Ecologic safety so as not to alter the microbiotic flora adversely
- Ease of use

No agent has yet been developed that has all these characteristics.

There are several main routes of administration of antiplaque agents designed for home use, including mouthwashes, dentifrices, gels, irrigators, floss, chewing gum, and lozenges. All of these are designed for local supragingival administration, except the irrigator delivery method. The irrigators can provide both supragingival and subgingival delivery.

Van der Ouderaa,<sup>65</sup> Mandel,<sup>66</sup> and Gunsolley<sup>67</sup> provided excellent reviews of the various chemotherapeutic agents and their uses. **Box 8.1** is adapted from those reviews. Space

### Box 8.1 Chemotherapeutic plaque control agents

#### Antiseptic Agents

**Positively Charged Organic Molecules:** Quaternary ammonium compounds—cetylpyridinium chloride  
Pyrimidines—hexedine

Bis-biguanides—chlorhexidine, alexidine

**Noncharged Phenolic Agents:** Listerine (thymol, eucalyptol, menthol, and methylsalicylate), triclosan, phenol, and thymol

**Oxygenating Agents:** Peroxides and perborate

**Bis-Pyridines:** Octenidine

**Halogens:** Iodine, iodophors, and fluorides

**Heavy Metal Salts:** Silver, mercury, zinc, copper, and tin

#### Antibiotics

Niddamycin, kanamycin sulfate, tetracycline hydrochloride, and vancomycin hydrochloride

#### Enzymes

Mucinases, pancreatin, fungal enzymes, and protease

#### Plaque-Modifying Agents

Urea peroxide

#### Sugar Substitutes

Xylitol, mannitol

#### Plaque Attachment Interference Agents

Sodium polyvinylphosphonic acid, perfluoroalkyl

does not allow for a complete discussion of the agents listed in this box; however, a few pertinent subjects are addressed. Recent systematic reviews provide additional insight into the effectiveness of chemotherapeutic agents, their mechanisms of action, and their suitability for clinical practice.<sup>68,69</sup>

## ANTISEPTIC AGENTS

The antiseptic agents used in chemotherapeutic plaque control have been shown to exhibit little or no oral or systemic toxicity in the concentrations used. Virtually no drug resistance is induced, and in most instances these agents have a broad antimicrobial spectrum. Chlorhexidine, a positively charged organic antiseptic agent, has received considerable attention and study because of its ability to reduce plaque and gingivitis scores. It has strong substantivity, binding well to many sites in the oral cavity and maintaining an ongoing antibacterial presence. Chlorhexidine binds with anionic glycoproteins and phosphoproteins on the buccal, palatal, and labial mucosa, and the tooth-borne pellicle. Its antibacterial effects include binding well to bacterial cell membranes, thereby increasing their permeability, initiating leakage, and precipitating intracellular components.

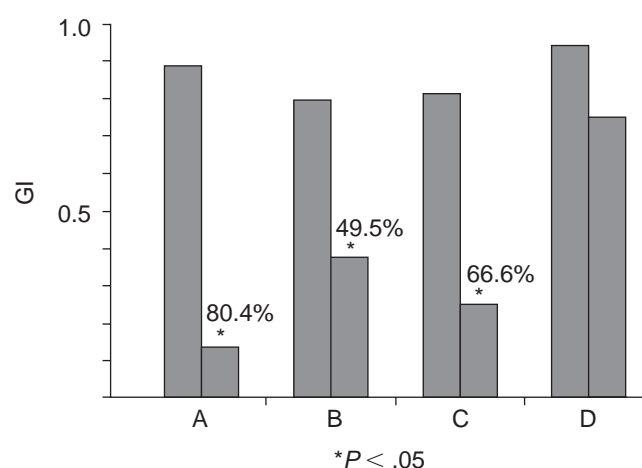
An abundance of clinical trials supports its efficacy in reducing plaque and gingivitis scores in conjunction with routine oral hygiene. Van Strydonck et al.<sup>70</sup> reviewed 30 clinical trials comparing the use of chlorhexidine mouthrinse with that of placebo/control mouthrinse or oral hygiene for longer than 4 weeks. Meta-analysis of studies with a low risk of author-estimated bias showed a 33% reduction in plaque with chlorhexidine and a 26%

reduction in gingivitis relative to control. Chlorhexidine rinsing groups did show higher levels of staining.<sup>70</sup> Clinical trials specifically targeting children have also shown significant reductions in plaque and gingivitis scores.<sup>71,72</sup> The benefits of chlorhexidine mouthrinses and varnishes with respect to caries prevention are inconclusive, especially in children with regular fluoride exposure.<sup>73,74</sup> Recent systematic reviews have failed to support any benefit for chlorhexidine mouthrinses in the prevention of dental caries in children,<sup>75,76</sup> although children with low exposure of fluoride may benefit from chlorhexidine varnish application (Fig. 8.11).<sup>71</sup>

Chlorhexidine spray has stimulated interest regarding its use in populations with disabilities because of its effectiveness and ease of administration. Burtner et al.<sup>77</sup> demonstrated a 35% reduction in plaque levels with the spray use compared with placebo use in a study of 16 institutionalized adult males with severe and profound cognitive/intellectual disabilities. Chikte et al.<sup>78</sup> conducted a 9-week, double-blind, randomized, crossover clinical trial involving 52 institutionalized individuals aged 10 to 26 years with mental disabilities. By the end of the trial, plaque and gingival indices were reduced by 48% and 52%, respectively, in the group treated with a stannous fluoride spray. In the group treated with chlorhexidine spray, reductions in plaque and gingival indices were 75% and 78%, respectively.<sup>78</sup>

In addition to its use in institutionalized patients with intellectual/cognitive disabilities, chlorhexidine has been studied for its use in immunocompromised patients. Clinical trials of its efficacy in preventing or ameliorating oral mucositis have produced conflicting results.<sup>79,80</sup> Recent evidence-based analyses suggest that the evidence for its use in immunocompromised children for the prevention of mucositis is equivocal, and therefore its use could not be recommended.<sup>81,82</sup> The use of positively charged antiplaque agents has been hampered by adverse reactions such as staining of teeth, impaired taste sensation, and increased supragingival calculus formation. Different attempts have been made to decrease these side effects, such as alteration of dietary habits, increase in mechanical plaque removal efforts, and use of hydrogen peroxide solutions in conjunction with the antiseptic agent. Continued research is needed to identify methods to limit these adverse reactions.

The most widely known noncharged phenolic antiseptic agent is Listerine (Pfizer Warner Lambert Division, Morris Plains, New Jersey, United States). It has demonstrated a long history of efficacy and was among the original antiseptic agents studied by W.D. Miller in 1890.<sup>5</sup> Moreover, it was the first over-the-counter mouthrinse to be accepted by the ADA Council on Dental Therapeutics for its use in controlling plaque and gingivitis.<sup>36</sup> Despite its long history of use, many studies have shown chlorhexidine to be significantly more effective than Listerine in reducing plaque and gingivitis indices.<sup>67-69</sup> Listerine tends to give patients a burning sensation, and it has a bitter taste. Lang and Brex<sup>83</sup> have summarized the changes in plaque index, gingival index, and discoloration index scores resulting from the use of four well-known chemotherapeutic plaque control agents (Fig. 8.12). The effects of two 10-mL rinses daily with 0.12% chlorhexidine digluconate, the quaternary ammonium compound cetylpyridinium chloride,

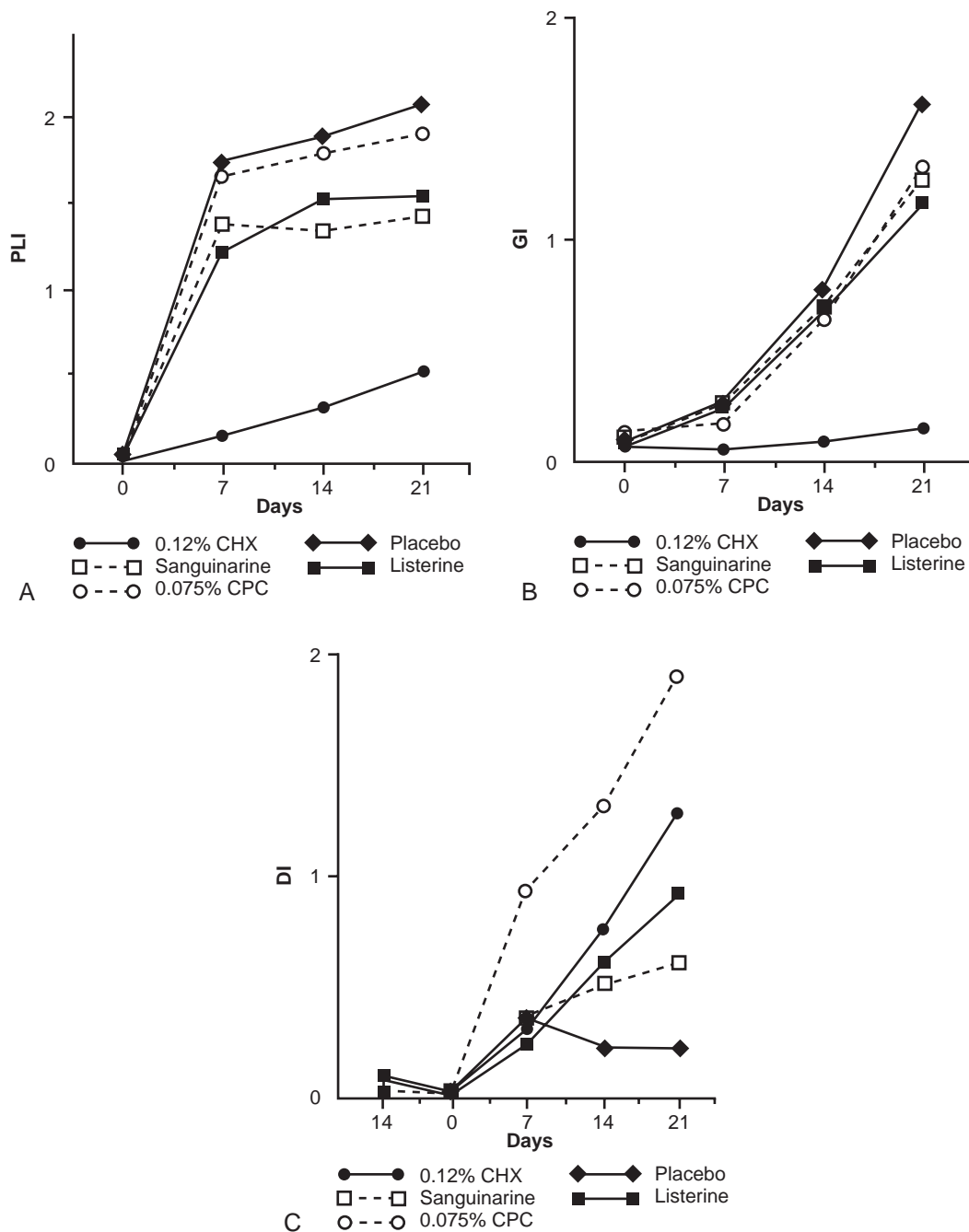


**Fig. 8.11** Mean gingival index (GI) in four groups of schoolchildren rinsing with chlorhexidine digluconate (CHX) or placebo solution for 6 months under supervision. Clear bars, before treatment; screened bars, after treatment; group A, 0.2% CHX six times weekly; group B, 0.2% CHX two times weekly; group C, 0.1% CHX six times weekly; group D, placebo six times weekly. (From Lang NP et al: Effects of supervised chlorhexidine mouthrinses in children, *J Periodontol Res* 17:101-111, 1982.)

the phenolic compound Listerine, or the plant alkaloid sanguinarine were compared with those of rinses with a placebo. All rinses were supervised by registered dental hygienists during these 21-day studies. The participants were divided into five groups of eight individuals each and were instructed to refrain from oral hygiene during the 21 days. Although the sanguinarine, Listerine, and cetylpyridinium chloride inhibited plaque formation to some extent, they did not prevent gingivitis significantly more than the placebo. The chlorhexidine, however, maintained the pre-experimental gingival index scores throughout the 21 days. Unfortunately, all the antiseptics demonstrated higher discoloration index scores than the placebo. As shown in Fig. 8.12C, chlorhexidine had the second highest discoloration score among the four agents. Not surprisingly, studies have shown improvement in plaque and gingivitis when antiseptic rinses are used in conjunction with dentifrices compared with dentifrice use alone.<sup>84-87</sup>

Listerine has one of the highest alcohol contents (approximately 25%) of any mouthwash. The alcohol content of some mouthwashes has been the cause for some concern. Although the development of oral and pharyngeal cancer with long-term mouthwash use has been investigated, alcohol intoxication is more relevant to pediatric dentistry. Alcohol intoxication of children and adolescents from mouthwashes is a concern because of the products' availability. Most parents do not recognize the potential harm from these rinses. Selbst et al.<sup>88</sup> reported the case of a 4-year-old boy who died after consuming approximately 12 ounces of a mouthwash containing 10% alcohol. They advocated for stronger legislation that would restrict the level of alcohol in substances that might be available to children and for continued education of practitioners and parents regarding the potential lethality of most mouthwashes so that accidental ingestions are prevented. One consumer advocacy group states that it is inconsistent for cough and cold products with 12% alcohol to have child-resistant caps when some mouthwashes with even higher alcohol content





**Fig. 8.12** Mean indices in five groups of eight individuals refraining from oral hygiene for 21 days and rinsing with 0.12% chlorhexidine digluconate (CHX), 0.075% cetylpyridinium chloride (CPC), Listerine, sanguinarine, or placebo. (A) Mean plaque index (PLI). (B) Mean gingival index (GI). (C) Mean discoloration index (DI). (From Lang NP, Brex MC: Chlorhexidine digluconate: an agent for chemical plaque control and prevention of gingival inflammation, *J Periodontol Res* 16 [Suppl 21]:74-89, 1986.)

have “designer” shot-glass tops. The ADA Council on Dental Therapeutics requires any mouthrinses that carry the ADA seal of acceptance and contain more than 5% ethyl alcohol to be packaged in bottles with child-resistant caps. Since 1995, such products in the United States have been legally required to have child-resistant packaging, with a documented reduction in these events.<sup>89</sup>

A few comments regarding the use of fluoride as a halogen antiseptic plaque control agent are appropriate here,

although its use in dentistry is discussed in other portions of the text. The fluoride ion inhibits the carbohydrate use of oral organisms by blocking enzymes involved in the glycolytic pathway; however, at preventive-use levels, it probably does not alter the plaque ecosystem. As mentioned earlier, stannous fluoride can produce reductions in plaque and gingivitis scores approaching those of chlorhexidine, but this effect is caused by the tin content of this salt, not the fluoride content.

## Age-Specific Home Oral Hygiene Instructions

The appropriateness and effectiveness of home oral hygiene procedures change throughout childhood. Specific age-related home oral hygiene recommendations are described in the following sections. It is necessary to involve the parent at some level in the oral hygiene procedure for each of the age categories.

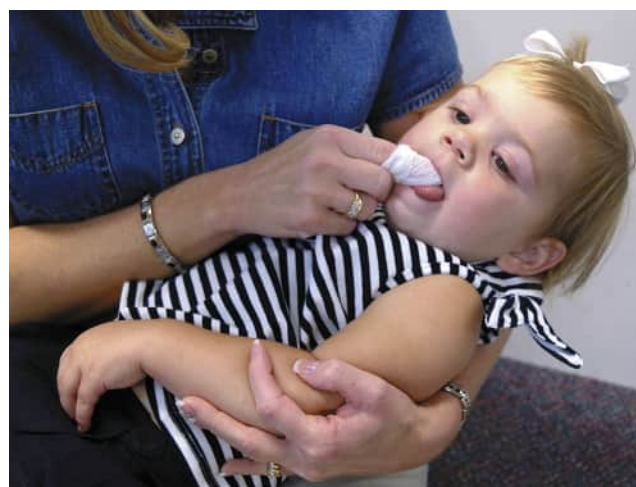
### PRENATAL COUNSELING

The best time to begin counseling parents and establishing a child's dental preventive program is before the birth of the child. This is beneficial for numerous reasons. For an expectant couple, particularly if the child is their first, this is a time in their lives when they are most receptive to preventive health recommendations. These parents-to-be become acutely aware of their child's dependence on them for all nurturing and health care needs. Parents have a strong instinct to provide the best that they can for their child. Counseling them on their own hygiene habits and the effect they can have on their children as role models will aid in improving both the parents' and the child's oral health. Discussing pregnancy gingivitis with the mother-to-be and dispelling some of the myths about childbirth and dental health can be beneficial. Additionally, a review of infant dental care is useful for the expectant parents.

### INFANTS (BIRTH TO 1 YEAR OLD)

It is important that a few basic home oral hygiene procedures begin during the child's first year of life. There is general agreement that plaque removal activities should begin when the first primary teeth erupt. This early cleaning must be done totally by the parent. It can be accomplished by wrapping a moistened gauze square or washcloth around the finger and gently massaging the teeth and gingival tissues. The child can be positioned in numerous ways during this procedure, but cradling the child with one arm while massaging the teeth with the hand of the other may be the simplest and provides the infant with a strong sense of security (Fig. 8.13). This procedure should be performed once daily. Generally, other plaque removal techniques are not necessary. The introduction of a moistened, soft-bristled, child- or infant-sized toothbrush during this age is advisable only if the parent feels comfortable using the brush. The use of a dentifrice is neither necessary nor advised, as the foaming action of the paste tends to be objectionable to the infant. If dentifrice is used, every attempt should be made to minimize fluoride ingestion by the child.

The child's first visit to the dentist should occur during this period. AAPD recommends that parents or caregivers establish a dental home for infants by 12 months of age.<sup>90</sup> When the child has special dental needs, such as medical problems or trauma, this visit can be sooner. Several objectives are accomplished at this visit. Certainly, instruction of the parents in the use of the oral hygiene practices mentioned herein is necessary. In addition, an infant dental examination and fluoride status review should be accomplished, dietary issues related to nursing and caries, as well



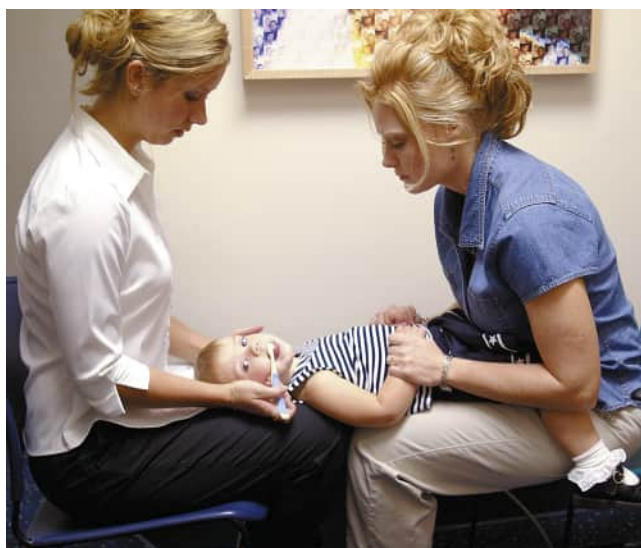**Fig. 8.13** Arm-cradled position of child for effective cleansing of the oral cavity. This figure shows the use of a gauze square for wiping the child's dentition and gingival tissues.

as other health concerns, should be addressed, anticipatory guidance should be provided, and caries risk assessment should be accomplished. These subjects are discussed in more detail in other sections of this text. These first dental visits are also a time for the child to become familiar with the dental environment, the dental staff, and the dentist, which makes any future dental treatment less anxiety provoking.

### TODDLERS (1 TO 3 YEARS OLD)

During "toddlerhood," the toothbrush should be introduced into the plaque removal procedure if this was not accomplished previously. Because of the inability of children in this age group to expectorate and because of the potential for fluoride ingestion, careful and minimal (a "smear" of toothpaste on the brush) introduction of fluoridated dentifrice can be used in 2- and 3-year-olds. Most children enjoy imitating their parents and will readily practice toothbrushing. However, adequate plaque removal is not usually accomplished by the child alone. Although the child should be encouraged to begin rudimentary brushing, the parent remains the primary caregiver in these hygiene procedures. The use of additional instruments for plaque control is generally unnecessary, although flossing may be needed if any interproximal contacts are closed. The use of a flossing aid may also be indicated.

Positioning of the child and parent is again important. Although most children enjoy brushing their own teeth, many are resistant to allowing anyone else to do the brushing. Several positions can be used by the parent, but the lap-to-lap position (shown in Fig. 8.14) allows one adult to control the child's body movements while the other adult brushes the teeth. Notice how the child's arms and legs are controlled with the hands and elbows of the adult responsible for body movements. The parents should be encouraged to make this a special time for the child and to praise the child as much as possible. For single-parent households, a one-adult position often becomes necessary. In this situation, the parent sits on the floor with his or her legs stretched out in front and the child is positioned between the legs. The child's head is placed between the thighs of the



**Fig. 8.14** Lap-to-lap position of child. Two adults sit with knees touching, using their laps as a table on which the child rests. The adult on the right holds the child's legs and arms, while the adult on the left performs the oral hygiene procedures.

parent, with the child's arms and legs carefully controlled by the legs of the parent. This position is a little awkward, but it does allow these procedures to be accomplished in a young child resistant to oral hygiene.

### PRESCHOOLERS (3 TO 6 YEARS OLD)

Although children in the preschool age range begin to demonstrate significant improvements in their ability to manipulate the toothbrush, it is still the responsibility of the parent to be the primary provider of oral hygiene procedures. All too often, parents of these children feel that the child has adequately achieved the skills necessary to clean the teeth. It is important to stress to the parents that they must continue to brush their child's teeth. Although fluoride ingestion remains a concern for this age group, most children develop the skills to expectorate toothpaste adequately during this time. Until this occurs, it is important for parents to use only a pea-sized amount of toothpaste on the child's brush (Fig. 8.15). Furthermore, it is during this age that flossing is most likely to begin. As mentioned previously, if the interproximal contacts are closed, the parent must begin flossing procedures. In the primary dentition, the posterior contacts may be the only areas where flossing is needed. The closure of the spaces between the primary molars tends to occur somewhere near the start of this age range. If any interproximal area has tooth-to-tooth contact, however, daily flossing of that area becomes necessary.

Proper positioning of the child continues to be useful for this age group in performing oral hygiene. One method advocated is that in which the parent stands behind the child and both face the same direction. The child rests his or her head back into the parent's nondominant arm. With the hand of this arm, the parent can retract the child's cheeks and use the other hand to brush. This position is also appropriate for flossing. To brush their child's teeth, many parents use a frontal approach, which is awkward



**Fig. 8.15** Only a smear of fluoride toothpaste (size of a rice grain, left) should be used for children under 3 years of age, and no more than a pea size of fluoride toothpaste should be used for children from 3 to 6 years of age (right).

and provides little head support. This positioning technique should be discouraged.

It is also during this stage that fluoride gels and rinses for home use may be introduced. Because of the risk of ingestion, however, these agents should be used in small quantities, and their use should be limited to those patients demonstrating high risk of caries. The use of other chemotherapeutic plaque control agents is generally not recommended.

### SCHOOL-AGED CHILDREN (6 TO 12 YEARS OLD)

The 6- to 12-year stage is marked by acceptance of increasing responsibilities by the children. The need to assume responsibility for homework and household chores tends to occur during this time. In addition, the child can begin to assume more responsibility for oral hygiene. Parental involvement is still needed. However, instead of performing the oral hygiene, parents can switch to active supervision. By the second half of this stage, most children can provide their basic oral hygiene (brushing and flossing). Parents may find that they need to brush or floss their child's teeth only in certain difficult-to-reach areas of the mouth or if there is a compliance problem. Parents do need to actively inspect their child's teeth for cleanliness on a regular basis. One helpful adjunct is the periodic use of a disclosing agent. After the child has brushed, flossed, and used the disclosing agent on his or her teeth, the parent can easily visualize any remaining plaque and assist the child in removing it.

By this age, ingestion of fluoridated materials, such as dentifrices, gels, or rinses, is not as pronounced a concern because these children are able to expectorate well. Certainly the use of fluoridated dentifrices is essential; however, fluoridated gels and rinses can be reserved for children who are at high risk for caries. Moreover, the use of chlorhexidine or Listerine can be introduced to those at risk for periodontal disease and caries, although some children who might benefit from these chemotherapeutic agents will find their use objectionable.



Because early treatment of malocclusions has increased, this age group is more likely to have orthodontics appliances. Special attention to oral hygiene is necessary for these patients. Increased frequency and adequacy of brushing and flossing become necessary. Although fluoridated dentifrices provide cost-efficient fluoride exposure, the use of fluoridated gels or rinses is strongly encouraged. In addition, as with other patients at risk for caries and periodontal disease, the use of chemotherapeutic agents and adjuncts such as oral irrigators is recommended. Feil et al.<sup>91</sup> published an interesting study on the intentional use of the Hawthorne effect to improve oral hygiene compliance in orthodontic patients. Forty adolescent orthodontic patients with histories of poor oral hygiene were assigned to one of two groups. Those in the experimental group were presented with a situation that stimulated participation in an experiment, whereas the control individuals had no knowledge of study participation. Although there were no statistically significant differences between the control and the experimental groups at baseline, those in the experimental group showed significantly lower plaque scores at 3 months and again at 6 months. The experimental participants had significantly improved oral hygiene, which suggests that the Hawthorne effect (participating in an “experimental study”) caused the adolescent patients to pay more attention to oral hygiene and, therefore, to do a better job.

### ADOLESCENTS (12 TO 19 YEARS OLD)

Although the adolescent patient usually has developed the skills for adequate oral hygiene procedures, compliance is a major problem during this age period. Griffen and Goepferd<sup>92</sup> point out that motivating an adolescent to assume responsibility for personal oral hygiene may be complicated by reactions of rebellion against external authority and some incapacity to appreciate long-term consequences. Macgregor and Balding's<sup>93</sup> survey of 4075 children of 14 years of age suggests a positive relationship between self-esteem and toothbrushing behavior and motivation for mouth care in adolescents. Because self-esteem declines between the ages of 11 and 14 years and then shows a gradual improvement into adulthood, it is not difficult to understand why plaque control in these patients declines. Furthermore, poor dietary habits and pubertal hormonal changes increase adolescents' risk for caries and gingival inflammation.

Therefore, it is important for practitioners and parents to continue to help and guide adolescents as they progress through this difficult stage. Stressing the children's increased responsibility as young adults without appearing authoritarian can aid them in accepting their new role. The parents must be ready to adapt to their child's changing personality and to continue to reinforce the need for oral health care and hygiene. Increasing the adolescents' knowledge regarding plaque control and oral diseases, as well as appealing to their appearance, may also help in motivating these patients.

### IN-OFFICE ORAL HYGIENE PROGRAMS

Preventive dentistry is the foundation on which all oral health care must be built. In establishing this foundation

for their patients, practitioners must first look at themselves and their office environment. *Each practice must establish a preventive philosophy that is evident throughout the patient's encounter with the dental office.* This means that the dentist, the staff, and the practice systems and design must reflect this concept. All staff members must have a personal understanding and appreciation of the importance of this basic concept. This must be evident in their personal hygiene and in their routine interactions with patients.

After this introspective look and adjustment, the practitioner can turn to the patient directly. Ong<sup>94</sup> has discussed several basic concepts for developing a plaque control program in the dental office. Gathering information from the child and parent is necessary for the practitioner to understand their concerns and to let them know that he or she understands these concerns. By discussing the patient's and parents' needs, and listening to and observing their reactions, the practitioner can gauge their readiness to begin the plaque control program. Dental education of the parent and child should be accomplished next, with tailoring to the patient's individual problem. Describing exactly why oral hygiene is important in the patient's particular case can help with motivation. The information should be delivered in simple terms and with enthusiasm and conviction. It also needs to be conveyed to the child in age-appropriate language.

When specific age-appropriate oral hygiene instructions are given, it is important to be positive and reassuring, not critical. Use phrases like, “Let me show you how to improve,” rather than saying, “You're doing it all wrong.” Be gentle but firm, and enlist the parents' and patient's help in the treatment plan and therapy. Setting goals and complimenting achievements will assist in keeping the parents' and patient's attitudes positive. It is very useful to be open to parental and patient feedback regarding their priorities and progress. As with many long-term commitments, cyclic participation can be expected and accepted to a certain extent. However, the parents and patient must know the consequences of neglect. Finally, establishment of a regular maintenance schedule is imperative. Along with prophylaxis, reinstruction and remotivation in the plaque control program are necessary elements for success. Recare intervals should be personalized to the individual patient's needs, with consideration of factors such as: caries and periodontal disease risk; restorative, orthodontic, and prosthetic concerns; and individual patient and parental dental education and skill levels. It is the responsibility of every dental practitioner to make oral hygiene and prevention the core of his or her practice. By listening to, educating, adapting to, and motivating our patients and their parents, we can make our preventive practices successful and enjoyable.

### References

1. McDonald RE: Pediatrics allied with pedodontics, *Pediatr Herald* 1(5):1, 1960.
2. Twetman S: Prevention of dental caries as a non-communicable disease, *Eur J Oral Sci* 126:19–25, 2018.
3. Marsh PD: Contemporary perspective on plaque control, *Br Dent J* 212(12):601–606, 2012.
4. <https://www.grandviewresearch.com/press-release/global-oral-care-market>. From Grand View Research, Inc. (accessed January 14, 2021).
5. Miller WD: *Microorganisms of the human mouth*, Philadelphia, 1890, SS White Dental Manufacturing.

6. Keyes PH: The infectious and transmissible nature of experimental dental caries, *Arch Oral Biol* 1(4):304–320, 1960.
7. Løe H, Theilade E, Jensen SB: Experimental gingivitis in man, *J Periodontol* 36(3):177–187, 1965.
8. Wade WG: The oral microbiome in health and disease, *Pharmacolog Res* 69(1):137–143, 2012.
9. Kuramitsu HK, He X, Lux R, et al.: Interspecies interactions with oral microbial communities, *Microbiol Mol Biol Rev* 71(4):653–670, 2007.
10. Jakubovics NS, Kolenbrander PE: The road to ruin: the formation of disease-associated oral biofilms, *Oral Dis* 16(8):729–739, 2010.
11. Jakubovics NS: Intermicrobial interactions as a driver for community composition and stratification of oral biofilms, *J Mol Biol* 427(23):3662–3675, 2015.
12. Balakrishnan M, Simmonds RS, Tagg JR: Dental caries is a preventable infectious disease, *Aust Dent J* 45(4):235–245, 2000.
13. Bradshaw DJ, Lynch RJ: Diet and the microbial aetiology of dental caries: new paradigms, *Int Dent J* 63(Suppl 2):64–72, 2013.
14. Park KK, Matis BA, Christen AG: Choosing an effective toothbrush, *Clin Prev Dent* 7(4):5–10, 1985.
15. Updyke JR: A new handle for a child's toothbrush, *J Dent Child* 46(2):123–125, 1979.
16. Voelker MA, Bayne SC, Liu Y, et al.: Catalogue of tooth brush head designs, *J Dent Hyg* 87(3):118–133, 2013.
17. Sharma NC, Qaqish JG, Galustians HJ, et al.: Plaque removal efficacy and safety of the next generation of manual toothbrush with angled bristle technology: results from three comparative clinical studies, *Am J Dent* 18(1):3–7, 2005.
18. Kalf-Scholte SM, Van der Weijden GA, Bakker EW, et al.: Plaque removal with triple-headed vs single-headed manual toothbrushes—a systematic review, *Int J Dent Hyg* 16(1):13–23, 2017.
19. Slot DE, Wiggelinkhuizen L, Rosema NA, et al.: The efficacy of manual toothbrushes following a brushing exercise: a systematic review, *Int J Dent Hyg* 10(3):187–197, 2012.
20. Tan E, Daly C: Comparison of new and 3-month-old toothbrushes in plaque removal, *J Clin Periodontol* 29(7):645–650, 2002.
21. Conforti NJ, Cordero RE, Liebman J, et al.: An investigation into the effect of three months' clinical wear on toothbrush efficacy: results from two independent studies, *J Clin Dent* 14(2):29–33, 2003.
22. Drisko CL: Periodontal self-care: evidence-based support, *Periodontol* 62(1):243–255, 2013.
23. Sambunjak D, Nickerson JW, Poklepovic T, et al.: Flossing for the management of periodontal diseases and dental caries in adults, *Cochrane Database Syst Rev* (12):CD008829, 2011.
24. Corby PM, Biesbrock A, Bartizek R, et al.: Treatment outcomes of dental flossing in twins: molecular analysis of the interproximal microflora, *J Periodontol* 79(8):1426–1433, 2008.
25. Richards D: The effectiveness of interproximal oral hygiene aids, *Evid Based Dent* 19(4):187–188, 2018.
26. Chen MS, Rubinson L: Preventive dental behavior in families: a national survey, *J Am Dent Assoc* 105(1):43–46, 1982.
27. Ashkenazi M, Bidoosi M, Levin L: Factors associated with reduced compliance of children to dental preventive measures, *Odontology* 100(2):241–248, 2012.
28. Carr MP, Rice GL, Horton JE: Evaluation of floss types for interproximal plaque removal, *Am J Dent* 13(4):212–214, 2000.
29. Terézhalmy GT, Bartizek RD, Biesbrock AR: Plaque-removal efficacy of four types of dental floss, *J Periodontol* 79(2):245–251, 2008.
30. Goh EX, Lim LP: Fact or fiction? Powered toothbrushing is more effective than manual toothbrushing, *Oral Health Prev Dent* 15(1):52–61, 2017.
31. Kerlinger FN: *Foundations of behavioral research, educational and psychological inquiry*, Holt, Rinehart and Winston: New York.
32. Ho HP, Niederman R: Effectiveness of the Sonicare toothbrush on reduction of plaque, gingivitis, probing pocket depth and subgingival bacteria in adolescent orthodontic patients, *J Clin Dent* 8(1):15–19, 1997.
33. Nowak AJ, Skotowski MC, Cugini M, et al.: A practice-based study of a children's power toothbrush: efficiency and acceptance, *Compendium* 23(Suppl 2):25–32, 2002.
34. Grossman E, Proskin H: A comparison of the efficacy and safety of an electric and a manual children's toothbrush, *J Am Dent Assoc* 128(4):469–474, 1997.
35. Jongenelis AP, Wiedemann W: A comparison of plaque removal effectiveness of an electric versus a manual toothbrush in children, *J Dent Child* 64(3):176–182, 1997.
36. Heanue M, Deacon SA, Deery C, et al.: Manual versus powered toothbrushing for oral health, *Cochrane Database Syst Rev* (1):CD002281, 2003.
37. Robinson P, Deacon SA, Deery C, et al.: Manual versus powered toothbrushing for oral health [review], *Cochrane Database Syst Rev* (2):CD002281, 2005.
38. Deacon SA, Glenny AM, Deery C, et al.: Different powered toothbrushes for plaque control and gingival health [review], *Cochrane Database Syst Rev* (12):CD004971, 2010.
39. Yaacob M, Worthington HV, Deacon SA, et al.: Powered versus manual toothbrushing for oral health, *Cochrane Database Syst Rev* 6:CD002281, 2014.
40. American Dental Association: *Council on scientific affairs: acceptance program guidelines—toothbrushes*, American Dental Association: Chicago.
41. Cochrane NJ, Cai F, Huq NL, et al.: New approaches to enhanced remineralization of tooth enamel, *J Dent Res* 89(11):1187–1197, 2010.
42. Cochrane NJ, Reynolds EC: Calcium phosphopeptides—mechanisms of action and evidence for clinical efficacy, *Adv Dent Res* 24(2):41–47, 2012.
43. Adair SM, Picitelli WP, McKnight-Hanes C: Comparison of the use of a child and an adult dentifrice by a sample of preschool children, *Pediatr Dent* 19:99–103, 1997.
44. Levy SM, Zarei-M Z: Evaluation of fluoride exposures in children, *J Dent Child* 58(6):467–473, 1991.
45. Simard PL, Naccache H, Lachapelle D, et al.: Ingestion of fluoride from dentifrices by children aged 12 to 24 months, *Clin Pediatr* 30(11):614–617, 1991.
46. American Academy of Pediatric Dentistry: *Guidelines on fluoride*, Reference Manual, Chicago, 2019–2020.
47. Cury JA, Tenuta LM: Evidence-based recommendation on toothpaste use, *Braz Oral Res* 28(SPE):1–7, 2014.
48. Wong MC, Clarkson J, Glenny AM, et al. Cochrane Reviews on the benefits/risks of fluoride toothpastes. *J Dent Res*. 2001;90(5):573–579.
49. Wright JT, Hanson N, Ristic H, et al.: Fluoride toothpaste efficacy and safety in children younger than 6 years: a systematic review, *J Am Dent Assoc* 145(2):182–189, 2014.
50. Lim LP, Tay FB, Waite IM, et al.: A comparison of four techniques for clinical detection of early plaque formed during different dietary regimes, *J Clin Periodontol* 13(7):658–665, 1986.
51. Harris NO, Garcia-Godoy F, Nathe CN: *Primary preventive dentistry*, ed 8, Saddle River, NJ: Pearson Education.
52. Anaise JZ: The toothbrush in plaque removal, *J Dent Child* 42(3):186–189, 1975.
53. McClure DB: A comparison of toothbrushing techniques for the preschool child, *J Dent Child* 33:205–210, 1966.
54. Sangnes G, Zachrisson B, Gjerme P: Effectiveness of vertical and horizontal brushing techniques in plaque removal, *J Dent Child* 39(2):94–97, 1972.
55. Starkey P: Instructions to parents for brushing the child's teeth, *J Dent Child* 28:42–47, 1961.
56. Rodrigues CR, Ando T, Singer JD, et al.: The effect of training on the ability of children to use dental floss, *J Dent Child* 63(1):39–41, 1996.
57. Terhune JA: Predicting the readiness of elementary school children to learn an effective dental flossing technique, *J Am Dent Assoc* 86(6):1332–1336, 1973.
58. Mescher KD, Brine P, Biller I: Ability of elementary school children to perform sulcular toothbrushing as related to their hand function ability, *Pediatr Dent* 2(1):31–36, 1980.
59. Preisch JW: *The relationship between visual motor integration and oral hygiene in children [Master's thesis]*, Indiana University: Bloomington, Indiana.
60. Løe H: How frequently must patients carry out effective oral hygiene procedures in order to maintain gingival health? *J Periodontol* 42:312–313, 1971.
61. Lang NP, Cumming BR, Løe H: Toothbrushing frequency as it relates to plaque development and gingival health, *J Periodontol* 44:396–405, 1973.

62. Kumar S, Tadakamadla J, Johnson NW: Effect of toothbrushing frequency on incidence and increment of dental caries: A systematic review and meta-analysis, *J Dent Res* 95(11):1230–1236, 2016.
63. Hodges CA, Bianco JG, Cancro LP: The removal of dental plaque under timed intervals of toothbrushing, *J Dent Res* 60:425, 1981 [abstract 460].
64. Honkala E, Nyyssönen V, Knuutila M, et al.: Effectiveness of children's habitual toothbrushing, *J Clin Periodontol* 13(1):81–85, 1986.
65. Van der Ouderaa FJ: Anti-plaque agents: rationale and prospects for prevention of gingivitis and periodontal disease, *J Clin Periodontol* 18(6):447–454, 1991.
66. Mandel ID: Chemotherapeutic agents for controlling plaque and gingivitis, *J Clin Periodontol* 15(8):488–498, 1988.
67. Gunsolley JC: Clinical efficacy of antimicrobial mouthrinses, *J Dent* 38:S6–S10, 2010.
68. Stoeken JE, Paraskevas S, Van der Weijden GA: The long-term effect of a mouthrinse containing essential oils on dental plaque and gingivitis: a systematic review, *J Periodontol* 78(7):1218–1228, 2007.
69. Gunsolley JC: A meta-analysis of six-month studies of antiplaque and antigingivitis agents, *J Am Dent Assoc* 137(12):1649–1657, 2006.
70. Van Strydonck DA, Slot DE, Van der Velden U, et al.: Effect of a chlorhexidine mouthrinse on plaque, gingival inflammation and staining in gingivitis patients: a systematic review, *J Clin Periodontol* 39(11):1042–1055, 2012.
71. Lang NP, Hotz P, Graf H, et al.: Effects of supervised chlorhexidine mouthrinses in children, *J Periodontol Res* 17(1):101–111, 1982.
72. De la Rosa M, Sturzenberger OP, Moore DJ: The use of chlorhexidine in the management of gingivitis in children, *J Periodontol* 59(6):387–389, 1988.
73. Twetman S: Antimicrobials in future caries control? A review with special reference to chlorhexidine treatment, *Caries Res* 38(3):223–229, 2004.
74. James P, Parnell C, Whelton H: The caries-preventive effect of chlorhexidine varnish in children and adolescents: a systematic review, *Caries Res* 44:333–340, 2010.
75. Walsh T, Oliveira-Neto JM, Moore D: Chlorhexidine treatment for the prevention of dental caries in children and adolescents, *Cochrane Database Syst Rev* 4:CD008457, 2015.
76. Richards D: Caries prevention—little evidence for use of chlorhexidine varnishes and gels, *Evid Based Dent* 16(2):43–44, 2015.
77. Burtner AP, Low DW, McNeal DR, et al.: Effects of chlorhexidine spray on plaque and gingival health in institutionalized persons with mental retardation, *Spec Care Dentist* 11(3):97–100, 1991.
78. Chikte UM, Pochee E, Rudolph MJ, et al.: Evaluation of stannous fluoride and chlorhexidine sprays on plaque and gingivitis in handicapped children, *J Clin Periodontol* 18(5):281–286, 1991.
79. Ferretti GA, Ash RC, Brown AT, et al.: Control of oral mucositis and candidiasis in marrow transplantation: a prospective, double-blind trial of chlorhexidine gluconate oral rinse, *Bone Marrow Transplant* 3(5):483–493, 1988.
80. Raether D, Walker PO, Bostrum B, et al.: Effectiveness of oral chlorhexidine for reducing stomatitis in a pediatric bone marrow transplant population, *Pediatr Dent* 11(1):37–42, 1989.
81. Qutob AF, Gue S, Revesz T, et al.: Prevention of oral mucositis in children receiving cancer therapy: a systematic review and evidence-based analysis, *Oral Oncol* 49(2):102–107, 2013.
82. Cardona A, Balouch A, Abdul MM, et al.: Efficacy of chlorhexidine for the prevention and treatment of oral mucositis in cancer patients: a systematic review with meta-analyses, *J Oral Pathol Med* 46(9):680–688, 2017, <https://doi.org/10.1111/jop.12549>. Epub 2017 Feb 8. Review.
83. Lang NP, Brecx MC: Chlorhexidine digluconate: an agent for chemical plaque control and prevention of gingival inflammation, *J Periodontol Res* 16(Suppl 21):74–89, 1986.
84. Sharma N, Charles CH, Lynch MC, et al.: Adjunctive benefit of an essential oil-containing mouthrinse in reducing plaque and gingivitis in patients who brush and floss regularly: a six-month study, *J Am Dent Assoc* 135(4):496–504, 2004.
85. White DJ, Barker ML, Klukowska M: In vivo antiplaque efficacy of combined antimicrobial dentifrice and rinse hygiene regimens, *Am J Dent* 21(3):189–196, 2008.
86. Gunsolley JC: A meta-analysis of six-month studies of antiplaque and antigingivitis agents, *J Am Dent Assoc* 137(12):1649–1657, 2006.
87. Gunsolley JC: Clinical efficacy of antimicrobial mouthrinses, *J Dent* 38(Suppl 1):S6–10, 2010, [https://doi.org/10.1016/S0300-5712\(10\)70004-X](https://doi.org/10.1016/S0300-5712(10)70004-X).
88. Selbst AM, DeMaio JG, Boenning D: Mouthwash poisoning, *Clin Pediatr* 24(3):162–163, 1985.
89. Mrvos R, Krenzelok EP: Child-resistant closures for mouthwash. Do they make a difference? *Pediatr Emerg Care* 23(10):713–715, 2007.
90. Manual of Pediatric Dentistry: Perinatal and Infant Oral Health. American Academy of Pediatric Dentistry, Chicago, Illinois, 2020–2021, pp. 252–256
91. Feil PH, Grauer JS, Gadbury-Amyot CC, et al.: Intentional use of the Hawthorne effect to improve oral hygiene compliance in orthodontic patients, *J Dent Educ* 66(10):1129–1135, 2002.
92. Griffen AL, Goepferd SJ: Preventive oral health care for the infant, child, and adolescent, *Pediatr Clin North Am* 38(5):1209–1226, 1991.
93. Macgregor ID, Balding JW: Self-esteem as a predictor of toothbrushing behavior in young adolescents, *J Clin Periodontol* 18(5):312–316, 1991.
94. Ong G: Practical strategies for a plaque-control program, *Clin Prev Dent* 13(3):8–11, 1991.



## 9

# Nutritional Considerations for the Pediatric Dental Patient

LAURA M. ROMITO

## CHAPTER OUTLINE

### MyPlate Food Guidance System

#### Dietary Intake Patterns

Eating Out

Portion Sizes

Meal Pattern and Frequency

#### Malnutrition and Food Insecurity

#### Pediatric Undernutrition

Iron

Zinc

Calcium

Vitamin D

Vitamin B<sub>12</sub>

#### Pediatric Overnutrition

Health Impact of High Salt Intake

#### Feeding and Eating Disorders

Anorexia Nervosa

Bulimia

Binge Eating Disorder

#### Gastroesophageal Reflux

#### Q & A Concerning Pediatric Nutrition Issues

This chapter focuses on healthful dietary and nutritional practices for dental patients presented within the framework of a pediatric dentistry textbook. Obviously, eating nutritiously promotes not only healthy teeth and gums but also a healthy body. Contemporary research continues to demonstrate that pursuing nutritious eating behaviors is essential in maximizing health, vitality, and longevity.

Heart disease and cancer top the list of the leading causes of death in the United States, with chronic obstructive pulmonary disease and stroke being the third and fourth leading causes, respectively.<sup>1</sup> However, three major lifestyle choices are the underlying causes of these diseases: using tobacco products, leading a sedentary lifestyle, and making poor dietary choices. Clearly, both what we eat and what we do not eat are major factors affecting the length and quality of our lives. The basis of our dietary choices is established early in life, and these food choices and dietary patterns will affect our health and well-being at every stage of life. There are many ways in which health professionals can promote the health of their patients. One means is to educate them and their caregivers regarding proper eating behaviors.

Research studies show that individuals who live in countries bordering the Mediterranean Sea live longer and are less prone to a variety of diseases than are those residing in other countries. This is often attributed

to the consumption of a diet rich in fruits, vegetables, nuts, whole grains, legumes, and olive oil and low in red meat, sugar, and saturated fat. Eating in this manner provides many health benefits, especially when these dietary patterns are combined with regular physical activity. Although a cause-effect relationship has not been conclusively demonstrated, an association does exist between consumption of the Mediterranean diet and good health outcomes.<sup>2</sup> Eating a Mediterranean diet results in better control of body weight and blood pressure and assists in more effective regulation of blood sugar and cholesterol levels. The Mediterranean dietary pattern also provides protection against cardiovascular diseases, Parkinson's disease, Alzheimer's, type 2 diabetes, and certain types of cancer. It is enlightening to compare life expectancy data between the United States and several countries located in the vicinity of the Mediterranean Sea (Table 9.1).<sup>3</sup>

Although several factors may contribute to these differences in life expectancy, the United States ranks behind four Mediterranean countries in this regard. On average, American men live 3.3 fewer years than do their Italian counterparts, with American women living some 3.6 fewer years than Italian women. Currently, scientific evidence supports the potential value of the Mediterranean style of eating as an important factor in promoting health and longevity.

In the United States, the *Healthy People 2020* document provides evidence-based goals and 10-year benchmarks to guide national health promotion and disease prevention efforts to improve the health of all Americans. Released by the U.S. Department of Health and Human Services,<sup>4</sup> it builds on the accomplishments of three decades of previous *Healthy People* initiatives (In 2020, *Healthy People 2030* was released and is accessible at: <https://health.gov/our-work/healthy-people-2030>).<sup>5</sup> Objectives under the topic of *Nutrition and Weight Status* support consumption of a healthful diet and maintenance of a healthy body weight and recognize that factors critical to the adoption of healthy lifestyles include individual suggestions as well as the policies and environments that support such behaviors. **Table 9.2** summarizes key objectives related to pediatric nutrition.

The Dietary Guidelines for Americans 2015–2020<sup>6</sup> disseminated by the U.S. Department of Agriculture (USDA) support the objectives in the *Healthy People* documents and emphasize the following major goals for Americans:

- **Follow a healthy eating pattern across the lifespan.** This includes consuming appropriate calorie levels of fruits, vegetables, protein, dairy, grains, and oils, and limiting saturated and trans fats, added sugars, and sodium.
- **Focus on variety, nutrient density, and amount.**
- **Limit calories from added sugars and saturated fats and reduce sodium intake.**
- **Shift to healthier food and beverage choices.**
- **Support healthy eating patterns for all.**

**TABLE 9.1** Life Expectancy Comparison

Country	Mean Life Expectancy (in years) at Birth by Gender	
	Men	Women
Italy	79.2	84.5
France	78.2	84.8
Spain	78.2	84.4
Greece	77.4	82.7
United States	75.9	80.9

**TABLE 9.2** *Healthy People 2020*-Selected Nutritional Goals

Objective	Baseline	Target
NWS-1 Increase the number of states with nutrition standards for foods and beverages provided to preschool-aged children in child care	24	34
NWS-2.1 Increase the proportion of schools that do not sell or offer calorically sweetened beverages to students	9.3%	21.3%
NWS-2.2 Increase the proportion of school districts that require schools to make fruits or vegetables available whenever other food is offered or sold	6.6%	18.6%
NWS-3 Increase the number of states that have state-level policies that provide incentives to food retail outlets to provide foods that are encouraged by the Dietary Guidelines for Americans	8	18
NWS-10.4 Reduce the proportion of children and adolescents aged 2–19 years who are considered obese	16.1%	14.5%
NWS-12 Eliminate very low food security among children (% of households)	1.3%	0.2%
NWS-14 Increase the contribution of fruits to the diets of the population aged 2 years and older; *cup equivalent per 1000 calories	0.5*	0.9*
NWS-15.1 Increase the contribution of total vegetables to the diets of the population aged 2 years and older; *cup equivalent per 1000 calories	0.8*	1.1*
NWS-20 Increase consumption of calcium in the population aged 2 years and older	1119 mg	1300 mg

## MyPlate Food Guidance System

The MyPlate Food Guidance System is a pictorial representation of the USDA's daily food recommendations. In MyPlate, the five food groups are visually represented by a place setting in which each of the food groups (fruits, vegetables, proteins, dairy, and grains) is depicted proportionally according to the current recommendations. In addition, the website [ChooseMyPlate.gov](http://ChooseMyPlate.gov) offers numerous educational resources, videos of real-life examples, and practical guidance for consumers, educators, and health professionals in building a healthful diet. For example, one can develop an individualized nutrition plan based on personal factors such as age, gender, and physical activity by utilizing the online tools, such as the MyPlate Plan (<http://choosemyplate.gov>).<sup>7</sup> The site offers several food plans based on age and calorie level. Health and nutrition information for preschoolers, children, and teenagers is also provided on the site and includes interactive games, videos, coloring pages, and nutritional tips, as well as guides for parents and educators concerning children's nutrition and meal planning (**Fig. 9.1**).


## Dietary Intake Patterns

Trends in US dietary intake patterns reflect changes in several factors, including the consumption of low-nutrient, high-calorie foods and beverages (empty calories), as well as changes in the average portion size, snacking habits, and eating away from home.<sup>8</sup> National surveys measuring nutritional status and dietary patterns of children and adolescents revealed that the total caloric intake of US children increased from the 1970s to the 1990s; these results reflect an increased consumption of soft drinks, grain products, fried potatoes, noncitrus juices, cheese, candy, and fruit drinks.<sup>9,10</sup> Conversely, over this time period, decreases were found in intakes of milk in general, whole milk, vegetables and legumes, beef, pork, and eggs. Less than half of children consumed the recommended number of servings of any given food group, and their intakes of discretionary fat and added sugar were much higher than recommended.



United States Department of Agriculture

## 10 tips Nutrition Education Series



# MyPlate MyWins

Based on the  
Dietary  
Guidelines  
for Americans

# Cut back on your kid's sweet treats

Set your kids on a path for lifelong healthy eating by limiting the amount of added sugars they eat. Sweet treats and sugary drinks have lots of calories but few nutrients. Most added sugars come from sodas; sports, energy, and fruit drinks; cakes; cookies; ice cream; candy; and other desserts.

## 1 Serve small portions

Show kids that a small amount of treats can go a long way. Use smaller bowls and plates for these foods and serve them in bite-size portions.

## 2 Sip smarter

Soda and other sugar-sweetened drinks contain a lot of sugar and are high in calories. Offer water when kids are thirsty.



## 3 Use the checkout lane that does not display candy

Most grocery stores will have a candy-free checkout lane to help avoid temptation. Waiting in a regular checkout lane tempts children to ask for candy that is right in front of them.

## 4 Choose not to offer sweets as rewards

By offering food as a reward for good behavior, children learn to think that some foods are better than other foods. Reward your child with kind words and comforting hugs, or give them non-food items, like stickers, to make them feel special.

## 5 Make fruit the first choice

Offer a variety of fruits in different ways. Make fruit kabobs using cantaloupe, bananas, and strawberries or offer whole fruits such as pears, clementines, or apples.



## 6 Make food fun

Sugary foods that are marketed to kids are advertised as “fun foods.” Make nutritious foods fun by preparing them with your child’s help and being creative together. Create a smiley face with sliced bananas and raisins. Cut fruit into fun and easy shapes with cookie cutters.

## 7 Encourage kids to invent new snacks

Make your own snack mixes from dry whole-grain cereal, dried fruit, and unsalted nuts or seeds. Let school-age kids choose the ingredients to create their own snack.



## 8 Play detective in the grocery aisle

Show kids how to find the amount of total sugars on the Nutrition Facts label in various cereals, yogurts, and other products. Challenge them to compare products they like and select the one with the lowest amount of sugar.


## 9 Make treats “treats,” not everyday foods

Treats are okay once in a while. Just don’t make treat foods an everyday thing. Limit sweet treats to special occasions.

## 10 If kids don’t eat their meal, they don’t need sweet “extras”

Keep in mind that candy or cookies should not replace foods that are not eaten at meal time.





**Fig. 9.1** Choose My Plate. (Courtesy of USDA's Center for Nutrition and Policy Promotion.)

Using data from the National Health and Nutrition Examination Survey (NHANES), researchers have continued to monitor dietary trends among American children and adolescents. For example, in evaluating beverage consumption for children from birth to 5 years of age, Fulgoni and Quann<sup>11</sup> found that although milk remains the primary beverage, milk intake has declined. From the 1970s through the 1990s, approximately 85% of preschoolers consumed some form of milk, but by 2000–2006, milk consumption had declined to 77%.<sup>11</sup> Conversely, fruit juice consumption increased dramatically over the same time period. While fruit juice can be an important source of vitamin C, potassium, and magnesium, it may also replace other nutritious foods, including those with calcium. From 1976 to 2006, preschoolers' consumption of fruit drinks, which contain less than 10% fruit juice but generous amounts of added sugars, remained relatively stable at approximately 35%–37% of this population.<sup>11</sup> An NHANES-based analysis of beverage consumption among infants to preschoolers from 2011 to 2014 found that the consumed amounts of sugar-sweetened beverages increased with child age, and by 5 years of age, over half of all children consumed sweetened beverages daily. Non-Hispanic black children were the most likely to consume sugar-sweetened beverages.<sup>14</sup> Han and Powell<sup>13</sup> reported that in the United States, regular soda was the major form of sugar-sweetened beverage consumed by young people, particularly teenagers and those from low socioeconomic backgrounds. However, while consumption of soda has decreased in recent years, the prevalence of sports/energy drink consumption has tripled. This is concerning because, along with the well-known risk for dental caries, there is evidence that high intakes of sweetened beverages are associated with increased caloric intake, weight gain, and obesity.<sup>14,15</sup> Furthermore, an increased intake of sugar-sweetened beverages among children aged 3–11 years has been associated with a decrease in high-density lipoprotein cholesterol levels and increases in waist

circumference and C-reactive protein, a known marker of inflammation and cardiometabolic disease.<sup>16</sup>

From 1989 to 2004, there was an appreciable rise in daily calories consumed among US children and teenagers.<sup>17</sup> One study found that in individuals aged 2–18 years, empty calories accounted for nearly 40% of daily energy intake.<sup>19</sup> The increase in calories during this period was attributed to an increased intake of the following foods: sugar-sweetened beverages, pizza, full-fat milk, grain-based desserts, breads, pasta, and savory snacks. However, from 2003 to 2010, along with an increase in fruit consumption, total caloric intake in American children declined, as did their consumption of many of the aforementioned foods. However, this trend did not occur among preschool-aged children and those of low socioeconomic status; compared with 1989–1991, their total energy intakes remained significantly higher in 2009–2010.<sup>17</sup> Additional dietary surveys on infants, toddlers, and young children through 2016 have indicated that total energy intakes in these groups have been stable.<sup>21</sup> In preschoolers, from 1989 to 2008, there was an increase in foods with high levels of added sugar and fat such as savory snacks, pizza, calzones, Mexican dishes, sweet snacks/candy, and fruit juice.<sup>20</sup>

Although current trends may indicate a shift toward improved dietary intake, consumption of excess calories and foods with added fat and sugar negatively affects the overall quality of children's diets. In the National Growth and Health Study, Moore et al.<sup>21</sup> found that the aforementioned excesses contributed to inadequate intakes of essential vitamins and minerals, as well as to intakes of dairy foods, fruits, and vegetables that fell short of recommended levels in more than 90% of teenage girls. Similarly, from a survey of a nationally representative sample of 6th to 10th graders, Iannotti and Wang<sup>22</sup> determined that only 25% of the children consumed the highest proportions of daily vegetables and fruits and the smallest proportions of energy-dense, low-nutrient foods.

In 2016, nearly 15 million children participated in the School Breakfast Program (SBP)<sup>27</sup> and over 30 million participated in the National School Lunch Program (NSLP).<sup>27</sup> These federally funded programs evolved as efforts to assist children from low-income households. Children from households with incomes at or below the poverty level are eligible for free meals, whereas children from households with higher incomes may be eligible for reduced-price meals.<sup>24</sup> Because school meal programs can have a significant impact on children's health, their ability to meet nutritional quality standards is important. An analysis of a nationally representative sample of children in the NSLP from grades 1 to 12 found that school lunches provided lower-calorie, higher-quality food compared with meals eaten at home. Additionally, NSLP participants obtained fewer calories from sugar-sweetened beverages at school than did nonparticipants, but obtained more calories from low-nutrient, energy-dense solid foods such as fries and higher-fat baked goods in secondary schools. Overall, compared with nonparticipants, NSLP participants' dietary intake at school was lower in calories.<sup>25</sup>

However, Clark and Fox<sup>26</sup> reported that while the majority of US public schoolchildren obtained nutritionally adequate diets from school meals, 80% consumed excess saturated fat and 92% consumed excess sodium. High-sodium intake

may increase the dietary intake of sugary beverages.<sup>27</sup> A survey of school principals from a nationally representative sample of elementary schools found that participation in the federal school nutrition program, Fresh Fruits and Vegetable Program, increased the availability of fresh fruits during school lunch meals.<sup>28</sup> Likewise, a systematic review and meta-analysis by Evans et al.<sup>29</sup> found that from 1989 to 2009, school-based nutrition programs generated a modest improvement on children's fruit consumption but had no impact on vegetable intake. However, more recent studies have shown considerable improvements in the quality of children's dietary intakes by participation in school meals programs.<sup>36,37</sup>

## EATING OUT

Children and teenagers continue to obtain more of their meals outside of the home, often from fast-food establishments. From the late 1970s through the mid-2000s, the percentage of daily calories consumed in fast-food restaurants by children aged 2–18 years grew from 2% to 13%, while full-service restaurants' contribution to their daily caloric intake increased from 1% to 5%.<sup>32,33</sup> From 2000 to 2008, fast-food and full-service restaurant meal consumption by children and teenagers was associated with increased calories, particularly for adolescents and those in low socioeconomic groups, as well as higher intakes of soda and sugar-sweetened drinks. Fast-food intake increased total fat, saturated fat, sugar for both groups, and sodium and protein for teenagers.<sup>34</sup> However, the type of restaurant may be a moderating factor. Larson et al.<sup>35</sup> found that compared with “burger and fries” establishments, those serving primarily sandwiches/subs were associated with fewer markers of poor diet quality and had no relationship with body weight. Likewise, recent systematic reviews examining the association between eating out, dietary intake, and weight concluded that eating away from home is a risk factor for higher fat and calorie intakes and lower consumption of micronutrients<sup>36</sup> but remain less conclusive about weight gain, especially in young populations.<sup>37</sup>

## PORTION SIZES

Along with an increase in eating outside the home, there is a trend toward expanded food-serving sizes. Most marketplace portions of foods exceed standard serving sizes by at least a factor of 2 (e.g., bagels and sodas) and sometimes by a factor of 8 (e.g., cookies).<sup>37</sup> Fast-food chains offer larger sizes of hamburgers, sodas, and fries. The current serving sizes are often two to five times larger than the size originally marketed. These changes in dietary patterns parallel the progressive increase in obesity seen in the United States. Based on this information, eating away from home is associated with a compromised quality of nutritional intake and may increase the risk for chronic diseases. An analysis of the dietary patterns of US children and adolescents from 2003 to 2006 found that, compared with younger children, teenagers were more susceptible to distorted portion sizes and that high-calorie, low-nutrient foods such as sugar-sweetened beverages, fries, and pizza were popular with youth of all age groups and accounted for a significant portion of their diet.<sup>38</sup>

## MEAL PATTERN AND FREQUENCY

Although from 2000 to 2011 US kids and teenagers had increased intakes of high-calorie, low-nutrient snacks, an association between snacking behavior and obesity remains unclear.<sup>40</sup> More recent research has found that compared with snacks consumed by normal-weight teens, snacks consumed by overweight and obese teens had more added sugar, saturated fat, and sodium but had a lower average energy density per snack.<sup>49</sup> Larson and colleagues observed cross-sectional associations suggesting that snack consumption is a risk factor for poor diet, but unless energy-dense foods are consumed, snacking does not consistently contribute to overweight in US adolescents.<sup>50</sup> However, Koletzko and Toschke<sup>43</sup> found that a higher meal frequency among children was associated with a decreased risk of obesity, which led the authors to suggest that children should consume 5 nutritious meals per day.

Eating dinner at home in a dining area and helping to prepare meals were associated with a decreased body mass index (BMI) in children.<sup>44</sup> Furthermore, in teenagers, Berge et al.<sup>45</sup> found that positive interpersonal communications with family members at the dinner table was associated with lower BMI and greater vegetable consumption. However, from 1999 to 2010, a widening gap in family meals based on socioeconomic status was noted by a Minnesota study. Youth in the lowest socioeconomic status showed a decrease from 4 to 3.6 family meals per week, whereas those in upper socioeconomic groups showed an increase in family meals.<sup>46</sup> This trend does not bode well for low-income youth who have greater risk of poor health outcomes.

## Malnutrition and Food Insecurity

Malnutrition includes undernutrition (inadequate intake of nutrients that potentially leads to deficiencies) and overnutrition (excessive dietary intake of energy, fat, or cholesterol that predisposes individuals to chronic diseases). While the latter excessive consumption pattern may be quantitatively more relevant to overall mortality and morbidity rates in contemporary US society than are nutrient deficiencies, malnutrition from dietary insufficiency has not been eradicated.

Chronic malnutrition as measured by low weight for age and low growth rates has decreased; some of this decline has been attributed to better nutrition. Today, the proportion of mothers receiving early prenatal care is at a record high. Data released in 2018 by the U.S. Department of Health and Human Services reported that as of 2017, the overall rate at which infants die before their first birthday was 579.3 deaths per 100,000 live births.<sup>58</sup> However, infant death rates are disproportionately higher in specific racial/ethnic groups, such as African Americans and Native Americans. Furthermore, the US infant mortality rate continues to rank among the highest of the industrialized nations. More than 16 million children in the United States live in poverty, and some estimates indicate that children in approximately 10% of households experience hunger or the risk of hunger.

Knol et al.<sup>48</sup> evaluated the dietary patterns of children of 2–3 years and 4–8 years of age from low-income households

and found that the predominant eating patterns in both groups were not indicative of a balanced diet as described by national recommendations. Rather, the diets mimicked those of adults, with high intakes of added sugars and discretionary fats as a percentage of daily calories. Thus children from households with low socioeconomic status are at risk for the long-term consequences of malnutrition.

According to USDA, food security is generally defined as “access by all people at all times to enough food for an active, healthy life.” Conversely, food insecurity describes a “household-level economic and social condition of limited or uncertain access to adequate food.” Hunger is an individual-level physiological condition that may result from food insecurity, and refers to “a potential consequence of food insecurity that, because of prolonged, involuntary lack of food, results in discomfort, illness, weakness, or pain that goes beyond the usual uneasy sensation.”<sup>49,50</sup> Thus food insecurity is considered a risk factor for malnutrition.

Data regarding the food security of US households are obtained by USDA from federally sponsored national surveys. The food security status of each household is categorized according to the following labels.

- *High food security:* Households had no problems or anxiety about consistently accessing adequate food.
- *Marginal food security:* Households had problems at times or anxiety about accessing adequate food, but the quality, variety, and quantity of their food intake were not substantially reduced.
- *Low food security:* Households reduced the quality, variety, and desirability of their diets, but the quantity of food intake and normal eating patterns were not substantially disrupted.
- *Very low food security:* At times during the year, eating patterns of one or more household members were disrupted and food intake reduced because the household lacked money and other resources for food.

The USDA reported that in 2017, 84.3% of US households with children were food secure; however, 7.7% of all US households (2.9 million households) reported being food insecure, with 4.5% reporting very low food security.<sup>62</sup> Prevalence of food insecurity was greater in all households with children, households with children headed by single women or single men, and those with children under 6 years of age. Other groups with food insecurity higher than the national average included African American and Hispanic households, poor households, and those in metropolitan areas and those located in the South.<sup>67</sup>

Because food-insecure households are eligible to receive assistance from federally funded programs such as the Supplemental Nutrition Assistance Program, research has been ongoing to understand the impact of these programs on food insecurity and nutrition. In addition, studies are seeking to clarify the relationships between food insecurity and nutritional status, health risks, and reduced quality of life, especially in children. Ryu and Bartfield<sup>52</sup> analyzed household food security data from a nationally representative sample of US children followed from kindergarten in 1998 through eighth grade in 2007. More than one-fifth of the children resided in a food-insecure home during the 9-year timeframe, which was a transient situation in many cases.

Nevertheless, results suggested poorer health status for children living with persistent household food insecurity. Food insecurity has also been associated with increased mental and substance abuse disorders in adolescents.<sup>53</sup>

An early literature review found that there is a growing body of evidence supporting the association between food insecurity and obesity in teenagers, but the relationship remains unclear in children.<sup>54</sup> For example, a longitudinal study of the relationship of food insecurity on obesity, conducted with a sample of nearly 30,000 non-white, low-income children participating in the Massachusetts Special Supplemental Nutrition Program for Women, Infants, and Children, found that children experiencing persistent household food insecurity had 22% greater odds of being obese than children in food-secure households.<sup>55</sup> However, this finding was moderated by maternal pre-pregnancy weight status, with obesity being more common among children of underweight and obese women. A 2019 study found that food insecurity in the home, particularly in pre-teens and teens, was linked to some nutrition-related behaviors and higher obesity rates.<sup>67</sup> Additional research has suggested that there is a dose-response relationship between low intake of vegetables, higher dietary added sugars, and food insecurity in young children. However, outcomes suggested that the teen years may be the time in a child's life when food insecurity can be most detrimental to consuming a healthful diet.<sup>68</sup>

## Pediatric Undernutrition

Undernutrition is the insufficient consumption of essential nutrients, resulting in health problems. Failure to thrive is a concern sometimes observed among infants and children. This term refers to individuals whose current body weight or rate of weight gain falls significantly below that of other children of similar age and gender. These children are much smaller and shorter than their counterparts and may lack mental and social skills as well as physical abilities such as rolling over, sitting, standing, and walking. Although there are numerous potential environmental and medical causes of failure to thrive, poor eating habits such as not having formal mealtimes or chronically eating in front of the television may play a role.

Typically, in mild but chronic undernutrition, weight loss with normal height and head circumference is seen. If the situation continues, growth will slow down, and head circumference and height will be below age- and gender-related standards. Severe lack of caloric intake results in a wasting condition known as marasmus. Adequate intake of calories with insufficient protein can produce kwashiorkor, a condition characterized by increased susceptibility to infections and edema. However, these latter two conditions are primarily seen in areas plagued with famine and are rarely seen in the United States.

The Third School Nutrition Dietary Assessment Study<sup>58</sup> assessed the quality and contributions of the NSLP and SBP to children's nutritional health. Both are longstanding government programs designed to bring nutritious food to American children. The results indicate that most US schoolchildren consume nutritionally adequate diets, though many may have deficient fiber intake, with



excessive consumption of saturated fat and sodium. Nevertheless, 15% of children still showed inadequate intakes of vitamin A, vitamin C, vitamin E, phosphorus, and magnesium. These inadequacies were greatest among female adolescents. Elementary schoolchildren showed excessive intakes of calories, but this was not observed among high-school students. Since these three vitamins and two minerals seem to be an issue among some children, a short consideration of each follows.

Vitamin A has two fundamental forms in foods: retinoids found in animal foods and carotenoids present in plant foods. Since both plant and animal food are good sources, true dietary deficiencies are generally not likely to be a problem in Westernized societies. In contrast, vitamin C, which is required for wound healing and healthy blood vessels, is found only in fruits and vegetables, and if these foods are not regularly eaten, suboptimal deficiencies of this vitamin can occur. Vitamin E represents a collection of chemically similar vitamins that provide important resistance to oxidative stress in the body. Richest dietary sources are nuts, seeds, fruits, fish, and plant oils. Supplements of this vitamin are quite popular, but food sources are likely a safer and more effective choice.

Phosphorus is an essential mineral nutrient required for strong bones and teeth. It is found in practically every food item in the human diet. Consequently, a dietary deficiency is extremely unlikely. Magnesium is another mineral with important roles in human metabolism and is widespread in animal and plant foods alike. Richest sources are green leafy vegetables, nuts and seeds, fish, legumes, and whole grains.

Nutrient undernutrition may have several causes, only one of which is an inadequate dietary intake. Some cases may be secondary to poor socioeconomic status, lack of education, perceived allergies/food intolerances, and child neglect or abuse. Historically, iron, calcium, and zinc are three minerals sometimes ingested only at marginal levels by many youth. Vitamins D and B<sub>12</sub> have also been found difficult to ingest at recommended levels among children and adolescents in research studies.<sup>59,60</sup>

## IRON

Iron fulfills its primary role in the body as a component of blood hemoglobin and muscle myoglobin by providing cells with a constant supply of oxygen. It also functions as a cofactor for many enzymatic reactions in the body and is important for proper functioning of the immune system. Although the prevalence of iron deficiency has declined in recent years, it remains an enormous problem globally and an important pediatric public health problem even in the United States. Many of the adverse consequences of iron deficiency are associated with its most severe form, iron-deficiency anemia. However, iron deficiency without anemia is associated with poor cognition and lower scholastic achievement in children and adolescents.<sup>61</sup> Clinical signs of iron-deficiency anemia may include weakness, fatigue, pallor, and numbness and tingling of the extremities. Common oral manifestations are glossitis and fissures at the corners of the mouth (angular cheilitis). The papillae of the tongue may be atrophied, which gives the tongue a smooth, shiny, red appearance. In addition, pallor of the oral mucosa or

lips may be observed. Affected individuals may also be at increased risk for fungal infections, such as candidiasis.

Iron needs are higher during growth stages, and those most vulnerable to iron deficiency include pre-term and low-birthweight infants, older infants and toddlers, teenage girls, and women of child-bearing age. Iron deficiency early in life appears related to behavioral problems in infants who score significantly lower on various tests measuring intellectual and motor functioning. An assessment of iron deficiency prevalence in US children from 1 to 3 years of age during 1976–2002 showed no significant changes during this period, with overall prevalence ranging from 8% to 10%. Iron deficiency prevalence decreased from 22% to 9% in toddlers in low-income households but remained at 7% in toddlers from households above the poverty level. During this 26-year period, iron deficiency prevalence in African American toddlers decreased from 16% to 6% but remained unchanged in both Hispanic and white children at 13% and 6%, respectively. Prolonged bottle feeding for up to 48 months of age was positively correlated with increased prevalence of iron deficiency and may account for the higher prevalence in Hispanic toddlers.

Somewhat surprisingly, overweight toddlers have a significantly higher prevalence of iron deficiency than do comparable normal-weight or underweight peers. This has also been observed in older children and adolescents. Possible explanations for this association include a greater intake of foods high in calories but low in iron, an alteration in iron absorption or metabolism, and a reduced level of physical activity among the overweight children. Additionally, overweight girls may grow faster and mature earlier than normal-weight peers, making it more difficult to meet their iron requirements. To prevent iron deficiency, vulnerable populations should be encouraged to eat iron-rich foods and breastfeed or use iron-fortified formula for infants. Iron is found primarily in meat, poultry, and fish. However, other foods such as beans, lentils, fortified cereal grain products, and certain vegetables can also contribute to dietary intake of iron.

## ZINC

The trace mineral zinc has important roles in growth and development, sexual maturation, immune function, and wound healing; it also has a role in taste and smell acuity. Recently, it has become a popular medicament for treating the common cold (Box 9.1).

Severe zinc deficiency in children is common in developing countries, but far less so in the United States. Chronic low dietary zinc intakes may produce a deficiency, as may low bioavailability, and/or adverse interactions with other nutrients. Iron and zinc share many common food sources, so individuals at risk for iron deficiency may also be at risk for zinc deficiency. Zinc is present in foods that are high in protein, such as beef, eggs, poultry, and legumes, as well as in whole grains, fortified, ready-to-eat cereals, and dark green and yellow vegetables. However, as is the case with iron, zinc from plant food sources is not as well absorbed as that found in animal foods. Briefel et al.<sup>64</sup> assessed zinc intakes from food and supplements in the US population between 1988 and 1994 using NHANES III data. Results indicated that in children younger than 10 years, boys and girls had

**Box 9.1 Zinc study<sup>62,63</sup>**

Two studies conducted with a study population of schoolchildren have suggested that taking zinc-containing lozenges can ease the symptoms of the common cold and shorten its duration. Dosages tested were 10–15 mg zinc sulfate daily.

similar zinc intakes, but in those older than 10 years, boys' zinc intakes exceeded those of girls. Furthermore, 81% of 1- to 3-year-olds and 48% of 4- to 6-year-olds had inadequate zinc intake, defined as less than 77% of the 1989 Recommended Dietary Allowance. In addition, roughly 61% of adolescent girls had inadequate intake compared with 38% of adolescent boys.<sup>64</sup>

One of the first clinical manifestations of severe zinc deficiency in children is stunted growth. Other signs and symptoms include abnormal immune responses, decreased reproductive development and function, and skeletal abnormalities. Oral manifestations include impaired wound healing, alterations of the oral epithelium, xerostomia, reduced or altered sense of taste or smell, and reduced appetite. During tooth formation, children with zinc deficiency may be at increased risk for dental caries. In addition, because of its impact on immune function, zinc deficiency may increase the risk of oral infections such as periodontal disease and candidiasis.

**CALCIUM**

Calcium and vitamin D function together to maximize the mineralization of bones and teeth. Calcium is also needed for proper nerve and muscle activity, blood clotting, and transport of ions across cell membranes. Individuals at risk for inadequate calcium intake include those who dislike milk and other food sources of calcium, as well as those with milk allergies, lactose intolerance, and malabsorptive disorders. Inadequate calcium intake over time can increase the risk of bone demineralization and osteoporosis.

Osteoporosis is a bone disease of older individuals and is most commonly diagnosed in postmenopausal women. It is characterized by a reduction in the quantity of skeletal tissue and thus is often considered to be a geriatric disorder. Education for its prevention, however, is legitimately within the domain of pediatricians and pediatric dentists. Childhood and adolescence are crucial times for development of the skeletal system, and the dietary requirement for calcium peaks during the teenage years. The Food and Nutrition Board of the Institute of Medicine recommends an intake of 1300 mg/day of calcium during adolescence. This equals roughly the amount of calcium present in 4.25 cups of milk, so this is not an easy recommendation to meet.

Achieving a high peak bone mass is the first line of defense against osteoporosis. Low calcium intake, particularly in combination with low levels of physical activity, may compromise the attainment of optimal peak bone mass. This is a particularly important consideration for adolescent girls because almost half of the adult skeletal mass is formed during the second decade of life, and calcium accumulation normally triples during the pubertal

growth spurt. Unfortunately, this is the very age group that is at highest risk for low calcium intakes. Only 30% of adolescent girls reach 75% of the recommended daily allowance for calcium, and its intake appears to be declining among 6- to 11-year-olds. This problem may be alleviated by educating youth to select more calcium-rich foods (e.g., cheese, yogurt, fortified breakfast cereals, fortified orange juice concentrates) or to consider using calcium supplements. Calcium carbonate has a good absorption rate and has been characterized as a relatively inexpensive supplement containing a high percentage level of calcium. The concept that dental alveolar bone height loss is associated with osteoporosis is supported by research; therefore, strategies for reducing osteoporosis risk may also help retard alveolar bone loss. Dental professionals can help improve both the oral and systemic health of their pediatric patients over the long term by guiding them in meeting calcium intake recommendations.<sup>65</sup>

**VITAMIN D**

Vitamin D is a fat-soluble vitamin that promotes the absorption of calcium from foods in the gastrointestinal tract, leading to proper mineralization of bones and teeth. As a result, having adequate stores of this vitamin is crucial for proper skeletal and dental development. Vitamin D also acts in concert with parathyroid hormone to maintain tight control of blood calcium levels. A slight reduction in blood calcium concentration stimulates secretion of parathyroid hormone, which mobilizes calcium and phosphorus from the skeleton to re-establish calcium homeostasis in the blood. Vitamin D seems to play a role in immune function; in addition, lack of this vitamin may contribute to several diseases, including hypertension, multiple sclerosis, and certain cancers. It has recently been suggested to be a factor in serotonin synthesis in the brain and to perhaps play a role in autism.<sup>66</sup>

Vitamin D deficiency is increasingly being recognized as pandemic. The problem is threefold:

1. There is a lack of appreciation that exposure to sunlight is a significant source of the vitamin.
2. Few foods naturally contain vitamin D.
3. Foods that are fortified with vitamin D are often not consumed in sufficient amounts to meet the requirement.

Weng et al.<sup>67</sup> discovered that, in a large sample of 6- to 21-year-olds in the northeastern United States, more than half the individuals were found to have low serum vitamin D concentrations; the prevalence of deficiencies increased with advancing age, and also during the winter months, especially in African American children. In a different study of nearly 400 healthy infants and toddlers, 12% of the children had suboptimal serum levels of vitamin D, and one-third of these children exhibited radiographic evidence of bone demineralization. Predictors of vitamin D deficiency included breastfeeding without supplementation in the infants and low milk intake among the toddlers. Cushman et al.<sup>68</sup> evaluated the effects of subclinical vitamin D deficiency on bone mineral density (BMD) and bone turnover in healthy adolescent boys and girls. Even though no relation between BMD and vitamin D status was observed in boys, the 12- to 15-year-old girls with high vitamin D status had

significantly greater bone density, lower serum parathyroid hormone, and lower bone turnover markers than girls with low vitamin D status.

Exposure to sunlight is the major source of vitamin D for most people. Ultraviolet rays from the sun trigger vitamin D synthesis in the skin from its chemical precursor, 7-dehydrocholesterol. Natural sources of this vitamin are fatty fish such as salmon, mackerel, and herring, as well as fish oil, including cod liver oil. In the United States, although some juices, breads, yogurts, and cheeses are enriched with vitamin D, fortified milk is considered as the primary dietary source of the vitamin.

Because vitamin D is an essential nutrient for proper skeletal development, children who receive too little may develop rickets—a bone disease characterized by bone deformities, poor muscle development, abnormal spinal curvature, and bowed legs. The latter manifestation occurs because the skeleton cannot support the body weight of the child. In addition, enlarged joints and delayed closure of the skull bones may be present. The presence of rickets during tooth development may result in enamel and dentin hypoplasia, incomplete development, or delayed tooth eruption.

During the first half of the 20th century, thousands of cases of nutritional rickets were reported in the United States, particularly in the northern climates during the winter months, when exposure to sunlight was minimal. This disease was virtually eradicated once vitamin D began to be added to milk. In recent years, however, a resurgence of rickets has occurred, particularly in African American breastfed babies. There appear to be two major reasons for this resurgence. First is the increase in breastfeeding. Breastfeeding is the preferred method of infant nutrition, but by itself does not supply adequate amounts of vitamin D. Second, endogenously produced vitamin D via effective sun exposure has decreased; it can vary with time of exposure, amount of skin exposed, degree of air pollution and cloud cover, the time of day, latitude, season, sunscreen use, and skin pigmentation. Time spent indoors watching television or playing electronic games does not provide sun exposure.

Compared with individuals possessing a lighter complexion, those with heavily pigmented skin are less efficient in synthesizing vitamin D from sunlight. In addition, some African Americans are unable to digest the lactose in milk efficiently, which leads to a significant reduction in milk intake and consequently in vitamin D levels. The increase in reported cases of nutritional rickets prompted the American Academy of Pediatrics to issue new guidelines in 2003 recommending supplemental vitamin D for all breastfed infants. However, this recommendation has not been universally adopted by pediatricians, which leaves concerns about the continued risks of vitamin D-dependent rickets in US children.<sup>69</sup>

## VITAMIN B<sub>12</sub>

Vitamin B<sub>12</sub> is one of the B-complex vitamins, and cobalt is present within the molecule, classifying it as the only vitamin containing a mineral element. Vitamin B<sub>12</sub> is essential in producing red blood cells in the bone marrow and for myelin synthesis in the nervous system. B<sub>12</sub> is thought to be present only in animal foods (meat, fish, eggs, and dairy products), and as a result, strict vegetarians are considered to be at risk for a dietary deficiency. Those suffering from

anorexia nervosa and bulimia are also considered to be vulnerable to a deficiency.

Neurologic impairment resulting from a vitamin B<sub>12</sub> deficiency has been reported in two children breastfed by vegetarian mothers. In one of these cases, the diagnosis was made at 15 months, and vitamin B<sub>12</sub> therapy was initiated. At age 28 months, the child's developmental skill levels ranged from 9 months for fine motor skills to 18 months for gross motor skills. Her expressive language was at a 10-month level.<sup>70</sup> Health care providers should be alert to the possibility of B<sub>12</sub> deficiency under these circumstances. Plant foods fortified with this vitamin, such as selected cereals, meat analogues, soy or rice beverages, and nutritional yeast, can be reliable and regular sources.

Chronic vitamin B<sub>12</sub> deficiency can result from a lack of the vitamin in the diet, and it can also be due to an autoimmune reaction in which intrinsic factor, a stomach protein required for the absorption of B<sub>12</sub>, is not produced. The lack of intrinsic factor can result in a vitamin B<sub>12</sub> anemia known as pernicious anemia, which is characterized by large, immature blood cells. Additional signs and symptoms of deficiency of this vitamin include pallor, dizziness, fatigue, weight loss, confusion, hypotension, and peripheral nerve degeneration. Oral manifestations of vitamin B<sub>12</sub> deficiency include soreness of the soft tissues and atrophic glossitis.<sup>71</sup>

## Pediatric Overnutrition

For most children and adolescents in the United States today, negative health outcomes brought on by malnutrition are far more likely to be related to overconsumption of food, sodium, and calories than to deficiencies brought on by underconsumption of food and nutrients. In other words, the risk of a child suffering from type 2 diabetes related to obesity is considerably greater than that of getting scurvy due to insufficient vitamin C intake.

Perhaps the greatest current public health threat for our country is the incrgng prevalence of overweight and obesity, which have ballooned during the last three decades of the 20th century. This issue invariably leads to a lifelong struggle with body weight control issues, and the attendant increased risk for heart disease, cancer, and stroke. Until recently, this epidemic appeared to be continuing unabated.<sup>72</sup>

Simply stated, obesity results from a chronic imbalance between energy intake and energy expenditure, in which the former exceeds the latter. However, its increasing incidence is related to a complex array of genetic, environmental, psychosocial, biological, and economic factors. Obesity is traditionally defined as the excessive accumulation of fat in the body, whereas overweight means weighing more than is considered normal. These terms are often defined based on BMI. BMI is calculated by dividing the individual's weight in kilograms by the square of the height in meters. When BMI is plotted on age- and gender-appropriate growth charts, overweight individuals can be identified as those between the 85th and 95th percentiles for age and gender. It is clear that this mathematical calculation is rather complex and can best be determined online by means of a BMI calculator ([https://www.cdc.gov/healthyweight/assessing/bmi/childrens\\_bmi/about\\_childrens\\_bmi.html#percentile](https://www.cdc.gov/healthyweight/assessing/bmi/childrens_bmi/about_childrens_bmi.html#percentile)).<sup>73</sup> Standards for BMI values in children are shown in Table 9.3.



**TABLE 9.3** Body Mass Index Values and Standards for Children

Value	Standard
<5th percentile	Underweight
5th to <85th percentile	Normal weight
85th to <95th percentile	Overweight
≥95th percentile	Obese

A major focus of the nationwide health promotion and disease prevention agenda in *Healthy People 2020* was to reduce the proportions of children and adolescents who are overweight or obese. Unfortunately, current estimates are that 36% of US adults are obese, whereas the corresponding value for children and adolescents is 17%.<sup>74</sup> This latter figure translates to roughly 12.5 million young individuals. The prevalence of overweight among children aged 6–11 years has more than doubled in the past 20 years; the rate among adolescents has more than tripled.

However, several recent reports, including an article in the *Journal of the American Medical Association*,<sup>75</sup> have reported a significant reduction in obesity among 2- to 5-year-old children over the past decade. In this latter study, obesity was defined in children as a BMI > the 95th percentile of the gender-specific Centers for Disease Control and Prevention (CDC) BMI-for-age growth charts. In adults, obesity was defined as a BMI ≥ 30. A 43% drop in the obesity rate among 2- to 5-year-old children was an unexpected finding.

Several theories have been proposed to help explain this observation:

1. Children are consuming fewer calories provided as sugary beverages than they did 10 years ago.
2. More women are breastfeeding their infants, which is associated with a lower risk of obesity.
3. There has been a slight overall drop in calories ingested per capita in the past decade.
4. Some combination of state, local, and federal programs designed to reduce obesity is beginning to bear fruit.

Regarding the latter idea, former First Lady Michelle Obama led an effort to alter young people's eating and exercise behaviors in a healthier direction. Many childcare centers across the country were engaged, and numerous cities have also been striving to fight obesity by reducing sugary beverage ingestion and the use of trans fats in restaurants. It is encouraging to see progress against obesity being demonstrated in 2- to 5-year-olds because reversing unhealthy eating habits at a later age is difficult. However, a note of caution is necessary. Very young children make up only a small fraction of the American population, and other age groups are not showing corresponding declines in obesity rates. For example, women over 60 years of age have shown an increase in obesity during the past decade. Nevertheless, if this trend continues in young children in America and expands to the adult population, we can be more optimistic about ultimately reversing the obesity epidemic.

There are many consequences of obesity, both short- and long-term consequences. An estimated 61% of overweight youth have at least one additional risk factor for heart disease, such as high cholesterol or high blood pressure. Overweight children are at greater risk for bone and joint problems, as well as obstructive sleep apnea, which has been observed in as many as one in six obese children. The latter condition can lead to daytime somnolence, neurocognitive abnormalities, and impaired learning. Because obese children tend to become obese adults, the potential impact of childhood obesity on the health care system is enormous. It has been suggested that the increased medical care costs associated with obesity may be greater than those associated with smoking and drinking alcohol.<sup>76</sup>

As overweight young people grow older, they are at increased risk for heart disease, type 2 diabetes mellitus, stroke, several types of cancer, and osteoarthritis. The current epidemic of type 2 diabetes escalating in children and adolescents is associated with obesity and a persistently elevated BMI. Roughly one of four obese children (aged 4–10 years) has been reported as glucose intolerant.<sup>77</sup> This condition is a precursor to diabetes and is a generic term referring to metabolic conditions resulting in higher than normal (hyperglycemia) blood glucose levels. A sedentary lifestyle and obesity are associated with glucose intolerance.

Severe obesity has long been thought to reduce life expectancy. A recent report states that 20-year-old white men with a BMI greater than 45 (extreme obesity) are estimated to lose 13 years of life because of their body weight.<sup>78</sup> In spite of several decades of public health efforts to educate the population regarding the dangers of obesity, the trend toward progressively increasing body weight has not abated.

Aside from the obvious health risks associated with obesity in childhood and adolescence, there are also significant psychological and quality-of-life issues to be considered. Ackard et al.<sup>79</sup> reported that objective overeating with loss of control in adolescents was associated with lower scores on measures of body satisfaction and self-esteem and higher scores regarding depressive mood. Overeating was also associated with elevated risk of suicide. Thus, objective overeating among adolescents is linked to several adverse behaviors and negative psychological experiences. It remains to be determined whether objective overeating is an early warning sign of psychological distress or, rather, a potential consequence of compromised psychological health.

Schwimmer et al.<sup>80</sup> compared the health-related quality of life of obese children and adolescents with that of both their healthy (non-obese) counterparts and a cohort of children and adolescents diagnosed with cancer. Quality-of-life ratings of severely obese children and adolescents were lower than those of healthy children and adolescents and similar to those of children and adolescents with cancer. An impaired self-image and perception of low quality of life in this population are not surprising because obesity is one of the most stigmatizing and least socially acceptable conditions in childhood. These and similar findings emphasize how critical it is for health professionals, teachers, and parents to be aware of not only the medical risks of obesity in children but also the potential psychological significance of this condition.

The eating environment existing in contemporary America often promotes the intake of convenient, relatively inexpensive, highly palatable foods served in large portions.<sup>81</sup> As previously mentioned, this type of eating pattern from childhood through adult life contributes to obesity as well as diabetes, hypertension, coronary heart disease, and certain types of cancer. Regrettably, the factors contributing to future obesity are thought to begin in infancy and early childhood.<sup>82</sup> Since these diseases only become evident during adulthood despite having their origins in childhood and adolescence, they provide the health care professional with a potential avenue for preventive medicine. Early intervention approaches in these population groups may promote healthier eating patterns. Atherosclerotic heart disease is such a case. Modifiable risk factors can be identified and addressed in the pediatric population, with the goal of preventing or ameliorating heart disease in later life. Thus, prevention of coronary heart disease is a pediatric health issue, as is prevention of the other diseases mentioned earlier.

Epidemiologic studies have identified a web of factors that can contribute to the obesity epidemic in US children and adolescents. These influences exist at the individual, family, community, and societal levels. They include changing meal environments, increased TV viewing and video game playing, food availability, less parental leisure time, changes in suburbia that discourage physical activity, increased concern over neighborhood safety, increased advertising and availability of high-fat, calorie-dense fast food, changes in parental work patterns, increased need for child care, and increased utilization of labor-saving devices (e.g., cars, computers, smart phones, etc.). Because the problem is multifactorial, solutions should target multiple factors. An extensive review of the literature by Wofford<sup>83</sup> clearly identified the preschool years as a critical time to intervene in obesity prevention. Parental involvement and a role by health care practitioners in emphasizing recommendations were vital to successful interventions. In addition, prevention strategies should focus on building positive, healthy behaviors that produce more satisfactory long-term results than do strategies that focus on limiting behaviors.<sup>83</sup>

A classic research study showed that the prevalence of obesity is lowest among children watching <1 hour of television a day and highest among those watching  $\geq 4$  hours a day.<sup>84</sup> Not only will sedentary children expend less energy, but they will also invariably be increasing their consumption of high-fat, high-sugar, high-calorie snack foods during these sedentary periods.<sup>85</sup> Research from roughly two decades ago indicates that food (typically a sweet snack) is consumed or referred to three to five times per 0.5 hour on prime-time programming.<sup>86</sup> Additionally, the majority of commercials shown during children's programming promote foods with low nutritional value, including candy, soft drinks, sugared cereals, and potato chips, as well as other high-salt, high-fat snacks.<sup>87</sup>

Any effort to attack the obesity problem should focus not only on making better food choices but also on increasing physical activity levels, which increases energy use and helps achieve a healthy weight. Exercise promotes both physical health and emotional well-being. How much and

how often you exercise is a major determinant of both morbidity and mortality. It has been identified as a national priority area for promoting the health of the US population.<sup>88</sup> However, many children and adolescents do not meet the recommendations for physical activity. This fact is particularly sobering because the adolescent years are thought to be the period during which adult health-related behaviors such as dietary and physical activity patterns are being shaped. Childhood is likely to be a critical time for promoting physical activity. In 2005, the CDC reported that only 27.8% of high-school girls and 43.8% of high-school boys participated in at least 60 minutes of physical activity per day. By 2011,<sup>89</sup> this proportion declined to 18.5% for girls and 38.3% for boys. In 2017, the CDC reported that only 26.1% of high-school students participated in at least 60 minutes of daily physical activity and fewer than 25% of children aged 6–17 years participated in 60 minutes of daily physical activity.<sup>102</sup>

Walking as a means of transportation is a component of an active lifestyle associated with a reduced risk of chronic diseases and an increased sense of well-being; however, time spent walking has declined among US children. One of the objectives of *Healthy People 2010* was to increase the proportion of walking trips to school from 28.8% to 31.7% among children and adolescents. In 1969 approximately half of all US schoolchildren walked or biked to and from school; of those living within 1 mile of school, 87% walked or biked to school. By 2004, fewer than 15% of children used an active mode of transportation. In 2004, the CDC reported the results of a Consumer Styles survey of parents that cited distance to school as the most common barrier to walking to school, followed by traffic-related dangers.<sup>91</sup> The reduction in total physical activity that occurs from mid-to late adolescence appears to be related more to a reduction in the number of activities in which adolescents choose to participate than to a decline in the time spent on each activity.<sup>92</sup> This finding supports other evidence that physical activity declines during adolescence.

According to the 2015–2020 Dietary Guidelines for Americans, it is recommended that children and adolescents participate in at least 60 minutes of moderately intense physical activity most days of the week, preferably daily. For youth, regular physical activity has beneficial effects on weight, muscular strength, cardiorespiratory fitness, bone mass, blood pressure, anxiety, and self-esteem. Walking programs are being increasingly promoted for youth in selected school systems. Many of these programs are using pedometers to register the number of steps being taken. These small units, which clip onto waistbands, resemble tiny pagers and are reasonably accurate in counting all the steps taken over a given period of time. For some programs, the goal is to reach 12,000 steps per day, but for all the programs, a general objective is to motivate the person wearing the pedometer to progressively increase the step count over time and to maintain a minimally acceptable level of steps per day.

## HEALTH IMPACT OF HIGH SALT INTAKE

When we consider the issue of overnutrition and how it might relate to health problems, sodium intake generally

emerges as an important topic for consideration. More specifically, we question whether children and adolescents are consuming too much sodium from dietary salt and initiating a behavior of eating that will be problematic during their lifetimes. According to a recent study,<sup>93</sup> the answer is likely to be “yes.” This team of researchers monitored the eating habits of more than 760 high-school adolescents for a week. They observed that these teenagers were ingesting as much dietary salt as were their adult counterparts, an amount far exceeding guidelines for good health. On average, the teenagers were taking in almost 3300 mg sodium each day, an amount more than double the 1500 mg currently recommended by the American Heart Association.<sup>94</sup>

An additional finding of the research was that a direct link existed between the high levels of salt intake and an increased risk for overweight and obesity. Previous studies<sup>95,96</sup> have shown that salt typically promotes the desire to drink more sugary sodas and consume more calories, thereby providing a potential mechanism for weight gain.

An elevated sodium intake has often been cited as being associated with an increase in blood pressure, raising hypertension rates and the risk for heart disease and early death.<sup>97</sup> It has also been suggested that by significantly reducing the average daily intake of sodium, the general population could enjoy improved health.

From a dental health perspective, the increased desire for sugary beverage consumption, triggered by a high-salt diet, could contribute to dental caries and other harmful effects. Several strategies to offset these kinds of adverse oral effects from high-salt diets would be to read food labels carefully and not choose those with high sodium content, not to add salt to food via the salt shaker, and to select fresh fruits and vegetables as food choices whenever possible.

## Feeding and Eating Disorders

Physical appearance is of prime importance for most teenagers, and for some adolescent girls, getting “thin enough” can become an obsession. It is estimated that 20 million women and 10 million men suffer from a clinically significant eating disorder such as anorexia nervosa, bulimia nervosa, or binge eating disorder at some point during their lifetime.<sup>98</sup> Because women and men are often secretive about their eating disorders, existing epidemiologic studies may underestimate the true prevalence of these conditions.<sup>99</sup> Some personality traits, such as perfectionism and obsession with weight and body dissatisfaction, may cluster in families of women with eating disorders. Perfectionism may be an environmental or genetic factor.<sup>101,102</sup>

*Disordered eating* is a term that includes a full spectrum of unhealthy eating behaviors from inappropriate dieting to clinical eating disorders.<sup>102</sup> The mass media are viewed by many as major contributors in influencing disordered eating behaviors in young people through the presentation of often unattainable physical images and emphasis on the “thin ideal.”<sup>103</sup>

Analyses of body measurements of 500 models listed on modeling agency websites and in adult magazines over a 12-year period showed that nearly all the centerfolds and

three-fourths of the models had BMIs that approximated the American Psychological Association’s criteria for anorexia nervosa.<sup>104</sup> Although boys may be increasingly influenced by the portrayals of muscular men in the media, most research has focused on the effects of media portrayals on girls’ eating and dietary habits. Teenage girls are most at risk for developing eating disorders as they struggle with bodies that are getting larger in a culture that simultaneously attempts to sell them junk food and tells them that they should be thin. A study by Field et al.<sup>105</sup> found that more than 10% of adolescent girls and 3% of boys binge eat or purge at least once a week. Risk factors for these disordered eating behaviors included frequent dieting, concerns about weight, and in girls younger than 14 years, maternal history of an eating disorder.

Research has shown that being overweight in childhood is a risk factor for disordered eating, and both are risk factors for full-syndrome eating disorders. Shape and weight concerns appear to be elevated in overweight children and teenagers, especially in white girls. Up to 79% of overweight youth report unhealthy weight control behaviors, and up to 17% report extreme weight control behaviors such as self-induced vomiting or laxative or diuretic abuse.<sup>106</sup>

A study of risk factors for eating disorders conducted by Rohde et al.<sup>107</sup> in a sample of over 400 US adolescent girls found that body dissatisfaction, negative effect, pressure to be thin, internalization of the thin ideal, and dieting were significant predictors of eating disorder development. Findings indicated that although eating disorders tend to manifest in late adolescence, most of these risk factors assessed are present much earlier, and that body dissatisfaction appears to present in advance of any perceived pressure to achieve an ideal thinness.<sup>107</sup> Unlike the findings of others,<sup>108</sup> this study determined that BMI was not a predictor for eating disorder development up to age 21, which led the authors to suggest that subjective dissatisfaction with body shape and size, rather than actual levels of adiposity, might be a more important factor in the appearance of eating disorders.<sup>107</sup> Likewise, analysis of data from the National Longitudinal Study of Adolescent Health, a large, nationally representative sample of over 14,000 individuals, found that early dieting, depression, and body image distortion were associated with eating disorders in young adulthood. The prevalence of eating disorders among the males and females in the sample ranged from 2% to 6%, with the most common being binge eating. Dieting was reported by 27% of females and 11% of the males.<sup>109</sup>

Considering the high prevalence of weight-related concerns and body dissatisfaction among young people in the United States, it would be prudent to aim appropriate interventions at all youth.

## ANOREXIA NERVOSA

Preoccupation with appearance and body weight during adolescence may lead to anorexia nervosa—a condition of self-induced starvation. Anorexia may be of the restrictive type, in which food intake is severely limited, or of the binge eating/purging type, in which individuals engage in



self-induced vomiting or the misuse of laxatives, diuretics, or enemas. This illness, which is much less common in males and is also less common than bulimia nervosa, is characterized by self-imposed weight loss, amenorrhea, and a distorted attitude toward eating and body weight. In some instances, this behavior is used as a means of establishing a sense of identity and control. Anorexia nervosa has captured the interest of psychoanalysts, behavior therapists, family therapists, nutritionists, and endocrinologists alike because of the interplay among the powerful psychological, environmental, genetic, and physiologic components of the disease. Anorexia nervosa rarely begins before puberty and probably manifests across a wide range of severity levels. Affected individuals often lack the ability to recognize that their emaciated bodies are too thin. Despite their advanced state of wasting, they may continue to believe that they are overweight. According to the *Diagnostic and Statistical Manual, Fifth Edition (DSM-5)*, the three diagnostic criteria for anorexia nervosa are the following:<sup>110,111</sup>

- Persistent restriction of energy intake leading to significantly low body weight (in context of what is minimally expected for age, gender, developmental trajectory, and physical health).
- Either an intense fear of gaining weight or of becoming fat, or persistent behavior that interferes with weight gain (even though significantly low in body weight).
- Disturbance in the way one's body weight or shape is experienced, undue influence of body shape and weight on self-evaluation, or persistent lack of recognition of the seriousness of the current low body weight.

A wide range of complications, including many of the consequences of starvation, is possible in anorexia nervosa. Fat depletion is the most obvious physical consequence. Qualitative deficiencies in the diet may lead to anemia, hypoproteinemia, and sometimes vitamin deficiencies. Serious electrolyte imbalances, notably hypokalemia, can occur when vomiting or laxative or diuretic abuse is practiced. Anorexia may be accompanied by enlargement of the parotid glands, edema of the legs, increased facial hair, and reductions in blood pressure and pulse rate. Nutritional deficiencies may lead to glossitis, gingivitis, a reduction in the amount and pH of the saliva, and an increase in dental caries susceptibility. Dental erosion may be evident on the palatal aspects of anterior and posterior teeth (perimolysis) secondary to the use of sports drinks, caffeinated/carbonated drinks, wine, vinegar, and lemon juice used to quell sensations of hunger. Anorexics who engage in self-induced vomiting may exhibit epithelial erosion, gingivitis, and dental erosion on the palatal surfaces of the maxillary anterior teeth.<sup>110</sup>

Long-term studies have demonstrated diverse outcomes ranging from full recovery to chronicity and death. Outpatient treatment is preferred for most individuals. Treatment is typically multidisciplinary and involves medical, nutritional, social, and psychological components.<sup>112</sup> If the illness is severe and family and environmental circumstances are too damaging, or if there is little response to outpatient treatment, then hospitalization is indicated.

Fluoxetinehydrochlorideappearstohelpcontroltheobsessive-compulsive behavior involved in both anorexia nervosa and bulimia. This drug raises the brain levels of serotonin, and consequently, the urge to binge and the preoccupation with food appear to lessen.

## BULIMIA

Another eating disorder, bulimia nervosa, is characterized by binge eating and invariably by self-induced vomiting. It also is more prevalent in young women and is more common than is anorexia nervosa. It usually begins during late adolescence or early adult life. Its prevalence among males is probably vastly underestimated because of underreporting. The American Psychiatric Association's diagnostic criteria for bulimia nervosa are the following<sup>111</sup>:

- Eating, in a discrete period of time (e.g., within any 2-hour period), an amount of food that is definitely larger than what most individuals would eat in a similar period of time under similar circumstances.
- A sense of a lack of control overeating during the episode (e.g., a feeling that one cannot stop eating or control what or how much one is eating).
- Recurrent inappropriate compensatory behaviors to prevent weight gain, such as self-induced vomiting; misuse of laxatives, diuretics, or other medications; fasting; or excessive exercise.
- The binge eating and compensatory behaviors both occur, on average, at least once a week for 3 months.
- Self-evaluation is unduly influenced by body shape and weight.
- The disturbance does not occur exclusively during episodes of anorexia nervosa.

Although it is more medically benign than anorexia nervosa, bulimia nervosa is associated with significant health consequences. Approximately half of patients with this disorder have fluid and electrolyte abnormalities. Hypokalemia develops in a small percentage of patients. Enlargement of the parotid glands, esophagitis, and gastric necrosis may also occur. Because of the exposure of the tooth surfaces to the highly acidic regurgitated gastric contents, enamel erosion is common among patients with bulimia nervosa. The degree of enamel damage can be extensive. Although unanimity of opinion does not exist, the suggestion has been made that toothbrushing after vomiting promotes enamel loss and that, instead, patients should be instructed to rinse with an alkaline solution such as sodium bicarbonate dissolved in water. Other suggestions include the use of liquid sugar-free antacids, water, or milk. A fluoride treatment should be considered because of its potential for re-mineralizing previously demineralized areas of the dentition. Daily rinses with 0.5% sodium fluoride and administration of a 1.1% neutral fluoride gel in custom trays can be recommended.

Most bulimic patients can be treated effectively as outpatients. Although antidepressant medications may be useful in some cases, a multidisciplinary approach to treatment

is often indicated.<sup>112</sup> There is some evidence that individuals, particularly girls, who have family meals in a positive atmosphere are at lower risk for bulimia. Family meals may serve a protective function against disordered eating as well as other problems by acting as a forum for working through various issues.<sup>114</sup>

## BINGE EATING DISORDER

Within the DSM-5, released in 2013, binge eating disorder achieved official diagnostic recognition. The essential feature of binge eating disorder is recurrent episodes of binge eating that must occur, on average, at least once per week for 3 months. It is defined by the consumption of excessive amounts of food along with the sensation of loss of control. The following are the DSM-5<sup>111</sup> criteria for this disorder:

- Recurrent episodes of binge eating. A recurrent episode is characterized by both of the following:
  - Eating in a discrete period (e.g., within any 2-hour period) an amount of food that is definitely larger than what most people would eat in a similar period of time and under similar circumstances.
  - A sense of a lack of control overeating during the episode (e.g., a feeling that one cannot stop eating or control what or how much one is eating).
- The binge eating episodes are associated with three or more of the following:
  - Eating much more rapidly than normal.
  - Eating until feeling uncomfortably full.
  - Eating large amounts of food when not feeling hungry.
  - Eating alone because of feeling embarrassed by how much one is eating.
  - Feeling disgusted with oneself, depressed, or very guilty afterward.
- Marked distress regarding binge eating is present.
- Binge eating occurs, on average, at least once a week for 3 months.
- Binge eating is not associated with the recurrent use of inappropriate compensatory behavior as in bulimia nervosa and does not occur exclusively during the course of bulimia nervosa or anorexia nervosa.

Patients with binge eating disorder may be treated as outpatients in a multidisciplinary manner. In overweight patients with binge eating disorder, the goals include achieving a sustainable weight loss and abstaining from binge eating. Pharmacotherapy with antidepressants and selective serotonin reuptake inhibitors has been used. Other classes of medications, such as anti-obesity drugs and anticonvulsants, have also been studied and have shown some success. Psychotherapy in the form of cognitive-behavioral therapy has been a popular approach, and other modalities such as exercise, self-help, and virtual reality therapy have also been tried as adjunctive therapies for binge eating disorder. Furthermore, some studies indicate that there may be a benefit to combined behavioral therapy and pharmacotherapy in the treatment of binge eating disorder; however, more research is needed

for a better understanding of the long-term effects of these treatments. As health care professionals deal with eating disorders in their patients, they recognize that primary prevention combined with early detection and treatment clearly helps reduce morbidity and mortality in affected youth.<sup>112</sup>

## Gastroesophageal Reflux

Gastroesophageal reflux (GER), also known as acid reflux, can occur in children and teens from backward flow of stomach contents into the esophagus producing heartburn symptoms. Thus, it should be noted that GER can produce oral manifestations resembling those seen in bulimia, including the erosion of tooth enamel. If GER symptoms become chronic, the child should be evaluated for gastroesophageal reflux disease. Depending upon the contributing factors, treatment may include diet and lifestyle changes, medications, or surgery.<sup>113</sup>

## Q & A Concerning Pediatric Nutrition Issues

*Why is a nutritious breakfast important to begin the day?*

Examined from a nutrient density perspective (nutrients provided per calorie), breakfast is generally the most important meal of the day; however, 40% of children and teenagers in America are thought to skip breakfast. Those who skip it are literally on an unintended 36-hour fast until lunchtime, and are observed to suffer from more physical, intellectual, and behavioral problems compared with those who eat a nutritious breakfast. Eating a healthy breakfast is associated with improved cognitive function, memory, reduced tardiness, and improved mood.

*Is a vegetarian diet healthy for children?*

Since plant-based foods are generally quite nutritious, a vegetarian diet can be healthful if well planned. An important question is what food items will replace the meat. If primarily legumes, beans, nuts, and soy products, there should be no protein inadequacy. If primarily cheese and whole milk, then there may be concerns over excess calories and saturated fat intake. Planning exclusively vegetarian diets will require careful consideration on how to receive adequate intakes of protein, iron, and vitamin B<sub>12</sub>.

*Are changes in store for food and nutrition labeling practices?*

The Food and Drug Administration has introduced significant changes in food and nutrition labels for the first time since such labels became mandatory some 20 years ago. The changes will make it easier for consumers to make better informed food choices. Calories appear in larger and bolder type. Added sugars are listed and serving sizes adjusted upward to reflect more accurately the amounts that Americans are actually consuming. Although large food manufacturers are required to use the new label by 2020, it is already in use on many food items.

*Why is healthy eating so important in childhood and adolescence?*

Ingesting nutritious foods early in life initiates an eating behavior that conveys protection against obesity, diabetes, and dental caries currently and later in life. Continuing to follow these patterns of eating over a lifetime is associated with a reduction in risk for heart disease, cancer, osteoporosis, hypertension, stroke, and early death. There are emotional and psychological benefits to be gained as well.

*What are the major concerns regarding unhealthy eating during childhood?*

Eating too few nutrients and calories in childhood will ultimately negatively affect growth, performance in school, cognitive development, and overall health. In contrast, overconsumption of fast food, processed snack foods, and sugar-sweetened beverages will invariably lead to weight gain, overweight, obesity, and an increased risk of diabetes, and may increase the risk for dental caries.

*What would a child's ideal dinner plate look like?*

Ideally, half the food on a child's plate would be fruits and vegetables. Protein would be provided largely by lean meats, nuts, and eggs. High-fiber, whole-grain breads and cereals would be served in lieu of refined grains. Fried foods would be limited, and milk and water would be offered instead of sugary fruit drinks and sodas. Of course, many children would not select such a plate voluntarily. This is where parents or guardians must help guide the children's food selections in a logical and loving manner.

*What are harmful dietary fats?*

Researchers agree that there are two major types of fat detrimental to health: saturated fat and fats containing trans fatty acids. Saturated fat comes primarily from animal foods such as meat, poultry, and certain dairy products. A high intake of this kind of fat increases low-density lipoprotein (LDL) cholesterol levels and elevates the risk for cardiovascular disease. Most trans fatty acids in our diet come as a result of a food manufacturing process known as hydrogenation, in which unsaturated fat is partially hydrogenated to enhance consumer properties. These latter fatty acids also increase blood levels of LDL cholesterol and increase the risk for cardiovascular disease. The U.S. Food and Drug Administration has recently proposed a regulatory change that would essentially ban artificial trans fats from the American diet by no longer considering them as "generally recognized as safe."

*What are considered as healthful dietary fats?*

Monounsaturated fat is found in vegetable oils, fruits, nuts, legumes, and fish, and has been reported to lower blood cholesterol and help reduce the risk of heart diseases. This type of fat may also help regulate blood insulin and glucose levels and pose beneficial for persons with type 2 diabetes. Polyunsaturated fat is primarily found in plant-based foods such as vegetable oils. These oils are thought to improve blood cholesterol levels, thereby lessening the risk of heart disease. Omega-3 fatty acids appear to be of particular benefit in preventing heart disease. These healthful fatty acids

are primarily found in fatty cold-water fish and fish oils. They are present in plant oils as well, but it is less certain if that source is as effective in promoting heart health as are fish oils. Omega-3 fatty acid supplements are not thought to be as beneficial as those from natural food sources.

*Do healthy children need vitamin supplements?*

Foods that we consume contain essential vitamins, minerals, protein, fiber, phytochemicals, and other beneficial chemicals whose roles in human nutrition have not yet been fully identified. Nutritional supplements do not contain this range of essential nutrients present within the natural environment of a food substance. Vitamin and other supplements are not intended to serve as food substitutes. Children should be encouraged and helped to receive their nutrients from foods, rather than from nutritional supplements.

*Are there foods that fight flu and colds?*

There are neither specific foods nor nutrients that can either prevent or cure a cold or influenza. However, some evidence suggests that there are strategies to help strengthen the immune system and aid in resisting these illnesses. Examples include getting plenty of sleep, participating in regular exercise, keeping well hydrated, and minimizing stress. The foods that may help in this endeavor by contributing protective substances include green leafy vegetables, highly pigmented vegetables and fruits, citrus fruits, vegetable oils, nuts, whole grains, and seafood. This diverse collection of foods provides high levels of nutrients such as beta-carotene, vitamin A, vitamin C, vitamin E, assorted other antioxidants, and the minerals zinc and selenium, all of which may fortify the immune system.

*Are fruit drinks and juices healthy for children?*

Most children enjoy the taste of fruit juices but may drink them in excess to the exclusion of other more nutritious foods. Many fruit drinks are high in added sugar and calories, and even 100% fruit and vegetable juices are often highly acidic. The outcome of this may be the intake of too much sugar and calories, thus contributing to problems such as poor overall nutritional quality of the diet, obesity, as well as enamel erosion and dental caries. Far more acceptable dietary choices than fruit drinks and juices are whole fruits, low-fat dairy, or water.

*Are meal replacement shakes and smoothies good snack choices for children and adolescents?*

The consumption of fruit-, vegetable-, or protein-based smoothies and shakes has become popular in recent years. These products are often high in acid, sugar, and fermentable carbohydrates. If kids and teenagers are consuming such meal replacement beverages multiple times per day as snacks, the amount of time the oral cavity is exposed to a reduction in pH is increased, which increases the risk of demineralization, enamel erosion, and dental caries. More healthful choices would include non-cariogenic snacks of solid foods such as nuts, cheese, popcorn, milk, yogurt, and raw vegetables.



*Are diet sodas and sports/energy drinks harmful to children and adolescents?*

Diet sodas are popular among children and teenagers and are perceived as healthier than sugared beverages; in addition, they are often used by youth concerned about gaining weight. Sports and energy drinks are also marketed as “healthy” alternatives to regular soda and as a means to obtain better physical performance or maintain alertness. The American College of Sports Medicine recommends consumption of adequate food and fluids before, during, and after exercise to help maintain blood glucose during exercise, maximize performance, and improve recovery time; consumption of sport drinks containing carbohydrates and electrolytes during intense exercise periods lasting longer than 1 hour may be helpful in refueling muscles and decreasing the risk of dehydration. However, for shorter exercise periods, consumption of plain water is recommended. The so-called energy drinks are often high in caffeine, and adverse cardiovascular events have been reported with their use in some individuals. Moreover, these beverages are often highly acidic and can cause dissolution of tooth enamel.

Additionally, although diet sodas do not contain sugar, sports and energy drinks often do, and whether they contain sugar or not, excessive consumption of any of these beverages can be harmful to oral health. These beverages contain acids such as phosphoric and citric acid, which can contribute to enamel erosion and dental caries, particularly if the consumer sips on these products throughout the day.

*How common are food allergies?*

It is estimated that 3% to 4% of the American population is affected by food allergies, generally affecting the digestive or respiratory system or the skin. True food allergies have a sudden onset and occur whenever the offending food is eaten. The most common culprits are nuts, fish or shellfish, milk, eggs, soy, and wheat, with symptoms ranging from mild to potentially life threatening. They are caused by an allergic response by the immune system to a food component, mistakenly thought to pose a threat to the body. The resulting biologic reaction against the allergen produces the symptoms. In contrast, food intolerances have a more gradual onset, are generally less severe, and do not have a fatal outcome. These food sensitivities are usually produced by stomach irritation and improper food digestion. Lactose intolerance is probably the most common food intolerance. Gluten may produce either an allergic response or a sensitivity reaction. Once the offending food allergen has been identified, the primary treatment is to remove that item from the diet permanently. Food intolerances can be treated more easily. Simply reducing the quantity and frequency of the offending food that is eaten can alleviate most symptoms.

*Is the gluten in foods a common problem for children and adolescents?*

Gluten is a mixture of proteins found in foods processed from wheat and other grains. Roughly 1% of the US population suffers from celiac disease, which is an autoimmune disease of the small intestine in which the individual is intolerant to gluten in the diet. Those affected generally exhibit a broad range and severity of intestinal symptoms. Perhaps 6% of the population may be affected by non-celiac gluten intolerance/sensitivity, which is usually a less severe gastrointestinal condition and does not fall into the conventional autoimmune disease category. These ailments are often helped by avoiding gluten in the diet, which is sometimes a difficult task to accomplish in view of the rather ubiquitous distribution, albeit at low concentrations, of gluten in a variety of food products. An important first step for sufferers is to receive an accurate diagnosis from a physician to determine the best treatment approach.

*Are there any “addictive” foods?*

An addiction is simply defined as a powerful and harmful need to have regular access to something (such as a drug) or participate in an activity (such as gambling). The definition becomes less clear when applied to food addictions. Some scientists feel that certain foods behave similar to addictive drugs and cause a release of “feel-good” chemicals in the brain when they are eaten. Others disagree, insisting that overeating is basically an emotional problem, not one of an addiction. A few studies have identified chocolate, sugar, and cheese as likely suspects in the addictive foods category. All three have been demonstrated at times to promote the release of opiate-like substances that stimulate the brain’s pleasure center and promote the eating of these foods frequently and compulsively.

## References

1. Xu JQ, Murphy SL, Kochanek KD, et al. Deaths: Final data for 2016. National Vital Statistics Reports; vol 67 no 5. Hyattsville, MD: National Center for Health Statistics. 2018.
2. Samieri C, Sun Q, Townsend MK, et al.: The association between dietary patterns at midlife and health in aging. *Ann Intern Med* 159(9):584–591, 2013.
3. CIA World Fact Book. World Life Expectancies.
4. U.S. Department of Health and Human Services: *Nutrition and weight status*. . <http://www.healthypeople.gov/2020/default.aspx>, 2014.
5. U.S. Department of Health and Human Services: *Office of Disease Prevention and Health Promotion*, . <http://www.health.gov/dietaryguidelines/2010.asp>, 2014.
6. U.S. Department of Health and Human Services and U.S. Department of Agriculture: *2015–2020 Dietary Guidelines for Americans*, 8th ed., . December., Available at. <http://health.gov/dietaryguidelines/2015/guidelines/>, 2015.
7. United States Department of Agriculture (USDA). <http://choosemyplate.gov>.
8. Briefel RR, Johnson CL: Secular trends in dietary intake in the United States, *Annu Rev Nutr* 24:401–431, 2004.
9. Nicklas T, Johnson R: Position of the American Dietetic Association: dietary guidance for healthy children ages 2–11 years, *J Am Diet Assoc* 104(4):660–667, 2004.

10. Enns CW, Mickle SJ, Goldman JD: Trends in food and nutrient intakes by children in the United States. *Fam Econ Nutr Rev* 14(2):56–68, 2002.
11. Fulgoni EL, Quann EE: National trends in beverage consumption in children from birth to 5 years: analysis of NHANES across three decades. *Nutr J* 11(1):92, 2012.
12. Demmer E, Cifelli CJ, Houchins JA, Fulgoni 3rd VL: Ethnic disparities of beverage consumption in infants and children 0-5 years of age: National Health and Nutrition Examination Survey 2011 to 2014. *Nutr J* 17(1):78, 2018. <https://doi.org/10.1186/s12937-018-0388-0>. Aug 22.
13. Han E, Powell LM: Consumption patterns of sugar-sweetened beverages in the United States. *J Acad Nutr Diet* 113(1):43–53, 2013.
14. Dubois L, Farmer A, Girard M, et al.: Regular sugar-sweetened beverage consumption between meals increases risk of overweight among preschool-aged children. *J Am Diet Assoc* 107(6):924–935, 2007.
15. Hu FB: Resolved: there is sufficient scientific evidence that decreasing sugar-sweetened beverage consumption will reduce the prevalence of obesity and obesity-related diseases. *Obes Rev* 14(8):606–609, 2013.
16. Kosova EC, Auinger P, Bremer AA: The relationships between sugar-sweetened beverage intake and cardiometabolic markers in young children. *J Acad Nutr Diet* 113(2):219–227, 2013.
17. Slining MM, Mathias KC, Popkin BM: Trends in food and beverage sources among US children and adolescents: 1989-2010. *J Acad Nutr Diet* 113(12):1683–1694, 2013.
18. Eldridge AL1, Catellier DJ2, Hampton JC2, Dwyer JT3, Bailey RL4: Trends in Mean Nutrient Intakes of US Infants, Toddlers, and Young Children from 3 Feeding Infants and Toddlers Studies (FIITS). *J Nutr* 149(7):1230–1237, 2019. <https://doi.org/10.1093/jn/nxz054>. Jul 1.
19. Reedy J, Krebs-Smith SM: Dietary sources of energy, solid fats, and added sugars among children and adolescents in the United States. *J Am Diet Assoc* 110(10):1477–1484, 2010.
20. Ford CN, Slining MM, Popkin BM: Trends in dietary intake among US 2- to 6-year-old children, 1989-2008. *J Acad Nutr Diet* 113(1):35–42, 2013.
21. Moore LL, Singer MR, Qureshi MM, et al.: Food group intake and micronutrient adequacy in adolescent girls. *Nutrients* 4(11):1692–1708, 2012.
22. Iannotti RJ, Wang J: Trends in physical activity, sedentary behavior, diet, and BMI among US adolescents, 2001-2009. *Pediatrics* 132(4):606–614, 2013.
23. USDA's Food and Nutrition Service [www.fns.usda.gov/](http://www.fns.usda.gov/) November 2017
24. USDA: *Food and Nutrition Service National Lunch Program (NSLP)*. Accessed September 25, 2020 <https://fns-prod.azureedge.net/nslp-fact-sheet>, 2019.
25. Briefel RR, Wilson A, Gleason PM: Consumption of low-nutrient, energy-dense foods and beverages at school, home, and other locations among school lunch participants and nonparticipants. *J Am Diet Assoc* 109(2 Suppl):S79–S90, 2009.
26. Clark MA, Fox MK: Nutritional quality of the diets of US public school children and the role of the school meal programs. *J Am Diet Assoc* 109(2 Suppl):S44–S56, 2009.
27. Grimes CA, Wright JD, Liu K, et al.: Dietary sodium intake is associated with total fluid and sugar-sweetened beverage consumption in US children and adolescents aged 2-18 y: NHANES 2005-2008. *Am J Clin Nutr* 98(1):189–196, 2013.
28. Ohri-Vachaspati P, Turner L, Chaloupka FJ: Fresh Fruit and Vegetable Program participation in elementary schools in the United States and availability of fruits and vegetables in school lunch meals. *J Acad Nutr Diet* 112(6):921–926, 2012.
29. Evans CE, Christian MS, Cleghorn CL, et al.: Systematic review and meta-analysis of school-based interventions to improve daily fruit and vegetable intake in children aged 5 to 12 y. *Am J Clin Nutr* 96(4):889–901, 2012.
30. Au LE, Gurzo K, Gosliner W, Webb KL, Crawford PB, Ritchie LD: Eating School Meals Daily Is Associated with Healthier Dietary Intakes: The Healthy Communities Study. *J Acad Nutr Diet*. 2018 Aug;118(8):1474-1481.e1. doi: 10.1016/j.jand.2018.01.010. Epub 2018 Mar 17.
31. Au LE, Rosen NJ, Fenton K, Hecht K, Ritchie LD: Eating School Lunch Is Associated with Higher Diet Quality among Elementary School Students. *J Acad Nutr Diet* 116(11):1817–1824, 2016. <https://doi.org/10.1016/j.jand.2016.04.010>. Epub 2016 May 21.
32. Guthrie JF, Lin BH, Frazao E: Role of food prepared away from home in the American diet, 1977-78 versus 1994-96: changes and consequences. *J Nutr Educ Behav* 34(3):140–150, 2002.
33. Poti JM, Popkin BM: Trends in energy intake among US children by eating location and food source, 1977-2006. *J Am Diet Assoc* 111(8):1156–1164, 2011.
34. Powell LM, Nguyen BT: Fast-food and full-service restaurant consumption among children and adolescents: effect on energy, beverage, and nutrient intake. *JAMA Pediatr* 167(1):14–20, 2013.
35. Larson N, MacLehose R, Fulkerson JA, et al.: Eating breakfast and dinner together as a family: associations with sociodemographic characteristics and implications for diet quality and weight status. *J Acad Nutr Diet* 113(12):1601–1609, 2013.
36. Lachat C, Nago E, Verstraeten R, et al.: Eating out of home and its association with dietary intake: a systematic review of the evidence. *Obes Rev* 13(4):329–346, 2011.
37. Bezerra IN, Curioni C, Sichieri R: Association between eating out of home and body weight. *Nutr Rev* 70(2):65–79, 2012.
38. Young L, Nestle M: Expanding portion sizes in the U.S. marketplace: implications for nutrition counseling. *J Am Diet Assoc* 103(2):231–234, 2003.
39. Piernas C, Popkin BM: Increased portion sizes from energy-dense foods affect total energy intake at eating occasions in US children and adolescents: patterns and trends by age group and sociodemographic characteristics, 1977-2006. *Am J Clin Nutr* 94(5):1324–1332, 2011.
40. Larson N, Story M: A review of snacking patterns among children and adolescents: what are the implications of snacking for weight status? *Child Obes* 9(2):104–115, 2013.
41. Tripicchio GL, Kachurak A, Davey A, Bailey RL, Dabritz LJ2 Fisher JO. Associations between Snacking and Weight Status among Adolescents 12-19 Years in the United States. *Nutrients*. 2019 Jun 29;11(7). pii: E1486. doi: 10.3390/nu11071486. Dunford EK, Popkin BM. 37 year snacking trends for US children 1977-2014. *Pediatr Obes*. 2018 Apr;13(4):247-255. doi: 10.1111/ijpo.12220. Epub 2017 May 15.
42. Larson NI, Miller JM, Watts AW, Story MT: Neumark-Sztainer DR Adolescent Snacking Behaviors Are Associated with Dietary Intake and Weight Status. *J Nutr* 146(7):1348–1355, 2016. <https://doi.org/10.3945/jn.116.230334>. Epub 2016 Jun 8.
43. Koletzko B, Toschke AM: Meal patterns and frequencies: do they affect body weight in children and adolescents? *Crit Rev Food Sci Nutr* 50(2):100–105, 2010.
44. Wansink B, Van Kleef E: Dinner rituals that correlate with child and adult BMI. *Obesity* 22(5):E91–E95, 2014.
45. Berge JM, Jin SW, Hannan P, et al.: Structural and interpersonal characteristics of family meals: associations with adolescent body mass index and dietary patterns. *J Acad Nutr Diet* 113(6):816–822, 2013.
46. Child Welfare League of America 2013. <http://www.cwla.org/programs/health/healthtips/malnutrition.htm>. Accessed March 10, 2013.
47. Murphy SL, Xu JQ, Kochanek KD, Arias E: *Mortality in the United States, 2017*. NCHS Data Brief, no 328, Hyattsville, MD, 2018, National Center for Health Statistics.
48. Knol LL, Haughton B, Fitzhugh EC: Dietary patterns of young, low-income US children. *J Am Diet Assoc* 105(11):1765–1773, 2005.
49. United States Department of Agriculture Economic Research Service (2014). Available at [http://www.ers.usda.gov/topics/food-nutrition-assistance/food-security-in-the-us.aspx#\\_Ux87hoWwXwo](http://www.ers.usda.gov/topics/food-nutrition-assistance/food-security-in-the-us.aspx#_Ux87hoWwXwo). Accessed March 8, 2014.
50. Coleman-Jensen A, Nord M, Singh A: *Household Food Security in the United States in 2012. Table 1B*. USDA ERS, 2013. [http://feedingamerica.org/hunger-in-america/hunger-facts/child-hunger-facts.aspx#\\_edn10](http://feedingamerica.org/hunger-in-america/hunger-facts/child-hunger-facts.aspx#_edn10).
51. USDA Economic Research Service <https://www.ers.usda.gov/topics/food-nutrition-assistance/food-security-in-the-us/key-statistics-graphics.aspx>.
52. Ryu JH, Bartfeld JS: Household food insecurity during childhood and subsequent health status: the early childhood longitudinal study—kindergarten cohort. *Am J Public Health* 102(11):e50–e55, 2012.
53. McLaughlin KA, Green JG, Alegria M, et al.: Food insecurity and mental disorders in a national sample of U.S. adolescents. *J Am Acad Child Adolesc Psychiatry* 51(12):1293–1303, 2012.

54. Franklin B, Jones A, Love D, et al.: Exploring mediators of food insecurity and obesity: a review of recent literature, *J Community Health* 37(1):253–264, 2012.
55. Metallinos-Katsaras E, Must A, Gorman K: A longitudinal study of food insecurity on obesity in preschool children, *J Acad Nutr Diet* 112(12):1949–1958, 2012.
56. Au LE, Zhu SM, Nhan LA, Plank KR, Frongillo EA, Laraia BA, Gurzo K: Ritchie LD Household Food Insecurity is Associated with Higher Adiposity among US Schoolchildren Ages 10-15 Years: The Healthy Communities Study, *Nutrxz108*, 2019, <https://doi.org/10.1093/jn/nxz108>. [Epub ahead of print].
57. Eicher-Miller HA, Zhao Y: Evidence for the age-specific relationship of food insecurity and key dietary outcomes among US children and adolescents, *Nutr Res Rev* 31(1):98–113, 2018, <https://doi.org/10.1017/S0954422417000245>. Epub 2018 Jan 10.
58. The Third School Nutrition Dietary Assessment Study. Findings and Policy Implications for Improving the Health of U.S. Children, *J Am Diet Assoc* 109(Suppl):S1–S136, 2009.
59. Kids and Vitamin D Deficiency: *American Academy of Pediatrics*, Online publication, 2012.
60. Black M: Effects of vitamin B<sub>12</sub> and folate deficiency on brain development in children, *Food Nutr Bull* 29(2 Suppl):S126–S131, 2008. NIH Public Access.
61. Baker R, Greer F: Diagnosis and prevention of iron deficiency and iron-deficiency anemia in infants and children (0-3 years of age), *Pediatrics* 126(5):1040–1050, 2010.
62. Kurugöl Z, Akilli M, Bayram N, et al.: The prophylactic and therapeutic effectiveness of zinc sulphate on common colds in children, *Acta Paediatr* 95(10):1175–1181, 2006.
63. Singh M: Zinc for the common cold, *Cochrane Database Syst Rev* 6:CD001364, 2013.
64. Briefel RR, Bialostosky K, Kennedy-Stephenson J, et al.: Zinc intake of the US population: findings from the third national health and nutrition examination survey, 1988-1994, *J Nutr* 130(Suppl 5):1367S–1373S, 2000.
65. Keye E: Bone health and oral health, *J Sch Health* 77(10):701–705, 2007.
66. Patrick R, Ames B: Vitamin D hormone regulates serotonin synthesis. Part 1: relevance for autism, *FASEB J* 28(6):2398–2413, 2014.
67. Weng FL, Shults J, Leonard MB, et al.: Risk factors for low serum 25-hydroxyvitamin D concentrations in otherwise healthy children and adolescents, *Am J Clin Nutr* 86(1):150–158, 2007.
68. Cashman KD, Hill TR, Cotter AA, et al.: Low vitamin D status adversely affects bone health parameters in adolescents, *Am J Clin Nutr* 87(4):1039–1044, 2008.
69. Vitamin D Supplements for Infants, *American Academy of Pediatrics* (March, 2010). On-line reference.
70. Neurologic impairment in children associated with maternal dietary deficiency of cobalamin—Georgia, 2001, *MMWR Morb Mortal Wkly Rep* 52(4):61–64, 2003.
71. Palmer C. Vitamins today. In: *Diet and nutrition in oral health*. Prentice Hall: New Jersey.
72. Centers for Disease Control and Prevention. 1600 Clifton Road Atlanta, GA 30329-34027, USA.
73. Centers for Disease Control and Prevention, National Center for Health Statistics. Centers for Disease Control and Prevention 1600 Clifton Road Atlanta, GA 30329-4027 USA.
74. Centers for Disease Control and Prevention 1600 Clifton Road Atlanta, GA 30329-4027 USA. Available at: <http://www.cdc.gov/obesity/childhood/index.html>
75. Ogden CL, Carroll MD, Kit BK, et al.: Prevalence of childhood and adult obesity in the United States, 2011-2012, *J Am Med Assoc* 311(8):806–814, 2014.
76. Sturm R: The effects of obesity, smoking, and drinking on medical problems and costs: obesity outranks both smoking and drinking in its deleterious effects on health and health costs, *Health Aff* 21(2):245–253, 2002.
77. Sinha R, Fisch G, Teague B, et al.: Prevalence of impaired glucose tolerance among children and adolescents with marked obesity, *N Engl J Med* 346(11):802–810, 2002.
78. Fontaine KR, Redden DT, Wang C, et al.: Years of life lost due to obesity, *J Am Med Assoc* 289(2):187–193, 2003.
79. Ackard DM, Neumark-Sztainer D, Story M, et al.: Overeating among adolescents: prevalence and associations with weight-related characteristics and psychological health, *Pediatrics* 111(1):67–74, 2003.
80. Schwimmer JB, Burwinkle TM, Varni JW: Health-related quality of life of severely obese children and adolescents, *J Am Med Assoc* 289(14):1813–1819, 2003.
81. Rolls B, Morris E, Roe L: Portion size of food affects energy intake in normal-weight and overweight men and women, *Am J Clin Nutr* 76(6):1207–1213, 2002.
82. Savage JS, Fisher JO, Birch LL, et al.: Parental influence on eating behavior, *J Law Med Ethics* 35(1):22–34, 2007.
83. Wofford L: Systematic review of childhood obesity prevention, *J Ped Nurs* 23(1):5–19, 2008.
84. Crespo CJ, Smit E, Troiano RP, et al.: Television watching, energy intake, and obesity in U.S. children: Results from the third National Health and Nutrition Examination Survey, 1988-1994, *Arch Pediatr Adolesc Med* 155(3):360–365, 2001.
85. Vader AM, Walters ST, Harris TR, et al.: Television viewing and snacking behaviors of fourth- and eighth-grade school children in Texas, *Prev Chronic Dis* 6(3):489, 2009.
86. Story M, Faulkner P: The prime time diet: a content analysis of eating and food messages in television content and commercials, *Am J Public Health* 80(6):738–740, 1990.
87. Taras HL, Gage M: Advertised foods on children's television, *Arch Pediatr Adolesc Med* 149(6):649–652, 1995.
88. CDC: Youth Risk Behavior Surveillance—United States, 2011, *MMWR Morb Mortal Wkly Rep* 61:2012
89. Pate R, O'Neill J: Physical activity guidelines for young children, *JAMA Pediatr* 166(12):1095–1096, 2012.
90. Division of Population Health, National Center for Chronic Disease Prevention and Health Promotion <https://www.cdc.gov/healthyschools/physicalactivity/facts.htm>
91. Centers for Disease Control: Barriers to children walking to or from school—United States, 2004, *MMWR Morb Mortal Wkly Rep* 54(38):949–952, 2005.
92. Aaron DJ, Storti KL, Robertson RJ, et al.: Longitudinal study of the number and choice of leisure time physical activities from mid to late adolescence: implications for school curricula and community recreation programs, *Arch Pediatr Adolesc Med* 156(11):1075–1080, 2002.
93. Zhu H, Pollock NK, Kotak I, et al.: Dietary sodium, adiposity and inflammation in healthy adolescents, *Pediatrics* 133(3):e635–e642, 2014.
94. American Heart Association Advisory Recommendation. Consume no more than 1500 mg of sodium a day (Jan 13, 2011).
95. He FJ, Marrero NM, MacGregor GA: Salt intake, hypertension, and obesity in children, *Hypertension* 51(3):629–634, 2008.
96. Grimes CA, Riddell LJ, Campbell KJ, et al.: Dietary salt intake, sugar-sweetened beverage consumption, and obesity risk, *Pediatrics* 131(1):14–21, 2013.
97. Mugavero K, Losby JL, Gunn JP, et al.: Reducing sodium intake at the community level: the Sodium Reduction in Communities program, *Prev Chronic Dis* 9:E168, 2012, <https://doi.org/10.5888/pcd9.120081>.
98. Wade TD, Keski-Rahkonen A, Hudson J. Epidemiology of eating disorders. In: (editors: Tsuang M.; Tohen M.) *Textbook in psychiatric epidemiology*. ed. 3. Wiley: New York, pp. 343–360.
99. Faine MP: Recognition and management of eating disorders in the dental office, *Dent Clin North Am* 47(2):395–410, 2003.
100. Woodside DB, Bulik CM, Halmi KA, et al.: Personality, perfectionism, and attitudes toward eating in parents of individuals with eating disorders, *Int J Eat Disord* 31(3):290–299, 2002.
101. Keel PK, Forney KJ: Psychosocial risk factors for eating disorders, *Int J Eat Disord* 46(5):433–439, 2013.
102. Sherman RT, Thompson RA: The female athlete triad, *J Sch Nurs* 20(4):197–202, 2004.
103. Fernandez S, Pritchard M: Relationships between self-esteem, media influence and drive for thinness, *Eat Behav* 13(4):321–325, 2012.
104. Brown JK, Witherspoon EM: The mass media and American adolescents' health, *J Adolesc Health* 31(Suppl 66):153–170, 2002.
105. Field AE, Javaras KM, Aneja P, et al.: Family, peer, and media predictors of becoming eating disordered, *Arch Pediatr Adolesc Med* 162(6):574–579, 2008.
106. Goldschmidt AB, Aspen VP, Sinton MM, et al.: Disordered eating attitudes and behaviors in overweight youth, *Obesity* 16(2):257–264, 2008.



107. Rohde P, Stice E, Marti CN: Development and predictive effects of eating disorder risk factors during adolescence: implications for prevention efforts, *Int J Eat Disord* 48(2):187–198, 2015, <https://doi.org/10.1002/eat.22270>.
108. Micali N, Ploubidis G, De Stavola B, et al.: Frequency and patterns of eating disorder symptoms in early adolescence, *J Adolesc Health* 54(5):574–581, 2014.
109. Liechty JM, Lee MJ: Longitudinal predictors of dieting and disordered eating among young adults in the U.S., *Int J Eat Disord* 46(8):790–800, 2013.
110. Lo LM, Lo LR, Massaccesi C, et al.: Eating disorders: a threat for women's health. Oral manifestations in a comprehensive review, *Minerva Stomatolog* 56(5):281–292, 2007.
111. Attia E, Becker AE, Bryant-Waugh R, et al.: Feeding and eating disorders in DSM-5, *Am J Psychiatry* 170(11):1237–1239, 2013.
112. Treasure J, Claudino AM, Zucker N: Eating disorders, *Lancet* 375(9714):583–593, 2010.
113. Treatment for GER & GERD in Children & Teens National Institute of Diabetes and Digestive and Kidney Diseases. National Institutes of Health. US Department of Health and Human Services. <https://www.niddk.nih.gov/health-information/digestive-diseases/acid-reflux-ger-gerd-children-teens/treatment>
114. Neumark-Sztainer DR, Wall MM, Haines JI, et al.: Shared risk and protective factors for overweight and disordered eating in adolescents, *Am J Prev Med* 33(5):359–369, 2007.

## 10

# Dental Caries in the Child and Adolescent

JUDITH R. CHIN, JOAN E. KOWOLIK, E. ANGELES MARTINEZ-MIER and JOSÉ LUIS UREÑA CIRETT

## CHAPTER OUTLINE

### Dentist's Role In Caries Risk Assessment

#### Etiology of Dental Caries

#### Early Childhood Caries

#### Severe Early Childhood Caries, Baby Bottle Tooth Decay

#### Additional Factors Known to Influence Dental Caries

Saliva

Socioeconomic Status

Anatomic Characteristics of the Teeth

Arrangement of the Teeth in the Arch

Presence of Dental Appliances and Restorations

Hereditary Factors

#### Early Detection of Disease

#### Activity

#### Prediction of Patients' Risk for Future Disease (Risk Assessment)

#### Care Pathways for Caries Management

Management of All Active Caries Lesions

Reduction in the Intake of Freely Fermentable Carbohydrates

Reduction of Dental Biofilm and Microorganisms with Good Oral Hygiene Procedures

### Use of Fluorides for Caries Prevention and Management

Community Water Fluoridation

Fluoride-Containing Dentifrices

Topical Fluorides in the Dental Office

Silver Diamine Fluoride (SDF)

Over-the-Counter Mouthrinses and Gels

Prescription Home-Use Fluoride

Mouthrinses, Toothpastes and Gels

Dietary Fluoride Supplements

Combinations of Fluoride Therapies

Enamel Fluorosis

### Other Preventive Therapies

Chlorhexidine and Thymol

Xylitol

Other Remineralizing or Antimicrobial Products

Caries Vaccine

Dental Caries Activity Test

### Diagnostic Tools

Infrared Laser Fluorescence (DIAGNOdent)

Digital Imaging Fiberoptic Transillumination

Quantitative Light Fluorescence

Conclusion

## Dentist's Role in Caries Risk Assessment and Management

Oral health is an integral component of general health. One of the strategies to achieve good oral health is to establish a dental home, which is defined as "the ongoing relationship between the dentist and team and the patient, inclusive of all aspects of oral health care delivered in a comprehensive, continuously accessible, coordinated, and family-centered way. Establishment of a dental home begins no later than 12 months of age and includes referral to dental specialists when appropriate."<sup>1,2</sup> Children should receive their first dental examination between 6 and 12 months of age or when the first tooth erupts

Although enjoying good oral health includes more than just having healthy teeth, many children have inadequate oral and general health because of active and uncontrolled

dental caries. Pitts and colleagues reported in 2019 that caries affects more than 600 million children worldwide and remains largely untreated. Caries has common risk factors associated with cardiovascular disease, diabetes and obesity.<sup>3</sup> Despite advances in the reduction of oral diseases, dental caries remains common among children worldwide, especially among underserved populations. Over the last 80 years, we have seen the meaning of oral health evolve from a narrow focus on teeth and gingiva to the recognition that the mouth is the center of vital tissues and functions that are critical to total health and well-being across the life span. Dental caries can negatively affect individuals' overall health and quality of life. While death as a direct result of dental caries remains rare, its presence does result in years lived with disability.<sup>4</sup> Dental caries is five times more common than asthma. These statistics continue and were reaffirmed by the United States Surgeon General's report in 2010.<sup>2</sup> Furthermore, as Edelstein and Douglass noted,

dental caries is not self-limiting, like the common cold, nor amenable to treatment with a simple course of antibiotics, like an ear infection.<sup>3</sup> Dental care is the most prevalent unmet health need among American children.<sup>2</sup> Although effective methods are known for prevention and management of dental disease, the unmet need for treatment, especially in children, does not seem to be diminishing.<sup>5</sup>

## Etiology of Dental Caries

Dental caries is a multifactorial disease. It is site specific and depends on the composition and metabolism of each site's biofilm.<sup>6</sup> Dental caries is influenced by multiple biological factors, including saliva, diet, anatomy, as well as genetic factors. At the individual and population levels, cultural, behavioral, and socioeconomic factors can also influence dental caries development.<sup>7</sup> Pitts and colleagues have described caries as a biofilm-mediated, sugar-driven, multifactorial process that results in demineralization.<sup>3</sup> The development of a caries lesion is the result of a continuous dynamic process involving repeating periods of demineralization by organic acids of microbial origin and subsequent remineralization by salivary components (and/or therapeutic agents), but in which the overall oral environment is unbalanced towards demineralization.

For many years, when microorganisms were only studied through culturing techniques, it was considered that the microbiological risk indicators for caries lesion initiation and progression were the transmission and presence of *Streptococcus mutans*, and the *Lactobacillus* species. This understanding has changed since the implementation of molecular microbiology techniques (PCR, Polymerase Chain Reaction technique, as well as sequencing with the gene16s rRNA). With the implementation of these new techniques, it has been possible to understand the complexity of the human microbiome.<sup>8</sup> The symbiosis between the microbiome and the host is essential to maintain general and oral health. Diseases related to imbalances between microorganisms and the host are known as dysbiosis; dental caries is one of them. The single factor that most commonly modifies the oral environment is the frequent consumption of carbohydrates, leading to acid production as an end result. Acid overproduction leads to a selection of and increase of acid-producing microorganisms (acidogenic), which, in turn, are acid-tolerant (acidophilic) and aciduric (produce acid under acidic conditions). Knowing the structure and functioning of the microbiome associated with dysbiosis is important in order to reverse this imbalance and obtain a state of equilibrium.<sup>9</sup>

For dental caries to develop, the presence of dental hard tissues in the oral environment, consumption of carbohydrates, and aciduric bacteria are required.<sup>7,10</sup> The saliva and the bacteria form a biofilm that adheres to the tooth surface. Over time, the presence of the carbohydrates serves as a nutrient for bacteria, and bacteria produce acids that can demineralize the tooth. The flow, dilution, buffering, and remineralizing capacity of saliva are also recognized to be critical factors that affect, and in some ways regulate, the progression and regression of the disease. If the oral environment is balanced and favorable, saliva can contribute to strengthen the tooth by supplying the components

known to help build a strong apatite structure. If the oral environment is unfavorable (too much acid is produced too often), an adequate flow of saliva can help dilute and buffer the acid, and thus slow the rate of progression of damage to the tooth or even repair it. The critical pH for dissolution of enamel has been shown to be about 5.5, where saliva normally has a pH of about 7.2. Once the process reaches dentin, dissolution can occur at a considerably higher pH.

Dental caries is a preventable disease; it begins in enamel or cementum and progresses slowly through cycles of demineralization and remineralization. Once the balance in these cycles is disrupted, and more demineralization events occur, an initial caries lesion develops. Cavitation of the tooth structure is a late-stage development of the disease process. Before cavitation, caries lesions may be remineralized if a favorable oral environment can be achieved. Even after cavitation occurs, if the pulp is not yet involved and if the cavitated area is open enough to be self-cleansing and for saliva to access it, the caries process can halt and the lesion can become arrested. Arrested lesions typically exhibit coronal destruction, but the remaining exposed dentin is hard and usually very dark, there is no evidence of pulpal damage, and the patient has no pain. We also must emphasize that treating a caries-affected tooth by providing a restoration does not cure the disease. If the unfavorable oral environment that caused the cavity persists, so will the disease, and more restorations will be required in time. Featherstone and colleagues have stated that: "it is recognized that in order to reduce the caries experience and try to maintain health will no longer solely depend on the development of cost-effective products or devices to target the biofilm and/or the tooth, but will require a series of effective behavioral modification and targeted approaches—including efforts to reduce sugar consumption—for ultimate success, and these will be based on the individual or community risks for dental caries"<sup>11</sup>

Many microorganisms can produce enough acid to demineralize tooth structure. The microorganisms associated with dental caries development and progression share acidogenic and acid-tolerant traits. Caries lesions studied with newer molecular biology techniques show that caries is a disease associated to poly microorganisms rather than a single one. As a matter of fact, the *Streptococcus mutans* species may be frequently observed in caries-free subjects and represents <1% of the total bacterial community observed in caries lesions.<sup>12</sup> The oral microbiome is individually unique and diverse, colonized by around 200 out of more than 700 different species. At this time, the study of microorganisms implicated in dental caries benefits from both culturing and molecular methods. Culturing bacteria requires specific media growth, temperature, presence of oxygen, among others, plus some species are difficult to grow. Molecular research may be complicated since some bacterial cells are difficult to break open for DNA to be released, sequenced, and classified. Even with newer technologies, gene expression understanding is limited.<sup>13</sup> At the moment, there are no tools available to describe the metabolic activity of biofilm and its interaction with enamel. Once established, the resident oral microbiota is fairly stable and may resist various environmental disturbances. The main stress factor that may alter this stability and promote dysbiosis is sugar ingestion. Other biological, social, and behavioral determinants such as age, diet, socioeconomic, lifestyle, and

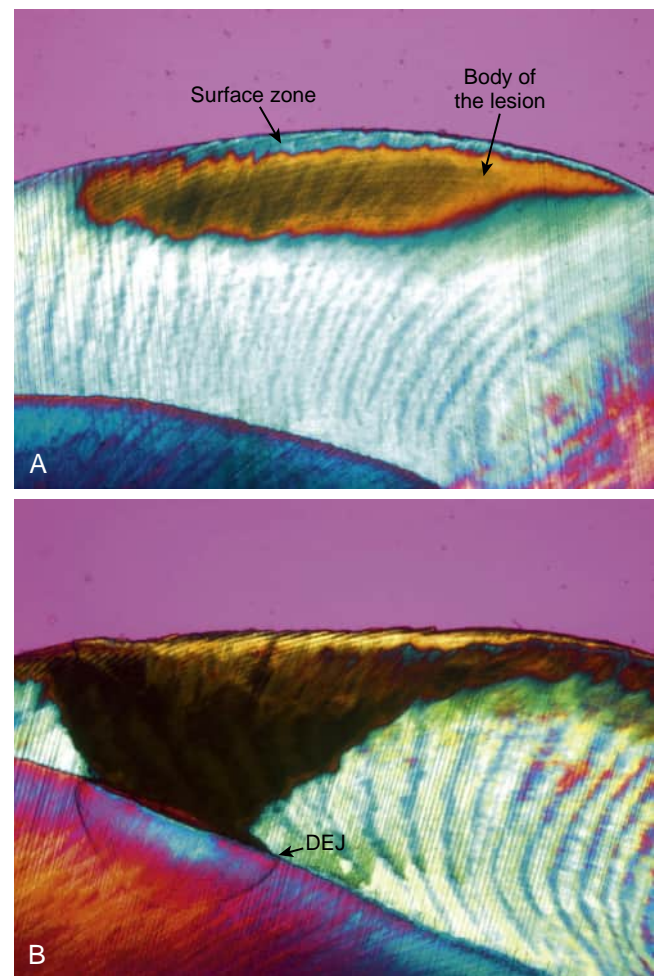


genetics have also been implicated. The FDI World Dental Federation has indicated that caries could be considered as a noncommunicable disease (NCD), sharing risk factors with many other NCDs, in particular overweight and diabetes. NCDs require patient and family involvement in order to become successfully managed.<sup>14</sup>

The use of molecular microbiology techniques has also allowed us to better understand the microbial diversity in the oral cavity. It is now understood that differences exist amongst the different sites and compartments in the oral cavity, with the largest number of species-level phylotypes being found in saliva. Recent data obtained via RNA techniques points out to the presence of 40 to 160 caries-related organisms in active caries lesions. These bacteria are not necessarily present in saliva. *Veillonella*, *Fusobacterium*, and *Porphyromonas* appear to be the most commonly genera in active caries lesions, with recent studies reporting *Candida albicans* playing a role as a secondary agent, especially in maintaining the progression of dentinal caries.<sup>15</sup> On the other hand, *Streptococcus*, *Neisseria*, and *Prevotella* are found in saliva. Alternatively, genera present in biofilm samples are similar to that of active caries lesions.<sup>16</sup>

The acids that initially demineralize the enamel have a pH of 5.5 to 5.2 or less and are formed in the biofilm material, which firmly attaches to the tooth structure. This biofilm, which exists primarily in biofilm accumulation sites on the teeth (i.e., occlusal and facial surfaces). Considerable emphasis is currently being given to biofilm thickness and site specific and microbiome, and its relationship to oral disease. The acids involved in the initiation of the caries process are normal metabolic byproducts of the microorganisms and are generated by the metabolism of carbohydrates. Because the outer surface of enamel is far more resistant to demineralization by acid than is the deeper portion of enamel, the greatest amount of demineralization occurs 10 to 15  $\mu\text{m}$  beneath the enamel surface (Fig. 10.1). The continuation of this process results in the formation of an incipient subsurface enamel lesion that is first observed clinically as a so-called white spot. Unless the demineralization is arrested or reversed (remineralization), the subsurface lesion continues to enlarge, with the eventual collapse of the thin surface layer and the formation of a cavitated lesion.<sup>17</sup>

Remineralization of incipient subsurface lesions may occur as long as the surface layer of the enamel remains intact. Saliva, which is supersaturated with calcium and phosphate and has acid-buffering capability, diffuses into biofilm, where it may help neutralize the microbial acids and repair the damaged enamel. The time required for remineralization to replace the hydroxyapatite lost during demineralization is determined by the age of the biofilm, the nature of the carbohydrate consumed, and the presence or absence of fluoride. For example, it has been suggested that, in the presence of a biofilm that has developed for 12 hours or less, the enamel demineralization resulting from a single exposure to sucrose will be remineralized by saliva within about 10 minutes. In contrast, a period of at least 4 hours is required for saliva to repair the damage to enamel resulting from a similar exposure to sucrose in the presence of dental biofilm that is 48 or more hours old. The presence of fluoride has a profound effect on the remineralization process; fluoride not only greatly enhances the rate



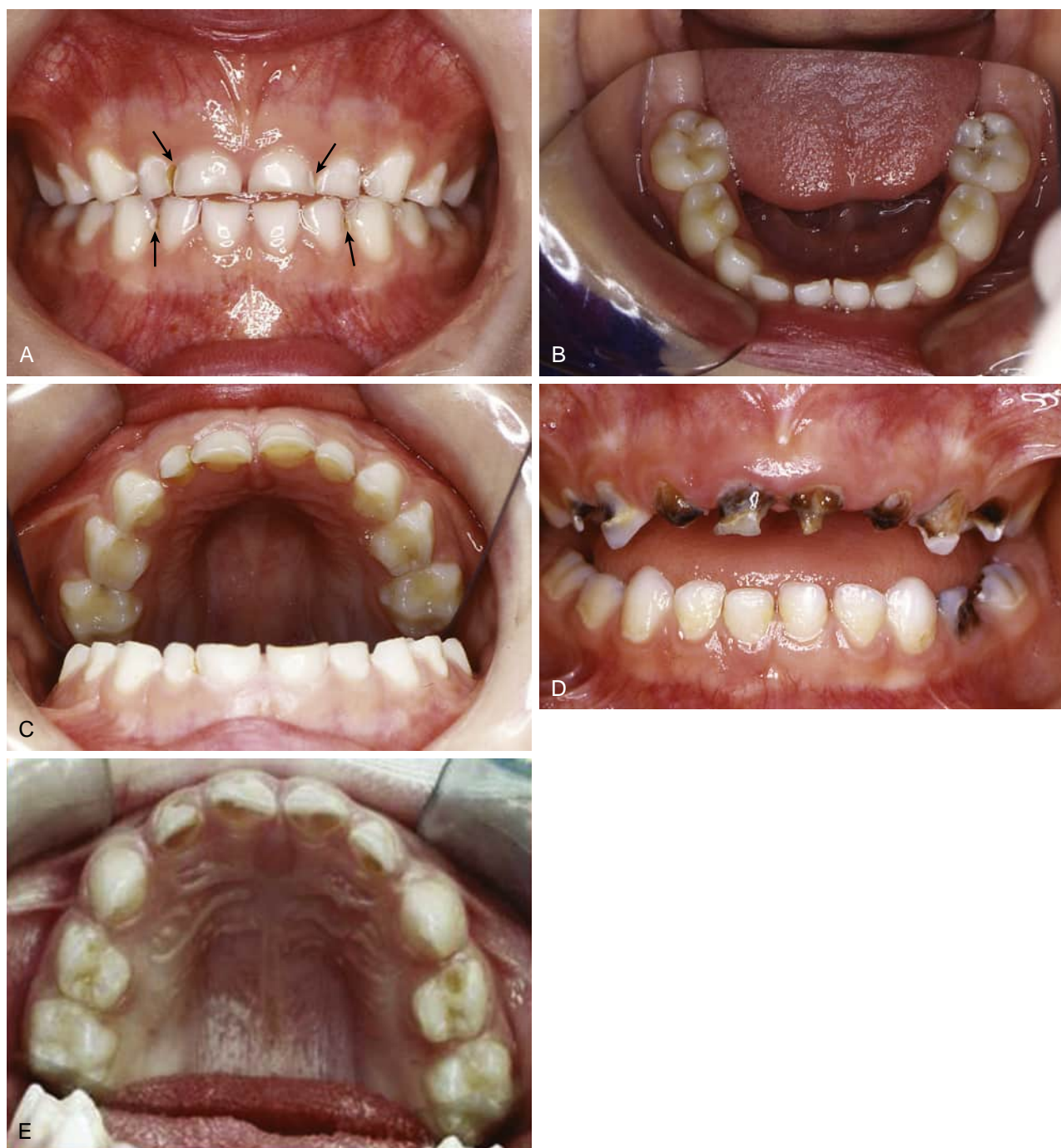**Fig. 10.1** Polarized light appearance of natural subsurface caries lesion. (A) Blue/green line represents surface zone; yellow/brown represents the most demineralized area, the body of the lesion. (B) More advanced natural subsurface lesion reaching the dentino-enamel junction (DEJ). This would be a white-spot lesion. (Courtesy Dr. James Wefel.)

of remineralization of enamel by saliva but also results in the formation of fluorohydroxyapatite during the process, which increases the resistance of the remineralized enamel to future attack by acids. Fluoride in higher concentrations also has antimicrobial effects.<sup>17</sup>

## Early Childhood Caries, Severe Early Childhood Caries, Baby Bottle Tooth Decay

Early childhood caries (ECC) is defined as “the presence of one or more decayed (non-cavitated or cavitated lesions), missing or filled (due to caries) surfaces, in any primary tooth of a child under six years of age.”<sup>3</sup> The American Academy of Pediatric Dentistry (AAPD) supports this definition of ECC. AAPD also specifies that, in children younger than 3 years of age, any sign of smooth-surface caries is indicative of severe early childhood caries (S-ECC).<sup>18</sup>

Research shows that human breastfeeding in infants has many advantages and has not been epidemiologically

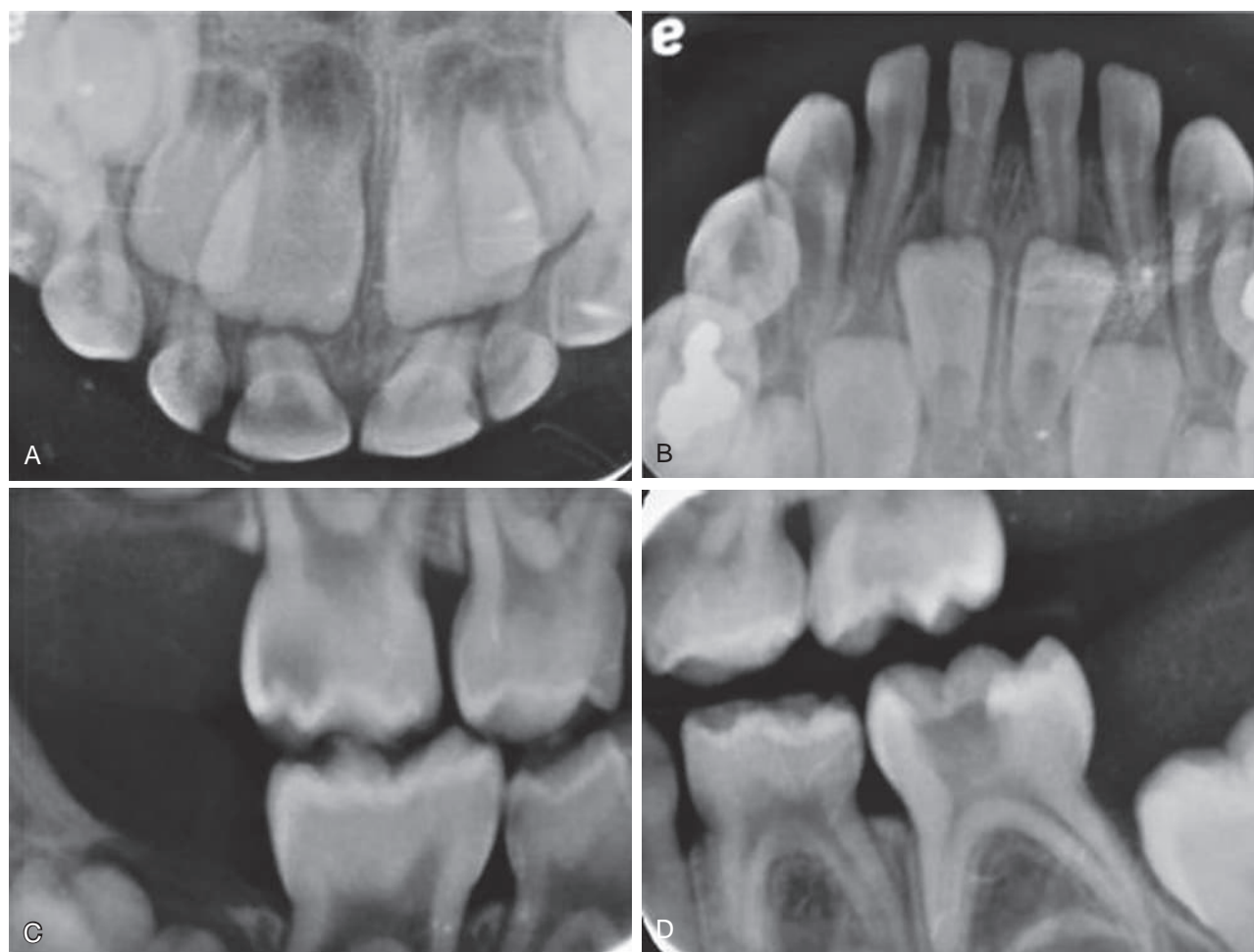


**Fig. 10.2** (A) Early childhood caries (ECC). (B) Occlusal ECC in mandible. (C) Occlusal and interproximal ECC in maxilla (mirror image). (D) Rampant dental caries and evidence of dental neglect in a preschool child. (E) Palatal caries on maxillary incisor teeth.

associated with caries in the absence of other factors such as poor oral hygiene or a carbohydrate diet. Breastfeeding in combination with other carbohydrates has been found *in vitro* to be highly cariogenic.<sup>19</sup> Frequent nighttime bottle feeding with milk is associated with, but not consistently implicated in, S-ECC. Breastfeeding more than seven times daily after 12 months of age is associated with increased risk for ECC.<sup>20,21</sup> Nighttime bottle feeding with juice, prolonged use of a sippy or no-spill cup, and frequent between-meal consumption of sugar-containing snacks or drinks (e.g., juice, formula, soda) will increase the risk of caries.<sup>22,23</sup> The

clinical appearance of the teeth in S-ECC in a child 2, 3, or 4 years of age is typical and follows a definite pattern.<sup>24,25</sup> There is early caries involvement of the maxillary anterior teeth, the maxillary and mandibular first primary molars, and sometimes the mandibular canines (Figs. 10.2 and 10.3). The mandibular incisors are usually unaffected. A discussion with parents often reveals an inappropriate feeding pattern: the child has been put to bed at afternoon nap time and/or at night with a bottle holding milk or a sugar-containing beverage. The child falls asleep, and the liquid becomes pooled around the teeth (the lower anterior teeth





**Fig. 10.3** Radiographs illustrating early childhood caries. (A) Maxillary incisors (interproximal). (B) Mandibular incisors. (C) Deep caries in mandibular molar. (D) Maxillary molar distally and on mandibular first molar.

tend to be protected by the tongue). The carbohydrate-containing liquid provides an excellent culture medium for acidogenic microorganisms. Salivary flow is also decreased during sleep, and clearance of the liquid from the oral cavity is slowed. Additionally human breastmilk is more cariogenic because it contains a higher percentage of lactose (7.5 g/100mL) than bovine milk (5 g/100mL).

AAPD endorses the policy statement of the American Academy of Pediatrics (AAP) on breastfeeding and the use of human milk.<sup>26</sup> The AAP statement includes the acknowledgment that “breast-feeding ensures the best possible health as well as the best development and psychosocial outcomes for the infant.” However, both organizations discourage extended or excessive frequency of feeding times (from the breast or bottle) and encourage appropriate oral hygiene measures for infants and toddlers.

There is considerable scientific evidence from experiments *in vitro* and in animal models to suggest that some dairy products such as bovine milk and cheese, as well as human breast milk, are not cariogenic and may actually be protective to tooth structure and promote remineralization under certain conditions. Similar experiments show that many infant formulas, with refined food additives, do promote caries. There is much still to learn about caries progression. Anticipatory guidance is essential for counseling parents to practice good oral hygiene measures for the child

and avoid inappropriate feeding habits that are associated with S-ECC.<sup>20</sup>

Studies in the United States report caries prevalence in children age 4 years and under as ranging from 38% to 49%.<sup>5,27</sup> In general, other reports of caries prevalence among children in various parts of the world show rates that seem to be comparable with those cited here. Another common element of caries prevalence in the United States and throughout the world is that children from families in low socioeconomic groups consistently have greater caries prevalence than their peers from families at a higher socioeconomic level. Higher caries prevalence has also been found in children who are of Hispanic or African American

In a longitudinal evaluation of caries patterns in 317 children followed up for an average of 7.8 years in private dental practices, Greenwell and colleagues made several noteworthy discoveries.<sup>28</sup> They found that 84% of the children who were caries-free in the primary dentition remained caries-free in the mixed dentition. Children with pit-and-fissure caries in the primary dentition were more likely to develop smooth-surface caries of primary teeth than were the caries-free children. Fifty-seven percent of the children with proximal lesions in primary molars in the primary dentition developed additional primary molar proximal lesions in the mixed dentition. Children with early childhood caries were at the highest



risk of any group for developing additional caries lesions. These investigators also discovered levels of caries susceptibility in children that can be characterized as caries-free, pit-and-fissure caries, and proximal molar caries patterns.

The report by Vargas and colleagues provides additional representative data for schoolchildren as well.<sup>29</sup> Their report revealed that 61% of the sample of children from 6 to 12 years of age had at least one decayed or filled primary tooth. Furthermore, in the sample of 4116 children from 6 to 14 years of age, 40% had at least one decayed or filled permanent tooth. Of the 1383 children from 15 to 18 years of age, 89.8% had at least one decayed or filled permanent tooth. This information, along with that in many other published reports, clearly indicates that managing the disease of dental caries among children remains a formidable task, despite the advances made in various preventive programs.

## Additional Factors Known to Influence Dental Caries

### SALIVA

Although saliva was identified in the etiology section earlier as part of the host component and thus a primary part of the caries process, the role of saliva overall is unique. Further discussion is warranted regarding its influence on several aspects of the caries process that may help produce favorable environments to combat the process. Any patient with a salivary deficiency, from any cause, is at a higher risk for caries activity.

Saliva, among other functions, protects enamel throughout life. Without saliva and the lack of its protective effects, severe caries lesions develop in surfaces usually not affected by caries. Saliva has caries preventive effects based on its different components. Different salivary parameters have been studied and correlated to dental caries such as microbiome dysbiosis, pH evaluation, buffer capacity, viscosity, and flow rate levels.<sup>30</sup> The preventive caries effects of saliva are different in the various stages of biofilm formation and within the demineralization–remineralization process. Pellicle formation includes electrostatic interactions between enamel and salivary proteins Proline Rich Proteins (PRPs), histatine, and statherin are absorbed into enamel, followed by complex protein-protein interactions. However thin, pellicle plays a role in the caries lesion initiation. It is the base for specific bacterial adhesion or repulsion. It also serves as a diffusion barrier to dietary acids and protects against demineralization, possibly by maintaining calcium and phosphate ions in proximity to enamel.<sup>31</sup> PRPs promote selective attachment of bacteria and differ between Caucasians and African Americans. Genetic differences in pellicle proteins could relate to bacterial colonization and probably help explain differences in caries indices among different races.<sup>32,33</sup> Different salivary proteins have been associated either with caries promotion or protection. Small sample size in the studies makes it difficult to determine a definite association.<sup>34,35</sup> A recent meta-analysis of case-control studies that explores salivary IgA levels in dental caries concludes that higher levels of IgA were observed

in patients with caries.<sup>36</sup> Results regarding salivary anti-bacterial peptides and other proteins like agglutinins, amylase, lactoferrin, and lysozyme, have been contradictory. Proteomics (the study of proteins) will give us further knowledge of the whole saliva proteome and will provide a deeper insight into the etiology of tooth decay at early stages. The study of salivary proteins could serve as potential indicators for diagnosis of early caries activity, caries risk assessment, and management, among other diagnostic capabilities.

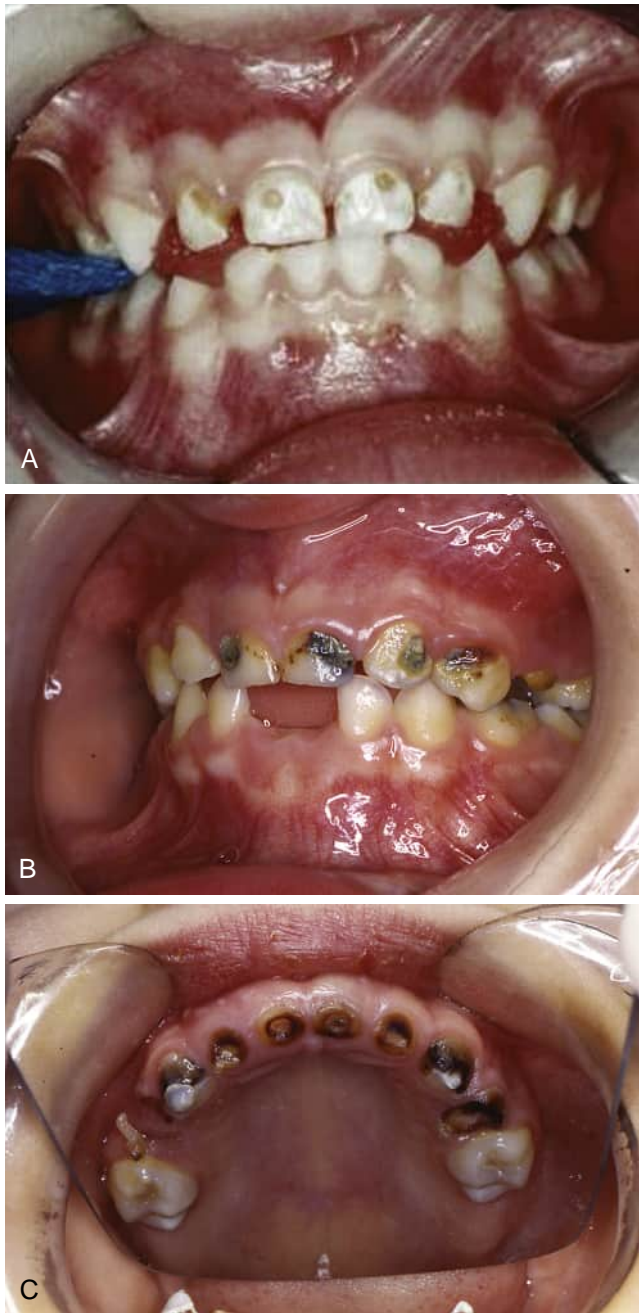
Saliva is secreted by three paired masses of cells—the submandibular, sublingual, and parotid glands. Small accessory glands are also scattered over the oral mucous membranes. Each of these has its own duct. The salivary glands are under the control of the autonomic (involuntary) nervous system, receiving fibers from both its parasympathetic and sympathetic divisions. Stimulation of either the parasympathetic (chorda tympani) fibers or the sympathetic fibers to the submandibular or sublingual gland causes a secretion of saliva. In most animals, the secretion resulting from parasympathetic stimulation is profuse and watery. Sympathetic stimulation, however, causes a scanty secretion of a thick, mucinous juice. Stimulation of the parasympathetic fibers to the parotid gland causes a profuse, watery secretion, but stimulation of the sympathetic fibers causes no secretion.<sup>17</sup>

### Salivary Deficiency

A reduction in the salivary flow may be temporary or permanent. When the quantity is only moderately reduced, the oral structures may appear normal. A pronounced reduction or complete absence of saliva, however, results in an acidic environment with caries (Fig. 10.4). In addition to the rapid destruction of the teeth, there may be dryness and cracking of the lips, with fissuring at the corners of the mouth, burning and soreness of the mucous membranes, crusting of the tongue and palate, and sometimes paresthesia of the tongue or mucous membranes.

There are many reasons for a reduction in salivary flow. Acquired salivary dysfunction may be the result of many different biological and psychological factors and may be either temporary or permanent. During the acute stages, mumps may cause a temporary reduction in salivary flow. Immune disorders, such as Sjögren's syndrome, and genetic conditions, such as hypohidrotic ectodermal dysplasia, often exhibit chronic xerostomia (dry mouth). Many oncology patients receive head and neck or total-body irradiation that also results in salivary gland dysfunction. Patients with deficient salivary flow often have active caries. In contrast, patients with greater than average salivary flow are usually relatively free from dental caries.<sup>37</sup>

If a patient has no known existing conditions that may cause hyposalivation, and if the clinician notices a small pool of saliva in the floor of the mouth during oral examination, it is not unreasonable to assume that the patient has adequate salivary quantity and flow. Little information is available about salivary flow rates in children, but Crossner reported that in children from 5 to 15 years of age, the rate of mixed whole stimulated saliva increases with age, and boys have consistently higher rates than girls.<sup>38</sup> Saliva substitutes, as well as fluoride and chlorhexidine rinses, are reported to enhance remineralization and promote



**Fig. 10.4** Progression of early childhood caries illustrated in three different children. (A) Restorable with resins. (B) Restorable with crown forms (possibly). (C) Nonrestorable.

resistance to demineralization of tooth surfaces, and may help prevent radiation-induced caries.<sup>37</sup>

### SOCIOECONOMIC STATUS

According to a report by the United States Census Bureau, in 2016, the poverty rate for children under age 18 was 18%—almost one in five children.<sup>39</sup> Children and adolescents living in poverty suffer twice as much tooth decay as their more affluent peers, and that their disease is more likely to go untreated.

Following the 2010 report of the surgeon general, Edelstein pointed out that paradoxically, children living in

poverty also have the highest rates of dental insurance coverage, largely through the Medicaid program and the state Children's Health Insurance Program.<sup>40</sup> Yet Medicaid-eligible children who have cavities have twice the number of caries-affected teeth and twice the number of visits for pain relief but fewer total dental visits than do children in families with higher incomes. He also noted that these disparities continue into adolescence and young adulthood, albeit to a lesser degree. Because practitioners have the opportunity to assess the oral health of poor children individually, they will identify some patients at low risk for dental caries. However, the available data confirm that, from a demographic perspective, economically poor children are at high risk for dental caries.

### ANATOMIC CHARACTERISTICS OF THE TEETH

Certain teeth of many patients, particularly permanent teeth, are vulnerable to dental caries development as they erupt, and, in caries-active mouths, they may show evidence of caries development almost coincident with their eruption into the oral cavity. Enamel undergoes a post-eruptive accumulation of fluoride after an acidic attack, becoming more caries resistant. Mineralization of the enamel is incomplete at the time of eruption of the teeth and an additional period of about 2 years is required for this process to be completed by exposure to saliva. The teeth are especially susceptible to caries formation during the first 2 years after eruption. Permanent molars often have incompletely coalesced pits and fissures with or without hypoplasia that allows the dental biofilm material to be retained at the base of the defect, sometimes in contact with exposed dentin. These defects or anatomic characteristics can readily be seen if the tooth is dried and the debris and biofilm removed. In addition to occlusal surfaces, lingual pits on the maxillary permanent molars, buccal pits on the mandibular permanent molars, and lingual pits on the maxillary permanent lateral incisors are vulnerable areas in which the process of dental caries may proceed rapidly.<sup>41</sup> Molar incisor hypomineralization (MIH) is a common developmental enamel defect characterized by asymmetrical distribution of hypomineralized demarcated opacities in first permanent molars and incisors. It is now generally accepted that it is a multifactorial genetic condition that modulates the individual's response to the different environmental insults. Severe hypomineralized enamel is not resistant to mastication forces and breakdowns easily upon eruption favoring aggressive caries development. Several reports indicate that severe/MIH permanent molars have a higher probability to develop fast-progressing caries lesions, regardless of socioeconomic status. However, the result of these studies is likely to be related to the participants' caries risk.<sup>42-45</sup>

### ARRANGMENT OF THE TEETH IN THE ARCH

Crowded and irregular teeth are not readily cleansed during the natural masticatory process. It is likewise difficult for the patient to clean the mouth properly with a toothbrush and floss if the teeth are crowded or overlapped. This condition therefore may contribute to the problem of dental caries.<sup>46</sup>



## PRESENCE OF DENTAL APPLIANCES AND RESTORATIONS

Space maintainers and orthodontic appliances often encourage the retention of food debris and biofilm and have been shown to result in an increase in the bacterial population.<sup>45,43</sup> Few patients keep their mouths meticulously clean, and even those who make an attempt may be hampered by the presence of dental appliances that retain biofilm between brushings. Rosenbloom and Tinanoff evaluated the MS levels of patients before, during, and after orthodontic treatment.<sup>47</sup> Microbial levels were significantly elevated during active treatment. When samples were taken 6 to 15 weeks into the retention phase of treatment, however, the microbial levels were found to have decreased significantly to levels comparable with those of untreated children.

Dentists have known for many years that the tooth structure at the interface with restorative material is especially vulnerable to recurrent caries. Clinical studies suggest that dentists and their patients should not expect successful restorative treatment to reduce a patient's risk for future development of caries lesions.

## HEREDITARY FACTORS

Although parents of children with active caries often have the perception that hereditary factors or tendencies are major factors in caries development, and some scientific evidence (as reviewed in [Chapter 6](#)) acknowledges certain genetic influences on the caries process, most evidence-based research demonstrates that genetic influences on dental caries are relatively minor in comparison with the overall effect of environmental factors. The fact that children acquire their dietary habits, oral hygiene habits, and oral microflora from their parents makes dental caries more an environmental than a hereditary disease. Although several hereditary factors (see [Chapter 6](#)) may be influential in promoting or preventing dental caries activity, available effective preventive therapies along with proper dietary and biofilm control measures can override the hereditary factors that contribute to caries development.

## Early Detection of Disease Activity

Current standards of care dictate that the detection of dental caries must be accomplished via visual and/or radiographic procedures, limiting tactile procedures to selected cases. These procedures involve the visual identification of demineralized areas (typically white spots). Caries lesions located on interproximal tooth surfaces have generally been detected with the use of bitewing radiographs. These procedures have been used routinely in virtually every dental office in the United States for the past 80 years. Our ability to reverse the caries process depends on the presence of an intact surface layer which may be disrupted by applying pressure. The use of the dental explorer to routinely probe enamel is, therefore, no longer recommended. Primary concerns that led to the discontinuation of the probing procedure were as follows: (1) The insertion of the explorer into the suspected lesion inevitably disrupts the surface layer covering very early lesions, thereby eliminating the

possibility for remineralization of the demineralized area; (2) The probing of lesions and suspected lesions results in the transport of cariogenic bacteria from one area to another; and (3) Frank lesions requiring restoration are generally apparent visually without the need for probing. The clinical caries detection procedures commonly used worldwide, the International Caries Classification and Management System (ICCMS), have been described by several clinical investigators.<sup>48-53</sup>

Caries lesions are detected visually on the basis of their location (demineralization can occur only in areas where dental biofilm may accumulate regularly) and the presence of enamel opacities with or without staining. The state of activity is determined of clean teeth dried with a gentle stream of compressed air for approximately 5 seconds. The visual appearance of an opacity (i.e. shiny versus chalky), the color of the area (i.e., presence of incipient caries “white-spot”), and the roughness of the enamel surface as assessed by dragging of the explorer parallel to the surface in question. Again, the only use of the dental explorer as a probe is to remove biofilm or debris from tooth surfaces.<sup>48</sup>

While this visual examination procedure for clinically detecting dental caries maintains the integrity of the enamel surface over the demineralized area and the possibility for the remineralization of the area, there remain some practical limitations to this caries detection procedure. The detection process requires the visual detection of demineralized areas of incipient caries or so-called white spots. First, these areas are relatively small, and tooth surfaces must be air-dried during the visual examination. By the time these areas can be detected visually as incipient caries, the demineralization will have progressed through at least one third of the outer portion of the enamel.<sup>54</sup> Mineralization of this magnitude requires longer time periods and a greater number of treatments to remineralize completely.

Lesions detected on radiographs have generally progressed to the outer one third of dentin. The increased desire of dental professionals and patients for more conservative restorative procedures and the implementation of measures to control and reverse the caries process led to significant efforts to develop technologies for the early detection of dental caries. Dental scientists have explored other measures to assist with the detection of caries at an earlier stage of the formation process, which resulted in the development and evaluation of a variety of instruments.<sup>49-52</sup>

## Prediction of Patients' Risk for Future Disease (Risk Assessment)

In contemporary health care practices, caries risk assessment and management are now recognized as an important component in providing appropriate dental care for infants, children, and adolescents. AAPD supports that appropriate oral health assessment should begin within 6 months of the eruption of the first tooth and certainly by the first birthday. This assessment should continue as appropriate by the same dentist and dental team providing the child with a dental home. With the very young infant, the caries risk focuses on the parents' and caregiver's oral health habits. The habits of parents and any other caregiver greatly influence the oral health of the child. These questions that help



**TABLE 10.1** Caries Risk Assessment Form for Children 6 Years Old or Younger

(FOR DENTAL PROVIDERS)			
Factors	High Risk	Moderate Risk	Low Risk
<b>BIOLOGICAL</b>			
Patient is of low socioeconomic status	Yes		
Patient has >3 between-meal sugar-containing snacks or beverages per day	Yes		
Patient has special health care needs		Yes	
Patient is a recent immigrant		Yes	
<b>PROTECTIVE</b>			
Patient receives optimally fluoridated drinking water			Yes
Patient brushes teeth daily with fluoridated toothpaste			Yes
Patient receives topical fluoride from health professional			Yes
Patient receives additional home measures (e.g., xylitol, MI paste, antimicrobial)			Yes
Patient has dental home/regular dental care			Yes
<b>CLINICAL FINDINGS</b>			
Patient has >1 interproximal lesions	Yes		
Patient has active white spot lesions or enamel defects	Yes		
Patient has low salivary flow	Yes		
Patient has defective restorations		Yes	
Patient is wearing an intraoral appliance		Yes	

Circling those conditions that apply to a specific patient helps the practitioner and patient/parent understand the factors that contribute to or protect from caries. Risk assessment categorization of low, moderate, or high is based on preponderance of factors for the individual. However, clinical judgment may justify the use of one factor (e.g.,  $\geq 1$  interproximal lesions, low salivary flow) in determining overall risk.

Overall assessment of the dental caries risk: High  Moderate  Low

From Council on Clinical Affairs: Guideline on Caries-risk Assessment and Management for Infants, Children, and Adolescents, American Academy of Pediatric Dentistry, Reference Manual 36(6), 127-134, 2014.

to start guide oral health education for the patient, including the following questions<sup>1</sup>:

1. When did they last have dental care and treatment?
2. What are their eating habits of consumption of sugar-containing beverages and snacks??
3. What is the duration of consumption of sugar-containing beverages and food? How long does it take the patient to eat?
4. How often do they brush and floss their teeth?

Education and training required to achieve optimal oral health must be provided to adults who care for the child. Only once the child has grown and has achieved the required dexterity for proper oral hygiene should the patient have more input into his/her eating and toothbrushing habits.

In 2003, Petersson reported the complex nature of dental caries and the difficulties in predicting the development of the disease in any one patient.<sup>50-55</sup> Over the years, these difficulties have not decreased but are better understood. There are several tools for predicting dental caries development. In 2012, Tellez conducted a systematic review of caries risk assessment tools and concluded, "There is an urgent need to develop valid and reliable methods for caries risk assessment that are based on best evidence for prediction and disease epidemiology management rather than opinions of experts." In this review the four most commonly used caries risk assessment tools were reviewed (Cariogram, Caries Management by Risk Assessment [CAMBRA], American Dental Association, and the American Academy of Pediatric Dentistry) and were found to be of equal value.<sup>51</sup> The "Cariogram" is a computer caries

risk program that records several data points, including past caries experience, diet, oral hygiene habits, fluoride exposures, and analysis of saliva. The pictorial presentation with the associated personal plan may be good for patients or parents, although students in this study did not support the usefulness of the tool in the academic setting. The Cariogram has been validated in several clinical studies and has been demonstrated to be successful in predicting caries risk. While assessment of caries risk undoubtedly is benefiting from emerging science and technologies, AAPD believes that sufficient evidence exists to support the creation of a framework for classifying caries risk in infants, children, and adolescents based on a set of physical, environmental, and general health factors. It has also been documented that the caries risk tools commonly used for adults do not support future risk for children.<sup>51-53</sup> AAPD has published guidelines on caries risk assessment and management and the caries risk assessment tool (CAT) (Tables 10.1 and 10.2).

Of course, accurate caries risk assessments of patients can guide clinicians and health care facilities toward better allocation of their time and resources for their high-risk patients. Accuracy and efficiency in identifying patients with active disease or high potential to develop disease improve is important. Parents, patients, and health care insurance plans will then accept this newer approach to care. The standard "6-month recall visit" for children may change to a more customized plan for individual patients or groups of patients. Children who are at low risk for caries and who do not have other oral conditions that need frequent monitoring may not require oral health care visits as often as those at high risk (with or without active disease),

**TABLE 10.2** Example of a Caries Management Protocol for Children 6 Years Old or Younger

Risk Category	Diagnostics	Interventions			
		Fluoride	Diet	Sealants	Restorative
<b>Low risk:</b>	<ul style="list-style-type: none"> <li>Recall every 6 to 12 months</li> <li>Radiographs every 12 to 24 months</li> </ul>	<ul style="list-style-type: none"> <li>Twice-daily brushing with fluoridated toothpaste <sup>μ</sup></li> </ul>	No	Yes	<ul style="list-style-type: none"> <li>Surveillance <sup>χ</sup></li> </ul>
<b>Moderate risk:</b> patient/parent engaged	<ul style="list-style-type: none"> <li>Recall every 6 months</li> <li>Radiographs every 6 to 12 months</li> </ul>	<ul style="list-style-type: none"> <li>Twice-daily brushing with fluoridated toothpaste <sup>μ</sup></li> <li>Fluoride supplements <sup>δ</sup></li> <li>Professional topical treatment every 6 months</li> </ul>	<ul style="list-style-type: none"> <li>Counseling</li> </ul>	Yes	<ul style="list-style-type: none"> <li>Active surveillance <sup>ε</sup> of incipient lesions</li> <li>Restoration of cavitated or enlarging lesions</li> </ul>
<b>Moderate risk:</b> patient/parent not engaged	<ul style="list-style-type: none"> <li>Recall every 6 months</li> <li>Radiographs every 6 to 12 months</li> </ul>	<ul style="list-style-type: none"> <li>Twice-daily brushing with toothpaste <sup>μ</sup></li> <li>Professional topical treatment every 6 months</li> </ul>	<ul style="list-style-type: none"> <li>Counseling, with limited expectations</li> </ul>	Yes	<ul style="list-style-type: none"> <li>Active surveillance <sup>ε</sup> of incipient lesions</li> <li>Restoration of cavitated or enlarging lesions</li> </ul>
<b>High risk:</b> patient/parent engaged	<ul style="list-style-type: none"> <li>Recall every 3 months</li> <li>Radiographs every 6 months</li> </ul>	<ul style="list-style-type: none"> <li>Brushing with 0.5 percent fluoride</li> <li>Fluoride supplements <sup>δ</sup></li> <li>Professional topical treatment every 3 months</li> </ul>	<ul style="list-style-type: none"> <li>Counseling</li> <li>Xylitol</li> </ul>	Yes	<ul style="list-style-type: none"> <li>Active surveillance <sup>ε</sup> of incipient lesions</li> <li>Restoration of cavitated or enlarging lesions</li> </ul>
<b>High risk:</b> patient/parent not engaged	<ul style="list-style-type: none"> <li>Recall every 3 months</li> <li>Radiographs every 6 months</li> </ul>	<ul style="list-style-type: none"> <li>Brushing with 0.5 percent fluoride</li> <li>Professional topical treatment every 3 months</li> </ul>	<ul style="list-style-type: none"> <li>Counseling, with limited expectations</li> <li>Xylitol</li> </ul>	Yes	<ul style="list-style-type: none"> <li>Restore incipient, cavitated, or enlarging lesions</li> </ul>

<sup>α</sup>, Salivary mutans streptococci bacterial levels; <sup>φ</sup>, interim therapeutic restoration; <sup>γ</sup>, parental supervision of a "pea-sized" amount of toothpaste; <sup>β</sup>, parental supervision of a "smear" amount of toothpaste; <sup>λ</sup>, indicated for teeth with deep fissure anatomy or developmental defects;

<sup>χ</sup> periodic monitoring for signs of caries progression;

<sup>δ</sup> need to consider fluoride levels in drinking water;

<sup>ε</sup> careful monitoring of caries progression and prevention program;

<sup>μ</sup> less concern about the quantity of toothpaste.

From Council on Clinical Affairs: Guideline on Caries-risk Assessment and Management for Infants, Children, and Adolescents, American Academy of Pediatric Dentistry, Reference Manual 36(6), 127-134, 2014.

whereas compliant high-risk patients may, at times, require frequent visits and multiple forms of caries control therapies in addition to their voluntary modification of caries-promoting dietary and behavioral habits.

## Care Pathways for Caries Management

Many practical measures for the control of caries are applicable to private practice. Caries risk assessment and management protocols, also called care pathways, assist practitioners with decisions regarding treatment based on a child's age, caries risk and compliance. Most practitioners have tried control measures with various degrees of success. One cannot emphasize too strongly, however, that no single measure for the control of caries will be entirely satisfactory. All possible preventive measures and approaches must be considered in the hope of successfully controlling and preventing the caries process. None of these preventive approaches can have any hope for success without the regular and full cooperation and commitment from the caregiver and patient along with home-care vigilance.

### MANAGEMENT OF ALL ACTIVE CARIES LESIONS

When active caries occurs, the first steps are to initiate treatment of all caries lesions to stop or at least slow the progression of the disease and to identify the most important causes of the

existing condition. Next, or even simultaneously, if possible, the practitioner begins working with the patient and/or parents to achieve appropriate behavioral modifications required to prevent recurrence. The problem may then be approached in a systematic manner. Invariably, modifications in oral hygiene procedures and dietary habits are necessary. Often, achieving caregiver and patient compliance with the recommended modifications is the greatest challenge of all.

### REDUCTION OF THE INTAKE OF FREELY FERMENTABLE CARBOHYDRATES

Excellent studies have shown a relationship between diet and dental caries. As a result of these studies, considerable emphasis has been placed on this phase of the caries control program. There is also much evidence to confirm that between-meal snacking and the frequency of eating and drinking are related to dental caries incidence. As mentioned earlier, sweetened liquids provided to young children in nursing bottles can have enormous cariogenic potential. Likewise, carbonated soft drinks, juices, sweetened drinks, and energy drinks are popular with older children and adolescents and are readily available. Frequent ingestion of these drinks is another form of snacking that can promote and accelerate caries progression.<sup>54-57</sup>

The pH of saliva is traditionally ~7.2, which aids in buffering the individual's response to acidic challenges. Investigations by Schachtele and Jensen<sup>56</sup> and by Park and colleagues<sup>57</sup> have indicated that the acidity of biofilm

located in interproximal areas, which generally have less exposure to saliva, may remain below the critical pH for periods in excess of 2 hours after carbohydrate ingestion. Because foods containing sugars in solution and retentive sugars are included in the dietary analysis, 20 minutes may be considered the minimal time each exposure permits acid concentrations to be available in the bacterial biofilm. If the initial restorative treatment is to be done in one appointment with the patient under general anesthesia or in one or two appointments with sedation, control of the existing lesions will be definitive at that time. If the restorative care is to be performed over several visits in the outpatient setting, other options, such as silver diamine fluoride (SDF) or gross caries excavation, may be considered as an initial approach in the control of active dental caries have several advantages.

### REDUCTION OF DENTAL BIOFILM (AND MICROORGANISMS) WITH GOOD ORAL HYGIENE PROCEDURES

Chapter 8 discusses the importance of good oral hygiene in more detail, but it must be mentioned here as a critically important component of any caries management program.<sup>58</sup> The investigators concluded that constant reinforcement is necessary to maintain effective biofilm control in preschool children.<sup>59</sup>

Wright and colleagues conducted a clinical study to evaluate the effect of frequent interdental flossing on the incidence of proximal dental caries.<sup>60</sup> Schoolchildren from a fluoride-deficient area were studied after clinical and radiographic examinations were performed. Based on the observations of this study, the authors concluded that frequent interdental flossing resulted in a 50% reduction in the incidence of proximal caries in primary teeth during a 20-month period. The longer the period of interdental flossing, the greater the benefit; however, there was little residual effect after flossing was discontinued.

### USE OF FLUORIDES FOR CARIES PREVENTION AND MANAGEMENT

Without doubt, the repeated use of fluorides is of critical importance for the control and prevention of dental caries in both children and adults. Numerous controlled clinical investigations have consistently demonstrated the cariostatic properties of fluoride provided in a variety of forms. As a topically applied therapeutic agent, fluoride is effective in preventing future lesion development, in arresting and slowing the progression of active cavitated lesions, and in remineralizing active incipient lesions. Topical fluoride also has some antimicrobial properties.<sup>61</sup>

Existing evidence indicates that the cariostatic activity of fluoride involves several different mechanisms, but that it is mainly topical. It is incorporated into the enamel of newly erupted teeth, thereby enhancing enamel mineralization (frequently called *enamel maturation*), which decreases caries susceptibility. The exposure of the teeth to fluoride through professional application of fluoride varnishes, gels, foams, and solutions, in addition to exposure from dentifrices, engages almost all of the foregoing mechanisms except the pre-eruptive incorporation into enamel.

Numerous studies have shown that the presence of fluoride greatly enhances the rate of remineralization of demineralized enamel and dentin. Moreover, tooth structure remineralized in the presence of fluoride contains increased concentrations of fluorohydroxyapatite, which makes the remineralized tissue more resistant to future attack by acids than was the original structure. In view of fluoride's multiple mechanisms of action, it is not surprising that treatment with fluoride through multiple delivery systems has additive benefits. This supports the recommendation that frequent exposure to fluoride is beneficial for maximal caries prevention and control.

### Community Water Fluoridation

Research studies continue to support fluoridation of the community water supply as an effective method of reducing the dental caries problem in the general population.<sup>62</sup> Water fluoridation is widely accepted, reaching over 370 million people in 27 countries, and is accepted as safe and effective with the exception of dental enamel fluorosis as a possible side effect. Salt fluoridation is commonly used in Latin American and Europe. Historical clinical trials demonstrate that salt fluoridation is effective in preventing caries.<sup>63-65</sup>

Murray reviewed 113 studies conducted in 23 countries to help clarify various reports on the benefits to primary teeth of communal water fluoridation.<sup>66</sup> A thorough review of the data clearly showed that water fluoridation provides protection for primary teeth against dental caries but to a somewhat lesser degree for permanent teeth. The caries reduction benefits to primary teeth ranged between 40% and 50%, whereas the range for permanent teeth was between 50% and 60%.

Carmichael and colleagues<sup>67</sup> and Rock and colleagues<sup>68</sup> have reported data in separate studies comparing the caries incidence in children living in two fluoridated communities with that in children living in two non-fluoridated communities in England. The role of fluoridation in reducing dental caries is clear in both studies. The study by Carmichael and colleagues also demonstrated that children in lower social classes gain an even greater caries-preventive benefit than children in higher social classes. The reason is that, as a group, the children in the lower social classes have a higher prevalence of caries.

The protection afforded by the ingestion of fluoridated water benefits both children and adults. Several studies have shown that the continuous exposure to fluoridated water during adulthood decreases the prevalence of dental caries by about the same magnitude as that observed in children.<sup>62</sup>

The posteruptive benefits associated with the ingestion of fluoridated water have been demonstrated. The posteruptive ingestion of fluoridated water can result in decreases in caries prevalence up to 30%.<sup>62</sup> The halo effect of fluoride benefits is associated with the preparation of numerous foods and beverages in fluoridated communities and their consumption in non fluoridated communities. Reports have attempted to quantify this halo effect by measuring the fluoride intake of children residing in communities that do not have a fluoridated communal water supply, and have shown that fluoride ingestion is nearly 70% of that by residents of optimally fluoridated communities.<sup>69,70</sup> Thus it is not surprising



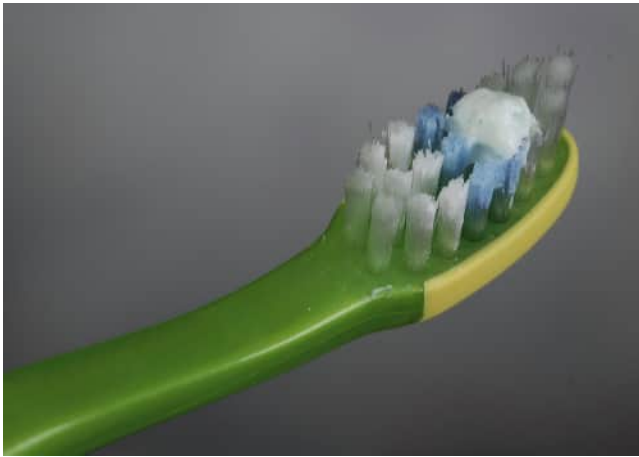

Fig. 10.5 Toothbrush with pea-sized amount of toothpaste.

that only modest differences in caries prevalence rates are noted between children residing in fluoridated and non fluoridated communities. When fluoridation is discontinued in a community, an increase in the dental caries incidence follows.

In 2013, Melbye reported that community fluoridated water in the United States reached 64% for the total population and 72% of the population had access to public water systems. Considerable variation exists to fluoridated water across the United States, ranging from 100% of residents in the District of Columbia to only 10% of residents in Hawaii. The average annual cost of fluoridating communal water supplies was approximately \$0.50 per person.<sup>63</sup> The annual cost varied with the size of the community, ranging from approximately \$3.70 per person in very small communities to as low as \$0.50 per person in larger metropolitan areas. Communal water fluoridation remains by far the most cost-effective caries-preventive measure available.<sup>62</sup> In 2001, the Task Force on Community Preventive Services of the CDC strongly recommended community water fluoridation and school-based or school-linked pit-and-fissure sealant delivery programs for the prevention and control of dental caries.<sup>71</sup>

### Fluoride-Containing Dentifrices

Extensive research initiated in the early 1950s ultimately resulted in the identification of the first fluoride-containing dentifrice (Crest; Procter & Gamble, Cincinnati, Ohio, USA) capable of decreasing the incidence of dental caries. This dentifrice contained stannous fluoride ( $\text{SnF}_2$ ) in combination with calcium pyrophosphate as the cleaning and polishing system. In 1964, based on more than 20 clinical trials, it was accepted by the Council on Dental Therapeutics of the American Dental Association (ADA) as the first therapeutic dentifrice. The significance of this original development has been profound. Meta-analyses of more than 70 randomized or quasi randomized controlled clinical trials have shown that fluoride toothpaste is efficacious in reducing the prevalence of dental caries in permanent teeth. The effect was increased in children with higher baseline levels of caries who used a higher concentration of fluoride in the toothpaste, had greater frequency of use, and brushed under supervision.<sup>72</sup>

Caregivers should be counseled based on the child's age and caries risk status.<sup>61</sup> A smear of fluoridated toothpaste for children less than 2 years of age at increased risk for dental caries may decrease risk of fluorosis. A "pea-sized" amount of toothpaste is appropriate for children with moderate to high caries risk aged three and above (Fig. 10.5).<sup>73,74</sup> Several systematic reviews including one Cochrane review from 2010 have reported that fluoride containing dentifrice less than 1000 ppm is not as effective in preventing caries. The recommendation for any patient is to use a toothpaste that contains at least 1000 ppm fluoride. Any decision to use fluoridated toothpaste for children under 6 years old should take into account the caries risk status of the patient balanced with the risk of enamel fluorosis.<sup>75,76</sup> Another Cochrane review from 2003 found that the effect of fluoride toothpaste increases with higher frequency of use. Children should brush twice a day.<sup>77</sup>

Before 1981, attempts to identify a fluoride dentifrice system significantly more effective than the original stannous fluoride formulation were unsuccessful. However, in 1981, the results of two clinical studies demonstrated the superiority of a sodium fluoride composition.<sup>72,78</sup> A 3-year clinical study was conducted by Beiswanger and colleagues<sup>72</sup> to determine the effect of a sodium fluoride-silica abrasive dentifrice on dental caries. The dentifrice, containing 0.243% sodium fluoride, was compared with stannous fluoride in a study group of 1824 schoolchildren from 6 to 14 years of age where water supplies were fluoride deficient (containing less than 0.35 ppm fluoride). After 3 years, the group brushing with the sodium fluoride dentifrice had significantly lower DMFT and DMFS increments than did the group brushing with the stannous fluoride dentifrice. Two independent examiners found that the reductions were 14.8% and 10.5% for DMFT and 16.4% and 13.1% for DMFS. These results are consistent with those reported by Zacherl in which the sodium fluoride dentifrice resulted in a 40.7% decrease in DMFS, compared with a 23.4% decrease observed with the stannous fluoride dentifrice.<sup>78</sup> Similarly, studies conducted by Gerdin<sup>79</sup> and by Edlund and Koch<sup>80</sup> indicated that the use of sodium fluoride dentifrices by children resulted in significantly less caries than the use of dentifrices containing sodium monofluorophosphate.

### Topical Fluorides in the Dental Office

Fluoride-containing varnishes have been widely used worldwide for approximately 40 years but were not available in the United States until 1994. The first fluoride varnish was introduced in Europe in 1964 and contained 5.0% sodium fluoride (or 2.26% fluoride, equivalent to 22,600 ppm). A second product was introduced in Europe in 1975 and contained 0.9% silane fluoride (or 0.1% fluoride). Much more research has been conducted on the sodium fluoride system, and it is the most widely accepted.

Weyant,<sup>81</sup> Gao,<sup>82</sup> and Ijaz and colleagues<sup>83</sup> have reviewed the numerous controlled clinical trials of fluoride varnishes and concluded that these materials are equally as effective as professional topical fluoride applications for the prevention of dental caries in children. Gao<sup>82</sup> performed a meta-analysis of the data from several clinical trials and found that use of the sodium fluoride varnish resulted in an overall remineralization of enamel caries of 64% in caries of the teeth.<sup>84</sup>

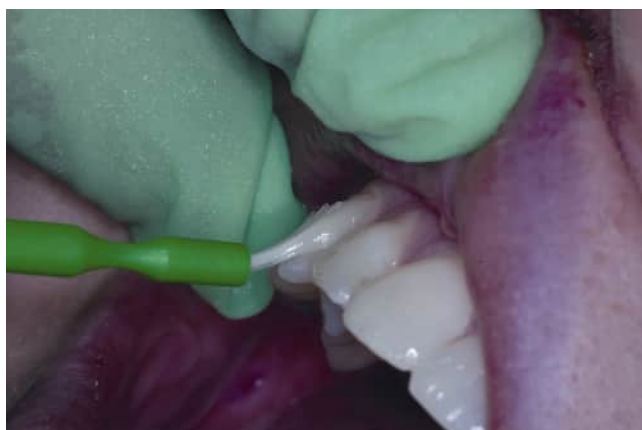

Fig. 10.6 Application of white fluoride varnish.

The periodic professional topical application of more concentrated fluoride solutions, gels, foams, or varnishes has been repeatedly demonstrated to result in a significant reduction in the incidence of dental caries in both children and adults, as well as in the arrest of incipient lesions.<sup>81</sup> As a result, professional topical fluoride applications are recommended for all children and adolescents at moderate to high caries risk. Even in the absence of dental caries activity, topical fluoride applications for children are recommended as a means of raising the fluoride content of the enamel of newly erupted teeth, thereby increasing the resistance of these teeth to caries formation. Hundreds of publications confirm the efficacy of professionally applied topical fluoride treatments for caries prevention.<sup>81</sup>

A 4-minute treatment time has been typically recommended for professionally applied topical fluoride solutions, gels, or foams. They are less effective than fluoride varnish.<sup>81</sup> Some manufacturers recommend only a 1-minute application. Most of the fluoride uptake in the enamel occurs during the first minute after application. However, measurable benefits do continue to accrue for approximately 4 minutes if the topical preparation remains in contact with the teeth. Therefore, the 4-minute application is recommended whenever possible. Several investigators have expressed concern regarding the amount of fluoride foam or gel swallowed by children during a topical fluoride application.<sup>85,86</sup> These reports indicated that, depending on the manner of application, 15 to 31 mg of fluoride may be swallowed during the treatment. The patient should be encouraged not to eat, drink, or rinse for 30 minutes after the treatment to maximize fluoride uptake in enamel. If gel or foam is applied with a tray technique, the trays should be about one-third full for gel and one-half full for foam. The patient sits in an upright position with his/her head tipped slightly forward to allow excess saliva and fluoride to flow toward the lips. With a saliva ejector inside the patient's mouth, the tip is moved to help control drooling and the swallowing of fluoride. The dentist or appropriate office staff should supervise the treatment and provide assistance as needed.

The results of independent clinical trials have raised serious questions about the need for dental prophylaxis before the topical application of fluoride.<sup>87</sup> Caries increments after several years were essentially identical in all the treatment

groups, indicating that the manner of cleaning the teeth before the fluoride treatment may not influence the cariostatic activity of the fluoride applications.<sup>88,89</sup> Collectively these studies indicate that prophylaxis before a topical fluoride application is an optional procedure with regard to caries reduction.

The sodium fluoride varnish (Fig. 10.6) is particularly recommended for use in children because of its ease of application and equal efficacy to APF systems.<sup>90</sup> Varnish is applied with a soft brush, with reapplications recommended at 3- to 6-month intervals, depending on caries risk assessment. A more intensive annual treatment regimen consisting of 3 applications within a 10-day period was investigated and was observed to be as effective as applications every 4 months.<sup>91-93</sup> Furthermore, single annual applications have been found to be without clinical benefit. Because less than a milliliter of varnish is used for a professional treatment in children, the amount of fluoride that will ultimately be ingested when the varnish is lost from the tooth surfaces is less than 3 mg. Thus there are no practical concerns regarding safety, and this procedure is frequently recommended for use in children in place of the traditional topical fluoride gel application.

### Silver Diamine Fluoride

Silver compounds have been used as antimicrobials for over 40 years in a variety of forms. Clinical data indicates that 38% silver diamine fluoride (SDF) may be considered for the non surgical management of dental caries.<sup>94,95</sup> It consists of 44,000 parts per million of fluoride. SDF was approved for use by the Food and Drug Administration (FDA) as a desensitizing agent in the United States in 2014 (Advantage Arrest, Elevate Oral Care, West Palm Beach, FL, United States). The approval of SDF by the FDA as a desensitizing agent is the same as fluoride varnish. SDF has a pH of 10 and is marketed both as a tinted or colorless liquid. The mechanism of action is not fully understood. Current research theorizes fluoride ions act mainly on the tooth structure, while silver ions are antimicrobial. Additionally, SDF is thought to react with hydroxyapatite in its alkaline pH to form calcium fluoride and silver phosphate as major reaction products. Calcium fluoride then forms fluorapatite, which is less soluble than hydroxyapatite in an acidic environment.<sup>96,97</sup>

Most evidence-based research suggests the chemical reaction is  $\text{Ca}_{10}(\text{PO}_4)_6(\text{OH})_2 + \text{Ag}(\text{NH}_3)_2\text{F} + \text{CaF}_2 + \text{Ag}_3\text{PO}_4 + \text{NH}_4\text{OH}$ .<sup>94,98</sup>

Many clinical trials have evaluated SDF on prevention and caries arrest.<sup>94,95</sup> Studies consistently conclude that SDF is more effective for arresting caries than fluoride varnish. Based on the clinical data, the use of SDF may arrest select caries lesions up to 80% of the time.<sup>94,95</sup> SDF alone does not reduce adhesion of restorative materials, but in particular resin or glass ionomer restorative products. The FDA approved the use of a second SDF material as a desensitizing agent that contains potassium iodide in the United States in 2018 (Riva Star, SDI Limited, Bayswater, Victoria, Australia). Products with SDF and potassium iodide have shown some caries arrest but not to the same extent and have reducing bonding ability of restorative materials.<sup>99,100</sup> Additionally, these products have not been recommended for use on a patient under the age of 21 years old and has longer chairside application times.

Case selection is important. Caries dentist removal prior to SDF application is not necessary. Patients who may benefit the most are patients who may exhibit uncooperative or preoperative behavior to dental treatment; or for whom alternative treatment options are not possible due to medical or financial reasons; or who have limited access to care or have special health care needs. Teeth to be treated should not show signs of pulpal inflammation or unsolicited pain, as the treatment does not manage pulpal inflammation. Treatment can be used for a variety of indications, including caries control or definitive caries lesion management. SDF should not be used on patients who have ulcerative gingivitis, stomatitis or known allergy to silver. Caries lesions on any surface can be treated as long as they are accessible with a brush for applying the SDF. Orthodontic separators, wedges, and thick floss have been used to help gain access to proximal lesions. For large proximal lesions, it may be desirable to treat the lesions with SDF prior to placing a protective restoration as part of caries control therapy. Both anterior and posterior primary and posterior teeth can be treated.<sup>94,101</sup>

Inclusion criteria for caries management with SDF are cavitated dental caries that may extend to dentin. Caries should not be in close proximity to the dental pulp based on clinical and/or radiographic findings. The patient also should not have spontaneous or elicited pain associated with the caries lesion that is to be treated. Caries arrest may take up to 2 weeks to develop so active surveillance by a dental health care provider is recommended.<sup>94</sup>

Patients and parents should be advised regarding the black staining of the lesions associated with the application of silver products. Before-and-after clinical photographs may be shown as part of gaining informed consent for this procedure. Soft tissue, countertops, clothes, and other materials also will stain black. Soft tissue staining will fade as the mucosa or skin cells turn over and are replaced.

The application of SDF involves barrier protection of all surface countertops and the use of a patient napkin to reduce staining. Placing a lubricant such as cocoa butter on the lips and liberally around the perioral area should reduce accidental staining. To reduce the risk of silver toxicity, the recommendation for pediatric patients is to treat no more than 5 teeth for a total of only one drop per appointment. If additional teeth require SDF, a reappointment for 2 weeks later to minimize silver ion exposure is recommended. The tooth or teeth to be treated are isolated with cotton rolls or another appropriate isolation method. The minimum amount of SDF should be applied to the cavitated tooth surface to prevent contamination of adjacent surfaces and swallowing of the material. Careful application with a microbrush should be adequate to prevent intraoral and extraoral soft tissue exposure. Contact with the lips or skin causes a rapid red-brown discoloration that may take several weeks to disappear as the stained cells are replaced. The tooth is dried with compressed air and the SDF solution is placed directly on the caries lesion for 2-3 minutes if possible. Do not light cure SDF to speed up the caries arrest process. Light curing SDF will only rapidly precipitate the silver ions from SDF, which will then reduce the depth and efficacy of caries arrest. Application time will likely be shorter in very young and difficult to manage patients. Teeth treated with shorter applications will likely benefit from additional future applications. At the end of the application

air dry or blot the lesion with a cotton pellet to remove any excess unreacted SDF.<sup>94,101</sup>

The optimal periodicity for reapplication has not been established. SDF and the timing or need for additional treatments should be based on the extent of disease, rate of disease progression, and other factors that influence patient recall schedules such as patient education and monitoring of preventive program. Evaluation of SDF treatment at 4-6 weeks after the initial application is recommended to determine if the lesion is arrested, unless treating only lesions with only superficial dentinal involvement. Reapplication of SDF may be indicated if the treated lesion(s) do not appear arrested. Additional SDF can be applied at recall appointments if necessary depending on the color and hardness of the lesion or evidence of lesion progression. Treated lesions can be restored after SDF treatment, but the recommendation is to treat after caries arrest has been determined. The CDT code for SDF placement is: D1354, Interim Caries Arresting Medicament Application.<sup>94,101</sup>

The removal of the superficial caries and the filling of the cavity with a glass-ionomer material or bioactive dentin substitute (i.e. Biodentine; Septodont, Lancaster, PA USA) will at least temporarily arrest the caries process and prevent its rapid progression to the dental pulp. Gross caries removal can usually be accomplished easily in one appointment. If there are many extensive caries lesions, however, a second appointment may be necessary. Newer dental materials containing bioactive dentin substitutes have shown to be better at reducing progression of caries, more tolerant to pulpal tissue and arresting caries than zinc oxide eugenol cement (IRM, Intermediate Restorative Material, LD Caulk Co, Milford, DE, USA).<sup>102-104</sup> These materials are discussed more in depth in [Chapter 14](#), Treatment of Deep Caries, Vital Pulp Exposure, and Pulpless Teeth.

An alternative approach for some compliant children (with compliant parents) old enough to rinse and expectorate, and for compliant adolescents, is to initiate intensive and multiple topical fluoride therapies in conjunction with the necessary behavioral lifestyle modifications and then to proceed systematically with restorations and other indicated individualized therapies such as fluoride varnish, prescription-strength fluoride toothpaste, higher recall frequency, etc.)

### Over-the-Counter Fluoride Mouthrinses and Gels

The use of dilute oral fluoride rinses and gels as an additional dental caries control measure has become another helpful adjunct. Children who may not have full control over their swallowing reflexes and may not be proficient with expectorating. Children should only be recommended a fluoride rinse if they can expectorate; therefore, caution should be exercised when these products are recommended for home use for these children.

Extensive field research has been conducted on the use of fluoride mouthrinses. Most studies incorporate the use of a 0.2% sodium fluoride rinse once weekly or a 0.05% sodium fluoride rinse once daily. These studies show unquestionable caries-preventive benefits of the regular use of self-administered fluoride rinses when properly supervised. These benefits accrue to primary and permanent teeth, and seem to be helpful both in fluoridated areas and in areas with non fluoridated water.<sup>87,105</sup> There are too few well conducted studies to support the use of the dilute gels.



### Prescription Home-Use Fluoride Mouthrinses, Toothpastes, and Gels

Additional at-home topical fluoride treatments involving increased concentrations of fluoride should be considered for children at moderate to high risk for caries. These may include over-the-counter or prescription-strength formulations. If a patient expectorates an over-the-counter toothpaste after use but does not rinse with water, then it can become prescription strength, as almost all toothpastes with fluoride in it have at least 1000 ppm fluoride in the United States. A meta-analysis of permanent teeth indicated that there is a statistically significant reduction in caries with the use of prescription-strength fluoride mouthrinses (0.09% fluoride, equivalent to 900 ppm) compared with placebo, no treatment, or oral hygiene instruction (OHI) and prophylaxis. By frequency of use, daily and weekly rinsing showed statistically significant effects, while biweekly rinsing showed no significant improvement.<sup>96</sup>

The primary difference between gels and toothpastes (0.5% fluoride, equivalent to 5000 ppm) is that pastes contain a small amount of an abrasive component. Two meta-analyses, one for primary teeth and another for permanent teeth, showed a statistically significant reduction of dental caries with prescription-strength 0.5% fluoride toothpaste or gel compared with no treatment, placebo, or a 0.125% to 0.145% fluoride toothpaste.<sup>96</sup>

### Dietary Fluoride Supplements

A review of the literature on the value of fluorides administered during pregnancy failed to disclose any valid evidence to support such use, even in non fluoridated areas.

Participants in a symposium concerning the use of prenatal fluorides agreed that transfer of fluoride does occur from the mother to the fetus through the placenta.<sup>106</sup> The effect of fluoride on teeth is mainly topical, posteruption, and postnatal.<sup>107,108</sup>

Consider systemic fluoride supplements judiciously in children due to the increased risk of fluorosis. The natural fluoride content of the water should first be determined. Fluoride supplements should be prescribed only for children who are at high risk of developing caries, only in cases when the use of topical fluoride is not possible, and after all other sources of fluoride (toothpaste, fluoride in water, infant formula, prepared baby food, etc.) have been evaluated. When the primary source of drinking water is low in fluoride and the child is at high risk for caries, topical fluorides would be the first recommendation. Only in cases where the use of topical fluoride is not feasible should careful consideration of systemic fluoride supplements (drops, lozenges, beads) be given before fluoride supplements are prescribed. If the natural fluoride content is 0.3 ppm or higher, supplements should not be administered.<sup>109</sup> If the fluoride content is below 0.3 ppm, the administration of fluoride supplements should be considered only after a review of all other types of fluoride sources, and if the child is at moderate to high risk for caries.<sup>109</sup>

Several studies have reported the caries-preventive effects of adding fluoride to a variety of foods and beverages. Fluoride in countries outside the United States has been used as a caries-preventive additive in salt, milk, and even sugar.<sup>110</sup> Numerous reports show that these products can have measurable and favorable results when used as intended. Such

products are designed for use by specific and targeted population groups.

### Combinations of Fluoride Therapies

There is considerable evidence to suggest that using combinations of therapeutic fluoride agents often produces additive anticariogenic effects. The evidence also indicates that the earlier fluoride therapy is initiated in moderate to high caries risk children, the more effective the caries control will be. However, one must use caution in prescribing multiple therapies in children to avoid excessive fluoride ingestion.

### Enamel Fluorosis

Fluoride is the most effective caries-preventive agent commercially available today. Except in a patient with a fluoride allergy (very rare), it is considered safe when properly used. Dental enamel fluorosis is associated with cumulative fluoride intake during enamel development, with the severity dependent on the dose, duration, and timing of systemic fluoride ingestion.<sup>61</sup> The ingestion of high concentrations can lead to nausea, vomiting, dental enamel fluorosis (mottling), or, in extreme cases, even death, especially in children. Sources of dietary fluoride may include drinking water from home, day care, and school; beverages such as soda, juice, and infant formula; prepared food; and toothpaste. Infant formulas, especially powdered formulas that have been reconstituted with fluoridated water, have been associated with an increased risk of fluorosis.<sup>111</sup> It is imperative that the dental profession have full awareness of its use and yet be prepared to use it to the patient's maximum advantage through careful consideration of each patient's individual situation.

## Other Preventive Therapies

### CHLORHEXIDINE AND THYMOL

As an oral antimicrobial, chlorhexidine has been used in oral rinses, dentifrices, chewing gum, varnish, and gel. In the United States, it is used most often in the form of a prescription oral rinse. Many children object to the taste of these products, but they have been shown to be effective against the microorganisms causing both caries and periodontal disease. Additionally, most chlorhexidine mouthrinses contain a high concentration of alcohol. Thymol has also been included with chlorhexidine in some varnish preparations. To date, these products have not shown superior caries-preventive results when compared with multiple fluoride therapies, and they may require more frequent application to be effective.

### XYLITOL

Xylitol is a five-carbon sugar alcohol and has been used as sweetener since the early 1960s. Xylitol and other sugar alcohols are not readily metabolized by oral bacterial and are considered non cariogenic sugar substitutes.<sup>112,113</sup> Numerous studies confirm its antimicrobial capability.<sup>114</sup> Xylitol has been tested as an additive to a variety of foods and to dentifrices. However, the vast majority of published data come from studies in which xylitol was incorporated

into chewing gum.<sup>112</sup> An evidence-based review concluded that there is insufficient evidence that the use of xylitol gum, chlorhexidine varnish or gel, or calcium supplementation lowers the incidence of caries

Most research studies reported very large doses (4 to 15 grams per day) and high frequency of consumption, making it unrealistic for clinical practice. Overall results of multiple clinical trials are inconclusive. There were issues in study design as well as bias in many of the studies. Data is inconclusive for both short-term and long-term effectiveness in caries reduction.<sup>113,115-118</sup>

## OTHER REMINERALIZING OR ANTIMICROBIAL PRODUCTS

Recently, homeopathic remedies (i.e., oil pulling using coconut oil, sunflower, sesame, or olive oil) have gained more popularity on social media for the use of controlling caries. These homeopathic remedies have been used for centuries. There is a growing number of people looking for herbal remedies to treat disease. Almost all treatment using oil pulling for dental therapy is done unsupervised by a dental health professional and varies greatly in amount used of oil, frequency, and duration. There are no peer-reviewed, evidenced-based publications in reputable journals which support this type of therapy is beneficial in arrest or reduction of caries. All studies which have been conducted report no additional benefit.<sup>119,120</sup>

Some data exist from laboratory and animal studies to confirm suppression of MS by iodine. Several studies in humans have been conducted, but there is insufficient evidence that the use of iodine lowers the incidence of caries. Short-term reductions of MS have been noted, but long-term reductions have not been reported.<sup>121</sup>

Data are also available regarding the use of amorphous calcium phosphate (ACP) and casein phosphopeptide (CPP)-ACP in caries prevention. However, a panel of experts convened by the ADA to produce clinical recommendations reviewed the available literature and provided a recommendation against the use of 10% CPP-APP for caries prevention.<sup>114</sup>

## CARIES VACCINE

Dental researchers have worked on the development of a vaccine to prevent the disease of dental caries since at least the early 1940s. Research efforts have generally assumed that MS is the principal etiologic organism of dental caries, and the development of a method of immunization specifically targeted at neutralizing MS has been a major thrust of caries vaccine research. Most current research is being directed toward a greater understanding of the immune system and the multiple contributions of many different caries inducing factors. Because of our new understanding of caries as a dysbiosis, a caries vaccine may never happen.

## DENTAL CARIES ACTIVITY TESTS

For the larger part of a century, dental scientists have been trying to develop a convenient method for quantitatively measuring the degree of dental caries activity

in individual patients. Techniques requiring laboratory procedures to determine oral bacterial counts or their aciduric potential have been developed and used. More recently, paper test strips to gauge salivary microbial density in patients have been tested.<sup>122,123</sup> No truly convenient and efficient test method has yet been developed that has sufficient accuracy to be a reliable caries activity indicator. Research continues in this area because having an accurate, convenient, and efficient test to measure early caries activity and its level of potential, especially in young children, would be a very useful diagnostic tool for private practitioners and public health assistance providers.<sup>124</sup>

## Diagnostic Tools

Over the past three decades, technologies capable of detecting lesions at an earlier stage of development and quantifying the impact of noninvasive professional fluoride treatments such as fluoride varnishes have been developed. There are several different instruments available on the market that may be able to assist with the early detection of caries. Each of these instruments must be used in combination with a detailed clinical examination and review of caries risk for each child. There is insufficient scientific evidence to fully characterize the diagnostic accuracy regarding fiberoptic methods and quantitative light-induced fluorescence. The electrical methods and laser fluorescence could be useful adjuncts to visual-tactile and radiographic examinations, especially on occlusal surfaces in permanent and primary molars, but evidence is graded as limited. No conclusions can be drawn regarding the cost effectiveness of these detection methods. Early identification will provide evidence to guide the dental professional in implementing various measures for the reversal and control of these caries lesions.<sup>125,126</sup>

## INFRARED LASER FLUORESCENCE (DIAGNODENT)

DIAGNOdent is an instrument designed to facilitate the detection and quantification of dental caries on occlusal and smooth surfaces (Kaltenbach & Voigt GmbH & Co., Biberach/Riss, Germany) (Fig. 10.7). It uses a diode laser light source and a fiberoptic cable that transmits the light to a handheld probe with a fiberoptic eye in the tip. The light is absorbed and induces infrared fluorescence by organic and inorganic material. The emitted fluorescence is collected at the probe tip, transmitted through ascending fibers, and processed and presented on a display window as an integer between 0 and 99. Increased fluorescence reflects potential caries-affected tooth substance. The identity of the material responsible for the fluorescence is still under investigation, but it appears to be bacterial metabolites, particularly the porphyrins.<sup>126,128</sup> Results of *in vitro* and *in vivo* studies on smooth, interproximal, or occlusal surfaces have indicated that the diagnostic sensitivity of this technology ranges from 0.31 to 0.98, while its specificity ranges from 0.67 to 0.96.<sup>127-131</sup>

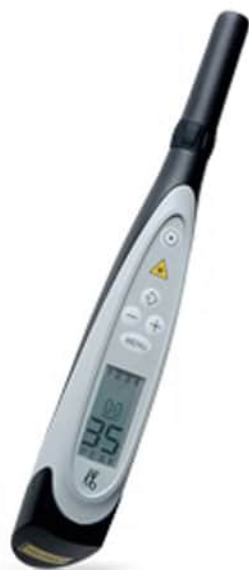

Fig. 10.7 Infrared laser fluorescence diagnostic machine.

## DIGITAL IMAGING FIBEROPTIC TRANSILLUMINATION

Clinical caries examinations often use transillumination to identify lesions located on the interproximal surfaces of the anterior teeth. For at least 50 years, a fiberoptic transillumination (FOTI) instrument has been available for clinical use. It provides an intense light beam that is transmitted through a fiberoptic cable to a specially designed probe to permit the use of transillumination on the proximal surfaces of posterior teeth. Repeated improvements have been made in the instrument so that it may be used on occlusal and proximal tooth surfaces and the instrument is commonly used, often in place of radiographs, in private practices worldwide. Digital imaging fiber optic transillumination (DIFOTI) (Electro-Optical Sciences, Inc., Irvington, New York, USA) is a further advancement of this technology, in which the visually observed images are captured with the use of a digital charge-coupled device (CCD) camera and sent to a computer for analysis with dedicated algorithms. Results of *in vitro* and *in vivo* studies on smooth, interproximal or occlusal surfaces have indicated that the diagnostic sensitivity of this technology ranges from 0.10 to 0.83, while its specificity ranges from 0.15 to 0.90.<sup>132-135</sup>

## QUANTITATIVE LIGHT FLUORESCENCE

Quantitative light fluorescence (QLF) is a technique available for the early detection of dental caries. *In vitro* and *in situ* studies have confirmed a correlation between the amount of observed fluorescence and the mineral content of the lesions, and have made it possible to develop a system that can assess changes in either the progression or regression of caries lesions. Results of *in vitro* and *in vivo* studies on smooth, interproximal, or occlusal surfaces have indicated that the diagnostic sensitivity of this technology ranges from 0.64 to 1.0 while its specificity ranges from 0.57 to 0.88.<sup>136-138</sup>

## Conclusion

The success of a dental caries management program depends to a great extent on the interest and cooperation of the patient and the patient's caregivers. Caries should not be viewed as a hopeless problem. Diagnostic, therapeutic, and preventive measures are available to control caries. In the clinical management of caries, the dentist's role consists of seeking and eliminating the cause. This includes trying to correct inappropriate habits or deficiency states that may be contributing factors, restoring the salvageable teeth to good form and function, and, finally, making use of all available therapeutic preventive and control measures in an established, evidence-based ongoing manner.

Successful management of all dental caries also requires careful diagnosis, complete dental and medical history-taking, the initiation of a comprehensive preventive program, the application of sound principles of restorative dentistry, and the establishment of a regular recall schedule for maintenance and reemphasis of the preventive procedures. The recall appointment should be set at each visit based on the clinician's judgment of the patient's caries risk for future disease at that time.<sup>126</sup>

## References

1. American Academy of Pediatric Dentistry: Policy on the dental home, *Pediatr Dent* 42(6):34–35, 2020.
2. Benjamin RM: The Surgeon General's vision for a healthy and fit nation, *Public Health Rep* 125(4):514–515, 2010.
3. Pitts N, Baez R, Diaz-Guallory C, et al.: Early childhood caries: IAPD Bangkok declaration, *Int J Paediatr Dent* 29:384–386, 2019.
4. Kassebaum NJ, Smith AGC, Bernabe E, et al.: Global, regional, and national prevalence, incidence, and disability-adjusted life years for oral conditions for 195 countries, 1990–2015: a systematic analysis for the global burden of diseases, injuries, and risk factors, *J Dent Res* 96(4):380–387, 2017.
5. Pew Charitable Trusts. In search of dental care, *Public Health Rep* 1–15, 2013.
6. Thylstrup A, Bruun C, Holmen L: In vivo caries models—mechanisms for caries initiation and arrestment, *Adv Dent Res* 8(2):144–157, 1994.
7. Fisher-Owens SA, Gansky SA, Platt LJ, et al.: Influences on children's oral health: a conceptual model, *Pediatrics* 120(3):e510–520, 2007.
8. Kilian M, Chapple IL, Hannig M, et al.: The oral microbiome—an update for oral healthcare professionals, *Br Dent J* 221(10):657–666, 2016.
9. Marsh PD: Sickness and in health—what does the oral microbiome mean to us? An ecological perspective, *Adv Dent Res* 29(1):60–65, 2018.
10. Featherstone JD: The continuum of dental caries—evidence for a dynamic disease process, *J Dent Res* 83:C39–42, 2004. Spec No C.
11. Featherstone JD, Fontana M, Wolff M: Novel anticaries and remineralization agents: future research needs, *J Dent Res* 97(2):125–127, 2018.
12. Simon-Soro A, Guillen-Navarro M, Mira A: Metatranscriptomics reveals overall active bacterial composition in caries lesions, *J Oral Microbiol* 6:25443, 2014.
13. Tanner AC, Kressler CA, Faller LL: Understanding caries from the oral microbiome perspective, *J Calif Dent Assoc* 44(7):437–446, 2016.
14. Twetman S: Prevention of dental caries as a non-communicable disease, *Eur J Oral Sci* 126(Suppl 1):19–25, 2018.
15. Pereira D, Seneviratne CJ, Koga-Ito CY, Samaranyake LP: Is the oral fungal pathogen *Candida albicans* a cariogen? *Oral Dis* 24(4):518–526, 2018.
16. Simon-Soro A, Mira A: Solving the etiology of dental caries, *Trends Microbiol* 23(2):76–82, 2015.



17. Nyvad B, Fejerskov O: Assessing the stage of caries lesion activity on the basis of clinical and microbiological examination, *Community Dent Oral Epidemiol* 25(1):69–75, 1997.
18. American Academy of Pediatric Dentistry: Policy on early childhood caries (ECC): unique challenges and treatment options, *Pediatric Dent* 42(6):74–75, 2020.
19. Erickson PR, Mazhari E: Investigation of the role of human breast milk in caries development, *Pediatr Dent* 21(2):86–90, 1999.
20. Iida H, Auinger P, Billings RJ, Weitzman M: Association between infant breastfeeding and early childhood caries in the United States, *Pediatrics* 120(4):e944–952, 2007.
21. Mohebbi SZ, Virtanen JI, Vahid-Golpayegani M, Vehkalahti MM: Feeding habits as determinants of early childhood caries in a population where prolonged breastfeeding is the norm, *Community Dent Oral Epidemiol* 36(4):363–369, 2008.
22. Feldens CA, Giugliani ER, Vigo A, Vitolo MR: Early feeding practices and severe early childhood caries in four-year-old children from southern Brazil: a birth cohort study, *Caries Res* 44(5):445–452, 2010.
23. Tinanoff N, Kanellis MJ, Vargas CM: Current understanding of the epidemiology, mechanisms, and prevention of dental caries in preschool children, *Pediatr Dent* 24(6):543–551, 2002.
24. Policy on early childhood caries (ECC): Classifications, consequences, and preventive strategies, *Pediatr Dent* 30(Suppl 7):40–43, 2008.
25. Wojcik KY, Rechtman DJ, Lee ML, Montoya A, Medo ET: Macronutrient analysis of a nationwide sample of donor breast milk, *J Am Diet Assoc* 109(1):137–140, 2009.
26. Policy on dietary recommendations for infants, children, and adolescents, *Pediatr Dent* 30(Suppl 7):47–48, 2008.
27. Dye BA, Hsu KL, Afful J: Prevalence and measurement of dental caries in young children, *Pediatr Dent* 37(3):200–216, 2015.
28. Greenwell AL, Johnsen D, DiSantis TA, Gerstenmaier J, Limbert N: Longitudinal evaluation of caries patterns form the primary to the mixed dentition, *Pediatr Dent* 12(5):278–282, 1990.
29. Vargas CM, Crall JJ, Schneider DA: Sociodemographic distribution of pediatric dental caries: NHANES III, 1988–1994, *J Am Dent Assoc* (1939) 129(9):1229–1238, 1998.
30. Gao X, Jiang S, Koh D, Hsu CY: Salivary biomarkers for dental caries, *Periodontol* 70(1):128–141, 2016.
31. Bruvo M, Moe D, Kirkeby S, Vorum H, Bardow A: Individual variations in protective effects of experimentally formed salivary pellicles, *Caries Res* 43(3):163–170, 2009.
32. Zakhary GM, Clark RM, Bidichandani SI, Owen WL, Slayton RL, Levine M: Acidic proline-rich protein Db and caries in young children, *J Dent Res* 86(12):1176–1180, 2007.
33. Levine M: Susceptibility to dental caries and the salivary proline-rich proteins, *Int J Dent* 2011:953412, 2011.
34. Hemadi AS, Huang R, Zhou Y, Zou J: Salivary proteins and microbiota as biomarkers for early childhood caries risk assessment, *Int J Oral Sci* 9(11):e1, 2017.
35. Slomiany BL, Piotrowski J, Czajkowski A, Slomiany A: Control of mucin molecular forms expression by salivary protease: differences with caries, *Int J Biochem* 25(5):681–687, 1993.
36. Fidalgo TK, Freitas-Fernandes LB, Ammari M, Mattos CT, de Souza IP, Maia LC: The relationship between unspecific s-IgA and dental caries: a systematic review and meta-analysis, *J Dent* 42(11):1372–1381, 2014.
37. Tinanoff NT: The oral cavity. In Kliegman R, Nelson WE, editors: *Nelson textbook of pediatrics*, ed 19, Philadelphia, PA, 2011, Elsevier/Saunders, p 1257.
38. Crossner CG: Salivary flow rate in children and adolescents, *Swed Dent J* 8(6):271–276, 1984.
39. Semega JL, Fontenot KR, Kollar MA: Income and poverty in the United States: 2016, *Curr Popul Rep* P60–259, 2017.
40. Edelstein BL: Disparities in oral health and access to care: findings of national surveys, *Ambul Pediatr* 2(Suppl 2):141–147, 2002.
41. Weerheijm KL: Molar incisor hypomineralisation (MIH), *Eur J Paediatr Dent* 4(3):114–120, 2003.
42. Kuhnisch J, Kabary L, Malyk Y, et al.: Relationship between caries experience and demarcated hypomineralised lesions (including MIH) in the permanent dentition of 15-year-olds, *Clin Oral Invest* 22(5):2013–2019, 2018.
43. Grossi JA, Cabral RN, Leal SC: Caries experience in children with and without molar-incisor hypomineralisation: a case-control study, *Caries Res* 51(4):419–424, 2017.
44. Wuollet E, Laisi S, Alaluusua S, Waltimo-Siren J: The association between molar-incisor hypomineralization and dental caries with socioeconomic status as an explanatory variable in a group of Finnish children, *Int J Environ Res Publ Health* 15(7), 2018.
45. Americano GC, Jacobsen PE, Soviero VM, Haubek D: A systematic review on the association between molar incisor hypomineralization and dental caries, *Int J Paediatr Dent* 27(1):11–21, 2017.
46. Hafez HS, Shaarawy SM, Al-Sakiti AA, Mostafa YA: Dental crowding as a caries risk factor: a systematic review, *Am J Orthod Dentofacial Orthop* 142(4):443–450, 2012.
47. Rosenbloom RG, Tinanoff N: Salivary Streptococcus mutans levels in patients before, during, and after orthodontic treatment, *Am J Orthod Dentofacial Orthop* 100(1):35–37, 1991.
48. Ekstrand KR, Gimenez T, Ferreira FR, Mendes FM, Braga MM: The international caries detection and assessment system - ICDAS: a systematic review, *Caries Res* 52(5):406–419, 2018.
49. Nyvad B, Machiulskiene V, Bælum V: The Nyvad criteria for assessment of caries lesion activity. Paper presented at: Clinical Models Workshop: remin-demin, Precavitation, *Caries*, 2005.
50. Petersson GH: Assessing caries risk—using the Cariogram model, *Swed Dent J Suppl* (158):1–65, 2003.
51. Tellez M, Gomez J, Pretty I, Ellwood R, Ismail AI: Evidence on existing caries risk assessment systems: are they predictive of future caries? *Community Dent Oral Epidemiol* 41(1):67–78, 2013.
52. ADA Council on Scientific Affairs: Fluoride toothpaste use for young children, *J Am Dent Assoc* (1939) 145(2):190–191, 2014.
53. Dean JA, Barton DH, Vahedi I, Hatcher EA: Progression of interproximal caries in the primary dentition, *J Clin Pediatr Dent* 22(1):59–62, 1997.
54. Gustafsson BE, Quensel CE, Lanke LS, et al.: The Vipeholm dental caries study: the effect of different levels of carbohydrate intake on caries activity in 436 individuals observed for five years, *Acta Odontol Scand* 11(3–4):232–264, 1954.
55. Weiss RL, Trithart AH: Between-meal eating habits and dental caries experience in preschool children, *Am J Public Health Nation's Health* 50:1097–1104, 1960.
56. Schachtele CF, Jensen ME: Comparison of methods for monitoring changes in the pH of human dental plaque, *J Am Dent Assoc* 61(10):1117–1125, 1982.
57. Park K, Ashmore R, Stookey G: Prolonged response period for indwelling plaque pH studies. Paper presented at, *J Dent Res* 1986.
58. Berenij R, Ripa LW, Leske G: The relationship of frequency of toothbrushing, oral hygiene, gingival health, and caries-experience in school children, *J Publ Health Dent* 33(3):160–171, 1973.
59. Tsamtsouris A, White GE, Clark ER: The effect of instruction and supervised toothbrushing on the reduction of dental plaque in kindergarten children, *ASDC J Dent Child* 46(3):204–209, 1979.
60. Wright GZ, Banting DW, Feasby WH: The Dorchester dental flossing study: final report, *Clin Prev Dent* 1(3):23–26, 1979.
61. Wright JT, Hanson N, Ristic H, Whall CW, Estrich CG, Zentz RR: Fluoride toothpaste efficacy and safety in children younger than 6 years: a systematic review, *J Am Dent Assoc* (1939) 145(2):182–189, 2014.
62. US Department of Health Human Services Federal Panel on Community Water Fluoridation: US Public Health Service recommendation for fluoride concentration in drinking water for the prevention of dental caries, *Publ Health Rep* 130(4):318–331, 2015.
63. Harding MA, O'Mullane DM: Water fluoridation and oral health, *Acta Med Acad* 42(2):131–139, 2013.
64. Iheozor-Ejirofor Z, Worthington HV, Walsh T, et al.: Water fluoridation for the prevention of dental caries, *Cochrane Database Syst Rev* (6):Cd010856, 2015.
65. Marthaler TM: Salt fluoridation and oral health, *Acta Med Acad* 42(2):140–155, 2013.
66. Murray JJ: Efficacy of preventive agents for dental caries. Systemic fluorides: water fluoridation, *Caries Res* 27(Suppl 1):2–8, 1993.
67. Carmichael CL, Rugg-Gunn AJ, French AD, Cranage JD: The effect of fluoridation upon the relationship between caries experience and social class in 5-year-old children in Newcastle and Northumberland, *Br Dent J* 149(6):163–167, 1980.
68. Rock WP, Gordon PH, Bradnock G: Dental caries experience in Birmingham and Wolverhampton school children following the fluoridation in Birmingham water in 1964. Method and overall caries experience in the two populations, *Br Dent J* 150(3):61–66, 1981.

69. Jackson R, Kelly S, Dunipace A, Brizendine E, Kelly L, Stookey G. Fluoride level of biological samples collected from adolescents. Paper presented at, *J Dent Res* 1998.
70. Jackson RD, Brizendine EJ, Kelly SA, Hinesley R, Stookey GK, Dunipace AJ: The fluoride content of foods and beverages from negligibly and optimally fluoridated communities, *Community Dent Oral Epidemiol* 30(5):382–391, 2002.
71. Centers for Disease Control Prevention: Promoting oral health: interventions for preventing dental caries, oral and pharyngeal cancers, and sports-related craniofacial injuries. A report on recommendations of the task force on community preventive services, *MMWR Recomm Rep* 50(RR-21):1–13, 2001.
72. Beiswanger BB, Gish CW, Mallatt ME: A three-year study of the effect of a sodium fluoride-silica abrasive dentifrice on dental caries, *Pharmacol Ther Dent* 6(1–2):9–16, 1981.
73. Scottish Intercollegiate Guideline Network. Dental interventions to prevent caries in children. In *Healthcare Improvement Scotland*, Edinburgh, 2014.
74. Maternal Child Health Bureau. Topical fluoride recommendations for high-risk children: development of decision support matrix, 2007.
75. Ammari AB, Bloch-Zupan A, Ashley PF: Systematic review of studies comparing the anti-caries efficacy of children's toothpaste containing 600 ppm of fluoride or less with high fluoride toothpastes of 1,000 ppm or above, *Caries Res* 37(2):85–92, 2003.
76. Walsh T, Worthington HV, Glenny AM, Appelbe P, Marinho VC, Shi X: Fluoride toothpastes of different concentrations for preventing dental caries in children and adolescents, *Cochrane Database Syst Rev* 1):Cd007868, 2010.
77. Marinho VC, Higgins JP, Sheiham A, Logan S: Fluoride toothpastes for preventing dental caries in children and adolescents, *Cochrane Database Syst Rev* 1):Cd002278, 2003.
78. Zacherl WA: A three-year clinical caries evaluation of the effect of a sodium fluoride-silica abrasive dentifrice, *Pharmacol Ther Dent* 6(1–2):1–7, 1981.
79. Gerdin PO: Studies in dentifrices. 6. The inhibitory effect of some grinding and non-grinding fluoride dentifrices on dental caries. Including tests of a new, non-grinding manganese-fluoride dentifrice, *Swed Dent J* 65(10):521–532, 1972.
80. Edlund K, Koch G: Effect on caries of daily supervised toothbrushing with sodium monofluorophosphate and sodium fluoride dentifrices after 3 years, *Scand J Dent Res* 85(1):41–45, 1977.
81. Weyant RJ, Tracy SL, Anselmo TF, et al.: Topical fluoride for caries prevention: executive summary of the updated clinical recommendations and supporting systematic review, *J Am Dent Assoc* (1939) 144(11):1279–1291, 2013.
82. Gao SS, Zhang S, Mei ML, Lo EC, Chu CH: Caries remineralisation and arresting effect in children by professionally applied fluoride treatment—A systematic review, *BMC Oral Health* 16:12, 2016.
83. Ijaz S, Croucher R, Onwude O, Rutterford C, Marinho VC: Professionally applied fluoride paint—on solutions for the control of dental caries in children and adolescents, *Cochrane Database Syst Rev* 2018(5), 2018.
84. Helfenstein U, Steiner M: Fluoride varnishes (Duraphat): a meta-analysis, *Community Dent Oral Epidemiol* 22(1):1–5, 1994.
85. Ekstrand J, Koch G, Lindgren LE, Petersson LG: Pharmacokinetics of fluoride gels in children and adults, *Caries Res* 15(3):213–220, 1981.
86. LeCompte EJ, Whitford GM: Pharmacokinetics of fluoride from APF gel and fluoride tablets in children, *J Dent Res* 61(3):469–472, 1982.
87. Ripa LW, Leske GS, Sposato A, Varma A: Effect of prior toothcleaning on bi-annual professional acidulated phosphate fluoride topical fluoride gel-tray treatments. Results after three years, *Caries Res* 18(5):457–464, 1984.
88. Houpt M, Koenigsberg S, Shey Z: The effect of prior toothcleaning on the efficacy of topical fluoride treatment. Two-year results, *Clin Prev Dent* 5(4):8–10, 1983.
89. Bijella MF, Bijella VT, Lopes ES, Bastos JR: Comparison of dental prophylaxis and toothbrushing prior to topical APF applications, *Community Dent Oral Epidemiol* 13(4):208–211, 1985.
90. Stookey GK: Caries prevention, *J Dent Educ* 62(10):803–811, 1998.
91. Petersson LG, Arthursson L, Östberg C, Jönsson G, Gleerup A: Caries-inhibiting effects of different modes of duraphat varnish reapplication: a 3-year radiographic study, *Caries Res* 25(1):70–73, 1991.
92. Petersson LG, Westerberg I: Intensive fluoride varnish program in Swedish adolescents: economic assessment of a 7-year follow-up study on proximal caries incidence, *Caries Res* 28(1):59–63, 1994.
93. Skold L, Sundquist B, Eriksson B, Edeland C: Four-year study of caries inhibition of intensive duraphat application in 11–15-year-old children, *Community Dent Oral Epidemiol* 22(1):8–12, 1994.
94. Crystal YO, Marghalani AA, Ureles SD, et al.: Use of silver diamine fluoride for dental caries management in children and adolescents, including those with special health care needs, *Pediatr Dent* 39(5):135–145, 2017.
95. Gao SS, Zhao IS, Hiraishi N, et al.: Clinical trials of silver diamine fluoride in arresting caries among children: a systematic review, *JDR J Clin Transl Res* 1(3):201–210, 2016.
96. Fung HTM, Wong MCM, Lo ECM, Chu CH. Arresting early childhood caries with silver diamine fluoride—a literature review, *J Oral Hygiene Health*. 2013.
97. Yamaga R, Nishino M, Yoshida S, Yokomizo I: Diamine silver fluoride and its clinical application, *J Osaka Univ Dent Sch* 12:1–20, 1972.
98. Lou YL, Botelho MG, Darvell BW: Reaction of silver diamine [corrected] fluoride with hydroxyapatite and protein, *J Dent* 39(9):612–618, 2011.
99. Knight GM, McIntyre JM, Mulyani: The effect of silver fluoride and potassium iodide on the bond strength of auto cure glass ionomer cement to dentine, *Aust Dent J* 51(1):42–45, 2006.
100. Love RM: *Evaluation of the antimicrobial activity of combined silver diamine fluoride (SDF) and potassium iodide (KI) as an endodontic medication*, New Zealand, 2010, University of Otago.
101. American Academy of Pediatric Dentistry: Chairside guide: silver diamine fluoride in the management of dental caries lesions, *Pediatr Dent* 39(6):478–479, 2017.
102. Nowicka A, Wilk G, Lipski M, Kolecki J, Buczkowska-Radlinska J: Tomographic evaluation of reparative dentin formation after direct pulp capping with Ca(OH)<sub>2</sub>, MTA, biodentine, and dentin bonding system in human teeth, *J Endod* 41(8):1234–1240, 2015.
103. Valles M, Roig M, Duran-Sindreu F, Martinez S, Mercade M: Color stability of teeth restored with biodentine: a 6-month in vitro study, *J Endod* 41(7):1157–1160, 2015.
104. Tziafa C, Koliniotou-Koumpia E, Papadimitriou S, Tziafas D: Dentinogenic activity of biodentine in deep cavities of miniature swine teeth, *J Endod* 41(7):1161–1166, 2015.
105. Heitetz SB, Horowitz HS, Meyers RJ, Li SH: Evaluation of the comparative effectiveness of fluoride mouthrinsing, fluoride tablets, and both procedures in combination: interim findings after two years, *Pediatr Dent* 9(2):121–125, 1987.
106. Horowitz H: Perspectives on the use of prenatal fluorides—A symposium, *J Dent Child* 48(2):102–102, 1981.
107. Katz S, Muhler JC: Prenatal and postnatal fluoride and dental caries experience in deciduous teeth, *J Am Dent Assoc* 76(2):305–311, 1968.
108. Hennon DK, Stookey GK, Muhler JC: The clinical anticariogenic effectiveness of supplementary fluoride-vitamin preparations. Results at the end of three years, *J Dent Child* 33(1):3–12, 1966.
109. Rozier RG, Adair S, Graham F, et al.: Evidence-based clinical recommendations on the prescription of dietary fluoride supplements for caries prevention: a report of the American Dental Association Council on Scientific Affairs, *J Am Dent Assoc* (1939) 141(12):1480–1489, 2010.
110. Espelid I: Caries preventive effect of fluoride in milk, salt and tablets: a literature review, *Eur Arch Paediatr Dent* 10(3):149–156, 2009.
111. Hujuel PP, Zina LG, Moimaz SA, Cunha-Cruz J: Infant formula and enamel fluorosis: a systematic review, *J Am Dent Assoc* (1939) 140(7):841–854, 2009.
112. Makinen KK: The rocky road of xylitol to its clinical application, *J Dent Res* 79(6):1352–1355, 2000.
113. American Academy of Pediatric Dentistry: Policy on the use of xylitol, *Pediatr Dent* 40(6):55–57, 2015.
114. Slayton RL, Urquhart O, Araujo MWB, et al.: Evidence-based clinical practice guideline on nonrestorative treatments for carious lesions: a report from the American Dental Association, *J Am Dent Assoc* (1939) 149(10):837–849, 2018. e819.
115. Alamoudi NM, Hanno AG, Sabbagh HJ, Masoud MI, Almushayt AS, El Derwi DA: Impact of maternal xylitol consumption on mutans streptococci, plaque and caries levels in children, *J Clin Pediatr Dent* 37(2):163–166, 2012.

116. Soderling E, Isokangas P, Pienihakkinen K, Tenovuori J, Alanen P: Influence of maternal xylitol consumption on mother-child transmission of mutans streptococci: 6-year follow-up, *Caries Res* 35(3):173–177, 2001.
117. Campus G, Cagetti MG, Sale S, et al.: Six months of high-dose xylitol in high-risk caries subjects—a 2-year randomised, clinical trial, *Clin Oral Invest* 17(3):785–791, 2013.
118. Laitala ML, Alanen P, Isokangas P, Soderling E, Pienihakkinen K: Long-term effects of fluoride mouthrinse on children's dental decay and need for restorative treatment, *Community Dent Oral Epidemiol* 41(6):534–540, 2013.
119. Jauhari D, Srivastava N, Rana V, Chandna P: Comparative evaluation of the effects of fluoride mouthrinse, herbal mouthrinse and oil pulling on the caries activity and Streptococcus mutans count using Oratest and Dentocult SM strip mutans Kit, *Int J Clin Pediatr Dent* 8(2):114–118, 2015.
120. An TD, Pothiraj C, Gopinath R, Kayalvizhi BJAJMR: Effect of oil-pulling on dental caries causing bacteria, 2(3):63–66, 2008.
121. Rethman MP, Beltran-Aguilar ED, Billings RJ, et al.: Nonfluoride caries-preventive agents: executive summary of evidence-based clinical recommendations, *J Am Dent Assoc (1939)* 142(9):1065–1071, 2011.
122. Cannon M, Trent B, Vorachek A, Kramer S, Esterly R: Effectiveness of CRT at measuring the salivary level of bacteria in caries prone children with probiotic therapy, *J Clin Pediatr Dent* 38(1):55–60, 2013.
123. Hertel S, Wolf A, Basche S, et al.: Initial microbial colonization of enamel in children with different levels of caries activity: an in situ study, *Am J Dent* 30(3):171–176, 2017.
124. Bader JD, Shugars DA, Bonito AJ: Systematic reviews of selected dental caries diagnostic and management methods, *J Dent Educ* 65(10):960–968, 2001.
125. Pereira AC, Eggertsson H, Martinez-Mier EA, Mialhe FL, Eckert GJ, Zero DT: Validity of caries detection on occlusal surfaces and treatment decisions based on results from multiple caries-detection methods, *Eur J Oral Sci* 117(1):51–57, 2009.
126. Twetman S, Axelsson S, Dahlen G, et al.: Adjunct methods for caries detection: a systematic review of literature, *Acta Odontol Scand* 71(3–4):388–397, 2013.
127. Diniz MB, Campos PH, Sanabe ME, et al.: Effectiveness of fluorescence-based methods in monitoring progression of noncavitated caries-like lesions on smooth surfaces, *Operat Dent* 40(6):E230–241, 2015.
128. Unal M, Kockanat A, Guler S, Gulturk E: Diagnostic performance of different methods in detecting incipient non-cavitated occlusal caries lesions in permanent teeth, *J Clin Pediatr Dent* 43(3):173–179, 2019.
129. Menem R, Barnkggei I, Beiruti N, Al Haffar I, Joury E: The diagnostic accuracy of a laser fluorescence device and digital radiography in detecting approximal caries lesions in posterior permanent teeth: an in vivo study, *Laser Med Sci* 32(3):621–628, 2017.
130. Cortes DF, Ellwood RP, Ekstrand KR: An in vitro comparison of a combined FOTI/visual examination of occlusal caries with other caries diagnostic methods and the effect of stain on their diagnostic performance, *Caries Res* 37(1):8–16, 2003.
131. Ribeiro AA, Purger F, Rodrigues JA, et al.: Influence of contact points on the performance of caries detection methods in approximal surfaces of primary molars: an in vivo study, *Caries Res* 49(2):99–108, 2015.
132. Schneiderman A, Elbaum M, Shultz T, Keem S, Greenebaum M, Driller J: Assessment of dental caries with digital imaging fiber-optic Transillumination (DIFOTI): in vitro study, *Caries Res* 31(2):103–110, 1997.
133. Ando M: Performance of digital imaging fiber-optic transillumination (DIFOTI) for detection of non-cavitated primary caries. Preliminary report. Paper presented at: 83rd General Session International Association for Dental Research, Baltimore, Maryland, 2005.
134. Astvaldsdottir A, Ahlund K, Holbrook WP, de Verdier B, Tranaeus S: Approximal caries detection by DIFOTI: in vitro comparison of diagnostic accuracy/efficacy with film and digital radiography, *Int J Dent* 2012:326401, 2012.
135. Bin-Shuwaish M, Yaman P, Dennison J, Neiva G: The correlation of DIFOTI to clinical and radiographic images in Class II carious lesions, *J Am Dent Assoc (1939)* 139(10):1374–1381, 2008.
136. Park SW, Kim SK, Lee HS, Lee ES, de Jong EdJ, Kim BI: Comparison of fluorescence parameters between three generations of QLF devices for detecting enamel caries in vitro and on smooth surfaces, *Photodiagnosis Photodyn Ther* 25:142–147, 2019.
137. Jallad M, Zero D, Eckert G, Ferreira Zandona A: In vitro detection of occlusal caries on permanent teeth by a visual, light-induced fluorescence and Photothermal radiometry and modulated Luminescence methods, *Caries Res* 49(5):523–530, 2015.
138. Ko HY, Kang SM, Kim HE, Kwon HK, Kim BI: Validation of quantitative light-induced fluorescence-digital (QLF-D) for the detection of approximal caries in vitro, *J Dent* 43(5):568–575, 2015.



## 11

# Pit-and-Fissure Sealants and Preventive Resin Restorations

BRIAN J. SANDERS

## CHAPTER OUTLINE

**Clinical Trials****Rationale for Use of Sealants****Selection of Teeth for Sealing****Sealant Technique**

Cleaning

Isolation

Etching

Washing

**Application of Sealant**

Check of Occlusal Interferences

Re-evaluation

**Preventive Resin Restoration (Sealed Composite Resin Restoration)**

► **For additional resources, please visit the website.**

In 1955 Buonocore<sup>1</sup> described the acid-etching technique as a simple method of increasing the adhesion of self-curing methyl methacrylate resin materials to dental enamel; 85% phosphoric acid was used to etch enamel for 30 seconds. This produces a roughened surface at the microscopic level, which allows for the mechanical bonding of low-viscosity resin materials.

The first materials used experimentally as sealants were based on cyanoacrylates but were not marketed. By 1965, Bowen<sup>2</sup> had developed the bis-GMA resin, which is the chemical reaction product of bisphenol A (BPA) and glycidyl methacrylate. This is the base resin used in most of the current commercial sealants. Urethane dimethacrylate and other dimethacrylates are alternative resins used in sealant materials. Dental sealant materials do not contain BPA but may contain compounds that turn into BPA on contact with saliva. There may be small amounts present for a short duration after the application of the sealant, but no detectable BPA has been reported in blood samples indicating no systemic exposure.<sup>3</sup>

For chemically cured sealants, a tertiary amine (activator) in one component is mixed with another component containing benzoyl peroxide; their reaction produces free radicals, which initiate polymerization of the sealant material.

The other sealant materials are activated by an external energy source. The early light-activated sealants were polymerized by the action of ultraviolet rays (which are no longer used) on benzoin methyl ether or higher-alkyl benzoin ethers to activate the peroxide curing system. The visible light-curing sealants have diketones and aromatic ketones, which are sensitive to visible light in the wavelength region of 470 nm (blue region). Some sealants contain filler, usually silicon dioxide microfill or even quartz.

Sealant materials may be transparent or opaque. Opaque materials are available in tooth color or white. Transparent

sealants are clear, pink, or amber. The clear and tooth-colored sealants are aesthetic but may be difficult to detect at recall examinations. Advances in sealant technology include light-activated coloring agents that allow for color change during and/or after polymerization. These compositional changes do not affect the sealant but offer the benefit in the recognition of sealed surfaces.

The cariostatic properties of sealants are attributed to the physical obstruction of pits and grooves. This prevents colonization of pits and fissures with new bacteria and also prevents fermentable carbohydrates from reaching any bacteria remaining in the pits and fissures, so that the remaining bacteria cannot produce acid in cariogenic concentrations.

## Clinical Trials

Many clinical studies have reported the success of pit-and-fissure sealants with respect to reduction in dental caries. As the longevity of the sealant increases, the retention rate becomes a determinant of its effectiveness as a caries-preventive measure.

In 1983, a National Institutes of Health Consensus Panel considered the available information on pit-and-fissure sealants and concluded that “the placement of sealants is a highly effective means of preventing pit-and-fissure caries. [...] Expanding the use of sealants would substantially reduce the occurrence of dental caries in the population beyond that already achieved by fluorides and other preventive resources.”<sup>4</sup>

In 1991, Simonsen<sup>5</sup> reported regarding a random sample of participants in a sealant study recalled after 15 years. He reported that in the group with sealants, 69% of the surfaces were sound 15 years after a single sealant application, whereas 31% were carious or restored. In the group without sealants, matched by age, gender, and residence, 17%

of the surfaces were sound, whereas 83% were carious or restored. He also estimated that a pit-and-fissure surface on a permanent first molar is 7.5 times more likely to be carious or restored after 15 years if it is not sealed with a single application of pit-and-fissure sealant.

The use of glass ionomer as a sealant material has the advantage of continuous fluoride release; in addition, it is hydrophilic and its preventive effect may continue with the visible loss of the material. Glass ionomer may be useful as a transitional sealant material in deeply fissured primary molars that are difficult to isolate due to the child's pre-cooperative behavior and in partially erupted permanent molars that the clinician believes are at risk for developing decay. Antonson et al.<sup>6</sup> concluded that glass-ionomer sealants had greater success in the sealing of partially erupted teeth and combating potential salivary contamination. In such cases, glass-ionomer materials may be considered a provisional sealant to be reevaluated and probably replaced with resin-based sealants when better isolation is possible. Long-term studies of glass-ionomer sealants have shown a poorer retention rate despite having cariostatic properties associated with fluoride release.<sup>7</sup>

A systematic review of evidence regarding the effectiveness of sealants in stabilizing or reducing bacterial levels in carious lesions found that sealants were effective in reducing total bacteria, and this number continued to decrease with the time of sealant placement. The findings of these investigators continue to support the notion that a retained sealant can deprive bacteria of access to nutrients and, therefore, can be effective in reducing caries progression.<sup>8-10</sup>

Wendt and Koch<sup>11</sup> annually followed 758 sealed occlusal surfaces in first permanent molars for 1–10 years. At the end of their study, evaluation of the surfaces that had been sealed 10 years previously revealed that only 6% showed caries or restorations. Romcke et al.<sup>12</sup> annually monitored 8340 sealants placed on high-risk (for caries) first permanent molars during a 10-year period. Maintenance resealing was performed as indicated during the annual evaluations. One year after the sealants were placed, 6% required resealing; thereafter, 2%–4% required resealing annually. After 8–10 years, 85% of the sealed surfaces remained caries-free.

A 9-year study comparing fluoride varnish application with sealant application found that sealants were less expensive and more effective than fluoride varnish in prevention of occlusal caries on permanent molars.<sup>13</sup> Retrospective studies based on billing data from large third-party databases reveal that sealant use is still surprisingly low, even in populations for whom sealants are a covered benefit.<sup>14,15</sup> Moreover, these studies show that the effectiveness of sealants in preventing the need for future restorative care on the sealed surfaces declines after the first 3 years following sealant treatment. These data argue again for the importance of vigilant recall and upkeep of sealants after placement.

There is concern with the placement of sealants immediately after topical fluoride application. Clinical and in vitro studies with topical fluoride gels do not interfere with the bonding between the sealant and enamel.<sup>16,17</sup> This may not be true for fluoride varnish application. Frazer et al.<sup>18</sup> demonstrated in an in vitro study that the placement of fluoride varnish immediately prior to sealant application

reduced the shear bond strength and had a negative effect on sealant retention. Further long-term studies are necessary prior to making specific recommendations regarding the efficacy of placing sealants immediately after fluoride varnish application.

## Rationale for Use of Sealants

In 2008 the report on “Evidence-Based Clinical Recommendations for the Use of Pit-and-Fissure Sealants” by the American Dental Association Council on Scientific Affairs concluded that sealants are effective in caries prevention and can prevent the progression of early noncavitated caries lesions.<sup>19</sup>

The American Academy of Pediatric Dentistry's Pediatric Restorative Dentistry Consensus Conference<sup>20</sup> confirmed support for sealant use and published these recommendations:

1. Bonded resin sealants, placed by appropriately trained dental personnel, are safe, effective, and underused in preventing pit-and-fissure caries on at-risk surfaces. Effectiveness is increased with good technique, appropriate follow-up, and resealing as necessary.
2. Sealant benefit is increased by placement on surfaces judged to be at high risk for, or surfaces that already exhibit, incipient caries lesions. Placing sealant over minimal enamel caries has been shown to be effective at inhibiting lesion progression. As with all dental treatment, appropriate follow-up care is recommended.
3. The best evaluation of risk is made by an experienced clinician using indicators of tooth morphology, clinical diagnostics, past caries history, past fluoride history, and present oral hygiene.
4. Caries risk, and therefore potential sealant benefit, may exist in any tooth with a pit or fissure, and at any age, including primary teeth of children and permanent teeth of children and adults.
5. Sealant placement methods should include careful cleaning of the pits and fissures without removal of any appreciable enamel. Some circumstances may indicate use of a minimal enameloplasty technique.
6. Placement of a low-viscosity, hydrophilic material-bonding layer as part of or under the actual sealant has been shown to enhance its long-term retention and effectiveness.
7. Glass-ionomer materials have been shown to be ineffective as pit-and-fissure sealants but can be used as transitional sealants.
8. The professional must be alert to new preventive methods effective against pit-and-fissure caries. These may include changes in dental materials or technology.

## Selection of Teeth for Sealing

To achieve the greatest benefit, the clinician should determine the caries risk; thus the term risk-based sealant treatment has come into use. In risk-based sealant treatment, the practitioner takes into account prior caries experience, fluoride history, oral hygiene, and fissure anatomy in determining when sealant should be applied.

Good professional judgment should be used in the selection of teeth and patients. The use of pit-and-fissure sealants is contraindicated when rampant caries or interproximal lesions are present. Occlusal surfaces that are already carious with involvement of the dentin require restoration.

All caries-susceptible surfaces should be carefully evaluated because caries is unlikely in well-coalesced pits and fissures. In this case sealants might be unnecessary or, at least, not cost-effective. Finally, although sealant application is relatively simple, the meticulous technique requires patient cooperation and should be postponed for uncooperative patients until the procedures can be properly executed.

While the cost effectiveness of sealing permanent teeth is well established, it has not been well studied for primary teeth. Chi et al.<sup>21</sup> attempted to address this concern by analyzing the cost-effectiveness comparing two primary molar sealing strategies, always seal or never seal, with the standard care for Medicaid-enrolled children. Using Iowa Medicaid claims data, they found that:

1. Primary molar sealants prevent dental disease.
2. Primary molar sealants lead to higher costs, although sealants for children at increased risk for tooth decay would be one cost-reducing strategy.
3. Compared with standard care, the incremental cost and treatment avoided for always sealing primary molars are less than the incremental cost and treatment avoided for never sealing primary molars.

In a 3-year retrospective review of the dental records from 297 children less than 6 years old and at high caries risk, Hong et al.<sup>22</sup> found that the odds of developing pit-and-fissure carious lesions on sealed primary molars were 0.055 times and 0.013 times the odds of that on nonsealed primary molars in the outpatient clinic and in the operating room, respectively. In molars that became carious, those sealed were associated with longer time to caries development in both the outpatient clinic (2.69 years) and operating room (1.97 years).

## Sealant Technique

After selection, the tooth is washed and dried, and the deep pits and fissures are re-evaluated (Fig. 11.1A). If caries is present, restoration or a combination of restoration and sealing may be indicated (see later).

Marking centric stops with articulating paper provides information so that excess sealant does not interfere with occlusion. This is not necessary when the tooth has just erupted but is helpful in a well-established occlusion.

### CLEANING

Adequate retention of the sealant requires that the pits and fissures be clean and free of excess moisture (see Fig. 11.1B and C). Acid etching completely removes the enamel pellicle, and a dental prophylaxis (even with a dental explorer) does not increase the retention of sealants. From a practical standpoint, in cases of poor oral hygiene, fissure cleansing with a rotating dry bristle brush may be beneficial.

In a laboratory study, Pope et al.<sup>32</sup> found that the use of a quarter-round bur produced the greatest penetration of the sealant into the etched enamel. The use of an aluminum oxide air abrasion system enables sealant penetration greater than that achievable by the use of pumice or a dry bristle brush alone. It is not known if the increased depth of sealant penetration will result in greater sealant retention. When pumice or aluminum oxide is used, particulate matter is left in the deep recesses of the pits, the impact of which has not been determined.

Hatibovic-Kofman et al.<sup>23</sup> measured the microleakage of sealants placed in three groups of extracted teeth. The teeth received conventional (etch), quarter-round bur, or air abrasion surface preparation. Teeth prepared with the bur exhibited the least microleakage. The amount of microleakage in the conventional and air abrasion groups was about equal.

The routine procedure of fissure eradication is probably not necessary. In fact, inappropriate or aggressive use of fissure opening or enameloplasty often removes the last of the enamel overlying the dentin at the bottoms of fissures, which leaves the tooth more susceptible to future caries in case of sealant loss. Good sealant methodology and proper sealant volume are probably more beneficial than enameloplasty.

### ISOLATION

The tooth (or quadrant of teeth) to be sealed is first isolated. Rubber dam isolation is ideal but may not be feasible in certain circumstances. Cotton rolls, absorbent shields, and high-volume evacuation with compressed air may also be used effectively.

Eidelman et al.<sup>24</sup> reported comparable retention results with the use of a rubber dam and cotton rolls for the isolation of teeth to be sealed.

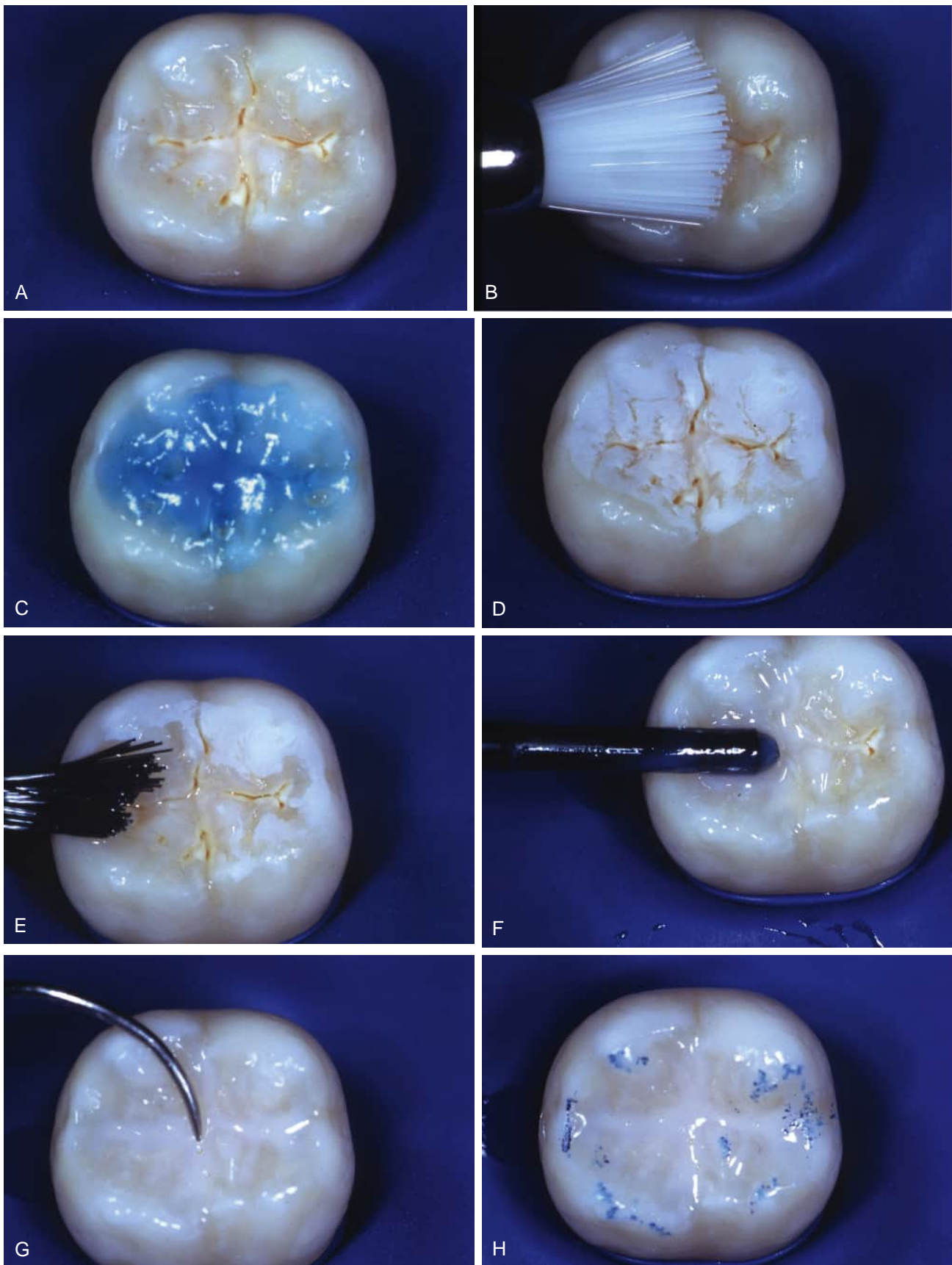
### ETCHING

Microporosities in the enamel surface are created by the acid-etching technique. This facilitates the application of a low-viscosity resin that penetrates the roughened surface and produces a mechanical lock of resin tags when cured.

Various phosphoric acid solutions have been evaluated for the etching procedure. Zidan and Hill<sup>25</sup> tested the amount of surface loss of the enamel after 60 seconds of etching with different phosphoric acid concentrations ranging from 0.5% to 80%. They reported that the maximum loss of the enamel was produced by the 35% concentrations, whereas the bond strengths were not significantly different after being etched with 2%, 5%, and 35% concentrations. Generally, 30% to 50% concentrations of acid solutions or gels are recommended.

The etchant in solution should be placed on the enamel with a brush, small sponge, cotton pellet, or applicator provided by the manufacturer. The etchant should be placed widely across the surface to be sealed, so that there is no chance that resin placement and polymerization will occur over an unetched enamel area. If a solution is used, one should gently agitate and replenish it, making an effort to avoid rubbing and breaking the enamel rods.





**Fig. 11.1** (A) An occlusal view of a molar with susceptible pits and fissures. (B) The tooth is cleaned with a rotary brush. (C) The tooth is etched. (D) The tooth appears frosty after being etched, washed, and dried. (E) The bonding agent is placed on the tooth. (F) The sealant is applied to the tooth. (G) The sealant is checked for polymerization voids and excess. (H) The occlusion is adjusted as necessary.

Occasionally a viscous gel etchant may show a “skipping” effect, which occurs when the etchant does not completely and uniformly wet the entire enamel surface, and unetched areas are evident after washing and drying. If this occurs, re-etching is necessary.

Generally a 20-second etching time is recommended. Enamel rich with fluorhydroxyapatite may be resistant to etching and may need to be exposed for longer periods. Primary teeth may also sometimes be resistant to etching and may require a longer etching time. Redford et al.<sup>26</sup> reported no increase in bond strength with 120-second etching on primary teeth compared with 15-, 30-, and 60-second etching times. Their in vitro study showed that the etch depth increased between 60 and 120 seconds, but there was no corresponding increase in the bond strength.

Some advocate preparing the enamel for sealant application with an aluminum oxide air abrasion system or a laser system approved for hard tissue procedures. Overall, while the retention rate of sealants was slightly higher when using a laser (Waterlase, Biolase Technology, San Clemente, CA), the difference was not statistically significant.<sup>27</sup> To date, studies indicate that additional acid etching is needed after each of these techniques to allow for adequate resin bonding to the enamel.

## WASHING

Most manufacturers’ instructions advocate a thorough washing and drying of the etched tooth surface but do not specify a time interval, though Norling<sup>28</sup> advocated a washing time of 20 seconds.

The etched enamel is dried with a compressed air stream that is free of oil contaminants. The dry etched enamel should exhibit a characteristic frosty appearance (Fig. 11.1D).

Feigal et al.<sup>29</sup> found that the use of a dentin-bonding agent increased sealant retention in teeth even when salivary contamination occurred. Choi et al.<sup>30</sup> have reported similar corresponding findings in vitro on moisture-contaminated bovine enamel.

Although the recommendation is still to avoid moisture contamination whenever possible during sealant application, the use of a dentin-bonding agent as part of the technique may be warranted (Fig. 11.1E). Furthermore, the use of a dentin-bonding agent is recommended in clinical situations that do not lend themselves to strict isolation.<sup>31</sup> The use of a dentin-bonding agent is also advantageous on the buccal surfaces of molars, which traditionally have shown a lower retention rate than the occlusal surfaces of teeth.<sup>32</sup> When used, the bonding agent must be thoroughly air-dried across the surface to be sealed to avoid a thick layer of adhesive residue.

## APPLICATION OF SEALANT

### Chemically cured sealant

The manufacturer’s instructions should be followed. Precise mixing without vigorous agitation can help prevent the formation of air bubbles.

The addition of the catalyst to the base immediately begins the polymerization of the material, and this should be kept in mind so that no time is lost in carrying the material to the etched and dried tooth. Working time is limited with a chemically cured sealant.

### Visible light-cured sealant

The curing of a light-polymerized sealant is not completed without the exposure of the material to the curing light, but the operating light and ambient light can also affect the material over a period of time; therefore, material should be dispensed only when it is time to place it on the tooth. The working time is longer than that with chemically cured sealant. The method of placement varies with the different applicators provided by the manufacturers. The sealant is applied to the prepared surface in moderation and then gently teased with a brush or probe into the pits and grooves (Fig. 11.1F and G). With careful application, incorporation of air bubbles is avoided. Care should also be taken to avoid applying large amounts of the sealant material.

If a light-curing material is used, the intensity of the light should be considered. If a large surface area requires polymerization, place the light directly over each area of the occlusal surface for the recommended time.

With light-cured sealants, there is less chance for the incorporation of air bubbles because no mixing of materials is required. After the material has been cured and while the treated teeth are still isolated, the unpolymerized surface layer should be removed by washing and drying to avoid an unpleasant taste.

## CHECK OF OCCLUSAL INTERFERENCES

Articulating paper should be used to check for occlusal interferences, and the occlusion should be adjusted if necessary (Fig. 11.1H). All centric stops should be on the enamel.

If a filled sealant has been used, it is essential to adjust the occlusion before the patient is dismissed.

Other excess sealant that may have flowed over the marginal ridge or toward the cervical area should also be removed. If the tooth is isolated with a rubber dam, the excess should be removed before the rubber dam is detached. A small round bur at slow speed will remove the excess effectively. If etchant has been well localized, excess sealant may be removed with a sharp instrument from the unetched tooth enamel without removing sealant from the etched groove areas.

## RE-EVALUATION

It is important to recognize that sealed teeth should be observed clinically at periodic recall visits, so that the effectiveness of the sealant can be determined. Periodic recall and reapplication of sealants are necessary because it is estimated that 5% to 10% of sealants need to be repaired or replaced yearly. If a sealant is partially or completely lost, any discolored or defective old sealant should be removed and the tooth re-evaluated. A new sealant can be applied using the method previously described.

## Preventive Resin Restoration (Sealed Composite Resin Restoration)

The preventive resin restoration is an alternative procedure for restoring young permanent teeth that require only

minimal tooth preparation for caries removal but also have adjacent susceptible fissures.

Simonsen and Stallard<sup>33</sup> described the technique of removing only the carious tooth structure in small class I cavities. A resin restoration was then placed, and the adjacent pits and fissures were sealed at the same time.

Henderson and Setcos<sup>34</sup> described the sequence of the preventive resin restoration that is particularly applicable for young patients with recently erupted teeth and minimally carious pits and fissures. They pointed out that this preparation requires a meticulous technique that involves more time than the traditional occlusal amalgam restoration. This type of restoration was advocated for carefully selected non-stress-bearing areas to minimize anatomic wear.

Occlusal surfaces often have small carious pits. For minimal caries, restorations are not likely to be subjected to substantial stresses that might lead to wear of resin materials. Fig. 11.2 shows diagrams illustrating the principles of the sealant-composite combination. In this case, a small caries lesion has penetrated the dentin. In general, bitewing radiographs should indicate no interproximal caries.

A clinical series showing the sequence for this conservative preparation and restoration is portrayed in Fig. 11.3. Caries is identified by careful visual examination of a dry occlusal tooth surface using an explorer, a mirror, and a light (Fig. 11.3A). Articulating paper marks on the tooth would indicate the points of occlusal contact.

The tooth is anesthetized if necessary, isolated, and re-examined so that the extent of the caries process can be determined. A No. 329 bur or a laser system approved for hard tissue can be used to gain access to the depth of the lesion and to complete caries removal (Fig. 11.3B). The preparation, which should not extend to the occlusal contact marks, is washed, dried, and examined.

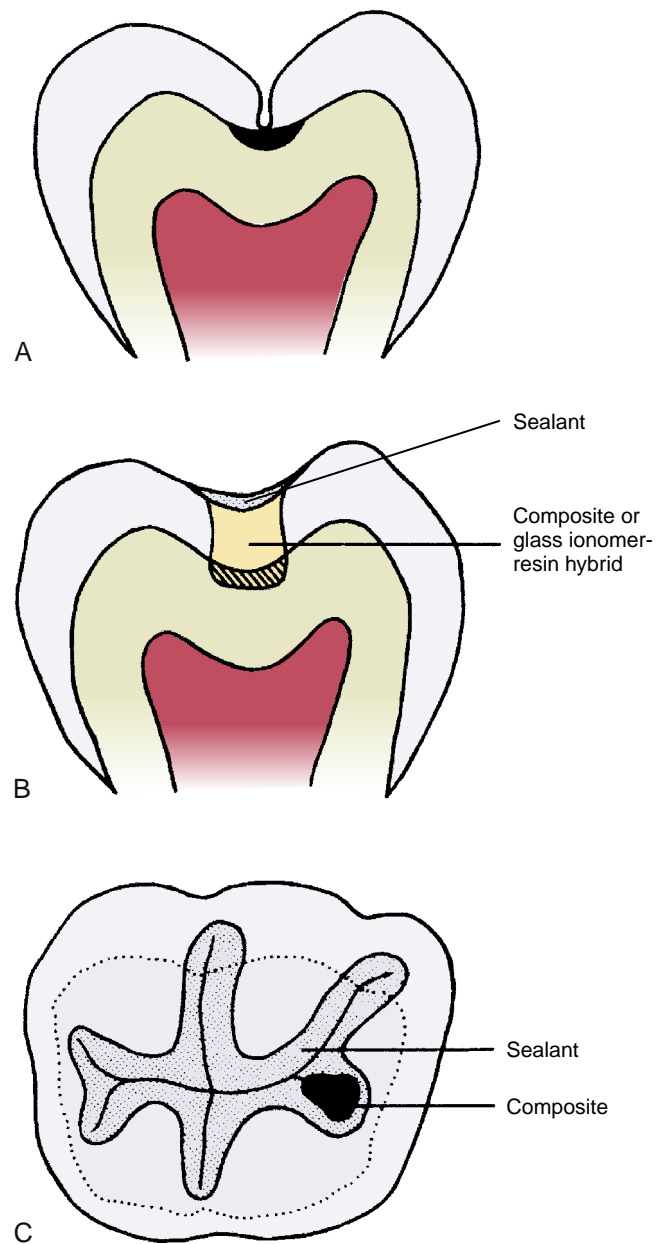
The cavity and the enamel beside the susceptible grooves are etched (Fig. 11.3C). A gel or liquid form of 37% phosphoric acid is commonly used for 20 seconds. Surface preparation with aluminum oxide air abrasion or a laser system approved for hard tissue may not substitute for acid etching. If these cleaning methods are used, etchant must still be applied to provide adequate resin-bonding enamel. The lingual grooves of maxillary molars and the buccal grooves of mandibular molars are also commonly etched and sealed. The tooth is thoroughly washed for approximately 30 to 40 seconds and completely dried.

A thin layer of bonding agent is applied to the cavity (Fig. 11.3D). A stream of air must be used to thin the bonding agent and to prevent pooling of bonding agent in the cavity.

The cavities are filled with a light-curing composite or resin-modified glass ionomer, which may be cured at this time (Fig. 11.3E). A light-curing sealant is placed over the remaining susceptible areas and brushed into the pits and grooves (Fig. 11.3F). The materials are polymerized with visible light in accordance with the manufacturer's instructions.

The rubber dam is removed, and the occlusal contacts are checked. A small-particle diamond rotary instrument or finishing bur may be used to remove the excess sealant and ensure centric stops on the enamel (Fig. 11.3G and H).

A meticulous technique is used in the selection, preparation, and restoration of minor pit-and-fissure caries with the preventive resin restoration.



**Fig. 11.2** Diagrams illustrating the sealed composite resin restoration. (A) A cross-section showing caries extending to the dentin. (B) A cross-section through a preparation with a glass-ionomer or composite restoration and a sealant. (C) An occlusal view of the outline of a small restoration where a pit-and-fissure sealant illustrates the extension-for-prevention principle of cavity preparation.

The long-term effectiveness of the bonded restoration with sealant overlay has been proven. The restorations have success equivalent to or better than that of amalgam restorations. Once again, however, success is dependent upon whether the sealant remains intact.

The use of flowable composite systems is also gaining popularity because they are easy to apply and because evidence shows that less microleakage occurs with these systems than when teeth are restored with condensable composite resins, such as sealant materials that have slightly more filler than filled sealants. Therefore the practical results of sealing with a flowable or a filled sealant should not differ.



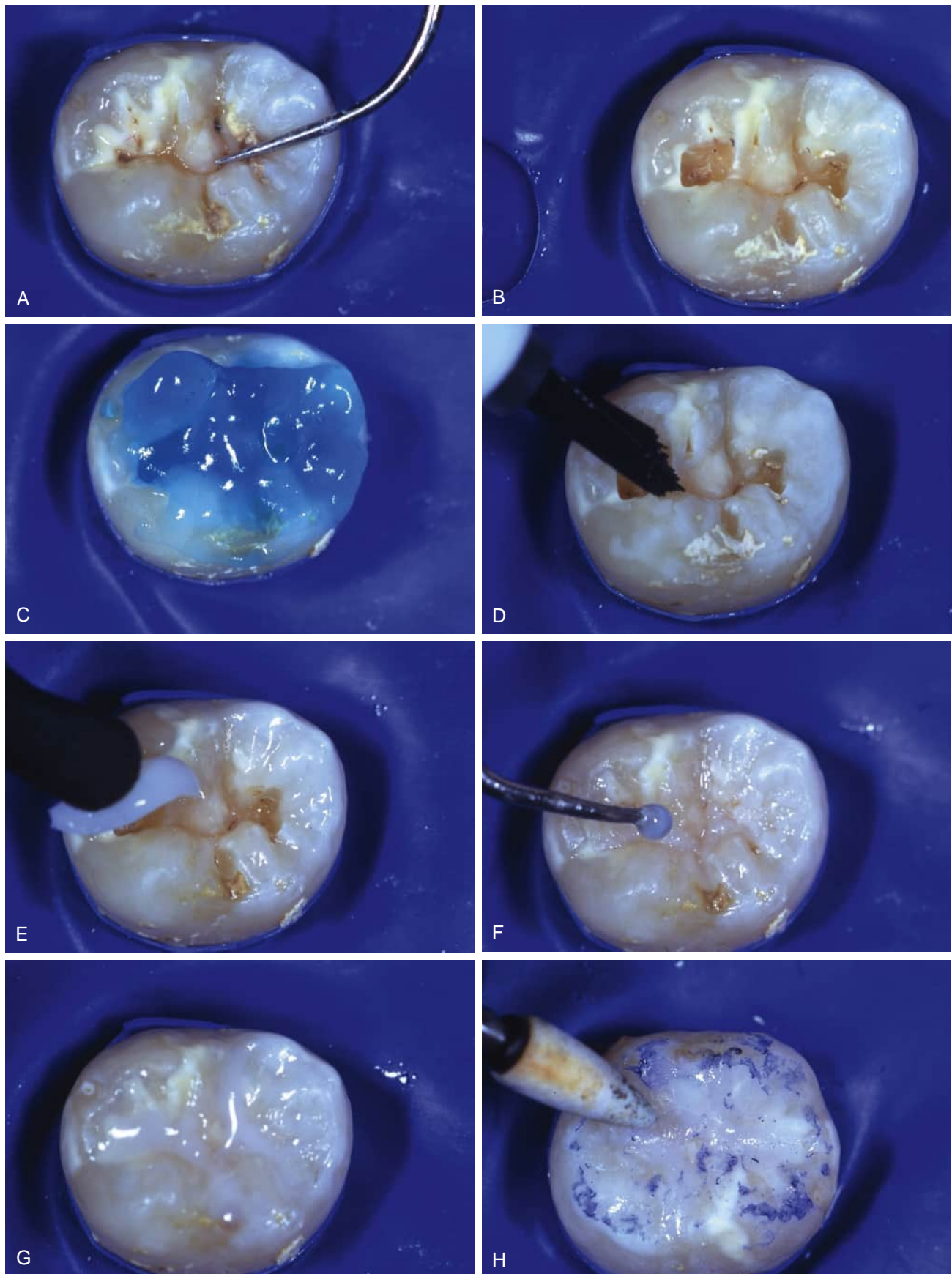


Fig. 11.3 (A) Occlusal caries identified with susceptible pits and grooves. (B) Caries is removed from the dentin. (C) The tooth is etched. (D) The bonding agent is placed. (E) Composite resin is placed. (F) Sealant is placed over resin. (G) Polymerized preventive resin restoration. (H) The occlusion is adjusted.

There is no single perfect conservative restoration. Each dentist must decide, on an individual basis, the appropriate type of procedure. The restoration described can be very effective in carefully selected cases.

Walker et al.<sup>35</sup> reported on preventive resin restorations placed in patients aged 6 to 18 years and observed for up to 6.5 years. Of the 5185 restorations, 83% did not require further intervention. Those requiring intervention included 37% that needed sealant alone and 21% that required treatment because of the development of an interproximal lesion. Houpt et al.<sup>36</sup> reported complete retention of 54% of their preventive resin restorations, partial loss of sealant in 25%, and complete loss of sealant in 20% after 9 years. Caries occurred in 25% of the teeth that had sealant loss and 88% of the restored surfaces remained caries-free 9 years after treatment. These researchers concluded that preventive restorations produce excellent long-term results. Conservative cavity preparation with sealing for prevention is a successful approach for treating selected decayed teeth.

## References

- Buonocore MG: A simple method of increasing the adhesion of acrylic filling materials to enamel surfaces, *J Dent Res* 34(6):849–853, 1955.
- Bowen RL: Method of preparing a monomer having phenoxy and methacrylate groups linked by hydroxyl glycerol groups, *US Patent No 3 194:783*, 1965.
- Rathee M, Malik P, Singh J: Bisphenol A in dental sealants and its estrogen like effect, *India J Endocrinol Metab* 16(3):339–342, 2012.
- Dental sealants in the prevention of tooth decay. Proceedings of the National Institutes of Health Consensus Development Conference, *J Dent Educ* 48:4–131, 1984.
- Simonsen RJ: Retention and effectiveness of dental sealant after 15 years, *J Am Dent Assoc* 122(10):34–42, 1991.
- Antonson SA, Antonson DE, Brener S, et al.: Twenty-four month clinical evaluation of fissure sealants on partially erupted permanent first molars, *J Am Dent Assoc* 143(2):115–122, 2012.
- Baseggio W, Scarparo Naufel F, de Oliveira Davidoff DC, et al.: Caries preventive efficacy and retention of a resin modified glass ionomer cement and a resin based fissure sealant: a 3 year split mouth randomized clinical trial, *Oral Health and Prev Dent* 8(3):261–268, 2010.
- Griffin SO, Oong E, Kohn W, et al.: The effectiveness of sealants in managing caries lesions, *J Dent Res* 87(2):169–174, 2008.
- Azarapazhooh A, Main PA: Pit and fissure sealants in the prevention of dental caries in children and adolescents: a systematic review, *J Can Dent Assoc* 74(2):171–177, 2008.
- Oong EM, Griffin SO, Kohn WG, et al.: The effect of dental sealants on bacteria levels in caries lesions, *J Am Dent Assoc* 139(3):271–278, 2008.
- Wendt LK, Koch G: Fissure sealant in permanent first molars after 10 years, *Swed Dent J* 12(5):181–185, 1988.
- Romcke RG, Lewis DW, Maze BD, et al.: Retention and maintenance of fissure sealants over 10 years, *J Can Dent Assoc* 56(3):235–237, 1990.
- Khouja T, Smith KJ: Cost effectiveness analysis of two caries prevention methods in the first permanent molar in children, *J Public Health Dent* 78(2):118–126, 2017.
- Dennison JB, Straffon LH, Smmith RC: Effectiveness of sealant treatment over five years in an insured population, *J Am Dent Assoc* 131(5):597–605, 2000.
- Robison VA, Rozier RG, Weintraub JA: A longitudinal study of school children's experience in the North Carolina dental Medicaid program, 1984 through 1992, *Am J Public Health* 88(11):1669–1673, 1998.
- Koh SH, Chan JT, You C: Effects of topical fluoride treatment on tensile bond strength of pit and fissure sealants, *Gen Dent* 46(3):278–280, 1998.
- Warren DP, Infante NB, Rice HC, et al.: Effect of topical fluoride on retention of pit and fissure sealants, *J Dent Hyg* 75(1):21–24, 2001.
- Frazer RA, Platt JA, Sanders BJ, et al.: The effect of fluoride varnish enamel bond strength of pit and fissure sealants, *Pediatr Dent* 39(2):155–158, 2017.
- Beauchamp J, Caufield PW, Crall JJ, et al.: Evidence based clinical recommendations for the use of pit and fissure sealants, *J Am Dent Assoc* 139(3):257–268, 2008.
- Papers from the Pediatric Restorative Dentistry Consensus Conference. San Antonio, Texas. April 15–16, 2002, *Pediatr Dent* 24(5):374–516, 2002.
- Chi DL, van der Goes DN, Ney JP: Cost-effectiveness of pit-and-fissure sealants on primary molars in Medicaid-enrolled children, *Am J Pub Health* 104(3):555–561, 2014.
- Hong M, et al.: Sealed primary molars are less likely to develop caries, *J Am Dent Assoc* 150(8):641–648, 2019.
- Pope JB, Garcia-Godoy F, Summitt JB, et al.: Effectiveness of occlusal fissure cleansing methods and sealant micromorphology, *J Dent Child* 63(3):175–180, 1996.
- Hatibovic-Kofman S, Wright GZ, Braverman I: Microleakage of sealants after conventional, bur, and air-abrasion preparation of pits and fissures, *Pediatr Dent* 20:173–176, 1998.
- Eidelman E, Fuks AB, Chosack A: The retention of fissure sealants: rubber dam or cotton rolls in a private practice, *J Dent Child* 50(4):259–261, 1983.
- Zidan O, Hill G: Phosphoric acid concentration: enamel surface loss and bonding strength, *J Prosthet Dent* 55(3):388–391, 1986.
- Redford DA, Clarkson BH, Jensen M: The effect of different etching times on the sealant bond strength, etch depth, and pattern in primary teeth, *Pediatr Dent* 8(1):111–115, 1986.
- Kumar G, Dhillon JK, Rehman F: A comprehensive evaluation of retention of pit and fissure sealants placed with conventional acid etching and Er, Cr:YSGG laser etching: a randomized control study, *Laser Ther* 25(4):291–298, 2016.
- Norling BK: Bonding. In: Anusavice KJ editor: Phillips' science of dental materials, ed 11, St Louis, Saunders, 2003.
- Feigal RJ, Hitt J, Splieth C: Retaining sealants on salivary contaminated enamel, *J Am Dent Assoc* 124(3):88–96, 1993.
- Choi JW, Drummond JL, Dooley R, et al.: The efficacy of primer on sealant shear bond strength, *Pediatr Dent* 19:286–288, 1997.
- Feigal RJ: Sealants and preventive restorations: review of effectiveness and clinical changes for improvement, *Pediatr Dent* 20:85–92, 1998.
- Feigal RJ, Musherure P, Gillespie B, et al.: Improved sealant retention with bonding agents: a clinical study of two-bottle and single-bottle systems, *J Dent Res* 79(11):1850–1856, 2000.
- Simonsen RJ, Stallard RE: Sealant-restorations utilizing a diluted filled composite resin: one year results, *Quintessence Int* 8(6):77–84, 1977.
- Henderson HZ, Setcos JC: The sealed composite resin restoration, *J Dent Child* 52(4):300–302, 1985.
- Walker J, Floyd K, Jakobsen J, et al.: The effectiveness of preventive resin restorations in pediatric patients, *J Dent Child* 63(5):338–340, 1996.
- Houpt M, Fuks A, Eidelman E: The preventive resin (composite resin/sealant) restoration: nine-year results, *Quintessence Int* 25(3):155–159, 1994.

## 12

# Restorative Dentistry

KEVIN J. DONLY and JEFFREY A. DEAN

**CHAPTER OUTLINE****Introduction****Status of Common Restorative Materials****Maintenance of a Clean Field**

Armamentarium for Rubber Dam Placement

## SELECTION OF A CLAMP

**Isolite System****Morphologic Considerations****Basic Principles in Cavity Preparation in Primary Teeth****Cavity Preparation in Primary Teeth**

INCIPIENT CLASS I CAVITY IN A VERY YOUNG CHILD

PIT OR FISSURE CLASS I CAVITY

Deep-Seated Class I Cavity

Class II Cavity

Class III Cavity

Modified Class III Cavity Preparation

**Restoration of Proximal Incisal Caries in Primary Anterior Teeth**

Aesthetic Resin Restoration

Stainless-Steel Crowns

Direct Resin Crowns

**Preparation of Cavities in Young Permanent Teeth**

Interim Therapeutic Restoration for Hypoplastic or Hypomineralized Permanent Molars

**Stainless-Steel Crowns for Posterior Teeth**

Preparation of the Tooth

Selection of the Crown Size

Contouring of the Crown (When Necessary)

**Cosmetic Zirconia Crowns****Alternative Restorative Treatment****Cosmetic Restorative Procedures for Young Permanent Anterior Teeth**

Bonded Composite Veneer Restorations (Resin-Based Composite Bonding)

Bonded Laminate Veneer Restorations (Dental Laminates or Laminate Veneers)

**Controversies in Pediatric Restorative Dentistry**

Laser Use

Minimalist Approach to Restorative Care

**Bleaching and Microabrasion**

## Introduction

Advances in preventive dentistry and their application in the private dental office, the widespread acceptance of communal fluoridation, and greater emphasis on dental health education have dramatically changed the nature of dental practice. Today the dentist devotes more time to preventive procedures and less time to the routine restoration of caries-affected teeth.

Nevertheless, restoration of carious lesions in primary and young permanent teeth continues to be among the important services that pediatric dentists and general practitioners provide for the children in their practices. Patients and fellow practitioners often judge dentists on the effectiveness of their preventive programs and the skill with which they perform routine operative procedures.

The Reference Manual of the American Academy of Pediatric Dentistry (AAPD) includes a Guideline on Pediatric Restorative Dentistry (revised in 2020) that states the following, in part<sup>1</sup>:

Restorative treatment is based on the results of an appropriate clinical examination and is ideally part of a comprehensive treatment plan. The treatment plan should consider the following:

1. The developmental status of the dentition.
2. A caries-risk assessment.

3. Patient's oral hygiene.
4. Anticipated parental compliance and likelihood of timely recall.
5. Patient's ability to cooperate for treatment.

The caries management plan must be prepared in conjunction with an individually tailored program, including considerations such as child and parent preferences (child-centered care), child's age, medical and dental history, and extent of treatment needs. In addition, restoration of primary teeth differs significantly from restoration of permanent teeth, partly due to the differences in tooth morphology.

In 2002 AAPD, with financial assistance from the American Society of Dentistry for Children, held a pediatric restorative dentistry consensus conference in San Antonio, Texas. Sixteen literature review and position papers were presented at the conference, and numerous consensus statements about appropriate pediatric restorative materials and procedures were developed. The papers and consensus statements are compiled in the September/October 2002 issue of *Pediatric Dentistry*. These consensus statements were updated at the *AAPD Pediatric Restorative Dentistry Symposium* and are published in the March/April 2015 issue of *Pediatric Dentistry*.



## Status of Common Restorative Materials

Advances in the development of improved biomaterials for dental restorations have been rapid, and they continue to occur at a fast pace. This fact creates a significant challenge for dentists striving to remain at the cutting edge of dental technology. The more common restorative materials used in pediatric dentistry are composite and other resin systems, glass ionomers, silver amalgam alloys, and stainless-steel alloys. Porcelain, zirconia, and cast metal alloy materials are also used in pediatric restorative dentistry but less frequently than those listed in the previous sentence.

Resin-based composites, glass ionomers, or some combination of the two are being used progressively more and silver amalgam progressively less in pediatric restorative dentistry. Many pediatric dentistry practices do not use silver amalgam at all; instead, some form of resin-based composite or glass ionomer is used. These materials have bonding capability. Glass ionomers may be considered pharmacologically therapeutic because they release fluoride over time; they also have minimal shrinkage during setting. Resin-based composites possess durability and superior aesthetic qualities. When managed properly, both materials are capable of providing excellent marginal sealing at the tooth-material interface. The manufacturers of these materials have also combined them in an effort to bring together the primary advantages of each type of material. Berg<sup>2</sup> has suggested that we think of these materials and their combinations on a continuum, with glass ionomer on the left, resin-based composite on the right, and the combined materials somewhere in between, depending on the relative amounts of each material in the mix. Two major categories on the continuum are described as “resin-modified glass ionomer” (“hybrid ionomer” or “light-cured glass ionomer”) and “compomers” (“polyacid-modified composite resin” or “glass ionomer-modified resin-based composite”). A fifth formulation has been added on the right side of the continuum in the form of “flowable resin-based composite.” Berg<sup>2</sup> points out that knowing the particular strengths and weaknesses of each type of material on the continuum will enhance the clinician’s ability to make the best choices for each individual restorative situation. Use of any of these restorative materials generally requires more effort and time than those needed for corresponding conventional amalgam restorations.

Despite its declining use, silver amalgam remains one of the most durable and cost-effective restorative materials. Success in using this filling material depends on adherence to certain principles of cavity preparation that do not always apply when materials on the glass-ionomer-composite-resin continuum are used. The development of “bonded amalgams” has resulted in renewed interest in silver amalgam. Bonded amalgams are silver amalgam restorations that have been condensed into etched cavity preparations lined with a dentin-bonding agent and some material on the glass-ionomer-composite-resin continuum. Bonded amalgams require considerable extra effort and expense to place compared with conventional amalgam restorations. The improvements in tooth support and

marginal integrity gained with these restorations have been demonstrated in many studies. Some longer-term studies, however, suggest that the advantages of bonded amalgams may be transient and relatively short-lived, possibly 1 year or less.<sup>3,4</sup> In general, the use of bonded amalgams seems difficult to justify for the routine restoration of primary teeth because traditional silver amalgam provides comparable quality more efficiently and cost-effectively in most situations.

Stainless-steel alloy is another commonly used pediatric restorative material. It is used extensively for full coronal coverage restorations of primary teeth. Stainless-steel crowns have undoubtedly preserved the function of many primary teeth that otherwise would have been unrestorable. Furthermore, stainless-steel crowns are often used to restore all posterior teeth in young patients with high risk for caries who exhibit multiple proximal lesions that could otherwise be restored with silver amalgam or aesthetic materials. Crowns are used instead simply because they better protect all posterior tooth surfaces from developing additional caries and because the posterior crown restoration has proven to be the most durable and cost-effective in the primary dentition. Anterior and posterior stainless-steel crowns may have labial and/or occlusal resin or porcelain veneers to enhance aesthetics.

## Maintenance of a Clean Field

The maintenance of a clean operating field during cavity preparation and placement of the restorative material helps ensure efficient operation and development of a serviceable restoration that will maintain the tooth and the integrity of the developing occlusion.

The rubber dam aids in the maintenance of a clean field. The use of the rubber dam is known to offer the following advantages:

1. Saves time. The dentist who has not routinely used the rubber dam needs only to follow the routine presented later in this chapter or a modification of it for a reasonable period to be convinced that operating time can be appreciably reduced. The time spent in placing the rubber dam is negligible as long as the dentist works out a definite routine and uses a chairside assistant. Heise<sup>5</sup> reported an average time of 1 minute and 48 seconds to isolate an average of 2.8 teeth with the rubber dam in 302 cases. These applications of the rubber dam, placed with the aid of a capable dental assistant, were for routine operative dentistry procedures. The minimum time recorded for placing a rubber dam was 15 seconds (single-tooth isolation), and the maximum time was 6 minutes. Many of the applications ranged from 25 to 50 seconds. Heise<sup>5</sup> also observed that approximately 10 seconds are required to remove the rubber dam. The elimination of rinsing and spitting by the pediatric patient will invariably make up for the time required for the placement of the rubber dam and may save additional time.
2. Aids management. A few explanatory words and reference to the rubber dam as a “raincoat” for the tooth or as a “Halloween mask” help allay the child’s anxiety. It

has been found through experience that apprehensive or otherwise uncooperative children can often be controlled more easily with a rubber dam in place. Because the rubber dam efficiently controls the patient's tongue and lips, the dentist has greater freedom to complete the operative procedures.

3. Controls saliva. Control of saliva is an extremely important consideration when one is completing an ideal cavity preparation for primary teeth. The margin of error is appreciably reduced when a cavity is prepared in a primary tooth that has a large pulp and extensive caries involvement. Small pulp exposures may be more easily detected when the tooth is well isolated. It is equally important to observe the true extent of the exposure and the degree and type of hemorrhage from the pulp tissue. Thus the rubber dam aids the dentist in evaluating teeth that are being considered for vital pulp therapy.
4. Provides protection. The use of the rubber dam prevents foreign objects from coming into contact with oral structures. When filling material, debris, or medicaments are dropped into the mouth, salivary flow is stimulated and interferes with the operative or restorative procedure. A rubber dam also prevents the small child in a reclining position from swallowing or aspirating foreign objects and materials.
5. Helps the dentist educate parents. Parents are always interested in the treatment that has been accomplished for their child. While the rubber dam is in place, the dentist can conveniently show parents the completed work after an operative procedure. The rubber dam creates the feeling that the dentist has complete control of the situation and that a conscientious effort has been made to provide the most efficient service.

### ARMAMENTARIUM FOR RUBBER DAM PLACEMENT

The armamentarium consists of 5 × 5-inch sheets of medium latex, a rubber dam punch, clamp forceps, a selection of clamps, a flat-blade instrument, dental floss, and a rubber dam frame. If one visualizes an approximately 1 1/4-inch square in the center of a sheet of rubber dam, each corner of the square indicates where the punch holes for the clamp-bearing tooth in each of the four quadrants of the mouth are to be made (Fig. 12.1). As experience is gained in applying the dam, the dentist and assistant will soon learn the proper location for punching the holes. If the holes are punched too far apart, the dam will not readily fit between the contact areas. In addition, the greater bulk of material between the teeth will greatly increase the possibility that the rubber will become a barrier to proximal surface preparation. Conversely, if the holes are punched too close together, salivary leakage will contaminate the operating field. In general, the holes should be punched the same distance apart as the holes on the cutting table of the rubber dam punch.

The large punch hole is used for the clamp-bearing tooth and for most permanent molars, the medium-sized punch hole is generally used for the premolars and primary molars, the second smallest hole is used for maxillary permanent incisors, and the smallest hole is adequate for the primary incisors and lower permanent incisors.

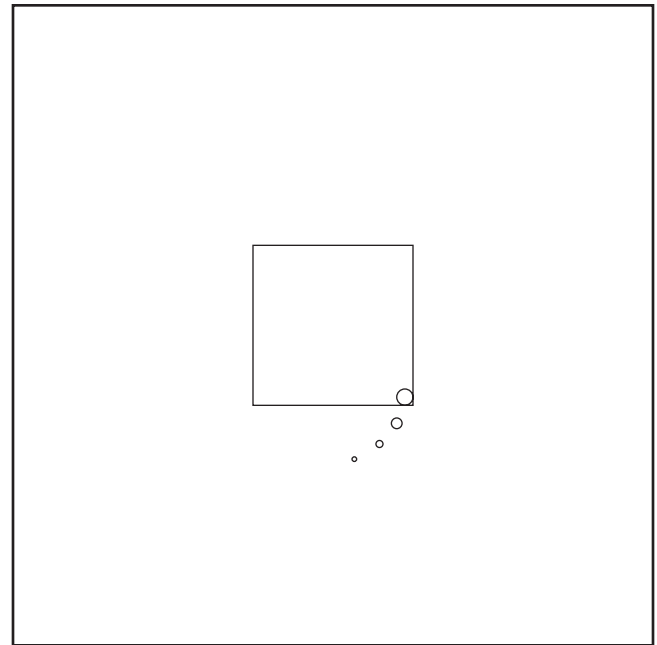


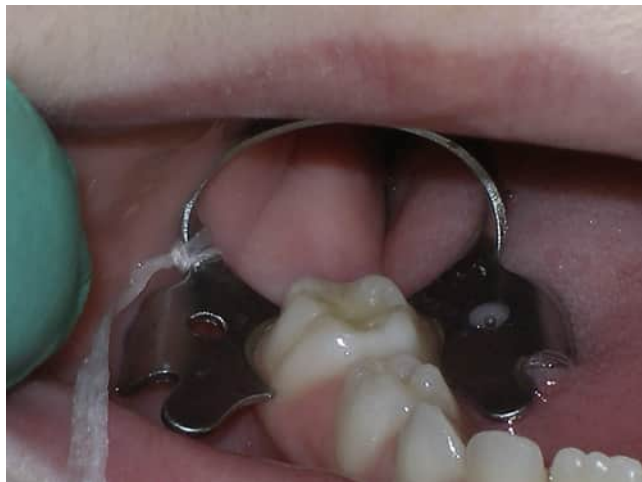Fig. 12.1 The corners of the square represent points where punch holes should be made for the clamp-bearing tooth.

### SELECTION OF A CLAMP

The operator will soon develop a personal preference for specific clamps to use to secure the dam in isolating different areas in the mouth. Unless the clamp is firmly anchored to the tooth, the tension of the stretched rubber will easily dislodge it. Therefore proper selection of a clamp is of utmost importance. It is recommended that the clamp be tried on the tooth before the rubber dam is placed to ascertain that the clamp can be securely seated and will not be easily dislodged by the probing tongue, lip, or cheek musculature. An 18-inch-long dental floss should be doubled and securely fastened to the bow of the clamp. The floss will facilitate retrieval in the unlikely event that the clamp slips and falls toward the pharynx (Fig. 12.2).

The following procedure is recommended for rubber dam application (Fig. 12.3). The previously selected and ligated clamp is placed in the rubber dam. The dentist grasps the clamp forceps with the clamp engaged. The assistant, seated to the left of the patient (the dentist is right-handed in this example), grasps the upper corners of the dam with the right hand and the lower left corner between the left thumb and index finger. The dam is moved toward the patient's face as the dentist carries the clamp to the tooth while holding the lower right portion of the dam. After securing the clamp on the tooth, the dentist transfers the clamp forceps to the assistant, who receives it while continuing to hold the upper corners of the dam with the right hand. The dentist then places the frame over the rubber dam. Together the assistant and dentist attach the corners of the dam to the frame. The flat blade of a plastic instrument or a right-angle explorer may be used to remove the rubber dam material from the wings of the clamp and to complete the seal around the clamped tooth. If necessary, light finger pressure may

seat the clamp securely by moving it cervically on the tooth. If additional teeth are to be isolated, the rubber is stretched over them, and the excess rubber between the punched holes is placed between the contact areas with



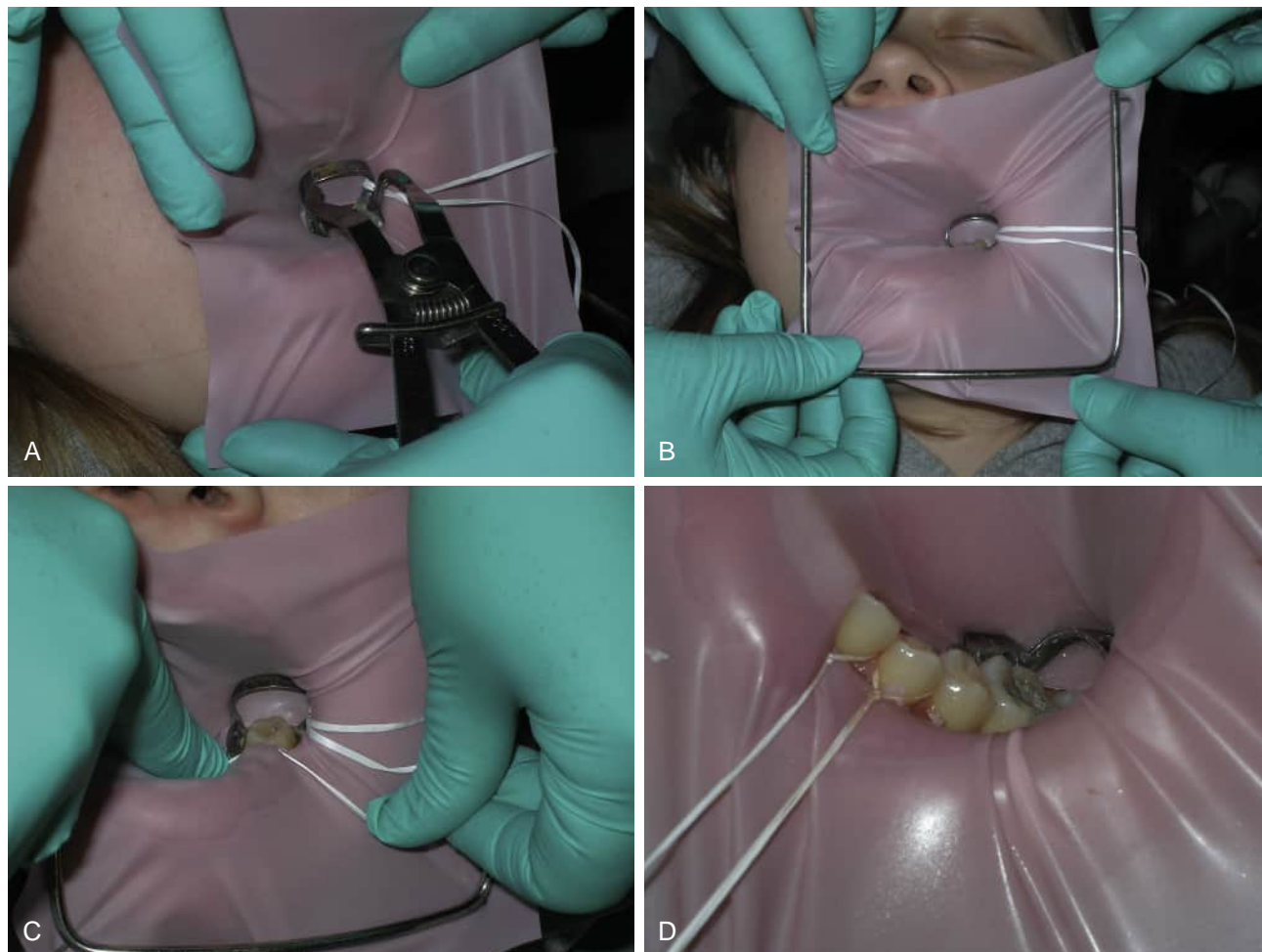
**Fig. 12.2** An Ivory No. 3 clamp has been trial-fitted to the second primary molar. The clamp will be removed and placed in the rubber dam.

the aid of dental floss. The most anterior tooth and others, if necessary, are ligated to aid in the retention of the dam and prevention of cervical leakage. The free ends of the floss are allowed to remain because they may aid in further retraction of the gingival tissue or the patient's lip during the operative procedure. At the end of the operative procedure, the length of floss will also aid in removing the ligature.

When a quadrant of restorations in the primary dentition is planned and no pulp therapy is anticipated, Croll<sup>6</sup> recommends the "slit-dam method." One long opening is made in the dam, and the entire quadrant is isolated without interseptal dam material between the teeth.

It is unwise to include more teeth in the rubber dam than are necessary to isolate the working area adequately. If the first or second permanent molar is the only tooth in the quadrant that exhibits caries and if it requires only an occlusal preparation, it is often desirable to punch only one hole in the dam and isolate the single tooth (Fig. 12.4). This procedure will require only seconds and will save many minutes.

Due to an increase in latex allergies, latex-free rubber dams are available and used in the same manner already described.



**Fig. 12.3** (A) The dental assistant holds the top and lower right corners of the rubber dam as the dentist holds the lower left corner and carries the clamp to the tooth. (B) The assistant and dentist attach the corners of the rubber dam to the frame. (C) Dental floss is used to carry the rubber dam between the teeth. (D) The teeth are isolated and ready for the operative procedure. (A, B, C, and D Courtesy of Dr. Richard Troyer.)



## Isolite System

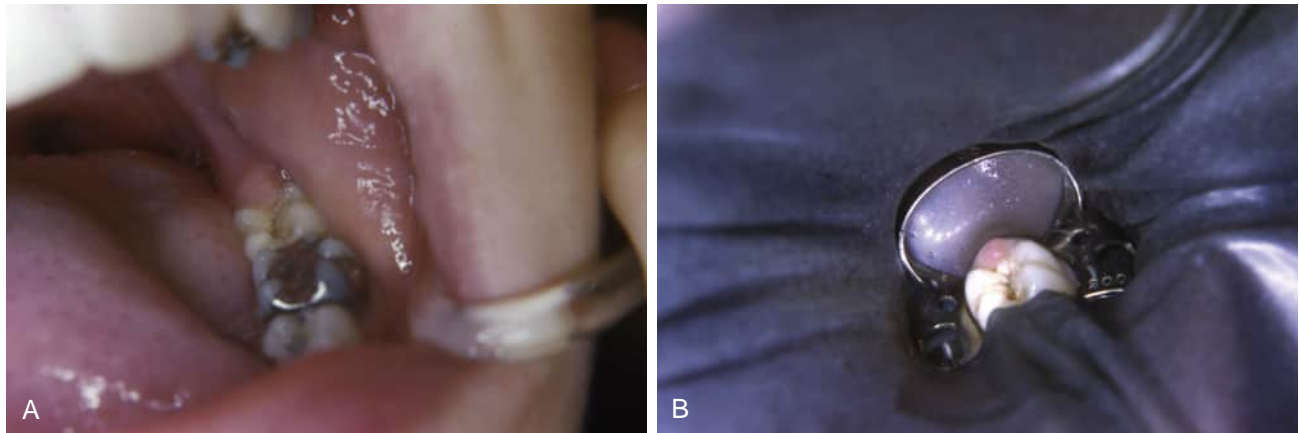
The Isolite system has also been recommended for achieving an isolated field. This dental isolation device is designed to function as a vacuum suction and to provide intraoral illumination. The system helps retract the tongue and has an integrated 6-foot-long vacuum-powered silicone hose that connects easily to most standard high-volume ports (Fig. 12.5).<sup>7</sup>

## Morphologic Considerations

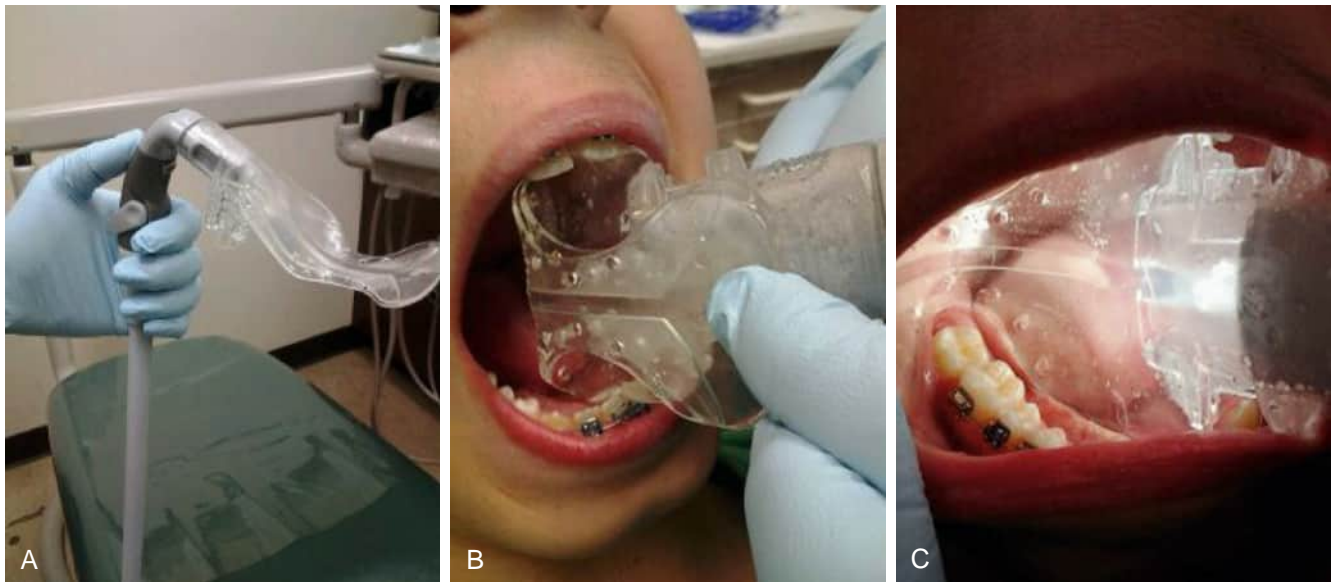
The crowns of the primary teeth are smaller but more bulbous than those of the corresponding permanent teeth, and the molars are bell-shaped, with a definite constriction in the cervical region. The characteristic sharp

lingual inclination occlusal to the facial surfaces results in the formation of a distinct faciogingival ridge that ends abruptly at the cemento-enamel junction. The sharp constriction at the neck of the primary molar necessitates special care in the formation of the gingival floor during class II cavity preparation. The buccal and lingual surfaces of the molars, sharply converging occlusally, form a narrow occlusal surface or food table; this is especially true of the first primary molar.

The pulpal outline of the primary teeth follows the dentino-enamel junction more closely than that of the permanent teeth. The pulpal horns are longer and more pointed than the cusps would indicate. The dentin also has less bulk or thickness, so the pulp is proportionately larger than that of the permanent teeth. The enamel of the primary teeth is thin but of uniform thickness. The enamel surface tends to be parallel to the dentino-enamel junction.



**Fig. 12.4** (A) The second permanent molar requires an occlusal restoration. It is not necessary to isolate more than a single tooth. (B) A No. 200 clamp has been selected to hold the rubber dam in place. The rubber dam has retracted the tissue that extended over the distal marginal ridge.



**Fig. 12.5** (A) The Isolite system attached to the unit's vacuum. (B) The isolation system folded for insertion into the oral cavity. (C) The isolation system position intraorally.

## Basic Principles in Cavity Preparation in Primary Teeth

Traditional cavity preparations for class I and class II lesions include areas that have caries involvement and areas that retain food and plaque material and may be considered areas of potential caries involvement. A flat pulpal floor is generally advocated. However, a sharp angle between the pulpal floor and the axial wall of a two-surface preparation should be avoided. Rounded angles throughout the preparation will result in less concentration of stresses and will permit better adaptation of the restorative material into the extremities of the preparation.

Although the traditional class I cavity preparation and restoration may occasionally be the most practical treatment for a tooth in certain circumstances, such treatment is currently obsolete for most class I lesions. The traditional treatment has been replaced, for the most part, by conservative caries excavation and restoration with a combination of bonding restorative and sealant materials (see [Chapter 11](#)).

Likewise, the traditional class II cavity preparation and restoration, although not yet considered obsolete, are currently used less frequently as steadily improving restorative materials with therapeutic and bonding capability are developed. In the traditional class II cavity preparation for amalgam, the buccal and lingual extensions should be carried to self-cleansing areas. The cavity design should have greater buccal and lingual extension at the cervical area of the preparation to clear contact with the adjacent tooth. This divergent pattern is necessary because of the broad, flat contact areas of the primary molars and because of the distinct buccal bulge in the gingival third. Ideally, the width of the preparation at the isthmus should be approximately one-third the intercuspal dimension. The axiopulpal line angle should be beveled or grooved to reduce the concentration of stresses and to provide greater bulk of material in this area, which is vulnerable to fracture.

Because many occlusal fractures of amalgam restorations are caused by sharp opposing cusps, it is advisable to identify these potentially damaging cusps with articulating paper before cavity preparation. The slight reduction and rounding of a sharp opposing cusp will reduce the number of such fractures.

## Cavity Preparation in Primary Teeth

The steps in cavity preparation in a primary tooth are not difficult, but they do require precise operator control. Many authorities advocate the use of small, round-ended carbide burs in the high-speed handpiece to establish the cavity outline and perform the gross preparation. For efficiency and convenience, all necessary high-speed instrumentation for a given preparation may be completed with a single bur in most situations. Therefore the dentist should select the bur that is best designed to accomplish all the high-speed cutting required for the procedure being planned. [Fig. 12.6](#) illustrates four high-speed carbide burs designed to cut



**Fig. 12.6** Round-ended, high-speed carbide burs No. 329, No. 330, No. 245, and No. 256, which may be used for cutting cavity preparations.

efficiently and yet allow for conservative cavity preparations with rounded line angles and point angles. Alternatively, cavity preparations may be made with aluminum oxide air abrasion systems or with laser systems approved for hard-tissue procedures, when indications allow.

### INCIPIENT CLASS I CAVITY IN A VERY YOUNG CHILD

During the routine examination of a child younger than 2 years of age, the dentist may occasionally discover a small but definite carious lesion in the central fossa of one or two first primary molars, with all other teeth being sound. Thus restorative needs are present but minimal. Because of the child's psychological immaturity and because it is usually impossible to establish effective communication with the child, the parent should hold the child on his/her lap in the dental chair. This helps the child feel more secure and provides a better opportunity to restrain the child's movement during the operative procedure. The small cavity preparation may be made without the aid of a rubber dam or local anesthetic. A No. 329 or No. 330 bur is used to open the decayed area and extend the cavosurface margin only to the extent of the carious lesion. If the patient is resistant (usually), completing the preparation with an air abrasion or laser system would be inconvenient. The preparation can be completed in just a few seconds. Restoring the tooth with amalgam or a resin-modified glass ionomer arrests the decay and at least temporarily prevents further tooth destruction without a lengthy or involved dental appointment for the child. If the child is cooperative, a preventive resin restoration, preceded by application of a dentin-bonding agent, may be used.

### PIT OR FISSURE CLASS I CAVITY

The preparation and restoration of a pit or fissure class I cavity are discussed in the section on preventive resin restoration in [Chapter 11](#).

## DEEP-SEATED CLASS I CAVITY

If an amalgam restoration is planned, the first step in the preparation of an extensive class I cavity is to plane back the enamel that overhangs the extensive carious lesion. Then the cavity preparation should be extended throughout the remaining grooves and anatomic occlusal defects. The caries-affected dentin should next be removed with large, round burs or spoon excavators. If a caries exposure is not encountered, the cavity walls should be finished as previously described. With deep carious lesions and near pulp exposures, the depth of the cavity should be covered with a biocompatible base material to provide adequate thermal protection for the pulp.

If a resin-based composite and/or glass-ionomer restoration is planned, any disease-free pits and grooves may be sealed as part of the bonded restoration. The restorative material also provides thermal insulation to the pulp (Video 12.1 and 12.2).

- ▶ **Video 12.1** Resin Modified Glass Ionomer: preparation and restoration.
- ▶ **Video 12.2** Amalgam: preparation and restoration.

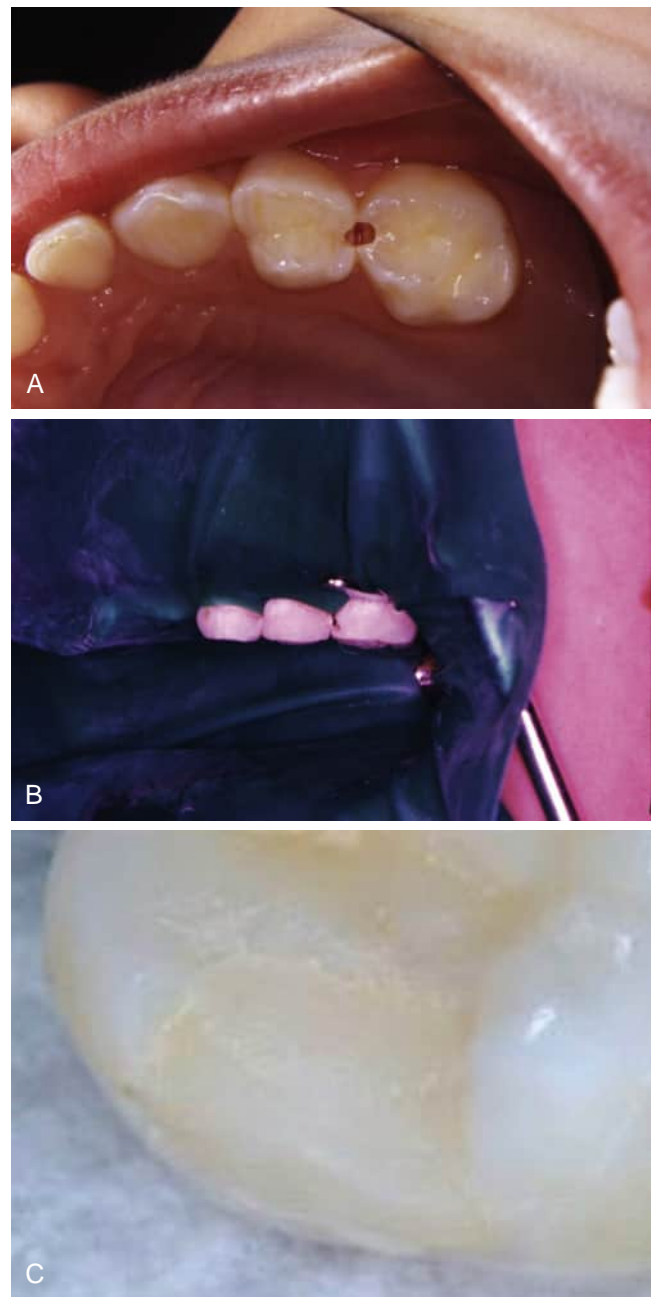
## CLASS II CAVITY

Proximal lesions in a preschool child indicate excessive caries activity; a preventive and restorative program should be undertaken immediately.

### Small Lesions

Very small incipient proximal lesions may be chemically restored with topical fluoride therapy provided by the dentist, along with the judicious use of fluoride products designed for topical application at home. If this treatment regimen is accompanied by improved diet and improved oral hygiene, some incipient proximal lesions may remineralize or remain in an arrested state indefinitely. However, the parents should be informed of the incipient lesions, and emphasis should be placed on the need to continue practicing the recommended procedures and to bring the child back for periodic examinations. If the parents and the patient do not follow the instructions properly, subsequent bitewing radiographs will reveal advancement of the lesion, and restorative procedures should be initiated before the defects become extensive carious lesions.

As bonded restorations have improved, especially those capable of fluoride release, more conservative cavity preparation designs have also been advocated. In otherwise sound teeth free of susceptible pits and fissures, accessing small class II carious lesions via small openings in the marginal ridges or in the facial surfaces of the teeth is becoming a popular technique (Fig. 12.7). Gaining access to the lesion with openings only large enough to allow caries excavation is the goal. Caries is removed by pendulous motions of small burs or by tilting of the air abrasion tip laterally and pulpally at the initial opening. This technique is particularly useful in cooperative patients who have one or two affected primary molars and who are judged to be at relatively low risk for additional caries activity. Suwatviroj et al.<sup>8</sup> have shown in vitro that various tooth-colored restorations placed in box-only preparations did not differ in fracture resistance from those placed in dovetail preparations. However, resin-modified glass-ionomer restorations placed in box-only preparations were more likely to show adhesive failure than those placed in dovetail preparations.

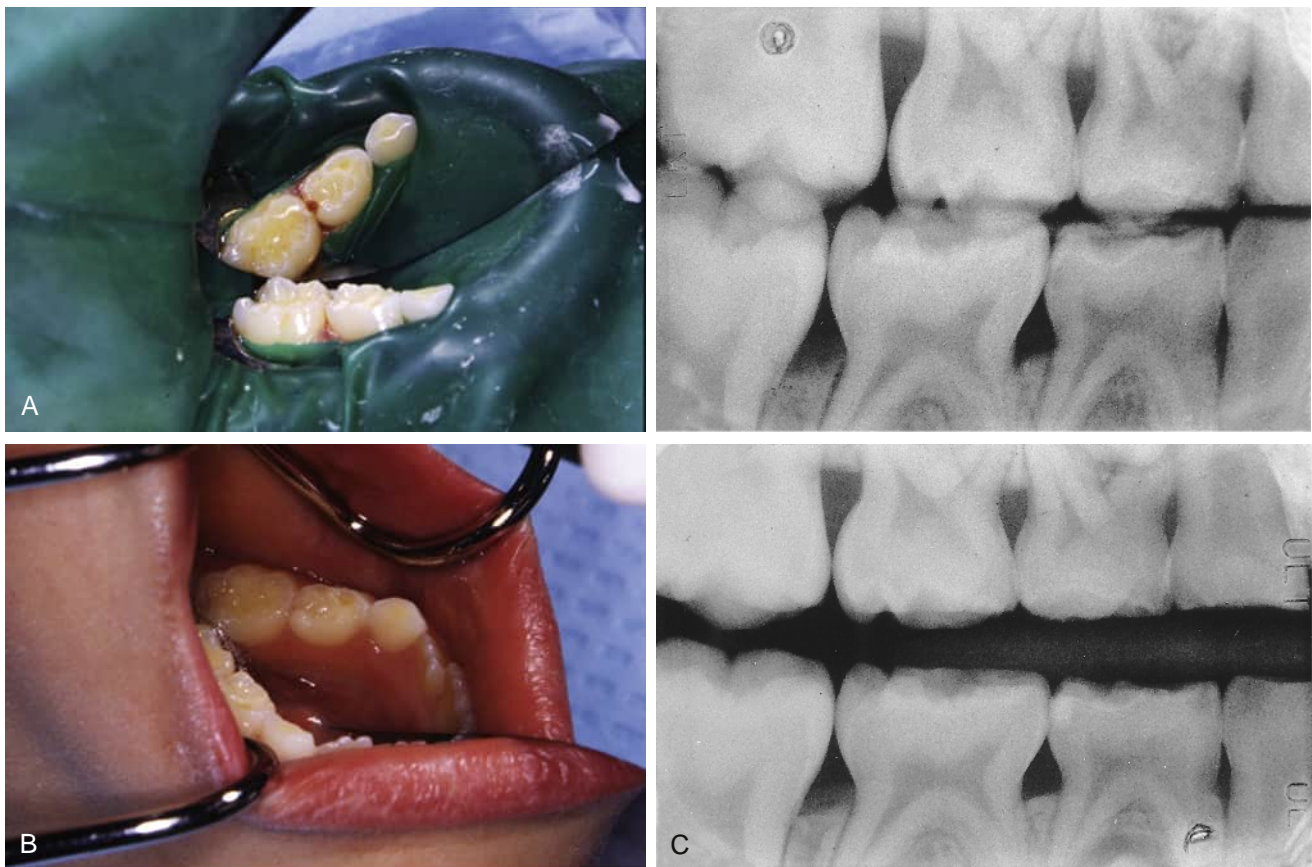


**Fig. 12.7** Approximating conservative preparations to remove small class II carious lesions in primary molars. (A) Marginal ridge access. (B) Facial surface access. (C) Resin-modified glass-ionomer class II restoration in an exfoliated primary molar.

Croll<sup>9</sup> and Vaikuntam<sup>10</sup> have also advocated conservative preparations and restorations with fluoride-releasing restorative materials. Our experience has shown that local anesthesia is usually unnecessary to make the preparation. When this short procedure is performed in cooperative patients, rubber dam isolation is often optional, especially on maxillary teeth. The use of resin-modified glass-ionomer materials results in excellent restorations for this conservative procedure (Fig. 12.8).

Marks et al.<sup>11</sup> and Welbury et al.<sup>12</sup> (who also restored class I preparations) have reported satisfactory results using conservative class II preparations and compomers





**Fig. 12.8** (A) Conservative class II preparation. (B) Resin-modified glass-ionomer restoration. (C) Preoperative radiograph (top) and 17-month postoperative film.

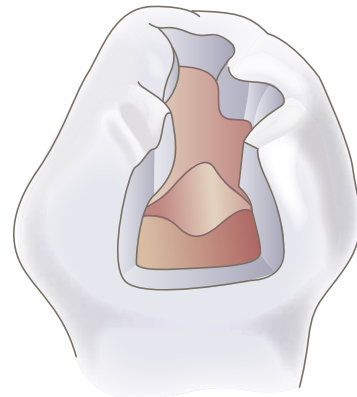
to restore primary molars in studies of 36 and 42 months' duration, respectively. In a 3-year study, Hübel and Mejare<sup>13</sup> reported regarding the successful performance of conservative class II resin-modified glass-ionomer restorations in primary molars.

### Lesions With Greater Dentin Involvement

The first step in the traditional preparation of a class II cavity in a primary tooth for an amalgam or an aesthetic restoration involves opening the marginal ridge area. Extreme care must be taken when breaking through the marginal ridge to prevent damage to the adjacent proximal surface.

### Amalgam

The gingival seat and proximal walls should break contact with the adjacent tooth. The angle formed by the axial wall and the buccal and lingual walls of the proximal box should approach a right angle. The buccal and lingual walls necessarily diverge toward the cervical region, following the general contour of the tooth (Fig. 12.9). The occlusal extension of the preparation should include any caries-susceptible pits and fissures. If the occlusal surface is sound and not caries-susceptible, then a minimal occlusal dovetail is still often needed to enhance the cavity retention form. If caries-affected tooth structure remains after the preparation outline is established, it should be removed next. An appropriate liner or intermediate base, if indicated, and a snug-fitting matrix should be placed before the amalgam is inserted.



**Fig. 12.9** Traditional class II cavity preparation for a primary molar. The preparation includes converging proximal walls towards the occlusal and a beveled and grooved axiopulpal line angle.

### Aesthetic Materials

Because of improvements in the properties of resin-based composites, many dentists use them routinely for posterior restorations. More recently, the use of glass-ionomer restoratives (or other materials on the glass-ionomer-composite-resin continuum) has also been advocated. The preparation and restoration may be similar to those described earlier for amalgam when significant caries exists on both the occlusal and proximal surfaces. However, little or no occlusal

preparation may be required when the occlusal pits and fissures are caries-susceptible but sound or incipient. The proximal restoration may then be combined with the application of an occlusal sealant (with or without enameloplasty). Whenever composite restorative materials are used, enamel beveling, etching, and application of bonding agents are recommended.

Clinical trials of restorations of primary molars, reported by Paquette et al.<sup>14</sup> and Oldenburg et al.<sup>15</sup> revealed that traditional preparations modified only by beveling of enamel margins and restored with bonded resin-based composites yielded highly successful results during 12- and 24-month observation periods. Tonn and Ryge<sup>16</sup> also reported acceptable 2-year results for primary molars restored with bonded resin-based composites in traditional cavity preparations modified only by the beveling of enamel margins.

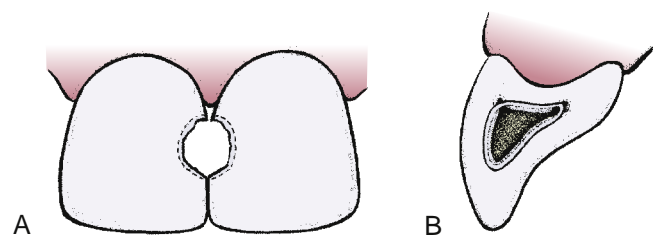
Dilley et al.<sup>17</sup> have demonstrated that the placement and finishing of posterior composite restorations are significantly more time consuming than those for comparable amalgam restorations. In addition to increasing the cost of care, the extra time required for treatment may complicate patient management for some young patients.

After 3 years of observation, Donly et al.<sup>18</sup> have reported successful results for class II resin-modified glass-ionomer restorations in primary molars. In an interesting study by dos Santos et al.,<sup>19</sup> class I and II preparations in primary molars were restored with a resin-modified glass ionomer, a polyacid-modified composite, or a traditional resin-based composite. After 24 months, no statistically significant differences were found among the materials although, not too surprisingly, the class I restorations showed higher survival rates than did the class II restorations. The dentist's sound professional judgment is the key to selecting the restoration that will best serve the patient in each situation.

### Resin Infiltrate

Recently introduced to the marketplace is a resin infiltrate (Icon-DMG, Hamburg, Germany) that is designed to infiltrate subsurface lesions, preventing lesion advancement. Icon resin infiltrate is indicated for placement on incipient smooth surface enamel lesions that may be white or yellow in color. Enamel is etched with hydrochloric acid prior to the placement of the resin. The resin can be placed on facial or lingual tooth surfaces and proximal lesions. An applicator specifically designed to allow proximal flow of the resin is provided by the manufacturer. The resin is tooth-colored but not radiopaque.

In a 1-year clinical study involving 42 children (mean age, 7.17 years), a resin infiltrate and 5% sodium fluoride varnish were placed on 2 subsurface enamel lesions. After 1 year, 31% of the lesions treated with resin infiltrate had progressed compared with 67% of the lesions treated with 5% sodium fluoride varnish.<sup>20</sup> In another clinical trial involving 22 adults, 29 lesion pairs, where the lesion was located in the inner half of enamel to the outer third of dentin, had either a resin infiltrate or no treatment provided. After 3 years, 4% of the lesions treated with resin infiltrate had progressed and 42% of lesions that received no treatment had progressed.<sup>21</sup> Another clinical trial involving 39 adults with 3 proximal lesions in the outer third of dentin received a resin infiltrate, a sealant, and one lesion was left untreated (control). After 3 years, there was no significant



**Fig. 12.10** (A) Schematic drawing of carious lesions on the mesial surfaces of maxillary primary central incisors that do not undermine the mesial angles of the teeth. The dotted line indicates the proposed labial outline of the class III cavity preparation. (B) Proximal view illustrates that the class III preparation is limited to the cervical two-thirds of the primary incisor. (From Roche JR: Restorative dentistry. In Goldman HM et al, eds. *Current Therapy in Dentistry*, vol 4, St. Louis: Mosby; 1970.)

difference in the progression of the lesions treated with the resin infiltrate or sealant; however, both the resin infiltrate and sealant were significantly better at inhibiting lesion progression than was the untreated control.<sup>22</sup> Analysis of future clinical data will provide further information on the effectiveness of and indications for resin infiltrate in pediatric dentistry.

### CLASS III CAVITY

Cariou lesions on the proximal surfaces of anterior primary teeth sometimes occur in children whose teeth are in contact and in children who have evidence of arch inadequacy or crowding. Caries involvement of the anterior primary teeth, however, may be interpreted as evidence of excessive caries activity requiring a comprehensive preventive program.

If the carious lesion has not advanced appreciably into the dentin and if removal of the caries will not involve or weaken the incisal angle, a small conventional class III cavity may be prepared and the tooth may be restored with the dentist's choice of bonding materials (Fig. 12.10).

Mandibular primary incisors with small proximal carious lesions may not require conventional restorations at all. Enameloplasty of the affected proximal surface (usually described as "disking") to open the proximal contact and remove most, if not all, of the cavitation, followed by topical treatments with fluoride varnish, will often suffice until the teeth exfoliate naturally. Extraction is usually indicated when mandibular primary incisors have extensive caries.

### MODIFIED CLASS III CAVITY PREPARATION

The distal surface of the primary canine is a frequent site of caries attack in patients at high risk for caries if the canine is in proximal contact with the first molar. The position of the tooth in the arch, the characteristically broad contact between the distal surface of the canine and the mesial surface of the primary molar, and the height of the gingival tissue sometimes make it difficult to prepare a typical class III cavity and restore it adequately. The modified class III preparation uses a dovetail on the lingual or occasionally on the labial surfaces of the tooth. A lingual lock is normally considered for the maxillary canine, whereas a labial lock may be more conveniently prepared on the mandibular teeth, for which the aesthetic requirement is



not as important (Figs. 12.11 and 12.12). The preparation allows for the additional retention and access necessary for proper insertion of the restorative material.

Trairatvorakul and Piwat<sup>23</sup> compared 31 paired slot preparations with dovetail class III preparations in primary anterior teeth in a well-controlled clinical study in children from 2 years 6 months to 5 years 3 months of age. All teeth were restored with composite and evaluated for marginal adaptation, anatomic form, secondary caries, and marginal discoloration at 6, 12, and 24 months. At the end of the study, 22 pairs of restorations were available. Only one restoration in the slot group and three restorations in the dovetail group were unacceptable. There was no statistically significant difference between the two groups. These results suggest that the simpler and more conservative slot preparation may often be preferred.

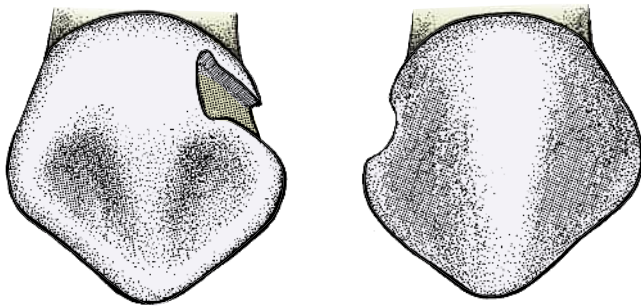


Fig. 12.11 Lingual and labial views of a modified class III preparation for a maxillary primary canine. The dovetail improves the retention form of the preparation and allows access for placement of the restorative material to ensure adequate contact with the adjacent tooth.

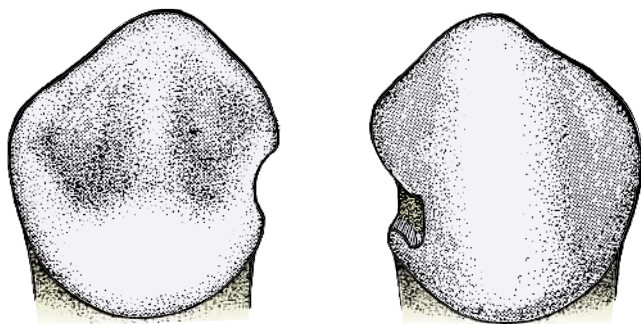

Fig. 12.12 Lingual and labial views of a modified class III preparation for a mandibular primary canine.

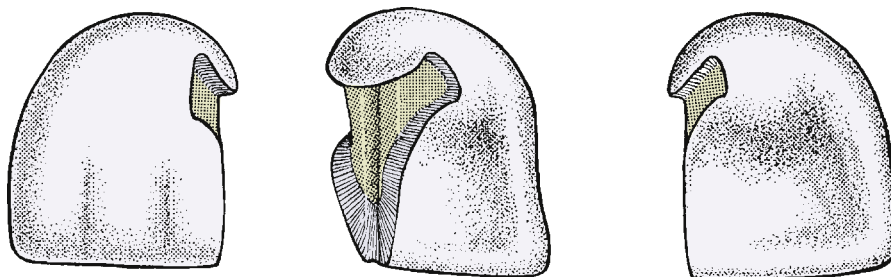


Fig. 12.13 Labial, proximolingual, and lingual views of a preparation for an aesthetic resin restoration in a primary incisor. The preparation includes a proximal reduction and the establishment of a definitive cervical seat that extends to labial and lingual locks in the cervical third of the tooth.

## Restoration of Proximal Incisal Caries in Primary Anterior Teeth

### AESTHETIC RESIN RESTORATION

One type of preparation used for the aesthetic restoration of primary incisors in which dental caries approximates or involves the incisal edge of the teeth is illustrated in Fig. 12.13. As with other operative procedures for the pediatric patient, the use of the rubber dam aids in the maintenance of a dry field, provides better vision for the clinician, and facilitates control of the patient's lips and tongue.

The preparation includes a proximal reduction through the incisal angle and the carious lesion, and ends at the established cervical seat. Labial and lingual locks are then prepared in the cervical third of the tooth. The remaining caries is removed, the tooth is etched, and a bonding agent is applied.

A properly placed matrix tightly wedged at the cervical seat aids the operator in placing, shaping, and holding the resin-based composite during the curing process. A good matrix also simplifies the finishing procedures.

McEvoy<sup>24</sup> described a similar preparation and restoration for primary incisors, except that the retentive locking component is placed on the labial surface only in the gingival third of the tooth. The lock extends minimally across two-thirds of the labial surface and may extend even farther to include decalcified enamel in the cervical area. We also recommend beveling the enamel margins slightly before etching to further improve the marginal bonding of the restoration.

Initial shaping of the restoration may be accomplished with a flame-shaped finishing bur. The excess resin is removed, and the contour of the restoration is established. The gingival margins may be finished with a sharp scalpel blade. Final polishing may be accomplished with the rubber cup and a fine, moist abrasive material or one of the composite polishing systems (Fig. 12.14).

### STAINLESS-STEEL CROWNS

Primary incisors or canines that have extensive proximal lesions involving the incisal portion of the tooth may be restored with stainless-steel crowns, although its use for anterior teeth in many cases has been replaced by more aesthetic materials.

A stainless-steel crown of appropriate size is selected, contoured at the cervical margin, polished, and cemented



into place. (The crown technique is discussed in detail later in this chapter.) Although the crown will be well retained even on teeth that require removal of extensive portions of caries-affected tooth structure, the aesthetic requirements of some children may not be met by this type of restoration.

Most of the labial metal may be cut away, leaving a labial “window” that is then restored with resin-based composite (Fig. 12.15). This restoration is called an open-face stainless-steel crown.

Several brands of stainless-steel crowns with aesthetic facings veneered to the labial surfaces are also available to restore primary anterior teeth (Fig. 12.16). Such crowns are available for direct adaptation to the prepared teeth and have had a significant amount of success. One retrospective study of 226 crowns has shown that an overall 91% of crowns retained good to excellent clinical appearance.<sup>25</sup> In addition, anterior crowns made of zirconia have become very popular because of their durability and aesthetics; however, they do require considerably more tooth structure removal to fit the crown than strip or stainless-steel crowns<sup>26</sup>.

## DIRECT RESIN CROWNS

Webber et al.<sup>27</sup> described the resin crown technique wherein the tooth is restored with resin-based composite with a celluloid crown form used as a matrix. They point out that very little finishing of the restoration is required when the celluloid crown has been properly fitted.

The jacket crown technique illustrated in Fig. 12.17 incorporates the use of a celluloid crown form and resin-based composite as advocated by Webber et al.<sup>27</sup> and is now commonly called a “strip crown.” In a retrospective study by Kupietzky et al.<sup>28</sup>, strip crowns were shown to perform well for restoring primary incisors with large or multisurface caries for longer than 3 years. There was an 80% overall retention rate for the 145 restorations.

Celluloid crown forms are also available for primary posterior teeth. These crown forms are useful matrices for some posterior bonded restorations. A good example of an indication for the use of such a crown form is to provide a

bonded crown build-up for temporary reestablishment of arch integrity and occlusion of an ankylosed (submerged) primary molar. A final comment about crown restoration for primary incisors is worth mentioning related to patient-centered care. These techniques take considerable time and patient cooperation that most preschoolers are unable to easily provide. Moreover, these teeth tend to exfoliate within just a couple of years or so of crown placement. As Sharaf (Dr. Aly Sharaf, Alexandria, Egypt; personal communication, December 2019) has contemplated, are these restorative choices more out of medical necessity or are they a personal luxury? The practitioner is urged to review the pros and cons of these restorations thoroughly with the patient/family (Video 12.3).

**Video 12.3** Direct Resin Crowns: anterior primary tooth preparation and restoration with a celluloid crown form.

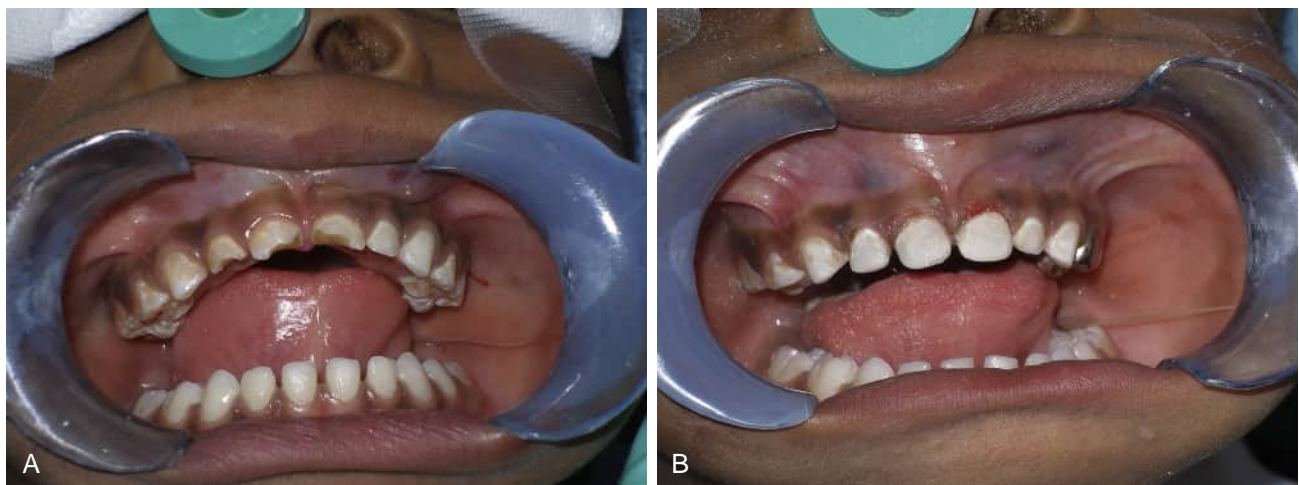


## Preparation of Cavities in Young Permanent Teeth

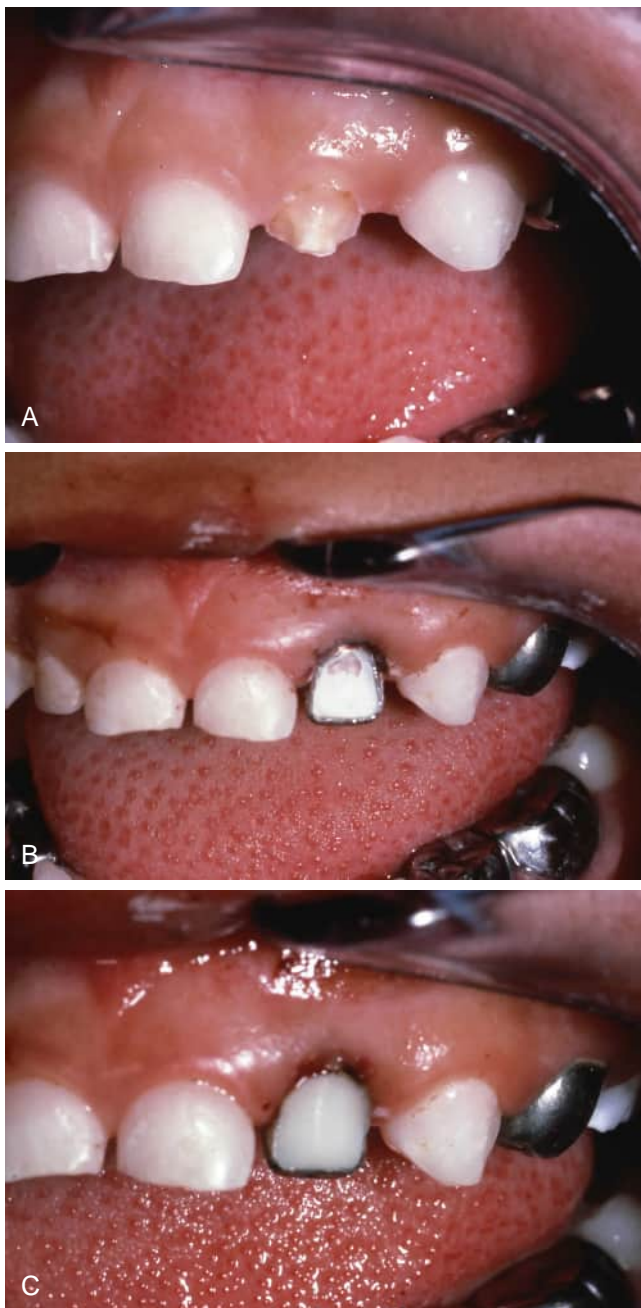
Many of the caries management procedures presented in this textbook also often apply to young permanent teeth. Entire textbooks are devoted to operative dentistry procedures, and the primary focus of these books is restoration of permanent teeth. Repeating all of that information (or portions thereof) in this chapter is impractical and unrealistic. For detailed information about the various cavity preparation designs for permanent teeth and the matrix systems to facilitate the placement and contour of restorations, please consult a standard textbook of operative dentistry listed in the references, such as the text by Roberson et al.<sup>29</sup>

## INTERIM THERAPEUTIC RESTORATION FOR HYPOPLASTIC OR HYPOMINERALIZED PERMANENT MOLARS

The dentist who routinely treats children occasionally faces a difficult restorative problem when severely hypoplastic or hypomineralized first permanent molars erupt,

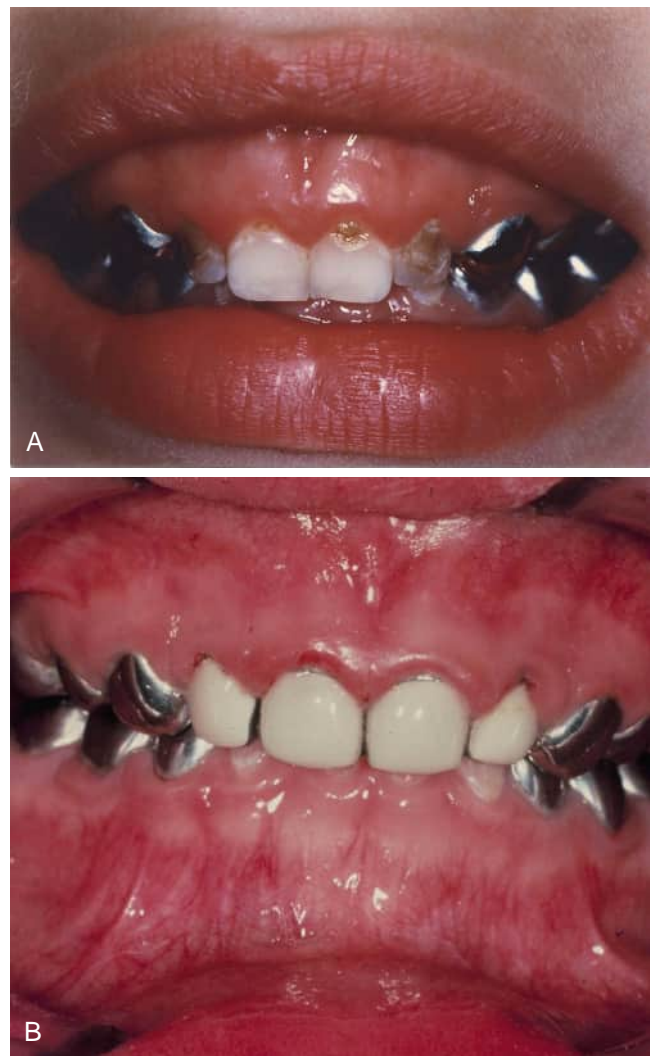

**Fig. 12.14** (A) Extensive carious lesions of the maxillary right central, left central, and lateral incisors of a 3-1/2-year-old patient. (B) Postoperative view of the restored teeth. The restorations are retained with labial and lingual locks incorporated into the preparations. The maxillary lateral preparation was designed as illustrated in Fig. 12.13.



**Fig. 12.15** (A) After the removal of caries in the maxillary left primary lateral incisor and preparation of the tooth, a stainless-steel crown was fitted to the tooth and (B) the labial portion of the stainless-steel crown was removed. (C) The facial surface was then restored with resin.

particularly in the case of a patient with molar-incisor hypomineralization (MIH). Indeed, Tagelsir et al.<sup>30</sup> noted that global MIH prevalence has been shown to be as high as 14% and is defined as a spectrum of developmental qualitative hypomineralization enamel defects affecting the permanent first molars with or without involvement of the permanent incisors. These defects are distributed in an asymmetrical fashion and have discernible variations in severity, ranging from demarcated white, yellow, or brown opacities to severe defects with post eruption disintegration of enamel. Often the teeth are so defective that they require restoration at a very early stage of

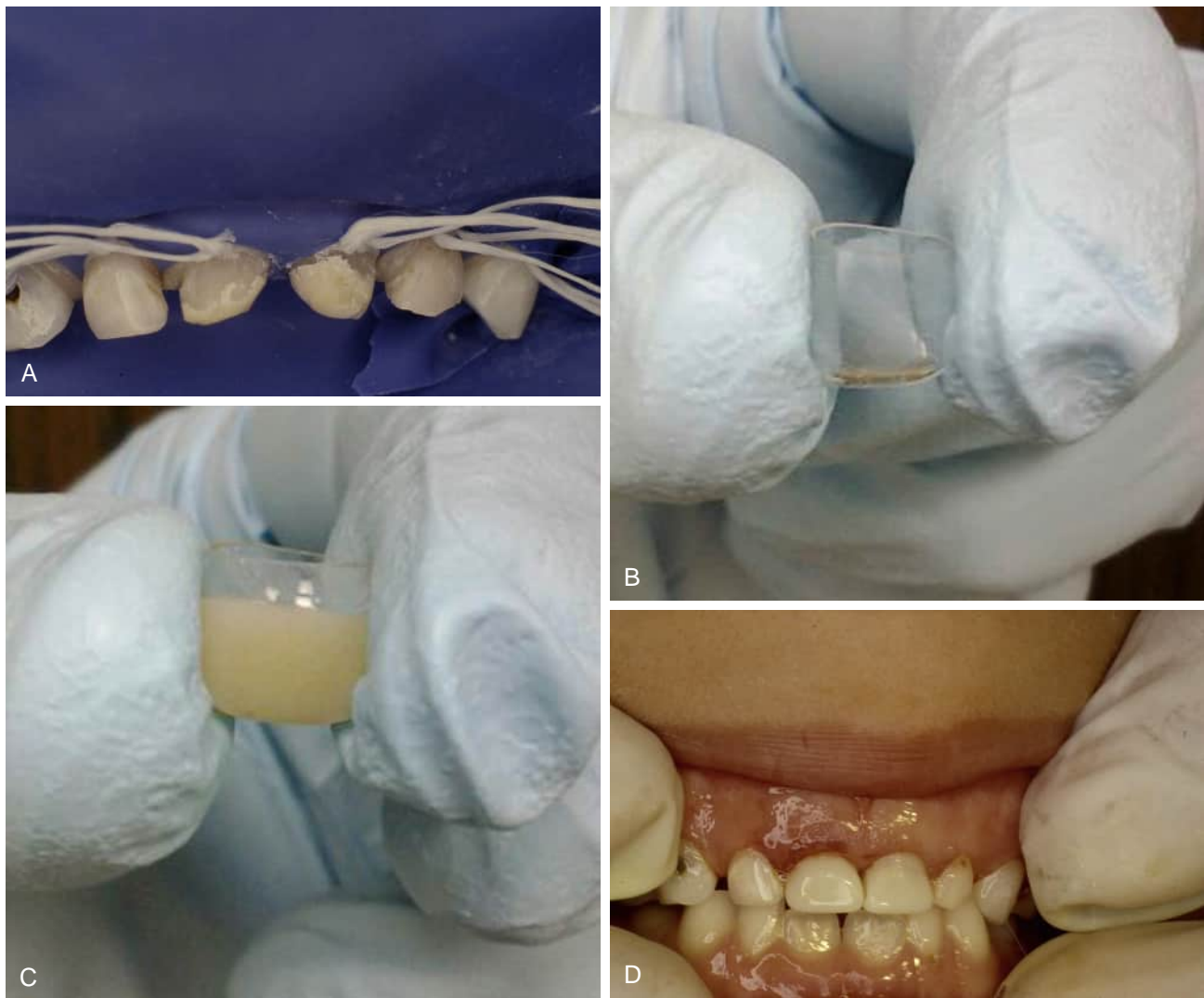


**Fig. 12.16** (A) Extensive caries involving the maxillary primary incisors. (B) Resin-faced stainless-steel crowns following cementation with a glass-ionomer cement.

eruption. Many of these teeth have been saved by early restoration with stainless-steel crowns as an interim procedure. However, this procedure may require sacrificing sound tooth surfaces to provide adequate space for the crown. Such full-coverage restorations are sometimes difficult to fit.

The composite materials have proved to provide a more satisfactory interim restoration for many of these teeth in a technique called interim therapeutic restoration (ITR). Such a bonded composite build-up restoration allows for the preservation of all sound tooth structure and depends on the presence of some enamel surfaces to provide bonded retention for the restorative material. Any soft defective areas are excavated, but little or no additional tooth preparation is done. Usually even undermined enamel surfaces are preserved for additional retention and support of the restorative material. In some cases, gingivoplasty around the erupting tooth may first be necessary to enable adequate access to and isolation of the defective areas. Even if the restoration requires occasional repair, it still often provides a





**Fig. 12.17** (A) Extensive caries of the primary maxillary right central, left central, and left lateral incisors of a 4-year-old patient. (B) Fitted celluloid crown forms were trimmed to just cover the cervical margins of the prepared teeth. (C) Two-thirds filled with a heavily filled resin-based composite, seated over the prepared teeth, with excess resin being removed from the cervical margins and light polymerization. (D) Polishing.

more satisfactory interim result than the stainless steel crown. Some of the newer restorative materials on the glass-ionomer–composite-resin continuum may provide an even better interim restoration for hypoplastic teeth because of their ability to release fluoride and to bond to hypoplastic enamel.

In situations where a stainless-steel crown is required to restore a young permanent molar, Radcliffe and Cullen<sup>31</sup> have noted the importance of conservative tooth preparation to preserve better options for future restoration of the same tooth. They advocate a preparation similar to that described in the following section.

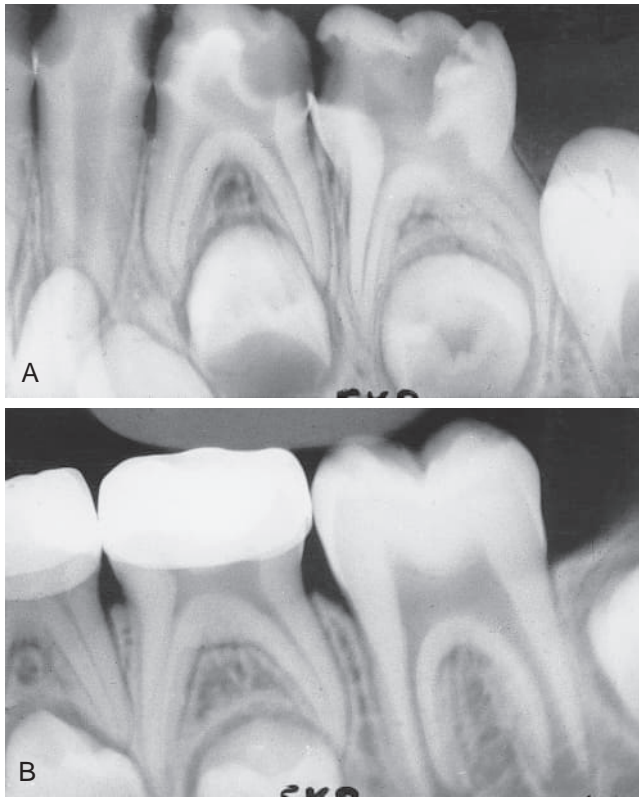
## Stainless-Steel Crowns for Posterior Teeth

Chrome steel crowns, introduced by Humphrey<sup>32</sup> in 1950, have proved to be serviceable restorations for children and adolescents and are now commonly called

stainless-steel crowns. The indications for the use of stainless-steel crowns in pediatric dentistry include the following:

1. Restorations for primary or young permanent teeth with extensive and/or multiple carious lesions (Fig. 12.18)
2. Restorations for hypoplastic primary or permanent teeth that cannot be adequately restored with bonded restorations
3. Restorations for teeth with hereditary anomalies, such as dentinogenesis imperfecta or amelogenesis imperfecta
4. Restorations for pulpotomized or pulpectomized primary or young permanent teeth when there is increased danger of fracture of the remaining coronal tooth structure
5. Restorations for fractured teeth
6. Restorations for primary teeth to be used as abutments for appliances
7. Attachments for habit-breaking and orthodontic appliances





**Fig. 12.18** (A) Primary molars with extensive carious lesions. (B) Adequately contoured stainless-steel crowns have maintained function and the relationship of the primary teeth in the arch.

Randall<sup>33</sup> published an extensive review of the literature that reports on the use of preformed metal crowns for primary and permanent molars. She found five clinical studies that compared the performance of crown restorations with that of multi-surface amalgam restorations. The five studies included a total of 1210 crowns and 2201 amalgams that were followed from a minimum of 2 years to a maximum of 10 years. The findings in all five studies were in agreement that the crown restorations were superior to the amalgam restorations in the treatment of multisurface cavities in primary molars. Randall's review was followed by a position paper prepared by Seale<sup>34</sup> that included additional scientific evidence favoring the use of stainless-steel crown restorations, especially in children at high risk for caries. Seale's published abstract states the following:

The stainless steel crown (SSC) is an extremely durable restoration. Children with extensive decay, large lesions or multiple surface lesions in primary molars should be treated with stainless steel crowns. Because of the protection from future decay provided by their feature of full coverage and their increased durability and longevity, strong consideration should be given to the use of SSCs in children who require general anesthesia. Finally, a strong argument for the use of the SSC restoration is its cost effectiveness based on its durability and longevity.

#### PREPARATION OF THE TOOTH (Video 12.4)

**Video 12.4** Traditional Stainless Steel Crown: tooth preparation and restoration with a pre-cripped stainless steel crown.

A local anesthetic should be administered and a rubber dam placed as for other restorative procedures. The proximal

surfaces are reduced using a No. 69L bur at high speed (Fig. 12.19). Care must be taken not to damage adjacent tooth surfaces during the proximal reductions. A wooden wedge may be placed tightly between the surface being reduced and the adjacent surface to provide a slight separation between the teeth for better access. Near-vertical reductions are made on the proximal surfaces and carried gingivally until the contact with the adjacent tooth is broken and an explorer can be passed freely between the prepared tooth and the adjacent tooth. The gingival margin of the preparation on the proximal surface should be a smooth feathered edge with no ledge or shoulder present. The cusps and the occlusal portion of the tooth may then be reduced with a No. 69L bur revolving at a high speed. The general contour of the occlusal surface is followed, and approximately 1 mm of clearance with the opposing teeth is required.

The No. 69L bur at high speed may also be used to remove all sharp line and point angles. It is usually not necessary to reduce the buccal or lingual surfaces; in fact, it is desirable to have an undercut on these surfaces to aid in the retention of the contoured crown. In some cases, however, it may be necessary to reduce the distinct buccal bulge, particularly on the first primary molar.

If any caries-affected dentin remains after these steps in crown preparation are completed, it is excavated next. In the event that a vital pulp exposure is encountered, a pulpotomy procedure is usually performed.

#### SELECTION OF THE CROWN SIZE (Video 12.5)

**Video 12.5** Hall Technique Stainless Steel Crown: sizing and restoration with a pre-cripped stainless steel crown using the Hall Technique

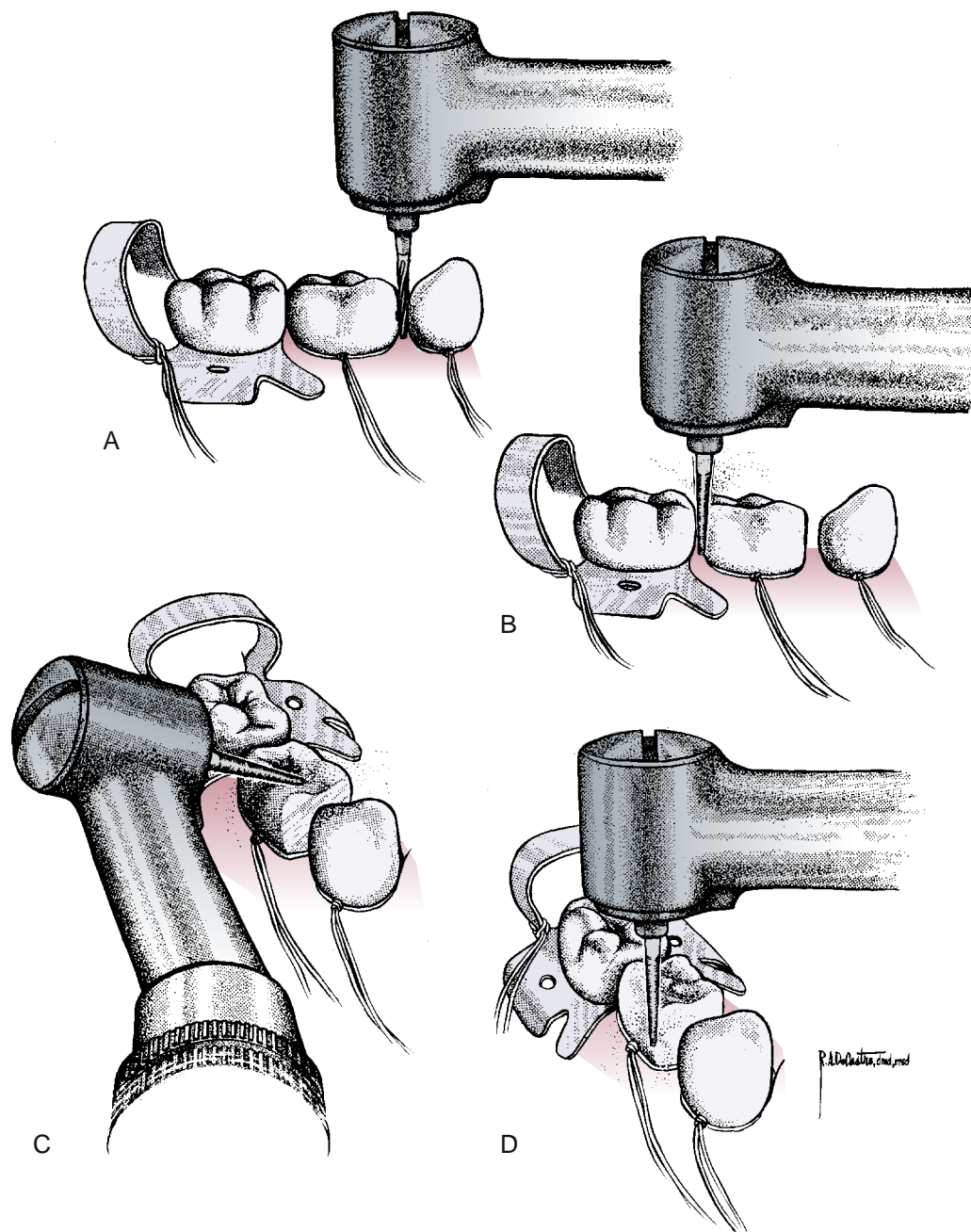
The smallest crown that completely covers the preparation should be chosen. Spedding<sup>35</sup> has advocated adhering to 2 important principles that will help to produce well-adapted stainless-steel crowns consistently. First, the operator must establish the correct occlusogingival crown length. Second, the crown margins should be shaped circumferentially to follow the natural contours of the tooth's marginal gingivae. The crown should be reduced in height, if necessary, until it clears the occlusion and is approximately 0.5 to 1 mm beneath the free margin of the gingival tissue. The patient can force the crown over the preparation by biting an orangewood stick or a tongue depressor. After making a scratch mark on the crown at the level of the free margin of the gingival tissue, the dentist can remove the crown and determine where additional metal must be cut away with No. 11B curved shears or a rotating stone (Fig. 12.20).

With curved-beak pliers, the cut edges of the crown are redirected cervically, and the crown is replaced on the preparation. The child is again directed to bite on an orangewood stick to seat the crown forcibly so that the gingival margins may be checked for proper extension.

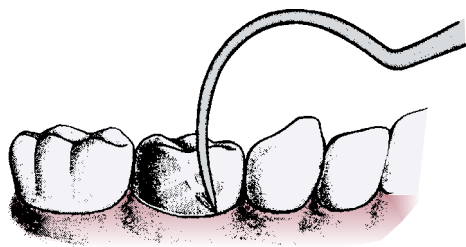
The precontoured and festooned crowns currently available often require very little, if any, modification before cementation.

#### CONTOURING OF THE CROWN (WHEN NECESSARY)

Crown-contouring pliers with a ball-and-socket design are used at the cervical third (if loosely fitting, start at the middle

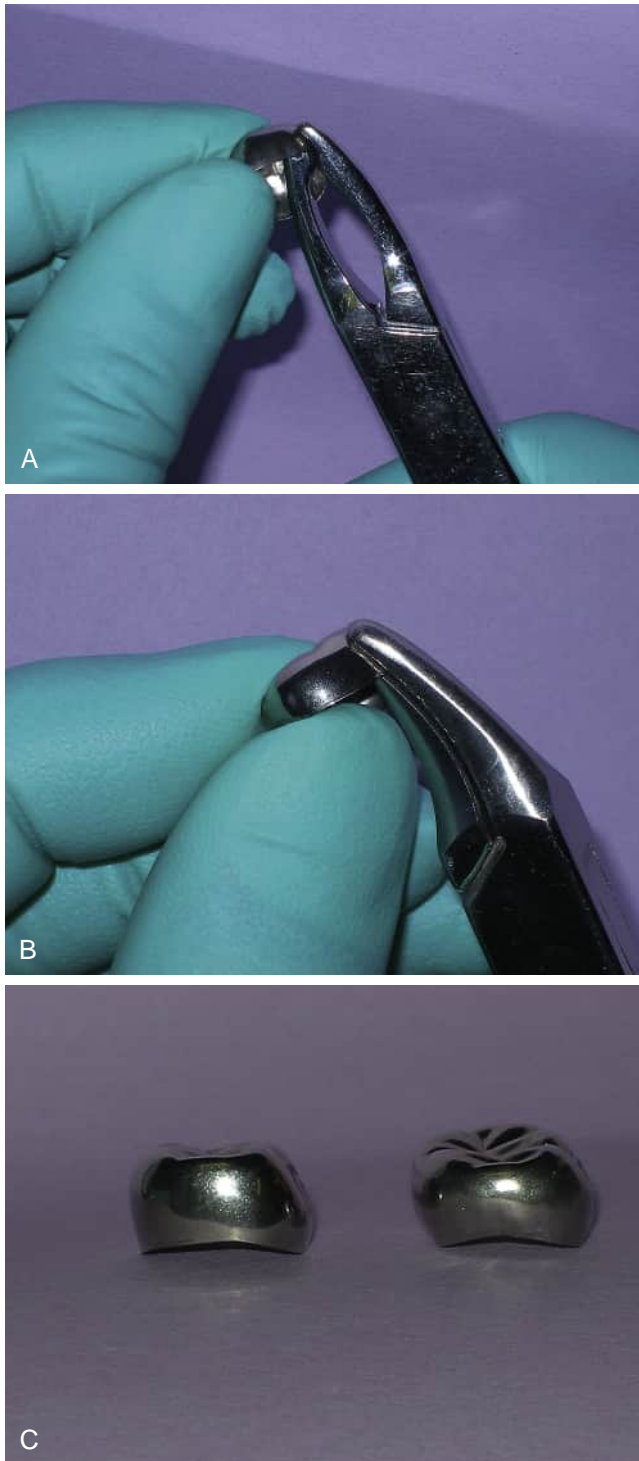


**Fig. 12.19** Steps in the preparation of a primary molar for a stainless-steel crown restoration with a No. 69L bur in the high-speed handpiece. (A) Mesial reduction. (B) Distal reduction. (C) Occlusal reduction. (D) Rounding of the line angles.



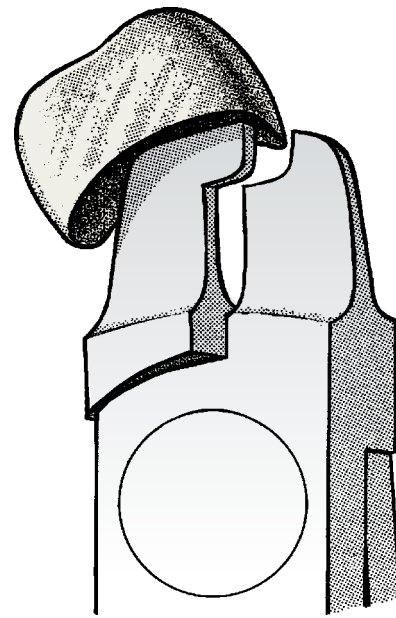
**Fig. 12.20** A scratch is made at the level of the free margin of the gingival tissue as an aid in determining where additional metal must be removed.

third) of the buccal and lingual surfaces to help adapt the margins of the crown to the cervical portion of the tooth. The handles of the pliers are tipped toward the center of the crown, so that the metal is stretched and curled inward as the crown is moved toward the pliers from the opposite side. Curved-beak pliers are used to further improve the contour on the buccal and lingual surfaces (Fig. 12.21). The curved-beak pliers may also be used to contour the proximal areas of the crown and develop desirable contact with adjacent teeth. Many clinicians prefer to complete the crown-contouring procedures using crown-crimping pliers (Fig. 12.22). If necessary, solder may be added to the

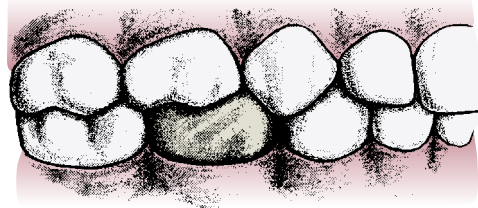

**Fig. 12.21** (A) Crown-contouring pliers are used to contour the buccal and lingual surfaces of the crown. The crown is held firmly with the pliers, and pressure is exerted with the finger from the opposite side of the crown to bend the surface inward. (B) The curved-beak pliers are “walked” completely around the cervical margins of the crown to direct all margins inward with smooth, flowing contour. (C) The crown on the right was the same size and shape as the crown on the left before it was contoured. This illustrates the effectiveness of the contouring procedures with the pliers as described.

proximal surfaces of the crown to improve the proximal contacts and contour. Trimming and contouring are continued until the crown fits the preparation snugly and extends under the free margin of the gingival tissue.



**Fig. 12.22** Crown-cramping pliers may also be used for crown contouring.



**Fig. 12.23** Final adaptation of the crown should result in good occlusion before cementation.

The crown should be replaced on the preparation after the contouring procedure to ensure that it snaps securely into the place. The occlusion should be checked at this stage to ensure that the crown is not opening the bite or causing a shifting of the mandible into an undesirable relationship with the opposing teeth (Fig. 12.23).

The final step before cementation is to produce a beveled gingival margin that may be polished and that will be well tolerated by the gingival tissue. A rubber abrasive wheel can be used to produce the smooth margin.

Occasionally, the best-fitting crown may need to be modified to produce a more desirable adaptation to the prepared cervical margin. Mink and Hill<sup>36</sup> have referred to methods of modifying stainless-steel crowns for primary and permanent teeth. The oversized crown may be cut as illustrated in Fig. 12.24 and the cut edges overlapped. The crown is replaced on the tooth to ensure that it now fits snugly at the cervical region, and a scratch is made at the overlapped margin. The crown is removed from the tooth, and the overlapped material is repositioned and welded. A small amount of solder is allowed to flow over the outside margin. The crown is finished in the previously recommended manner and cemented to the prepared tooth.

If the dentist encounters a tooth that is too large for the largest crown, a similar technique may be helpful. The



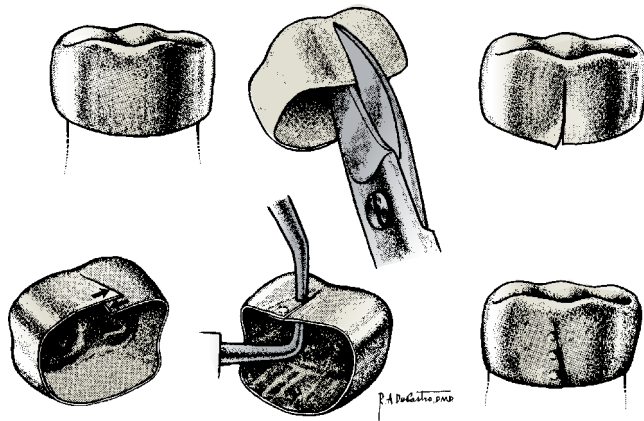


Fig. 12.24 Technique for adapting an oversized crown to a prepared tooth.

crown may be cut on the buccal or lingual surface. After the crown has been adapted to the prepared tooth, an additional piece of 0.004-inch stainless-steel band material may be welded into place. A small amount of solder should be added to the outer surfaces of the margins. The crown may then be contoured in the usual manner, polished, and cemented into place.

Finally, just as with crowns for anterior teeth, preveneered stainless-steel crowns for posterior primary teeth have been developed. These crowns require considerably more crown preparation than conventional stainless-steel crowns, but Yilmaz and Kocogullari<sup>37</sup> have reported success rates as high as 80%.

## Cosmetic Zirconia Crowns (Video 12.6)

▶ **Video 12.6** Pulpectomy and Zirconia Crown: anterior primary tooth pulpectomy and Zirconia crown preparation and restoration.

Zirconia crowns are marketed for the aesthetic restoration of primary anterior (Fig. 12.25) and posterior teeth (Fig. 12.26). These crowns offer a aesthetically pleasing appearance while providing durability. An in vitro study has demonstrated that natural teeth opposing zirconia crowns have much more favorable wear than natural teeth opposing porcelain crowns.<sup>38</sup> A clinical trial demonstrated posterior prefabricated primary molar zirconia crowns to perform as well as stainless-steel crowns over a 2-year period.<sup>39</sup> Further use of these crowns and clinical research will offer additional information for these crowns in the future.

## Alternative Restorative Treatment

Alternative or atraumatic restorative treatment (ART) is a popular descriptive term for the conservative method of managing both small and large carious lesions when treating the disease by more traditional restorative procedures is impossible or impractical for many reasons, including lack of access to traditional dental settings. This method may prevent pain and preserve teeth in individuals who do not have access to regular and conventional oral health care. ART may be performed with only hand instruments when no other dental equipment is available, but it may be useful sometimes in the

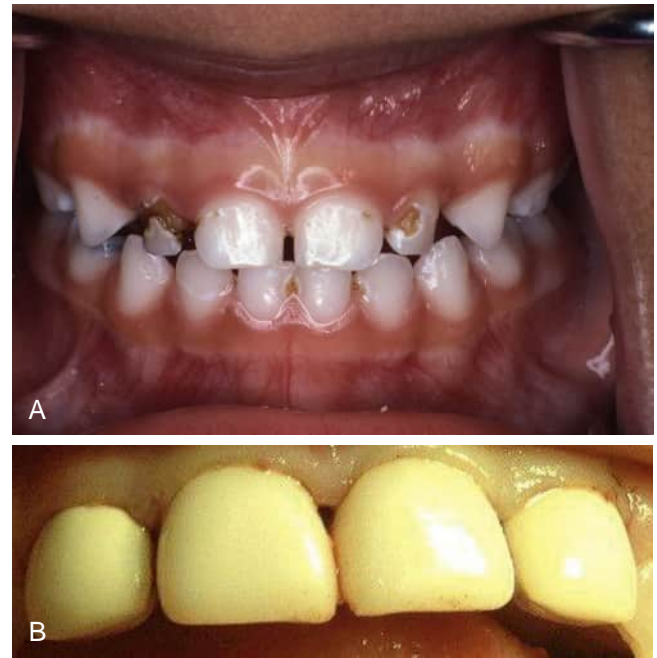


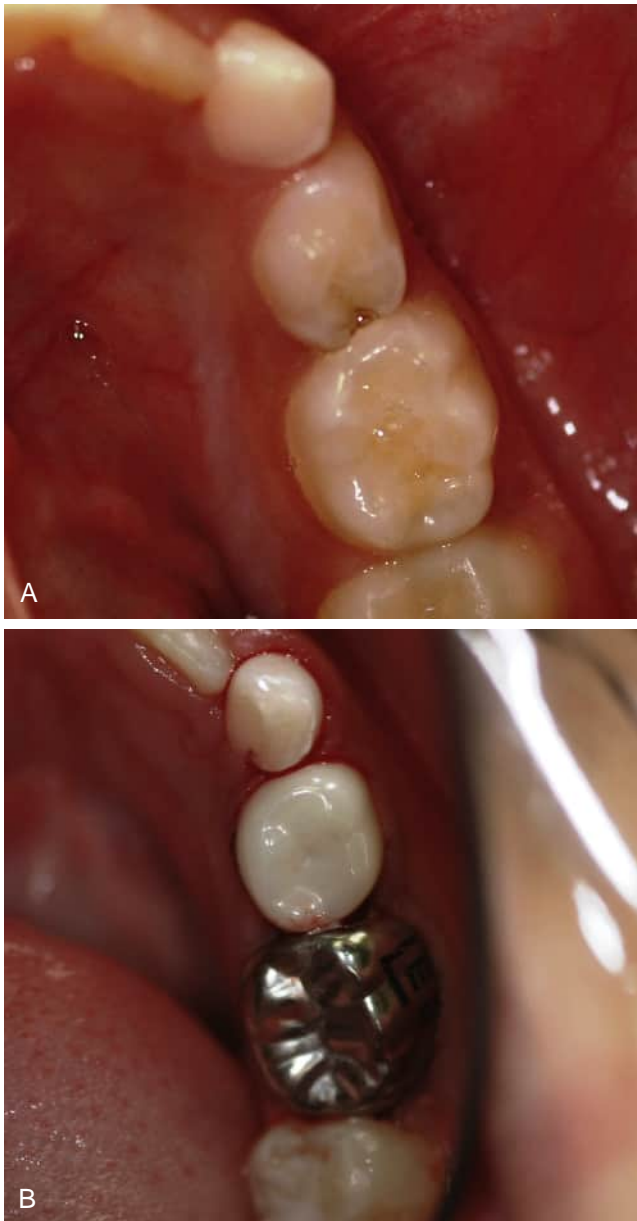
Fig. 12.25 (A) Extensive caries of the maxillary primary lateral incisors, with caries involving the lingual surfaces of the central incisors. (B) The lateral incisors restored with resin-faced crowns and the central incisors restored with zirconia crowns.

conventional dental setting as well. ART does not require complete excavation of dentinal caries before placement of the restorative material. This is not a totally new concept in dentistry, but it has enjoyed renewed recognition as a viable restorative approach because of the development of the more durable fluoride-releasing glass ionomer and resin-modified glass-ionomer restorative materials. (The principles validating this technique are discussed in the section *Treatment of the Deep Carious Lesion* in Chapter 14.) Also, ART can be supplemented by applying sodium diamine fluoride to the caries lesion prior to glass-ionomer placement in an attempt to enhance caries control in a technique known as “silver modified atraumatic restorative technique” or SMART.

This technique is promoted and endorsed by the World Health Organization with the goals of preserving tooth structure, reducing infection, and avoiding discomfort. Recognizing the technique as a means of restoring and preventing dental caries, the International Association for Dental Research held a symposium on ART in June 1995. The procedure does not require a traditional dental setting. Preventive measures to control the bacterial infection and the causative agents of the disease should also be used for optimal results following treatment.

It is important to understand differences between this technique and the ITR technique mentioned previously in this chapter. Saber et al.<sup>40</sup> reviewed these two approaches as they are similar and are performed using the same material, but they differ in the purpose of their use. The AAPD added the term ITR, and their reference manual differentiates ART from ITR as follows<sup>1</sup>:

Because circumstances do not allow for follow-up care, ART has been mistakenly interpreted as a definitive restoration. ITR utilizes similar techniques, but has different therapeutic goals. ITR more accurately describes the procedure used in contemporary dental practice.



**Fig. 12.26** (A) A mandibular first primary molar exhibiting occlusodistal caries. (B) A posterior primary molar zirconia crown cemented with resin cement.

## Cosmetic Restorative Procedures for Young Permanent Anterior Teeth

A common problem confronting dentists who treat children is the aesthetic management of anterior teeth that are discolored, developmentally undersized or malformed, malposed, or fractured. Dentists recognize that aesthetic impairments of the teeth often adversely affect the social and psychological development of the growing child. Aesthetic restorative systems and bonding techniques are usually used when restorations are indicated in these situations. Although bonding procedures are also applicable to primary tooth restorations (as

described earlier in this chapter), the following discussion applies primarily to permanent anterior teeth simply because few indications are encountered in the primary dentition. However, Aron<sup>41</sup> has reported the successful use of bonded porcelain veneers for primary incisors in a young patient.

The following discussion assumes that one understands dental bonding principles and has a working knowledge of the process. These principles and procedures are similar for sealants, restorative resins, and resin luting agents (see [Chapter 11](#)). Some tooth preparation confined to enamel (as much as possible) is often indicated, although not always required, before cosmetic bonding procedures are performed.

### BONDED COMPOSITE VENEER RESTORATIONS (RESIN-BASED COMPOSITE BONDING)

Resin-based composite restoratives (and bonding agents) are frequently applied directly to etched enamel. The restorative resin simply becomes a veneer to improve tooth color or contour. Restorative resin-bonding techniques are particularly useful for restoring anterior crown fractures (see [Chapter 28](#)) and for cosmetically increasing the mesial-distal widths of young permanent anterior teeth ([Fig. 12.27](#)). Bonded composite veneers are also useful for restoring small hypoplastic or discolored areas on visible tooth surfaces. Many dentists also use this type of restoration to mask intrinsic discolorations by veneering the entire labial surfaces of the discolored anterior teeth ([Fig. 12.28](#)). This approach may provide satisfactory cosmetic restorations for teeth with mild to moderate discolorations that will not respond to the bleaching or microabrasion procedures discussed in [Chapter 3](#).

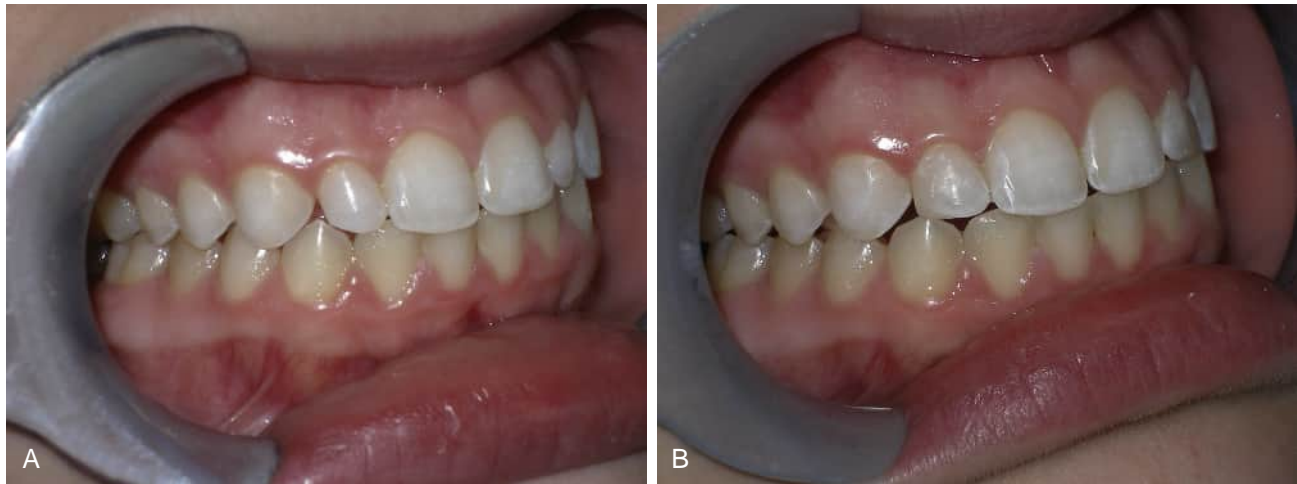### BONDED LAMINATE VENEER RESTORATIONS (DENTAL LAMINATES OR LAMINATE VENEERS)

The use of thin, prefitted porcelain facings (laminare veneers) that are bonded to enamel surfaces has become commonplace in cosmetic dentistry. Interest in laminate veneer restorations has grown steadily since their introduction by Faunce and Faunce.<sup>42</sup> Such restorations for maxillary anterior teeth are recognized as conservative, aesthetically satisfactory restorations, especially in children and young adults. Laminate veneer restorations have also been used successfully on mandibular anterior teeth.

The laminate veneer technique offers aesthetic improvement because the restored teeth simulate the natural hue and appearance of normal, healthy tooth structure. When properly finished, the laminate restorations are well tolerated by the gingival tissues, even though their contour may be slightly excessive. Immaculate oral hygiene is essential, but experience has shown that the maintenance of gingival health around the restorations is certainly possible in cooperative patients ([Fig. 12.29](#)).

The luting materials are tooth-colored resin systems designed for use in bonding techniques. If the teeth being treated are severely discolored, tinting or opaquing agents may also be required. The laminate veneer procedure is not complicated, but it requires meticulous attention to detail for success.





**Fig. 12.27** (A) Undersized maxillary right lateral incisor in a young patient. (B) Improved appearance of tooth after restoration with a bonded laminate veneer restoration.

The bonding procedure for a laminate veneer restoration requires proper preparation of the inside laminate surface and proper etching of the outer enamel surface. The inside of the porcelain laminate surface is etched with a hydrofluoric acid etchant and then coated with silane, which results in a bond with the resin luting agent similar to that achieved on etched enamel but also enhanced chemically by the silane. Excellent bond strengths to the porcelain surface have been reported by Lee et al.<sup>43</sup>

The intra-enamel preparation includes removal of 0.5 to 1 mm of facial enamel, tapering to about 0.25 to 0.5 mm at the cervical margin. This margin is finished in a well-defined chamfer with the crest of the gingival margin not more than 0.5 mm subgingivally. The incisal margin may end just short of the incisal edge, or it may include the entire incisal edge ending on the lingual surface. It is better not to place incisal margins where direct incising forces occur. Bonded porcelain techniques have significant value in cosmetic dental procedures (Fig. 12.30).

Refer to the text by Nixon<sup>44</sup> for additional information on the many varieties of materials and techniques available for dental cosmetic procedures.

## Controversies in Pediatric Restorative Dentistry

### LASER USE

In 2013, AAPD released its first policy statement on the use of lasers for pediatric dental patients. While lasers are recognized as a viable alternative to traditional preparation tools in restorative dentistry, as with any tool, there are advantages and limitations. Laser use is perhaps best viewed as an alternative and complementary method. Less heat generation, the necessity for little or no local anesthesia, and removal of caries with minimal involvement of surrounding tooth structure are among several advantages of lasers. Limitations include high start-up costs, the need for different equipment for different applications, and the need for additional practitioner training in the methodology. However, despite acknowledging that cavity preparation with a

laser takes longer and smells unpleasant, one study<sup>45</sup> has recently shown that adolescents prefer the laser to conventional preparation because they found it more comfortable. For a more thorough review, see Olivi et al.<sup>46</sup> user guide entitled *Pediatric Laser Dentistry*.

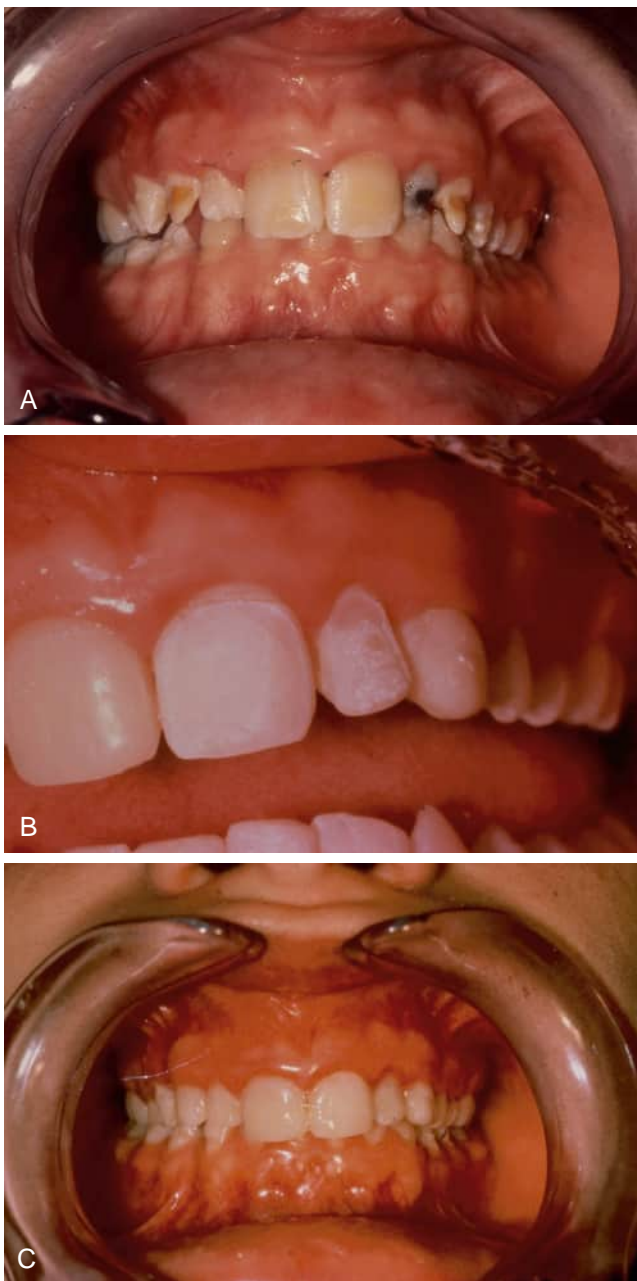
### MINIMALIST APPROACH TO RESTORATIVE CARE

Many of us are familiar with the technique demonstrated in Fig. 12.31, where adjacent interproximal lesions have been managed by simply opening up the contact between the two teeth with a high-speed handpiece, applying fluoride varnish, and having the parents use focused toothbrushing in the area to slow or arrest the decay. This is used particularly with lower primary incisor tooth interproximal decay. However, an article by Kidd<sup>47</sup> stretches the boundaries of options for management of caries in primary teeth by suggesting the following:

- No caries removal, but opening the lesion to allow for cleaning (as above)
- Sealing techniques with no caries removal (the Hall technique)
- Partial caries removal and restoration (the atraumatic restorative technique)
- Complete caries removal and restoration
- Not restoring or opening the tooth, but leaving it as is.

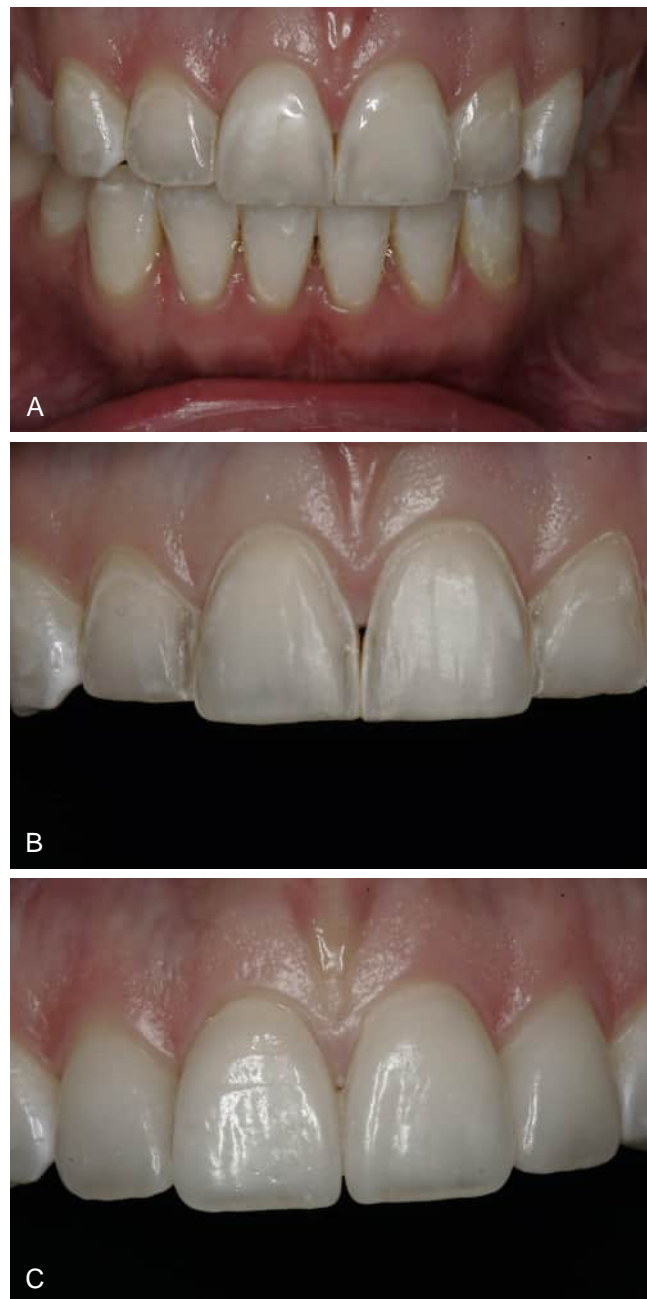The Hall technique involves restoration of non-pulpally-involved, significantly decayed primary molars with stainless-steel crowns luted with glass-ionomer cement, but without caries removal. While this technique remains controversial<sup>48</sup> and raises concerns such as gingival health around the crowns and bite opening, numerous studies have addressed the success of the technique.<sup>49–52</sup> In particular, Elamin et al.<sup>53</sup> conducted a well-designed, prospective, randomized controlled trial comparing survival and cost effectiveness of the Hall technique versus the conventional preparation technique in the placement of just over 100 stainless-steel crowns in each group and followed 2 years. Survival rates were high (over 90%) for both techniques and not statistically different, child anxiety scores were significantly higher





**Fig. 12.28** Resin-based composite bonding. (A) Preoperative appearance of a 15-year-old girl who said, "I don't like my teeth." (B) A heavily filled resin-based composite restorative material bonded to teeth 9, 10, and 11 with a chamfer preparation placed. (C) Postoperative appearance of finished restorations after placement of a microfilled resin-based composite.

for the conventional technique, gingival and plaque indices were similar between groups, and while occlusions were initially higher for the Hall technique, the occlusion adjusted overtime in both groups. Both the average procedure time and crown cost were approximately one-third less with the Hall technique. It seems clear from the results of this study and other research conducted over the last 10 years and more that the Hall technique for stainless-steel crown placement is a promising procedure and has a place in dental practice. Indeed, the entire

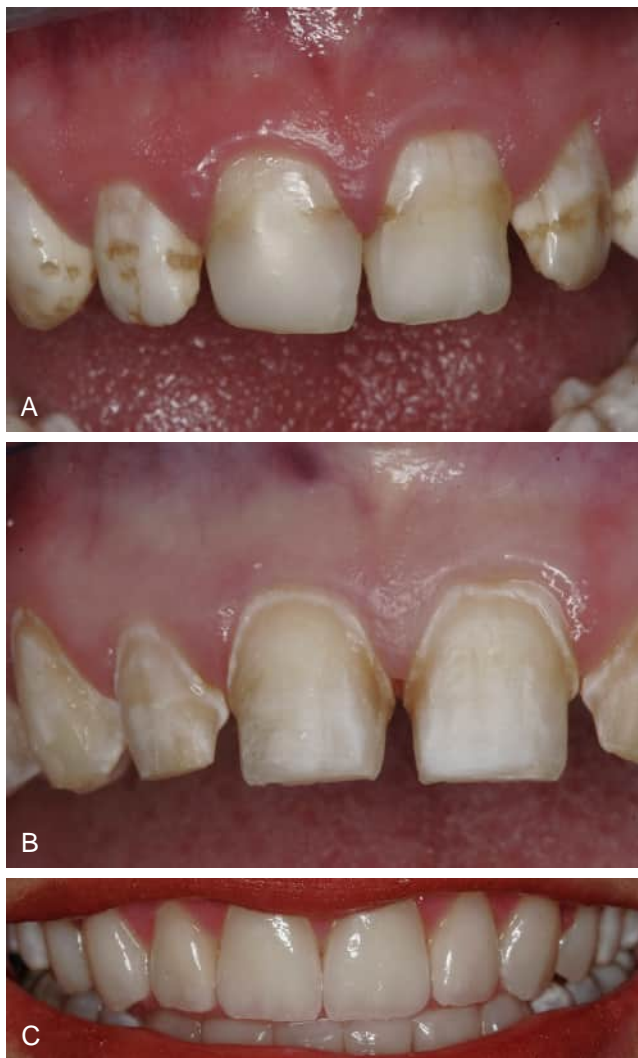

**Fig. 12.29** (A) Anterior teeth of a teenager after the removal of bonded orthodontic appliances. The hypoplastic defects are obvious on the canines and lateral incisors, and the central incisors are mildly affected as well. (B) Photograph of same patient after completion of the intra-enamel preparations. (C) Bonded resin veneer restorations. (Courtesy of Dr. Nasser Barghi.)

concept of minimalist restorative techniques is gaining ground in modern dentistry and it will be interesting to see it evolve over the coming years.

## Bleaching and Microabrasion

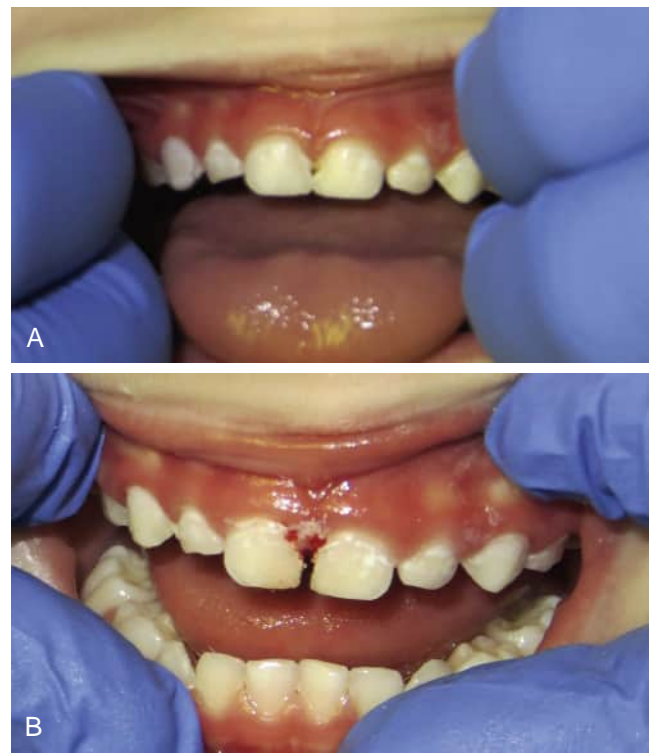
Tooth whitening for children has become a component of the practice of pediatric dentistry.<sup>54</sup> Tooth whitening can



**Fig. 12.30** (A) Severe tooth “pitting” and discoloration in a teenager. (B) The teeth are prepared for porcelain-bonded veneer restorations. (C) Final porcelain veneer restorations. (Courtesy of Dr. Nasser Barghi.)

be achieved by professional vital tooth bleaching, over-the-counter bleaching, and bleaching in conjunction with enamel microabrasion.<sup>55,56</sup> Tooth whitening may be indicated for children who present with mild or moderate fluorosis, developmental tooth discolorations, and generalized darkened teeth. **Fig. 12.32** Most professional and over-the-counter bleaching products are based on the whitening effects of peroxide, hydrogen peroxide, and carbamide peroxide at different strengths.<sup>57,58</sup>

Bleaching should be performed according to manufacturer’s instructions. Although there has been a case report of bleaching primary teeth with no adverse events,<sup>59</sup> a majority of controlled research has been completed on adolescents with an erupted permanent anterior dentition.<sup>60</sup> Research has demonstrated the whitening effectiveness of professional and over-the-counter bleaching systems, as well as minimal tooth or gingiva sensitivity.<sup>61,62</sup> Should bleaching be completed prior to the entire eruption of the permanent dentition, patients and their



**Fig. 12.31** (A) Adjacent interproximal lesions on teeth E and F. (B) Sluceway opened up with a high-speed handpiece to allow for direct fluoride varnish application and easier cleansing with brushing. No restoration was placed.

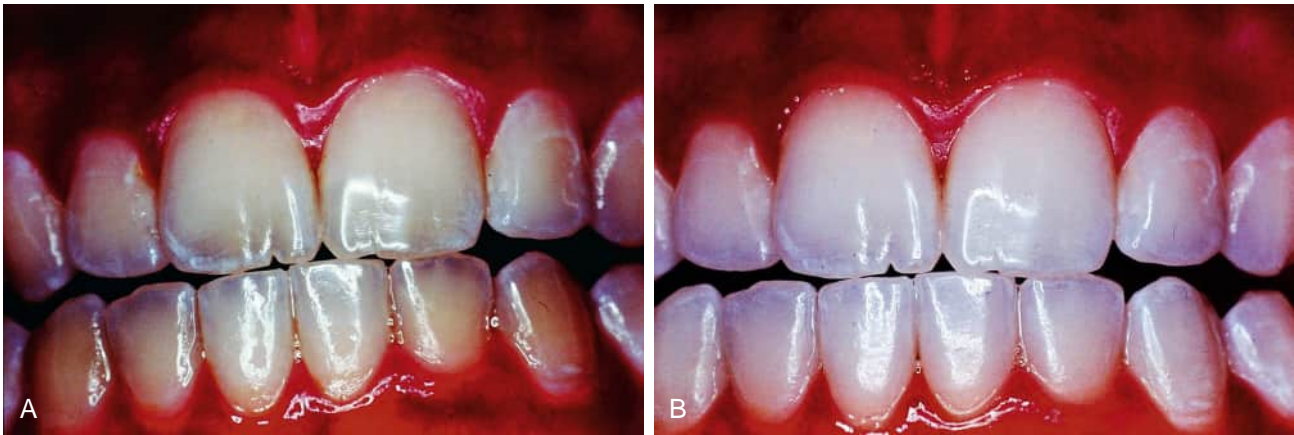
parents need to understand that bleaching may need to be completed again when all the permanent anterior dentition has erupted.

When bleaching does not successfully camouflage tooth discoloration, microabrasion can be provided, followed by bleaching.<sup>63</sup> Microabrasion removes enamel tooth structure, approximately 25 microns per 1 minute of microabrading, but it also creates a “smear layer” of calcium and phosphate.<sup>64</sup> The smear layer at the enamel surface can then be bleached, which can be much more effective at camouflaging underlying tooth discoloration than bleaching alone.<sup>65</sup>

The clinical steps of microabrasion are<sup>66</sup>:

- Isolate teeth to be microabraded (this can be done with a rubber dam or cotton rolls).
- The clinician may wish to place sodium bicarbonate at the free gingival margin to neutralize any acid that approaches the gingiva.
- Microabrade for 1 minute with Prema Compound (Premier Dental Products Company, Plymouth Meeting, PA, USA), Opalustre (Ultradent Products, Inc., South Jordan, UT, USA), or a mixture of hydrochloric acid and pumice.
- Rinse thoroughly and complete further 1 minute microabrasion applications. Typically, 5 to 10 applications are adequate.
- Following microabrasion, immediately apply a neutral 2% sodium fluoride gel for 4 minutes.
- Professional bleaching or over-the-counter bleaching may then be completed.





**Fig. 12.32** (A) The baseline image of an 11-year-old female who wishes to have her teeth bleached. (B) An image of the same girl 4 weeks after bleaching with a 10% hydrogen peroxide polyethylene strip system (Crest Whitestrips Premium, The Procter and Gamble Company, Cincinnati, OH, USA). (Courtesy of Dr. Donly.)

## References

- American Academy of Pediatric Dentistry. Best Practices. Pediatric Restorative Dentistry: *The Reference Manual of Pediatric Dentistry* 42: 340–352, 2020.
- Berg JH: The continuum of restorative materials in pediatric dentistry: a review for the clinician, *Pediatr Dent* 20:93–100, 1998.
- Bonilla E, White SN: Fatigue of resin-bonded amalgam restorations, *Oper Dent* 21:122–126, 1996.
- Mahler DB, Engle JH, Simms LE, et al.: One-year clinical evaluation of bonded amalgam restorations, *J Am Dent Assoc* 127(3):345–349, 1996.
- Heise AL: Time required in rubber dam placement, *J Dent Child* 38(2):116–117, 1971.
- Croll TP: Restorative dentistry for preschool children, *Dent Clin North Am* 39(4):737–770, 1995.
- Collette J, Wilson S, Sullivan D: A study of the Isolite system during sealant placement: efficacy and patient acceptance, *Pediatr Dent* 32(2):146–150, 2010.
- Suwatviroj P, Messer LB, Palamara JE: The effects of cavity preparation and lamination on bond strength and fracture of tooth-colored restorations in primary molars, *Pediatr Dent* 25(6):534–540, 2003.
- Croll TP: Lateral-access class II restoration using resin-modified glass-ionomer or silver-cermet cement, *Quintessence Int* 26(2):121–126, 1995.
- Vaikuntam J: Resin-modified glass ionomer cements (RM GICs): implications for use in pediatric dentistry, *J Dent Child* 64(2):131–134, 1997.
- Marks LA, Weerheijm KL, Van Amerongen WE, et al.: Dyract versus Tytin class II restorations in primary molars: 36 months evaluation, *Caries Res* 33(5):387–392, 1999.
- Welbury RR, Shaw AJ, Murray JJ, et al.: Clinical evaluation of paired compomer and glass ionomer restorations in primary molars: final results after 42 months, *Br Dent J* 189(2):93–97, 2000.
- Hübel S, Mejäre I: Conventional versus resin-modified glass-ionomer cement for class II restorations in primary molars. A 3-year clinical study, *Int J Paediatr Dent* 13(1):2–8, 2003.
- Paquette DE, Vann WF, Oldenburg TR, et al.: Modified cavity preparations for composite resins in primary molars, *Pediatr Dent* 5(4):246–251, 1983.
- Oldenburg TR, Vann Jr WF, Dilley DC: Composite restorations for primary molars: two-year results, *Pediatr Dent* 7(2):96–103, 1985.
- Tonn EM, Ryge G: Two-year clinical evaluation of light-cured composite resin restorations in primary molars, *J Am Dent Assoc* 111(1):44–48, 1985.
- Dilley DC, Vann JW, Oldenburg TR, et al.: Time required for placement of composite versus amalgam restorations, *J Dent Child* 57(3):177–183, 1990.
- Donly KJ, Segura A, Kanellis M, et al.: Clinical performance and caries inhibition of resin-modified glass ionomer cement and amalgam restorations, *J Am Dent Assoc* 130(10):1459–1466, 1999.
- dos Santos MP, Passos M, Luiz RR, et al.: A randomized trial of resin-based restorations in class I and class II beveled preparations in primary molars, *J Am Dent Assoc* 140(2):156–166, 2009.
- Ekstrand KR, Bakhshandeh A, Martignon S: Treatment of proximal superficial caries lesions on primary molar teeth with resin infiltration and fluoride varnish only: efficacy after 1 year, *Caries Res* 44(1):41–46, 2010.
- Myer-Lueckel H, Bitter K, Paris S: Randomized controlled clinical trial on proximal caries infiltration: three-year follow-up, *Caries Res* 46(6):544–548, 2012.
- Martignon S, Ekstrand KR, Gomez J, et al.: Infiltrating/sealing proximal caries lesions: a 3-year randomized clinical trial, *J Dent Res* 91(3):288–292, 2012.
- Trairatvorakul C, Piwat S: Comparative clinical evaluation of slot versus dovetail class III composite restorations in primary anterior teeth, *J Clin Pediatr Dent* 28(2):125–130, 2004.
- McEvoy SA: A modified class III cavity preparation and composite resin filling technique for primary incisors, *Dent Clin North Am* 28(1):145–155, 1984.
- MacLean JK, Champagne CE, Waggoner WF, et al.: Clinical outcomes for primary anterior teeth treated with veneered stainless steel crowns, *Pediatr Dent* 29(5):377–381, 2007.
- Waggoner WF: Restoring primary anterior teeth, *Pediatr Dent* 37(2):163–170, 2015.
- Webber DL, Epstein NB, Wong JW, et al.: A method of restoring primary anterior teeth with the aid of a celluloid crown form and composite resins, *Pediatr Dent* 1(4):244–246, 1979.
- Kupietzky A, Waggoner WF, Galea J: Long-term photographic and radiographic assessment of bonded resin composite strip crowns for primary incisors: results after 3 years, *Pediatr Dent* 27(3):221–225, 2005.
- Roberson T, Heymann HO, Swift Jr EJ: *Sturdevant's art & science of operative dentistry*, ed 5, St. Louis, 2006, Mosby.
- Tagelsir A, Dean JA, Eckert GJ, et al.: U.S. Pediatric dentists' perception of molar incisor hypomineralization, *Pediatr Dent* 40(4):272–278, 2018. Retrieved from <http://docserver.ingentaconnect.com/deliver/connect/aapd/01641263/v40n4/s6.pdf?expires=1565096121&id=0000&titleid=75004753&checksum=063709F8CD7ACB2E47957AE420680306>. NOW 30.
- Radcliffe RM, Cullen CL: Preservation of future options: restorative procedures on first permanent molars in children, *J Dent Child* 58(2):104–108, 1991.
- Humphrey WP: Uses of chrome steel in children's dentistry, *Dent Surv* 26:945–949, 1950.
- Randall RC: Prefabricated metal crowns for primary and permanent molar teeth: review of the literature, *Pediatr Dent* 24(5):489–500, 2002.
- Seale NS: The use of stainless steel crowns, *Pediatr Dent* 24(5):501–505, 2002.



35. Spedding RH: Two principles for improving the adaptation of stainless steel crowns to primary molars, *Dent Clin North Am* 28(1):157–175, 1984.
36. Mink JR, Hill CJ: Modification of the stainless steel crown for primary teeth, *J Dent Child* 38(3):61–69, 1971.
37. Yilmaz Y, Kocogullari ME: Clinical evaluation of two different methods of stainless steel esthetic crowns, *J Dent Child (Chic)*. 71(3):212–214, 2004.
38. Jung YS, Lee JW, Choi YJ, et al.: A study on the in-vitro wear of the natural tooth structure by opposing zirconia or dental porcelain, *J Adv Prosthodont* 2(3):111–115, 2010.
39. Donly KJ, Sasa I, Contreras CI, et al.: Prospective randomized clinical trial of primary molar crowns: 24-month results, *Pediatr Dent* 40(4):253–258, 2018.
40. Saber AM, El-Housseiny AA, Alamoudi NM: Atraumatic restorative treatment and interim therapeutic restoration: a review of the literature, *Dent J (Basel)* 7(1):28, 2019. Retrieved from [https://res.mdpi.com/d\\_attachment/dentistry/dentistry-07-00028/article\\_deploy/dentistry-07-00028.pdf](https://res.mdpi.com/d_attachment/dentistry/dentistry-07-00028/article_deploy/dentistry-07-00028.pdf). <https://doi.org/10.3390/dj7010028>.
41. Aron VO: Porcelain veneers for primary incisors: a case report, *Quintessence Int* 26(7):455–457, 1995.
42. Faunce FR, Faunce AR: The use of laminate veneers for restoration of fractured or discolored teeth, *Tex Dent J* 93(8):6–7, 1975.
43. Lee JG, Moore BK, Avery DR, et al.: Bonding strengths of etched porcelain discs and three different bonding agents, *J Dent Child* 53(6):409–414, 1986.
44. Nixon RL: Masking severely tetracycline-stained teeth with ceramic laminate veneers, *Pract Periodontics Aesthet Dent* 8(3):227–235, 1996.
45. Hjertton PM, Er Bagesund M: YAG laser or high-speed bur for cavity preparation in adolescents, *Acta Odontol Scand* 71(3-4):610–615, 2013.
46. Olivi G, Margolis FS, Genovese MD: *Pediatric laser dentistry, A user's guide*, Chicago, 2011, Quintessence Publishing Co., Inc.
47. Kidd E: Should deciduous teeth be restored? reflections of a cariologist, *Dent Update* 39(3):159–166, 2012.
48. Dean JA: Response to the Letter to the Editor, *Pediatr Dent* 38(3):190, 2016. Retrieved from <http://docserver.ingentaconnect.com/deliver/connect/aapd/01641263/v38n3/s3.pdf?expires=1565096001&id=0000&titleid=75004753&checksum=E86B05BC33B1AE741988C9ED3041D27>.
49. Innes NPT, Evans DJP: Modern approaches to caries management of the primary dentition, *Br Dent J* 214:559–566, 2013.
50. Ludwig KH, Fontana M, Vinson LA, et al: The success of stainless steel crowns placed with the Hall technique: a retrospective study, *J Am Dent Assoc* 145(12):1248–1253, 2014. Retrieved from [https://scholarworks.iupui.edu/bitstream/handle/1805/6159/Ludwig\\_2014\\_sccess.pdf?sequence=1](https://scholarworks.iupui.edu/bitstream/handle/1805/6159/Ludwig_2014_sccess.pdf?sequence=1). <https://doi.org/10.14219/jada.2014.89>.
51. Schwendicke F, Krois J, Robertson M, et al.: Cost-effectiveness of the Hall technique in a randomized trial, *J Dent Res* 98(1):61–67, 2019, <https://doi.org/10.1177/0022034518799742>.
52. Welbury RR: The Hall technique 10 years on: its effect and influence, *Br Dent J* 222(6):421–422, 2017, <https://doi.org/10.1038/sj.bdj.2017.262>.
53. Elamin F, Abdelazeem N, Salah I, et al.: A randomized clinical trial comparing Hall vs conventional technique in placing preformed metal crowns from Sudan, *PLoS One* 14(6):e0217740, 2019. Retrieved from <https://www.ncbi.nlm.nih.gov/pmc/articles/PMC6546341/pdf/pon0217740.pdf>. <https://doi.org/10.1371/journal.pone.0217740>.
54. Croll TP: Tooth bleaching for children and teens: a protocol and examples, *Quintessence Int* 25(12):811–817, 1994.
55. Croll TP, Segura A: Tooth color improvement for children and teens: enamel microabrasion and dental bleaching, *J Dent Child* 63(1):17–22, 1996.
56. Croll TP, Helpin ML: Enamel microabrasion: a new approach, *J Esthet Dent* 12(2):64–71, 2000.
57. Haywood VB: Nightguard vital bleaching: current concepts and research, *J Am Dent Assoc* 128:19S–25S, 1997.
58. Gerlach RW, Gibb RD, Sagel PA: A randomized clinical trial comparing a novel 5.3% hydrogen peroxide whitening strip to 10%, 15% and 20% carbamide peroxide tray-based bleaching systems, *Compend Contin Educ Dent* 21:811–817, 1994.
59. Brantley DH, Barnes KP, Haywood VB: Bleaching primary teeth with 10% carbamide peroxide, *Pediatr Dent* 23(6):514–516, 2001.
60. Donly KJ, Gerlach RW: Clinical trials on the use of whitening in children and adolescents, *Gen Dent* 50(3):242–245, 2002.
61. Donly KJ, Segura-Donly A, Baharloo L, et al.: Tooth whitening in children, *Compend Contin Educ Dent* 23(1A):22–28, 2002.
62. Donly KJ, Kennedy P, Segura A, et al.: Effectiveness and safety of tooth bleaching in teenagers, *Pediatr Dent* 27(4):298–302, 2005.
63. Croll TP, Segura A, Donly KJ: Enamel microabrasion: new considerations in 1993, *Practical Periodontics Aesthet Dent* 5(8):19–29, 1993.
64. Waggoner WF, Johnston WM, Schumann S, et al.: Microabrasion of human enamel in vitro using hydrochloric acid and pumice, *Pediatr Dent* 11(4):319–323, 1989.
65. Donly KJ, O'Neil M, Croll TP: Enamel microabrasion: a microscopic evaluation of the "abrosion effect." *Quintessence Int* 23(3):175–179, 1992.
66. Donly KJ: The adolescent patient: special whitening challenges, *Compend Contin Educ Dent* 24(4A):390–396, 2003.

## 13

# Dental Materials

SABRINA FEITOSA-SOCHACKI and JEFFREY A. PLATT

**CHAPTER OUTLINE****Regulatory Considerations****The Tooth-Restoration Interface**

Overview

**Treatment of the Cavity Preparation**

Dental Pulp Protection

Bonding to the Tooth Structure—Acid Etching

Bonding to the Tooth Structure—Primer

Bonding to the Tooth Structure—Adhesive

**Temporary and Permanent Restorations****Restorative Resins**

Composite Resin

Microfilled Composites

Hybrid Composites

Bulk-Fill Composites

Flowable Composites

Light-Cured Composites

Posterior Composite Restoration

Resin Inlays

Light-Curing Units

**Amalgam**

Selection of the Alloy

High-Copper Alloys

Mercury/Alloy Ratio

Trituration

Mechanical Amalgamators

Condensation

Moisture

Marginal Breakdown and Bulk Fracture

Bonded Amalgam Restorations

Mercury Toxicity

**Ceramics****Other Aesthetic Alternatives/Fiberglass-Reinforced Resin****Cements**

Luting Cements

**Bioactive Dental Materials**

## Regulatory Considerations

Development of materials to meet the challenging needs of restorative dentistry is accomplished under the guidance of a series of standards that provide thresholds for different properties considered to be important for clinical success. The American National Standards Institute, working through the American Dental Association (ADA), governs standards development in the United States. These standards have become international in scope through the work of the International Organization for Standardization (ISO), providing more global consistency for the profession. The standards are often used to show suitability for the marketplace when marketing approval is sought from the Food and Drug Administration in the United States or from similar organizations in other countries.

Concerns about infection control and ease of delivery have resulted in many materials being supplied in unit dose packaging. Eliminating bulk packaging has greatly reduced chairside disinfection concerns. Another area of concern involves the safety of individuals working with restorative materials. In the United States, the Occupational Safety and Health Administration is responsible for developing and enforcing standards deemed necessary to ensure workplace safety. Most countries have similar oversight entities. Many dental materials contain hazardous components and create a risk for an adverse biologic response. Safety data sheets

are supplied by manufacturers that provide important precautionary information to minimize exposure risks and treatment guidance for inappropriate exposures. The ADA provides several compliance resources to assist the dentist/owner in meeting regulatory requirements.

## The Tooth-Restoration Interface

### OVERVIEW

A critical component in the success of an “ideal” restorative material involves the interaction along the tooth-restoration interface. Multiple investigations seem to indicate that the presence of a clinically intact interface can prevent the progression of caries, although maintaining a sealed interface is a challenge in the oral environment.

Key factors that challenge tooth-restoration interface stability include:

1. Changes in temperature
2. Mechanical stress
3. Cariogenic biofilms
4. Poor material adaptation during placement

Loss of interface integrity and subsequent microleakage may be the precursors of caries, marginal discoloration,

postoperative sensitivity, and pulp pathology. Microleakage poses a particular concern for teeth in the pediatric patient because the floor of the cavity preparation may be close to the pulp. The added insult to the pulp caused by the seepage of irritants that penetrate around the restoration and through the thin layer of dentin, or a microscopic pulpal exposure, may produce irreversible pulp damage. There is a lack of strong evidence that microleakage laboratory testing correlates with clinical performance of materials. However, there is significant clinical evidence that providing a good seal inhibits caries progression under a restoration. This makes the formation of a good tooth-restoration interface a significant concern.

The concept of bonding involves mechanical interlocking, chemical bonding, and a mixed mechanism. For the mechanical bonding mechanism, acid etching is commonly used to accomplish the bonding of a restorative resin to enamel followed by the application of a liquid adhesive that will flow into the enamel surface irregularities and then solidify. For true adhesion to occur, bonding takes place at a molecular level and involves a chemical interaction between the molecules of the adhesive and the solid surface. Dental materials such as the glass-ionomer cements (GICs) are current examples of this potential for true adhesion to tooth structure and have an established clinical record of success.

Advancements in adhesive science have provided materials for all types of unusual applications, yet dental substrates remain a challenge. A tooth possesses numerous undesirable characteristics as a substrate for bonding of an adhesive. Dentin and enamel are rough, inhomogeneous in composition, covered with a tenacious layer of surface debris, and wet. These factors discourage adhesion. Furthermore, the reactivity (surface energy) of enamel and dentin is fairly low, and therefore, the surface does not easily attract other molecules. When fluoride is included in the mineral structure of the tooth, the surface energy is further reduced.

On the other hand, the surface energy of most restorative materials, particularly metallic ones, is higher than that of normal intact tooth structure. Therefore, debris accumulates on the surfaces of restorations more than on the adjoining enamel. In addition, biofilms form readily on methacrylate-based materials. This could contribute to the incidence of recurrent caries associated with most restorative materials. Biofilm accumulation can promote marginal deterioration by the loss of tooth structure or adhesive at the interface. Such conditions would be expected to increase microleakage and its associated negative outcomes.

Marginal leakage has been of greater concern with resins than with any other restorative material. Amalgam restorations tend to counteract the microleakage phenomenon by the formation of corrosion products along the tooth-restoration interface. Other restorative materials may provide a mechanism for resisting secondary caries attributable to microleakage, such as the fluoride released from GIC. With most direct restorative resins, however, there is no inherent resistance to the dangers of marginal penetration of deleterious agents beyond some attempts to incorporate antibacterial components in the materials. This reality challenges the dentist in maintaining good adaptation of the resin restoration material to the tooth surface under oral conditions.

## Treatment of the Cavity Preparation

### DENTAL PULP PROTECTION

When the preparation approaches the pulp tissue, a hard-setting calcium hydroxide formulation has long been used as a therapeutic aid associated with dentin bridge formation between the material and remaining vital pulp tissue. When placed directly on the pulp, this material causes necrosis of the superficial pulp tissue, stimulates odontoblast activity, and subsequently results in dentin formation. Early versions of calcium hydroxide liners were very susceptible to dissolution and had poor mechanical properties. Newer versions have been improved, but calcium hydroxide does not seal the dentin. GIC or resin-modified GIC liners placed over calcium hydroxide provide a level of protection from future bacterial penetration. Dental adhesives used with resin composite restorations can provide this protection, more predictably when the restoration margins are all in enamel.

Newer approaches to pulp-capping and pulpotomy methodologies include using materials containing calcium silicate and calcium aluminate. Calcium silicates modified with light-activated resins form lining materials with enhanced dentin interaction when compared to calcium hydroxide. Mineral trioxide aggregate (MTA) is a mixture of Portland cement, bismuth oxide, and gypsum. In primary teeth, MTA is indicated in the treatment of vital teeth with deep caries lesions treated with pulpotomy and direct pulp capping. Factors that need to be considered when using MTA are: (1) the cost of the product that sometimes is provided as single use; (2) the possibility of a grayish discoloration of the remaining tooth; and (3) long setting time. To address tooth discoloration, companies currently provide this material in two colors, gray and white (tooth-colored). Although marketed as tooth-colored MTA, some staining is still present with the white composition. Therefore, the American Academy of Pediatric Dentistry recommends that clinicians should alert parents or guardians regarding the possibility of tooth staining. An attractive feature of MTA is its antibacterial potential against some facultative bacteria such as *Streptococcus mitis*, *S. mutans*, and *S. salivarius*, even though there may be no effect against strict anaerobic bacteria, such as *Bacteroides fragilis*, *Prevotella intermedia*, and *Fusobacterium nucleatum*.

### BONDING TO THE TOOTH STRUCTURE—ACID ETCHING

Various materials are used in the cavity preparation prior to placement of the final restoration. In preparations that do not approach the pulp, the method of cavity surface preparation is dependent upon the final restorative material. After the tooth preparation, a thin layer (approximately 1.0  $\mu\text{m}$ ) called the smear layer is formed by tooth debris, saliva, and bacteria. For glass-ionomer restorations, the smear layer is removed with a polyacrylic acid-based conditioner, followed by placement of the glass-ionomer material directly onto the tooth. For resin composite restorations, enamel and dentin are treated according to the type of dental adhesive selected. Dental adhesive systems use a separate acid to prepare the tooth surface (etch-and-rinse) or use an adhesive that is inherently acidic (self-etch or glass-ionomer). Some systems have multiple components, whereas other systems are supplied as a single component.



Acid gels, like 37% phosphoric acid (etch-and-rinse system), or a bonding system that can penetrate beyond the smear layer (self-etch system) helps to remove the smear layer, resulting in a clean and rough enamel and dentin surface capable of mechanically interlocking with the resin-based material. The dentin-bonding systems that first exhibited good bond strengths involved removal of the dentin smear layer and decalcification of the outer layer of intact dentin with an acid.

For etch-and-rinse three- or two-step systems, enamel and dentin are acid-etched with phosphoric acid gel for 15–20 seconds. The next critical step in the technique is the use of a water rinse to remove the produced debris and the etchant. If the surface is not flushed clean, the resin will not wet the etched surface. Therefore, a minimum wash time of 30 seconds is often recommended. If an enamel adhesive or pit-and-fissure sealant is being placed, the etched surface must be dried for at least 15 seconds before the resin is placed. Differently than in enamel, dentin should be lightly dried in order to avoid the collapse of the collagen fibrils.

If the surface is accidentally contaminated by saliva, the salivary film cannot be completely removed by simply being washed. Rather, the surface should be re-etched for 10 seconds, then washed and dried. An etched enamel surface is shown in Fig. 13.1A. In addition to providing a seal between the resin and tooth, the acid-etch technique results in mechanical retention. The acid cleans the enamel to provide better wetting of the resin and creates pores into which the resin flows to produce “tags” that greatly increase retention (Fig. 13.1B). The resulting bond should reduce the possibility of marginal staining, which is a potential outcome of microleakage.

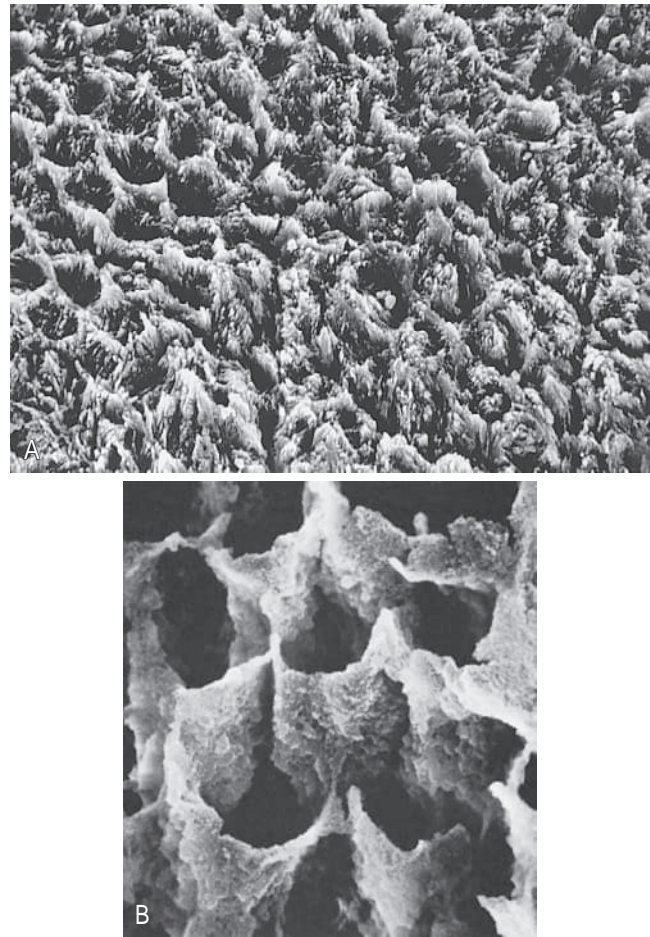
### BONDING TO THE TOOTH STRUCTURE—PRIMER

For etch-and-rinse three-step dentin adhesives, after acid etching, the dentin receives the application of a thin layer of hydrophilic primer. For etch-and-rinse two-step adhesives, primer and adhesive are mixed with a solvent in the same bottle. It is important to highlight that adhesive systems can be etch-and-rinse or self-etch. For the etch-and-rinse systems (three- and two-step systems), the dentist follows three steps (acid + primer + adhesive) or two steps (acid + combined primer-adhesive). For the self-etch systems, the dentist follows one step (one bottle) or two steps (combined acid-primer + adhesive).

### BONDING TO THE TOOTH STRUCTURE—ADHESIVE

As an adjunct to the acid-etch technique, manufacturers formerly supplied enamel-bonding agents. The bonding agent consisted of bisphenol A–glycidylmethacrylate (bis-GMA) resin matrix material diluted with a low-viscosity methacrylate monomer. After acid etching the enamel, the bonding agent is used. The composite resin is then immediately placed, and it is in turn bonded to the intermediate layer of the resin-bonding agent. The resulting bond to the tooth structure is strictly mechanical. Some current orthodontic bonding resins and pit-and-fissure sealants resemble these early enamel-bonding agents.

Successful bonding to dentin has gone through multiple generations of development. Early efforts to etch dentin and apply enamel-bonding agents were not successful. The



**Fig. 13.1** Effects of acid etching. (A) Scanning electron micrograph of enamel surface etched with phosphoric acid. (B) Scanning electron micrograph of resin tags formed by penetration of resin into etched enamel surface (5000x). (A and B from Anusavice KJ: *Phillips' Science of Dental Materials*. 11<sup>th</sup> ed. St. Louis: WB Saunders; 2003, courtesy of K.J. Söderholm.)

structure of dentin is far more complex, and it has a lower concentration of hydroxyapatite. Because of the microstructural organization of dentin, the regular etch patterns seen with enamel are not produced. Due to the organic component of dentin and the permeability that results from the dentinal tubules, the vital dentin surface has low surface energy and is constantly wet. This presents the ultimate challenge for adhesion. For many years, research has focused on the development of agents that will bond adhesively to dentin. This has led to the introduction of dental adhesives, which are either chemically activated or light cured. They are applied to enamel and dentin before placement of the composite. For two- or three-step systems, a thin layer of the adhesive should be applied, and the excess solvent should be evaporated by applying air followed by light curing according to the manufacturer's instructions. This results in the creation of a hybrid layer between the intact dentin and the resin adhesive because resin components in the primer penetrate the decalcified dentin, reacting with and modifying the remaining dentin structure. High laboratory bond strengths are generally reported for these systems, along with generally accepted clinical performance.

Current advances have focused on the development of adhesive systems that simplify the steps involved in their

application. Acidic primers that are self-etching have been introduced. These simultaneously demineralize and penetrate the smear layer and underlying dentin. Other systems combine the primer and the resin adhesive into one component. These simplified systems mix the acidic primer and resin adhesive before they are placed on the tooth surface. Even though these newer systems use fewer separate components, their application still requires that several steps be performed with great attention to detail. New products that have been gaining attention are the universal dentin adhesives, which are self-etch adhesives (one-step dentin adhesives). These materials can be used as etch-and-rinse and self-etch dentin adhesives. Some of these adhesives also include active molecules for interaction with ceramic and metallic surfaces. Use of these materials remains extremely technique sensitive. The status of these agents remains controversial, particularly with regard to their long-term stability in the oral cavity. Until these matters are resolved, it would be prudent not to deviate too far from accepted restorative procedures. One should assume that the newer dental adhesives will not eliminate the need for the use of traditional methods for retention of resin restorations, such as acid etching of the enamel and retentive cavity preparations when bonding to dentin or cementum.

Overall, the chemistry of different products is complex and varied. Some agents rely on micromechanical retention, whereas there is some evidence that others form chemical bonds to the organic or inorganic portions of the dentin. However, even with growing evidence that the dental adhesives currently marketed may form chemical bonds to dentin, it is more likely that the primary bonding mechanism is micromechanical. Performance is often supported by reports of bond strengths to dentin. Tensile bond strengths appear to provide better clinical relevance than shear bond strengths. Often, the bond strengths measured in vitro decrease markedly with time, exposure to water, and thermocycling. The presence of matrix metalloproteinases and collagenases in etched dentin appears to contribute to bond degradation as does the presence of microbial biofilms.

Analysis of laboratory data has shown incompatibility between some of the newer dental bonding systems and restorative resins or resin cements that are activated by chemical or dual means. Many of the resins used for crown buildup as core materials fall into these categories. The use of acidic primers may interfere with the chemical activation of these resin materials unless a separate resin adhesive is placed over the primer and light-activated before the core material or cement is placed. The simplified adhesive systems are also relatively hydrophilic and act as permeable membranes, allowing water to move through the adhesive layer and interfere with the bond to the overlying resin, particularly if curing is delayed.

Current dental adhesives are to be used with both dentin and enamel. Bond strengths reported for etched enamel usually equal those for the original enamel-bonding agents that have largely disappeared. Regardless of whether an auxiliary resin-bonding agent is used, adequate etching of the enamel is an important step in securing micromechanical bonding of any restorative resin to enamel. Some of the systems that use self-etching primers or acids other than phosphoric acid do not routinely yield enamel bond strengths as high as expected with conventional acid

etching. Conventional phosphoric acid etchants can be used to ensure etching of the enamel margins of a cavity preparation in what is called a selective etching technique. Questions exist about the effectiveness of dental bonding systems with self-etching primers when these are used in place of phosphoric acid treatment for bonding orthodontic appliances and pit-and-fissure sealing.

In the context of dental bonding, one should not ignore the polyacrylic acid systems. GIC has been recommended as a dentin-bonding agent in the so-called sandwich technique. Fast-setting GICs are available as cavity liners (type III GIC and light-cured GIC). The enamel is not covered with GIC; rather, it is acid-etched in the conventional manner. A resin-bonding agent is then applied and a composite resin placed. The ionomer bonds adhesively to the tooth, whereas the bonding agent bonds mechanically to the ionomer and the enamel. This adds yet another dimension to dentin bonding technology, particularly for class II restorations.

Dental resins are irritating to the pulp, as are several other commonly used restorative materials. Whenever the cavity preparation is deep, the same precautions should be taken with resins as with other restorative materials.

## Temporary and Permanent Restorations

Temporary restorations should possess good biologic characteristics; have minimal solubility; and be rigid, strong, and resistant to abrasion. The relative importance of each of these properties depends on the degree of permanence desired. For example, in the caries-affected mouth, it is often desirable to remove some or all of the caries immediately and place temporary restorations which are subsequently replaced with more permanent restorative materials. In such situations, the temporary restoration may need to serve for several months or longer. Strength and resistance to abrasion and dissolution are of paramount importance in these cases. In most cases, however, temporary restorations need to remain in place only for days. For short-duration restorations, emphasis may be placed on the biologic properties when the restorative material is selected.

For intermediate restorations, zinc oxide–eugenol cement has long been used because of its excellent tissue tolerance and ability to minimize the effects of initial microleakage. The strength, rigidity, and resistance to abrasion of conventional zinc oxide–eugenol mixtures are improved by the addition of polymers and by the surface treatment of the zinc oxide powder.

Type II GICs or the newer resin-modified GICs are also useful as long-term, temporary restoratives. Because of its desirable biologic and adhesive characteristics, GIC can be used without the need for a retentive cavity preparation. If conventional GICs are used as restorative materials, they must be protected from exposure to moisture in the early stages of setting and from dehydration for a very long time, preferably the entire time the restoration will serve. Resin-modified glass ionomer is sometimes chosen because of its ability to be rapidly light cured.

The GIC formulations that include enhanced filler composition to improve their mechanical properties have higher viscosity and are advocated for atraumatic



**TABLE 13.1** Classification of Direct Restorative Resin Composites

By Filler Size and Content	By Use or Characteristic	By Activation Mechanism
Hybrid	Multipurpose	Light cured
Microhybrid	Bulk-fill	Chemically cured
Microfill	Flowable	Dual cured
Nanohybrid	Core	
Nanocomposite	Provisional	

restorative treatment applications and for class I and class II restorations in the primary dentition. Improvements in the mechanical properties of these “reinforced” GICs have shown promise in some clinical trials. Whether their mechanical properties, such as fracture toughness, are adequate to resist masticatory stress for long periods of time is yet to be shown.

## Restorative Resins

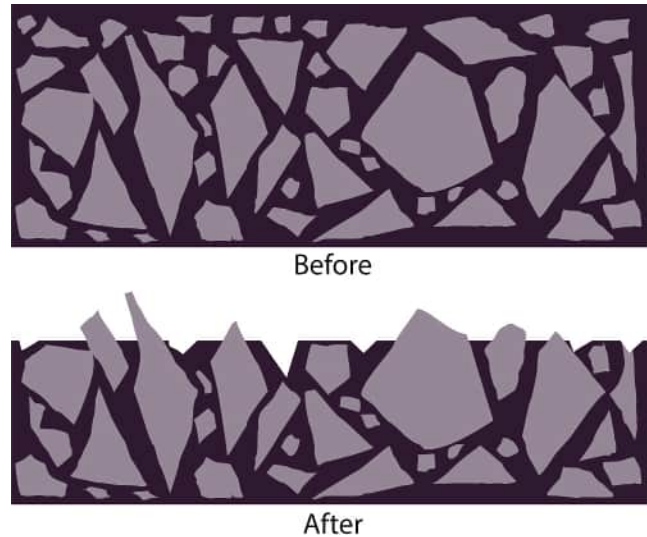
### COMPOSITE RESIN

The term composite material refers to a multiphase material with a distinct interface separating the components. When properly constructed, the combination of materials results in properties that could not be obtained with any of the components alone. In a resin composite dental restorative material, inorganic filler is added to a resin (organic) matrix in such a way that the physical and mechanical properties of the matrix are improved.


Several filler characteristics have a pronounced influence on the ultimate composite properties. The shape, size, orientation, concentration, and distribution of the filler are very important. The filler size has been used as one method of classifying these materials (Table 13.1).

Likewise, the composition of the resin matrix has a significant impact on the properties. The resin matrix of most of the currently available composite materials is based on combinations of bis-GMA, urethane dimethacrylate, and triethylene glycol dimethacrylate, which is a low-viscosity resin added as a diluent. Among the materials used for macrofillers are ground particles of fused silica; crystalline quartz; and soft glasses such as barium, strontium, and zirconium silicate glass. These particles, which make up 70% to 80% of the material by weight of multipurpose composites, enhance the physical and mechanical properties of the material. When compared with an unfilled acrylic resin, the composite resins demonstrate increased stiffness and hardness, a reduced coefficient of thermal expansion, and reduced polymerization shrinkage.

The filler and the resin matrix may be chemically bonded together with a coupling agent on the surface of the filler. If this bonding is not accomplished, the particles may be easily dislodged, water sorption at the filler-matrix interface may take place, and stress transfer between matrix and filler may not occur. Despite the use of this coupling system, the filler particles do become dislodged during cutting and finishing and under abrasive action such as toothbrushing or occlusal contact. This abrasive action likely affects the



**Fig. 13.2** Schematic drawing of a conventional composite resin with macrofiller (black areas) before and after finishing or wear. (Redrawn from Phillips RW: *Science of Dental Materials*, 9<sup>th</sup> ed. Philadelphia: WB Saunders; 1991.)

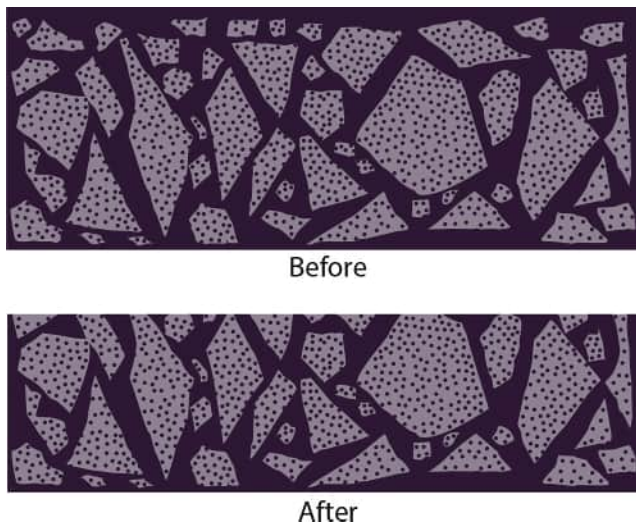


**Fig. 13.3** Scanning electron micrograph showing generalized wear of a hybrid composite exposing the enamel margin.

softer resin matrix, which can erode and expose the filler particles. When enough of the filler particle is exposed, it will break free of the resin. This process continually leaves a rough surface (Figs. 13.2 and 13.3). Because the composites are 70% to 80% filled, this surface roughness is clinically noticeable.

Based on clinical experience, there has been a definite preference for use of smaller filler particles. In the early resin composites, it was common for the particle size to approach 100  $\mu\text{m}$ ; now the coarsest particles would not exceed 30  $\mu\text{m}$ . The average mean particle size of the fillers in conventional composites is in the range of 8 to 12  $\mu\text{m}$ . So-called nanohybrid composites and nanocomposites contain fillers as small as 0.002  $\mu\text{m}$ .





**Fig. 13.4** Structure of a microfilled resin showing microfiller (dots) and prepolymerized macrofiller particles before and after being finished. (Redrawn from Phillips RW: *Science of Dental Materials*, 9<sup>th</sup> ed. Philadelphia: WB Saunders; 1991.)

## MICROFILLED COMPOSITES

Efforts to improve the surface smoothness and polishability of composite resins led to the development of the microfilled composite. These composites are based on the use of an extremely small silica filler particle of size 0.02 to 0.04  $\mu\text{m}$ ; therefore they are called microfine, microfilled, or polishable resins. The particles may be dispensed directly into the paste, but the amount that can be added in this manner is very limited. Addition of amounts in excess of 20% results in a paste too viscous for the dentist to use.

Matrix resin monomer can be heavily filled with microfine silica and polymerized in the manufacturing process. The resulting composite is ground to filler particle sizes comparable with those of the inorganic filler in conventional composite. This “organic” filler with additional colloidal silica is then added to the resin monomer to form the composite resin paste. The structure of such a resin is illustrated in Fig. 13.4. Including these fillers results in filler content of about 50% by weight compared with a filler loading of 70% to 80% for conventional composites. Thus, the microfilled composite has higher resin matrix content. Consequently, such resins are softer and have a slightly higher coefficient of thermal expansion, higher water absorption, more polymerization shrinkage, and somewhat lower mechanical properties.

The appealing characteristic of these microfilled resins is their ability to be finished to an extremely smooth surface, which was a major challenge with the conventional composites. When microfilled resins are finished, the polymerized resin filler particles cut at the same rate as the matrix, which results in a much smoother surface, as shown in Fig. 13.4. Even if some of the very small silica particles are dislodged, the surface irregularities cannot be detected visually. Microfilled resins should be used where aesthetics is the principal consideration and where undue stress will not be placed on the restoration, such as in class III or class V restorations. When the restoration is subject

to stress, such as the incisal margin of a class IV restoration, a composite having better physical properties is preferred. The development of different types of hybrid composites has significantly reduced the use of microfilled composites.

## HYBRID COMPOSITES

The conventional macrofilled composite is no longer in common use. Filler sizes have been continuously reduced to approach the surface smoothness of the microfilled resin but retain the filler levels and physical properties of the conventional composite. Most composites currently marketed are the result of this move toward smaller particle size. They contain microfine filler particles (0.01–0.1  $\mu\text{m}$ ) and fine particles (0.1–10  $\mu\text{m}$ ). The total filler level in a hybrid resin is significantly higher than that in a microfill resin, at 70% to 80% by weight. Because these composites combine two types of sizes of fillers in the same resin matrix, they are called hybrid composites.

Although the surfaces of hybrid resins are not as smooth as those of microfilled resins, these resins find extensive anterior use if they are carefully polished. In addition, one of the primary motivations in the development of these hybrid materials was to find a material that could compare favorably with dental amalgam in wear resistance in class I and II restorations. (The use of composites in such situations is discussed in the section on posterior composite restorations.) The most recent trend in composite resins has been the marketing of multipurpose restorative materials for use in either anterior or posterior applications.

Nanoparticles are now included in the nanocomposite and nanohybrid composite materials. These particles range from 0.002 to 0.075  $\mu\text{m}$  and are formed from sols of silica or zirconia. It is apparent that much of this size range was present in the microfill resins, making the nomenclature somewhat misleading. However, improved filler manufacturing techniques have resulted in filler levels approaching 80% for these materials. Their polishability and relatively good mechanical properties have made them popular clinical choices for many applications.

## BULK-FILL COMPOSITES

Bulk-fill composite is gaining attention as a restorative material since it can be placed in thicker increments, ranging in size from 3 to 5 mm, while conventional composites can be placed in increments up to 2 mm. The clinical indication varies according to the manufacturer and with the depth of cure of the selected material, but usually includes, class I, II, III, IV, and V restorations. The advantages of using bulk-fill restorations include reduced chair time and reduced porosities in the restoration. The disadvantages are that the light passing through the restoration exponentially decreases with the increased resin thickness, and that some restorations are too large for one increment. Currently, to enhance the chances of a successful bulk-fill restoration as with other composite resins, it has been recommended that the operator use a calibrated and well-maintained light-curing unit. It is important to keep the tip of the light-curing unit in position for the entire cure time to ensure thorough

polymerization of the entire restoration. This can be better accomplished by requiring the dentist and staff to wear appropriate protective glasses when light curing, so that the position of the light can be observed and maintained during the procedure and that all regions of the restorations will be exposed to the light (multiple exposures).

## FLOWABLE COMPOSITES

Flowable composites have become popular for small restorations and are marketed for use in nonstress-bearing restorations such as class V, as a liner under restorative materials, and as pit-and-fissure sealants. Filler content is decreased, or matrix monomers changed to decrease the viscosity of the resin composite. This generally comes with a sacrifice of mechanical properties. Recently, bulk-fill flowable restorative composites have been introduced into the market as a microhybrid resin with zirconia and silica fillers (3M ESPE). Similar to the traditional bulk-fill composite, the flowable version of the material can be placed in one increment up to 4 mm. The indicated uses for bulk-fill flowable restorative composites are similar to flowables that are not bulk-fill composites.

## LIGHT-CURED COMPOSITES

Originally, composite resins were chemically activated, which required the mechanical mixing of two pastes to initiate the chemical reaction. Light-cured or light-activated composites have largely supplanted the chemically activated composites. Light-activated resins do not differ significantly in composition from the chemically activated resins except for the polymerization activation mechanism. However, light curing provides an advantage in working time and other handling characteristics. The dentist has complete control over the working time and is not confined to the rather short working time of the chemically activated systems. This is particularly beneficial when large restorations such as class IV restorations are placed or when working with the pediatric population.

Most currently available visible light-cured resins contain the photosensitive initiator camphorquinone, which absorbs visible light at wavelengths between 450 and 500 nm (blue light) and forms free radicals that activate an amine accelerator. Because of the yellow color of camphorquinone, other photoinitiators such as phenylpropanedione and 2,4,6-trimethylbenzoyl-diphenylphosphine oxide have also been used in some lighter-shade composites.

One major disadvantage of light-cured composites must be emphasized. Polymerization will occur only if the resin is exposed to light of sufficient intensity for an adequate length of time. The top surface of a restoration, which is nearly in direct contact with the light source, will always be cured if the light and resin are serviceable. However, the curing of the portion of the restoration farthest removed from the light is less certain. Normally this portion of the restoration is not accessible for any kind of probing to test its hardness. If the cure is incomplete on the bottom side of the resin compared with the top surface, the physical properties will be reduced and a color shift may occur in time. Likewise, unpolymerized monomer may increase the potential for pulpal irritation. Microleakage is another potential

scenario. For ensuring maximum polymerization, the end of the light source should be within 1 mm of the surface of the resin and the depth of most resins should not exceed 2.5 mm. Furthermore, the curing time should match the manufacturer's recommendation for the type of light unit and resin shade. Larger restorations and dark shades of resin require an incremental placement technique.

Dual-activated resins are available that combine both light and chemical activation. In situations in which light access to parts of the restoration is problematic, a dual-activated material may be preferred. Bulk-fill composites have recently been introduced that provide a 4–5 mm depth of cure through the use of refined filler geometry, highly sensitive photoinitiators, or very light resin shades.

Essential components of the light-curing technique include:

1. Position the patient for maximum control.
2. Stabilize the light guide during the curing cycle.
3. Be sure the end of the light guide is clean and not damaged.
4. Begin the polymerization with the guide about 1 mm away from the resin surface.
5. After 1 second, move the guide as close to the resin surface as possible.
6. Wear eye protection to allow for visual monitoring of the curing cycle.

When visible light-curing systems were first introduced into dentistry, considerable emphasis was placed on the claim that the light output of the unit remained constant with use, unlike the previously used ultraviolet light units. Unfortunately, this statement is only partially true. Numerous factors influence the light output of a visible light-curing unit, such as power line variations, aging of the filters, aging of the lamp, damage to the light-conducting pipe or optic fiber, and resin buildup on the end of the light tip. Many visible light activation units have built-in meters to verify adequate light intensity. Inexpensive meters are available for this purpose and should be used regularly. If such a device is not available, a simple curing light usage test should be performed to ensure adequate light intensity. Place a mass of light-curing resin that is about the thickness of a nickel over a Mylar matrix strip on a sheet of white paper. Cover this mass with a Mylar matrix strip. Holding the curing light within 1 mm of the top surface, cure the resin for the length of time normally used. Remove the Mylar matrix strips and probe both the top and bottom resin surfaces with an explorer. There should be no noticeable difference in hardness or scratch resistance. Dark shades of composite resin may require longer curing times or curing of a thinner layer according to the manufacturer's instructions. If a comparable cure on both top and bottom cannot be achieved, the combination of resin and curing light is unsatisfactory for clinical use.

## POSTERIOR COMPOSITE RESTORATION

Composite resins were originally used for anterior or lower-stress applications such as class III, IV, and V restorations. They are now widely used for class I and II restorations. Early attempts with conventional macrofilled composites failed because of unacceptable wear on the occlusal surface.

Only in the case of conservative restorations in primary dentition was any success observed. A major goal of composite resin research has been to develop properties adequate for use as alternatives to dental amalgam.

The improved strength, hardness, and modulus of elasticity of newer composite resins, with their low thermal conductivity and superior aesthetics, indicate that they may serve in the restoration of occlusal and proximal surfaces in posterior teeth (class I and II restorations). Extensive clinical testing has been performed to compare the performance of these new resins with that of amalgam. Resin composites now exist with documented clinical wear of less than 20  $\mu\text{m}/\text{year}$  over a 5-year period. The patient and guardian should be cautioned that the performance of these restorations over long periods ( $\geq 5$ –10 years) should be monitored for wear and occlusal relationships.

The dentist needs to be aware of two additional factors when choosing composite resins for posterior occlusal service. Although the microleakage problems with anterior composite restorations have been significantly reduced by the development of the acid-etch enamel-bonding technique, posterior class II restorations often have gingival margins in dentin or cementum. Furthermore, the class II restoration presents a proximal surface with poor, if any, direct access to the curing light. (As mentioned under the heading “Light-Cured Composites” earlier in this chapter, exposure to light of adequate intensity is essential to cure a light-cured composite.) Various solutions have been suggested, including the use of light-conducting interproximal wedges. Probably the best general procedures are to utilize incremental buildup and pay careful attention to the light-curing technique.

Another challenge with posterior restorations is related to the curing shrinkage pattern. Most composite resins exhibit linear shrinkage of 2% or more during curing. The light-cured composite hardens first on the surface immediately adjacent to the curing light tip. Consequently, the direction of shrinkage is toward well-bonded enamel interfaces and away from the floor of the preparation or the gingival margin. This places the largest stresses from curing shrinkage on the sections of resin that are least well cured and whose bond to the tooth structure may be the poorest. Increased microleakage may be the result. Recent developments have resulted in the marketing of new resin matrix systems with very low polymerization shrinkage. Analysis of laboratory data shows that these materials minimize polymerization stresses at the resin interface. The use of liners with a lower modulus of elasticity also reduces these stresses and potentially increases adaptation of the material to the tooth. Long-term clinical data, however, are not available to fully substantiate the importance of these laboratory observations.

Resin composites are greatly compromised by moisture contamination during placement, so effective isolation of the operative field is essential. Operative techniques that control moisture are critical to reduce this risk, described in [Chapter 13](#).

Knowledge about the safety of composite resins is important. A resin monomer often used in restorative resin composites is bis-GMA. This monomer is the reaction product of bisphenol A and a dimethacrylate. Bisphenol A is chemically similar to synthetic estrogen. Therefore,

concerns have been raised about the potential for promoting certain types of malignancies. Complete conversion of the bisphenol A during the synthesis of bis-GMA resin monomers does not occur, and trace amounts can be found in dental composites. Although bisphenol A is commonly used in many commercial polymers for non-dental uses, its use in food or drink containers, particularly in resin baby bottles, is severely restricted. Components used in the light activation of polymerization initiation are very reactive. Traces of these components remain after the resin has hardened. Moreover, enzymes in biofilms, saliva, and in oral tissues may promote degradation of dental resins, which could release reactive species. It is important that the dental consumer, who may be the parent of a pediatric patient, be aware of the risks and benefits of the dental materials used in a proposed treatment plan.

The clinical application of pit-and-fissure sealants is discussed elsewhere in this text; however, some comments about these materials are relevant to the discussion of light-activated resin composites. Clinicians often tend to assume that a sealant is so thin that if the surface is hard, the material is properly polymerized. Cross-sections through extracted molar teeth show that thicknesses exceeding 2 mm are common in occlusal pits. Deep developmental grooves may have exposed dentin at the bottom, and if the bottom of the sealant is not adequately polymerized, the dentin is in contact with reactive components of the resin. The geometry of the occlusal surface may result in reduced light intensity because of the distance of the tip from the occlusal grooves. Use of a large-diameter curing tip further reduces the intensity. Opaque sealants are popular, but the opacity also reduces the light transmitted to the bottom of the sealant. Adequate polymerization is a function of the energy delivered to the entire mass of the resin. Radiant exposure is the product of light intensity and the activation time. Good light curing of opaque sealants requires meticulous attention to detail.

## RESIN INLAYS

Some of the shortcomings of composite resins, particularly the difficulties involving placement and light curing (discussed previously), can be minimized with the use of direct or indirect resin inlay restorations. The indirect inlay restoration is fabricated in the laboratory on a die poured from an impression of the prepared tooth—similar to a wax pattern for a cast restoration—whereas the direct resin inlay is fabricated in the operatory. In the latter instance, a separating medium is applied to the prepared tooth prior to the placement and light curing of the resin. Then, the direct inlay is removed from the mouth and subjected to additional curing procedures. Finally, the finished inlay is cemented in the mouth with resin cement.

Both techniques allow better access for light curing the composite, and the finished restoration can be subjected to additional curing under intense light, heat, pressure, or some combination of these. In theory, the properties of the resulting composite are maximized, and the presence of unreacted monomer is minimized. More importantly, the polymerization shrinkage occurs outside the mouth. The stresses at the tooth-restoration interface should be much lower than that in direct-placement resin restorations.





Fig. 13.5 Rechargeable, battery-powered, light-emitting diode light activation unit.

## LIGHT-CURING UNITS

The original visible light activation units incorporated a quartz-tungsten-halogen lamp (QTH) as a light source. This light is filtered to retain the wavelengths between 400 and 500 nm (blue light). One of the benefits of using QTH units is the low-cost technology. The disadvantages of using QTH units are the low efficiency and the frequent need for bulb replacement as they decrease in output. In an effort to accomplish more rapid polymerization of a greater thickness of resin, manufacturers have marketed other light sources, such as plasma arc lamps and lasers. Both are significantly more expensive than the QTH units, and there is evidence that more rapid polymerization may increase polymerization shrinkage stresses at the tooth-resin interface. The most popular type of activation unit uses blue light-emitting diodes (LED). LEDs are nearly 100% efficient at generating light over a relatively narrow wavelength band (often from 460 to 480 nm). The diodes are commonly made of indium, gallium, and nitride. Variations in concentrations of these elements within the diode can shift the spectral output of the light, and some lights now contain multiple diodes. These lights are often self-contained, rechargeable, battery-powered activation lights that internally generate less heat than QTH units. (More than 95% of the electrical energy delivered to a QTH light becomes heat and light at wavelengths longer than 500 nm.) An LED light maintains a fairly constant output throughout its lifetime but is dependent on a well-charged battery. High-output LED units can provide enough energy to burn tissue and should not be held against the mucosa for long periods of time.

The total power delivered in the 400- to 500-nm band from LED lights was initially much lower than that of QTH units. Recently marketed LED lights have significantly improved power output, and the useful light intensity for some LED units exceeds that of the best QTH units. A significant advantage of the LED lights appears to be convenience because they do not require a power cord fixed to a base unit (Fig. 13.5). The disadvantages are the cost and the constant need to recharge the battery. Because of the risk of retinal damage to the operator, patient, and staff, protective glasses or shields are recommended to protect the eyes from the glare of the intense light produced by visible-spectrum curing lights.

## Amalgam

Controversy regarding the safety of the dental amalgam restoration has existed since the material was introduced to the profession more than 150 years ago. Periodically, this controversy surfaces in the news media and becomes a matter for public and professional debate. In 2012 the inclusion of dental amalgam in the United Nations Environment Program Mercury Treaty brought heightened awareness to dentistry's impact on the environment. As a result, the dentist who uses dental amalgam can expect questions to be raised by patients and their guardians and can expect requests for replacement of intact amalgam restorations with other materials.

Amalgam is no longer the most commonly used material for restoring posterior caries lesions. Tooth-colored restorative materials are increasingly being used. The popularity of dental amalgam likely will continue to decline as these other materials demonstrate their longevity and their suitability as general amalgam replacements in the permanent dentition.

The unique clinical success of amalgam during 150 years of use has been associated with many characteristics. It is likely that its excellent clinical service, even under adverse conditions, is related to the tendency for its microleakage to decrease as the restoration ages in the oral cavity. Although amalgam does not bond to the tooth structure, and the margins of an amalgam restoration may appear open, the restoration-tooth interface immediately below the exposed margin becomes filled with relatively insoluble corrosion products that inhibit leakage. Amalgam is unique from this standpoint. The microleakage around other restorative materials usually increases with time. Amalgam is the least technique-sensitive material of all current direct restorative materials. Another unique property of amalgam as a direct filling material is its lack of dimensional change during hardening. The ADA specification for dental amalgam limits its maximum acceptable dimensional change to  $\pm 0.2\%$ . If this is compared with a common value of 2% or higher for the polymerization shrinkage of a resin matrix composite material, the potential impact on microleakage is obvious.

Nevertheless, failures of amalgam restorations are observed. These may occur in the form of recurrent caries, fracture (either gross or severe marginal breakdown), dimensional change, or involvement of the pulp or periodontal membrane. More significant than the type of failure is its cause. Two factors that lead to such clinical failures are improper design of the prepared cavity and faulty manipulation. In other words, the deterioration of amalgam restorations can often be associated with the clinician's neglect in observing the fundamental principles of cavity design or abuse in preparing and inserting the material. Another factor involved is the choice of the alloy used.

## SELECTION OF THE ALLOY

Several criteria are involved in the selection of an amalgam alloy. The first criterion is that the alloy should meet the requirements of ADA Specification No. 1 or ISO Specification 24234.

The manipulative characteristics of dental amalgam are extremely important and a matter of subjective preference.

Rate of hardening, smoothness of the mix, and ease of condensation and finishing vary with the alloy. For example, the resistance felt with lathe-cut amalgams during condensation is entirely different from that with spherical amalgams. The alloy selected must be one with which the dentist feels comfortable because the operator variable is a major factor influencing the clinical lifetime of the restoration. Use of alloys and techniques that encourage standardization in the manipulation and placement of the amalgam enhances the quality of the service rendered. Coincident with this is the delivery system provided by the manufacturer—its convenience, expediency, and ability to reduce human variables.

Obviously, the physical properties should be reviewed in the light of claims made for the superiority of one alloy over competing products. Ideally such a list of properties should be accompanied by documented clinical performance in the form of well-controlled clinical studies. Although the cost of the alloy is a factor, this criterion should not be overemphasized when balanced against the alloy's ability to render maximum clinical service. The dentist should always consider the fractional costs of any material compared with the overall total charges for a dental procedure when making price comparisons among brands, particularly when comparing a brand with documented clinical performance against a generic brand of material.

Dental amalgam alloys generally are available as either small filings called lathe-cut alloys or spherical particles called spherical alloys. Spherical alloys tend to amalgamate readily. Therefore amalgamation can be accomplished with smaller amounts of mercury than required for lathe-cut alloys, and the material gains strength more rapidly. Also, the condensation pressure and technique used by the dentist in placing the restoration are somewhat less critical in achieving the same properties of the amalgam. This is an advantage in difficult clinical situations in which optimal access for condensation is limited. Spherical amalgam alloys have a somewhat different feel during condensation and require less condensation pressure than do lathe-cut alloys. The dentist and auxiliary personnel should familiarize themselves with the handling characteristics of a new alloy before placing clinical restorations.

## HIGH-COPPER ALLOYS

The original dental amalgam alloys comprised silver and tin with a maximum of 6% copper. When significantly more copper is available, improved laboratory properties and clinical performance have been demonstrated. This improvement has been attributed to the displacement of the tin-mercury reaction product with a copper-tin phase during the amalgamation reaction. Alloys that contain enough copper to eliminate the formation of the tin-mercury phase (from 11% to 30%) are called high-copper amalgam alloys. The first such alloy of this type was an admixed system. Small spherical particles of a silver-copper alloy were added to filings of a conventional silver-tin alloy. High-copper alloys can also be made with single-composition particles. Each of these alloy particles has the same chemical composition, usually silver, copper, and tin. Amalgams made from high-copper alloys have low creep. Creep is the tendency of a material to deform continuously under a constant applied

stress and has been associated with the marginal breakdown (ditching) of amalgam restorations. Creep of modern high-copper amalgam alloys is less than 1%. Choice of amalgam alloy today should be limited to high-copper alloy systems.

Regardless of the alloy used, manipulation plays a vital role in controlling the properties and the clinical performance of the restoration.

## MERCURY/ALLOY RATIO

Most of the properties of amalgam restorations have been shown to depend on the relative amount of mercury contained in the finished restoration (the residual mercury). One variable that controls the final mercury content is the amount of mercury required to mix the amalgam.

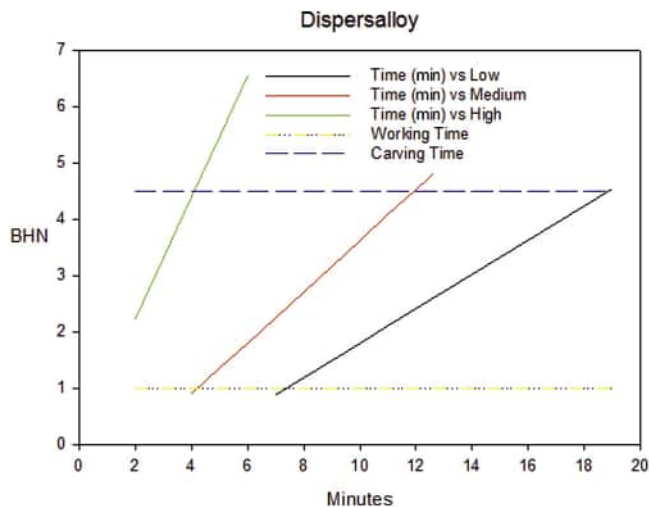
Amalgam alloy is sold in the form of prefilled, disposable mixing capsules containing the proper amounts of alloy and mercury. This delivery system provides several advantages. The alloy/mercury ratio is accurately preproportioned. The need for disinfection procedures is minimized because the capsule system is discarded after use. Most importantly, exposure of dental personnel and environmental contamination by mercury vapor are minimized. These prefilled capsules are usually available for mixes of different sizes, often called single- or double-spill capsules.

## TRITURATION

The second manipulative variable that controls the residual mercury content is trituration. Trituration time can significantly influence both consistency and working time of the mixed amalgam. These in turn relate to the ability to bring excess mercury to the surface during condensation. The correct trituration time varies depending on the composition of the alloy, the mercury/alloy ratio, the size of mix, and other factors. The best practice is to acquire an appreciation for the appearance of a proper mix and then to adjust the trituration time accordingly. The most serious error in amalgamation is generally undertrituration. An undertritured mix appears dry and sandy and does not cohere into a single mass. Such an amalgam will set too rapidly, which results in high residual mercury content, reduced strength, and the increased likelihood of fracture or marginal breakdown. Properly mixed amalgam is a shiny, coherent mass that can be readily removed from the capsule.

## MECHANICAL AMALGAMATORS

When first introduced, mechanical amalgamators for dental amalgam operated at a single speed that was usually below 3000 cpm. High-copper alloys in prefilled, self-activating capsules are designed for shorter trituration times at higher trituration speeds. Failure to activate these capsules reliably results in undertrituration and is a common problem with the use of older single-speed amalgamators. Because amalgamators also deteriorate with time, replacement of an older unit with a new high-speed amalgamator is desirable. A unit that allows multiple speeds of operation should be selected because numerous other products such as dental cements are now marketed in capsules to be mixed in a dental amalgamator. The



**Fig. 13.6** The influence of amalgamator speed (low-medium-high) on the hardening rate of a high-copper amalgam alloy, as measured by the Brinell hardness test (BHN). BHN = 1.0 indicates the working time and BHN = 4.5 indicates the carving time. (Redrawn from Brackett W. Master's thesis. Indianapolis: Indiana University School of Dentistry; 1986.)

trituration times suggested by the amalgam alloy supplier are starting points. Amalgamators may vary in operating speed even within the same brand, and a unit's performance may vary with line voltage or the number of times it is used in rapid succession. Trituration speed and time significantly influences the rate at which some amalgams harden (Fig. 13.6).

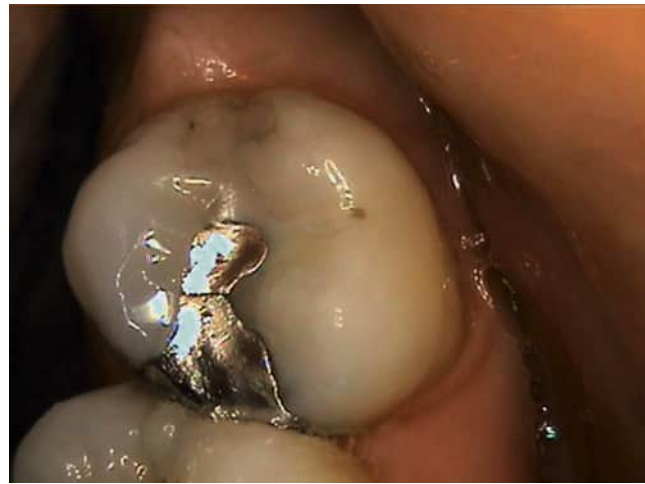## CONDENSATION

The purpose of condensation is to adapt the amalgam to the walls of the cavity preparation as closely as possible, to minimize the formation of internal voids, and to express excess mercury from the amalgam. Within reasonable limits, the greater the condensation pressure, the lower the amount of residual mercury left in the restoration and the greater the strength of the restoration. The selection of the condenser and the technique of "building" the amalgam should be designed to achieve those objectives, as described in detail in textbooks of operative dentistry, and should be tailored to the handling characteristics of the type of amalgam alloy chosen.

## MOISTURE

Moisture contamination of an amalgam restoration can promote failure. If zinc is present in the alloy, it will react with water, and hydrogen gas will be formed. As this gas builds up within the amalgam, a significant delayed expansion can occur and may cause protrusion of the amalgam from the cavity preparation, which enhances the possibility of fracture at the margins.

Such moisture contamination can result from failure to maintain a dry field during the placement of the restoration. Exposure to saliva after the amalgam has been completely condensed is not harmful. It is only moisture incorporated within the amalgam as it is being prepared or inserted that must be avoided.



**Fig. 13.7** Bulk fracture of an amalgam restoration. Such failure may occur from improper cavity design or premature occlusal loading.

Zinc-free alloys are available, and their physical properties are generally comparable with those of their zinc-containing counterparts. A zinc-free, high-copper alloy should be used when the dentist operates in a field where moisture control is difficult.

## MARGINAL BREAKDOWN AND BULK FRACTURE

Because dental amalgam is a brittle material, a commonly observed type of amalgam failure is the restoration in which the marginal areas have become severely chipped. The exact mechanisms that produce this breakdown of the amalgam or the adjoining tooth structure are not established, but it is likely that the deterioration is precipitated by manipulation and the finishing technique rather than by dimensional changes during setting.

If the restoration is improperly finished by the dentist, a thin ledge of amalgam may be left that extends slightly over the enamel at the margins. These thin edges of such a brittle material cannot support the forces of mastication. In time they fracture, leaving an opening at the margins.

Bulk fracture of amalgam is much less common with high-copper amalgam alloys. Those cases that do occur likely have one of two causes. Poor cavity design resulting in an insufficient bulk of material across the isthmus can lead to failure of even a high-strength alloy, as illustrated in Fig. 13.7. The other reason for bulk fracture is premature loading of the restoration. Unlike a resin matrix composite, amalgam gains strength slowly over the first 24 hours. Premature loading can result in minute fractures that are not apparent for weeks or even months. The use of a rapid-setting amalgam with a high 1-hour compressive strength should be considered during the treatment of a pediatric patient in whom compliance with instructions to refrain from biting down hard on the freshly placed amalgam is in question.

## BONDED AMALGAM RESTORATIONS

Because dental amalgam does not adhere to the tooth structure, it must be retained mechanically by the design of the cavity preparation and/or mechanical devices such as pins.



The placement of an amalgam does not strengthen the compromised remaining tooth structure, and subsequent fracture may occur, particularly in molar teeth with relatively large mesio-distal-occlusal amalgam restorations. The use of dental adhesive systems, as described in detail in the section related to resin composites, as lining materials for amalgam to create a “bonded amalgam restoration” has been suggested. Several products are marketed specifically for this purpose. In general, they are chemically activated dentin-bonding systems over which the amalgam is condensed before the resin adhesive has hardened. This results in an intermixing of the unset resin and the plastic amalgam at the interface and forms a mechanical bond as both materials harden. It is important to distinguish this application from the use of a dental adhesive to seal the dentin surface and reduce early microleakage as previously discussed. When dental adhesives are used to seal the dentin surface, the adhesive should be polymerized before the amalgam is placed.

Bond strengths reported in laboratory studies between amalgam and dentin are lower than the maximum reported for resin composite bonded to dentin. In vitro studies also show that teeth restored with bonded amalgams are more resistant to fracture than those in which amalgam is placed without a bonding adhesive. These are relatively short-term laboratory studies. Even though longer-term clinical data are available, little is known about the potential influence of embedding the resin into the bulk of the amalgam on the long-term properties of the restoration. Currently, amalgam bonding should be considered only as an adjunct for conventional, accepted practices of cavity preparation and mechanical retention of amalgam.

## MERCURY TOXICITY

The amalgam restoration is possible only because of the unique characteristics of mercury. Mixing this liquid metal with the alloy powder provides a plastic mass that can be inserted into the tooth and then hardens rapidly to a structure that resists the rigors of the oral environment. As the restoration hardens, mercury reacts with silver and tin to form stable, intermetallic compounds. Most of the public controversy about the safety of dental amalgam has focused on the hazards associated with elemental mercury and some of its organic compounds. Many substances commonly regarded as quite safe contain extremely dangerous elemental ingredients. No one would ever consider human ingestion of elemental sodium or chlorine, but ordinary table salt, which is the compound sodium chloride, is an important dietary substance. Since the earliest use of amalgam, it has been questioned whether mercury in a dental restoration can produce local or systemic toxic effects in humans. It is periodically conjectured that mercury toxicity from dental restorations is the cause for numerous illnesses of unknown etiology.

The possibility of toxic reactions by the patient to traces of mercury penetrating the tooth or sensitization from mercury dissolving from the surface of the amalgam is remote. The danger has been evaluated in numerous studies. The patient's encounter with mercury vapor during insertion of the restoration is brief, and the total amount of mercury vapor is small. Furthermore, the amount of mercury

released from the amalgam in service is small compared with that released from other sources of mercury from air, water, and food. Metallic mercury in the human digestive tract is apparently not converted to lethal organo-mercury compounds and is excreted by the body.

Both the National Institutes of Health and the FDA have examined the evidence for risk of dental restorative materials to the patient. The conclusion was that, except for the very small fraction of the population with a true allergic reaction to mercury or other constituents of amalgam, the dental amalgam restoration remains a safe and effective treatment. No evidence was found that related the presence of amalgam restorations to disorders such as arthritis, multiple sclerosis, or other diseases in which amalgam has been implicated. It should be noted that no currently available restorative material is completely risk-free, and that patients should be informed of the relative risks associated with all dental treatment alternatives.

The question about the replacement of existing serviceable amalgams with other materials remains one of professional judgment. Both the ADA and some state dental licensing boards have found that a dentist who recommends replacement of amalgam restorations with other materials based on the claim that this will improve the physical health of the patient may be acting unethically and may be subject to sanctions by licensing bodies and to suits for civil damages. Patients who believe that they have medical problems related to the presence of any dental restorative material should be referred to a physician for diagnosis and treatment recommendations.

What about dental office personnel? Restorative dentists and their office personnel are potentially exposed to mercury daily, even in offices in which amalgam restorations are not being placed. Although metallic mercury can be absorbed through the skin or by ingestion, the primary risk to dental personnel is from inhalation. A potential hazard exists for both the dentist and staff from long-term inhalation of mercury vapor in the dental clinic, although the few actual incidents reported have been related to poor mercury handling technique. The maximum level considered safe for occupational exposure is 0.1 mg of inorganic mercury per cubic meter of air averaged over a standard 8-hour workday. Mercury at room temperature has a vapor pressure almost 400 times the maximum level considered safe. This vapor has no color, odor, or taste and cannot be readily detected by simple means at the level of maximum safe exposure. Because liquid mercury is almost 14 times denser than water, a small spill can be significant. Eliminating the use of bulk mercury by the use of prefilled, disposable capsules significantly reduces the exposure to mercury vapor.

The dental operatory should be well ventilated. All mercury waste and amalgam scrap removed during the placement or removal of amalgam restorations should be collected and stored in well-sealed containers. When amalgam is cut, water spray and high-speed evacuation should be used. More detailed recommendations can be obtained from materials published by the ADA. The risk to dental personnel from mercury exposure cannot be ignored. However, adherence to simple hygienic procedures will ensure a safe working environment.

Waste materials containing mercury or amalgam scrap should be disposed of responsibly in accordance with the

regulations of the local Environmental Protection Agency. These materials should not be incinerated or subjected to heat sterilization. Biologically contaminated wastes containing mercury, including extracted teeth, should be cold sterilized with a chemical agent before disposal. The most significant threat to the continued use of dental amalgam will likely be from government regulations on environmental waste discharge. In Japan, the use of amalgam has been discontinued because it is not feasible for a dental office using amalgam to meet restrictions on mercury discharge into sewers. Amalgam-mercury separators on dental clinic wastewater discharge lines are now required in several countries, including the United States, and are considered best practices by the ADA.

## Ceramics

Increased demands for aesthetic restorations and the encouraging performance of all-ceramic restorations in the permanent dentition have led to significant advances in dental ceramics. Dental ceramics are biocompatible, wear resistant, and present long-term color stability. Restorative dental ceramics can be classified as predominantly glassy materials (feldspathic glasses), particle-filled glasses (filler particles such as leucite are added to the glass content), and polycrystalline ceramics (no glass content, zirconia). Glass ceramics used in all-ceramic restorations provide highly aesthetic results, but their relatively low mechanical properties and brittle nature prohibit their predictable use in high-stress applications unless supported by a high-strength substrate. Polycrystalline ceramics, such as zirconia, are marketed for use as preformed crowns in pediatric applications as an aesthetic alternative to stainless-steel crowns. Because of the brittle nature of the material, these crowns cannot be crimped or adapted to a preparation. Retention is largely dependent on the luting agent and proper preparation, which requires more tooth reduction when compared to stainless steel crowns. Encouraging outcomes have been reported when using zirconia crowns, including an acceptable gingival index, closed margins, no opposing tooth wear, and no recurrent caries. Further evidence is needed to understand the clinical importance of this new treatment option.

## Other Aesthetic Alternatives/ Fiberglass-Reinforced Resin

Recently, a company released a preformed fiberglass-reinforced resin pediatric crown that is metal-free and tooth-colored as an alternative to ceramic preformed dental crowns. Although promising, currently there is no long-term clinical evidence supporting the use of this material.

## Cements

### LUTING CEMENTS

Cements are used for luting applications and as restorative materials. Luting cements are used to fill the space between

the tooth structure and restorations or appliances made outside of the mouth. Restorative applications of cements include temporary and permanent restorations and bases under other restorative materials. In addition, at least one cement is used as a pit-and-fissure sealant. The fundamental chemistry of the luting and restorative cements is similar. Changes are made in the formulation to enhance the viscosity of luting cements and the strength of restorative cements. Cements with particular interest in the pediatric population include the zinc oxide–eugenol, polycarboxylate, glass-ionomer, resin-modified glass-ionomer, self-adhesive resin, and resin cements.

Different applications are associated with different requirements for luting cements. When an indirect restoration such as a stainless-steel crown is luted, the ideal characteristics of the cement would include low solubility, the ability to bond to the tooth structure, and enough strength to resist dislodgement during function. When an orthodontic band that needs to be retrieved at some point is luted, the cement needs to be weak enough to be broken during band removal and must be easily cleansed from the tooth surface. Zinc phosphate cement was used historically for broad application. It finds very little use in today's pediatric practice.

Restorative cements are of lower strength than other direct restorative materials. This limits their use to temporary and low-stress permanent applications.

### Zinc Oxide–Eugenol Cement

The acid-base reaction between zinc oxide and eugenol results in a cement that can be used as both a luting and a restorative material. Because of its low strength and high oral solubility, zinc oxide–eugenol cement is not recommended as permanent luting cement. However, because of its exceptionally kind biologic behavior, it is often used as a base material, temporary luting cement, and temporary restorative material. Eugenol is an inhibitor for addition-polymerization resins and can interfere with subsequent use of resin cements, restorative materials, and even some impression materials. Because of this, non-eugenol zinc oxides cements are available.

### Zinc Phosphate Cement

Formerly, zinc phosphate cement was the most widely used luting agent. Composed essentially of phosphoric acid liquid that is mixed with zinc oxide powder, the cement has excellent handling characteristics such as setting time, fluidity, and film thickness. Furthermore, this type of cement has a long history of successful applications for permanent cementation. It does not have an anticariogenic effect, does not adhere to the tooth structure, and demonstrates a moderate degree of intraoral solubility.

Because of the phosphoric acid liquid, zinc phosphate cement is an irritant; proper pulp protection is therefore recommended. When experience indicates that sensitivity and pulp response are likely to be problems, the use of cement that is more biologically compatible, such as polycarboxylate cement, is recommended.

### Polycarboxylate Cement

When zinc polycarboxylate cement is used, the bond occurs between the carboxylic acid groups in the liquid polyacrylic

acid and the calcium in the tooth structure. The powder of the cement is essentially zinc oxide. This cement continues to maintain some presence in the marketplace because it offers good biocompatibility with the pulp tissue.

Because the ultimate properties are affected by changes in the water content of the liquid, the cement liquid should not be dispensed until just before the mix is to occur. Increases in the powder/liquid ratio make the cement less adherent to the tooth, whereas decreases in the ratio result in increased solubility. The powder is quickly added to the liquid and the mix completed within 30 seconds. If the surface of the cement is not glossy in appearance, the mix should be discarded and a new one prepared. The gloss is an indicator of the presence of the carboxylic acid groups required for cement-tooth bonding.

### Glass-Ionomer Cement

Another cement that is based on polyacrylic acid is GIC. Type 1 GIC is used for luting applications. Because of their fluoride release and potential for adherence to the calcium in the tooth, GIC formulations have been prepared for use as restorative materials (type II) and as base and liner materials (type III).

Like zinc polycarboxylate cement, the glass-ionomer liquid is a polyacrylic or other alkenoic acid, such as itaconic or maleic, with tartaric acid added to improve handling properties. The acid has the potential for bonding to calcium in the manner described for polycarboxylate. This chemical bond provides retention of the cement to the tooth.

The powder is a fluoroaluminosilicate glass and displays fluoride release patterns that change over time. Analysis of data from glass-ionomer restorations of class V erosion lesions for periods of more than 7 years indicates that GIC shows resistance to secondary caries. The desirability of the GIC system should be readily apparent: it has a potential for adherence to the tooth structure and possesses anticariogenic potential.

The material is supplied as a powder and liquid and is commonly preproportioned in a disposable capsule to be mixed in an amalgamator. With type I GIC, the liquid acid may be freeze-dried and combined in the powder. When this powder is mixed with water, the acid reconstitutes, resulting in the same setting reaction. The freeze-dried products have better shelf life and somewhat lower viscosity, which are important characteristics for luting cements.

The mix can be made either on a disposable, moisture-resistant paper pad or on a glass slab. For minimal contamination of the mix from abraded metal, a plastic spatula is preferred to a metal one. As with polycarboxylate cement, the polyacrylic-acid-based liquid is not dispensed until just before the start of the mix. GICs are mixed in a manner similar to polycarboxylate cements: large increments of the powder are rapidly incorporated into the liquid, and the mix should be completed within 40 seconds. The working time is short, usually no more than 3 minutes from the start of the mix. If the mix has lost its gloss or a skin has formed on the surface, the material should be discarded.

After setting, the material is more brittle than polycarboxylate cement. It can be trimmed and finished in a similar manner as zinc phosphate cement. Before the patient is dismissed, all the accessible margins should be covered with the varnish or protective resin supplied by the manufacturer.

This protects the cement from oral fluids and dehydration during the critical hours of the setting reaction.

Instances of postoperative sensitivity have been reported when GIC is used as a luting agent, particularly in deep preparations with minimal remaining dentin. This is possibly attributable to the low initial pH of the cement and its relatively slow set. As a guard against potential irritation, a liner such as calcium hydroxide should be placed in very deep areas. The cut dentin surface can be cleaned mechanically with pumice, but the smear layer should not be removed. After being cleaned, the dentin should be rinsed and dried but not desiccated. A slightly damp surface appears to help minimize sensitivity and does not interfere with the setting reaction.

Glass-ionomer luting cements have lower intraoral solubility and mechanical properties similar to those of zinc phosphate cements. Because of their potential for fluoride release and adhesion to tooth structure, they are popular for the luting of metallic restorations.

In addition to its use as a luting agent for metallic restorations, GIC has been used for luting orthodontic bands to posterior teeth and for bonding orthodontic brackets to acid-etched enamel. GIC has cohesive strength lower than that of the resin orthodontic adhesives, but the fluoride release from GIC should minimize the white spotting and decalcification sometimes seen around orthodontic brackets or bands.

### Resin-Modified Glass-Ionomer Cements

Resin monomers have been added to GIC to make *resin-modified GICs*. These cements, less appropriately referred to as hybrid glass ionomers or light-cured glass ionomers, are created by the addition of resin monomers or a co-monomer of acrylic acid and a methacrylate such as hydroxyethyl methacrylate to the glass-ionomer formulation. In addition to the powder-liquid options, these materials can be supplied as a paste-paste system. Either equal lengths of the pastes are dispensed and mixed or the pastes are dispensed through mixing tips. The known disadvantages of conventional glass ionomers (short working time, slow development of ultimate properties, sensitivity to both moisture exposure and dehydration during setting, and, when compared with resin cements, lower cohesive strength) have been largely addressed in the resin-modified GIC. The resin component hardens immediately on exposure to the light, which results in an initial set of the cement. The material then continues to undergo the acid-base GIC setting reaction that occurs more slowly than that of a conventional GIC, resulting in a much longer working time for the resin-modified glass ionomer. The rapid set after light exposure yields a material that is much less sensitive to dehydration or moisture. Type I resin-modified GIC luting cements have gained wide acceptance when used with metallic restorations; in this case the resin component is either chemically activated or dual activated (chemically and light). Resin-modified GIC type II restorative materials appear to exhibit the advantages of conventional GIC and have gained popularity because they facilitate decreased treatment times.

### Resin Cements

Derived from the composite resin systems used for restorative materials, resin luting cements may be viewed as lightly filled



composites. The resin matrix systems used are the same as, or closely related to, those used for restorative resins. Although these materials are not new to dentistry, they are becoming more extensively used. Their first major clinical application was in direct bonding of orthodontic attachments to acid-etched enamel, for which they quickly became the materials of choice. Similar formulations were developed with pit-and-fissure sealants. The resin-bonded bridge, such as the “Maryland” bridge, is another application in which resin cements came to the forefront. The demand for dentistry has resulted in extensive use of both resin and ceramic veneers. Here, too, resin cements are the cements of choice. In addition, new technology for fabricating all-ceramic crowns and inlays has greatly increased the use of these restorations. Because resin cements have high strength, low film thickness, very low oral solubility, and can be bonded to etched enamel, ceramics, resins, and etched or treated metal surfaces, they are the cements of choice for veneers and all-ceramic crowns. With the advent of dentin adhesives, resin cements provide the possibility of bonded, indirect restorations.

Resin cements are usually available in different shades for color matching beneath translucent restorations, and opaque cements are made for masking metal substructure or discolored tooth structure. The first resin cements were two-component, chemically activated curing systems. Visible light-activated, single-component systems are now available and popular when used with translucent restorative materials. Dual-activated (chemically and light) materials are recommended for use beneath thick restorations and in locations where geometry may limit access to the curing light.

Self-adhesive resin cements have become popular choices for luting applications. In principle, these materials are similar to the self-etch dental adhesives. They are acidic, do not require a separate adhesive, and form a thin hybrid layer with dentin as they polymerize. As a group, these materials do not have the same level of mechanical properties as traditional resin cements.

## Bioactive Dental Materials

Bioactive materials are capable of inducing a specific response from the living tissue, organisms, or cells. In the past, a material was considered bioactive if it was capable of releasing fluoride to enhance the conversion of hydroxyapatite to fluorapatite. Currently, bioactive materials can also present antimicrobial properties, stimulate the formation of reparative dentin or enamel, and stimulate bone growth. Resin-based products that release calcium and fluoride ions for remineralization purposes are in the marketplace. In endodontics, MTA has been used for hard-tissue conductive activity in pulp capping, pulpotomy, and apexification. In implant dentistry, the titanium dental implant surface spontaneously reacts with oxygen to form a self-repairing oxide layer which makes the implant surface resistant to corrosion and biocompatible.

### Suggested Readings

#### General

Anusavice KJ: *Phillips' science of dental materials*, ed 12, Philadelphia, 2013, WB Saunders.

Sakaguchi RL, Powers JM: *Craig's restorative dental materials*, ed 13, Philadelphia, 2012, Elsevier Mosby.

O'Brien WJ: *Dental materials and their selection*, ed 4, Chicago, 2008, Quintessence Publishing.

#### Dental pulp protection

Song JS, Mante FK, Romanow WJ, et al.: Chemical analysis of powder and set forms of Portland cement, gray ProRoot MTA, white ProRoot MTA, and gray MTA-Angelus. *Oral Surg Oral Med Oral Pathol Oral Radiol Endod* 102(6):809–815, 2006.

Dhar V, Marghalani AA, Crystal YO, et al.: Use of vital pulp therapies in primary teeth with deep caries lesions. *Pediatr Dent* 39(5):E146–E159, 2017.

Fuks AB, Peretz B: *Pediatric endodontics: current concepts in pulp therapy for primary and young permanent teeth*, Switzerland, 2016, Springer International Publishing.

Torbinejad M, Hong CU, Pitt Ford TR, et al.: Antibacterial effects of some root end filling materials. *J Endod* 21(8):403–406, 1995.

#### Adhesion

Buonocore MG: *The use of adhesives in dentistry*, Springfield, IL, 1975, Charles C. Thomas.

Peumans M, Kanumilli P, De Munck J, et al.: Clinical effectiveness of contemporary adhesives: a systematic review of current clinical trials. *Dent Mater* 21(9):864–881, 2005.

Garcia-Godoy F, Donly KJ: Dentin/enamel adhesives in pediatric dentistry. *Pediatr Dent* 24(5):462–464, 2002.

Gerdolle DA, Mortier E, Droz D: Microleakage and polymerization shrinkage of various polymer restorative materials. *J Dent Child* 75(2):125–133, 2008.

Heintze SD: Clinical relevance of tests on bond strength, microleakage and marginal adaptation. *Dent Mater* 29(1):59–84, 2013.

Heintze SD, Ruffieux C, Rousson V: Clinical performance of cervical restorations—a meta-analysis. *Dent Mater* 26(10):993–1000, 2010.

Mertz-Fairhurst EJ, Curtis Jr JW, Ergle JW, et al.: Ultraconservative and cariostatic sealed restorations: results at year 10. *J Am Dent Assoc* 129(1):55–66, 1998.

Van Meerbeek B, Peumans M, Poitevin A, et al.: Relationship between bond-strength tests and clinical outcomes. *Dent Mater* 26(2):e100–e121, 2010.

Sofan E, Sofan A, Palaia G, et al.: Classification review of dental adhesive systems: from the IV generation to the universal type. *Ann Stomatol (Roma)* 8(1):1–17, 2017.

#### Amalgam

Batchu H, Rakowski D, Fan PL, et al.: Evaluating amalgam separators using an international standard. *J Am Dent Assoc* 137(7):999–1005, 2006.

Browning WD, Johnson WW, Gregory PN: Clinical performance of bonded amalgam restorations at 42 months. *J Am Dent Assoc* 131(5):607–611, 2000.

Khangura DS, Seal K, Esfandiari S, et al.: *Composite resin versus amalgam for dental restorations: a health technology assessment*, 2018, Ottawa, CA.

Mahler DB, Engle JH: Clinical evaluation of amalgam bonding in Class I and II restorations. *J Am Dent Assoc* 131(1):43–39, 2000.

Mahler DB, Pham BV, Adey JD: Corrosion sealing of amalgam restorations in vitro. *Oper Dent* 34(3):312–320, 2009.

Marshall GW, Marshall SJ, Letzel H: Mercury content of amalgam restorations. *Gen Dent* 37:473–477, 1989.

Osborne JW, Summitt JB, Roberts HW: The use of dental amalgam in pediatric dentistry: review of the literature. *Pediatr Dent* 24(5):439–447, 2002.

Summitt JB, Burgess JO, Berry TG, et al.: The performance of bonded vs. pin-retained complex amalgam restorations: a five-year clinical evaluation. *J Am Dent Assoc* 132(7):923–931, 2001.

#### Cements

Chadwick BL, Evans DJ: Restoration of class II cavities in primary molar teeth with conventional and resin modified glass ionomer cements: a systematic review of the literature. *Eur Arch Paediatr Dent* 8(1):14–21, 2007.

Kloukos D, Pandis N, Eliades T: Bisphenol-A and residual monomer leaching from orthodontic adhesive resins and polycarbonate brackets: a systematic review. *Am J Orthod Dentofacial Orthop* 143(4):S104–112, 2013.

Mickenausch S, Yengopal V: Caries-preventive effect of glass ionomer and resin-based fissure sealants on permanent teeth: an update of systematic review evidence. *BMC Res Notes* 4(1):22, 2011.

Roberts HW, Toth JM, Berzins DW, et al.: Mineral trioxide aggregate material use in endodontic treatment: a review of the literature. *Dent Mater* 24(2):149–164, 2008.

Yengopal V, Mickenautsch S: Caries-preventive effect of resin-modified glass-ionomer cement (RM-GIC) versus composite resin: a quantitative systematic review, *Eur Arch Paediatr Dent* 12(1):5–14, 2011.

### Composites

Braga RR, Ballester RY, Ferracane JL: Factors involved in the development of polymerization shrinkage stress in resin-composites: a systematic review, *Dent Mater* 21(10):962–970, 2005.

Bücher K, Tautz A, Hickel R, et al.: Longevity of composite restorations in patients with early childhood caries (ECC), *Clin Oral Investig* 18(3):775–782, 2014.

Margeas R: Versatile composite resins simplifying the practice of restorative dentistry, *Compend Contin Educ Dent* 35(1):52–55, 2014.

Moore BK, Platt JA, Borges G, et al.: Depth of cure of dental resin composites: ISO 4049 depth and microhardness of types of materials and shades, *Oper Dent* 33(4):408–412, 2008.

Platt JA, Clark H, Moore BK: Curing of pit and fissure sealants using light emitting diode curing units, *Oper Dent* 30(6):764–771, 2005.

Price RB, Shortall AC, Palin WM: Contemporary issues in light curing, *Oper Dent* 39(1):4–14, 2014.

### Light-curing units

Malhotra N, Mala K: Light-curing considerations for resin-based composite materials: a review. Part I, *Compend Contin Educ Dent* 31(8):498–505, 2010; quiz 6, 8.

Santini A: Current status of visible light activation units and the curing of light-activated resin-based composite materials, *Dent Update* 37(4):214–216, 2010.

Alasiri RA, Algarni HA, Alasiri RA: Ocular hazards of curing light units used in dental practice—A systematic review, *Saudi Dent J* 31(2):173–180, 2019.

Toh SL, Messer LB: Evidence-based assessment of tooth-colored restorations in proximal lesions of primary molars, *Pediatr Dent* 29(1):8–15, 2007.

### Ceramics

Kelly JR, Benetti P: Ceramic materials in dentistry: historical evolution and current practice, *Aust Dent J* 56(Suppl 1):84–96, 2011.

Clark L, Wells MH, Harris EF, et al.: Comparison of amount of primary tooth reduction required for anterior and posterior zirconia and stainless steel crowns, *Pediatr Dent* 38(1):42–46, 2016.

Holsinger DM, Wells MH, Scarbecz M, et al.: Clinical evaluation and parental satisfaction with pediatric zirconia anterior crowns, *Pediatr Dent* 38(3):192–197, 2016.

### Bioactive dental materials

Lowe RA: Focus On" Bioactive Dental Materials, *Dent Today* 36(5):16, 2017.

Sonarkar S, Purba R: Bioactive materials in conservative dentistry, *Int J Contemp Dent Med Rev* 2015, 2015. Article ID: 340115.

## 14

# Treatment of Deep Caries, Vital Pulp Exposure, and Nonvital Teeth

JEFFREY A. DEAN and BRIAN J. SANDERS

## CHAPTER OUTLINE

### Diagnostic Aids in the Selection of Teeth for Vital Pulp Therapy

History of Pain

Clinical Signs and Symptoms

Radiographic Interpretation

Pulp Testing

Physical Condition of the Patient

### Evaluation of Treatment Prognosis Before Pulp Therapy

### Vital Pulp Therapy Techniques

### Treatment of the Deep Caries Lesion

Indirect Pulp Treatment (Gross Caries Removal or Indirect Pulp Therapy)

### Vital Pulp Exposure

Size of the Exposure and Pulpal Hemorrhage

Direct Pulp Capping

Pulpotomy

### Nonvital Pulp Treatment With Irreversible Pulpitis or Necrotic Pulp

Pulpectomy

### Summary of Pulp Therapy

### Restoration of the Pulpally Involved Tooth

### Reaction of the Pulp to Various Capping Materials and Use of Dental Stem Cells

Zinc Oxide–Eugenol

Calcium Hydroxide

Preparations Containing Formalin

Ferric Sulfate

Mineral Trioxide Aggregate

Other Capping Materials and Methods

Summary of Pulp Capping Materials

### Failures After Vital Pulp Therapy

Internal Resorption

Alveolar Abscess

### Early Exfoliation or Over Retention of Primary Teeth With Pulp Treatments

The last decade of research into dental pulp therapy has seen significant developments, from newer medicament application to vital tissue, which stimulate healthy tissue, enhanced clarification regarding success and efficacy of medicaments, endodontic tissue regeneration, and now to the possibility of the use of dental stem cells and scaffolding to produce new tooth components<sup>1</sup>. This chapter will cover the diagnosis and management of deep caries lesions, as well as vital and nonvital pulp therapy.

## Diagnostic Aids in the Selection of Teeth for Vital Pulp Therapy

### HISTORY OF PAIN

The history of either the presence or the absence of pain may not be as reliable in the differential diagnosis of the condition of the exposed primary pulp as it is in permanent teeth. Degeneration of primary pulp even to the point of abscess formation without the child recalling pain or discomfort is not uncommon. Nevertheless, the history of a toothache should be the first consideration in the selection of teeth for vital pulp therapy. A toothache coincident

with or immediately after a meal may not indicate extensive pulpal inflammation. The pain may be caused due to accumulation of food within a caries lesion, pressure, or chemical irritation to vital pulp protected by only a thin layer of intact dentin.

A severe toothache at night usually signals extensive degeneration of the pulp and calls for more than conservative pulp therapy. A spontaneous toothache of more than momentary duration occurring at any time usually means that pulpal disease has progressed too far for treatment, even with a pulpotomy.

### CLINICAL SIGNS AND SYMPTOMS

A gingival abscess or draining fistula associated with a tooth having a deep caries lesion is an obvious clinical sign of an irreversibly diseased pulp. Such infections can be resolved only by successful endodontic therapy or extraction of the tooth.

Abnormal tooth mobility is another clinical sign that may indicate a severely diseased pulp. When such a tooth is evaluated for mobility, the manipulation may elicit localized pain in the area, but this is not always the case. If pain is absent or minimal during manipulation of the diseased



mobile tooth, the pulp is probably in a more advanced and chronic degenerative condition. Pathologic mobility must be distinguished from normal mobility in primary teeth near exfoliation.

Sensitivity to percussion or pressure is a clinical symptom suggestive of at least some degree of pulpal disease, but the degenerative stage of the pulp is probably of the acute inflammatory type. Tooth mobility or sensitivity to percussion or pressure may be a clinical sign of other dental problems as well, such as a high restoration or advanced periodontal disease. However, when this clinical information is identified in a child and is associated with a tooth having a deep caries lesion, the problem is most likely to be caused by pulpal disease and inflammatory involvement of the periodontal ligament.

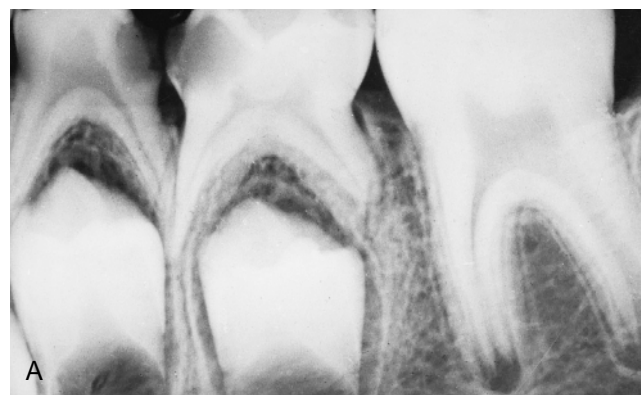### RADIOGRAPHIC INTERPRETATION

A recent x-ray film must be available to examine for evidence of periradicular or periapical changes such as thickening of the periodontal ligament or rarefaction of the supporting bone. These conditions almost always rule out treatment other than an endodontic procedure or extraction of the tooth. Radiographic interpretation is more difficult in children than in adults. The permanent teeth may have incompletely formed root ends, giving an impression of periapical radiolucency, and the roots of the primary teeth undergoing even normal physiologic resorption often present a misleading picture or suggest a pathologic change.

The proximity of caries lesions to the pulp cannot always be determined accurately in the x-ray film. What often appears to be an intact barrier of secondary dentin protecting the pulp may actually be a perforated mass of irregularly calcified and carious material. The pulp beneath this material may have extensive inflammation (Fig. 14.1). Radiographic evidence of calcified masses within the pulp chamber is diagnostically important. If the irritation to the pulp is relatively mild and chronic, the pulp will respond with inflammation and will attempt to eliminate the irritation by blocking (with irregular dentin) the tubules through which the irritating factors are transmitted. If the irritation is intense and acute, and if the caries lesion is developing rapidly, the defense mechanism may not have a chance to lay down the reparative dentin barrier, and the disease process may reach the pulp. In this instance the pulp may attempt to form a barrier at some distance from the exposure site. These calcified masses are sometimes evident in the pulp horn or even in the region of the pulp canal entrance. A histologic examination of these teeth shows irregular, amorphous masses of calcified material that are not like pulp stones (Fig. 14.2). The masses bear no resemblance to dentin or to a dentinal barrier and are always associated with advanced degenerative changes of the coronal pulp and inflammation of the tissue in the canal.

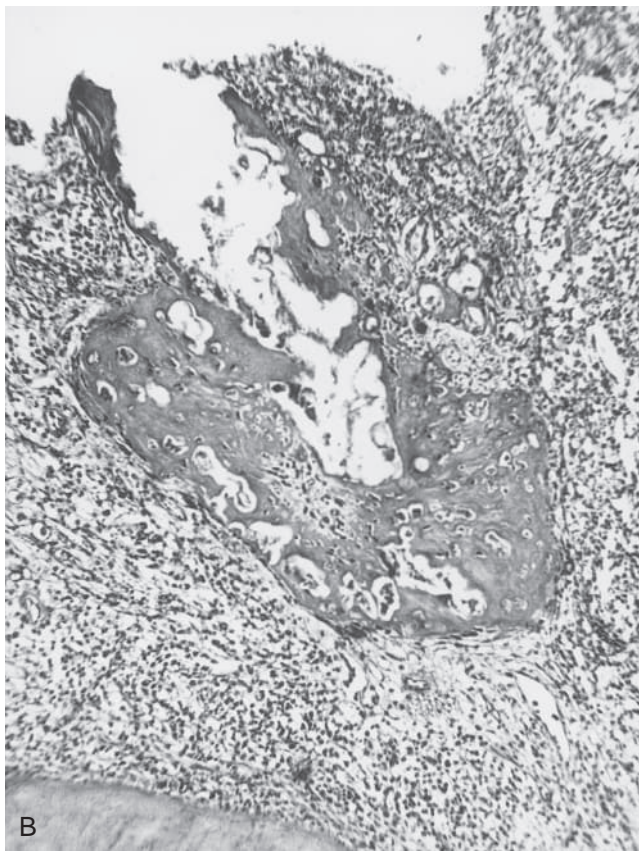
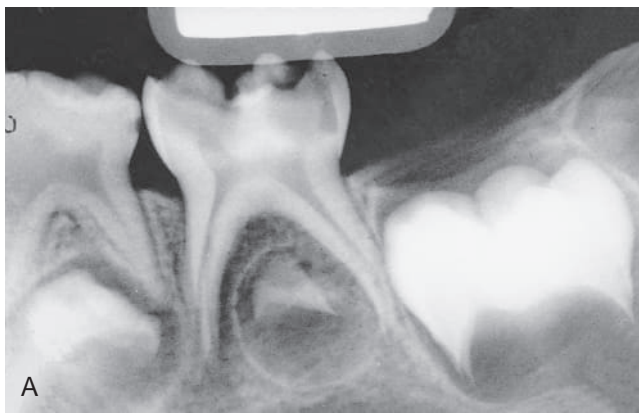### PULP TESTING

Historically, the value of the electric pulp test in determining the condition of the pulp of primary teeth has been viewed as questionable. Although it will give an indication of whether the pulp is vital, the test does not provide reliable evidence of the degree of pulpal inflammation. A complicating factor



**Fig. 14.1** (A) First primary molar appears to have an intact dentinal barrier beneath the caries lesion. (B) Histologic section shows a perforation of the barrier with necrotic material at the exposure site. There is advanced inflammation of the pulp tissue, which is likely to evoke a spontaneous pain response.

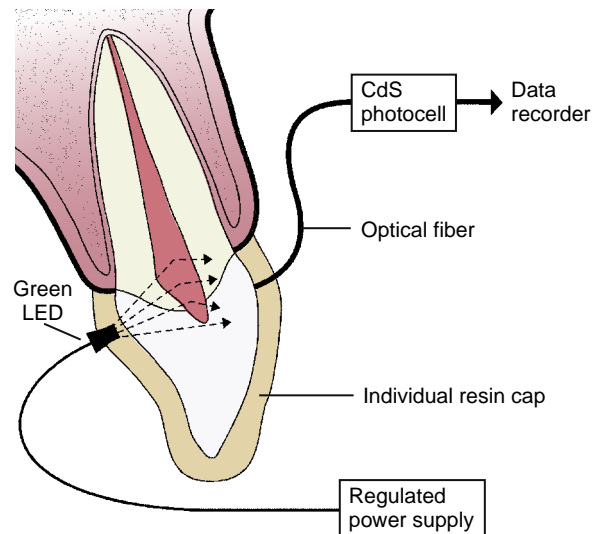
is the occasional positive response to the test in a tooth with a necrotic pulp if the content of the canals is liquid. The reliability of the pulp test for the young child can also be questioned sometimes because of the child's apprehension associated with the test itself. Thermal tests also have reliability problems in the primary dentition. The lack of reliability is possibly related to the young child's inability to understand the tests. However, Hori et al.<sup>2</sup> have found the electric pulp test to be reliable in diagnosing the pulp



**Fig. 14.2** (A) Calcified mass in the pulp chamber beneath the exposure site is associated with extensive inflammation of the pulp in the coronal area and in the pulp canals. (B) The amorphous mass is surrounded by pulp tissue with advanced inflammation.

status in primary teeth. On comparing the electric pulp test with thermal testing, they found the highest accuracy for the electric pulp test, followed by heat and then cold tests.

Several noninvasive techniques have been developed and advocated for recording the blood flow in human dental pulp. Two of these methods include the use of a laser Doppler flowmeter and transmitted-light photoplethysmography. As shown in the schematic in Fig. 14.3, these methods essentially work by the transmission of a laser or light beam through the crown of the tooth; the signal is picked up on the other side of the tooth by an optical fiber and photocell. A distinct advantage of this technique is its noninvasive nature, particularly in comparison with electric pulp testing. Not only is there inaccuracy in the response of the pulp



**Fig. 14.3** Schematic drawing of transmitted-light photoplethysmography. LED, Light-emitting diode. (Adapted from Miwa Z, Ikawa M, Iijima H, et al. Pulpal blood flow in vital and nonvital young permanent teeth measured by transmitted-light photoplethysmography: a pilot study. *Pediatr Dent.* 2002;24(6):594–598.)

to electric stimuli but also, the electric pulp tester may elicit pain. Because the testing may be uncomfortable for young patients, further dental treatment may be affected. A study by Miwa et al.<sup>3</sup> suggested that the transmitted-light technique can detect pulpal blood flow in young permanent teeth and is thus applicable to the assessment of pulp vitality. Recent research has explored the use of pulse oximetry to measure oxygen saturation levels of the dental pulp. Although the technique may not be ready for routine clinical use, it is a novel and promising study area.

### PHYSICAL CONDITION OF THE PATIENT

Although local observations are of extreme importance in the selection of cases for vital pulp therapy, the dentist must also consider the physical condition of the patient. In seriously ill children, extraction of the involved tooth after proper premedication with antibiotics, rather than pulp therapy, should be the treatment of choice. Children with conditions that render them susceptible to subacute bacterial endocarditis or those with nephritis, leukemia, solid tumors, idiopathic cyclic neutropenia, or any condition that causes cyclic or chronic depression of granulocyte and polymorphonuclear leukocyte counts, should not be subjected to the possibility of an acute infection resulting from failed pulp therapy.<sup>4</sup> Occasionally, pulp therapy for a tooth of a chronically ill child may be justified, but only after careful consideration is given to the prognosis of the child's general condition, the prognosis of the endodontic therapy, and the relative importance of retaining the involved tooth.

### Evaluation of Treatment Prognosis Before Pulp Therapy

The diagnostic process of selecting teeth that are good candidates for vital pulp therapy has at least two dimensions. First, the dentist must decide that the tooth has a



good chance of responding favorably to the pulp therapy procedure indicated. Second, the advisability of performing the pulp therapy and restoring the tooth must be weighed against extraction and space management. For example, nothing is gained by successful pulp therapy if the crown of the involved tooth is nonrestorable or the periodontal structures are irreversibly diseased. By the same rationale, a dentist is likely to invest more time and effort to save a pulpally involved second primary molar in a 4-year-old child with unerupted first permanent molars than to save a pulpally involved first primary molar in an 8-year-old child.

Other factors to consider include the following:

1. The level of patient and parent cooperation and motivation in receiving the treatment.
2. The level of patient and parent desire and motivation in maintaining oral health and hygiene.
3. The caries activity of the patient and the overall prognosis of oral rehabilitation.
4. The stage of dental development of the patient.
5. The degree of difficulty anticipated in adequate performance of the pulp therapy (instrumentation) in the particular case.
6. Space management issues resulting from previous extractions, preexisting malocclusion, ankylosis, congenitally missing teeth, and space loss caused by the extensive carious destruction of teeth and subsequent drifting.
7. Excessive extrusion of the pulpally involved tooth resulting from the absence of opposing teeth.

These examples, in any combination, illustrate the almost infinite number of treatment considerations that could be important in an individual patient with pulpal pathosis. Fortunately, a considerable shift in the management of caries-affected tooth structure has occurred that helps provide some clarification. The 2016 International Caries Consensus Collaboration clinical recommendations for carious tissue provides significant new insight supporting less invasive caries lesion management, delaying entry

to, and slowing down, the restorative cycle by preserving tooth tissue, and retaining teeth long term.<sup>5</sup> (Fig. 14.4).

## Vital Pulp Therapy Techniques

For many centuries, and probably since the beginning of time for humans, there has been a search for the best (safe and effective) methods of managing pulpal disease and traumatic pulpal exposure. These efforts have led to considerable controversy and debate as proponents of specific materials and methods attempt to justify their chosen techniques. Despite several impressive scientific advancements, these controversies remain unsettled in the 21st century. The identification of the best formulations of ingredients and techniques for producing predictable pulpal healing remains elusive. To complicate this issue further, the predominant belief is that pulp therapies appropriate for permanent teeth may not always be equally effective in treating similar conditions in primary teeth.

The prognosis after any type of pulp therapy usually improves in the absence of contamination by pathogenic microorganisms. Thus biocompatible neutralization of any existing pulpal contamination and prevention of future contamination (e.g., microleakage) are worthy goals in vital pulp therapy. If the treatment material in direct contact with the pulp also has some inherent quality that promotes, stimulates, or accelerates a true tissue-healing response, so much the better; however, vital pulp tissue can recover spontaneously from various insults in a favorable environment.

The techniques and procedures discussed in the following pages represent the standards as we perceive them at this writing. Some go back to the time when treatment decisions were made empirically. Their effectiveness has been proved over time, if not by science, and they represent the benchmarks against which newer techniques are compared. We look forward to having even more effective, biologically compatible, and scientifically sound methods in the future.

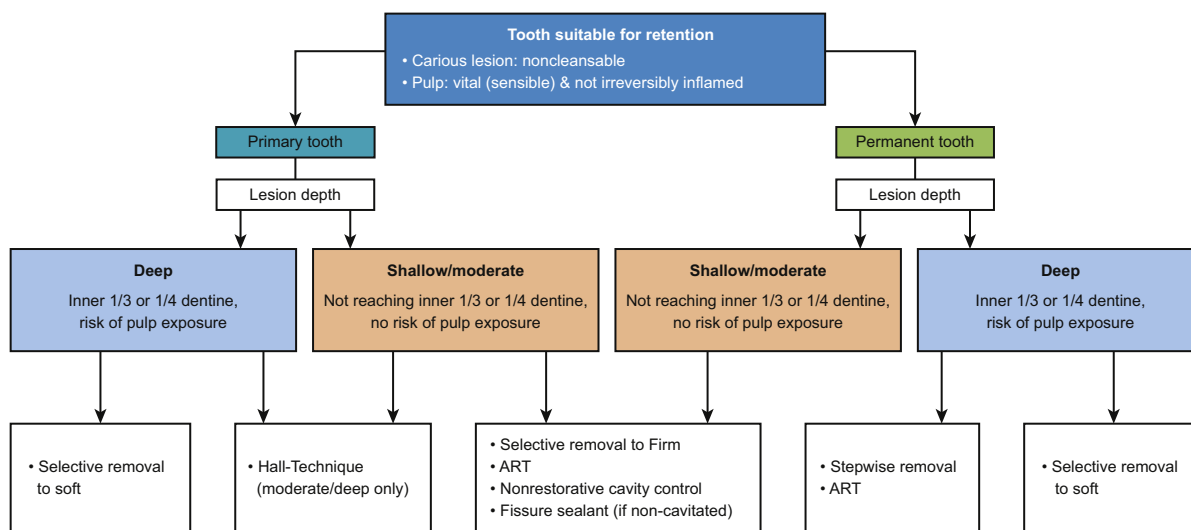


Fig. 14.4 Decision making for noncleansable caries lesions in retainable teeth with vital pulps. ART, Atraumatic restorative treatment. (Printed with permission from Schwendicke et al. 2016.)



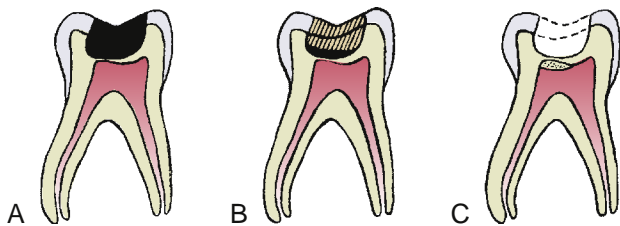
## Treatment of the Deep Caries Lesion

Children and young adults who have not received early and adequate dental care and optimal systemic fluoride and who lack adequate oral hygiene often develop deep caries lesions in the primary and permanent teeth. Many of the lesions appear radiographically to be dangerously close to the pulp or to actually involve the dental pulp. Based on clinical observations, approximately 75% of teeth with deep caries are found to have pulpal exposures; however, well over 90% of asymptomatic teeth with deep caries lesions can be successfully treated by indirect pulp therapy techniques without pulp exposure. This procedure is described herein.

If a carious exposure discovered during the initial caries excavation could be routinely treated with consistently good results, a major problem in dentistry would be solved. Unfortunately, the treatment of vital exposures, especially in primary teeth, has not been entirely successful. Therefore clinicians prefer to avoid pulp exposure during the removal of deep caries whenever possible.

### INDIRECT PULP TREATMENT (GROSS CARIES REMOVAL OR INDIRECT PULP THERAPY)

The procedure in which only the gross caries is removed from the lesion and the cavity is sealed for a time with a biocompatible material is referred to as indirect pulp treatment (Fig. 14.5).



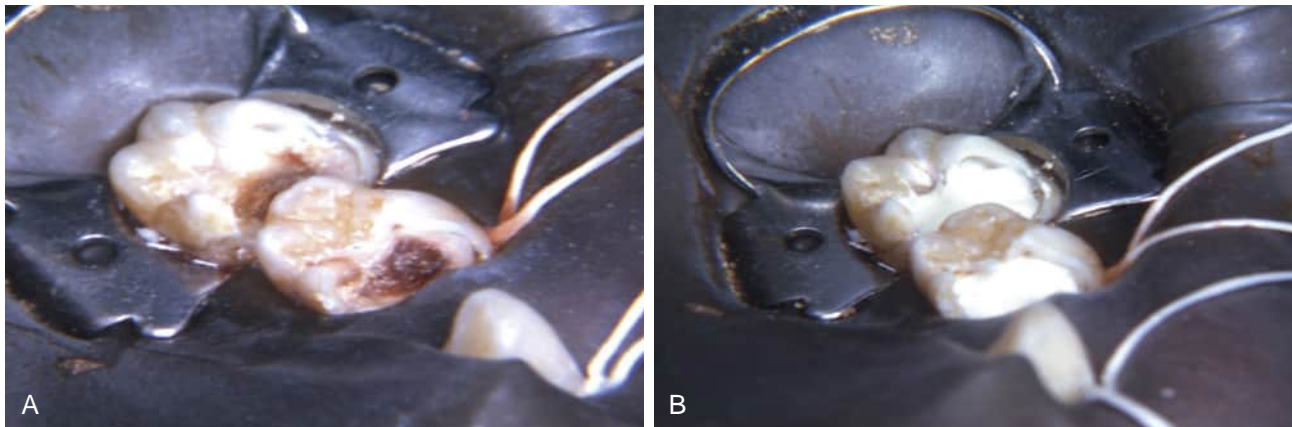
**Fig. 14.5** Indirect pulp therapy. (A) A primary or permanent tooth with deep caries. (B) The gross caries has been removed and the cavity sealed with durable biocompatible cement or restorative material. (C) After 6 to 8 weeks, the cavity is reopened and the remaining caries excavated. A sound dentin barrier protects the pulp, and the tooth is ready for final restoration. (Courtesy of Dr. Paul E. Starkey.)

Indirect pulp treatment is not a new procedure but has attracted renewed interest. Laboratory studies and favorable clinical evidence justify its routine use. Teeth having deep caries without any symptoms of painful irreversible pulpitis are candidates for this procedure.

The clinical procedure involves removing the gross caries but allowing sufficient caries to remain over the pulp horn to avoid exposure of the pulp. The walls of the cavity are extended to sound tooth structure because the presence of carious enamel and dentin at the margins of the cavity will prevent the establishment of an adequate seal (extremely important) during the period of repair. The remaining thin layer of caries at the base of the cavity is covered with a radiopaque biocompatible base material and sealed with a durable final restoration (Fig. 14.6). Although waiting 6 to 8 weeks for the placement of a final restoration has been suggested in the past (stepwise excavation), there is no conclusive evidence that this is necessary and in fact may decrease the success of the treatment in primary teeth.<sup>6</sup> Therefore it is common for clinicians to place a definitive final restoration that seals the tooth from microleakage.

If the decision is made to re-enter the tooth after 6 to 8 weeks, careful removal of the remaining carious material, now somewhat sclerotic, may reveal a sound base of dentin without pulp exposure. If a sound layer of dentin covers the pulp, the tooth is restored in the conventional manner (Fig. 14.7). Al-Zayer et al.<sup>7</sup> reported that the use of a base over the calcium hydroxide liner, in addition to a stainless-steel crown, dramatically increases the success rate. If a small pulp exposure is encountered, a different type of treatment must be used based on the clinical signs and symptoms and local conditions.

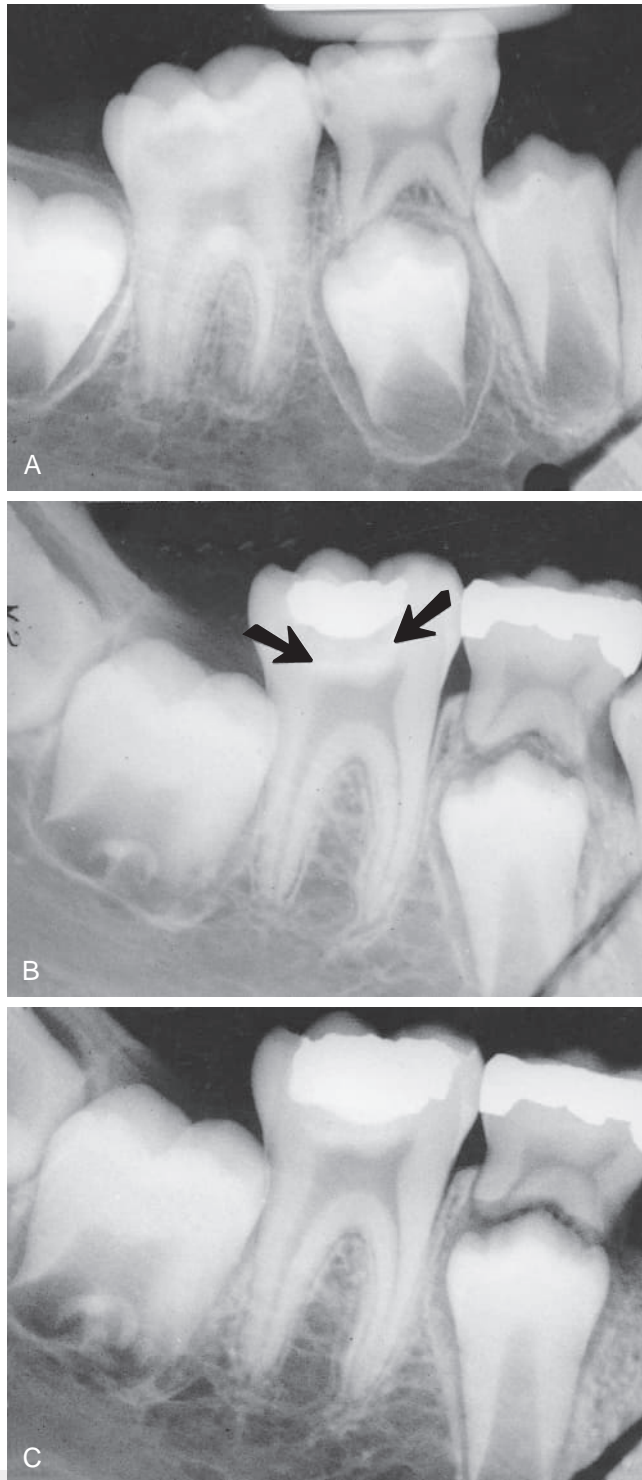
Nirschl and Avery<sup>8</sup> performed indirect pulp therapy on 38 carefully selected primary and young permanent teeth. Gross caries removal under rubber dam isolation was accomplished, calcium hydroxide was used in each tooth as a sedative base, and the teeth were restored with amalgam. Successful treatment occurred in 32 (94.1%) of the 34 teeth that were available for the 6-month evaluation procedure. In all cases of successful treatment, the base material and the residual carious dentin were observed to be dry on re-entry and clinical examination. Of the successfully treated teeth, only four had residual carious dentin



**Fig. 14.6** (A) First and second primary molars with deep caries removed with a small amount of soft carious dentin remains at the base of the lesion. The teeth were free of painful pulpitis. (B) Calcium hydroxide has been placed over the remaining caries and the teeth are ready for placement of an intermediate restorative base material if desired, followed by cementation of stainless-steel crowns.

that felt somewhat soft when probed with an explorer; in the remainder, the dentin felt hard.

Of particular importance in vital pulp therapy was a 2017 landmark systematic review and meta-analysis by



**Fig. 14.7** (A) Radiograph of the first permanent molar revealed a deep caries lesion. Gross caries was removed, and calcium hydroxide was placed over the remaining caries. The tooth was restored with amalgam and was not re-entered for complete caries removal for 3 months. (B) Sclerotic dentin can be seen beneath the remaining caries and the covering of calcium hydroxide (arrows). (C) The tooth was re-entered, and the remaining caries was removed. A sound dentin barrier was observed at the base of the cavity. A new amalgam restoration was placed after complete caries removal.

Coll et al.<sup>9</sup> regarding primary molar vital pulp therapy. Compared with direct pulp caps and pulpotomies (described in the next sections), indirect pulp therapy involves less tissue removal, does not expose or damage the pulp, represents a biologic approach to pulp therapy, and appears to be equally or more successful. Additionally, their review suggested that the choice of indirect pulp therapy liner or direct pulp capping agent does not influence the success of these two procedures.

## Vital Pulp Exposure

Although the routine practice of indirect pulp therapy in properly selected teeth will significantly reduce the number of direct pulp exposures encountered, all dentists who treat severe caries in children will be faced with treatment decisions related to the management of vital pulp exposures.

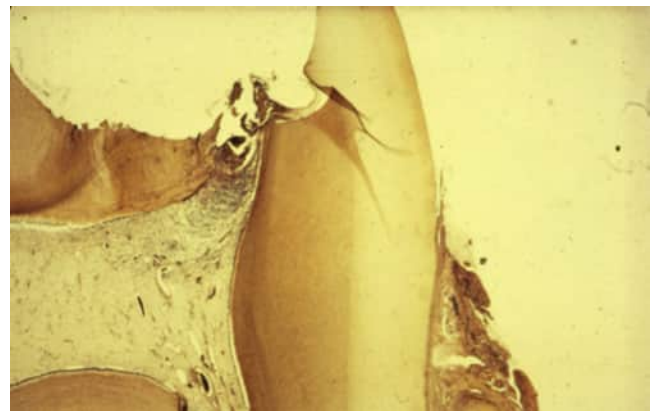The appropriate procedure should be selected only after a careful evaluation of the patient's symptoms, results of diagnostic tests, and conditions at the exposure site. The health of the exposed dental pulp is sometimes difficult to determine, especially in children, and there is often lack of conformity between clinical symptoms and histopathologic condition.

### SIZE OF THE EXPOSURE AND PULPAL HEMORRHAGE

The size of the exposure, appearance of the pulp, and amount of bleeding are valuable observations for diagnosing the condition of the primary pulp. Therefore the use of a rubber dam to isolate the tooth is extremely important; in addition, with the rubber dam, the area can be kept clean and the work can be done more efficiently.

The most favorable condition for vital pulp therapy is the small pinpoint exposure surrounded by sound dentin. However, a true carious exposure, even of pinpoint size, will be accompanied by inflammation of the pulp, the degree of which is usually directly related to the size of the exposure (Fig. 14.8).

A large exposure—the type that is encountered when a mass of leathery dentin is removed—is often associated with a watery exudate or pus at the exposure site. These



**Fig. 14.8** Pulp exposed by caries will show inflammation at the exposure site. Fragments of necrotic dentin will be introduced into the pulp during excavation of the caries.



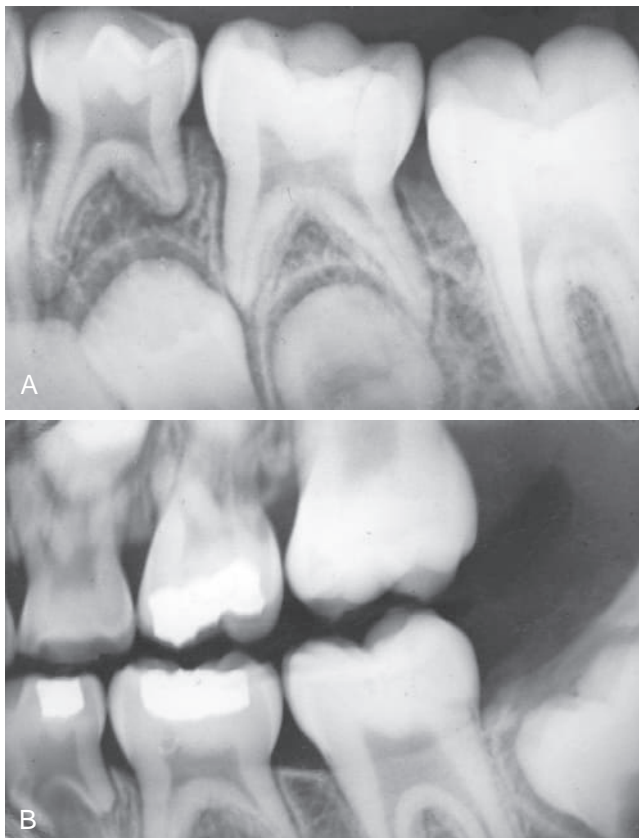
conditions are indicative of advanced pulp degeneration and often internal resorption in the pulp canal. Furthermore, excessive hemorrhage at the point of carious exposure or during pulp amputation is invariably associated with hyperemia and generalized inflammation of the pulp. When the latter is observed, endodontic therapy or extraction of the tooth is the treatment of choice.

## DIRECT PULP CAPPING

Pulp capping has been widely practiced for years and remains the favorite method of many dentists for treating vital pulp exposures. Although pulp capping has been condemned by some, others report that excellent results can be obtained if the teeth are carefully selected.

It is generally agreed that pulp capping procedures should be limited to small exposures produced accidentally by trauma or during cavity preparation or to true pinpoint carious exposures that are surrounded by sound dentin (Fig. 14.9). Pulp capping should be considered only for teeth in which there is an absence of pain, with the possible exception of discomfort caused by the intake of food. Moreover, there should be either no bleeding at the exposure site, as is often the case in a mechanical exposure, or bleeding in an amount that would be considered normal in the absence of a hyperemic or inflamed pulp.

All pulp treatment procedures should be performed with sterile instruments in clean conditions. Use of the rubber dam will help keep the pulp free of external contamination. All peripheral carious tissue should be excavated before excavation is



**Fig. 14.9** (A) Mesial pulp horn of the mandibular second primary molar accidentally exposed during cavity preparation was covered with calcium hydroxide. (B) Dental bridge across the mesial pulp horn is evidence of pulp healing.

begun on the portion of the carious dentin most likely to result in pulp exposure. Thus most of the bacterially infected tissue will have been removed before actual pulp exposure occurs. The work of Walshe,<sup>10</sup> which is described later in this chapter, supports the desirability of using a surgically clean technique to minimize bacterial contamination of the pulp tissue.

Calcium hydroxide has remained the standard material for pulp capping of normal vital pulp tissue as it can possibly stimulate the repair reaction. If the tooth is small (such as a first primary molar), hard-setting calcium hydroxide may also be used as the base for the restoration. Some studies have shown successful results with direct capping of exposed pulps with adhesive bonding agents, whereas others have reported pulpal inflammation and unacceptable results with this technique. In addition, the use of mineral trioxide aggregate (MTA) has shown promising results.<sup>11</sup> Coll et al.'s meta-analysis result at 24 months indicated that the use of direct pulp caps may be a viable option, and as stated above, their review suggests that the choice of indirect pulp liner or direct pulp capping agent does not influence the success.

## PULPOTOMY (Video 14.1)

**Video 14.1** Pulpotomy: technique for posterior primary tooth.

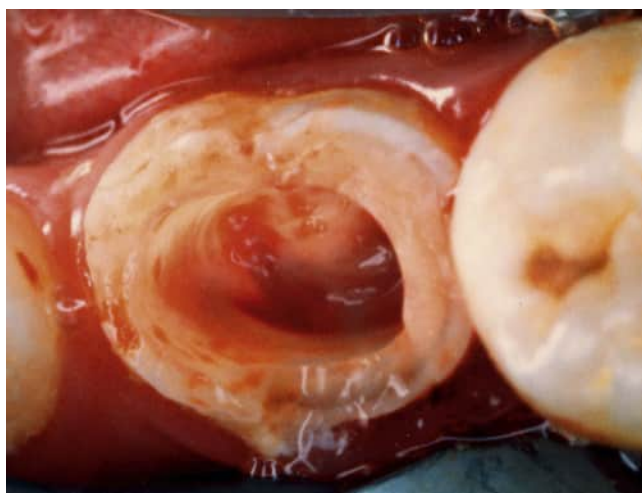
The removal of the coronal portion of the pulp is an accepted procedure for treating both primary and permanent teeth with carious pulp exposures. The justification for this procedure is that the coronal pulp tissue, which is adjacent to the carious exposure, usually contains microorganisms and shows evidence of inflammation and degenerative change. The abnormal tissue can be removed, and the healing can be allowed to take place at the entrance of the pulp canal in an area of essentially normal pulp. Even the pulpotomy procedure, however, is likely to result in a high percentage of failures unless the teeth are carefully selected.

In the pulpotomy procedure, the tooth should first be anesthetized and isolated with the rubber dam. A surgically clean technique should be used throughout the procedure. All remaining dental caries, as well as the overhanging enamel, should be removed to provide good access to the coronal pulp. Pain during caries removal and instrumentation may be an indication of faulty anesthetic technique. More often, however, it indicates pulpal hyperemia and inflammation, which makes the tooth a poor risk for vital pulpotomy. If the pulp at the exposure site bleeds excessively after complete removal of caries, the tooth is also a poor risk for vital pulpotomy (Video 14.2).

**Video 14.2** Hyperemic Pulp: primary tooth pulp chamber with evidence of hyperemia after removal of the coronal pulp.

The entire roof of the pulp chamber should be removed. No overhanging dentin from the roof of the pulp chamber or pulp horns should remain. No attempt is made to control the hemorrhage until the coronal pulp has been amputated. Funnel-shaped access to the entrance of the root canals should be created. A sharp discoid spoon excavator, large enough to extend across the entrance of the individual root canals, may be used to amputate the coronal pulp at its entrance into the canals. The pulp stumps should be excised cleanly, with no tissue tags extending across the floor of the pulp chamber. The pulp chamber should then be irrigated with a light flow of water from a water syringe, or if water line contamination is a concern, via syringe with





**Fig. 14.10** Cleanly excised pulp stumps with no tissue tags across the floor or along the walls of the chamber. The hemorrhage has been controlled. Notice also that the roof of the pulp chamber has been completely removed to provide total access to the pulp canals.

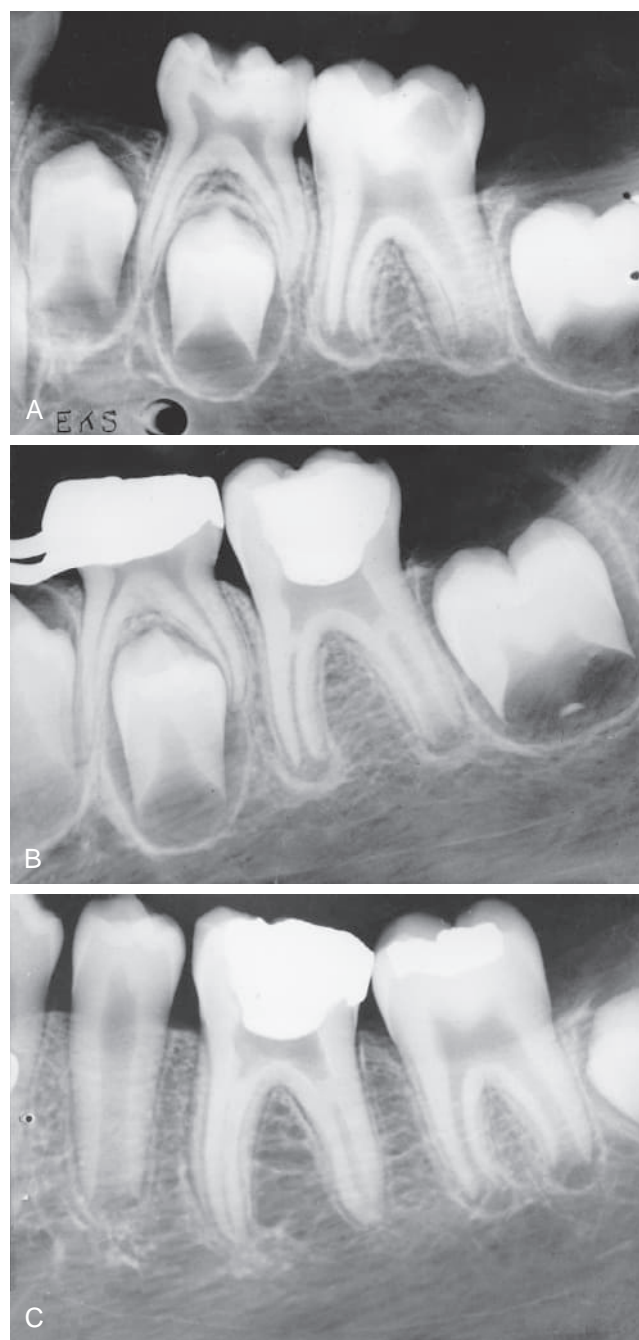
sterile water, and evacuated. Cotton pellets moistened with water should be placed in the pulp chamber and allowed to remain over the pulp stumps until a clot forms (Fig. 14.10).

Laboratory and clinical observations indicate that a different technique and capping material are necessary in the treatment of primary teeth than in the treatment of permanent teeth. As a result of these observations, two specific pulpotomy techniques have evolved and are in general use.

### Pulpotomy Technique for Permanent Teeth

The use of either calcium hydroxide or MTA can be recommended in the treatment of permanent teeth with carious pulp exposures when there is a pathologic change in the pulp at the exposure site.<sup>12</sup> This procedure is particularly indicated for permanent teeth with immature root development but with healthy pulp tissue in the root canals. It is also indicated for a permanent tooth with a pulp exposure resulting from a crown fracture when the trauma has also produced a root fracture of the same tooth. (For more information on apexification, apexogenesis, and regenerative endodontic procedures, see Chapter 28, Management of Trauma.) The procedure is completed during a single appointment. Only teeth that are free of symptoms of painful pulpitis are considered for treatment. The procedure involves the amputation of the coronal portion of the pulp as described, the control of hemorrhage, and the placement of the capping material over the pulp tissue remaining in the canals (Fig. 14.11). A protective layer of hard-setting cement is placed over the calcium hydroxide to provide an adequate seal. The tooth is subsequently prepared for full-coverage restoration. However, if the tissue in the pulp canals appears hyperemic after the amputation of the coronal tissue, a pulpotomy should no longer be considered. Endodontic treatment is indicated if the tooth is to be saved.

After 1 year, a tooth that has been treated successfully with a pulpotomy should have a normal periodontal ligament and lamina dura, radiographic evidence of a calcified bridge, and no radiographic evidence of internal resorption or pathologic resorption. The treatment of permanent teeth by the pulpotomy method has resulted in a higher rate of



**Fig. 14.11** (A) Pulp of the first permanent molar was exposed by caries. The tooth was considered a candidate for the calcium hydroxide pulpotomy technique. (B) Calcified bridge has formed over the vital pulp in the canals. (C) Continued root development and pulp recession are indicative of continuing pulp vitality. The crown should be supported with a full-coverage restoration.

success when the teeth are selected carefully based on existing knowledge of diagnostic techniques.

### Pulpotomy Technique for Primary Teeth

The same diagnostic criteria recommended for the selection of permanent teeth for the pulpotomy procedure should be used in the selection of primary teeth for this procedure. The treatment is also completed during a single appointment. A surgically clean technique should be used. The coronal portion of the pulp should be amputated as described

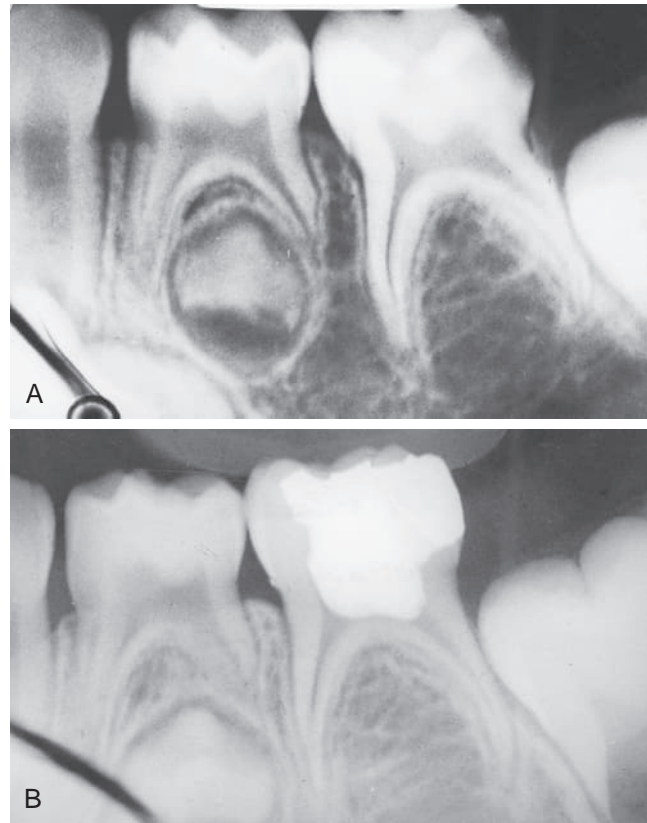
previously, the debris should be removed from the chamber, and the hemorrhage should be controlled. If there is evidence of hyperemia after the removal of the coronal pulp, which indicates that inflammation is present in the tissue beyond the coronal portion of the pulp, the technique should be abandoned in favor of pulpectomy or the removal of the tooth. If the hemorrhage is controlled readily and the pulp stumps appear normal, it may be assumed that the pulp tissue in the canals is normal, and it is possible to proceed with pulpotomy.

Although the formocresol pulpotomy technique has been recommended for many years as the principal method for treating primary teeth with carious exposures, a substantial shift away from use of this medicament has occurred because of concerns about its toxic effects. Many alternatives, including MTA, sodium hypochlorite, ferric sulfate, electrosurgery, and lasers, have been investigated to replace formocresol as the medicament of choice for pulpotomy. Yet, formocresol continues to be a very commonly used pulpotomy medicament.<sup>13</sup> Indeed, Milnes'<sup>14</sup> re-evaluation of earlier and more recent research about formaldehyde metabolism, pharmacokinetics, and carcinogenicity led him to suggest that there is an inconsequential risk associated with the use of formocresol in pediatric pulp therapy. The pulp chamber is dried with sterile cotton pellets. Next, a pellet of cotton moistened with a 1:5 concentration of Buckley's formocresol and blotted on sterile gauze to remove the excess is placed in contact with the pulp stumps and allowed to remain for 5 minutes. Because formocresol is caustic, care must be taken to avoid contact with the gingival tissues. The pellets are then removed, and the pulp chamber is dried with new pellets. A thick paste of hard-setting zinc oxide–eugenol is prepared and placed over the pulp stumps. The tooth is then restored with a stainless-steel crown (Fig. 14.12).

Although the recommendation is that the blotted cotton pellet moistened with a 1:5 concentration of formocresol be applied to the pulp stumps for 5 minutes, the 5-minute application time has been determined somewhat arbitrarily. Few data are available to verify the optimal application time, although García-Godoy et al.<sup>15</sup> have suggested that, based on their limited work with pulpotomies in dogs, a 1-minute application time may be adequate and perhaps superior to the recommended 5 minutes.

Buckley's original formula for formocresol calls for equal parts of formaldehyde and cresol (Sultan Chemists, Inc., Englewood, New Jersey, United States). The 1:5 concentration of this formula is prepared by first thoroughly mixing three parts of glycerin with one part of distilled water, and then adding four parts of this diluent to one part of Buckley's formocresol, followed again by thorough mixing.

Despite the continuing common use of formocresol, other materials and techniques have been studied and are used regularly in practice. An excellent prospective randomized clinical trial was conducted by Fernandez et al.<sup>16</sup> comparing the use of formocresol, MTA, sodium hypochlorite, and ferric sulfate. Each group began with 25 treated teeth, and at the end of 24 months of follow-up, of the teeth available for study, no statistically significant difference was found among the four groups. However, a randomized clinical trial by Juneja and Kulkarni<sup>17</sup> showed a more favorable result with both MTA and biodentine when compared with formocresol in an 18-month comparison.



**Fig. 14.12** (A) Pretreatment radiograph. (B) Posttreatment formocresol pulpotomy with normal appearance of the supporting tissues is indicative of success; tooth now ready for stainless-steel crown. (Note the apparently congenitally missing tooth #20.)

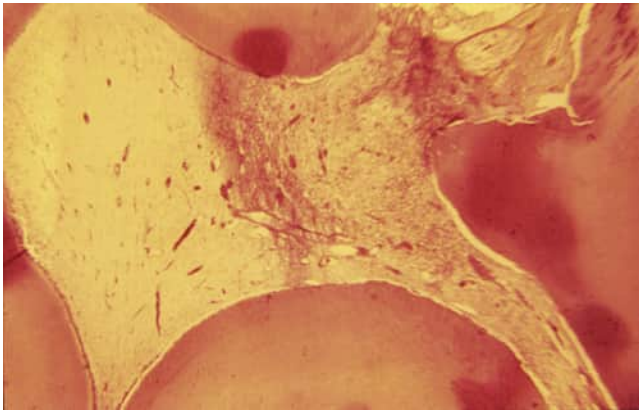
Despite these results, the systematic review by Coll et al. showed that while pulpotomies continue to be successful, MTA and formocresol are the two agents most successful over time with the highest level of evidence. In addition, they suggested that some materials be removed from the choices (calcium hydroxide) or be given reduced recommendations (sodium hypochlorite, laser, and ferric sulfate) based on the evidence in their meta-analysis.

## Nonvital Pulp Treatment With Irreversible Pulpitis or Necrotic Pulp

### PULPECTOMY

A pulpectomy may be performed on primary teeth when the coronal pulp tissue and the tissue entering the pulp canals are vital but show clinical evidence of hyperemia (Fig. 14.13) or if the root canals show evidence of necrosis (suppuration). It is unwise to maintain untreated infected primary teeth in the mouth. They may be opened for drainage and often remain asymptomatic for an indefinite period. However, they are a source of infection and should be treated or removed. The morphology of the root canals in primary teeth makes endodontic treatment difficult and often impractical. Mature first primary molar canals are often so small that they are inaccessible even to the smallest barbed



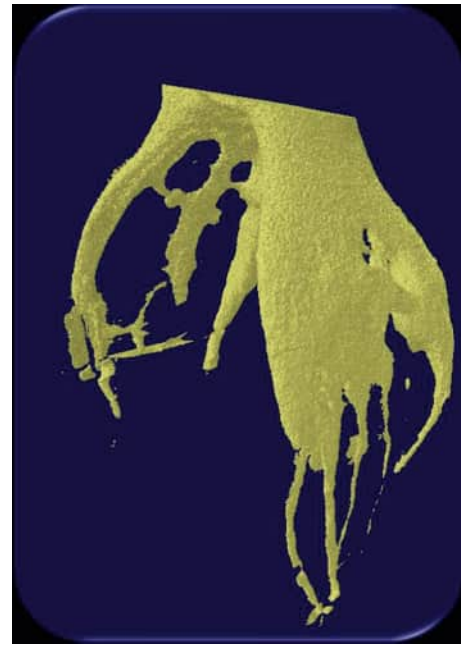


**Fig. 14.13** Histologic section of a second primary molar with a carious pulp exposure. There was clinical evidence of hyperemia and inflammation of the pulp. Inflammation is evident in half the coronal pulp and in the pulp canal. This condition should be treated by the pulpectomy technique.

broach. If the canal cannot be properly cleansed of necrotic material, sterilized, and adequately filled, endodontic therapy is more likely to fail. Indeed, for many years performing pulpectomies on first primary molars has been discouraged. In a large (1149 procedures in 830 children) retrospective study comparing the success of pulpectomies versus pulpoto- mies, the authors found that while second primary molar pulpectomies had better survival than first primary molars, the difference was not significantly different.<sup>18</sup>

Hibbard and Ireland<sup>19</sup> studied the primary root canal morphology by removing the pulp from extracted teeth, forcing acrylic resin into the pulp canals, and dissolving the covering of tooth structure in 10% nitric acid. Apparently only one root canal was initially present in each of the mandibular and maxillary molar roots. The subsequent deposition of secondary dentin throughout the life of the teeth caused a change in the morphologic pattern of the root canal, producing variations and eventual alterations in the numbers and sizes of the canals. The variations included lateral branching, connecting fibrils, apical ramifications, and partial fusion of the canals. The use of micro-computed tomography has produced some exquisite views of the anatomy of primary molars (Figs. 14.14 and 14.15). These findings explain the complications often encountered in root canal therapy.

Endodontic procedures for the treatment of primary teeth are indicated if the canals are accessible and if there is evidence of essentially normal supporting bone. Aminabadi et al.<sup>20</sup> have demonstrated that while primary second molars are more accessible than first molars, all of them are negotiable. Furthermore, other studies have investigated ultrasonic instrumentation<sup>21</sup> and root apex locators<sup>22</sup> in the root canal treatment of primary teeth. If the supporting bone is also compromised, the likelihood of successful endodontic therapy is lower. If the second primary molar is lost before the eruption of the first permanent molar, the dentist is confronted with the difficult problem of preventing the first permanent molar from drifting mesially during its eruption. Special effort should be made to treat and retain the second primary molar even if it has a necrotic pulp. Similarly, longer-than-normal retention of a second primary molar may be desired when the succedaneous second premolar is congenitally missing (Fig. 14.16).



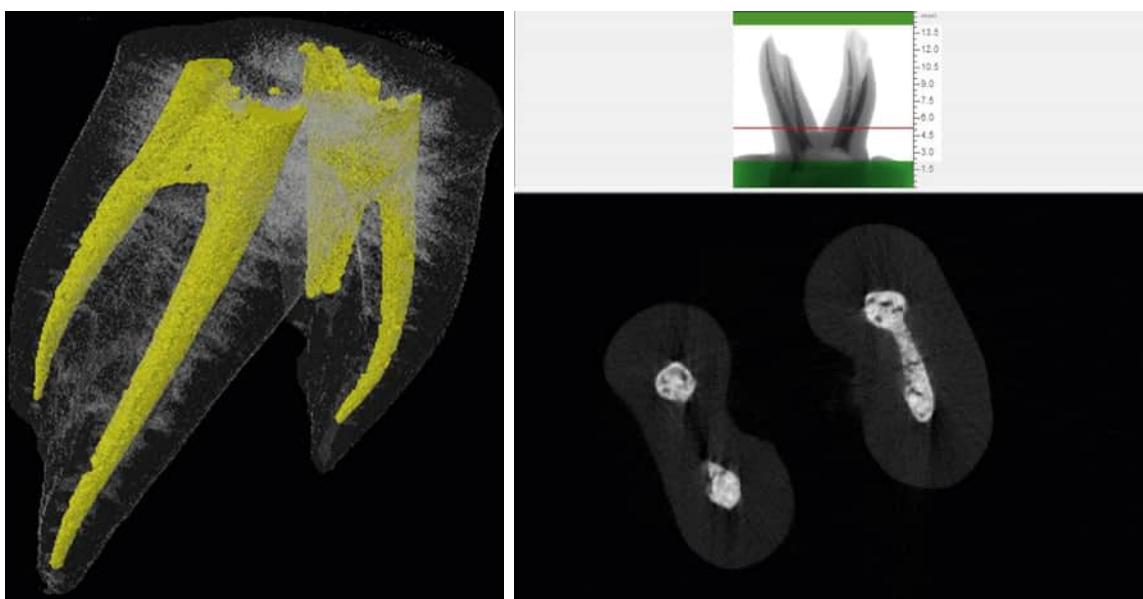
**Fig. 14.14** Micro-computed tomography of a mandibular second primary molar root canal system. (Courtesy of Dr. Ashraf Al-Hosainy, Mansoura University School of Dentistry, Egypt.)

Many dentists prefer to use root canal instruments placed in a special rotary handpiece and nickel titanium files for root canal debridement. Root canal instrumentation may be facilitated with the judicious use of this mechanical technique, especially in canals that are difficult to negotiate with hand instruments. Cautious manipulation is important, however, to prevent breaking the file or overinstrumenting the canal and apical tissues.

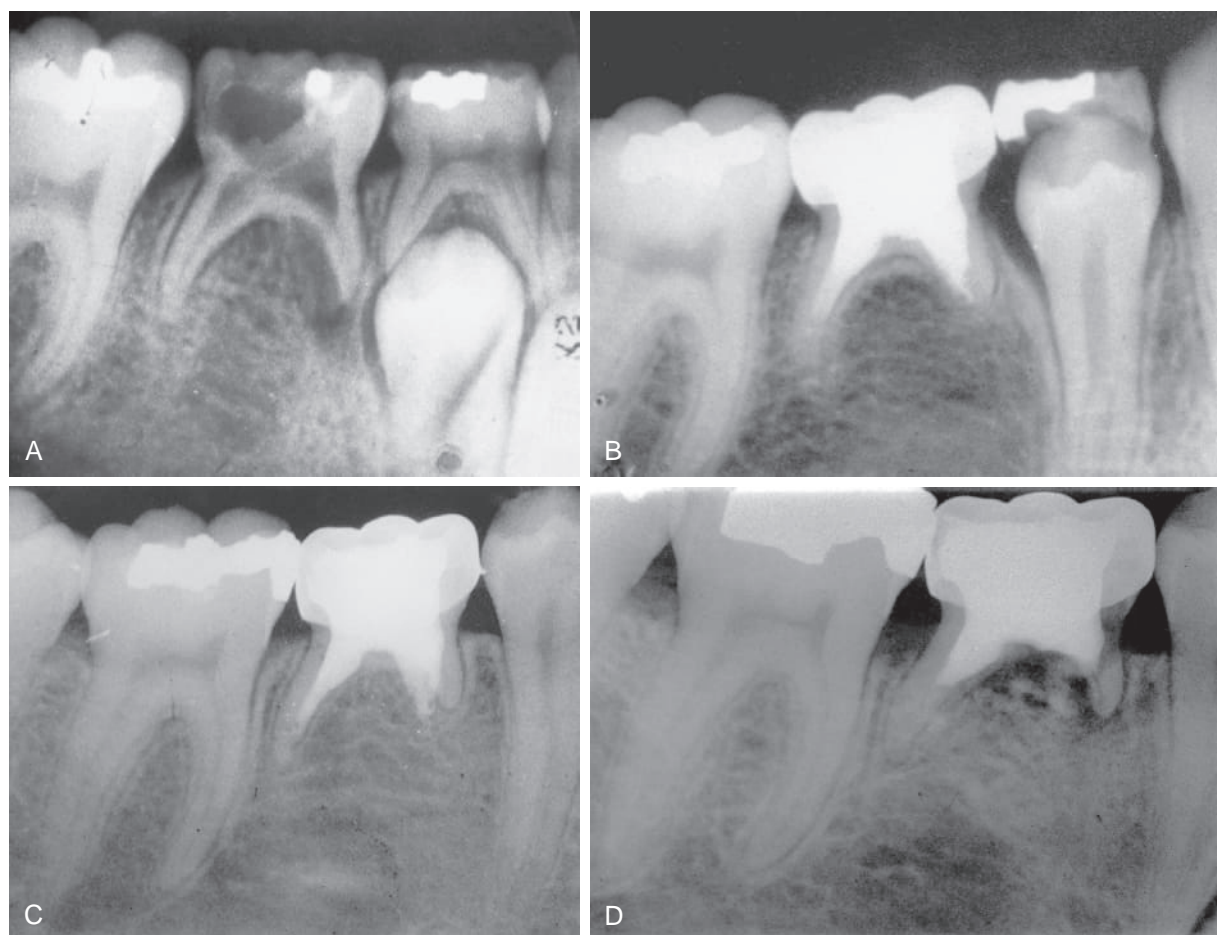
After the pulp tissue has been removed from the canals, a syringe is used to irrigate them with 3% hydrogen peroxide followed by sodium hypochlorite. Clinicians are especially cautioned in the gentle and judicious use of sodium hypochlorite in irrigating the canals as significant morbidity has been reported when this irrigant is expressed past the apices of primary teeth. The canals should then be dried with sterile paperpoints. When hemorrhage is controlled and the canals remain dry, a thin mix of filling paste may be prepared. Small Kerr files may be used to apply the paste to the walls. The excess thin paste may be removed with paperpoints and Hedström files. A thick mix of the treatment paste should then be prepared, rolled into a point, and carried into the canal. Root canal pluggers may be used to condense the filling material into the canals. Alternatively, a Lentulo spiral file can be placed on an endodontic handpiece to spiral the filling material into the canals. An x-ray film may be necessary to allow the success in filling the canals to be evaluated (Fig. 14.17). Further condensation may be performed if required. The tooth should be restored with full coverage.

Although zinc oxide–eugenol paste has been viewed as the traditional root canal filling material for primary teeth, results from multiple studies<sup>23–28</sup> suggest that KRI paste (Pharmachemie AG, Zürich, Switzerland) may be preferable. Excellent results have been observed in many cases. The primary components of KRI paste are zinc oxide and iodoform. The main advantages of KRI paste over zinc





**Fig. 14.15** Three views of micro-computed tomographs of a mandibular second primary molar root canal system obturated with Vitapex. (Courtesy of Dr. Ashraf Al-Hosainy, Mansoura University School of Dentistry, Egypt.)



**Fig. 14.16** (A) Necrotic tooth resulting from a carious exposure of the pulp of the second primary molar. Because the succedaneous second premolar was congenitally missing, a decision was made to attempt to save the tooth as a functional space maintainer through the growing years, if possible. Note the evidence of internal resorption at the floor of the pulp chamber. (B) Radiograph made 1 year and 7 months after the pulp canals were treated and filled. The mesial canal was treated with complete pulpectomy; the distal canal was treated with partial pulpectomy. (C) Six years and seven months after treatment, the tooth is asymptomatic; the supporting tissues appear normal, but some root resorption has occurred. (D) Fourteen years and six months postoperatively, the tooth was extracted because of the development of symptoms and loss of bone support. At this time, the patient was a young adult, and a fixed bridge was made.

oxide–eugenol paste are that KRI paste resorbs in synchrony with primary roots and is less irritating to surrounding tissues if a root is inadvertently overfilled.

Another popular root canal filling material for primary teeth is Vitapex (Dia Dent Group International, Inc., Vancouver, British Columbia, Canada), a product that has received many favorable reports about its successful use in infected primary teeth. The primary components of Vitapex are calcium hydroxide and iodoform. Vitapex may be at least as effective as KRI paste, and Nurko and García-Godoy<sup>27</sup> have published some reports of studies in humans.

Currently, pulpectomies in primary teeth are commonly completed in a single appointment. If the tooth has painful

necrosis with purulence in the canals, however, completing the pulpectomy procedure over two or three visits should improve the likelihood of success.

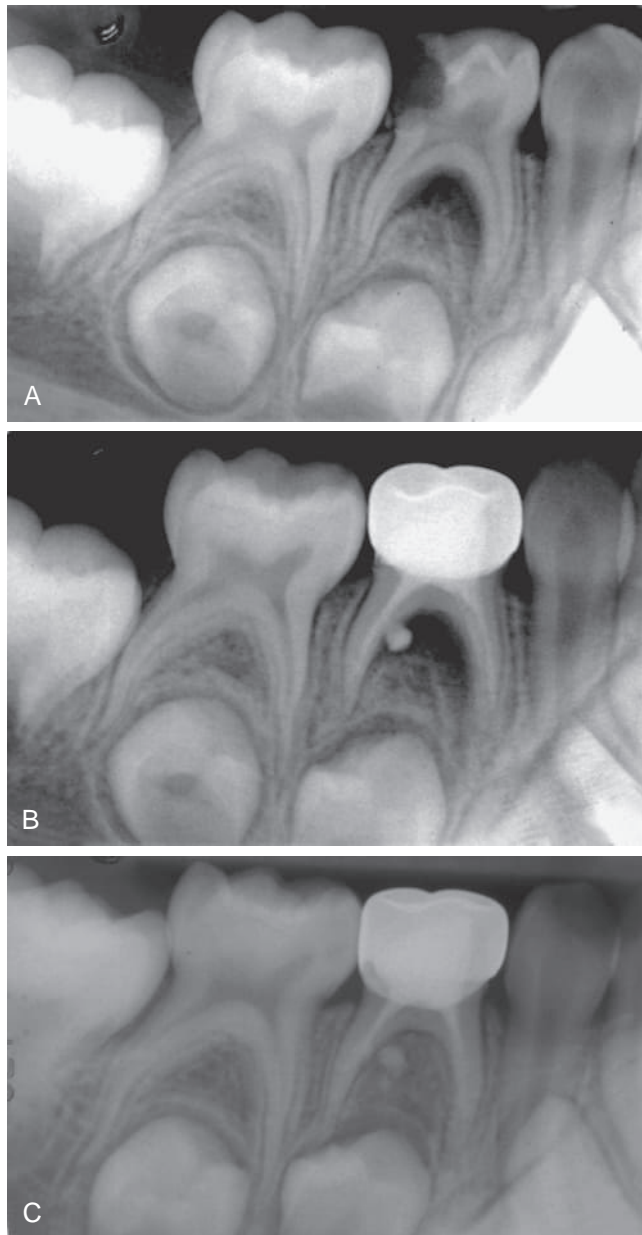
## Summary of Pulp Therapy

The preceding discussion of various pulp therapies conforms, in principle, to the Guidelines for Pulp Therapy for Primary and Young Permanent Teeth as published by the American Academy of Pediatric Dentistry.<sup>28</sup>

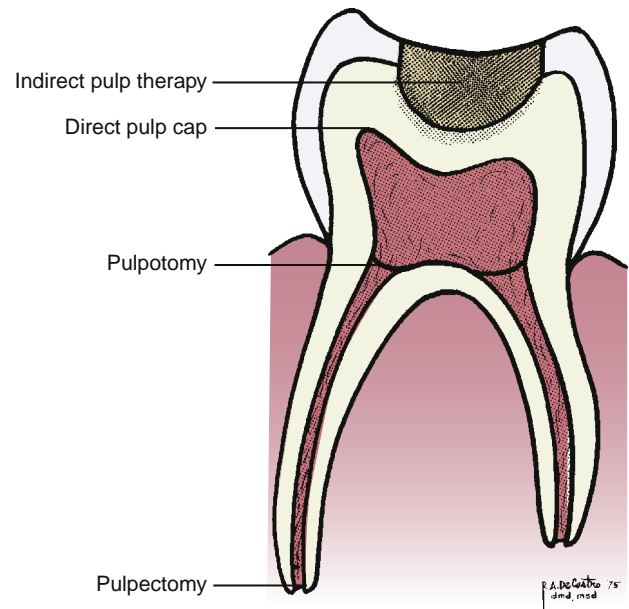
In cases of clinical problems that will likely require pulp therapy to return the patient to satisfactory oral health, treatment decisions are not always clear-cut. Proper diagnosis of the pulpal problem is important to allow the dentist to select the most conservative treatment procedure that offers the best chance of long-term success with the least chance of subsequent complications. The dentist should think of the possible treatment options in a progressive manner that takes into account both treatment conservatism (e.g., a pulpotomy is more conservative than a pulpectomy) and posttreatment problems (Fig. 14.18). The most conservative treatment possible may not always be the indicated procedure after the dentist also weighs the risks of posttreatment failure in a particular case.

## Restoration of the Pulpally Involved Tooth

It has been a common practice for some dentists to delay for weeks or months the permanent restoration of a tooth that has undergone vital pulp therapy in order to allow time to determine whether the treatment procedure will be successful. However, failures in pulp therapy are usually not evident for many months. Rarely does a failure in pulp therapy or an endodontic procedure on a primary tooth cause the child to experience acute symptoms. Failures are



**Fig. 14.17** Successful single-appointment pulpectomy. Note extrusion of zinc oxide–eugenol into furcal area from distal root accessory canal, but adequate subsequent healing. (A) Pretreatment. (B) Immediately after treatment. (C) Ten months after treatment.



**Fig. 14.18** Pulp therapy progression.

usually evidenced by pathologic root resorption or rarefied areas in the bone and are discovered during regular recall appointments.

Primary and permanent molars that have been treated by the pulpotomy or pulpectomy technique have a weak, unsupported crown that is liable to fracture. Failure of the buccal or lingual plate often occurs below the gingival attachment or even below the crest of the alveolar bone. This type of fracture makes subsequent restoration of the tooth impractical. Also, a delay in restoring the tooth with a material that will adequately seal the tooth and prevent the ingress of oral fluids is one cause for failure of pulp therapy. Application of a layer of hard-setting cement over the capping material, followed by a substantial restoration, will adequately protect the pulp against contaminating oral fluids during the healing process.

An amalgam, composite resin, or glass-ionomer restoration may serve as the immediate and often the final restoration for teeth with pulp caps and well-supported crowns. As soon as it is practical, however, other pulpally treated posterior teeth should be prepared for stainless-steel crowns. Pulp treatment of a primary molar is typically followed by placement of a stainless-steel crown restoration during the same appointment.

## Reaction of the Pulp to Various Capping Materials and Use of Dental Stem Cells

So many different materials have been proposed that a brief review of several popular agents is valuable for an understanding of the various reactions of the pulp. In addition to this section, Chen and Jordan<sup>29</sup> present a well-written article on the present and future of materials for primary tooth pulp treatment.

### ZINC OXIDE–EUGENOL

Before calcium hydroxide came into common use, zinc oxide–eugenol was used more often than any other pulp capping material. Although dentists have apparently had good clinical results with the use of zinc oxide–eugenol, it is generally not recommended as a direct pulp capping material.

### CALCIUM HYDROXIDE

Because of its high alkalinity (pH 12), it is so caustic that when it is placed in contact with the vital pulp tissue, the reaction produces a superficial necrosis of the pulp. The irritant qualities seem to be related to its ability to stimulate development of a calcified barrier. The superficial necrotic area in the pulp that develops beneath the calcium hydroxide is demarcated from the healthy pulp tissue below by a new, deeply staining zone composed of basophilic elements of the calcium hydroxide dressing. The original proteinate zone is still present. However, against this zone is a new area of coarse fibrous tissue likened to a primitive type of bone. On the periphery of the new fibrous tissue, cells resembling odontoblasts appear to line up. A month after

the capping procedure, a calcified bridge is evident radiographically. This bridge continues to increase in thickness during the next 12 months (Fig. 14.19). The pulp tissue beneath the calcified bridge remains vital and is essentially free of inflammatory cells. Many studies have reported on the use of calcium hydroxide as a pulp capping material; a few are included in the references for this chapter.

### PREPARATIONS CONTAINING FORMALIN

The belief that exposing the pulp to formocresol or capping it with materials that contain formocresol will promote pulp healing or even maintain the pulp in a healthy state has not been substantiated. Some studies have indicated that the formocresol pulpotomy technique may be applied to permanent teeth, but its use in permanent teeth remains an interim procedure, to be followed by conventional endodontic therapy. The clinical success experienced in the treatment of primary pulps with these materials is possibly related more to the drug's bactericidal action and fixation qualities than to its ability to promote healing.

Doyle<sup>30</sup> compared the success of the full-strength formocresol pulpotomy technique with the success of the calcium hydroxide pulpotomy technique. Experimental pulpotomies were performed on 65 normal human primary teeth, many of which could later be extracted for histologic examination. The formocresol technique was used on 33 teeth, and the calcium hydroxide technique was used in the treatment of the other 32 teeth. Under the conditions of this study, the

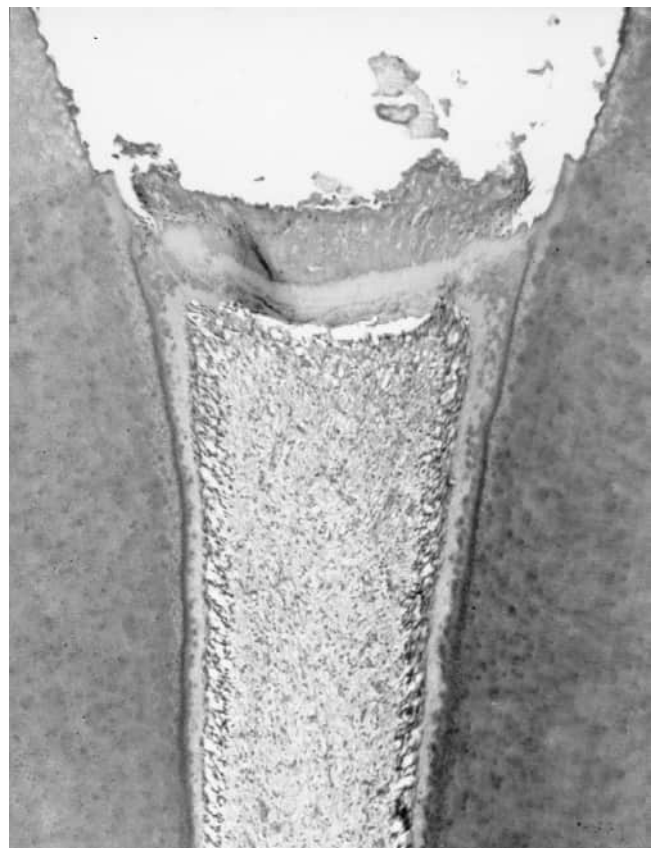


Fig. 14.19 Calcified bridge covering an amputated pulp that was capped with calcium hydroxide.



formocresol pulpotomy technique yielded outcomes superior to those of the calcium hydroxide technique for at least the first 18 months after treatment. Formocresol did not stimulate the healing response of the remaining pulp tissue but rather tended to fix essentially all the remaining tissue (Figs. 14.20 and 14.21). The use of calcium hydroxide was associated with the formation of a dentin bridge and the complete healing of the amputated primary pulp in 50% of the cases that were available for histologic study.

### FERRIC SULFATE

Considerable interest and research has been devoted to investigating the effectiveness of ferric sulfate to treat the surface of the remaining pulp tissue after pulpotomy of primary teeth. Ferric sulfate agglutinates blood proteins and controls hemorrhage in the process without clot formation.

Ferric sulfate is available in a 15.5% solution under the trade name of Astringent (Ultradent Products, Inc., South Jordan, Utah, United States).

A study by Casas et al.<sup>31</sup> compared the outcome of ferric sulfate pulpotomy with a pulpectomy on cariously exposed vital pulps of primary molars. Although their study showed that a pulpectomy had produced more acceptable treatment outcomes than ferric sulfate pulpotomy in vital pulp treatment of primary molars at a 2-year follow-up visit, the survival rates for the two techniques were not statistically

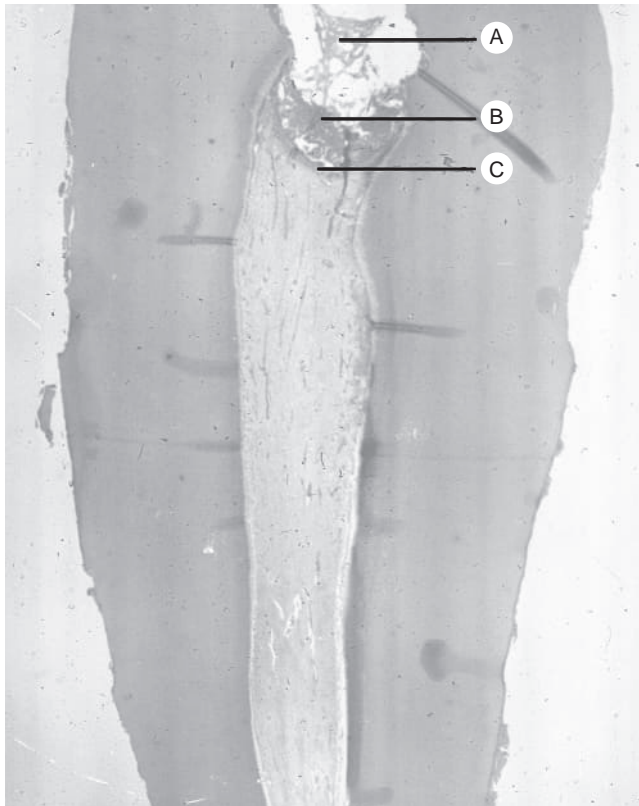
different. There was no clinical evidence of pathosis in 96% of the ferric sulfate pulpotomies and 98% of the pulpectomies. They suggest that, for clinicians who wish to avoid aldehydes in vital molar pulp therapy for children, either of these two alternatives is feasible. The main advantage of the ferric sulfate pulpotomy over a pulpectomy for dentists working with children is the considerably faster speed with which a pulpotomy can be performed.

### MINERAL TRIOXIDE AGGREGATE

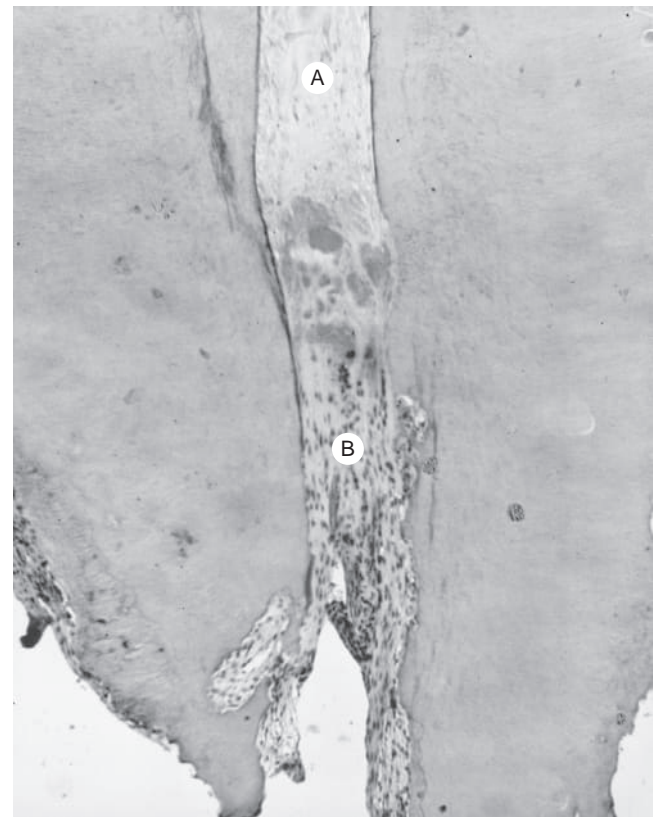
MTA is a popular product for pulpotomies secondary to a variety of factors. Originally developed as a root-end filling material, its main components are tricalcium silicate, tricalcium aluminate, tricalcium oxide, and silicate oxide. The positive properties of MTA are biocompatibility, good sealing properties, antimicrobial activity, and the ability to set in the presence of moisture and blood. The negative attributes include difficulty in handling and the cost. Moreover, along with formocresol and ferric sulfate, MTA can cause pulp canal obliteration. Despite this, it seems to come closest to our goal of formation of a natural dentinal bridge across the exposed pulpal tissue.

### OTHER CAPPING MATERIALS AND METHODS

Pulp capping experiments in animals have assessed a variety of antibiotics and corticosteroids, alone or in combination with calcium hydroxide.



**Fig. 14.20** Histologic section of a primary pulp exposed to formocresol for 4 days. The medicament came into contact with the pulp at (A), the debris and blood clot are evident at (B), and a noticeably eosinophilic, compressed line is evident at (C). The underlying pulp was a pale, homogeneously stained tissue with a loss of basophilic nuclei. (Courtesy of Dr. Walter A. Doyle.)



**Fig. 14.21** Histologic section of a primary pulp exposed to formocresol for 41 days. (A) The pulp appeared pale and pink, and there was a loss of cellular definition. (B) Vital tissue can be seen in the apical portion. (Courtesy of Dr. Walter A. Doyle.)

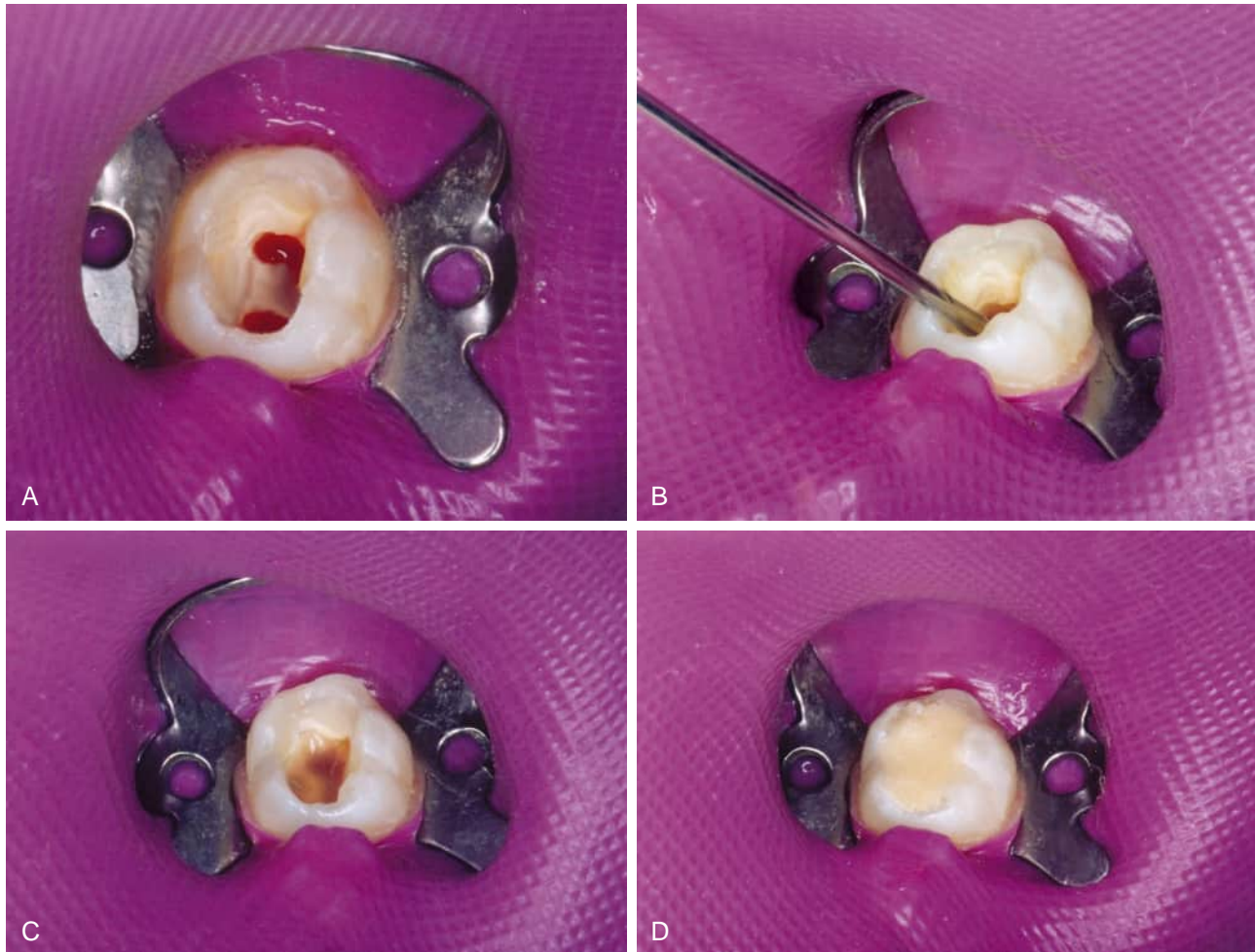
Investigations in search of improved pulp capping materials, agents that showed at least promising preliminary results have included freeze-dried bone, chlorhexidine, feracrylum, calcium phosphate ceramics, tetracalcium phosphate cement, dentin-bonding agents in combination with bonded resin or glass-ionomer materials, and bone morphogenetic proteins.<sup>32-38</sup>

In an excellent review on pulpotomies in primary teeth, Ranly<sup>37</sup> suggested that pulpotomy modalities can be classified by treatment objective into three categories: devitalization, preservation, and regeneration. He noted that the treatment objective of an ideal pulpotomy agent is to leave the radicular pulp vital, healthy and completely enclosed within an odontoblast-lined dentin chamber. The regeneration modality most closely resembles this ideal. Using a family of bone morphogenetic proteins, it may be possible to induce reparative dentin formation with recombinant dentinogenic proteins similar to the native proteins of the body. Fuks<sup>39</sup> suggests that because the specificity of growth factors such as transforming growth factor  $\beta$  and bone morphogenetic protein in inducing reparative processes is not clear, further studies are required to further elucidate the kinetics of growth factor release and the sequence of growth factor-induced reparative dentinogenesis. Commercially available

recombinant human bone morphogenetic proteins for pulp therapy are now available for experimentation and clinical trials. Sabbarini et al.<sup>40</sup> have demonstrated the effective use, both histologically and clinically, of an enamel matrix derivative as a pulpotomy agent in primary teeth (Fig. 14.22). Interesting progress is being made in the use of stem cells to stimulate regeneration of dentin-pulp, whole tooth, bioroot, and periodontal tissue (Fig. 14.23).<sup>41,42</sup> While not practical as of yet for daily clinical practice, research in this area appears promising.

Mack and Dean<sup>43</sup> reported the results of a retrospective human study of electrosurgical pulpotomies performed on primary molars. The mean postoperative observation time for the 164 teeth studied was 2 years and 3 months. They reported a 99.4% success rate (one failure) for this pulpotomy technique. In addition, Dean et al.<sup>44</sup> demonstrated no statistically significant difference between the electrosurgical and formocresol pulpotomy techniques in a prospective clinical study involving 50 children requiring at least one pulpotomy. Rivera et al.<sup>45</sup> obtained results similar to those of Dean et al.<sup>44</sup> However, Fishman et al.<sup>46</sup> found considerably lower success rates with the use of electrosurgical pulpotomy.

Moritz et al.<sup>47</sup> applied 200 direct pulp caps in adult patients after mechanical pulp exposures. Half of the teeth

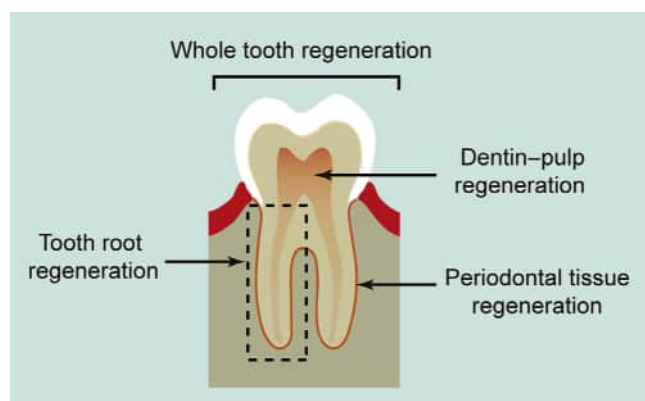


**Fig. 14.22** (A) Access opening and hemostasis for primary molar pulpotomy. (B) Enamel matrix derivative (Emdogain, Straumann, Basel, Switzerland) is injected over the exposed pulp stumps. (C) View of enamel matrix derivative in place. (D) Tooth restored with light-cured glass ionomer followed by placement of a stainless-steel crown. (Courtesy of Dr. Jumana Sabbarini, Jordan Ministry of Health.)

(control group) received a conventional calcium hydroxide pulp cap. The other half (experimental group) received a calcium hydroxide cap after first undergoing CO<sub>2</sub> laser radiation until the “exposed pulps were completely sealed.” The teeth were monitored monthly. One year after the treatment, the success rate for teeth in the experimental group was 89%, whereas that in the control group was 68%. While both the electrosurgical and the laser techniques seem to be favorable areas for further research in pulp therapy, a systematic review by De Coster et al.<sup>48</sup> states that, given the paucity and heterogeneity of high-quality articles, general recommendations for the clinical use of the laser in pulpotomies for primary teeth cannot yet be made.

## SUMMARY OF PULP CAPPING MATERIALS

Clarity does seem to be developing regarding some research results that should allow for the use of successful alternatives to formocresol. In fact the network meta-analyses by

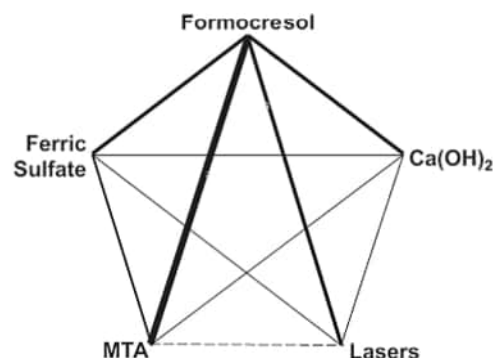


**Fig. 14.23** Investigations into stem cell-based tooth and periodontal regeneration, including dentin-pulp, tooth root, whole tooth, and periodontal tissue regeneration. (From L Hu, Y Liu, S Wang, Stem cell-based tooth and periodontal regeneration, *Oral Diseases*, 2018;24:696–705, 10.1111/odi.12703)

Lin et al.<sup>49</sup> led them to suggest that MTA is the first choice for primary molar pulpotomies, unless cost is an issue; in that case, they suggest that ferric sulfate may be the choice (Table 14.1; Fig. 14.24).

## Failures After Vital Pulp Therapy

Failure in the formation of a calcified bridge across the vital pulp has often been related to the age of the patient, degree of surgical trauma, sealing pressure, improper choice of capping material, low threshold of host resistance, and presence of microorganisms with subsequent infection. Kakehashi, Stanley and Fitzgerald<sup>50</sup> studied the effects of surgical exposures of dental pulps in germ-free and conventional laboratory rats. The injured pulpal tissue contaminated with microorganisms failed to show evidence of repair; especially lacking were matrix formation and attempted dentinal bridging. In the germ-free



**Fig. 14.24** Network for the comparisons among different medications for primary molar pulpotomy. Dotted lines refer to those comparisons that have not been tested directly in clinical trials. The width of the solid lines is in proportion to the amount of evidence available in the literature. Ca(OH)<sub>2</sub>, Calcium hydroxide; MTA, mineral trioxide aggregate. (Reprinted with permission from Lin PY, Chen HS, Wang YH, et al. Primary molar pulpotomy: a systematic review and network meta-analysis, *J Dent*. 2014;42(9):1060–1077.)

**TABLE 14.1** Failure Odds Ratio of Network and Standard Meta-Analysis for Clinical and Radiographic Outcome for Primary Molar Pulpotomy after 18–24-Month Follow-Up

	CLINICAL OUTCOME				RADIOGRAPHIC OUTCOME			
	Network Meta-Analysis		Standard Pair-Wise Meta-Analysis		Network Meta-Analysis		Standard Pair-Wise Meta-Analysis	
	Estimates	95% CI	Estimates	95% CI	Estimates	95% CI	Estimates	95% CI
FS vs FC	0.90	(0.48, 1.65)	1.00	(0.88, 1.12)	1.02	(0.60, 1.78)	1.0	(0.91, 1.11)
Ca(OH) <sub>2</sub> vs FC	1.94	(1.11, 3.25)*	1.20	(1.05, 1.37)*	2.97	(1.78, 4.99)*	1.40	(1.19, 1.65)*
MTA vs FC	0.90	(0.61, 1.32)	0.91	(0.79, 1.05)	0.66	(0.45, 0.98)*	0.83	(0.73, 0.96)*
Lasers vs FC	3.38	(1.37, 8.61)*	1.35	(1.14, 1.60)*	2.54	(1.32, 4.76)*	1.38	(1.15, 1.66)*
Ca(OH) <sub>2</sub> vs FS	2.16	(1.12, 4.31)*	1.22	(1.04, 1.42)*	2.90	(1.56, 5.54)*	1.37	(1.13, 1.67)*
MTA vs FS	1.00	(0.54, 1.86)	0.91	(0.70, 1.19)	0.64	(0.35, 1.22)	0.88	(0.66, 1.18)
Lasers vs FS	3.73	(1.27, 11.67)*	1.13	(0.92, 1.39)	2.47	(1.11, 5.23)*	1.27	(1.00, 1.62)*
MTA vs Ca(OH) <sub>2</sub>	0.47	(0.26, 0.83)*	0.80	(0.52, 1.23)	0.22	(0.12, 0.41)	0.58	(0.33, 1.00)
Lasers vs Ca(OH) <sub>2</sub>	1.72	(0.62, 4.98)	0.89	(0.68, 1.16)	0.86	(0.40, 1.72)	0.79	(0.56, 1.12)
Lasers vs MTA	3.76	(1.39, 10.08)*			3.88	(1.85, 8.05)*		

Ca(OH)<sub>2</sub>, Calcium hydroxide; CI, credible interval; FC, formocresol; FS, ferric sulfate; MTA, mineral trioxide aggregate; vs, versus.

\*P < 0.05.

Reprinted with permission from Lin PY, Chen HS, Wang YH, et al. Primary molar pulpotomy: a systematic review and network meta-analysis. *J Dent*. 2014;42(9):1060–77.



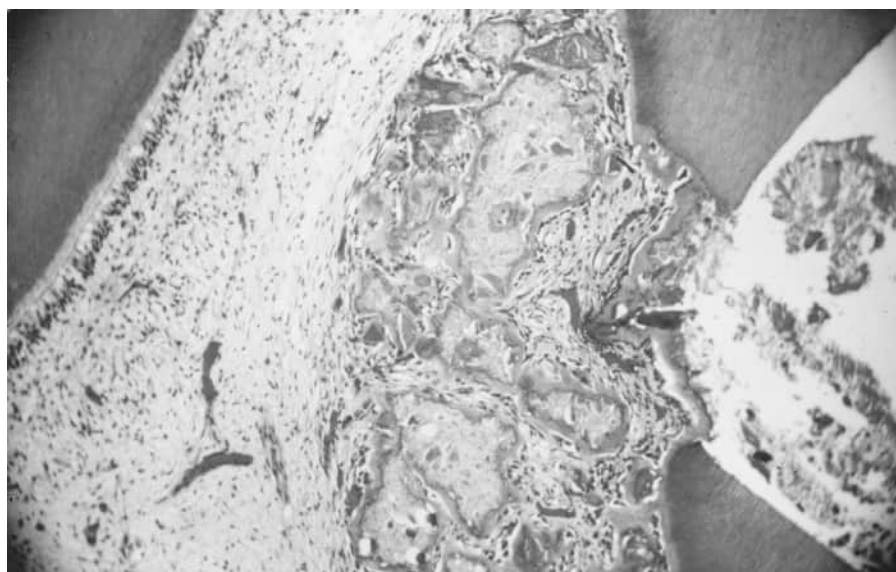
animals, bridging began in 14 days and was complete in 28 days regardless of the severity of the exposure. The major determinant in the healing of exposed rodent pulps appeared to be the presence or absence of microorganisms. These findings were later corroborated by Watts and Paterson.<sup>51</sup>

Walshe<sup>10</sup> provided further evidence that the success of vital pulp therapy depends on adherence to a surgically aseptic technique. In his experiment, the teeth of monkeys were capped with bovine dentin mixed with methylcellulose, and histologic observations were made 42 days postoperatively. Approximately half the teeth capped with the experimental material were successfully repaired with atubular dentin (Fig. 14.25). The remaining teeth showed various degrees of inflammation and repair. The Brown and Brenn staining technique demonstrated the presence of microorganisms

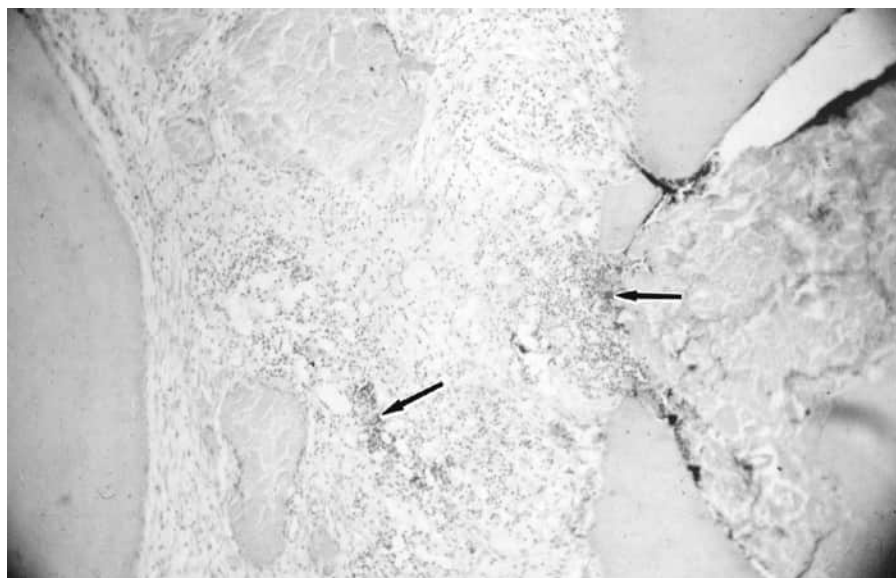
in the pulp of the teeth that failed to repair (Figs. 14.26 and 14.27). The stain also revealed microorganisms between the dentin walls and the filling material. The microorganisms were apparently introduced at the time of the pulp capping procedure, or leakage of the restoration allowed them to gain entrance to the pulp chamber. This study likewise supports the need for a good surgical technique and the placement of a restoration that will provide the best possible seal.

### INTERNAL RESORPTION

Radiographic evidence of internal resorption occurring within the pulp canal several months after the pulpotomy procedure is the most frequently seen evidence of an abnormal response in primary teeth (Fig. 14.28). Internal resorption is a destructive



**Fig. 14.25** Surgical exposure of the pulp of a monkey was capped with powdered bovine dentin. Atubular dentin bridging the exposure site was evident 42 days postoperatively.



**Fig. 14.26** Pulps capped with bovine dentin failed to undergo calcific repair and demonstrated microorganisms (arrows) in the pulp. (Courtesy of Dr. Martin Walshe.)

process generally believed to be caused by odontoclastic activity, and it may progress slowly or rapidly. Occasionally, secondary repair of the resorbed dentinal area occurs.

No satisfactory explanation for the postpulpotomy type of internal resorption has been given. It has been demonstrated, however, that with a true carious exposure of the

pulp, an inflammatory process will be present to some degree. The inflammation may be limited to the exposure site or it may be diffused throughout the coronal portion of the pulp. Amputation of all pulp showing the inflammatory change may be difficult or impossible, and abnormal pulp tissue may be allowed to remain. If the inflammation

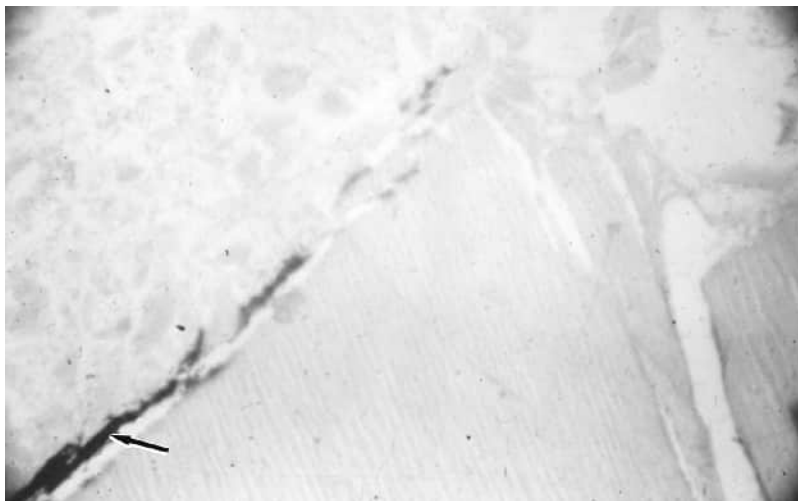

Fig. 14.27 Microorganisms (*arrow*) may be seen between the dentin walls and the filling material. (Courtesy of Dr. Martin Walshe.)

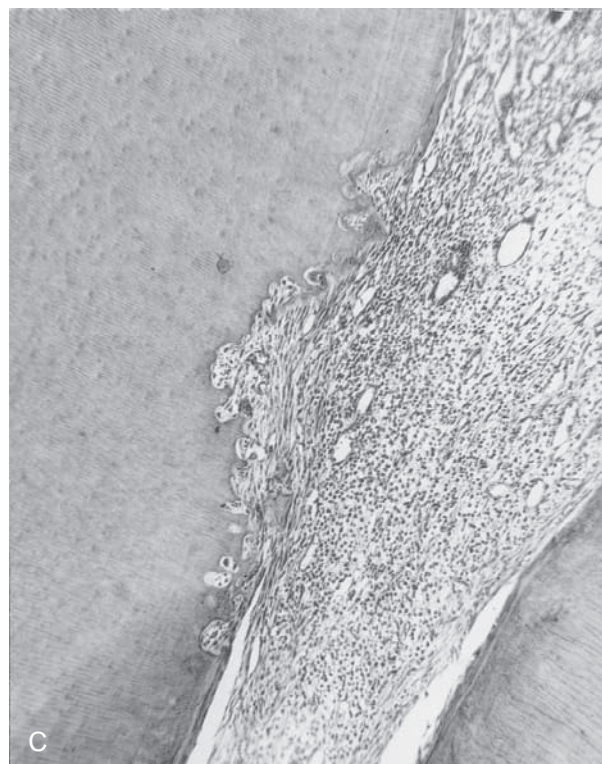
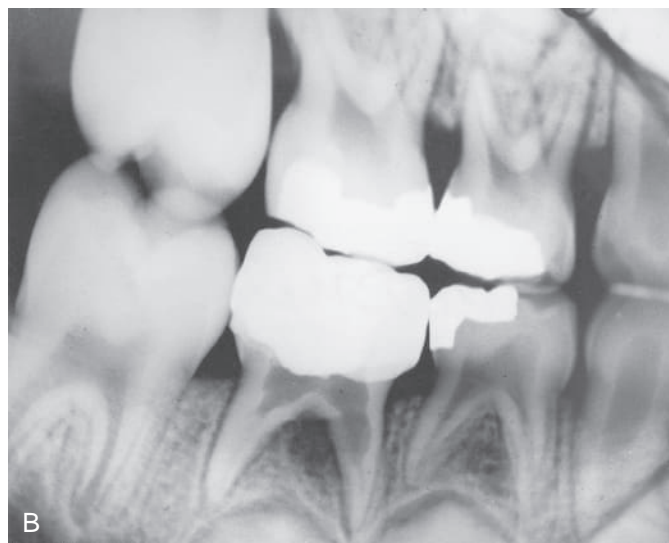
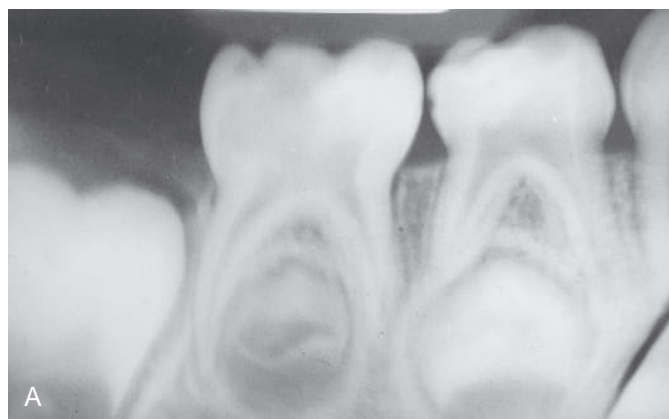


Fig. 14.28 (A) Preoperative radiograph of a second primary molar treated with the calcium hydroxide pulpotomy technique. (B) Two years after treatment, internal resorption and bone rarefaction are evident. (C) There may have been inflammation of the pulp apical to the amputation site and beginning internal resorption at the time of the initial treatment.



extended to the entrance of the pulp canal, odontoclasts may have been attracted to the area; if it were possible to examine the tooth histologically, small bays of resorption would be evident. This condition may exist during pulp therapy, but there is no way to detect it. The only indication would be the clinical evidence of a hyperemic pulp.

Inflammatory cells drawn to the area as a result of the placement of an irritating capping material might well attract odontoclastic cells and initiate internal resorption. This may explain the occurrence of internal resorption even though the pulp is normal at the time of treatment. Because the roots of primary teeth are undergoing normal physiologic resorption, vascularity of the apical region is increased. Odontoclastic activity present in the area may predispose the tooth to internal resorption when an irritant in the form of a pulp capping material is placed on the pulp.

### ALVEOLAR ABSCESS

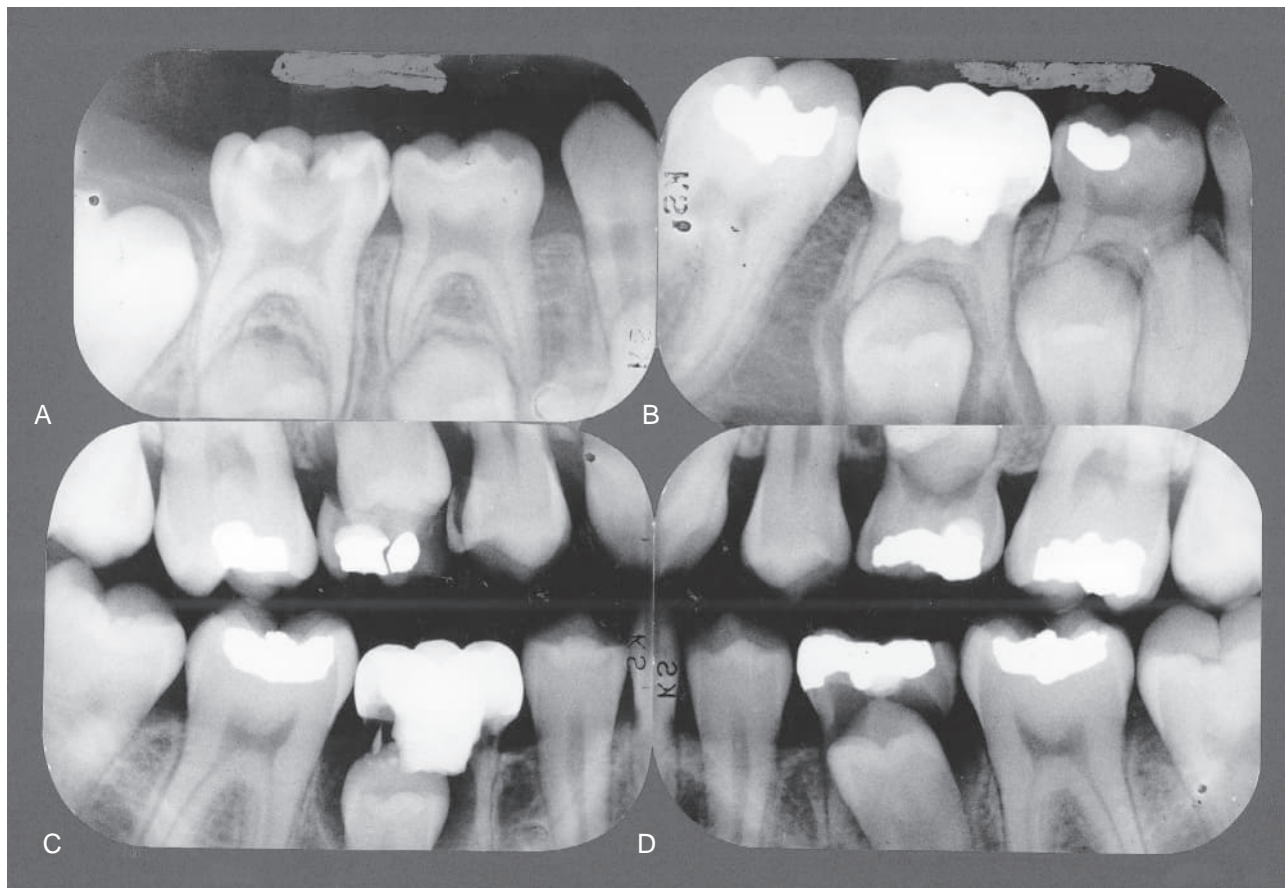
An alveolar abscess occasionally develops some months after pulp therapy is completed. The tooth usually remains asymptomatic and the child may be unaware of the infection, which may be present in the bone surrounding the root apices or in the area of the root bifurcation. A fistulous opening may be present indicating the chronic condition of the infection. Primary teeth that show evidence of an alveolar abscess should be removed. Permanent teeth that have previously been treated by pulp capping or pulpotomy and

later show evidence of pulpal necrosis and apical infection may be considered for endodontic treatment.

## Early Exfoliation or Over Retention of Primary Teeth With Pulp Treatments

Occasionally, a pulpally treated tooth previously believed to be successfully managed will loosen and exfoliate (or require extraction) prematurely for no apparent reason. Such a condition is believed to result from low-grade, chronic, asymptomatic, localized infection. Usually, abnormal and incomplete root resorption patterns of the affected teeth are also observed. When this occurs, space management should be considered.

Another sequela requiring close observation is the tendency for primary teeth undergoing successful pulpotomies or pulpectomies to be over retained. This situation may have the untoward result of interfering with the normal eruption of permanent teeth and adversely affecting the developing occlusion. Close periodic observation of pulpally treated teeth is necessary to intercept such a developing problem. Extraction of the primary tooth is usually sufficient. This phenomenon may occur when normal physiologic exfoliation is delayed by the bulky amount of cement contained in the pulp chamber. Even though the material is resorbable, its resorption is slowed significantly when large quantities are present (Fig. 14.29).



**Fig. 14.29** (A) A pulpally involved second primary molar was successfully treated with a formocresol pulpotomy and restored with a stainless-steel crown. (B) This 4-year posttreatment radiograph reveals long-term successful management. (C) and (D) Bilateral bitewing radiographs for the same patient 7 years after the pulpotomy reveal that the resorption of the pulpotomized molar is falling behind compared with its antimeres. The eruption of the permanent second premolar is also being delayed. The pulpally treated tooth should be extracted at this time. (Courtesy of Dr. Wayne A. Moldenhauer.)



## References

- Pediatric endodontics, Chapter 24. In Hargreaves KM, editor: *Cohen's pathways of the pulp*, ed 11, Berman L.M. St. Louis, 2015, Mosby-Elsevier.
- Hori A, Poureslami HR, Parirokh M, et al.: The ability of pulp sensibility tests to evaluate the pulp status in primary teeth, *Int J Paediatr Dent* 21(6):441–445, 2011.
- Miwa Z, Ikawa M, Iijima H, et al.: Pulpal blood flow in vital and non-vital young permanent teeth measured by transmitted-light photoplethysmography: a pilot study, *Pediatr Dent* 24(6):594–598, 2002.
- Dunlop RM, Sanders BJ, Jones JE, et al. Pulp therapy in pediatric patients with congenital heart disease: survey of American Academy of Pediatric Dentistry members. *J Dent Child*. 2001 3;80(3):139–144.
- Schwendicke F, Frencken JE, Bjørndal L, et al.: Managing carious lesions: consensus recommendations on carious tissue removal, *Adv Dent Res* 28(2):58–67, 2016, <https://doi.org/10.1177/0022034516639271>
- Elhennawy K, Finke C, Paris S, et al.: Selective vs stepwise removal of deep carious lesions in primary molars: 12-Months results of a randomized controlled pilot trial, *J Dent* 77:72–77, 2018, <https://doi.org/10.1016/j.jdent.2018.07.011>.
- Al-Zayer MA, Straffon LH, Feigal RJ, et al.: Indirect pulp treatment of primary posterior teeth: a retrospective study, *Pediatr Dent* 25(1):29–36, 2003.
- Nirschl RF, Avery DR: Evaluation of a new pulp capping agent in indirect pulp therapy, *J Dent Child* 50(1):25–30, 1983.
- Coll JA, Seale NS, Vargas K, et al.: Primary tooth vital pulp therapy: a systematic review and meta-analysis, *Pediatr Dent* 39(1):16–123, 2017.
- Walshe MJ. Pulp reaction to anorganic bovine dentin [Master's thesis], Indiana University School of Dentistry: Indianapolis.
- Chailertvanitkul P, Paphangkorakit J, Sooksantisakoonchai N, et al.: Randomized control trial comparing calcium hydroxide and mineral trioxide aggregate for partial pulpotomies in cariously exposed pulps of permanent molars, *Int Endod J* 47(9):835–842, 2014.
- Caicedo R, Abbott PV, Alongi DJ, et al.: Clinical, radiographic and histological analysis of the effects of mineral trioxide aggregate used in direct pulp capping and pulpotomies of primary teeth, *Aust Dent J* 51(4):297–305, 2006.
- Walker LA, Sanders BJ, Jones JE, et al.: Current trends in pulp therapy: a survey analyzing pulpotomy techniques taught in pediatric dental residency programs, *J Dent Child* 80(1):31–35, 2013.
- Milnes AR: Is formocresol obsolete? A fresh look at the evidence concerning safety issues, *Pediatr Dent* 30(3):237–246, 2008.
- Garcia-Godoy FR, Novakovic DP, Carvajal IN: Pulpal response to different application times of formocresol, *J Pedod* 6(2):176–193, 1982.
- Fernández CC, Martínez SS, Jimeno FG, et al.: Clinical and radiographic outcomes of the use of four dressing materials in pulpotomized primary molars: a randomized clinical trial with 2-year follow-up, *Int J Paed Dent* 23(6):400–407, 2013.
- Juneja P, Kulkarni S: Clinical and radiographic comparison of biodentine, mineral trioxide aggregate and formocresol as pulpotomy agents in primary molars, *Eur Arch Paediatr Dent* 18(4):271–278, 2017, <https://doi.org/10.1007/s40368-017-0299-3>
- Rawson TH, Rayes S, Strizich G, et al.: Longitudinal study comparing pulpectomy and pulpotomy treatments for primary molars of Alaska native children, *Pediatr Dent* 41(3):214–220, 2019. PMID: 31171074.
- Hibbard ED, Ireland RL: Morphology of the root canals of the primary molar teeth, *J Dent Child* 24:250–257, 1957.
- Aminabadi NA, Farahani RM, Gajan EB: Study of root canal accessibility in human primary molars, *J Oral Sci* 50(1):69–74, 2008.
- da Costa CC, Kunert GG, da Costa F, et al.: Endodontics in primary molars using ultrasonic instrumentation, *J Dent Child* 75(1):20–23, 2008.
- Bodur H, Odabaş M, Tulunoğlu Ö, et al.: Accuracy of two different apex locators in primary teeth with and without root resorption, *Clin Oral Invest* 12(2):137–141, 2008.
- Holan G, Fuks AB: A comparison of pulpectomies using ZOE and KRI paste in primary molars: a retrospective study, *Pediatr Dent* 15(6):403–407, 1993.
- Ritwik P: A review of pulp therapy for primary and immature permanent teeth, *Calif Dent Assoc J* 41(8):585–594, 2013.
- Rifkin A: A simple, effective, safe technique for the root canal treatment of abscessed primary teeth, *J Dent Child* 47(6):435–441, 1980.
- Rifkin A: The root canal treatment of abscessed primary teeth—a three to four year follow-up, *J Dent Child* 49(6):428–431, 1982.
- Nurko C, Garcia-Godoy F: Evaluation of the calcium hydroxide/iodoform paste (Vitapex) in root canal therapy for primary teeth, *J Clin Pediatr Dent* 23(4):289–294, 1999.
- American Academy of Pediatric Dentistry: Special issue: reference manual 2018–2019, *Pediatr Dent* 40(Suppl 6):343–351, 2019.
- Chen JW, Jordan M: Materials for primary tooth pulp treatment: the present and the future, *Endo Topics* 23(1):41–49, 2012.
- Doyle WA: Formocresol versus calcium hydroxide in pulpotomy, *J Dent Child* 29:86–97, 1962.
- Casas MJ, Layug MA, Kenny DJ, et al.: Two-year outcomes of primary molar ferric sulfate pulpotomy and root canal therapy, *Pediatr Dent* 25(2):97–102, 2003.
- Celik B, Ataç AS, Cehreli ZC, et al.: A randomized trial of mineral trioxide aggregate cements in primary tooth pulpotomies, *J Dent Child* 80(3):126–132, 2013.
- Pameijer CH, Stanley HR: The disastrous effects of the “total etch” technique in vital pulp capping in primates, *Am J Dent* 11(Spec Iss):S45–S54, 1988.
- Ford TR, Torabinejad M, Abedi HR, et al.: Using mineral trioxide aggregate as a pulp capping material, *J Am Dent Assoc* 127(10):1491–1494, 1996.
- Jepsen S, Albers HK, Fleiner B, et al.: Recombinant human osteogenic protein-1 induces dentin formation: an experimental study in miniature swine, *J Endod* 23(6):378–382, 1997.
- Calland JW, Harris SE, Carnes Jr DL: Human pulp cells respond to calcitonin gene-related peptide in vitro, *J Endod* 23(8):485–489, 1997.
- Ranly DM: Pulpotomy therapy in primary teeth: new modalities for old rationales, *Pediatr Dent* 16:403–409, 1994.
- Sabbarini J, Mounir M, Dean J: Histological evaluation of enamel matrix derivative as a pulpotomy agent in primary teeth, *Pediatr Dent* 29(6):475–479, 2007.
- Fuks AB: Current concepts in vital primary pulp therapy, *Eur J Paediatr Dent* 3(3):115–120, 2002.
- Sabbarini J, Mohamed A, Wahba N, et al.: Comparison of enamel matrix derivative versus formocresol as pulpotomy agents in the primary dentition, *J Endod* 34(3):284–287, 2008.
- Hu L, Liu Y, Wang S: Stem cell-based tooth and periodontal regeneration, *Oral Dis* 24(5):696–705, 2018, <https://doi.org/10.1111/odi.12703> Retrieved from <https://www.ncbi.nlm.nih.gov/pubmed/28636235>.
- Nakashima M, Iohara K, Murakami M, et al.: Pulp regeneration by transplantation of dental pulp stem cells in pulpitis: a pilot clinical study, *Stem Cell Res Ther* 8(1):61, 2017, <https://doi.org/10.1186/s13287-017-0506-5> Retrieved from <https://www.ncbi.nlm.nih.gov/pubmed/28279187>.
- Mack RB, Dean JA: Electrosurgical pulpotomy: a retrospective human study, *J Dent Child* 60(2):107–114, 1993.
- Dean JA, Mack RB, Fulkerson BT, et al.: Comparison of electrosurgical and formocresol pulpotomy procedures in children, *Int J Paediatr Dent* 12(3):177–182, 2002.
- Rivera N, Reyes E, Mazzaoui S, et al.: Pulpal therapy for primary teeth: formocresol vs electrosurgery: a clinical study, *J Dent Child* 70(1):71–73, 2003.
- Fishman SA, Udin RD, Good DL, et al.: Success of electrofulguration pulpotomies covered by zinc oxide and eugenol or calcium hydroxide: a clinical study, *Pediatr Dent* 18:385–390, 1996.
- Moritz A, Schoop U, Goharkhay K, et al.: The CO<sub>2</sub> laser as an aid in direct pulp capping, *J Endod* 24(4):248–251, 1998.
- De Coster P, Rajasekharan S, Martens L: Laser-assisted pulpotomy in primary teeth: a systematic review, *Int J Paediatr Dent* 23(6):389–399, 2013.
- Lin PY, Chen HS, Wang YH, et al.: Primary molar pulpotomy: a systematic review and network meta-analysis, *J Dent* 42(9):1060–1077, 2014.
- Kakehashi S, Stanley HR, Fitzgerald RJ: The effects of surgical exposures of dental pulps in germ-free and conventional laboratory rats, *Oral Surg Oral Med Oral Pathol* 20:340–349, 1965, [https://doi.org/10.1016/0030-4220\(65\)90166-0](https://doi.org/10.1016/0030-4220(65)90166-0)
- Watts A, Paterson RC: Bacterial contamination as a factor influencing the toxicity of materials to the exposed dental pulp, *Oral Surg* 64(4):466–474, 1987.

## 15

# Gingivitis and Periodontal Disease

DANIEL E. SHIN, JAMES E. JONES and VANCHIT JOHN

## CHAPTER OUTLINE

### Current Classification of Periodontal and Peri-Implant Diseases and Conditions

#### Eruption Gingivitis

#### Dental Biofilm-Induced Gingivitis—Gingivitis Caused by Biofilm (Bacteria)

#### Allergy and Gingival Inflammation

#### Acute Gingival Disease

Oral Herpes Simplex Virus Infection

Recurrent Aphthous Ulcer (Canker Sore)

Necrotizing Gingivitis

Acute Candidiasis (Thrush, Candidosis, Moniliasis)

Acute Bacterial Infections

#### Chronic Nonspecific Gingivitis

#### Chlorhexidine as a Therapeutic Plaque Control Agent

#### Gingival Diseases Modified by Systemic Factors

Gingival Diseases Associated with the Endocrine System

Gingival Lesions of Genetic Origin

Phenytoin-Induced Gingival Overgrowth

Ascorbic Acid Deficiency Gingivitis (Scurbutic Gingivitis)

#### Periodontal Diseases in Children

Periodontitis (Previously Called Aggressive Periodontitis and Early-Onset Periodontitis)

Generalized Periodontitis (Previously Called Generalized Aggressive Periodontitis)

Treatment of Generalized Periodontitis and Periodontitis with a Molar-Incisor Distribution

#### Periodontitis as a Manifestation of Systemic Disease

Vanishing Bone Disease (Gorham-Stout Syndrome) Premature Bone Loss in the Primary Dentition

Papillon-Lefèvre Syndrome

Gingival Recession

Oral Factitious Injuries

Abnormal Frenum Attachment

Frenotomy and Frenectomy

Technique for Mandibular Frenectomy and Vestibular Depth Increase

Free Soft Tissue Autograft (Previously Known as the Free Gingival Autograft) Procedure

Lasers

#### Clinical Assessment of Oral Cleanliness and Periodontal Disease

Plaque Control Record

Periodontal Screening and Recording

#### Extrinsic Stains and Deposits on Teeth

Green Stain

Orange Stain

Black Stain

Removal of Extrinsic Stains

Pigmentation Caused by Stannous Fluoride Application

#### Calculus

## Current Classification of Periodontal and Peri-Implant Diseases and Conditions

In 2017, the American Academy of Periodontology (AAP) and the European Federation of Periodontology (EFP) worked jointly to update the 1999 Classification of Periodontal Disease. Case definitions, diagnostic criteria, and the addition of peri-implant diseases and conditions were considered as part of the new classification.

Within this new classification system, periodontal diseases and conditions are divided into three main categories: 1) periodontal health, gingival diseases, and conditions; 2) periodontitis; and 3) other conditions affecting the periodontium.

Summary of the key changes in the current classification system:

1. The term “chronic periodontitis” has been replaced with “periodontitis.”
2. The term “aggressive periodontitis” is no longer considered a separate and distinct entity.
3. The concepts of staging (severity) and grading (rate of progression) of periodontitis have been introduced.
4. The terms mild, moderate, and severe that refer to disease severity have been removed and replaced with stages I, II, III, and IV with respect to periodontitis.
5. The term “periodontal biotype” has been replaced with “periodontal phenotype.”

**TABLE 15.1** Classification of Periodontal and Peri-Implant Diseases and Conditions

Periodontal Diseases and Conditions										
Periodontal Health, Gingival Diseases and conditions			Periodontitis			Other Conditions Affecting the Periodontium				
Periodontal Health and Gingival Health	Gingivitis: Dental Biofilm-Induced	Gingival Diseases: Non-dental Biofilm-Induced	Necrotizing Periodontal Diseases	Periodon- titis	Periodontitis as a Manifestation of Systemic Diseases	Systemic Diseases or Conditions Affecting the Periodontal Supporting Tissues	Periodontal Abscesses and Endodontic-Periodontal Lesions	Mucogingival Deformities and Conditions	Traumatic Occlusal Forces	Tooth and Prosthesis-Related Factors
Peri-Implant Diseases and Conditions										
Peri-Implant Health		Peri-Implant Mucositis		Peri-Implant			Peri-Implant Soft and Hard Tissue Deficiencies			

Adapted from Caton et al, *J Clin Periodontol*. 2018; 45(Suppl 20); S1-S8.

- The term “excessive occlusal force” has been replaced with the term “traumatic occlusal force.”
- The term “biologic width” has been replaced with “supracrestal tissue attachment.”
- “Linear gingival erythema” as a term has been removed.
- The term “ulcerative” has been removed from “necrotizing periodontal diseases.”
- The Miller Classification for gingival recession has been replaced with recession types 1–3.

Periodontal diseases and conditions include three major categories:

- Periodontal health and gingival diseases
  - Periodontal and gingival health
  - Gingivitis caused by biofilm (bacteria)
  - Gingivitis not caused by biofilm
- Periodontitis
  - Necrotizing diseases
  - Periodontitis as a manifestation of systemic disease
  - Periodontitis (more detailed explanation below)
- Other conditions affecting the periodontium
  - Systemic diseases affecting the periodontium
  - Periodontal abscess or periodontal/endodontic lesions
  - Mucogingival deformities and conditions
  - Traumatic occlusal forces
  - Tooth- and prosthesis-related factors

Peri-implant diseases and conditions include four major categories:

- Peri-implant health
- Peri-implant mucositis
- Peri-implantitis
- Peri-implant soft and hard tissue deficiencies

#### Periodontal Health and Gingival Diseases

##### Periodontal and Gingival Health

Key features: Presence of <10% bleeding sites along with probing depths (PDs)  $\leq$  3 mm

##### Gingivitis

##### Key Features:

Presence of 10% or more bleeding sites along with PDs  $\leq$  3 mm

Localized involvement is defined as 10%–30% bleeding sites

Generalized involvement is defined as >30% bleeding sites

The current classification system has introduced the concepts of staging and grading of periodontitis. Staging of periodontitis is based on both severity and complexity of management. Grading of periodontitis assesses the rate of progression of the disease, its anticipated response to treatment, and the impact on systemic health.

Staging of Periodontitis:

#### Stage I (Initial)

Key features of stage I periodontitis:

Initial manifestation of the disease. Features include 1–2 mm of interdental clinical attachment loss (CAL) at the site of greatest loss, <15% bone loss (BL) only in the coronal third of the root, no tooth loss due to periodontitis, PDs of 4 mm or less, with the bone being mostly horizontal in appearance (Fig. 15.1A and B).

#### Stage II (Moderate)

Key features of stage II periodontitis

Moderate manifestation of the disease, features include 3–4 mm of interdental CAL at the site of greatest loss, BL of 15%–33% in the coronal third of the root, PDs of 5 mm or less, with mostly horizontal BL (Fig. 15.2A and B).

#### Stage III (Severe)

Key features of stage III periodontitis

Severe manifestation of the disease, features include 5 mm or more of CAL at the site of greatest loss, BL extending to the middle third of the root and beyond, presence of vertical BL of  $\geq$  3 mm along with the presence of class 2 or 3 furcation involvement. In addition, the presence of tooth loss ( $\leq$  4 mm) is associated with moderate ridge defects (Fig. 15.3A and B).

#### Stage IV (Severe)

Along with all the features of stage III, stage IV periodontitis exhibits additional features that necessitate the need for complex rehabilitation due to masticatory dysfunction, secondary occlusal trauma, severe ridge defects, bite collapse, pathologic migration of teeth, and the presence of fewer than 20 remaining teeth (10 opposing pairs) (Fig. 15.4A and B).

Extent and distribution of periodontitis:

- Localized—BL is present in fewer than 30% of teeth in mouth
- Generalized—BL is present in 30% or more teeth in mouth



**TABLE 15.2** Staging of Periodontitis

## Staging and Grading Periodontitis

	Periodontitis	Stage I	Stage II	Stage III	Stage IV
<b>Severity</b>	<b>Interdental CAL</b> ( <i>at the site of greatest loss</i> )	1–2 mm	3–4 mm	≥5 mm	≥5 mm
	<b>RBL</b>	Coronal third (<15%)	Coronal third (<15%–33%)	Extending to middle third of root and beyond ≤4 teeth	Extending to middle third of root and beyond ≥5 teeth
	<b>Tooth loss</b> ( <i>due to periodontitis</i> )	No tooth loss			
<b>Complexity</b>	<b>Local</b>	Max. probing depth ≤4 mm Mostly horizontal bone loss	Max. probing depth ≤5 mm Mostly horizontal bone loss	In addition to stage II complexity: Probing depths ≥6 mm Vertical bone loss ≥3 mm Furcation involvement Class II or III Moderate ridge defects	In addition to stage III complexity: Need for complex rehabilitation due to: - Masticatory dysfunction - Secondary occlusal trauma (tooth mobility degree ≥2) - Severe ridge defects - Bite collapse, drifting, flaring - < 20 remaining teeth (10 opposing pairs)
<b>Extent and distribution</b>	<b>Add to stage as descriptor</b>	For each stage, describe extent as: Localized (<30% of teeth involved); generalized; or molar/incisor pattern			

The 2017 World Workshop on the Classification of Periodontal and Peri-Implant Diseases and Conditions resulted in a new classification of periodontitis characterized by a multidimensional staging and grading system. The charts below provide an overview. Please visit [perio.org/2017wwdc](http://perio.org/2017wwdc) for the complete suite of reviews, case definition papers, and consensus reports.

## PERIODONTITIS: STAGING

**Staging intends to classify the severity and extent of a patient's disease based on the measurable amount of destroyed and/or damaged tissue as a result of periodontitis and to assess the specific factors that may attribute to the complexity of long-term case management.**

Initial stage should be determined using clinical attachment loss (CAL). If CAL is not available, radiographic bone loss (RBL) should be used. Tooth loss due to periodontitis may modify stage definition. One or more complexity factors may shift the stage to a higher level. See [perio.org/2017wwdc](http://perio.org/2017wwdc) for additional information.

3. Molar-incisor—BL is found in molar (usually first) and incisors

## Grading of periodontitis:

1. Grade A (Slow progression)

Features include: no evidence of BL or CAL over a period of 5 years, percentage of BL in relationship to age is <0.25, clinical presence of heavy biofilm with low levels of destruction, patient is not a smoker and is normoglycemic or not diagnosed with diabetes.

2. Grade B (Moderate progression)

Features include: evidence of less than 2 mm BL or CAL over a period of 5 years, percentage of BL in relationship to age is 0.25–1.0, patient smokes fewer than 10 cigarettes per day, biofilm is commensurate with the extent of destruction, and glycated hemoglobin (HbA1c) is less than 7%.

3. Grade C (Rapid progression)

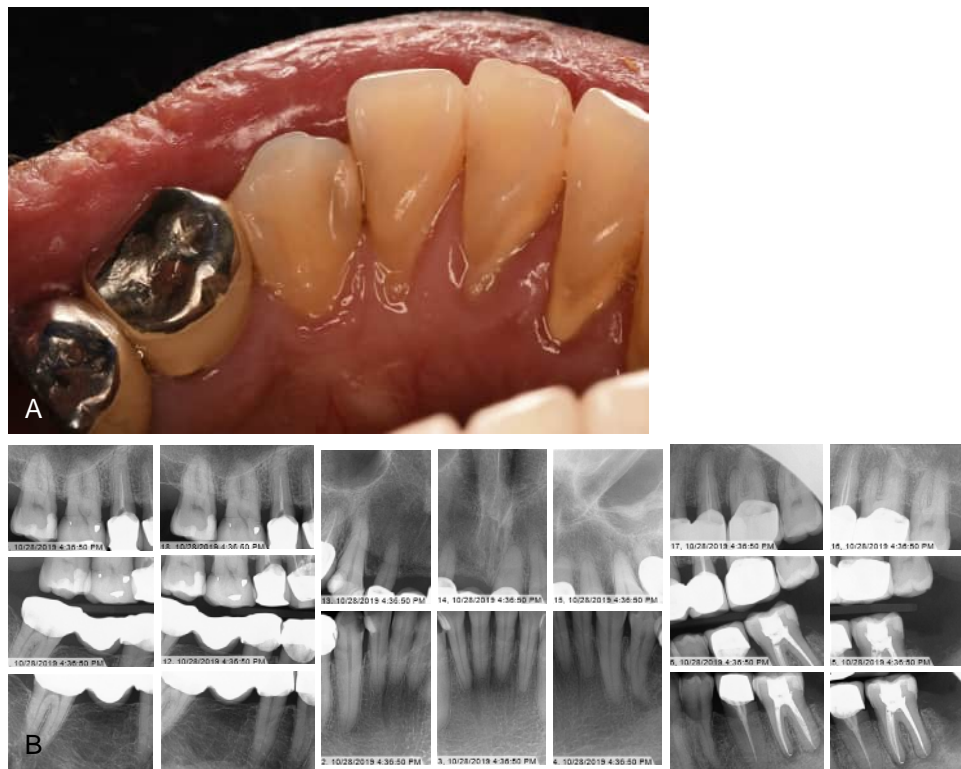
Features include: evidence of greater than 2 mm BL or CAL over a period of 5 years, destruction exceeds the amount of biofilm present, patient smokes more than 10 cigarettes per day, and HbA1c is 7% or higher.

The periodontium is composed of four structures: cementum, alveolar bone, periodontal ligament (PDL), and gingiva. Of these four periodontal structures, the gingiva is the only component that is visually accessible. The gingiva is the oral keratinized tissue that covers the alveolar processes and the cervical necks of the anatomic crown. Anatomically, the gingiva is divided into two zones—the free

gingiva and the attached gingiva. The free gingiva is considered “free” because it is not bound down to the underlying periosteum or tooth. Functionally, the free gingiva forms a cuff or collar of the gum tissue around the cervical neck of the anatomic crown of a tooth. Clinically, it extends from the gingival margin (the gumline) to the free gingival groove (which is the approximation of the base of the sulcus). In comparison, the attached gingiva is a firm, resilient tissue that is tightly bound down to the underlying periosteum and the tooth (hence called “attached”). Clinically, it extends apically from the free gingival groove to the mucogingival junction.

Healthy gingival tissues appear light pink, although the color may be related to the complexion of the person, the thickness of the tissue, and the degree of keratinization. The gingival color of the young child may be more reddish due to increased vascularity and thinner epithelium. The gingival surface of a child appears less stippled or smoother than that of an adult. In the healthy adult, the marginal gingiva has a sharp, knifelike edge. During the period of tooth eruption in the child, however, the gingiva is thicker with rounded margins due to the migration and cervical constriction of the primary teeth.

Delaney<sup>1</sup> reported PDs around primary teeth to be approximately 2 mm, with the facial and lingual probe sites shallower than the proximal sites. The PDL is wider in children than in adults. The width of the attached gingiva is narrower in the mandible than in the maxilla, and both widths increase with the transition from the primary to permanent dentition in the child. The alveolar



**Fig. 15.1** (A) Clinical presentation of a Stage I periodontitis case. This patient presented with 1-2 mm of interdental clinical attachment loss at the site of greatest loss and a maximum probing depths of 4 mm. Note the heavy buildup of supragingival calculus and the overt gingival inflammation. (B) Radiographic presentation. These are the radiographs of the same patient case pictured in Fig. 15-1(A). Along with the clinical presentation of the soft tissue, radiographs show mostly horizontal bone loss extending to the coronal one-third of the root length, which is consistent with Stage I periodontitis.

bone surrounding the primary dentition demonstrates fewer trabeculae, less calcification, and larger marrow spaces.

Recent recognition that periodontal disease may have its origins in childhood has led dentists to be more aggressive in treatment. Studies confirm a high prevalence of gingival inflammation in children. Periodontal conditions that progress rapidly and result in the loss of primary and permanent teeth have been noted with increased frequency.<sup>2</sup> Therefore, the American Academy of Pediatric Dentistry recommends placing greater emphasis on the prevention, early diagnosis, and treatment of gingival and periodontal disease in children.<sup>3</sup> By establishing excellent oral hygiene habits in children, the habits will carry over to adulthood and reduce the risk of periodontal disease and dental caries.

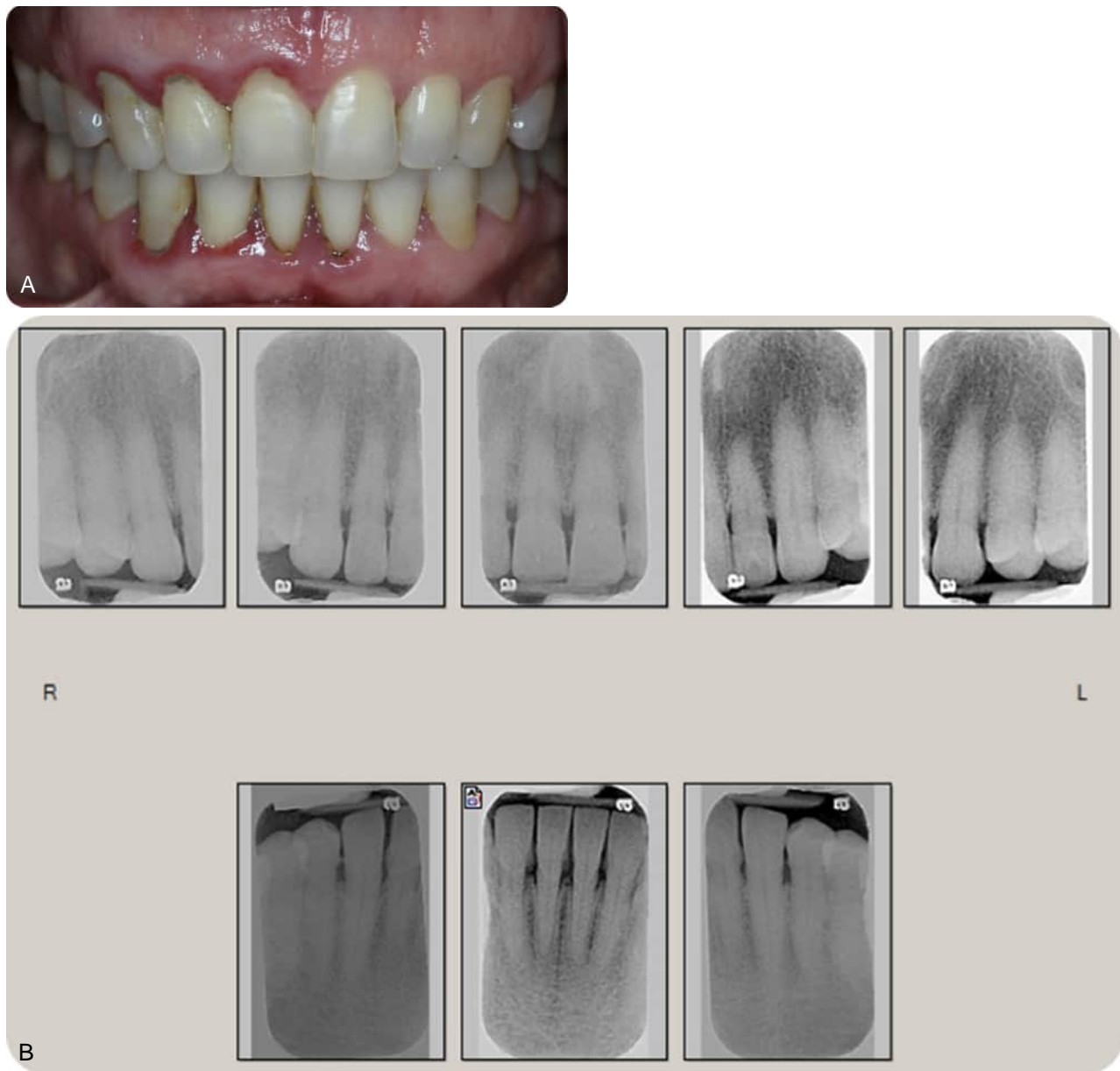
Gingivitis is inflammation involving only the gingival tissues surrounding the tooth. Microscopically, it is characterized by the presence of an inflammatory exudate and edema, some destruction of collagenous gingival fibers, and ulceration and proliferation of the epithelium facing the tooth and attached to the gingiva. Numerous studies indicate that marginal gingivitis is the most common form of periodontal disease and starts in early childhood.

Severe gingivitis is relatively uncommon in children, although numerous surveys have shown that a large portion of the pediatric population has mild gingivitis.

The major etiologic factors associated with gingivitis and more significant periodontal disease are uncalcified and calcified bacterial plaque (known as calculus, or in laymen's term "tartar"). However, gingivitis rarely progresses to periodontitis in the preschool and grade school child.

Bacterial plaque, which is composed of soft bacterial deposits that adhere firmly to the teeth, is considered to be a complex, metabolically interconnected, highly organized bacterial system consisting of dense masses of microorganisms embedded in an intermicrobial matrix (biofilm). In sufficient concentration, it can disturb the host-parasite relationship and cause dental caries and periodontal disease.

Eastcott and Stallard<sup>4</sup> have observed that plaque begins to form within 2 hours after the teeth are brushed. Coccal forms of bacteria appear first on a thin fenestrated pellicle (organic bacteria-free film deposited on the tooth surface). The surface is completely covered with a smooth material 3 hours after teeth are brushed. Within 5 hours, plaque microcolonies develop, apparently by cell division. Between 6 and 12 hours, the covering material becomes thinner and is reduced to discontinuous small scattered areas. About 30% of the cocci are in various stages of division by 24 hours. Rod-shaped bacteria appear for the first time in the 24-hour-old plaque. Within 48 hours, the surface of the plaque is covered with a mass of rods and filaments.



**Fig. 15.2** (A) Clinical presentation of stage II periodontitis. (B) Radiographic presentation of stage II periodontitis.

Dental calculus, which is considered to be a calcified dental plaque, is discussed later in the chapter. It is classified as supragingival or subgingival, depending on its location on the tooth. Supragingival calculus presents as hard, firmly adherent masses on the enamel of teeth, whereas subgingival calculus is found as a concretion on the tooth in the confines of the periodontal pocket. The surface of dental calculus is always covered by an uncalcified plaque. Calculus is an important factor in the development of gingival and periodontal disease.

In a study involving approximately 1700 children of 9–14 years of age, Suomi et al.<sup>5</sup> found that a relatively high percentage of children of all racial-ethnic groups had calculus (both supragingival and subgingival). About 56% to 85% of the children in the various age, gender, and racial-ethnic groups had supragingival calculus. The findings of

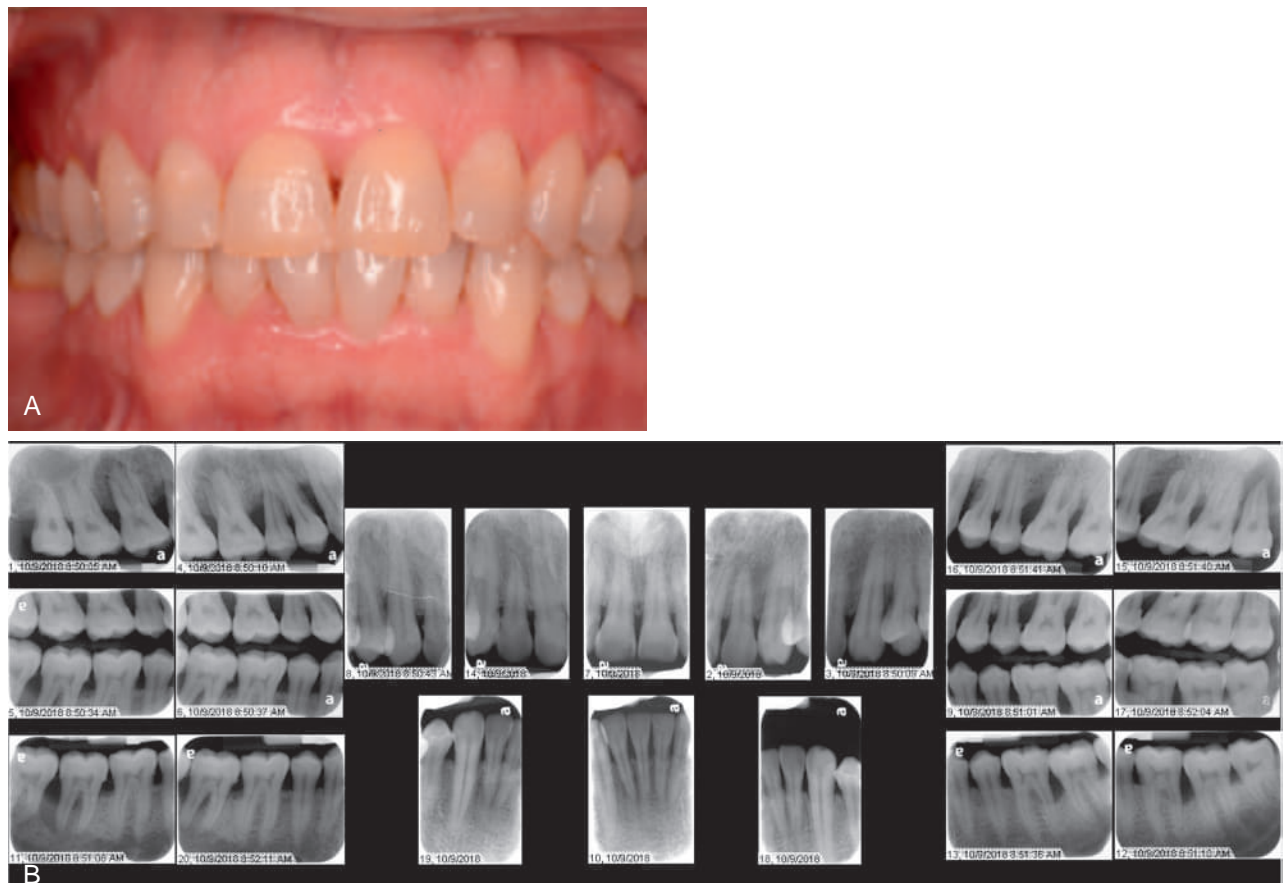
this study indicated that most children aged 9–14 years with low socioeconomic status would benefit from inclusion in a preventive periodontal disease program based on the improvement of oral hygiene.

## Eruption Gingivitis

A transitory type of gingivitis is often observed in young children when the primary teeth are erupting. This gingivitis, often localized and associated with difficult eruption, subsides after the teeth emerge into the oral cavity.

Weddell and Klein<sup>6</sup> conducted a study to determine the prevalence of gingivitis in a group of children between 6 and 36 months of age. The children, patients of pediatricians in the Indianapolis area, were born in the area which





**Fig. 15.3** (A) Clinical presentation of stage III periodontitis. (B) Radiographic presentation of stage III periodontitis.

had a fluoridated water supply. Among 299 white children, gingivitis was present in 13% of those in the age range 6–17 months, 34% of those in the age range 18–23 months, and 39% of those in the age range 24–36 months. African-American children were not included in the study because of the inconsistency of their gingival colors. The gingivitis observed by Weddell and Klein<sup>6</sup> was mostly eruption gingivitis. Nevertheless, their findings support the view that an oral hygiene program should be initiated by parents when the child is very young.

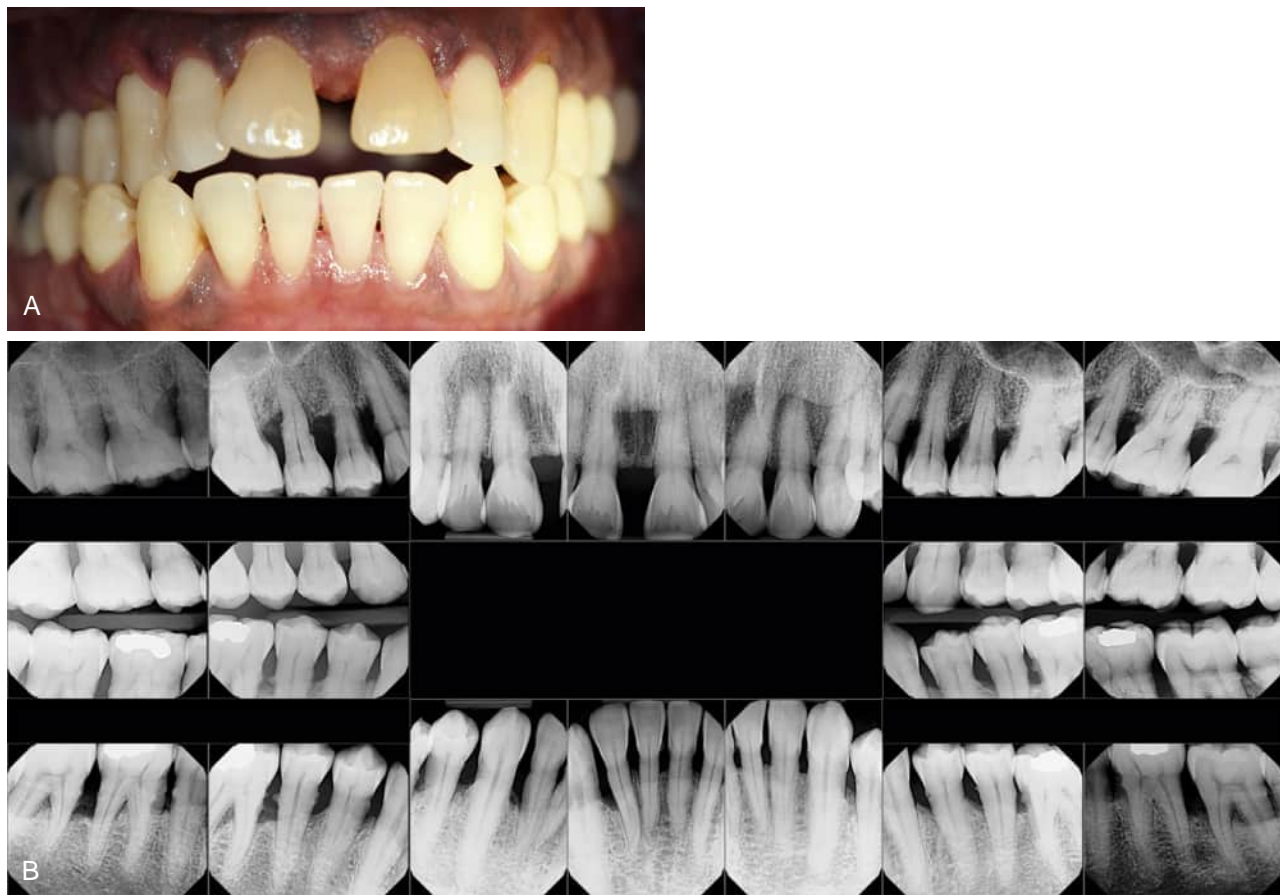The greatest increase in the incidence of gingivitis in children is often seen in the 6- to 7-year age group when the permanent teeth begin to erupt. This increase in gingivitis apparently occurs because the gingival margin receives no protection from the coronal contour of the tooth during the early stage of active eruption, and the continual impingement of food on the gingivae exacerbates the inflammatory process.

Food debris, materia alba, and bacterial plaque often collect around the cervical necks of the anatomic crown and extend below the gingival margin to colonize the sulcus. It can also partially cover the crown of the erupting tooth, leading to plaque accumulation, and ultimately trigger an inflammatory reaction (Fig. 15.5). This soft tissue inflammation is most commonly associated with the eruption of the first, second, and third permanent molars; the condition can be painful and can develop into pericoronitis or

a pericoronal abscess. Mild eruption gingivitis requires no treatment other than suppressing the inflammatory process by reinforcing a proper oral hygiene regimen for the patient. Painful pericoronitis may be managed by gently removing the plaque buildup around the inflamed soft tissue and irrigating the area with a counterirritant, such as Peroxyl (Colgate-Palmolive Co., New York, NY, USA), or surgically excised. Pericoronitis accompanied by swelling and lymph node involvement should be treated with antibiotic therapy and closely followed up until the symptoms have resolved.

### Dental Biofilm-Induced Gingivitis—Gingivitis Caused by Biofilm (Bacteria)

The degree of plaque biofilm accumulation and the inflammatory condition of the gingival tissues in children are related. Horowitz et al.<sup>7</sup> observed significant improvements in the gingivitis scores of schoolchildren after the initiation of a supervised daily plaque removal program. Children in grades 5 through 8 participated in the program, and successful results were sustained during 3 school years. The mean gingivitis scores were reduced (40% among girls and 17% among boys) during the program period, whereas the children in the control group who did not receive supervised



**Fig. 15.4** (A) Clinical presentation of stage IV periodontitis. (B) Radiographic presentation of stage IV periodontitis.\* \*Note while the patient is not missing teeth, the severity of the disease puts the patient in a stage IV category.

**TABLE 15.3** Grading of Periodontitis

	Progression		Grade A: Slow Rate	Grade B: Moderate Rate	Grade C: Rapid Rate
<b>Primary criteria</b> <i>Whenever available, direct evidence should be used.</i>	Direct evidence of progression	Radiographic bone loss or clinical attachment loss	No loss over 5 years	<2 mm over 5 years	≥2 mm over 5 years
	Indirect evidence of progression	% bone loss / age Case phenotype	<0.25 Heavy biofilm deposits with low levels of destruction	0.25 to 1.0 Destruction commensurate with biofilm deposits	>1.0 Destruction exceeds expectations given biofilm deposits; specific clinical patterns suggestive of periods of rapid progression and/or early onset disease
<b>Grade modifiers</b>	Risk factors	Smoking Diabetes	Non-smoker Normoglycemic/no diagnosis of diabetes	<10 cigarettes/day HbA1c <7.0% in patients with diabetes	≥10 cigarettes/day HbA1c ≥7.0% in patients with diabetes

**Grading aims to indicate the rate of periodontitis progression, responsiveness to standard therapy, and potential impact on systemic health.**

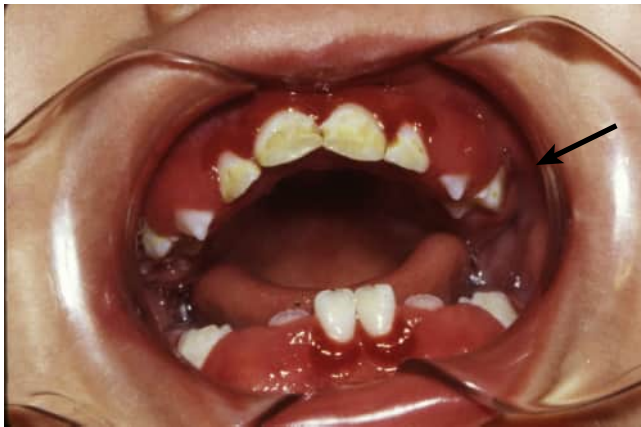Clinicians should initially assume grade B disease and seek specific evidence to shift to grade A or C.

See [perio.org/20017wwdc](http://perio.org/20017wwdc) for additional information.

The 2017 World Workshop on the Classification of Periodontal and Peri-Implant Diseases and conditions was co-presented by the American Academy of Periodontology and the European Federation of Periodontology.

daily instructions in plaque removal instructions and did not engage in daily plaque removal activities maintained essentially the same gingivitis scores throughout the study course. Adequate oral hygiene and cleanliness of the teeth are related to frequency of brushing and the thoroughness

with which bacterial plaque is removed from the teeth. Favorable occlusion (i.e., proper alignment of the teeth within the dental arch) and chewing of coarse detergent-type foods, such as raw carrots, celery, and apples, have a beneficial effect on oral cleanliness.



**Fig. 15.5** Mild inflammation (*arrow*) is evident in the tissue partially covering the crown of the erupting first permanent molar.

In a study of 2876 children residing in a naturally fluoridated area, Murray<sup>8</sup> confirmed a high prevalence of gingivitis in the young population. He observed that inflammation of one or more papillae or margins associated with the incisor and canine teeth occurred in 90% of children aged 8–18 years. He also pointed towards the importance of a good standard of oral cleanliness in reducing gingivitis and, thereby, in preventing the progression of the disease in later life.

Gingivitis associated with poor oral hygiene is usually classified as early (slight), moderate, or advanced. Early gingivitis is quickly reversible and can be treated with good oral prophylactic treatment and instruction in toothbrushing and flossing techniques to keep the teeth free of bacterial plaque (Figs. 15.6 and 15.7A and B). Gingivitis is generally less severe in children than in adults with similar plaque levels.

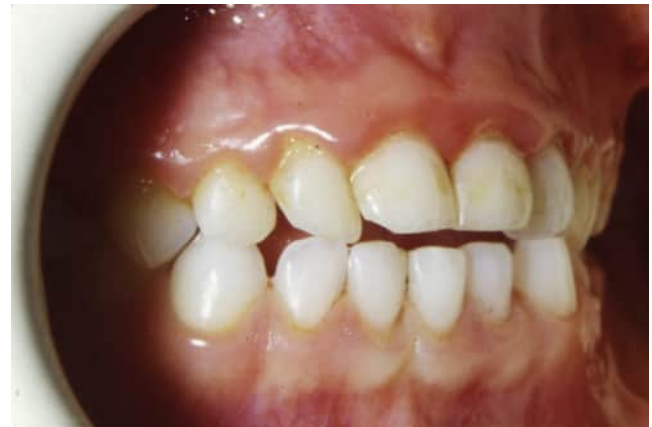## Allergy and Gingival Inflammation

Matsson and Moller<sup>9</sup> studied the degree of seasonal variation of gingival inflammation in children with allergies to birch pollen. A total of 34 children with the allergy were examined during two successive spring seasons and the one intervening fall. Age- and gender-matched controls were also examined in the fall. Gingival inflammation and the presence or absence of plaque were recorded, and a bleeding/plaque ratio was calculated for each child. The results indicated an enhanced gingival inflammatory reaction in the allergic children during the pollen seasons. Although the authors acknowledge that the significance of gingival reaction during short allergy seasons is difficult to assess, they speculate that patients with complex allergies who have symptoms for longer periods may be at higher risk for more significant adverse periodontal changes.

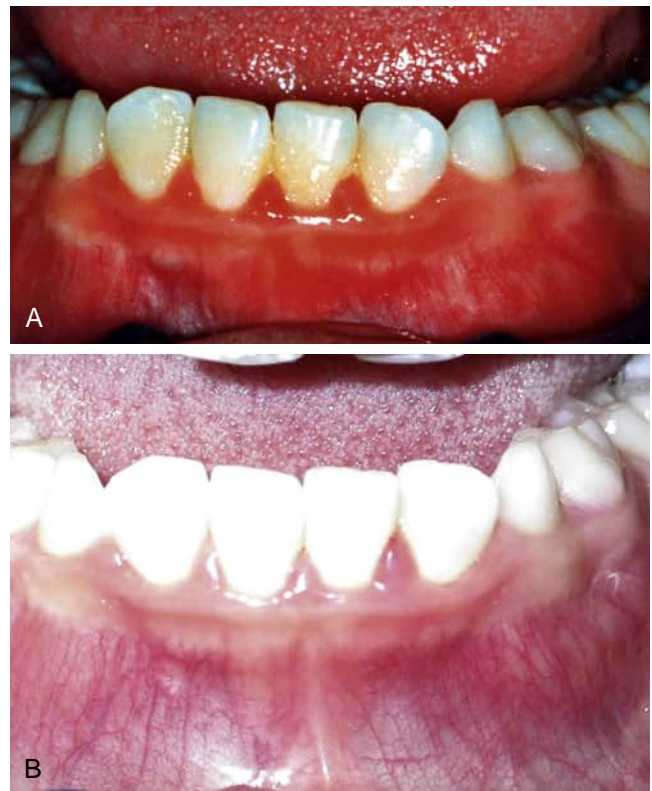## Acute Gingival Disease

### ORAL HERPES SIMPLEX VIRUS INFECTION

Oral herpes virus causes one of the most widespread viral infections. The primary infection usually occurs in a child



**Fig. 15.6** Gingivitis resulting from poor oral hygiene and reduced function in the area. A painful second primary molar has interfered with normal function on this side of the mouth.

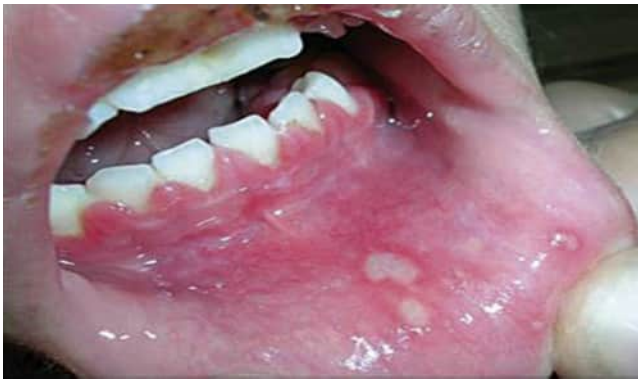

**Fig. 15.7** (A) Localized gingival inflammation and recession associated with minimal plaque accumulation on the mandibular right central incisor. (B) Gingival health was greatly improved after a thorough plaque removal regimen was initiated at home.

younger than 6 years who has had no previous exposure to the type 1 herpes simplex virus (HSV-1) and who, therefore, has no neutralizing antibodies. It is believed that 99% of all primary infections are of the subclinical type. The infection may also occur in susceptible adults who have not had a primary infection (Fig. 15.8).

In some preschool children, the primary infection may be characterized by only one or two mild sores on the oral mucous membranes, which may be of little concern to the child or may go unnoticed by the parents. In other children, the primary infection may manifest as acute symptoms



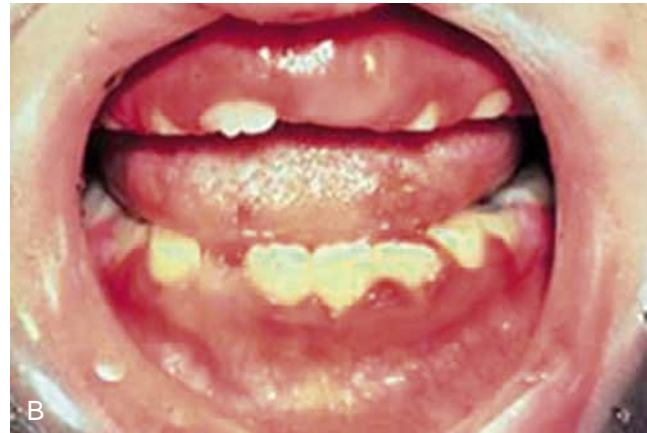
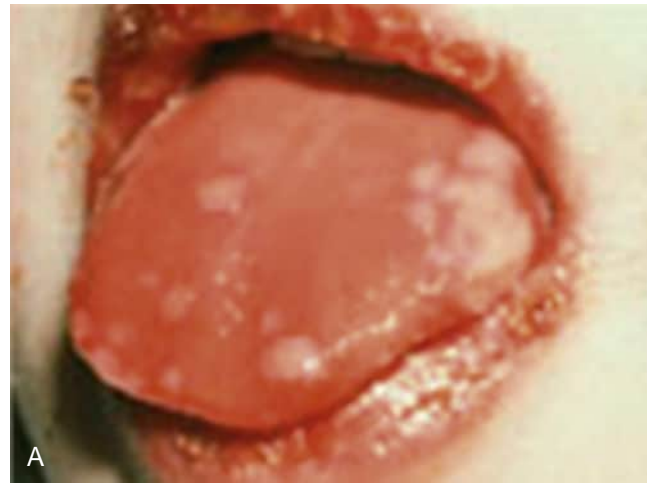
**Fig. 15.8** Ulcerated stage of primary herpes in a young adult. Notice the circumscribed confluent areas of inflammation.

(acute herpetic gingivostomatitis). The active symptoms of the acute form can occur in children with clean mouths and healthy oral tissues. The symptoms of the disease develop suddenly and include, in addition to the fiery red gingival tissues, malaise, irritability, headache, and pain associated with the intake of food and liquids of acidic content. A characteristic oral finding of HSV-1 is the appearance of yellow or white liquid-filled vesicles. In a few days, the vesicles rupture and form painful ulcers that are approximately 1–3 mm in diameter and covered with a whitish gray membrane with a circumscribed area of inflammation (Fig. 15.9A and B). The ulcers may be observed on any area of the mucous membrane, including the buccal mucosa, tongue, lips, hard and soft palate, and tonsillar areas. Large ulcerated lesions may occasionally be observed on the palate or gingival tissues or in the region of the mucobuccal fold. This distribution makes the differential diagnosis more difficult. An additional diagnostic criterion is a four-fold rise of serum antibodies to HSV-1. The lesion culture also shows positive results for HSV-1.

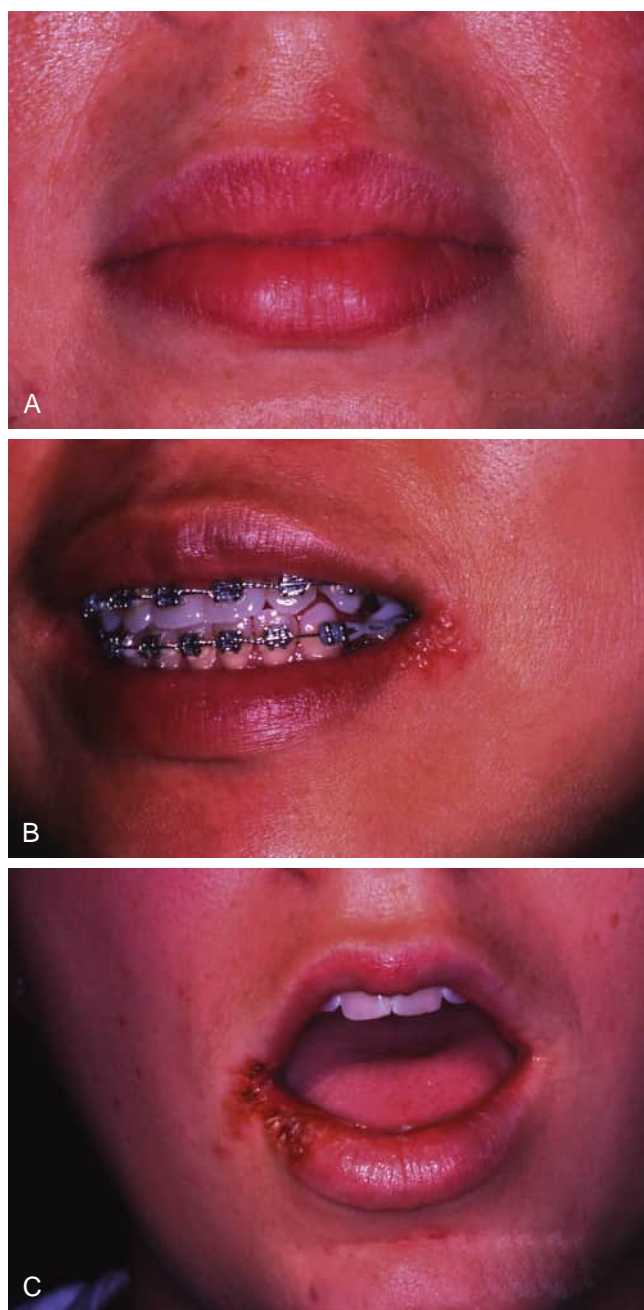
Treatment of acute herpetic gingivostomatitis in children, which runs a course of 10–14 days, should include specific antiviral medication and provision for the relief of the acute symptoms so that fluid and nutritional intake can be maintained. The application of a mild topical anesthetic, such as dyclonine hydrochloride (0.5%; Dyclone), before mealtime temporarily relieves the pain and allows the child to eat soft food. Another topical anesthetic, lidocaine (Xylocaine Viscous), can be prescribed for the child who can hold 1 teaspoon of the anesthetic in the mouth for 2–3 minutes and then expectorate the solution. As an alternative to topical anesthesia, Schaaf<sup>10</sup> recommends a mixture of equal parts of diphenhydramine (Benadryl) elixir and bismuth subsalicylate (Kaopectate). This palliative mixture can be compounded by the pharmacist or mixed by the parent. Diphenhydramine has mild analgesic and antiinflammatory properties, whereas the kaolin-pectin compound coats the lesions. Fruit juices may need to be avoided since the acidity of the juice can irritate the ulcerated area and lead to pain and discomfort. Therefore, the child (and the caregiver) should be advised to take daily vitamin supplements to maintain a nutritional balance until the lesions have resolved.

Although the treatments described may be useful, they are only palliative. The mainstay of definitive therapy is



**Fig. 15.9** (A) Acute herpetic gingivostomatitis on the tongue in a child. (B) Fiery red gingival tissues are characteristic findings.

regular doses of specific systemic antiviral medication combined with systemic analgesics (acetaminophen or ibuprofen) during the course of the disease. The antiviral medications currently available are acyclovir, famciclovir, and valacyclovir. These medications inhibit viral replication in host cells infected with the virus. Acyclovir (Zovirax; GlaxoSmithKline, Inc., Research Triangle Park, NC, USA) should be administered in five daily doses to equal 1000 mg/day for 10 days. Acyclovir is available in capsules or suspension. Acyclovir therapy has been successfully used in infants and children.<sup>11</sup> Famciclovir (Famvir; Novartis Pharmaceuticals Corporation, East Hanover, NJ, USA) and valacyclovir (Valtrex; GlaxoSmithKline, Inc.) are newer and possibly more effective antiviral agents, but their use in pediatric populations has not yet been studied. The Food and Drug Administration (FDA)-approved treatment for recurrent herpes simplex labialis (RHL) in children aged 12 years and older is valacyclovir 2 g initially, and 2 g 12 hours later. Famciclovir (a single 1500-mg dose) with prodrome (at the earliest sign of the lesions) is an FDA-approved treatment for herpes simplex labialis in adults, but its safety and effectiveness in adolescents and children have not yet been established. Bed rest and isolation from other children in the family are also recommended. Hale et al.<sup>12</sup> reported an outbreak of herpes simplex infection in a group of 13 children occupying one floor of an orphanage. The children were in the age range of 11–35 months. In three of the children, a



**Fig. 15.10** Recurrent herpes simplex labialis. (A) Early vesicular lesions. (B) Mature vesicular lesion. (C) Appearance of herpes labialis after the rupture of vesicles and crusting of the lesion. (Courtesy of Dr. Susan L. Zunt.)

mild fever of brief duration and small oral lesions were the only signs of infection; these signs and symptoms might easily have been overlooked in a situation different from that of an institutional study. The remaining children had symptoms of acute infection.

After the initial primary attack during early childhood, the herpes simplex virus becomes inactive and resides in sensory nerve ganglia. The virus often reappears later as the familiar cold sore or fever blister, usually on the outside of the lips (Fig. 15.10A–C). Thus the disease has been commonly referred to as *recurrent herpes labialis* (RHL). However, approximately 5% of recurrences are intraoral.

With the recurring attacks, the sores develop in essentially the same area. Kleinman et al.<sup>13</sup> published the results of a national survey of 39,206 schoolchildren aged 5–17 years. A history of RHL was reported by 33% of the children.

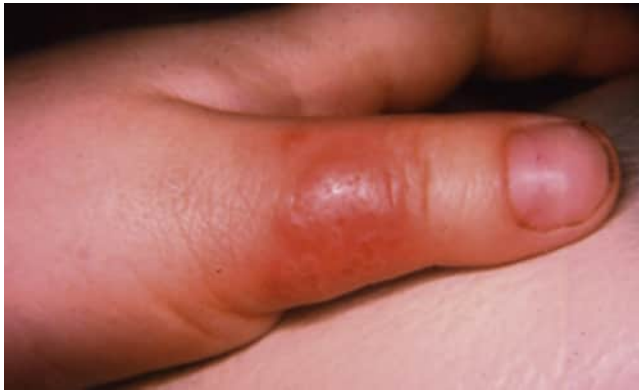The recurrence of the disease has often been related to conditions of emotional stress and lowered tissue resistance resulting from various types of trauma. Excessive exposure to sunlight may also be responsible for the appearance of the recurrent herpetic lesions on the lip. Use of sunscreen can prevent sun-induced recurrences. Lesions on the lip may appear after dental treatment and may be related to irritation from the rubber dam material or even routine daily oral hygiene procedures.

The most effective treatment for these recurrences is the use of the specific systemic antiviral medications already discussed in connection with the treatment of the primary herpetic infection (acyclovir, famciclovir, and valacyclovir). The medication should be taken immediately after the prodromal symptom of recurrence. The daily dosages are the same as those for the primary infection, but the course of treatment is usually 5 days instead of 10. The 1-day therapy for RHL is a total of 4 g valacyclovir divided in two doses: 2 g initially with the prodrome, followed by another 2 g 12 hours later. This regimen has been approved for children aged 12 years and older. Another topical antiviral agent, penciclovir cream (Denavar; Novartis Consumer Health, Inc., Parsippany, NJ, USA), may be applied to perioral lesions but should not be applied to intraoral lesions. The penciclovir cream and systemic antivirals should not be prescribed for concurrent use. The penciclovir cream can be applied for 4 days, every 2 hours while the patient is awake, and it is approved for use in children aged 12 years and older. Topical 5% acyclovir cream may be prescribed for use five times daily for 4 days in children aged 12 years and older.

In addition to the systemic antivirals, an over-the-counter topical antiviral agent, known as docosanol (Abreva), is available for the treatment and management of herpes labialis. Unlike the systemic antivirals reviewed above, docosanol does not affect viral replication. Instead, it inhibits the fusion of the HSV-1 viral envelope to the host cell membrane, thereby blocking viral entry into the cell. However, it should be noted that docosanol is not indicated for intraoral herpetic lesions, and its safety and effectiveness on children younger than 12 years of age have not yet been established.

Other remedies for herpes simplex infection include the amino acid lysine. The oral therapy is based on lysine's antagonistic effect on another amino acid, arginine. Griffith et al.<sup>14</sup> conducted an initial study in which 250 patients were given daily lysine doses of 1000 mg and were instructed to avoid eating arginine-rich foods, such as chocolate and nuts. The lysine therapy was continued until the patients had been lesion-free for 6 months. L-Lysine monohydrochloride is available commercially in capsule form or in tablets containing 100 or 312 mg of L-lysine (General Nutrition Corp., Pittsburgh, PA, USA). The patients reported that pain disappeared overnight in virtually every instance. New vesicles failed to appear, and a majority considered the resolution of the lesions to be more rapid than in the past. There was also a reduction in the frequency of occurrences in some patients. Griffith et al.<sup>14</sup> concluded that improper food selection may make adequate lysine





**Fig. 15.11** Primary herpetic infection involving the dorsal surface of the thumb of a 3-year-old child. An acute primary infection was present in the mouth.

intake precarious for some persons. Ingestion of cereals, seeds, nuts, and chocolate would produce a high arginine/lysine ratio and favor the development of herpetic lesions. Similar results are obtained when arginine is added to the medium in the laboratory to induce herpes proliferation. The avoidance of these foods, coupled with the selection of foods with adequate lysine, such as dairy products and yeast, should discourage herpes infection. These authors postulate that this may explain the low incidence of herpes in infants before they are weaned from a predominantly milk diet. Prophylactic lysine is apparently useful in managing selected cases of RHL if serum lysine is maintained at adequate concentrations.

Brooks et al.<sup>15</sup> have reported that dentists are frequently exposed to HSV-1. They evaluated the risk of infection with the virus by assessing disease experience, comparing the individual's history with the results of a complement fixation or antibody titration test, or both. Their study group consisted of 525 dental students, 94 dental faculty members, and 23 staff members. Although almost all of those with a history of herpetic infection showed antibodies to HSV-1, only 57% of those lacking such a history had neutralizing antibody titers of 1:10 or higher. This finding suggests that a considerable number of practicing dentists risk primary herpetic infection. Consequently, dentists and dental auxiliaries without a history of herpetic lesions might benefit from serologic testing. Considering the occupational disability that often accompanies HSV-1 infection of the finger or eye, effective barrier protection for health professionals is important.

Primary herpetic infection has been observed on the dorsal surface of the thumb of a pediatric patient (Fig. 15.11). The child was a thumb sucker, and the acute primary infection was present in the mouth. The dorsal surface of the thumb, which rested on the mandibular incisor teeth, apparently became irritated, and an inoculation of the virus took place. The oral condition and the lesions on the thumb, known as herpetic whitlow, subsided in 2 weeks. Herpetic whitlow illustrates the highly contagious nature of this disease and is an example of how the virus can be transmitted elsewhere on the body. Moreover, since the virus can spread through oral secretions, there is always the possibility that a pediatric patient with HSV-1 can spread the virus to other children or family members just by committing simple daily

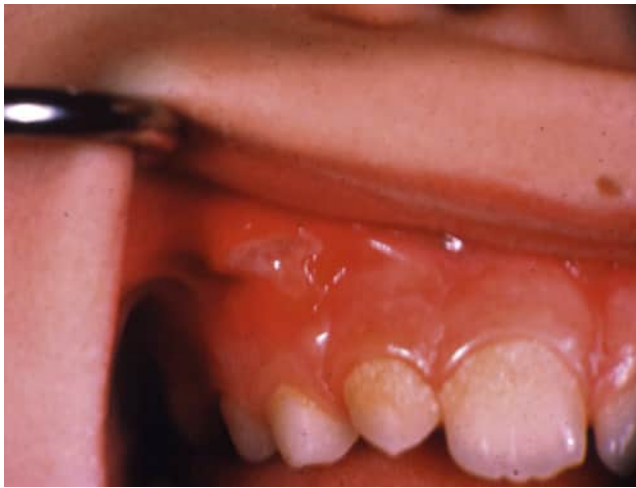acts, such as kissing loved ones or sharing utensils. Therefore, every effort should be made to minimize the spread of this disease by preventing the child from scratching or picking at the HSV-1 vesicle and stopping the sharing of toys or utensils. Caregivers must also ensure that the child with HSV-1 washes his/her hands and avoid contact with infants less than 6 months of age whose immune systems are not yet fully developed and immunocompromised individuals.

### RECURRENT APHTHOUS ULCER (CANKER SORE)

The recurrent aphthous ulcer (RAU)—also referred to as recurrent aphthous stomatitis (RAS) or canker sore—is a painful ulceration on the unattached mucous membrane that occurs in school-aged children and adults. The peak age for RAU is between 10 and 19 years. It is reportedly the most common mucosal disorder in people of all ages and races in the world. According to definitions adopted in the epidemiologic literature, this disease is characterized by recurrent ulcerations on the moist mucous membranes of the mouth, in which both discrete and confluent lesions form rapidly in certain sites and feature a round to oval crateriform base with raised, circumscribed, erythematous margins and pain. They may appear as attacks of minor or single, major or multiple, or herpetiform lesions. They may or may not be associated with ulcerative lesions elsewhere.<sup>16</sup> In the national survey reported by Kleinman et al.,<sup>13</sup> a history of RAU was reported by 37% of the schoolchildren occurring approximately three times more often in white children than in African-American schoolchildren. Ship et al.<sup>17</sup> reported the prevalence estimates of RAU to range between 2% and 50%, with most estimates between 5% and 25% (among medical and dental students, estimated prevalence is between 50% and 60%). Lesions persist for 4–12 days and heal uneventfully, leaving scars only rarely and only in cases of unusually large lesions. The description of RAU frequently includes the term *canker sores* (Fig. 15.12). The major form (RAS) is less common and has been referred to as *periaadenitis mucosa necrotica recurrens* and *Sutton disease*. RAS has been associated with other systemic diseases: PFAPA (periodic fever, aphthous stomatitis, pharyngitis, adenitis), Behçet disease, Crohn's disease, ulcerative colitis, celiac disease, neutropenia, immunodeficiency syndromes, Reiter's syndrome, systemic lupus erythematosus, and MAGIC (mouth and genital ulcers with inflamed cartilage) syndrome.

The cause of RAU is unknown. Local and systemic conditions along with a genetic predisposition and immunologic and infectious microbial factors have been identified as potential causes. The condition may also be caused by a delayed hypersensitivity to the L form of *Streptococcus sanguis*, which is a common constituent of the normal oral microbiota of humans. It is also possible that the lesions are caused by an autoimmune reaction of the oral epithelium. Epidemiologic studies by Ship et al.<sup>17</sup> lends credence to this hypothesis. Analysis of the available data indicates that both RHL and RAU may be produced by the same mechanism despite the known infectious nature of RHL and the absence of any known virus associated with the onset of RAU. Additionally, Scully and Porter<sup>16</sup> reported that there may be a genetic predisposition to an individual's increased susceptibility to this condition, as evidenced by strong





**Fig. 15.12** Evidence of the development of a recurrent aphthous ulcer in the mucobuccal fold above the primary canine. An area of inflammation and vesicle formation is apparent (arrow).

associations with interleukin genotypes and sometimes a family history.

Local factors include trauma, allergy to toothpaste constituents (sodium lauryl sulfate), and salivary gland dysfunction. In a review of the etiology and pathogenesis of RAU, Antoon and Miller<sup>18</sup> implicated minor oral trauma as the main precipitating factor, accounting for as many as 75% of the episodes. Nutritional deficiencies in iron, vitamin B<sub>12</sub>, and folic acid are found in 20% of individuals with aphthous ulcers. Stress may prove to be an important precipitating factor, particularly in stress-prone groups such as students in professional schools and military personnel.

According to Greenspan et al.,<sup>19</sup> either nonspecific factors (trauma, food allergy) or specific factors (bacterial or viral infection) may trigger a temporary imbalance in various cell subpopulations. This imbalance could then upset immune regulation and result in local destruction of the oral epithelium and tissue ulceration. Ship et al.<sup>17</sup> also suggested herpes simplex virus, human herpesvirus type 6, cytomegalovirus, Epstein-Barr virus, and varicella-zoster virus as causative agents of RAS.<sup>17</sup> Current treatment is focused on promoting ulcer healing, reducing ulcer duration and patient pain, maintaining the patient's nutritional intake, and preventing or reducing the frequency of disease recurrence.

Numerous treatments have been recommended for RAU, but a cure has not been found. Topical antiinflammatory and analgesic medicines and/or systemic immunomodulatory and immunosuppressive agents have been used for RAU. The first line of treatment included antiinflammatory topical gels, creams, and ointments. Currently, a topical corticosteroid (e.g., 0.5% fluocinonide, 0.025% triamcinolone, or 0.5% clobetasol) is applied to the area with a mucosal adherent (e.g., isobutyl cyanoacrylate, Orabase). For example, the application of triamcinolone acetonide (Kenalog in Orabase) to the surfaces of the lesions before meals and before sleeping may also be helpful. Binnie et al.<sup>20</sup> reported that an antiinflammatory and antiallergic medication in the form of a topical paste is effective in reducing pain and accelerating healing of RAU ulcers. The active ingredient in the paste is 5% amlexanox (Aphthasol; Access Pharmaceuticals, Dallas, TX, USA). The

paste is applied to the ulcer four times daily, after meals and at bedtime, until the ulcer heals. Zilactin (Zila Pharmaceuticals, Phoenix, AZ, USA), a topical paste with hydroxypropyl cellulose film, has also been used to adhere to the mucosa and cover the ulcer while providing pain relief for an extended period of time. Occlusive topical 2-otylcyanoacrylate adheres for 6 hours. Aloe vera freeze-dried gel extract adheres and forms an occlusive protective patch. In severe cases, oral prednisone has been prescribed.

Topical rinses have also been helpful for the relief of RAU. Sucralfate has proved to be useful by its property of coating the affected area. The topical application of tetracycline to the ulcers is often helpful in reducing the pain and in shortening the course of the disease. A mouthwash containing suspension of one of the tetracyclines has been helpful to some, but the mouthwash should not be swallowed. Chlorhexidine (CH) mouthwash has also been known to alleviate the symptoms of RAU. Dexamethasone elixir, when swished, is useful to treat ulcerations in areas of the mouth that are difficult to access. Meiller et al.<sup>21</sup> have reported that the duration and severity of RAU lesions can be markedly reduced by vigorous twice-daily rinsing with an antimicrobial mouthwash (Listerine Antiseptic; Pfizer Warner Lambert Division, Morris Plains, NJ, USA).

## NECROTIZING GINGIVITIS

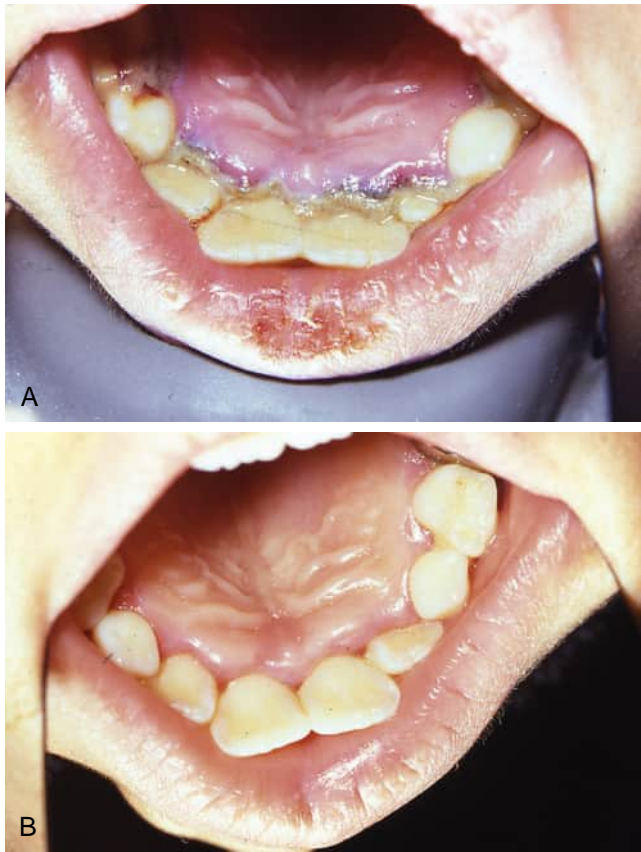The 2017 AAP/EFP World Workshop on the Classification of Periodontal and Peri-implant Diseases and Conditions removed the word “ulcerative” from the name of this disease because tissue ulceration is secondary to the necrosis that takes place in necrotizing periodontal disease.

Among adults and children, necrotizing gingivitis (NG) is a rare, infectious, acute, necrotizing form of periodontal disease. The condition may affect children aged 6–12 years, and may be seen in young adults who are either immunocompromised, experience long durations of chronic psychological stress, or suffer from severe bouts of malnutrition. NG differs from the more severe necrotizing periodontitis (NP) in that NG only affects the gingival tissues, whereas NP affects both the gingival tissue and the underlying hard tissue.

The clinical hallmarks of NG is tissue necrosis of the interproximal papillae, spontaneous gingival bleeding, and the presence of a pseudomembranous necrotic covering of the marginal tissue (Fig. 15.13). Other clinical signs and symptoms of the disease include poor appetite, temperature as high as 40°C (104°F), general malaise, regional lymph nodes, a fetid mouth odor, and sialorrhea in children. Microbially, *Prevotella intermedia*, *Fusobacterium*, *Treponema*, and *Selenomonas* species are several predominant microorganisms that have been found in the microflora of NG lesions.

The disease typically responds dramatically within the initial 24 to 48 hours following supragingival and subgingival debridement and the use of mild oxidizing solutions. If the gingival tissues are acutely and extensively inflamed when the patient is first seen, gentle supragingival debridement and antibiotic therapy is indicated. Improved oral hygiene, use of mild oxidizing mouthrinses after each meal, and twice-daily rinsing with CH may help in resolving the NG-associated symptoms.

There should be no difficulty in distinguishing NG from acute herpetic gingivostomatitis although the two are sometimes

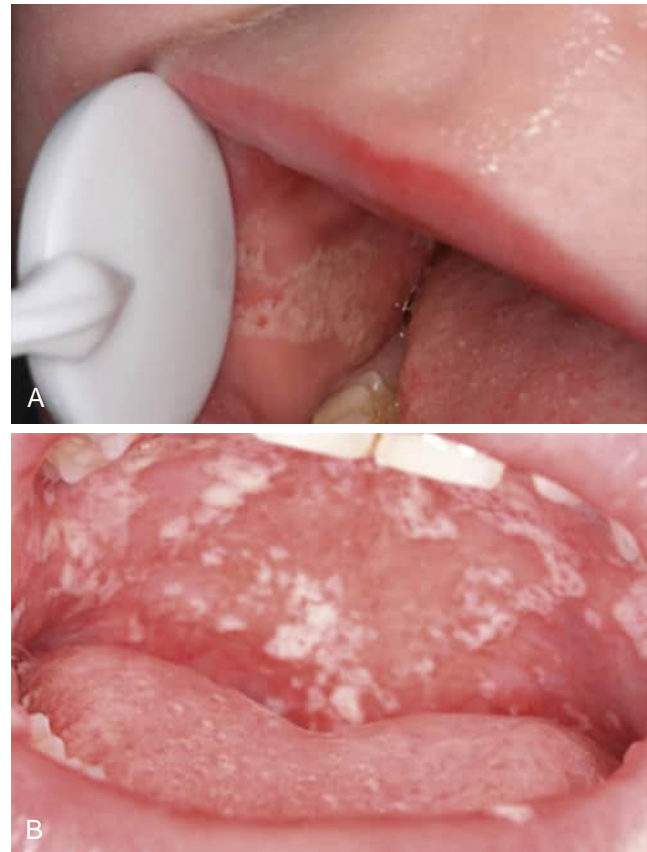


**Fig. 15.13** (A) A rare example of necrotizing ulcerative gingivitis in an 8-year-old boy. (B) Local treatment and improved oral hygiene resulted in a dramatic recovery from the infection.

confused. Round ulcers with red areolae on the lips and cheeks are characteristic of herpetic gingivostomatitis. Therapeutic debridement leads to a favorable response in cases of NG but not in acute herpetic gingivostomatitis. A therapeutic trial of antibiotics reduces the acute symptoms in NG, but not in the viral infection associated with herpetic gingivostomatitis. Acute herpetic gingivostomatitis is most frequently seen in preschool children and its onset is rapid, whereas NG rarely occurs in preschool children. When present, it develops over a longer period, usually in a mouth in which plaque and poor oral hygiene are present. On the other hand, acute oral infections, initially diagnosed as NG, have frequently been found later to be an oral manifestation of one of the xanthomatoses. The early stages of conditions such as Hand-Schüller-Christian disease and Langerhans cell histiocytosis are associated with many of the symptoms of NG.

### ACUTE CANDIDIASIS (THRUSH, CANDIDOSIS, MONILIASIS)

*Candida (Monilia) albicans* is a common inhabitant of the oral cavity but may multiply rapidly and cause a pathogenic state when host resistance is lowered. Young children sometimes develop thrush after long-term oral steroid use or antibiotic therapy, which allows the fungi to proliferate in the oral cavity. The lesions of oral candidiasis appear as raised, furry white patches, which can be removed easily to produce a bleeding underlying surface (Fig. 15.14 A and B). Neonatal candidiasis, contracted during passage through



**Fig. 15.14** (A) The characteristic appearance of acute candidiasis on the upper and lower lips of a young patient. (B) The hard and soft palates were also severely affected. The infection was controlled with a 7-day regimen of nystatin.

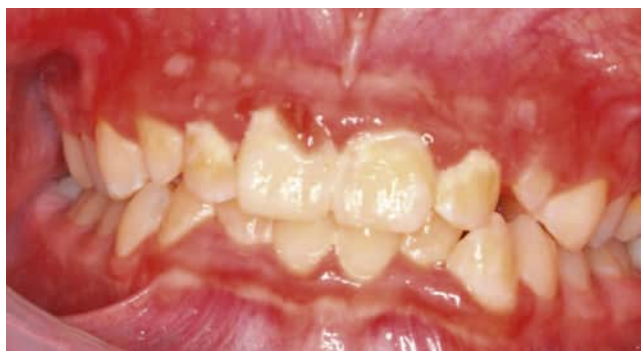the vagina and erupting clinically during the first 2 weeks of life, is a common occurrence. This infection is also common in immunosuppressed patients (see Chapter 27).

Antifungal antibiotics control thrush. For infants and very young children, a suspension of 1 mL (100,000 units) of nystatin (Mycostatin) may be dropped into the mouth for local action four times a day. Nystatin is nonirritating and non-toxic. Clotrimazole suspension (10 mg/mL), 1–2 mL applied to affected areas four times daily, is an effective antifungal medication. Systemic fluconazole suspension (10 mg/mL) is safe to use in infants at a total dosage of up to 6 mg/kg/day. For children old enough to manage solid medications allowed to dissolve in the mouth, clotrimazole troches or nystatin pastilles are recommended because the therapeutic agent remains in the saliva longer than with the liquid medication. For children old enough to swallow, systemic fluconazole (100-mg tablets) in a 14-day course may be prescribed when the infection has not responded to topical antifungal agents.

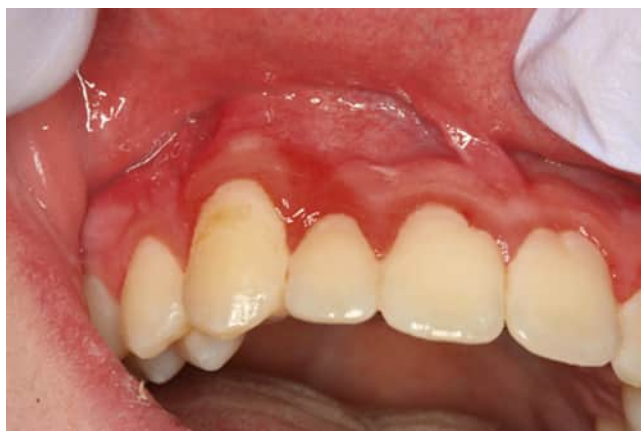### ACUTE BACTERIAL INFECTIONS

The prevalence of acute bacterial infection in the oral cavity is unknown. Acute streptococcal gingivitis is an example of this atypical type of infection. It is characterized by enlarged papilla, gingival abscesses, and painful, erythematous gingiva that bleed easily. Cultures show a predominance of hemolytic streptococci. Acute infections of this type may be more common than was previously realized.





**Fig. 15.15** Chronic nonspecific gingivitis. The cause of this type of gingivitis is complex, and it often persists for prolonged periods without significant improvement.



**Fig. 15.16** Fiery red gingival lesions essentially limited to the anterior labial tissues. Only minimum local deposits were evident. The gingivitis was classified as the chronic nonspecific type.

However, diagnosis is difficult without extensive laboratory tests. Broad-spectrum antibiotics are recommended if the infection is believed to be bacterial in origin. Improved oral hygiene is important in treating the infection. As with any acute microbial oral infection, CH mouthrinses are also appropriate.

## Chronic Nonspecific Gingivitis

A type of gingivitis commonly seen during the pre-teenage and teenage years is often referred to as *chronic nonspecific gingivitis*. The chronic gingival inflammation may be localized to the anterior region or may be more generalized. Although the condition is rarely painful, it may persist for long periods without much improvement (Fig. 15.15).

Glaser et al.<sup>22</sup> observed an unusual gingivitis in Navajo Indians between 12 and 18 years of age, similar to that seen in Fig. 15.16, in which the fiery red gingival lesion was not accompanied by enlarged interdental labial papillae or closely associated with local irritants. The gingivitis showed little improvement after a prophylactic treatment. The age of the patients involved and the prevalence of the disease in girls suggested a hormonal imbalance as a possible factor. Histologic examination of tissue sections and the use of special stains ruled out a bacterial infection. Inadequate oral hygiene, which allows for food impaction and the accumulation of

materia alba and bacterial plaque, is undoubtedly the major cause of this chronic type of gingivitis.

The cause of chronic gingivitis is complex and is considered to be based on a multitude of local and systemic factors. Because dietary inadequacies are often found in the pre-teenage and teenage groups, a 7-day diet survey can be an important diagnostic aid. Insufficient quantities of fruits and vegetables in the diet, leading to a subclinical vitamin deficiency, may be an important predisposing factor. An improved dietary intake of vitamins and the use of multivitamin supplements can improve the gingival condition in many children.

Malocclusion, which interferes with adequate function, and crowded teeth, which hinders proper oral hygiene and plaque removal, are also important predisposing factors in gingivitis. Caries lesions, with irritating sharp margins and faulty restorations with overhanging margins (both of which cause food accumulation), also favor the development of the chronic type of gingivitis. Therefore the placement of dental restorations to restore the adequate function and contour of defective teeth after the reduction of acute symptoms is an equally important treatment consideration.

A wide variety of local irritants can produce a hyperplastic type of gingivitis in children and young adults. The irritation to the gingival tissue produced by mouth breathing is often responsible for the development of the chronic hyperplastic form of gingivitis, particularly in the maxillary arch. All these factors should be considered contributory to chronic nonspecific gingivitis and should be corrected in the treatment of the condition. The importance of thorough daily oral hygiene must be emphasized repeatedly to the patients.

## Chlorhexidine as a Therapeutic Plaque Control Agent

Chlorhexidine (CH) is a cationic bisbiguanide with broad antimicrobial activity that acts by rupturing bacterial cell membranes. It is commonly used as an antiseptic skin and wound cleanser for presurgical preparation of the patient and as a handwash and surgical scrub for health care personnel. It is also added as a preservative to ophthalmic products and used internally in very dilute concentrations in the peritoneal cavity and urinary bladder. In addition to its broad antimicrobial activity, CH exhibits a unique property known as substantivity, which allows the agent to bind to negatively charged proteins on the mucosal surface and to the negatively charged bacterial cell wall. From there, the agent is slowly released, thereby producing a sustained antimicrobial activity against a wide range of microorganisms that include gram-positive bacteria, gram-negative bacteria, and fungi. The substantivity property makes CH the gold standard of all mouthrinses.

In dentistry, CH has been used to control smooth surface caries, disinfect dentures, and inhibit plaque accumulation in the oral cavity. Its use in controlling dental plaque accumulations has received the most attention in dental research. Numerous studies have demonstrated that CH reduces plaque by 50%–55% and gingivitis by up to 45%.<sup>23,24</sup> Mouthrinses containing CH have been popular as therapeutic agents in several countries for some time, and in 1986 CH was approved for use in the United States. Two products under the trade names Peridex (Colgate-Palmolive Co.) and PerioGard (Zila Pharmaceuticals) have received



FDA approval as prescription agents. These mouthrinses contain 0.12% CH gluconate as the active ingredient. Outside of the United States, CH is offered as a 0.2% solution. However, in a double-blinded, randomized, crossover study comparing the two different concentrations' antimicrobial effects and clinical efficacies in reducing de novo plaque formation, Quirynen et al.<sup>25</sup> did not find any statistically significant differences between the two.

The widespread use of CH mouthrinses over many years, especially in Europe, has benefited from an excellent safety record. Few adverse side effects have been reported with CH mouthrinses, but their use has been linked to mouth dryness and burning sensations in some persons due to the alcohol base. An alcohol-free CH product is marketed under the trade name Gum Paroex (Sunstar Americas, Inc., Chicago, IL, USA). Generalized staining over long-term use and taste alterations have been reported. Poorly defined desquamative lesions have been observed after the mouthrinse was used. Allergic reactions to CH are rare. If the rinse is inadvertently swallowed, it has essentially little systemic effect due to poor absorption in the gastrointestinal system.

Löe and Schiött<sup>26</sup> reported significant inhibition of plaque formation and the prevention of gingivitis with the use of an aqueous solution of 0.2% CH digluconate as a mouthrinse twice daily with swishing for 1 minute. Yankell et al.<sup>27</sup> showed that dental stain from CH mouthrinse can be considerably reduced with the regular use of a tartar control dentifrice.

It is important to recognize that the beneficial use of CH as a therapeutic mouthrinse should be considered adjunctive to the practice of sound conventional plaque control measures as presented in [Chapter 8](#) and elsewhere in this text. In other words, CH should not be used as a stand-alone therapy in controlling plaque levels; rather it should be used to supplement, not supplant, conventional manual plaque control measures. In a study investigating the efficacy of Listerine, Meridol, and CH mouthrinses, Brex et al.<sup>28</sup> found CH to be the most effective to supplement habitual mechanical oral hygiene. They also found that a combination of habitual self-performed and nonsupervised oral hygiene with Listerine or Meridol is more beneficial for plaque control than the use of mechanical oral hygiene alone. Moreover, the adjunctive use of CH may be beneficial in cases where attaining adequate plaque control is more difficult, such as individuals with limited manual dexterity or individuals suffering from a debilitating illness or convalescence following serious injuries.

The rationale for including the use of a daily antimicrobial mouthrinse to the child's and adolescent's oral hygiene regimens when inadequate plaque control exists is widely accepted.<sup>29</sup>

## Gingival Diseases Modified by Systemic Factors

### GINGIVAL DISEASES ASSOCIATED WITH THE ENDOCRINE SYSTEM

The pathogenesis of several types of gingival diseases can be modified by several endocrine-related conditions. One of these gingival diseases is puberty gingivitis which is a distinctive subtype of gingivitis that commonly affects children in the prepubertal and circumpubertal periods.

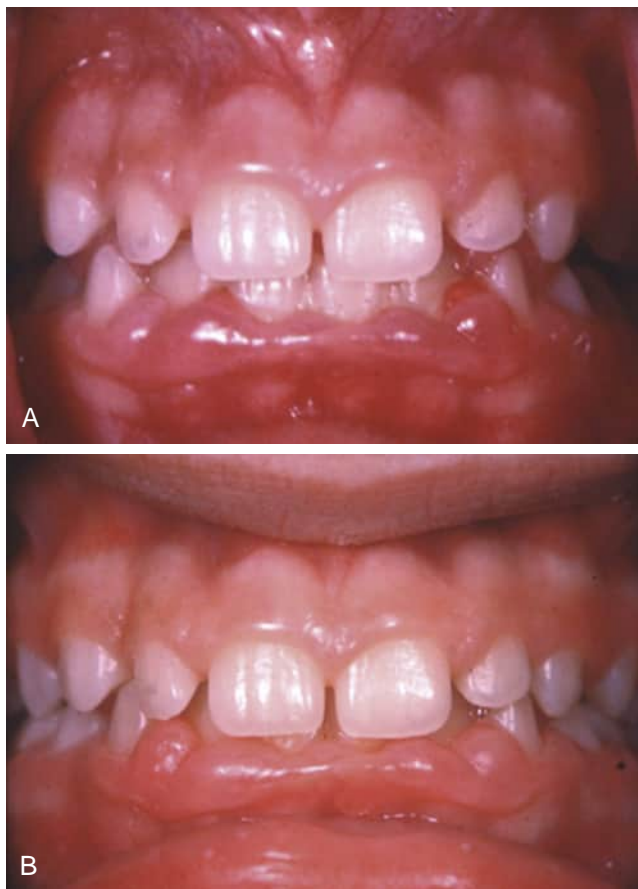Like the adult form of gingivitis, the primary etiologic factor of puberty gingivitis is dental plaque. Moreover, like the adult form, the inflammation caused by puberty gingivitis stays confined to the marginal gingiva without affecting the attachment levels and underlying crestal bone levels. However, unlike the adult form, hormonal fluctuations that occur throughout childhood can exaggerate the degree and severity of inflammation. In a study of 270 boys and girls in the aged range 11–14 years, Cohen<sup>30</sup> observed that gingival enlargement in the anterior segment occurred with regularity in the prepubertal and premenarcheal period, as well as in pubescence. The gingival enlargement was marginal in distribution and, in the presence of local irritants, was characterized by prominent bulbous interproximal papillae far greater than gingival enlargements associated with local factors. Nakagawa et al.<sup>31</sup> found a statistically significant increase in gingival inflammation, sex hormones, and the occurrence of *Prevotella intermedia* in adolescents during puberty.

In a 6-year longitudinal study conducted to assess the changes in gingivitis which occur as pubertal children develop and mature, Sutcliffe<sup>32</sup> examined a group of children beginning at age 11, and re-examined them annually until 17 years of age. At baseline, 89% of 11-year-olds and 92% of 12-year-olds exhibited signs consistent with gingivitis (as defined by the presence of redness or swelling). However, by 17 years of age, the prevalence of gingivitis among the children declined to 69%. This finding indicates that the initially high prevalence of gingivitis seen when the patients were younger tended to decline with age as fluctuations in hormonal levels subsided.<sup>32</sup> Furthermore, although the prevalence of gingivitis tended to decrease with age in both genders, girls tended to reach their maximum puberty gingivitis experience earlier than boys. The above findings are consistent with the view that the tendency for gingivitis in children was closely linked to puberty as girls physiologically enter puberty at an earlier age than boys.

The enlargement of the gingival tissues in puberty gingivitis is confined to the anterior segment and may be present in only one arch. The lingual gingival tissue generally remains unaffected ([Fig. 15.17A and B](#)). Treatment of puberty gingivitis should be directed toward improved oral hygiene, removal of all local irritants, restoration of carious teeth, and dietary changes necessary to ensure an adequate nutritional status. Cohen<sup>30</sup> observed a marked improvement in gingival inflammation and enlargement after the oral administration of 500 mg of ascorbic acid. However, the improvement did not occur until the vitamin had been taken for approximately 4 weeks.

A second endocrine condition that not only influences the onset and progression of gingival inflammation but also is a rising public health concern, especially among children and adolescents of minority racial and ethnic groups, is diabetes. In a study published in the *New England Journal of Medicine*, the incidence of type I and type II diabetes mellitus among youths increased significantly during the 2002–2012 period. If this trend continues, medical and dental health care practitioners will not only see substantially increased numbers of youth with diabetes but also an alarming prevalence of youth with diabetes who are more susceptible to periodontal disease.

Studies have demonstrated that patients with diabetes tend to develop a more exaggerated inflammatory response



**Fig. 15.17** (A) Puberty gingivitis. The enlargement of the gingival tissues was limited to the mandibular anterior region. (B) Local treatment resulted in only a slight improvement of the condition. A persistence of the hyperplastic enlargement would indicate the need for gingivoplasty.

to dental plaque than do those without diabetes. In a cross-sectional investigation comparing the gingival health of 85 adolescents with type I diabetes mellitus (previously known as insulin-dependent diabetes) and 38 healthy controls, De Pommereau et al.<sup>33</sup> found that adolescents with type I diabetes mellitus suffered significantly more gingival inflammation than healthy controls despite having similar plaque scores. A definitive reason for this finding could not be reached; however, the investigators recommended close periodontal monitoring of children and adolescents with type I diabetes mellitus.<sup>33</sup> In another study, Karjalainen and Knuuttila<sup>33a</sup> discovered that children with poorly controlled type I diabetes (HbA1c > 13%) exhibited significantly higher bleeding scores than those who were systemically healthy or had lower blood glucose levels, irrespective of differences or changes in the dental plaque status when examined twice at 3-month intervals. An increase in gingival bleeding observed in hyperglycemic patients supports the concept that an imbalance in glucose metabolism predisposes an individual to gingival inflammation which, in turn, lowers host resistance to plaque.

### GINGIVAL LESIONS OF GENETIC ORIGIN

Hereditary gingival fibromatosis (HGF) is a slowly progressive, benign enlargement of the gingiva. Clinically, the

gingiva of a patient with HGF has a normal healthy color, firm consistency, nonhemorrhagic, and is asymptomatic with an equal gender predilection. HGF, which is an autosomal dominant genetic disorder, is the most common genetic form of gingival enlargement. This rare type of gingivitis has been referred to as *elephantiasis gingivae* or *hereditary hyperplasia* of the gums. The gingival tissues appear normal at birth but begin to enlarge with the eruption of the primary teeth. Although mild cases are observed, the gingival tissues usually continue to enlarge with eruption of the permanent teeth until the tissues essentially cover the clinical crowns of the teeth (Fig. 15.18A and B). The dense fibrous tissue often causes displacement of the teeth and malocclusion. The condition is not painful until the tissue enlarges to the extent that it partially covers the occlusal surfaces of the molars and is traumatized during mastication.

Zackin and Weisberger<sup>34</sup> histologically described fibromatosis as a moderate hyperplasia of the epithelium, with hyperkeratosis and elongation of the rete pegs. The increase in tissue mass is primarily the result of an increase and thickening of the collagen bundles in the connective tissue stroma. The tissue shows a high degree of differentiation, and a few young fibroblasts are present (Fig. 15.18C).

Surgical removal of the hyperplastic tissue achieves a more favorable oral and facial appearance. However, hyperplasia can recur within a few months and can return to the original condition within a few years. Although the tissue usually appears pale and firm, the surgical procedure is accompanied by excessive hemorrhage. Therefore, localized quadrant surgery, rather than full-mouth surgical gingivectomy, is usually the recommended course of action. Brown et al.<sup>35</sup> reported a case in which apically positioned flap surgery and CO<sub>2</sub> laser evaporation were used to reduce the enlarged gingival tissue. The importance of excellent plaque control should be stressed to the patient because this suppresses the recurrence of the gingival overgrowth.

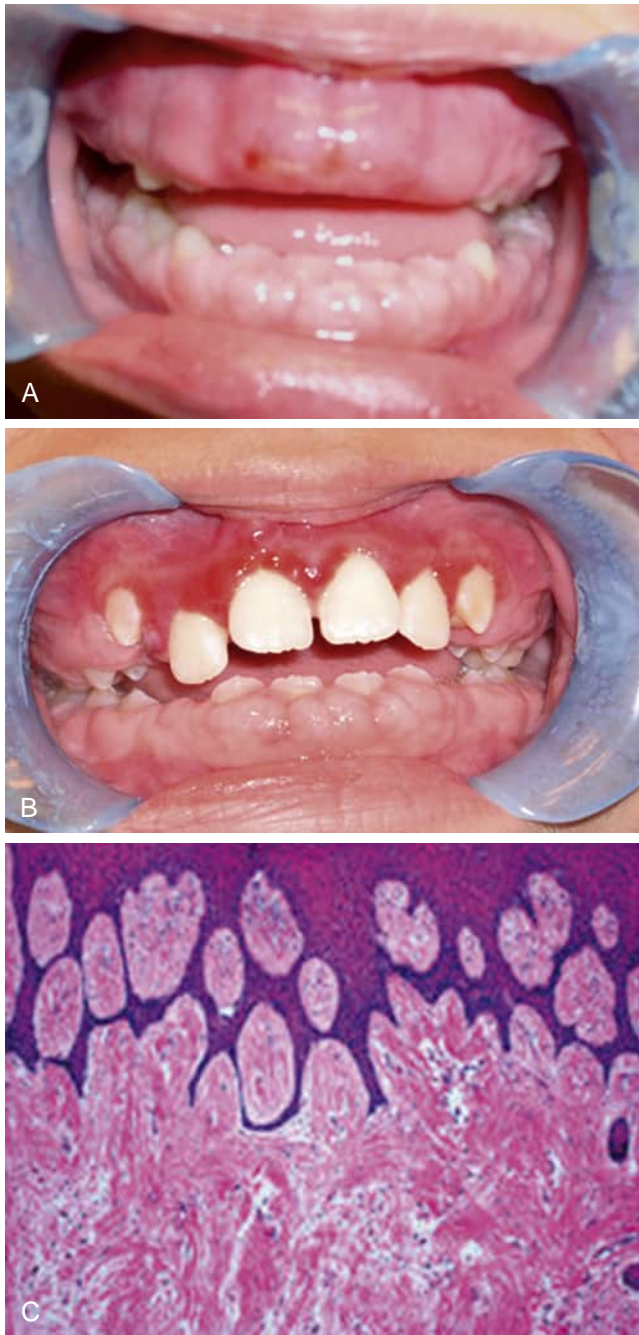
### PHENYTOIN-INDUCED GINGIVAL OVERGROWTH

In the late 1930s, phenytoin (Dilantin, or diphenylhydantoin) was discovered to have a major anticonvulsant property. Subsequently, it was indicated for the treatment of epilepsy. However in 1939, Kimball<sup>36</sup> reported that phenytoin was associated with various degrees of gingival hyperplasia. He reported that 57% of 119 patients taking phenytoin for the control of seizure activity experienced some degree of gingival overgrowth.

Early research showed an increase in the number of fibroblasts in patients receiving Dilantin; hence, the condition was termed *Dilantin hyperplasia*. However, this is no longer considered to be a hyperplastic condition since Hassell et al.<sup>38</sup> found true hyperplasia not to exist in the tissue of patients diagnosed with what was formerly called Dilantin hyperplasia. Furthermore, there was neither excessive collagen accumulation per unit of tissue nor abnormally sized or abnormally numbered fibroblasts. As such, the old term for this condition has been replaced with the name *phenytoin-induced gingival overgrowth* (PIGO).

Since its discovery, phenytoin has become one of the most widely used anticonvulsants because of its indication to treat a wide variety of seizures. At the same time, the incidence of PIGO in patients undergoing long-term phenytoin

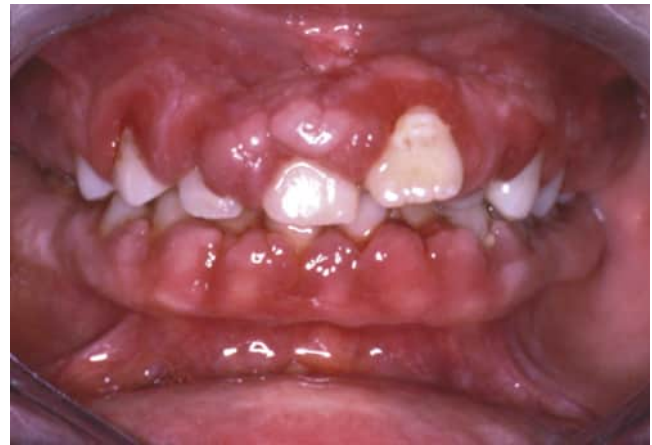



**Fig. 15.18** (A) Hereditary gingival fibromatosis (HGF) in an 11-year-old girl. The maxillary anterior gingival tissues completely covered the crowns of teeth #6, 7, 8, 9, 10, and 11. (B) Clinical presentation approximately 6 weeks after the maxillary teeth were surgically exposed by the removal of excessive tissue. Although oral hygiene still needs to improve, the results of the surgical procedure were dramatic. (C) Histologic specimen of HGF. Note the moderate hyperplasia of the epithelium with elongated rete pegs. The underlying connective tissue is composed of thick, irregularly arranged collagen fibers. (C, From Coletta RD, Graner E. Hereditary gingival fibromatosis: a systematic review. *J Periodontol.* 2006;77:753–764.)

therapy is quite high. Studies have reported the prevalence of PIGO ranging from 0% to 95%, with numerous investigators reporting figures around the 40% to 50% level.<sup>37</sup>

The influence of serum and salivary levels of phenytoin on the development of PIGO has also been investigated.



**Fig. 15.19** Phenytoin gingivitis of the severe generalized type in an 11-year-old child. The enlarged gingival tissue covers a significant portion of the clinical crowns of the maxillary and mandibular surfaces of the anterior dentition.

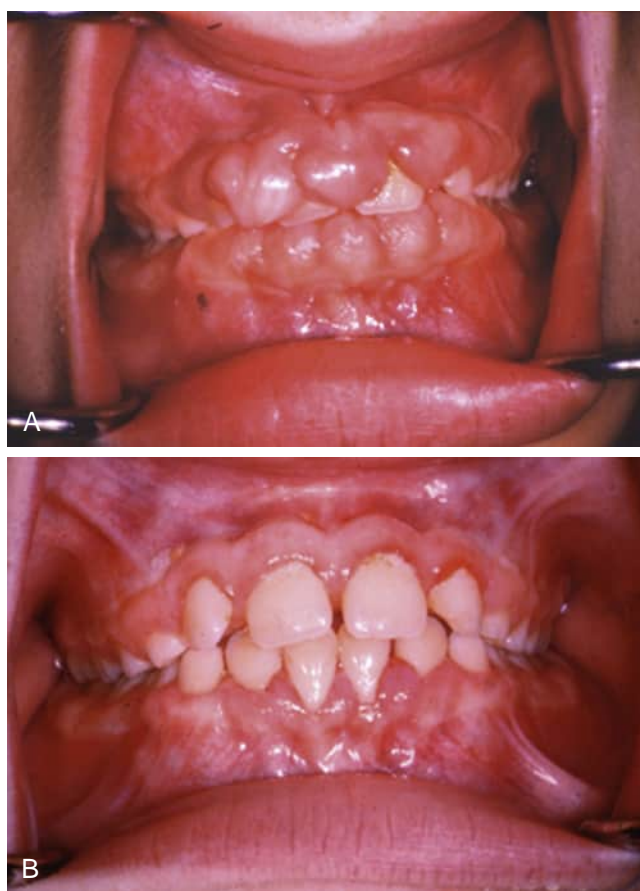Some authors report a positive relationship between the level of phenytoin in serum and saliva and the severity of PIGO in some cases.<sup>39–41</sup> Other investigators have reported that no such correlation exists.<sup>42,43</sup> It is generally agreed that a relationship exists between dosage level and PIGO when the level of phenytoin per unit body weight or actual serum level is considered. Sasaki and Maita<sup>44</sup> reported a significant correlation between the degree of gingival overgrowth and a high level of basic fibroblast growth factor in serum. No such correlations were observed for patient age, daily or total phenytoin dose, duration of therapy, or serum phenytoin level.

Most investigators agree on the existence of a close relationship between oral hygiene and PIGO. PIGO can be suppressed or prevented by scrupulous oral hygiene and dental prophylaxis. The relationship between plaque, local irritants, and PIGO is also supported by the observation that phenytoin patients without teeth almost never develop PIGO.

When it does develop, PIGO begins to appear as early as 2–3 weeks after the initiation of phenytoin therapy and peaks at 18–24 months. The initial clinical appearance is asymptomatic enlargement of the interproximal gingiva. The buccal and anterior segments are more often affected than the lingual and posterior segments (Figs. 15.19 and 15.20A). The affected areas are isolated at first but can become more generalized later. Unless secondary infection or inflammation is present, the gingiva appears pink and firm and does not bleed easily when probed. As the interdental lobulations grow, clefting becomes apparent at the midline of the tooth. With time, the lobulations coalesce at the midline, forming pseudopockets and covering more of the crown of the tooth. The epithelial attachment level usually remains constant. In some cases, the entire occlusal surface of the tooth is covered. The gingival overgrowth may remain purely fibrotic or may be combined with a noticeable inflammatory component.

PIGO may result in an unaesthetic appearance, difficulty in mastication, speech impairment, delayed tooth eruption, tissue trauma, and secondary inflammation leading to periodontal disease.<sup>45</sup> No cure exists, and treatment is often based on the presence of symptoms. Antihistamines, topical





**Fig. 15.20** (A) Phenytoin gingivitis of the severe generalized type. (B) Surgical removal of the overgrowth of hyperplastic gingival tissue results in temporary improvement of the condition. Excellent oral hygiene is essential in controlling the gingival enlargement.

corticosteroids, ascorbic acid (vitamin C) supplements, topical antibiotics, and alkaline mouthwashes are considered to be ineffective.

Steinberg and Steinberg<sup>46</sup> recommended the following types of dental treatment based on clinical oral signs and symptoms. For patients with mild PIGO (i.e., less than one-third of the clinical crown is covered), daily meticulous oral hygiene and more frequent dental care is recommended. For patients with moderate PIGO (i.e., one- to two-thirds of the clinical crown is covered), meticulous oral home care and the judicious use of an irrigation device is all that is needed. Use of an antiplaque mouthrinse (0.12% CH gluconate) in the irrigation device further helps control bacterial growth. Initially, a series of four consecutive weekly office visits for prophylaxis and topical stannous fluoride application is recommended. The fifth week is used to evaluate the gingiva and note any change in size. Phenytoin levels should be checked (normal therapeutic range is 10–15 mg/mL). If there has been no change, consultation with the patient's physician concerning the possibility of using a different anticonvulsant drug may be helpful. If no improvement occurs, surgical removal of the overgrowth may be recommended. For patients with severe PIGO (i.e., more than two-thirds of the tooth is covered) who do not respond to the previously mentioned therapeutic regimens, surgical removal is necessary. As in any periodontal surgery, meticulous supragingival and subgingival scaling before

surgery and meticulous oral hygiene after surgery are essential to minimize the overgrowth, which can occur as early as 3–4 weeks after surgery (Fig. 15.20B). Donnenfeld et al.<sup>47</sup> found no PIGO recurrence for as long as 9 months postoperatively.<sup>47</sup> If surgery is required a second time and the patient has a history of rapid recurrence, a pressure appliance should be considered as an adjunct to home oral care. If the patient has undergone multiple gingivectomies, clinical management becomes one of trying to maintain the postsurgical outcomes so as to make surgical retreatment unnecessary, if possible.

Specific surgical approaches for PIGO include gingivectomy with periodontal knives, laser, or electrosurgery, and internal bevel flap surgery. The use of periodontal knives allows the tissue to heal more quickly, but more intraoperative and postoperative bleeding occurs, and the procedure requires more time and patient cooperation. Electrosurgery is less time-consuming, decreases blood loss, improves visibility, allows for superior control in areas of limited access, is self-sterilizing, and does not always require the use of periodontal packs. Disadvantages include its contraindication in patients with cardiac pacemakers, unpleasant odor, delayed healing, and the potential for error in application that results in undesired bone or tissue loss. Advantages of the surgical laser include the following: lack of hemorrhage, which yields a nonbleeding field that improves visual access to the surgical site; noncontact during surgery; sterilization of the surgical area; prompt healing; minimal postoperative discomfort; and minimal time spent in performance of the procedures. Disadvantages include the cost and size of equipment, necessity for hospitalization, potential for delayed healing of some tissues, greater degree of operator expertise required, loss of tactile feedback, requirement for eye protection, ability of the laser to ignite a plastic or rubber endotracheal tube, and a need to cover the nonsurgical field with moist sponge shields to prevent penetration of the laser beam. Internal bevel flap surgery has some advantages over the previously mentioned treatment modalities. The internal bevel flap promotes faster healing (facilitated by healing by primary intention), controls postoperative bleeding, minimizes postoperative pain, and allows for the optional use of a periodontal pack. The choice of surgical approach must be left to the operator and is based on the medical history of the patient, patient cooperation and compliance, the degree of gingival overgrowth, and operator expertise. Healing is usually rapid with all these modalities.

The surgical removal of severely overgrown tissue in PIGO and good oral hygiene after surgery are generally considered to be the most effective treatment. However, even these procedures have often been followed by a gradual recurrence of the gingival overgrowth.

A study in the use of a pressure appliance for PIGO has been reported by Davis et al.<sup>48</sup> Immediately after the surgical removal of fibrous tissue, an impression was taken and a positive-pressure splint was constructed. Periodontal dressings were removed at the end of 1 week, and the positive-pressure appliance was inserted. Seven of the nine members of the experimental group had no recurrence of gingival overgrowth, one had a slight recurrence, and one had a moderate recurrence. The natural rubber, mouth-protector type of appliance and the type with a cast chromium-cobalt framework lined with soft plastic were equally effective. The

appliance is generally used only at night but may be worn night and day if such a schedule is required. Sheridan and Reeve<sup>49</sup> also reported success in controlling gingival overgrowth with positive-pressure appliances.

Steinberg<sup>50</sup> suggested that use of a series of pressure appliances may help reduce the size of the gingival overgrowth without surgery. He reported one case in which existing systemic conditions contraindicated surgical removal of the gingival tissue. After oral hygiene was improved, pressure appliances were made on stone casts of the patient's maxillary and mandibular arches after 2 mm of the stone were trimmed away in the gingival overgrowth areas. The patient wore the appliance about 12 hours each day for 4 weeks, after which a new pressure device was made. Steinberg observed a pronounced decrease in the sizes of the gingival overgrowth after 8 weeks of therapy. He suggested that a series of such appliances could succeed in gradually reducing gingival overgrowth to clinically tolerable limits. He also cautioned that this therapeutic approach is not practical for the average patient, but that it may be a valuable alternative for patients for whom oral surgery is contraindicated.

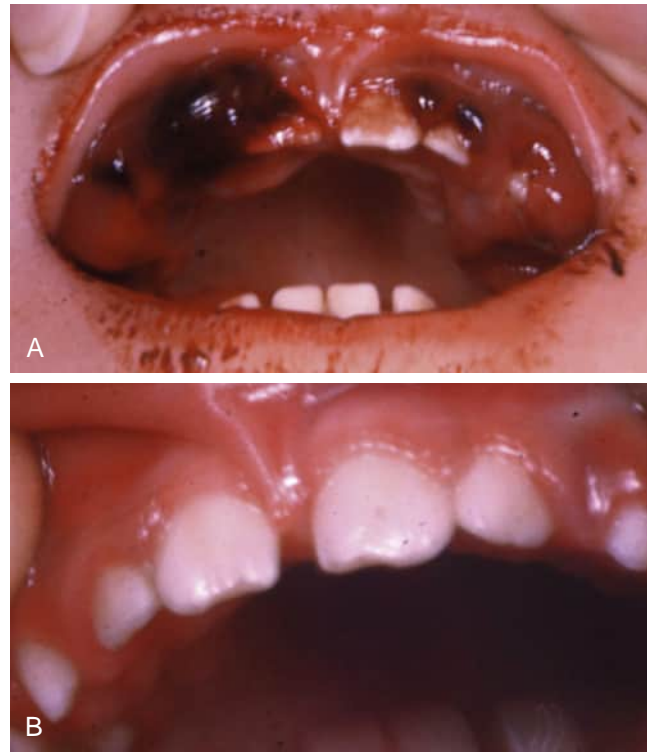Drew et al.<sup>51</sup> and Bäckman et al.<sup>52</sup> have reported that patients with PIGO or at risk for developing it may benefit from receiving folic acid therapy. Their work demonstrated a reduction in the severity of PIGO in patients who received systemic folic acid supplementation. The work of Drew et al.<sup>51</sup> further demonstrated that twice-daily oral rinsing with a topical folic acid solution resulted in tissue responses significantly better than those achieved with systemic folic acid therapy. Their studies suggest that folic acid therapy may inhibit PIGO and that additional related studies are indicated.

Other medications that have been reported to induce gingival overgrowth in some patients include cyclosporine, calcium channel blockers, valproic acid, and phenobarbital. As with all disorders affecting periodontal tissues, the maintenance of excellent oral hygiene is the primary key to successful therapy.

### ASCORBIC ACID DEFICIENCY GINGIVITIS (SCORBUTIC GINGIVITIS)

Nutritional deficiencies may be modifiable risk factors that affect the health of the gingival tissue. One such well-documented nutritional deficiency that can affect the periodontium is scorbutic gingivitis. Scorbutic gingivitis is associated with vitamin C deficiency and differs from the more typical dental biofilm-induced gingivitis. The involvement is usually limited to marginal tissues and papillae. The child with scorbutic gingivitis may complain of severe pain. Spontaneous hemorrhage may be evident. Aside from dietary deficiencies, ascorbic acid deficiency gingivitis can be seen in both pediatric and adult cancer patients undergoing radiotherapy and/or chemotherapy where the mucosal linings of the intestinal walls are affected and the absorption of nutrients is impaired.

Severe clinical scorbutic gingivitis is rare in children. However, it may occur in children allergic to fruit juices when provision of an adequate dietary supplement of vitamin C is neglected (Fig. 15.21A). When laboratory analysis of a patient's blood sample indicates a vitamin C deficiency and excludes other possible systemic conditions, the daily



**Fig. 15.21** (A), Severe scorbutic gingivitis in a 16-month-old child. Large hematomas were evident in the maxillary arch. The condition was initially incorrectly diagnosed as Vincent infection. (B) Daily administration of 400 mg of ascorbic acid resulted in a dramatic recovery.

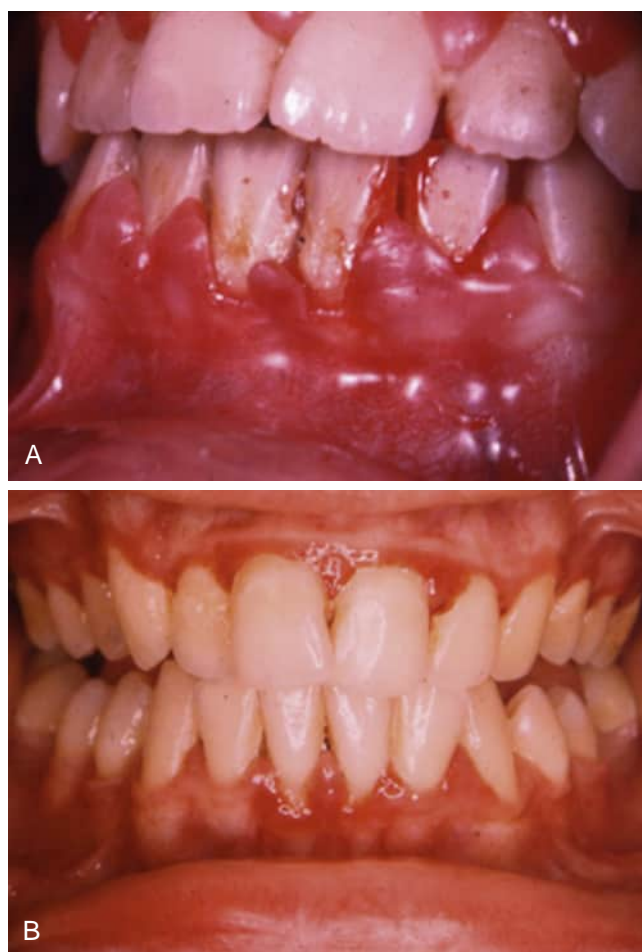
administration of 250–500 mg of ascorbic acid is recommended and will achieve drastically favorable results (Fig. 15.21B). Older children and adults may require 1 g of vitamin C for 2 weeks to speed recovery.

Although reports indicate that the prevalence of scorbutic gingivitis is low, it is probably much more common than we realize because it can be easily overlooked if the practitioner does not know how to recognize the signs of the disease. Inflammation and enlargement of the marginal gingival tissue and papillae in the absence of local predisposing factors are possible evidence of scorbutic gingivitis (Fig. 15.22A and B). Questioning the child and adult caregivers regarding eating habits, dietary intake, and using the 7-day diet survey frequently reveal that the child is receiving inadequate amounts of foods containing vitamin C. Complete dental care, improved oral hygiene, and supplementation with vitamin C and other water-soluble vitamins will greatly improve the gingival condition.

## Periodontal Diseases in Children

Periodontitis is an inflammatory disease that affects both the gingiva and the deeper tissues of the periodontium, specifically the cementum, PDL, and alveolar bone. It is characterized by pocket formation, CAL, and destruction of the supporting alveolar bone. BL in children can be assessed in bitewing radiographs by measuring the height of the alveolar bone in relation to the cemento-enamel junction (CEJ). Distances between 2 and 3 mm indicate questionable BL, and distances greater than 3 mm indicate definite BL.





**Fig. 15.22** (A) Scorbutic gingivitis in a 13-year-old girl. The diet was almost entirely lacking in foods containing vitamin C. (B) An improved diet, supplemental amounts of fresh fruit juices, and toothbrushing instruction resulted in an improved gingival condition in 2 weeks.

Periodontal probing for attachment loss and bitewing radiography are often used for the clinical confirmation of the diagnosis. BL is usually between the first and second primary molars.

In its previous classification of periodontitis, the AAP categorized the early-onset form of periodontitis under aggressive periodontitis.<sup>53</sup> However, the new classification has eliminated the term “aggressive” just as they have eliminated the term “chronic.” The rationale behind this change of direction is that there is no clear distinction between chronic and aggressive periodontitis. These conditions are likely those that present with different clinical findings with regards to the rate of progression while still possessing similar etiologies (bacteria) and pathophysiology. In other words, both chronic and aggressive periodontitis are likely the same disease entity with different clinical presentations.

### PERIODONTITIS (PREVIOUSLY CALLED AGGRESSIVE PERIODONTITIS AND EARLY-ONSET PERIODONTITIS)

Periodontitis can occur in younger individuals who may or may not be otherwise healthy. It can be viewed as two categories of periodontitis that may have overlapping etiologies and clinical presentations: (1) a localized form,

i.e., molar-incisor distribution (previously called localized aggressive periodontitis [LAP] and localized juvenile periodontitis) and (2) a generalized form (previously called generalized aggressive periodontitis [GAP]). Using data from a 1986–1987 survey, Albandar et al.<sup>54</sup> estimated the prevalence of what was previously termed as “aggressive periodontitis” in adolescent schoolchildren in the United States to be 10% in African Americans, 5% in Hispanics, and 1.3% in whites.

Löe and Brown<sup>55</sup> have reported observations from a periodontal assessment of 1107 adolescents aged 14–17 years.<sup>55</sup> Approximately 0.53% were estimated to have LAP, 0.13% to have GAP, and 1.61% to have incidental loss of attachment. Boys were more likely to have GAP than girls (ratio, 4.3:1).

Aggressive periodontitis-periodontitis of the primary dentition can occur in a localized form but is usually seen in the generalized form. Periodontitis with a molar-incisor distribution (previously referred to as LAP) is localized attachment loss and alveolar BL only in the primary dentition in an otherwise healthy child. The exact time of onset is unknown, but it appears to arise around or before 4 years of age, when the BL is usually seen on radiographs around the primary molars and/or incisors. Abnormal PDs with minor gingival inflammation, rapid BL, and minimal to various amounts of plaque have been demonstrated at the affected sites of the child’s dentition. Abnormalities in host defenses (e.g., leukocyte chemotaxis), extensive proximal caries facilitating plaque retention and BL, and a family history of periodontitis have been associated with the condition in children.<sup>56</sup> As the disease progresses, the child’s periodontium shows signs of gingival inflammation, with gingival clefts and localized ulceration of the gingival margin.

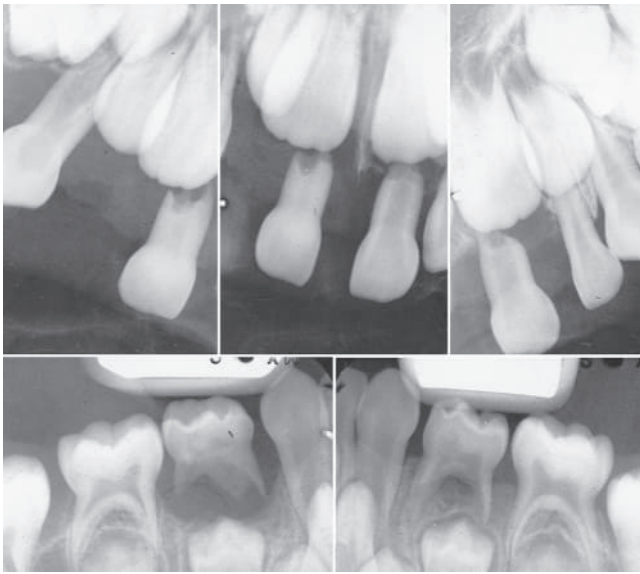
### GENERALIZED PERIODONTITIS (PREVIOUSLY CALLED GENERALIZED AGGRESSIVE PERIODONTITIS)

The onset of generalized periodontitis in children is during or soon after the eruption of the primary teeth. It results in severe gingival inflammation and generalized attachment loss, tooth mobility, and rapid alveolar BL with premature exfoliation of the teeth (Fig. 15.23). The gingival tissue may initially demonstrate only minor inflammation with minimal plaque accumulation. It often affects the entire dentition. Alveolar bone destruction proceeds rapidly, and the primary teeth may be lost by 3 years of age. Because of its wide distribution and rapid rate of alveolar bone destruction, generalized periodontitis that affects children was previously known as *generalized juvenile periodontitis*, *severe periodontitis*, and *rapidly progressive periodontitis*. Chronic cases display the presence of clefting and pronounced recession with associated acute inflammation. See the later section on Premature Bone Loss in the Primary Dentition.

### PERIODONTITIS WITH MOLAR-INCISOR DISTRIBUTION (PREVIOUSLY CALLED LOCALIZED AGGRESSIVE PERIODONTITIS AND LOCALIZED JUVENILE PERIODONTITIS)

This condition presents a classic pattern of rapid and severe loss of alveolar bone localized to the molars and incisors.



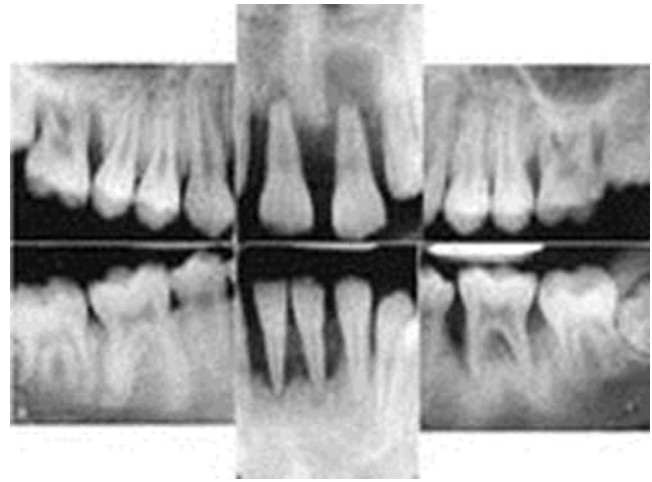


**Fig. 15.23** Radiographs of periodontitis in a 4½-year-old girl. A generalized loss of alveolar bone can be seen in the radiographs.

It typically occurs in otherwise healthy children and adolescents without clinical evidence of systemic disease (Figs. 15.24 and Fig. 14.25A and B). Molar-incisor periodontitis is believed to be self-limiting, and analysis of retrospective data obtained from these what was previously diagnosed as patients suggests that BL around the primary teeth can be an early finding in this disease. The prevalence of molar-incisor periodontitis is reportedly estimated to range from 0.1% to 1.5%, with a bilaterally symmetric pattern of BL in a geographically diverse adolescent population. The prevalence in the African-American population is greater (2.5%). Clinically, patients with molar-incisor periodontitis have less tissue inflammation and very little supragingival dental plaque or calculus. However, they do present with the evidence of subgingival plaque accumulation, both tissue-associated and tooth-associated plaque. Progression of BL is three to four times faster than in generalized periodontitis.

### TREATMENT OF GENERALIZED PERIODONTITIS AND PERIODONTITIS WITH A MOLAR-INCISOR DISTRIBUTION

Successful treatment of **generalized periodontitis and periodontitis with a molar-incisor distribution** depends on early diagnosis, the use of antibiotics against the infecting microorganisms, thorough supragingival and subgingival mechanical debridement of the affected areas via nonsurgical and/or surgical treatment modalities with or without adjunctive antimicrobial therapy, reinforcement of meticulous home care, strict periodic follow-ups to monitor patient compliance and intercept disease recurrence at its early stage, and the provision of an infection-free environment for healing. Consultation with the patient's physician and supplemental diagnostic testing that includes microbiological, genetic, or biochemical assessment during the course of treatment may be needed to rule out systemic conditions that have periodontitis manifestations (i.e., cyclic neutropenia,

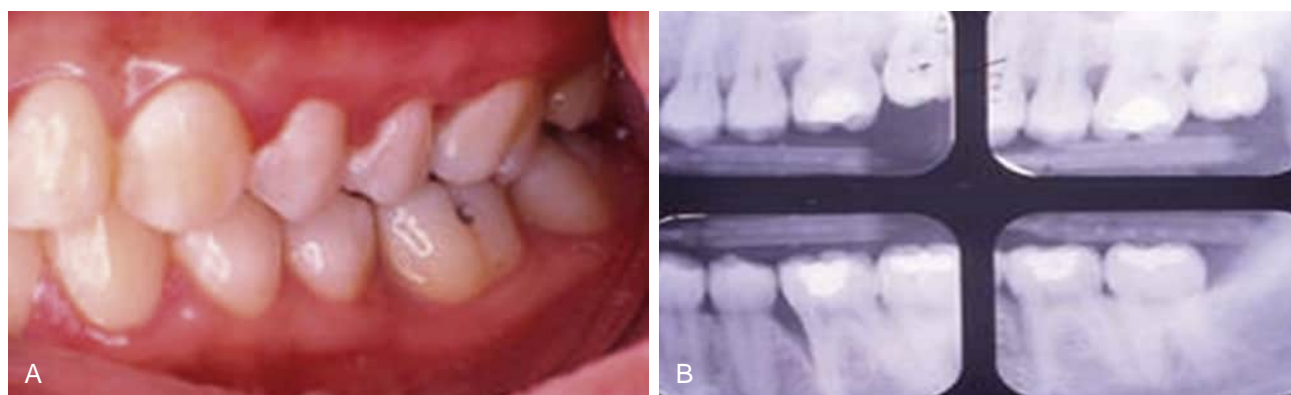


**Fig. 15.24** Radiographs of a 12-year-old boy with the Localized Periodontitis-Molar-Incisor Distribution. The films revealed loss of support in the incisor and first permanent molar areas. The maxillary central incisors, mandibular incisors, and first permanent molars were removed. Partial dentures were constructed.

histiocytosis) or conditions that affect the periodontal supporting tissues (i.e., diabetes, hyperparathyroidism). In a study of deep periodontal lesions, Christersson et al.<sup>57</sup> demonstrated that scaling and root planing alone was ineffective for the elimination of *Aa*. Hence, the provision of adjunctive antimicrobial therapy may be indicated to aid in the elimination of any periodontal pathogens, such as *Pg* or *Aa* organisms that have penetrated through the microscopic ulcerations of the crevicular epithelium and gained entry into the underlying connective tissue. A combination regimen of amoxicillin and metronidazole over 1–2 weeks has been found to eliminate *Aa* and suppress *Pg* significantly. On the other hand, the use of tetracyclines to treat periodontitis in the pediatric population should be avoided because this could cause discoloration of teeth as they form and develop. Tetracycline staining occurs because of tetracycline's unique ability to be incorporated into the dental and skeletal tissues during active mineralization. Therefore, tetracyclines are classified as FDA pregnancy category D agents because they may affect the development of the fetal skeletal system. As such, tetracyclines are contraindicated in pregnancy and in women who are breastfeeding their developing neonates.

Microdentex manufactures the DMDx (Microdentex, Fort Myers, FL, USA) test, a DNA test kit for periodontal pathogens. The test aids in establishing the risk for periodontitis and confirms whether the child has responded favorably to the use of adjunctive antibiotics. Re-testing in 4–6 weeks after the completion of antibiotic therapy determines the patient's response to the treatment. The test involves collection of a plaque specimen by the insertion of a paper point provided in the kit into a periodontal pocket for 10 seconds. The paper point is placed in a test vial and returned for microbial testing. Although the Pedo probe test provides a detailed analysis only for *Aa*, the laboratory will also perform a more detailed microbial analysis.

Treatment of generalized periodontitis in children is often less predictable. Alternative antibiotics directed at



**Fig. 15.25** (A) Localized periodontitis-Molar-Incisor Distribution. (B) Radiographic evidence of vertical bone loss on the mesial surfaces of tooth #14 and especially tooth #19.

the specific pathogenic flora may be required when traditional therapies yield no improvement. The multidisciplinary approach combines clinical laboratory evaluation with conventional periodontal therapeutic methods for the diagnosis and treatment of severe generalized periodontitis cases.

## Periodontitis as a Manifestation of Systemic Disease

In 2017, the AAP and EFP reaffirmed the periodontal disease category called periodontitis as a manifestation of systemic disease as a separate and distinct disease condition. Several of these systemic conditions are known to affect the child and adolescent population. The following is a complete list of systemic conditions that can manifest as periodontitis.

Systemic disorders that have a major impact on the loss of periodontal tissues by influencing periodontal inflammation:

1. Genetic Disorders
  - 1a. Diseases associated with immunologic disorders
    - Down syndrome
    - Leukocyte adhesion deficiency syndromes
    - Papillon-Lefèvre syndrome (PLS)
    - Haim-Munk syndrome
    - Chédiak-Higashi syndrome
    - Severe neutropenia (congenital neutropenia, cyclic neutropenia)
    - Primary immunodeficiency disease (chronic granulomatous disease, hyperimmunoglobulin E syndromes)
    - Cohen syndrome
  - 1b. Diseases affecting the oral mucosa and gingival tissues
    - Epidermolysis bullosa (dystrophic epidermolysis bullosa, Kindler syndrome)
    - Plasminogen deficiency
  - 1c. Diseases affecting the connective tissues
    - Ehlers-Danlos syndromes (types IV, VIII)
    - Angioedema
    - Systemic lupus erythematosus

- 1d. Metabolic endocrine disorders
  - Glycogen storage disease
  - Gaucher disease
  - Hypophosphatasia
  - Hypophosphatemic rickets
  - Hajdu-Cheney syndrome
- 1.2 Acquired immunodeficiency diseases
  - Acquired neutropenia
  - HIV infection
- 1.3 Inflammatory diseases
  - Epidermolysis bullosa acqvista
  - Inflammatory bowel diseases
2. Other systemic disorders that influence the pathogenesis of periodontal diseases
  - Diabetes mellitus
  - Obesity
  - Osteoporosis
  - Arthritis (rheumatoid, osteoarthritis)
  - Emotional stress and depression
  - Smoking (nicotine dependence)
  - Medications
3. Systemic disorders that can result in loss of periodontal tissues independent of periodontitis
  - 3a. Neoplasms
    - Primary neoplastic diseases of the periodontal tissues (oral squamous cell carcinoma, odontogenic tumors, other primary neoplasms of the periodontal tissues)
    - Secondary metastatic neoplasms of the periodontal tissues
  - 3b. Other disorders that may affect the periodontal tissues
    - Granulomatosis with polyangitis
    - Langerhans cell histiocytosis
    - Giant cell granulomas
    - Hyperparathyroidism
    - Systemic sclerosis (scleroderma)

### VANISHING BONE DISEASE (GORHAM-STOUT SYNDROME) PREMATURE BONE LOSS IN THE PRIMARY DENTITION

Advanced alveolar BL associated with systemic disease occurs in children and adolescents, as well as in adults.

In the primary dentition, this is rare. Although most premature tooth loss from nonsystemic diseased individuals results from trauma or caries, the cause of advanced alveolar BL is often not readily apparent. Local factors (periodontitis, trauma, and infection secondary to caries) account for the majority of cases of premature BL. Goepferd<sup>58</sup> reports that bony destruction in the primary dentition in the absence of local factors is highly suggestive of systemic disease. Many possibilities exist, including hypophosphatasia, PLS, histiocytosis X, agranulocytosis, leukocyte adherence deficiency, neutropenias, leukemias, diabetes mellitus, scleroderma, fibrous dysplasia, acrodynia, Down syndrome, and Chédiak-Higashi syndrome. The defect in immune and neutrophil cell function associated with these diseases is thought to increase patient susceptibility to periodontitis, causing alveolar BL, and to other infections.

### PAPILLON-LEFÈVRE SYNDROME

Of all the systemic diseases that have periodontitis as a manifestation, PLS is perhaps the most well-documented syndrome because of its distinct clinical presentation. PLS is a rare genetic disorder that is characterized by precocious periodontitis and palmar-plantar hyperkeratosis which typically becomes apparent in children before they reach the age of 5 years. Coccia et al.<sup>59</sup> observed PLS (precocious periodontitis) in a child aged 2½ years. Moreover, the cause is still unknown. However, in the families of affected children (1–4 per 1,000,000) in which a familial predisposition to the disorder is noted, an autosomal recessive mode of inheritance has been identified.<sup>60</sup> There is no racial or gender predominance.

The observations made in the young child (Fig. 15.26) are typical of those reported by Gorlin et al.<sup>61</sup> The primary teeth erupted at the normal time. However, as early as 2 years of age, the child rubbed the gingival tissues and acted as if they were painful. There was a tendency toward gingival bleeding when the teeth were brushed. Hyperkeratosis of the palms and soles was present (Fig. 15.27); the first evidence was erythema and scaliness noted initially at 8 months of age. Delaney<sup>1</sup> noted that hyperkeratotic lesions of the elbows and knees may be observed. Repeated laboratory tests, including complete blood count, urinalysis, and micro serum calcium and phosphorus determinations, yielded essentially normal results.

At 2½ years of age, all the primary teeth became mobile, and full-mouth radiographs revealed severe horizontal bone resorption not typically seen at this age (Fig. 15.28). Because of gingival inflammation, patient discomfort, and the presence of infected periodontal pockets, all the primary teeth were extracted by 3 years of age. Histologic analysis of the extracted teeth exhibited a pattern of premature resorption with essentially normal pulp tissue. Cementum was apparently normal and covered the root structure. An accumulation of adherent basophilic plaque, composed of a mass of filamentous microorganisms, was noted on almost the entire length of the root surface. Periodontal pathogens (*Aggregatibacter actinomycetemcomitans*, *Fusobacterium nucleatum*, *Capnocytophaga species*, and *Eikenella corrodens*)

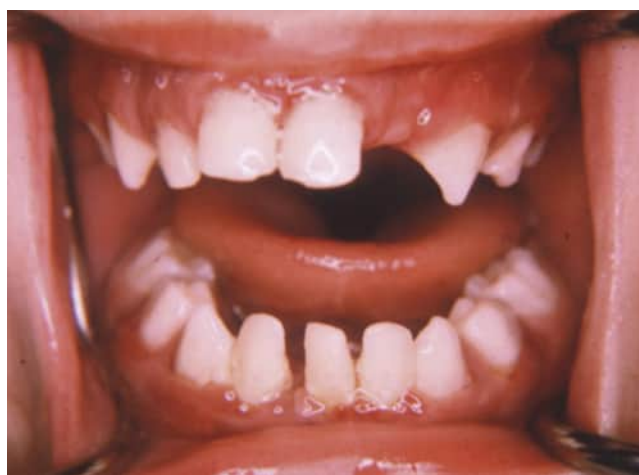

Fig. 15.26 Intraoral condition of a 2½-year-old child with Papillon-Lefèvre syndrome. Inflammatory gingival engorgement and accumulated accretions were present, especially in the mandibular incisor area.

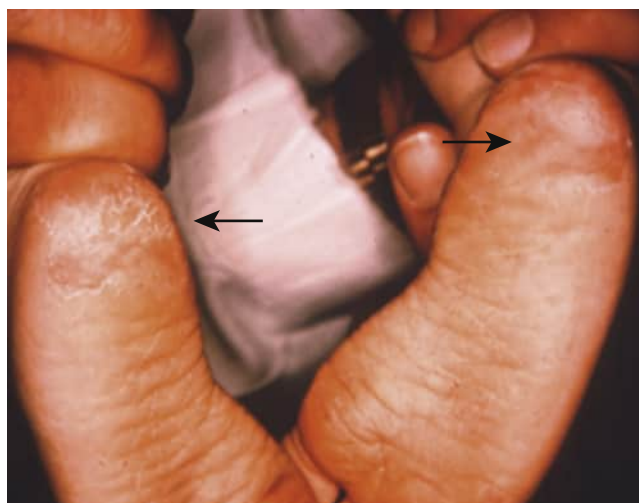

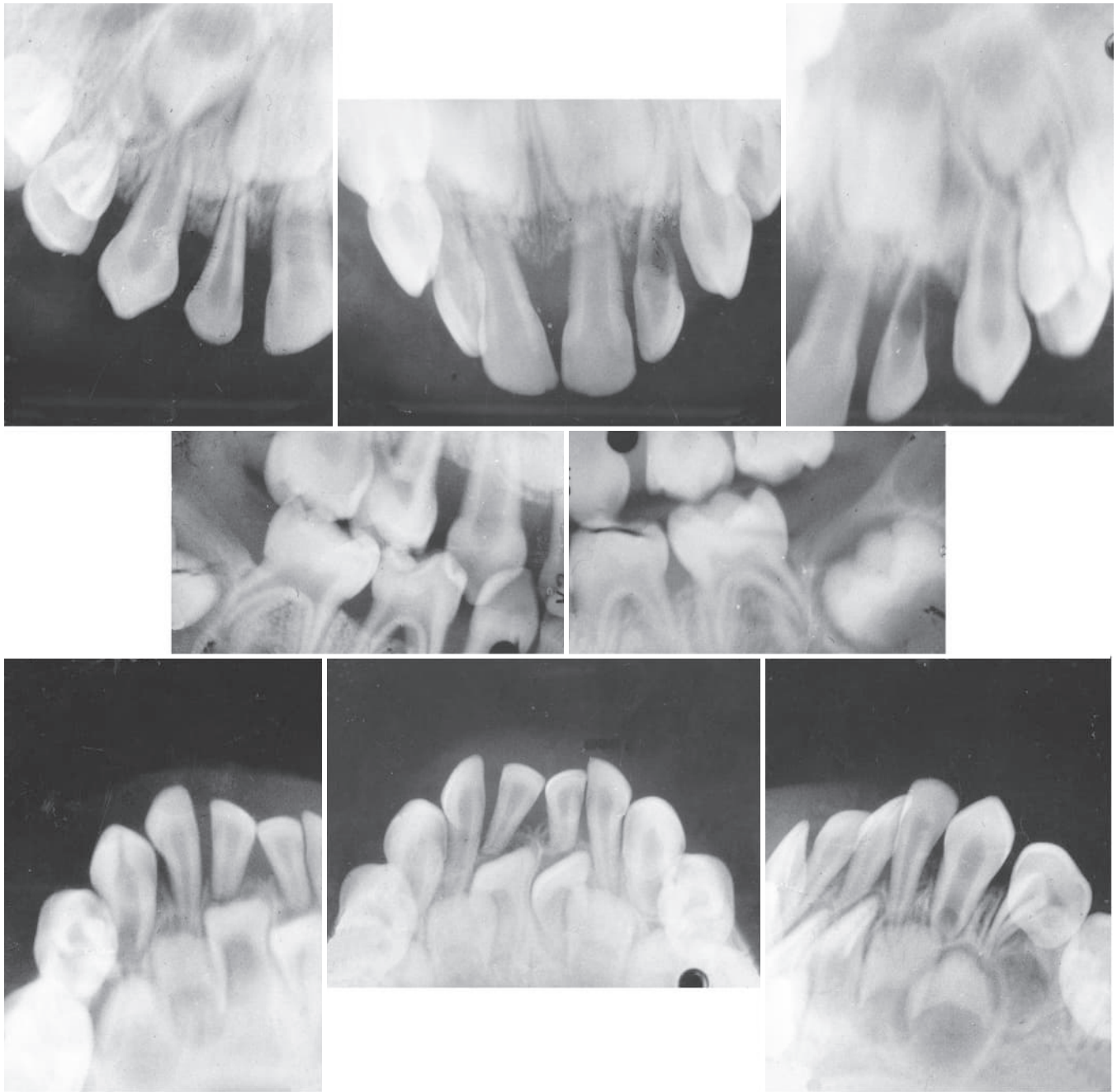
Fig. 15.27 Hyperkeratosis of the plantar surfaces of the feet (arrows).

have been isolated in the dental plaque of patients with PLS, according to Tinanoff et al.<sup>62</sup>

Complete dentures were constructed 3 months after the removal of the primary teeth. The child tolerated the dentures well, both functionally and psychologically (Fig. 15.29A and B). The first permanent molars and mandibular central incisors erupted at the expected time, and the denture base was adjusted to allow for the emergence of the teeth. Although the previous reports have indicated that the permanent dentition will also be affected, the child whose history is reported here was followed-up into young adulthood, and the dentition including the supporting tissues appeared normal (Fig. 15.30). In addition, the patient had successfully undergone orthodontic treatment.

Reports of the effectiveness of tetracycline therapy as an adjunct to meticulous subgingival debridement in the management of periodontal disease prompted McDonald to reinvestigate the history in the reported case of PLS. The father,



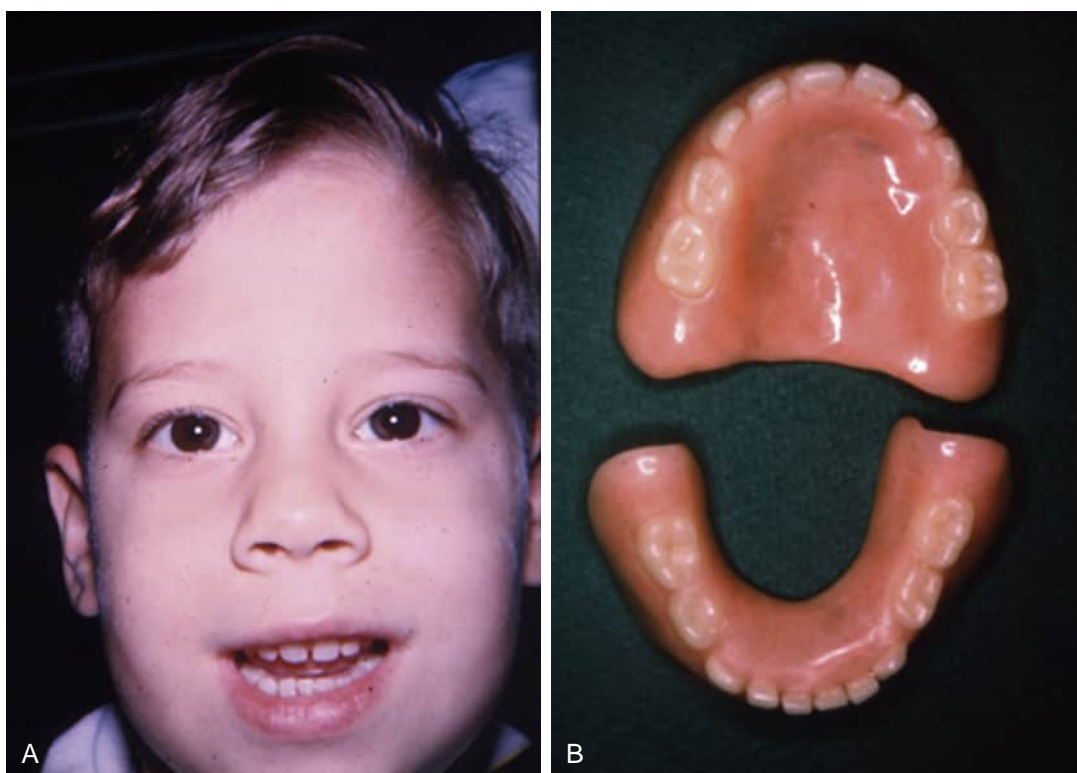

**Fig. 15.28** Full-mouth and bitewing radiographs of a 2½-year-old child with Papillon-Lefèvre syndrome. Severe horizontal bone resorption is readily detected in all four quadrants. The incisor areas display extreme alveolar bone loss to the extent that only the apical third of the root remains supported. All primary teeth were extracted by 3 years of age, and dentures were constructed.

a physician, reported that tetracyclines were given to the child repeatedly for ear infections between 3 and 6 years of age. This regimen may have been responsible for eliminating pathogens and preventing the destructive process of the syndrome from affecting the development and normal eruption of the permanent dentition. However, attempts at conventional therapy have been unsuccessful in preventing tooth loss. Delaney reports that periodontal treatment for these young children includes identification of specific pathogens, specific antibiotic therapy against these organisms, and full-mouth extractions early enough to provide an edentulous period before permanent tooth eruption.<sup>1</sup>

## GINGIVAL RECESSION

Gingival recession is often observed in children. Several factors predispose patients to gingival recession. These factors include the presence of a narrow band of attached or keratinized gingiva, alveolar bony dehiscence, toothbrush trauma, tooth prominence, impinging frenum attachment, soft tissue impingement by opposing occlusion, orthodontic tooth movement, use of impression techniques including subgingival tissue retraction, oral habits, periodontitis, pseudorecession (extrusion of teeth), and intraoral piercings, such as



**Fig. 15.29** (A) A 3-year-old child with complete dentures. (B) Constructed complete dentures, which were later modified to allow for eruption of the mandibular incisors and the first permanent molars.

tongue piercings. Recession is dealt with conservatively by elimination of the etiology if possible, while excellent oral hygiene is maintained in the affected areas. If the recession of the affected area remains unchanged (does not worsen) or improves, continued periodic monitoring is recommended. If the recession has progressed after a 4- to 8-week period of observation, surgical periodontal procedures may be required based on the identified predisposing factor.

### The New Classification of Gingival Recession

In 2017, the AAP and EFP endorsed a new system to classify gingival recession. Originally proposed by Cairo et al in 2011, this classification system categorizes gingival recession defects based on the interproximal clinical attachment level, which is an important presurgical parameter to consider because the interproximal clinical attachment level is associated with the stability of the future graft and serves as the primary source of blood supply to the soft tissue graft. As such, the Cairo classification has predictive value in forecasting the amount of root coverage that can occur following conventional root coverage procedures.

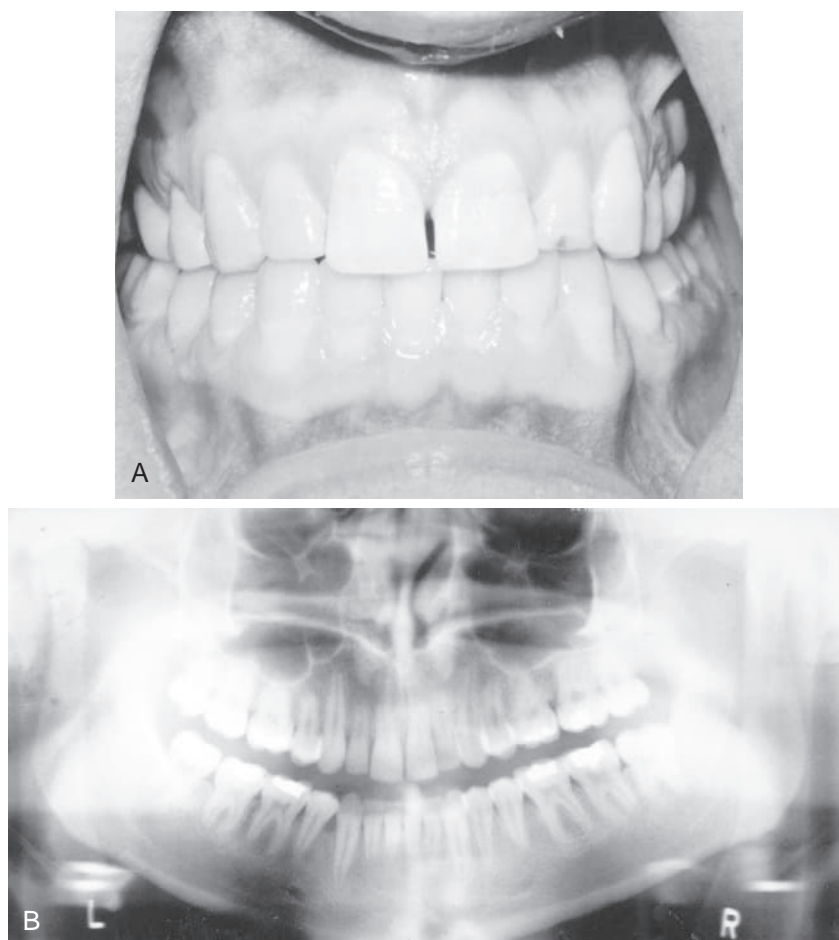**Recession Type 1.** Recession type 1 (RT1) refers to gingival recession with no loss of interproximal attachment. Interproximally, the CEJ is clinically not detectable at both mesial and distal aspects of the tooth. For RT1 defects, attaining 100% root coverage following a soft tissue graft procedure is predictable (Fig. 15.31).

**Recession Type 2.** RT2 refers to gingival recession associated with loss of interproximal attachment. The amount of interproximal attachment loss (measured from the interproximal CEJ to the depth of the interproximal sulcus/pocket) is less than or equal to the buccal attachment loss (measured from the buccal CEJ to the apical end of the buccal sulcus/pocket) (Fig. 15.32).

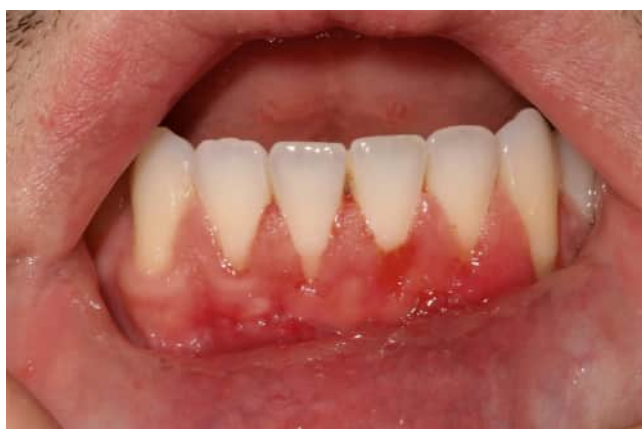**Recession Type 3.** RT3 refers to gingival recession associated with loss of interproximal attachment. The amount of interproximal attachment loss (measured from the interproximal CEJ to the apical end of the sulcus/pocket) is greater than the buccal attachment loss (measured from the buccal CEJ to the apical end of the buccal sulcus/pocket) (Fig. 15.33).

### ORAL FACTITIOUS INJURIES

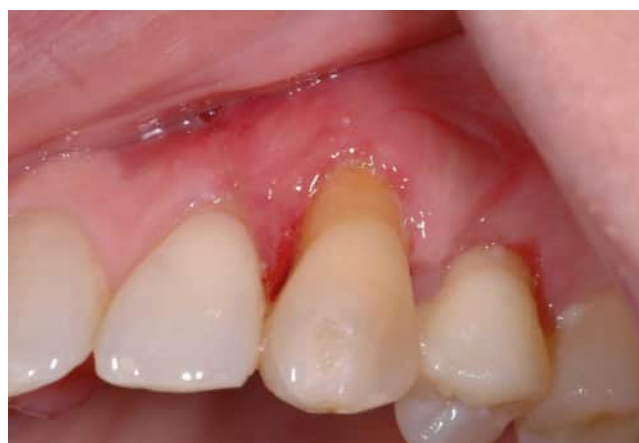An oral factitious injury (previously referred to as self-mutilating injury) is defined as a self-inflicted injury that leads to damage of tooth structure, soft tissue, and/or bone. In their review of oral factitious injuries, Stewart and Kernohan<sup>66</sup> have highlighted four distinguishing features of oral factitious injuries: 1) the lesion does not appear to be related to any type of disease process; 2) the lesion appears to have a bizarre and irregular configuration with a sharp outline; 3) the lesion is found in areas of the mouth that is accessible to the patient's hands; 4) the lesion may occur singly or with multiple other factitious injury-related lesions. While oral factitious injuries can



**Fig. 15.30** (A) Anterior intraoral view. (B) Panorex of the patient noted in Figs. 14.24 and 14.25 at 15 years of age. The survey revealed normal alveolar bone. Some apical root resorption related to orthodontic treatment can be seen in the mandibular incisors.



**Fig. 15.31** Recession type 1. Note the recession on the mandibular right central incisor. Mid-buccal CAL is clinically detectable, while interproximal clinical attachment loss is not at the mesial and distal sites. Full root coverage following a conventional grafting procedure on an RT1 defect is anticipated.

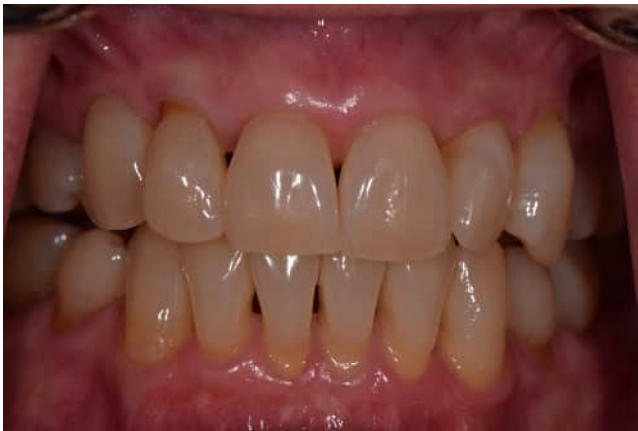

**Fig. 15.32** Recession type 2. Note the recession on the maxillary canine. Both mid-buccal CAL and interproximal CAL are clinically detectable. Using a periodontal probe, the mid-buccal CAL measures approximately 6 mm while the interproximal CAL is 4 mm. Following grafting, 100% root coverage may be possible.

be seen within the adult population, this type of injury is more often seen in children and may be a manifestation of an underlying emotional or behavioral problem. To date, several case reports describe cases of children who have either intentionally or unintentionally inflicted

trauma to their own oral structures. Plesset<sup>63</sup> reported observing a 9-year-old girl of apparently normal intelligence who worked her maxillary primary canine and mandibular permanent incisors loose from their supporting tissues and removed them. In another case, Leksell



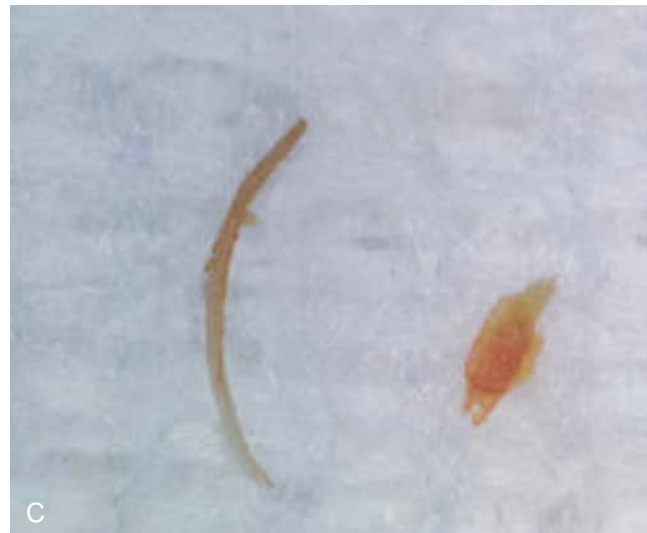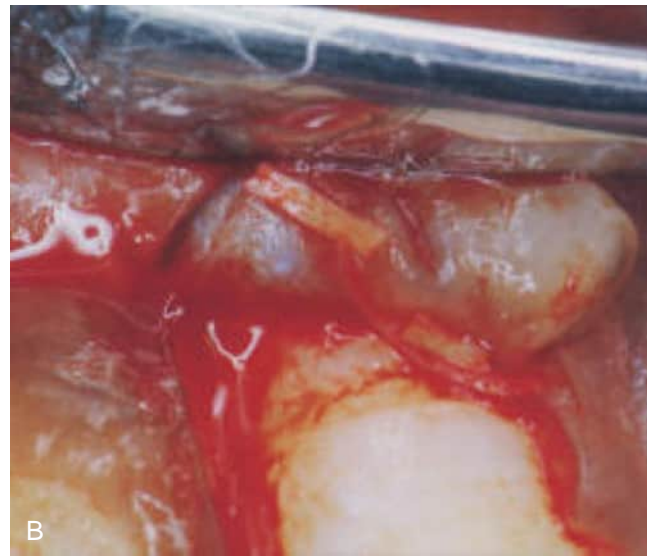

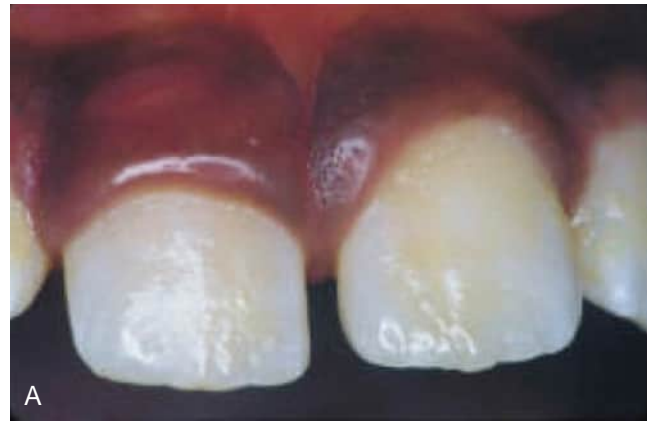
**Fig. 15.33** Recession type 3. Note the recession on the mandibular incisors. CAL is clinically detectable in both mid-buccal and interproximal regions. Using a periodontal probe, the mid-buccal CAL measures approximately 4 mm while the interproximal CAL is approximately 6 mm. In an RT3 case, 100% root coverage following soft tissue grafting procedures is not attainable due to the amount of interproximal tissue loss.

and Edvardson<sup>64</sup> reported regarding a 4-year-old female patient who presented to her pediatric dentist for self-luxation of teeth caused by oral motor tics. Further investigation revealed that the patient's oral self-injurious behavior was associated with a previously undiagnosed Tourette syndrome.

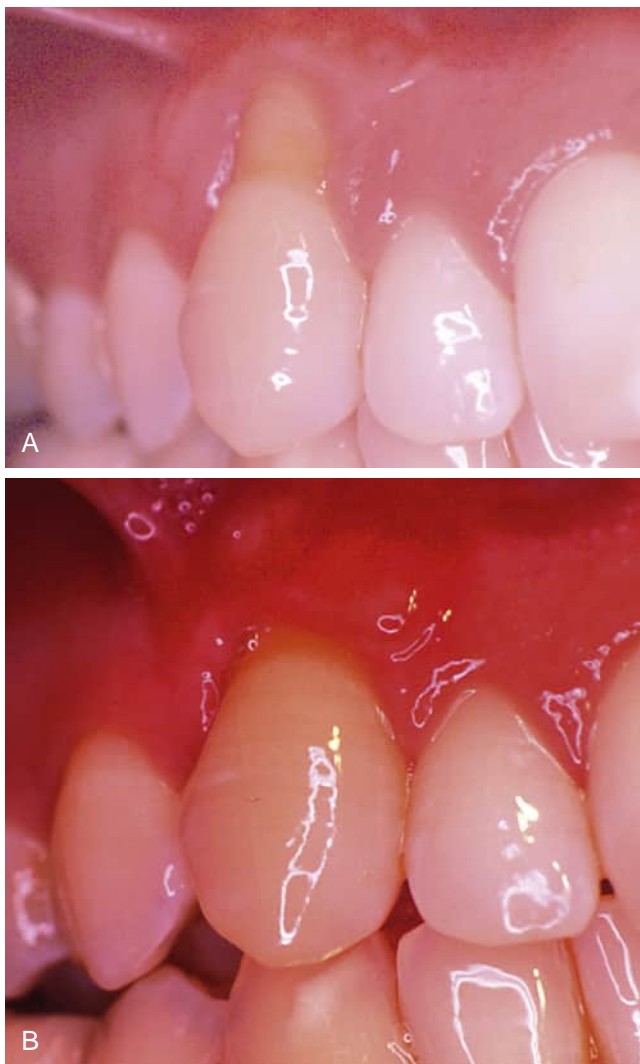
Oral factitious injury probably occurs more frequently than is realized because relatively few children will admit to the act unless they are observed practicing it. Therefore, the self-inflicted lesions may be either easily overlooked or incorrectly diagnosed by a health care practitioner and/or caregiver. Dentists should be aware of the possibility that children may exhibit either conscious or subconscious self-injurious behaviors, and should approach the problem in the same manner as they do for thumb sucking. An attempt should be made to determine the cause. If it is found to be the result of local dental factors, it can be corrected. However, in the majority of children, a behavioral or emotional problem may be the underlying cause, and the family must be directed to seek competent counseling services. Furthermore, if abuse or neglect is suspected as a contributing factor to the self-inflicting injury, the nature, extent, location, and frequency of the oral factitious injury must be carefully documented in the patient's chart and may need to be reported to the appropriate authorities.

Children as young as 4 years of age have been observed to traumatize the free and the attached gingival tissues with a fingernail, occasionally to the extent that the supporting alveolar bone has been destroyed. In a case report, Krejci<sup>65</sup> reported regarding an 8-year-old African-American male who presented with gingival swelling along the facial marginal gingiva of the maxillary right central incisor. The investigation revealed that the patient had a positive history of fingernail chewing and a habit of sliding the cleaved fingernails underneath the gingival margins of his maxillary central incisors. Consequently, surgical intervention and counseling were recommended (Fig. 15.34A–C). A 14-year-old girl produced unilateral stripping of the buccal



**Fig. 15.34** (A) An 8-year-old African American with gingival swelling along the maxillary right central incisor. (B) Surgical intervention reveals fragments of embedded fingernail in the gingiva. (C) Fingernail remnants removed during surgical procedure.

tissue in the maxillary canine area with her fingernail (Fig. 15.35A and B). The condition can be successfully treated surgically once the habit is stopped.



**Fig. 15.35** (A) Stripping of the free and attached tissue from the buccal side of a cuspid and exposure of the root surface secondary to constant scraping with a fingernail. (B) After a surgical procedure and the cessation of scraping, adequate healing had occurred.

Traumatic gingival recession in infants resulting from a dummy (pacifier) sucking habit has been observed by Stewart and Kernohan.<sup>66</sup> In the unconventional sucking habit, the infant's lower lip wraps around a segment of the plastic shield so that the inner surface of the shield bears against the labial aspect of the incisors and the gingival tissues. If the shield is held tightly in this position, the edge of the shield moves with an abrasive action during sucking, leading to gingival injury, recession, and possible trauma to the underlying alveolar bone.

Factitious injury caused by biting has been associated with severe emotional disturbances such as Lesch-Nyhan syndrome, congenital insensitivity to pain, and autism. Friedlander et al.<sup>67</sup> reported regarding autistic children with facial bruising, abrasions, and intraoral traumatic ulcerations that are most often the result of self-injurious behaviors rather than abuse by parents or caregivers. Management requires a choice between the initial use of protective appliances versus surgical procedures. Littlewood

and Mitchell<sup>68</sup> reported that mouthguards are helpful for children with congenital indifference to pain until they are mature enough to appreciate and avoid self-mutilating behaviors, a learning process normally acquired by painful experiences. Cusumano et al.<sup>69</sup> reported that the use of carbamazepine may be beneficial for children with Lesch-Nyhan syndrome.

### ABNORMAL FRENUM ATTACHMENT

A frenum is a membranous fold that joins two parts and restricts the individual movement of each. Henry et al.<sup>70</sup> have described frenum as a mucous membrane fold containing epithelium and connective tissue fibers but no muscle. In contrast, Ross et al.<sup>71</sup> histologically analyzed 40 frenal biopsy specimens and found that 37.5% of the specimens contained skeletal or striated muscle. A normal frenum attaches apically to the free gingival margin so as to not exert a pull on the zone of the attached gingiva, usually terminating at the mucogingival junction. Although a wide variety of aberrant positions occur, commonly observed locations of frena in the child are on the facial gingival surface of the anterior midline of the maxilla, on the facial and lingual gingival surfaces of the anterior midline of the mandible, and on the mandibular and maxillary premolar facial area. Some frena have bifid and trifid attachments to the alveolar process.

An abnormal or high frenum is present when there is inadequate attached gingiva in the terminal insertion area. A frenum attached too closely to the gingival margin may interfere with proper toothbrush placement, may cause opening of the gingival crevice during function, or may interfere with speech. Furthermore, an abnormally high frenum can apically displace the gingival margin which leads to exposure of the root surface and subsequent plaque accumulation. As a result, the tooth would be at an increased risk of developing root caries and the surrounding periodontal tissues will be severely inflamed (see Fig. 15.36). High frenum attachments may also be associated with isolated gingival recessions and diastemas; however, a cause-and-effect relationship cannot be established.

On the lingual side, an abnormally thick, short lingual frenum that connects the underside of the tongue to the floor of the mouth characterizes a congenital condition known as ankyloglossia (tongue-tie).<sup>72</sup> This is of particular concern in breastfed neonates who suffer from ankyloglossia. In an ultrasonic study conducted to assess the biomechanics of neonatal tongue movements during breastfeeding, it was observed that peristaltic-like rhythmic motility of the neonatal tongue is required to create a vacuum which expands the nipple and allows for the milk to be expressed into neonatal oral cavity.<sup>72a</sup> In contrast, neonates with ankyloglossia needed to apply stronger compression on the nipple, which, in turn, resulted in elevated maternal pain and reduced the amount of milk flowing into the infant's oral cavity. Consequently, ankyloglossia may be a risk factor for successful breastfeeding. However, while a lingual frenectomy may seem to be indicated for all ankyloglossia cases, recent evidence has been inconclusive in either supporting or refuting the benefits

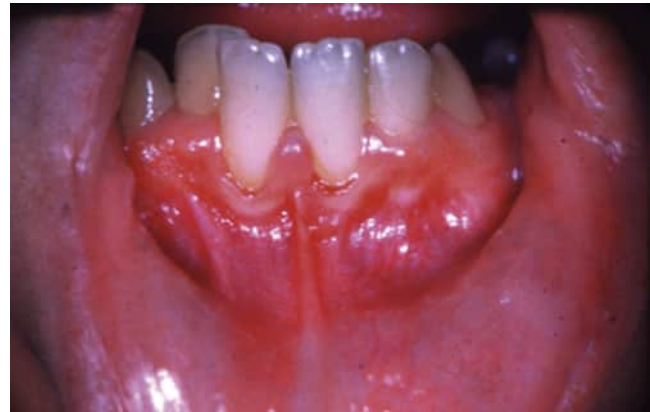

of performing this type of surgical procedure as it relates to breastfeeding outcomes. As such, the decision to proceed with a lingual frenectomy in an infant should be made following careful and thorough deliberation with all members of the health care team (such as the pediatrician, pediatric dentist, ENT specialist, breastfeeding specialist, speech therapist) and family members who are knowledgeable in the possible implications of ankyloglossia, early lingual frenectomies, and breastfeeding outcomes. Indeed, in a study by Dixon et al.,<sup>86,87</sup> a multifaceted program was initiated to improve the care offered to mothers and babies with breastfeeding difficulties. There was concern that overemphasis on tongue-tie may delay access to the most appropriate breastfeeding support and that unnecessary frenotomy surgery may have been provided. A program was introduced to evaluate the diagnosis and treatment of frenulum releases in newborn infants with suspected tongue-tie (ankyloglossia). This embedded an expert breastfeeding review and assessment of lingual function using a validated method, the Bristol Tongue-tie Assessment Tool. An education program was developed to support introduction of the new clinical pathway and included seminars and online information for health care professionals and the general public. The results showed that frenotomy intervention rate reduced markedly within 2 years from 11.3% in 2015 to 3.5% and feeding methods were not different before or after surgery between infants who received a frenotomy and those who did not. It should be noted that normal function can occur with a mild form of ankyloglossia, and the frenum may lengthen with normal growth and maturation of the child. Thus, a lingual frenectomy may not be needed for all ankyloglossia cases.

On the facial aspect, a mandibular anterior frenum occasionally inserts into the free or marginal gingival tissue and causes subsequent recession and pocket formation. The abnormal frenum attachment is most often observed in the central incisor area (Fig. 15.36), although it may involve the labial tissue in the canine areas. The abnormal attachment is frequently associated with a vestibular trough that is more shallow than normal throughout the anterior region.

Movements of the lip cause the abnormal frenum to pull on the fibers inserting into the free marginal tissue. Plaque and food accumulates around the abnormally high frenum, thereby causing inflammation and eventual development of a periodontal pocket between the labial surface of the tooth and the vestibular mucosa. Early surgical treatment of the abnormal frenum attachment is indicated to prevent continued stripping of the labial tissue, subsequent loss of alveolar bone, and possible eventual loss of the tooth. Although traumatic occlusion and poor oral hygiene are occasionally associated with the gingival stripping condition, the abnormal frenum attachment is more often the offender.

The maxillary anterior frenum connects the upper lip to the suture line areas between the central incisors. The notion that a frenum may spread apart neighboring central incisors, thereby creating an open contact between the two teeth, has been the subject of debate. The literature indicates that a diastema may be considered normal as the maxillary central incisors erupt and can be expected to close as the other permanent front teeth erupt. Seldom has



**Fig. 15.36** Abnormal attachment of the frenum. The fibers can be seen extending to the papilla between the central incisors, with branching auxiliary fibers inserting into the marginal tissue.

any correlation been found between a maxillary frenum problem and recession.

## FRENOTOMY AND FRENECTOMY

A frenotomy involves an incision of the periosteal fiber attachment and possibly suturing of the frenum to the periosteum at the base of the vestibule. It is associated with less postoperative discomfort than a frenectomy and will usually suffice. A frenectomy involves complete excision of the frenum and its periosteal attachment. A frenectomy is indicated when large, fleshy frena are involved. The need for a frenectomy or frenotomy should be based on the individual's ability to maintain gingival health. The surgical management of the abnormal maxillary labial frenum is presented in Chapter 43 (Figs. 3.50–3.52).

Indications for treating a high frenum include the following:

1. A high frenum attachment associated with an area of persistent gingival inflammation that has not responded to root planing and good oral hygiene
2. A frenum associated with an area of recession that is progressive
3. A high maxillary frenum and an associated midline diastema that persist after complete eruption of the permanent canines
4. A mandibular lingual frenum that inhibits the tongue from touching the maxillary central incisors. This would interfere with the child's ability to make /t/, /d/, and /l/ sounds. As long as the child has enough range of motion to raise the tongue to the roof of the mouth, no surgery would be indicated. Most children cannot normally make these sounds until after 6 or 7 years of age. Speech therapy may be indicated.

If a high frenum is associated with an area of no or minimal keratinized gingiva and a frenotomy or frenectomy is indicated, a gingival graft or vestibular extension should be used to augment the procedure. Under these circumstances, a frenotomy or frenectomy often does not create stable long-term results. Bohannan<sup>73–75</sup> indicated that, if there is an adequate band of attached gingiva, high frena and vestibular depth do not pose a problem. Use of the latter



procedures to accomplish elimination of the frenum pull is considered a more standard approach.

### TECHNIQUE FOR MANDIBULAR FRENECTOMY AND VESTIBULAR DEPTH INCREASE

Bohannan<sup>73–75</sup> has published a series of reports of his studies in the alteration of vestibular depth and frenectomy. Three different surgical procedures, referred to as complete denudation, periosteum retention, and vestibular incision, were studied as methods to produce increased vestibular depth and frenum alteration.

#### Complete Denudation

The complete denudation procedure is preceded by a routine gingivectomy extending laterally to the first premolars. By blunt dissection, the periosteum and adherent fibrous tissue are detached apically, and the labial plate is exposed to a depth of approximately 12 mm. The resulting soft tissue flap is removed by excision. A rapid-setting dressing is placed directly over the osseous tissue and is changed at 7-day intervals for 4 weeks.

#### Periosteum Retention

The periosteum retention procedure, as described by Bohannan, does not always result in maintenance of the desirable amount of vestibular depth.<sup>74</sup> The procedure is essentially the same as that described previously, except that the periosteum is retained.

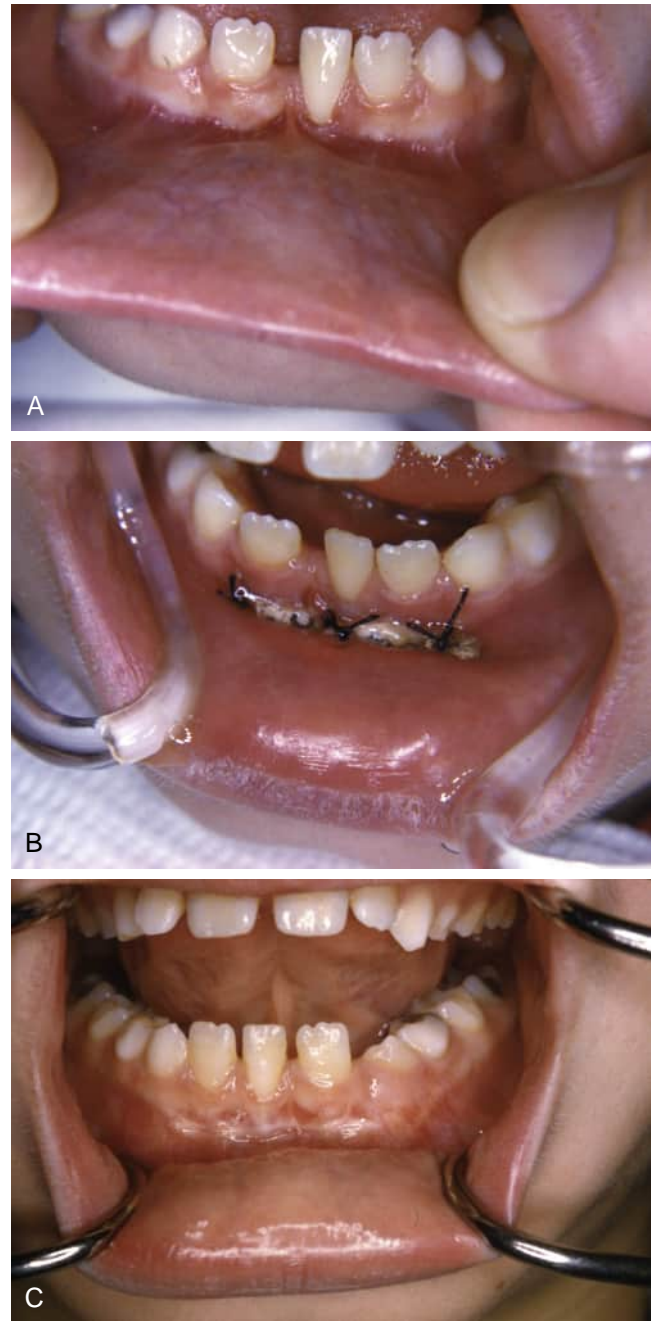#### Vestibular Incision

The vestibular incision method (mandibular frenectomy) is a surgical procedure that has been used with success. The elimination of the abnormal frenum should remain the objective of the procedure, although it is often desirable to alter the vestibular depth also. However, the frenum is the primary etiologic factor in the stripping of the gingival tissue and labial pocket formation.

A preliminary prophylactic procedure should be performed to remove hard deposits, debris, and plaque material from the teeth. The surgical procedure should be more extensive than a conservative incision of the frenum. Such a procedure would allow the muscle fibers to reattach, with resultant scar tissue formation, and would perhaps make the condition more severe (Fig. 15.37A–C).

A local anesthetic is administered prior to the surgical procedure. Administration of a right and a left inferior alveolar injection is the method of choice. Some dentists prefer to inject the local anesthetic solution throughout the operative field. However, caution should be exercised because the anesthetic may distend the tissue, which makes it more difficult to find landmarks during the surgical procedure.

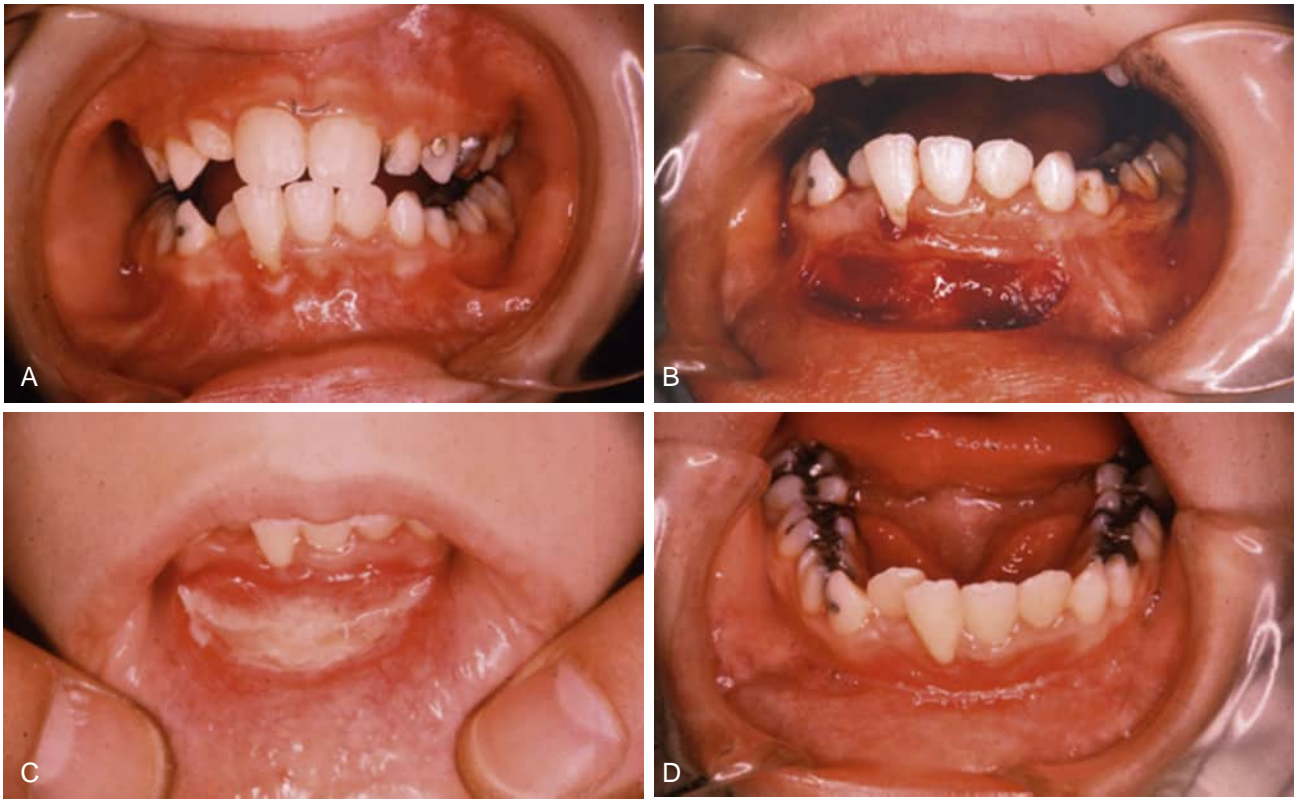The lower lip should be stretched outward and downward, and an incision approximately 1 cm in depth beyond the level of the vestibular trough should be made at a right angle to the underlying bone. The incision is made at the junction of the mucobuccal fold and attached gingiva, and should extend at least two teeth on either side of the attachment. If the abnormal attachment is on the incisor area, an incision is often made from an area opposite one canine to the canine on the other side of the mouth. The connective tissue and muscle attachments are then freed by blunt



**Fig. 15.37** (A) Tissue has been stripped and a pocket formed on the labial surface of the right central incisor. A frenectomy procedure to increase the depth of the vestibular trough is indicated. (B) An incision has been made, and a pack has been placed and secured with three sutures. (C) Three months after the operation, improvement in the health of the gingival tissue in the mandibular anterior region is evident.

dissection with a periosteal elevator (Fig. 15.38A–C). No attempt is made to strip the underlying periosteum.

A periodontal pack or some type of splint must be used to prevent reattachment of the tissue and to allow granulation to occur at a greater depth. A piece of rubber tubing 2–3 mm in diameter and the exact length of the incision can be coated with surgical paste and sutured in the trough. The patient is seen 24 hours postoperatively, and any granulation tissue that has developed over the ends of the tubing



**Fig. 15.38** (A) Stripping of the tissue and loss of alveolar bone from the labial aspect of the mandibular right central incisor are related to an abnormal frenum attachment and shallow vestibule. (B) An incision has been made, and the connective tissue and muscle attachments have been freed by blunt dissection. (C) One week after the operation, there is evidence of granulation tissue. (D) An improvement is evident in the gingival contour of the tissue surrounding the right central incisor.

is removed. The pack is normally removed after 4 or 5 days, and the wound is irrigated as necessary until healing occurs.

As an alternative method of encouraging healing at a new depth, the entire surgical wound is filled with a stiff periodontal dressing of the zinc oxide–eugenol type. The pack, which extends over the labial surfaces of the anterior teeth, may be covered with dry foil and allowed to remain for 3–4 weeks with only weekly changes. Some dentists ligate an acrylic splint to the teeth after surgery to aid in the reestablishment of the new sulcular depth.

### FREE SOFT TISSUE AUTOGRAFT (PREVIOUSLY KNOWN AS THE FREE GINGIVAL AUTOGRAFT) PROCEDURE

The AAP's Glossary of Periodontal Terms describes a free soft tissue autograft procedure (FSTA) as a surgical procedure that involves transplanting donor tissue composed of both epithelial and connective tissue from one area of the mouth to another. Previous terms of FSTA were referred to as *free gingival autograft* or *free gingival graft*. However, the term was revised as the donor tissue is composed of not only gingival tissue but also connective tissue. The FSTA procedure may be considered for children and young adults when there is a tooth with a prominent root convexity that is complicated by either a complete or a partial lack of keratinized gingiva, a shallow vestibular fornix, or a high midline frenum attachment (Fig. 15.39). FSTA is also indicated when there are areas of root exposure that are of aesthetic

concern to the patient, when the labial gingiva of some teeth require subgingival crown margins, when teeth with a narrow band of keratinized gingiva are clasped by a removable dental prosthesis, and when teeth with inadequate labial keratinized gingiva need orthodontic movement, which makes them more prominent in the arch. When these indications are kept in mind, it will be apparent to the clinician that FSTA is not always the best procedure. There may be an aesthetic concern with the surrounding gingiva because the autograft will remain the same color and texture as the palatal donor site (Fig. 15.40). If root coverage and aesthetics is the goal, the connective tissue graft, laterally positioned pedicle graft, and coronally positioned flap procedures are preferable. When the amount of attached gingiva is adequate, FSTA is not indicated. If pocket elimination is a concern, an apically repositioned flap should be a choice.

In the FSTA procedure, the receptor site is first prepared. When a high frenum attachment has contributed to the mucogingival problem, tension is placed on the lower lip to activate the frenum and trace its insertion into the marginal tissue. A horizontal incision is made at the mucogingival junction, including the attachment of the frenum to the gingiva. The mucosa is displaced apically by blunt dissection, and a non-movable receptor site is left, consisting of periosteum and a thin covering of firm connective tissue. Any gingival epithelium coronal to the primary incision is trimmed away, which leaves a receptor bed of connective tissue with an adequate blood supply.

The next step is to fenestrate the periosteum to help prevent mobility of the graft after healing. To do this, two



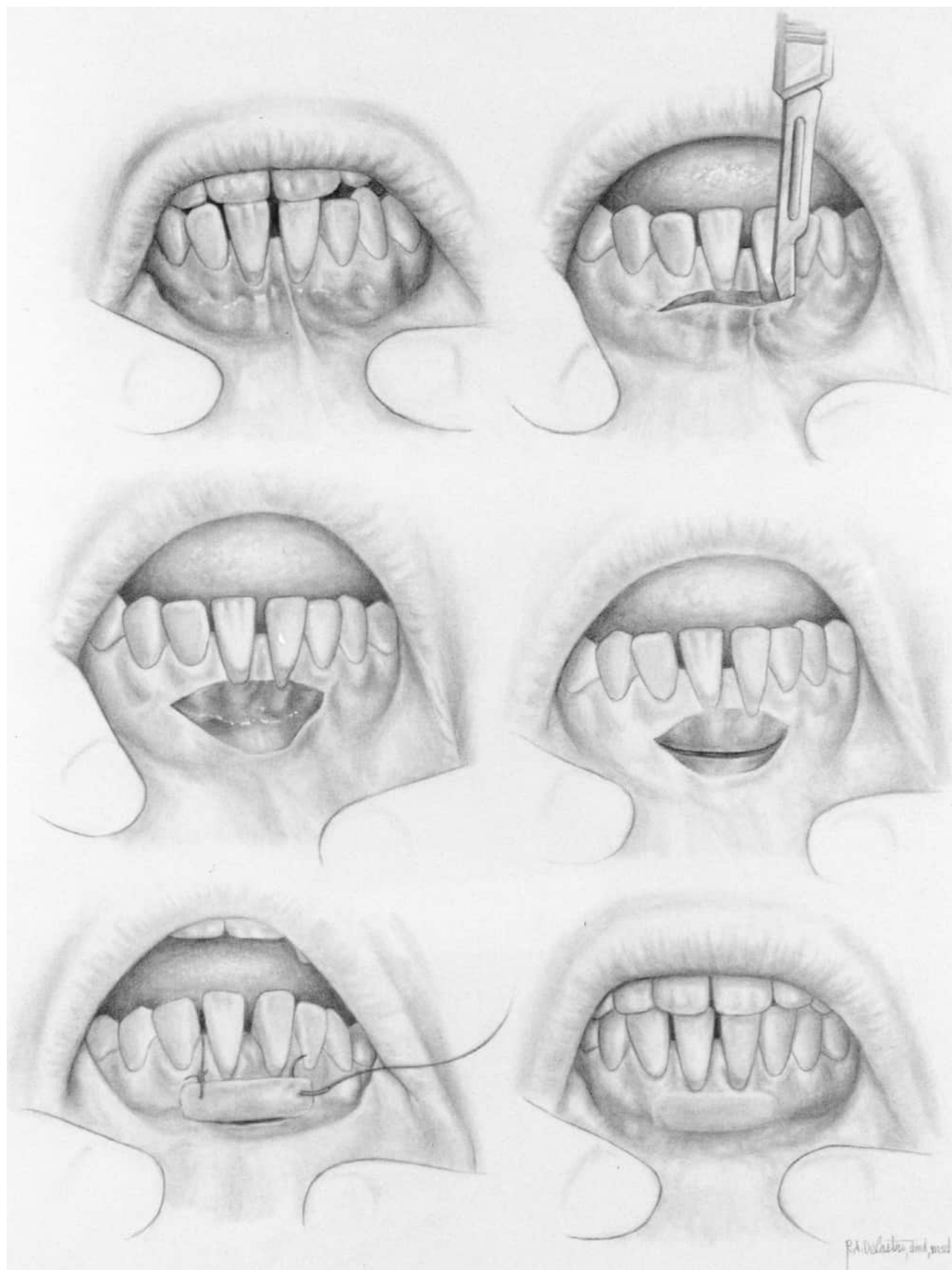
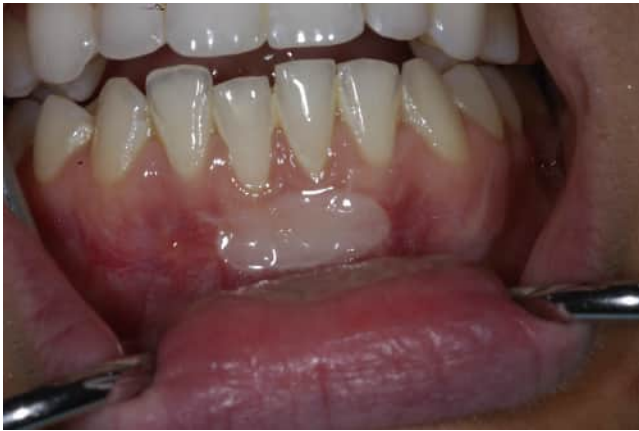

Fig. 15.39 The free gingival graft procedure may be considered for children and adults when there is a shallow vestibular fornix and a high midline frenum attachment.





**Fig. 15.40** Two-year clinical postoperative appearance of a free gingival graft. Note the color mismatch of the free gingival graft with the surrounding soft tissue.

horizontal incisions, 1 mm apart, are made through the periosteum at the apical boundary of the displaced mucosa. The isolated periosteum between the two horizontal incisions is peeled away so that the facial cortical plate of bone is exposed. A template of adhesive foil slightly larger than the mandibular receptor site is made, and the palatal donor site is anesthetized. The template is placed on the anesthetized tissue and is outlined with a shallow incision. The graft is then gently freed from the underlying submucosa by sharp dissection. The operator should strive to secure an intermediate-thickness graft (approximately 1 mm thick).

After the graft is removed from the palate, the connective tissue side is inspected to ensure that no fatty tissue remains on it (adherent fatty tissue would prevent revascularization of the graft from the connective tissue of the receptor site). If present, the fatty tissue is carefully dissected from the graft with a sharp scalpel blade. The graft is carried to the receptor site, and any final trimming is done to secure an approximation of the donor tissue to the receptor site. The graft is stabilized onto the recipient site using a thin non-resorbable or resorbable suture with an atraumatic (tapered) needle. Multiple sling sutures, horizontal sutures, and interrupted sutures are routinely needed to secure and immobilize the graft over the recipient site. Depending on the case, a periodontal dressing may be placed over the graft to protect it. When the patient returns 7–10 days after surgery, the dressing (if previously applied) is removed, the area is debrided and irrigated, and the sutures are removed.

By 7–10 days, the graft should be firmly fixed to the underlying receptor site, and the epithelial covering should be continuous with that of the contiguous gingiva and oral mucosa. The patient is instructed to gently clean away any debris from the area with a cotton ball soaked in warm water and to continue the interdental flossing routine. Normal brushing can usually be reintroduced between 21 and 25 days after FSTA has successfully integrated to the recipient site.

## LASERS

Within the last few decades, lasers have been used to perform selective caries removal (with special care to avoid pulpal damage of vital teeth), pulpotomies, and incisional

or excisional soft tissue biopsies. The term “laser” stands for “light amplification by stimulated emission of radiation.” Upon absorption of the laser wavelength, the light energy is converted into thermal energy (heat) in the targeted tissue, thereby triggering a photothermal effect. In other words, as heat builds up in the affected tissue, the targeted area will undergo physical and biological changes: coagulation at 65°C to 90°C, protein denaturation at 90°C to 100°C, or vaporization over 100°C.<sup>77</sup>

A laser’s biological effect is dependent on the targeted tissue’s affinity to a specific wavelength of laser energy.<sup>76</sup> For instance, a CO<sub>2</sub> laser wavelength (10,600 nm) is readily absorbed by tissue that has high water content. This makes CO<sub>2</sub> laser ideal in soft tissue excisional procedures, such as frenectomies, operculum removal, or soft tissue lesion biopsies. In comparison, an Nd:YAG laser emits an energy beam at 1064 nm and is also absorbed by tissue high in water content but not as readily as a CO<sub>2</sub> laser. However, unlike a CO<sub>2</sub> laser, an Nd:YAG laser is readily absorbed by pigmented soft tissue which allows for the excision of pigmented tissues, pigmented lesions, or hemorrhagic lesions. A diode laser (819 nm) is similar to the Nd:YAG laser in its affinity for pigmented tissues and hemorrhagic tissues. An Er:YAG laser (2940 nm) and Er,Cr:YSGG laser (2780 nm) emit wavelengths that have a strong affinity for tissue with high water content and/or high hydroxyapatite content. Therefore, Er:YAG and Er,Cr:YSGG lasers are more appropriate for soft tissue removal procedures, removal of osseous tissue, and cavity preparations.

In periodontology, lasers have been introduced as an alternative to conventional nonsurgical and surgical periodontal therapy.<sup>78</sup> Purportedly, the laser used in periodontology emits an energy beam that is readily absorbed by inflamed, hemorrhagic tissue which ablates the diseased pocket epithelium while preserving the noninflamed healthy tissue. Additionally, because the Nd:YAG laser is attracted to pigment, pathogenic black-pigmented bacteria (such as *Porphyromonas* and *Prevotella* spp) absorb the energy and are lysed. However, although lasers have the potential to be revolutionary technology in periodontology, evidence to support the use of lasers to treat periodontitis remains inconclusive.<sup>79</sup> Further research is still necessary to determine the effectiveness and predictability of lasers to treat periodontitis.

## Clinical Assessment of Oral Cleanliness and Periodontal Disease

### PLAQUE CONTROL RECORD

O’Leary et al.<sup>80</sup> developed the plaque control record to give the dentist, hygienist, and dental educator a simple method of recording the presence of plaque on individual tooth surfaces (mesial, distal, facial, and lingual).

At the initial appointment, a suitable disclosing solution, such as Bismarck brown, is painted on all exposed tooth surfaces. After the patient has rinsed, the operator, using an explorer, examines each stained surface for soft accumulations at the dentogingival junction. When found, these



(right and left maxillary and mandibular). The gingival sulcus depth of each tooth or implant is measured in at least six areas (three facial and three lingual areas) by gentle probing with a periodontal probe in the standard manner. Each sextant is scored for periodontal health based on a code number from 0 to 4 as follows:

- Code 0 indicates that all sulcus depths in the sextant are 3.5 mm or less; no calculus is present and no gingival bleeding occurred from the gentle probing.
- Code 1 indicates that all sulcus depths are 3.5 mm or less; no calculus is present, but some bleeding occurred from the gentle probing.
- Code 2 indicates that all sulcus depths are 3.5 mm or less; some calculus is present. Supra or subgingival calculus and/or defective margins are detected.
- Code 3 indicates that one or more sulcus depths are between 3.5 and 5.5 mm.
- Code 4 indicates that one or more sulcus depths are more than 5.5 mm.

In addition to the code number, an asterisk (\*) may accompany the code score to indicate furcation involvement, abnormal tooth mobility, mucogingival problems, or significant gingival recession.

Appropriate preventive care, oral hygiene instruction, and therapy (plaque and calculus removal) are indicated, as required, for patients who receive PSR code scores of 2, 1, or 0. Patients receiving code scores of 3 or 4 require more comprehensive periodontal evaluation and treatment.

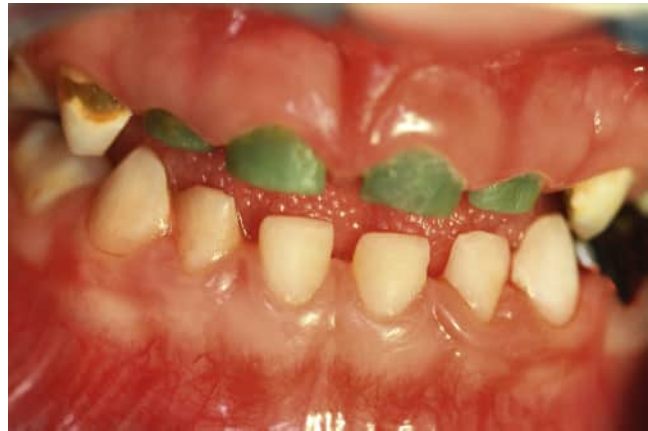## Extrinsic Stains and Deposits on Teeth

Previous work regarding the staining of children's teeth has been related primarily to studies of orange and green stain of the extrinsic type. It has been generally accepted that this stain is of microbial origin, although some reports have indicated that oral iron preparations or other medications may be responsible for an additional type of extrinsic staining. The accumulation of dental deposits and stains is affected by salivary composition and flow rates, poor oral hygiene, enamel defects, and aging with exposed extrinsic factors (medications, coffee, tea, tobacco, and intrinsic physiological changes). Extrinsic stains are identified by color, distribution, and tenaciousness along with age, gender, and home care.

Staining is generally believed to be caused by extrinsic agents, which can be readily removed from tooth surfaces with an abrasive material. The agents responsible for staining are deposited in enamel defects or become attached to the enamel without bringing about a change in its surface. Pigmentation, in contrast to extrinsic staining, is associated with an active chemical change in the tooth structure, and the resulting pigment cannot be removed without alteration of the tooth structure.

### GREEN STAIN

The cause of green stain, which is most often seen on the teeth of children, is unknown although it is believed to be the result of the action of chromogenic bacteria on the



**Fig. 15.42** Dark green stain is evident on the maxillary anterior teeth. Papillary and marginal gingivitis is also present. The patient had poor oral hygiene and was a mouth-breather.

enamel cuticle. Boys are more frequently affected than girls. The color of the stain varies from dark green to light yellowish-green. This tenacious deposit is seen most often in the gingival third of the labial surfaces of the maxillary anterior teeth in mouth breathers. It tends to recur even after careful and complete removal. The enamel beneath the stain may be roughened or may have undergone initial demineralization. The roughening of the surface is believed to be related to the frequency of recurrence of the stain (Fig. 15.42). Fungi (*Penicillium* and *Aspergillus*) and fluorescent bacteria have been associated with the discoloration.

### ORANGE STAIN

The cause of orange stain is likewise unknown. Orange stain occurs less frequently and is more easily removed than green or brown stain. The stain is most often seen in the gingival third of the tooth and is associated with poor oral hygiene (Fig. 15.43).

### BLACK STAIN

A black stain occasionally develops on the primary or permanent teeth of children, but it is much less common than the orange or green type (Fig. 15.44). A thin black line of dots or band of stain may be seen following the gingival contour or it may be apparent in a more generalized pattern on the clinical crown, particularly if there are roughened or pitted areas. The black stain is difficult to remove, especially if it collects in pitted areas. It has been reported more frequently in females. Many children who have black stain are relatively free of dental caries and have excellent oral hygiene. The chromogenic bacterium primarily associated with this stain is *Actinomyces*.<sup>82</sup>

### REMOVAL OF EXTRINSIC STAINS

Extrinsic stains can be removed by polishing with a rubber cup and flour of pumice. If the stain is resistant and difficult to remove, the excess water should be blotted from the pumice and the teeth should be dried before the polishing



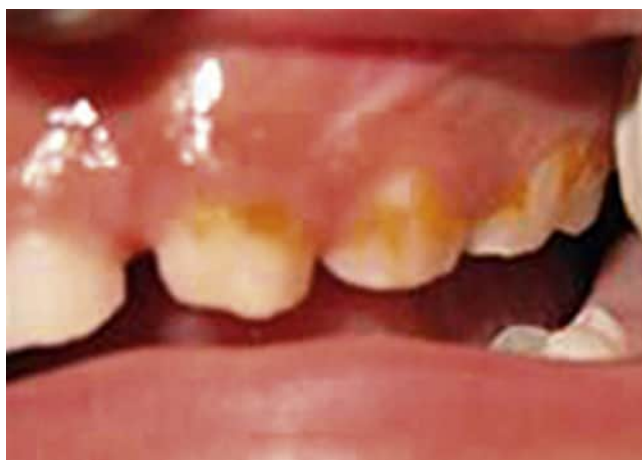

Fig. 15.43 Orange stain is evident in the gingival half of the maxillary left posterior teeth.

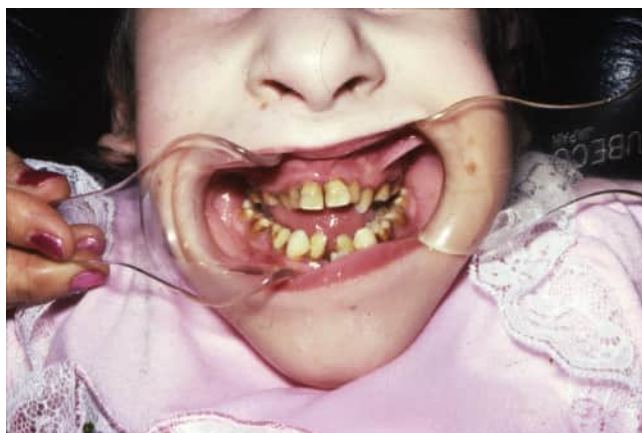

Fig. 15.44 Black stain is evident on the primary teeth. The stain is difficult to remove, particularly when it collects in roughened areas of the tooth.

procedure is performed. Because stains are most often seen in a mouth in which there is poor oral hygiene, improving the oral hygiene minimizes the recurrence of the stain.

### PIGMENTATION CAUSED BY STANNOUS FLUORIDE APPLICATION

During the first clinical trials involving the topical application of an 8% stannous fluoride solution, certain areas of the tooth became discolored. A characteristic pigmentation of both caries and pre-carious lesions has been found to be associated with exposure to stannous fluoride.

## Calculus

Calculus is not often seen in preschool children, and even in children of grade-school age, it occurs with much lower frequency than in adult patients. A low caries incidence is related to high calculus incidence. Bhat<sup>83</sup> reported findings in 14- to 17-year-old children who participated in the 1986-1987 National Survey of Oral Health. Supragingival calculus was observed in nearly 34% of the children and

subgingival calculus in approximately 23%. Both types showed a predilection for molars in the maxilla and incisors and canines in the mandible. Children with intellectual developmental disorders often have accumulations of calculus on their teeth. This accumulation may be related to difficulty in focusing on routine patient self-care, abnormal muscular function, a poor diet, and stagnation of saliva.

The observations of Turesky et al.<sup>84</sup> regarding early calculus formation in children and adults substantiate those of previous reports which indicate that calculus begins as a soft, adherent, bacteria-laden plaque that undergoes progressive calcification over time. They observed calculus formation on cellulose acetate strips that were fixed in children's mouths. Plaque material that accumulated on the strips underwent progressive calcification. A soft plaque material consisted, for the most part, of bacteria appearing as a dense meshwork of diffusely distributed gram-negative cocci with occasional rod forms. Filamentous or thread-shaped organisms were scarce. Leukocytes and epithelial cells were also scattered within the amorphous matrix.

Supragingival deposits of calculus occur most frequently and in greater quantity on the buccal surfaces of the maxillary molars and the lingual surfaces of the mandibular anterior teeth. These areas are near the openings of the major salivary glands. Local factors are unquestionably important in the initiation of calculus formation. Furthermore, since calculus has a rough and porous outer surface, it can serve as a nidus of bacterial plaque accumulation. Thus, periodontal inflammation will persist so long as the calculus deposit remains either in close proximity to the gingiva or remains located subgingivally. Every effort must therefore be made to mechanically remove both supra- and subgingival plaque biofilm deposits and calculus deposits.

### References

1. Delaney JE: Periodontal and soft-tissue abnormalities, *Dent Clin North Am* 39(4):837-850, 1995.
2. Armitage GC: Development of a classification system for periodontal disease and conditions, *Ann Periodontol* 4(1):1-6, 1999.
3. American Academy of Pediatric Dentistry: Reference manual 2013-2014, *Pediatr Dent* 35(Suppl 6):338-345, 2013.
4. Eastcott AD, Stallard RE: Sequential changes in developing human dental plaque as visualized by scanning electron microscope, *J Periodontol* 44(4):218-224, 1973.
5. Suomi JD, Smith LW, McClendon BJ, et al.: Oral calculus in children, *J Periodontol* 42(6):341-345, 1971.
6. Weddell JA, Klein AI: Socioeconomic correlation of oral disease in 6- to 36-month children, *Pediatr Dent* 3(4):306-310, 1981.
7. Horowitz AM, Suomi JD, Peterson JK, et al.: Effects of supervised daily dental plaque removal by children after 3 years, *Community Dent Oral Epidemiol* 8(4):171-176, 1980.
8. Murray JJ: The prevalence of gingivitis in children continuously resident in a high fluoride area, *J Dent Child* 41(2):133-139, 1974.
9. Matsson L, Moller C: Gingival inflammatory reactions in children with rhinoconjunctivitis due to birch pollinosis, *Scand J Dent Res* 98(6):504-509, 1990.
10. Schaaf JE: Non-dental pharmacotherapeutics, *Alumni Bull Sch Dent Indiana Univ Spring* 48-53, 1984.
11. Faden H: Management of primary herpetic gingivostomatitis in young children, *Pediatr Emerg Care* 22(4):268-269, 2006.
12. Hale BD, Rendtorff RC, Walker LC, et al.: Epidemic herpetic stomatitis in orphanage children, *Dent Abst* 8:556, 1963.
13. Kleinman DV, Swango PA, Pindborg JJ: Epidemiology of oral mucosal lesions in United States schoolchildren: 1986-87, *Community Dent Oral Epidemiol* 22(4):243-253, 1994.
14. Griffith RS, Norins AL, Kagan C: A multicentered study of lysine therapy in herpes simplex infection, *Dermatologica* 156(5):257-267, 1978.

15. Brooks SL, Rowe NH, Drach JC, et al.: Prevalence of herpes simplex virus disease in a professional population, *J Am Dent Assoc* 102(1):31–34, 1981.
16. Scully C, Porter S: Oral mucosal disease: recurrent aphthous stomatitis, *Br J Oral Maxillofac Surg* 46(3):198–206, 2008.
17. Ship JA, Chavez EM, Doerr PA, et al.: Recurrent aphthous stomatitis, *Quintessence Int* 31(2):95–112, 2000.
18. Antoon JW, Miller RL: Aphthous ulcers: a review of the literature on etiology, pathogenesis, diagnosis, and treatment, *J Am Dent Assoc* 101(5):803–808, 1980.
19. Greenspan JS, Gadol N, Olson JA, et al.: Lymphocyte function in recurrent aphthous ulceration, *J Oral Pathol* 14(8):592–602, 1985.
20. Binnie WH, Curro FA, Khandwala A, et al.: Amlexanox oral paste: a novel treatment that accelerates the healing of aphthous ulcers, *Compendium Contin Educ Dent* 18(11):1116–1118, 1120–1122, 1124–1126, 1991.
21. Meiller TF, Kutcher MJ, Overholser CD, et al.: Effect of an antimicrobial mouth rinse on recurrent aphthous ulcerations, *Oral Surg Oral Med Oral Pathol* 72(4):425–429, 1991.
22. Glauser RO, Humphreys PK, Stanley HR, et al.: An unusual gingivitis among Navajo Indians, *Periodontics* 1:255–259, 1963.
23. Grossman E, Reiter G, Sturzenberger OP, et al.: Six-month study of the effects of chlorhexidine mouthrinse on gingivitis in adults, *J Periodontol Res* 21:33–43, 1986.
24. Banting D, Bosma M, Bollmer B: Clinical effectiveness of a 0.12% chlorhexidine mouthrinse over two years, *J Dent Res* 68:1716–1718, 1989.
25. Quirynen M, Avontroodt P, Peeters W, et al.: Effect of different chlorhexidine formulations in mouthrinses on de novo plaque formation, *J Clin Periodontol* 28(12):1127–1136, 2001.
26. Loe H, Schiött CR: The effect of mouthrinses and topical application of chlorhexidine on the development of dental plaque and gingivitis in man, *J Periodontol Res* 5(2):79–83, 1970.
27. Yankell SL, Emling RC, Prencipe M, et al.: Laboratory and clinical stain removal evaluations of two tartar control dentifrices, *J Clin Dent* 6(4):207–210, 1995.
28. Brex M, Brownsone E, MacDonald L, et al.: Efficacy of Listerine, Meridol and chlorhexidine mouthrinses as supplements to regular tooth-cleaning measures, *J Clin Periodontol* 19(3):202–207, 1992.
29. Barnett ML: The rationale for the daily use of an antimicrobial mouthrinse, *J Am Dent Assoc* 137(Suppl 7):S16–S21, 2006.
30. Cohen MM: The effect of large doses of ascorbic acid on gingival tissue at puberty, *J Dent Res* 34:750–751, 1955. (abstract).
31. Nakagawa S, Fujii H, Machida Y, et al.: A longitudinal study from prepuberty to puberty of gingivitis, *J Clin Periodontol* 21(10):658–665, 1994.
32. Sutcliffe P: A longitudinal study of gingivitis and puberty, *J Periodontol Res* 7(1):52–58, 1972.
33. De Pommereau V, Dargent-Pare C, Robert JJ, et al.: Periodontal status in insulin-dependent diabetic adolescents, *J Clin Periodontol* 19(9):628–632, 1992.
- 33a. Karjalainen KM, Knuuttila MLE, The onset of diabetes and poor metabolic control increases gingival bleeding in children and adolescents with insulin-dependent diabetes mellitus, *J Clin Perio* 23(12):1060–1067, 1996 <https://doi.org/10.1111/j.1600-051X.1996.tb01804.x>.
34. Zackin SJ, Weisberger D: Hereditary gingival fibromatosis: report of a family, *Oral Surg Oral Med Oral Pathol* 14(7):825–835, 1961.
35. Brown RS, Trejo PC, Weltman R, et al.: Treatment of a patient with hereditary gingival fibromatosis: a case report, *Spec Care Dentist* 15(4):149–153, 1995.
36. Kimball OP: Treatment of epilepsy with sodium diphenylhydantoinate, *J Am Med Assoc* 112:1244–1245, 1939.
37. Casetta I, Granieri E, Desiderá M, et al.: Phenytoin-induced gingival overgrowth, a community-based cross-sectional study in Ferrara, Italy, *Neuroepidemiology* 16(6):296–303, 1997.
38. Hassell TM, Page RC, Narayanan AS, et al.: Diphenylhydantoin (Dilantin) gingival hyperplasia: drug-induced abnormality of connective tissue, *Proc Natl Acad Sci USA* 73(8):2909–2912, 1976.
39. Addy V, McElnay JC, Eyre DG, et al.: Risk factors in phenytoin-induced gingival hyperplasia, *J Periodontol* 54(6):373–377, 1983.
40. Kapur RN, Girgis S, Little TM, et al.: Diphenylhydantoin-induced gingival hyperplasia: its relationship to dose and serum level, *Dev Med Child Neurol* 15(4):483–487, 1973.
41. Little TM, Girgis SS, Masotti RE: Diphenylhydantoin-induced gingival hyperplasia: its response to changes in drug dosage, *Dev Med Child Neurol* 17(4):421–424, 1975.
42. Livingston S, Puce I, Pauli LL, et al.: The medical treatment of epilepsy: managing side effects of antiepileptic drugs, *Pediatr Ann* 8(4):261–266, 1979.
43. Ciancio SG, Yaffe SJ, Catz CC: Gingival hyperplasia and diphenylhydantoin, *J Periodontol* 43(7):411–414, 1972.
44. Sasaki T, Maita E: Increased BfGF level in the serum of patients with phenytoin-induced gingival overgrowth, *J Clin Periodontol* 25(1):42–47, 1998.
45. Jones JE, Weddell JA, McKown CG: Incidence and indications for surgical management of phenytoin-induced gingival overgrowth in a cerebral palsy population, *J Oral Maxillofac Surg* 46(5):385–390, 1988.
46. Steinberg SC, Steinberg AD: Phenytoin-induced gingival overgrowth control in severely retarded children, *J Periodontol* 53(7):429–433, 1982.
47. Donnenfeld OW, Stanley HR, Bagdonoff L: A nine-month clinical and histological study of patients on diphenyl hydantoin following gingivectomy, *J Periodontol* 45(8P1):547–557, 1974.
48. Davis RK, Baer PN, Palmer JH: A preliminary report on a new therapy for Dilantin gingival hyperplasia, *J Periodontol* 34(1):17–22, 1963.
49. Sheridan PJ, Reeve CM: Effective treatment of Dilantin gingival hyperplasia, *Oral Surg Oral Med Oral Pathol* 35(1):42–46, 1973.
50. Steinberg AD: Clinical management of phenytoin-induced gingival overgrowth in handicapped children, *Pediatr Dent* 3(Spec Iss):130–136, 1981.
51. Drew HJ, Vogel RI, Molofsky W, et al.: Effect of folate on phenytoin hyperplasia, *J Clin Periodontol* 14(6):350–356, 1987.
52. Bäckman N, Holm AK, Hånström L, et al.: Folate treatment of diphenylhydantoin-induced gingival hyperplasia, *Scand J Dent Res* 97(3):222–232, 1989.
53. American Academy of Periodontology: Parameter on aggressive periodontitis, *J Periodontol* 71(Suppl):867–869, 2000.
54. Albandar JM, Brown LJ, Loe H: Clinical features of early-onset periodontitis, *J Am Dent Assoc* 128(10):1393–1399, 1997.
55. Loe H, Brown LJ: Early onset of periodontitis in the United States of America, *J Periodontol* 62(10):608–616, 1991.
56. Deas DE, Mackey SA, McDonnell HT: Systemic disease and periodontitis: manifestations of neutrophil dysfunction, *Periodontol* 2000 32(1):82–104, 2003.
57. Christersson LA, Slots J, Rosling BG, et al.: Microbiological and clinical effects of surgical treatment of localized juvenile periodontitis, *J Clin Periodontol* 12(6):465–476, 1985.
58. Goepferd SJ: Advanced alveolar bone loss in the primary dentition: a case report, *J Periodontol* 52(12):753–757, 1981.
59. Coccia CT, McDonald RE, Mitchell DF: Papillon-Lefevre syndrome: precocious periodontosis with palmar-plantar hyperkeratosis, *J Periodontol* 37(5):408–414, 1966.
60. Canger EM, Celenk P, Devrim I, et al.: Intraoral findings of Papillon-Lefevre syndrome, *J Dent Child* 75(1):99–103, 2008.
61. Gorlin RJ, Sedano H, Anderson VE: The syndrome of palmar-plantar hyperkeratosis and premature periodontal destruction of the teeth, *J Pediatr* 65(6):895–908, 1964.
62. Tinanoff N, Tempro P, Maderazo EG: Dental treatment of Papillon-Lefevre syndrome: 15-year follow-up, *J Clin Periodontol* 22(8):609–612, 1995.
63. Plesset DN: Auto-extraction, *Oral Surg Oral Med Oral Pathol* 12(3):302–303, 1959.
64. Leksell E, Edvardson S: A case of Tourette syndrome presenting with oral self-injurious behaviour, *Int J Paediatr Dent* 15(5):370–374, 2005.
65. Krejci CB: Self-inflicted gingival injury due to habitual fingernail biting, *J Periodontol* 71(6):1029–1031, 2000.
66. Stewart DJ, Kernohan DC: Traumatic gingival recession in infants: the result of a dummy sucking habit, *Br Dent J* 135(4):157–158, 1973.
67. Friedlander AH, Yagiela JA, Paterno VI, et al.: The neuropathology, medical management and dental implications of autism, *J Am Dent Assoc* 137(11):1517–1527, 2006.
68. Littlewood SJ, Mitchell L: The dental problems and management of a patient suffering from congenital insensitivity to pain, *Int J Paediatr Dent* 8(1):47–50, 1998.
69. Cusumano FJ, Penna KJ, Panossian G: Prevention of self-mutilation in patients with Lesch-Nyhan syndrome: review of literature, *J Dent Child* 68(3):175–178, 2001.
70. Henry SW, Levin MP, Tsaknis PJ: Histologic features of the superior labial frenum, *J Periodontol* 47(1):25–28, 1976.

71. Ross RO, Brown FH, Houston GD: Histologic survey of the frena of the oral cavity, *Quintessence Int* 21(3):233–347, 1990.
72. Suter VG, Bornstein MM: Ankyloglossia: facts and myths in diagnosis and treatment, *J Periodontol* 80(8):1204–1219, 2009.
- 72a. Geddes DT, Kent JC, Mitoulas LR, Hartmann PE. Tongue movement and intra-oral vacuum in breastfeeding infants. *Early Hum Dev.* 2008;84(7):471–7. <https://doi.org/10.1016/j.earlhumdev.2007.12.008>. PMID: PMID 18262736.
73. Bohannon HM: Studies in the alteration of vestibular depth. I. Complete denudation, *J Periodontol* 33(2):120–128, 1962.
74. Bohannon HM: Studies in the alteration of vestibular depth. II. Periosteum retention, *J Periodontol* 33(4):354–359, 1962.
75. Bohannon III HM: Vestibular incision, *J Periodontol* 34:209–215, 1963.
76. Cobb CM: AAP-Commissioned Review: Lasers in periodontics: a review of the literature, *J Periodontol* 77(4):545–564, 2006.
77. American Academy of Periodontology Academy Report: Lasers in periodontics, *J Periodontol* 73(10):1231–1239, 2002.
78. Gregg 2nd RH, McCarthy D: Laser periodontal therapy for bone regeneration, *Dent Today* 21(5):54–59, 2002.
79. American Academy of Periodontology: Statement on the efficacy of lasers in non-surgical treatment of inflammatory periodontal disease, *J Periodontol* 82(4):513–514, 2011.
80. O'Leary TJ, Drake R, Naylor JE: The plaque control record, *J Periodontol* 43(1):38, 1972.
81. Clerehugh V, Tugnait A: Periodontal diseases in children and adolescents: I. Aetiology and diagnosis, *Dent Update* 28(5):222–232, 2001.
82. Slots J: The microflora of black stain on primary teeth, *Scand J Dent Res* 82(7):484–490, 1974.
83. Bhat M: Periodontal health of 14- to 17-year-old US schoolchildren, *J Public Health Dent* 51(1):5–11, 1991.
84. Turesky S, Renstrup G, Glickman I: Histologic and histochemical observations regarding early calculus formation in children and adults, *J Periodontol* 32(1):7–14, 1961.
85. A new classification scheme for periodontal and peri-implant diseases and conditions – Introduction and key changes from the 1999 classification. Caton JG et al. *J Clin Periodontol.* 2018; 45:45 (Suppl 20): S1–S8. <https://doi.org/10.1111/jcpe.12935>.
86. Cairo F, Nieri M, Cincinelli S. The interproximal clinical attachment level to classify gingival recessions and predict root coverage outcomes: an explorative and reliability study. *J Clin Perio* 38(7): 661–66, 2011.
87. Dixon, BJ. Gray N. Elliot B. Shand and A. Lynn. A multifaceted programme to reduce the rate of tongue-tie release surgery in newborn infants: Observational study. *Int J Pediatr Otorhinolaryngol* 113: 156–163, 2018.



## 16

# Local Anesthesia and Pain Control for the Child and Adolescent

JAMES E. JONES and ALLISON C. SCULLY

## CHAPTER OUTLINE

### Topical Anesthetics

#### Jet Injection

#### Local Anesthesia by Conventional Injection

#### Anesthetization of Mandibular Teeth and Soft Tissue

#### Inferior Alveolar Nerve Block (Conventional Mandibular Block)

#### Lingual Nerve Block

#### Long Buccal Nerve Block

#### Infiltration Anesthesia for Mandibular Primary Molars

#### Infiltration for Mandibular Incisors

#### Mandibular Conduction Anesthesia (Gow-Gates Mandibular Block Technique)

#### Anesthetization of Maxillary Primary and Permanent Incisors and Canines

#### Supraperiosteal Technique (Local Infiltration)

#### Anesthetization of Maxillary Primary Molars and Premolars

### Anesthetization of Maxillary Permanent Molars

#### Anesthetization of the Palatal Tissues

#### Nasopalatine Nerve Block

#### Greater (Anterior) Palatine Injection

#### Supplemental Injection Techniques

#### Infraorbital Nerve Block and Mental Nerve Block

#### Periodontal Ligament Injection (Intraligamentary Injection)

#### Intraosseous Injection, Interseptal Injection, and Intrapulpal Injection

#### Computer-Controlled Local Anesthetic Delivery System (WAND)

#### Complications After a Local Anesthetic

#### Anesthetic Toxicity

#### Trauma to Soft Tissue

#### Reversal of Dental Anesthesia

#### Analgesics

One of the most important aspects of child behavior guidance in the dental office is the control of pain during dental procedures. If children experience pain during restorative or surgical procedures, their future as dental patients may be damaged. Therefore it is important at each visit to reduce discomfort to a minimum and to control painful situations. There are many pharmacologic pain control strategies to help children cope with these situations, both preoperatively and postoperatively. Most of these strategies involve the use of local anesthetics or analgesics.

Because there is usually some discomfort associated with the procedure, use of a local anesthetic is generally indicated when operative work is to be performed on the permanent teeth, and the same is true of cavity preparations in primary teeth. Dental procedures can be carried out more effectively if the child is comfortable and free of pain. The local anesthetic can prevent discomfort that may be associated with placing a rubber dam clamp, ligating teeth, and cutting tooth structure. Even the youngest child treated in the dental office normally has no contraindications for the use of a local anesthetic.

Investigators have found that injection is the dental procedure that produces the greatest negative response

in children. Responses become increasingly negative over a series of four or five injections. Venham and Quatrocelli<sup>1</sup> have reported that a series of dental visits desensitizes children to the stressful injection procedure while reducing their apprehension toward relatively nonstressful procedures. Thus dentists should anticipate the need for continued efforts to help the child cope with dental injections.

## Topical Anesthetics

Topical anesthetics reduce the slight discomfort that may be associated with the insertion of the needle before the injection of the local anesthetic. Some topical anesthetics, however, present a disadvantage if they have a disagreeable taste. Also, the additional time required to apply them may increase the child's apprehension concerning the approaching procedure.

Topical anesthetics are available in gel, liquid, ointment, and pressurized spray forms. However, the pleasant-tasting and quick-acting liquid, gel, or ointment preparations seem to be preferred by most dentists. These agents are applied to

the oral mucous membranes with a cotton-tipped applicator. Numerous anesthetic agents have been used in topical anesthetic preparations, including ethyl aminobenzoate, butacaine sulfate, cocaine, dyclonine, lidocaine, and tetracaine.

Ethyl aminobenzoate (benzocaine) liquid, ointment, or gel preparations are probably best suited for topical anesthesia in dentistry. They offer a more rapid onset and longer duration of anesthesia than other topical agents. They are not known to produce systemic toxicity as oral topical anesthetics, but a few localized allergic reactions have been reported from prolonged or repeated use. Examples of commercially available products are Hurricaine (Beutlich L.P. Pharmaceuticals, Inc., Chicago, IL, USA), Topicale (Premier Dental Products, Inc., Plymouth Meeting, PA, USA), and Gingicaine (Gingi-Pak, Inc., Camarillo, CA, USA). All three products are available in gel form. Gingicaine is also available in liquid and spray forms, Hurricaine in a liquid form, and Topicale in ointment and patch forms. All products are supplied in a variety of flavors.

The mucosa at the site of the intended needle insertion is dried with gauze, and a small amount of the topical anesthetic agent is applied to the tissue with a cotton swab. Topical anesthesia usually produces an effect within 30 seconds, although keeping it in place between 2 and 3 minutes may provide the best results.

During the application of the topical anesthetic, the dentist should prepare the child for the injection. The explanation should not necessarily be a detailed description but simply an indication that the tooth is going to be put to sleep so that the treatment can proceed without discomfort.

## Jet Injection

The jet injection instrument is based on the principle that small quantities of liquids forced through very small openings under high pressure can penetrate the mucous membrane or skin without causing excessive tissue trauma. One jet injection device, the Syrijet Mark II (Keystone Industries, Cherry Hill, NJ, USA), holds a standard 1.7-mL cartridge of local anesthetic solution. It can be adjusted to expel 0.05–0.2 mL of solution under 2000 psi pressure.

Jet injection produces surface anesthesia instantly and is used instead of topical anesthetics by some dentists. The method is quick and essentially painless; however the abruptness of the injection may produce momentary anxiety in the patient. This technique is also useful for obtaining gingival anesthesia before a rubber dam clamp is placed for isolation procedures that otherwise do not require local anesthetic. Similarly, soft tissue anesthesia may be obtained prior to band adaptation of partially erupted molars or for the removal of a very loose (soft tissue-retained) primary tooth. A more recently developed jet injection device, reported by Duckworth et al.,<sup>2</sup> delivers a dose of dry powdered anesthetic to the oral mucosa. In this study—an initial trial with 14 adult participants—successful topical analgesia without tissue damage was reported. More clinical trials are required before substantial claims can be made regarding the efficacy of this

technique and whether its routine use for topical anesthesia is warranted.

## Local Anesthesia by Conventional Injection

Wittrock and Fischer,<sup>3</sup> followed by Trapp and Davies,<sup>4</sup> demonstrated that human blood could be readily aspirated with the smaller-gauge needles. Trapp and Davies reported positive aspiration through 23-, 25-, 27-, and 30-gauge needles without a clinically significant difference in resistance to flow. Malamed<sup>5</sup> recommends the use of larger-gauge needles (i.e., 25-gauge) for injection into highly vascular areas or areas where needle deflection through soft tissue may be a factor. Regardless of the size of the needle used, the anesthetic solution should be injected slowly, and the dentist should watch the patient closely for any evidence of an unexpected reaction. The injections that are most commonly used in the treatment of children are described in the following sections.

## Anesthetization of Mandibular Teeth and Soft Tissue

### INFERIOR ALVEOLAR NERVE BLOCK (CONVENTIONAL MANDIBULAR BLOCK)

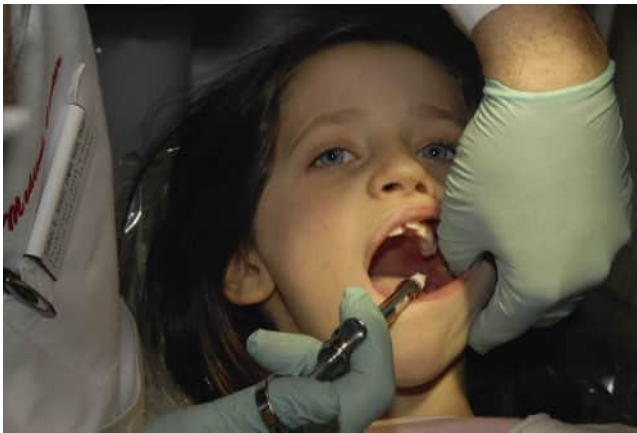In general, when deep operative or surgical procedures are undertaken for the mandibular primary or permanent teeth, the inferior alveolar nerve must be blocked. The supraperiosteal injection technique may sometimes be useful in anesthetizing primary incisors, but it is not as reliable for complete anesthesia of the mandibular primary or permanent molars.

Olsen<sup>6</sup> reported that the mandibular foramen is situated at a level lower than the occlusal plane of the primary teeth of the pediatric patient. Therefore the injection must be made slightly lower and more posteriorly than for an adult patient. An accepted technique is one in which the thumb is laid on the occlusal surface of the molar, with the tip of the thumb resting on the internal oblique ridge and the ball of the thumb resting in the retromolar fossa. Firm support during the injection procedure can be given when the ball of the middle finger is resting on the posterior border of the mandible. The barrel of the syringe should be directed on a plane between the two primary molars on the opposite side of the arch. It is advisable to inject a small amount of the solution as soon as the tissue is penetrated and to continue to inject minute quantities as the needle is directed toward the mandibular foramen.

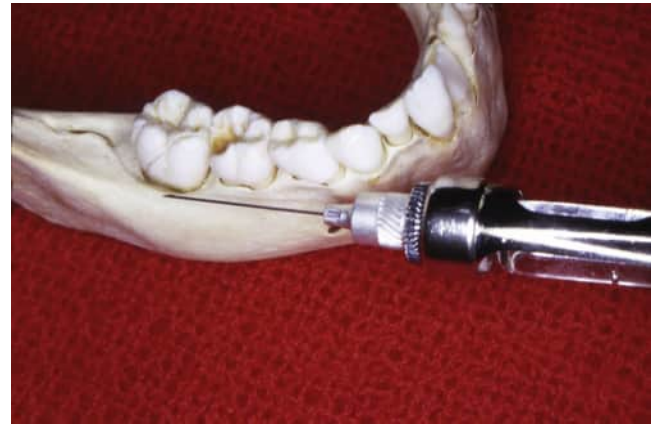The depth of insertion averages about 15 mm but varies with the size of the mandible and its changing proportions depending on the age of the patient. Approximately 1 mL of the solution should be deposited around the inferior alveolar nerve (Figs. 16.1 and 16.2).

### LINGUAL NERVE BLOCK

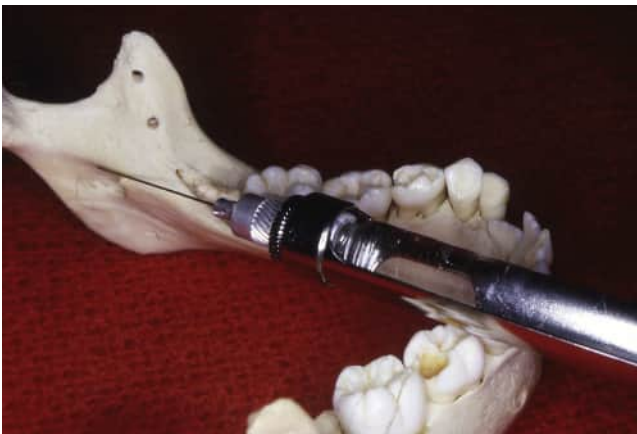One can block the lingual nerve by bringing the syringe to the opposite side with the injection of a small quantity of the solution as the needle is withdrawn. If small amounts of



**Fig. 16.1** The mandible is supported by the thumb and middle finger, while the needle is directed toward the inferior alveolar nerve.



**Fig. 16.3** In anesthetization of the long buccal nerve, a small quantity of the solution may be deposited in the mucobuccal fold adjacent to the first permanent molar.



**Fig. 16.2** Anesthetic solution is deposited around the inferior alveolar nerve.

anesthetic are injected during insertion and withdrawal of the needle for the inferior alveolar nerve block, the lingual nerve will invariably be anesthetized as well.

### LONG BUCCAL NERVE BLOCK

For the removal of mandibular permanent molars or sometimes for the placement of a rubber dam clamp on these teeth, it is necessary to anesthetize the long buccal nerve. A small quantity of the solution may be deposited in the mucobuccal fold at a point distal and buccal to the indicated tooth (Fig. 16.3).

All facial mandibular gingival tissue on the side that has been injected will be anesthetized for operative procedures, with the possible exception of the tissue facial to the central and lateral incisors, which may receive innervation from overlapping nerve fibers from the opposite side.

### INFILTRATION ANESTHESIA FOR MANDIBULAR PRIMARY MOLARS

To test the hypothesis that dental pain control by infiltration/intrapapillary injection was less effective than inferior alveolar block/long buccal infiltration anesthesia in children, Naidu et al.<sup>7</sup> conducted a two-group, randomized, blinded,

controlled design study comparing two local anesthesia techniques using 2% lidocaine with 1:100,000 epinephrine. They studied 101 healthy children, aged 5–8 years, who had no contraindication for local anesthetic and who needed a pulpotomy treatment and stainless-steel crown placement in a mandibular primary molar. All children were given 40% nitrous oxide. Children self-reported pain using the color analog scale (1, indicating “no pain” to 10, indicating “most pain”). The overall pain levels reported by the children were low, and there were no differences between conditions at any point in the procedure. Mean self-reported pain reports for clamp placement were 2.8 for block/long buccal and 1.9 for infiltration/intrapapillary injection ( $P = 0.1$ ). Pain reports for drilling were 2.0 for block/long buccal and 1.8 for infiltration/intrapapillary ( $P = 0.7$ ). Supplementary local anesthetic was required by 9% of the children (4 of 52) in the block/long buccal group and by 10.2% (5 of 49) of those in the infiltration/intrapapillary group ( $P = 0.07$ ). There was no difference in pain control effectiveness between infiltration/intrapapillary injection and inferior alveolar block/long buccal infiltration by 2% lidocaine with 1:100,000 epinephrine when mandibular primary molars received pulpotomy treatment and stainless-steel crowns.

Oulis et al.<sup>8</sup> reported similar results when comparing the effectiveness of mandibular infiltration anesthesia with that of mandibular block anesthesia in children aged 3–9 years requiring the same type of treatment on contralateral mandibular molars. The half-mouth study design was used. Dental procedures included class I and II amalgam restorations, stainless-steel crowns, formocresol pulpotomies, and extractions. Evaluations of pain and behavior for each anesthetic technique and type of treatment were made based on sounds, motor, and ocular changes indicating pain and on the Frankl behavior rating scale. Evaluations were made upon probing, rubber dam placement, and during tooth preparation and extraction. Study results report that for amalgam and stainless-steel crown restorations, there was no statistically significant difference between the two anesthetic techniques for measuring pain ( $P > 0.07$ ). Mandibular infiltration was less effective than mandibular block for pulpotomy and extraction ( $P < 0.05$ ). No significant relationship between effectiveness and age, as determined by primary or mixed dentition, was noticed.



In 1976, a new local anesthetic, articaine, was introduced in Europe, and by 1983, it was in use in Canada. It was not available in the United States until 2000, by which time the preservative had been removed from the formulation, and it received approval from the Food and Drug Administration (FDA). Articaine (Septocaine), manufactured by Septodont (<http://www.septodontusa.com>), underwent several research studies to test its reliability and effectiveness, and it became readily available and widely used. Articaine is unique among local anesthetics because it contains a thiophene group and both ester and amide groups. Articaine is an amide anesthetic (it has an amide intermediate chain) that is metabolized in the liver. The associated ester group also allows for plasma metabolism via pseudocholinesterase, which purportedly increases the rate of breakdown and reduces toxicity. This difference in metabolism gives articaine the advantage of having a 30-minute half-life; lidocaine, for example, has a 90-minute half-life.<sup>9-13</sup>

Sharaf<sup>14</sup> demonstrated that behavior in young children can be adversely affected by the painful mandibular block. It is well known that articaine has a high bone-penetrating ability, which suggests that it may be more successful as a locally injected infiltration. From these reports, one may infer that mandibular infiltration anesthesia may produce adequate anesthesia in mandibular deciduous molars for most restorative procedures. (Video 16.1)

**Video 16.1** Local Anesthetic Techniques: 1, suprapariosteal, and 2, palatal injections for primary molars.

For evaluating the effectiveness of articaine versus lidocaine, Rathi et al.<sup>15</sup> treated 100 patients aged 7–12 years requiring primary molar extractions. Patients were randomly divided into two groups: Group A ( $n = 50$ , 25 males and 25 females; mean age = 9.9 years) and Group B ( $n = 50$ , 25 males and 25 females, mean age = 9.3 years). Group A received single buccal infiltration using 1.7-mL articaine HCl 4% with epinephrine 1:100,000 (Septanest, Septodont). Group B received 1.8-mL lidocaine HCl 2% with epinephrine 1:80,000 (Lignospan special, Septodont). The Wong-Baker Facial Pain Scale (FPS) was employed in the study for patients' subjective evaluation of pain perception during extraction as it shows good construct and validity. The FPS values (mean  $\pm$  standard deviation) were lower in the articaine group ( $1.52 \pm 1.64$ ) than in the lidocaine group ( $5.6 \pm 1.8$ ) and it was statistically significant ( $P < .05$ ). The authors concluded that, for pediatric patients aged 7–12 years, single buccal infiltration of 4% articaine with 1:100,000 epinephrine effectively provided adequate palatal or lingual local anesthesia for primary molar extraction, whereas 2% lidocaine with 1:80,000 epinephrine failed to provide adequate palatal or lingual anesthesia based on subjective patient report.

## INFILTRATION FOR MANDIBULAR INCISORS

The terminal ends of the inferior alveolar nerves cross over the mandibular midline slightly and provide conjoined innervation of the mandibular incisors. A single inferior alveolar nerve block may not be adequate for operative or surgical procedures on the incisors, even on the side of the block anesthesia. The labial cortical bone overlying the mandibular incisors is usually thin enough for suprapariosteal anesthesia techniques to be effective.

If only superficial caries excavation of mandibular incisors is needed or if the removal of a partially exfoliated primary incisor is planned, infiltration anesthesia alone may be adequate. Incisor infiltration is most useful as an adjunct to an inferior alveolar nerve block when total anesthesia of the quadrant is desired. In this case, the infiltration injection is made close to the midline on the side of the block anesthesia, but the solution is deposited labial to the incisors on the opposite side of the midline.

## MANDIBULAR CONDUCTION ANESTHESIA (GOW-GATES MANDIBULAR BLOCK TECHNIQUE)

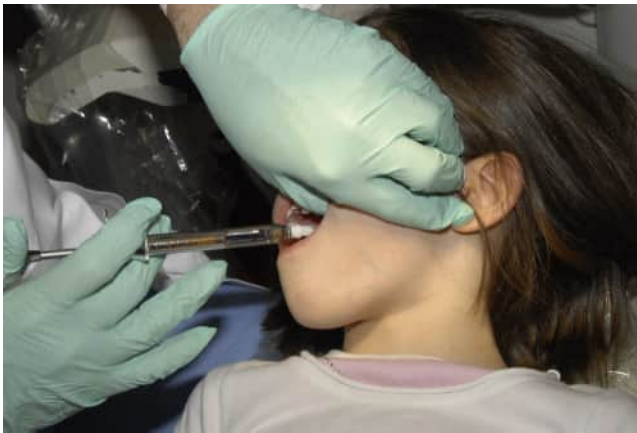In 1973, Gow-Gates<sup>16</sup> introduced a new method of achieving mandibular anesthesia, referred to as *mandibular conduction anesthesia*. This approach uses external anatomic landmarks to align the needle so that anesthetic solution is deposited at the base of the neck of the mandibular condyle. This technique is a nerve block procedure that anesthetizes virtually the entire distribution of the fifth cranial nerve in the mandibular area, including the inferior alveolar, lingual, buccal, mental, incisive, auriculotemporal, and mylohyoid nerves. Thus with a single injection, the entire right or left half of the mandibular teeth and soft tissues can be anesthetized, except possibly the mandibular incisors, which may receive partial innervation from the incisive nerves of the opposite side. Gow-Gates<sup>16</sup> suggested that, once the technique is learned properly, it rarely fails to produce good mandibular anesthesia. He used the technique in practice more than 50,000 times. The technique has become increasingly popular and is often referred to as the *Gow-Gates technique*.

The external landmarks to help align the needle for this injection are the tragus of the ear and the corner of the mouth. The needle is inserted just medial to the tendon of the temporal muscle and considerably superior to the insertion point for conventional mandibular block anesthesia. The needle is also inclined upward and parallel to a line from the corner of the patient's mouth to the lower border of the tragus (intertragic notch). The needle and the barrel of the syringe should be directed toward the injection site from the corner of the mouth on the opposite side (Fig. 16.4).

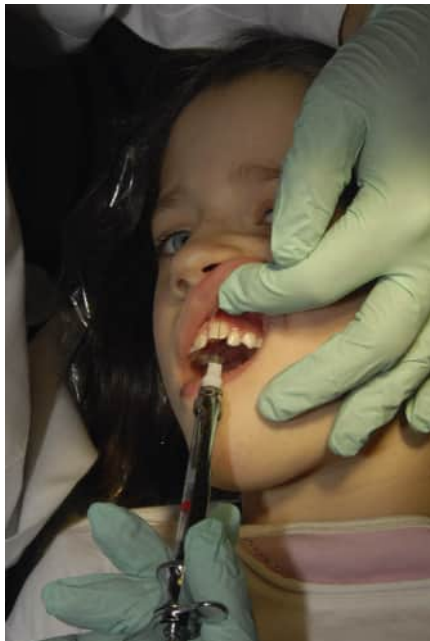## Anesthetization of Maxillary Primary and Permanent Incisors and Canines

### SUPRAPERIOSTEAL TECHNIQUE (LOCAL INFILTRATION)

Local infiltration (suprapariosteal technique) is used to anesthetize the primary anterior teeth. The injection should be made closer to the gingival margin than in the patient with permanent teeth, and the solution should be deposited close to the bone. After the needle tip has penetrated the soft tissue at the mucobuccal fold, it needs little advancement before the solution is deposited (2 mm at most) because the apices of the maxillary primary anterior teeth are essentially at the level of the mucobuccal fold. Some dentists prefer to pull the upper lip down over the needle tip to penetrate the tissue rather than advancing the needle upward. This approach works quite well for the maxillary anterior region (Figs. 16.5–16.7).



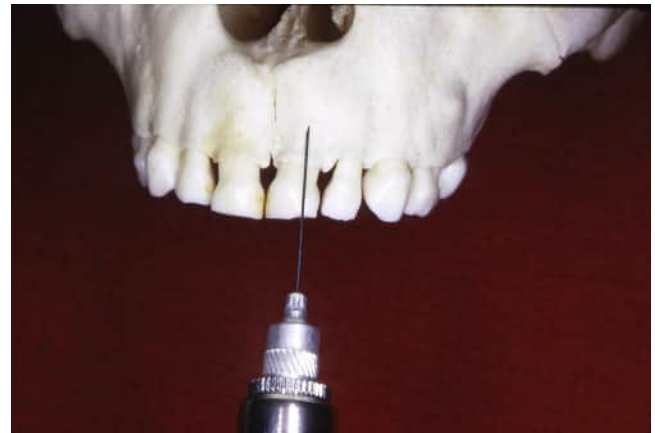**Fig. 16.4** Barrel of the syringe is aligned with a line from the corner of the mouth to the intertragic notch.



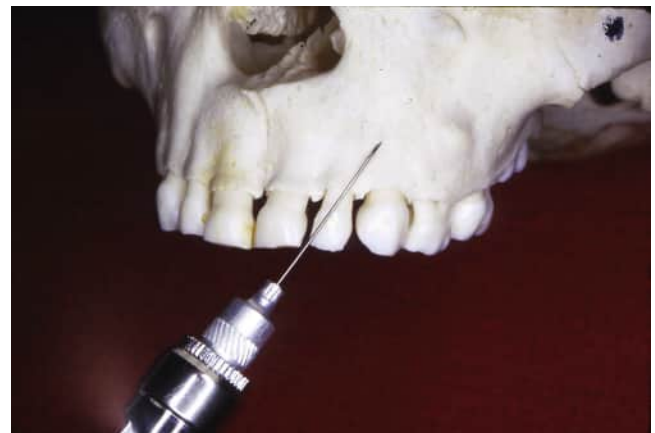**Fig. 16.5** Anesthetization of a central incisor. The suprapariosteal injection should be close to the bone and adjacent to the apex of the tooth.

In the anesthetization of the permanent central incisor teeth, the puncture site is at the mucobuccal fold so that the solution may be deposited slowly and slightly above and close to the apex of the tooth. Because nerve fibers may be extending from the opposite side, it may be necessary to deposit a small amount of the anesthetic solution adjacent to the apex of the other central incisor to obtain adequate anesthesia in either primary or permanent teeth. If a rubber dam is to be applied, it is advisable to inject a drop or two of anesthetic solution into the lingual free marginal tissue to prevent the discomfort associated with the placement of the rubber dam clamp and ligatures.

Before extraction of the incisors or canines in either the primary or permanent dentition, it is necessary for the palatal soft tissues to be anesthetized. The nasopalatine injection provides adequate anesthesia for the palatal tissues of all four incisors and at least partial anesthesia of the



**Fig. 16.6** Needle point is opposite the apex of the maxillary primary incisor.

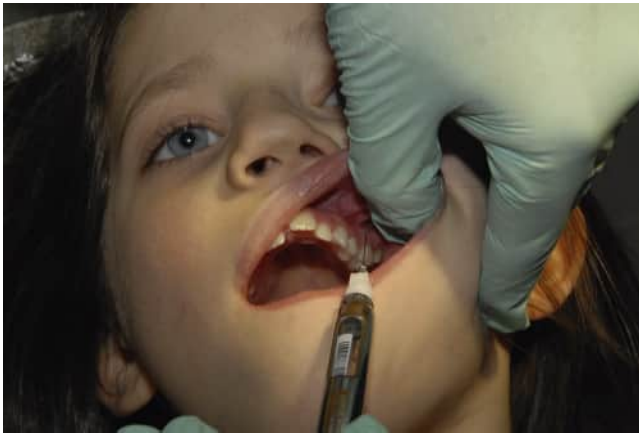

**Fig. 16.7** Position of the needle for anesthetization of a maxillary primary canine.

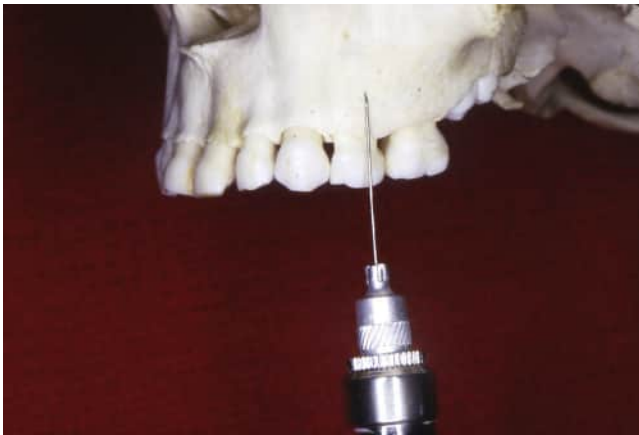canine areas. Nerve fibers from the greater (anterior) palatine nerve usually extend to the canine area as well. If only a single anterior tooth is to be removed, adequate palatal anesthesia may also be obtained when anesthetic solution is deposited in the attached palatal gingiva adjacent to the tooth to be removed. If it is observed that the patient does not have profound anesthesia of anterior teeth during the operative procedures with the suprapariosteal technique, a nasopalatine injection is advisable.

## Anesthetization of Maxillary Primary Molars and Premolars

Traditionally, dentists have been taught that the middle superior alveolar nerve supplies the maxillary primary molars, the premolars, and the mesiobuccal root of the first permanent molar. There is no doubt that the middle superior alveolar nerve is at least partially responsible for the innervation of these teeth. However during child cadaver dissections, Jorgensen and Hayden<sup>17</sup> have demonstrated plexus formation of the middle and posterior superior alveolar nerves in the primary molar area. The role of the posterior superior alveolar nerve in innervating the primary molar area has not received adequate attention previously.



**Fig. 16.8** Injection of the anesthetic solution to anesthetize the maxillary second primary molar for operative procedures.

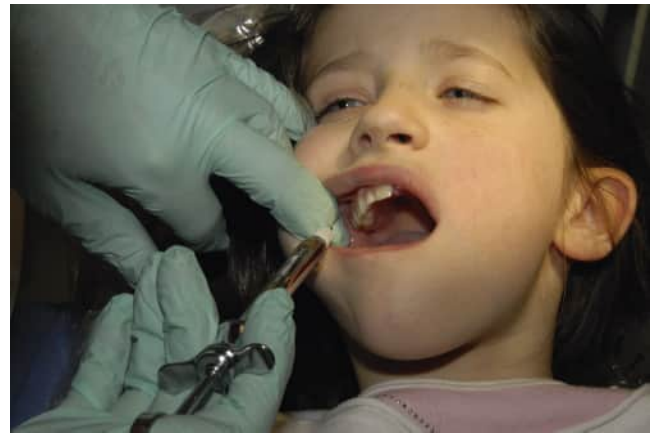

**Fig. 16.9** Anesthetic solution is injected opposite the apices of the buccal roots of the first primary molar.

Moreover, Jorgensen and Hayden<sup>17</sup> have demonstrated maxillary bone thickness approaching 1 cm overlying the buccal roots of the first permanent and second primary molars in the skulls of children.

The bone overlying the first primary molar is thin, and this tooth can be adequately anesthetized by injection of anesthetic solution opposite the apices of the roots (Figs. 16.8 and 16.9). However, the thick zygomatic process overlies the buccal roots of the second primary and first permanent molars in the primary and early-mixed dentition. This thickness of bone renders the supraperiosteal injection at the apices of the roots of the second primary molar much less effective; the injection should be supplemented with a second injection superior to the maxillary tuberosity area to block the posterior superior alveolar nerve, as has been traditionally taught for permanent molars (Fig. 16.10). This supplemental injection helps compensate for the additional bone thickness and the posterior middle superior alveolar nerve plexus in the area of the second primary molar, which compromise the anesthesia obtained by injection at the apices only.

For anesthetization of the maxillary first or second premolar, a single injection is made at the mucobuccal fold to allow the solution to be deposited slightly above the apex of the tooth. Because of the horizontal and vertical growth of the maxilla that has occurred by the time the premolars



**Fig. 16.10** Posterior superior alveolar injection for maxillary permanent molars and second primary molar.

erupt, the buccal cortical bone overlying their roots is thin enough to permit good anesthesia with this method. The injection should be made slowly, and the solution should be deposited close to the bone; these recommendations hold true for all supraperiosteal and block anesthesia techniques in dentistry.

Before operative procedures for maxillary primary molars and maxillary premolars are undertaken, the appropriate injection techniques for the buccal tissues, as described, should be performed. If the rubber dam clamp impinges on the palatal tissue, injection of a drop or two of the anesthetic solution into the free marginal tissue lingual to the clamped tooth alleviates the discomfort and is less painful than the true greater (anterior) palatine injection. The greater palatine injection is indicated if maxillary primary molars or premolars are to be extracted or if palatal tissue surgery is planned.

## Anesthetization of Maxillary Permanent Molars

To anesthetize the maxillary first or second permanent molars, the dentist instructs the child to partially close the mouth to allow the cheek and lips to be stretched laterally. The tip of the dentist's left forefinger (for a right-handed dentist) will rest in a concavity in the mucobuccal fold and is rotated to allow the fingernail to be adjacent to the mucosa. The ball of the finger is in contact with the posterior surface of the zygomatic process. Bennett<sup>18</sup> suggests that the finger be on a plane at right angles to the occlusal surfaces of the maxillary teeth and at 45 degrees to the patient's sagittal plane. The index finger should point in the direction of the needle during the injection. The puncture point is in the mucobuccal fold above and distal to the distobuccal root of the first permanent molar. If the second molar has erupted, the injection should be made above the second molar. The needle is advanced upward and distally, depositing the solution over the apices of the teeth. The needle is inserted for a distance of approximately 2 cm in a posterior and upward direction; it should be positioned close to the bone, with the bevel toward the bone (Fig. 16.10).

For complete anesthesia of the first permanent molar for operative procedures, the supraperiosteal injection is made



by insertion of the needle in the mucobuccal fold and deposition of the solution at the apex of the mesiobuccal root of the molar.

## Anesthetization of the Palatal Tissues

Anesthesia of the palatal tissues can be one of the more exquisitely painful procedures performed in dentistry. Ramirez et al.<sup>19</sup> have discussed methods for achieving profound anesthesia with minimal pain in the palatal and lingual aspects. After buccal infiltration, they suggest interdental (interpapillary) infiltration, with slow injection of the anesthetic solution as the needle is penetrating the papilla. The interdental infiltration allows for diffusion of the anesthetic to the palatal aspect via the craterlike area of the interproximal oral mucosa joining the lingual and buccal interdental papillae, known as the *col*. Blanching of the area indicates sufficient anesthesia of the superficial soft tissues; however, additional palatal infiltration may be given as needed.

### NASOPALATINE NERVE BLOCK

Blocking the nasopalatine nerve anesthetizes the palatal tissues of the six anterior teeth. If the needle is carried into the canal, it is possible to anesthetize the six anterior teeth completely. However, this technique is painful and is not routinely used before operative procedures. If the patient experiences incomplete anesthesia after suprapariosteal injection above the apices of the anterior teeth on the labial side, it may be necessary to resort to the nasopalatine injection. The path of insertion of the needle is alongside the incisive papilla, just posterior to the central incisors. The needle is directed upward into the incisive canal (Fig. 16.11). The discomfort associated with the injection can be reduced by deposition of the anesthetic solution in advance of the needle. When anesthesia of the canine area is required, it may be necessary to inject a small amount of anesthetic solution into the gingival tissue adjacent to the lingual aspect of the canine to anesthetize overlapping branches of the greater palatine nerve.

### GREATER (ANTERIOR) PALATINE INJECTION

The greater palatine injection anesthetizes the mucoperiosteum of the palate from the tuberosity to the canine region and from the median line to the gingival crest on the injected side. This injection is used with the middle or posterior alveolar nerve block before surgical procedures. The innervation of the soft tissues of the posterior two-thirds of the palate is derived from the greater and lesser palatine nerves.

Before the injection is made, it is helpful to bisect an imaginary line drawn from the gingival border of the most posterior molar that has erupted to the midline. Approaching from the opposite side of the mouth, the dentist makes the injection along this imaginary line and distal to the last tooth (Figs. 16.12 and 16.13). In the child in whom only the primary dentition has erupted, the injection should be made approximately 10 mm posterior to the distal surface of the second primary molar. It is not necessary to enter the

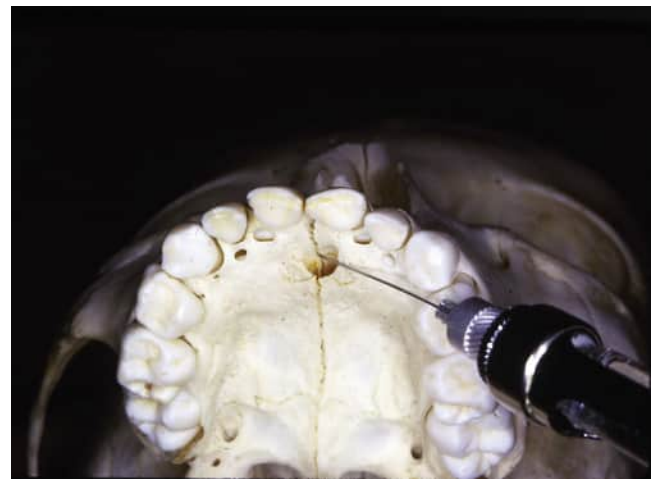


Fig. 16.11 The needle is directed upward into the incisive canal when the nasopalatine nerve is anesthetized.

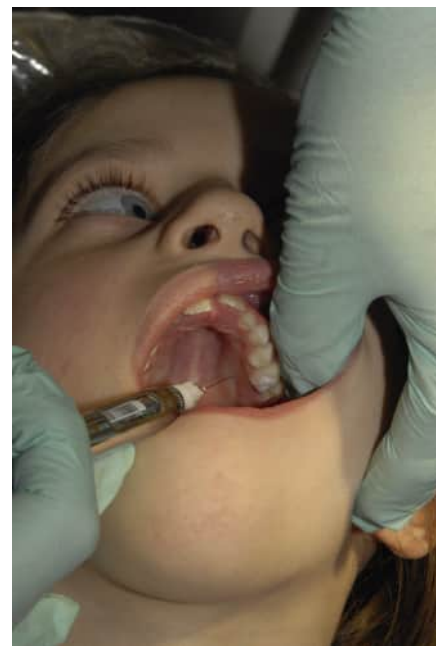


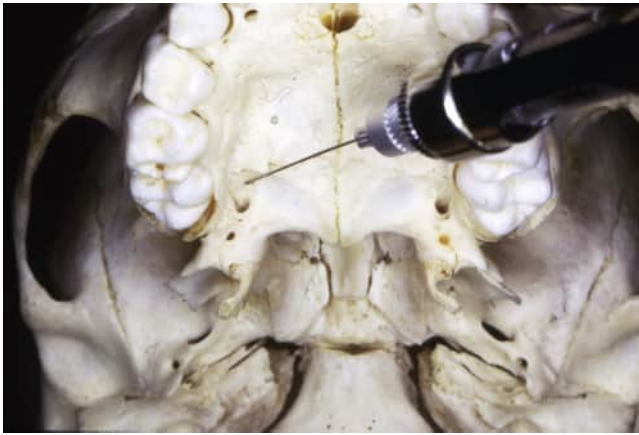Fig. 16.12 Greater palatine injection is used in conjunction with the middle or posterior alveolar nerve block before removal of a maxillary primary molar.

greater palatine foramen. A few drops of the solution should be injected slowly at the point where the nerve emerges from the foramen.

## Supplemental Injection Techniques

### INFRAORBITAL NERVE BLOCK AND MENTAL NERVE BLOCK

The infraorbital nerve block and mental nerve block are two additional local anesthetic techniques used by many dentists. The infraorbital nerve block anesthetizes the branches of the anterior and middle superior alveolar nerves. It also affects



**Fig. 16.13** The needle is inserted approximately 10 mm posterior to the distal surface of the second primary molar.

innervation of the soft tissues below the eye, half of the nose, and the oral musculature of the upper lip on the injected side of the face. This leaves the child with a feeling of numbness above the mouth similar to that below the mouth when an inferior alveolar nerve is blocked. Furthermore, there is temporary partial oral paralysis. These effects do not contraindicate use of the technique when it is truly needed. However, its use can be difficult to justify in routine operative and extraction procedures for teeth innervated by the anterior and middle superior alveolar nerves because the supraperiosteal techniques are more localized and just as effective. The infraorbital block technique is preferred when impacted teeth (especially canines or first premolars) or large cysts are to be removed, when moderate inflammation or infection contraindicates use of the supraperiosteal injection site, or when longer duration or a greater area of anesthesia is needed.

The mental nerve block leaves the patient with essentially the same feelings of numbness as the inferior alveolar nerve block. Blocking the mental nerve anesthetizes all mandibular teeth in the quadrant except the permanent molars. Thus the mental nerve block makes it possible for routine operative procedures to be performed on all primary teeth without discomfort to the patient. However, the inferior alveolar nerve block should be favored unless there is a specific contraindication to its use at the inferior alveolar nerve injection site. The mental nerve block is no more comfortable for the patient, and the technique puts the syringe in clear view of the patient, whereas the inferior alveolar nerve block may be performed with the syringe out of the child's direct vision.

Refer to the textbook by Malamed<sup>5</sup> for more detailed information concerning the infraorbital block, the mental block, and other local anesthetic techniques.

### PERIODONTAL LIGAMENT INJECTION (INTRALIGAMENTARY INJECTION)

The periodontal ligament injection has been used for many years as an adjunctive method of obtaining more complete anesthesia when supraperiosteal or block techniques fail to provide adequate anesthesia. This technique has also gained credibility as a good method of obtaining primary anesthesia for one or two teeth.

The technique is simple, requires only small quantities of anesthetic solution, and produces anesthesia almost

instantly. The needle is placed in the gingival sulcus, usually on the mesial surface, and is advanced along the root surface until resistance is met. Approximately 0.2 mL of anesthetic is then deposited into the periodontal ligament. For multirooted teeth, injections are made both mesially and distally. Considerable pressure is necessary to express the anesthetic solution.

A conventional dental syringe may be used for this technique. However, the great pressure required to express the anesthetic makes it desirable to use a syringe with a closed barrel, to offer protection in the unlikely event that the anesthetic cartridge breaks. Some syringes are equipped with a metal or Teflon sleeve that encloses the cartridge and provides the necessary protection in case of breakage.

Syringes designed specifically for the periodontal ligament injection technique have been developed. One syringe, the Peri-Press (Universal Dental Implements, Fanwood, NJ, USA), is designed with a lever-action "trigger" that enables the dentist to deliver the necessary injection pressure conveniently. The Peri-Press syringe has a solid metal barrel and is calibrated to deliver 0.14 mL of anesthetic solution each time the trigger is completely activated.

There are some possible psychological disadvantages to the use of the periodontal ligament injection technique, especially for the inexperienced pediatric patient. The technique provides the patient with an opportunity to see the syringe and to watch the administration of the anesthetic. This may not be a significant problem for the experienced, well-adjusted dental patient, but it may contribute to the anxiety reaction of the new or anxiety-prone patient. In addition, the very design of the Peri-Press (which resembles a handgun) probably has some adverse psychological effects.

There are two types of syringes designed specifically for intraligamentary injections: gun like and pen like. They both have the additional disadvantage of being quite expensive compared with good, conventional aspirating syringes. The pen like syringe would be preferred in pediatric dentistry, but it is even more expensive than the gun like instrument. Nevertheless, the periodontal ligament injection technique seems to offer a valuable adjunctive method of achieving dental anesthesia.

Malamed<sup>20</sup> has reported a clinical study in which impressive results were obtained for certain procedures when the periodontal ligament injection technique was used. The sample size was small for some procedures, and he pointed out that additional research was warranted. However, seven periodontal procedures (curettage and root planing) were performed with 100% effective anesthesia, and two teeth were extracted with 100% effective anesthesia (injections were administered to the mesial, distal, buccal, and lingual areas for these procedures). In total, 71 routine restorative procedures were performed under periodontal ligament anesthesia, with 91.5% effectiveness. Because of the confined space and the limited blood circulation at the injection site for the periodontal ligament technique, the use of vasoconstrictors as an additive to the anesthetic solution may not be warranted. In fact, vasoconstrictors might conceivably contribute to ischemia of the periodontal ligament, which could at least add to localized postoperative discomfort or possibly cause more serious damage to the periodontal ligament. Walton and Abbott<sup>21</sup> have also reported a clinical evaluation of the technique that showed a 92% success rate.

The periodontal ligament injection offers the following advantages for either primary or adjunctive anesthesia:

1. It provides reliable pain control rapidly and easily.
2. It provides pulpal anesthesia for 30–45 minutes, long enough for many single-tooth procedures without an extended period of postoperative anesthesia.
3. It is no more uncomfortable than other local anesthesia techniques.
4. It is completely painless if used adjunctively.
5. It requires very small quantities of anesthetic solution.
6. It does not require aspiration before injection.
7. It may be performed without removal of the rubber dam.
8. It may be useful in patients with bleeding disorders that contraindicate use of other injections.
9. It may be useful in young or disabled patients in whom the possibility of postoperative trauma to the lips or tongue is a concern.

### INTRAOSSEOUS INJECTION, INTERSEPTAL INJECTION, AND INTRAPULPAL INJECTION

Intraosseous, interseptal, and intrapulpal injection techniques have been known for many years. The intrapulpal injection is an adjunctive anesthesia technique designed to obtain profound pulpal anesthesia during direct pulp therapy when other local anesthesia attempts have failed. The intrapulpal injection often provides the desired anesthesia, but the technique has the disadvantage of being initially painful, although the onset of anesthesia is usually rapid.

Intraosseous injection techniques (of which the interseptal injection is one type) require the deposition of local anesthetic solution in the porous alveolar bone. This is done by forcing a needle through the cortical plate and into the cancellous alveolar bone, or a small, round bur may be used to create access in the bone for the needle. A small, reinforced intraosseous needle may be used to penetrate the cortical plate more easily. This procedure is not particularly difficult in children because their cortical bone is less dense than that of adults. The intraosseous techniques have been advocated for both primary anesthesia and adjunctive anesthesia when other local injections have failed to produce adequate anesthesia. These techniques have been reported by Lilienthal<sup>22</sup> to produce profound anesthesia. They do not seem to offer any advantages over the periodontal ligament injection, except when use of the latter is contraindicated by infection in the periodontal ligament space.

### COMPUTER-CONTROLLED LOCAL ANESTHETIC DELIVERY SYSTEM (WAND)

Reports by Friedman and Hochman<sup>23</sup> and by Krochak and Friedman<sup>24</sup> have emphasized on the advantages of a computer-controlled local anesthetic delivery system known as the Wand (Milestone Scientific, Livingston, NJ, USA). The system includes a conventional local anesthetic needle and a disposable wand like syringe held by a pen grasp when used for oral local anesthetic injections. A microprocessor with a foot control regulates the delivery of anesthetic solution through the syringe at a precision-metered flow rate, constant pressure, and controlled volume. The system includes an aspiration cycle for use when

necessary. Block, infiltration, palatal, and periodontal ligament injections are all reported to be more comfortable for the patient with the Wand than with conventional injection techniques. In a randomized clinical trial comparing the Wand with the traditional anesthetic delivery system, Allen et al.<sup>25</sup> demonstrated that use of the Wand led to significantly fewer disruptive behaviors ( $P < 0.01$ ) in preschool-aged children. None of the preschool-aged children exposed to the Wand required restraint during the initial interval, whereas nearly half of the children receiving a traditional injection required some type of immediate restraint.

## Complications After a Local Anesthetic

### ANESTHETIC TOXICITY

Systemic toxic reactions from anesthetics are rarely observed in adults. However, young children are more likely to experience toxic reactions because of their lower body weight. Young children are also often sedated with pharmacologic agents before the treatment. The potential for toxic reactions increases when local anesthetics are used in conjunction with sedation medications. Aubuchon<sup>26</sup> found a direct linear relationship between the number of cartridges of local anesthetic administered and the frequency of severe reactions. It is most important for dentists who treat children to be acutely aware of the maximum recommended dosages of the anesthetic agents they use because allowable dosages are based on the patient's weight (Table 16.1 and Fig. 16.15). For example, the toxic dose of lidocaine would be attained if hardly more than 1.5 cartridges (3 mL) of 2% lidocaine with 1:100,000 epinephrine were injected at one time in a patient weighing 14 kg (30 lb). Yet 5.5 cartridges of the same anesthetic agent would be required to reach the toxic level in an adolescent patient weighing 46 kg (100 lb).

Another simple alternative for calculating maximum safe doses of local anesthetics is offered by Moore and Hersh<sup>27</sup> who suggested that it is the most conservative guideline that can be applied to all anesthetic formulations used in dentistry. "The rule of 25" states that for healthy patients, a dentist can safely use 1 cartridge of anesthetic for every 25 pounds of patient weight; that is, 1 cartridge for a patient weighing 25 pounds, 2 cartridges for a patient weighing 50 pounds, 3 cartridges for a patient weighing 75 pounds, and 6 cartridges for a patient weighing 150 pounds or greater.

Because there is the possibility of toxic reaction to local anesthetic in some children, Wilson et al.<sup>28</sup> have studied and reported on the clinical effectiveness of 1% and 2% lidocaine. They found that 1% and 2% lidocaine were equally effective for minor procedures on primary molars. However, 1% lidocaine had a slightly lower effectiveness for major procedures, including pulpotomies and extractions.

### TRAUMA TO SOFT TISSUE

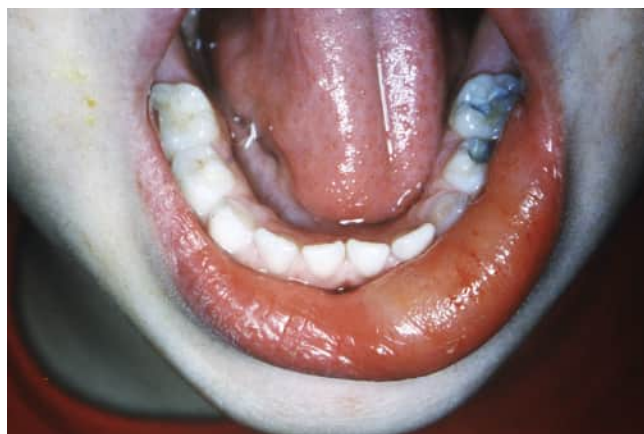Parents of children who receive regional local anesthesia in the dental office should be warned that the soft tissue in the area will be without sensation for 1 hour or



**TABLE 16.1** Maximum Recommended Doses of Local Anesthetics

Dose	Proprietary Name	Percent of Local Anesthetic	Vasoconstrictor	Duration of Anesthetic	Maximum Recommended Dose
Lidocaine	Xylocaine	2	Epinephrine 1:100,000	Pulpal: 60 min Soft tissue: 3–5 h	4.4 mg/kg (300 mg total maximum)
Mepivacaine	Carbocaine	3		Pulpal: 20–40 min Soft tissue: 2–3 h	4.4 mg/kg (300 mg total maximum)
Prilocaine	Citanest Forte	4	Epinephrine 1:200,000	Pulpal: 60–90 min Soft tissue: 3–8 h	6.0 mg/kg (400 mg total maximum)
Articaine	Septocaine	4	Epinephrine 1:100,000	Pulpal: 60–75 min Soft tissue: 180–360 min	7 mg/kg (500 mg total maximum)

Partially adapted from Malamed SF. *Handbook of local anesthesia*. 6<sup>th</sup> ed. St. Louis: Elsevier; 2013.



**Fig. 16.14** Child who has chewed his lip after an inferior alveolar nerve block for operative procedures.

more. These children should be observed carefully so that they will not purposely or inadvertently bite the tissue. Children who receive an inferior alveolar injection for routine operative procedures may bite the lip, tongue, or inner surface of the cheek. Sometimes a parent calls the dentist's office an hour or two after a dental appointment to report an injury to the child's oral mucous membrane. The parent may wonder if the accident occurred during the dental appointment; in all probability, the child has chewed the area, and the result 24 hours later is an ulceration that is often termed as a traumatic ulcer (Fig. 16.14). Complications after a self-inflicted injury of this type are rare. However, the child should be seen in 24 hours, and a warm saline mouthrinse is helpful in keeping the area clean.

In a prospective study, College et al.<sup>29</sup> evaluated unilateral versus bilateral mandibular nerve block anesthesia with regard to postoperative soft tissue trauma and other complications in a pediatric population. Their results showed that after unilateral and bilateral blocks, 13% of patients experienced postoperative soft tissue trauma, with the younger patients (<4 years old) experiencing more than twice as many problems as the older patients (>12 years old). Interestingly the study showed that, in the group younger than 4 years, patients receiving the unilateral nerve blocks had a significantly higher incidence of trauma than patients receiving the bilateral nerve blocks (35% vs. 5%). Although the use of bilateral mandibular nerve blocks has been discouraged in the past, College et al.<sup>29</sup> concluded that there is no contraindication to the use of bilateral mandibular block anesthesia in pediatric patients.

## Reversal of Dental Anesthesia

With the granting of marketing approval by the FDA in May 2008, OraVerse (Septodont, Inc., Louisville, CO, USA, [www.septodont.com](http://www.septodont.com)) (phentolamine mesylate) became the first pharmaceutical agent indicated for the reversal of soft tissue anesthesia—that is, anesthesia of the lip and tongue, and the associated functional deficits resulting from an intraoral submucosal injection of a local anesthetic containing a vasoconstrictor.

In randomized, double-blind, controlled phase 3 studies, following the administration of local anesthetics and completion of the dental procedure, patients were given either OraVerse or the control treatment. OraVerse reduced the median time to recovery of normal sensation in the lower lip (as measured by standardized lip-tapping procedures) by 85 minutes compared with the control. OraVerse reduced the median time to recovery of normal sensation in the upper lip by 83 minutes. Within 1 hour after administration of OraVerse, 41% of the patients reported normal lower lip sensation compared with 7% in the control group, and 59% of patients in the OraVerse group reported normal upper lip sensation compared with 12% in the control group. Similar results in additional pediatric patients (6–11 years of age) have been recently reported.<sup>30</sup>

In all OraVerse clinical trials, no serious adverse events were reported. The most common adverse reaction was transient injection site pain. Although tachycardia and cardiac arrhythmia may occur with the parenteral use of alpha-adrenergic blocking agents, such events are uncommon after the submucosal administration of OraVerse. The recommended maximum dose for OraVerse is as follows: (<http://oraverse.com/dental-professionals/>)

- Two cartridges for adults and adolescents 12 years and older
- One cartridge for patients aged 6–11 years and weighing over 66 lbs
- ½ cartridge for children aged 6–11 years and weighing 33–66 lbs
- In pediatric patients weighing at least 10 kg (22 lbs), the maximum dose of OraVerse recommended is ¼ cartridge.

## Analgesics

In addition to local administration of anesthetics, systemic administration of analgesics is occasionally necessary to help control pain. These analgesics may be needed in instances of moderate to severe pain associated with trauma or infectious processes such as abscessed teeth, or they may be administered

**TABLE 16.2** Common Medications and Dosages for Oral Pediatric Postoperative Pain Management

Medication	Availability	Dosage
Acetaminophen	Elixir: 160 mg/5 mL Tablets: 325 mg Chewable: 160 mg	10–15 mg/kg/dose given at 4- to 6-hour intervals
Ibuprofen	Suspension: 100 mg/5 mL Tablets: 200, 300, 400, 600, 800 mg	4–10 mg/kg/dose given at 6- to 8-hour intervals
Tramadol*	Tablets: 50, 100 mg	1–2 mg/kg/dose given at 4- to 6-hour intervals; maximum 100 mg
Codeine and acetaminophen*	Suspension: 12 mg/5 mL 12 mg codeine/120 mg acetaminophen/5 mL	0.5–1.0 mg/kg/dose given at 4- to 6-hour intervals
Hydrocodone and acetaminophen	Suspension: 7.5 mg hydrocodone/325 mg acetaminophen/15 mL Tablets: 5 mg hydrocodone/325 mg acetaminophen	0.3 mL/kg/dose given at 4- to 6-hour intervals <50 kg 0.135 mg/kg

\*In 2017, the Federal Drug Administration issued a warning specifically for codeine and tramadol in all patients younger than 12 years stating that they are no longer considered safe to use in this age group. Archived at WebCite at: <http://www.webcitation.org/6xVGnS3vO>

Partially adapted from Tate AR, Acs G. Dental postoperative pain management in children. *Dent Clin North Am.* 2002;46:707–717.

<Begin Equation>

$$\text{Weight [kg]} \times \text{MRD} \left[ \frac{\text{mg}}{\text{kg}} \right] = \text{Maximum weight based dose [mg]} \text{ (not to exceed maximum total dose)}$$

$$\frac{\text{Maximum dose [mg]}}{\left[ \frac{\text{mg}}{\text{carpule}} \right]} = \text{Maximum \# of carpules}$$

</End Equation>

For example: If a child weighs 20 kg and you are anesthetizing with 2% lidocaine, the calculation would be as follows:

<Begin Equation>

$$20 \text{ [kg]} \times 4.4 \left[ \frac{\text{mg}}{\text{kg}} \right] = 88 \text{ [mg]} \text{ (not to exceed 300 mg)}$$

$$\frac{88 \text{ [mg]}}{\left[ \frac{34 \text{ mg}}{\text{carpule}} \right]} = 2.5 \text{ carpules}$$

</End Equation>

**Fig. 16.15** Local anesthetic maximum recommended dose calculation.

preoperatively or postoperatively in association with a dental procedure that may cause pain for the child. The rationale for the preoperative administration of analgesics draws on the theory that giving the drug before the procedure provides effective analgesia because it precedes the inflammatory response and subsequent pain incurred during the operative procedure. However, there are conflicting reports within the literature pertaining to the efficacy of this technique.

Tate and Acs<sup>31</sup> have suggested that the selection and dosages of analgesics vary because of the changes in body weight and composition that occur throughout childhood. The first choice in most cases is the least potent analgesic with the fewest side effects. Table 16.2 and Fig. 16.16 provide common pediatric pain management agents and their weight-appropriate dosage schedules. Given the devastating opioid abuse crisis in the United States, practitioners must be even more diligent in their pain control prescribing habits. Indeed, from the National Institute of Dental and Craniofacial Research website (<https://www.nidcr.nih.gov/health-info/opioids-information-dentists>, accessed Nov 22, 2019), “Opioids—Information for Dentists” advice is provided:

- Consider nonsteroidal antiinflammatory analgesics as the first-line therapy for acute pain management.<sup>2</sup>
- Consider using multimodal opioid-sparing strategies such as pre-treatment with nonsteroidal antiin-

flam matory drugs (NSAIDs) and long-acting local anesthesia.

- If you consider prescribing an opioid for acute pain, follow the Centers for Disease Control and Prevention guidelines:
  - Prescribe the lowest effective dose of immediate-release opioids.
  - Prescribe no greater quantity than needed for the expected duration of pain severe enough to require opioids.
  - Note that 3 days or less will often be sufficient, and more than 7 days will rarely be needed.
- Be aware: You may be the first to prescribe an opioid to an adolescent if you write a prescription after third molar extraction. It is also important to know that according to the research, medical use of prescription opioids is highly correlated with nonmedical use of prescription opioids among high-school seniors. Among adolescents who reported both types of use, medical use generally came first. In view of this risk, consider nonopioid analgesics for this population instead.
- Register with and use your state’s Prescription Drug Monitoring Program (PDMP) to promote the appropriate use of opioids and deter misuse and abuse. When opioid prescribing is indicated, risk of misuse and diversion may be mitigated by consistent PDMP use and patient education.

&lt;Begin Equation&gt;

$$\text{Weight [kg]} \times \text{minimum dose range} \left[ \frac{\text{mg}}{\text{kg} \times \text{dose}} \right] = \text{Minimum dose [mg/dose]}$$

$$\text{Weight [kg]} \times \text{maximum dose range} \left[ \frac{\text{mg}}{\text{kg} \times \text{dose}} \right] = \text{Maximum dose [mg/dose]}$$

&lt;/End Equation&gt;

After the dose range is selected, you can choose the recommended mg/dose within the range. The next equation is for converting mg to mL if the child cannot swallow pills or prefers liquid.

&lt;Begin Equation&gt;

$$\frac{\text{Dose [mg]}}{\text{Suspension strength [mg]}} \times \text{[mL]} = \text{Dose [mL/dose]}$$

&lt;/End Equation&gt;

For example: If a child weighs 21 kg and requires ibuprofen for postoperative pain control, the calculation would be as follows:

&lt;Begin Equation&gt;

$$21 \text{ [kg]} \times 4 \left[ \frac{\text{mg}}{\text{kg} \times \text{dose}} \right] = 84 \text{ [mg/dose]}$$

$$21 \text{ [kg]} \times 10 \left[ \frac{\text{mg}}{\text{kg} \times \text{dose}} \right] = 210 \text{ [mg/dose]}$$

&lt;/End Equation&gt;

You decide to give 200 mg/dose and the child prefers to take liquid medication:

&lt;Begin Equation&gt;

$$\frac{200 \text{ [mg]}}{100 \text{ [mg]}} \times 5 \text{ [mL]} = 10 \text{ [mL/dose]}$$

&lt;/End Equation&gt;

**Fig. 16.16** Analgesic dosage calculation. Davis's Drug Guide: [https://anesth.unboundmedicine.com/anesthesia/view/Davis-Drug-Guide/109514/all/Pediatric\\_Dosage\\_Calculations](https://anesth.unboundmedicine.com/anesthesia/view/Davis-Drug-Guide/109514/all/Pediatric_Dosage_Calculations) (Last accessed 10.7.2020).

- Counsel your patients if you prescribe an opioid pain medication:
  - Ask about any other medications they are currently taking, and whether they or any family members have had problems with substance abuse, such as with alcohol, prescription medications, or illicit drugs.
  - Explain the risks of taking the medication.
  - Describe how to take the medicine and how long to take it.
  - Explain that alcohol should never be used when taking an opioid medication.
  - Provide guidance on storing medication in a safe place out of sight and out of reach of children, preferably in a locked cabinet.

Rarely does the recommended dosage of acetaminophen or NSAIDs fail to control the dental pain, and in such cases, the combination of codeine and acetaminophen provides the needed pain relief. Finally, in cases of severe pain in which codeine and acetaminophen are not effective, hydrocodone and acetaminophen may be indicated. In 2017, the Federal Drug Administration issued a warning specifically for codeine and tramadol in all patients younger than 12 years, stating that they are no longer considered safe to use in this age group. Additional warnings include that codeine and tramadol should not be prescribed to adolescents aged 12–18 years who are obese or have conditions affecting breathing such as obstructive sleep apnea or severe lung disease.<sup>32</sup>

## References

1. Venham L, Quatrocelli S: The young child's response to repeated dental procedures. *J Dent Res* 56(7):734–738, 1977.
2. Duckworth GM, Millward HR, Potter CD, et al.: Oral Powderject: a novel system for administering local anaesthesia to the oral mucosa. *Br Dent J* 185(10):536–539, 1998.
3. Wittrock JW, Fischer WE: The aspiration of blood through small-gauge needles. *J Am Dent Assoc* 76(1):79–81, 1968.
4. Trapp LD, Davies RO: Aspiration as a function of hypodermic needle internal diameter in the in vivo human upper limb. *Anesth Prog* 27(2):49–51, 1980.
5. Malamed SF: Local complications. In *Handbook of local anesthesia*, 6th Ed, Mosby, 2013:292–310.
6. Olsen NH: Anesthesia for the child patient. *J Am Dent Assoc* 53(5):548–555, 1956.
7. Naidu S, Loughlin P, Coldwell SE, et al.: A randomized controlled trial comparing mandibular local anesthesia techniques in children receiving nitrous oxide-oxygen sedation. *Anesth Prog* 51(1):19–23, 2004.
8. Oulis CJ, Vadiakas GP, Vasilopoulou A: The effectiveness of mandibular infiltration compared to mandibular block anesthesia in treating primary molars in children. *Pediatr Dent* 18:301–305, 1996.
9. Oertel R, Rahn R, Kirch W: Clinical pharmacokinetics of articaine. *Clin Pharmacokinet* 33(6):417–426, 1997.
10. Oertel R, Oertel A, Weile K, et al.: The concentration of local anesthetics in the dental alveolus, comparative studies of lidocaine and articaine in the mandible and maxilla. *Schweiz Monatsschr Zahnmed* 104(8):952–955, 1994.
11. Vree TB, Gielen MJ: Clinical pharmacology and the use of articaine for local regional anaesthesia. *Best Pract Res Clin Anaesthesiol* 19(2):293–308, 2005.
12. Claffey E, Reader A, Nusstein J, et al.: Anesthetic efficacy of articaine for inferior alveolar nerve blocks in patients with irreversible pulpitis. *J Endodont* 30(8):568–571, 2004.
13. Kanaa MD, Whitworth JM, Corbett IP, et al.: Articaine and lidocaine mandibular buccal infiltration anesthesia: a prospective randomized double blind cross-over study. *J Endodont* 32(4):296–298, 2006.



14. Sharaf AA: Evaluation of mandibular infiltration versus block anesthesia in pediatric dentistry, *J Dent Child* 64(4):276–281, 1997.
15. Rathi NV, Khatri AA, Agrawal AG, et al.: Anesthetic efficacy of buccal infiltration articaine versus lidocaine for extraction of primary molar teeth, *Anesth Prog* 66(1):3–7, 2019.
16. Gow-Gates GAE: Mandibular conduction anesthesia: a new technique using extraoral landmarks, *Oral Surg* 36(3):321–328, 1973.
17. Jorgensen NB, Hayden J: *Sedation, local and general anesthesia in dentistry*, 3rd Ed, Lea & Febiger, 1980.
18. Bennett CR: *Monheim's local anesthesia and pain control in dental practice*, 7th Ed, Mosby, 1990.
19. Ramirez K, Lee JK, Takara JT: Painless pediatric local anesthesia, *Gen Dent* 49(2):174–176, 2001.
20. Malamed SF: The periodontal ligament (PDL) injection: an alternative to inferior alveolar nerve block, *Oral Surg* 53(2):117–121, 1982.
21. Walton RE, Abbott BJ: Periodontal ligament injection: a clinical evaluation, *J Am Dent Assoc* 103(4):571–575, 1981.
22. Lillenthal B: A clinical appraisal of intraosseous dental anesthesia, *Oral Surg* 39(5):692–697, 1975.
23. Friedman MJ, Hochman MN: A 21st century computerized injection system for local pain control, *Compend Contin Educ Dent* 18(10):995–1000, 1997, 1002–1004.
24. Krochak M, Friedman N: Using a precision-metered injection system to minimize dental injection anxiety, *Compend Contin Educ Dent* 19(2):137–143, 1998, 146–150.
25. Allen KD, Kotil D, Larzelere RE, et al.: Comparison of a computerized anesthesia device with a traditional syringe in preschool children, *Pediatr Dent* 24(4):315–320, 2002.
26. Aubuchon RW: Sedation liabilities in pedodontics, *Pediatr Dent* 4:171–180, 1982.
27. Moore PA, Hersh EV: Local anesthetics: pharmacology and toxicology, *Dent Clin North Am* 54(4):587–599, 2010.
28. Wilson TG, Primosch RE, Melamed B, et al.: Clinical effectiveness of 1 and 2% lidocaine in young pediatric dental patients, *Pediatr Dent* 12(6):353–359, 1990.
29. College C, Feigal R, Wandera A, et al.: Bilateral versus unilateral mandibular block anesthesia in a pediatric population, *Pediatr Dent* 22(6):453–457, 2000.
30. Tavares M, Goodson JM, Studen-Pavlovich D, et al.: Reversal of soft-tissue local anesthesia with phentolamine mesylate in pediatric patients, *J Am Dent Assoc* 139(8):1095–1104, 2008.
31. Tate AR, Acs G: Dental postoperative pain management in children, *Dent Clin North Am* 46(4):707–717, 2002.
32. Food and Drug Administration. FDA Drug Safety Communication Update: *FDA restricts use of prescription codeine pain and cough medicines and tramadol pain medicines in children; recommends against use in breastfeeding women*. Food and Drug Administration; Sept, 2015.

### Suggested Readings

- Berde CB, Sethna NF: Drug therapy: analgesics for the treatment of pain in children, *N Engl J Med* 347(14):1094–1103, 2002.
- Blanton PL, Jeske AH: The key to profound local anesthesia: neuroanatomy, *J Am Dent Assoc* 134(6):753–760, 2003.
- Davis's Drug Guide: [https://anesth.unboundmedicine.com/anesthesia/view/Davis-Drug-Guide/109514/all/Pediatric\\_Dosage\\_Calculations](https://anesth.unboundmedicine.com/anesthesia/view/Davis-Drug-Guide/109514/all/Pediatric_Dosage_Calculations) (Last accessed 10.7.2020).
- Tanega S, Singh A, Jain A: Anesthetic effectiveness of Articaine and Lidocaine in pediatric patients during dental procedures: A systematic review and meta-analysis. *Pediatr Dent* 42(4): 273–279. 2020.

## 17

# Nonpharmacologic Management of Children's Behaviors

JENNY ISON STIGERS

## CHAPTER OUTLINE

**Pediatric Dental Patients**

Variables Influencing Children's Dental Behaviors

Classifying Children's Cooperative Behavior

The Functional Inquiry

**Parents of Pediatric Patients**

Strategies of the Dental Team

## Preappointment Behavior Modification

Fundamentals of Behavior Guidance

Communicating With Children

Behavior Shaping

Retraining

Practical Considerations

Limitations

The foundation of practicing dentistry for children is the ability to guide them through their dental experiences. In the short term, this ability is a prerequisite to providing for their immediate dental needs. More long-lasting beneficial effects also can result when the seeds for future oral health are planted early in life and children are supported in becoming involved in their own health care then, ultimately, assuming treatment decision making. For many years, the process of leading a child through a dental appointment had been termed behavior management. Since 2005, the term *behavior guidance* has been used in the American Academy of Pediatric Dentistry's (AAPD's) clinical recommendations to emphasize that the goals are not to "deal with" a child's behavior, but rather, to enhance communication and partner with the child and parent to promote a positive attitude and good oral health. Wright and Kupietzky<sup>1</sup> reported that *behavior management* continued to be the preferred term globally.

A professional goal is to promote positive dental attitudes and improve the oral health of society. A major difference between the treatment of children and the treatment of adults is the relationship. Treating adults generally involves a one-to-one relationship, that is, a dentist-patient relationship. Treating a child, however, usually relies on a one-to-two relationship among the dentist, the patient, and parents or caregivers. Fig. 17.1 illustrates this relationship, known as the *pediatric dentistry treatment triangle*.<sup>1</sup> Because these individuals and their relationships cannot be segregated from external influences, the triangle is encircled by society. Management methods acceptable to society and the litigiousness of society have been factors influencing treatment modalities. Juntgen et al.<sup>2</sup> found that obstacles to incorporating previously unused techniques into pediatric dental practices include legal concerns, parental acceptance to change, and limited resources. Note that the child is at the apex of the triangle and is the focus of attention of both the family and the dental team. Because the roles of families

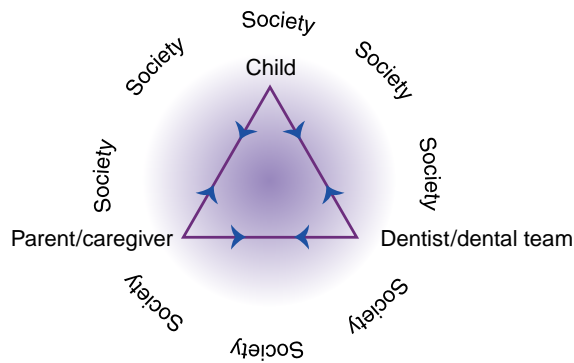
have been changing and the family is the basis for a child's relationships, the entire family environment must be considered an influence on the child's behaviors in the dental office. In addition, changes are constantly occurring within each personality resulting in an ever-evolving, dynamic relationship among the corners of the triangle—the child, the family, and the dental team. The arrows placed on the lines of communication remind us that communication is reciprocal.

The importance of this unifying concept will become evident as behavior guidance techniques are described. However, this model also serves as the basis of organization for this chapter, the goal of which is to discuss nonpharmacologic approaches to guiding children's behavior in dentistry.

## Pediatric Dental Patients

Child development involves the study of all areas of human development from conception through young adulthood. It involves more than physical growth, which often implies only an increase in size. *Development* implies a sequential unfolding that may involve changes in size, shape, function, structure, or skill.

Over the years, numerous child development theories have evolved which have helped explain physical, cognitive, language, motor, and social/emotional development. Recently fields such as *behavior genetics* and *social epigenetics* have focused on the influences of both nature and nurture on health outcomes. Considerable development occurs in utero and during the early years of life. Boyce<sup>3</sup> reported that being reared in poverty or disadvantaged settings affects brain development both structurally and functionally. He described a neurobiologic susceptibility to social contexts that can jeopardize development. The convergence of social-environmental conditions and genetically derived differences in vulnerability is a rapidly expanding



**Fig. 17.1** The pediatric treatment triangle illustrates basic relationships in pediatric dentistry. (Modified from Wright GZ, Kupietzky A. Introductory remarks. In: Wright GZ, Kupietzky A, eds. Behavior management in dentistry for children. 2nd edition, 2014, Wiley Blackwell, 3–9.)

area of research, one that is important to oral health care for children. Although there may be expectations for children's skills based upon chronological age, the practitioner must assess the individual child's understanding and be familiar with the family environment. Differences in genetics, personality, and experience influence the way the child engages with his surroundings. If influences are in harmony, healthy development of the child can be expected; if they are dissonant, behavioral problems are almost sure to ensue. Key to a practitioner's interaction with a child is remembering that each child is unique and exists in the context of his/her family.

Early child development study linked changes to specific chronologic ages. The initial work gathered age norms for physiologic developmental tasks. Eventually, personality description principles also evolved. One of the pioneering and most notable groups, headed by Arnold Gesell, was at Yale University. Typical personality characteristics related to specific chronologic ages that have relevance to dentistry are listed in [Box 17.1](#).<sup>4</sup> These can help in the development of behavioral guidance strategies. For example, if the dentist knows the limitations of a 2-year-old's vocabulary, it becomes apparent that communication must occur through the sense of touch and voice modulation rather than through the spoken word. Recognizing also the close symbiotic relationship with parents, dentists generally try to keep the parent-child pair intact.

Relating personality characteristics to chronologic ages has led to some interesting labeling. For example, a non-compliant 2-year-old is often referred to as being in the stage of the "terrible twos." Unfortunately in some instances, this has led to use of the age of the child, rather than the child's ability, as a reason for noncompliance. Dentists sometimes refer to such children as being in the *precooperative stage* of development. Cooperation cannot be expected when communication cannot be established. It is, therefore, important for the dentist to help the parent of a very young patient establish realistic expectations for behavior during the initial appointment.

The broad area of physical development involves changes that occur in children's size, strength, motor coordination, functioning of body systems, and so forth. Thus the child's total physical growth and efficiency from the moment of conception until adulthood are together termed *physical development*. Because a child's physical development

### Box 17.1 Age-related psychosocial traits and skills for 2- to 5-year-old children

#### 2 years

Geared to gross motor skills, such as running and jumping  
Likes to see and touch  
Very attached to parent  
Plays alone; rarely shares  
Has limited vocabulary; shows early sentence formation  
Becoming interested in self-help skills

#### 3 years

Less egocentric; likes to please  
Has very active imagination; likes stories  
Remains closely attached to parent

#### 4 years

Tries to impose powers  
Participates in small social groups  
Reaches out—expansive period  
Shows many independent self-help skills  
Knows "thank you" and "please"

#### 5 years

Undergoes a period of consolidation; deliberate  
Takes pride in possessions  
Relinquishes comfort objects, such as a blanket or thumb  
Plays cooperatively with peers

Based on the work of Dr. A. Gesell.<sup>4</sup>

is relatively independent of other major areas of development, subareas of physical development must be relatively independent. Neither can a child's coordination be judged by physical size nor is physical strength related to dental development.

Relating key aspects of development to chronologic ages has led to the establishment of developmental milestones as a means of assessing individual children. Selected developmental, cognitive, and psychosocial milestones are listed in [Table 17.1](#). There is a normal range of ages at which motor and language skills are acquired; a general principle is that the earlier a skill emerges, the narrower is the range. On the other hand, developmental tasks tend to occur with wider ranges of normality as age increases. For the dentist, this holds practical importance. For example, consider the task of teaching children how to floss their teeth. Because the ability to floss occurs later in life (9–12 years of age), there is a wide performance range. Knowing the general developmental principle reminds the clinician to consider the ability or readiness of the individual to perform a given task.

Another area that has received great attention from psychologists is the socialization of children. As with physical development, age-specific skills have been derived for social development; these take into account both interpersonal relationships and independent functioning skills. An important process for dentists is the child's growth toward independent functioning. For their survival, infants are dependent on others to clothe, feed, and nurture them. As children grow and their ability to care for themselves improves, they gain social independence. Recognizing that the change from functional dependency to functional autonomy is a normal process in social development can



assist the dentist. Many young children want to brush their own teeth but lack sufficient digital dexterity. Parents, on the other hand, understand the lack of digital skills and often insist on attending to their children's oral health care. Appreciating that this tug of war is a normal part of social maturation allows the dentist to intercede and make appropriate conciliatory recommendations.

Autonomy is an increasingly important consideration in health care for pediatric patients. While it is the right of patients to have autonomy over their health care decisions, a pediatric patient generally does not have legal authority to consent to or refuse health care services. Most minors either have limited capacity for health care decision making or have not established independence. Children should

**TABLE 17.1** Developmental, Cognitive, and Psychosocial Stages of Children

Age	Social/Emotional	Language/Communication	Cognitive	Movement/Physical Development
6 months	<ul style="list-style-type: none"> <li>Knows familiar faces and begins to know if someone is a stranger</li> <li>Likes to play with others, especially parents</li> <li>Responds to other people's emotions and often seems happy</li> <li>Likes to look at self in a mirror</li> </ul>	<ul style="list-style-type: none"> <li>Responds to sounds by making sounds</li> <li>Strings vowels together when babbling ("ah," "eh," "oh") and likes taking turns with parent while making sounds</li> <li>Responds to own name</li> <li>Makes sounds to show joy and displeasure</li> <li>Begins to say consonant sounds (jabbering with "m," "b")</li> </ul>	<ul style="list-style-type: none"> <li>Looks around at things nearby</li> <li>Brings things to mouth</li> <li>Shows curiosity about things and tries to get things that are out of reach</li> <li>Begins to pass things from one hand to the other</li> </ul>	<ul style="list-style-type: none"> <li>Rolls over in both directions (front to back, back to front)</li> <li>Begins to sit without support</li> <li>When standing, supports weight on legs and might bounce</li> <li>Rocks back and forth, sometimes crawling backward before moving forward</li> </ul>
12 months	<ul style="list-style-type: none"> <li>Is shy or nervous with strangers</li> <li>Cries when mom or dad leaves</li> <li>Has favorite things and people</li> <li>Shows fear in some situations</li> <li>Hands you a book when he wants to hear a story</li> <li>Repeats sounds or actions to get attention</li> <li>Puts out arm or leg to help with dressing</li> <li>Plays games such as "peek-a-boo" and "pat-a-cake"</li> </ul>	<ul style="list-style-type: none"> <li>Responds to simple spoken requests</li> <li>Uses simple gestures, like shaking head "no" or waving "bye-bye"</li> <li>Makes sounds with changes in tone (sounds more like speech)</li> <li>Says "mama" and "dada" and exclamations like "uh-oh!"</li> <li>Tries to say words you say</li> </ul>	<ul style="list-style-type: none"> <li>Explores things in different ways, like shaking, banging, throwing</li> <li>Finds hidden things easily</li> <li>Looks at the right picture or thing when it is named</li> <li>Copies gestures</li> <li>Starts to use things correctly; for example, drinks from a cup, brushes hair</li> <li>Bangs two things together</li> <li>Puts things in a container, takes things out of a container</li> <li>Lets things go without help</li> <li>Pokes with index (pointer) finger</li> <li>Follows simple directions like "pick up the toy"</li> </ul>	<ul style="list-style-type: none"> <li>Gets to a sitting position without help</li> <li>Pulls up to stand, walks holding on to furniture ("cruising")</li> <li>May take a few steps without holding on</li> <li>May stand alone</li> </ul>
24 months	<ul style="list-style-type: none"> <li>Copies others, especially adults and older children</li> <li>Gets excited when with other children</li> <li>Shows more and more independence</li> <li>Shows defiant behavior (doing what he has been told not to)</li> <li>Plays mainly beside other children, but is beginning to include other children, such as in chase games</li> </ul>	<ul style="list-style-type: none"> <li>Points to things or pictures when they are named</li> <li>Knows names of familiar people and body parts</li> <li>Says sentences with 2 to 4 words</li> <li>Follows simple instructions</li> <li>Repeats words overheard in conversation</li> <li>Points to things in a book</li> </ul>	<ul style="list-style-type: none"> <li>Finds things even when hidden under two or three covers</li> <li>Begins to sort shapes and colors</li> <li>Completes sentences and rhymes in familiar books</li> <li>Plays simple make-believe games</li> <li>Builds towers of 4 or more blocks</li> <li>Might use one hand more than the other</li> <li>Follows two-step instructions such as "Pick up your shoes and put them in the closet."</li> <li>Names items in a picture book such as a cat, bird, or dog</li> </ul>	<ul style="list-style-type: none"> <li>Stands on tiptoe</li> <li>Kicks a ball</li> <li>Begins to run</li> <li>Climbs onto and down from furniture without help</li> <li>Walks up and down stairs holding on</li> <li>Throws ball overhand</li> <li>Makes or copies straight lines and circles</li> </ul>
36 months	<ul style="list-style-type: none"> <li>Copies adults and friends</li> <li>Shows affection for friends without prompting</li> <li>Takes turns in games</li> <li>Shows concern for a crying friend</li> <li>Understands the idea of "mine" and "his" or "hers"</li> <li>Shows a wide range of emotions</li> <li>Separates easily from mom and dad</li> <li>May get upset with major changes in routine</li> <li>Dresses and undresses self</li> </ul>	<ul style="list-style-type: none"> <li>Follows instructions with two or three steps</li> <li>Can name most familiar things</li> <li>Understands words like "in," "on," and "under"</li> <li>Says first name, age, and sex</li> <li>Names a friend</li> <li>Says words like "I," "me," "we," and "you" and some plurals (cars, dogs, cats)</li> <li>Talks well enough for strangers to understand most of the time</li> <li>Carries on a conversation using two to three sentences</li> </ul>	<ul style="list-style-type: none"> <li>Can work toys with buttons, levers, and moving parts</li> <li>Plays make-believe with dolls, animals, and people</li> <li>Does puzzles with three or four pieces</li> <li>Understands what "two" means</li> <li>Copies a circle with pencil or crayon</li> <li>Turns book pages one at a time</li> <li>Builds towers of more than six blocks</li> <li>Screws and unscrews jar lids or turns door handle</li> </ul>	<ul style="list-style-type: none"> <li>Climbs well</li> <li>Runs easily</li> <li>Pedals a tricycle (three-wheel bike)</li> <li>Walks up and down stairs, one foot on each step</li> </ul>

Continued

**TABLE 17.1** Developmental, Cognitive, and Psychosocial Stages of Children.—cont'd

Age	Social/Emotional	Language/Communication	Cognitive	Movement/Physical Development
48 months	<ul style="list-style-type: none"> <li>■ Enjoys doing new things</li> <li>■ Plays “Mom” and “Dad”</li> <li>■ Is more and more creative with make-believe play</li> <li>■ Would rather play with other children than by himself</li> <li>■ Cooperates with other children</li> <li>■ Often cannot tell what's real and what's make-believe</li> <li>■ Talks about what she likes and what she is interested in</li> </ul>	<ul style="list-style-type: none"> <li>■ Knows some basic rules of grammar, such as correctly using “he” and “she”</li> <li>■ Sings a song or says a poem from memory such as “Itsy Bitsy Spider” or “Wheels on the Bus”</li> <li>■ Tells stories</li> <li>■ Can say first and last name</li> </ul>	<ul style="list-style-type: none"> <li>■ Names some colors and some numbers</li> <li>■ Understands the idea of counting</li> <li>■ Starts to understand time</li> <li>■ Remembers parts of a story</li> <li>■ Understands the idea of “same” and “different”</li> <li>■ Draws a person with two to four body parts</li> <li>■ Uses scissors</li> <li>■ Starts to copy some capital letters</li> <li>■ Plays board or card games</li> <li>■ Tells you what he thinks is going to happen next in a book</li> </ul>	<ul style="list-style-type: none"> <li>■ Hops and stands on one foot up to 2 seconds</li> <li>■ Catches a bounced ball most of the time</li> <li>■ Pours, cuts with supervision, and mashes own food</li> </ul>
60 months	<ul style="list-style-type: none"> <li>■ Wants to please friends</li> <li>■ Wants to be like friends</li> <li>■ More likely to agree with rules</li> <li>■ Likes to sing, dance, and act</li> <li>■ Is aware of gender</li> <li>■ Can tell what's real and what's make-believe</li> <li>■ Shows more independence (for example, may visit a next-door neighbor by himself [adult supervision is still needed])</li> <li>■ Is sometimes demanding and sometimes very cooperative</li> </ul>	<ul style="list-style-type: none"> <li>■ Speaks very clearly</li> <li>■ Tells a simple story using full sentences</li> <li>■ Uses future tense; for example, “Grandma will be here.”</li> <li>■ Says name and address</li> </ul>	<ul style="list-style-type: none"> <li>■ Counts 10 or more things</li> <li>■ Can draw a person with at least six body parts</li> <li>■ Can print some letters or numbers</li> <li>■ Copies a triangle and other geometric shapes</li> <li>■ Knows about things used every day, like money and food</li> </ul>	<ul style="list-style-type: none"> <li>■ Stands on one foot for 10 seconds or longer</li> <li>■ Hops; may be able to skip</li> <li>■ Can do a somersault</li> <li>■ Uses a fork and spoon and sometimes a table knife</li> <li>■ Can use the toilet on her own</li> <li>■ Swings and climbs</li> </ul>

Adapted from Centers for Diseases Control and Prevention (CDC) [http://www.cdc.gov/ncbddd/actearly/pdf/checklists/all\\_checklists.pdf](http://www.cdc.gov/ncbddd/actearly/pdf/checklists/all_checklists.pdf) (Last accessed August 26, 2019).

**TABLE 17.2** Piaget's stages of Cognitive Development<sup>7</sup>

Stage	Ages	Features
Sensorimotor	0 to 18–24 months	Reflex, habits, object permanence
Preoperational	2 years to 7 or 8 years	Language development, symbolic functioning, difficulty in seeing things from different points of view
Concrete operational	7 or 8 years to 11 or 12 years	Begins using logic to problem solve actual (concrete) events; can see other points of view; moral feelings and judgment; autonomy
Formal operational	11 or 12 years and up	Hypotheses and reasoning

not, however, be excluded from treatment decision-making processes. According to the American Academy of Pediatrics (AAP), individuals as young as 7 years of age may be presented with diagnostic and treatment information and allowed choices about aspects of care.<sup>5,6</sup> It is around the age of 7 or 8 that children enter Piaget's concrete operational stage of cognitive development (Table 17.2).<sup>7</sup> Although children continue to think in concrete (literal) terms, they begin to utilize logic and consider other people's perspectives. Such advances can lead to certain autonomy. Piaget's next stage of cognitive development is the formal operational stage, beginning at the age of 11 or 12 years.<sup>7</sup> Children in this stage may utilize abstract thinking and a more organized approach to problem solving. A lack of perspective or life experiences, however, may limit their capacity for decision making.

When the pediatric patient begins to demonstrate an ability to think logically and understand outcomes, he should be involved in the informed consent/assent process. Assent is an interactive process; engaging the child demonstrates a respect for his emerging autonomy and may

promote confidence building and cooperation. The practitioner should provide information regarding the nature of the condition and proposed treatment plan using descriptive language and detail commensurate with the patient's cognitive ability. Booklets, videos, or models may help the patient better understand the conditions and therapeutic interventions. Sufficient time should be allotted for the patient to ask questions and demonstrate understanding of the proposed care. Assent by the minor is an expressed agreement to participate in the treatment; only the parent has the legal authority to provide permission for or refusal of care. Assent should not be solicited if the treatment is required to meet the goals of care as agreed by the parent and practitioner.<sup>5</sup> If a child's refusal for care would not be respected (e.g., risks of foregoing care exceed the benefits of intervention), the child should be so informed in developmentally appropriate way. In such cases, the patient might be allowed to decide other aspects (e.g., the timing or sequence) of care so the child does not feel excluded from the decision-making process. When assent is sought and the pediatric patient refuses treatment, practitioners

### Box 17.2 Elements of informed consent for medical decision making<sup>5</sup>

Provision of information about the following:

- The nature of the illness or condition
- The proposed diagnostic steps and/or treatments and the probability of their success
- The potential risks, benefits, and uncertainties of the proposed treatment and alternative treatments, including the option of no treatment other than comfort measures
- Assessment of patient and surrogate understanding and medical decision-making capacity, including assurance of time for questions by patient and surrogate

should inquire about the reasons for dissent in order to provide appropriate education regarding any misconceptions.<sup>6</sup> Dissent should be given serious consideration, especially when a proposed intervention is not essential and/or can be deferred without substantial risk. A good example is a teenager dissenting from recommended orthodontic treatment. If the patient is against this treatment, even though both parent and practitioner recommend it, noncompliance could easily undermine the value (e.g., poor oral hygiene leading to caries, intentional debonding of brackets).

Elements of informed consent and practical aspects of pediatric assent as described by the AAP appear in [Box 17.2](#) and [Box 17.3](#). During the informed consent process, the practitioner should consider having the patient/parent repeat back information regarding the diagnoses and proposed interventions to help assure understanding. The practitioner also should ask about the family's goals and values, including socioeconomic and cultural considerations, so that treatment decisions address the needs of all parties. Including the child in the discussion may promote cooperation with the treatment plan and home compliance. Practitioners are strongly encouraged to consult their state statutes and other resources for additional information on informed consent for pediatric patients.<sup>5,6,8</sup>

Intellectual development is probably the area most comprehensively studied, beginning in the early 1900s with the work of Alfred Binet.<sup>9</sup> The method that he employed quantified mental abilities in relation to chronologic age. It led to the concept of the intelligence quotient (IQ), one's global level of intelligence, which was measured by tasks examining the memory, spatial relationships, reasoning, and a variety of other primary mental skills. By determining the average age required to pass each task, he derived age norms. This enabled an examiner to determine a child's mental age based on performance.

Quantification of intelligence has led to various classification guides. Since the time of Binet,<sup>9</sup> more than 300 tests have been devised to measure intellectual development. The best-known and most frequently used of these tests are the Wechsler intelligence scales. These are individualized as opposed to group tests, and separate forms of the test are available for preschoolers (Wechsler Preschool and Primary Scale of Intelligence, or WPPSI), children (Wechsler Intelligence Scale for Children-Revised, or WISC-R), and adults (Wechsler Adult Intelligence Scale, or WAIS).

Intellectual functioning is measured by assessment with one or more standardized, individually administered

### Box 17.3 Practical aspects of assent by pediatric patients for medical decision making<sup>5</sup>

- Help the patient achieve a developmentally appropriate awareness of the nature of his or her condition.
- Tell the patient what he or she can expect with tests and treatments.
- Make a clinical assessment of the patient's understanding of the situation and the factors influencing how he or she is responding (including whether there is inappropriate pressure to accept testing or therapy).
- Solicit an expression of the patient's willingness to accept the proposed care.
- Ensure that there is voluntary agreement with the plan.

intelligence tests such as the Wechsler Intelligence Scales for Children or the Revised Stanford-Binet. Generally, an IQ test has a median raw score of 100 and a standard deviation of 15. Performance classifications such as "very superior" or "borderline" have been used over the years; other terms such as "upper extreme" and "lower extreme" have been suggested to reflect deviations from the norm while being more value-neutral.

Those with an IQ test score of around 70 (approximately two standard deviations below the mean) may have a significant limitation in intellectual functioning. However, *intellectual disability* requires limitations in both intellectual and adaptive functioning. Three areas of adaptive functioning are considered: conceptual, social, and practical.<sup>10</sup> Adaptive functioning is assessed through a developmental and medical history, standardized measures, and one or more reliable collateral sources (e.g., family, caregiver, and educator). Scales have been designed to quantify adaptive functioning, such as the Vineland Adaptive Behavior Scales, whose measures provide a composite score reflective of subscores in several adaptive skill domains.

Scores from tests, even the highly standardized ones, are only estimates and may not be a fair appraisal for a given child on a given day. The younger the child, the less reliable are the test scores. The more delayed the child, the less reliable are the test scores. The more an individual's cultural and educational opportunities differ from the norm, the less reliable and valid that test is for that individual. Illness, fatigue, and poor motivation also can prevent optimal performance on intelligence tests. Without evaluating the potential influences of such factors, intelligence test scores may be misinterpreted. While all children should be approached in an individualized manner, information from psychometric assessments can alert a dentist to the possibility that a child may require special behavior guidance techniques that are used infrequently for other patients. For anxious patients having an intellectual disability but with cooperative potential, desensitization to the dental setting in incremental steps prior to the initial appointment may prove beneficial. Other approaches and complimentary therapies, such as use of a sensory adapted environment (e.g., altered lighting and sounds to the specific needs of the patient)<sup>11</sup> or animal-assisted intervention (e.g., use of a trained animal to decrease a patient's anxiety, pain, or distress in a medical setting)<sup>12,13</sup> may have a calming effect and help the anxious child respond to treatment in a more positive manner.



## VARIABLES INFLUENCING CHILDREN'S DENTAL BEHAVIORS

The responses of children to the dental environment are diverse and complex. Children present for treatment with differences in age, maturity, temperament, experience, family background, culture, and oral health status. Klingberg and Broberg<sup>14</sup> reported that dental fear/anxiety and dental behavior management problems were relatively common for pediatric dental patients, each affecting 9% of children and adolescents. Girls exhibited more dental anxiety and dental behavior management problems than did boys. Dental fear/anxiety was more closely associated with temperamental traits such as shyness, inhibition, and negative emotionality, whereas behavioral problems were associated with activity and impulsivity. Blomqvist et al.<sup>15</sup> found a significant correlation between dental fear and anxiety and verbal IQ, but not any other cognitive index, in a population of children with behavior and learning problems.

Most dentists readily recognize children with dental behavior management problems, whereas dental fear and anxiety may be more subtle. Fear is best understood in the context of personal, environmental, and situational influences. It can be a normal reaction for young children, especially in unfamiliar situations where they lack control or perceive the potential for pain. As children age, with increasing ability to anticipate, understand, and control impulses, fears may be expected to decline. But if fear or anxiety is disproportionate to the situation, an unpleasant experience is likely and the child may become uncooperative and display disruptive behavior.

Dental fear/anxiety is not synonymous with dental behavior management problems. In a study of more than 3200 Swedish children, Klingberg and Berggren<sup>16</sup> found that 27% of patients with dental behavior management problems showed dental fear/anxiety, whereas 61% of those with fear/anxiety reacted with behavioral problems. The key to successful outcomes (i.e., cooperation, relief of anxiety, completion of quality care, development of a trusting relationship) is an appropriate assessment of the child and family to prepare them to participate actively in a positive manner in the child's oral health care. Dentistry has had some difficulty identifying the stimuli that lead to misbehavior in the dental office, although several variables in children's backgrounds have been related to it.

### Parental Anxiety

With few exceptions, investigations indicate a significant correlation between maternal anxiety and a child's cooperative behavior at the first dental visit. High anxiety on the part of parents tends to affect their children's behavior negatively. Parents can and do convey their fears to their children. Although analysis of the scientific data reveals that children of all ages can be affected by their mothers' anxieties, the effect is greatest with those younger than 4 years of age. This might be anticipated because of the child-parent symbiosis that begins in infancy and gradually diminishes.

### Parenting Styles

In the 1960's, Baumrind<sup>17</sup> reported a close relationship between parenting styles (patterns of behavior that parents use to interact with their children) and children's behavior.

She described three styles of parental control: permissive, authoritarian, and authoritative. The permissive parent behaves in an acceptant and nonpunitive manner, not as an agent to alter current or future behavior. The authoritarian parent values obedience and restricts autonomy. The authoritative parent, however, values both disciplined authority and autonomous self-will and will set standards for future conduct. Lee et al.<sup>18</sup> recently conducted a systematic review intended to assess the influence of parenting styles on child behavior and dental anxiety. An association between parenting styles and dental anxiety and behavior problems was limited to preschool children without dental phobia at the first dental visit. Children with authoritative parents were found to exhibit more positive behavior than those with permissive and authoritarian parents. The parent's ability to interact with a child in a consistent, positive, and nurturing way is central to the child's ability to cope and contain anxiety during dental treatment.<sup>19</sup>

### Toxic Stress

Stress is first experienced in utero and will recur throughout life. Although stress produces some minor physiologic changes, it is normal and necessary for survival. Many stresses, such as receiving immunizations and beginning daycare, are short-lived. Parents offer support to young children experiencing these stressors, but children ultimately must learn how to cope with challenges they encounter. Stress that continues over a prolonged period and has life-long effects is termed *toxic stress*. Toxic stressors include child abuse/neglect, chronic exposure to drugs or violence in the home, and parental depression or mental illness. Economic hardship is a stressor experienced by many families. Long<sup>20</sup> summarized the influence of economic hardship on children and parents. Parental support, discipline, and caregiving suffer. The child, in turn, may develop behavioral and emotional adjustment problems.

### Medical Experiences

The importance of medical experiences, a highly complex variable, has been debated over the years. There is general agreement, however, that children who view medical experiences positively are more likely to be cooperative with the dentist. The emotional quality of past visits rather than the number of visits is significant. The behavior of children with special health care needs may differ from that of healthy children. Those with chronic medical conditions (without developmental delay) can become "adultified."<sup>21</sup> Because of recurring medical experiences, they may become accustomed to the health care setting and behave "better" than expected.

Pain during previous health care visits is another consideration in a child's medical experiences. The pain may have been moderate or intense, real or imaginary. Nonetheless, parental beliefs about past medical pain are significantly correlated with their children's cooperative behavior in the dental environment. Studies have also shown that previous surgical experiences adversely influence behavior at the first dental visit, but this was not the case in subsequent visits.

### Awareness of Dental Problem

Some children may approach their dentist knowing that they have a dental problem. The problem may be as serious

as a chronic dental abscess or as simple as extrinsic staining of the dentition. However, there is a tendency toward negative behavior at the first dental visit when the child believes that a dental problem exists. Concern about the presence of caries may also lead to missed appointments. Such considerations provide the dentist with greater motivation for educating the parents about the value of establishing a dental home early—before any dental problems develop. Early, regular dental visits decrease a child's risk of preventable oral disease, help a child develop appropriate coping mechanisms, and enhance a positive attitude for future visits.

### General Behavior Problems

Klingberg and Broberg<sup>14</sup> found some support for a relationship between general behavioral problems and dental behavior management problems. Children who have difficulty focusing attention and/or adjusting activities in their general environment have increased problems complying with behavioral expectations in the dental environment. General fears can be important etiologic factors in the development of dental fears. Some children, however, have behavioral problems only in the dental environment; this may be due to previous negative experiences with dental care.

## CLASSIFYING CHILDREN'S COOPERATIVE BEHAVIOR

Numerous systems have been developed for classifying children's behavior in the dental environment. An understanding of these systems holds more than academic interest. Such knowledge can be an asset to the dentist in several ways: assisting in directing the behavior guidance approach, providing a means for the systematic recording of behaviors, and assisting in evaluating the validity of current research.

Wright's<sup>22</sup> clinical classification places children in one of three categories:

- Cooperative
- Lacking in cooperative ability
- Potentially cooperative.

When a child is being examined, his/her cooperative behavior is taken into account because it is a key to the rendering of treatment. Most children seen in the dental office cooperate. Cooperative children are reasonably relaxed. They have minimal apprehension and may even be enthusiastic. They can be treated by a straightforward, behavior-shaping approach. When guidelines for behavior are established, these children perform within the framework provided.

In contrast is the child lacking in cooperative ability. This category includes very young children with whom communication cannot be established and of whom comprehension cannot be expected. Because of their age, they lack cooperative abilities. Another group of children who lack cooperative ability is those with specific debilitating or disabling conditions. The severity of the child's condition prohibits cooperation in the usual manner. At times, special behavior guidance techniques are used for these children. Although their treatment can be carried out, immediate major positive behavioral changes cannot be expected.

Characteristically the nomenclature applied to a potentially cooperative child is "behavior problem." This type of behavior differs from that of children lacking cooperative ability because these children have the capability to perform cooperatively. This is an important distinction. When a child is characterized as potentially cooperative, clinical judgment is that the child's behavior can be modified, that is, the child can become cooperative.

The dental literature is filled with descriptions of potentially cooperative patients. Moreover, the adverse reactions have been given specific labels, such as uncontrolled, defiant, timid, tense-cooperative, and whining. Dentists often use these labels because they convey, in as few words as possible, the essence of the child's response to the dental care.

Another system that has been used in behavioral science research is the Frankl behavior rating scale.<sup>23</sup> A description of the scale that divides observed behavior into four categories follows:

- *Rating 1: Definitely negative.* Refusal of treatment, forceful crying, fearfulness, or any other overt evidence of extreme negativism.
- *Rating 2: Negative.* Reluctance to accept treatment, uncooperativeness, some evidence of negative attitude but not pronounced (sullen, withdrawn).
- *Rating 3: Positive.* Acceptance of treatment; cautious behavior at times; willingness to comply with the dentist, at times with reservation, but patient follows the dentist's directions cooperatively.
- *Rating 4: Definitely positive.* Good rapport with the dentist, interest in the dental procedures, laughter and enjoyment.

The Frankl method of classification has been a popular research tool, and it also lends itself to a shorthand form that can be used for recording children's behavior in the dental office: positive cooperative behavior can be jotted down as "+" or "+ +" and uncooperative behavior as "-" or "--." A shortcoming of this method is that the scale does not communicate sufficient clinical information regarding uncooperative children. If a child is judged as "-", the user of this classification system must qualify and categorize the reaction. If "-", "tearful" is recorded, a better description of the clinical response is made.

## THE FUNCTIONAL INQUIRY

Before the dentist treats a child, the medical, dental, and social histories are essential. However, a functional inquiry, from a behavioral viewpoint, should also be conducted. During the inquiry, there are two primary goals: (1) to learn about patient and parental concerns and (2) to gather information to enable a reliable estimate of the cooperative ability of the child. Coupling the findings from the functional inquiry with the clinical experience, the dentist is in a much better position to meet the patient's needs and to apply appropriate behavior guidance strategies to treat individual pediatric patients than by simply proceeding inadequately informed.

Usually, functional inquiries are conducted in two ways: (1) by a paper-and-pencil questionnaire completed by the parent and (2) by direct interview of child and parent. In some offices, one method may predominate, whereas in others both techniques are used. Each method has specific merits.

### Box 17.4 Clinically Relevant Questions that can be Added to History Forms

*(CIRCLE ONE)*

How do you think your child has reacted to past medical procedures?	Very well Moderately well Moderately poorly Very poorly
How would you rate your own anxiety (fear, nervousness) at this moment?	High Moderately high Moderately low Low
Does your child think there is anything wrong with his or her teeth, such as a chipped tooth, decayed tooth, or gum boil?	Yes No
How do you expect your child to react in the dental chair?	Very well Moderately well Moderately poorly Very poorly

Written questionnaires can be important tools for gaining information because probing questions can uncover critical facts about child-rearing practices at home, a child's school experiences, or the patient's developmental status. Four questions with clinical relevance that can be added to history forms are listed in [Box 17.4](#).

The responses to these questions, originally from behavioral science research, can alert the clinician to a potential behavioral problem. If a parent responds negatively to more than one question, the chance of encountering a behavior problem rises considerably. An unlimited list of questions could be prepared for paper-and-pencil questionnaires, but from the dentist's viewpoint, a lengthy list is impractical.

Most practicing dentists recognize the merits of personal contact with parents. For the personal interview to serve as an efficient functional inquiry tool, a structured framework is necessary. The paper-and-pencil questionnaire is a starting point. It provides general information or clues that help guide the personal interview. Consider the following question:

Do you consider your child to be (check one):

- advanced in learning?
- progressing normally?
- a slow learner?

If the parent has indicated that the child is a slow learner, more factual information is necessary. A leading question in the personal interview might be, "Does your child receive special services at school?" A child may receive support services through an individualized education program or attend a specialized classroom. Knowledge of the child's educational plan or special academic environment can offer a clue about the functional level of the patient. There is no limit to the depth of the personal interview, but if it is to be efficient, questioning must be thoughtful. Other avenues that can be explored include rewards and consequences used in the home environment. These provide insight into the type of behavior guidance techniques that would be acceptable to a parent.

## Parents of Pediatric Patients

From the moment of their children's birth, parents shape children's behaviors by selective encouragement and discouragement of particular behaviors, by their disciplinary techniques, or lack thereof, and by the amount of freedom they allow. In early years, at least historically, it is mainly from parents that children learn what they are supposed to do and what behavior is forbidden. Single-parent families, blended families, families with same-sex parents, and multigenerational households all have their special sets of circumstances. Furthermore, societal changes in recent years have created dynamics that can indirectly affect the behavior of children in dental offices. For example, when children are brought to dental offices by caregivers or child-care workers unfamiliar with the children's histories, and to whom the children have little attachment, insecurity may interfere with the child's ability to communicate effectively with the dentist. When providing dental care for children, it is important that dentists understand parents' expectancies. In dentist-parent relationships, a difficult question is, "What does a parent or caregiver consider an acceptable behavioral guidance technique?" Considering societal changes and that North America is a cultural mosaic with many parents having dental attitudes deeply rooted in their heritage, it is not an easy question to answer. Because some ethnic minorities rely on family elders in health care decision making, it may be wise to ask whether anyone besides the presenting parent should be included in treatment planning discussions.<sup>24</sup>

Despite the acknowledged importance of the parental role in the pediatric treatment triangle and the necessity of gaining parental cooperation, it is only recently that the dental literature has provided dentists with advice for collaborating with parents. When the parent is confused and the confusion goes unrecognized by the dentist, compliance with health behaviors suffers. Bidirectional communication is critical. Three notable works on parental acceptance are reported by Murphy et al.,<sup>25</sup> Lawrence et al.,<sup>26</sup> and Eaton et al.<sup>27</sup> The three studies are similar in design; parents are shown videotapes of different behavioral guidance methods and instructed to indicate their acceptability of them on a rating scale. The studies span two decades, provide interesting information, and show how parental attitudes change. In the earliest study, 10 techniques were videotaped.<sup>25</sup> Four of the techniques found to be acceptable were tell-show-do, positive reinforcement, voice control, and use of a mouth prop. Six techniques found to be unacceptable involved restraint methods, sedation, and general anesthesia.

The latter two studies<sup>26,27</sup> used the same videotape and demonstrated eight behavior guidance methods. All studies reported tell-show-do as the most acceptable technique. In the latter two studies, nitrous oxide sedation was found to be the next most acceptable technique. All studies were able to establish a hierarchy of parental acceptance based upon the mean ratings of parent responses, allowing for the observation of two interesting changes. Hand-over-mouth (HOM) became the least accepted technique, whereas general anesthesia became the third most accepted method for behavior guidance. HOM has since been excluded from the AAPD's Best Practices on Behavior Guidance for the Pediatric Dental Patient.<sup>28</sup>



Caution must be exercised when the results of these investigations are applied to clinical practice. Eaton et al.<sup>27</sup> noted considerable variability in parental attitudes to all techniques. Parental gender, age, and social status were unrelated to attitudes. The studies require replication with the same videotapes in different locales. Do New England parents, Spanish-speaking parents in Florida or New Mexico, Native American parents, and West Coast parents all hold the same views as do parents in the American Midwest, where these studies were performed?

Casamassimo et al.<sup>29</sup> surveyed diplomates of the American Board of Pediatric Dentistry regarding parenting styles and the impact on dental practice. Most diplomates indicated that there has been a change in parental demographics. There are more single parents, increased mobility, and more dual-income families. The findings from this report determined that children's behaviors in dental offices were strongly related to parenting styles, preferences, and demands. Failure of parents to set limits on their children's behaviors was the main parental child-rearing problem. The investigators also found that parental expectations were often unattainable. Dentists in practice must anticipate these types of problems and learn to contend with them. The diplomates suggested several methods of coping with parent's and children's behaviors; however, one recommendation dwarfed all others in frequency—the improvement of communication. Communication can mean many things, but in this instance, it refers to the dentist's getting his or her message across to the parents and having them work with the dentist. All messages should be communicated in a manner that is respectful of the family's values, beliefs, and behaviors. Building rapport is critical in gaining both parental and patient cooperation and compliance. Motivational interviewing is one technique for the assessment of parental beliefs and underlying social determinants that can be effective in altering health behaviors.<sup>30</sup>

## Strategies of the Dental Team

A primary objective during dental procedures is to lead children step by step so that they develop a positive attitude toward dentistry. Fortunately, most children progress easily and pleasantly through their dental visits, without undue pressure on themselves or the dental team. These successes can be attributed to several factors, such as a child's confident personality, a parent's proper preparation of the child for the appointment, or a dental team's excellent communicative skills. In contrast, some children's dental office experiences cause anxiety and the beginning of a negative dental attitude. Often, these controllable but apprehensive children can be managed without medication, as long as appropriate nonpharmacologic psychologic techniques are used.

Because behavior guidance techniques are used daily and come naturally to many persons, their importance sometimes is overlooked or taken for granted. This increases the potential for avoidable behavior problems. However, a full understanding and conscious implementation of strategies can lead to recognizable improvements in child management skills. Although this section heightens the awareness of various techniques commonly used in dental offices

today, it should be regarded as only a start to the study of behavior guidance strategies.

## PREAPPOINTMENT BEHAVIOR MODIFICATION

Psychologists have developed many techniques for modifying patients' behaviors by using the principles of learning theory. These techniques are called *behavior modification*. Usually they are thought about in conjunction with dentist-patient intraoperative relationships. However, preappointment behavior modification, as it is used here, refers to anything that is said or done to have a positive influence on the child's behavior before the child enters a dental operatory. The merit of this strategy is that it prepares the pediatric patient and eases the introduction to dentistry. It has received a great deal of attention because the first dental visit is crucial in the formation of the child's attitude toward dentistry. If the first visit is pleasant, it paves the road for future successes.

Several methods of preappointment behavior modification are recognized. Films or videotapes have been developed to provide a model for the young patient. The goal is for the patient to reproduce behavior exhibited by the model. On the day of the appointment, or perhaps at a previous visit, the new pediatric patient views the presentation.

Most modeling studies indicate that there is merit in introducing children to dentistry in this way, but not all studies show statistically improved cooperative behavior on the part of the children. The lack of replication may be the result of differences in experimental design, dental teams, or videotapes or films. It suggests a necessity for careful videotape or film selection for office use.

Preappointment behavior modification can also be performed with live patient models such as siblings, other children, or parents. Many dentists allow young children into the operatory with parents to preview the dental experience. Because the observing child likely will be initiated into dental care with a dental examination, a parent's recall visit offers an excellent modeling opportunity. On these occasions, many young children climb into the dental chair after their parents' appointments. These previews should be selected carefully. Young children are sometimes frightened by loud noises, as from a high-speed handpiece.

The merits of modeling procedures, commonly involving audiovisual or live models, are recognized by psychologists. Rimm and Masters<sup>31</sup> summarized them as follows: (1) stimulation of new behaviors, (2) facilitation of behavior in a more appropriate manner, (3) disinhibition of inappropriate behavior due to fear, and (4) extinction of fears. These procedures offer the practicing dentist some interesting ways to modify children's behavior before their dental visit.

Another behavior modification method involves preappointment parental education via mailings, prerecorded messages, or customized web pages. Precontact with the parent can provide directions for preparing the child for an initial dental visit, explain office procedures, and answer questions. Setting expectations for the first visit can increase the likelihood of a successful appointment. Beneficial effects of preappointment mailings were demonstrated in a controlled study by Wright et al.<sup>32</sup> Children seemed better prepared by their mothers, and the dentist saw more cooperative pediatric patients. Almost all parents

Dear Parent:

Children who have pleasant dental appointments when they are very young are likely to have a favorable outlook toward dental care throughout life. The first appointment is very important in this attitude formation. That is the reason I am writing to you.

At our first appointment, we will examine your child's teeth and gums and take any necessary x-ray films. For most children, this will be an interesting and even happy occasion. All the people on our staff enjoy children and know how to work with them, but you, parents, play an important role in getting children started with a good attitude toward dental care. One of the useful things that you can do is to be completely natural and easygoing when you tell your child about the appointment with the dentist. This approach enables children to view their dental visit as an opportunity to meet some new people who want to help them stay healthy.

Your cooperation is appreciated. Remember, good general health depends partly on the development of good habits, such as sensible eating, sleeping routines, and exercise. Dental health also depends on good habits, such as proper toothbrushing, regular dental visits, and a good diet. We will have a chance to further discuss these points during your child's appointment.

Sincerely,

**Fig. 17.2** Letter to assist parents in preparing children for first dental visit. (Adapted from Wright GZ, Alpern GD, Leake JL. The modifiability of maternal anxiety as it relates to children's cooperative dental behavior. *J Dent Child.* 1973;40:265–271.)

understood the letter's contents, acknowledged the dentist's thoughtfulness, and welcomed the concern for the proper presentation to their children. A similar letter is shown in Fig. 17.2. Dentists using preappointment educational materials should be selective. Overpreparation could confuse a parent or provoke unnecessary anxiety.

## FUNDAMENTALS OF BEHAVIOR GUIDANCE

Behavior guidance involves the total dental health team. Indeed, many dental auxiliaries are invaluable when it comes to providing care for children. All personnel have a stake in guiding a child through the dental experience.

Over the years, behavior guidance has meant different things to different people. In 1895 McElroy<sup>33</sup> wrote, "Although the operative dentistry may be perfect, the appointment is a failure if the child departs in tears." This was the first mention in dental literature of measuring the success or failure of a child's appointment by anything other than technical proficiency. Pediatric dentistry has progressed since then, and one definition of behavior guidance is as follows:

*Behavior guidance is the means by which the dental health team effectively and efficiently performs treatment for a child and, at the same time, instills a positive dental attitude.*

*Effectively* in this definition refers to the provision of high-quality dental care. Efficient treatment is a necessity in private practice today. Quadrant dentistry, or perhaps half-mouth dentistry, utilizing auxiliary personnel, is vital in the delivery of efficient service to children. Finally, the development of a pediatric patient's positive attitude is an integral part of this definition. In the past, many practitioners have considered "getting the job done" to be behavior

management. The current definition suggests a great deal more.

What has been omitted from the definition of behavior guidance is interesting. There is no mention of any specific techniques or modalities of treatment. The definition allows for the exercise of individuality. The challenge to the dentist is to satisfy the elements of the definition as frequently as possible and as safely as possible for each child in a dental practice.

Although various approaches to engaging pediatric dental patients have evolved over the years, certain practices and concepts remain fundamental to successful behavior guidance. These are basic to the establishment of good dental team–pediatric patient relationships. These practices increase the chances for success in the provision of care for children. They should be considered inviolate. The following fundamentals of behavior guidance center on the attitude and integrity of the entire dental team.

### Positive Approach

There is general agreement that the attitude or expectations of the dentist can affect the outcome of a dental appointment. The child will respond with the type of behavior expected. In essence, the child fulfills the dentist's prophecy. Thus positive statements increase the chances of success with children. They are more effective than thoughtless questions or remarks. To obtain success with children, it is important that the dentist anticipates success.

### Team Attitude

Personality factors such as warmth and interest that can be conveyed without a spoken word are critical when children are treated. A pleasant smile tells a child that an adult cares. Children respond best to a natural and friendly attitude. Often this can be conveyed immediately to the pediatric

patient through a casual greeting. Children also can be made to feel comfortable in the dental office by the use of nicknames, which can be placed on a patient's record. Noting school accomplishments or extracurricular activities such as scouting, baseball, gymnastics, or other hobbies helps in initiating future conversations and demonstrates a friendly, caring attitude to a pediatric patient. Limiting the focus of conversations to the individual patient and his needs during the delivery of dental care can allow the patient to feel prioritized.

### Organization

Plans in the dental office have many dimensions, beginning, for example, with the reception area. Who summons the new patient—the dentist, the dental assistant, the dental hygienist, or the receptionist? Who will address the problem if a child creates a disturbance in the reception area? Each dental office must devise its own contingency plans, and the entire office staff must know in advance what is expected of them and what is to be done. Such plans are key features of many pediatric dental offices because they increase efficiency and contribute to successful dental staff–pediatric patient relationships. Also, a well-organized, written treatment plan must be available for the dental office team. Delays and indecisiveness can build apprehension in young patients.

### Truthfulness

Unlike adults, most children see things as either “black” or “white.” The shades between are difficult for them to discern. To youngsters, the dental health team is either truthful or not. Because truthfulness is extremely important in building trust, it is a fundamental principle in caring for children. Recognizing and acknowledging a patient's fear and anxiety can strengthen that trust. Empathizing with, rather than denying, such emotions helps provide assurance that the dentist appreciates the patient as an individual.

### Tolerance

Tolerance level, a seldom discussed concept, varies from person to person. It refers to the dentist's ability to cope rationally with misbehaviors while maintaining composure. Recognizing individual tolerance levels is especially important in the treatment of children. In addition to varying from person to person, tolerance levels fluctuate for a given individual. For example, an upsetting experience at home can affect the clinician's mood in the dental office. Some people are in a better frame of mind early in the morning, whereas the coping abilities of others improve as the day progresses. Thus afternoon people should instruct receptionists not to book children with behavior problems the first thing in the morning. Learning to recognize factors that overtax tolerance levels is another fundamental because it prevents loss of self-control.

### Flexibility

Because children can also experience fluctuations in tolerance between appointments or even during an appointment, the dental team must be prepared to change its plans at times. A child may begin fretting or squirming in the dental chair after half an hour, and the treatment intended for that day may have to be divided into multiple appointments.

On the other hand, a dentist may plan a step-wise indirect pulp treatment, but because the child is fidgety and treatment is difficult, the indirect pulp procedure may have to be completed during a single session. Many dentists, following accepted four-handed dentistry practices, work at the 11-o'clock or 12-o'clock position. Treatment of small children may demand a change in operating position. Thus the dental team must be as flexible as the situation demands.

## COMMUNICATING WITH CHILDREN

Several effective communication techniques can be suggested. These key points are guidelines and not inflexible rules because in the unpredictable world of pediatric health care, one must always be prepared to improvise.

### Establishment of Communication

Previous editions of this textbook have stated that the first objective in the successful management of the young child is to establish communication. Involving a child in a conversation not only enables the dentist to learn about the patient but also may relax the child. There are many ways of initiating verbal communication, and the effectiveness of these approaches differs with the age of the child. Generally, verbal communication with younger children is best initiated with complimentary comments, followed by questions that elicit an answer other than “yes” or “no.”

### Establishment of the Communicator

Members of the dental team must be aware of their roles when communicating with a pediatric patient. Generally, the dental assistant talks with the child during the transfer from reception room to the operatory and during preparation of the child in the dental chair. When the dentist arrives, the dental assistant usually assumes a more passive role because the child can listen to only one person at a time. It is important that communication occurs from a single source. When both the dentist and dental assistant provide directions, the result may be a response that is undesirable simply because the child becomes confused. The same holds true when parents are present in the operatory. The communication must be primarily bidirectional, between the dentist and the child.

### Message Clarity

Communication is a complex, multisensory process. It includes a transmitter, a medium, and a receiver. The message must be understood in the same way by both the sender and the receiver. Very often, to improve the clarity of messages to young patients, dentists use euphemisms to explain procedures. For pediatric dentists, euphemisms or word substitutes are like a second language. Examples of word substitutes that can be used to explain procedures to children are listed in [Box 17.5](#).

It is important to be careful in selecting words and phrases used to indoctrinate the new pediatric dental patient because for the young child, language labels are the basis for many generalizations. The classic example is the language label for “doctor,” which confuses many youngsters. This is known as *mediated generalization*. Eventually, as a result of experiences, the child learns that the “dentist doctor” is different from the “physician doctor” and that



### Box 17.5 Word substitutes for explaining procedures to children

Dental terminology	Word substitutes
Rubber dam	Rubber raincoat
Rubber dam clamp	Tooth button
Rubber dam frame	Coat rack
Sealant	Tooth paint
Fluoride varnish	Tooth vitamins
Air syringe	Wind gun
Water syringe	Water gun
Suction	Vacuum cleaner
Alginate	Pudding
Study models	Statues
High-speed handpiece	Whistle
Low-speed handpiece	Motorcycle
Stainless-steel crown	Silver cap
Radiographs	Tooth pictures
Local anesthetic	Sleepy juice
Cement	Tooth glue
Gauze	Tooth towel
Prophylaxis cup	Tooth polisher

the physician's office and the dentist's office are different environments. The process of sorting out such differences is referred to as *discrimination*.

#### Voice Control

Throughout the dental literature, reference is made to voice control. It is difficult to describe this effective communicative technique using the written word. In one form of voice control, sudden and firm commands are used to capture the child's attention, establish authority, or to stop the child's undesirable behavior. Another form of voice control is a slow and deliberate cadence that can function like music to set a mood. In both cases, how it is said is more important than what is said because the dentist is attempting to influence behavior directly, not through understanding.

Although dentists have long recognized the merits of employing voice control when children's behaviors have been disruptive, Greenbaum et al.<sup>34</sup> have given it scientific credence. Considering the use of loud commands as a punishment technique, they compared the effects of loud and normal voice commands given to 40 children with potential behavior problems. Their findings demonstrated that loud commands reduced disruptive behaviors.

Chambers<sup>35</sup> theory is that voice control is most effective when used in conjunction with other communications. A sudden command of "Johnny, pay attention!" may be a preliminary measure necessary for future communication. The same message spoken in a foreign language probably would be equally effective in stopping disruptive patient behavior that was preventing communication. When the child follows the directive, such response should be acknowledged and the conversation continued in a positive tone. Used properly in correct situations, voice control is an effective behavior guidance tool. However, because parents may find abrupt, loud, and/or firm commands to be an aversive technique, discussing voice control with parents prior to its use may decrease the risk for misunderstanding.<sup>28</sup>

#### Multisensory Communication

In verbal communications, the focus is on what to say or how it is said. However, nonverbal messages can also be sent to patients or received from them. Body contact can be a form of nonverbal communication. The dentist's simple act of placing a hand on a child's shoulder while sitting on a chairside stool conveys a feeling of warmth and friendship. Greenbaum et al.<sup>34</sup> found that this type of physical contact helped children to relax, especially those aged 7 to 10 years.

Eye contact is also important. The child who avoids it often is not fully prepared to cooperate. Apprehension can be conveyed without a spoken word. Detecting a rapid heart-beat or noticing beads of perspiration on the face are observations that alert the dentist to a child's nervousness. When the dentist talks to children, every effort should be made not to tower above them. Sitting and speaking at eye level allow for friendlier and less authoritative communications.

#### Problem Ownership

In difficult situations, dentists sometimes forget that they are guiding the behavior of children. They begin by sending "you" messages, for example, "You stop that immediately!" or "If you don't stay still, we will have to hold your hands." "You" messages have been termed *roadblocks to communication*; instead of gaining cooperation, they only undermine the rapport between a pediatric patient and dentist. Nash<sup>36</sup> discussed that "you" messages may impugn a child's character, depreciate him as a person, shatter his self-esteem, underscore his inadequacies, and cast judgment. They are more likely to provoke conflict and rebellion than "I" messages. "I" messages reflect the practitioner's experience and disclose the focus of the problem, such as "I can't fix your teeth if you don't open your mouth wide." They are honest, clear, and inarguable. This self-disclosing assertiveness is one technique that is particularly well suited to increase the flow of information between the dentist and the pediatric patient.

A technique that encourages the use of "you" is *attending*. Attending describes the desirable conduct to help shape compliance.<sup>21</sup> For example, "You are staying so still" reinforces the specific cooperative behavior that is necessary for the treatment to be completed. Positive attention to discrete behaviors confirms to children that they are doing what was requested and can nurture the relationship between patients and providers.

#### Active Listening

Listening is important in the treatment of children. Children express their feelings by words and by actions. Listening to the spoken words may be more important in establishing rapport with the older child, whereas attention to nonverbal behavior is often more crucial in guiding the behavior of a younger child. Active listening mirrors the communicated emotion. Whether the child says "I'm scared" or hesitates in opening his mouth, the dentist needs to acknowledge, not ignore, what the child is feeling. Sensitivity to the expressed emotions can reassure the child and encourage genuine communication. The patient is stimulated to express feelings, and the dentist does the same, as necessary processes in communication.

## Enhancing Control

Enhancing control can influence how the patient experiences a situation. Allowing an anxious child to have some sense of control during procedures may help contain anxiety and avert disruptive behaviors. This technique allows the patient to alert the dentist through the use of a predetermined stop signal (e.g., a raised hand) that he needs a brief pause before continuing care. Use of this technique has been shown to reduce pain during injection and routine dental care.<sup>19</sup> The signal should be rehearsed, and the dentist should act quickly in response to its use. This technique, if introduced too early in the fear hierarchy, may actually increase anxiety by implying that the child has need to be concerned about the impending care.<sup>19</sup>

## Appropriate Responses

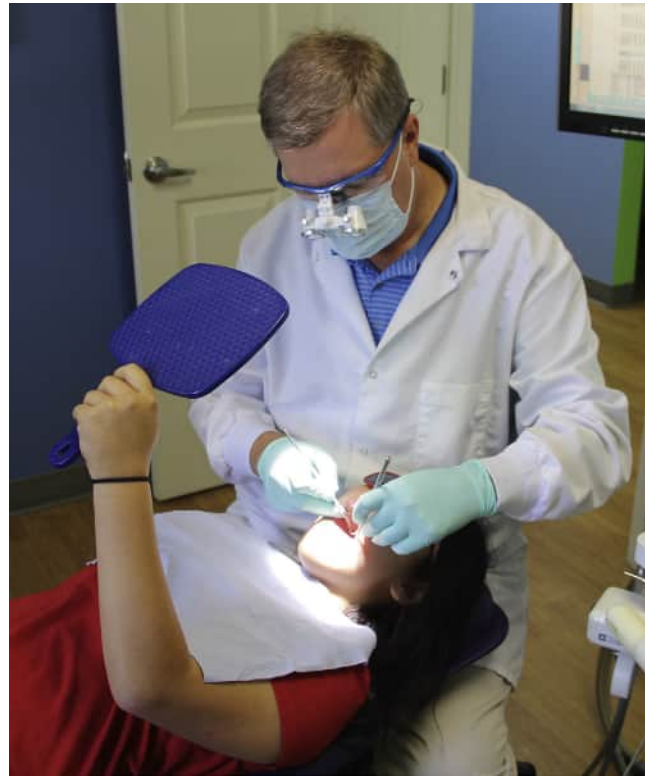Another principle in communicating with children is that the response should be appropriate to the situation. The appropriateness of the response depends primarily on the extent and nature of the relationship with the child, the age of the child, and evaluation of the motivation of the child's behavior. An inappropriate response would be a dentist displaying extreme displeasure with an anxious young child on the first visit when there has been insufficient time to establish a good rapport. On the other hand, if a dentist has made inroads with a child who then displays unacceptable behavior, a dentist may well express disapproval without losing personal control. The response is then appropriate.

## BEHAVIOR SHAPING

Behavior shaping is a common nonpharmacologic technique. It is a form of behavior modification; hence, it is based on the established principles of social learning. By definition, it is that procedure which very slowly develops behavior by reinforcing successive approximations of the desired behavior until the desired behavior occurs. Proponents of the theory hold that most behavior is learned and that learning is the establishment of a connection between a stimulus and a response. Therefore, it is sometimes called stimulus-response theory.

When shaping behavior, the dental assistant or dentist is teaching a child how to behave. Young children are led through these procedures step by step. Patients have to be communicative and cooperative to absorb information that may be complex for them. The following is an outline for a behavior-shaping model:

1. State the general goal or task to the child at the outset.
2. Explain the necessity for the procedure. A child who understands the reason is more likely to cooperate.
3. Divide the explanation for the procedure. Children cannot always grasp the overall procedure with a single explanation; consequently, they have to be led through the procedure slowly.
4. Give all explanations at a child's level of understanding. Use euphemisms appropriately.
5. Use successive approximations. Since its introduction in 1959, tell-show-do has remained a cornerstone of behavior guidance. It is a series of successive approximations, and it should be used routinely by all members of the dental team who work with children. Dental



**Fig. 17.3** Child views intraoral procedure with hand mirror. If the mirror blocks light to the oral cavity, a smaller mirror is used. With fiberoptic handpieces, blockage of light is not a problem.

assistants, dental hygienists, and dentists should demonstrate various instruments step by step before their application by telling, showing, and doing. When the dentist works intraorally, a pediatric patient should be shown as much of the procedure as possible. Only when the child has a view of the procedures being undertaken are successive approximations being performed properly (Fig. 17.3).

6. Reinforce appropriate behavior. Be as specific as possible because specific reinforcement is more effective than a generalized approach. Immediate and specific reinforcements can reduce children's fear-related behaviors.
7. Disregard minor inappropriate behavior. Ignored minor misbehavior tends to extinguish itself when not reinforced.

Behavior shaping is regarded as a learning model. The most efficient learning models are those that follow the learning theory model most closely. Deviations from the model create less efficiency in terms of learning. One way to improve consistency in this area is for the dental team to record various clinical sessions with pediatric patients and then to review the recordings, keeping in mind the basics of the behavior-shaping learning model.

Although tell-show-do is similar to behavior shaping, the two differ. In addition to demanding the reinforcement of cooperative behavior, behavior shaping also includes the need for steps to be retraced if misbehavior occurs. For example, if a child is shown an instrument and looks away, the dentist must go back to the explanatory portion of the procedure. Behavior shaping requires that the "desired behavior" be observed along the way. If the dentist

proceeds along the sequential steps and begins performing treatment when the desired behavior is not present, there is deviation from the learning model and a greater likelihood of increased misbehavior.

## RETRAINING

Children who require retraining approach the dental office displaying considerable apprehension or negative behavior. The demonstrated behavior may be the result of a previous dental visit or the effect of improper parental or peer orientation. Determining the source of the problem is helpful because the undesirable behavior can then be avoided through another technique or deemphasized, or a distraction can be used. These ploys begin the retraining program, which eventually leads to behavior shaping.

When encountering negative behavior, the dentist should always remember that an objective is to build a new series of associations in the child's mind. If a child's expectation of being hurt is not reinforced, a new set of expectations is learned. The dentist can be trusted! The child develops a new perception of the dental office and a new relationship to dentistry. Unacceptable behavior previously learned extinguishes. It is critical to remember that the stimulus must be altered to elicit a change in the response.

Individuals respond to stimuli to which they have been preconditioned. If the original stimulus and the new one are very similar, then the response will be similar. This is known as *stimulus generalization*. If a child has had an unpleasant experience in the dental office and then is taken to a different office where there is a different dentist and an entirely different staff and surroundings, the child still tends to generalize that an unpleasant event will occur in this new dental office. There are enough similar stimuli to produce this response. To offset the generalization, the dental team must demonstrate a "difference." This is one of the reasons why the use of nitrous oxide–oxygen sedation often works when retraining children. It offers a difference.

## PRACTICAL CONSIDERATIONS

Some procedural aspects of dental practice help guide children successfully through their dental experiences. Like many of the techniques described previously, they have evolved over the years without being experimentally tested. Nevertheless, these practical considerations form an integral part of modern day dental practice. They also would be fruitful areas for future research.

### Scheduling

Children are bundles of energy. Lacking the patience of adults, many children become restless and tired when faced with long delays in a reception area. This should be considered when designing an office schedule. A good general rule is that a child should not be kept waiting in the reception area and that every effort should be made to be on time.

Morning appointment times have been suggested for children. It is a practice that has guided scheduling in many dental offices because children are more alert and the dental team is fresher in the morning. Many dentists also believe that when age groups are kept together (preschoolers in the morning and older children in the afternoon), the peer

group has a positive influence, with children serving as models for each other. Another advantage is that the dental office may run more smoothly with less psychological change of pace.

Sometimes expediency rather than a realistic evaluation of a child's behavior may predispose the dentist toward morning appointments for preschool children. Frequently, it is easier to persuade parents to take younger children out of nursery school or kindergarten than to arrange morning appointments for elementary or junior high school children. From a behavioral standpoint, other factors seem important when appointment times are determined. Patient-related concerns include patient age, presence of a disabling condition, and need for any sedation. The dentist's attitude is also important. Some dentists avoid seeing children with behavior problems first thing in the morning. A policy regarding scheduling should be formulated by the dentist, and scheduling should not be left to chance.

Another scheduling concern has been appointment length. Historically, writers have agreed that the nature of childhood precludes giving the sustained attention that may be required for long dental visits. Improved technology, the application of time and motion studies by efficiency experts, and a trend toward quadrant or half-mouth dentistry have influenced contemporary practices. A 2018 systematic review by Jamali et al.<sup>37</sup> found a general tendency toward deterioration of behavior with an increase in the treatment duration and that younger children are more likely to demonstrate negative behavior with an increase in treatment time. Appointment duration must not be extended beyond a patient's tolerance level solely for the practice's convenience.

### Parent-Child Separation

Years ago, parents did not expect to enter the operator. Today's parents actively participate in health care services through the process of informed consent, and increasingly want to accompany their children during their health care experiences. Having parents stay with their child can streamline informed consent and communication into the normal office flow. Adair et al.<sup>38</sup> found that a clear majority of pediatric dentists in all age/gender groups allowed parents to be present in the operator for a variety of procedures. In addition to increasing communication efficiency, parental presence can reassure both the child and the parent. Parents can witness the dentist's compassionate approach and hear the educational instructions provided to the children. At the same time, the dentist obtains rapid feedback on parental attitudes and beliefs.

A parent can be a major asset in supporting and communicating with a child who has a disability, often providing important information and interpretation. Because of the close symbiotic relationship that very young children (those who have not reached the age of understanding and full verbal communication) have with their parents, they often remain together. Excluding the parent from the operator could be justified for many reasons, including parental interference and limitations on dentist-child interactions. With older children, an independent experience may contribute toward development of confidence and appropriate coping mechanisms and, ultimately, a positive attitude on the part of the child. Furthermore, an adolescent may wish



to discuss personal health history concerns in confidence. Another reason for advocating a separation policy is that the dentist may be more relaxed and comfortable when the parent remains in the reception area, so as not to be perceived as “performing.” As a consequence of this more relaxed manner, the dentist’s actions are likely to have a more positive effect on the child’s behavior.

The separation procedure warrants serious consideration. The dentist must develop an office policy, inform the office staff, and assume responsibility to train office personnel in reception room strategies. In this age of accountability, the dentist may also have to explain the policy to a parent. Establishment of the policy should therefore be based on a rationale that takes into account the benefits and drawbacks resulting from separation, the benefits to the individual child, and the dental team’s personal comfort level. Because some dentists become tense when parents are present and others enjoy having parents in the operatory, an office policy becomes an individual decision to some extent.

### Tangible Reinforcements

Giving gifts to children has become a fact of commercial life in North America. There is general agreement on the merit of this practice in the dental office. Giving a gift can serve as a reward, especially much better if the gift has a dental significance (e.g., an oral hygiene kit). In these situations the gift is also used to reinforce the importance of oral health.

Various trinkets in a toy chest should be used as tokens of affection for children, not as bribes. The practice of giving gifts can have spectacular results. Many children who seem tense during operative procedures suddenly perk up when the procedures are completed and scurry for a gift. These gifts provide a pleasant reminder of the appointment.

### LIMITATIONS

Today’s children differ from those of past generations. They begin school earlier. Through the media, they are more aware than children were years ago. We hear more of children facing poverty, experiencing learning disorders, and developing poor coping skills, and are more aware of children with eating disorders and drug use. Children also have legal and social advocates who have influenced management techniques. Limitations on the dentist exist today that were unheard of previously.

Parenting also has changed. Much of the behavioral science research was done with traditional families in the 1960s and 1970s. Single-parent homes were less common, and terms such as *reconstituted families* and *same-sex marriages* were unknown. What about the child-rearing practices in these families? Decades ago, when “father” came to the office, it usually meant that the child had a behavior problem and “father” was the enforcer. With both parents working or with single-parent families, it is not unusual for a father to accompany a child to the dental office. Have parental expectations changed in the dental office? Yes. This chapter discusses the reasons why parents might be excluded from the operatory, but it also urges periodic review of the policy. Many parents insist on their right to accompany their child. Societal changes influence our management methods, and there is a need to review past research carefully and assess its applicability to the present.

Dentists also face societal limitations, and they are changing their approaches to management. Modern behavior guidance for the pediatric dental patient places a greater focus on communication techniques and a decreased or discontinued use of physical approaches. Parental concerns, as well as legal and ethical considerations, have resulted in a decreased or discontinued use of the controversial technique HOM. Furthermore, an increased acceptance of pharmacologic management techniques has been noted.<sup>39</sup>

The corners of the pediatric treatment triangle have been changing rapidly, which influences the practice of dentistry for children. Recognizing these changing times, the Council on Clinical Affairs of AAPD regularly updates its best practices for behavior guidance.<sup>28</sup> The techniques recommended in this chapter conform to these recommendations. Dental students and dentists must remember to keep abreast of the times in this highly dynamic area.

### References

1. Wright GZ, Kupietzky A: Introductory remarks. In Wright GZ, Kupietzky A, editors: *Behavior management in dentistry for children*, ed 2. Ames, Iowa, 2014, Wiley Blackwell, pp 3–9.
2. Juntgen LM, Sanders BJ, Walker LA, et al.: Factors influencing behavior guidance: a survey of practicing pediatric dentists. *Pediatr Dent* 35(7):539–545, 2013.
3. Boyce WT: The lifelong effects of early childhood adversity and toxic stress. *Pediatr Dent* 36(2):102–108, 2014.
4. Gesell A, Ilg FL: *Child development: an introduction to the study of human growth*. New York, 1949, Harper & Row.
5. American Academy of Pediatrics Committee on Bioethics: Policy statement: Informed consent in decision-making in pediatric practice. *Pediatrics* 138(2):e20161484, 2016.
6. Katz AL, Webb SA: American Academy of Pediatrics Committee on Bioethics. Technical report: informed consent in decision-making in pediatric practice. *Pediatrics* 138(2):e20161485, 2016.
7. Piaget J, Inhelder B: *The psychology of the child*. 1969. Originally published in French: *La Psychologie de l'enfant*, Paris, 1966, Presses Universitaires de France.
8. American Academy of Pediatric Dentistry. Best Practices on Informed Consent. 2019. In Press.
9. Binet A: New methods for the diagnosis of the intellectual level of subnormals. *Amee Psychol* 12:191–244, 1905.
10. American Psychiatric Association: What is intellectual disability?. Available at: <https://www.psychiatry.org/patients-families/intellectual-disability/what-is-intellectual-disability>.
11. Shapiro M, Melmed RN, Sgan-Cohen HD, et al.: Effect of sensory adaptation on anxiety of children with developmental disabilities: a new approach. *Pediatr Dent* 31(3):222–228, 2009.
12. Waite TC, Hamilton L, O'Brien W: A meta-analysis of animal assisted interventions targeting pain, anxiety and distress in medical settings. *Complement Ther Clin Pract* 33:49–55, 2018.
13. Charry-Sánchez JD, Pradilla I, Talero-Gutiérrez C: Effectiveness of animal-assisted therapy in the pediatric population: systematic review and meta-analysis of controlled studies. *J Dev Behav Pediatr* 39(7):580–590, 2018.
14. Klingberg G, Broberg AG: Dental fear/anxiety and dental behaviour management problems in children and adolescents: a review of prevalence and concomitant psychological factors. *Int J Paediatr Dent* 17(6):391–406, 2007.
15. Blomqvist M, Ek U, Fernell E, et al.: Cognitive ability and dental fear and anxiety. *Eur J Oral Sci* 121(2):117–120, 2013.
16. Klingberg G, Berggren U, Carlsson SG, et al.: Child dental fear: cause-related factors and clinical effects. *Eur J Oral Sci* 103(6):405–412, 1995.
17. Baumrind D: Effects of authoritative parental control on child behavior. *Child Dev* 37(4):887–907, 1966.
18. Lee DW, Kim JG, Yang YM: The influence of parenting style on child behavior and dental anxiety. *Pediatr Dent* 40(5):327–333, 2018.
19. Campbell C, Soldani F, Busuttill-Naudi A, et al.: British Society of Paediatric Dentistry Guidelines: Update of non-pharmacological behaviour management guideline, 2011. Available at: <https://pdfs.semanticscholar.org/df1e/9887d77186a777d5ee78e0e831d34707de01.pdf>.

20. Long N: Stress and economic hardship: the impact on children and parents, *Pediatr Dent* 36(2):109–114, 2014.
21. Fisher-Owens S: Broadening perspectives on pediatric oral health care provision: social determinants of health and behavior management, *Pediatr Dent* 36(2):115–120, 2014.
22. Wright GZ: *Behavior management in dentistry for children*, Philadelphia, 1975, WB Saunders.
23. Frankl SN, Shiere FR, Fogels HR: Should the parent remain in the operator? *J Dent Child* 29(1):150–163, 1962.
24. Goleman J: Cultural factors affecting behavior guidance and family compliance, *Pediatr Dent* 36(2):121–127, 2014.
25. Murphy ML, Fields Jr HW, Machen JB: Parental acceptance of pediatric dentistry behavior techniques, *Pediatr Dent* 6(4):193–198, 1984.
26. Lawrence SM, McTigue DM, Wilson S, et al. Parental attitudes toward behavior management techniques in pediatric dentistry. *Pediatr Dent*. 99(1);13(3):151
27. Eaton JJ, McTigue DJ, Fields HW, et al.: Attitudes of contemporary parents toward behavior management techniques used in pediatric dentistry, *Pediatr Dent* 27(2):107–113, 2005.
28. American Academy of Pediatric Dentistry: Best practices for behavior guidance for the pediatric dental patient, *Pediatr Dent* 40(special issue):254–267, 2018.
29. Casamassimo P, Wilson S, Gross L: Effects of changing US parenting styles on dental practice: perceptions of diplomates of the American Board of Pediatric Dentistry, *Pediatr Dent* 24(1):18–22, 2002.
30. Watt RG: Motivational interviewing may be effective in dental setting, *Evid Based Dent* 11(1):13, 2010.
31. Rimm DC, Masters JC: *Behavior therapy: techniques and empirical findings*, New York, 1974, Academic Press.
32. Wright GZ, Alpern GD, Leake JL: The modifiability of maternal anxiety as it relates to children's cooperative dental behavior, *J Dent Child* 40:265–271, 1973.
33. McElroy CM: Dentistry for children, *Calif Dent Assoc Trans* 85, 1895.
34. Greenbaum PE, Lumley MA, Turner C, et al.: Dentist's reassuring touch: effects on children's behavior, *Pediatr Dent* 15(1):20–24, 1993.
35. Chambers DW: Behavior management techniques for pediatric dentists: an embarrassment of riches, *J Dent Child* 44(1):30–34, 1977.
36. Nash DA: Engaging children's cooperation in the dental environment through effective communication, *Pediatr Dent* 28(5):455–459, 2006.
37. Jamali Z, Najafpour E, Aminabadi NA, et al.: Does the length of dental procedure influence children's behavior during and after treatment? A systematic review and critical appraisal, *J Dent Res Dent Clin Dent Prospect* 12(1):68–76, 2018.
38. Adair SM, Schafer TE, Waller JL, et al.: Age and gender differences in the use of behavior management techniques by pediatric dentists, *Pediatr Dent* 29(5):403–408, 2007.
39. Patel M, McTigue DJ, Thikkurissy S, et al.: Parental attitudes toward advanced behavior guidance techniques used in pediatric dentistry, *Pediatr Dent* 38(1):30–36, 2016.

### Suggested Readings

Centers for Diseases Control and Prevention (CDC) [https://www.cdc.gov/ncbddd/actearly/pdf/checklists/all\\_checklists.pdf](https://www.cdc.gov/ncbddd/actearly/pdf/checklists/all_checklists.pdf) (Last accessed August 26, 2019).

## 18

# Pharmacologic Management of Patient Behavior

MARK A. SAXEN

## CHAPTER OUTLINE

**Definition of Terms**

Pharmacologic Management  
 The Continuum of Anesthesia and Sedation  
**Fundamental Concepts**  
 Anatomic and Physiologic Differences  
 Routes of Drug Administration  
 Drugs and Agents Used for Sedation  
 Antihistamines  
 Benzodiazepine Agonists and Antagonists  
 Opioid Agonists and Antagonists  
 Other Sedative-Hypnotics  
**Nitrous Oxide Administration**  
 Objectives  
 Equipment  
 Technique

**Monitoring and Documentation**

**Enteral Sedation Technique**  
**Combinations of Methods and Agents**  
**Facilities and Equipment**  
**Documentation**  
**Patient Selection and Preparation**  
 Indications  
 Preoperative Evaluation  
 Informed Consent  
 Instructions to Parents  
**Monitoring**  
 Intraoperative Monitoring  
 Postoperative Monitoring  
**Concluding Thoughts**

## Definition of Terms

### PHARMACOLOGIC MANAGEMENT

Pharmacologic management is a broad term that describes the use of drugs to manage the behavior of pediatric patients undergoing dental procedures. The types of drugs used include inhaled gases, oral medications, drugs administered via intravenous infusion, intramuscular injection, and other routes of administration. Pharmacologic management is further divided into two subcategories, sedation and general anesthesia.<sup>1</sup> This chapter will focus on minimal and moderate sedation (formerly termed “conscious sedation”), as administered by the dentist while simultaneously performing dental procedures in the dental office.

Dentists often think of sedation as a limited form of anesthesia that falls within the broader realm of behavior management (Fig. 18.1). In contrast, anesthesiologists view sedation as part of a broader physiologic continuum that ranges from an awake, relaxed, conscious state to unconscious with no responsiveness. The level of sedation often changes during the course of medical and dental procedures, and the distinction between different levels of sedation and general anesthesia is not always well defined (Fig. 18.2). When sedation is administered to children, respiratory depression and loss of protective reflexes may occur rapidly and unexpectedly, regardless

of the intended level of sedation. Furthermore, maintaining a sustained level of moderate sedation can be difficult. Dr. Charles Coté, a well-known pediatric anesthesiologist and educator, maintains that the term “conscious sedation” is an oxymoron when applied to young children. “When caring for young children, particularly when they have to remain quiet for any length of time, one must induce pharmacologic coma” (deep sedation/general anesthesia).<sup>2</sup>

Incorporating sedation into a dental practice requires knowledge and skills beyond the scope of many predoctoral education programs. Very few dentists pursue the advanced residency training required to administer sedation and general anesthesia in a dental office. Pediatric dental residency programs provide training that allows pediatric dentists to administer minimal and moderate sedation in their practices. Professional and state standards usually require additional trained staff to be present when sedation is administered to dental patients.<sup>3</sup> Taken together, these reasons illustrate why the term *pharmacologic management* remains nebulous and may explain why it is not commonly and universally practiced by pediatric dentists.<sup>4</sup> In spite of these issues, pharmacologic management provides a valuable component to the pediatric dental practice. Safe and effective practice of this skill requires a broad understanding of pharmacology, physiology, current professional standards, and relevant outcomes.



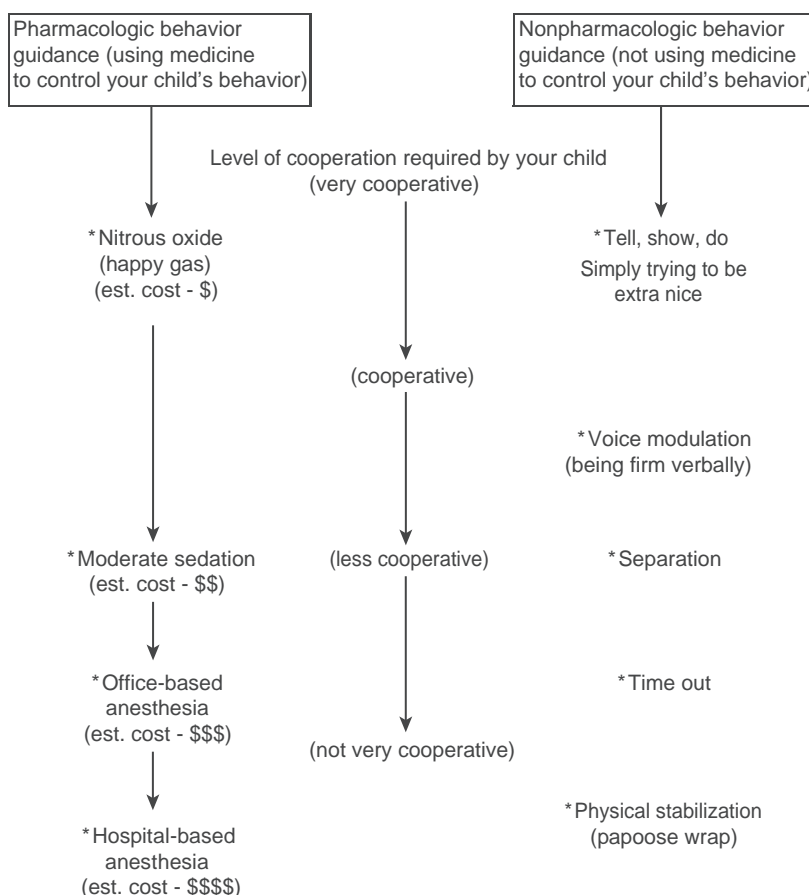


Fig. 18.1 Behavior guidance flowchart. (Adapted from the private practice of Dr. Matthew Pate, Kokomo, Indiana.)

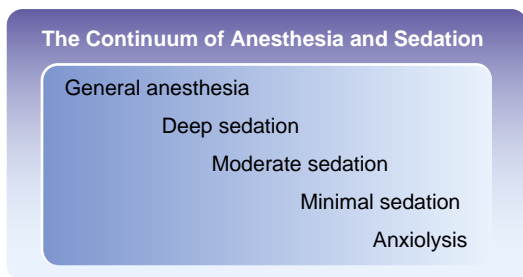


Fig. 18.2 Clinical assessment of the level of sedation is usually not as straightforward as the definitions of various levels of anesthesia imply. There is considerable overlap among the levels of sedation, and a patient's level of sedation may easily change throughout the course of a procedure. For this reason, proper vigilance and monitoring are essential for the safe administration of sedation and anesthesia.

## THE CONTINUUM OF ANESTHESIA AND SEDATION

The concept of a spectrum of anesthesia is essential to proper understanding of anesthesia and sedation. It is the basis for the American Dental Association's Guidelines for the Use of Sedation and General Anesthesia by Dentists and provides a framework for many state dental board regulations, hospital privileges, and professional liability insurance policies. Although the levels of anesthesia exist on a continuum, the spectrum defines the various levels of sedation and anesthesia as follows.

**Minimal sedation:** a minimally depressed level of consciousness produced by a pharmacologic method that retains the patient's ability to maintain an airway independently and continuously and respond normally to tactile stimulation and verbal commands. Although cognitive function and coordination may be modestly impaired, ventilatory and cardiovascular functions are unaffected. When the intent is minimal sedation for adults, the appropriate initial dosing of a single enteral drug is no more than the maximum recommended dose of a drug that can be prescribed for unmonitored home use.

**Moderate sedation:** a drug-induced depression of consciousness during which patients respond purposefully to verbal commands, either alone or accompanied by light tactile stimulation. No interventions are required to maintain a patent airway, and spontaneous ventilation is adequate. Cardiovascular function is usually maintained. Repeated dosing of an agent before the effects of previous dosing can be fully appreciated may result in a greater alteration of the state of consciousness than the dentist intends.

A patient whose only response is reflex withdrawal from a painful stimulus is not considered to be in a state of minimal or moderate sedation. Drugs used to produce a state of minimal or moderate sedation should carry a margin of safety sufficiently wide to avoid unintended loss of consciousness.

**Deep sedation:** a drug-induced depression of consciousness during which patients cannot be easily aroused

but respond purposefully following repeated or painful stimulation. The ability to maintain ventilatory function independently may be impaired. Patients may require assistance in maintaining a patent airway, and spontaneous ventilation may be inadequate. Cardiovascular function is usually maintained.

*General anesthesia:* a drug-induced loss of consciousness during which patients are not arousable, even by painful stimulation. The ability to maintain ventilatory function independently is often impaired. Patients often require assistance in maintaining a patent airway, and positive pressure ventilation may be required because of depressed spontaneous ventilation or drug-induced depression of neuromuscular function. Cardiovascular function may be impaired.

Because sedation and general anesthesia are on a continuum, practitioners intending to produce minimal or moderate sedation should be able to diagnose and manage the physiologic consequences of patients whose level of sedation becomes deeper than initially intended. The term “rescue” is often used to describe this management and refers to steps taken to return the patient to the initially desired level of sedation.<sup>5</sup>

It is important to note the absence of any mention of routes of administration in these definitions. Prior to the 21st century, it was common for many state dental boards and other institutions to delineate privileges and guidelines for “intravenous sedation” or “oral sedation.” These terms are inherently misleading because the level of sedation is completely independent of the route of administration. For example, one is capable of producing general anesthesia with oral medications, and a state of minimal sedation can easily be obtained through an intravenous route. Similarly, the term “conscious sedation,” a term originally coined to describe the sedation of dental patients, is purposefully avoided in these definitions because consciousness is not clearly defined and is always limited to a particular level of sedation. Although terms like “oral sedation,” “IV sedation,” and “conscious sedation” continue to be used in dentistry today, they are anachronistic, potentially misleading, and should be avoided.<sup>6</sup>

## Fundamental Concepts

The goals of sedation for the pediatric patient are: (1) to guard the patient’s safety and welfare; (2) to minimize physical discomfort and pain; (3) to control anxiety, minimize psychological trauma, and maximize the potential for amnesia; (4) to control behavior or movement so that the procedure can be completed safely; and (5) to return the patient to a physiologic state in which safe discharge, as determined according to recognized criteria, is possible.<sup>7</sup>

Having a systematic routine to follow during sedation is an essential element of safe practice. The sedation routine should be reflected in the documentation an office uses for every step of the process. This includes preoperative evaluation, physical assessment, intraoperative and postoperative notes, and follow-up notes. The simple process of following a well-conceived procedural checklist has been demonstrated to reduce preventable errors in all areas of

health care.<sup>8</sup> The Guidelines for Monitoring and Management of Pediatric Patients Before, During and After Sedation for Diagnostic and Therapeutic Procedures provides an excellent framework for the dentist wishing to establish a sedation protocol for one’s dental office.<sup>9</sup> The procedural guidelines recommended in this chapter are largely based upon this foundational set of guidelines, which was created as a joint effort between the American Academy of Pediatric Dentistry (AAPD) and the American Academy of Pediatrics.

Outcomes assessment is also a critical element of safe sedation practice. The practice of obtaining follow-up data and recording outcomes in a systematic database is not currently as strong in dentistry as it is in medicine, yet it is no less critical. Analysis of data derived from follow-up phone calls and other postoperative assessments helps the dentist identify previously unappreciated treatment sequelae and also gauge the appropriateness of his/her discharge criteria, an area previously underappreciated by many sedation practitioners.<sup>10,11</sup>

## ANATOMIC AND PHYSIOLOGIC DIFFERENCES

The adage “children are not small adults” is well appreciated by clinicians who treat children on a regular basis. Physiologic systems grow and develop at different rates, particularly in children under the age of 8 years. A sound understanding of the anatomic and physiologic differences of children is crucial to the safe practice of pharmacologic management, which is most typically used to manage preschool-aged children.

### Central Nervous System

Although the brain of a full-term newborn accounts for approximately 10% of the total body weight, only 25% of the neuronal cells of an adult are present at birth. Growth in the central nervous system (CNS) of a newborn is extremely rapid, with brain weight doubling by the age of 6 months and tripling by 12 months. By 12 months, brain stem and cortex neuronal cell development is nearly complete; however, myelination lags behind and is not complete until the third year of life.

In the last decade, research performed in nonhuman primates has suggested that several anesthetic and sedative drugs may be toxic to developing neurons, leading to concern about the possible damaging effects of sedation and anesthesia on infants and young children. While the relevance of these studies to humans remains unknown, two large-scale studies are currently under way to determine the clinical relevance of these findings. The Pediatric Anesthesia and Neurodevelopment Assessment study (PANDA) is a multicenter study investigating the neurodevelopment of children in the United States who have undergone general anesthesia prior to 3 years of age. The General Anesthesia Spinal study (GAS) is a worldwide, multinational comparison of children who have undergone either general anesthesia or spinal anesthesia.<sup>12</sup> With an estimated 10 million anesthetic procedures performed on children aged 3 years and younger in the United States each year, the importance of research in this area cannot be overestimated.<sup>13</sup> While these studies are still ongoing at the time of this writing, both the GAS and PANDA studies have found no evidence of any difference in the neurodevelopmental outcome in

**TABLE 18.1** Vital Signs at Various Ages

Age (yr)	Heart Rate (beats/min)	Blood Pressure (mmHg)	Respiratory Rate (breaths/min)
1–3	70–110	90–105/55–70	20–30
3–6	65–110	95–110/60–75	20–25
6–12	60–95	100–120/60–75	14–22
12	55–85	110–135/65–85	12–18

Adapted from Behrman RE et al: *Nelson textbook of pediatrics*, 19th edition, Philadelphia: Elsevier Science; 2011.

children having less than 2 hours of anesthesia in infancy. At this time, it is not possible to make a single definitive conclusion as to whether or not the human evidence supports or refutes the possibility that anesthetic exposure in children causes adverse effects on neurodevelopment.<sup>14</sup>

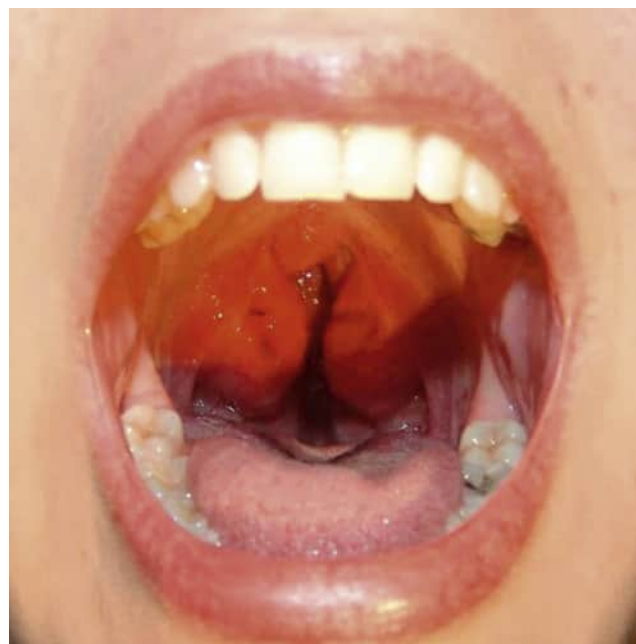### Cardiovascular System

Autonomic control of the heart is a balance between the sympathetic and parasympathetic nervous systems; however, these two systems develop at different rates. The parasympathetic system controls heart rate in utero and is fully intact at birth, whereas the sympathetic control begins shortly after birth and continues to develop in the first several months of life. Wide variations in heart rate can continue for several months and even appear in young children because of variations in autonomic tone.<sup>15</sup>

The heart of a newborn infant is characterized by an immature left ventricle and myocardium. In contrast to fully mature hearts, the infant heart cannot use changes in myocardial contractility to increase cardiac output in times of stress. Heart rate is the major determinant of cardiac output of a young child's heart. Myocardial contractility continues to develop in the toddler, reaching near-adult levels of contractility by the age of 8 years. This rate dependency of the pediatric heart is reflected in normal heart rate values, which drop from a rate of  $120 \pm 20$  in a 6-month-old infant to  $90 \pm 10$  in a 5-year-old and  $70 \pm 17$  in a 12-year-old child.<sup>16</sup> In contrast, blood pressure rises rapidly in the first days to weeks (Table 18.1).

### Respiratory System

As with the heart, the lungs of a newborn are immature. Growth in the number of alveoli occurs mainly after birth and continues to the age of 8 years, whereas the sizes of alveoli continue to increase until the growth of the chest wall is complete. As the number of alveoli increases, blood vessels proliferate in the gas exchange areas, primarily in the first 5 years of life. The development of alveolar smooth muscle begins after birth and continues into late childhood and adolescence. Conditions that disturb the flow of blood in the lungs, particularly congenital heart lesions, may disturb the normal growth and development of the pulmonary vasculature.<sup>17</sup> A higher metabolic rate is present in infants and children, resulting in a rate of alveolar ventilation that is two to three times greater than that in adults. Functional reserve capacity (FRC) is also significantly smaller in children than in adults. FRC acts as a buffer to maintain consistent alveolar ventilation during inspiration and expiration. In the adult, the ratio of alveolar ventilation to FRC is 1.5:1, whereas in the infant, it is 5:1. Placing a patient in the supine position, as is commonly done during dental



**Fig. 18.3** Enlarged tonsils, particularly when inflamed, increase the risk of airway complications during sedation.

treatment, decreases FRC by 20% to 30%. One can therefore appreciate why hypoxemia can develop so rapidly in the pediatric dental patient when normal respiratory function is diminished.<sup>18,19</sup>

The characteristic anatomic differences of the pediatric airway must also be appreciated. In general, children have proportionately larger heads and shorter necks. The larynx is more cephalad and anterior in the child (at the level of C3-4) than in the adult (at the level of C4-5). The relatively narrow nasal passages, large tongues, and large tonsils and adenoids contribute to the tendency of the upper airway to be blocked by secretions or edema. In addition, the relatively vascular and fragile nature of tonsils adds an additional risk factor in patients with large tonsils undergoing procedures in the airway, particularly when the tonsils are inflamed. Generally, patients with the tonsillar tissue that occupies more than 50% of the pharyngeal space are not good candidates for pharmacologic management (Fig. 18.3).<sup>19</sup>

### Body Size and Composition

Obesity is an important, but often underappreciated, risk factor for pharmacologic management. According to estimates from the Centers for Disease Control and Prevention, approximately one out of three children in the United States is obese or overweight by the time he/she reaches his/her fifth birthday.<sup>20</sup> The risk is increased in children belonging to low-income families.<sup>21</sup> Obesity affects the delivery of all levels of sedation and anesthesia in many ways. Increased adiposity may affect the ability of a sedated child to maintain a patent airway and complicate airway management. Obstructive sleep apnea, which occurs in up to 60% of obese children, may complicate both procedural sedation and the recovery of patients after sedation.<sup>22</sup> Venous access may be more difficult, complicating resuscitation in the event of an emergency. Obesity may affect the pharmacokinetic properties of certain sedative drugs, which may distribute



preferentially to fatty tissues. Dose calculations for certain sedative drugs may need to be adjusted to avoid inadvertent oversedation. Normal vital signs, such as blood pressure, may be affected.<sup>23</sup> Should rescue or resuscitation be required, obesity may complicate the management of older children. Members of the dental team must be confident that they are capable of moving and handling an obese child should unconsciousness occur.

## ROUTES OF DRUG ADMINISTRATION

Pharmacokinetics is the study of the absorption, distribution, metabolism, and excretion of a drug and its metabolites. This information helps determine how much drug is made available to the actual site where the drug binds and takes effect. The route of administration describes where and how the body initially absorbs the drug. A given dose of a drug, administered via different routes, can have very different effects. For example, the analgesia and side effects following intravenous administration of meperidine differ dramatically from those seen following oral administration.<sup>24</sup> This is primarily due to differences in the pharmacokinetic properties of these two forms of the drug.

### Inhalational Route

The inhalational route is a highly effective route of administration, allowing nonirritating gases and volatile drugs to be inhaled and absorbed directly through the pulmonary epithelium and mucous membranes of the respiratory tract into the circulation. The almost instantaneous absorption of agents delivered through this route is due to the large surface area of the lung. Equilibrium is quickly established among the partial pressure of the drug in the alveolar gas space, serum, and target tissues in the brain. As a result, inhaled anesthetic gases are easily titrated by adjustment of the amount of inhaled gas, provided the rate and depth of ventilation are adequately controlled.

### Enteral Route

Enteral sedation is achieved by drugs that are swallowed and absorbed through the digestive or enteric system. Although this form of drug delivery is simple and relatively inexpensive, the effects are not produced as reliably as those of drugs delivered through parenteral routes, that is, routes that do not involve the digestive tract. Disadvantages of the oral route include limited absorption of some drugs due to physiochemical factors, destruction by digestive enzymes or gastric pH, and metabolism from enzymes in the liver (termed first-pass metabolism).<sup>25</sup> Dosing discrepancies may also occur during swallowing by an uncooperative patient. Once swallowed, medication may be broken down by gastric enzymes in the stomach; however, no absorption occurs until the drug enters the small intestine. Differences in drug formulation may result in some drugs being broken down more completely in the stomach than others. Because high sympathetic nervous system tone inhibits gastric emptying time, anxious patients may demonstrate a longer time to the onset of sedation than predicted. Once absorbed in the small intestine, drugs pass through the hepatic portal system where they are metabolized to various degrees by hepatic enzymes. The amount and activity of hepatic enzymes vary significantly among patients, with as much

as an eight-fold difference noted among populations of normal individuals. This effect, known as the first-pass effect, may account for large discrepancies between the amount of drug present in the initial drug formulation and the amount of drug that remains active after the first-pass metabolism (Fig. 18.4A). The onset, peak, and duration of drug effects may still be affected by numerous factors once they bind to their effect site in the brain; however, as a general rule, most clinically useful agents will display an onset approximately 30 minutes after administration, with peak effect noted by 60 minutes. The duration of effect is usually proportional to the elimination half-life of the drug.

Although the enteral route of administration is better accepted by pediatric patients over injections, not all patients will readily accept orally administered drugs. The taste may be quite objectionable, especially to very young children. This can usually be overcome when the drug is mixed with a palatable liquid (e.g., flavoring drops). A syringe is sometimes used to deliver oral medication to uncooperative children, but caution must be exercised with this technique to avoid inadvertent aspiration of the drug.<sup>26</sup> Enteral drugs should only be administered to patients while under supervision by trained personnel. The practice of having parents administer oral medications to children prior to arrival at the office should be avoided.<sup>27</sup>

### Intramuscular Route

Intramuscular administration relies upon the high vascularity of the muscle tissue to achieve a moderately rapid onset of action, usually within 5 to 10 minutes. When properly administered, intramuscular injection provides a more rapid onset and offset compared with enteral techniques (Fig. 18.4B). As with enteral techniques, practitioners are limited to a single dose of medication; however, the onset of sedation is more predictable than is the onset of oral techniques. For pediatric dental sedation, injections are typically performed in the vastus lateralis or deltoid muscle. Aqueous solutions are well absorbed following intramuscular injection. Care should be taken to prepare the solution in a volume that is appropriate for the size of the injected muscle because excessive volume may cause pain and/or tissue damage and hinder absorption. The most common error in the delivery of intramuscular injections is failure of the injected solution to be deposited deep in the muscle bed where maximum absorption can take effect. Misplaced or superficial injections result in deposition of the solution in the fascia or subcutaneous tissue, resulting in slower, less predictable onset.

As with local anesthetic techniques, knowledge of the anatomy of the injection site is mandatory for safe and effective delivery. The vastus lateralis muscle on the ventral thigh is often preferred due to its larger size and relatively easy access in small children. The upper outer quadrant of the gluteus maximus muscle and the middle of the deltoid muscle are other acceptable sites as long as muscle development is adequate. Once the medication has been injected, if the desired effect is not achieved within 25 to 30 minutes, termination should be considered. As with oral agents, additional intramuscular injections are not advisable, and may create unintended sequelae for a prolonged period.

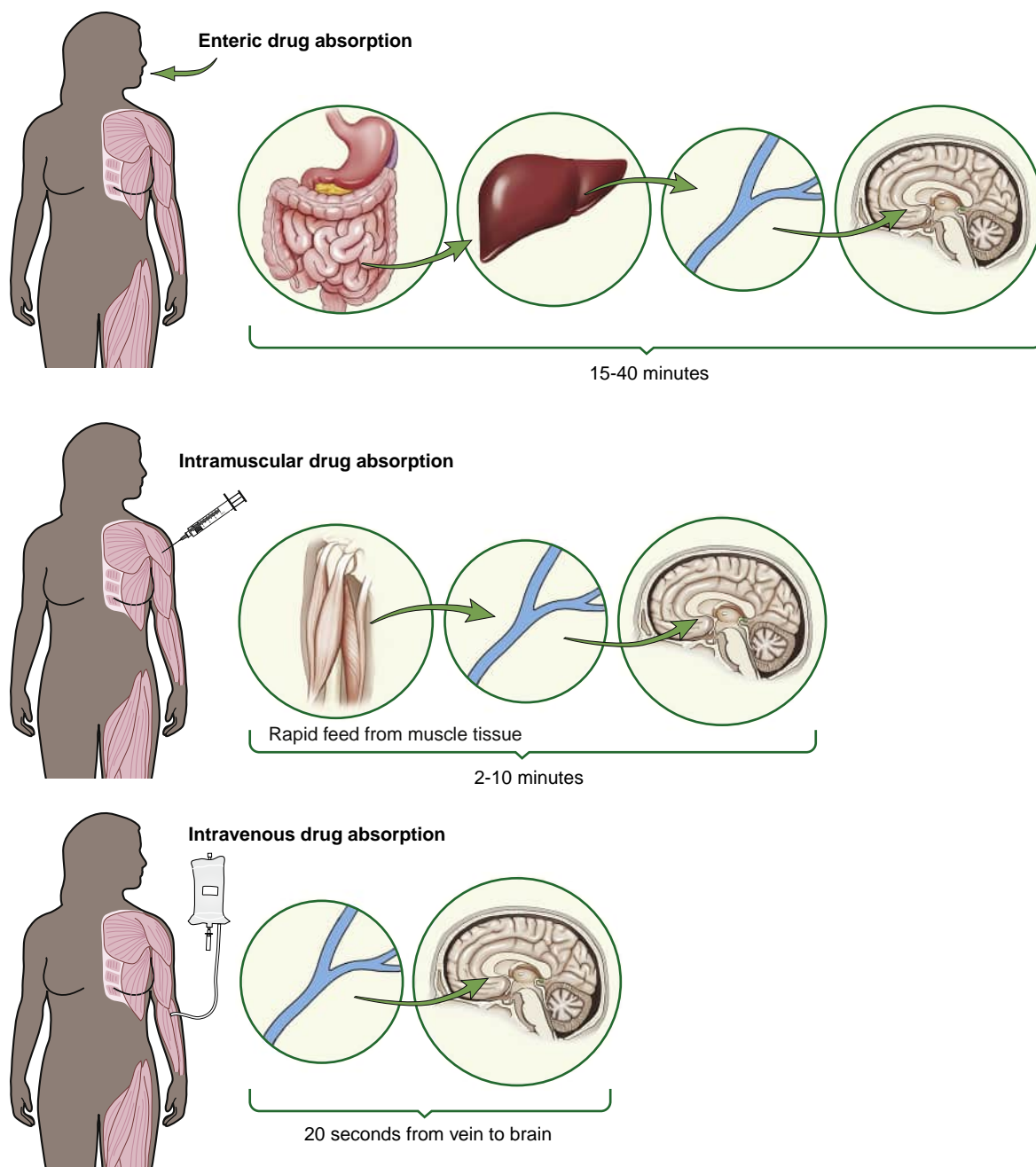


Fig. 18.4 Comparison of drug absorption and distribution to the brain through the enteral, intramuscular, and intravenous routes.

### Submucosal and Subcutaneous Routes

Submucosal sedation involves the deposition of the drug beneath the oral mucosa. Its use is almost exclusively the province of dentistry. It is analogous to subcutaneous injection, with the solution being deposited below the intraoral mucosa. From a pharmacologic perspective, there is little advantage of the submucosal route over the subcutaneous route. From a practical perspective, it is often more difficult to administer a well-controlled intraoral injection than administer an intramuscular injection. Details of this technique may be found in earlier editions of this text.

### Intravenous Route

The intravenous route of administration shares most of the desirable pharmacokinetic and pharmacodynamic features of inhalational anesthetics. Drugs delivered through the intravenous route circulate directly to the brain, with onset occurring within 20 to 40 seconds. The level of sedation or anesthesia is readily titrated and can be sustained for extended periods of time. Recovery from intravenously administered drugs is often more rapid than that from drugs delivered through the oral or intramuscular route. Multiple doses can be administered through an intravenous infusion, with a high degree of versatility and control.

The intravenous route also requires the most training and experience to perform because drug-related complications often arise very rapidly, with increased potential for severe consequences.

Despite the clear advantages of the intravenous route of administration, it is often difficult to achieve sustained moderate sedation through the intravenous route in the pediatric patient. The reasons for this have less to do with the route of administration and more to do with how easy it is to achieve a state of general anesthesia when attempting to provide moderate sedation to children during dental procedures. Advanced training for intravenous and other parenteral administration techniques is required.<sup>3</sup> Dentists with limited parenteral moderate sedation permits will often find this modality best suited to older children and adolescents for a combination of behavioral, pharmacologic, and practical reasons.

### Rectal Route

Rectal administration of sedative drugs with suppositories has a limited history in pediatric dentistry. Drugs administered through this route are absorbed through two different vascular systems, one of which delivers agents to the liver and the second bypasses the liver. Consequently, wide variations of bioavailability are seen after rectal administration. References report that 50% of a drug delivered by the rectal route undergoes first-pass metabolism in the liver, but this is a broad approximation, and absorption is often irregular and incomplete. For this reason, and because of the tendency toward mucosal irritation from drugs delivered via this route, rectal administration is not recommended for pediatric sedation.<sup>28</sup>

## DRUGS AND AGENTS USED FOR SEDATION

### Nitrous Oxide

About 85% of pediatric dentists use inhalation of nitrous oxide and oxygen to sedate patients, making it the most frequently used pediatric sedation technique today. Nitrous oxide is a slightly sweet-smelling, colorless, inert gas. It is compressed in cylinders as a liquid that vaporizes on release. The gas is nonflammable but will support combustion.

The pharmacokinetic properties of nitrous oxide are well suited to producing moderate sedation. The small molecular size and low solubility allow for rapid alveolar uptake and distribution through the arterial circulation to the brain. Within 3 to 5 minutes of the patient inhaling a fixed concentration of nitrous oxide, equilibrium is reached among the concentrations in the alveolar gas, blood, and target sites in the brain. There is good correlation between the mixture set with the flowmeter and the observed effect. The nitrous oxide machine feeds a steady, consistent mixture, making it relatively easy for the dentist to achieve a steady state of moderate sedation in a patient whose rate and depth of breathing and level of procedural stimulation remain reasonably consistent. The lack of significant biotransformation in the liver or other sites allows for an equally rapid recovery. Excretion occurs almost entirely through the lungs; only very small amounts may be excreted in body fluids and intestinal gas.

The mechanism through which nitrous oxide produces its clinical effects remains undefined. Current evidence

**TABLE 18.2** Minimum Alveolar Concentration Values for Common Inhaled Anesthetics

Minimum Alveolar Concentration (MAC)	%
Nitrous oxide	104
Desflurane	6.0
Sevoflurane	2.0
Isoflurane	1.2
Halothane	0.75

Adapted from Nickalls RW, Mapleson WW. Age-related iso-MAC charts for isoflurane, sevoflurane and desoflurane in man, *Br J Anaesth.* 2003;91(2):170–174.

suggests an interaction with the endogenous opioid system because its effects are abolished by the administration of the opioid antagonist, naloxone. The strongest evidence suggests that nitrous oxide stimulates the release of enkephalins, which trigger the descending noradrenergic pathways. The most common estimate of analgesic efficacy suggests that 30% nitrous oxide delivered by full mask is equivalent to 10–15 mg of morphine. This interaction with the endogenous opioid system may account, in part, for the abuse potential that has been attributed to nitrous oxide.

Nitrous oxide is the weakest of all inhalational agents, with a minimum alveolar concentration (MAC) of 105. The MAC of an inhalational agent is a measure of its anesthetic potency; it is defined as the concentration required to produce immobility in 50% of patients upon surgical skin incision. Most commonly used inhalational general anesthetics today have MAC values between 1% and 6% (Table 18.2). The exceedingly high MAC value of nitrous oxide precludes its use as the sole means of producing general anesthesia; however, it possesses very useful clinical effects when delivered at subanesthetic concentrations far below MAC value.

A nitrous oxide concentration between 30% and 50% (roughly 0.3–0.5 MAC) will produce a relaxed, somnolent, and sometimes euphoric patient who may appear dissociated and easily susceptible to suggestion. Amnesia may occur in some patients, but there is little alteration of learning or memory. The concentration of nitrous oxide should not routinely exceed 50% in clinical dental practice because concentrations in this range increase the likelihood of nausea, vomiting, and disorientation. At concentrations greater than 60%, patients may experience ataxia, giddiness, dysphoria, and increased sleepiness. Like all inhaled agents, nitrous oxide can be titrated, allowing the doctor to adjust the level of sedation to match the level of surgical stimulation.

Nitrous oxide reduces the ventilatory response to hypoxemia but has minimal effect on the hypercapnic respiratory drive when delivered in concentrations less than 50%. However, it should be avoided in patients who rely significantly on hypoxia-driven ventilation. When combined with other agents that depress respiration, nitrous oxide may diminish the body's normal response to low oxygen tension. These effects are usually negligible, however, because of the high concentration of oxygen administered in combination with nitrous oxide. Nitrous oxide slightly increases the respiratory minute volume. As the patient becomes more relaxed from the effects of nitrous oxide, the respiratory rate may decrease slightly. The gas is nonirritating to the respiratory tract and can be given to patients with asthma without fear



of bronchospasm. Caution must be exercised when nitrous oxide is used with CNS depressants because it may enhance those actions.

Nitrous oxide–oxygen has an excellent safety record with few adverse effects. Nausea and vomiting are the most common adverse effects, occurring in 1% to 10% of patients. The incidence of adverse effects increases with concentrations in excess of 50%, rapid fluctuations of concentrations, and rapid induction and reversal. The likelihood of nausea and vomiting also increases with the length of the procedures, beginning at durations of approximately 20 minutes. Fasting is not required for nitrous oxide–oxygen sedation.

Nitrous oxide will become entrapped in gas-filled spaces such as the middle ear, sinuses, and gastrointestinal (GI) tract. Middle ear pressure will increase significantly, and although it is of little significance in a patient with normal patency of Eustachian tubes, it can induce pain in patients with acute otitis media and should be avoided. Other contraindications include severe behavioral problems and emotional illness, uncooperativeness, claustrophobia, maxillofacial deformities that prevent nasal hood placement, nasal obstruction (e.g., upper respiratory infection, nasal polyps, deviated septum), chronic obstructive pulmonary disease, pregnancy, and situations in which high oxygenation is inadvisable (e.g., bleomycin therapy).

When medical-quality nitrous oxide and oxygen are used properly, there is little to no risk of toxicity for the dental patient. The greatest concern regarding toxicity centers on the exposure of dental personnel to high ambient air levels of the gas when it is used for patient sedation. Chronic exposure to nitrous oxide, including recreational abuse, can produce neurotoxicity, sexual and reproductive problems, hepatotoxicity, and renal dysfunction. The rate of spontaneous abortion is known to be higher in operating room personnel and in the spouses of operating room personnel. In addition, individuals exposed over the long term may experience a decrease in fertility. An increase in hepatic disease was found among dentists and dental personnel exposed to high levels of nitrous oxide for periods longer than 3 hours per week.<sup>29</sup> In light of these findings, leakage from open nitrous oxide delivery systems, such as those used in the dental office, should be reduced as much as possible. This can be accomplished by limiting the amount of mouth breathing by the patient and the use of an efficient scavenging system. The office location as well as office personnel should be periodically monitored for exposure to ambient nitrous oxide. Numerous units are available that use infrared spectrophotometry to measure levels of unscavenged nitrous oxide in the dental operator environment. These machines can detect levels as low as 1 ppm and are particularly useful for uncovering leaks around tanks and flowmeters. A less costly and more practical approach is the use of dosimetry badges that are worn by office personnel when using nitrous oxide. These units are generally worn for an 8-hour period and report exposure as time-weighted averages. Methods to limit exposure to ambient nitrous oxide are listed in [Box 18.1](#).

## ANTIHISTAMINES

### Hydroxyzine (Atarax, Vistaril)

Hydroxyzine is an antihistamine with weak sedative, anticholinergic, and antiemetic properties. It produces sedation

### Box 18.1 Recommendations for use of nitrous oxide for pediatric dental patients

- Use scavenging systems that remove nitrous oxide (N<sub>2</sub>O) during patient's exhalation.
- Ensure that exhaust systems adequately vent scavenged air and gases to the outside of the building and away from fresh air intake vents.
- Where possible, use outdoor air for dental operator ventilation.
- Implement careful, regular inspection and maintenance of the N<sub>2</sub>O–oxygen delivery equipment.
- Carefully consider patient selection criteria (i.e., indications and contraindications) prior to administering N<sub>2</sub>O.
- Select a properly fitted mask size for each patient.
- During administration, visually monitor the patient and titrate the flow/percentage to the minimal effective dose of N<sub>2</sub>O.
- Encourage patients to minimize talking and mouth breathing during N<sub>2</sub>O administration.
- Use rubber dam and high-volume dental evacuator when possible during N<sub>2</sub>O administration.
- Administer 100% oxygen to the patient for at least 5 minutes after terminating N<sub>2</sub>O use to replace the N<sub>2</sub>O in the gas delivery system.

Data from the American Academy of Pediatric Dentistry Policy on Minimizing Occupational Health Hazards Associated with Nitrous Oxide Reference Manual. 2018;40(6):104–105. [www.aapd.org/media/Policies\\_Guidelines/G\\_Nitrous.pdf](http://www.aapd.org/media/Policies_Guidelines/G_Nitrous.pdf)

by inhibiting the hypothalamic H-1 histamine receptors involved in governing the sleep-wake cycle in humans.<sup>30</sup> The antimuscarinic action of hydroxyzine inhibits the flow of saliva, resulting in various degrees of xerostomia. Although clinical anxiolysis is sometimes reported with hydroxyzine, this effect is most likely related to the production of drowsiness and is not linked to specific actions on the neural substrates involved in anxiety. In normal doses, it has no cardiovascular or respiratory depressant effects. Absorption through the GI tract is relatively rapid, with the onset of action occurring in 15–30 minutes. Peak levels occur at 2 hours. Recovery is slow by modern standards, reflected by the mean half-life of 3 hours. It is available in two forms, hydroxyzine hydrochloride (Atarax) and hydroxyzine pamoate (Vistaril).

Preparation: tablets, elixir

Dosage: 0.5 to 1.0 mg/kg

Side effects: prolonged drowsiness, ataxia, dry mouth. In children, paradoxical reactions may occur at sedative doses.

### Promethazine (Phenergan)

Although promethazine is classified here as an antihistamine, it is primarily classified as a phenothiazine, a group of drugs characterized by a wide range of clinical effects. Phenothiazines bind to a variety of receptors in the CNS, including histaminic, alpha adrenergic, muscarinic, serotonergic, and dopaminergic receptors.<sup>31</sup> As a class, phenothiazines are most commonly used as antipsychotics, antiemetics, and sedatives. Promethazine lacks antipsychotic effects, but has strong anticholinergic, antiemetic, and antihistaminic effects. It has been used in clinical practice in the

United States since 1946, most commonly as an antiemetic and sedative agent. It continues to be used as a sedative in pediatric dentistry; however, its use has been supplanted by newer sedative agents with better pharmacokinetic properties.

Like hydroxyzine, promethazine is readily absorbed by the GI tract, with the onset of action noted at 20 minutes and peak effect occurring within 2–3 hours.<sup>32</sup> It is highly bound to plasma proteins and has a serum half-life of 7–14 hours.<sup>33</sup> The long half-life may be seen as beneficial in terms of its antiemetic effects but may also contribute to prolonged drowsiness, particularly when used in combination with other sedative drugs. Promethazine is rapidly degraded by first-pass metabolism, resulting in limited bioavailability after oral or rectal administration. Promethazine has been associated with an enhanced risk of sudden infant death syndrome (SIDS) and worsening of sleep apnea. Although the mechanisms remain unclear, relaxation of the oral pharyngeal musculature may be a contributing factor in patients with compromised airways or a history of SIDS.<sup>34</sup>

Preparation: tablets, rectal suppository

Dosage: 0.5 to 1 mg/kg to a maximum single dose of 50 mg

Side effects: blurred vision, prolonged drowsiness, ataxia

### Diphenhydramine (Benadryl)

Along with hydroxyzine, diphenhydramine is the most commonly used antihistamine for procedural sedation and antiemetic therapy in children. When compared with other antihistamines, diphenhydramine is noted for its pronounced tendency to produce sedation and its strong antimuscarinic effects. It is approved by the Food and Drug Administration (FDA) for over-the-counter use as a sleep aid and therapeutic for motion sickness. It is well absorbed through the GI tract but undergoes significant first-pass metabolism in the liver, resulting in a bioavailability of 40%–60%. The peak clinical effect occurs at approximately 1 hour. The half-life of diphenhydramine ranges from 2 to 8 hours. It is metabolized by the liver and is completely excreted in 24 hours.

Preparation: tablets, elixir, capsules, injectable

Dosage: oral, intramuscular, or intravenous—1.0 to 1.5 mg/kg; maximum single dose is 50 mg

## BENZODIAZEPINE AGONISTS AND ANTAGONISTS

Benzodiazepines are the most commonly used drugs for procedural sedation in medicine and dentistry today. The popularity of this class of drugs is due to its wide therapeutic index, shallow dose-response curve, and its specific effects on the GABAergic neurons of the CNS. GABA is the major inhibitory neurotransmitter in the brain, and GABA receptors are found in high concentrations in the cerebral cortex, midbrain, hippocampus, and other sites involved in the neural processing of awareness, anxiety, and learning.<sup>35</sup>

Benzodiazepines have five major clinical effects: anxiolysis, hypnosis, amnesia, muscle relaxation, and anti-convulsant activity.<sup>36</sup> Each of the clinically available benzodiazepine drugs is characterized by the relative degree to which it produces each of these five major effects. Despite having marked effects on awareness and memory,

benzodiazepines have negligible effects on cardiovascular or respiratory function when used as single agents. Members of this class of drugs also lack analgesic activity, although they are believed to play a role in the prevention of hyperalgesia from surgical trauma.

### Diazepam (Valium)

Introduced in 1963, diazepam is the oldest benzodiazepine in use for clinical sedation and is often considered the standard with which all other benzodiazepines are compared. It is rapidly absorbed from the GI tract, reaching peak serum levels in as little as 15–30 minutes in children. Due to its high lipid solubility, diazepam redistributes rapidly to other tissues. It is metabolized into two principal metabolites—desmethyldiazepam and oxazepam. Desmethyldiazepam is only slightly less potent than its parent compound diazepam and is believed to be the chief cause of secondary drowsiness, or re-sedation, which may happen hours after the initial dose. Enterohepatic recirculation also contributes to the long elimination half-life of this drug, which ranges from 21 to 37 hours.<sup>37</sup> When compared with newer, more potent benzodiazepines, diazepam is distinguished by its ability to produce rapid and sustained anxiolysis. The prolonged recovery period poses a potential for re-sedation and airway obstruction in the postprocedural phases of treatment, especially in obese children and in cases where opioid agents had been coadministered during the procedure. Side effects most commonly include ataxia and prolonged sedation.

Dosage: oral—0.2 to 0.5 mg/kg to a maximum single dose of 10 mg; intravenous—0.25 mg/kg

Supplied: tablets—2, 5, and 10 mg; suspension—5 mg/mL

### Midazolam (Versed)

Midazolam was introduced into US medical and dental practice in 1985 as the first water-soluble benzodiazepine. This property accounts for its stability in aqueous solutions, making it nonirritating to tissues following intravenous or intramuscular administration. When administered orally, it undergoes rapid absorption, but 50%–65% of the dose is lost to first-pass metabolism. The onset of sedation occurs within 20 to 30 minutes, allowing an average of 30 minutes of working time for the dentist. After binding to receptor sites in the brain, the drug is rapidly redistributed to other tissues or metabolized. Although biotransformation of midazolam in the liver produces one active metabolite, it is of negligible clinical importance. The elimination half time of midazolam is 1–4 hours, which is significantly shorter than that of diazepam. Cognitive testing in adults shows return of normal mental function within 4 hours.<sup>38</sup>

Midazolam is much more potent than diazepam, as predicted by its greater affinity to bind benzodiazepine receptors in the brain.<sup>39</sup> The clinical potency of midazolam is estimated to be two to five times that of diazepam. Part of the reason for this discrepancy is the difference in dose-response relationships of the two drugs. Diazepam is characterized by a more gradual increase in effects with dose, whereas midazolam shows greater potency with increasing dose.<sup>40</sup> This difference in potency was not fully appreciated in the late 1980s when midazolam was first introduced and commercially prepared in the same concentrations as

diazepam. Early reports of hypoxia associated with midazolam were almost entirely due to lack of appreciation for the difference in potency between the two drugs.<sup>41</sup> This difference may also explain the differences in cognitive effects seen when midazolam and diazepam are compared. Midazolam produces more consistent anterograde amnesia during moderate sedation than diazepam, whereas diazepam is more likely to produce anxiolysis with less amnesia. Both effects are dose dependent, and precise ranges for enteral sedation techniques are difficult to define because nearly all clinical examinations of these effects were performed with intravenous or intramuscular administration.<sup>42,43</sup> It is worth noting that amnesia may not be desirable for all types of sedation in pediatric practice. Older children and adolescents with a desire to cooperate may tolerate procedures better with anxiolysis compared with deeper levels of sedation and accompanying amnesia.

Midazolam is available as a premixed suspension; however, independent studies have reported superior bioavailability, shorter onset, and better sedation scores with a mixture of a standard parenteral midazolam preparation with Syrpalta, a commercial syrup.<sup>44,54</sup>

Preparation: syrup, parenteral injection solution

Dosage: oral—0.25 to 1.0 mg/kg to a maximum single dose of 20 mg; intramuscular—0.1 to 0.15 mg/kg to a maximum dose of 10 mg

### Flumazenil (Romazicon)

Flumazenil is a direct, specific reversal agent used in clinical practice to treat benzodiazepine overdose. Pharmacologically, it acts as a competitive antagonist at the benzodiazepine receptor sites in the CNS. In selected situations, the drug is capable of rescuing patients from the effects of benzodiazepine overdose. Several state boards, institutions, and organizations include it as a required drug when sedation with benzodiazepines is performed. Unfortunately, the use of this drug has been misinterpreted, leading to practices that undermine its intended purpose and effective use in an emergency.

Flumazenil is approved by FDA for intravenous administration. Effective and safe reversal in adults is achieved by titration, by the injection of 0.2-mg doses every 3–5 minutes up to a total dosage of 1 mg. When an adequate dose is achieved, reversal of effects occurs within 2 minutes; however, the duration of reversal is short, lasting only 20–45 minutes. The manufacturer states that “conscious sedation is reversed in most patients with cumulative doses between 0.6 mg and 1.0 mg. For children, an initial intravenous dose of 0.01 mg/kg (maximum dose: 0.2 mg) given over 15 seconds is recommended, with repeat 0.01 mg/kg (maximum dose: 0.2 mg) after 45 seconds, and then every minute to a maximum total cumulative dose of 0.05 mg/kg or 1 mg, whichever is lower; usual total dose: 0.08 to 1 mg (mean: 0.65 mg).”

Alternate routes of administration via intraoral submucosal injection in the sublingual area have been described; however, the onset of action is slower, and accurate titration is not possible outside of the intravenous route.<sup>46</sup> Practitioners using this route must estimate the appropriate dose or use the recommended starting dose for a single injection. Furthermore, there is no support for the practice

of routinely administering flumazenil at the end of sedation in an attempt to accelerate recovery. In a study of adults undergoing moderate sedation with benzodiazepines, Hosaka et al.<sup>47</sup> found that a single dose of 0.2-mg flumazenil was inadequate to reverse the effects of a typical enteral sedation with triazolam. They concluded that reversal for the purpose of discharging the patient early is neither appropriate nor safe.

A more insidious issue with flumazenil is a misunderstanding of its role in sedation emergencies. Respiratory events account for the greatest share of sedation-related morbidity and mortality. Sedation with a benzodiazepine is a common practice in children, and one may be led to believe that the administration of flumazenil is an appropriate first step for the management of hypoventilation or apnea during benzodiazepine sedation. Proper and effective airway management is always the first step undertaken when respiratory distress is encountered. Delaying airway management for the purpose of administering flumazenil may cause delays resulting in hypoxia, serious morbidity, or death.

Dosage: intravenous—as described

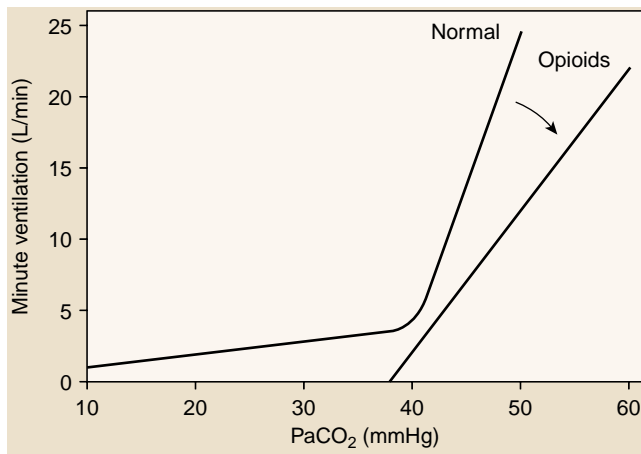
Supplied: 5- and 10-mL multiple-use vials containing 0.1 mg/mL in boxes of 10

## OPIOID AGONISTS AND ANTAGONISTS

Opioids are drugs that bind to receptors in the endogenous opioid system, a collection of neurons with diverse connections throughout the CNS and peripheral nervous system. Although the endogenous opioid system is most commonly appreciated for its ability to diminish or block the sensation of painful sensory stimulation, it is also involved in numerous homeostatic functions, such as breathing, digestion, movement control, airway reflexes, and modulation of the stress response. Opioids are most useful during moderate sedation for their ability to suppress the cough reflex, provide analgesia, and produce a sensation of well-being; however, direct scientific evidence for their utilization in pediatric dental sedation is extremely limited. They are also closely linked with several important side effects, including respiratory depression, nausea and vomiting, delayed gastric emptying, constipation and urinary retention, and itching.

Opioids differ from the benzodiazepines in several critical ways that are relevant to the clinician seeking to provide moderate sedation. They produce analgesia by raising the threshold for perceiving painful stimulation, whereas benzodiazepines have no significant effect on pain perception. At sedative doses, opioids produce analgesia while not affecting awareness and memory, whereas benzodiazepines produce profound, dose-dependent amnesia. All opioid agonists produce dose-dependent respiratory depression through direct action on the ventilatory control center in the medulla and blunt the response to hypercarbia and hypoxia. The effects of opioids on the response to hypercarbia are particularly relevant to clinical sedation because they raise the apneic threshold, i.e., the point at which patients stop breathing (Fig. 18.5). Under these conditions, the accumulation of carbon dioxide secondary to airway obstruction may not increase the rate of ventilation, leading to acute hypoxia.





**Fig. 18.5** Effects of opioids on the ventilatory response to hypercapnia. *PaCO<sub>2</sub>*, Partial pressure of carbon dioxide.

Because the rate and depth of ventilation may already be reduced during sedation, changes in breathing may be subtle. Continuous and careful observation of the rate and depth of breathing should accompany the use of any opioid.

Opioids also induce nausea and vomiting through direct action on the chemoreceptor trigger zone in the medulla. In comparison, benzodiazepines do not depress ventilation at sedative doses and are not associated with the production of nausea and vomiting. Tolerance, dependence, and abuse potential are associated with repeated dosing of both agents. While these phenomena are not generally induced by a single exposure of the patient to these drugs during a sedative procedure, practitioners may find patients under therapy with these drugs to be refractory to moderate sedation. Although most opioids are readily absorbed through the GI tract, bioavailability is limited by significant first-pass metabolism. In general, the parenteral administration of opioids is more effective and reliable than oral administration.

For the purposes of this chapter, discussion will be limited to fentanyl, meperidine, and naloxone.

### Fentanyl (Sublimaze)

Fentanyl is a potent synthetic opiate agonist. A dose of 0.1 mg is approximately equivalent to 10 mg of morphine or 75 mg of meperidine. Fentanyl acts rapidly, and after intramuscular injection the onset occurs in 7–15 minutes; duration of effects is 1–2 hours. The drug is metabolized by the liver and is excreted in the urine. Fentanyl produces little histamine release and has a much lower emetic effect than morphine or meperidine. Fentanyl can be administered by the intramuscular, intravenous, or submucosal route.

Supplied: 0.05 mg/mL in 2- and 5-mL ampules  
 Dosage: 0.002 to 0.004 mg/kg

### Meperidine (Demerol)

Meperidine is a synthetic opiate agonist closely related to fentanyl in chemical structure. It is water-soluble but is incompatible with many other drugs in solution. Meperidine may be administered through either enteral or parenteral administration; however, oral administration is only about half as effective as intramuscular injection. It is

rapidly and well absorbed from the GI tract, reaching peak effect in about 60 minutes. Approximately 90% of an oral dose undergoes biotransformation via first-pass metabolism to normeperidine and meperidinic acid. Normeperidine is an active metabolite with approximately 50% of the analgesic activity as the parent compound, and manifests an elimination half-life of 15–40 hours. Normeperidine also possesses CNS stimulation and can become proconvulsant with prolonged accumulation of the metabolite. Its use is contraindicated in patients with a history of hepatic disease, renal disease or dysfunction, or seizure disorders.

Supplied: oral tablets—50 and 100 mg; oral syrup—50 mg/5 mL; parenteral solution—25, 50, 75, and 100 mg/mL

Dosage: oral, subcutaneous, or intramuscular—1.0 to 2.2 mg/kg, not to exceed 100 mg when given alone or 50 mg when in combination with other CNS depressants

### Naloxone (Narcan)

A semisynthetic opioid receptor antagonist used to reverse the effects of opioid drug overdose, naloxone is a pure antagonist, with no intrinsic agonist activity. Following subcutaneous or intramuscular injection, reversal begins within 2 to 5 minutes compared with 30 seconds to 2 minutes following intravenous administration. Reversal persists for approximately 45 minutes via either route. Excessive or too rapid reversal may result in adverse reactions including nausea, vomiting, sweating, hypotension, hypertension, ventricular tachycardia and fibrillation, and pulmonary edema. Therefore, naloxone should be titrated judiciously, with the intravenous route used whenever possible. As with benzodiazepine reversal discussed earlier, the administration of naloxone should never take precedence over basic airway management and resuscitative measures.

Dosage: intravenous, subcutaneous, intramuscular—initial dose: 0.01 mg/kg; subsequent doses: 0.1 mg/kg (2 mg maximum) every 2 to 3 minutes  
 Supplied: parenteral solution—0.02, 0.4, 1.0 mg/kg

### OTHER SEDATIVE-HYPNOTICS

Prior to the modern era, many drugs with nonspecific mechanisms of action were introduced into clinical medical and dental practice for producing sleep or sedation. These include paraldehyde, chloral hydrate, ethchlorvynol, meprobamate, and others. The effects of all of these drugs resemble those of barbiturate drugs, in that they produce profound hypnosis with little or no effect upon pain perception. Like barbiturates, they are characterized by a limited therapeutic window and possess a significant risk of respiratory depression and other toxic effects when doses exceed clinically accepted ranges. The last of these agents to be used routinely in clinical practice was chloral hydrate, which was used by many pediatric dentists until it was discontinued in 2012. The discussion of these agents in this chapter will be limited to chloral hydrate.

### Chloral Hydrate

Chloral hydrate is an aldehyde compound that is metabolized by alcohol dehydrogenase in the liver to its active metabolite, trichloroethanol. In vitro studies have suggested

that trichloroethanol acts upon GABA receptors in a manner similar to barbiturates and benzodiazepines.<sup>48</sup> It is a chemical irritant to the skin and mucous membranes and is associated with a high rate of nausea and vomiting, particularly when administered on an empty stomach. After oral administration, the drug was characterized by a slow onset time (30–60 minutes) with action duration of 4–8 hours and an elimination half-life of 8–11 hours.

Children given chloral hydrate would often enter a period of disinhibition resulting in excitement and irritability before reaching a level of clinically useful sedation. Large doses sensitize the myocardium to the effects of epinephrine, resulting in arrhythmias.<sup>49,50</sup> The lethal dose of chloral hydrate is stated to be 10 g in adults, yet ingestion of 4 g has been associated with a fatal outcome.<sup>51</sup>

Chloral hydrate is no longer available commercially in the United States through conventional pharmaceutical sources. It is included here because of its history in pediatric dentistry and references in the pediatric dentistry literature.

## Nitrous Oxide Administration

### OBJECTIVES

The objectives of nitrous oxide sedation, as stated by the AAPD,<sup>52</sup> include the following:

- Reducing or eliminating anxiety
- Reducing untoward movement and reaction to dental treatment
- Enhancing communication and patient cooperation
- Raising the pain threshold
- Increasing tolerance for longer appointments
- Aiding in the treatment of a patient with mental and/or physical disabilities or a medically compromised patient
- Reducing gagging
- Potentiating the effects of sedatives

Disadvantages of nitrous oxide–oxygen inhalation may include:

- Lack of potency
- Dependence on psychological reassurance
- Interference of the nasal hood with injection to the anterior maxillary region
- Need for the patient to be able to breathe through the nose
- Nitrous oxide pollution and potential occupational exposure health hazards

### EQUIPMENT

Several manufacturers produce machines for the safe delivery of nitrous oxide–oxygen sedation in the dental office. All newly installed facilities that include nitrous oxide–oxygen delivery systems must be inspected for proper gas delivery and intact safety features prior to use. Acceptable machines must possess a high-flow oxygen flush valve and be capable of delivering 100% oxygen at a flow rate appropriate for pediatric emergency management. Fail-safe mechanisms include nitrous oxide–oxygen proportioning systems that do not allow oxygen concentrations to drop below 30%. If systems are used that allow more than 70% nitrous oxide

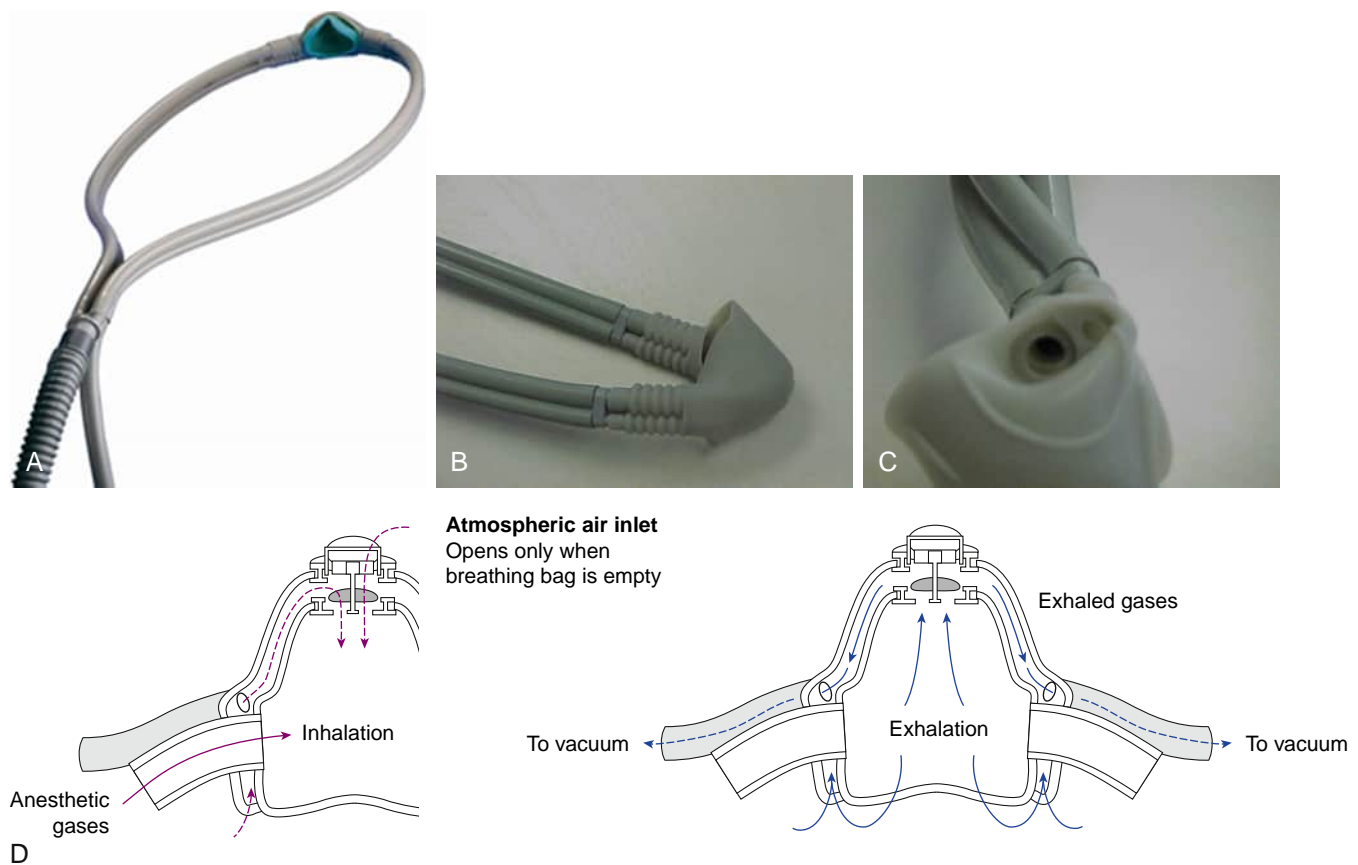
and less than 30% oxygen, an inline oxygen analyzer must be used. An acceptable scavenging system must be demonstrated to minimize the risk of occupational exposure and room contamination.<sup>29</sup> The double-mask type is the most efficient type of scavenger<sup>53</sup> (Fig. 18.6). These systems send exhaust into the vacuum waste system, which should be vented to the outside to prevent dispersal of gases to other areas of the office or building. Nasal hoods should be of good design and should be available in pediatric and adult sizes to ensure adequate fit, which further reduces leakage.

An additional safety feature for all nitrous oxide systems, mobile or fixed, is the pin index yoke system. Gas tanks will align only at right angles and produce a normal coupling when gas-specific pins are properly aligned (Fig. 18.7). Although it seems highly unlikely that gas tanks could be mistakenly attached to the wrong line with a pin index system in place, such errors have occurred. Gas tank crossover errors are more likely to occur when office renovations are done and when fittings wear with age and use.

### TECHNIQUE

After a thorough inspection of the equipment, the mask should be introduced to the patient with an explanation delivered at the appropriate level of understanding, and then the mask should be carefully placed over the patient's nose. Traditional behavior guidance techniques should be used because the effectiveness of nitrous oxide–oxygen sedation is closely linked to psychological reassurance. The delivery tubes are tightened behind the chair back with the patient in a comfortable position. The bag is filled with 100% oxygen and delivered to the patient for 1–2 minutes at an appropriate flow rate, typically between 4 and 6 L/min. With an appropriate flow rate, movement covering one quarter to one half of the breathing bag should be observed with each inhalation and exhalation. With too high a flow rate, the bag will be overinflated, movement will not be seen with each breath, and leakage will occur from around the mask. In this instance, the flow rate should be adjusted downward. Too low a flow rate will deplete the bag of mixed gases. Once the proper flow rate is achieved, nitrous oxide can be introduced by slowly increasing the concentration in increments of 10% to 20% until the desired level is achieved.

The dentist should encourage the patient to breathe through the nose with the mouth closed. It is helpful to explain the sensations as the patient begins to experience the effects of the gas. Effects are often described as a floating, giddy feeling with tingling of fingers and toes. The appearance of ptosis (sagging of the eyelids) is used by many as an objective marker of when local anesthetic should be administered. Once this is completed, the concentration can be reduced to approximately 30% nitrous oxide and 70% oxygen or lower. The level of moderate sedation can then be maintained throughout the procedures with minor adjustments of the oxygen and nitrous gas proportion. The dentist and staff should communicate with the patient throughout the procedure, paying particular attention to the rate and depth of breathing. This should be recorded for future reference. An emesis basin should be readily available; if vomiting does occur, the patient's head should be rotated to the side. However, the laryngeal reflex is not obtunded with



**Fig. 18.6** Example of a double-mask scavenger breathing circuit. (A) The “mask within a mask design.” (B–D) Combination of fresh inhalation and exhalation lines within the mask. (Photos courtesy of Porter Instrument Co., Hatfield, Pennsylvania, United States.)

nitrous oxide when used at proper concentrations, so aspiration of vomitus is unlikely.<sup>54</sup>

Recovery can be achieved quickly by reverse titration. Once the flow of nitrous oxide is reduced to zero, the patient should be allowed to breathe 100% oxygen for 3–5 minutes. The patient should be allowed to remain in the sitting position for a brief period to ensure against dizziness upon standing. The patient is then ready for discharge.

Diffusion hypoxia refers to conditions in which inhalation of high concentrations of nitrous oxide is abruptly discontinued, resulting in the quick reversal of the nitrous oxide concentration gradient between the gases in the lung and alveolar circulation. Under these conditions, nitrous oxide rapidly dilutes the oxygen in the alveoli, creating the conditions for hypoxemia. Many dentists provide the patient with 100% oxygen during the first few minutes following discontinuation of nitrous oxide to counteract the development of hypoxemia; however, this concern may be more theoretical than clinical. Studies have shown that hypoxemia is significant for only a few minutes and has been documented only when high concentrations (>70%) have been delivered by full mask or by endotracheal tube. These conditions cannot be met with the use of conventional dental nitrous oxide machines with nasal masks, and any tendency for diffusion hypoxia in the dental setting is likely to be trivial.

One must be cautious when attempting to extrapolate concentrations quoted from the anesthesia literature on nitrous oxide delivered through a full-face mask or endotracheal tube and applying them to a dental office

setting. The typical dental unit is constructed very differently from standard anesthesia machines. Loosely fitting nasal hood masks, dead space in large-bore tubing, and escape of nitrous oxide through the mouth of a spontaneously breathing patient dilute the intended concentration of nitrous oxide in the typical dental unit. Machines set to deliver 70% nitrous oxide, for example, may be delivering only 30% to 50% nitrous oxide to the patient’s alveoli due to the factors described above (Fig. 18.8).

## MONITORING AND DOCUMENTATION

Clinical observation and intermittent assessment of the level of sedation must occur throughout the procedure. This must include the patient’s responsiveness, color, and assessment of respiratory rate and rhythm. Furthermore, the percent of nitrous oxide used, flow rate, duration of the procedure, and post treatment oxygenation must be documented. Informed consent along with the indication for the use of nitrous oxide/oxygen must be documented in the record. A dedicated section or form, apart from the general consent to dental treatment, should be used.

## Enteral Sedation Technique

After the sedative agents have been selected, the proper dose of medication is calculated for the child. Once the sedative is administered, the patient should be kept in an



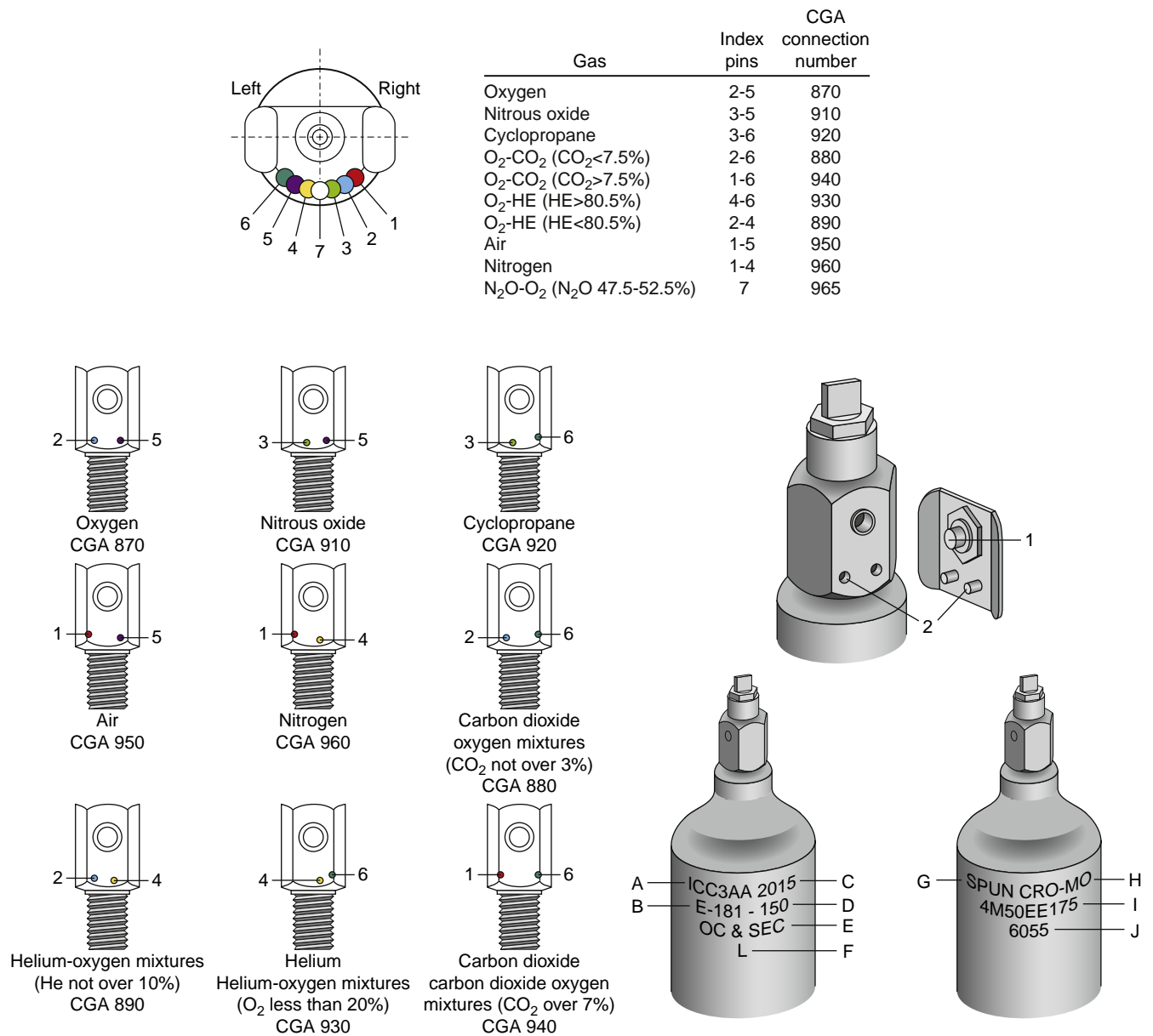


Fig. 18.7 The pin index system is used universally to minimize the chance of inadvertent connection of a medical gas to the wrong supply system.

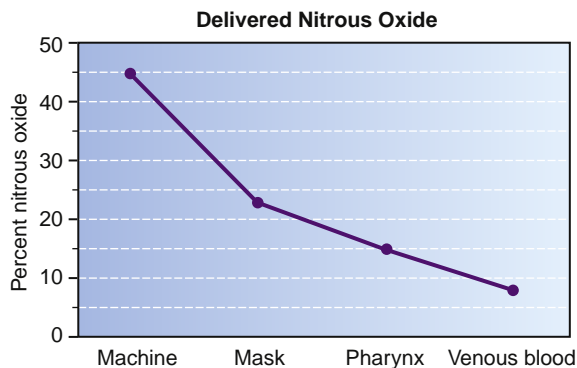



Fig. 18.8 The concentration of nitrous oxide that reaches the blood is often significantly less than the concentration indicated on the flow-meter.

area of the office that allows for continuous monitoring. When the desired effect is observed (usually after 30–60 minutes), the patient is transferred to the chair. Protective restraint devices, such as a papoose board (Fig. 18.9A), are often helpful to control potentially harmful movements in a sedated child. When such devices are used, the arms, legs, and pelvis should be aligned and secured, leaving the chest and diaphragm unrestrained, so that spontaneous breathing is not hindered. A shoulder roll, placed carefully beneath the upper part of the scapulae, will often help maintain airway patency during procedures (Fig. 18.9B). Nitrous oxide and oxygen may be started at this time to improve oxygenation and provide small adjustments to the level of sedation as needed. If the patient is not adequately sedated to the point that treatment can be accomplished, the attempt should be aborted. If the patient enters a level of deep sedation or general anesthesia, and the dentist does



**Fig. 18.9** (A) Papoose board. (B) Shoulder roll placement. The shoulder roll functions to keep the head rolled up and back, which allows for a more patent airway.

not possess comprehensive training in general anesthesia, the procedure should be stopped and the patient returned to the appropriate level of sedation (usually moderate sedation). If the dentist is unable to manage the patient after using the maximum amount of oral medication and nitrous oxide, the procedure should be terminated. Adding an additional enteral drug to deepen the level of sedation is often unpredictable, prolongs recovery, and may place the child at risk for re-sedation after discharge, when professional supervision is unavailable.

### Box 18.2 Discharge criteria

1. Cardiovascular function and airway patency are satisfactory and stable.
2. Patient is easily arousable and protective reflexes are intact.
3. The patient can talk (if age appropriate).
4. Patient can sit unaided (if age appropriate).
5. For a young child or a child with disabilities, incapable of the usual expected responses, the pre-sedation level of responsiveness or a level as close as possible to the normal level for that child should be achieved.
6. The state of hydration is adequate.

### Box 18.3 Minimum elements of post-sedation discharge instructions

1. Dietary guidelines
2. Instructions for taking medications
3. Description of any restrictions in activity
4. Identification of a responsible adult who will accompany and observe the patient after discharge
5. Contact information, including a phone number, and instructions to follow in the event of postoperative complications or an emergency

Timing is the most critical factor for successful treatment with enteral sedation techniques, yet practitioners have little ability to control the depth and duration of enteral sedation. Enteral sedation techniques are best suited for short procedures that can be accomplished within the expected working time of the sedative drug. Properly administered local anesthesia will enhance any level of anesthesia, but it is particularly useful in maximizing the effectiveness of minimal and moderate sedation. The patient should be monitored carefully during the procedure to ensure responsiveness. Discharge to the parent should occur only after minimal discharge criteria have been met (Box 18.2). Full oral and written instructions on post sedation care should be carefully reviewed with the caregiver, and the written information should be given to that person for easy reference at home (Box 18.3).

## Combinations of Methods and Agents

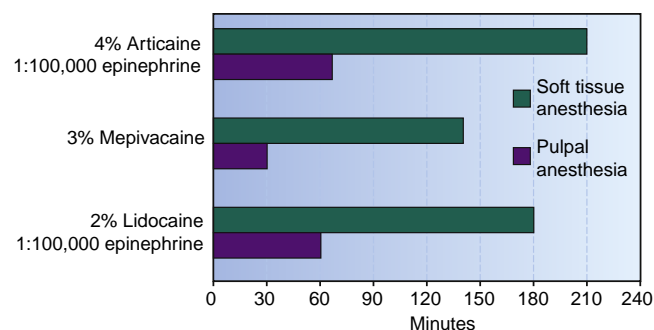
Pain is a complex process consisting of several interrelated components. The most basic component of pain is nociception, the unconscious, reflexive neuronal response to actual or potential tissue damage. Nociception, in turn, elicits other involuntary responses such as stimulation of the sympathetic nervous system, reflex withdrawal from the stimulus, and various neuroendocrine responses in both the CNS and the peripheral tissues. Conscious awareness of the event adds another layer to response, resulting in the *experience* of pain. Anxiety, the learned anticipation of pain acquired from previous experiences, may also modify present and future experiences of pain. Each of these responses possesses its own neurologic substrate in the nervous system.

No single drug available to the pediatric dentist for moderate sedation will neutralize all of the components of the pain process. For example, opioid drugs raise the threshold for nociception but, when used alone, do not usually eliminate the dental patient's awareness of the procedure. Benzodiazepines have specific anxiolytic, amnesia-producing, and muscle relaxant effects that minimize or eliminate awareness of the procedure but do not affect nociception. If sedative drugs are chosen and dosed appropriately, drug combinations can be more effective than single drugs in a given situation because more components of the pain and anxiety response are neutralized with the drug combination. The practice of using drug combinations must be judicious and thoughtful, however, because the potential for adverse outcomes is likely to increase when three or more sedative drugs are administered during pediatric sedation.<sup>55</sup> This is because each sedative drug has side effects in addition to the intended action; drugs interact with each other to produce new, unanticipated effects, and the chances of unintended consequences increase with the complexity of the drug combination.

Local anesthetics block the nociceptive process, preventing both the immediate sensation of pain and secondary disruption of sedation caused by autonomic and neuroendocrine responses. Local anesthesia is an integral part of levels of dental sedation and is often the most appropriate first choice of drugs to combine with other sedative agents to enhance the efficacy of moderate sedation.<sup>56</sup> Evidence shows that the use of local anesthetics improves the intraoperative and recovery phases of dental rehabilitation under general anesthesia.<sup>57</sup> In many instances, the apparent lack of local anesthetic efficacy during pediatric sedation is due to inattention to the expected onset, depth, and duration of local anesthesia. For most anesthetics, profound pulpal anesthesia exists for a much smaller window of time than the numbness produced in the surrounding soft tissue<sup>58</sup> (Fig. 18.10). Operators should time the local anesthetic administration so that the expected peak pulpal anesthesia coincides with the execution of known painful procedures, such as tooth extraction, pulpotomy, and surgical operations.

Inhalational sedation with nitrous oxide and oxygen is the next most frequently used agent in combination techniques. The onset, duration, and offset of oral sedative agents are relatively slow and beyond the control of the dentist once the drug is swallowed. In contrast, nitrous oxide is characterized by rapid onset and offset, is highly controllable, and is easily titrated. It is well suited to the making of intraoperative adjustments to the level of sedation provided by an oral agent. In contrast to the nonrecommended practice of dose-stacking (adding additional doses of oral sedatives in an attempt to deepen sedation), nitrous oxide provides rapid enhancement of the sedation level while allowing for equally rapid reversal of its effects should the enhanced level of sedation prove to be beyond the intended level of sedation.

Oral sedative combinations have a long history in pediatric dentistry. Given the rapid expansion of our knowledge of CNS physiology and pharmacology over the past 50 years, it is not surprising that our clinical criteria for oral sedative combinations have evolved as well. The current concept of an ideal oral sedative combination calls for drugs with



**Fig. 18.10** Producing high-quality local anesthesia is a fundamental component of successful moderate sedation. The peak effect of local anesthesia should ideally correspond to the peak surgical stimulation produced by the dental procedure. The use of a clock is useful for timing the appropriate administration of local anesthetic during sedation.

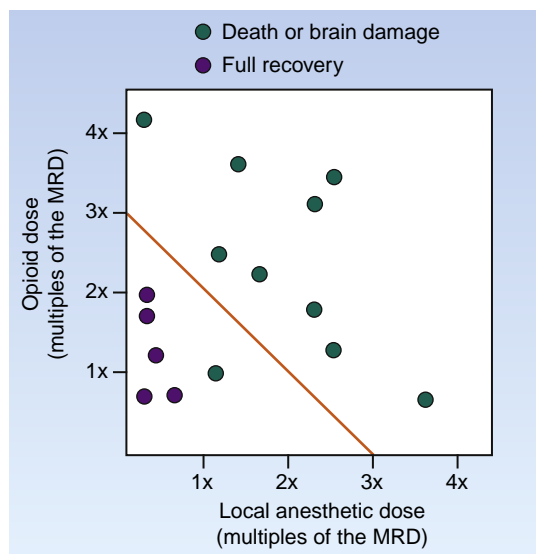
well-described mechanisms of actions, a wide margin of safety, and evidence to support their use in pediatric dentistry. These criteria are difficult to fulfill with many of the traditional techniques that used drugs with nonspecific mechanisms of actions and few documented outcome data. In an analysis of 53 studies of enteral sedation techniques published between 1996 and 2005, Robb<sup>59</sup> was unable to identify differences in the efficacy of drug combinations used for pediatric dentistry due to poor reporting practices and the lack of a standard scoring system. An analysis of 36 more recent studies of pediatric dental sedations showed weak evidence for the efficacy of oral midazolam and nitrous oxide.<sup>60</sup> Chowdhury and Vargas<sup>61</sup> compared a chloral hydrate, meperidine, and hydroxyzine combination with oral midazolam and concluded that the chloral hydrate combinations showed significantly more effective sedation than midazolam. A comparison of hydroxyzine/midazolam with hydroxyzine and chloral hydrate/hydroxyzine by Torres-Pérez et al.<sup>62</sup> concluded that regimens of midazolam or chloral hydrate mixed with hydroxyzine represented excellent choices for conscious sedation.

Chloral hydrate became unavailable in the United States after February 2012. Prior to its discontinuance, certain chloral hydrate combinations had a reputation for being effective, yet remained controversial. A retrospective chart review of 195 cases showed that 50 mg/kg chloral hydrate combined with either meperidine or hydroxyzine was judged to be satisfactory in 72% of cases.<sup>63</sup> Higher doses of chloral hydrate with nitrous oxide were also judged as effective; however, the risk of airway compromise, respiratory depression, and exceeding moderate sedation increased significantly with increasing doses.<sup>64,65</sup> Despite the apparent success of these combinations, concerns surfaced in several reports about the use of chloral hydrate. In a review of poor outcomes associated with chloral hydrate in medical and dental practice, Coté et al.<sup>66</sup> found that 5 of 13 cases of death or permanent brain damage were dental patients. Incorrect dosing, poor communication among dental staff, and failure to rescue patients from deeper than intended levels of sedation have been cited as major factors leading to the poor outcomes in dental settings.<sup>67</sup>

One attempt to identify an alternative to chloral hydrate combinations has been the use of midazolam in combination with meperidine and hydroxyzine. Sheroan et al.<sup>68</sup> found no difference in behavioral outcomes or physiologic



parameters when this combination was compared with chloral hydrate, meperidine, and hydroxyzine.<sup>68</sup> Further investigation of the safety and efficacy of this and similar combinations is needed, particularly regarding the continued use of opioids in such combinations. A dose-dependent increase in untoward outcomes, including hypoxia, has been demonstrated for meperidine.<sup>69</sup> Opioids have also been associated with significant local anesthetic toxicity when both have been used as part of a pediatric sedation regimen.<sup>70,71</sup> The interaction results in a lowering of the convulsant threshold for local anesthetic toxicity. Although the mechanism is multifaceted, opioids may produce a mild respiratory acidosis that decreases the binding of local anesthetics to serum albumin, permitting more of the free drug to circulate to the CNS. In a review of adverse drug interactions in dental practice, an expert panel rated this interaction as highly significant, particularly with the combination of meperidine and mepivacaine<sup>72</sup> (Fig. 18.11).



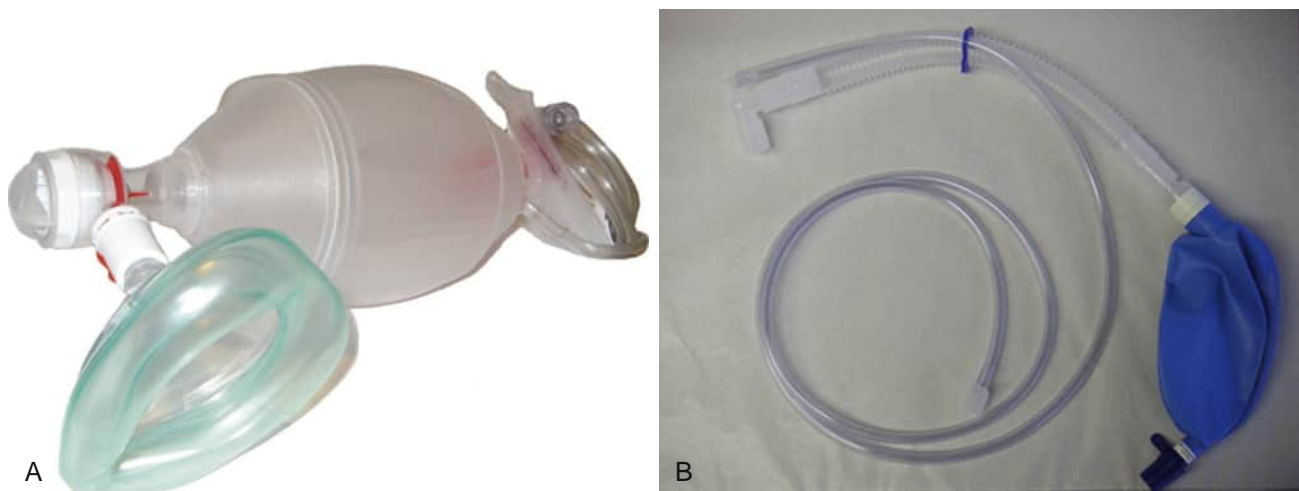
**Fig. 18.11** Caution must be exercised when local anesthetics are used together with opioids during pediatric sedation. MRD, maximum recommended dose.

## Facilities and Equipment

Although not necessary, a comfortable, single-patient, “quiet room” is helpful. It isolates the sedation in progress from the activity of a typical pediatric dental practice and reduces noise and other distractions that may compromise the ability of the doctor and staff to focus fully on the patient. The facility should be equipped to manage sedation rescue maneuvers and sedation-related emergencies. The most common dental sedation emergencies involve airway compromise resulting in obstruction, impaired ventilation, laryngospasm, apnea and hypoxia. Specific equipment items include adequate suction, monitoring devices, and a positive-pressure oxygen delivery system that is capable of sustaining greater than 90% oxygen at a flow rate of 10 L/min for at least 60 minutes (650-L E cylinder). When a self-inflating bag-valve-mask device is used for delivering positive-pressure oxygen, a flow rate of 15 L/min is recommended. A functional suction apparatus with appropriate suction catheters and a sphygmomanometer with cuffs of appropriate size for pediatric patients must be immediately available. All equipment must be adaptable to children of all ages and sizes.<sup>2</sup>

As previously stated, all inhalational sedation equipment must have the capability for immediate delivery of 100% oxygen with a minimum delivery of 30%. The apparatus must have a fail-safe system that accomplishes complete shutdown when the oxygen supply drops below the 30% level. If nitrous oxide–oxygen delivery equipment capable of delivering more than 70% nitrous oxide and less than 30% oxygen is used, an in-line oxygen analyzer must be used. This system must be checked and calibrated annually.

Timely and effective airway management is the most important factor. In the emergency airway armamentarium, drugs and equipment needed to resuscitate an apneic, unconscious patient must be fresh and close at hand. An adequate positive-pressure device, such as an Ambu bag or a modified Jackson-Rees circuit, should be kept in the quiet room to provide immediate positive-pressure ventilation should a patient become apneic (Fig. 18.12). Although



**Fig. 18.12** Nitrous oxide delivery systems are designed to provide a sedative mixture of gas to patients breathing spontaneously. They are not designed to deliver positive-pressure ventilation in an emergency. Dentists should have an adequate emergency breathing circuit, such as (A) an Ambu bag or (B) modified Jackson-Rees circuit, which can be used to deliver positive-pressure oxygen when indicated.

**TABLE 18.3** Continuum of Depth of Sedation: Definition of General Anesthesia and Levels of Sedation/Analgesia

	<b>Minimal Sedation Anxiolysis</b>	<b>Moderate Sedation/ Analgesia (“conscious sedation”)</b>	<b>Deep Sedation/Analgesia</b>	<b>General Anesthesia</b>
Responsiveness	Normal response to verbal stimulation	Purposeful response to verbal or tactile stimulation	Purposeful response following repeated or painful stimulation	Unarousable even with painful stimulus
Airway	Unaffected	No intervention required	Intervention may be required	Intervention often required
Spontaneous ventilation Cardiovascular function	Unaffected Unaffected	Adequate Usually maintained	May be inadequate Usually maintained	Frequently inadequate May be impaired

Accessed from the American Society of Anesthesiologists, *Anesthesiology* 3 2018, Vol.128, 437-479. <https://doi.org/10.1097/ALN.0000000000002043> Last accessed June 7, 2019.

ventilation with an Ambu bag and insertion of a supraglottic emergency airway device are part of the current Basic Life Support guidelines offered by the American Heart Association, the use of these devices should be reviewed in regular emergency drills in offices that provide sedation to pediatric patients.

## Documentation

Clear and complete documentation of the sedation procedure is essential for many reasons. Good records enable a practitioner to address postoperative concerns after discharge, evaluate problems or concerns discovered on follow-up or subsequent appointments, and participate in continuous quality improvement practices. Preprocedural records should document: (1) adherence to food and liquid intake restrictions; (2) preoperative health evaluation, including the patient's health history and a complete physical assessment along with the patient's current weight, age, and baseline vital signs; (3) name and address of the physician who usually cares for the child; (4) a note as to why the particular method of management was selected; (5) documentation of informed consent; and (6) the delivery of instructions to the caregiver. Before the procedure is undertaken, a “time out” should be performed to confirm the patient's name, procedure to be performed, and site of the procedure.

Intraoperatively, the appropriate vital signs should be recorded as they are assessed (Table 18.3). Timed notations regarding the patient's appearance and significant intraoperative events should be included. The type of drug, dose administered, route and site of administration, and time of administration should be clearly indicated. If a prescription is used, either a copy of the prescription or a note as to what was prescribed should also be a part of the permanent record.

After the treatment is completed, the patient should be observed in a recovery area equipped with suction and the capability to provide positive-pressure ventilation. Vital signs should be recorded at specific intervals. If the patient is not fully alert, oxygen saturation and heart rate should be continuously monitored until discharge criteria are met. The doctor administering the sedation is responsible for determining when fitness for discharge is achieved.

## Patient Selection and Preparation

### INDICATIONS

No single agent, drug combination, or technique should be expected to be successful every time. The dentist should choose the agent and technique that best fit the patient type as well as the nature of what needs to be accomplished. Pediatric dentists have often found behavioral or anxiety-assessment profiles to be helpful in determining the most appropriate form of behavioral management for a child.<sup>73,74</sup> As the practitioner gains experience, equal or greater value will be placed on his/her intuition and judgment.

Patient selection, as well as the choice of drugs, support personnel, and technique, should be guided by the intended level of sedation. The drugs and techniques should possess a wide therapeutic window for moderate sedation, making the unintended loss of consciousness unlikely. For moderate sedation, the treatment team should include a person, in addition to the practitioner, whose responsibility is to monitor appropriate physiologic parameters and assist in any supportive resuscitative measures, if required. This individual may also be responsible for assisting with interruptible patient-related tasks of short duration, such as holding an instrument or troubleshooting equipment.<sup>75</sup> Likewise, the use of drugs and techniques likely to produce unconsciousness should be avoided as the training, personnel, and safety requirements for deep sedation and general anesthesia exceed those for moderate sedation.<sup>9</sup>

### Preoperative Evaluation

A thorough review of the medical history is required to determine whether a patient is a good candidate for sedation. This review may also include a recent medical history and physical examination from another qualified provider, as indicated. The review of medical history, along with a focused physical assessment, enables the dentist to arrive at a physical status classification.

The physical status classification system of the American Society of Anesthesiologists (ASA) is the most commonly used method of determining the physical status for patients undergoing any form of anesthesia (Box 18.4). Following a review of the medical history and physical evaluation, patients are classified into one of six categories. Patients who are classified as ASA class I are frequently considered

### Box 18.4 American society of anesthesiologists' physical status classification system

ASA Physical Status 1: A normal healthy patient  
 ASA Physical Status 2: A patient with mild systemic disease  
 ASA Physical Status 3: A patient with severe systemic disease  
 ASA Physical Status 4: A patient with a severe systemic disease that is a constant threat to life  
 ASA Physical Status 5: A moribund patient who is not expected to survive without the operation  
 ASA Physical Status 6: A patient who has been declared brain dead and whose organs are being removed for donor purposes

appropriate candidates for minimal, moderate, or deep sedation. Many children classified as ASA class II may also benefit from appropriate procedural sedation; however, consultation with an anesthesiologist or appropriate medical specialist is often desired. Children classified as ASA class III and ASA class IV, children with special needs, and those with anatomic airway abnormalities or extreme tonsillar hypertrophy require additional medical consultation as part of the preoperative evaluation, and are often better managed by a physician anesthesiologist or dentist anesthesiologist.

The medical history should include the following information:

1. Allergies and previous allergic or adverse drug reactions.
2. Current medications, including dosage, time, route, and site of administration for prescription, over-the-counter, herbal, or illicit drugs. Many drugs, including herbal agents (e.g., St. John's wort, echinacea, kava, valerian), may alter drug pharmacokinetics, prolonging the effects of sedative agents.
3. Diseases or abnormalities in the patient, including pregnancy status of adolescents and neurologic impairment that might increase the potential for airway obstruction, such as a history of snoring or obstructive sleep apnea.
4. Previous hospitalizations, including the date, purpose, and hospital course.
5. History of general anesthesia or sedation and any associated complication.
6. Family history of diseases and sedation or anesthetic complications.
7. Review of body systems.
8. Age (in years and months) and weight.
9. Name, address, and contact information of the child's medical home.

The physical evaluation should include the following:

1. Height and weight.
2. Vital signs, including heart and respiratory rates, blood pressure, and temperature. If determination of baseline vital signs is prevented by the patient's physical resistance or emotional condition, the reason(s) should be documented.
3. Evaluation of airway patency to include tonsillar size and anatomic abnormalities that may increase the risk of airway obstruction (e.g., mandibular hypoplasia, large, short neck, limited mandibular range of motion).

4. Physical abnormalities or conditions that may affect routine intraoperative monitoring (e.g., recent orthopedic injuries to arms or legs, active skin rashes).

Dentists should also assess the degree to which behavioral abnormalities will affect the ability for the child to be assessed during sedation. The child's failure to respond appropriately to verbal interaction places a greater degree of responsibility upon the dentist for determining and maintaining an appropriate level of sedation.

### INFORMED CONSENT

The parent or legal guardian must consent to the use of sedation for the child. These individuals are entitled to receive complete information regarding the reasonably foreseeable risks and the benefits associated with the particular technique and agents being used, as well as any alternative methods available. Therefore, the explanation should be in clear, concise terms that are familiar to them. Informed consent forms should contain the parent's or guardian's signature and the date upon which informed consent was obtained, as well as the date upon which the sedation is planned. If informed consent is obtained prior to the date of the procedure, consent should be reaffirmed on the day of surgery prior to the start of treatment. The doctor must be satisfied that the parent or legal guardian has the capacity to understand the risks and benefits of the procedure and is able to provide voluntary consent that is free of coercion.<sup>76</sup> Because sedation is not considered a routine part of every dental visit, this consent should be separate and distinct from permission to treat the patient.

### INSTRUCTIONS TO PARENTS

Information in written form should be reviewed with the person caring for the child and given to this person along with the notice of the scheduled appointment. This information should include a 24-hour contact number for the practitioner.

The AAPD specifies the following preoperative dietary instructions:

1. Clear liquids: water, fruit juices without pulp, carbonated beverages, clear tea, or black coffee up to 2 hours before the procedure.
2. Breast milk up to 4 hours before the procedure.
3. Infant formula up to 6 hours before the procedure.
4. Nonhuman milk up to 6 hours before the procedure.
5. A light meal up to 6 hours before the procedure. A light meal typically consists of toast and clear liquids. Meals that include fried or fatty foods or meat may prolong gastric emptying times and should be avoided.
6. It is permissible for routine necessary medications to be taken with a sip of water on the day of the procedure.

The reasons for these recommendations are two-fold. First, emesis during or immediately after a sedative procedure is a potential complication that can result in the aspiration of stomach contents, leading to laryngospasm or severe airway obstruction. Aspiration may have serious sequelae, including aspiration pneumonitis and potentially



fatal pulmonary damage. Second, the uptake of sedative agents administered by the oral route is maximized when the stomach is empty.

The parent or guardian should also be advised that he or she will be expected to remain in the area of the office during the sedation appointment. With regard to transportation, the instructions should request that a second person accompany the parent so that the person caring for the child may be free to attend to the child's needs during the trip home.

The caregiver should be advised that, on arriving home, the child might sleep, feel drowsy, or display irritability. It is important to stress the need for frequent observation of the child for an appropriate period of time. The dentist should consider the types of agents used and the expected duration of drug effects when advising the caregiver on the length of time a child should be closely supervised at home. Inappropriate or inaccurate postoperative instructions may cause caregivers to question their credibility or dismiss other postoperative instructions.

Many pediatric dentists recommend that children first be offered clear liquids after sedation and advance to solid foods as tolerated. Once solids are tolerated, there are no dietary restrictions other than those imposed because of the dental procedure performed. This practice is based on concern that premature feeding may contribute to nausea, thus prolonging the reintroduction of solid foods. There are several causes of nausea and vomiting after sedation. Risk factors include the use of nitrous oxide or opioid medications, swallowing of blood, relative hypoxia, premature ambulation, inadequate pain control, and procedures lasting over 30 minutes.<sup>77</sup> Dentists should carefully consider additional factors to maximize the prevention of postoperative nausea and vomiting. Verbal and written instructions should be provided to the parent or guardian before the patient is discharged from the office (Box 18.2). The time at which the dentist determined fitness for discharge should be noted, along with a notation that oral and written discharge instructions were provided.

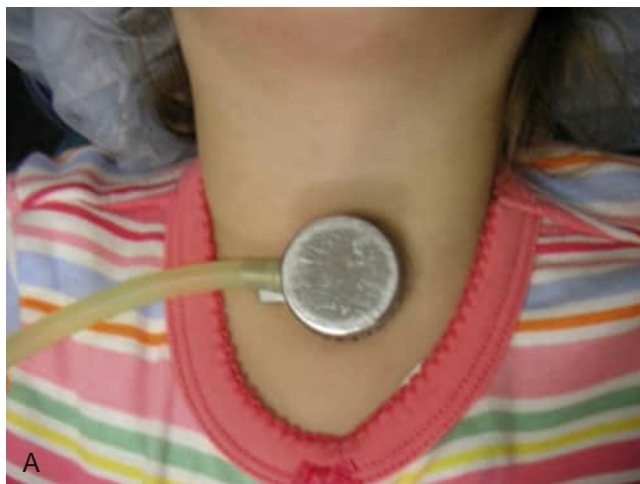## Monitoring

### INTRAOPERATIVE MONITORING

Intraoperative monitoring must include an assessment of oxygenation, ventilation, and circulation. The depth of sedation dictates the degree and frequency of monitoring required.<sup>78</sup>

As the treatment progresses, the state of consciousness should be evaluated frequently by bidirectional verbal communication with the patient. If bidirectional verbal communication is not appropriate or possible, the use of a pretracheal stethoscope or capnography (discussed in more detail below) is required. For patients who are incapable of communication because of age or disability, some means of evoking a response should be used. Another area of assessment is the patient's external appearance. The oral mucosa, nail beds, and complexion of the skin provide indications of perfusion of the patient. This should be done at intervals throughout the procedure and documented in the record. If restraining devices that cover the patient are used, a hand or foot should be exposed. These devices should be carefully applied to the sedated patient to ensure that there is no restriction of the chest.

The heart and respiratory rates can be continuously monitored with a pretracheal stethoscope (Fig. 18.13). The bell of the stethoscope is secured in the suprasternal notch, where breath and heart sounds are easily auscultated. This instrument allows for continuous monitoring of the rate and depth of breathing. These devices are manufactured with a variety of amplification schemes, including a remote earpiece and a wireless speaker that transmits the patient's breath sounds throughout the entire operatory. Additional ventilatory monitoring should include observation of chest excursions. The common dental team habit of using the patient's chest as an ad hoc instrument table, or completely covering the chest with towels or other barriers, interferes with the observation of chest excursions and should be avoided when possible.



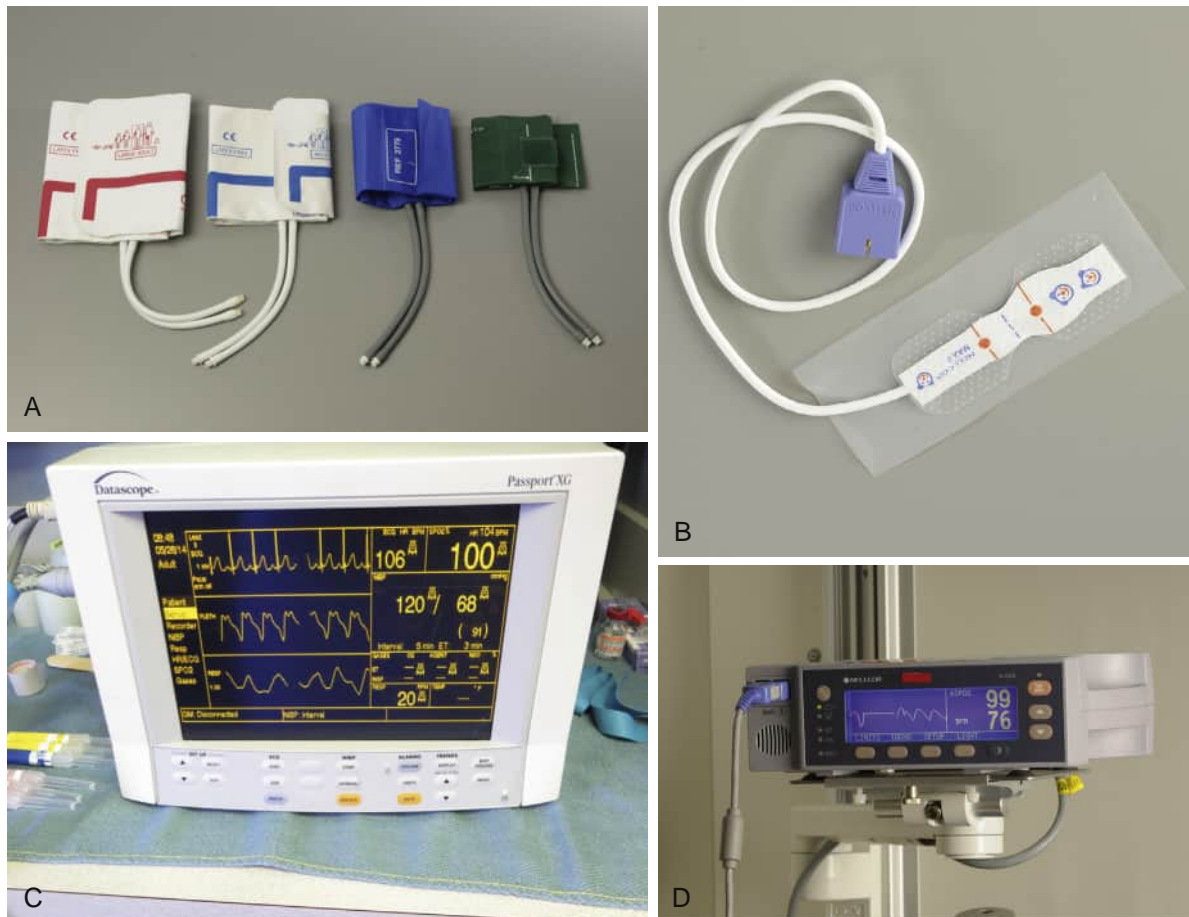
**Fig. 18.13** Pretracheal stethoscopy provides the dentist with the ability to listen to breath sounds while watching other indicators of ventilation. (A) Proper placement of chest piece on patient. (B) Wireless system. (B, Courtesy of Sedation Resource.)

Although it is acceptable to measure physiologic parameters using the basic methods of auscultation and an aneroid sphygmomanometer with a manually inflated cuff, numerous automatic, continuous monitoring blood pressure devices are available. In all instances, the cuff should be of the appropriate size for the patient. Pulse oximetry probes are available that attach to the finger or earlobe and produce both visual and audible signals. The pulse oximeter and automatic blood pressure cuff are often bundled together in a single monitor that may also include additional physiologic monitoring devices (Fig. 18.14).

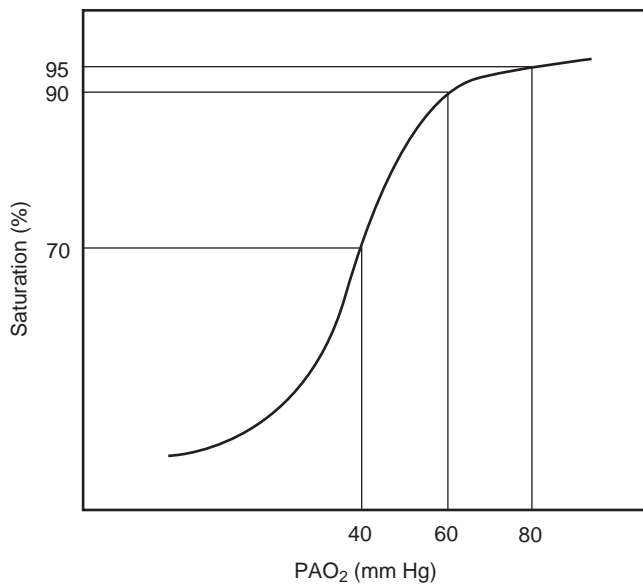
In 1981, the introduction of pulse oximetry to health care providers created a revolution in patient safety monitoring. By 1987, it had become part of the standard monitoring armamentarium for anesthesia providers and is used in many other locations where the monitoring of the effectiveness of a patient's breathing is desired. The device measures the extent to which hemoglobin is saturated with oxygen while simultaneously monitoring the peripheral pulse rate. A probe consisting of an optical diode sensor and a second, light-emitting diode is applied to a digit on the hand or foot, or to the earlobe. The light-emitting diode emits both red and infrared wavelengths of light, and the light-detecting diode detects light transmitted through the tissue. Red wavelengths are absorbed primarily by

oxygenated hemoglobin, whereas infrared wavelengths are absorbed primarily by deoxygenated hemoglobin. The ratio of deoxygenated hemoglobin to oxygenated hemoglobin is determined and displayed. One shortcoming of the pulse oximeter is a processing delay of approximately 20 to 40 seconds. This is particularly pertinent for pediatric dentists because children may begin to experience oxygen desaturation within 10 to 20 seconds after the onset of breathlessness. Therefore, it is important that the pulse oximeter be appreciated as a monitor of oxygenation, not of ventilation. Several conditions can also lead to inaccurate oximeter readings, including: (1) failure to place diodes directly opposite each other, (2) interference from ambient light, (3) placement of diodes on the same limb as a blood pressure cuff, (4) fingernail polish on the digit to which the sensor is attached, (5) cold limbs, (6) profound tissue pigmentation, (7) reuse of disposable sensors, and (8) motion artifacts. Sensor displacement is the most common cause for false readings in children and can be minimized by the use of a sensor with adhesive tabs rather than a clip-on sensor. Securing the sensor with an additional tape and using a toe rather than a finger may also help minimize displacement.

The correlation between the percent oxygen saturation of hemoglobin ( $\text{SaO}_2$ ) and oxygen tension in arterial



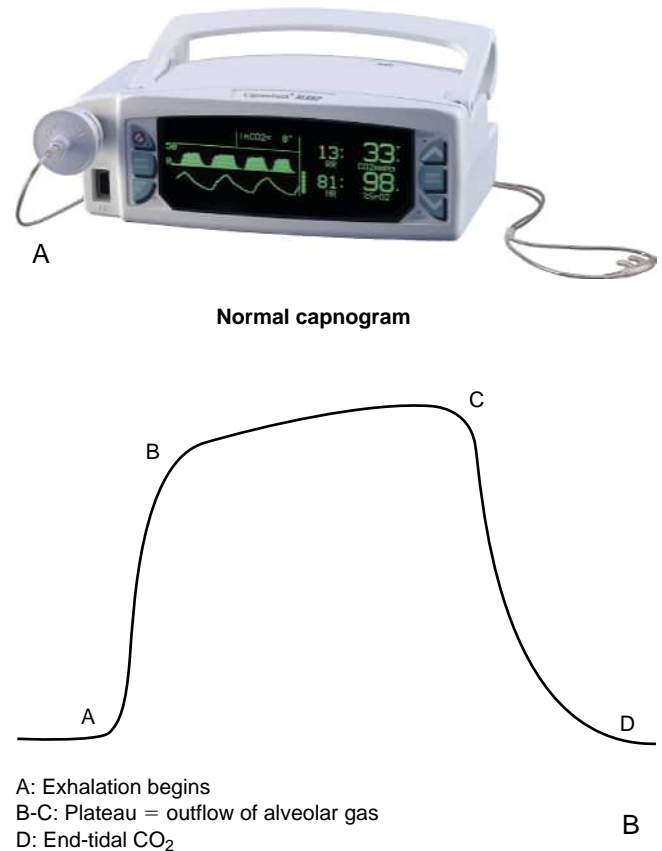
**Fig. 18.14** Physiologic monitoring should be chosen to conform to basic standards of intraoperative monitoring while matching the needs of the pediatric dentist. Devices should be appropriately sized for pediatric patients. A wide variety of monitors exists. (A) Blood pressure cuffs in various sizes. (B) Pulse oximetry probes with and without adhesive tabs. (C) Automated vital signs monitor. (D) Pulse oximeter.



**Fig. 18.15** Oxyhemoglobin dissociation curve, which shows the saturation of hemoglobin with oxygen ( $SaO_2$ ) relative to oxygen tension ( $PaO_2$ ). Hypoxemia is defined as  $PaO_2$  below 80 mmHg (95%  $SaO_2$ ). (From Dionne R, Phero, J, Becker D. *Management of pain and anxiety in the dental office*, Philadelphia: WB Saunders; 2002.)

blood ( $PaO_2$ ) must be appreciated when oxygen saturation is interpreted. The relationship between the two parameters is plotted on the oxyhemoglobin dissociation curve (Fig. 18.15). Unbound oxygen dissolved in blood produces the oxygen tension ( $PaO_2$ ) required to supply oxygen to the peripheral tissues. When a patient stops breathing, hypoxemia begins when oxygen saturation drops to 95%, corresponding to an oxygen tension of 80 mmHg. Once the arterial saturation levels drop to 90% ( $PaO_2 = 60$  mmHg), the patient will begin to desaturate rapidly if effective ventilation is not immediately restored. Awareness of the peripheral oxygen saturation from moment to moment is important during the administration of sedation because hypoxia is usually the initial event in morbidity and mortality related to sedation.<sup>79</sup>

Ventilation—the mechanical act of moving air throughout the respiratory system—must be evaluated independently from oxygenation. Methods used to monitor ventilation include visual monitoring for chest wall movement, listening for breath sounds with a precordial stethoscope, determination of respiratory rate, and capnography. Capnography is the most sensitive of these methods, providing direct confirmation of apnea within seconds after breathing is interrupted. When possible, the combination of capnography and precordial stethoscopy provides the optimal strategy for monitoring the adequacy of breathing during the course of pediatric sedation. The capnograph (Fig. 18.16A) detects both the presence and the quality of ventilation by analyzing the concentration of carbon dioxide in the exhaled gases through differential infrared absorption. The end-tidal carbon dioxide concentration is the concentration of carbon dioxide measured at the terminal portion of the exhalation curve (Fig. 18.16B).<sup>20</sup> The sampling line is placed either in the nostril or in close approximation to the nose or mouth and allows for sampling of exhaled



A: Exhalation begins  
B-C: Plateau = outflow of alveolar gas  
D: End-tidal  $CO_2$

**Fig. 18.16** Capnography. (A) The monitor produces a waveform by the continuous analysis of expired gas for carbon dioxide. (B) The presence of a waveform implies exhalation of gases from the lungs. The end-tidal carbon dioxide concentration (point C) corresponds to the concentration of alveolar gas, which correlates closely with the arterial partial pressure of carbon dioxide. (A, Courtesy of Capnograph by Smiths Medical ASD, Inc., St. Paul, Minnesota; B, from Anderson J, Vann W. Respiratory monitoring during pediatric sedation: pulse oximetry and capnography, *Pediatr Dent*. 1988;10:94–101.)

air into the unit. There are limitations to the accuracy of readings, especially when the device is used in children. Head movement, mouth breathing, crying, and tube blockage by mucus all result in inaccurate readings. In 2014, the American Association of Oral and Maxillofacial Surgeons mandated the use of capnography whenever possible during moderate sedation as part of its standard of care.<sup>80</sup>

## POSTOPERATIVE MONITORING

Determining fitness for discharge is a critical part of the sedation process because it marks the point at which supervision of the child is relinquished from the professional staff to the parents. The child must be reasonably alert, able to talk, ambulating with minimal assistance, and sitting unaided. The child should be able to remain awake for at least 20 minutes, unstimulated, before discharge. For the very young patient or a patient with disabilities, either of whom might be incapable of the usually expected responses, a level of awareness that is as close to the usual state as possible for that person must be achieved before discharge. Fitness for discharge is the responsibility of the doctor and must be documented.<sup>53</sup>



## Concluding Thoughts

The AAPD and the American Dental Association have published several guidelines to assist the dentist in performing moderate sedation. Items from these guidelines have been referenced in several places throughout this chapter. In addition to these valuable sets of guidelines, three principles are offered here for dentists undertaking moderate sedation for children:

- 1) *Primum non nocere* is the Latin phrase translated as “first, do no harm.” It is the guiding bioethical principle for all health care providers and is based on the Hippocratic Oath. Prior to undertaking any pediatric sedation, the dentist must be satisfied that the potential benefits of treatment outweigh potential risks, and that the decision is founded on appropriate information.
- 2) *Airway management supersedes pharmacologic management.* The maintenance of adequate ventilation and oxygenation must be ensured throughout all phases of pharmacologic management. Where there is doubt, the sedation protocol should be modified or abandoned.
- 3) *Appreciate the limits of moderate sedation.* Patient responsiveness is inherent in moderate sedation. Sometimes the responsiveness of the patient will interfere with dental treatment, causing treatment to be modified or abandoned. When treatment cannot be accomplished with moderate sedation, alternative strategies such as general anesthesia performed by appropriately trained providers should be considered.

## References

1. Wilson S: Pharmacological management of the pediatric dental patient, *Pediatr Dent* 26(2):131–136, 2004.
2. Coté CK: Commentary on article by Vlade et al, *Am J Roentgenol* 165(4):910–912, 1995.
3. Boynes S: *Dental anesthesiology: a guide to the rules and regulations of the USA*, ed 5, USA, 2013, No-No Orchard Publishing, pp 52–1024.
4. Hicks CG, Jones JE, Saxen MA, et al.: Demand in pediatric dentistry for sedation and general anesthesia by dentist anesthesiologists: a survey of directors of dentist anesthesiologists and pediatric dentistry residencies, *Anesth Prog* 59(1):3–11, 2012.
5. American Society of Anesthesiologists (ASA): excerpted from Continuum of depth of sedation: definition of general anesthesia and levels of sedation/analgesia, Park Ridge, 2004. A copy of the full text can be obtained from ASA, 520 N. Northwest Highway, IL 60068–62573.
6. Green SM, Krauss B: Procedural sedation: moving beyond conscious sedation, *Anal Emerg Med* 39(4):433–435, 2002.
7. Coté CJ, Wilson S: Guidelines for the monitoring and management of pediatric patients during and after sedation for diagnostic and therapeutic procedures, *Pediatrics* 118(6):2587–2603, 2006.
8. Haynes AB, Weiser TG, Berry WR, et al.: A surgical safety checklist to reduce morbidity and mortality in a global population, *New Engl J Med* 360(5):491–499, 2009.
9. Coté C, Wilson C, American Academy of Pediatrics, et al.: Guidelines for monitoring and management of pediatric patients before, during, and after sedation for diagnostic and therapeutic procedures, *Pediatrics* 143(6):e20191000, 2019.
10. Coté C: Discharge criteria for children sedated by nonanesthesiologists, *Anesthesiology* 100(2):207–209, 2004.
11. Lee HH, Milgrom P, Starks H, et al.: Trends in death associated with pediatric dental sedation and general anesthesia, *Pediatr Anesth* 23(8):741–746, 2013.
12. Perouansky M, Hemmings HC: Neurotoxicity of general anesthetics: cause for concern? *Anesthesiology* 111(6):1365–1371, 2009.
13. Sun L: Early childhood general anaesthesia exposure and neurocognitive development, *Br J Anaesth* 105(Suppl 1):i61–i68, 2010.
14. Davidson AJ, Sun LS: Clinical evidence for any effect of anesthesia on the developing brain, *Anesthesiology* 128(4):840–853, 2018.
15. Southall DP, Richards JE, Mitchell P, et al.: Study of cardiac rhythm in healthy newborn infants, *Br Heart J* 43(1):14–20, 1980.
16. Katz J, Steward DJ: *Anesthesia and uncommon diseases*, ed 6, Philadelphia, 2012, WB Saunders.
17. Hislop A, Muir DC, Jacobsen M, et al.: Postnatal growth and function of the pre-acinar airways, *Thorax* 27(3):265–274, 1972.
18. Giovannitti Jr JA: Dental anesthesia and pediatric dentistry, *Anesth Prog* 42(3–4):95–99, 1995.
19. Coté CJ, Lerman J, Todres ID: *A practice of anesthesia for infants and children*, ed 6, Philadelphia, 2018, WB Saunders.
20. 2009 Pediatric Nutrition Surveillance System data (PedNSS), Last accessed June 3, 2019. [www.cdc.gov/pednss/pdfs/PedNSS](http://www.cdc.gov/pednss/pdfs/PedNSS).
21. Childhood obesity facts, last accessed June 3, 2019. <http://www.cdc.gov/healthyyouth/obesity/facts.htm>.
22. Narang I, Mathew JL: Childhood obesity and obstructive sleep apnea, *J Nutrition Metab* 22:2012, 2012.
23. Sorof J, Daniels S: Obesity hypertension in children: a problem of epidemic proportions, *Hypertension* 40(4):441–447, 2002.
24. Stambaugh JE, Wainer IW, Sanstead JK, et al.: The clinical pharmacology of meperidine—comparison of routes of administration, *J Clin Pharmacol* 16(5–6):245–256, 1976.
25. Pharmacokinetics. In Brunton L, Chabner B, Knollman E, editors: *Goodman and Gilman's the pharmacological basis of therapeutics*, 13th edition, New York, 2017, McGraw-Hill.
26. Granoff DM, McDaniel DB, Borkowf SP: Cardiorespiratory arrest following aspiration of chloral hydrate, *Am J Dis Child* 122(2):170–171, 1971.
27. American Dental Association: *Guidelines for the use of sedation and anesthesia by dentists*, [www.ada.org](http://www.ada.org), 2012. Last accessed June 1, 2019.
28. Hau S: Physiological and Pharmaceutical Considerations for Rectal Drug Formulations, *Front Pharmacol*, 10:1196, 2019. <https://www.frontiersin.org/articles/10.3389/fphar.2019.01196>. Last accessed September 22, 2020.
29. Cohen EN, Brown BW, Wu ML, et al.: Occupational disease in dentistry and exposure to trace anesthetic gases, *J Am Dent Assoc* 101(1):21–31, 1980.
30. Thakkar MM: Histamine in the regulation of wakefulness, *Sleep Med Rev* 15(1):65–74, 2011.
31. Richelson E: Neuroleptic affinities for human brain receptors and their use in predicting adverse effects, *J Clin Psychiatry* 45(8):331–336, 1984.
32. Paton DM, Webster DR: Clinical pharmacokinetics of H1 receptor antagonists, *Clin Pharmacokinet* 10(6):447–479, 1985.
33. Taylor G, Calvert RT, Houston JB: Determination of promethazine in biological fluids, *Anal Lett* 12(14):1435–1442, 1997.
34. Hickson GB, Altemeier WA, Clayton EW: Should promethazine in liquid form be available without prescription? *Pediatrics* 86(2):221–225, 1990.
35. Ghoneim MM, Mewaldt SP: Benzodiazepines and human memory: a review, *Anesthesiology* 72(5):926–938, 1990.
36. Griffin CE 3<sup>rd</sup>, Kaye AM, Bueno FR, Kaye AD: Benzodiazepine pharmacology and central nervous system-mediated effects. *Ochsner J* 13(2):214–23, 2013. <https://pubmed.ncbi.nlm.nih.gov/23789008>. Last accessed September 22, 2020.
37. Stoelting RK: Benzodiazepines. In *Pharmacology and physiology in anesthetic practice*, ed 4, New York, 2006, Lippincott.
38. Reves JD, Fragen RJ, Vinik HR, et al.: Midazolam: pharmacology and uses, *Anesthesiology* 62(3):310–324, 1985.
39. Mohler HT, Okada T: Benzodiazepine receptor: demonstration of the central nervous system, *Science* 198(4319):849–851, 1977.
40. White PF, Vasconez LO, Mathes SA, et al.: Comparison of midazolam and diazepam for sedation during plastic surgery, *Plast Reconstr Surg* 81(5):703–712, 1988.
41. Bailey PL, Pace NL, Ashburn MA, et al.: Frequent hypoxia and apnea after sedation with midazolam and fentanyl, *Anesthesiology* 73(5):826–830, 1990.
42. Miller DR, Blew PG, Martineau RJ: Midazolam and awareness with recall during total intravenous anesthesia, *Can J Anaesth* 43(9):946–953, 1996.
43. Miller RI, Bullard DE, Patrissi GA: Duration of amnesia associated with midazolam/fentanyl intravenous administration, *J Oral Maxillofac Surg* 47(2):155–158, 1989.

44. Brosius KK, Bannister CF: Midazolam premedication in children: a comparison of two dosage formulations on sedation score and plasma levels, *Anesth Analg* 96(2):392–395, 2003.
45. Khalil SN, Vije HN, Kee SS, et al.: A paediatric trial comparing midazolam/Syrplata mixture with premixed midazolam syrup (Roche), *Paediatr Anaesth* 13(3):205–209, 2003.
46. Heniff MS, Moore GP, Trout A, et al.: Comparison of routes of flumazenil administration to reverse midazolam-induced respiratory depression in a canine model, *Acad Emerg Med* 4(12):1115–1118, 1997.
47. Hosaka K, Jackson D, Pickrell JE, et al.: Flumazenil reversal of sublingual triazolam: a randomized controlled clinical trial, *J Am Dent Assoc* 140(5):559–566, 2009.
48. Lovinger DM, Zimmerman SA, Levitin MA, et al.: Trichloroethanol potentiates synaptic transmission mediated by gamma aminobutyric acid receptors in hippocampal neurons, *J Pharmacol Exp* 264(3):1079–1103, 1993.
49. Bowyer K, Glasser SP: Chloral hydrate overdose and cardiac arrhythmias, *Chest* 77(2):232–235, 1980.
50. Brown AM, Cade JF: Cardiac arrhythmias after chloral hydrate overdose, *Med J Aust* 1(1):28–29, 1980.
51. Gerretsen M, de Groot G, van Heijst AN, et al.: Chloral hydrate poisoning: its mechanism and therapy, *Vet Hum Toxicol* 21:53–56, 1979.
52. Use of nitrous oxide for pediatric dental patients, *Am Acad Pediatr Dent* 40(6):281–286. [www.aapd.org/media/Policies\\_Guidelines/G\\_Nitro.us.pdf](http://www.aapd.org/media/Policies_Guidelines/G_Nitro.us.pdf). Last accessed June 3, 2019.
53. Chrysikopoulou A, Matheson P, Milles M, et al.: Effectiveness of two nitrous oxide scavenging nasal hoods during routine pediatric dental treatment, *Pediatr Dent* 28(3):242–247, 2006.
54. Allen GD, Ricks CS, Jorgensen NB: The efficacy of the laryngeal reflex in conscious sedation, *J Am Dent Assoc* 94(5):901–903, 1977.
55. Coté CJ, Notterman DA, Karl HW, et al.: Adverse sedation events in pediatrics: analysis of medications used for sedation, *Pediatrics* 106(4):633–644, 2000.
56. American Dental Association: *Guidelines for the use of sedation and general anesthesia by dentists*. [www.ada.org](http://www.ada.org). Last accessed June 5, 2019.
57. Townsend JA, Martin A, Hagan JL, et al.: The use of local anesthesia during dental rehabilitation: a survey of AAPD members, *Pediatr Dent* 35(5):422–425, 2013.
58. Yagiela JA: Local anesthetics, *Anesth Prog* 38(4–5):128–141, 1991.
59. Robb ND: Which is the most effective drug or method of sedation used for anxious children? What are the most effective techniques for the use of conscious sedation behavior management in paediatric dentistry? *Evid Based Dent* 6(3):71, 2005.
60. Lourenço-Matharu L, Ashley PF, Furness S: Sedation of children undergoing dental treatment, *Cochrane Database Syst Rev* 14(3):77–79, 2012.
61. Chowdhury J, Vargas KG: Comparison of chloral hydrate, meperidine and hydroxyzine to midazolam regimens for oral sedation of pediatric dental patients, *Pediatr Dent* 27(3):191–197, 2005.
62. Torres-Pérez J, Tapia-García I, Rosales-Berber MÁ: Comparison of three conscious sedation regimens for pediatric dental patients, *J Clin Pediatr Dent* 31(3):183–186, 2007.
63. Leelataweedwud P, Vann WF: Adverse events and outcomes of conscious sedation for pediatric patients: study of an oral sedation regimen, *J Am Dent Assoc* 132(11):1531–1539, 2001.
64. Litman RS, Kottra JA, Verga KA, et al.: Chloral hydrate sedation: the additive respiratory depressant effects of nitrous oxide, *Anesth Analg* 86(4):724–728, 1998.
65. Moore PA, Mickey EA, Hargreaves JA, et al.: Sedation in pediatric dentistry: a practical assessment procedure, *J Am Dent Assoc* 109(4):564–569, 1984.
66. Coté CJ, Karl HW, Notterman DA, et al.: Adverse sedation events in pediatrics: analysis of medications used for sedation, *Pediatrics* 106(4):633–642, 2000.
67. Hayden J: Chloral hydrate as a sedative in dentistry, *J Colo Dent Assoc* 61(3):3–4, 1982.
68. Sheroan MM, Dilley DC, Lucas WJ, et al.: A prospective study of 2 sedation regimens in children: chloral hydrate, meperidine and hydroxyzine versus midazolam, meperidine and hydroxyzine, *Anesth Prog* 53(3):83–90, 2006.
69. McKee KC, Nazif DM, Jackson MD, et al.: Dose response characteristics of meperidine in preschool children, *Pediatr Dent* 12(4):222–227, 1990.
70. Goodson JM, Moore PA: Life-threatening reactions following pedodontic sedations: an assessment of narcotic, local anesthetic and antiemetic drug interactions, *J Am Dent Assoc* 107(2):239–245, 1983.
71. Moore PA, Goodson JM: Risk appraisal of narcotic sedation for children, *Anesth Prog* 32(4):129–139, 1985.
72. Moore PA: Adverse drug interactions in dental practice: interactions associated with local anesthetics, sedatives and anxiolytics, *J Am Dent Assoc* 130(4):541–554, 1999.
73. Venham LL, Gaulin-Kremer E, Munster E, et al.: Interval rating scales for children's dental anxiety and uncooperative behavior, *Pediatr Dent* 2(3):195–202, 1980.
74. Frankl SN, Shiere FR, Fogels HR: Should the parent remain with the child in the dental operator? *J Dent Child* 29:150–163, 1962.
75. American Society of Anesthesiologists Task Force on Sedation and Analgesia by Non-Anesthesiologists: Practice guidelines for sedation and analgesia by non-anesthesiologists, *Anesthesiology* 96(4):1004–1017, 2002.
76. Beauchamp TL, Childress JF: *Principles of biomedical ethics*, ed 4, New York, 1994, New Oxford University Press.
77. Kovac AL: Management of postoperative nausea and vomiting in children, *Pediatr Drugs* 9(1):47–69, 2007.
78. American Academy of Pediatric Dentistry: Guidelines for monitoring and management of pediatric patients during and after sedation for diagnostic and therapeutic procedures, *Pediatr Dent* 40(6):287–316, 2018.
79. Coté CJ, Notterman DA, Karl HW, et al.: Adverse sedation events in pediatrics: a critical incident analysis of contributing factors, *Pediatrics* 105(4):805–814, 2000.
80. American Association of Oral and Maxillofacial Surgeons: [www.aao.ms.org/president/11202013.html](http://www.aao.ms.org/president/11202013.html). Last accessed June 3, 2019.

### Suggested Readings

Nickalls RW, Mapleson WW: Age-related iso-MAC charts for isoflurane, sevoflurane and desflurane in man, *Br J Anaesth* 91(2):170–174, 2003.

## 19

# Hospital Dental Services for Children and the Use of General Anesthesia

JAMES E. JONES, JOHN D. EMHARDT and JUAN F. YEPES

## CHAPTER OUTLINE

**Obtaining Hospital Staff Privileges**  
**Indications for General Anesthesia in the Treatment of Children**  
**Psychological Effects of Hospitalization on Children**  
**Outpatient Versus Inpatient Surgery**  
**Medical History and Physical Examination**  
**Admission to the Hospital**  
**Operating Room Protocol**  
**Inhaled General Anesthesia and Conduct of Anesthesia**

**Neurotoxicity of Anesthetic Agents in Young Children**  
**Anesthetic Preparation of the Child**  
**Time-Out Protocol**  
**Perioral Cleaning, Draping, and Placement of Pharyngeal Throat Pack**  
**Restorative Dentistry in the Operating Room**  
**Completion of the Procedure**  
**End Time-Out Protocol**  
**Postanesthesia Care Unit**  
**Postoperative Care**

Dentists can provide essential services to patients within an operating room setting in addition to providing consultative and emergency services. Staff membership is necessary. National commissions such as the Joint Commission (formerly the Joint Commission on Accreditation of Healthcare Organizations) issue the standards for hospital governance for all hospital services. Ambulatory surgery centers (ASCs) also offer operating room facilities and may be accredited by organizations focused solely on outpatient care, such as the Accreditation Association for Ambulatory Health Care (AAAHC). Staff membership is required as well.

In recent years, with the increasing number of general practice residencies and postdoctoral specialty programs, the qualified dentist finds that staff privileges in a facility offering operating room resources are a necessity. Active involvement in hospital dentistry has added a rewarding component to the practices of many dentists. Many hospitals have incorporated not only dental specialties but also general dental services, providing a comprehensive health care facility in which to serve the community.

## Obtaining Hospital Staff Privileges

Requirements for obtaining hospital staff privileges vary among institutions. The dentist must fulfill the following three basic requirements to become a hospital staff member:

1. The applicant must have graduated from an accredited dental school.

2. The applicant must be licensed to practice dentistry in the state in which the facility is located.
3. The applicant must have high moral and ethical standards.

Additional requirements may have to be met to obtain staff privileges. Many hospitals ask staff members to sign a “Delineation of Privileges” form indicating the procedures that staff members are qualified to perform and that are accepted by the governing body of the hospital. The applicant must show proof of professional liability insurance, and, in many hospitals, specialty board certification is required.

In a children’s hospital, dentists might be required to have adequate advanced training to treat and manage children in the hospital. The requirements may include a dental residency of 1–4 years in a teaching hospital in which the dentist (1) gains experience in recording and evaluating the medical history and current medical status of children; (2) receives instruction in physical examination techniques and in recognition of conditions that may influence dental treatment decisions; (3) learns to initiate appropriate medical consultations when a problem arises during treatment; (4) learns the procedure for admitting, monitoring, and discharging children; and (5) develops proficiency in operating room protocol. A rotation in which the dental resident was actively involved in administering general anesthesia to children is highly desirable. Current certification in basic cardiopulmonary resuscitation should be maintained by all members of the hospital’s professional staff, including dentists. It is highly desirable to have participated in a pediatric advanced life support (PALS) course as well. If the dentist is



a specialist in pediatric dentistry and is applying for operating room privileges, board certification with the American Board of Pediatric Dentistry may, over a defined period, be required for final approval.

As active members of the hospital staff, dentists should be aware of the hospital's bylaws, rules, regulations, and meetings. A copy of the bylaws should be obtained for easy reference. Fully understanding the responsibilities of staff membership will enable dentists to treat their patients within the established protocol of the institution. Full participation in the active staff includes willing participation in necessary committee work, such as credentialing or operations committees, so that the pediatric dentist will be well informed as to the needs and expectations of his/her colleagues. Most important, dentists should endeavor to provide the highest quality of care within the specialty area for which they are trained. The American Academy of Pediatric Dentistry encourages the participation of pediatric dentistry practitioners on hospital medical-dental staffs, recognizes the American Dental Association as a corporate member of the Joint Commission, and encourages hospital member pediatric dentists to maintain strict adherence to the rules and regulations of the policies of the hospital medical staff.

## Indications for General Anesthesia in the Treatment of Children

The use of general anesthesia for dental care in children is sometimes necessary for safe, efficient, and effective care. Depending on the patient, this will be done in an ambulatory care setting or inpatient hospital setting. It should be only one component of the dentist's overall treatment regimen. Oral hygiene and preventive care must be implemented at the onset of treatment with parents/guardians and patients in order to eliminate the cause of the dental problem.

The safety of the patient and practitioner, as well as the need to diagnose and treat, must justify the use of general anesthesia. All available management techniques, including acceptable restraints and sedation, should be considered before the decision is made to use a general anesthetic. Patient restraints should be used only after consideration of the possibility for psychological trauma. In the event that conscious sedation is necessary, a qualified and credentialed sedation team must be utilized. Parental or guardian written consent must be obtained before administering general anesthesia. Documentation regarding dental treatment needs, unmanageability in the dental setting, and contributory medical problems must be included in the patient's hospital record. Records must be clearly written so others are able to read and understand them. The introduction of the electronic medical record has improved the issue of legibility of written notes; however, the simple retrieval of pertinent medical information or the writing of required orders may be more difficult with such a system. The practitioner must be able to appropriately utilize the medical record system of the institution. Review organizations examine dental admissions for proper documentation in the hospital chart for insurance payment and quality assurance purposes.

Patients for whom general anesthesia has been the management technique of choice include the following:

1. Patients unable to cooperate due to a lack of psychological or emotional maturity and/or those who have a physical, mental, or medically compromising disability that precludes conscious sedation.
2. Patients with dental restorative or surgical needs for whom local anesthesia is ineffective because of acute infection, anatomic variations, or allergy.
3. The extremely uncooperative, fearful, anxious, physically resistant, or uncommunicative child or adolescent with substantial dental needs for whom there is no expectation that the behavior will soon improve.
4. Patients who have sustained extensive orofacial or dental trauma and/or require significant surgical procedures.
5. Patients requiring immediate, extensive comprehensive oral or dental needs.
6. Patients requiring dental care for whom the use of general anesthesia may protect the developing psyche and/or reduce medical risks.

If the benefits of the procedure outweigh the risk of anesthesia, there are few if any contraindications to general anesthesia. However, when a concern about the medical condition exists, consultation with an anesthesiologist would be desirable. Patients for whom general anesthesia is usually contraindicated include those with a medical contraindication to general anesthesia and healthy and cooperative patients with minimal dental needs.

## Psychological Effects of Hospitalization on Children

Hospitalization is a frequent source of anxiety for children. According to King and Nielson,<sup>1</sup> 20%–50% of children demonstrate some degree of behavioral change after hospitalization. Separation of the child from the parent appears to be a significant factor in post hospitalization anxiety, although other causes are also documented. Allowing the parent to stay with the child during the hospitalization, and especially to be present when the child leaves for and returns from surgery, can reduce anxiety for the child and parent alike.

According to Camm et al.,<sup>2</sup> postoperative behavioral changes reported by mothers of a limited sample of children who received dental treatment with general anesthesia in a hospital were similar to those observed in children who received treatment under conscious sedation in a dental clinic. Mothers of children receiving dental treatment with general anesthesia in a hospital setting were found to experience more stress during the procedure. Ways to decrease these stresses include providing a prior tour of the operating room facility, informing the parents of the status of the child during the procedure, and letting them know that “everything is all right.” (Video 19.1)

**Video 19.1** Child Life Specialists: non-pharmacologic pre-operative behavior guidance of children in preparation for general anesthesia

About 75% of the children receiving general anesthesia exhibited some type of behavioral change. Positive changes

included less fuss about eating, fewer temper tantrums, and better appetite. Negative changes included biting the fingernails, becoming upset when left alone, being more cautious or avoiding new things, staying with the parent more, needing more attention, and being afraid of the dark. Ways to minimize negative changes include: (1) involving the child in the operating room tour, (2) allowing the child to bring along a favorite doll or toy, (3) giving preinduction sedation, (4) providing a nonthreatening environment, (5) giving post-procedural sedation as needed, and (6) allowing parents to rejoin their children as early as possible in the recovery area.

Some centers allow parents to be present at the induction of anesthesia. This decision is at the discretion of the anesthesiologist.

Usually anesthesia is induced when the child breathes anesthetic gases such as sevoflurane and/or nitrous oxide through a face mask. As the child becomes anesthetized, the parent is encouraged to provide calm, loving reassurance until the child is unaware of the parent's presence. For this technique to be effectively utilized, it is mandatory that the operating room team be comfortable with the parent's presence and prepared to care for the parent if he/she were to become distressed. It is also critical that the parent be educated as to what to expect as the child is anesthetized, including the possibility that the child may not readily accept the mask, that the child's breathing may become obstructed or "snory," or that the child's eyes may display abnormal movements as he/she enters the excitement stage of anesthesia. Parental presence can be especially helpful with the child with autism spectrum disorder or with a child who refuses or is resistant to oral sedation such as midazolam.

Another similar technique utilizes certified child life therapists skilled in the application of distraction techniques and play therapy. These personnel must also be educated as to their responsibilities during the induction of anesthesia. Utilization of parental presence or child life therapists can markedly reduce the requirement for oral sedation and thus enhance facility throughput by avoiding any delays in medication administration, emergence from anesthesia, or postoperative observation time required to meet discharge criteria.

To limit the severity and duration of psychological disturbances, the dentist should strive to reduce parental apprehension concerning the operative procedure. Because children often sense apprehension in their parents, effectively reducing the parents' anxiety will put the child more at ease. Thoroughly explaining the procedure, describing the normal postanesthetic side effects, and familiarizing the child and parents with the hospital can reduce postoperative anxiety.

Peretz et al.<sup>3</sup> concluded that children treated for early childhood caries (ECC) under general anesthesia or under conscious sedation at a very young age behaved similarly or better in a follow-up examination approximately 14 months after treatment than at their pretreatment visit, as measured by the Frankl scale and by the "sitting pattern." Fuhrer et al.<sup>4</sup> found that children were more likely to exhibit positive behavior at their 6-month recall appointment following dental treatment for childhood caries under general anesthesia compared with those treated under oral conscious sedation.

## Outpatient Versus Inpatient Surgery

During the past 30 years, the popularity of outpatient anesthesia and surgery has continued to increase. Currently, more than 70% of all pediatric surgical and diagnostic procedures are performed on an outpatient basis. The criteria for and advantages of ambulatory general anesthesia procedures are well recognized. The increasing cost of inpatient hospital care, advances in anesthetic management, and quality assessment of patient care have led to changes in preoperative and postoperative management of many surgical procedures performed under general anesthesia that were previously assumed to be possible only on an inpatient basis. Ambulatory care is more expeditious, better tolerated by both family and hospital teams, and less traumatic for the patient. Development of freestanding ambulatory care surgical centers (i.e., same-day surgery centers) and hospital ambulatory surgical care areas has decreased health care costs for consumers and third-party providers. The advances in perioperative anesthesia care are related to the wider availability of more highly qualified anesthesia care providers (board-certified anesthesiologists with pediatric subspecialty training) and the availability of modern, safer, short-acting anesthetic and adjuvant drugs and monitoring equipment. Several studies have reported a significant decrease in anesthesia-related morbidity and mortality in children over the past two decades.

Good patient selection is an important criterion for a successful outpatient surgery program. A young child or adolescent who requires a general anesthetic and is free of any significant medical disorders (i.e., categorized as class I or II on the American Society of Anesthesiologists [ASA] physical status classification; Box 18.4) can be considered as a candidate for outpatient surgery. Certain patients with well-controlled chronic systemic diseases, such as asthma, diabetes, and congenital heart disease, can also be considered for outpatient anesthesia following prior consultation with an anesthesiologist.

When outpatient surgery is planned, the child undergoes a complete preoperative evaluation, including a comprehensive medical history and physical examination, anesthesia assessment, and limited hematologic evaluation. Many medical facilities allow this preadmission preparation to be performed outside of the medical outpatient treatment facility. Biery et al.<sup>5</sup> suggest that routine laboratory tests, such as urinalysis and complete blood count with indices and electrolyte levels, are neither cost-effective nor necessary for patients in whom the prior complete medical history and physical examination were unremarkable. Current recommendations for preoperative laboratory examination are indicated only if required for a patient's comorbidities. ASA no longer suggests required preoperative laboratory examination in a patient without medical comorbidity.

As an outpatient, the child should be brought by the parents to the hospital at least 1½ hours before the dental surgery. The nursing staff will verify that all preoperative instructions have been followed and that the appropriate laboratory tests have been performed. Several hours after the procedure is completed, the patient is released to the

parent or guardian. Postoperative instructions are given, and a follow-up appointment is scheduled.

The dentist will be more responsible for team communication, physical assessment, management, and postoperative evaluation for outpatient procedures performed under general anesthesia than for inpatient procedures. To qualify for treatment, pediatric outpatient general anesthesia patients must have reliable parents or guardians. For example, the parents must have transportation available to return the child to the hospital in case postoperative complications develop at home.

In some cases, the management of the child in an outpatient facility will be precluded by the patient's comorbidities. Accreditation guidelines from AAAHC do not permit scheduling a case in an outpatient center when it is certain that the patient will require postoperative observation in an outpatient facility. Some outpatient facilities have resources permitting a prolonged observation period such as 23 hours, but many do not. In this case, the procedure would best be scheduled in a facility with the resources for postoperative inpatient hospitalization. The child should be treated as an inpatient if a medical condition exists that requires close follow-up, if the child lives outside the general area of the hospital, or if the parents demonstrate questionable ability to comply with preoperative or postoperative instructions. In many instances, patients with medical or developmental disabilities and/or with multiple problems requiring lengthy dental treatment are not good candidates for ambulatory care with general anesthesia. However, even some of these patients can be managed in an ambulatory setting when they are properly assessed and when no postoperative complications are anticipated. Conditions such as those listed in [Table 19.1](#) commonly preclude an outpatient procedure.

## Medical History and Physical Examination

Once the decision has been made that a general anesthetic would be preferable for a pediatric patient, the dentist should evaluate the child's medical history, the current medical status, and the possibility of complications resulting from the procedure. This process is discussed in [Chapter 18](#) and the patient-classification categories are shown in [Box 18.4](#). The parents should be told of any potential complications, and their informed consent must be obtained ([Fig. 19.1](#)).

Intraoperative medical complications of dental patients with and without disabilities undergoing general anesthesia have been reported at 0% to 1.4%. In a survey of 200 pediatric dental general anesthesia cases, Enger and Mourino<sup>6</sup> indicated that the most common postoperative complications following general anesthesia in children younger than 5 years were vomiting, fever, and sore throat. Treatment consisted of antiemetic medications for nausea with vomiting, ice chips for sore throat, and acetaminophen (Tylenol) for fever. Common minor reversible complications include pain, swelling, bleeding, separation anxiety, sleepiness, and iatrogenic trauma (such as minor abrasion, burn, or laceration). A majority of these will resolve within 2 weeks after the procedure. Seto and Lynch<sup>7</sup> found that no significant long-term complications resulting from anesthesia or

**TABLE 19.1** Comorbidities Possibly Necessitating Postoperative Hospital Observation

### RESPIRATORY:

Airway  
 History of difficult intubation or mask management  
 Craniofacial abnormality  
 Hypoplastic or retrognathic mandible  
 Obstructive Sleep Apnea  
 Asthma, poorly controlled  
 Mediastinal lymphoma or mass

### CARDIAC:

Congenital heart disease, especially those with single ventricle physiology  
 Cardiac transplant  
 Congestive heart failure  
 Pacemaker or implantable defibrillator  
 Reduced ejection fraction on echocardiography  
 Stenotic valve lesions (e.g., aortic stenosis)

### NEUROLOGIC:

Chronic neuromuscular disease  
 Seizure disorder

### METABOLIC:

Diabetes, poorly controlled  
 Inborn errors of metabolism  
 Malignant hyperthermia  
 Mitochondrial myopathy  
 Morbid obesity

### COAGULOPATHY:

Hemophilia  
 von Willebrand's  
 Medication- or herbal therapy-induced (aspirin is not a contraindication)

### CANCER:

ASA status greater than 3 (a patient with a severe systemic disease)

Patients with cardiac lesions repaired previously and/or appropriately managed by a cardiologist may still be candidates for outpatient management. These patients' cases should be discussed with an anesthesiologist.

operative procedures were observed in 100 patients with and without disabilities.

The Joint Commission requires that all patients admitted to a hospital or treated under general anesthesia as outpatients have a physical examination performed by a physician or qualified dentist. The child's physician must therefore be consulted for the completion of a comprehensive medical history and physical examination ([Box 19.1](#)). If the physician is not a member of the hospital staff, a staff physician should complete the medical history and physical examination before the child is admitted. The dentist should perform a thorough intraoral examination and submit a record of the findings together with a summary of the child's dental history and the reason for admission ([Box 19.2](#)). The hospital must be notified to reserve an appropriate surgical suite and a bed for the child. Furthermore, 2 weeks prior to admission or an outpatient dental surgery appointment, a letter containing general instructions concerning the procedure, results of the dental examination, and pertinent dates and times should be mailed to the parents.

In the event that a child is expected to be admitted for hospital observation, it may be inappropriate to utilize an ASC. AAAHC requires that a patient be cared for in the ASC only if it is intended that the patient will be discharged to



102869  
CH-7841 (SEP 13)  
Effective 2012

## ROC SURGERY, LLC

# CONSENT FOR PROCEDURE

By signing this form, I agree to the procedure(s) listed here:

Any necessary dental treatment under general anesthesia including: examination, radiographs, prophylaxis, periodontal therapy, restorations, extractions, pulpal therapy, space maintainers, fluoride treatment, and photographs

to be done by: University Pediatric Dentistry Associates, member of the ROC Surgery, LLC medical staff and other appropriate licensed personnel.

The exceptions to my consent are as follows: NONE

From this point on all procedures will be called the "procedure;" and the persons performing the procedure will be called "treating practitioner."

I understand and agree to the following items:

- Residents and students may help with my care.
- Medical staff other than the treating practitioner may do part of my procedure.
- Health care industry representatives may be in the room to consult during my procedure.
- The treating practitioner may do other procedures not listed here if they are needed.
- An unexpected outcome may occur. An unexpected outcome does not mean care was not appropriate.
- I may be given local anesthetics or sedation that the Treating Practitioner believes appropriate. I have been told about the risks of these medications. These include injury to my teeth, dentures, throat, mouth, surrounding structures, and death.
- Parts of my body taken out during surgery can be thrown away or used for research so long as I am not identified.
- Pictures may be taken and used for teaching as long as I am not identified.
- I have talked with the Treating Practitioner about the procedure and why I need it, the expected outcome and risks, and the chances of success. We have also discussed other possible treatment(s) including the risks and benefits, and what could happen if I do not have the procedure. I have been told additional choices, including not having the procedure, other procedures, medicine, and therapy.
- I have been told about the risk of the procedure, which include but are not limited to bleeding, infection, injury, scarring, and/or damage to parts of my body, and death. Other risks:

Common: sore throat, nausea, vomiting, fever, pain, bleeding, swelling, separation anxiety, sleepiness, iatrogenic trauma  
(minor abrasion, laceration, burn)

Uncommon: aspiration/foreign body, idiosyncratic drug reaction, dental trauma

Rare: heart and lung complications, cardiac depression and arrest

Patient/Guardian Signature (or Surrogate, if Incapacitated/minor)

Patient/Guardian Name (please print):

Date: \_\_\_\_\_ Time: \_\_\_\_\_

If signed by Surrogate: Relationship to Patient:

Healthcare Professional Witness

Witness Signature:

Witness Name (please print):

Date: \_\_\_\_\_ Time: \_\_\_\_\_

### TREATING PRACTITIONER USE ONLY

I have discussed with the patient the nature of the proposed care, treatment, services, medications, interventions, or procedures; the potential benefits, risks, or side effects, including potential problems related to recuperation; the likelihood of achieving care, treatment, and service goals; the reasonable alternatives to the proposed care, treatment, and service; the relevant risks, benefits and side effects related to alternatives, including the possible results of not receiving care, treatment and services; and when indicated, any limitations on the confidentiality of information learned from or about the patient.

Signed:

\_\_\_\_\_

Date: \_\_\_\_\_ Time: \_\_\_\_\_



**CONSENT FOR PROCEDURE**  
(Page 1 of 1)

Medical Record Copy

**M-1**

Fig. 19.1 Sample of form similar to one that may be used to obtain parental consent for dental treatment of a child under general anesthesia. (Courtesy of Indiana University Health, Riley Outpatient Center Surgery, LLC.)

## SIGNATURES REQUIRED

1. If the patient is an adult (age 18 or over) – signature of patient; or, if the patient is incompetent, the guardian's signature.
2. Minor patient (under age 18) – if emancipated (providing own support and living apart from the parents) patient's signature.

If married, signatures of patient and spouse are required.

Otherwise, signature of parent or guardian is required.

3. In an emergency threatening the life or well-being of the patient, and if signatures as required above are not available, there should be an entry in the chart documenting the emergency nature of the procedure and the need for prompt action, attested by the signatures of two physicians. Also, the signature of the closest adult relative should be obtained, if available.

Fig. 19.1—Cont'd

### Box 19.1 Components of the pediatric medical history and physical examination for admission to the hospital

#### A Pediatric History

1. Identification: age, gender, racial-ethnic profile
2. Informant and estimate of reliability
3. Problem leading to admittance
4. History of present illness: date of onset, chronologic description of illness, presence or absence of previous similar episodes, treatment given prior to admittance
5. Medical survey
  - a. Immunization against diphtheria, pertussis, tetanus, polio, measles, mumps, rubella
  - b. Previous hospitalizations, operations, major illnesses, or injuries
  - c. Allergies, including allergies to food and drugs
  - d. Dietary history (younger than 2 years of age)
  - e. Current medications
6. Developmental status
  - a. Infants younger than 2 years: statement regarding motor and language development
  - b. Preschool children: general statement regarding development
  - c. Children in school: statement regarding school performance
7. Family history
  - a. Coagulation abnormalities
  - b. Anesthesia complications

#### B Physical Examination

1. Vital signs: temperature, pulse, respiration, blood pressure, oxygen saturation
2. Measurements: weight, height, or length
3. General observations: nutrition, color, distress
4. Head: size and shape, description of fontanel if present
5. Eyes: pupils, extraocular movements
6. Ears: position and shape
7. Airway: size of mouth and degree of opening, mobility of cervical spine and temporomandibular joint, size of mandible, Mallampati score
8. Nose: patency, secretions
9. Mouth: teeth, tongue, pharynx, and tonsils
10. Neck: masses, lymphadenopathy, range of motion
11. Lungs: auscultation
12. Cardiovascular system: heart sounds, rate, rhythm, murmurs, pulses
13. Abdomen: masses, distention
14. Genitalia: male testes, female introitus
15. Skin: rashes, bruises, lacerations
16. Lymph nodes
17. Skeleton: joints, spine, history of fractures
18. Nervous system: state of consciousness, gait (if walking)
19. Summary list of problems on tentative diagnosis

### Box 19.2 Components of the dental history and intraoral examination to be completed before hospitalization

1. Past dental history
2. Head and neck physical examination
  - a. General
  - b. Head
  - c. Neck
  - d. Face
  - e. Lateral facial profile
3. Intraoral examination
  - a. Lips
  - b. Tongue
  - c. Floor of mouth
  - d. Buccal mucosa
  - e. Hard and soft palates
  - f. Oropharynx
  - g. Periodontium
4. Teeth
  - a. Caries
  - b. Eruption sequence
  - c. Occlusion molar, cuspid, overbite, overjet, and midline
5. Oral habits
6. Behavior
7. Recommendations

home from the center. If hospital admission following a procedure is anticipated or considered likely, that patient should be cared for in a facility with the resources available for prolonged postoperative observation.

A dental procedure may be canceled before the administration of general anesthesia due to patient illness; productive cough, rhinitis, or wheezing; failure to comply with preoperative instructions such as abstention from eating or drinking; or risks related to coexisting diseases. Issues identified on preoperative contact with parents may require a general anesthetic case to be rescheduled. The risks of morbidity from the anesthesia must be weighed against the risk of postponement.

## Admission to the Hospital

Some patients presenting for elective surgery are brought in on the day of surgery as an "AM admit." In this instance, the child may come to the hospital the same day as the operative procedure and stay postoperatively until the next morning

<b>Outpatient NPO Guidelines*</b>
<b>Over one year of age</b>
<ul style="list-style-type: none"> <li>• Clear liquids permitted until 3 hours prior to scheduled surgery</li> </ul>
<ul style="list-style-type: none"> <li>• Breast milk until 4 hours prior to surgery</li> </ul>
<ul style="list-style-type: none"> <li>• Formula, fortified breast milk, and solid food stopped at midnight**</li> </ul> <p style="text-align: center;">**if the procedure is not to be done until after noon, dry cereal or toast and juice permitted until 0600</p>
<ul style="list-style-type: none"> <li>• Clear liquids include water, apple juice, Gatorade, and Sprite. No Jello or broth after midnight.</li> </ul>
<ul style="list-style-type: none"> <li>• A clear recipe specifying what foods or liquids are acceptable can minimize confusion on the day of the procedure.</li> </ul>
<p>*These guidelines are utilized by the Riley Outpatient Center in Indianapolis, Indiana. These are based on factors unique to the surgery center, permit some leeway in the case of changes in the schedule, and are consistent with recommendations of the American Society of Anesthesiologists (Anesthesiology 2011; 114:495-511).</p>

**Fig. 19.2** Nothing by mouth (*nil per os* [NPO]), times according to age. (Courtesy of Indiana University Health, Riley Outpatient Center Surgery, LLC.)

or longer. The parents must complete the necessary forms for admission to the hospital. The dentist must write the child's admission orders, which give the nursing staff the preliminary information needed and outline the basic care procedures for the child. Modern hospital practice includes consultation and discussion with the hospitalist regarding the reasons for admission and the potential postoperative concerns. This conversation should include the dentist, anesthesiologist, and hospitalist and/or team who will be caring for the child postoperatively. The nursing staff will explain standard hospital procedures to the parents and make any recommendations needed to foster a comfortable experience for the patient.

During this time, the child will be visited by the anesthesiologist involved in the anticipated procedure. The anesthesiologist will assess the child's present state of health and review the past and present hospital records, focusing on prior exposures to general anesthetics and any complications that may have occurred. The anesthesiologist will explain the procedures involved during his or her part of the procedure and answer any questions that the child or parent might have. The decision regarding the length of time the child should refrain from consuming solid foods and liquids before the procedure is also determined by the anesthesiologist; time may vary for younger patients to prevent hypoglycemia (Fig. 19.2).

A simple way to remember standard fasting orders is the 2-4-6-8 rule. This rule describes allowable ingestion of clear liquids until 2 hours prior to anesthesia, breast milk until 4 hours prior, formula until 6 hours prior, a light, nonfat-containing meal until 6 hours prior (such as toast and a clear liquid), and no solid or fatty food until 8 hours prior to the procedure. Some centers may modify these guidelines to not make food or liquid ingestion potentially preclude a case going earlier because of inadequate fasting. The guidelines from the ASA are available at *Anesthesiology*, 2017.

Prior to surgery, the dentist can answer any questions the parents or the child might have. The dentist should also evaluate the preoperative laboratory data so that appropriate consultations can be initiated if any abnormal values are found. The dentist should record an admitting note in the medical chart to provide the supporting staff with a concise record of the child's medical history, current medical and oral status, diagnosis, and proposed treatment (Box 19.3). With the onset of

### Box 19.3 Components of dentist's admitting note on the medical history-physical: progress note form

1. Name, age, gender, race, chief complaint, and rationale for admission
2. History of the present illness
3. Past medical history
4. Present medications (list all with dosages and times given)
5. Results of current laboratory tests
6. Documentation of informed consent and physical examination
7. Impression of case (intraoral examination, diagnosis, and prognosis)
8. Plan for treatment
9. Dentist's signature

paperless charting, abbreviations are not as common when information is recorded in the medical chart. Modern hospital care discourages the use of abbreviations because of the risk of ambiguity. Box 19.4 provides a list of common abbreviations one may encounter with the medical chart review. The dentist and the staff should be in the operating room area 30 minutes before the dental procedure.

## Operating Room Protocol

All persons involved in the care of patients in the operating room must follow Occupational Safety and Health Administration guidelines. They must wear appropriate attire designed to prevent contamination of the surgical suite, hallways, and recovery room. This generally consists of a shirt, pants or skirt, and coverings for the face, head, and feet. A hood is used to cover all unshaven facial hair. Eyeglasses, goggles, or a face shield must be used to protect the surgeon's eyes, and a mask must cover the mouth and nose. Hand hygiene measures must be followed, including alcohol-based hand rubbing before and after any patient contact.

The dentist and staff should be familiar with the standard scrub technique for sterile procedures. Neither the medical nor the dental literature documents that a sterile



### Box 19.4 Abbreviations Commonly Used in the Hospital

<b>a.c.:</b> Before meals ( <i>ante cibos</i> )	<b>neg:</b> Negative
<b>ad lib.:</b> At liberty or at pleasure	<b>N<sub>2</sub>O:</b> Nitrous oxide
<b>anom:</b> Anomalies	<b>NPO:</b> Nothing by mouth ( <i>nil per os</i> )
<b>AP:</b> Anteroposterior	<b>NSA:</b> No significant abnormality
<b>aq.:</b> Aqueous, water	<b>n/v:</b> Nausea and vomiting
<b>BP:</b> Blood pressure	<b>op:</b> Operation
<b>BRP:</b> Bathroom privileges	<b>OPD:</b> Outpatient department
<b>BUN:</b> Blood urea nitrogen	<b>OR:</b> Operating room
<b>bx:</b> Biopsy	<b>PA:</b> Posteroanterior
<b>c:</b> With (cum)	<b>p.c.:</b> After meals ( <i>post cibos</i> )
<b>C:</b> Celsius (formerly centigrade)	<b>PE (or Px):</b> Physical examination
<b>Caps.:</b> Capsule	<b>Ped:</b> Pediatric
<b>CBC:</b> Complete blood count	<b>PH:</b> Past history
<b>CC:</b> Chief complaint	<b>PMH:</b> Past medical history
<b>CNS:</b> Central nervous system	<b>p.o.:</b> By mouth ( <i>per os</i> )
<b>cong:</b> Congenital	<b>postop:</b> Postoperative
<b>CP:</b> Cerebral palsy	<b>preop:</b> Preoperative
<b>CV:</b> Cardiovascular	<b>prep:</b> Prepare
<b>d/c:</b> Discontinue	<b>prn:</b> As required ( <i>pro re nata</i> )
<b>Dent:</b> Dental	<b>pro Time:</b> Prothrombin time
<b>Diff:</b> Differential blood count	<b>Pt:</b> Patient
<b>disch:</b> Discharge	<b>PT:</b> Physical therapy
<b>D5W:</b> 5% dextrose in water	<b>PTT:</b> Partial thromboplastin time
<b>Dx:</b> Diagnosis	<b>Px:</b> Physical examination
<b>ECG:</b> Electrocardiogram (also EKG)	<b>q:</b> Every ( <i>quaque</i> )
<b>Elix:</b> Elixir	<b>qs:</b> Sufficient quantity ( <i>quantum sufficit</i> )
<b>ER:</b> Emergency room	<b>R/O:</b> Rule out
<b>FHx:</b> Family history	<b>ROS:</b> Review of symptoms
<b>FUO:</b> Fever of unknown origin	<b>RR:</b> Respiratory rate
<b>Fx:</b> Fracture	<b>RR:</b> Recovery room
<b>GA:</b> General anesthesia (or gen an)	<b>RSR:</b> Regular sinus rhythm
<b>ging:</b> Gingiva	<b>Rx:</b> treatment (or prescription)
<b>Hr:</b> Hour	<b>s:</b> Without ( <i>sine</i> )
<b>Hct:</b> Hematocrit	<b>SBE:</b> Subacute bacterial endocarditis
<b>HEENT:</b> Head, eyes, ears, nose, and throat	<b>Subq:</b> Subcutaneous
<b>Hg:</b> Mercury	<b>SH:</b> Social history
<b>Hx:</b> History	<b>Hep:</b> Hepatitis
<b>HPI:</b> History of present illness	<b>S/P:</b> Status post
<b>h.s.:</b> Just before sleep ( <i>hora somni</i> )	<b>Stat:</b> At once ( <i>statim</i> )
<b>I&amp;D:</b> Incision and drainage	<b>rect:</b> Rectal
<b>IM:</b> Intramuscular	<b>surg:</b> Surgery
<b>I&amp;O:</b> Intake and output	<b>Sx:</b> Signs and symptoms
<b>IV:</b> Intravenous	<b>tbsp:</b> Tablespoon
<b>kg:</b> Kilogram	<b>TPR:</b> Temperature, pulse, and respiration
<b>Mand:</b> Mandible	<b>Tx:</b> Treatment
<b>Max:</b> Maxilla	<b>UA:</b> Urinalysis
<b>M:</b> Molar, in moles	<b>WBC:</b> White blood count
<b>MCH:</b> Mean corpuscular hemoglobin	<b>WD:</b> Well developed
<b>MCHC:</b> Mean corpuscular hemoglobin concentration	<b>W/F:</b> White female
<b>MCV:</b> Mean corpuscular volume	<b>W/M:</b> White male
<b>Med:</b> Medication	<b>WN:</b> Well nourished
<b>norm:</b> Normal	<b>WNL:</b> Within normal limits
	<b>w/o:</b> Without

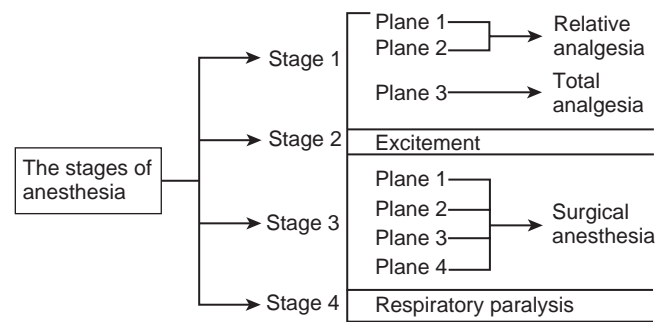
technique is more advantageous than a modified sterile, or clean, technique for restorative dental procedures. Therefore intraoral dental procedures are generally considered clean procedures rather than sterile procedures. However, the dentist should wear sterile gloves. A sterile gown is worn at the discretion of the dentist. The barrier technique should be followed to prevent cross-contamination between and among patients in the hospital.

## Inhaled General Anesthesia and Conduct of Anesthesia

The goals of general anesthesia are to produce unconsciousness, amnesia, and analgesia. While the precise mechanism is unknown, all anesthetic agents produce anesthesia by depressing specific areas of the brain. With the inhalational (or volatile) anesthetics, the magnitude of depression is

proportional to the partial pressure of the inhalation agents reaching specific sites in the central nervous system (CNS) after entering through the lungs and being distributed by the circulation to the tissues. The resulting physiologic signs of CNS depression produced by general anesthetic agents have been described by Guedel<sup>8</sup> in 1937 as stages of anesthesia with ether (Fig. 19.3).<sup>9</sup> Guedel's classification of the stages of anesthesia is largely of historical interest; however, the recognition of the signs of anesthesia utilizing respiratory rate and depth, eye movement, and airway patency are still commonly used to gauge the depth of anesthesia. In the treatment of the child with an inhalation induction, the stages do have some application. In the first stage of anesthesia, the patient is still conscious and responsive and may have some degree of analgesia. As the concentration of anesthetic increases, the patient enters stage 2. This is also commonly called the excitement stage. In this stage, the patient may exhibit nonpurposeful movement, disconjugate gaze, and upper airway obstruction. It is during this stage that the patient is at risk for laryngospasm as well as vomiting and aspiration. As the anesthetic deepens, the patient enters stage 3, or surgical anesthesia. Modern inhaled anesthetics are extremely potent. Induction of anesthesia occurs quickly, and passage through the stages of anesthesia is quite rapid.

The potency of an inhalational anesthetic is measured as the concentration of the agent required to inhibit response to a standard surgical stimulus. The potency is expressed in terms of the minimal alveolar concentration (MAC) value for the agent. The MAC of a given agent will abolish the response to stimulus in 50% of patients. MAC is useful in that it provides an estimate of the anesthetic requirement for each patient. Fine adjustment of anesthetic administration can then be made by monitoring the patient's physiologic responses such as heart rate, blood pressure, and respiratory rate. Commonly used inhalation anesthetics in children include nitrous oxide, isoflurane, desflurane, and sevoflurane. Each of these is useful in different applications. Nitrous oxide is the least soluble of the anesthetic gases, which promotes a rapid onset and offset of effect. It is odorless and least potent. The other modern anesthetic gases are nonflammable halogenated ethers. Desflurane is the least soluble volatile anesthetic. Its low solubility permits a rapid onset as well as offset of anesthesia; however, its utility is limited by its noxious odor. Sevoflurane is also quite insoluble but not as much as desflurane. It is widely used because its odor is non-noxious and it can be safely used to induce an anesthetic in an awake patient. Isoflurane is the oldest and most soluble of the halogenated anesthetic vapors in clinical use. It is more noxious than sevoflurane and has a slower onset and offset than other gases. Its utility is mainly in the area of maintenance of anesthesia. Of historical interest in the United States is halothane, the drug supplanted by sevoflurane for anesthetic induction in the awake child in the early to mid-1990s. It has a slightly different chemical structure and possesses a relatively non-noxious odor. It is much more soluble in blood, which produces a slower onset and offset of anesthesia. It is associated with a rare form of drug-induced hepatitis. It is also associated with a much greater incidence of cardiac arrhythmia than the other inhaled anesthetic vapors. While it is no longer used in the United States, it is still used in other parts of the world.



**Fig. 19.3** Stages of anesthesia observed with ether. (Adapted from Roberts GJ: Relative analgesia in clinical practice. In Coplans MD, Green RA, eds. *Anaesthesia and sedation in dentistry*, vol 12. Amsterdam: Elsevier Science; 1983.)

Another general anesthetic technique which might be employed in the event that an inhalational technique is contraindicated or not available is known as total intravenous anesthesia (TIVA). A condition that would require TIVA management is the patient with a history/family history of malignant hyperthermia. In a patient with malignant hyperthermia, it is vital to avoid any medications known to trigger the disease. These include the volatile anesthetics and succinylcholine. In this scenario, intravenous access is established and a combination of propofol, opioid, ketamine, and/or dexmedetomidine is infused at a rate to produce general anesthesia.

In children, to avoid the trauma of establishing intravenous access while awake, anesthesia is commonly induced by inhalation of a halogenated volatile anesthetic via a face mask. While many children are able to cooperate with this, some cannot. Various methods to aid in separation from the parent and willingness to breathe the anesthetic agents have been employed and have been previously described. These include distraction techniques, certified child life specialists, parental presence, or sedatives such as midazolam, dexmedetomidine, ketamine, and clonidine. Due to its non-noxious odor, sevoflurane is the most commonly used anesthetic vapor used for mask induction. As the anesthesia deepens, the child will progress through the stages of anesthesia. Following induction of anesthesia, intravenous access is established. For maintenance of anesthesia, sevoflurane, isoflurane, and desflurane are all acceptable.

Inhalational anesthesia is delivered via a specialized breathing circuit, which includes a vaporizer unique to each volatile anesthetic. The most common modern breathing system for the administration of inhaled anesthesia is known as a circle system. This system utilizes a CO<sub>2</sub> absorber to remove exhaled carbon dioxide, a pressure relief valve to limit the pressure in the system, a reservoir bag to permit assisted ventilation of the lungs, unidirectional valves to permit gas flow in a "circular" fashion, and fresh gas inflow to provide oxygen and anesthetic vapors. Oxygen and carrier gases are passed through the vaporizer, which produces the desired concentration of anesthetic vapor. One advantage of this type of system is the conservation of anesthetic gases by passing exhaled gas through the CO<sub>2</sub> absorbent system, which allows the scrubbed gas to be delivered back to the patient. Exhaled gases mingle with fresh gas and are rebreathed after all the carbon dioxide is removed by the

chemical absorber. Inhaled gases are humidified, and the reservoir bag or ventilator allows for assisted ventilation. Advantages of the system include reduced loss of body heat and water vapor, increased economy of flow, and decreased environmental contamination. Continuous addition of oxygen and a scavenging system to collect excess gases are required for this technique.

Another type of inhaled anesthesia administration system formerly used but not as much with modern inhaled anesthesia is known as a Mapleson D system. This system does not use CO<sub>2</sub> absorbent or unidirectional valves, and rebreathing is prevented by maintaining high fresh gas flow rates. A pressure relief valve to limit the pressure in the system and a reservoir bag to permit positive-pressure ventilation are components of this system. Since a high gas flow is required to prevent rebreathing of carbon dioxide, the system is not able to effectively conserve anesthetic vapor as the circle system does. The primary utility of this system is in the administration of oxygen and positive-pressure ventilation in a resuscitative situation.

After the induction of general anesthesia and the establishment of intravenous access, the anesthesiologist will usually intubate the trachea with an endotracheal tube. The depth of the anesthetic might be supplemented with an intravenous medication such as propofol for this procedure. Sometimes a neuromuscular blocking agent might be used for this purpose. Endotracheal intubation permits the safe administration of a general anesthetic via a secure airway as the dentist is operating. Frequently, the dentist would benefit from the endotracheal tube being placed through the nose. There are many methods to accomplish this task, but it should be recognized that nasotracheal intubation is not without potential complications such as epistaxis or trauma to the nasopharynx. Nasotracheal intubation is commonly avoided in patients with a history of frequent nosebleeds, coagulation disorders, or cleft palate repair. In the event that nasotracheal intubation is deemed inadvisable, oral endotracheal intubation is an alternative. If so, taping the endotracheal tube such that it resides outside the most posterior uppermost molar on the least affected side can provide the dentist with room to work on the other quadrants and if necessary, move the tube to the other side of the mouth to finish in the last quadrant. After endotracheal intubation and prior to initiating the dental work, the dentist will pack a surgical sponge in the pharynx around the endotracheal tube to decrease the risk of foreign material entering the airway upon extubation. Obviously, this throat pack must be removed prior to extubation, and a reminder confirming its removal at the conclusion of the procedure should be included as part of any safe practice.

The child is monitored using all ASA-recommended equipment including electrocardiogram, sphygmomanometer, pulse oximeter, capnography, and thermometer. The anesthesiologist will calculate all fluid deficit and maintenance requirements to determine fluid administration for the procedure. In the event the child has congenital heart disease, appropriate antibiotics should be administered prior to initiating the dental work. Special care is taken to protect the eyes and all pressure points should be padded. A safety belt should be fastened.

Intraoperative anesthetic management will commonly include administration of antiemetic agents, such as

dexamethasone and ondansetron, as a common side effect of general inhaled anesthesia is postoperative nausea and vomiting. Dentist-administered local anesthesia is also helpful to minimize the anesthetic requirements and possible side effects as well as to provide postoperative analgesia. Administration of the intravenous nonsteroidal antiinflammatory agent, ketorolac, can also provide significant postoperative analgesia. Upon completion of the required dental work, the trachea is extubated when appropriate and the patient is transported to the postoperative recovery phase.

## Neurotoxicity of Anesthetic Agents in Young Children

The possibility that anesthetic agents might cause neurotoxicity and resultant learning deficits in young children has become an important topic over the past few years. Pediatric anesthesiologists and dentists have been asked by parents and caregivers about toxic effects and long-term cognitive and behavioral outcomes. This issue was first recognized in animal studies in the early 2000s. Exposure of anesthetic agents during critical periods of synaptogenesis is associated with learning deficits in rodents and nonhuman primates. In these animal studies, the neurotoxicity was generated with long durations of exposure and large doses of the anesthetic agents. The mechanism of harm appears to be exaggerated neuroapoptosis or programmed cell death when the animal is exposed at critical times in development. Most anesthetics and sedatives commonly used in humans have been implicated in animal studies. Human studies have also raised the possibility for cognitive deficits later in life. These reports were retrospective and do not recognize the confounding variables in such an analysis. Multiple prospective studies are under way. The issue has generated a “black box” warning from the Food and Drug Administration (<https://www.fda.gov/drugs/drugsafety/ucm532356.htm>). An organization developed by the FDA and the International Anesthesia Research Society called SmartTots (<http://www.smarttots.org/>) has statements available for parents and providers addressing the topic.

## Anesthetic Preparation of the Child

### TIME-OUT PROTOCOL

After donning operating room attire, the dentist should report to the surgical suite and inform the anesthesiologist of any special requests concerning the procedure before the induction of anesthesia. When the patient enters the operating room, the mandatory “time-out protocol,” usually initiated by the circulating nurse, identifies the patient, allergies, planned medications, and proposed treatment to the dentist and anesthesiologist before induction for the child’s safety (Fig. 19.4). Nasotracheal intubation is preferred to ensure good access to the oral cavity. However, a history of epistaxis or certain medical comorbidities may make nasotracheal intubation relatively contraindicated. One technique for nasal endotracheal intubation utilizes a latex-free red rubber catheter to serve as an atraumatic



102887  
CH-7859 (JUL 12)  
Page 1 of 1

**ROC SURGERY, LLC**

**ASC Universal Protocol Checklist**

- to be initiated by a licensed professional

Patient Sticker

Procedures: \_\_\_\_\_  
\_\_\_\_\_

Assessment/Prep Area	Yes	No	N/A
Correct patient verified using 2 patient identifiers			
Allergies validated			
Current History & Physical <i>(dated within 30 days)</i>			
Current Clinical Note (N/A if H&P completed today)			
Consent form is accurate and signed <i>(dated/timed within 60 days)</i>			
Diagnostic, radiology and lab results are available: <input type="checkbox"/> EKG <input type="checkbox"/> H/H <input type="checkbox"/> Glu <input type="checkbox"/> Preg <input type="checkbox"/> K+ <input type="checkbox"/> PTT/INR <input type="checkbox"/> Other			
Patient/Surrogate questions for Treating Practitioner answered			
Driver/Caretaker availability confirmed			
Site marked 'YES' by Treating Practitioner			
Parent/Guardian band on			

Handoff	Yes	No	N/A
Correct patient verified using 2 patient identifiers			
Allergies validated			
Current History & Physical <i>(dated within 30 days)</i>			
Current Clinical Note (N/A if H&P completed today)			
Consent form is accurate and signed <i>(dated/timed within 60 days)</i>			
Diagnostic, radiology and lab results are available: <input type="checkbox"/> EKG <input type="checkbox"/> H/H <input type="checkbox"/> Glu <input type="checkbox"/> Preg <input type="checkbox"/> K+ <input type="checkbox"/> PTT/INR <input type="checkbox"/> Other			
Site marked 'YES' by Treating Practitioner			
Implants/Devices or special equipment available			

First Time Out	Yes	No	N/A
Allergies verified			
Verbalized procedure(s) match consent			
Verbal acknowledgement by all procedure team members present			

Second Time Out	Yes	No	N/A
Correct patient verified using 2 patient identifiers			
Correct site confirmed with Informed Consent and marked			
Verbal congruency from ALL team members that site matches consent			
Relevant images displayed/labeled with correct pt. identifiers			
Antibiotic administered			
Fluids/medications labeled appropriately on sterile field			
DVT/VTE prophylaxis			
Verbal acknowledgement by all procedure team members present			

Final Time Out	Yes	No	N/A
Consent reviewed – all procedures have been documented			
Specimens addressed, labeled and identified			
All foreign bodies not intended for implantation have been removed			
Counts addressed			
Verbal acknowledgement by all procedure team members present			

Initials	Signature	Initials	Signature



**UNIVERSAL PROTOCOL CHECKLIST** (Page 1 of 1)  
*Please Place Behind Consent In Chart*

Intra-OP Records

**M-22**

Fig. 19.4 Universal protocol checklist. (Courtesy of Indiana University Health, Riley Outpatient Center Surgery, LLC.)

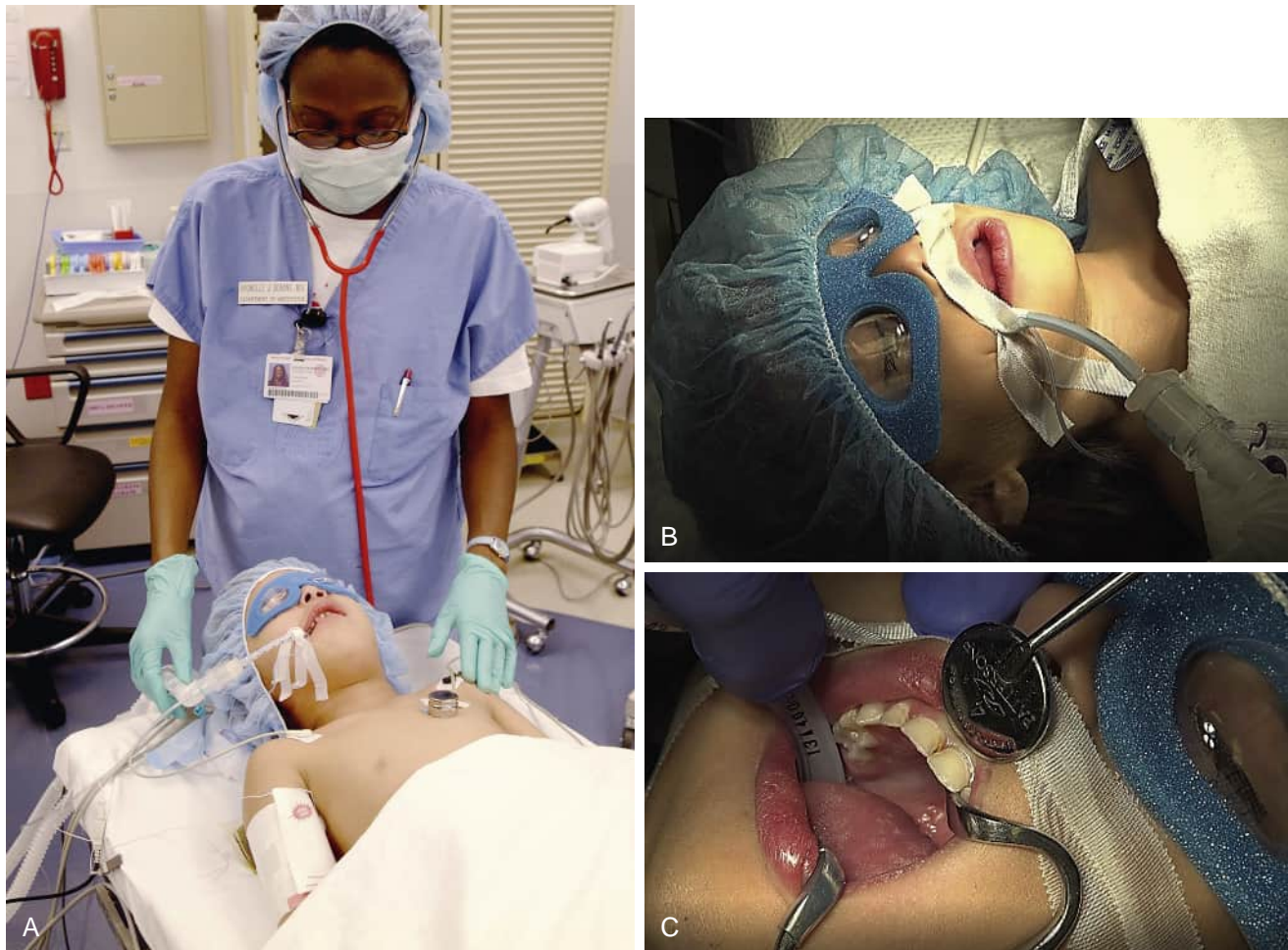
dilation device to prevent the passage of the hollow-pointed endotracheal tube through the nasopharyngeal tissues.<sup>10</sup> This typically is done without the instillation of a topical vasoconstrictor such as neosynephrine. Orotracheal intubation is not contraindicated, however, and can be used in a dental case with minimal restorative needs. In this event, the anesthesiologist will typically place the endotracheal tube to the least affected side of the oral cavity first and then move it to the other side after treatment of disease not obscured by the tube is completed. One must recognize that complications related to the administration of general anesthesia (i.e., laryngospasm, tooth avulsion or aspiration, traumatic intubation, compromised airway, and malignant hyperthermia) are possible and may require expert management by the anesthesiologist.

The anesthesiologist is responsible for starting intravenous fluids, securing the necessary monitoring equipment, performing the intubation, and stabilizing the endotracheal tube. The anesthesiologist will select the type of intravenous fluid, calculate the estimated fluid replacement and fluid deficit volumes, and perform a physical assessment of dehydration. The monitoring equipment should include

(1) an automatic sphygmomanometer, (2) electrocardiographic leads, (3) a temperature monitoring device, (4) a pulse oximeter, and (5) a capnography device. The anesthesiologist must confirm that the child is in stable condition prior to the onset of the dental operation. If orotracheal intubation is used, special attention is focused on optimal tube placement (Fig. 19.5A–C).

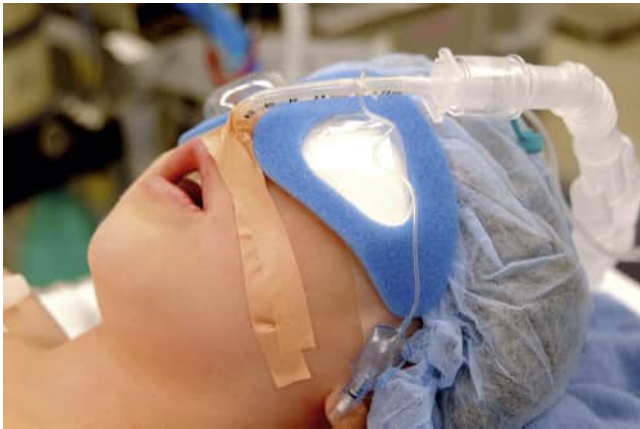Special care is taken to protect the child's eyes (Fig. 19.6). In addition, a shoulder roll is placed, padding is added to the patient's pressure points, the endotracheal tube and head are stabilized, heating or cooling blankets are used as needed, and the safety belt is secured. The dentist has the table positioned to conduct dental procedures, and the anesthesiologist administers any preoperative intravenous medications requested.

Before scrubbing, the dentist should obtain any necessary preoperative radiographic studies. All persons involved in the radiologic procedure should wear protective lead apparel. Radiographs of excellent quality can be made while a patient is under general anesthesia without exposing the patient or staff to unnecessary radiation (Fig. 19.7). Digital radiographs are advantageous because radiation exposure is decreased and image feedback is immediate.

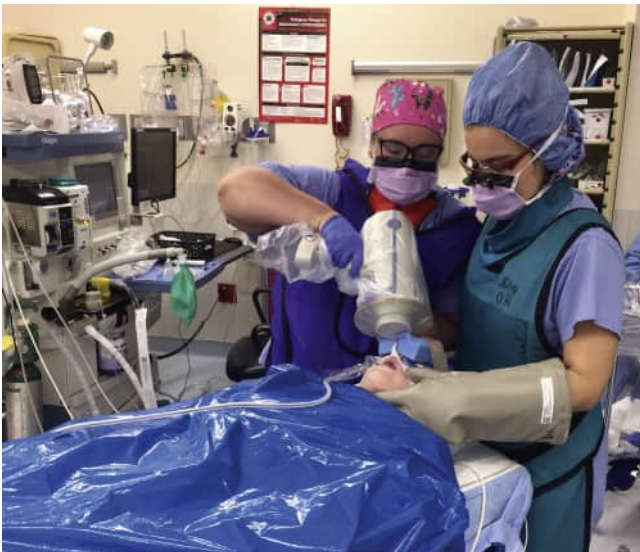

**Fig. 19.5** (A) Patient is in a stable anesthetic condition and ready for the dental procedure. Notice the position of the precordial stethoscope, blood pressure cuff, and orotracheal tube. (B) This shows the position of the orotracheal tube taped to the far right side of the mouth. Note the tape is solely on the maxilla to not impede mouth opening. (C) This shows the intraoral portion of the orotracheal tube. Note the tube is positioned buccal to the maxillary second primary molar to allow access to most of the oral cavity. If work in that quadrant is impaired by the tube, it can be moved and taped to the other side.





**Fig. 19.6** A special eye guard protects the patient's eyes during the procedure.



**Fig. 19.7** Obtaining diagnostic radiographs. Notice the use of protective lead gloves, thyroid collar, gown, and lead aprons. The blue plastic bag lying over the patient contains a protective lead apron that will be replaced by a surgical patient drape at the conclusion of obtaining x-rays and before initiating the surgical procedure.

## Perioral Cleaning, Draping, and Placement of Pharyngeal Throat Pack

Before the dental procedure is begun, the perioral area is cleansed with sterile 4 × 4-inch gauze pads. The first gauze pad is saturated with a bacteriostatic cleansing agent and the second gauze pad with sterile water. Alcohol is not used in the operating room because it is a potential fire hazard (Fig. 19.8). This procedure is intended not to sterilize the area but only to remove gross debris (Fig. 19.9). A surgical sheet is then positioned over the remainder of the child's body. This helps maintain body temperature and provides a clean field during the procedure. The head is draped with three towels arranged to form a triangular access space for the mouth. The towels are secured in place with towel clamps or hemostats. The mouth should be fully exposed

(Fig. 19.10). The anesthesiologist may request that part of the nasotracheal tube remain exposed so that all connections can be easily monitored. The assistants then place all supporting carts and stands around the table in positions that the dentist finds comfortable and efficient (Fig. 19.11). The example set-up of the surgical suite provided is only a suggestion; the final positioning of equipment and individuals is at the discretion of the surgeon and surgical staff.

The patient's mouth is opened with the aid of a Molt mouth prop. Care should be taken not to impinge on the lips or tongue with the prop (Fig. 19.12). The mouth is thoroughly aspirated. The pharyngopalatine area is sealed off with a strip of moist 3-inch sterile gauze approximately 12–18 inches long (Fig. 19.13). Written documentation of throat pack placement and removal is required on the physical history form of the medical chart. This packing reduces the escape of anesthetic agents and prevents any material from entering the pharynx. The gauze should be tightly packed around the tube so that a good seal is ensured. (Video 19.2) Once the pack is in place, a thorough intraoral examination is performed, followed by dental prophylaxis. The dentist should then evaluate any new radiographic studies that have been obtained and formulate a final treatment plan.

**Video 19.2** Throat Pack Placement: placement of throat pack in a child under general anesthesia.



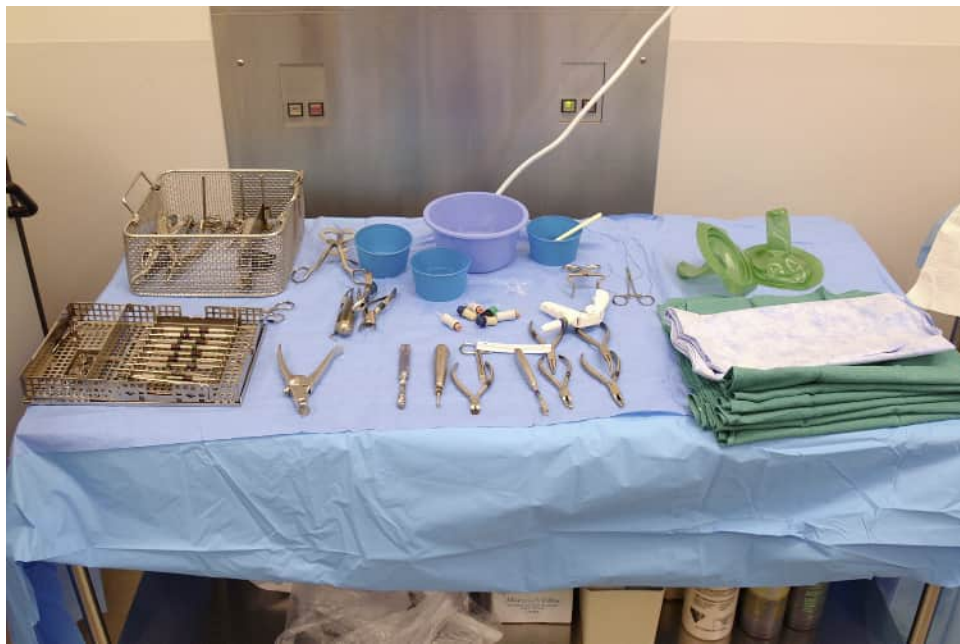## Restorative Dentistry in the Operating Room

Instruments used for restorative dental procedures in the operating room are the same as those used for procedures in the dental operatory. Local anesthesia may be used to minimize pain and bleeding. The use of local anesthesia can decrease the anesthetic requirements or need for postoperative opiate analgesia and thus decrease postoperative side effects such as nausea. The use of quadrant isolation with a rubber dam is preferred (Fig. 19.14). After the completion of all dental procedures, a topical fluoride varnish should be applied before the throat pack is removed. Documentation of dental procedures, extracted teeth, sutures, blood loss, and hydration in the medical chart is required.

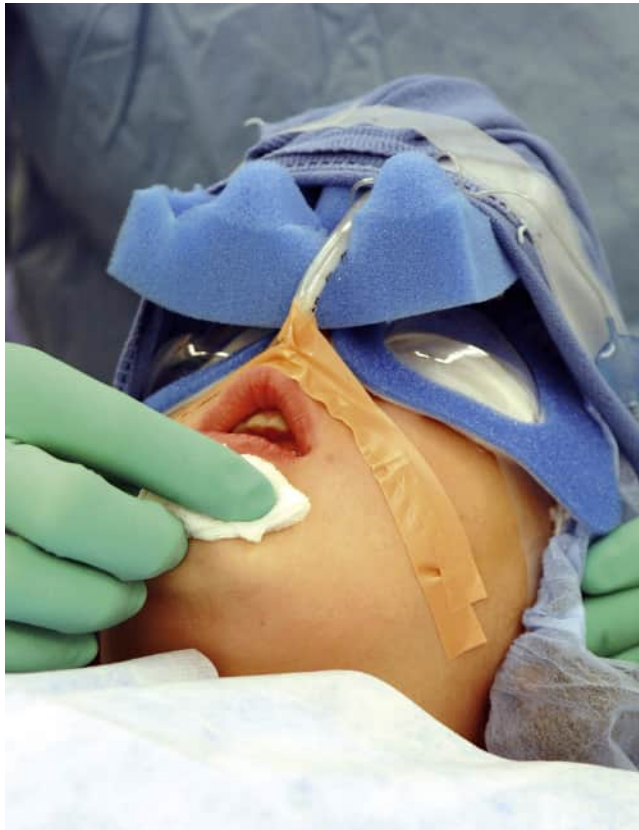Restorative dental care under general anesthesia allows for excellent patient compliance and the easy achievement of a well-lighted field, and therefore increases the quality and quantity of dental care while decreasing the anxiety level for the clinician and patient during dental treatment. Spiro and Burns<sup>11</sup> found that they were able to treat seven teeth per hour in children under general anesthesia compared with only three teeth per hour in children of similar age in a clinic setting. Eidelman et al.<sup>12</sup> reported that the quality of restorative treatment performed was better under general anesthesia than under conscious sedation.

The dentist should place restorations that will provide the greatest longevity with the least amount of maintenance, for example, full-coverage stainless-steel crowns rather than large amalgam restorations on posterior primary teeth. In a 3-year study of comprehensive dental cases treated under general anesthesia, O'Sullivan





**Fig. 19.8** Materials required for perioral cleaning. Clockwise from upper left: pharyngeal throat pack, towel clamps, patient drapes, bacteriostatic cleaning agent, sterile water, and alcohol.



**Fig. 19.9** Special care must be taken during perioral cleaning to prevent materials from entering the oral cavity.

and Curzon<sup>13</sup> found stainless-steel crowns to be significantly more successful (3% failure rate) than amalgam or composite restorations (29% failure rate). A 6-month retrospective study by Tate et al.<sup>14</sup> to assess the failure rates of dental restorative procedures performed under general anesthesia by pediatric dental residents

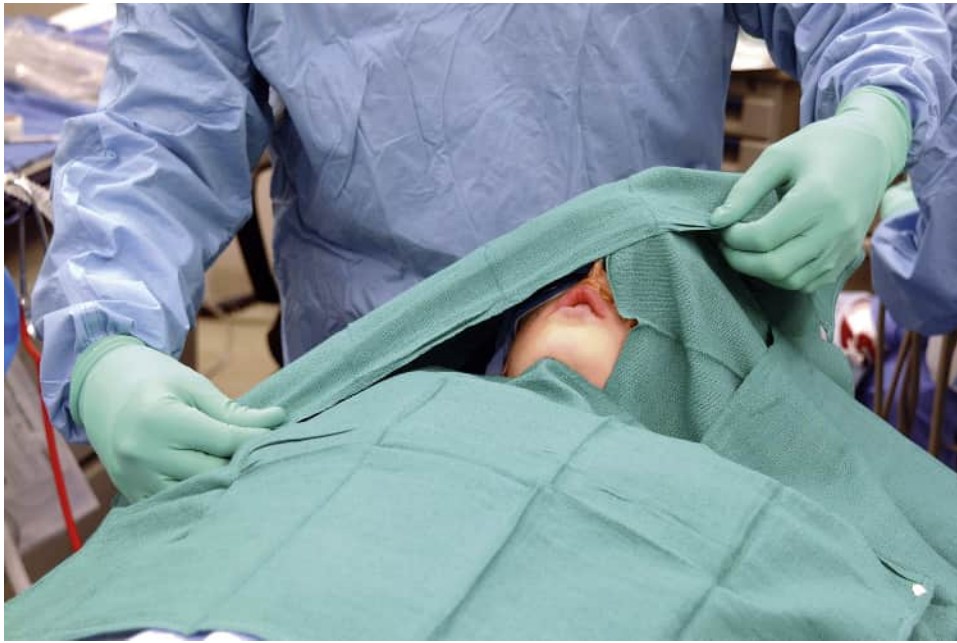found stainless-steel crowns to be best (8%), followed by amalgam (21%) and composite (30%); composite strip crowns (51%) had the lowest successful restorative treatment rate. In a 6- to 27-month postoperative period following general anesthesia, Al-Eheideb and Herman<sup>15</sup> reported similar values, with stainless-steel crowns (95.5%) being more successful than amalgams or composite restorations (50%). In their review, pulpomies had an extremely high success rate (97.1%), whereas sealants were retained only 68.3% of the time. In a 30-month longevity study of over 1000 composite restorations completed in the operating room, Bücher et al.<sup>16</sup> noted a high success rate (81.5%). In another study of composite strip crowns, Kupietzky et al.<sup>17</sup> found them to be aesthetic and durable, with an 88% overall retention rate after 6 months.

Intraoperative anesthesia complications (e.g., dislodged or obstructed endotracheal tube; intravenous infiltrates or disconnects; nasal bleeding or edema; abrasion; laceration of the tongue, lips, or mucosa; and arrhythmias) and extraoral complications (e.g., perioral abrasions, swellings, or lacerations) rarely occur. Care should be taken by the dentist not to displace the endotracheal tube and to minimize contact with the perioral tissues when possible. Priority is given by the dentist to the anesthesiologist to treat any adverse event quickly, even to the point of stopping treatment and removing rubber dams to allow access.

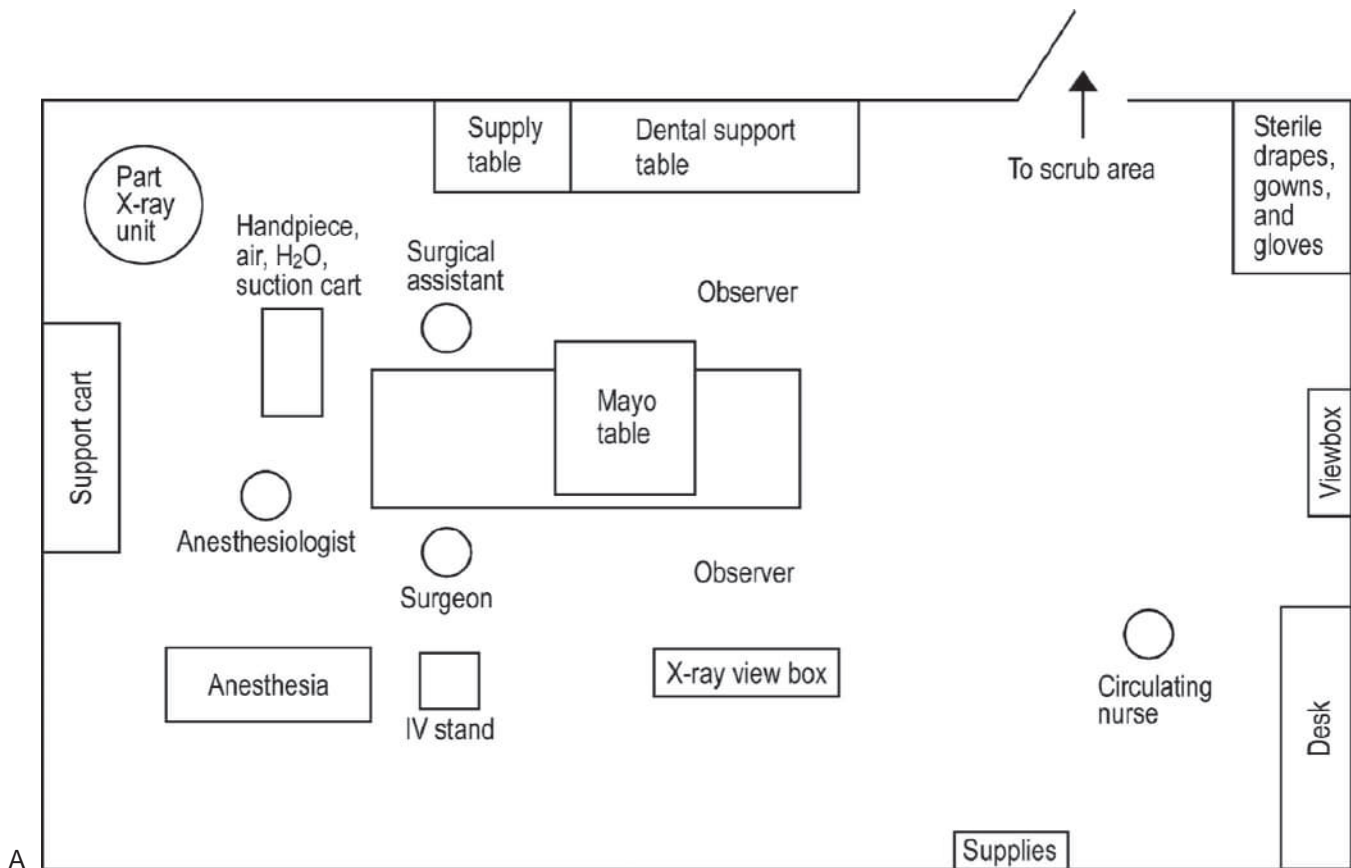
## Completion of the Procedure

### END TIME-OUT PROTOCOL

The anesthesiologist should be notified 10 minutes before the completion of the procedure so that the child can begin to be aroused and preparations can be made for extubation. The recovery room personnel are



**Fig. 19.10** Placement of the surgical sheet and triangular draping of the oral cavity area. The nasotracheal tube is exposed to allow for easy monitoring of its connections.



**Fig. 19.11** (A) Schematic drawing of one example of the positioning of personnel and equipment in the operating room. IV, Intravenous. (B) Operating room positions of the staff while performing the necessary dental procedures. From left: dental assistant, dental surgeon, anesthesiologist, assistant dental surgeon, and circulating nurse. (C) Sitting position in operating room. From left: dental surgeon, dental assistant (anesthesiologist is out of the picture to the left).

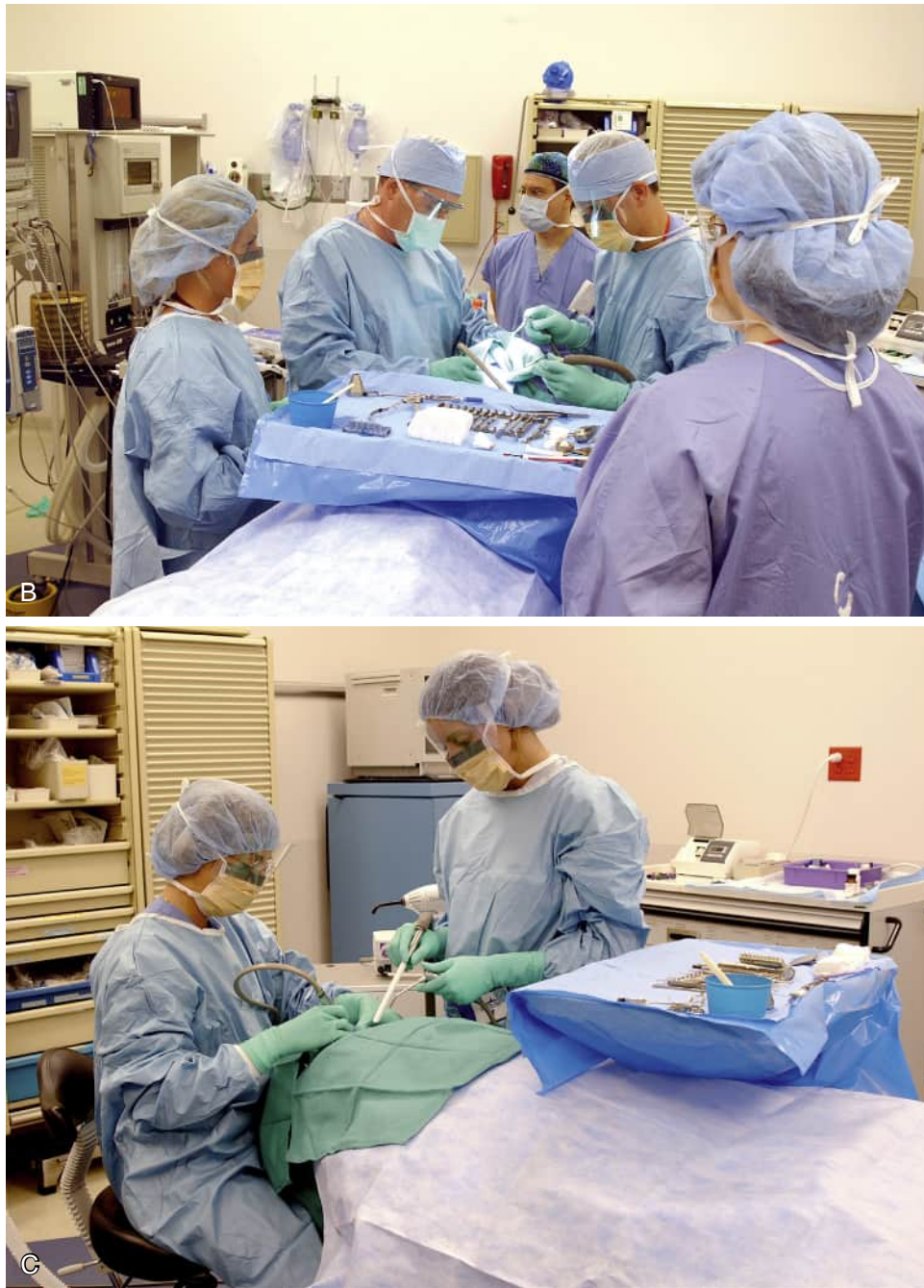

Fig. 19.11—Cont'd

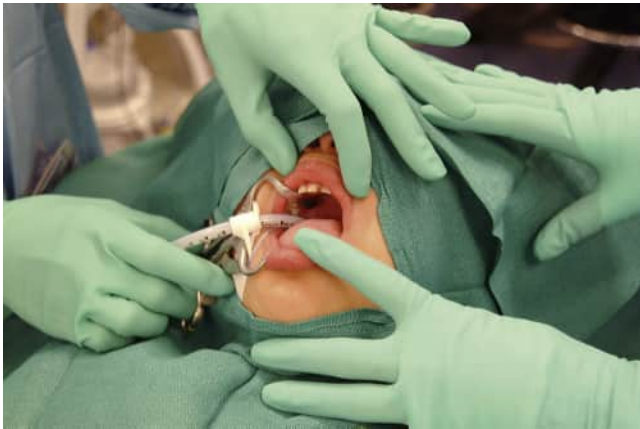notified that the child will soon be arriving so that they can begin preparations. On completion of the dental procedure, the oral cavity is thoroughly debrided, and the throat pack is removed carefully to prevent aspiration of any materials that might be lodged against it. The “end time-out protocol” is called by the circulating nurse to identify any patient safety concerns (Fig. 19.4). The dentist verbalizes a needle-and-sponge count and removal of the throat pack to the nurse. The anesthesiologist then brings the patient through emergence, and the trachea is extubated. The dentist should remain in the operating room during the extubation

process to assist the anesthesiologist if necessary. When the child is transported to the recovery room, the dentist should accompany the anesthesiologist and provide assistance during the transportation.

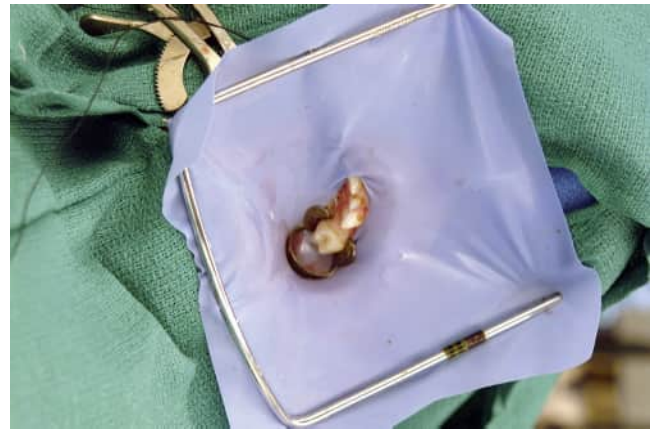## Postanesthesia Care Unit

When the child arrives in the postanesthesia care unit or recovery room, the dentist should inform the nursing staff of the procedures accomplished and of any special requests or instructions. If teeth have been removed, the

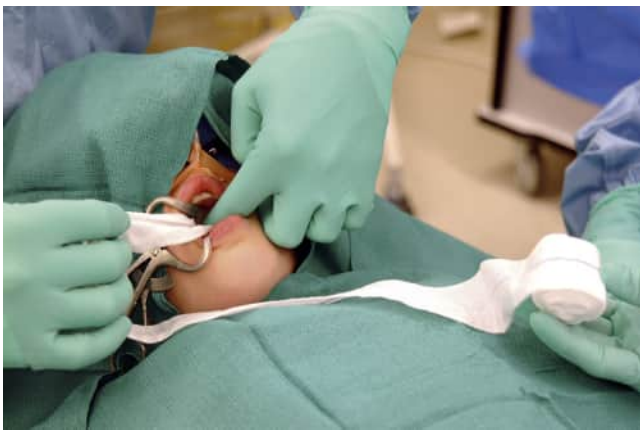



**Fig. 19.12** Positioning of a mouth prop. Special care is taken not to impinge on the lips or tongue with the prop.



**Fig. 19.14** Rubber dam isolation of the maxillary left quadrant.



**Fig. 19.13** Placement of the pharyngeal throat pack.

nurse should be specifically instructed how and where to apply gauze packs for hemostasis. The nurses and other medical staff are available to deal with immediate postoperative complications (e.g., fever, nausea, vomiting, croup, hypoxia, bleeding, and laryngospasm) if they occur. After the dentist has confirmed that the airway is patent and the vital signs are stable, and after the anesthesiologist is confident that the child is recovering well, the dentist should meet with the parents or guardian to provide a brief report of the child's condition and a review of the treatment. The parents or guardian of inpatients should be informed of the approximate time the child will be reunited with them. The parents or guardian of outpatients should be informed if events have occurred indicating that the child should be observed in the hospital. Prescriptions may be written for pain control agents (e.g., acetaminophen with hydrocodone, ibuprofen suspension), antibiotics (e.g., amoxicillin, clindamycin), or antiemetics for nausea (e.g., prochlorperazine, ondansetron [Zofran]). It should be noted that codeine is not routinely prescribed because of an association with death in patients at risk for postoperative airway obstruction or apnea. Codeine has also been found to be ineffective in a

significant part of the population because of an enzyme deficiency that prevents its metabolism to the active form.

## Postoperative Care

Postoperative orders and the operative note for the staff should be completed by the dentist and recorded in the medical chart while the child is in the postanesthesia care unit (Figs. 19.15; Box 19.5). Transfer orders may be used for individuals requiring more specialized care than the pediatric dentist usually provides (Fig. 19.5C). The operative report should be dictated as soon after the completion of the procedure as possible (Box 19.6).

If the child was treated as an outpatient, once the child is awake and alert, displays appropriate behavior, maintains his or her own airway, has stable vital signs, has no uncontrolled bleeding or pain, is voiding, and has no retention of liquids, the child could be discharged rather than kept overnight for further evaluation. The facility may have a list of discharge criteria to facilitate this decision (Fig. 19.16). If the child is to be kept for a 23-hour observation, an appropriate note is recorded in the medical chart, and a discharge summary is dictated (Box 19.7) after the child is released. Postoperative instructions and necessary prescriptions are given to the parents or guardian, and a predischarge observation appointment for the child is arranged. The dentist must be available that evening (a contact number must be given) in the event the parents or guardian needs assistance in caring for the child after returning home. These instructions and prescriptions help the patient deal with common complications after discharge, such as fever, nausea, vomiting, pain, and bleeding.

Effective communication is essential at this time to reaffirm the parents' or guardian's cooperation in performing oral health care and in keeping follow-up observation appointments and recall appointments. Enger and Mourino<sup>6</sup> reported that only 57% of dental patients undergoing a treatment in the operating room returned for 6-month recall visits, and suggested that procedures

### Outpatient Orders

1. PACU care per protocol.
2. Discontinue IV when released from PACU.
3. Begin clear liquids in day surgery.
4. Pain medication: Acetaminophen \_\_\_\_\_ mg po q4h prn pain (10-15 mg/kg/ standard dose. Hydrocodone (7.5 mg with acetaminophen 325 mg/15mL solution), po q6h for moderate to severe pain (typical dose 0.15 mg/kg).
5. Antibiotics (if indicated); amoxicillin \_\_\_\_\_ mg if not allergic to penicillins, clindamycin \_\_\_\_\_ mg, if allergic to penicillins.
6. Call dental house officer at \_\_\_\_\_ if questions.
7. Release from day surgery when discharge criteria are met.
8. Return appointment.
9. Call if problems arise.

Officer number \_\_\_\_\_

Pager number \_\_\_\_\_

Signature \_\_\_\_\_

A

### Inpatient Orders

1. Admit to \_\_\_\_\_ to Dr. \_\_\_\_\_ Service.
2. Allergies.
3. Vital signs q2h x 2, then q4h x 2, then q8h.
4. Continuous pulse oximetry x 24h.
5. Head of bed elevated 30 degrees.
6. Protective stabilization, if needed.
7. Encourage oral fluids.
8. Advance to soft diet as tolerates.
9. Medications: list all meds, dosage, times given.
10. Pain medication: Acetaminophen \_\_\_\_\_ mg po q4h prn pain (typical dose 10-15 mg/kg).  
Hydrocodone (7.5mg with acetaminophen 325 mg/15mL solution), po q6h for moderate to severe pain (typical dose 0.15 mg/kg).
11. Nausea medication (if indicated): Ondansetron \_\_\_\_\_ mg po or IV prn nausea (0.1-0.2 mg/kg, max dose 4 mg).
12. IV fluids: D5 1/2 ns + 20 meq KCL or Lactated Ringer's (LR) solution at \_\_\_\_\_ (typical maintenance fluid rate = 4 mL/kg for patients <10kg for patients >30 kg).
13. Antibiotics (if indicated); amoxicillin \_\_\_\_\_ mg if not allergic to penicillins, clindamycin \_\_\_\_\_ mg, if allergic to penicillins.
14. Apnea monitor, if indicated.
15. For oral swelling—apply ice pack to area for 30 minutes.
16. Check for oral bleeding q15 min x 1 hr. If needed, apply moist 4 x 4 sterile gauze to area with pressure.
17. Call if needed.

Officer number \_\_\_\_\_

Pager number \_\_\_\_\_

Signature \_\_\_\_\_

B

### Transfer Medical Orders

1. Transfer to pediatric medical service: Dr. MD pager number \_\_\_\_\_.
2. Vital signs per PACU protocol.
3. Change intravenous fluids per pediatric medical service.
4. Encourage clear liquids.
5. Advance to soft diet as tolerated.
6. Monitor for oral hemorrhage for 24 hours. Apply moist sterile gauze and pressure, if necessary. Call dentist for excessive hemorrhage or swelling.
7. Medications per pediatric medical service.
8. Continue additional medications per prescription:  
i.e., mild pain—acetaminophen or ibuprofen suspension;  
moderate pain—hydrocodone with acetaminophen elixir  
Antibiotic—amoxicillin; allergy clindamycin  
Nausea—ondansetron.
9. Give and review appropriate home care instructions, and return appointment with family prior to discharge.
10. For dental questions contact: Dr. \_\_\_\_\_ pager number \_\_\_\_\_.

C

Dentist Signature \_\_\_\_\_

Fig. 19.15 Components of the dentist's postoperative orders for a patient. (A) Inpatient orders. (B) Outpatient orders. (C) Transfer medical orders.

### Box 19.5 Components of the dentist's operative note

1. Title of dental procedure
2. Type of intubation and anesthesia used
3. Teeth restored
4. Teeth extracted
5. Other procedures completed
6. Dental prophylaxis and topical fluoride used
7. Summary (e.g., length of procedure, how the child tolerated the procedure, blood loss, complications)
8. Prognosis
9. Dentist's signature

### Box 19.6 Components of the dentist's operative report

1. Doctor's and assistants' names
2. Patient's name and hospital number
3. Preoperative diagnosis
4. Postoperative diagnosis
5. Title of the operative procedure
6. Preparation for anesthesia (preoperative medications, type of intubation, and anesthetic agents used)
7. Surgical procedure
  - a. Radiographs taken
  - b. Description of scrub, draping procedure, and throat pack
  - c. Number of teeth restored and type of restorations
  - d. Number of teeth receiving pulp therapy
  - e. Teeth extracted (name each)
  - f. Gingival therapy procedures
  - g. Band(s) for appliance(s) and impression(s)
  - h. Dental prophylaxis and fluoride applied
  - i. Types and amounts of intraoperative fluids used
  - j. Other information (if indicated)
8. Estimated blood loss and hemostasis
9. Condition of the patient at the conclusion of the surgical procedure (complications incurred if indicated)
10. Condition of the patient on arrival in the recovery room
11. Prognosis

requiring monitoring (i.e., space maintenance) be postponed if the patient's return is unlikely. In a study of patients needing repeat dental treatment in the operating room, Sheller et al.<sup>18</sup> found the best outcomes to result from aggressive treatment of caries, active patient follow-up, and education of parents. Common patient characteristics included the following: 100% with carious involvement of maxillary central incisors, most central incisors were nonrestorable, the child was still using a bottle at the time of the operating room procedure, the

### Box 19.7 Components of the dentist's discharge summary statement

1. Patient's name and hospital number
2. Date of admission
3. Date of discharge
4. Date of dictation
5. Preoperative diagnosis
6. Postoperative diagnosis
7. Age, race, and gender of patient
8. Reason for admission and treatment using general anesthetic
9. Results of preoperative history and physical examination (medical and dental) and present medications
10. Name of the physician completing the history and physical examination
11. Complete description of the surgical procedure (Box 19.6)
12. Patient's tolerance in the recovery room and ward
13. Condition of patient on discharge
14. Individual to whom patient is discharged
15. Home care instructions given to parents or guardian and medications prescribed (dosage and times to be given)
16. Patient's next appointment
17. Copies of discharge summary sent to patient's physician and referring dentist or physician

child is responsible for brushing his/her own teeth, the child showed poor cooperation in medical/dental setting, the child had a difficult personality as described by the parent, the social situation was dysfunctional, and follow-up care was lacking.

A study by Almeida et al.<sup>19</sup> regarding future caries susceptibility in children with early ECC following dental treatment under general anesthesia found that, despite implementation of increased preventive measures for these children, they were still highly predisposed to greater caries incidence in later years. The researchers concluded that more aggressive preventive therapies may be required in children who experience ECC.

There are several categories of dental problems in children who cannot be handled well in the office setting and are best managed in the hospital or outpatient surgery center. The ability to treat children in the hospital environment and to provide comprehensive dental care using a general anesthetic for such children is a valuable part of the dentist's treatment regimen. Granting hospital staff privileges to qualified dentists has become routine at many hospitals seeking to provide comprehensive health care for the community. The dentist who uses the hospital or outpatient surgery center for the care of patients often finds it to be a rewarding component of practice. Following dental treatment under general anesthesia, Anderson et al.<sup>20</sup> found that dental patient complaints of pain, problems with eating, sleeping, and behavioral concerns showed significant improvement, thereby improving their quality of life.



ROC SURGERY LLC  
Perioperative Care Center  
Riley Outpatient Surgery Center (ROC)

### Discharge Criteria to the Care of a Responsible Adult

#### Policy

Readiness for discharge from the Day Surgery Unit is based on nursing assessment and meeting pre-set discharge criteria.

#### Criteria for Discharge from SDS (or PACU) to Home

Assess the patient's readiness for discharge based on the following criteria:

1. Heart rate, respiratory rate, and blood pressure are within 10% of preoperative values. SaO<sub>2</sub> is >95 or at preoperative value. Owing to the nature of the pediatric patient, many patients may be upset upon admission to the point that vital signs are not representative of their baseline. In this situation, the first set of vital signs from the OR will be used.
2. Respirations are unlabored and breath sounds are equal and consistent with the preoperative examination.
3. Dressing is intact with minimal or no drainage present and/or incision is free of fresh drainage.
4. Patient is tolerating oral fluids with no nausea or vomiting unless physician has made an exception to this.
5. Patient is alert when awake or at preoperative level of function.
6. Older child is able to speak clearly or at preoperative level and infant has a clear cry.
7. Pain is controlled.
8. Patient's motor function has returned to baseline or is at an expected level consistent with the surgical or anesthetic management.
9. All postoperative orders have been addressed and completed where applicable.
10. Return appointments have been made if applicable.
11. Anesthesiologist has been notified of and/or has examined any child with prolonged emesis or croup.
12. Patient has discharge order signed by surgeon and anesthesiologist.

**Fig. 19.16** Discharge criteria for postoperative dental patient. (Courtesy of Indiana University Health, Riley Outpatient Center Surgery, LLC.)

### References

1. King KJ, Nielson RR: Dental treatment in the hospital utilizing general anesthesia. In Nowak AJ, editor: *Dentistry for the handicapped patient*, St. Louis, 1976, Mosby.
2. Camm JH, Mourino AP, Cobb EJ, et al.: Behavioral changes of children undergoing dental treatment using sedation versus general anesthesia, *Pediatr Dent* 9(2):111–117, 1987.
3. Peretz B, Faibis S, Ever-Hadani P, et al.: Children with baby bottle tooth decay treated under general anesthesia or sedation: behavior in a follow-up visit, *J Clin Pediatr Dent* 24(2):97–101, 2000.
4. Fuhrer CT, Weddell JA, Sanders BJ, et al.: Effect on behavior of dental treatment rendered under conscious sedation and general anesthesia in pediatric patients, *Pediatr Dent* 31(7):492–497, 2009.
5. Biery KA, Shamaskin RG, Campbell RL: Analysis of preoperative laboratory values prior to outpatient dental anesthesia, *Anesth Prog* 34(2):58–60, 1987.
6. Enger DJ, Mourino AP: A survey of 200 pediatric dental general anesthesia cases, *J Dent Child* 52(1):36–41, 1985.
7. Seto BG, Lynch S: Safety of hospital dental treatment for the high-risk patient, *Spec Care Dentist* 4(6):253–260, 1984.
8. Guedel AE: *Inhalation anesthesia*, New York, 1937, Macmillan.
9. Roberts GJ: Relative analgesia in clinical practice. In Coplans MD, Green RA, editors: *Anaesthesia and sedation in dentistry*, vol. 12. Amsterdam, 1983, Elsevier Science.
10. Ray TL, Tobias JD: An alternative technique for nasotracheal intubation, *South Med J* 96(10):1039–1042, 2003.
11. Spiro SR, Burns J: Current concepts of premedication and anesthesiological management for the pediatric dental patient who is hospitalized for dento-oral rehabilitation, *J Hosp Dent Pract* 14(1):35–39, 1980.
12. Eidelman E, Faibis S, Peretz B: A comparison of restorations for children with early childhood caries treated under general anesthesia or conscious sedation, *Pediatr Dent* 22(1):33–37, 2000.
13. O'Sullivan EA, Curzon ME: The efficacy of comprehensive dental care for children under general anesthesia, *Br Dent J* 171(2):56–58, 1991.
14. Tate AR, Ng MW, Needleman HL, et al.: Failure rates of restorative procedures following dental rehabilitation under general anesthesia, *Pediatr Dent* 24(1):69–71, 2002.
15. Al-Eheideb AA, Herman NG: Outcomes of dental procedures performed on children under general anesthesia, *J Clin Pediatr Dent* 27(2):181–183, 2003.
16. Bücher K, Tautz A, Hickel R, et al.: Longevity of composite restorations in patients with early childhood caries (ECC), *Clin Oral Investig* 18(3):775–782, 2013.

17. Kupietzky A, Waggoner WF, Galea J: The clinical and radiographic success of bonded resin composite strip crowns for primary incisors, *Pediatr Dent* 25(6):577–581, 2003.
18. Sheller B, Williams BJ, Hays K, et al.: Reasons for repeat dental treatment under general anesthesia for the healthy child, *Pediatr Dent* 25(6):546–552, 2003.
19. Almeida AG, Roseman M, Sheff M, et al.: Future caries susceptibility in children with early childhood caries following treatment under general anesthesia, *Pediatr Dent* 22(4):302–306, 2000.
20. Anderson HK, Drummond BK, Thomson WM: Changes in aspects of children's oral health related quality of life following dental treatment under general anesthesia, *Int J Paediatr Dent* 14(5):317–325, 2004.

### Suggested Readings

- American Academy of Pediatric Dentistry: Policy on hospitalization and operating room access for oral care of infants, children, adolescents, and individuals with special health care needs. Special issue: reference manual 2018-2019, *Pediatr Dent* 40(Suppl 6):106–107, 2018.
- American Academy of Pediatric Dentistry: Policy on hospital staff membership. Special issue: reference manual 2018-2019, *Pediatr Dent* 40(6):108–109, 2018.
- American Society of Anesthesiologists: Practice guidelines for preoperative fasting and the use of pharmacologic agents to reduce the risk of pulmonary aspiration; application to healthy patients undergoing elective procedures, *Anesthesiology* 114:495–511, 2011.
- Davis LB, Saxen MA, Jones JE, et al.: Effects of different levels of ambient oxygen in an oxygen-enriched surgical environment and production of surgical fires, *Anesth Prog* 65(1):3–8, 2018.
- Emhardt J, Yepes JF, Vinson LA, et al.: Factors related to failed pediatric dental appointments scheduled for care under general anesthesia in a university hospital-based residency program, *Pediatr Dent* 39(3):217–222, 2017.
- Practice guidelines for preoperative fasting and the use of Pharmacologic agents to reduce the risk of pulmonary aspiration: Application to healthy patients undergoing elective surgical procedures: An updated report by the American Society of Anesthesiologists Task Force on Preoperative Fasting and the use of pharmacologic agents to reduce the risk of pulmonary aspiration, *Anesthesiology* 126:376–393, 2017.
- Herlich A, et al.: Anesthesia for pediatric dentistry. In *Smith's Anesthesia for Infants and Children*, ed 9, Philadelphia, 2017, Elsevier.
- VanCleave AM, Jones JE, McGlothlin JD, et al.: Factors involved in dental surgery fires: a review of the literature, *Anesth Prog* 61(1):21–25, 2014.
- VanCleave AM, Jones JE, McGlothlin JD, et al.: The effect of intraoral suction on oxygen-enriched surgical environments: a mechanism for reducing the risk of surgical fires, *Anesth Prog* 61(4):155–161, 2014.
- Vinson LA, Rasche ML, Sanders BJ, et al.: Behavior assessment in children following hospital-based general anesthesia versus office-based general anesthesia, *Dent J* 4(3):27, 2016.

## 20

# Eruption of the Teeth: Local, Systemic, and Congenital Factors that Influence the Process

ERWIN G. TURNER and JEFFREY A. DEAN

## CHAPTER OUTLINE

### Chronologic Development and Eruption of the Teeth

Influence of Premature Loss of Primary Molars on Eruption Time of Their Successors

Variations in Sequence of Eruption

#### Lingual Eruption of Mandibular Permanent Incisors

#### Teething and Difficult Eruption

Eruption Hematoma (Eruption Cyst)

Eruption Sequestrum

Ectopic Eruption

#### Natal and Neonatal Teeth

### Epstein Pearls, Bohn Nodules, and Dental Lamina Cysts

#### Local and System Factors that Influence Eruption

Ankylosed Teeth

Ankylosis of Primary Molars With Absence of Permanent Successors

Ankylosed Permanent Teeth

Trisomy 21 Syndrome (Down Syndrome)

Cleidocranial Dysplasia

Hypothyroidism

Hypopituitarism

Achondroplastic Dwarfism

Other Causes

## Chronologic Development and Eruption of the Teeth

A variety of developmental defects that are evident after eruption of the primary and permanent teeth can be related to systemic and local factors that influence the matrix formation and calcification process. Thus it is important that the dentist be able to explain to the parents the time factors related to the early stages of tooth calcification both in utero and during infancy.

Past classic studies and reviews of the literature involving calcification of the primary teeth have compared their findings with the values in [Table 20.1](#) showing the Logan and Kronfeld chronology of the human dentition, which has been the accepted standard for many years.<sup>1</sup> Their findings offered revisions that established earlier ages than those previously accepted for initial calcification and later ages at which the primary teeth erupt.

These studies and reviews concluded that [Table 20.1](#) should be modified and that the sequence of calcification of the primary teeth should be changed to central incisor, first molar, lateral incisor, canine, and second molar. They determined that the times of initial calcification of the primary teeth are 2–6 weeks earlier than those given in [Table 20.1](#); they also concluded that the maxillary teeth are generally ahead of the mandibular teeth in development. Exceptions are the second molars, which generally

are advanced in the mandible, and the lateral incisors and canines, which at times may be ahead in the mandible.

These studies also propose that the lateral incisor, first molar, and canine tend to erupt earlier in the maxilla than in the mandible, compared with the Logan and Kronfeld table, which suggests that eruption in the mandible is generally ahead of that in the maxilla. The ages at which primary teeth erupt are 2 or more months later than those suggested in the Logan and Kronfeld table. The study by Hernández et al.<sup>2</sup> provides confirmation that more recent studies in different white populations have findings similar to those from these classic studies on eruption chronology. These findings are further substantiated by more recent studies. An example of these modifications to the Logan and Kronfeld table may be found in the Dental Growth and Development section of the American Academy of Pediatric Dentistry Reference Manual.<sup>3</sup>

The time of eruption of both primary and permanent teeth can vary greatly and researchers continue to study tooth eruption timing issues such as gender dimorphism<sup>4</sup> and age estimation.<sup>5</sup> Variations of 6 months on either side of the usual eruption date may be considered normal for a given child. A study by Parner et al.<sup>6</sup> compared the well-known general acceleration of the physical development of children over the past century with their own observations of the emergence of permanent teeth. They found that the emergence of permanent teeth has not been subject to a



**TABLE 20.1** Chronology of the Human Dentition

Tooth	Hard Tissue Formation Begins	Amount of Enamel Formed at Birth	Enamel Completed	Eruption	Root Completed
<b>DECIDUOUS DENTITION</b>					
<b>Maxillary</b>					
Central incisor	4 mo in utero	Five-sixths	1½ mo	7½ mo	1½ yr
Lateral incisor	4½ mo in utero	Two-thirds	2½ mo	9 mo	2 yr
Cuspid	5 mo in utero	One-third	9 mo	18 mo	3¼ yr
First molar	5 mo in utero	Cusps united	6 mo	14 mo	2½ yr
Second molar	6 mo in utero	Cusp tips still isolated	11 mo	24 mo	3 yr
<b>Mandibular</b>					
Central incisor	4½ mo in utero	Three-fifths	2½ mo	6 mo	1½ yr
Lateral incisor	4½ mo in utero	Three-fifths	3 mo	7 mo	1½ yr
Cuspid	5 mo in utero	One-third	9 mo	16 mo	3¼ yr
First molar	5 mo in utero	Cusps united	5½ mo	12 mo	2¼ yr
Second molar	6 mo in utero	Cusp tips still isolated	10 mo	20 mo	3 yr
<b>PERMANENT DENTITION</b>					
<b>Maxillary</b>					
Central incisor	3–4 mo		4–5 yr	7–8 yr	10 yr
Lateral incisor	10–12 mo		4–5 yr	8–9 yr	11 yr
Cuspid	4–5 mo		6–7 yr	11–12 yr	13–15 yr
First bicuspid	1½–1¾ yr		5–6 yr	10–11 yr	12–13 yr
Second bicuspid	2–2¼ yr		6–7 yr	10–12 yr	12–14 yr
First molar	At birth	Sometimes a trace	2½–3 yr	6–7 yr	9–10 yr
Second molar	2½–3 yr		7–8 yr	12–13 yr	14–16 yr
Third molar	7–9 yr		12–16 yr	17–21 yr	18–25 yr
<b>Mandibular</b>					
Central incisor	3–4 mo		4–5 yr	6–7 yr	9 yr
Lateral incisor	3–4 mo		4–5 yr	7–8 yr	10 yr
Cuspid	4–5 mo		6–7 yr	9–10 yr	12–14 yr
First bicuspid	1¾–2 yr		5–6 yr	10–12 yr	12–13 yr
Second bicuspid	2¼–2½ yr		6–7 yr	11–12 yr	13–14 yr
First molar	At birth	Sometimes a trace	2½–3 yr	6–7 yr	9–10 yr
Second molar	2½–3 yr		7–8 yr	11–13 yr	14–15 yr
Third molar	8–10 yr		12–16 yr	17–21 yr	18–25 yr

From Kronfeld R: *Bur* 35:18-25, 1935 (based on research by WHG Logan and R Kronfeld); adapted by Kronfeld R, Schour I: *J Am Dent Assoc.* 1939; 26:18-32; further adapted by McCall JO, Wald SS: *Clinical dental roentgenology: technic and interpretation including roentgen studies of the child and young adult.* Philadelphia: WB Saunders; 1940.

similar acceleration; in fact, the mean age of eruption has increased slightly, but only by a few days per year. They conclude that the age of eruption of the permanent teeth is a much more stable phenomenon than other aspects of physical development in children.

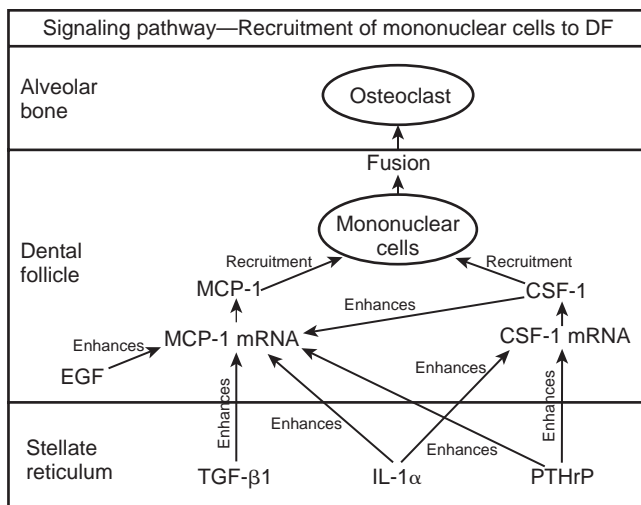
Numerous *in vivo* animal experiments and human radiographic studies have been conducted to further elucidate the process of tooth eruption. Although many theories have been advanced, the factors responsible for the teeth eruption are not fully understood. The factors that have been related to the eruption of teeth include elongation of the root, forces exerted by the vascular tissues around and beneath the root, growth of the alveolar bone, growth of dentin, growth and pull of the periodontal membrane, hormonal influences, presence of a viable dental follicle, pressure from the muscular action, and resorption of the alveolar crest.

A series of experiments by Cahill and Marks<sup>7</sup> established that a viable dental follicle is required for tooth eruption. Further studies resulted in the conclusion that “tooth eruption is a series of metabolic events in the alveolar bone characterized by bone resorption and formation on opposite sides of the dental follicle and the tooth does not contribute to this process, is influenced by pituitary growth hormone and thyroid hormone, and parathyroid hormone–related protein is required for tooth eruption.

Each tooth starts to move toward occlusion at approximately the time of crown completion, and the interval from crown completion and the beginning of eruption until the tooth is in full occlusion is approximately 5 years for permanent teeth.

Many investigators have observed that tooth emergence appeared to be more closely associated with the stage of root formation than with the chronologic or skeletal age of the child. By the time of clinical emergence, approximately three-fourths of root formation has occurred, with the teeth reaching occlusion before the root development is complete.

Demirjian and Levesque<sup>8</sup> presented a large sample of 5437 radiographs from a homogeneous (French-Canadian) population. They used this sample to investigate the gender differences in the development of permanent mandibular teeth from the early stages of calcification to closure of the apex. The analysis of the developmental curves of individual teeth shows a common pattern, namely the similarity in timing between the genders for the early stages of development. For the first stages of crown formation, which they refer to as A, B, and C, there was no difference between boys and girls in the chronology of dental calcification in the majority of teeth. For the fourth stage, D, which represents the completion of crown development, girls were more advanced than boys by an average of 0.35 year for four teeth. For the stages of root development, the mean difference between the genders for all teeth was 0.54 year; the



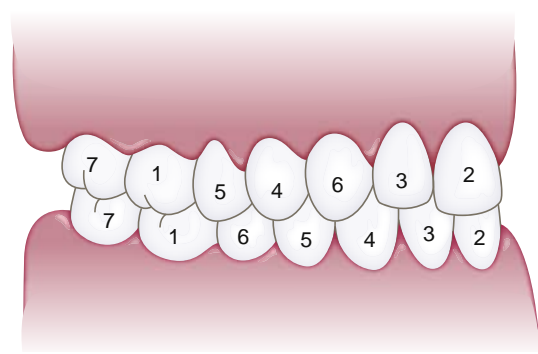
**Fig. 20.1** Paracrine signaling between the stellate reticulum and dental follicle (DF) results in the synthesis and secretion of chemotactic molecules, colony-stimulating factor 1 (CSF-1), and monocyte chemoattractant protein 1 (MCP-1) for the recruitment of mononuclear cells. EGF, epidermal growth factor; *IL-1 $\alpha$* , interleukin 1 $\alpha$ ; mRNA, messenger RNA; PTHrP, parathyroid hormone-related peptide; TGF- $\beta$ 1, transforming growth factor  $\beta$ 1. (From Wise GE et al: *Crit Rev Oral Biol Med*. 2002; 13(14):323-355.)

largest difference was for the canine (0.90 year). Analysis of the data from Demirjian and Levesque<sup>8</sup> show the importance of sexual dimorphism during the period of root development rather than during the period of crown development.

The tooth eruption process is clearly complex, and many different mechanisms are undoubtedly involved. Some of the leading scientists who are contributing to a better understanding of the tooth eruption process have written review articles to help consolidate the facts and theories associated with this process. A review article by Wise et al.<sup>9</sup> focuses on the molecular signals that initiate tooth eruption. The researchers state that tooth eruption is a complex and tightly regulated process that involves cells of the tooth organ and the surrounding alveolus. Mononuclear cells (osteoclast precursors) must be recruited into the dental follicle before the onset of eruption. These cells, in turn, fuse to form osteoclasts that resorb alveolar bone, creating an eruption pathway for the tooth to exit its bony crypt. In recent years, knowledge of the biology of tooth eruption has greatly increased. What has emerged is the realization that interactions of osteoblasts, osteoclasts, and dental follicles involve a complex interplay of regulatory genes that encode various transcription factors, proto-oncogenes, and soluble factors. For the clinician faced with treating both simple and complex dental complications arising from abnormal tooth eruption, knowledge of the basic molecular mechanisms involved is essential (Fig. 20.1). Reviews by Marks and Schroeder<sup>10</sup> and by Arid et al.<sup>11</sup> analyze experimental data to identify the basic principles of tooth eruption and offer guiding theories of the process.

### INFLUENCE OF PREMATURE LOSS OF PRIMARY MOLARS ON ERUPTION TIME OF THEIR SUCCESSORS

After reviewing the records of children in the Burlington study who had undergone unilateral extraction of primary



**Fig. 20.2** Desirable eruption sequence for the permanent teeth.

molars, Posen<sup>12</sup> came to the following conclusions: (1) eruption of the premolar teeth is delayed in children who lose primary molars at 4 or 5 years of age and before; (2) if extraction of the primary molars occurs after the age of 5 years, there is a decrease in the delay of premolar eruption; and (3) at 8, 9, and 10 years of age, premolar eruption resulting from premature loss of primary teeth is greatly accelerated. Hartsfield<sup>13</sup> stated that premature loss of teeth associated with systemic disease usually results from some change in the immune system or connective tissue. The most common of these conditions appears to be hypophosphatasia and early-onset periodontitis.

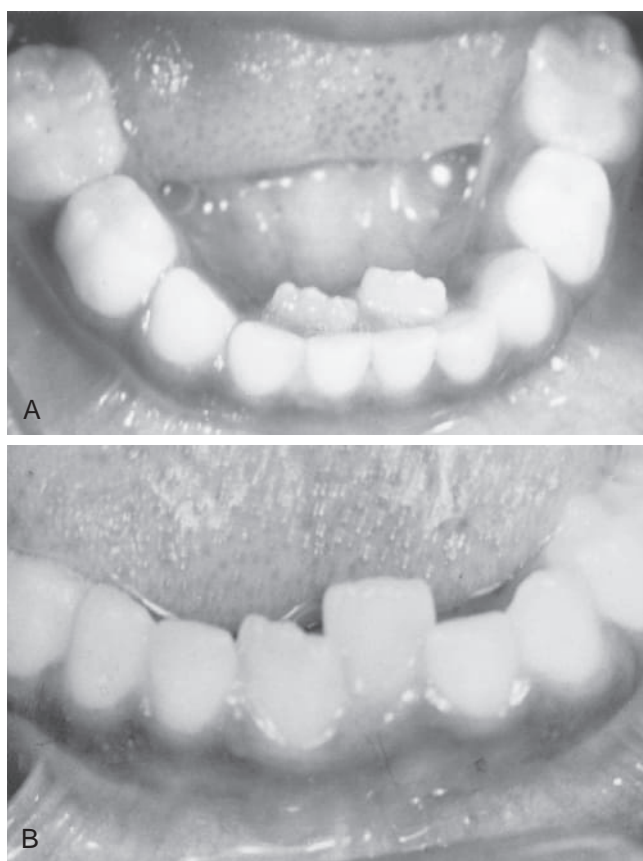
### VARIATIONS IN SEQUENCE OF ERUPTION

The mandibular first permanent molars are often the first permanent teeth to erupt. They are quickly followed by the mandibular central incisors. Previous studies found little or no clinical significance to the eruption of the incisors before the molars.

After analyzing serial records of 16,000 children in Newburgh and Kingston, New York, Carlos and Gittelsohn<sup>14</sup> concluded that the average eruption time of the mandibular central incisors was earlier than that of the first molars by about 1½ months in both boys and girls. Of considerable interest was the gender difference in the eruption sequence of permanent teeth. The mandibular canine erupted before the maxillary and mandibular first premolars in girls. In boys, the eruption order was reversed—the maxillary and mandibular first premolars erupted before the mandibular canine.

Moyers<sup>15</sup> stated that the most common sequence of eruption of permanent teeth in the mandible is first molar, central incisor, lateral incisor, canine, first premolar, second premolar, and second molar. The most common sequence for the eruption of the maxillary permanent teeth is first molar, central incisor, lateral incisor, first premolar, second premolar, canine, and second molar (Fig. 20.2). He identified these common sequences in each arch to be favorable for maintaining the length of the arches during the transitional dentition.

It is desirable that the mandibular canine erupt before the first and second premolars. This sequence aids in maintaining adequate arch length and in preventing lingual tipping of the incisors, which not only causes a loss of arch length but also allows an increased overbite to develop. An abnormal lip musculature or an oral habit that causes a greater

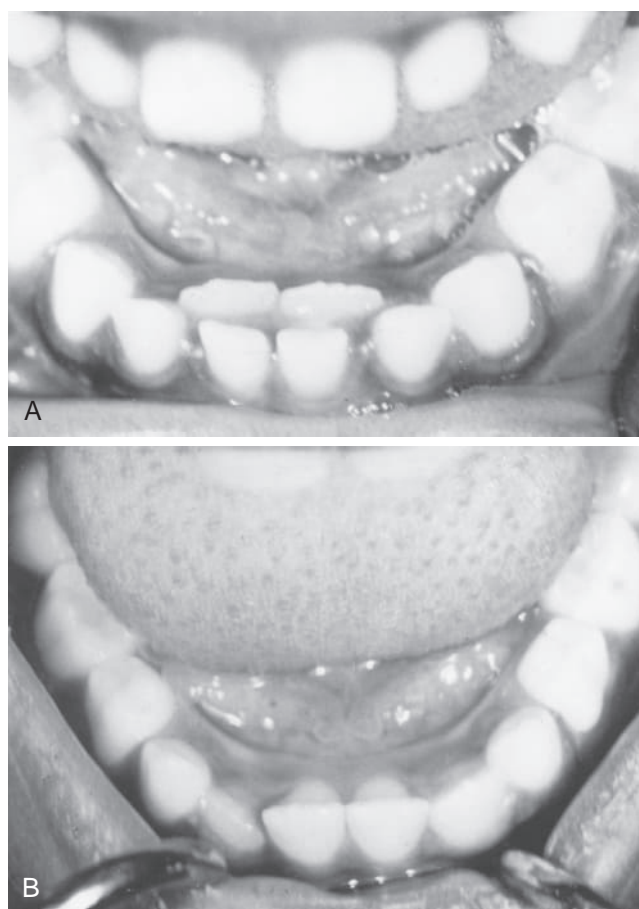


**Fig. 20.3** (A) The permanent central incisors are erupting lingual to the retained primary central incisors, which were extracted. (B) The arch length is inadequate to accommodate the permanent incisors. However, they have moved forward into a more favorable position as a result of the force exerted on them by the tongue.

force on the mandibular incisors than can be compensated for by the tongue allows the anterior segment to collapse. Therefore, use of a passive lingual arch appliance is often indicated when the primary canines have been lost prematurely or when the sequence of eruption is undesirable.

A deficiency in arch length can occur if the mandibular second permanent molar develops and erupts before the second premolar. Eruption of the second permanent molar first encourages mesial migration or tipping of the first permanent molar and encroachment on the space needed for the second premolar. In the maxillary arch, the first premolar ideally should erupt before the second premolar, and they should be followed by the canine. The untimely loss of primary molars in the maxillary arch, which allows the first permanent molar to drift and tip mesially, results in the permanent canine being blocked out of the arch, usually to the labial side.

The position of the developing second permanent molar in the maxillary arch and its relationship to the first permanent molar should be given special attention. Its eruption before the premolars and canine can cause a loss of arch length, just as in the mandibular arch. The eruption of the maxillary canine is often delayed because of an abnormal position or deviations in the eruption path. This delayed eruption should be considered along with its possible effect on the alignment of the maxillary teeth. The significance of the sequence of the eruption of permanent teeth is considered further in [Chapter 23](#).



**Fig. 20.4** (A) Primary teeth are desirably spaced with sufficient room for the permanent central incisors. However, the permanent teeth erupted lingually to the primary teeth. (B) Extraction of the primary central incisors resulted in a desirable positioning of the permanent teeth, but given enough time this condition probably would have been self-correcting.

Finally, deviations from accepted norms of eruption time are often observed in clinical practice. Premature eruption has been noted, but delayed tooth eruption is the most commonly encountered deviation from normal eruption time

## Lingual Eruption of Mandibular Permanent Incisors

The eruption of mandibular permanent incisors lingual to retained primary incisors is often a source of concern for parents. The primary teeth may have undergone extensive root resorption and may be held only by soft tissues. In other instances, the roots may not have undergone normal resorption and the teeth remain solidly in place. It is common for mandibular permanent incisors to erupt lingually, and this pattern should be considered essentially normal. It is seen both in patients with an obvious arch length inadequacy ([Fig. 20.3](#)) and in those with a desirable amount of spacing of the primary incisors ([Fig. 20.4](#)). In either case, the tongue and continued alveolar growth seem to play important roles in influencing the permanent incisors into a more normal position with time. Although there may be insufficient room in the arch for the newly erupted permanent



tooth, its position will improve over several months. In some cases, there is justification for removal of the corresponding primary tooth. Extraction of other primary teeth in the area is not recommended because it will only temporarily relieve the crowding and may even contribute to the development of a more severe arch length inadequacy. One common argument for primary lower incisor extraction is that incisor irregularity can lead to anterior coronal caries. However, while agreeing that there is a well-established effect of incisor crowding on plaque retention, Alsulaiman et al.<sup>16</sup> did not find any increase in the anterior coronal caries prevalence to be associated with incisor irregularity.

Gellin<sup>17</sup> has emphasized the anxiety created when parents discover a double row of teeth. He suggested that if the condition is identified before 7½ years of age, it is unnecessary to subject the child to the trauma of removing the primary teeth because the problem almost always self-corrects within a few months. However, he warned that when lingually erupted permanent mandibular incisors are seen in an older child and the radiograph shows no root resorption of the primary teeth, self-correction has not been achieved and the corresponding primary teeth should be removed.

Gellin and Haley<sup>18</sup> conducted a clinical study to determine whether removal of the corresponding primary tooth is necessary when the lingual eruption pattern of the mandibular permanent incisor is identified. They monitored 57 lingually positioned mandibular permanent central or lateral incisors in 44 children (22 boys and 22 girls). The children were selected for the study if they had one or more permanent mandibular incisors erupting immediately lingual to the corresponding primary incisor. Other inclusion criteria were the presence of both primary mandibular canines, the absence of any other anomalies of the mandibular primary or permanent incisors, and the absence of severe crowding of the permanent mandibular incisors characterized by eruption of the lateral incisors directly behind the central incisors. The mean age of the children at their first observation was 6 years 4 months (range, 4 years 10 months to 8 years 8 months). Of the permanent teeth studied, 47 were central incisors and 10 were lateral incisors.

In all cases, labial migration occurred naturally and extraction of the corresponding primary incisor was unnecessary. Gellin and Haley<sup>18</sup> reported that spontaneous correction of lingually erupted mandibular permanent central incisors occurred by age 8 years 2 months in 95% of the cases that met the criteria of their study. They also observed that spontaneous correction of lingually erupted lateral incisors occurred by at least 8 years 4 months of age. Although the sample of the lateral incisors was too small for specific conclusions to be drawn, correction occurred in all cases and central incisors migrated labially at an earlier age. Gellin and Haley<sup>18</sup> recommended a conservative approach of waiting and periodic observation to spare the child a surgical procedure. They suggested that if labial migration of the permanent incisor has not occurred by 8 years 2 months for central incisors and 8 years 4 months for lateral incisors, over-retention of the primary incisor should be suspected, and removal of the primary tooth considered. However, they recommended removal only if the primary incisor remained firm and the root had failed to resorb. These findings and suggestions have been further substantiated by more recent studies.

We recognize that spontaneous correction of lingually erupted permanent incisors is likely to occur given enough time, particularly in cases in which there is not severe crowding. A watchful waiting approach may be justified, especially when the patient is first seen in the dentist's office for this specific problem. Removal of a tooth during the first dental appointment of a child 6–8 years old probably compromises the dentist's ability to develop rapport with the child. However, the extraction procedure in such cases is quite simple, and we believe there may be many times when it is appropriate. The parents' feelings should not be ignored in the decision; even a 95% chance that correction will occur may not satisfy all parents. The dentist may find that some dental patients prefer to have the primary tooth extracted and the problem laid to rest. Although monitoring the condition without extraction is acceptable under the conditions outlined by Gellin and Haley,<sup>18</sup> there are no known significant contraindications to early removal of the offending primary incisor even in spaced dentitions if specific conditions warrant its consideration.

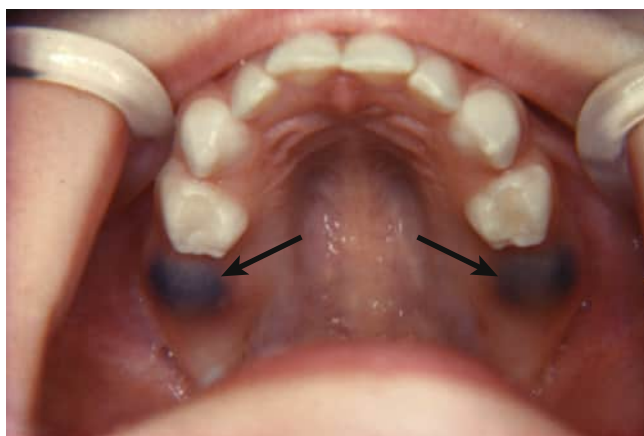
Even when mandibular permanent incisors erupt uneventfully, they often appear rotated and staggered in position; however, the molding action of the tongue and lips may improve their relationship within a few months.

## Teething and Difficult Eruption

In most children, the eruption of primary teeth is preceded by increased salivation, and the child will want to put the hand and fingers into the mouth—these observations may be the only indication that the teeth will soon erupt.

Some young children become restless and fretful during the time of eruption of the primary teeth. Many conditions including croup, diarrhea, fever, convulsions, primary herpetic gingivostomatitis, and even death have been incorrectly attributed to eruption. In the 19th century, complications from teething were believed to be a frequent cause of infant mortality.

Illingworth<sup>19</sup> performed a thorough search of the world literature and failed to produce evidence that teething causes fever, convulsions, bronchitis, or diarrhea. His findings were supported by Tasanen's<sup>20</sup> unique study of teething, in which 192 tooth eruptions were observed in 126 infants and 107 control children. All the babies were seen on the day of tooth eruption, and records were kept of the temperature, incidence of infection, erythrocyte sedimentation rate, white blood cell count, behavior (including sleep), color of the mucosa, sensitivity of the tissue covering the erupting tooth, and pain resulting from pressure on the tooth. Tasanen<sup>20</sup> concluded that teething does not increase the incidence of infection, does not cause any rise in temperature, erythrocyte sedimentation rate, or white blood cell count, and does not cause diarrhea, cough, sleep disturbance, or rubbing of the ear or cheek, but that it does cause daytime restlessness, an increase in the amount of finger sucking or rubbing of the gum, an increase in drooling, and possibly some loss of appetite. In one-third of the children, there was no change in the color of the mucosa in the area of the erupting tooth; in one-third children, the change was



**Fig. 20.5** Eruption hematomas (arrows) have developed before the eruption of the second primary molars.

slight; and in the remaining third, there was a pronounced change in the mucosa, often with small hemorrhages.

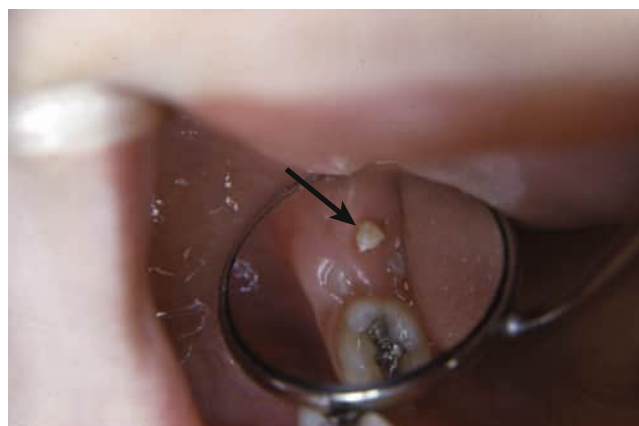
A later study of 46 healthy infants conducted by Jaber et al.<sup>21</sup> demonstrated a small increase in body temperature in 20 (43%) of the infants on the day of emergence of their first tooth. However, the authors emphasized a danger in attributing fever to teething. Other studies have confirmed these results.<sup>22</sup> Serious mistakes have been made in the health care of infants and toddlers when their symptoms were ascribed to teething without a thorough diagnostic evaluation, which resulted in the overlooking of significant systemic disturbances. Swann<sup>23</sup> observed 50 children who were hospitalized after parents or physicians initially attributed their symptoms to teething. After a careful medical evaluation, an organic cause of illness was identified in 48 of the 50 patients.

Because the eruption of teeth is a normal physiologic process, the association with fever and systemic disturbances is not justified. A fever or respiratory tract infection during this time should be considered coincidental to the eruption process rather than related to it.

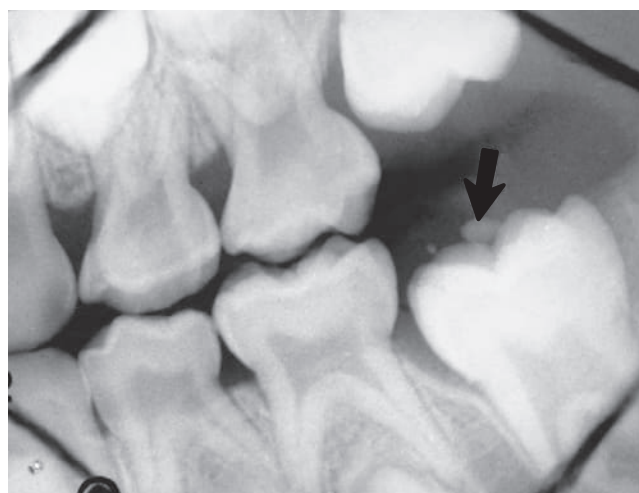
Inflammation of the gingival tissues before complete emergence of the crown may cause a temporary painful condition that subsides within a few days. The surgical removal of the tissue covering the tooth to facilitate eruption is not indicated. If the child is having moderate difficulty, the parent may use a clean moistened finger to massage the gingiva in the area of the erupting tooth to help ease the discomfort. The child may also suck or chew on a clean cloth moistened with cold water under direct supervision. A teething ring of appropriate size and without a liquid filler is also recommended. The use of any type of pain medication, whether topical or systemic, should not be given without consultation with the patient's pediatrician or dentist.

### ERUPTION HEMATOMA (ERUPTION CYST)

A bluish-purple elevated area of tissue, commonly called an eruption hematoma, occasionally develops a few weeks before the eruption of a primary or permanent tooth. The blood-filled cyst is most frequently seen in the primary second molar or the first permanent molar region. This fact substantiates the belief that the condition develops



**Fig. 20.6** Arrow points to an eruption sequestrum in a girl aged 5 years 11 months. It appears clinically as a white spicule of hard tissue overlying the central fossa of a mandibular first permanent molar, which is just beginning to erupt through the mucosa. (Courtesy Drs. Paul E. Starkey and William G. Shafer.)



**Fig. 20.7** Radiographic appearance of an eruption sequestrum (arrow) in a child aged 6 years 9 months. No treatment is required unless symptoms develop. (Courtesy Drs. Paul E. Starkey and William G. Shafer.)

as a result of trauma to the soft tissue during function (Fig. 20.5). Usually the tooth breaks through the tissue within a few days, and the hematoma subsides. Because the condition is almost always self-limiting, treatment of an eruption hematoma is rarely necessary. However, surgical uncovering of the crown may occasionally be justified.

When the parents discover an eruption hematoma, they may fear that the child has a serious disease such as a malignant tumor. The dentist must be understanding and sensitive to their anxiety while reassuring them that the lesion is not serious.

### ERUPTION SEQUESTRUM

The eruption sequestrum is occasionally seen in children at the time of the eruption of the first permanent molar (Figs. 20.6 and 20.7). Starkey and Shafer<sup>24</sup> have described the sequestrum as a tiny spicule of nonviable bone overlying the crown of an erupting permanent

molar just before or immediately after the emergence of the tips of the cusps through the oral mucosa. Case studies have reported that eruption sequestra are composed of dentin and cementum as well as a cementum-like material formed within the follicle. These findings have been confirmed by other studies. Maki et al.<sup>25</sup> have also reported that the ratio of calcium to phosphorus in their case study was higher than that seen in the normal osseous tissue. These various reports suggest that eruption sequestra may develop from either osteogenic or odontogenic tissue. Regardless of its origin, the hard tissue fragment is generally overlying the central fossa of the associated tooth, embedded, and contoured within the soft tissue. As the tooth erupts and the cusps emerge, the fragment sequesters.

Eruption sequestra are usually of little or no clinical significance. It is probable that some of these sequestra spontaneously resolve without noticeable symptoms. However, after an eruption sequestrum has surfaced through the mucosa, it may easily be removed if it is causing local irritation. The base of the sequestrum is often still well embedded in the gingival tissue when it is discovered, and application of a topical anesthetic or infiltration of a few drops of a local anesthetic may be necessary to avoid discomfort during removal.

## ECTOPIC ERUPTION

Arch length inadequacy, tooth mass redundancy, or various local factors may influence a tooth to erupt or try to erupt in an abnormal position. Occasionally, this condition may be so severe that actual transposition of teeth occurs. Several problems associated with the ectopic eruption of teeth and the management of these problems are presented in [Chapter 23](#).

## Natal and Neonatal Teeth

The prevalence of natal teeth (teeth present at birth) and neonatal teeth (teeth that erupt during the first 30 days) is low. Leung<sup>26</sup> conducted a retrospective study of hospital records of 50,892 infants born in Calgary, Alberta (Canada). These records identified 15 infants found to have natal teeth—a prevalence of 1 in 3392 births. In another survey, Kates et al.<sup>27</sup> found the calculated prevalence of natal teeth to be 1 in 3667 among 11,000 infants when the survey information was obtained indirectly; however, in a group of 7155 infants actually examined, the prevalence was found to be 1 in 716.

Zhu and King<sup>28</sup> conducted an extensive review of the literature of reported cases of natal and neonatal teeth. They found that about 85% of natal or neonatal teeth are mandibular primary incisors, and only small percentages are supernumerary teeth. It is common for natal and neonatal teeth to occur in pairs. Natal and neonatal molars are rare; Zhu and King<sup>28</sup> found only 20 reported cases dating from 1897. They also reported that most premature tooth eruption seems to occur in otherwise normal infants, with or without a family history of the condition. In some infants, however, the presence of such teeth may be a localized manifestation of various environmental

causes or an underlying syndrome, with the most common being Ellis-van Creveld syndrome, Hallermann-Streiff syndrome, Pierre Robin syndrome, and Sotos syndrome. This underscores the importance of thorough diagnostic evaluations of infants with natal or neonatal teeth. It has been reported that less than 10% of neonatal teeth are supernumerary.<sup>29</sup>

Spouge and Feasby<sup>30</sup> believe that the terms *natal teeth* and *neonatal teeth* constitute a relatively artificial distinction and should be further qualified to provide a more practical clinical meaning. They suggested that the terms *mature* and *immature* are more in keeping with the various prognoses associated with such teeth.

Most studies suggest that the etiology for the premature eruption or the appearance of natal and neonatal teeth is multifactorial. A possible factor involving the early eruption of primary teeth seems to be familial, i.e., due to inheritance as an autosomal dominant trait.

Many parents volunteer the information that their teeth erupted early, and studies have found that 10% to 15% of the children with natal or neonatal teeth had parents, siblings, or other near relatives with a history of such teeth.

A radiograph could be made to determine the amount of root development and the relationship of a prematurely erupted tooth to its adjacent teeth. One of the parents can hold the x-ray film in the infant's mouth during the exposure.

Most prematurely erupted teeth (immature type) are hypermobile because of limited root development. Some teeth may be mobile to the extent that there is danger of displacement of the tooth and possible aspiration, in which case the removal of the tooth is indicated.<sup>31</sup> In some cases, the sharp incisal edge of the tooth may cause laceration of the lingual surface of the tongue (Riga-Fede disease), and the tooth may have to be removed.

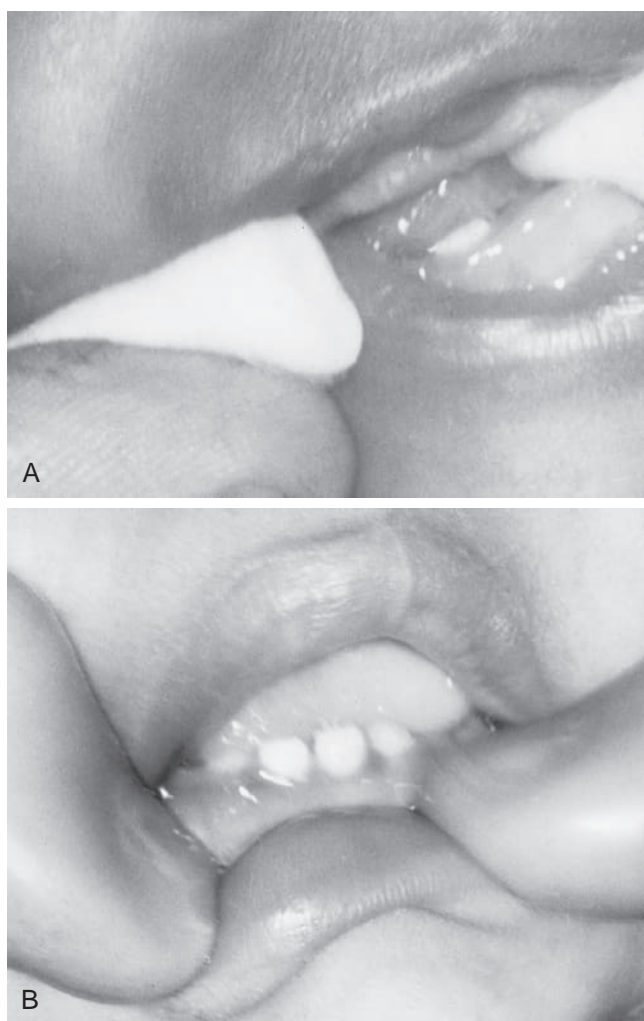
Zhu and King<sup>28</sup> were unable to find any reported cases of aspirated natal or neonatal teeth. Extraction of such a tooth, if necessary, is a simple procedure but is emotionally difficult for the parents. After the tooth is removed, careful curettage of the socket is indicated in an attempt to remove any odontogenic cellular remnants that may otherwise be left in the extraction site. Such retained remnants may subsequently develop atypical toothlike structures that require additional treatment.

The preferable approach, however, is to leave the tooth in place and to explain to the parents the desirability of maintaining this tooth in the mouth because of its importance in the growth and uncomplicated eruption of the adjacent teeth. Within a relatively short time, the prematurely erupted tooth will become stabilized, and the other teeth in the arch will erupt ([Fig. 20.8](#)).

Eruption of teeth during the neonatal period presents less of a problem. These teeth can usually be maintained even though root development is limited ([Figs. 20.9 and 20.10](#)).

A retained natal or neonatal tooth may cause difficulty for a mother who wishes to breast-feed her infant. If breast-feeding is too painful for the mother initially, the use of a breast pump and bottling of the milk are recommended. However, the infant may be conditioned not to "bite" during suckling in a relatively short time if the mother persists with breast-feeding. It seems that the infant senses the mother's discomfort and learns to avoid causing it.





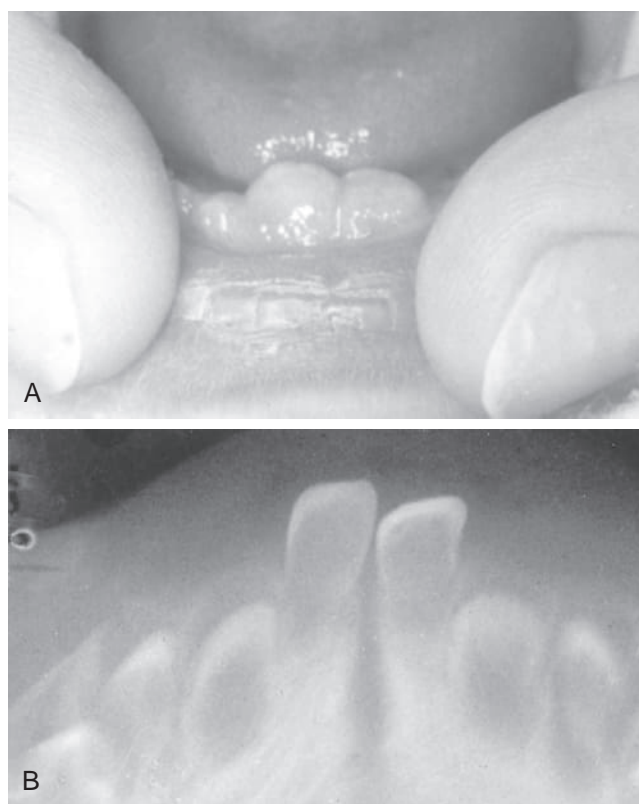
**Fig. 20.8** (A) Natal tooth in a 3-day-old infant. Because the tooth was not excessively mobile, there was no reason to recommend its removal. (B) Within 2 months, other teeth in the mandibular anterior region erupted. The ungloved fingers in the photographs are those of the infant's parent.

## Epstein Pearls, Bohn Nodules, and Dental Lamina Cysts

On rare occasions, small, white or grayish-white lesions on the alveolar mucosa of the newborn may be incorrectly diagnosed as natal teeth. The lesions are usually multiple but do not increase in size (Fig. 20.11). No treatment is indicated because the lesions are spontaneously shed a few weeks after birth.

Fromm<sup>32</sup> reported that clinically visible cysts were found in 1028 of 1367 newborn infants. He noted and classified the following three types of inclusion cysts:

1. Epstein pearls are formed along the midpalatine raphe. They are considered remnants of epithelial tissue trapped along the raphe as the fetus grew.
2. Bohn nodules are formed along the buccal and lingual aspects of the dental ridges and on the palate away from the raphe. The nodules are considered remnants of salivary gland tissue and are histologically different from Epstein pearls.



**Fig. 20.9** (A) Parents of a 3-week-old infant were concerned about the elevated mass of tissue on the mandibular ridge. (B) Radiograph revealed two primary central incisors that would soon erupt. The ungloved fingers in the photograph are those of the infant's parent.

3. Dental lamina cysts are found on the crests of the maxillary and mandibular dental ridges. The cysts apparently originated from remnants of the dental lamina.

These findings are supported by the work of Neville and associates.<sup>33</sup>

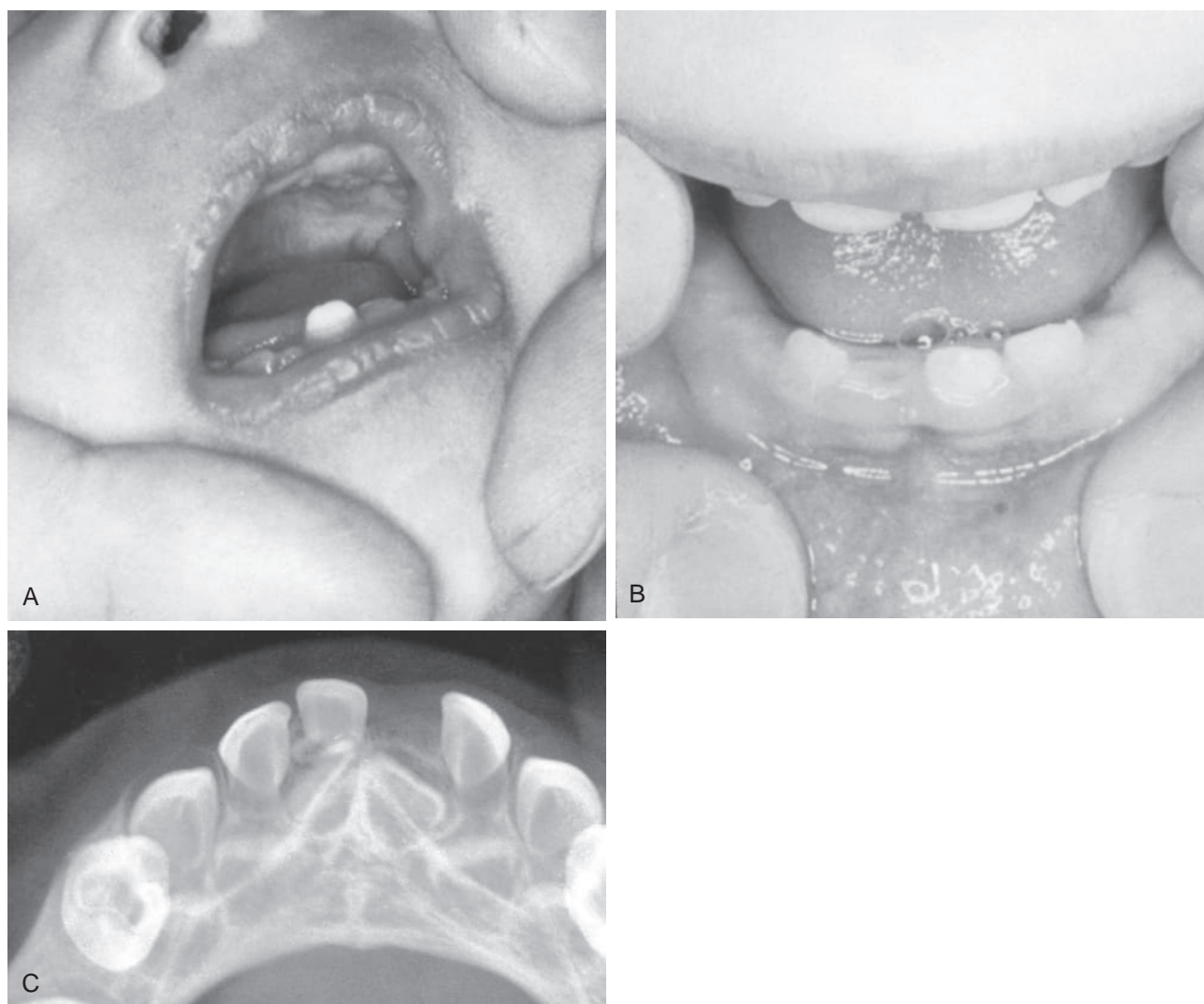
## Local and System Factors that Influence Eruption

### ANKYLOSED TEETH

The problem of ankylosed primary molars deserves much attention by dentists. Application of the term *submerged molar* to this condition is inaccurate, even though the tooth may appear to be submerging into the mandible or maxilla. This misconception results from the fact that the ankylosed tooth is in a state of static retention, whereas in the adjacent areas, eruption and alveolar growth continue. The term *infraocclusion*, although commonly used today, is not preferable to ankylosis in the authors' opinions.

Henderson<sup>34</sup> noted that ankylosis should be considered an interruption in the rhythm of eruption and that a patient who has one or two ankylosed teeth is more likely to have other teeth become ankylosed.

The mandibular primary molars are the teeth most often observed to be ankylosed (Figs. 20.12 and 20.13). In unusual cases, all the primary molars may become firmly attached to the alveolar bone before their normal exfoliation



**Fig. 20.10** (A) Eruption of one of the primary central incisors occurred at 4 weeks of age. The tooth was mobile because of limited root formation, but it was not extracted. (B) One of the prematurely erupted central incisors was subsequently lost as the result of a fall, but the other was retained. (C) Dilacerated root formation on one of the neonatal teeth. The ungloved fingers in the photographs are those of the infant's parent.

time. Ankylosis of the anterior primary teeth does not occur unless there has been a trauma.

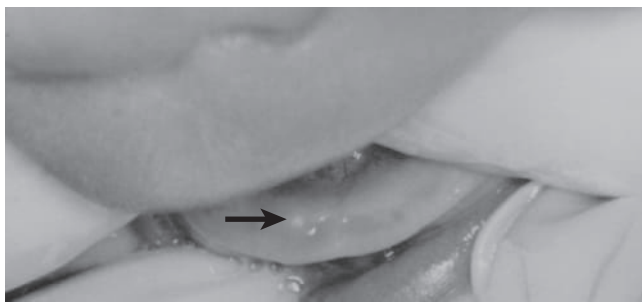
The cause of ankylosis in the primary molar areas is unknown, but at least three theories have been proposed. The observation of ankylosis in several members of the same family lends support to the theory that it follows a familial pattern. Studies have reported that the condition occurs more frequently among siblings of children with the characteristics. The occurrence is noted to have a familial tendency and is probably not a gender-linked trait. Investigators have observed the prevalence of ankylosis to be much lower among black children than among white children.

Darling and Levers<sup>35</sup> observed that, in a group of children with 108 ankylosed teeth, 21 of the affected primary teeth had no permanent successors. Others also reported a higher prevalence of developmentally absent premolar teeth in patients with ankylosis, suggesting that there is a relationship between the congenital absence of permanent teeth and ankylosed primary teeth. Steigman et al.<sup>36</sup> have

discounted this relationship. Based on observation and a careful review of the literature, they reported that there appears to be no causal relationship between ankylosed precursors and the congenital absence of their successors.

Normal resorption of the primary molar begins on the inner or lingual surfaces of the roots. The resorption process is not continuous but is interrupted by periods of inactivity or rest. A reparative process follows periods of resorption. In the course of this reparative phase, a solid union often develops between the bone and the primary tooth. This intermittent resorption and repair may explain the various degrees of firmness of the primary teeth before their exfoliation. Extensive bony ankylosis of the primary tooth may prevent normal exfoliation and the eruption of the permanent successor.

Ankylosis of the primary molar to the alveolar bone does not usually occur until after its root resorption begins. If ankylosis occurs early, eruption of the adjacent teeth may progress enough that the ankylosed tooth is far below the normal plane of occlusion and may even be partially



**Fig. 20.11** Dental lamina cyst (arrow). No treatment is indicated; such lesions disappear within a few weeks after birth.

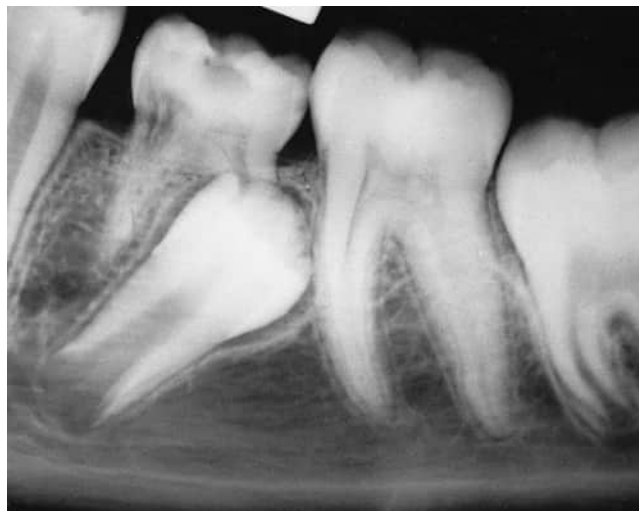covered with soft tissue (Fig. 20.14). An epithelium-lined track, however, will extend from the oral cavity to the tooth. Ankylosis may occasionally occur even before the eruption and complete root formation of the primary tooth (Fig. 20.15). Tsukamoto and Braham<sup>37</sup> reported a case of apparent early ankylosis of a mandibular second primary molar that was not diagnosed until the patient was 10 years of age, at which time the succedaneous second premolar was lying malposed but occlusal to the unerupted primary molar. Ankylosis can also occur late in the resorption of the primary roots and even then can interfere with the eruption of the underlying permanent tooth (Fig. 20.16).

The diagnosis of an ankylosed tooth is not difficult to make. Because eruption has not occurred and the alveolar process has not developed in normal occlusion, the opposing molars in the area seem to be out of occlusion. The ankylosed tooth is not mobile even in cases of advanced root resorption. Ankylosis can be partially confirmed by tapping the suspected tooth and an adjacent normal tooth with a blunt instrument and comparing the sounds. The ankylosed tooth will have a solid sound, whereas the normal tooth will have a cushioned sound because it has an intact periodontal membrane that absorbs some of the shock of the blow.

The radiograph is often a valuable diagnostic aid. A break in the continuity of the periodontal membrane, indicating an area of ankylosis, may even be evident radiographically.

In the management of an ankylosed tooth, early recognition and diagnosis are extremely important. The eventual treatment may involve surgical removal (Fig. 20.17). However, unless a caries problem is unusual or loss of arch length is evident, the dentist may choose to keep the tooth under observation. At some future time, a tooth that is definitely ankylosed may undergo root resorption and be normally exfoliated. When patient cooperation is good and recall periods are regular, a watchful waiting approach is best.

Belanger et al.<sup>38</sup> reported a case in which early ankylosis of even a mandibular second primary molar spontaneously resolved. The tooth was discovered to be unerupted in an otherwise complete primary dentition in occlusion at 3 years of age. The tooth remained in its ankylosed condition until the adjacent first permanent molar began erupting through the gingival tissue. By 6 years 9 months of age, the primary molar had erupted into functional occlusion, and a normal-appearing periodontal ligament



**Fig. 20.12** The second primary molar is ankylosed and below the normal plane of occlusion. There is evidence of root resorption and deposition of bone into the resorbed areas.

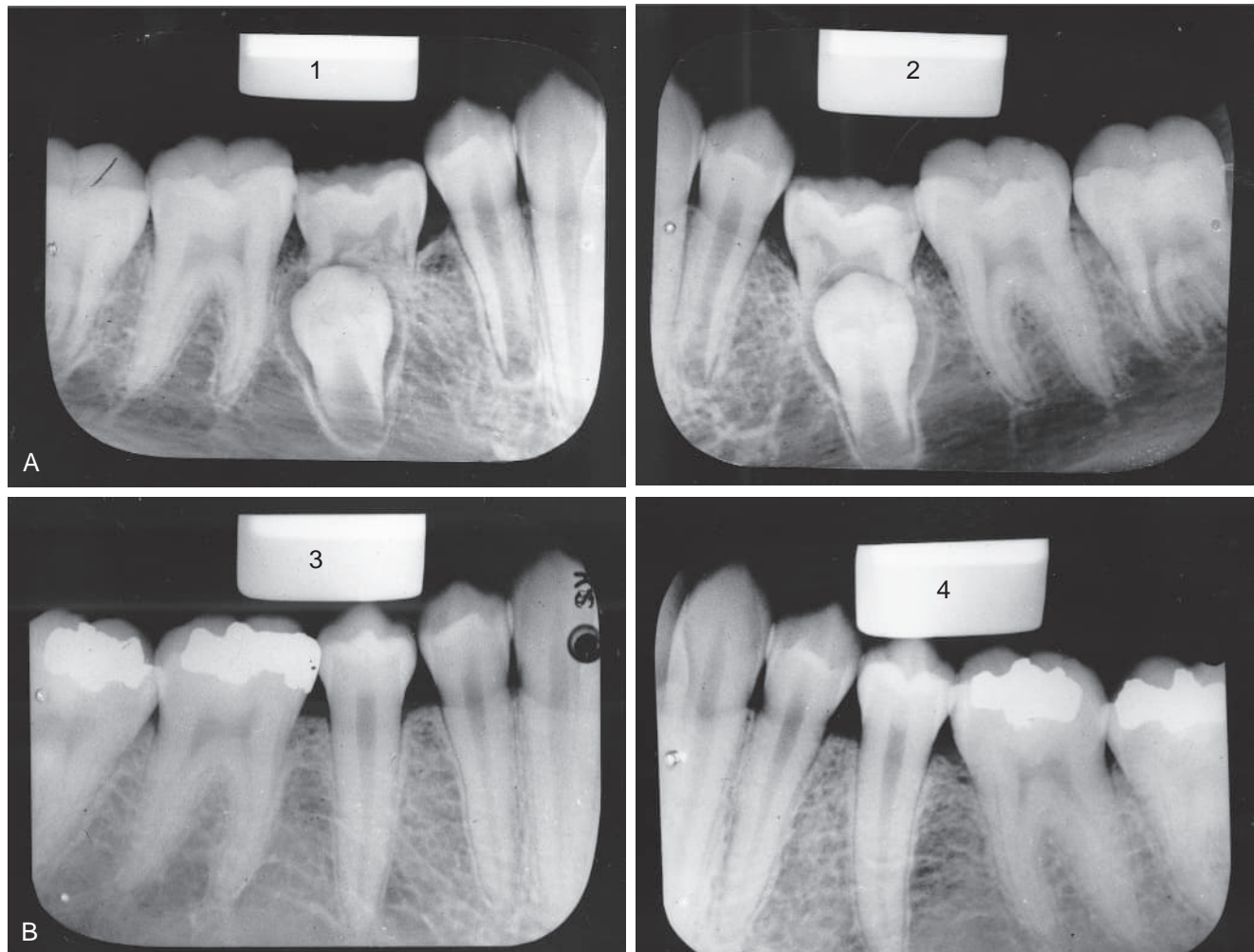
space could be seen radiographically even though no space was previously apparent in the furcation. Tieu et al.<sup>39</sup> present an excellent systematic review of the management of ankylosed primary molars with premolar successors.

### ANKYLOSIS OF PRIMARY MOLARS WITH ABSENCE OF PERMANENT SUCCESSORS

Kurol and Thilander<sup>40</sup> emphasized the importance of the presence of a permanent successor for normal exfoliation of a primary molar. In their longitudinal study, no ankylosed primary molars without permanent successors were found to exfoliate spontaneously. However, very slow root resorption was observed for most of the ankylosed teeth.

Messer and Cline<sup>41</sup> observed that failure to carry out timed extraction of severely infraoccluded molars results in reduced alveolar bone support for the premolars. However, Kurol and Olson<sup>42</sup> suggest that infraocclusions and ankylosis of primary molars do not constitute a general risk for future alveolar bone loss mesial to the first permanent molars. In their study of 119 infraoccluded primary molars next to permanent first molars, all but two of the first permanent molars showed a normal alveolar bone level mesially. Therefore the general treatment recommendation to await normal exfoliation and eruption of successors remains valid in their opinion. They suggest that, in patients in whom there is an abnormality associated with a succedaneous tooth (e.g., agenesis, ectopic eruption), early intervention is most likely required. In situations in which permanent successors of ankylosed primary molars are missing, attempts have been made to establish functional occlusion using stainless-steel crowns, overlays, or bonded composite resins on the affected primary molars. Currently, bonded restorations would be the preferred choice. This treatment is successful only if maximum eruption of permanent teeth in the arch has occurred. If the adjacent teeth are still in a state of active eruption, they will soon bypass the ankylosed tooth (Fig. 20.18).





**Fig. 20.13** (A) Bilateral ankylosis of second primary molars. (B) The ankylosed molars were eventually shed, and the second premolars erupted into good occlusion. Frequently, the ankylosed teeth must be removed surgically.

### ANKYLOSED PERMANENT TEETH

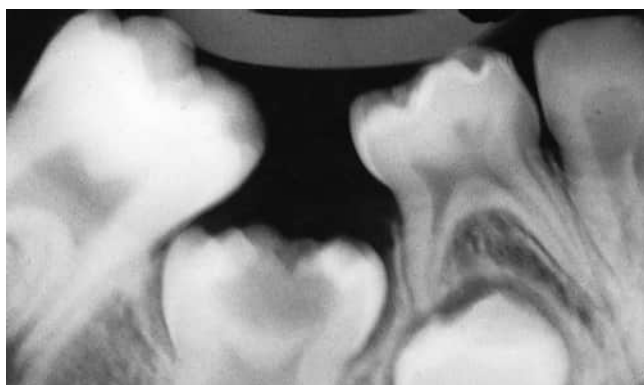
The incomplete eruption of a permanent molar may be related to a small area of root ankylosis. The removal of soft tissue and bone covering the occlusal aspect of the crown should be attempted first, and the area should be packed with surgical cement to provide a pathway for the developing permanent tooth (Fig. 20.19). If the permanent tooth is exposed in the oral cavity and at a lower occlusal plane than the adjacent teeth, ankylosis is the probable cause. In a systematic review of “Primary Failure of Eruption,” or PFE, Hanisch et al.<sup>43</sup> define PFE as a rare disease (prevalence 0.06%) with incomplete tooth eruption despite the presence of a clear eruption pathway and key manifestations involving partial or complete noneruption of initially non-ankylosed teeth due to a disturbed eruption mechanism and resulting in a posterior unilateral/bilateral open bite. Authors have described a luxation technique effective in breaking the bony ankylosis. If the rocking technique is not immediately successful, it should be repeated in 6 months. A delay in treatment may result in a permanently ankylosed molar (Fig. 20.20).

Unerupted permanent teeth may become ankylosed by inostosis of enamel. According to Franklin,<sup>44</sup> the process

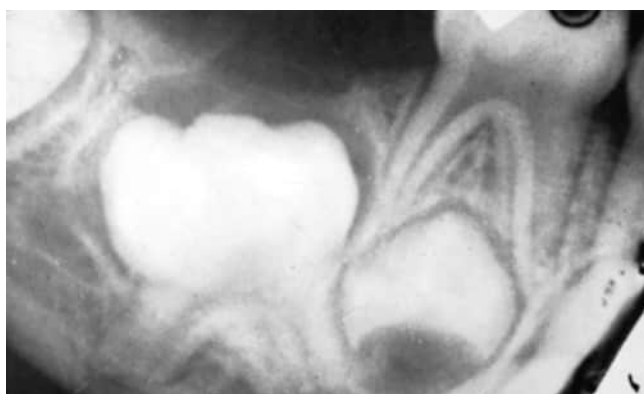follows the irritation of the follicular or periodontal tissue resulting from chronic infection. The close association of an infected apex with an unerupted tooth may give rise to the process. In the unerupted tooth, enamel is protected by enamel epithelium. The enamel epithelium may disintegrate as a result of infection (or trauma), the enamel may subsequently be resorbed, and bone or coronal cementum may be deposited in its place. The result is solid fixation of the tooth in its unerupted position (Fig. 20.21).

### TRISOMY 21 SYNDROME (DOWN SYNDROME)

Trisomy 21 syndrome or Down syndrome (DS)—the presence of three number 21 chromosomes rather than the normal two (diploid)—is one of the congenital anomalies in which delayed eruption of the teeth frequently occurs. The first primary teeth may not appear until 2 years of age, and the dentition may not be complete until 5 years of age. The eruption often follows an abnormal sequence, and some of the primary teeth may be retained until 15 years of age. In a study of 127 males and 128 females with DS, Ondarza et al.<sup>45</sup> found that, on average, 6 primary



**Fig. 20.14** Ankylosed second primary molar with a caries lesion in the occlusal surface. This tooth probably became ankylosed soon after root resorption began.

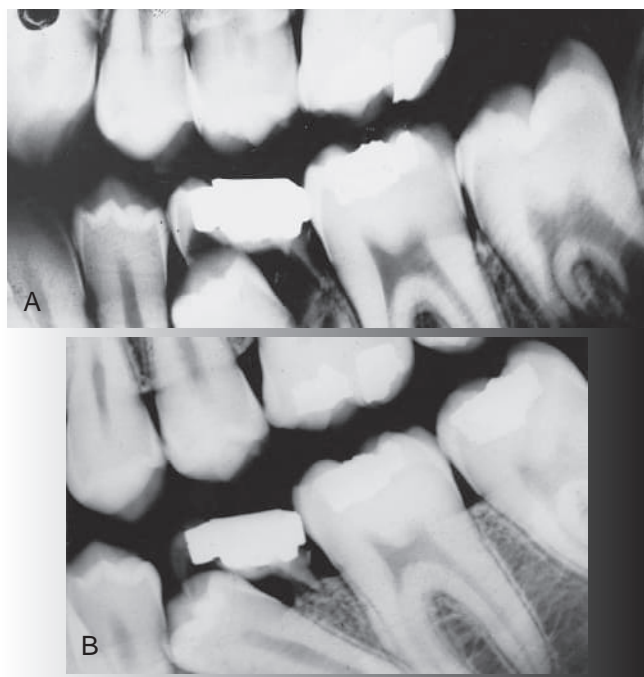


**Fig. 20.15** An ankylosed, deeply embedded second primary molar. Surgical removal of this tooth is indicated.

teeth were delayed in eruption in boys and 11 primary teeth were delayed in girls. A similar study conducted by Jara et al.<sup>46</sup> in 116 males and 124 females with DS showed delayed eruption of 13 permanent teeth in boys and 8 permanent teeth in girls. These studies seem to confirm that delayed tooth eruption is common but sporadic in children with DS.

As such, DS occurs very early in embryonic development, possibly during the first cell divisions. Anomalies of the eye and external ear are seen, and congenital heart defects are often present. The occurrence of DS is frequently related to maternal age. Various sources report the frequency of DS to be approximately 0.9 per 1000 births when the mother is younger than 33 years, 2.8 per 1000 when the mother is 35–38 years old, and 38 per 1000 when the mother is 44 years or older, with certain populations reporting a high of 91 per 1000 in this older age group.

The diagnosis of DS in a child is not usually difficult to make because of the characteristic facial pattern (Fig. 20.22). The orbits are small, the eyes slope upward, and the bridge of the nose is more depressed than normal. In a study of 194 children with DS, Cohen<sup>47</sup> reported that 54% children demonstrated anomalies in the formation of the external ear, characterized by outstanding “lap” ear with flat or absent helix. Intellectual disability is another characteristic finding, with most children in the mild to moderate range of disability (Table 17.2).



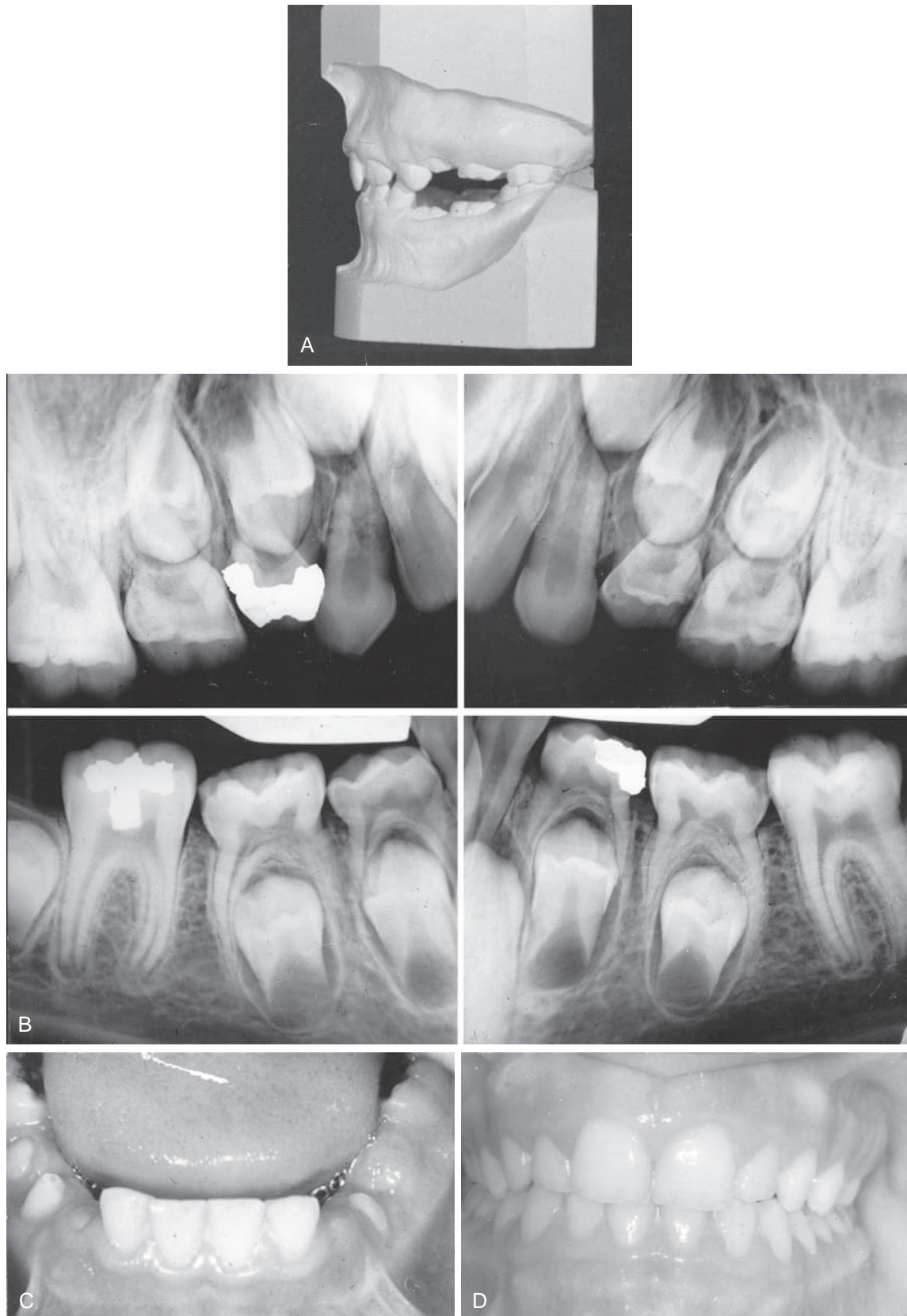
**Fig. 20.16** (A) A small spicule of root of the primary tooth is ankylosed to the alveolar bone. This was overlooked at the time of the routine examination. (B) One year later, the second primary molar is still retained, and the second premolar has moved into a more unfavorable position.

Landau<sup>48</sup> made a cephalometric comparison of children with DS and their normal siblings. Delayed growth of the maxillae and mandible was evident in those with DS. Both the maxillae and mandible were positioned anteriorly under the cranial base. The upper facial height was found to be significantly smaller. The midface was also found to be small in the vertical and horizontal dimensions. The smaller jaws contribute to a tendency for protrusion of the tongue and dental crowding, both of which may compromise the development of good occlusion. The tongue also tends to be larger than normal.

Many children with DS have chronic inflammation of the conjunctiva and a history of repeated respiratory tract infections. The use of antibiotics has reduced the incidence of chronic infection and has resulted in fewer deaths from infection.

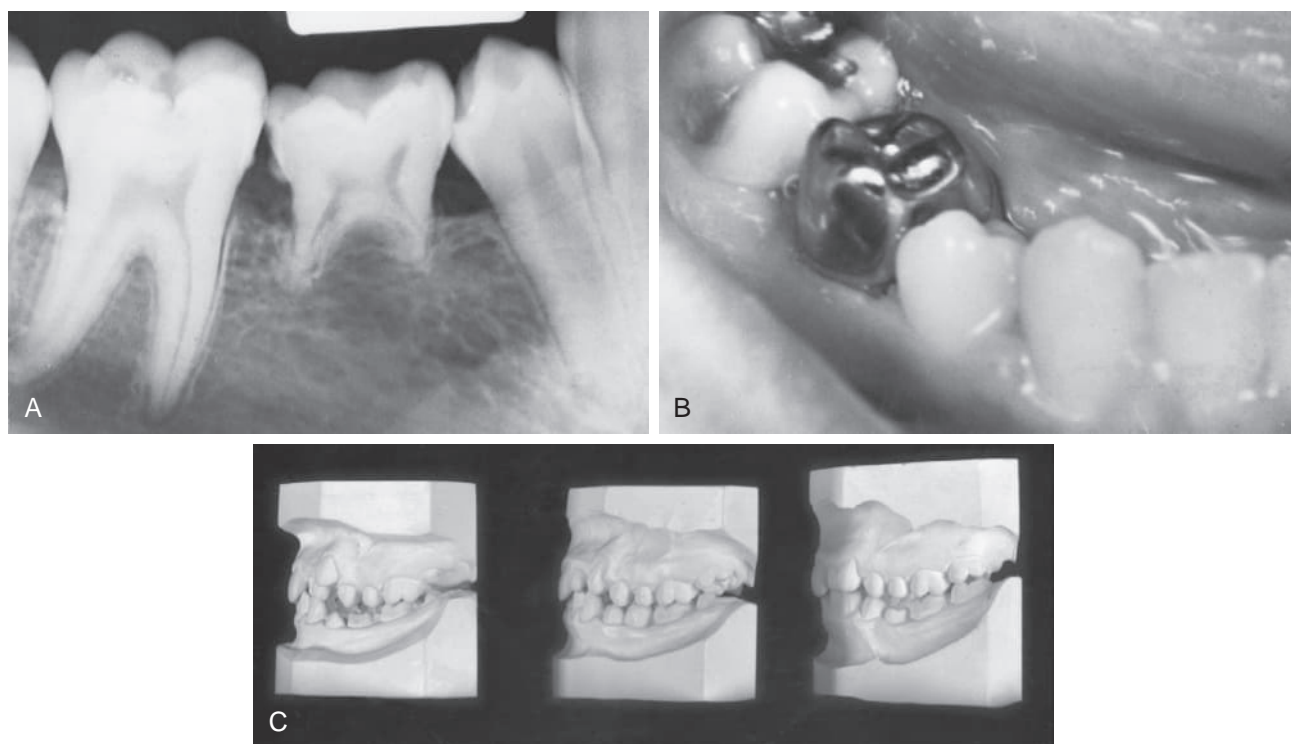
After a literature review, Cichon et al.<sup>49</sup> concluded that individuals with DS have a higher prevalence of periodontal disease than otherwise normal, age-matched control groups and other patients with mental disabilities and of similar age distribution. Furthermore, the reports of exaggerated immunoinflammatory responses of the tissues in patients with DS cannot be explained by poor oral hygiene alone and may be the result of impaired cell-mediated and humoral immunities and deficient phagocytic systems. In their study of 10 patients with DS and aged 20–31 years, Cichon et al.<sup>49</sup> demonstrated that young age of onset, severe destruction, and pathogenesis of disease in the periodontal tissues were consistent with a juvenile periodontitis disease pattern.

Morinushi et al.<sup>50</sup> obtained blood samples and conducted gingival health assessments of 75 individuals with



**Fig. 20.17** (A) All eight of the primary molars were ankylosed. Continuing eruption of the adjacent teeth has caused a loss of arch length. (B) Radiographs aided in the diagnosis of the ankylosed primary molars. The recommended treatment was surgical removal of the ankylosed teeth. (C) Space maintainers were constructed after removal of the ankylosed teeth and were worn until the permanent teeth erupted. (D) Ideal occlusion was achieved as a result of early diagnosis and the removal of the ankylosed teeth at the proper time.





**Fig. 20.18** (A) Ankylosed primary molar without a permanent successor. (B) Mesiodistal width of the primary molar was reduced to allow the premolar to erupt, and an overlay was constructed to establish occlusion with the opposing teeth. (C) Models at the left show the original condition. Center models show the occlusion at the time the overlay was placed on the ankylosed tooth. Models at the right show the continued eruption of the adjacent teeth that occurred in the subsequent 18-month period.

DS and aged 2–18 years. The extent of gingival inflammation and the antibody titers of the individuals with DS suggested that colonization of certain pathogenic organisms for periodontal disease had occurred before 5 years of age. The prevalence and extent of gingivitis were significantly higher than in normal children. The antibody titers also suggested that colonization of additional pathogenic organisms increased with age. The authors believe that there are abnormalities in the systemic defenses that are responsible for the early onset of disease in the individuals with DS. Similarly, Carlstedt et al.<sup>51</sup> have demonstrated significantly higher oral colonization with *Candida albicans* in children with DS compared with an age- and gender-matched control group. They believe that abnormalities of the immune response in children with DS are responsible for their greater susceptibility to oral mucosal disease.

Dental caries susceptibility is usually low in those with DS. This finding has been reported by Lee et al.<sup>52</sup> who noted a much lower incidence of dental caries in both the primary and the permanent dentitions. Shapira and Stabholz<sup>53</sup> successfully demonstrated caries reduction and improved periodontal health during a 30-month period after initiating a comprehensive preventive oral health program for 20 children with DS.

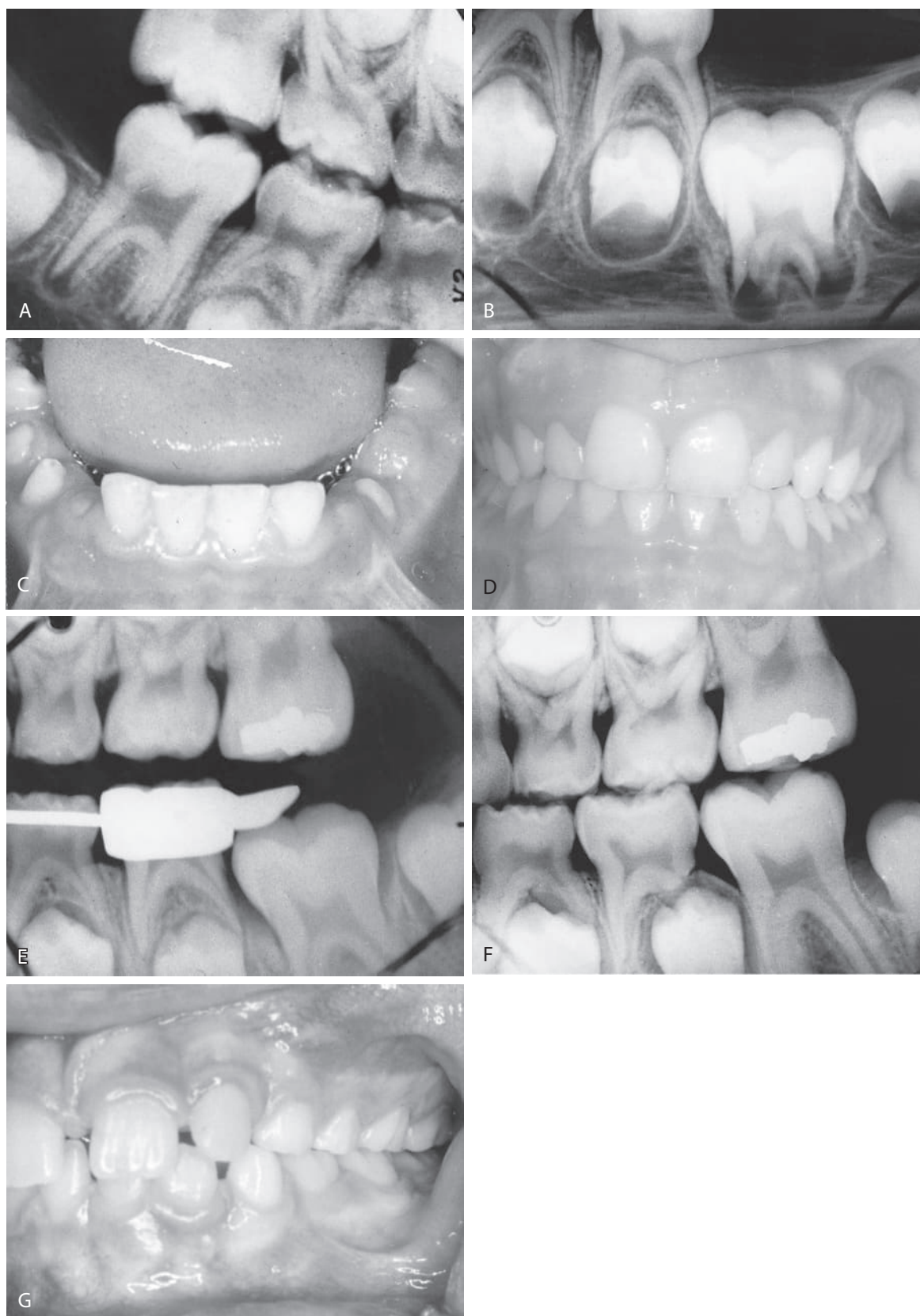
Seagriff-Curtin et al.<sup>54</sup> believe that although some children with low cognitive ability are unmanageable for dental procedures, most are pleasant, cheerful, affectionate, and well behaved. They can often be managed in the dental office in a conventional manner. The possibility of reduced resistance to infection should be considered in the dental management of the child with DS.

## CLEIDOCRANIAL DYSPLASIA

A rare congenital syndrome that has dental significance is cleidocranial dysplasia (CCD), which has also been referred to as *cleidocranial dysostosis*, *osteodentin dysplasia*, *mutational dysostosis*, and *Marie-Sainton syndrome*. Transmission of the condition is by either parent to a child of either gender, so that the disorder thus follows a true Mendelian dominant pattern. CCD can also occur sporadically with no apparent hereditary influence and with no predilection for race. The diagnosis is based on the finding of an absence of clavicles, although there may be remnants of the clavicles, as evidenced by the presence of the sternal and acromial ends. The fontanels are large, and radiographs of the head show open sutures, even late in the child's life. The sinuses, particularly the frontal sinus, are usually small.

Richardson and Deussen<sup>55</sup> performed cephalometric analyses of 17 patients with CCD. They found that, on average, the patients exhibited mandibular prognathism caused by increased mandibular lengths and short cranial bases. The maxillae tended to be short vertically but not anteroposteriorly.

The development of the dentition is delayed. Complete primary dentition at 15 years of age, resulting from delayed resorption of the deciduous teeth and delayed eruption of the permanent teeth, is not uncommon (Fig. 20.23). One of the important distinguishing characteristics is the presence of supernumerary teeth. Some children may have only a few supernumerary teeth in the anterior region of the mouth; others may have a large number of extra teeth throughout the mouth. Even with removal of the primary



**Fig. 20.19** Series of radiographs demonstrating the successful treatment of delayed eruption of a first permanent molar. (A) The first permanent molar has erupted on the right side. (B) The left first permanent molar remains embedded in bone and is probably ankylosed. (C) Soft tissue and bone have been removed, and surgical cement has been placed over the unerupted tooth. (D) Within 3 months, the first permanent molar has moved occlusally. (E) The lingual arch and distal extension hold the surgical cement in position and prevent continued eruption of the opposing molar. (F) and (G) The first permanent molar has erupted, and the occlusion is good. Notice the progressive resorption of the distal root of the mandibular second primary molar.

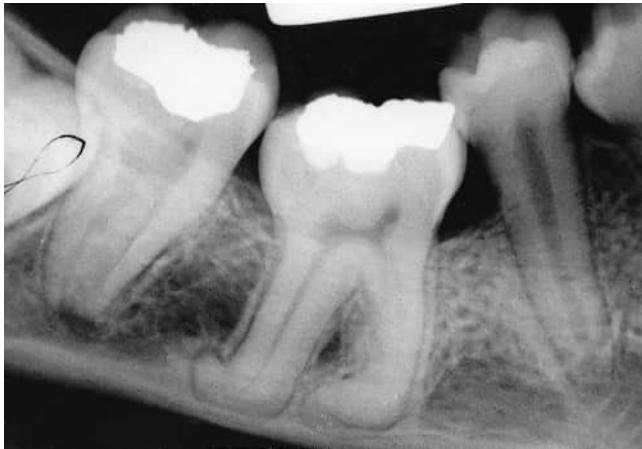

Fig. 20.20 Ankylosed first permanent molar.

and supernumerary teeth, eruption of the permanent dentition, without orthodontic intervention, is often delayed and irregular. Other reports by Jensen and Kreiborg,<sup>56-58</sup> based on their experiences and longitudinal study of 19 patients with CCD, provide information to help clinicians predict the location and time of onset of formation of supernumerary teeth. This information should help the clinician develop an optimal surgical treatment plan.

Hutton et al.<sup>59</sup> have reported the successful dental management of a patient with CCD over a 15-year period. The patient was first seen at 2 years of age. Treatment consisted of timed extractions of primary and supernumerary teeth and conservative uncovering of the permanent teeth. The surgical procedures were planned according to progressive radiographic evidence of the development of the permanent teeth. This management results in a nearly normal but slightly delayed eruption sequence. Orthodontic treatment

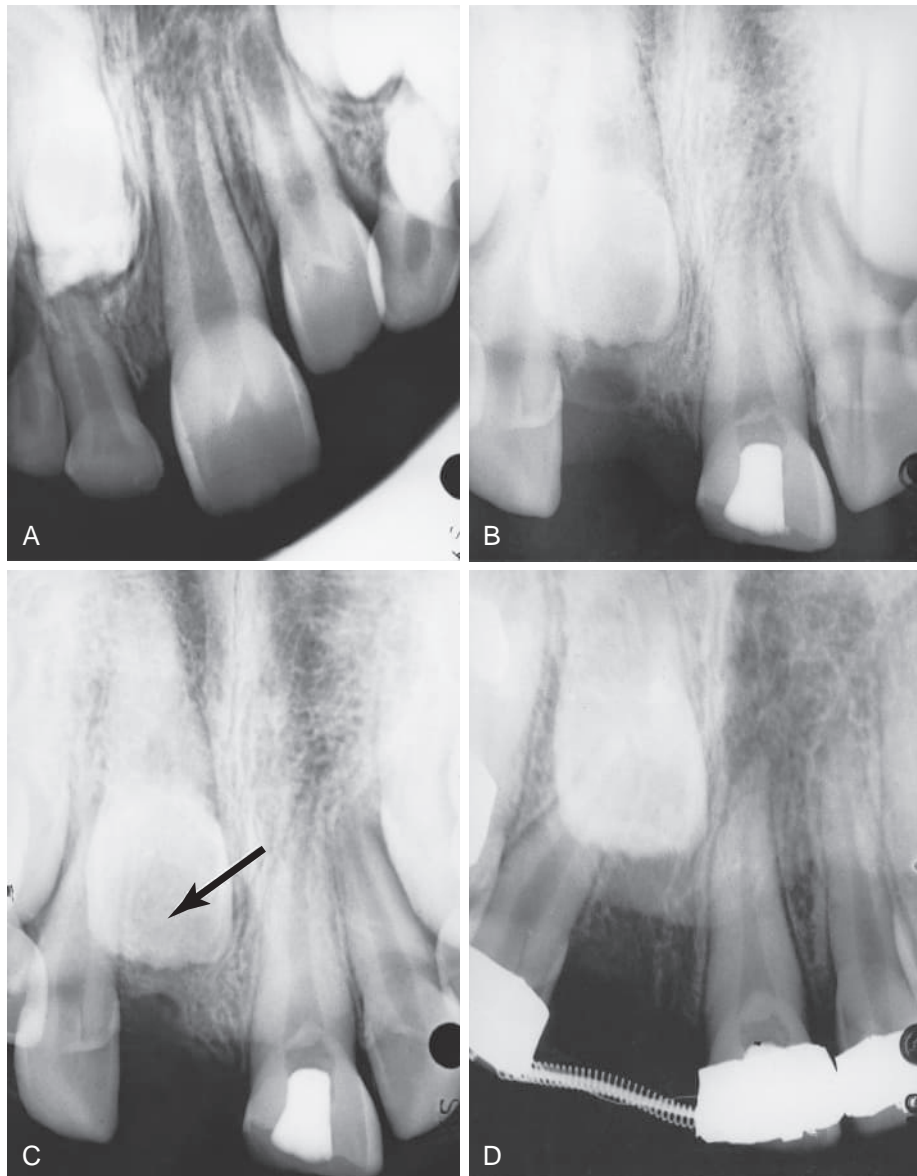


Fig. 20.21 Ankylosis by inostosis. (A) A mesiodens has delayed the eruption of the maxillary right permanent central incisor. (B) The primary incisors and the mesiodens were removed. During the surgical removal of the mesiodens, there was apparently damage to the enamel epithelium. (C) There is evidence of resorption of the enamel of the unerupted incisor and ankylosis of the tooth. (D) The left central incisor crown sustained a fracture and pulp exposure. A calcium hydroxide pulpotomy was successfully performed, which resulted in continued root development.





Fig. 20.22 Child with Down syndrome, at (A) 1 year, (B) 5 years, and (C) 9 years of age.

was initiated at 14 years of age, and by 16 years of age, the patient displayed acceptable occlusion and normal vertical dimension, root development, and periodontal bone support.

Learning from their experiences with the long-term management of 16 patients with CCD, Becker et al.<sup>60</sup> advocated cooperative efforts by clinicians from the disciplines of pediatric dentistry, oral and maxillofacial surgery, and orthodontics and dentofacial orthopedics. The pediatric dentist serves as the coordinator of overall oral health care and disease prevention during an extended treatment regimen that usually includes two surgical interventions and three stages of orthodontic surgery.

Delayed eruption has also been reported in other forms of osteopetroses.

## HYPOTHYROIDISM

Hypothyroidism is another possible cause of delayed eruption. Patients in whom the function of the thyroid gland is extremely deficient have characteristic dental findings.

### Congenital Hypothyroidism (Cretinism)

Hypothyroidism occurring at birth and during the period of most rapid growth, if undetected and untreated, causes mental deficiency and dwarfism. In earlier medical and dental literature, this condition was referred to as *cretinism*. Congenital hypothyroidism is the result of an absence or underdevelopment of the thyroid gland and insufficient levels of thyroid hormone (Fig. 20.24). Today, it is routinely diagnosed and corrected at birth because of mandatory blood screening of newborn infants. An inadequately treated child with congenital hypothyroidism is a small and disproportionate person, with abnormally short arms and legs. The head is disproportionately large, although the trunk shows less deviation from the norm. Obesity is common.

Without adequate hormonal therapy, the dentition of the child with congenital hypothyroidism is delayed in all stages, including eruption of the primary teeth, exfoliation of the primary teeth, and eruption of the permanent teeth. The teeth are normal in size but are crowded in jaws that are smaller than normal. The tongue is large and may protrude from the mouth. The abnormal size of the tongue and its position often cause an anterior open bite and flaring of the anterior teeth. Tooth crowding, malocclusion, and mouth breathing cause a chronic hyperplastic type of gingivitis.

Although untreated congenital hypothyroidism is rare, even in developing countries, Loevy et al.<sup>61</sup> published a case

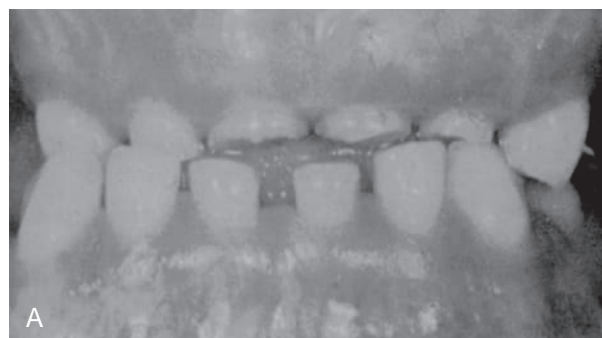

Fig. 20.23 Cleidocranial dysplasia. (A) Primary dentition is still present at 15 years of age. (B) Delayed dentition and the presence of many supernumerary teeth. (C) Removal of supernumerary teeth in the maxillary arch caused irregular and delayed eruption of some of the permanent teeth.

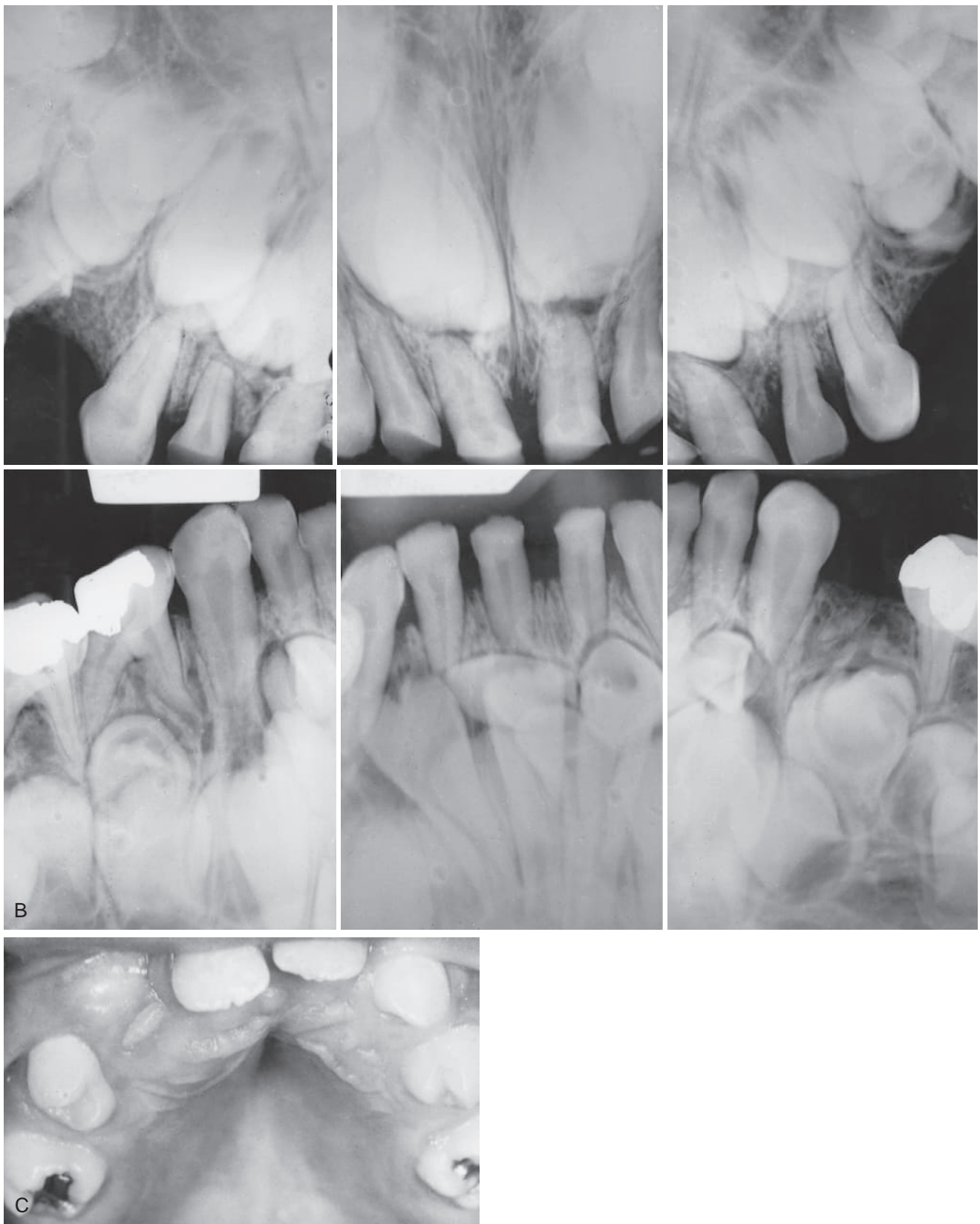
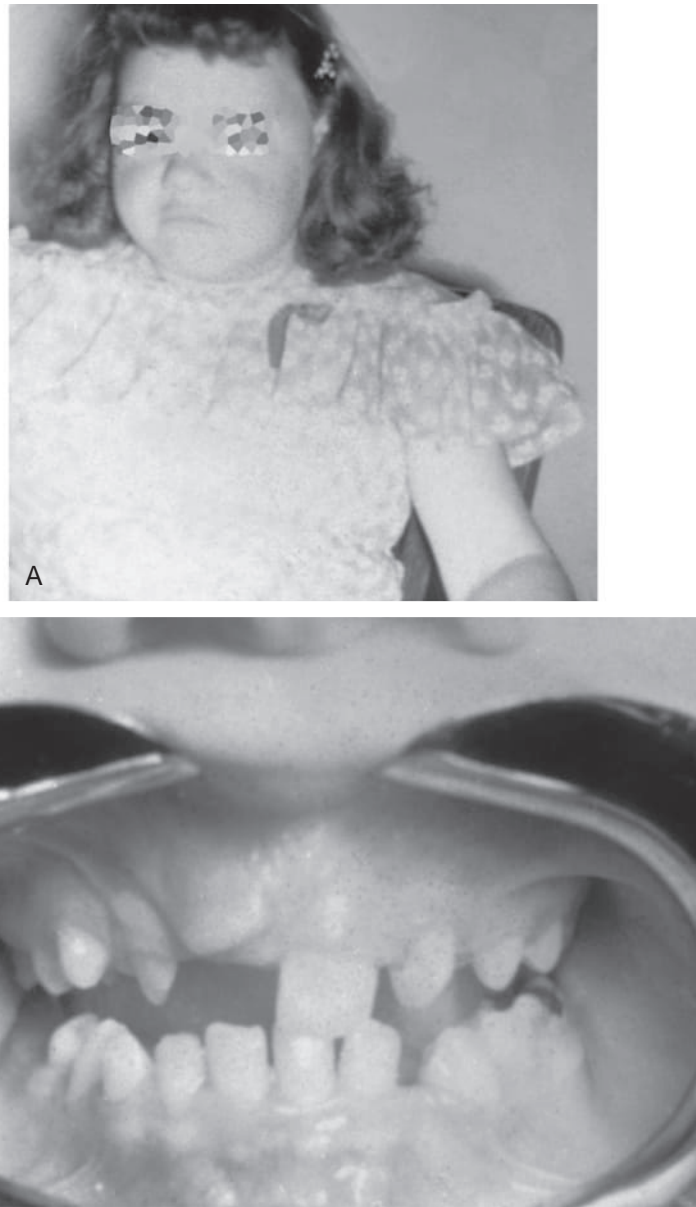


Fig. 20.23 — Cont'd

report documenting the condition discovered in a 19-year-old boy. The patient presented with a complete caries-free primary dentition and partially erupted maxillary first

permanent molars. All primary teeth showed some abrasion. At a subsequent oral examination 1 year and 9 months after appropriate l-thyroxine therapy was initiated,



**Fig. 20.24** (A) Greatly delayed dentition of a 24-year-old patient with congenital hypothyroidism. (B) With the administration of thyroxine, the eruption of the permanent teeth was accelerated. (Courtesy Dr. David F. Mitchell.)

several primary teeth had exfoliated, permanent incisors and first molars had erupted, and radiographs showed additional development of other permanent teeth.

### Juvenile Hypothyroidism (Acquired Hypothyroidism)

Juvenile hypothyroidism results from a malfunction of the thyroid gland, usually between 6 and 12 years of age. Because the deficiency occurs after the period of rapid growth, the unusual facial and body patterns characteristic of a person with congenital hypothyroidism are not present. However, obesity is evident to a lesser degree. In untreated juvenile hypothyroidism, delayed exfoliation of the primary teeth and delayed eruption of the permanent teeth are characteristic. A child with a chronologic age of 14 years may have a dentition in a stage of development comparable with that of a 9- or 10-year old child (Fig. 20.25).

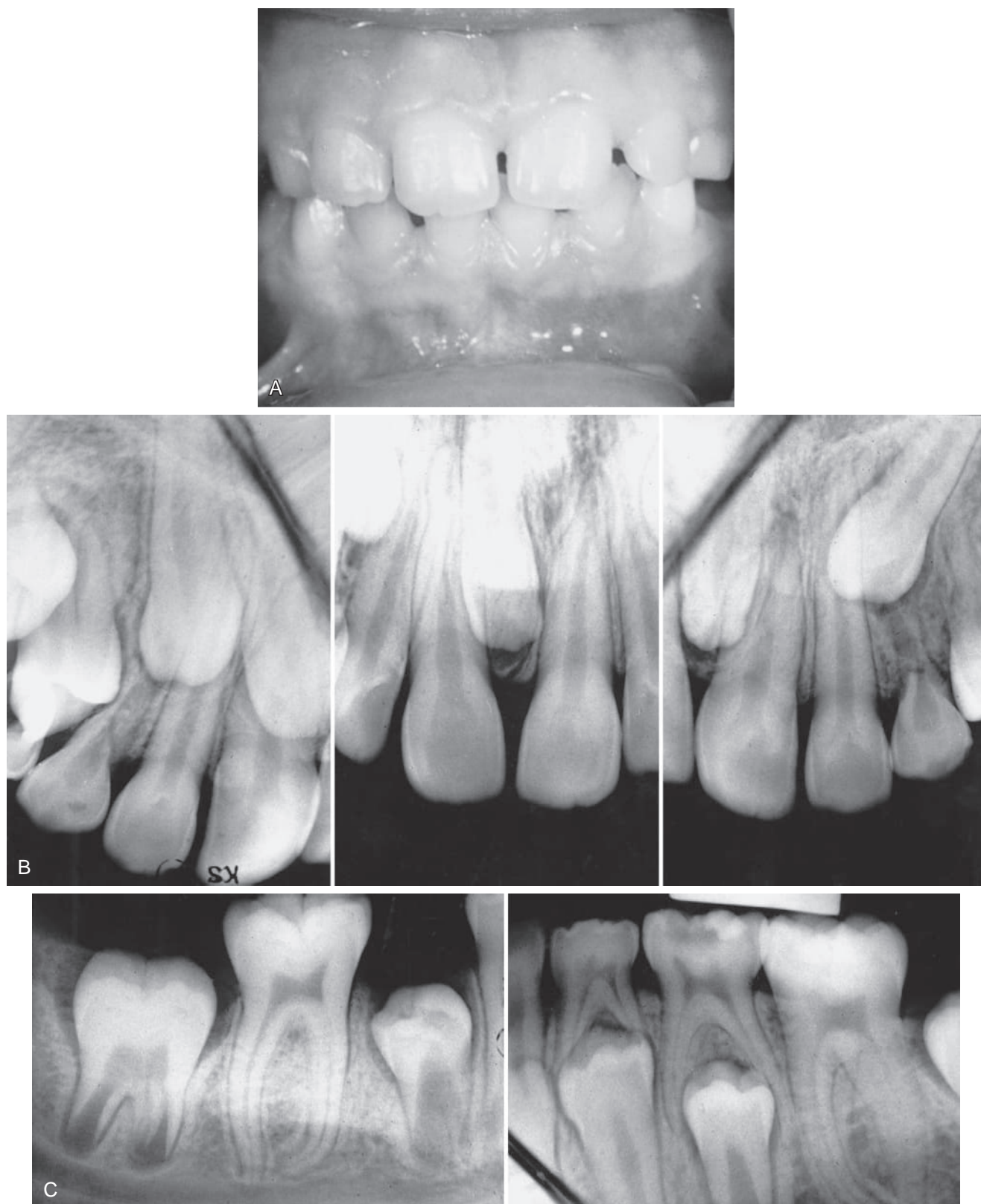
### HYPOPITUITARISM

A pronounced deceleration of the growth of the bones and soft tissues of the body results from a deficiency in secretion of the growth hormone. Pituitary dwarfism is the result of an early hypofunction of the pituitary gland. Again, early diagnosis is routine because of the mandatory blood screening of newborn infants for congenital hypothyroidism.

An individual with pituitary dwarfism is well proportioned but resembles a child of considerably younger chronologic age (Fig. 20.26). The dentition is essentially normal in size.

Delayed eruption of the dentition is characteristic. In severe cases, the primary teeth do not undergo resorption but instead may be retained throughout the life of the person. The underlying permanent teeth continue



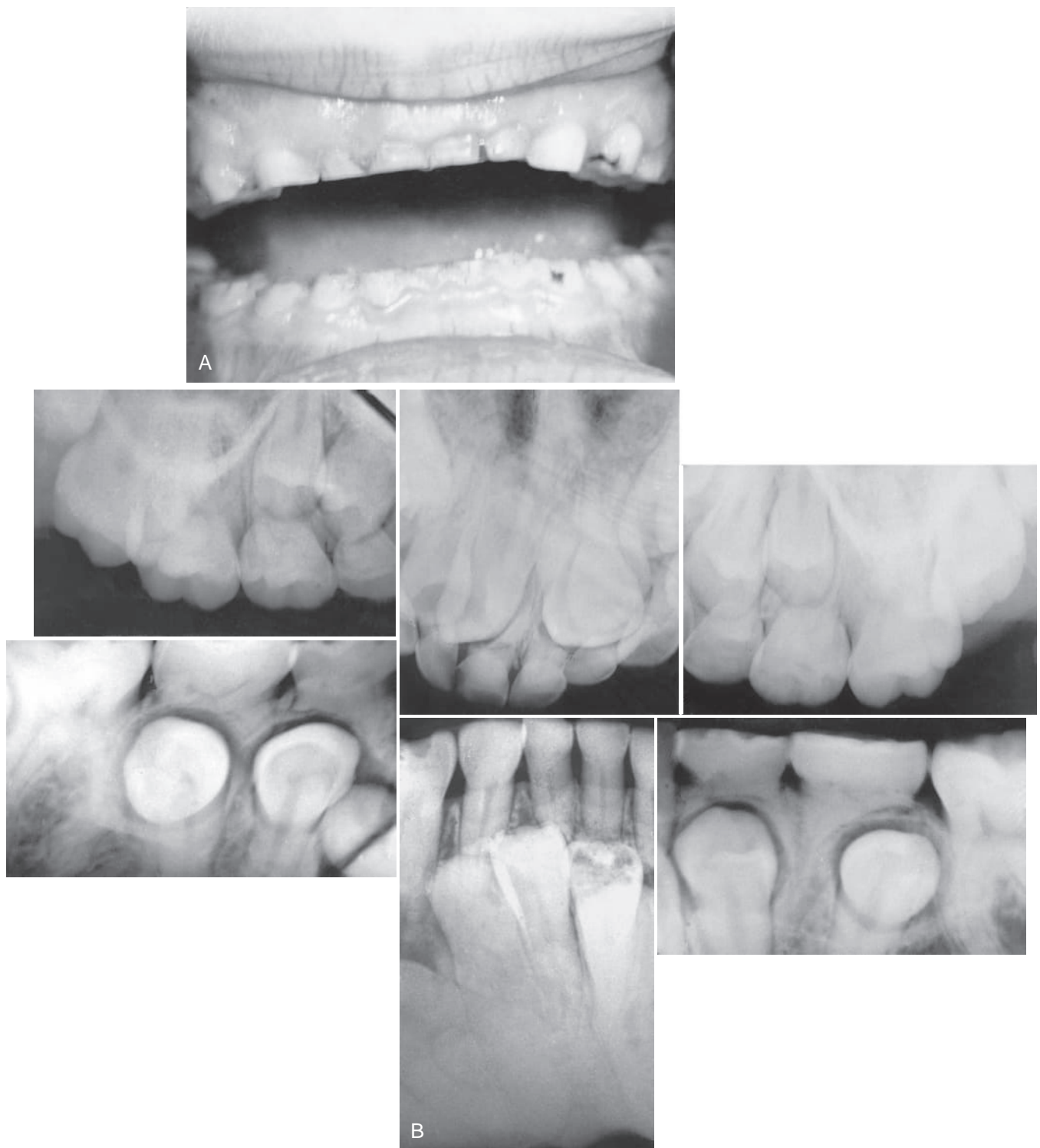


**Fig. 20.25** (A) A 14-year-old girl with juvenile hypothyroidism. (B) The occlusion was essentially normal but was delayed in its development. (C) Delayed development of the teeth in juvenile hypothyroidism. The maxillary midline supernumerary tooth is a coincidental finding.

to develop but do not erupt. Extraction of the deciduous teeth is not indicated because eruption of the permanent teeth cannot be ensured. Some degree of cognitive disability often occurs.

### ACHONDROPLASTIC DWARFISM

Achondroplastic dwarfism, also diagnosed at birth, demonstrates a few characteristic dental findings. Growth of

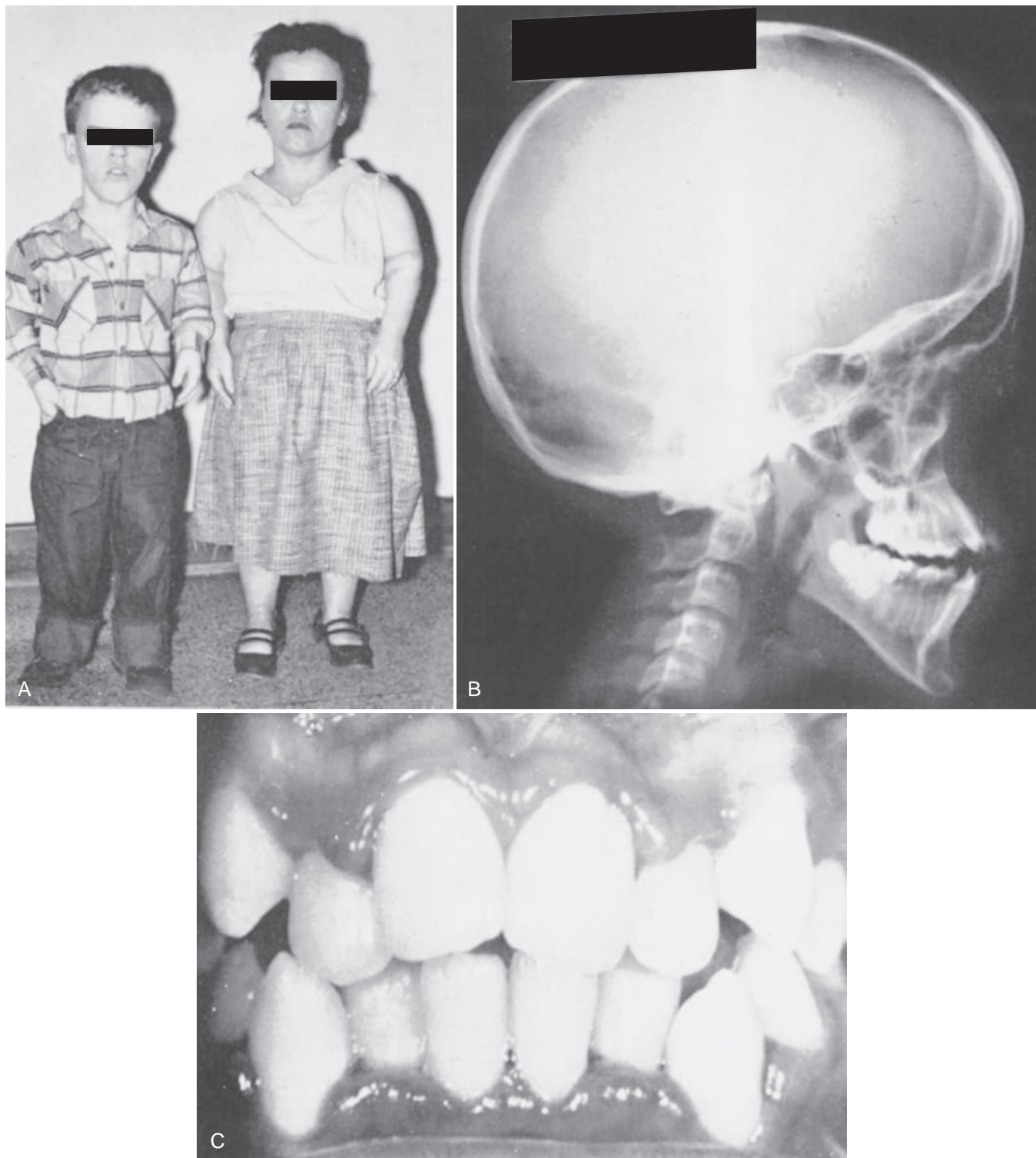


**Fig. 20.26** A 28-year-old woman diagnosed as having hypopituitary dwarfism. (A) Complete primary dentition at 28 years of age. The first permanent molars have erupted. (B) The roots of the primary teeth have not been resorbed to an appreciable degree, although some permanent teeth show complete development.

the extremities is limited because of a lack of calcification in the cartilage of the long bones. Stature improvements have been reported with surgical lengthening of the limbs and also with growth hormone therapy. The head is disproportionately large, although the trunk is normal in size. The fingers may be of almost equal length, and the hands are plump. The fontanels are open at birth. The

upper face is underdeveloped, and the bridge of the nose is depressed.

Although the etiology of achondroplastic dwarfism is unknown, it is clearly an autosomal dominant disorder, but sporadic spontaneous mutations occur. There is some evidence that the condition is more likely to occur when the ages of the parents differ significantly. In contrast to DS, the



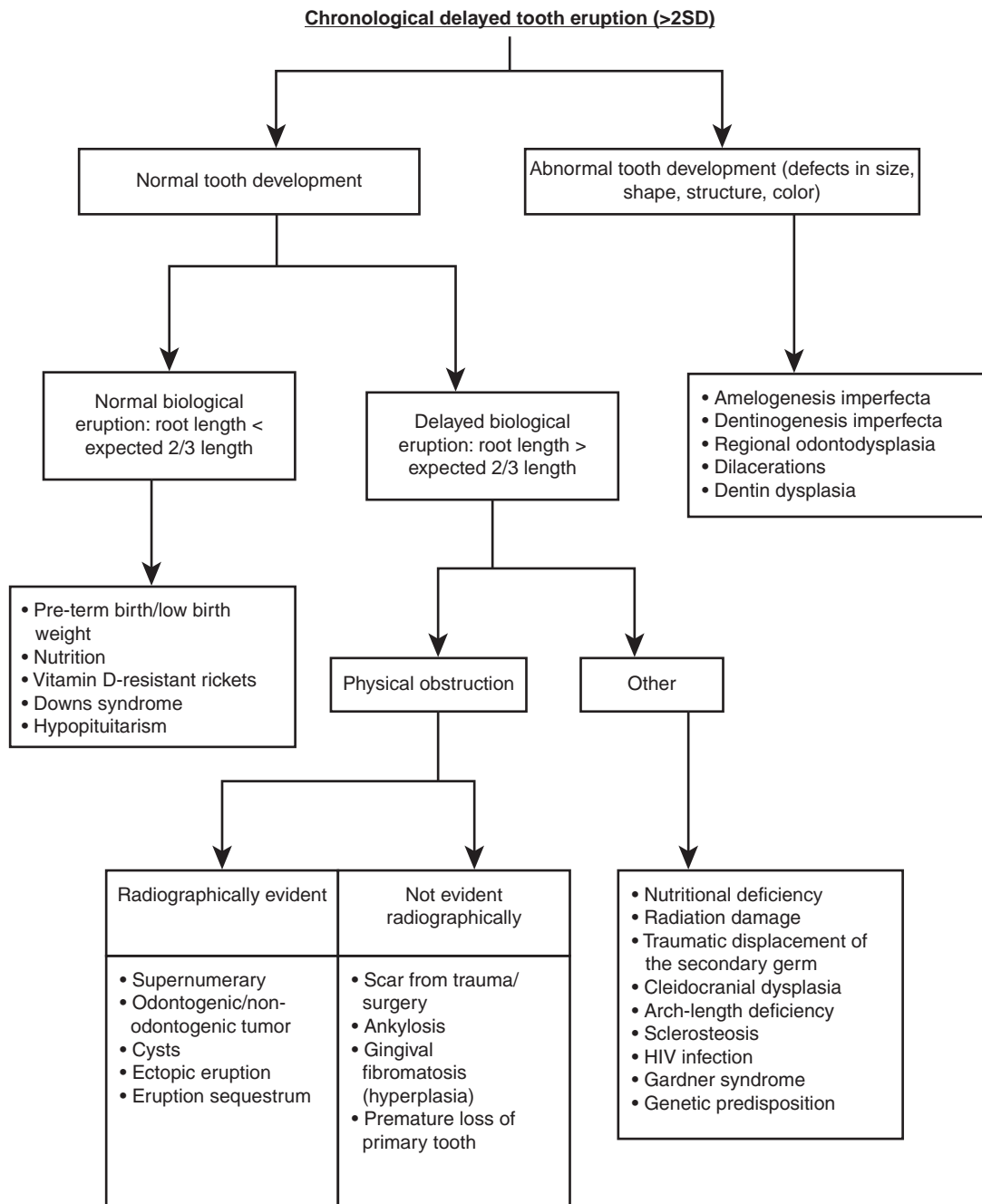
**Fig. 20.27** (A) A 14-year-old boy with achondroplastic dwarfism and his mother. Growth of the extremities is limited in both. (B) The upper face is greatly underdeveloped. (C) The arch length is inadequate, and the teeth are crowded. (A and B, courtesy Dr. Ralph E. McDonald. C, from Shafer W, Hine MK, Levy BM: *A textbook of oral pathology*, Philadelphia, 1958, WB Saunders.)

increased age of the father may be related to the occurrence of the condition.

Deficient growth in the cranial base is evident in many individuals with achondroplastic dwarfism. The maxilla may be small, with resultant crowding of the teeth and a

tendency for open bite. Chronic gingivitis is usually present. However, this condition may be related to the malocclusion and crowding of the teeth. In the patient shown in Fig. 20.27, the development of the dentition was slightly delayed.





**Fig. 20.28** Diagnostic algorithm of delayed tooth eruption. (From Suri L, Gagari E, Vastardis H: Delayed tooth eruption: pathogenesis, diagnosis, and treatment. A literature review, *Am J Orthod Dentofacial Orthop* 126:435, 2004.)

## OTHER CAUSES

Delayed eruption of the teeth has been linked to other disorders, including fibromatosis gingivae (see [Chapter 15](#)), Albright hereditary osteodystrophy, chondroectodermal dysplasia (Ellis-van Creveld syndrome), de Lange syndrome, frontometaphyseal dysplasia, Gardner syndrome, Goltz syndrome, Hunter syndrome, incontinentia pigmenti syndrome (Bloch-Sulzberger syndrome), Maroteaux-Lamy mucopolysaccharidosis, Miller-Dieker syndrome, progeria

syndrome (Hutchinson-Gilford syndrome), and familial hypophosphatemia.

Of additional interest is the effect of bisphosphonate therapy on children with osteogenesis imperfecta. Bisphosphonates inhibit the ability of osteoclasts to resorb bone. Indeed, one study demonstrated that children with osteogenesis imperfecta treated with bisphosphonates had an associated mean delay of 1.67 years in tooth eruption.<sup>62</sup> Finally, a well-designed diagnostic algorithm for delayed tooth eruption is shown in [Fig. 20.28](#).

## References

- Logan WH, Kronfeld R: Development of the human jaws and the surrounding structures from birth to the age of 15 years. *J Am Dent Assoc* 20(3):379–427, 1933.
- Hernández M, Espasa E, Boj J: Eruption chronology of the permanent dentition in Spanish children. *J Clin Pediatr Dent* 32(4):347–350, 2008.
- American Academy of Pediatric Dentistry Reference Manual. 2018/19: 40:352.
- Burgueño Torres L, Mourelle Martínez MR, Diéguez Pérez M, et al.: Sexual dimorphism of primary dentition in Spanish children. *Acta Odontol Scand* 76(8):545–552, 2018. Retrieved from <https://www.tandfonline.com/doi/full/10.1080/00016357.2018.1449963>. <https://doi.org/10.1080/00016357.2018.1449963>.
- De Souza N, Manju R, Hegde AM: Development and evaluation of new clinical methods of age estimation in children based on the eruption status of primary teeth. *J Indian Soc Pedod Prev Dent* 36(2):185–190, 2018. [https://doi.org/10.4103/jisppd.jisppd\\_121\\_17](https://doi.org/10.4103/jisppd.jisppd_121_17).
- Parner ET, Heidmann JM, Væth M, et al.: A longitudinal study of time trends in the eruption of permanent teeth in Danish children. *Arch Oral Biol* 46(5):425–431, 2001.
- Cahill DR, Marks SC: Tooth eruption: evidence for the central role of the dental follicle. *J Oral Pathol* 9(4):189–200, 1980.
- Demirjian A, Levesque GY: Sexual differences in dental development and prediction of emergence. *J Dent Res* 59(7):1110–1122, 1980.
- Wise GE, Frazier-Bowers S, D'souza RN: Cellular, molecular, and genetic determinants of tooth eruption. *Crit Rev Oral Biol Med* 12(4):323–335, 2002.
- Marks Jr SC, Schroeder HE: Tooth eruption: theories and facts. *Anat Rec* 245(2):373–374, 1996.
- Arid J, Xavier TA, da Silva RA, et al.: RANKL is associated with persistent primary teeth and delayed permanent tooth emergence. *Int J Paediatr Dent* 29(3):294–300, 2019. Retrieved from <https://onlinelibrary.wiley.com/doi/abs/10.1111/ipd.12467>. <https://doi.org/10.1111/ipd.12467>.
- Posen AL: The effect of premature loss of deciduous molars on premolar eruption. *Angle Orthod* 35(3):249–252, 1965.
- Hartsfield Jr K: Premature exfoliation of teeth in childhood and adolescence. *Adv Pediatr* 41:453–470, 1994.
- Carlos JP, Gittelsohn AM: Longitudinal studies of the natural history of caries. I. Eruption patterns of the permanent teeth. *J Dent Res* 44(3):509–516, 1965.
- Moyers RE: *Handbook of orthodontics*, ed 4, Chicago, Mosby, 1988.
- Alsulaiman AA, Briss DS, Parsi GK, et al.: Association between incisor irregularity and coronal caries: a population-based study. *Am J Orthod Dentofacial Orthop* 155(3):372–379, 2019. <https://doi.org/10.1016/j.ajodo.2018.04.029>. <https://www.ncbi.nlm.nih.gov/pubmed/30826040>.
- Gellin ME: Indications and contraindications for the removal of primary teeth. *Dent Clin North Am* 13(4):899–911, 1969.
- Gellin ME, Haley JV: Managing cases of overretention of mandibular primary incisors where their permanent successors erupt lingually. *J Dent Child* 49(2):118–122, 1982.
- Illingworth RS: Teething. *Dev Med Child Neurol* 11(3):376–377, 1969.
- Tasanen A: General and local effects of the eruption of deciduous teeth. *Ann Paediatr Fenn* 14(Suppl 29):1–40, 1968.
- Jaber L, Cohen IJ, Mor A: Fever associated with teething. *Arch Dis Child* 67(2):233–234, 1992.
- Massignan C, Cardoso M, Porporatti AL, et al.: Signs and symptoms of primary tooth eruption: a meta-analysis. *Pediatrics* 137(3):e20153501, 2016. <https://doi.org/10.1542/peds.2015-3501>. <https://pediatrics.aappublications.org/content/pediatrics/137/3/e20153501.full.pdf>.
- Swann IL: Teething complications: a persisting misconception. *Postgrad Med J* 55(639):24–25, 1979.
- Starkey PE, Shafer WG: Eruption sequestra in children. *J Dent Child* 30:84–86, 1963.
- Maki K, Ansai T, Nishida I, et al.: Eruption sequestrum: x-ray microanalysis and microscopic findings. *J Clin Pediatr Dent* 29(3):245–247, 2005.
- Leung AK: Natal teeth. *Am J Dis Child* 140:249–251, 1986.
- Kates GA, Needleman HL, Holmes LB: Natal and neo-natal teeth: a clinical study. *J Am Dent Assoc* 109(3):441–443, 1984.
- Zhu J, King D: Natal and neonatal teeth. *J Dent Child* 62(2):123–128, 1995.
- Adekoya-Sofowora CA: Natal and neonatal teeth: a review. *Niger Postgrad Med J* 15(1):38–41, 2008.
- Spouge JD, Feasby WH: Erupted teeth in the newborn. *Oral Surg* 22(2):198–208, 1966.
- Rahul M, Kapur A, Goyal A: Management of prematurely erupted teeth in newborns. *BMJ Case Rep* 2018, 2018. Retrieved from <https://casereports.bmj.com/content/2018/bcr-2018-225288>. <https://doi.org/10.1136/bcr-2018-225288>.
- Fromm AE: Epstein's pearls, Bohn's nodules and inclusion cysts of the oral cavity. *J Dent Child* 34:275–287, 1967.
- Neville JD, et al.: *Oral and maxillofacial pathology*, ed 4, Philadelphia, 2016, Elsevier, Inc. St. Louis.
- Henderson HZ: Ankylosis of primary molars: a clinical, radiographic, and histologic study. *J Dent Child* 46:117–122, 1979.
- Darling AL, Levers BG: Submerged human deciduous molars and ankylosis. *Arch Oral Biol* 18(8):1021–1040, 1973.
- Steigman S, Koyoumdjisky-Kaye E, Matrai Y: Submerged deciduous molars and congenital absence of premolars. *J Dent Res* 52(4):842, 1973.
- Tsukamoto S, Braham RL: Unerupted second primary molar positioned inferior to the second premolar: clinical report. *J Dent Child* 53(1):67–69, 1986.
- Belanger GK, Strange M, Sexton JR: Early ankylosis of a primary molar with self-correction: case report. *Pediatr Dent* 8:37–40, 1986.
- Tieu LD, Walker SL, Major MP, et al.: Management of ankylosed primary molars with premolar successors: a systematic review. *J Am Dent Assoc* 144(6):602–611, 2013.
- Kurul J, Thilander B: Infraocclusion of primary molars with aplasia of the permanent successor: a longitudinal study. *Angle Orthod* 54(4):283–294, 1984.
- Messer LB, Cline JT: Ankylosed primary molars: results and treatment recommendations from an eight-year longitudinal study. *Pediatr Dent* 2(1):37–47, 1980.
- Kurul J, Olson L: Ankylosis of primary molars—a future periodontal threat to first permanent molars? *Eur J Orthod* 13(5):404–409, 1991.
- Hanisch M, Hanisch L, Kleinheinz J, et al.: Primary failure of eruption (PFE): a systematic review. *Head Face Med* 14(1):5, 2018. Retrieved from [https://www.ncbi.nlm.nih.gov/pmc/articles/PMC5856369/pdf/13005\\_2018\\_Article\\_163.pdf](https://www.ncbi.nlm.nih.gov/pmc/articles/PMC5856369/pdf/13005_2018_Article_163.pdf). <https://doi.org/10.1186/s13005-018-0163-7>.
- Franklin CD: Ankylosis of an unerupted third molar by inostosis of enamel. *Br Dent J* 133(8):346–347, 1972.
- Ondarza A, Jara L, Munoz P, et al.: Sequence of eruption of deciduous dentition in a Chilean sample with Down's syndrome. *Arch Oral Biol* 42(5):401–406, 1997.
- Jara L, Ondarza A, Blanco R, et al.: The sequence of eruption of the permanent dentition in a Chilean sample with Down's syndrome. *Arch Oral Biol* 38(1):85–89, 1993.
- Cohen MM: Variability of facial and dental characteristics in trisomy G. *South Med J* 64:51–55, 1971.
- Landau MJ: A cephalometric comparison of children with Down's syndrome and their normal siblings [thesis]. Indiana University School of Dentistry: Indianapolis.
- Cichon P, Crawford L, Grimm WD: Early-onset periodontitis associated with Down's syndrome: clinical interventional study. *Ann Periodontol* 3(1):370–380, 1998.
- Morinushi T, Lopatin DE, Van Poperin N: The relationship between gingivitis and the serum antibodies to the microbiota associated with periodontal disease in children with Down's syndrome. *J Periodontol* 68(7):626–631, 1997.
- Carlstedt K, Krekmanova L, Dahllöf G, et al.: Oral carriage of *candida* species in children and adolescents with Down's syndrome. *Int J Paediatr Dent* 6(2):95–100, 1996.
- Lee SR, Kwon HK, Song KB, et al.: Dental caries and salivary immunoglobulin A in Down syndrome children. *J Paediatr Child Health* 40(9–10):530–533, 2004.
- Shapira J, Stabholz A: A comprehensive 30-month preventive dental health program in a pre-adolescent population with Down's syndrome: a longitudinal study. *Spec Care Dentist* 16(1):33–37, 1996.
- Seagriff-Curtin P, Pugliese S, Romer M: Dental considerations for individuals with Down syndrome. *N Y State Dent J* 72(2):33–35, 2006.
- Richardson A, Deussen FF: Facial and dental anomalies in cleidocranial dysplasia: a study of 17 cases. *Int J Paediatr Dent* 4(4):225–231, 1994.

56. Jensen BL, Kreiborg S: Craniofacial growth in cleidocranial dysplasia—a roentgencephalometric study, *J Craniofac Genet Dev Biol* 15(1):35–42, 1995.
57. Jensen BL, Kreiborg S: Development of the dentition in cleidocranial dysplasia, *J Oral Pathol Med* 19(2):89–93, 1990.
58. Jensen BL, Kreiborg S: Dental treatment strategies in cleidocranial dysplasia, *Br Dent J* 172(6):243–247, 1992.
59. Hutton CE, Bixler D, Garner LD: Cleidocranial dysplasia—treatment of dental problems: report of a case, *J Dent Child* 48(6):456–462, 1981.
60. Becker A, Shteyer A, Bimstein E, et al.: Cleidocranial dysplasia. Part II. Treatment protocol for the orthodontic and surgical modality, *Am J Orthod Dentofacial Orthop* 111(2):173–184, 1997.
61. Loevy HT, Aduss H, Rosenthal IM. Tooth eruption and craniofacial development in congenital hypothyroidism: report of case. *J Am Dent Assoc.* 1998;115(3):429-431.
62. Kamoun–Goldrat A, Ginisty D, Merrer ML: Effects of bisphosphonates on tooth eruption in children with osteogenesis imperfecta, *Eur J Oral Sci* 116(3):195–198, 2008.

# سایت کنکور

## WWW.KONKUR.IN

مرجع دانلود رایگان کتب علوم پزشکی و مهندسی  
آرشیو کامل و رایگان کنکورهای ارشد، دکتری و آزمونهای مقاطع و گرایشهای مختلف علوم پزشکی



## 21

# Growth of the Face and Dental Arches

DONALD J. FERGUSON

## CHAPTER OUTLINE

**The Nature of Growth**

Basic Concepts of Human Growth

Principles of Craniofacial Growth

Basic Concepts of Craniofacial Growth

**Craniofacial Pattern**

Ideal Paradigms for Dentofacial Pattern

**Growth and Facial Pattern**

Consistency in Pattern Maturation

Ideal Frontal Facial Pattern

Ideal Facial Profile Pattern

Maintenance of Overall Pattern

Facial Growth Emulates General Somatic Growth

**Growth and Pattern of Occlusion**

Consistency in Pattern Development

## Primary Dentition Terminus

Opposing First Molars at Initial Contact

Ideal Static Occlusion Pattern

Maintenance of Overall Pattern

**Growth and Dental Arch Pattern**

Similar Stage Sequencing

Ideal Dental Arch Pattern

Tooth Size/Arch Size Ratio as Pattern Determinant

Computation of Tooth Size/Arch Size Balance

Compensations in Dental Arch Development

Maintenance of Overall Pattern

Effects of Environmental Factors on Dental Arch Pattern

**Summary**

Historically, patient care in medicine and dentistry has been oriented toward the elimination of disease and the resolution of debilitating conditions. Competent care in dentistry today includes issues related not only to disease and functional disability but also to the patient's well-being. The appearance of the face and dentition is recognized with increasing frequency as a major factor in human psychosocial health.<sup>1</sup>

This chapter is about dental and facial malocclusion—the recognition and anticipation of malocclusion during the growing years. The dentofacial pattern can be easily and accurately assessed at chairside. In clinical terms, pertinent growth issues are discussed in relation to how growth changes the pattern of the face, occlusion, and dental arches. Knowledge of pattern appraisal and growth can be integrated into efficacious clinical decisions about a young patient. This chapter enhances the reader's diagnostic and treatment planning skills with reference to malocclusion in the pediatric patient.

The clinician treating malocclusion is primarily interested in the growth and development of craniofacial tissues as they result in facial and dentoalveolar patterns. Attanasio et al.<sup>2</sup> have demonstrated that our understanding of how genes express their influence on facial shape and dentofacial pattern, and how environment influences gene expression, has advanced at a remarkable pace. Moreover, understanding the mechanobiology of malocclusion treatment has advanced at macroscopic and tissue levels.<sup>3,4</sup> How molecular mechanisms are implicated at a clinically relevant level, however, has yet to be elucidated. Mao<sup>5</sup>

pointed out that what we understand about induced treatment effects at the macroscopic phenotype level has been described in moderate detail at the cellular level but is only beginning to be described at the level of protein and peptide production. For this reason, this chapter discusses dentofacial growth and development at a macroscopic level from the perspective of the practicing clinician.

## The Nature of Growth

Growth refers to an increase in the anatomic size. Three parameters commonly used in growth literature to assess the craniofacial size increase are magnitude, velocity, and direction. Magnitude refers to the linear dimension overall or the dimension of a part. Direction refers to the vector of size increase as might be described on a three-dimensional coordinate system. Velocity is defined as the amount of change per unit of time.

Size increase is typically illustrated in one of two ways. When growth is measured periodically and measurements are plotted as percentages of total growth, the result is a cumulative or distance curve (Fig. 21.1). A human post-natal cumulative curve is characterized by two plateaus and one period of accelerated growth. A second method of graphically demonstrating growth change is by the use of an incremental or velocity growth curve (Fig. 21.2). A velocity curve plots growth increments (e.g., centimeters per year) as a function of time. Characteristic of an incremental human growth curve is rapid accelerating prenatal

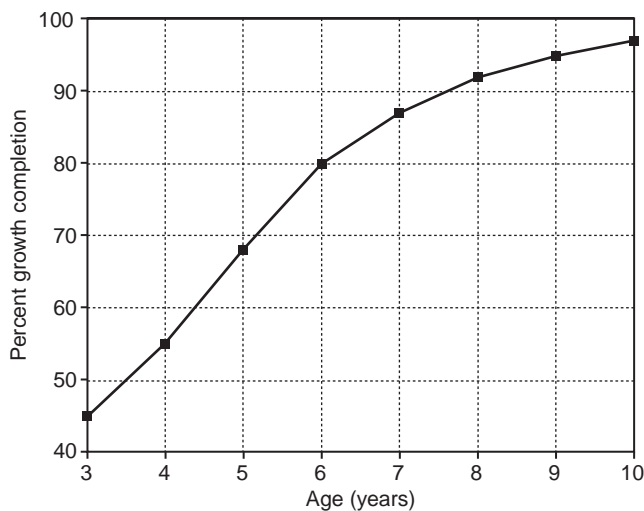


Fig. 21.1 Cumulative (distance) growth curve.

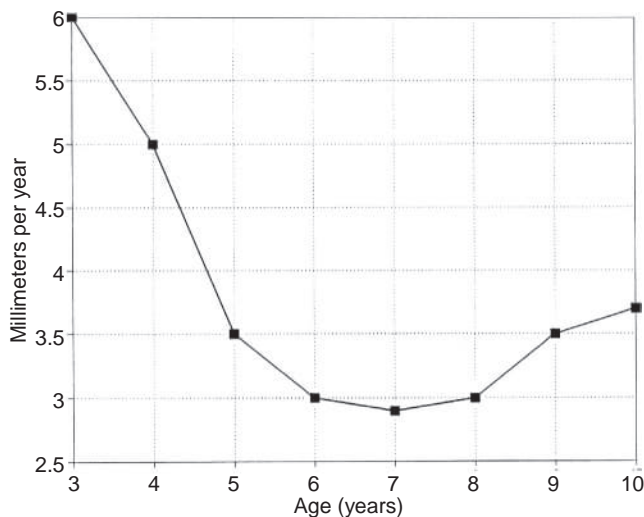


Fig. 21.2 Incremental (velocity) growth curve.

growth, rapid decelerating postnatal growth for the first 2 or 3 years, and a period of relatively slow incremental growth during childhood, followed by growth acceleration for 2 or 3 years during pubertal adolescence.

Three observations are central to a clinically relevant understanding of growth. First, growth implies change, a transition from one condition to another. This broader meaning of growth helps define growth as a concept. Conceptual growth refers to a passage from one anatomic form (i.e., size and shape) to another. Transitions in functional stage or activity refer to development. Development, in biologic literature, usually means increased specialization or a higher order of organization and also connotes an interaction of functioning parts. Development means increased organization or specialization of functioning (physiologic) parts.

Growth is more readily understood when a physical pattern is used to describe the effects of growth change. Growth, by nature, is a relational concept. Without reference to a structural model, growth has little clinical utility or meaning. This chapter discusses growth with reference to “ideal” facial, occlusion, and dental arch paradigms.

Growth is a complex phenomenon. There is a large volume of information available on craniofacial growth. Moreover, there is little consensus in the literature as to which data or combination of data is most useful to the practitioner committed to making competent decisions about direct patient care. In light of these prevailing circumstances, the following concepts and principles about craniofacial growth are presented in a way that should be clinically useful and difficult to refute. These postulates are derived and adapted in part from the widely held tenets about general human growth and development presented by Valadian and Porter.<sup>6</sup> The discussion of general craniofacial principles is followed by application of the principles to three areas of craniofacial growth: the face, occlusion, and dental arches. The goal of this chapter is to integrate growth principles into patient appraisal to enhance diagnostic and treatment planning efficacy.

## BASIC CONCEPTS OF HUMAN GROWTH

1. Growth disposition is similar for all healthy individuals. Healthy individuals go through growth stages that are the same for everyone, according to Valadian and Porter.<sup>6</sup> The prenatal period, from conception to birth, averages 40 weeks in length. Infancy includes the first 2 years of life after birth, and childhood ranges from 2 to 10 years for girls and from 2 to 12 years for boys. The length of adolescence is the same for both genders but comprises different years—from 10 to 18 years for girls and from 12 to 20 years for boys (Fig. 21.3).

Each growth stage is unique. The rate of size increase is most remarkable during the prenatal period and declines substantially during infancy. Generally, growth velocity plateaus during childhood and increases again during adolescence. All healthy individuals experience these growth cycles although the various basic tissues and body parts are affected differently.

2. Different body parts increase in length at different rates. From birth to adulthood, the head increases about twice in length, the trunk about three times, the arms about four times, and the legs about five times. Different parts of the body grow at different times and at different rates. For example, the head increases in size very early in life, and its rate of increase is very rapid during the prenatal and early postnatal periods.
3. The overall potential for growth is determined primarily by intrinsic or genetic factors. Genetic endowment is the main determinant of growth potential. Intrinsic factors are also those conditions and events that occur from conception to birth. Maternal nutrition or disease can modify child development before birth. Some tissues tend to demonstrate high genetic predilection. Neural and primary cartilage tissue growth seems genetically predisposed in size and growth timing. Tooth size appears to be under strict genetic control.<sup>7,8</sup>
4. The extent to which an individual attains his or her potential for growth is determined predominantly by extrinsic or environmental factors. Extrinsic factors include all postnatal environmental conditions, such as nutrition, illness, exercise, and climate. Environmental factors of particular interest to the dental clinician are

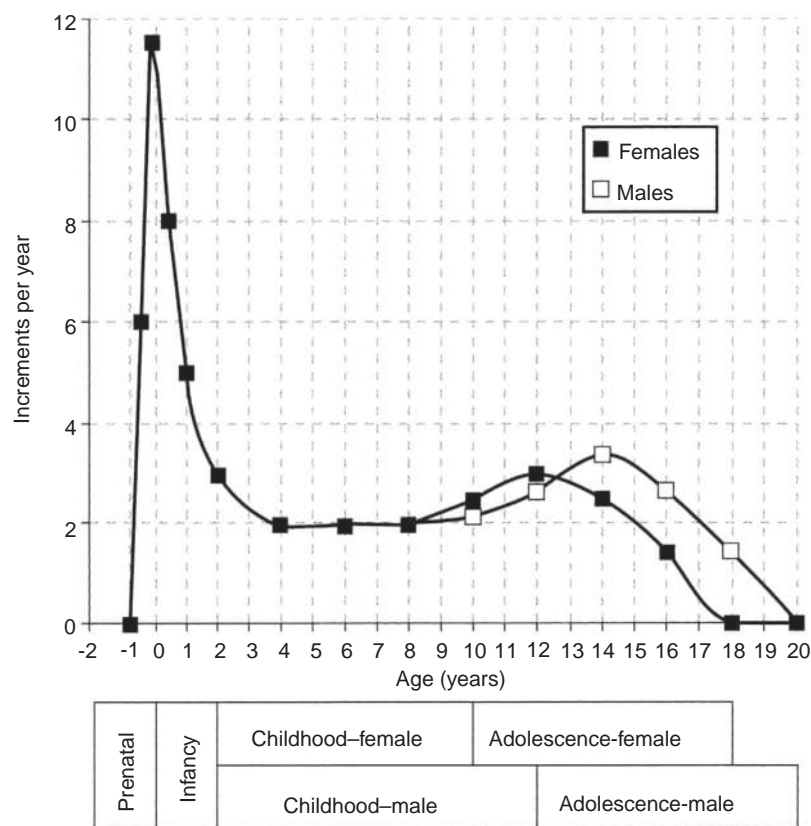


Fig. 21.3 Incremental growth curve illustrating growth stages.

oral habits, pathology, caries, premature loss of teeth, and metabolic disease. In the absence of detrimental extrinsic factors, the dentofacial complex will tend to attain its maximum potential in growth.

## PRINCIPLES OF CRANIOFACIAL GROWTH

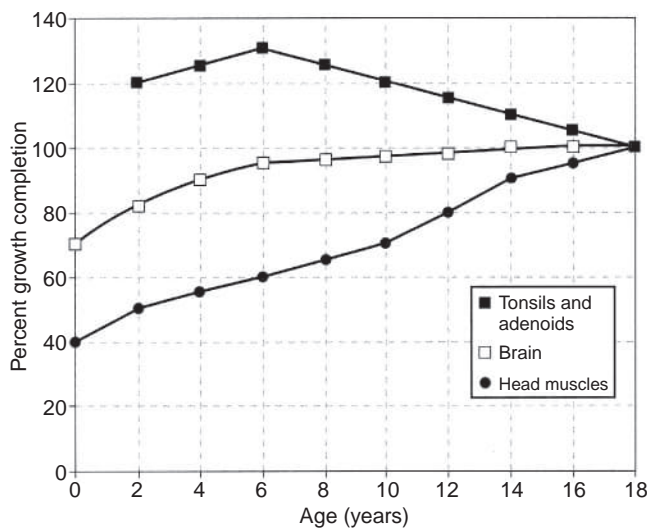
1. The basic tissue types and functioning spaces that comprise the head and face are subject to growth timing differences. The human head is composed of a variety of basic tissue types; the relative percentages of these types at any given age depend on the timing of their growth. Neural tissue completes its growth at an early age. By contrast, general somatic tissues, such as the muscle, bone, and connective tissue, mature at a slower rate. Neural tissue attains about 60%–70% of adult size by birth, and its growth is about 95% completed by middle childhood. This is in sharp contrast to growth of other craniofacial soft tissues (Fig. 21.4). Muscle tissue is only 40%–45% of its adult size by birth, and its growth is approximately 70% completed by 7 years of age. The size of craniofacial lymphoid tissue (tonsils and adenoids) is about 125% of adult size at 5 years of age and decreases gradually to adulthood. Linder-Aronson and Leighton<sup>9</sup> have shown that functional pharyngeal space increases in relation to decreased tonsillar-adenoid mass.

The growth timing of skeletal tissues also demonstrates variation. Craniofacial bone growth is about 45% completed by birth and 70% completed by 7 years of age. In contrast, primary cartilage of the head and face achieves approximately 75% of adult size by birth and

95% by 7 years of age (Fig. 21.5). The small amount of primary cartilage remaining in the head and face after middle childhood, however, continues to grow through puberty.

2. Growth of primary cartilage and functioning spaces has a directing influence on craniofacial pattern change. Primary cartilage is a tissue of particular interest to craniofacial growth theorists. According to Enlow and Hans,<sup>10</sup> it is singular in form; has the capacity to grow from within (interstitial growth); is tolerant to pressure, noncalcified, flexible, and nonvascular; and does not require a covering nutrient membrane for survival. Primary cartilage found in the head and face is identical to the growth plate cartilage of long bones. Scott<sup>11</sup> contends that primary cartilage is genetically predisposed, acts during growth as an autonomous tissue, and is able to directly influence the craniofacial pattern. Sperber<sup>12</sup> documents that primary cartilage first appears in the head during the fifth prenatal week. By the eighth prenatal week, a cartilaginous mass called the *chondrocranium* is present and is the precursor to the adult cranial base and nasal and otic structures. By middle childhood, most primary cartilage is replaced by bone in a process called *enchondral bone formation*. The overall growth-directing influence of primary cartilage on craniofacial pattern change is most profound in early life. By birth, cartilage constitutes a substantial portion of the nasal septum and cranial base. Interstitial expansion of primary cartilage probably has a direct influence on the position of the maxilla by way of the septopremaxillary suspensory ligament, as suggested





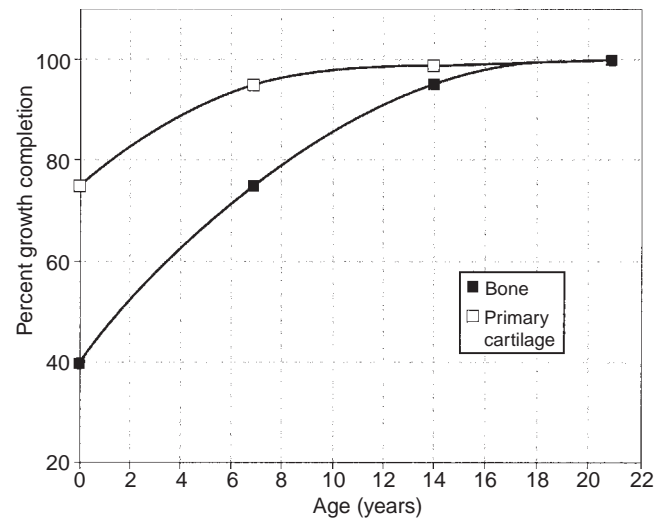
**Fig. 21.4** Cumulative growth curve for craniofacial neural, muscle, and lymphoid tissues. (From Linder-Aronson S, Leighton BC. A longitudinal study of the development of the posterior nasopharyngeal wall between 3 and 6 years of age. *Eur J Orthod.* 1983;5(1):47–58.)

by Latham<sup>13</sup> and later contended by Gange and Johnston.<sup>14</sup> The maxilla is most likely thrust downward and forward during infancy and early childhood. The contributions to midface growth of primary cartilage are greatly diminished after middle childhood.

The development of functioning spaces has also received considerable attention as a key concept among craniofacial growth theories.<sup>15</sup> The head carries out numerous functions. Some functions are more essential than others, but all require the development and maintenance of spaces. Neural integration is a critical function, and space is required for the brain and central and peripheral nervous system expansion. Respiration and deglutition are also essential to life and require development of nasal, pharyngeal, and oral spaces. Sight, olfaction, hearing, and speech are important but less critical craniofacial functions that also require development of functioning spaces for operation.

According to Moss and Salentijn,<sup>16</sup> a likely craniofacial growth scenario of functioning space development in head and facial patterns includes the following sequence of events. Rapid increase in the brain size during prenatal and early postnatal life thrusts the calvarial bony plates outward and the midface forward. Birth invokes a set of functional processes previously not essential for life (i.e., breathing and swallowing). Repositioning of the mandible and tongue takes place to ensure patency of nasal, oral, and pharyngeal spaces. The mandible is depressed and thrust forward for these functions to be supported and maintained.

3. Mandibular condylar cartilage, craniofacial sutures, and appositional-resorptive bone change facilitate pattern growth of the head and face. Koski<sup>17</sup> identifies the mandibular condyles, once considered growth centers with directive capacity, as an adaptive growth mechanism. Cartilage found at the head of the condyle is a secondary, fibrous cartilage and differs significantly from the primary, growth plate cartilage considered to be under high genetic control. During craniofacial growth, the



**Fig. 21.5** Cumulative growth curve for craniofacial bone and primary cartilage.

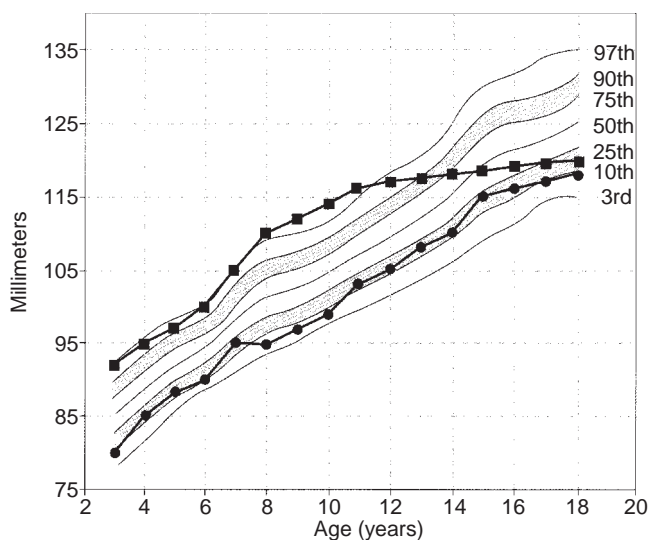
mandible is repositioned continuously to its best functional advantage. Reposturing alters the anatomic position of the condyle relative to that of the glenoid fossa. Compensatory growth of secondary condylar cartilage is one mechanism that facilitates the maintenance of mandibular position.

Koski<sup>17</sup> also noted that craniofacial sutures are important growth sites that serve to facilitate calvarial and midface growth. Calvarial sutures close by 5 years of age, but some facial sutures remain patent through puberty. Craniofacial bones are thrust apart by primary cartilage, and functioning space increases. Sutures enable osseous deposition to occur at bone edges, which allows bones of the face and skull to adapt.

Enlow and Hans<sup>18</sup> have shown that bone, unlike primary cartilage, is subject to environmental controls. Bone may assume many forms during growth; it is pressure sensitive, calcified, vascular, and relatively inflexible, and requires a covering membrane for survival. The craniofacial skeleton increases in size by way of surface addition only and increases in shape through differential appositional-resorptive bone growth. This differential growth process accounts for a considerable amount of size increase after middle childhood.

Growth theorists Moss and Salentijn<sup>15</sup> believe that the general somatic tissues (i.e., bone, muscle, and connective tissue) demonstrate growth change as a consequence of supporting the functioning operations of the head. Indeed, the research evidence of Linder-Aronson<sup>19</sup> and of Harvold et al.<sup>20</sup> is convincing in that bone and muscle, as basic tissues, are adaptive and compensatory. Understanding bone and muscle growth may come through understanding the temporal development of functioning spaces and the effects of interstitial cartilage expansion on surrounding tissues.

4. Growth of the head and face tends to demonstrate relative equivalency. Humans tend to grow with relative consistency. A percentile growth chart is a valuable instrument for assessing growth consistency over a time



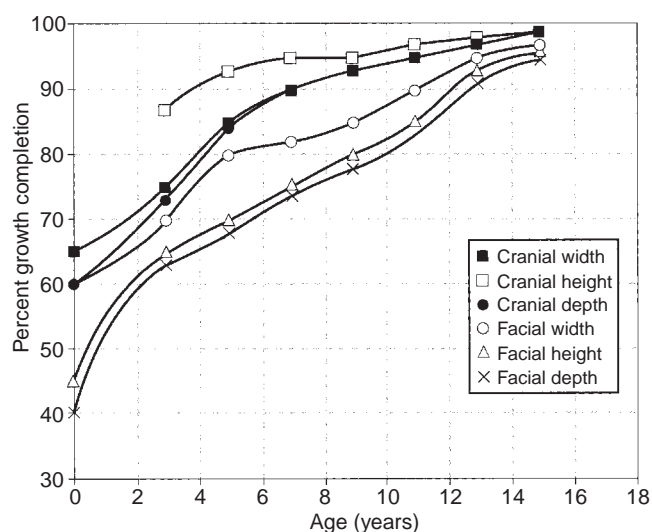
**Fig. 21.6** Cumulative growth chart for male face height (hard tissue nasion to menton), illustrating seven percentile levels. • Relatively normal growth; ■ deviation of several percentile levels during growth, suggestive of abnormalcy. (From Broadbent BH et al: *Bolton standards of dentofacial developmental growth*, St. Louis: Mosby; 1975.)

period (Fig. 21.6). Percentile charts are customarily divided into the following seven percentile levels: 97th, 90th, 75th, 50th, 25th, 10th, and 3rd. Healthy children tend to maintain a similar percentile level through successive stages of development. Deviations during growth of more than two percentile levels may indicate developmental problems, such as illness or disease.

Attributes (craniofacial parts) that are structurally related also maintain a consistent relationship throughout the successive stages of growth after infancy. Enlow and Hans<sup>18</sup> identify the dental arches of the maxilla and mandible as an example of a structural part-counterpart relationship. An Angle Class II skeletal pattern at 3 years of age is maintained into adulthood without corrective therapy. Both the dental arches in healthy individuals tend to increase in size at about the same rate. Therefore, balanced or equivalent growth tends to maintain architecturally related structures of any craniofacial pattern that is present after 2 years of age.

## BASIC CONCEPTS OF CRANIOFACIAL GROWTH

1. Different parts of the craniofacial complex grow at different times. The head takes on appearance characteristics unique to each particular growth stage. Different parts of the face experience differences in growth timing as well. The infant has a disproportionately large calvaria and forehead compared with the adult because growth of the neural tissue occurs earlier in life than facial growth. Size increase of the face and calvaria in the three spatial planes is a differential growth process. Scott<sup>21</sup> and Meredith<sup>22</sup> have contributed to an understanding of this process. By birth, the cranial height dimension attains about 70% of its adult status; cranial width, 65%; and cranial length or depth, 60% (Fig. 21.7). In contrast, only 40% of facial height and 45% of facial length (depth) is achieved by birth. Face width (i.e.,

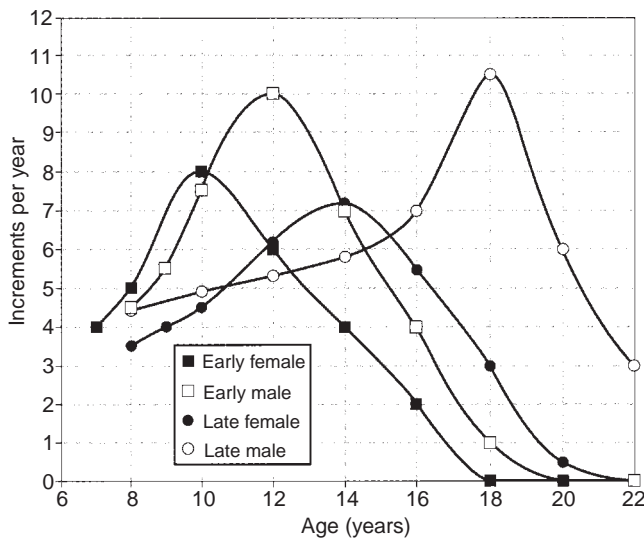


**Fig. 21.7** Cumulative growth curve for calvaria and face in width, height, and depth. (From Scott JH. The growth of the human face. *Proc R Soc Med.* 1954;47(2):91–100; Meredith HV. Changes in form of the head and face during childhood. *Growth.* 1960;24(215–264):218.)

bizygomatic and bigonial), on the other hand, attains about 60% of adult stature. Growth in face width actually falls between the classic neural and general somatic growth curves.

After birth, a pattern in facial growth timing emerges. The anterior cranial base completes most of its growth during infancy and early childhood, but frontal and nasal bones continue outward expansion through appositional-resorptive bone growth.<sup>23</sup> Growth magnitude and duration are greater for the anterior maxilla than for the forehead but less than for the anterior mandible. The posterior face demonstrates the greatest incremental growth during late puberty.

2. Differences in growth size, direction, velocity, and timing are observed among individuals. Bergersen<sup>24</sup> has also noted large variations in growth patterns among individuals and has shown that any measured attribute will demonstrate a range of expression about a central tendency. Incremental growth curves for healthy males and females will demonstrate the same general disposition but may show marked differences in maturation timing (Fig. 21.8). Generally, females mature 2 years earlier than males, but Valadian and Porter<sup>6</sup> have indicated that variations are so great that an early-maturing boy may mature earlier than a late-maturing girl. Males tend to grow larger in size than females.
3. The heads and faces of no two humans are exactly the same. Brodie<sup>25</sup> pointed out that no two humans are exactly the same. This fact is no more clearly evident than when one compares, at any given age, a measured attribute shared by healthy individuals. Most attributes have a range of expression that can be graphically illustrated by a normal distribution curve (Fig. 21.9). If the same attribute was measured in a population of individuals, the most frequently occurring value (mode), middle value in the series (median), or arithmetic average of all the measured values combined (mean) would represent the central tendency of the



**Fig. 21.8** Incremental growth curves for early- and late-maturing males and females.

population. Central tendency is often referred to as *normalcy*. Another way to describe attribute distribution is by using percentile equivalents. The 50th percentile indicates the center of the distribution, the 25th percentile the lower one-fourth, and so on.

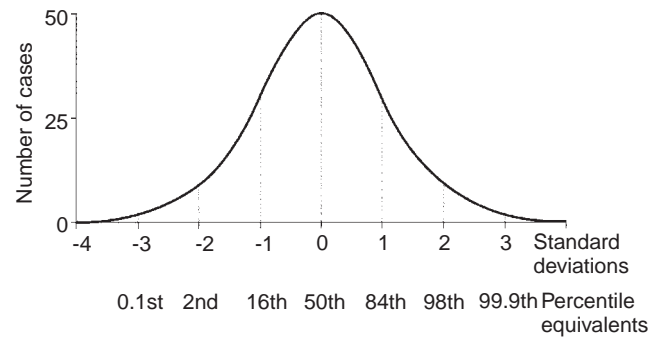
A third statistical parameter often used in growth literature to indicate distribution is the standard deviation (SD); SD of  $\pm 1$  includes about 68% of the entire population;  $\pm 2$  SD and  $\pm 3$  SD are equivalent to approximately 95% and 99% of the distribution, respectively. The mean values and SDs for a normative population are invaluable aids in describing a patient's condition. By comparing a patient's value to a population value for the same trait, the clinician can make statements about relative largeness or smallness. Generally, measurements beyond  $\pm 2$  SD are considered clinically important because those values fall outside 95% of the population on which the normative value is based.

In the remainder of this chapter, references are made to craniofacial growth principles and concepts in discussing growth of the face, occlusion, and dental arches.

## Craniofacial Pattern

In clinical assessment and treatment planning for the young patient, information about growth is often not considered to the degree that it should be. Craniofacial growth issues can be made more central to patient care concerns when a physical model is used to help visualize growth effects. Therefore, a particularly strong effort is made here to define physical craniofacial pattern.

There are two methods commonly used in dentistry to obtain information about craniofacial pattern. One method is to examine the patient physically at chairside. Information collected in this fashion is based on criteria contrived and established in the practitioner's mind. The second method is to analyze dental records. Historically, cephalometric analysis has been a particularly useful tool for collecting objective information about craniofacial patterns.



**Fig. 21.9** Normal distribution curve illustrating standard deviations and percentile equivalents.

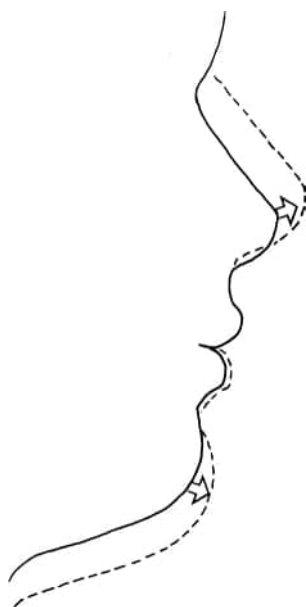Generally, the patient's radiographic values measured on the cephalogram are compared with normative values derived from a population database. In this way, degrees of normalcy can be estimated by the clinician. One database is unique in its composition in that only individuals presenting with optimal or ideal craniofacial pattern were included in the study.<sup>26</sup> This unique conceptual approach to defining craniofacial pattern enables the practitioner to make assessments about patient optimality. Patient-measured values are compared with values from cephalograms that have relatively ideal patterns. Cephalometric analysis is discussed in [Chapter 22](#). Darwis et al.<sup>27</sup> suggest that using a combination of methods, such as three-dimensional facial morphometry and Fourier analysis, can provide a more comprehensive knowledge of growth and development of craniofacial structures and thus may allow for the improved prediction of clinical outcomes. Fourier analysis is a mathematical curve-fitting procedure that can represent boundaries so that the outlines of objects can be addressed.

## IDEAL PARADIGMS FOR DENTOFACIAL PATTERN

Standards for chairside facial appraisal have been offered previously by various researchers.<sup>1,28–32</sup> Most of these physical appraisal models refer to the adult face. Horowitz and Hixon<sup>33</sup> have described idealized facial pattern as “the way things ought to be.” Models available for examining the face espouse an assessment of proportion, balance, and harmony—concepts that help define overall facial attractiveness. The concept of an ideal face can be a useful clinical tool if it is used properly and its limitations are acknowledged. The first limitation is the fact that an ideal has little or no biological basis. Biological data can neither refute nor support the contention that the face should be ideal. Second, faces do not need to be ideal to work properly; ideal pattern, for the most part, has little connection with physiologic function. Third, an ideal model is simply a mental construct, a fiction. The words *ideal paradigm* mean “perfect example.”

A perfect example, on the other hand, can be a powerful diagnostic and treatment-planning tool. The patient's facial pattern can be compared with criteria for idealness, the differences noted, and hence a problem list constructed. Criteria for an ideal face can help organize a vast array of information that is readily available to the clinician through physical observation. An ideal facial paradigm can





**Fig. 21.10** Graphic illustration of facial profile flattening from 6 years of age (solid line) to 18 years of age (broken line).

serve as a treatment-planning tool as well. Although the concept of an ideal face is fictitious and biologically unsupported, it can serve as a guide by providing an example toward which treatment may be directed. Ideal paradigms for dental occlusion and dental arch pattern are also represented in the dental literature; good examples may be found in the works of Angle,<sup>29</sup> Andrews,<sup>34</sup> and Roth.<sup>35</sup> The purposes served by these paradigms are the same as for ideal facial models; they are powerful diagnostic and treatment-planning aids.

## Growth and Facial Pattern

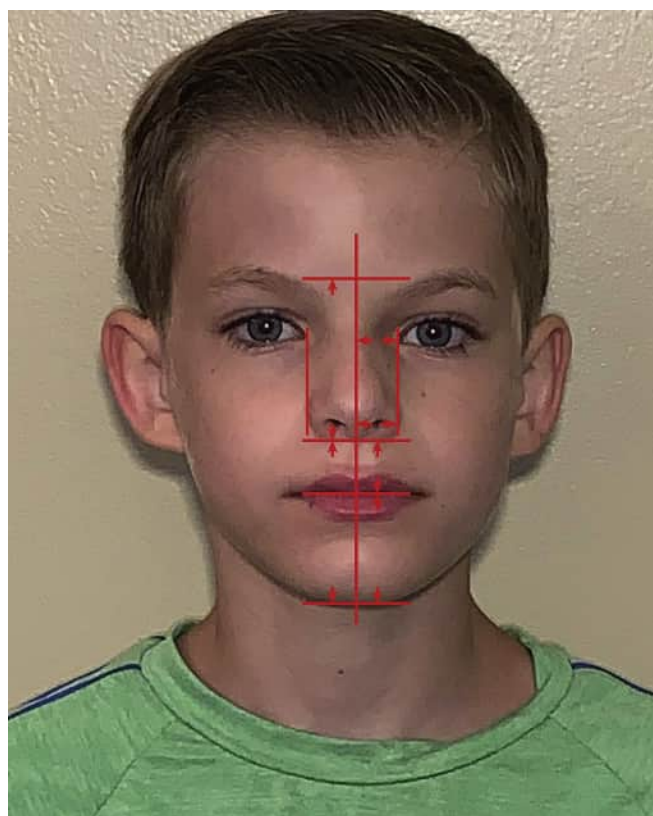
### CONSISTENCY IN PATTERN MATURATION

Following birth, the face increases in size to a greater extent than does the calvaria. Bell et al.<sup>30</sup> proposed that, by adulthood, the ideal face should be equally proportioned in forehead, midface, and lower face heights. Enlow<sup>36</sup> demonstrated that the facial profile flattens as the face ages. Nose and chin become more prominent, and lips become less pronounced (Fig. 21.10). Every healthy individual, regardless of the overall craniofacial pattern, experiences profile flattening and face height increases relative to the cranium.

### IDEAL FRONTAL FACIAL PATTERN

Criteria for facial idealness are age dependent. Because the face elongates and the profile becomes less convex with maturity, ideal criteria appropriate for the adult face would not necessarily apply to the younger face. The ideal frontal facial pattern for a 7-year-old child might include the following criteria (Fig. 21.11):

1. Right and left face halves are symmetrical.
2. Glabella (midpoint between eyebrows) to subnasale (point where columella merges with upper lip) equals subnasale to menton (inferior aspect of chin).



**Fig. 21.11** Ideal frontal facial pattern for a 7-year-old child.

3. Subnasale to lower border of upper lip represents one-third the distance from subnasale to menton.
4. The upper central incisor edge is 2 mm inferior to the lower border of the upper lip.
5. Alar base width equals inner canthal width.

### IDEAL FACIAL PROFILE PATTERN

Use of a reference plane is very helpful for evaluation of the facial profile at chairside. The Frankfort horizontal plane is an anthropometric reference line frequently used for analysis of the lateral face. It is defined by Farkas<sup>37</sup> as the superior limit of the external auditory meatus and the palpated border of the infraorbital bony rim. A second reference line constructed perpendicular to the Frankfort horizontal plane and through the glabella (FHP) has been used in lateral profile assessment by Legan and Burstone.<sup>38</sup>

The ideal profile pattern for a 7-year-old child might include the following criteria (Fig. 21.12):

1. Chin 5 mm behind FHP
2. Most anterior aspect of lower lip on FHP
3. Most anterior aspect of upper lip 5 mm ahead of FHP
4. Nasolabial angle of 100 degrees
5. No more than 2 mm lip separation when relaxed

### MAINTENANCE OF OVERALL PATTERN

The overall pattern presented by the individual at an early age will be maintained into adulthood. Although every individual experiences profile flattening and facial elongation as the face matures, Enlow et al.<sup>39</sup> demonstrated that

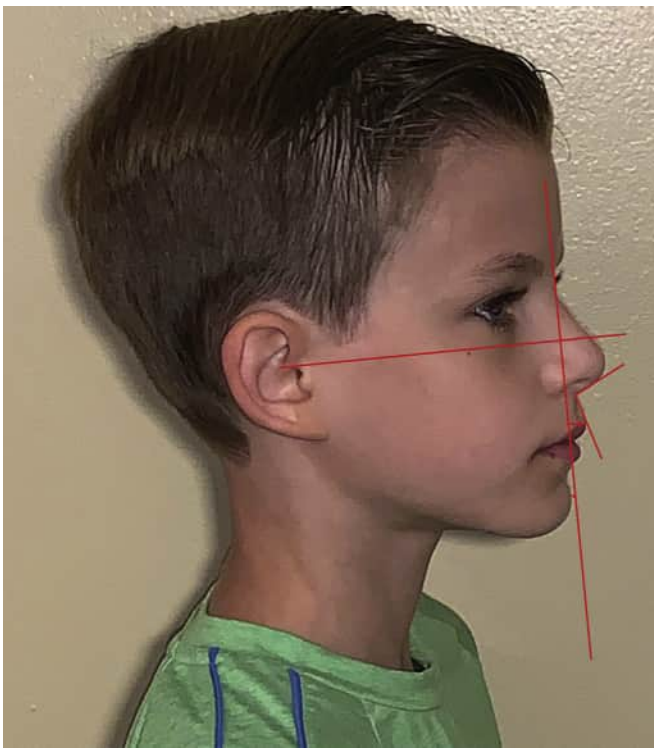


Fig. 21.12 Ideal profile facial pattern for a 7-year-old child.

the magnitude of these changes is not great enough to offset disharmonies in overall facial structure. Martinez-Maza et al.<sup>40</sup> examined facial bone modeling behaviors and confirmed that the skeletal components of the craniofacial complex maintain functional and structural balance integrity while increasing in size during growth. Discrepancies between the positions of the maxilla and mandible persist throughout life unless clinical therapy is used to rectify the disharmonies.

At chairside, disharmony between the maxilla and the mandible can be simply and readily identified. A list of differences can be formulated by comparison of the patient's facial measurements with the criteria of an ideal face. The differences serve as a patient problem list. Adding average growth change (i.e., magnitude, direction, and velocity) to the pattern presented by the individual will give an estimate of how facial patterns will look at a later age. This growth scheme is known as a *mean-change-expansion scheme*.<sup>33</sup> Balbach<sup>41</sup> demonstrated it to be the most useful way to predict the effects of growth on facial pattern. The mean-change-expansion scheme is useful for evaluation of almost all patients routinely seen in the dental office. Balanced or average growth affecting all aspects of the head and face relatively equally, however, cannot be assumed for all patients. The heads and faces of individuals who have some craniofacial congenital anomalies, hypoplastic defects, or acquired deformities that alter primary or compensatory craniofacial growth mechanisms do not grow in a typical manner.

Because growth change in healthy children affects the face in a relatively consistent and predictable way, the key to facial diagnosis and treatment planning is the clinician's ability to identify and diagnostically describe facial pattern.

Identification of a balanced, proportional facial pattern, as well as recognition of facial imbalances, should be routine during patient assessment. The use of criteria related to ideal facial patterns can be helpful.

The goal in treating facial imbalance in children is to establish architectural balance in the facial pattern. If corrective measures include compensation for the effects from treatment rebound or relapse, the facial pattern established by therapy will be maintained. As the face continues to grow and increase in size, all structurally related parts of the treated face will undergo relative growth equality.

Correction of facial imbalance in the child is achieved through clinical manipulation of the means by which adaptive, compensatory facial growth occurs. Some sutures of the upper face remain patent into adolescence. Application of forces through orthopedic headgear, controlled in direction and amount, can result in an alteration of maxillary growth direction and, ultimately, of maxillary position. Also, maxillary transverse size can be increased by judicious expansion of the palatal suture. The secondary cartilage of the mandibular condyle remains responsive to mechanical stimulation throughout life, but appositional response of this fibrocartilage decreases with age, as shown by McNamara and Carlson.<sup>42</sup> Facial bones respond to changes in microenvironmental stress and strain by changing form. Patterns of osseous deposition and resorption can be altered by the use of appliances that carefully load bone with physiologically compatible biomechanical forces.

Successful treatment of a child with facial imbalance secondary to mandibular retrognathia, for example, involves manipulation of several growth mechanisms. Mandibular anterior repositioning with a functional appliance probably affects many sites. Graber and Swain<sup>43</sup> believe that modification of the dentofacial complex occurs by the following means:

1. Condylar growth (secondary cartilage growth)
2. Glenoid fossa adaptation (apposition-resorption bone growth)
3. Elimination of functional retrusion
4. More favorable mandibular growth direction
5. Withholding of downward and forward maxillary arch movement (apposition-resorption bone growth)
6. Differential upward and forward eruption of the lower buccal segment (apposition-resorption bone growth)
7. Orthopedic movement of the maxilla and upper dentition (maxillary suture system growth)

## FACIAL GROWTH EMULATES GENERAL SOMATIC GROWTH

The degree to which the facial pattern can be altered through biomechanical therapy depends on the amount of growth potential remaining. In general, the magnitude of facial pattern alteration possible is inversely proportional to age: the older the individual, the less the facial pattern can be therapeutically modified. The opportunity to alter compensatory, adaptive growth mechanisms is also greater in a rapidly growing individual. Mellion et al.<sup>44</sup> reported that the adolescent growth spurt is characterized by increased growth velocity onset and peak at about 9.6 and 11.5 years of age for girls and 12 and 14.3 years of age

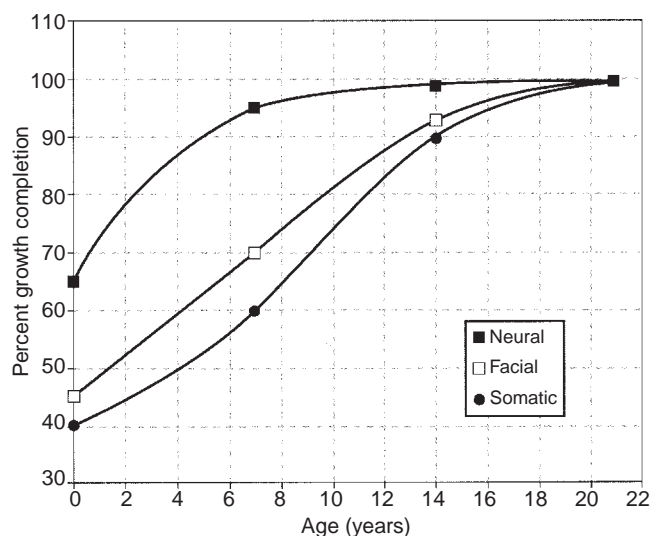


Fig. 21.13 Cumulative growth curves for neural, facial, and general somatic tissues.

for boys. The maximum velocity or peak height velocity of growth is attained approximately 2 years after pubertal onset. Cumulative facial growth closely parallels general somatic growth (Fig. 21.13). Analysis of skeletal hand development can be helpful in estimating general skeletal maturation and, hence, facial skeletal maturation. It is relevant to evaluate a child's maturity in direct relation to the child's own pubertal growth spurt to assess whether maximum pubertal growth is imminent, has been reached, or has been passed.

## Growth and Pattern of Occlusion

### CONSISTENCY IN PATTERN DEVELOPMENT

Usually, no teeth are clinically visible at birth. Leighton<sup>45</sup> demonstrated that the upper anterior gum pad (intercuspid width) is typically wider than the lower anterior pad, and the upper anterior gum pad protrudes (overjet) about 5 mm relative to the lower anterior gum pad. The upper anterior gum pad usually overlaps (overbite) the lower anterior pad by about 0.5 mm. In the first 6 months of postnatal life, there is marked palatal width increase, and the overjet decreases rapidly.

### PRIMARY DENTITION TERMINUS

By 3 years of age, the occlusion of 20 primary teeth is usually established. The relationship of the distal terminal planes of opposing second primary molar teeth can be classified into one of three categories (Fig. 21.14). A flush terminal plane (flush terminus) means that the anterior-posterior positions of the distal surfaces of opposing primary second molars are in the same vertical plane. A mesial-step terminus is defined as a lower second primary molar terminal plane that is mesial to the maxillary primary terminus. The distal-step terminal plane is a situation in which the mandibular second primary molar terminus is distal to the upper second primary molar terminus.

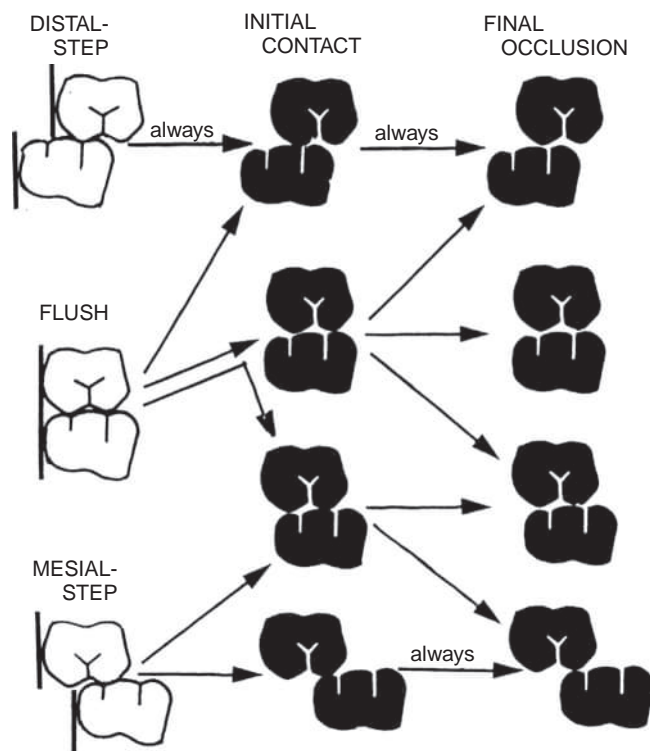


Fig. 21.14 Graphic illustration of permanent first molar occlusion development. Outlined crown images represent three terminal plane relationships of primary second molars at about 5 years of age. Darkened images represent various permanent first molar relationships at initial occluding contact (about 6½ years of age) and at full occlusion contact (about 12 years of age). (From Arya BS, Savara BS, Thomas DR. Prediction of first molar occlusion. *Am J Orthod.* 1973;63(6):610–621; Carlsen DB, Meredith HV. Biologic variation in selected relationships of opposing posterior teeth. *Angle Orthod.* 1960;30(3):162–173; Moyers RA: *Handbook of orthodontics*, 3<sup>rd</sup> ed. Chicago: Mosby; 1973.)

Statistical studies of primary terminal plane status report that 49% of the time, the terminal plane of the lower primary second molar is mesial to the upper terminus (mesial step); the lower terminus is flush with the upper terminus 37% of the time; and the distal-step primary terminus is seen in approximately 14% of cases. These data are derived from studies reported by Arya et al.<sup>46</sup> and by Carlsen and Meredith.<sup>47</sup>

### OPPOSING FIRST MOLARS AT INITIAL CONTACT

The permanent first molars are clinically visible at about 6 years of age and are the first permanent teeth to emerge. The relationship of permanent first molars when initial occluding contact occurs during eruption may be represented by one of four categories (Fig. 21.14). A Class I relationship means that the mesial-buccal (m-b) cusp of the upper permanent molar is in contact at or very near the buccal groove of the lower permanent first molar. This occurs approximately 55% of the time. An end-on relationship means that m-b cusps of both molars oppose one another. The incidence of this situation is about 25%. A Class II relationship, occurring 19% of the time, is one in which an upper m-b cusp is anterior to the lower m-b cusp. Class III represents the situation in which an upper m-b cusp is distal to the lower buccal groove. This occurs in only 1% of the population.<sup>47</sup>



**TABLE 21.1** Incidence of Terminal Molar Relationships at Three Stages of Occlusion Development

Primary Terminal Plane at Age 5 Years	Initial Permanent First Molar Occlusion at Age 6½ Years	Final Occlusion at About Age 12 Years
49% Class I (ms)	1% Class III	3% Class III
37% Flush	27% Class I	59% Class I
14% Class II (ds)	49% End-on	
	23% Class II	39% Class II

ds, Distal step; ms, medial step.

Arya BS, Savara BS, Thomas DR. Prediction of first molar occlusion. *Am J Orthod.* 1973;63(6):610–621.

Carlsen DB, Meredith HV. Biologic variation in selected relationships of opposing posterior teeth. *Angle Orthod.* 1960;30(3):162–173.

Table 21.1 shows the incidence of medial-step, flush, and distal-step primary terminus and end-on, Class I, Class II, and Class III permanent first molar occlusions during the three stages of occlusion development.<sup>46,47</sup>

## IDEAL STATIC OCCLUSION PATTERN

The concept of ideal occlusion development has been described by Sanin and Savara<sup>48</sup> who have also shown that, to a considerable extent, ideal occlusion at a young age predisposes to an ideal adult occlusion. The most desirable occlusion in the permanent dentition is a Class I interdigitation, and certain features in the primary and mixed dentitions, if observed accurately, can provide clinical clues as to whether a Class I relationship of the dentition will eventually develop.

The major difference between ideal adult and child occlusions is the teeth present. By 7 years of age, the primary central and lateral incisors have been or are in the process of being replaced by their permanent successors, and the permanent first molars are already erupted. The primary dentition remaining usually includes the canine and first and second molars of both arches. Criteria for ideal dental occlusion for a 7-year-old child might include the following:

1. Class I molar and canine interdigitation
2. 2-mm anterior and posterior overjet
3. 2-mm anterior overbite
4. Coincident dental midlines

## MAINTENANCE OF OVERALL PATTERN

Gum pad relationships at birth cannot be used as reliable diagnostic criteria for predicting subsequent arch relationship. The primacy of life-supporting functions (i.e., respiration and swallowing) is so great at birth that major unpredictable adjustments in maxillary and mandibular positions take place in the first few years of life. By 3 years of age, however, the relationship of maxilla to mandible is well established, and the overall maxillomandibular pattern does not change significantly thereafter.

One key diagnostic feature regarding future occlusion status is the relationships of the primary terminal planes. The likelihood of a Class I relationship developing in the permanent dentition is greatest when a mild mesial-step terminus exists during the primary dentition stage (Fig. 21.14). If an exaggerated mesial step exists, a Class III permanent molar relationship will develop. The possibility that a Class

I relationship will develop from a distal-step primary terminus is virtually nonexistent. Hence, the presence of a distal step is highly predictive of a developing Class II permanent molar relationship.

Another important diagnostic feature that is predictive of later occlusion status is the relationships of the first permanent molars during initial occluding contact. The first permanent molars erupt between 5 and 7 years of age. The chance that a Class I interdigitation of the dentition will evolve is best when a Class I relationship is represented at initial permanent first molar occluding contact. A Class II first permanent molar occlusion at initial occluding contact will predictably remain a Class II occlusion into the complete adult dentition. Also indicative of a developing malocclusion are some initially occluding end-to-end relationships. Three quarters of initially contacting end-on first molar occlusions will shift toward a Class I during the transition dentition phase. However, 25% of these end-on relationships will shift into a Class II relationship. A Class III occlusion at initial contact will predictably lead to a future Class III molar relationship. This discussion regarding diagnostic and predictive information is based on the work of Arya et al.,<sup>46</sup> Carlsen and Meredith,<sup>47</sup> and Moyers.<sup>49</sup>

The development of the transitional-phase occlusion and malocclusion is graphically illustrated in Fig. 21.14. Note that the distal-step terminus always leads to Class II initial contact and final permanent first molar occlusions. The probability that a Class III final first permanent molar relationship will develop from a Class III initial contact occlusion is also very high. Development of the occlusion from flush terminus, end-on, and Class I initial contact molar relationships is highly variable.

The occlusion relationship of upper to lower dentition remains nearly the same throughout the growing period.<sup>50</sup> Exceptions are cases in which environmental factors, such as premature loss of primary teeth, are superimposed on the developing occlusion, as shown by Northway et al.<sup>51</sup> Carlsen and Meredith<sup>47</sup> demonstrated that, 70% of the time, the lower permanent first molars move mesially relative to the upper permanent first molars during the transition occlusion phase. The magnitude of this shift, however, typically does not compensate for a permanent first molar malocclusion. Overall occlusion pattern is maintained during growth.

## Growth and Dental Arch Pattern

### SIMILAR STAGE SEQUENCING

The stage sequence of dental arch development is the same for everyone. According to Nery and Oka,<sup>52</sup> the crowns of primary teeth begin calcification between 3 and 4 months prenatally. The calcification of mandibular teeth usually precedes that of the maxillary dentition; the central incisors typically show first evidence of calcification and the second molars last. Boys typically begin calcification before girls.

The first primary tooth to erupt is the central incisor at about 7½ months, and the last to erupt is the second primary molar at about 2½ years. Closure of the root apex occurs at 3 years for the second primary molar. The usual sequence of primary dentition eruption is the central incisor (in Palmer notation, designated by the letter A), the lateral incisor (B), the first primary molar (D), and the canine (C),

followed by the second primary molar (E). Hence, the typical eruption sequence is A-B-D-C-E.

Calcification of the permanent teeth does not begin until after birth.<sup>53</sup> The first permanent molar is the first to show evidence of calcification, which occurs during the second postnatal month. The third molar is the last to begin calcification, which occurs at about 9 years.

The typical eruption sequence for the mandibular arch is as follows: first molar (in Palmer notation, designated by the number 6), central incisor (1), lateral incisor (2), canine (3), first premolar (4), second premolar (5), and second molar (7), followed by the third molar (8). For the maxillary arch, the usual sequence of eruption for the permanent teeth is as follows: 6-1-2-4-5-3-7-8. Eruption timing in girls generally precedes that in boys by an average of 5 months.

Eruption times for permanent teeth can vary considerably depending on the specific tooth. According to Garn,<sup>7</sup> eruption time for the lower incisor varies the least; 90% of lower permanent incisors erupt within a span of 3 years. In contrast, eruption time varies the most for the lower second permanent premolar, which shows a 6½-year span.

Dimensional changes for dental arch length, circumference, and intermolar and intercanine widths during childhood and adolescence have been compiled by Moorrees.<sup>53,54</sup> Average dimensional dental arch changes from ages 6 to 18 years for maxillary and mandibular arches are as follows:

Lower Arch	
Arch width	Bicanine: 3 mm increase; Bimolar: 2 mm increase
Arch length	1 mm secondary to incisor uprighting
Arch circumference	4 mm decrease
Upper Arch	
Arch width	Bicanine: 5 mm increase; Bimolar: 4 mm increase
Arch length	Slight decrease secondary to incisor uprighting
Arch circumference	1 mm increase

### IDEAL DENTAL ARCH PATTERN

Development of dental arch malocclusion is predictable. Likewise, development of a clinically acceptable dental arch can be predicted. The status of the dental arch at mid-adolescence is contingent on clinical features that can be easily recognized during the transition phase dentition. The simplest method of evaluating the dental arch for factors predisposing to malocclusion is to compare the patient's mixed dentition dental arch with an ideal dental arch pattern.

For the dental arch, the ideal pattern for a 7-year-old child might meet the following criteria:

1. Tight proximal contacts.
2. No rotations.
3. Specific buccal-lingual axial inclinations.
4. Specific mesial-distal axial inclinations.

5. Even marginal ridges vertically.
6. Flat occlusal plane.
7. Excess (positive) leeway space.

Ethnic background can make a difference in the dentition and occlusal development. An interesting study by Anderson<sup>55</sup> showed that the primary dental arch dimensions of African-American children were significantly larger than those of European-American children in arch width, length, perimeter, and interdental space.

### TOOTH SIZE/ARCH SIZE RATIO AS PATTERN DETERMINANT

Tooth size and alveolar size are the primary factors that determine the status of the permanent dental arch. If tooth size and arch size are not balanced, the effect on the permanent dental arch is crowding or spacing. Crowding is the most common feature of dental arch malocclusion. Only when the combined size of the permanent teeth is balanced with the size of the alveolar apical area is an ideal dental arch possible.

Van der Linden<sup>56</sup> referred to the alveolar bone surrounding the dental apex regions as the *apical area*. Ten Cate<sup>57</sup> reported evidence that the alveolus probably forms as a result of inductive action from cells of the dental follicle. The size of alveolar bone is influenced by the many environmental factors that affect intramembranous bone growth. It is possible to clinically increase or decrease the size of the alveolar apical area during growth. Fränkel<sup>58</sup> has demonstrated that the alveolar arch size can be increased dramatically during childhood and that the increases are stable into adulthood.

For the purpose of discussing dental arch development, tooth size refers to the mesial-distal dimensions of each tooth. According to Garn<sup>7</sup> and Potter et al.,<sup>8</sup> mesial-distal tooth size is determined primarily by genetic factors. Four chromosomal gene loci appear to be responsible for mesial-distal maxillary tooth size, and the mandibular dentition seems to be under the genetic control of six loci. Tooth size is polygenically determined and continuously variable (i.e., a wide range of individuality exists in terms of the width of any single tooth). Dental size is expressed through X-linked inheritance, and racial differences are known. The upper lateral incisor shows the most variability in tooth size.

Tooth size and alveolar apical area size are the most pertinent factors in the determination of the intraarch component of malocclusion. Therefore, it is relevant to consider these factors at length. The alveolar apical area will respond to biomechanical stimulation from orthodontic appliances because intramembranous bone is adaptive and compensatory. Crown size, on the other hand, cannot be predictably influenced during growth by clinical therapy.

The clinical crowns of all permanent teeth, except for the third molar, are completely formed by middle childhood. Mesial-distal crown widths will not change after crown formation unless affected by factors such as caries. Hence, mesial-distal crown dimension is a stable factor in the tooth size/arch size ratio. In an attempt to exploit the clinical usefulness of crown dimension stability, tooth size relationships are examined.

Comparison of primary and permanent mesial-distal tooth sizes is one such consideration. Moorrees<sup>54</sup> revealed that there is little about primary dentition size that predicts

permanent dentition size. Correlation coefficient ( $r$ ) values ranging from  $r = .2$  to  $r = .6$  are indicative of the poor predictive relationship between primary mesial-distal tooth sizes and the sizes of their permanent successors. Correlation coefficients of  $r = .8$  or higher are required to make predictions for the individual patient at chairside.<sup>32</sup> The combined mesial-distal sizes of all primary teeth and the combined sizes for the permanent teeth show a correlation of  $r = .5$ . Therefore, Moorrees<sup>53</sup> concluded that the sizes of the primary teeth are of little predictive value in estimating the sizes of their permanent successors.

The strength of the size relationships among the permanent teeth, however, is clinically important for some comparisons. Potter and Nance<sup>59</sup> demonstrated that the size of an individual tooth is highly correlated with the size of the contralateral tooth in the same arch, as reflected in an  $r$  value of around .9. The combined mesial-distal dimensions of contralateral quadrants of teeth show a slightly higher correlation of  $r = .95$ . Intraarch comparisons of tooth groupings, such as mesial-distal size of the lower incisors versus mesial-distal sizes of the lower canine and premolars combined, show only moderate correlation ( $r = .6$ ) and therefore are not clinically useful.<sup>60</sup>

### COMPUTATION OF TOOTH SIZE/ARCH SIZE BALANCE

The primary reason for dental arch malocclusion is imbalance between the tooth size and alveolar apical size. In the transition (mixed) dentition, it is possible to accurately determine if combined mesial-distal tooth size will be balanced with alveolar arch size in later life. This process of determination is called *mixed dentition space analysis*. Common to all mixed dentition space analysis methods is the attempt to determine the combined mesial-distal size of the unerupted permanent canine and first and second premolars. According to Horowitz and Hixon,<sup>33</sup> the lower dental arch is the focus for space analysis and the basis of orthodontic diagnosis and treatment planning. The mandibular alveolar base can be modified less therapeutically than can the upper alveolus and therefore restricts treatment possibilities. The mandibular arch also undergoes less growth change than the upper arch.

Efficacy studies by Gardner,<sup>61</sup> Kaplan et al.,<sup>62</sup> and Staley et al.<sup>63,64</sup> revealed one method to be the most accurate in predicting the combined size of the unerupted canine and premolars during the mixed dentition. This method, originally devised by Hixon and Oldfather,<sup>60</sup> has been refined by Bishara and Staley.<sup>65</sup> In summary, the analysis involves the following steps:

1. Measure the combined width of the lower lateral and central incisors on one side.
2. Measure (directly from the radiograph) the crown sizes of the unerupted 4-5 on the same side.
3. Add the incisor and the premolar sizes.
4. Refer to the prediction chart to determine the sizes of the unerupted 3-4-5.

Techniques of mixed dentition space analysis allow for the estimation of the sizes of the unerupted canine and premolars on the lower arch. This size estimate must then be compared with a measurement of the arch space available

between the mesial aspect of the lower molar and the distal aspect of the lateral incisor in the same quadrant. The difference between the combined width of the three unerupted permanent teeth and this arch space has been called *leeway space*.

The most favorable dental arch pattern is one in which leeway space is excessive (i.e., combined size of unerupted canine and premolars is smaller than arch space available). If leeway space is deficient, dental arch crowding predictably results. Average growth changes in the dental arch are not great enough to compensate for leeway deficiencies.

### COMPENSATIONS IN DENTAL ARCH DEVELOPMENT

Tooth size/arch size imbalances result in dental arch conditions that are less than ideal. When combined mesial-distal tooth size exceeds alveolar arch size, compensatory adjustments occur, resulting in dental arch crowding, excessive curve of Spee, or deviant axial tooth inclinations. Dental spacing results when alveolar arch size exceeds the combined mesial-distal size of the teeth.

Competent treatment planning during the mixed dentition must account not only for differences between the size of unerupted canine and premolars and the space available for them, but also for compensating dental factors. Ideal dental arch status provides a model for such planning. Each compensating factor (i.e., crowding, spacing, excess occlusal curve, or deviant axial tooth position) can be appraised relative to an ideal dental arch. Alteration of a crowded arch to an ideally aligned arch is not possible without creating extra space to resolve the crowding. Consequently, a competent dental arch treatment plan must specify the manner in which space will be clinically created. Several means are available for creating dental arch space:

1. Move molars distally.
2. Decrease the mesial-distal dimension of the teeth present in the arch.
3. Increase the buccal-lingual axial inclination of the incisors.
4. Reduce the number of teeth in the arch by extraction.

Resolution of an excessive occlusal curve also requires more space. Kirschen et al.<sup>66</sup> indicated that for 3 mm of excessive occlusal curve anterior to the second molars, 1 mm of arch length space is required. For labially inclined incisors to be uprighted, arch length space is also required. In contrast, more arch length is created when retroclined incisors are proclined through therapy; the length of the arch is increased by repositioning the incisal edges from a lingual to a more labial position.

### MAINTENANCE OF OVERALL PATTERN

Space analysis combined with evaluation of the impact of compensating factors on dental arch status is the means by which overall space requirements for the lower arch can be determined during the mixed dentition phase. Overall space appraisal during the mixed dentition is highly indicative of future arch status. The condition presented during the mixed dentition will, to a high degree, be maintained in the permanent dental arch. For this reason, a nonideal adult



**TABLE 21.2** Clinical Disposition Guidelines for Various Dental Arch Space Conditions Resulting From Overall Mixed Dentition Space Appraisal

Overall Appraisal	mm	Clinical Disposition
Large space excess	Greater than +3	Long-term planning
Space excess	Less than +3 to 0	No action; observation
Equivalency	0	Careful observation
Deficiency	Less than -3 to 0	Lower lingual holding arch
Moderate deficiency	-3 to -6	Space regaining or arch expansion
Large deficiency	Greater than -6	Space regaining, arch expansion, or extraction

arch status can be anticipated early, and many undesirable conditions can be resolved during the transition from the primary to the permanent dental arch.

Overall space appraisal is typically expressed as millimeters of arch length space excess or deficiency. Dental arch space excess (1–2 mm) is a relatively ideal situation. Clinically, little intervention is usually required because mesial drifting of the permanent teeth often results in little or no crowding or residual spacing. Space excess exceeding 3–4 mm, however, can lead to dental arch problems. For example, congenital absence of one or more teeth can leave so much arch space that mesial drifting cannot compensate. Decisions favoring retention of primary teeth as long as possible, extraction of primary teeth and retention of space for later restorative prosthesis, or extraction followed by space closure must be made as long-term planning decisions.

Space deficiencies less than -2 mm can usually be managed with a lower lingual holding arch. Arch space deficiencies of from -3 to -6 mm should be scrutinized carefully. Typically, a space-regaining lower lingual arch or arch length expansion treatment measure is indicated. Arches with deficiencies in excess of -6 mm are candidates for aggressive space-regaining techniques, dental arch expansion treatment, or one of several serial extraction sequences. The clinical approach to various conditions of space excess and deficiency is based on overall space appraisal (space analysis plus compensating factors), as shown in [Table 21.2](#).

## EFFECTS OF ENVIRONMENTAL FACTORS ON DENTAL ARCH PATTERN

The primary determinant of dental arch malocclusion is the mesial-distal tooth size/arch size imbalance. Nevertheless, secondary factors can dramatically influence the disposition of the dental arch during childhood. Dental arch status is subject to the ravaging effects of environmental factors that can include early loss of primary teeth, interproximal caries, pathology, ankylosis of primary teeth, oral habits, trauma, and early eruption of permanent second molars.

The environmental factors most commonly affecting dental arch status are probably caries and premature loss of primary teeth. Early primary tooth loss and caries can have a profound effect on dental arch status. Caries and early loss of the primary first molars (D), second molars (E), or both (D

+ E) result in a decrease in the dental arch length. A study by Northway et al.<sup>51</sup> showed the following specific details:

1. E loss had the most deleterious effect on dental arch length.
2. Early posterior primary loss resulted in space closure of 2–4 mm per quadrant in both arches.
3. Space loss was age-related in the upper but not in the lower arch.
4. Upper D loss typically resulted in blocked-out canines; upper E loss usually led to an impacted second permanent premolar.
5. The greatest space loss was caused by mesial molar movement.
6. More space was lost in the first year after premature tooth loss than in successive years.
7. No recovery of space was demonstrated during growth in the upper arch, and little was found in the lower arch.

## Summary

This chapter integrates basic growth principles with patient appraisal to enhance diagnostic and treatment-planning efficacy. Merging growth principles with dentofacial pattern brings to light-specific growth features pertinent to clinical patient care decision making. This chapter focused on growth events germane to a better understanding of malocclusion as it affects the face, occlusion, and dental arches. Two themes were consistent throughout the chapter. First, overall pattern is maintained from early childhood until growth completion. Growth change affects architecturally equivalent structures in a balanced way. For this reason, craniofacial pattern can be predicted to a great extent. The best estimation of future status is obtained by taking the pattern present at an early age and adding the average growth change. Second, dentofacial pattern changes regionally as an individual matures, and these maturation changes are common in all healthy individuals. Regional variation introduced by the maturing process, however, is not great enough to alter the overall dentofacial pattern.

## References

1. Lucker GW. Psychological aspects of facial form, Monograph No. 11. *Craniofacial growth series*, Ann Arbor.
2. Attanasio C, Nord AS, Zhu Y, et al.: Fine tuning of craniofacial morphology by distant-acting enhancers, *Science* 342(6157):12410061–12410068, 2013.
3. Karamesinis K, Basdra EK: The biological basis of treating jaw discrepancies: an interplay of mechanical forces and skeletal configuration, *Mol Basis Dis* 1864(5):1675–1683, 2018.
4. Ferguson DJ, Wilcko MT: Tooth movement mechanobiology: Toward a unifying concept. In Shroff B, editor: *Biology of orthodontic tooth movement—current concepts and applications in orthodontic practice*, Cham, Switzerland, 2016, Springer International Publishing AG, pp 13–44. (Chapter 2).
5. Mao JJ: Mechanobiology of craniofacial sutures, *J Dent Res* 81(12):810–816, 2002.
6. Valadian I, Porter D. Physical growth and development: from conception to maturity. Boston: John Wright-PSG.
7. Garn SM. Genetics of dental development. In McNamara Jr JA, editor: *The biology of occlusal development*. University of Michigan: Monograph No. 7. Craniofacial growth series, Ann Arbor.
8. Potter RH, Nance WE, Yu PL, et al.: A twin study on dental dimension. II. Independent genetic determinants, *Am J Phys Anthropol* 44(3):397–412, 1976.

9. Linder-Aronson S, Leighton BC: A longitudinal study of the development of the posterior nasopharyngeal wall between 3 and 6 years of age, *Eur J Orthod* 5(1):47–58, 1983.
10. Enlow DH, Hans MG. Essentials of facial growth. Philadelphia: WB Saunders.
11. Scott JH: The cartilage of the nasal septum, *Br Dent J* 95:37–43, 1953.
12. Sperber GH. Craniofacial embryology. 3rd ed. John Wright-PSG: Boston.
13. Latham RA: Maxillary development and growth: the septopremaxillary ligament, *J Anat* 107:471, 1974.
14. Gange RJ, Johnston LE: The septopremaxillary attachment and midfacial growth, *Am J Orthod* 66(1):71–81, 1979.
15. Moss ML, Salentijn L: The primary role of functional matrices in facial growth, *Am J Orthod* 55(6):566–577, 1969.
16. Moss ML, Salentijn L: The capsular matrix, *Am J Orthod* 56(5):474–490, 1969.
17. Koski KL: Cranial growth centers: facts or fallacies? *Am J Orthod* 54(8):566–583, 1968.
18. Enlow DH, Hans MG. Handbook of facial growth. Philadelphia: WB Saunders.
19. Linder-Aronson S: Effects of adenectomy on dentition and nasopharynx, *Am J Orthod* 65(1):1–15, 1974.
20. Harvold EP, Tomer BS, Vargervik K, et al.: Primate experiments on oral respiration, *Am J Orthod* 79(4):359–372, 1981.
21. Scott JH: The growth of the human face, *Proc R Soc Med* 47(2):91–100, 1954.
22. Meredith HV: Changes in form of the head and face during childhood, *Growth* 24(215–264):218, 1960.
23. Stramud L: External and internal cranial base, *Acta Odontol Scand* 17:239–266, 1959.
24. Bergersen EO: The directions of facial growth from infancy to adulthood, *Angle Orthod* 36(1):18–43, 1966.
25. Brodie AG: Facial patterns: a theme on variation, *Angle Orthod* 16(3):75–87, 1946.
26. Broadbent BH, Broadbent BH, Golden WH. *Bolton standards of dentofacial developmental growth*. St. Louis: Mosby; .
27. Darwis WE, Messer LB, Thomas CD: Assessing growth and development of the facial profile, *Pediatr Dent* 25(2):103–108, 2003.
28. Ackerman JL, Proffit WR: The characteristics of malocclusion: a modern approach to classification and diagnosis, *Am J Orthod* 56(5):443–454, 1969.
29. Angle EH. *Treatment of malocclusion of the teeth*, ed 7, Philadelphia: SS White Dental Mfg;
30. Bell WH, Proffit WR, White RP. Surgical correction of dentofacial deformities (vol 1). Philadelphia: WB Saunders; .
31. Cox NH, Van der Linden F: Facial harmony, *Am J Orthod* 60(2):175–183, 1971.
32. Patterson CN, Powell DG: Facial analysis in patient evaluation for physiologic and cosmetic surgery, *Laryngoscope* 84(6):1004–1019, 1974.
33. Horowitz SL, Hixon EH. The nature of orthodontic diagnosis. Mosby: St. Louis; .
34. Andrews LF: Six keys to normal occlusion, *Am J Orthod* 62(3):296–309, 1972.
35. Roth RH: Functional occlusion for the orthodontist. Part III, *J Clin Orthod* 15(2):100–123, 1981.
36. Enlow DH: A morphogenetic analysis of facial growth, *Am J Orthod* 52(4):283–299, 1966.
37. Farkas LG. Anthropology of the head and face in medicine. Elsevier: New York; .
38. Legan HL, Burstone CJ: Soft tissue cephalometric analysis for orthognathic surgery, *J Oral Surg* 38(10):744–752, 1980.
39. Enlow DH, Moyers RE, Hunter WS, et al.: A procedure for the analysis of intrinsic facial form and growth, *Am J Orthod* 56(1):6–23, 1969.
40. Martínez-Maza C, Rosas A, Nieto-Díaz M: Postnatal changes in the growth dynamics of the human face revealed from bone modelling patterns, *J Anat* 223(3):228–241, 2013.
41. Balbach DR: The cephalometric relationship between the morphology of the mandible and its future occlusal position, *Angle Orthod* 39(1):29–41, 1969.
42. McNamara JA, Carlson DS: Quantitative analysis of temporomandibular joint adaptations to protrusive function, *Am J Orthod* 76(6):593–611, 1979.
43. Graber TM, Swain BF. *Orthodontics: current principles and techniques*. Mosby: St. Louis.
44. Mellion ZJ, Behrents RG, Johnston Jr LE: The pattern of facial skeletal growth and its relationship to various common indexes of maturation, *Am J Orthod Dentofacial Orthop* 143(6):845–854, 2013.
45. Leighton BC. Early recognition of normal occlusion. In McNamara JA, editor: *The biology of occlusion development*. University of Michigan: Monograph No. 7, Craniofacial growth series, Ann Arbor.
46. Arya BS, Savara BS, Thomas DR: Prediction of first molar occlusion, *Am J Orthod* 63(6):610–621, 1973.
47. Carlsen DB, Meredith HV: Biologic variation in selected relationships of opposing posterior teeth, *Angle Orthod* 30(3):162–173, 1960.
48. Sanin C, Savara BS: The development of excellent occlusion, *Am J Orthod* 61(4):345–352, 1972.
49. Moyers RA. *Handbook of orthodontics*, ed 3, Mosby: Chicago; .
50. da Silva LP, Gleiser R: Occlusal development between primary and mixed dentitions: a 5-year longitudinal study, *J Dent Child* 75(3):287–294, 2008.
51. Northway WM, Wainright RL, Demirjian A, et al.: Effects of premature loss of deciduous molars, *Angle Orthod* 54(4):295–329, 1984.
52. Nery EB, Oka SW. Developmental stages of the human dentition. In Melnich M, et al., editors: *Clinical dysmorphology of oro-facial structures*. Boston: John Wright-PSG; .
53. Moorrees CF. *The dentition of the growing child*. Cambridge, MA: Harvard University Press; .
54. Moorrees CF, Grøn AM, Le Bret LM, et al.: Growth studies of the dentition: a review, *Am J Orthod* 55(6):600–616, 1969.
55. Anderson AA: The dentition and occlusal development in children of African American descent, *Angle Orthod* 77(3):421–429, 2007.
56. Van der Linden F.P.G.M. *Transition of the human dentition*. University of Michigan: Monograph No. 13, Craniofacial growth series, Ann Arbor.
57. Ten Cate AR: Formation of supporting bone in association with periodontal ligament organization in the mouse, *Arch Oral Biol* 20(2):137–138, 1975.
58. Fränkel R: Decrowding during eruption under the screening influence of vestibular shields, *Am J Orthod* 65(4):372–406, 1974.
59. Potter RH, Nance WE: A twin study on dental dimension. I. Discordance, asymmetry and mirror imagery, *Am J Phys Anthropol* 44(3):391–395, 1976.
60. Hixon EH, Oldfather RE: Estimation of the sizes of unerupted cuspid and bicuspid teeth, *Angle Orthod* 28(4):236–240, 1958.
61. Gardner RB: A comparison of four methods of predicting arch length, *Am J Orthod* 75(4):387–398, 1979.
62. Kaplan RG, Smith CC, Kanarek PH: An analysis of three mixed dentition analyses, *J Dent Res* 56(11):1337–1343, 1977.
63. Staley RN, Kerber PE: A revision of the Hixon and Oldfather mixed dentition prediction method, *Am J Orthod* 78(3):296–302, 1980.
64. Staley RN, O’Gorman TW, Hoag JF, et al.: Prediction of the widths of unerupted canines and premolars, *J Am Dent Assoc* 108(2):185–190, 1984.
65. Bishara SE, Staley RN: Mixed-dentition mandibular arch length analysis: a step-by-step approach using the revised Hixon-Oldfather prediction method, *Am J Orthod* 86(2):130–135, 1984.
66. Kirschen RH, O’Higgins EA, Lee RT: The Royal London space planning: An integration of space analysis and treatment planning part I: assessing the space required to meet treatment objectives, *Am J Orthod Dentofacial Orthop* 118(4):448–455, 2000.

## 22

# Cephalometrics and Facial Aesthetics: The Key to Complete Treatment Planning

JOHN T. KRULL, MATTHEW D. BORJAB and GEORGE E. KRULL

## CHAPTER OUTLINE

### Radiographic Technique

Lateral Head Film  
Frontal (Posteroanterior) Film  
Cone Beam Computed Tomography  
CBCT Technique  
3D Exposure (Quick Steps)

### Cephalometric Tracing Technique

**Reference Points for Lateral Tracing**  
**Reference Lines, Angles, and Planes**  
**Interpretation of Measurements**

### Lateral Cephalometric Assessment

Maxillary Skeletal  
Maxillary Dental  
Mandibular Skeletal  
Mandibular Dental  
Vertical  
Soft Tissue

### Frontal (Posteroanterior) Cephalometric Assessment

**Directions of Growth**

### Computerized Cephalometric Diagnosis and Treatment Planning

Digital Imaging

### Anteroposterior Interarch Discrepancies

Class I  
Class II Division I  
Class II Division II  
Class III

### Facial Types

Mesofacial Pattern  
Dolichofacial Pattern  
Brachyfacial Pattern

### Vertical Arch Discrepancies

Open Bite  
Deep Bite

### Angle Classification of Occlusion

Descriptive Skeletal and Dental Evaluation

### Evaluation of Facial Aesthetics

Frontal View  
Profile View

*In studying a case of malocclusion, give no thought to the methods of treatment or appliances until the case shall have been classified and all peculiarities and variations from the normal in type, occlusion, and facial lines have been thoroughly comprehended. Then the requirements and proper plan of treatment become apparent.*

EDWARD H. ANGLE

Cephalometrics, the assessment of craniofacial dimensions, particularly the ethnographic determination of cranial morphology, is an ancient skill practiced by anthropologists for centuries.

Beauty and harmony are the traditional guiding principles used to assess facial proportions, although the definition of beauty may change as civilizations change. Greek sculpture during the golden age of art (4th century BC) shows facial proportions very similar to those found desirable today. Basic facial features of Greek male and female figures appear to be depicted identically, with most sculpture angles within 5 degrees of contemporary standards;

the exceptions are a more acute mentolabial sulcus and nasofacial angle for the ancient Greek ideal.

In the early 20th century, dentistry began to include the concepts of facial harmony and balance in the theory and practice of cephalometrics. In 1922, Simon introduced this modern era with the development of gnathostatics, a photographic technique that relates the teeth and their respective bony bases to each other and to specific craniofacial structures. Although Racini and Carrera obtained the first x-ray films of the skull by the standard lateral view in 1926, it was not until the introduction of the cephalometer by Broadbent in 1931 that the science of cephalometrics became standardized. This sophisticated form of radiography enabled the practitioner to identify specific problem areas of craniofacial disproportion and devise detailed therapeutic interventions. Through the contributions of investigators such as Brodie, Downs, Reidel, Steiner, Tweed, and Ricketts, the clinical application of cephalometrics has developed techniques that permit the observation of discrepancies in the mandible, maxilla, dental units, and soft tissue profile.



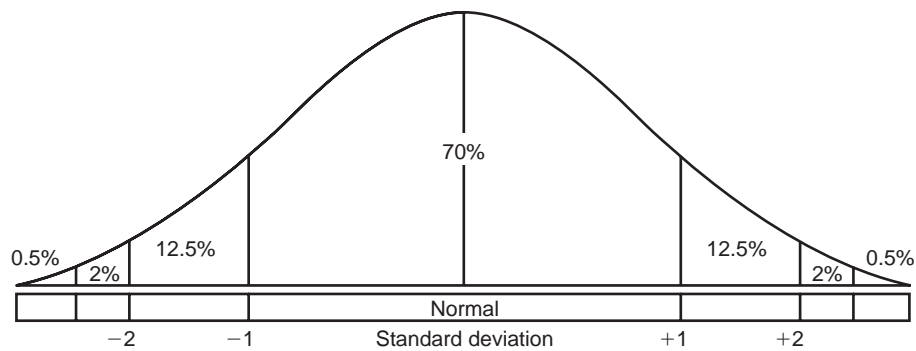


Fig. 22.1 Bell-shaped curve illustrating the approximate distribution of biologic variables in the general population.

The primary aim of cephalometric analysis is to localize malocclusion within a tracing of facial bone and soft tissue structures. The analysis is performed by using standardized cephalometric landmarks to construct lines, angles, and imaginary planes, which permits the linear and angular assessment of dental and facial relationships as seen on radiographic films of the head and face. These findings are compared with established normal values, and an individualized treatment protocol is developed for orthopedic, orthodontic, and orthognathic therapies.

The science of cephalometrics has often been referred to as a “numbers game” and has the reputation of being difficult to master. There appears to be a universal search for a reliable group of numbers that will ultimately lead one to an accurate diagnosis. Such a search is futile because all cephalometric measurements may at times lead to an erroneous conclusion. However, an accurate, in-depth analysis provides one with an assessment of dentofacial and craniofacial morphology. A cephalometric radiograph furnishes one with a static analysis, whereas subsequent films allow the clinician to follow the growth patterns of the adolescent patient on a longitudinal basis. In addition, comparison of serial cephalograms of the same patient may allow some developmental predictions to be made.

The use of cephalometrics serves to confirm the diagnosis and makes it possible to include the morphology of the cranium when alternative treatment modalities are considered. In patient care, cephalometrics can provide valuable data when treatment is first initiated and can serve a monitoring function during the course of orthodontic care. On completion of treatment, cephalometric radiology enables one to assess the relative degree of posttreatment stability and evaluate treatment results produced by various mechanical and appliance selections.

Cephalometric numbers or central tendencies have been developed to serve as guidelines in evaluation of the patient. Dentists must keep in mind that they are treating individuals, not averages, and that the numbers merely help or guide in the formulation of an accurate diagnosis and treatment plan. Because of individual anatomic, biological, and environmental variations, it is imperative that the clinician consider several factors to achieve a comprehensive case analysis. Any attempt to simplify the analysis is likely to lead to an erroneous conclusion.

The norm is commonly referred to as the *mean* or *average*. However, the norm, as it is applied in cephalometrics, is not

a set of averages. The average patient in any given population will generally deviate from the norm because the norm is derived from samples demonstrating ideal dental occlusions of the Class I variety.

Most biological variables are randomly distributed in the population and can be graphically illustrated by a bell-shaped curve (Fig. 22.1). Within this curve, approximately 70% of any given population lies within one standard deviation of the mean and 95% of the population falls within two standard deviations. Throughout this chapter, the statistical concept of standard deviation is referred to as *clinical deviation* (CD).

As a general rule, the goal in treatment planning is to treat in the direction of cephalometric norms. The clinical advantages include the following:

- A more favorable and predictable aesthetic result
- Greater posttreatment stability
- Improved function and periodontal health

## Radiographic Technique

The technique used in cephalometric radiology has been standardized to permit the comparison of initial and subsequent films for the same patient so that growth can be assessed and treatment progress monitored.

This standardization requires that the equipment include a head holder (cephalostat) and an x-ray tube positioned at a distance of 60 inches from the midsagittal plane of the patient and that the distance from the midsagittal plane of the patient to the film be approximately 7.5 inches. The cephalostat maintains a reproducible spatial relationship with respect to the position of the patient’s head, the film, and the x-ray source. The most common device uses a counterbalanced beam with the radiographic tube on one end and the cephalostat on the other. This entire unit can be adjusted vertically to compensate for variations in patient height.

The patient is positioned in the cephalostat by means of laterally adjusted ear rods and a vertically adjusted nasal piece. The nasal piece allows the clinician to orient the patient’s head so that the Frankfort horizontal plane (a plane extending from the tragus of the ear to the inferior border of the orbital rim) is parallel to the floor. The ear posts should be centrally aligned to the source of radiation so that a transporionic axis is established.

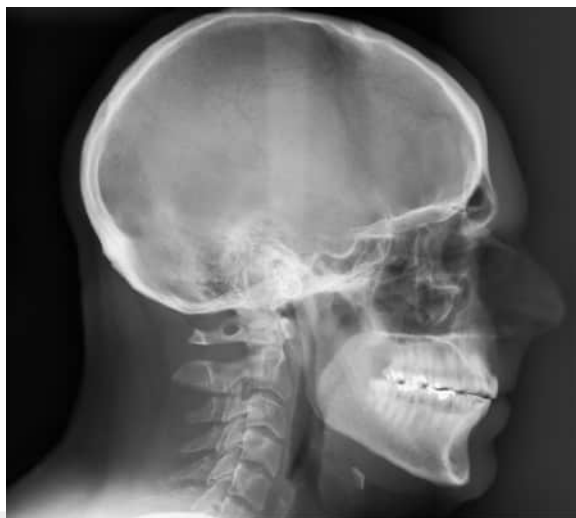

Fig. 22.2 Lateral cephalometric film.

### LATERAL HEAD FILM

For a lateral head radiograph, the patient is first positioned so that the left side of the face is tangent to an 8 × 10-inch film cassette, which permits less magnification and less distortion of the left-sided structures (Fig. 22.2).

The film cassette should be positioned as closely as possible to the patient to minimize the effects of magnification, maximize the resolution, and standardize the technique. The distance from the film cassette to the patient's midsagittal plane should be recorded to allow for comparison of serial films. Generally, the film is obtained with the mandible in its most retruded position and the lips in repose. Use of additional positions may be indicated. Once the patient has been positioned, the x-ray beam should enter through the ear rods perpendicular to the film.

Grids and intensifying screens are accessories used to improve the quality of the radiographic image. Rare earth intensifying screens allow for a reduction of radiographic exposure while increasing the clarity of the radiographic image. Because the film range does not provide for sharp skeletal and soft tissue contrast, a movable aluminum screen attached to the cassette must be used over the soft tissue profile area to reduce the radiation and provide a better differential contrast between the two tissue types.

### FRONTAL (POSTEROANTERIOR) FILM

Most diagnostic features related to vertical and antero-posterior (AP) problems are evident from the lateral film; however, severe maxillary transverse deficiencies or facial asymmetries may be better diagnosed using a posteroanterior (PA) film (Fig. 22.3). The patient is oriented facing the film cassette, with the ear rods and nasion piece positioning the patient so that the midsagittal and Frankfort planes are at right angles to the film cassette. After the patient's head is positioned so that the central x-ray beam passes through the head at the level of the transporionic axis and at its midpoint, the film cassette is moved into contact with the patient's nose. Because more radiation is required for this

view, the milliamperage must be increased over that used in the lateral film technique.

### CONE BEAM COMPUTED TOMOGRAPHY

Cone beam computed tomography (CBCT) has rapidly advanced to being considered the standard of care for evaluation of condylar positioning/anatomy and positioning of impacted teeth that require uncovering for orthodontic purposes. The CBCT is a valuable instrument in surgical planning for orthognathic surgery and surgical orthodontics. The ability to know the exact location and development of impacted teeth (canines, incisors, and premolars) makes surgical uncovering a more efficient surgical process compared with prior techniques that used a lateral cephalometric film and/or the SLOB—same-lingual/opposite-buccal—technique to localize the impacted tooth. One prominent example is the relationship of an impacted canine to the lateral incisor, the possibility of damage to the incisor by the impacted canine, and also the potential anatomic impediments to orthodontic movement of an impacted canine into the dental arch that has been exposed and bonded with an orthodontic bracket and gold chain (Figs. 22.4 and 22.5).

Unlike previously, CBCT enables us to determine abnormal development of teeth structural morphology. Finally, axial, coronal, and sagittal imaging allows the oral and maxillofacial surgeon and surgical orthodontist to view anatomical pathology including but not limited to condylar hyperplasia/hypoplasia, condylar/ramus elongation, and hemihyperplasia.

### CBCT TECHNIQUE

The patient is placed in the unit and aligned as recommended by the CBCT manufacturer. Images are then reformatted via the computer into axial, coronal, sagittal, and 3D rendering planes.

### 3D EXPOSURE (QUICK STEPS)

- Select the 3D program you wish to use.
- Specify the volume size and target area.
- Select the patient size.
- Select the image resolution.

## Cephalometric Tracing Technique

Precise localization of the anatomic landmarks used in cephalometric analysis requires adequate knowledge of the radiographic and anatomic appearance of the facial bones and their relationships to adjacent structures. Various features are discernible: lines, shadows, the projections of bony structures, and contours of various densities. All of these make it difficult for the clinician to interpret and identify the anatomic relationships. A clear understanding of craniofacial structures and their relative spatial relationships is imperative before a lateral head film is traced.

Fig. 22.6 depicts a lateral cephalometric tracing. The lateral tracing should include the soft tissue outline, bony profile, outline of the mandible, posterior and anterior cranial

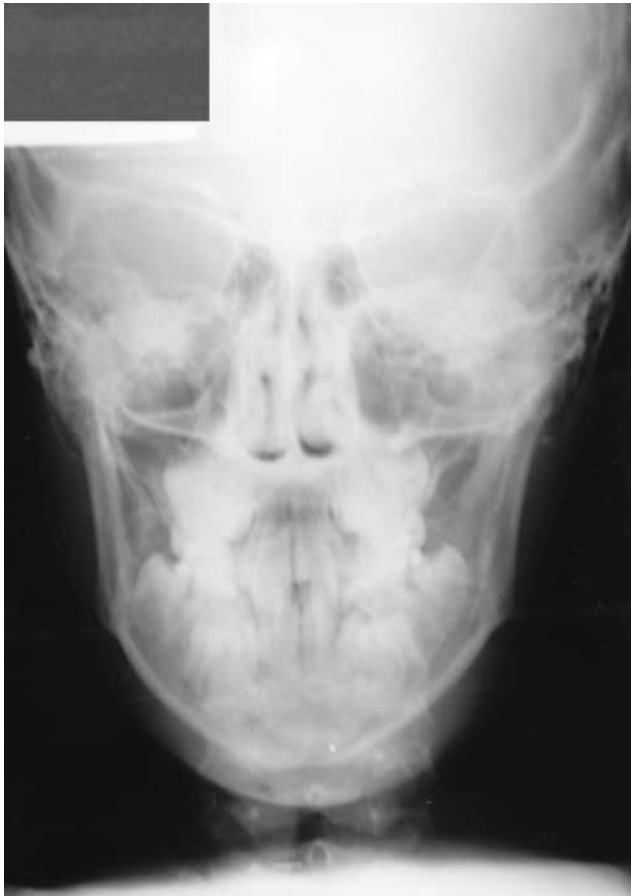


Fig. 22.3 Frontal (posteroanterior) cephalometric film. (Courtesy Dr. William W. Merow.)

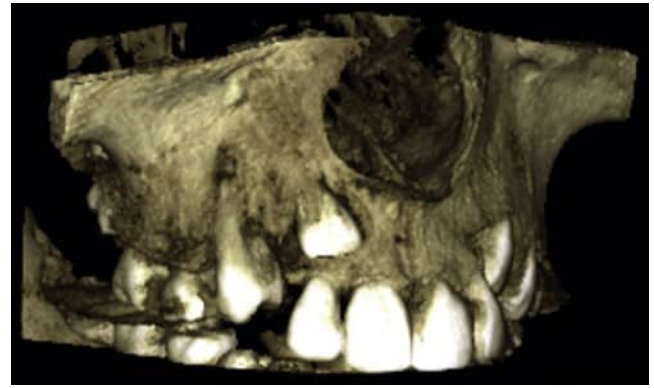


Fig. 22.5 CBCT three dimensional view of impacted canine.

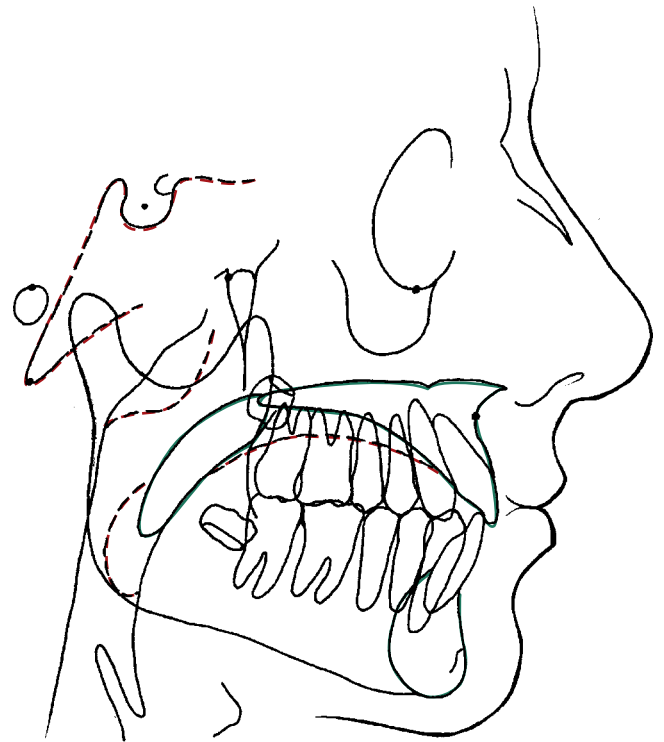


Fig. 22.6 Lateral cephalometric tracing.

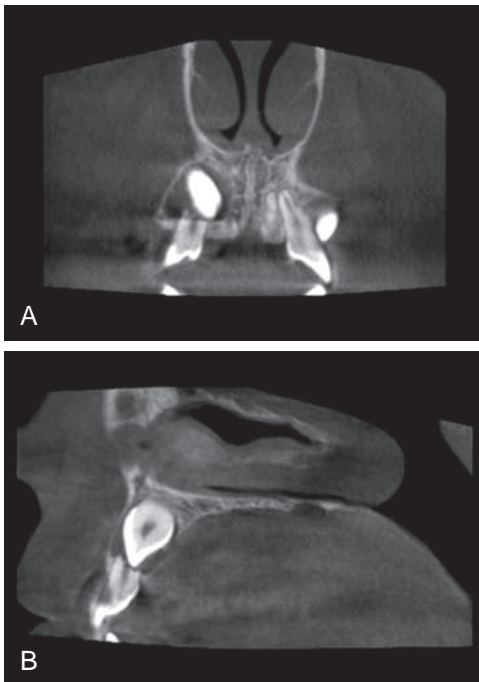


Fig. 22.4 CBCT Two Dimensional Views of Impacted Canine. A, Posterior Anterior View; B, Lateral View.

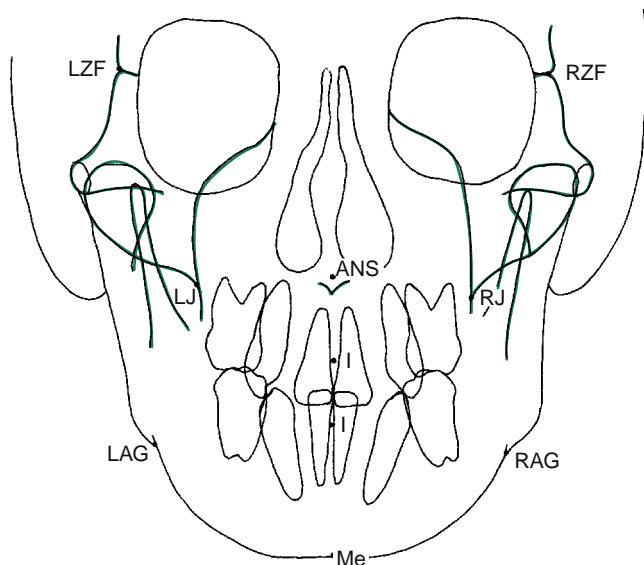
base, odontoid process of the axis, anterior lip of the foramen magnum, clivus, planum orbitale, sella turcica, orbit, pterygomaxillary fissure, floor of the nose, roof of the palate, and body of the hyoid bone. In addition to the bony tissues, at least the first permanent molars and the most anterior maxillary and mandibular incisors are commonly included. In certain situations it may be desirable to trace other teeth or the complete dentition, as shown in Fig. 22.6 (Video 22.1).

**Video 22.1** Cephalometric Tracing: lateral cephalometric tracing using computer software.

*This video was made in conjunction with Dr. Kelton Stewart, Indiana University.*

For the tracing to be made, the radiograph is placed on a view box with the facial profile to the right side. Acetate tracing paper (0.003 matte) is then placed over the radiograph with the matte side up. With a sharp No. 2 or 3H drawing pencil, all the necessary structures are traced (Video 22.1).





**Fig. 22.7** Frontal (posteroanterior) cephalometric tracing (see also Fig. 22.10). ANS, Anterior nasal spine; I, I (incisor) point; LAG, left antegonial notch; LJ, left jugal process of maxillary tuberosity; LZF, left zygomaticofrontal suture; Me, menton; RAG, right antegonial notch; RJ, right jugal process of maxillary tuberosity; RZF, right zygomaticofrontal suture.

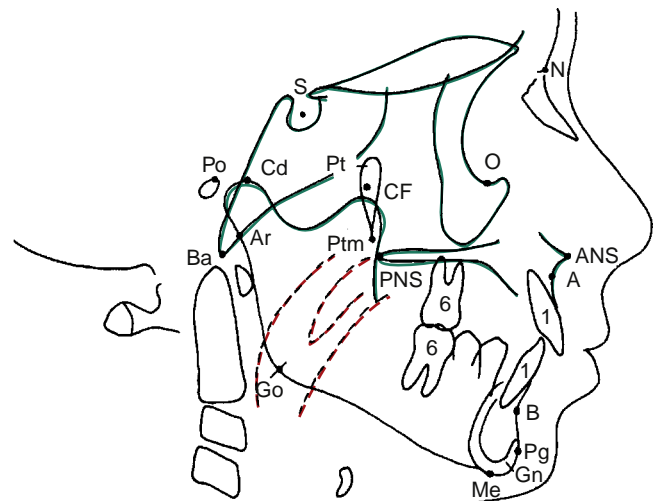
Because all x-rays become divergent once they emanate from the collimator, magnification of the subject will result, and a double-image effect will occur along the inferior border of the mandible and the area of the posterior teeth. All paired structures will produce double images on the head films. Because left-sided structures are magnified less by the radiographic beam and are considered more accurately rendered, the outline of these structures can be traced, although some prefer to make the tracing lines bisect bilateral images.

A PA cephalometric radiograph, as illustrated in Fig. 22.5, can be of significant diagnostic value in cases demonstrating mandibular displacement, facial asymmetry, severe posterior crossbite, or other types of bony dysplasia. Cephalometric analysis and a thorough and systematic clinical examination of these patients often reveal malocclusions accompanied by mandibular shifts when the patient is in maximum occlusion.

The PA radiograph is traced in the same manner as the lateral film. Fig. 22.7 illustrates the important skeletal and dental structures that must be traced for an accurate and complete analysis. Even though many practitioners are trained in cephalometrics using the manual tracing methodology, contemporary cephalometric tracing is now most often done digitally with a computer software program on a digital cephalogram. The principles of the tracing are the same, only the tools are different.

## Reference Points for Lateral Tracing

The ultimate diagnostic value of the cephalometric analysis is dependent on the initial accurate identification and localization of anatomic and anthropologic points (Fig. 22.8). These landmarks are used to construct the lines, angles, and



**Fig. 22.8** Lateral tracing with cephalometric reference points. (Adapted from Dr. William W. Merow.)

planes used to make a two-dimensional assessment of the patient's craniofacial and dental relationships. Although each analysis is completed in two dimensions, when the lateral and PA analyses for the same patient are considered together, a three-dimensional simulation emerges to contribute to the overall diagnosis and treatment plan. The following reference points are used in this chapter (Fig. 22.8).

- **Sella turcica (S, or sella):** The midpoint of the hypophyseal fossa. This is the ovoid area of the spheroid bone that contains the pituitary gland.
- **Nasion (N):** The external junction of the nasofrontal suture in the median plane. If the suture is not visible, this point is located at the deepest concavity of the two bones.
- **Orbitale (O):** The most inferior point on the external border of the orbit.
- **Condylion (Cd):** The most superior point on the articular head of the condyle.
- **Anterior nasal spine (ANS):** The most anterior projection of the ANS of the maxilla in the median plane.
- **A point (subspinale, or A):** The deepest point of the curvature of the anterior maxilla between the ANS and the alveolar crest. Although the A point may change with treatment, it represents the most forward point of the maxilla.
- **B point (supramentale, or B):** The most posterior point on the outer curve of the mandibular alveolar process between the alveolar crest and the bony chin. The B point delineates the most anterior point of the mandible in the median plane.
- **Pogonion (Pg):** The most anterior point on the midsagittal mandibular symphysis.
- **Menton (Me):** The most inferior point of the mandibular symphysis.
- **Gnathion (Gn):** A constructed point that is formed by the intersection of the facial and mandibular planes.
- **Gonion (Go):** Another constructed point that is represented by the intersection of the lines tangent to the posterior margin of the ascending ramus and the mandibular plane.

- **Articulare (Ar):** The point of intersection of the posterior margin of the ascending ramus and the outer margin of the cranial base.
- **Porion (Po):** A point located at the most superior point of the external auditory meatus or the superior aspect of the metal ring that is a component of the left ear rod of the cephalostat.
- **Basion (Ba):** The most inferior posterior point on the occipital bone that corresponds to the anterior margin of the foramen magnum.
- **Pterygomaxillary fissure (Ptm):** A teardrop-shaped fissure, the posterior wall of which is created by the anterior borders of the pterygoid plates of the sphenoid bone; the anterior wall represents the posterior border of the maxilla (maxillary tuberosity). The tip of this fissure denotes the posterior extent of the maxilla.
- **Posterior nasal spine (PNS):** The tip of the posterior spine of the palatine bone. This landmark is usually not visible even on well-exposed lateral head films; therefore it is a constructed point that is represented by the intersection of a continuation of the anterior wall of the pterygopalatine fossa and the floor of the nose. It also denotes the posterior limit of the maxilla.
- **Pt point (Pt):** The intersection of the inferior border of the foramen rotundum with the posterior wall of the Ptm.
- **CF point (center of face):** The cephalometric landmark formed by the intersection of the Frankfort horizontal plane and a perpendicular line through Pt.

## Reference Lines, Angles, and Planes

Linear assessment is derived when two reference points are connected. Angular measurements are possible when three points are used. Planes (and some lines) are actually imaginary when the cephalometric tracing is viewed because the planes are at right angles to the tracing and can be seen only as a line on the two-dimensional tracing (Fig. 22.9). In cephalometric analysis, the dentist must become accustomed to thinking in three dimensions while viewing a two-dimensional representation. Therefore a point on the tracing may not only be a point but also may represent a line (or axis). A line on the tracing may actually be a line (or axis) or it may represent a plane.

Several lines or planes are used in different cephalometric analyses, although one line or plane generally serves as the major reference on which the entire analysis is based. Two common references are the sella-nasion plane (anterior cranial base) and the Frankfort horizontal plane.

The basic units of cephalometric analysis are angles and distances (lines). Measurements may be treated as absolute values, or they may be related to one another and expressed as relative proportions. These measurements and interrelationships provide the basic framework for describing craniofacial abnormalities. The following definitions help explain the planes of reference used in this chapter (Fig. 22.9).

- **Frankfort horizontal plane (FH):** This plane is constructed from the porion (Po) to the orbitale (O) and represents the basic horizontal plane of the head.

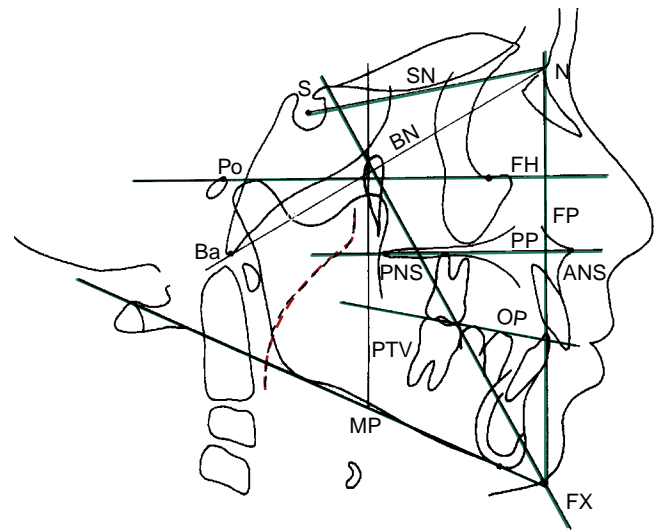


Fig. 22.9 Cephalometric reference lines and planes. (Adapted from Dr. William W. Merow.)

- **Sella-nasion plane (SN):** This plane is represented by a line connecting the sella (S) and the nasion (N). It denotes the AP extent of the anterior cranial base. This reference plane is of questionable diagnostic value in true mandibular prognathism.
- **Occlusal plane (OP):** This plane separates the maxillary and mandibular permanent molars (or, in younger patients, the primary second molars) and passes through the contact between the most anterior maxillary and mandibular incisors. If the incisors are not in contact, the line passes midway between the incisal edges. Ideally, the OP is nearly parallel to both the palatal plane (PP) and the FH.
- **Facial plane (FP):** A line constructed through the nasion (N) perpendicular to the FH represents this plane.
- **Mandibular plane (MP):** The mandibular plane is constructed as a tangent to the inferior border of the mandible.
- **Pterygoid vertical plane (PTV):** This plane is represented by a line perpendicular to the FH through the Pt point. Studies have shown that the intersection of the FH and the PTV is extremely stable because growth has little effect on this point. An overall view of patient growth may be gained by evaluation of serial cephalometric films on which the FH and the PTV are superimposed. The PTV represents a basic vertical reference plane.
- **Basion-nasion plane (BN):** This plane passes through the basion (Ba) and nasion (N). The plane represents the cranial base and is the dividing plane between the cranium and the face.
- **Facial axis (FX):** This line is constructed from the Pt point through the gnathion. The FX ideally crosses the BN at a right angle.
- **Palatal plane (PP):** This plane extends through the ANS and PNS. The relationship of this plane to the FH is useful in evaluation of the treatment changes occurring in the maxilla.

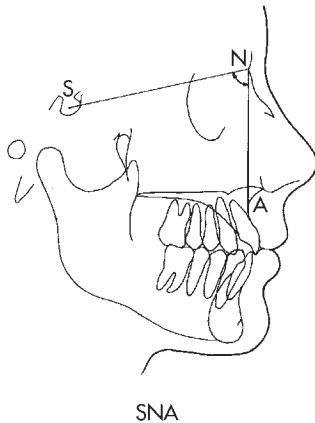
## Interpretation of Measurements

The objectives of cephalometric interpretation are summarized as follows:

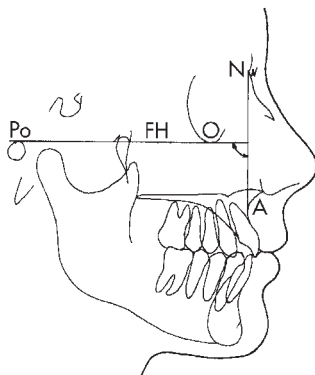
- To define both the skeletal and facial types
- To evaluate the relationship between the maxillary and mandibular basal bones
- To assess the dental relationships (the spatial relationships between the teeth, maxilla, mandible, and cranial base)
- To locate the malocclusion within the dentofacial complex and analyze its origin (skeletal or dentoalveolar)
- To study the facial soft tissue contours with respect to the cause of the malocclusion
- To consider the impact of the various options for correcting the malocclusion on the facial contours and on the skeletal and dental components
- To facilitate selection of a treatment plan
- To evaluate the results of various soft tissue surgical procedures.

## Lateral Cephalometric Assessment

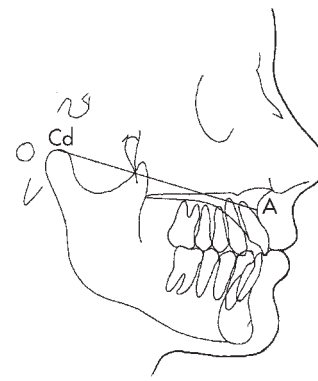
### MAXILLARY SKELETAL



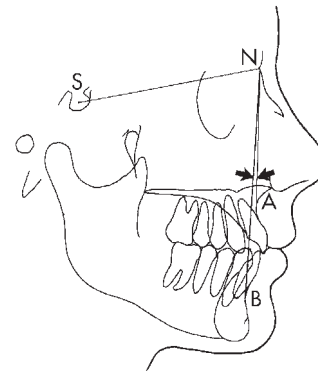
SNA



MAXILLARY DEPTH



MAXILLARY LENGTH



ANB

**SNA:** The angle between SN and N–A point line

Clinical norm: 82 degrees

Clinical deviation: 2 degrees

Interpretation: Establishes horizontal location of the maxilla. Deviation in cranial base (SN, angulation, or length) or vertical maxillary excess proves that this measurement is unreliable. Therefore reduced emphasis should be given in these instances.

**Maxillary depth:** The angle formed by the intersection of the FH and N–A point planes

Clinical norm: 90 degrees

Clinical deviation: 3 degrees

Interpretation: Indicates horizontal position of maxilla.

Class II skeletal patterns caused by a prognathic maxilla show values exceeding 90 degrees. Chronic thumb-suckers generally demonstrate large values.

**Maxillary length:** The measurement of the line extending from Cd to A point

Clinical norm: 85 mm (female), 87 mm (male)

Clinical deviation: 6 mm

Interpretation: Increases 1 mm per year until adult size is attained (95–100 mm). This measurement determines if the Class II or Class III skeletal pattern is attributable to a long or short maxilla, respectively.

**ANB:** The difference between the SNA and SNB angles

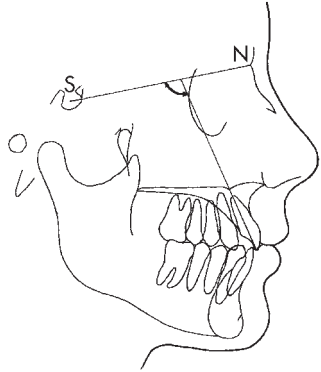
Clinical norm: +2 degrees

Clinical deviation: 2 degrees

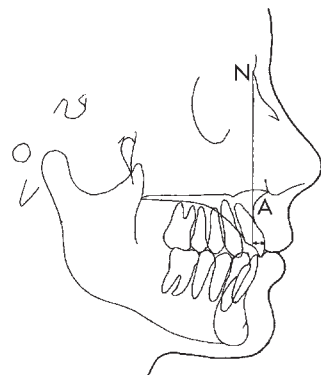
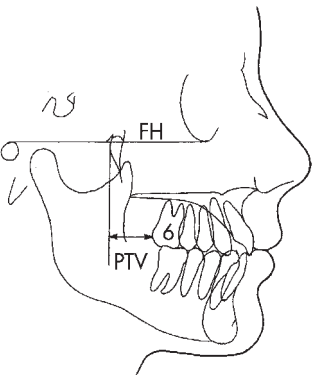
Interpretation: Indicates the horizontal relationship between maxilla and mandible. Positive values indicate that the maxilla is forward of the mandible, whereas negative values indicate a Class III skeletal relationship.



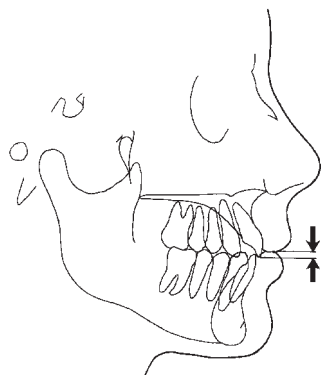
## MAXILLARY DENTAL



MAXILLARY INCISOR ANGULATION

MAXILLARY INCISOR  
(ANTERIOR-POSTERIOR) POSITION

UPPER MOLAR POSITION



MAXILLARY INCISOR TO UPPER LIP

**Maxillary incisor angulation:** The angle formed by SN and the incisor long axis

Clinical norm: 102 degrees

Clinical deviation: 3 degrees

**Interpretation:** Relates the upper incisor angulation to the upper and middle face. Values well above 102 degrees indicate angular incisor protrusion, whereas values significantly less than that demonstrate angular retrusion. It is also important to take into consideration that the incisal two-thirds of the maxillary central incisor crown is narrower and relatively flat. The labial surface has its greatest height at the center of the gingival margin and curves to the incisal edge. Ideally, the incisal two-thirds should be parallel to the facial plane.

**Maxillary incisor AP position:** The horizontal distance from the facial surface of the maxillary central incisors to the N-A point line

Clinical norm: 4 mm

Clinical deviation: 2 mm

**Interpretation:** Indicates horizontal position of the maxillary incisors. Values exceeding 6 mm indicate anterior dental protrusion, whereas values 1 mm or less show dental retrusion.

**Upper molar position:** The horizontal distance from PTV to the distal surface of the maxillary first molar

Clinical norm: Chronologic age of the patient + 3 mm (e.g., a 10-year-old has a clinical norm of  $10 + 3 = 13$  mm). The growth change is approximately 1 mm per year through the years of active growth.

Clinical deviation: 3 mm

**Interpretation:** Determines if the dental malocclusion is caused by the AP position of the maxillary molar. It is important in treatment planning considerations involving distal movement of the maxillary molars.

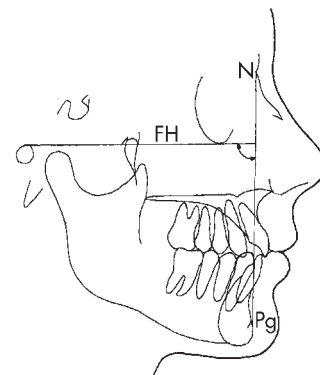
**Maxillary incisor to upper lip:** The vertical distance between the inferior border of the upper lip and the incisal edge of the maxillary incisor

Clinical norm: 3 mm

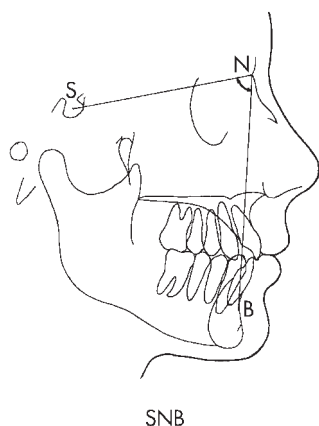
Clinical deviation: 1 mm

**Interpretation:** Gives an evaluation of the amount of upper incisor in repose. Values of 5 mm or more may be associated with vertical maxillary excess. This value must be compared with upper lip length. Patients with short upper lips will show more incisor at rest.

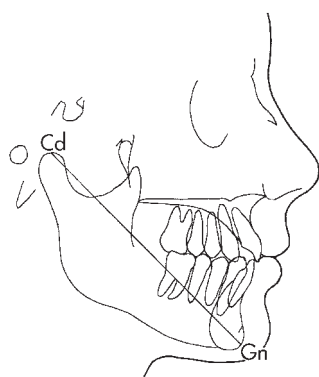
## MANDIBULAR SKELETAL



FACIAL ANGLE



SNB



MANDIBULAR LENGTH

**SNB:** The angle formed between the SN and N–B point planes  
 Clinical norm: 80 degrees  
 Clinical deviation: 2 degrees  
 Interpretation: Indicates horizontal location of the mandible. Abnormal cranial base angulation and vertical facial excess will adversely affect the reliability of this measurement.

**Facial angle (depth):** The angle formed between the N–Pg and FH planes  
 Clinical norm: 87 degrees at 9 years of age. Increases 0.33 degrees per year.

Clinical deviation: 3 degrees

Interpretation: Locates the horizontal position of the chin. Determines if the skeletal Class II or Class III relationship is attributable to a retrognathic or a prognathic mandible.

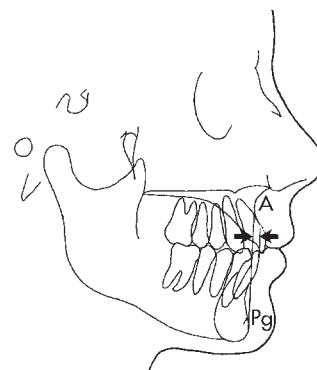
**Mandibular length:** The absolute distance between Cd and Gn

Clinical norm: 105 mm at 9 years of age with yearly growth increments of 2–2.5 mm, reaching a maximum of 120–130 mm. Generally 2 mm less in females than in males at 9 years of age.

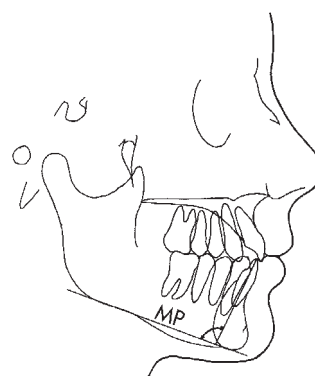
Clinical deviation: 6 mm

Interpretation: Determines whether the skeletal Class II or Class III relationship is attributable to a small or large mandible.

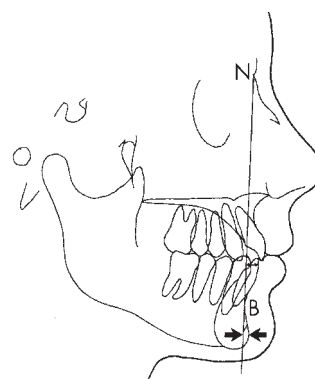
## MANDIBULAR DENTAL



MANDIBULAR INCISOR PROTRUSION



IMPA



HOLDAWAY RATIO

**Mandibular incisor protrusion:** The horizontal distance from the tip of the mandibular incisor to the A point–Pg line  
 Clinical norm: +2 mm

Clinical deviation: 2.3 mm

Interpretation: Defines the AP position of the mandibular dental unit and quantifies the reciprocal relationship of the maxillary and mandibular dental units. Not only is this a key aesthetic relationship, but it also needs to be correlated with a functional arch length analysis.

**Incisor mandibular plane angle (IMPA):** The inner angle between the long axis of the mandibular incisor and MP

Clinical norm: 90 degrees

Clinical deviation: 4 degrees

Interpretation: Gives an evaluation of the angular position of the incisor to the mandibular basal bone.

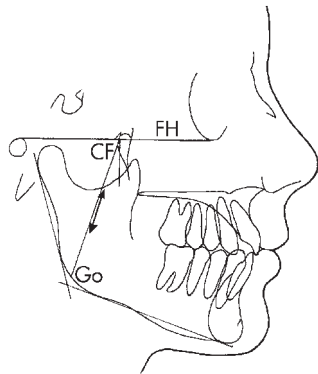
**Holdaway ratio:** The ratio of the mandibular incisor and Pg to the N-B point line

Clinical norm: 1:1

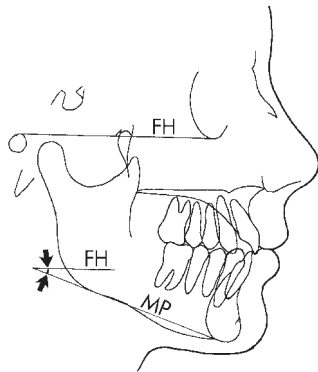
Clinical deviation: 2 mm

Interpretation: The AP position of the mandibular incisor and Pg should project equally from the N-B point line for good facial balance.

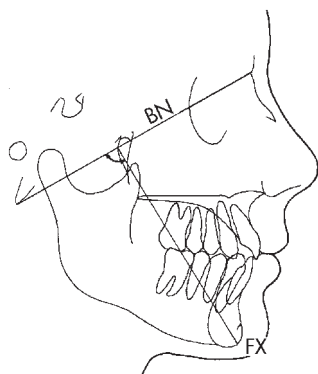
## VERTICAL



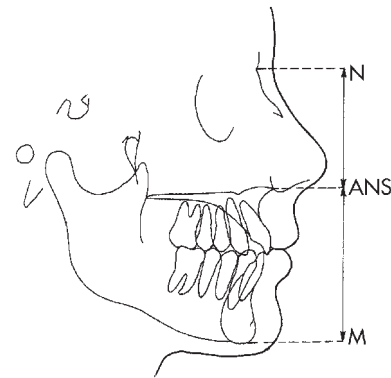
POSTERIOR FACIAL HEIGHT



FMA



FACIAL AXIS ANGLE



FACIAL HEIGHT

**Posterior facial height:** The linear distance between Go and the CF point

Clinical norm: 55 mm for the average-sized patient at 8½ years of age. Increases 1 mm per year.

Clinical deviation: 3.3 mm

Interpretation: Measures vertical growth of the ramus and can therefore be of value in predicting clockwise or counterclockwise growth patterns. Values less than 51 mm represent a leaning toward dolichofacial patterns, whereas values exceeding 59 mm may indicate brachyfacial or counterclockwise growth trends.

**Mandibular plane angle (FMA):** The angle formed by the intersection of FH and MP

Clinical norm: 26 degrees. Decreases 1 degree every 4 years during normal growth.

Clinical deviation: 4 degrees

Interpretation: Values exceeding 31 degrees may indicate clockwise growth with dolichofacial growth trends, whereas values less than 21 degrees imply vertical deficiency as often seen in brachyfacial growth patterns.

**Facial axis angle:** The angle between FX and BN

Clinical norm: 90 degrees

Clinical deviation: 3.5 degrees. Changes 1 degree every 3 years in the average patient.

Interpretation: Expresses the ratio of facial height to depth and thus indicates the direction of growth of the chin. Values exceeding 94 degrees may indicate counterclockwise growth and values less than 85 degrees may imply clockwise growth in brachyfacial and dolichofacial facial types, respectively.

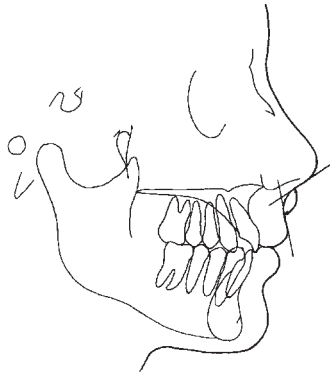
**Facial height:** The vertical relationship between upper and lower facial height (N-ANS:ANS-M)

Clinical norm: Upper, 53 mm; lower, 65 mm

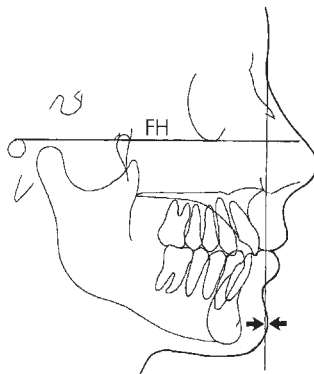
Interpretation: More important than the absolute value is the ratio between upper and lower facial height, which should be approximately 5:6 for a well-balanced face.



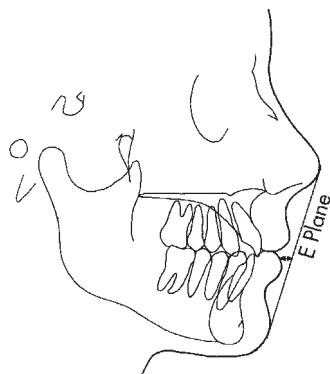
## SOFT TISSUE



NASOLABIAL ANGLE



ZERO MERIDIAN



LIP PROTRUSION

**Nasolabial angle:** The angle formed by the intersection of the lines tangent to the columella of the nose and the upper lip

Clinical norm: 90–110 degrees

Interpretation: Provides an assessment of the nose-to-upper lip relationship. Values exceeding 114 degrees may indicate upper lip retrusion, whereas values of 96 degrees or less may be associated with dental protrusion.

**Zero meridian:** The horizontal distance from the chin to a line perpendicular to FH and tangent to the soft tissue nasion

Clinical norm: 0 mm

Clinical deviation: 2 mm

Interpretation: May be helpful in assessment of the projection of the chin relative to FH.

**Interlabial distance:** The vertical distance between the inferior aspect of the upper lip and the superior surface of the lower lip with the patient in repose

Clinical norm: 1.9 mm

Clinical deviation: 1.2 mm

Interpretation: High values indicate lip incompetence and are often associated with hyperactivity of the mentalis muscle. Low values may be associated with overclosure.

**Lip protrusion:** The horizontal distance between the lower lip and the aesthetic plane (E plane). The aesthetic plane is a line connecting the tip of the nose and the most anterior point on the soft tissue chin.

Clinical norm:  $-2$  mm at  $8\frac{1}{2}$  years of age; decreases 0.2 mm per year. The values tend to decrease with age until adult values of  $-5$  mm are reached.

Clinical deviation: 2 mm

Interpretation: Indicates soft tissue balance between lips and profile (nose-chin). This measurement is important because it takes into account the variability in thickness of the soft tissue chin.

## Frontal (Posteroanterior) Cephalometric Assessment

Frontal cephalometric points and planes are used to evaluate the overall relationships of the cranium, maxilla, mandible, and denture from a frontal view. Fig. 22.10 is a graphic representation of the points, lines, and planes used in frontal cephalometric analysis.

**Dental midline:** The horizontal distance between the maxillary and mandibular incisor midlines

Clinical norm: 0 mm

Clinical deviation: 1.5 mm

Interpretation: Determines dental midline asymmetry.

**Maxillomandibular width:** The horizontal distance between the jugal process of the maxilla and the frontal facial plane

Clinical norm: 10 mm for patient of average size at  $8\frac{1}{2}$  years of age. Needs to be corrected for size.

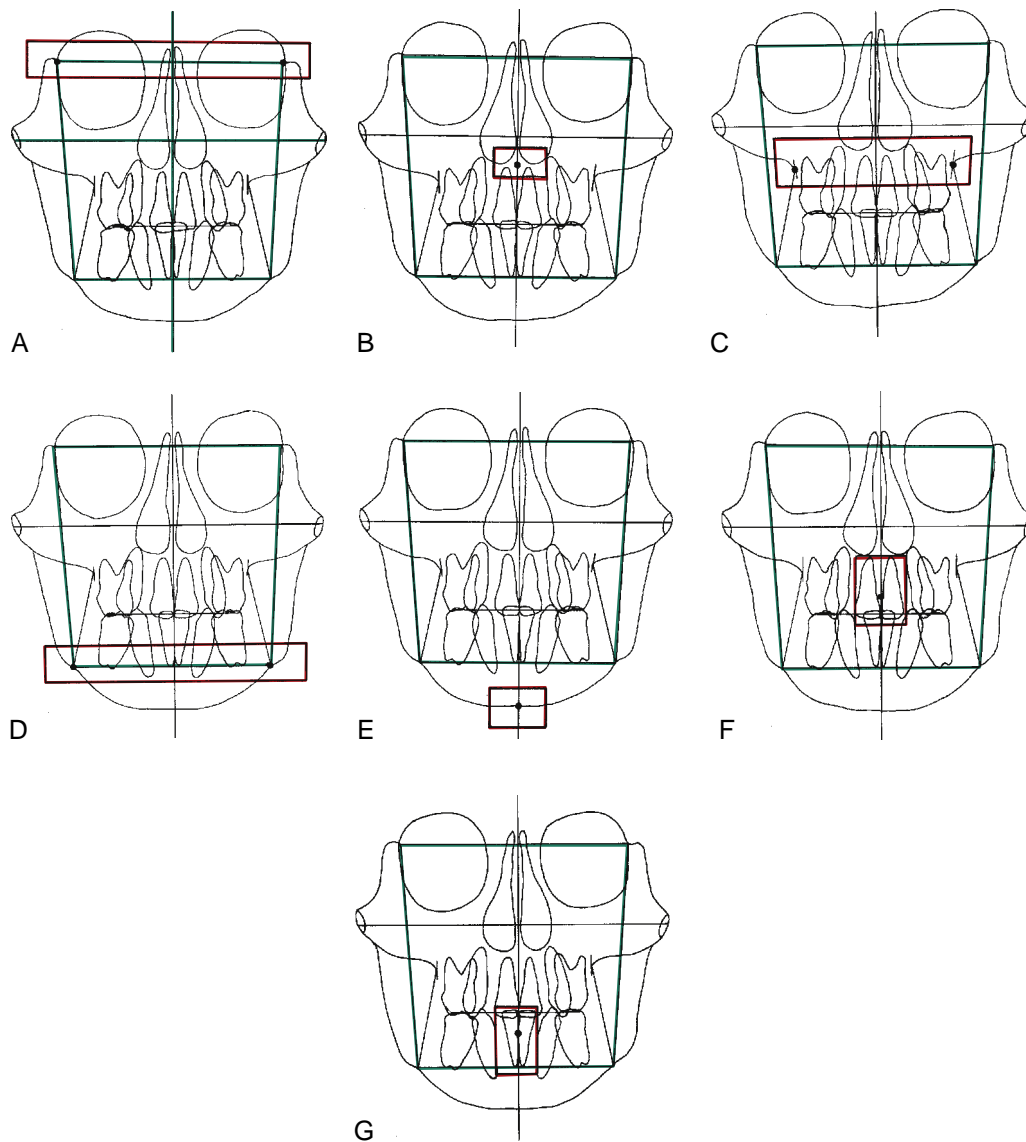
Interpretation: Determines if a crossbite is skeletal in nature. Large values are associated with skeletal lingual crossbites, whereas smaller values indicate skeletal buccal crossbites.

**Maxillomandibular midline:** The angle formed by the ANS-Me plane through ANS and perpendicular to the zygomatic frontal suture plane

Clinical norm: 0 mm

Clinical deviation: 2 mm

Interpretation: Determines whether facial asymmetry is attributable to total size discrepancy or a functional shift of the mandible.



**Fig. 22.10** Frontal reference points (see also Fig. 22.7). (A) *LZF/RZF*, Bilateral points on the medial aspect of the zygomaticofrontal sutures at the intersections of the orbits. (B) *ANS*, tip of the anterior nasal spine. (C) *LJ/RJ*, bilateral points on the jugal processes and the intersection of the maxillary tuberosities and the zygomatic buttresses. (D) *LAG/RAG*, points at the lateral inferior margin of the antegonial protuberances of the mandible. (E) *Me*, menton, point of the inferior border of the mandibular symphysis directly inferior to the mental protuberance. (F) *I* point, a point selected at the interdental papilla of the upper incisors at the junction of the crowns and gingiva. (G) *I* point, a point selected at the interdental papilla of the lower incisors at the junction of the crowns and gingiva.

**Denture to jaw midlines:** The horizontal distance between the midlines of the mandibular incisors and maxilla and mandible

Clinical norm: 0 mm

Clinical deviation: 1.5 mm

Interpretation: Aids differential diagnosis between denture shift and mandibular shift.

**Occlusal plane tilt:** Measures the degree of parallelism between the occlusal plane and a line through the zygomatic frontal sutures

Clinical norm: 0 mm

Clinical deviation: 2 mm

Interpretation: A skeletal asymmetry in addition to a tilt in occlusal plane is usually a signal of possible temporomandibular joint dysfunction.

**Maxillary width:** The horizontal distance between the jugal processes of the maxilla

Clinical norm: 61.9 mm at 9 years of age. Increases 0.6 mm per year.

Clinical deviation: 3 mm

Interpretation: Indicates the width of the maxilla. The change in value is useful in cases involving sutural expansion of the palate.

## Directions of Growth

The constructed gonial angle is formed by the intersection of the ascending ramus and the body of the mandible. This angle can be used as an initial assessment of future mandibular growth. The direction of growth

is very important in the selection of a functional appliance if that method of treatment is indicated. In cases such as mandibular prognathism, the information would lead one to the conclusion that treatment might best be delayed due to the possibility of latent mandibular growth.

The gonial angle is divided into two parts for determination of the angular relationship between the ascending ramus and the body of the mandible. A line is constructed between the nasion and the constructed gonial angle (facial depth line), dividing the gonial angle into upper and lower compartments. As a general rule, the upper angle, with a normal range of 52–55 degrees, indicates horizontal or counterclockwise growth. The lower angle, with a range of 70–75 degrees, is an indicator of vertical or clockwise growth. The astute clinician needs to keep in mind that growth rarely occurs in a straight line but rather exhibits more of a curve (Fig. 22.11).

A larger upper angle would indicate a more forward growth, whereas a larger lower angle would indicate downward growth. Conversely, a small upper angle would indicate clockwise growth and a small lower angle would indicate counterclockwise growth.

Another method of assessing the direction of growth is to divide the upper angle by the lower angle, resulting in a percentage. The numerical value can then be compared with the numbers in the following list to give an idea of the growth vector. A more in-depth analysis may be indicated in more difficult musculoskeletal discrepancies.

Ideal growth: 70%–78%

Clockwise tendency: 69.9%–68.1%

Clockwise growth:  $\leq 68\%$

Excessive clockwise growth:  $< 60\%$

Counterclockwise tendency: 78.1%–79.9%

Counterclockwise growth:  $\geq 80\%$

Excessive counterclockwise growth:  $> 88\%$

## Computerized Cephalometric Diagnosis and Treatment Planning

The availability of inexpensive and powerful computers in the dental office has made comprehensive cephalometric software a reliable tool for the practitioner. In addition to providing accurate models of the skeletal and soft tissue anatomy, these computer programs allow for an accurate prediction of aesthetic results by the evaluation of the soft tissue changes secondary to orthodontic and orthopedic alterations in the hard tissues. One can also evaluate multiple treatment plans and examine the changes that would result relative to the soft tissue before actually initiating a specific treatment plan.

### DIGITAL IMAGING

Imaging has been an important aspect of dental care since the early 1900s. The x-ray was discovered by Wilhelm

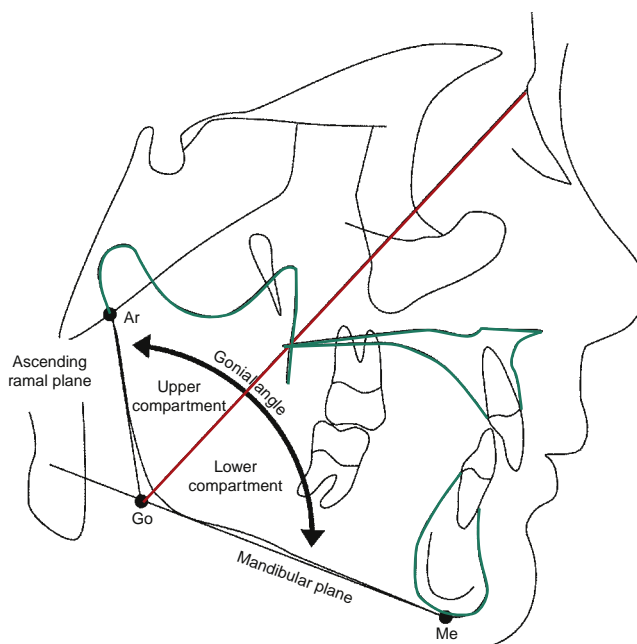


Fig. 22.11 Facial growth vector assessment and the gonial angle.

Conrad Roentgen in late 1895. This discovery resulted in a method whereby dental anatomy could be evaluated. Dr. Otto Walkoff took the first dental radiographs in 1896, with an exposure time of 25 minutes. Later that same year, advances were made in the field such that the exposure time was reduced to 9 minutes. The first dental radiographs were obtained in the United States that same year by the Eastman Kodak Company. Finally, in 1919, Kodak produced the first dental x-ray films designed for direct exposure. The F-speed film introduced in 2000 required 1/60th of the radiation of the 1919 films.

Over the years, dentistry has been on the cutting edge of radiology. Dentistry entered a new era of diagnostic imaging when French dentist Francis Mouyen introduced digital imaging in 1987. This method creates images with the use of a computer. In recent years, CBCT has come into play. This digital imaging system can produce both two- and three-dimensional images.

Digital imaging provides high-resolution images; compared with conventional radiography, the patient is exposed to reduced radiation. Additionally, digitally generated images provide an accurate and reproducible method of analysis. Digital radiographs used in conjunction with the appropriate software can generate three-dimensional images and allow for an accurate evaluation of anatomic structures. Improved image sharpness in, for example, the central incisor region can be accomplished by digital elimination of the shadows cast by the cervical vertebrae. A more relevant image results in a more accurate diagnosis.

The first CBCT scanner, TOM OR-DVT-9000, dedicated to dentomaxillofacial imaging was developed in the United States in 2001. Virtually every practitioner can benefit from this new technology. In the past few years, image centers have been established that allow clinicians in larger cities to have access to these facilities. Stand-alone



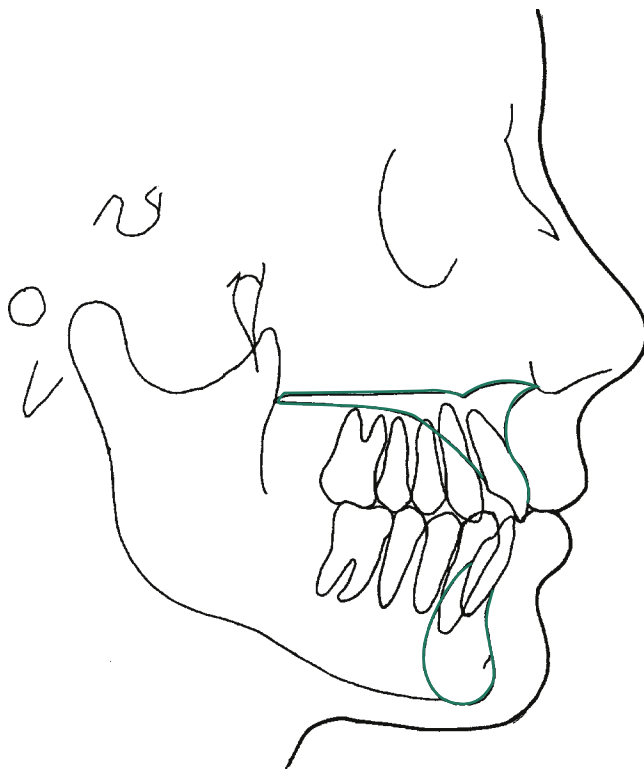


Fig. 22.12 Class I occlusion.

software packages placed at office workstations enable dentists to view a full range of sophisticated images. Software programs such as Dolphin ([www.dolphinimaging.com](http://www.dolphinimaging.com)), In-Vivo Dental ([www.anatimage.com](http://www.anatimage.com)), and V-Works ([www.cybermed.co.kr](http://www.cybermed.co.kr)) enable dentists to view the data from the CT machines.

## Anteroposterior Interarch Discrepancies

### CLASS I

A Class I occlusion is one in which the mesiobuccal cusp tip of the maxillary first molar aligns with the buccal groove of the mandibular first molar (Fig. 22.12). Because of this sagittal relationship, most Class I occlusions demonstrate reasonably normal skeletal and soft tissue profiles.

### CLASS II DIVISION I

In Class II division I malocclusion, the mesiobuccal cusp tip of the maxillary first molar is positioned anterior to the buccal groove of the mandibular first molar (Fig. 22.13). The sagittal molar relationship of these patients is referred to as a *disto-occlusion* as opposed to a *neutro-occlusion* in patients with Class I occlusion. The exact reason for this relationship may be skeletal, dental, or a combination of the two. The nature of the problem can be more accurately determined by the use of cephalometric analysis. This type of malocclusion is often characterized by excessive overjet in the anterior region. Unlike the patient with Class I occlusion, these patients often exhibit more downward

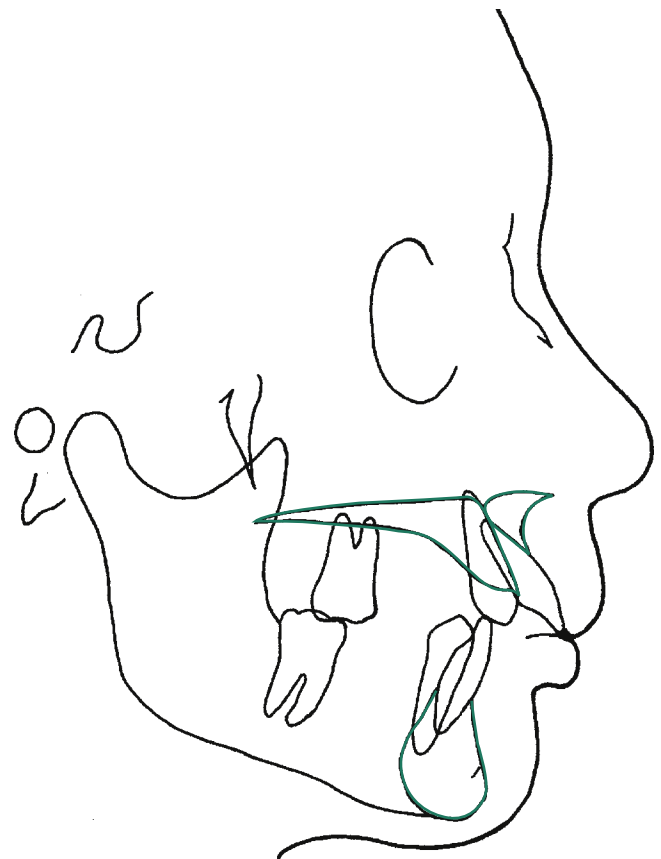


Fig. 22.13 Class II division I occlusion.

growth, abnormal muscle pressure, and a convex soft and hard tissue profile.

In vertical growth patterns in which the upper molars are erupting along the facial axis and the upper incisors are erupting in a protruded direction, space between the upper molars and incisors is increased, which results in the typical dental characteristics of the Class II division I malocclusion.

### CLASS II DIVISION II

The molar position observed in patients with Class II division II malocclusion is similar to that of patients with Class II division I malocclusion, although the excessive overjet associated with the latter is not seen (Fig. 22.14). The anterior relationship of a Class II division II malocclusion is characterized by lingual tipping of the central incisors and labial flaring of the lateral incisors. Whereas patients with Class II division I malocclusion show a weak chin, patients with division II malocclusion tend to have a square jaw, skeletal deep bite, and a short lower facial height. Class II division II malocclusions demonstrate strong growth patterns in which the upper molar grows down the facial axis, whereas the upper incisor moves down with a retroclination. In this case, there is a diminution of space between the molar and incisor. This results in a pinching or closing of the arch, which gives the characteristic flaring of the upper lateral incisors and linguoversion of the central incisors. In severe cases, an hourglass-shaped upper arch form may result.

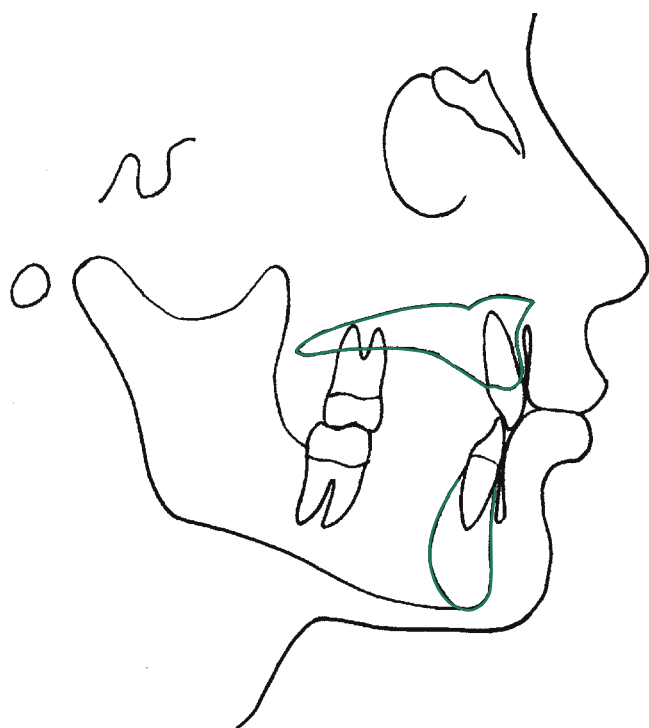


Fig. 22.14 Class II division II occlusion.

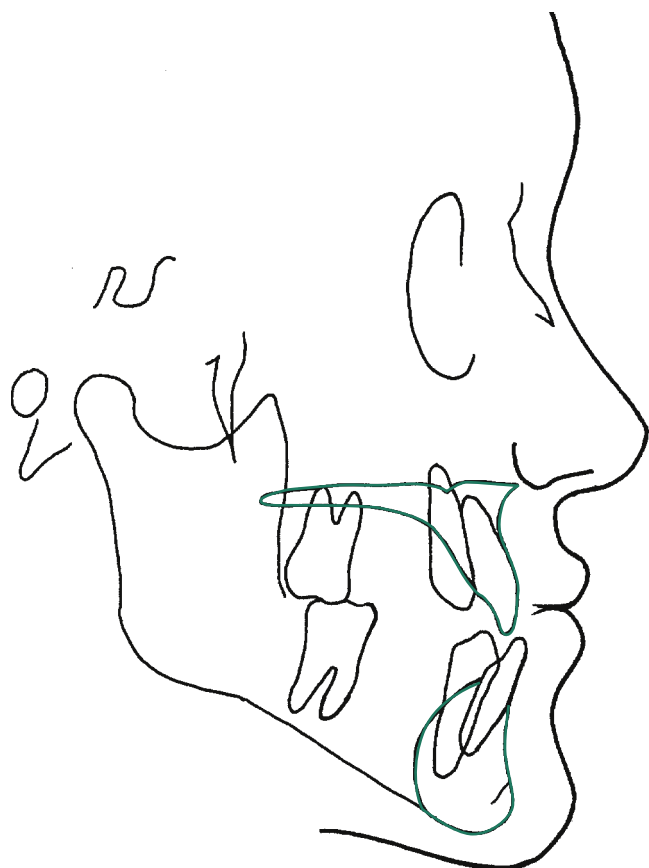


Fig. 22.15 Class III occlusion.

### CLASS III

In Class III malocclusion, the mesiobuccal cusp tip of the maxillary first permanent molar is posterior to the buccal groove of the mandibular first permanent molar (Fig. 22.15). The most common cause of Class III malocclusions is excessive growth of the mandible. The molar position of these patients is referred to as *mesio-occlusion*, whereas the anterior relationship shows a negative overjet. Many cases demonstrate dental compensations in which the maxillary incisors are excessively flared and the mandibular incisors are severely tipped lingually. These patients typically show concave facial profiles and steep mandibular plane angles attributable, in part, to an obtuse gonial angle.

### Facial Types

The three basic facial types or patterns are dolichofacial (vertical), mesofacial (ideal), and brachyfacial (horizontal). The determination of the patient's facial pattern is important in growth prediction and treatment planning, even though no definitive correlation between malocclusion and facial types has been demonstrated. It should be obvious that the prognosis for a pleasing facial result in the treatment of a Class II malocclusion associated with a retrognathic mandible would be more uncertain than that in the treatment of a Class II malocclusion occurring with an orthognathic mandible. Therefore one of the first assessments necessary for an accurate craniofacial diagnosis is classification of the patient's facial type.

Although all facial types may be observed in association with different malocclusions, a significantly higher incidence of specific types does occur with certain types of malocclusion, such as the association of Class II malocclusions with retrognathic mandibles and of Class III malocclusions with prognathic mandibles. On the other hand, an orthognathic facial type is not always associated with an ideal Class I occlusal relationship. As the clinician becomes more familiar with the different types of malocclusion, it will become obvious that certain facial patterns are commonly associated with each classification of malocclusion.

### MESOFACIAL PATTERN

The mesofacial pattern is most often associated with Class I occlusions because these patients are characterized by a relatively normal maxillary and mandibular relationship that results in good facial balance (Fig. 22.16).

### DOLICHOFACIAL PATTERN

The faces of patients with the dolichofacial pattern are usually long and of weak musculature because of the tendency for vertical growth. The molar occlusion is often of the Class II division I variety. The protruded dentition of these patients often results in facial grimacing and disharmony. Reduction of the interincisal angle will result in a more pleasing facial profile (Fig. 22.17).

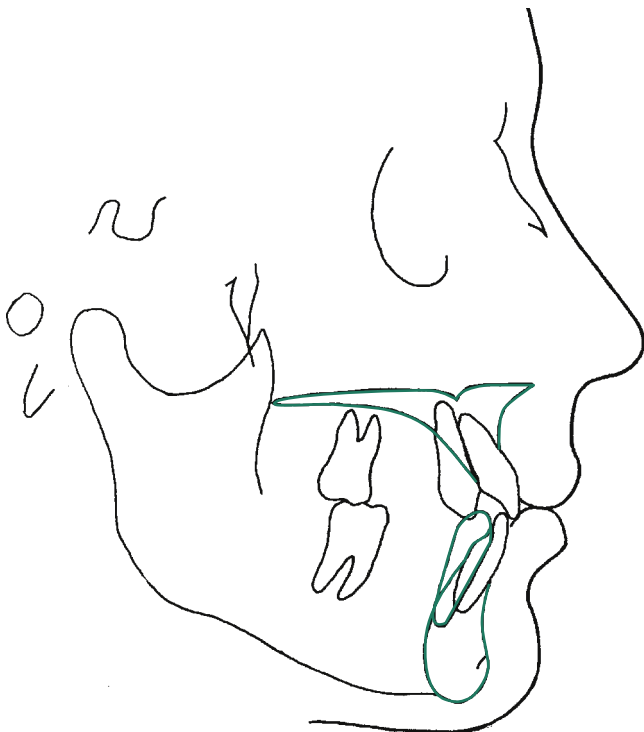


Fig. 22.16 Mesofacial pattern.

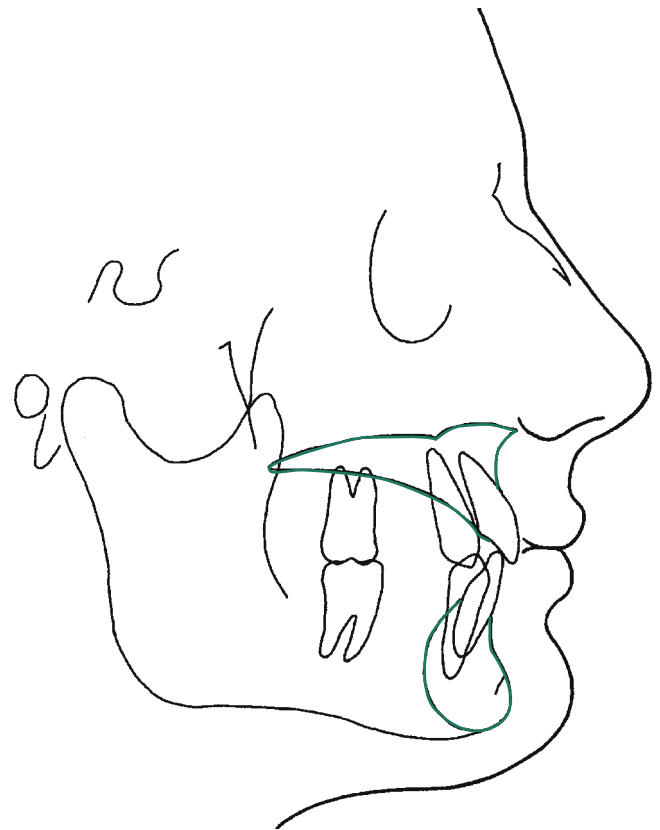


Fig. 22.18 Brachyfacial pattern.

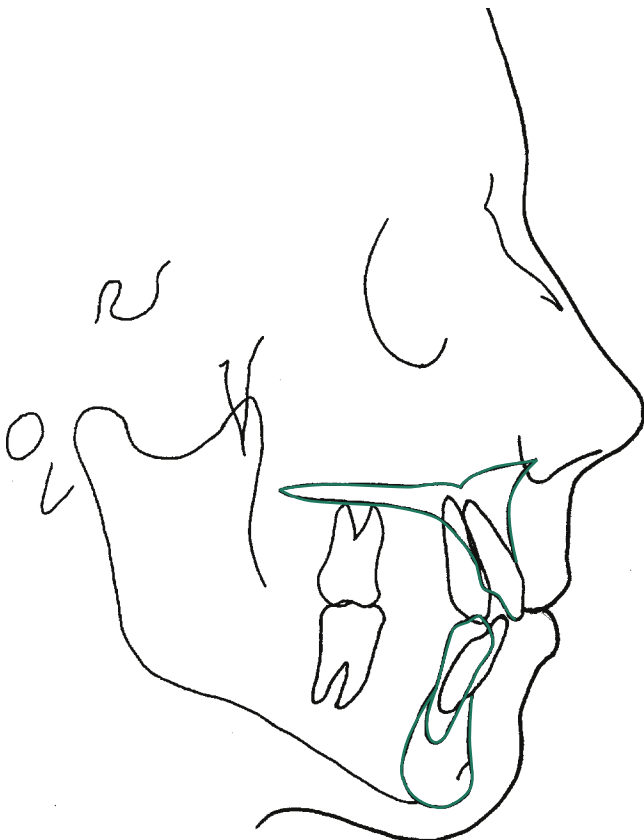


Fig. 22.17 Dolichofacial pattern.

### BRACHYFACIAL PATTERN

The short faces and wide, square mandibles of patients with a brachyfacial pattern are most often associated with Class II division II malocclusions. The mandibular growth of these patients is usually forward rather than downward. Consequently, these patients typically exhibit excessive anterior overbites and strong chins (Fig. 22.18). Aesthetically, the brachyfacial patient can generally accommodate a fuller dentition with a more acute interincisal angle. The fuller dentition helps balance the strong chin and the shorter lower facial height by giving more forward projection to the midfacial region.

### Vertical Arch Discrepancies

#### OPEN BITE

Open-bite relationships are characterized by failure of the teeth in both arches to meet properly (Fig. 22.19). Open bites may be observed in the anterior or posterior region and may be attributable to supraeruption of the adjacent teeth or infraeruption of the teeth in the area of question. Open bites may be caused by abnormal habits, deviant growth patterns, or an abnormal tongue position.



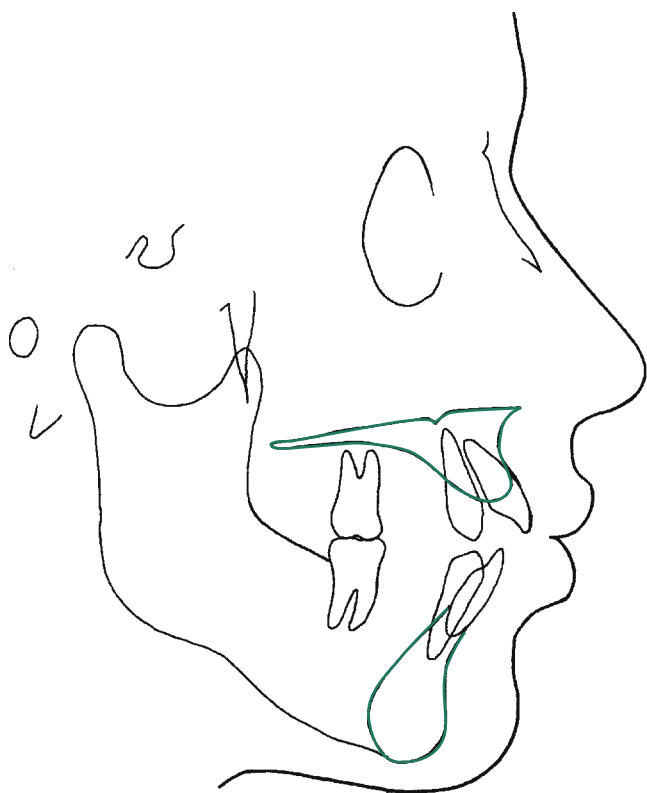


Fig. 22.19 Open-bite pattern.

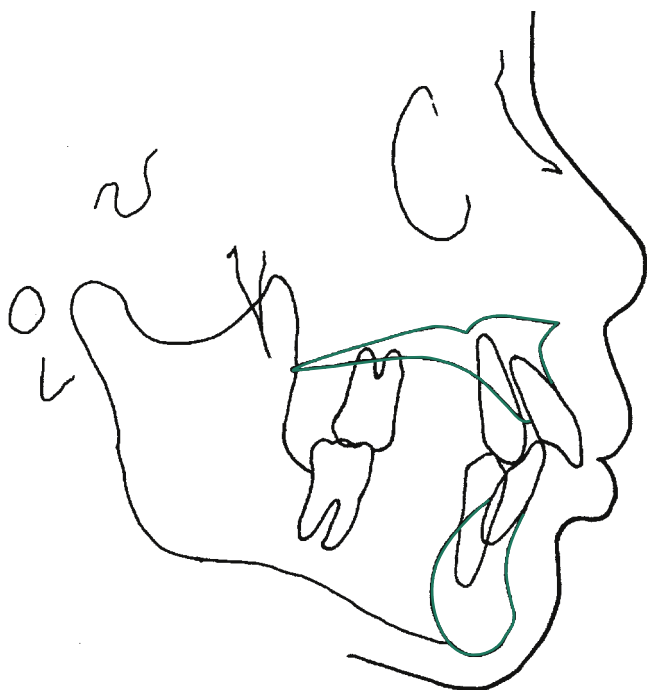


Fig. 22.20 Deep-bite pattern.

## DEEP BITE

Deep bites are most often observed in Class II division I malocclusion in which, because of the excessive overjet, the mandibular incisors supraerupt until they come into contact with the hard palate (Fig. 22.20). The Class II division II malocclusion is

also associated with a deep bite, although in these patients the cause may be infraeruption of the posterior teeth or supraeruption of the maxillary anterior teeth. In many deep-bite cases, the condition results in overclosure of the mandible, leading to labial movement of the upper incisors and, in some cases, generalized spacing of the maxillary anterior teeth. The correction leading to opening of the bite is determined by the type of malocclusion, the aesthetic goals, and the philosophical approach of the clinician. A comprehensive case analysis is therefore necessary to define the etiologic factors.

## Angle Classification of Occlusion

Orthodontists are concerned with facial form, function, oral health, and beauty. The primary criteria for classifying the occlusion were developed in 1899 by Edward Angle, the father of modern orthodontics, to evaluate the sagittal relationship of the canines and molars. Angle was a nonextractionist who considered the bust of Apollo Belvedere to be the epitome of facial balance, and consequently it served as a guide to his treatment objectives. Angle contended that dental arch expansion was necessary for proper orthodontic treatment. With this method of treatment, Dr. Angle rarely removed teeth. Insightful orthodontists such as Charles Tweed, Hays Nance, and P. R. Begg refuted Angle's approach to treatment, which often resulted in poor facial aesthetics, instability, and periodontal problems. These latter orthodontists often recommended the removal of teeth to improve facial aesthetics and avoid double protrusion. Over the years the pendulum has swung back and forth between extraction and nonextraction. The fear of creating a "dished-in" profile has been reported. The statement has been made that the removal of premolars in orthodontic therapy will result in flat facial profiles and temporomandibular joint dysfunction. A study conducted at Washington University evaluated 160 extraction cases. The study findings indicate that, if proper diagnostic criteria are used in the treatment evaluation, the removal of teeth is not detrimental to good facial balance. The Angle's system of classification (described earlier) is a simple analysis that allows one to classify a patient's occlusion into one of three different categories (Class I, II, or III). Although this system allows for ease of understanding and communication, it should be augmented with further data to develop an appreciation of facial form. It has been the authors' experience that better and more gratifying results are achieved when the original diagnosis and treatment plan correlate the sagittal, dental, and skeletal relationships with facial form.

Angle's description of the sagittal relationship of the maxillary and mandibular dental units does not take into account their spatial orientation with respect to the patient's facial type. For example, Figs. 22.21 and 22.22 show examples of two patients who both demonstrate an Angle Class III malocclusion. From the photographs it is apparent that the overall relationship of the bony bases and the teeth to the face are quite dissimilar, even though both examples are given the same Angle classification. Fig. 22.21 depicts an example of maxillary deficiency (retrognathism), whereas Fig. 22.22 represents a case demonstrating mandibular

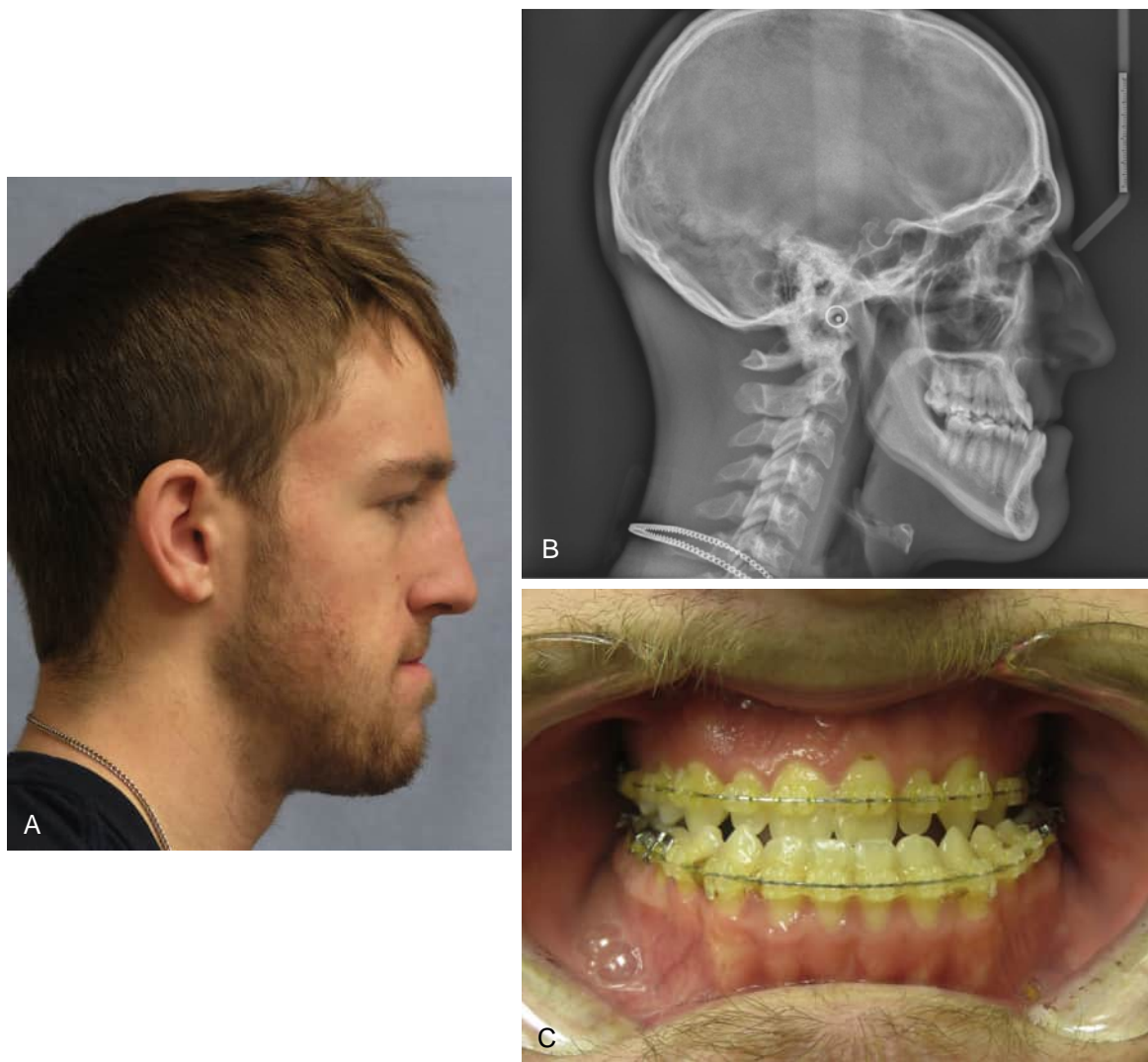


Fig. 22.21 (A) Maxillary retrognathism (clinical appearance). (B) Maxillary retrognathism (cephalometric radiograph). (C) Class III occlusion.

prognathism. Even though the Angle relationship is the same, the comprehensive diagnosis and treatment plan should be quite different if the most favorable result for each patient is to be achieved. Therefore, further supplementation of Angle's system of classification is in order.

### DESCRIPTIVE SKELETAL AND DENTAL EVALUATION

Before the basic steps involved in comprehensive analysis are outlined, the following five descriptive terms must be defined and clearly understood.

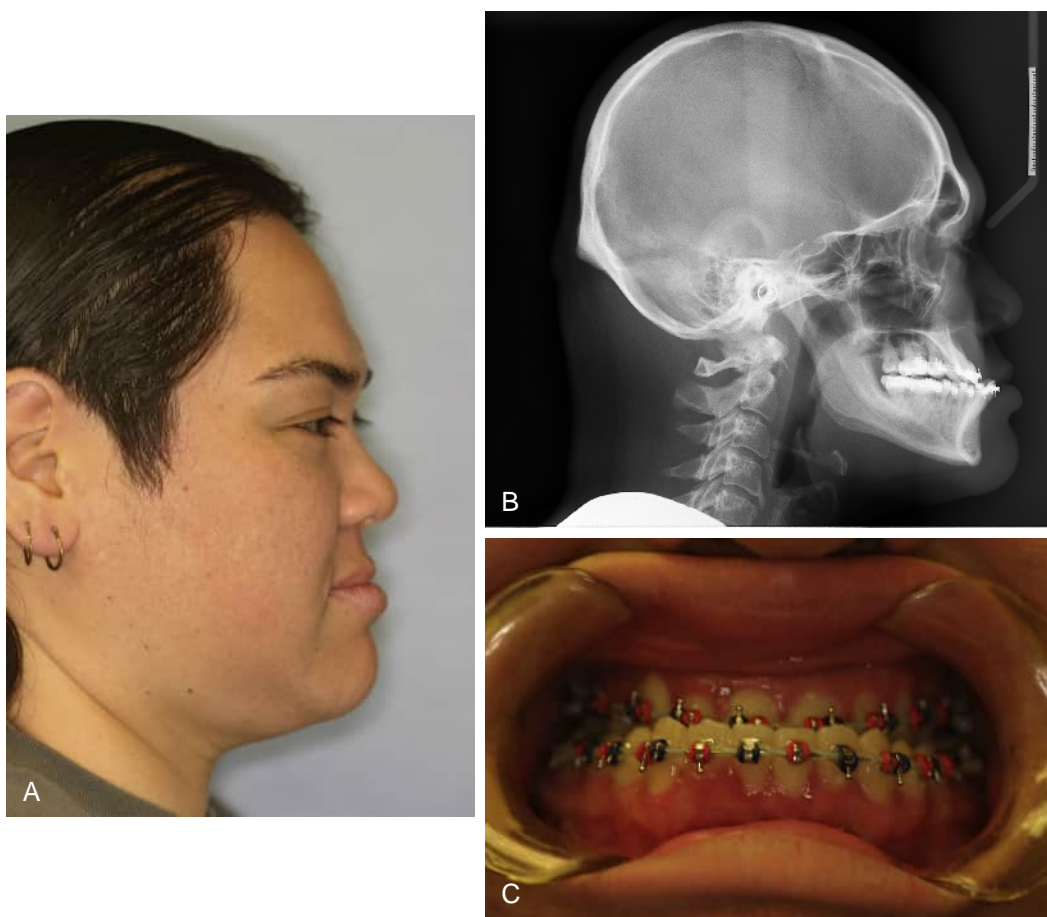- **Orthognathism:** A skeletal term indicating the ideal balance among the cranial base, the maxilla, and the mandible from a sagittal view.
- **Prognathism:** The anterior positioning of either one or both bony jaws relative to the facial skeleton and soft tissues. Hence the following entities may exist: maxillary prognathism, mandibular prognathism, or bimaxillary (maxillary and mandibular) prognathism.

- **Retrognathism:** The posterior placement of either one or both jaws relative to the face. Similar entities can be demonstrated as mentioned in the previous category.
- **Protrusion:** A forward positioning of the dental units (teeth) relative to their bony base. Again, protrusion may occur with maxillary or mandibular teeth or both.
- **Retrusion:** A posterior placement of either one or both dentoalveolar units relative to their respective bony bases.

Although the terms *prognathism* and *retrognathism* describe improper skeletal relationships of the jaws and the face, protrusion and retrusion simply indicate the relation of the dentoalveolar unit with respect to its supporting jaw.

Thus four components exist that can occur in any one of three possible sagittal positions (anterior, posterior, and ideal). These constitute 81 possible combinations.

By supplementing the Angle classification with additional analyses to determine the relative maxillary and mandibular skeletal, dental, and facial relationships, the clinician can obtain a more detailed diagnosis. The specific components of the craniofacial complex responsible for the



**Fig. 22.22** (A) Mandibular prognathism (clinical appearance). (B) Mandibular prognathism (cephalometric radiograph). (C) Class III occlusion.

discrepancy are also more clearly identified. Cephalometric analysis also must be correlated and compared with other diagnostic records and clinical findings because the former cannot be expected to provide all the information necessary for an accurate treatment analysis.

The accuracy of the diagnosis is dependent on a thorough and systematic evaluation of several of the morphologic components in combination; individual measurements are of little value by themselves. Isolated measurements may demonstrate CD from the norm, but when these dimensions are combined with others, they may show collective compensation yielding a normal occlusal relationship. In contrast, a malocclusion may also be the result of dimensions that, individually, are considered within normal limits yet in combination result in an abnormal arrangement.

Any cephalometric measurement may be misleading. There are no specific groups of factors that provide 100% accuracy. It is important to realize that the fewer the factors used in the analysis, the greater the risk of misdiagnosis.

It is the borderline cases that often require a more detailed analysis. Obvious cases involving severe skeletal dysplasia can often be diagnosed based on relatively few factors.

To properly analyze a cephalometric tracing, one must evaluate the interarch and the patient's facial characteristics.

## Evaluation of Facial Aesthetics

A thorough and systematic evaluation of a patient's facial structures forms the basis for an accurate diagnosis and subsequent treatment. Too often, the lateral cephalometric radiograph and diagnostic casts are used as substitutes for a complete clinical examination of the patient's facial characteristics. Most of us have been taught to focus on the lateral cephalometric radiograph in our diagnosis. In the process, we have migrated away from the clinical examination and the art of the soft tissue diagnosis. It is imperative that we reintroduce the fundamental concepts of art and beauty that were fundamental in the Angle School of Orthodontia. Over the years, advancements in orthodontic technology have resulted in a shift from the art in orthodontic diagnosis and treatment planning to a dependency on cephalometric measurements. The clinical examination has taken a back seat to the typical orthodontic records, which include the lateral cephalometric radiograph and study models. Orthodontic treatment goals based entirely on cephalometric numbers may result in excessive retraction of the maxillary and mandibular incisors. There is much more to modern-day orthodontics than just an excellent occlusion. It has been stated that hard tissue analysis alone is inadequate in treatment planning and may result in a compromised soft tissue profile.



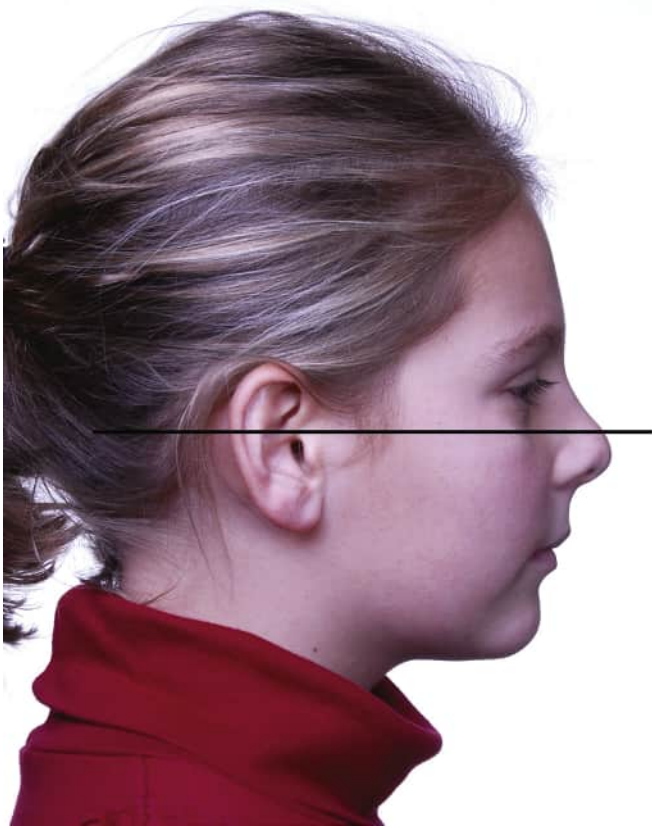

Fig. 22.23 Patient's head positioned with the Frankfort horizontal plane parallel to the floor.

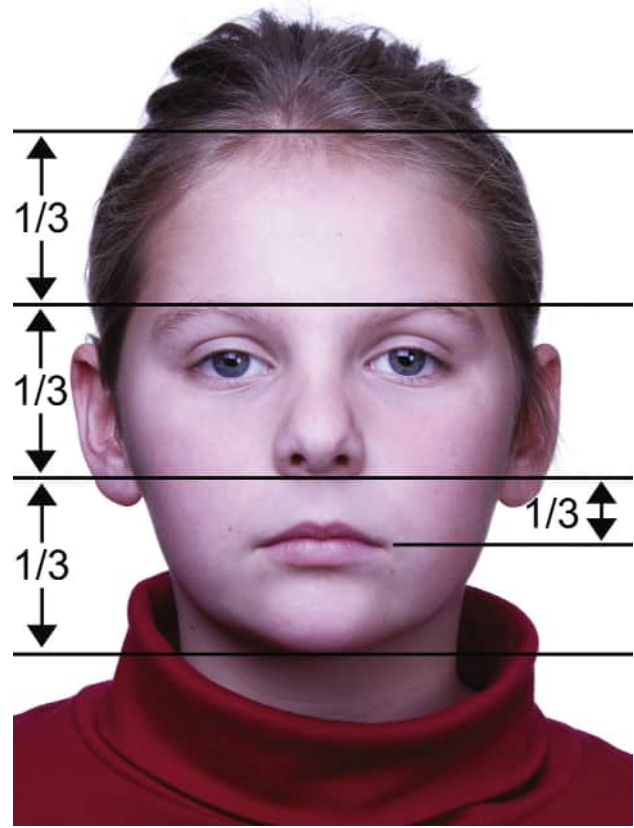


Fig. 22.24 Frontal facial thirds.

Lines, angles, and numbers should not be used as the only diagnostic tools, but rather should be viewed as an adjunct to what the clinician visually assesses about the patient's facial form. To develop the clinical ability to observe variations from the normal facial structure, the practitioner must have a firm grasp of what constitutes an ideal face (complete with ideal variations). This section deals with the facial examination of the ideal face. The guidelines are directed at the adolescent and teenaged patient and do not have complete application to patients from 5 to 10 years of age because facial proportions generally change with the approach of puberty.

To evaluate the patient properly, the clinician should have the patient stand in a relaxed position. The patient's head should be positioned with the Frankfort horizontal plane parallel to the floor (Fig. 22.23). Patients should not be asked to simply "look straight ahead" because patients tend to place the head in the position that is habitually preferred. It is also important to position the patient's occlusion in centric relation rather than centric occlusion. The patient's lips should be in repose during the examination. Patients frequently mask lip incompetence by forcing their lips together.

### FRONTAL VIEW

The evaluation begins with the frontal view. This is the view people most often see of themselves. The balance among the upper, middle, and lower thirds of the face is

analyzed (Fig. 22.24). The upper third is bounded by the hairline (when combed back) and glabellar area. This area is least informative and is not the area to which corrections would normally be directed. More emphasis is placed on the proportions and symmetry of the middle third (from the glabellar region to subnasale) and the lower third (from the subnasale to menton).

In the middle third of the face, when the patient is looking straight ahead, the sclera of the eye is not seen superior or inferior to the pupil. Normal intercanthal distance is 30–32 mm (CD,  $\pm 2$  mm). Normal interpupillary distance is 60–65 mm. The inner and outer canthal tendons should fall close to a straight horizontal axis through the palpebral fissures (the fissures created when the eyelids are closed). The distance between the semilunar folds in the intercanthal area should approximate the alar base width (Fig. 22.25). Deviations from these general guidelines could indicate some deformity of the middle facial third.

Evaluation of the lower facial third is then performed. The ratio of the middle to lower facial thirds in vertical height should be approximately 5:6. The upper lip and its relationship to the teeth are noted with the lips in repose and also during smiling. The distance between the medial limbus of the eyes should equal the width of the mouth when it is relaxed (Fig. 22.26). Interlabial distance is measured with the lips at rest; up to 3.5 mm of interlabial distance is considered acceptable. The upper lip length from subnasale to stomion (lip commissure) should represent one-third of the lower third facial height (Fig. 22.24). Normal upper lip length should be 22 mm (CD,  $\pm 2$  mm) in males and 20 mm (CD,  $\pm 2$  mm) in females. Ideally, with the lips in



Fig. 22.25 Comparison of the intercanthal distance and alar base width.

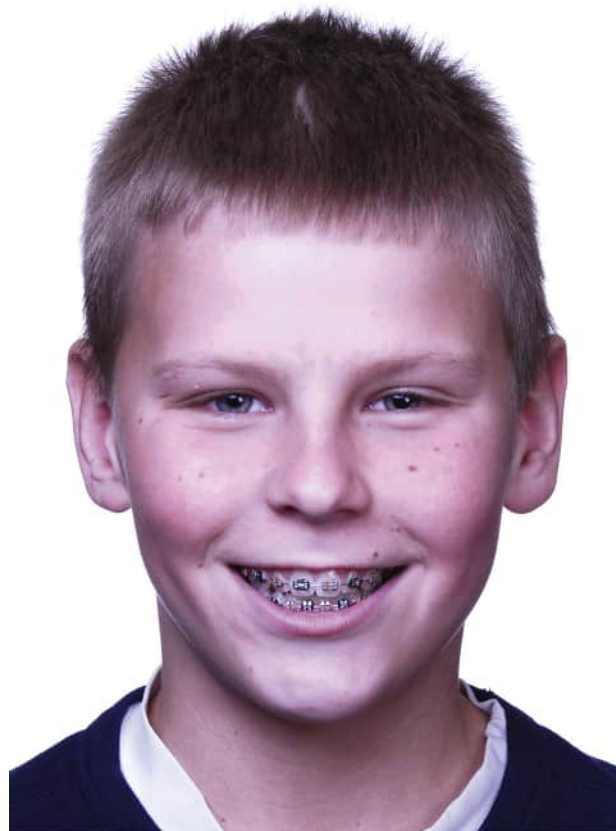

Fig. 22.27 Ideal smile pattern.



Fig. 22.26 Comparison of the medial limbus width and the width of the mouth.

repose, 2–4 mm of the upper incisor should be visible. More than this amount could indicate a vertical maxillary excess. One important characteristic that is often missed is that the incisal edges should approximate the lower lip line.

Next, the patient's smile is assessed. Another important aspect of a well-balanced smile is the height, uniformity, and contour of the gingival margins. Grafts and gingival recontouring may be an important treatment modality in selected cases. In addition, the facial surfaces of the anterior teeth should converge toward the facial midline; the long axis (direction of the anterior teeth) in an aesthetic smile also follows a progression as the teeth move away from the midline. The separations between the maxillary anterior teeth help to define an attractive smile. The spaces between the edges of the teeth are known as embrasure spaces. These spaces follow a pattern that begins between the central incisors and progresses as one moves away from the dental midline. Smile patterns vary with individuals, but aesthetically, when a person smiles, the upper lip vermilion should rest on or near the cervicogingival margin of the incisors (Fig. 22.27).

The smile analysis would not be complete without an evaluation of the buccal corridors, which are defined as the spaces between the buccal surfaces of the maxillary posterior teeth and the inner commissures (Fig. 22.27). Generally, smile attractiveness is improved as the buccal corridor is decreased. In other words, small buccal corridors are considered to be significantly more attractive than large buccal corridors. The position of the lower lip is also noted.



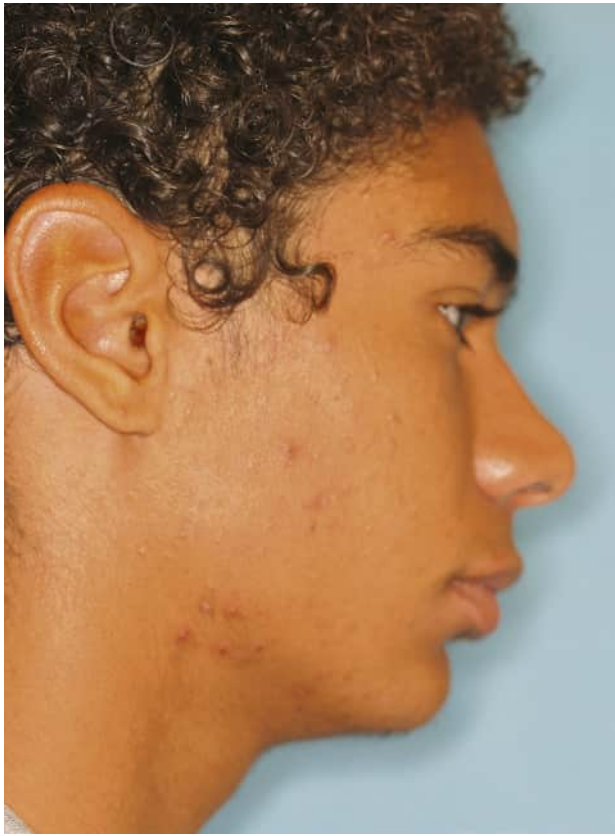

Fig. 22.28 Excessive eversion of the lower lip.

Excessive eversion of the lower lip is seen in patients with mandibular retrognathism (Fig. 22.28). The mentalis muscle can be hyperactive during forced closure of the lower lip (Fig. 22.29); such muscle hyperactivity is frequently seen in patients with mandibular retrognathia, vertical maxillary excess, apertognathia (open-bite deformity), and lip incompetence.

The last evaluation of the full face is that of facial symmetry. The face is divided in half by a line that bisects the glabella, nasal tip, upper lip, and chin (Fig. 22.30). The face is also divided vertically into equal fifths (Fig. 22.31).

### PROFILE VIEW

The patient is next evaluated from the profile view. The examination considers many of the same features noted in the frontal examination. The face is divided into thirds (Fig. 22.32). A comparison of the vertical facial heights and the AP relationship of the facial thirds constitutes the initial assessment. The vertical relationships are the same in the profile view as they are in frontal views.

The upper facial third profile establishes the relationship between the forehead and superior orbital rim. The further the forehead protrudes beyond the superior orbital rim, the less aesthetically acceptable it is. The globe of the eye and its relationship to the superior orbital rim are assessed. The superior orbital rim is normally 8–16 mm anterior of the globe.

The evaluation of the middle facial third involves an assessment of the relationship among the globes, inferior orbital rims, cheekbones, nose, and upper lip. The nasal bridge should project anterior to the globe by 5–15 mm.

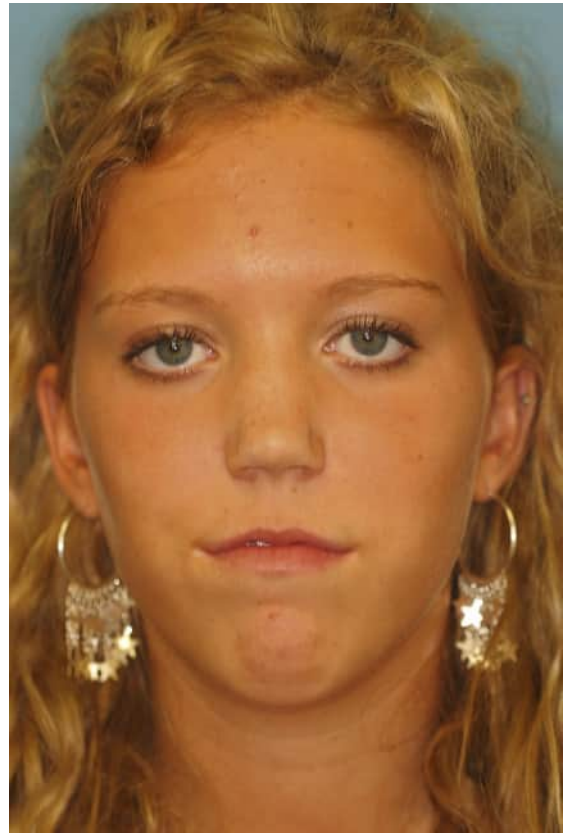


Fig. 22.29 Hyperactive mentalis muscle during forced lip closure. Patient has lip incompetence.



Fig. 22.30 Facial symmetry.

A reference line dropped from the most anterior projection of the globe and perpendicular to the Frankfort horizontal plane should fall on, or slightly behind, the soft tissue of the cheek.





Fig. 22.31 Vertical facial fifths.

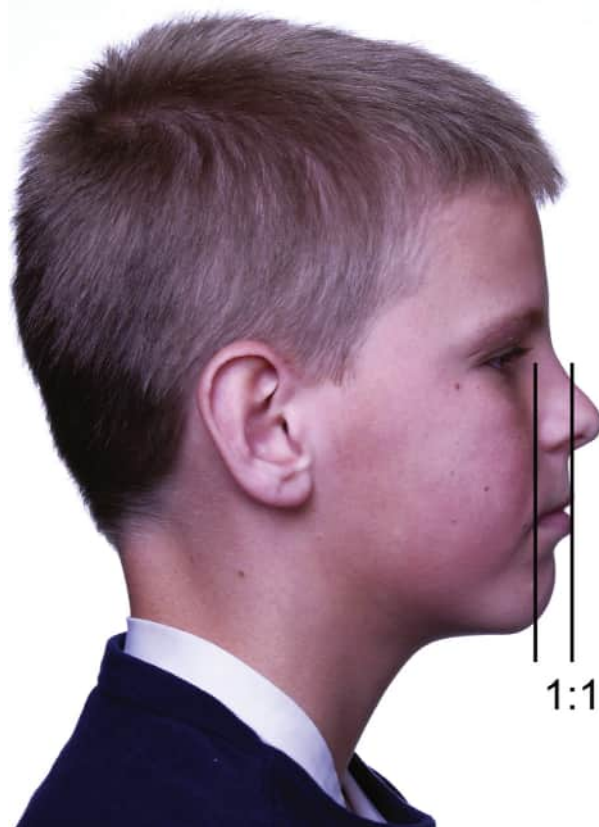


Fig. 22.33 Ratio shows 1:1 relationship from nasolabial fold to subnasale, and from subnasale to tip of the nose.

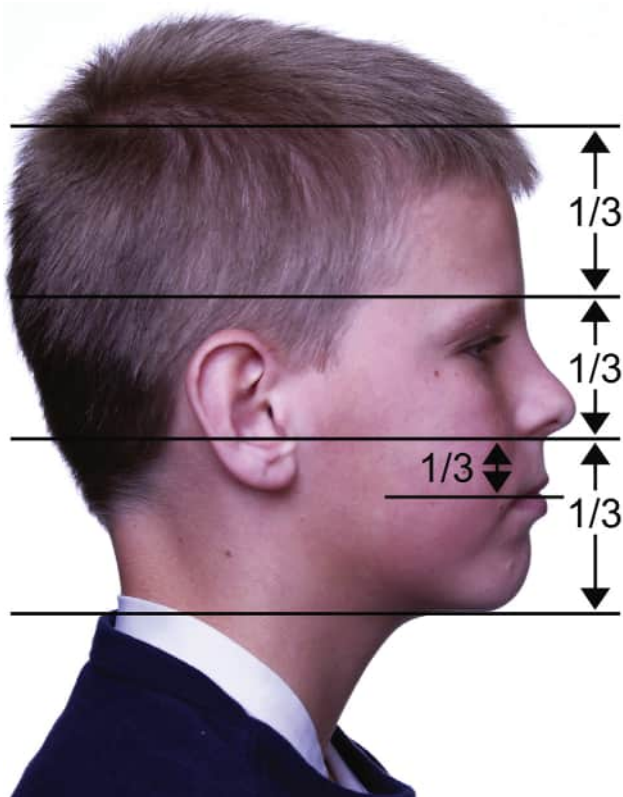


Fig. 22.32 Profile facial thirds.

In evaluation of the lower facial third, the vertical dimensions as described in the frontal view need to be considered. In addition, AP assessments are done. Projection of the upper lip is clinically evaluated by measuring from the nasolabial fold to the subnasale and comparing that numeric value with the distance from the subnasale to the tip of the nose. Ideally this ratio should be 1:1 (Fig. 22.33). The relationship of the nose and upper lip is determined by measuring the nasolabial angle (Fig. 22.34). This value can range from 90 to 110 degrees.

The lower facial third is compared with the middle and upper thirds. The zero meridian is a straight line constructed by placing a line through the soft tissue nasion, perpendicular to the Frankfort horizontal plane. The lips and chin should fall near this line (Fig. 22.35). During the profile evaluation of the lower facial third, any AP discrepancies between the maxilla and mandible (i.e., prognathism and retrognathism) are noted. The upper and lower lip positions are also assessed. The shape and size of the chin button are also appraised. In some cases apparent mandibular retrognathism is in reality a flat or deficient chin button (microgenia). Conversely, too prominent a chin may be visualized as a pseudoprognathism and may be aesthetically unacceptable.

The evaluation of the patient's face constitutes an important portion of the initial diagnosis and treatment plan phase of orthodontics. A systematic approach to examining the face is essential (Fig. 22.36). Basic guidelines of facial form have been reviewed. The values discussed are normal values for whites, but these must be used as relative guidelines only.

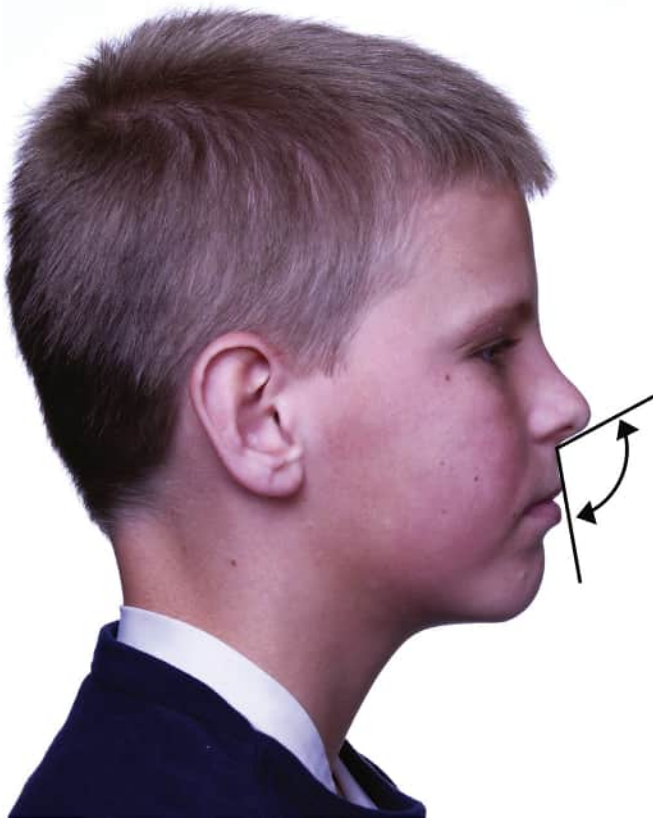


Fig. 22.34 Nasolabial angle.


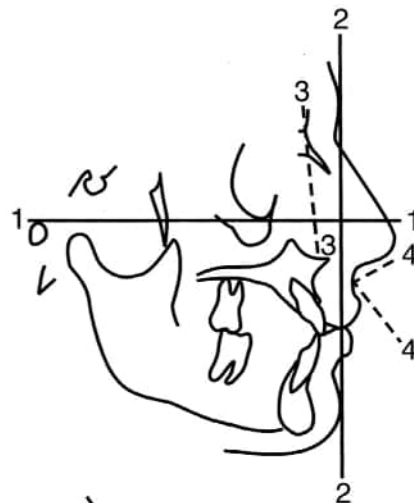


Fig. 22.35 Zero meridian.

## Lateral View

1. Frankfort Horizontal Plane: (FH)  
This plane is constructed from superior porion: (Po) to inferior orbitale (O) and represents the basic horizontal plane of the head.
2. Zero Meridian:  
The horizontal distance from the chin to a line perpendicular to (FH) and tangent to soft tissue nasion.
3. Maxillary Depth:  
The angle formed by the intersection of (FH) and N–A point planes.
4. Nasolabial Angle:  
The angle formed by the intersection of the lines tangent to the columella of the nose and the upper lip.



## Lateral View Lip Measurements

1. Interlabial Gap:  
0-3.5 mm with lips in repose.
2. Upper Lip Length:  
Measured from (SN) to the inferior border of the upper lip.
3. Upper Incisor relative to the Upper Lip:  
The amount of upper incisor relative to the inferior border of the upper lip in repose.

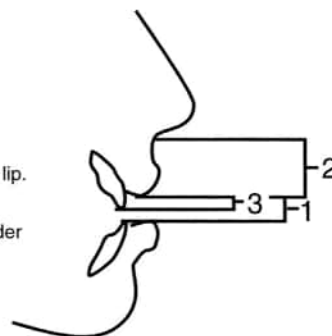


Fig. 22.36 Summary of lateral dentofacial measurements.

The clinician must look at the patient's face and assess the overall harmony that exists. When deviations from normal facial form are detected, variations in treatment modalities must be considered to achieve better facial harmony. The main treatment objective is always to provide the patient with the best functional and aesthetic result possible.

### Suggested Readings

- Ackerman MB, Ackerman J: Smile analysis and design in the digital era, *J Clin Orthod* 36(4):221–236, 2002.
- Angle EH: Classification of malocclusion, *Dent Cosmos* 41(248–264):350–357, 1899.
- Arnett GW, Bergman RT: Facial keys to diagnosis and treatment planning—part I, *Am J Orthod Dentofacial Orthop* 103(4):299–312, 1993.
- Arnett GW, Bergman RT: Facial keys to diagnosis and treatment planning—part II, *Am J Orthod Dentofacial Orthop* 103(5):395–411, 1993.
- Baek SH, Cho IS, Chang YI, et al.: Skeletodental factors affecting chin point deviation in female patients with Class III malocclusion and facial asymmetry: a three-dimensional analysis using computed tomography, *Oral Surg Oral Med Oral Pathol Oral Radiol Endod* 104(5):628–639, 2007.
- Bell WH, Proffit WR, White RP: *Surgical correction of dentofacial deformities*, Philadelphia, 1980, WB Saunders.
- Boley JC: Serial extraction revisited: 30 years in retrospect, *Am J Orthod Dentofacial Orthop* 121(6):575–577, 2002.
- Braun S: Diagnosis driven vs appliance driven treatment outcomes. In: (editor: Sachdeva RCL) *Orthodontics for the next millennium*. Glendora, CA: Ormco: pp. 32–45, 1997.
- Broadbent BH: A new x-ray technique and its application to orthodontia, *Angle Orthod* 1(2):45–66, 1931.
- Broadbent BH: The face of the normal child, *Angle Orthod* 7(4):183–208, 1937.
- Brodie AG, Downs WB, Goldstein A, et al.: Cephalometric appraisal of orthodontic results: a preliminary report, *Angle Orthod* 8(4):261–351, 1938.
- Burstone CJ: Lip posture and its significance in treatment planning, *Am J Orthod* 53(4):262–284, 1967.
- Cheong YV, Lo LJ: Facial asymmetry: etiology, evaluation, and management, *Chang Gung Med J* 34(4):341–351, 2011.
- Dickens S, Sarver DM, Proffit WR: The dynamics of the maxillary incisor and the upper lip: a cross-sectional study of resting and smile hard tissue characteristics, *World J Orthod* 3(4):313–320, 2003.
- Downs WB: Variations in facial relationships: their significance in treatment and prognosis, *Am J Orthod* 34(10):812–840, 1948.
- Dugoni SA, Lee JS, Varela J, et al.: Early mixed dentition treatment: posttreatment evaluation of stability and relapse, *Angle Orthod* 65(5):311–332, 1995.
- Gracco A, Cozzani M, D'Elia L, et al.: The smile buccal corridors: aesthetic value for dentists and laypersons, *Prog Orthod* 7(1):56–65, 2006.
- Havens DC, McNamara Jr JA, Sigler LM, et al.: The role of the posed smile in overall facial esthetics, *Angle Orthod* 80(2):322–328, 2010.
- James RD: A comparative study of facial profiles in extraction and non-extraction treatment, *Am J Orthod Dentofacial Orthop* 114(3):265–276, 1998.
- Katz MI: Angle classification revisited. Is current use reliable? *Am J Orthod Dentofacial Orthop* 102(2):173–179, 1992.
- Klocke A, Nanda RS, Kahl-Nieke B: Skeletal class II patterns in the primary dentition, *Am J Orthod Dentofacial Orthop* 121(6):596–601, 2002.
- Lines PA, Lines RR, Lines CA: Profilemetrics and facial esthetics, *Am J Orthod* 73(6):648–657, 1978.
- Long Jr RE, McNamara JA: Facial growth following pharyngeal flap surgery: skeletal assessment on serial lateral cephalometric radiographs, *Am J Orthod* 87(3):187–196, 1985.
- McLeod C, Fields HW, Hechter F, et al.: Esthetics and smile characteristics evaluated by lay-person, *Angle Orthod* 81(2):198–205, 2011.
- McNamara JA: Influence of respiratory pattern on craniofacial growth, *Angle Orthod* 51(4):269–300, 1981.
- Moore T, Southard KA, Casko JS, et al.: Buccal corridors and smile esthetics, *Am J Orthod Dentofacial Orthop* 127(2):208–213, 2005.
- Morley J: The role of cosmetic dentistry in restoring a youthful appearance, *J Am Dent Assoc* 130(8):1166–1172, 1999.
- Owen 3rd AH: Diagnostic block cephalometrics. Part 1, *J Clin Orthod* 18(6):400–422, 1984.
- Owen 3rd AH: Clinical interpretation of diagnostic block cephalometric analysis, *J Clin Orthod* 20(10):710–715, 1986.
- Parekh SM, Fields HW, Beck M, et al.: Attractiveness of variations in the smile arc and buccal corridor space as judged by orthodontists and laymen, *Angle Orthod* 76(4):557–563, 2006.
- Reidel RA: The relation of maxillary structures to cranium in malocclusion and in normal occlusion, *Angle Orthod* 22(3):142–145, 1952.
- Ricketts RM: Cephalometric analysis and synthesis, *Angle Orthod* 31(3):141–156, 1961.
- Ricketts RM, Schulhof RJ, Bagha L: Orientation—sella-nasion or Frankfort horizontal, *Am J Orthod* 69(6):648–654, 1976.
- Ritter DE, Gandini Jr LG, Pinto AD, et al.: Analysis of the smile photograph, *World J Orthod* 7(3):279–285, 2006.
- Rody Jr WJ, Araujo EA: Extraction decision-making Wigglegram, *J Clin Orthod* 36(9):510–519, 2002.
- Sarver DM: Video cephalometric diagnosis (VCD): a new concept in treatment planning? *Am J Orthod Dentofacial Orthop* 110(2):128–136, 1996.
- Schulhof RJ: When S-N is abnormal, *J Clin Orthod* 11(5):343, 1977.
- Severt TR, Proffit WR: The prevalence of facial asymmetry in the dentofacial deformities population at the University of North Carolina, *Int J Adult Orthod Orthognath Surg* 12(3):171–176, 1997.
- Simon PW: *Fundamental principles of a systematic diagnosis of dental anomalies*, Boston, 1926, The Stratford.
- Steiner CC: Cephalometrics for you and me, *Am J Orthod* 39(10):729–755, 1953.
- Tucker S, Cevidanes LH, Styner M, et al.: Comparison of actual surgical outcomes and 3-dimensional surgical simulations, *J Oral Maxillofac Surg* 68(10):2412–2421, 2010.
- Tweed CH: The Frankfort-mandibular incisor angle (FMIA) in orthodontic diagnosis, treatment planning and prognosis, *Angle Orthod* 24(3):121–169, 1954.
- You KH, Lee KJ, Lee SH, et al.: Three-dimensional computed tomography analysis of mandibular morphology in patients with facial asymmetry and mandibular prognathism, *Am J Orthod Dentofacial Orthop* 138(5):540. e1–e8, 2010.



## 23

# Managing the Developing Occlusion

JEFFREY A. DEAN and JOHN S. WALSH

## CHAPTER OUTLINE

**Development of Occlusion and Timing of Interventions**

Primate Spaces

Mesial Molar Shift

Leeway Space

Intervention Considerations

**Early Loss of Teeth and Space Maintenance**

Needs Assessment

Specific Tooth Loss Strategies

**Oral Habits in Children**

Bruxism

Non-Nutritive Sucking

Tongue-Thrust Swallowing

**Anterior Crossbite in Primary and Mixed Dentitions**

Tongue Blade/Popsicle Stick Therapy

Lower Inclined Plane

Palatal Spring Appliances (Removable Hawley or Fixed Palatal Wire)

Fixed Transpalatal Wires With Springs

**Posterior Crossbite in Primary and Mixed Dentitions**

Selective Equilibration

Maxillary Expansion

**Eruption Problems and Eruption "Guidance"**

Ectopic Eruption of First Permanent Molars

Eruption Guidance in the Lower Incisor Segment

Eruption Guidance in the Mandibular Canine And Premolar Segment

Eruption Guidance in the Maxillary Canine and Premolar Segment

**Obstructive Sleep Apnea and Orthodontics**
**Comprehensive Orthodontics for the Developing Occlusion**

Primary to Mid-Mixed Dentition (Ages 4–10 Years)

Mid- to Late Mixed Dentition (Ages 10–12 Years)

Early Permanent Dentition (Ages 12–16 Years)

The goal of every practitioner providing oral health care for children and adolescents should be to assess and guide the developing occlusion toward optimal outcomes. The Clinical Guidelines of the American Academy of Pediatric Dentistry<sup>1</sup> on "Management of the Developing Dentition and Occlusion in Pediatric Dentistry" illustrate this responsibility with the following statement:

*Guidance of eruption and development of the primary, mixed, and permanent dentitions is an integral component of comprehensive oral healthcare for all pediatric dental patients. Such guidance should contribute to the development of a permanent dentition that is in a stable, functional, and aesthetically acceptable occlusion. Early diagnosis and successful treatment of developing malocclusions can have both short-term and long-term benefits while achieving the goal of occlusal harmony, function, and dental facial aesthetics.*

Ngan et al.<sup>2</sup> illustrate this responsibility regarding contemporary practice in stating, "Pediatric dentistry has increasingly shifted from a conservative-restorative approach toward a concept of total pediatric patient care. Thus all aspects of oral health care including diagnosis, prevention, oral medicine, restoration, and correction of

malocclusion are increasingly the responsibility of the pediatric dentist." In the context of these statements, clinical decisions are presented daily that challenge pediatric practitioners in affecting outcomes in management of the developing occlusion. As defined by Moyers,<sup>3</sup> space supervision is "when the judgment of the dentist determines that the individual patient's occlusion will have a better chance of obtaining optimum development through supervised intervention of the transitional dentition than without clinician directed intervention." Space supervision encompasses procedures such as preventive orthodontics, guidance of eruption, interceptive orthodontics, and phased "early" orthodontic treatment that should be understood in terms of its diagnostic parameters, treatment basis, and clinical applications.

## Development of Occlusion and Timing of Interventions

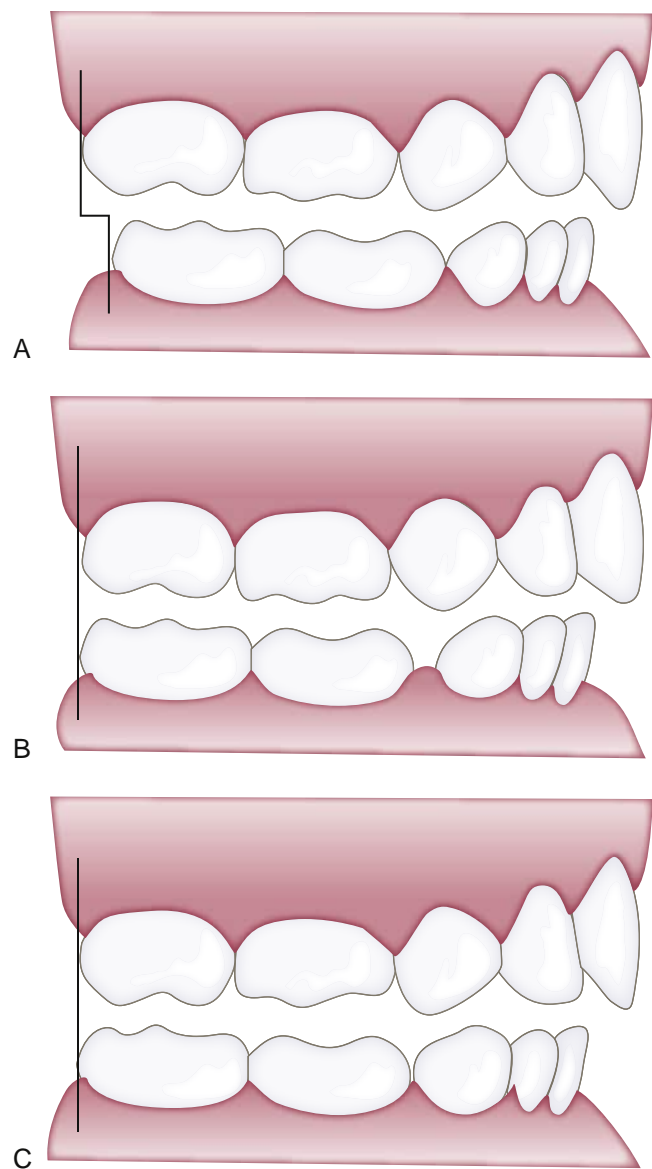
### PRIMATE SPACES

A review of studies by Baume,<sup>4</sup> Moorrees,<sup>5,6</sup> Bishara et al.,<sup>7</sup> and Moyers and Wainwright<sup>8</sup> provides an understanding

of the biogenetic course of the primary, transitional, and permanent dentitions that is critical to management of the developing dentition. Evaluating study models of the primary dentitions of 30 children obtained sequentially at various developmental stages, Baume<sup>4</sup> reported two consistent morphologic arch forms of the primary dentition: either generalized spaces between the teeth were present (Type I) or the teeth were in proximal contact without spacing (Type II). The arch form in both types appears congenital rather than developmental because the original pattern exhibited upon eruption was maintained from ages 3 to 6 years. Spaced arches frequently exhibit two distinct diastemas—referred to as *primate spaces*—one between the mandibular canine and first primary molar and the other between the maxillary lateral incisor and primary canine. Baume<sup>4</sup> observed that until the eruption of the permanent first molars, the sagittal dimension of the primary dental arches remained essentially unchanged, with the possible exception of a slight decrease as a result of the development of dental caries on the proximal surfaces of the molar teeth. Only minor changes in the transverse dimension of the primary dental arches occurred during 3–6 years of age unless negatively influenced by deleterious functional patterns. Given these findings, orthodontic intervention during the primary dentition up to 6 years of age is mostly directed toward maintaining inherent arch dimensions and arch integrity with preventive and restorative services. Space maintainers, when primary teeth are lost prematurely, are the next major consideration in maintaining arch dimensions. Control of functional problems such as elimination of deleterious thumb-sucking habits and correction of functional crossbites may also receive attention during the primary dentition years. While desirable, treatments for these factors are often deferred depending upon the cooperation of the child with appliance protocols.

### MESIAL MOLAR SHIFT

The early mixed dentition (6–9 years of age) is a period much more prone to localized factors that may result in severe malocclusion problems if undetected. In addition to continuation of basic preventive and space maintenance issues, problems encountered during this period include dentoalveolar anterior crossbites, ectopic eruption of permanent incisors and/or first permanent molars, posterior crossbites, open bite and flared maxillary incisors associated with deleterious oral habits, and developmental anomalies (e.g., ankylosis, supernumerary teeth, and missing teeth). Baume<sup>4</sup> compared models of 60 children before and after eruption of the permanent molars and found three distinct kinds of molar adjustment (Fig. 23.1). “Early” mesial shift during first permanent molar eruption occurs at the expense of any posterior spacing that might have been present to include breakdown spaces resulting from interproximal caries. Agreeing that the pattern of transition involving the straight terminal plane is normal, Moyers<sup>8</sup> suggested that the occlusion forming a mesial step (distal surface of the lower second primary molar is mesial to the same surface of the maxillary molar) is most ideal for Class I development. A distal step (distal surface of the lower second primary molar is distal to the same surface of the maxillary molar) indicates a developing Class II malocclusion. Proper



**Fig. 23.1** (A) Diagram showing mesial step terminal plane that allows the first permanent molar to erupt directly into proper Class I occlusion. (B) Straight terminal plane with primary spacing. “Early mesial shift” of mandibular molars closing primary spaces will help establish proper first permanent molar occlusion. (C) Straight terminal plane without primary spacing. Permanent molars erupt into end-on position in the mixed dentition. Proper first permanent molar occlusion may be attained when the second primary molars exfoliate and a “late mesial shift” of the mandibular first permanent molar occurs.

permanent molar occlusion was achieved from a straight terminal plane by a second mesial shift of the molars as second primary molars are exfoliated. This “late” shift of the mandibular first molar, often under the additional influence of the emerging second permanent molar, occurs at the expense of the leeway space with a decrease in the attendant arch length of 2–3 mm on average.

Further evaluation by Baume<sup>4</sup> indicated that a transverse widening of the intercanine width of the upper and lower dental arches occurred during eruption of the permanent incisors. The increase represented a physiologic widening by the lateral and frontal alveolar growth to provide space for the erupting permanent incisors and their greater

mesiodistal widths. The mean increase in the intercanine width was greater in the maxillary arch (3–4 mm) than in the mandibular arch (2–3 mm). In the mandibular arch, the greatest tendency to increased width was during eruption of the lower lateral incisors, whereas in the maxillary arch, it occurred primarily during eruption of the maxillary central incisors. Although the increase was slightly greater in nonspaced primary arches than in spaced arches, the arches with spaces generally resulted in a favorable alignment of the permanent incisors. About 40% of the arches without primary dental spacing resulted in crowded anterior segments. Moorrees<sup>5</sup> reported similar dimensional changes concurrent with incisor transitional periods.

Bishara et al.<sup>7</sup> also reported arch dimensional changes in their studies of patients from 6 weeks to 45 years of age, noting that (1) significant increases in the maxillary and mandibular arch width occurred between 6 weeks and 2 years of age; (2) the mandibular intercanine width was established by 8 years of age (i.e., after eruption of the four incisors); and (3) although the arch width increased between 3 and 13 years of age, there was a slight decrease in width, more in the intercanine than in the intermolar area, after complete eruption of the permanent teeth. In brief, incisor alignment patterns and intercanine arch dimensions are essentially established by 8 years of age. Interceptive procedures receive significantly more emphasis in this period to allow for a harmonious transition directed toward achieving alignment of the permanent incisors and 6-year molars with symmetric arch development and coincident midlines. Additionally, early recognition and elimination of deleterious oral habits or deviant functional patterns should enhance normal patterns of development while diminishing the long-term effects of atypical growth.

## LEEWAY SPACE

In addition to malocclusion factors identifiable during the first molar and incisor transition, corrective measures to align and position the erupting buccal segments come into play during the late mixed dentition (9–12 years of age), when primary canines and molars are exfoliating in conjunction with eruption of the permanent canines and premolars. Epidemiologic studies demonstrate that crowding and malalignment become significantly more prevalent and exhibit greater severity between the mixed dentition period (6–12 years of age) and the adolescent young permanent dentition (12–18 years of age). This suggests that normal transitional changes do not compensate for anterior malalignment and crowding, in that the late mesial shift of the buccal segments upon exfoliation of second primary molars results in decreased arch length and arch circumference. Nance<sup>9</sup> observed that in the average patient's mandibular arch, a leeway size difference of +1.7 mm per side exists, with the combined mesiodistal widths of the primary canine, first primary molar, and second primary molar being larger than the mesiodistal widths of the corresponding permanent canine and premolars. The difference between the total width of these same teeth in the maxillary arch is +0.9 mm per side of leeway space. Of interest is that Allen et al.<sup>10</sup> found a statistically significant decrease in leeway space, from 2.45 to 2.03 mm, when comparing two similar cohorts of American whites born in

the 1930s versus the 1990s. They suggest that this 21st-century decrease may present a challenge when managing arch length inadequacies.<sup>10</sup> The control of leeway space in terms of arch dimensional change through space supervision may offer opportunities for significant improvement in tooth size–arch size adjustments for the relief of typical levels of crowding. Gianelly<sup>11,12</sup> has shown that the control of leeway space will accommodate typical levels of lower incisor crowding in approximately 75% of mixed dentition patients presenting for orthodontic treatment. As applied to the late mixed dentition, a positive excess leeway space to an overall deficiency of less than 2 mm per quadrant may be considered potential situations for space supervision programs. However, there is a drawback; Sonis and Ackerman<sup>13</sup> have shown a significant increase in the mandibular second permanent molar impaction with this approach when compared with historic controls. There is a positive predictive value for such impaction in measurement of the pretreatment intermolar angulation between the first and second permanent mandibular molars. Finally, lower arch length deficiencies of more than 2–3 mm per quadrant should be considered a discrepancy beyond simple guidance procedures.

In keeping with supervision of leeway space as a fundamental concept, the vast majority of patients should be evaluated around the time of the clinical emergence of the lower canines and the lower and upper first premolars. These teeth erupt about 1 to 1½ years ahead of the final buccal segment transition. This leaves time for the practitioner to assess overall dimensional needs and plan treatment interventions for the relief of crowding, manage space to minimize future permanent tooth extractions, coordinate the transverse widths of the dental arches, and guide teeth into favorable positions that provide more stable long-term results. A second advantage for this timing in diagnosis and treatment planning is that it precedes the pubertal growth spurt in females, which in turn is approximately 2 years ahead of the pubertal growth spurt in males. If a skeletal malocclusion is noted, the opportunity for growth modification with dentofacial orthopedics, to take advantage of peak growth velocities, is available. Consultation with an orthodontist is helpful for children in whom skeletal considerations, severe growth problems, extensive crowding with pronounced tooth mass–arch length discrepancies, and dental anomalies are present that significantly compromise the child's orofacial development. Coordination will lead to more accurate identification of problems, aid in appropriate treatment decisions, and offer the potential for optimal results without having to resort to compromised treatment options in the full permanent dentition. Psychological aspects of treatment in terms of patient motivation, improved and dramatic dentofacial change, a social desire for treatment, and generally cooperative age group result in improved well-being for the child, and parents are good practice builders with timely coordinated management.

## INTERVENTION CONSIDERATIONS

One should recognize that certain disadvantages involved in “early” treatment must be factored into the equation on whether to intervene in an individual patient. These include: (1) the reality that overall treatment time is likely



prolonged; (2) multiple problems often arise in individual patients; (3) untoward responses may occur given the variability of growth dynamics; (4) there is potential for iatrogenic damage to the developing teeth; (5) some children cannot cope with treatment demands; and (6) patient and parent burnout can occur given that overall management is rarely a one-shot operation. Parents must have realistic perspectives of treatment goals and be willing to assume the financial and appointment obligations involved in treatment. While things happen slowly during the development of the occlusion, timing is critical for certain procedures, in that there are many problems that can occur and jeopardize successful outcome. In the decision-making process for an individual patient, the clinician involved in early orthodontic procedures should ask two key questions, each with its own subset of questions:

1. *What is the specific problem?* How did it happen? Is the etiology resolved? What will happen without treatment? Will it stay the same, get worse, or go away on its own? Simply put, not every child can or should be treated with interceptive procedures. Roughly half of patients fall into an area of real or absolute need in requiring corrective treatment for functional and aesthetic problems that will potentially lead to deterioration of the occlusion if untreated. Even though some children may benefit from interceptive treatments, there should be understanding that later comprehensive treatments will most likely be necessary to achieve acceptable results.
2. *What will the likely result of interceptive treatment be?* The remaining estimate of up to 50% of children is the population group that might benefit from early orthodontic interventions in the developing occlusion years. This group involves malocclusion factors in which treatment intervention will potentially eliminate or minimize the need for future orthodontic treatment. At the least, interceptive treatments should enhance long-term treatment options and outcomes without compromising future needs. So a subset of questions should be asked. Is treatment justified in terms of improvement in aesthetics and function while eliminating or minimizing the need for future treatment? Will the intervention correct a problem at the optimal time to enhance later options and outcomes? Can treatment methods be used to advantage such that the skill and experience of the clinician intersect with patient needs? Does treatment meet socioeconomic issues? Does the treatment present an outcome that can be easily realized in conjunction with later comprehensive care that will be required anyway?

For these questions to be answered, a thorough clinical examination supported by appropriate diagnostic records should be obtained before treatment interventions are initiated. The clinical examination should assess the patient's overall health status, extraoral facial patterns (profile, facial symmetry, and area of discrepancy), occlusion from an aesthetic and functional standpoint, temporomandibular joint function, neuromuscular patterns, growth patterns, and nasopharyngeal airway patterns. A form similar to the one depicted in Fig. 23.2 is helpful in composing clinical findings and formulating the patient's diagnosis, problem list, and treatment plan summary. In terms of diagnostic records beyond clinical findings, necessary records may range from

simple photos or study models for the treatment of a functional posterior crossbite to a complete set of orthodontic records for a patient with a skeletal malocclusion or severe crowding. More comprehensive records may include an eight-film series of extraoral and intraoral photographs, orthodontic study models, a full-mouth series or panoramic radiographs, lateral and anteroposterior cephalograms, and, when indicated, temporomandibular diagnostic views such as corrected axis tomograms or magnetic resonance imaging. Supplemental diagnostic procedures can also include a detailed tooth size–arch size space analysis (Chapter 20) and a cephalometric analysis (Chapter 21). Finally, cone beam computed tomography should be considered in special cases, such as patients with impacted teeth or craniofacial anomalies.

## Early Loss of Teeth and Space Maintenance

If arch integrity is disrupted by early loss of primary teeth, problems may arise that affect the alignment of the permanent dentition. Opposing teeth can supraerupt, more distal teeth can drift and tip mesially, and more forward teeth can drift and tip distally (Figs. 23.3 and 23.4). Altered tooth positions may include a “symptomatic” space deficiency with loss of arch length and circumference, blocked or deflected eruption of permanent teeth, unattractive appearance, food impaction areas, increased caries and periodontal disease, and other negative aspects of malocclusion. The altered occlusal relationships may evidence traumatic interference and untoward jaw relationships. When early primary tooth loss occurs, corrective measures such as passive space maintenance, active tooth guidance with space regained, or a combination of both may be needed to optimize the normal process of occlusal development.

Miyamoto et al.<sup>14</sup> observed the effects of the early loss of primary teeth by measuring crowding and malalignment in the permanent dentition of 255 schoolchildren aged 11 years or older. Children who had premature loss of one or more primary canines or molars were more likely to receive orthodontic treatment in the permanent dentition, with the need being more than three times greater in children who had lost one or more primary teeth through 9 years of age than in the control group. Premature loss of primary molars was especially associated with major malalignment of permanent teeth. No differences were observed in effects between the loss of first and second primary molars. Crowding of anterior teeth was directly affected by the premature loss of primary canines.

### NEEDS ASSESSMENT

A review of the clinical literature by Owen<sup>15</sup> revealed the following general factors that should be considered in assessing the implications of premature loss of primary teeth for arch development, the development of a malocclusion, and the need for a space maintainer.

1. *Incidence of space loss:* Almost all cases of early primary molar loss show some decrease in arch length (i.e., mesial movement of permanent molars, distal movement of



**4. Attach computerized cephalometric tracing and appropriate analysis.**

**5. Diagnostic and Arch Length Analysis Summary and Problem List**

**6. Treatment Plan or Objective Sequence**

**7. Mechanics Plan—Appliance Selection—Retention**

**8. Projected Treatment Time (with Good Compliance), Treatment Fees**

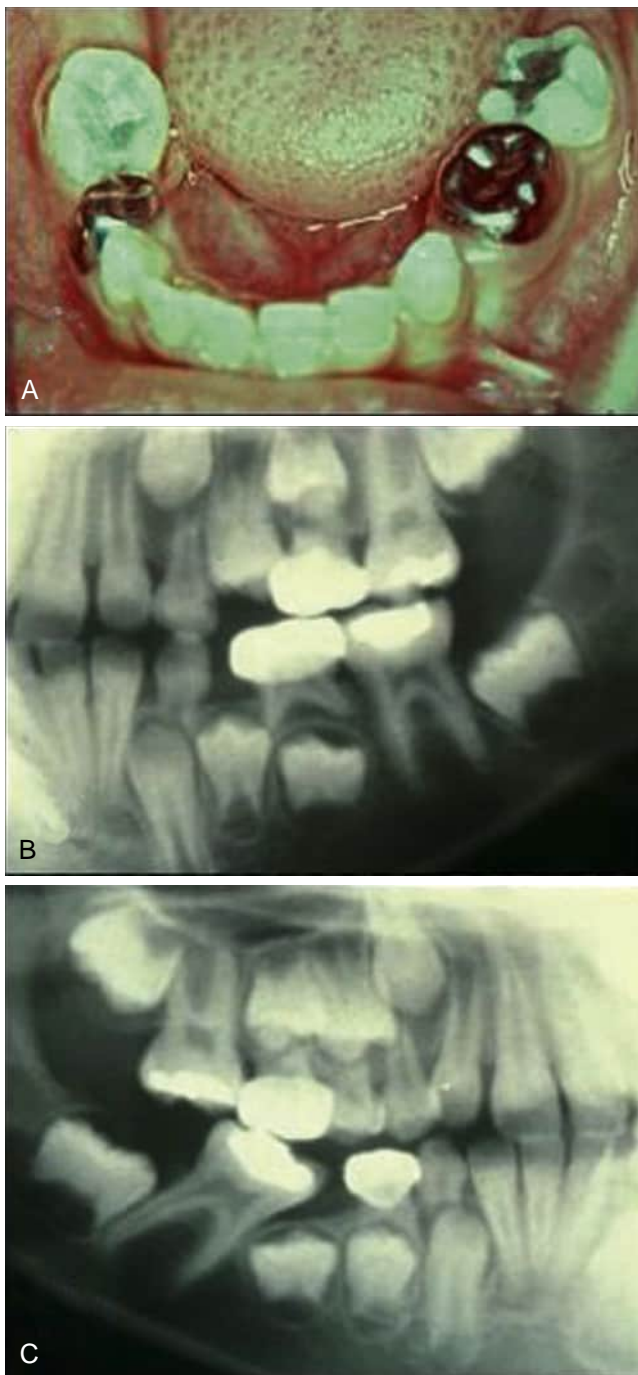
**9. Faculty Authorization to Start Treatment:**

\_\_\_\_\_  
Signature

\_\_\_\_\_  
Date

B

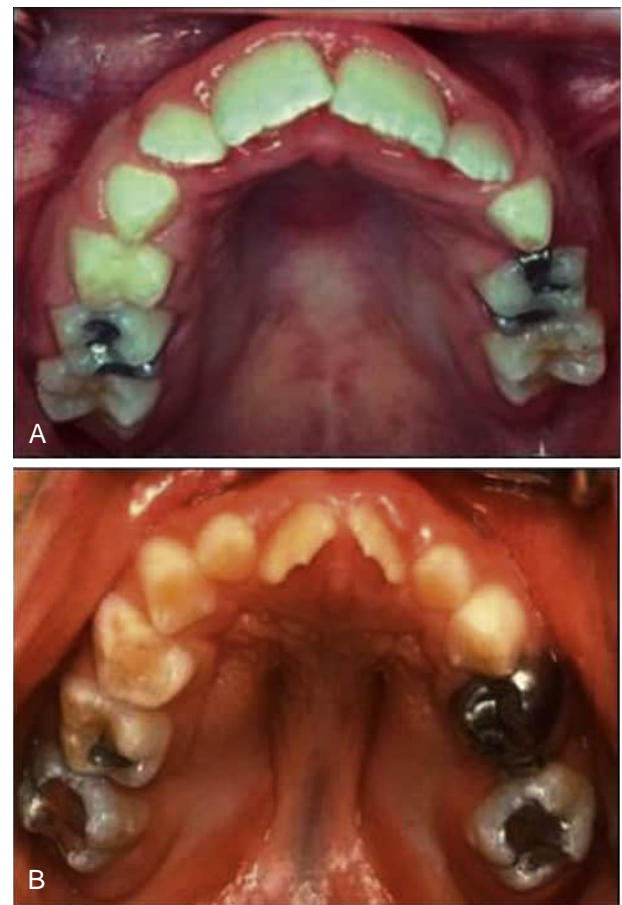




**Fig. 23.3** (A) Space loss and occlusal changes associated with early loss of lower primary molars. (B) Radiograph of left segment with loss of first primary molar. Note some distal movement of primary canine. (C) Radiograph of right segment with loss of mandibular second primary molar and associated space loss approximating 4–6 mm. Note the pronounced mesial tipping of permanent first molar crown without notable bodily movement.

anterior teeth). The amount of closure is affected by numerous variables (e.g., tooth involved, time of loss).

2. *Time elapsed since loss:* Most of the space loss usually occurs during the first 6 months after the primary tooth is lost, and space closure tends to occur more rapidly in the maxillary arch than in the mandible. Thus when a primary tooth is removed and factors indicate the need



**Fig. 23.4** Loss of upper primary molars in association with the eruption of first permanent molars and space loss. (A) Loss of upper left first primary molar with space loss approximating 4–6 mm. (B) Loss of upper left second primary molar with space loss approximating 6–8 mm. Note the rotation of first molar in conjunction with more bodily movement.

for space maintenance, it is best to insert an appliance as soon as possible after the extraction.

3. *Stage of development/dental age of the patient:* In general, more space loss is likely to occur if teeth are actively erupting adjacent to the area left by the premature loss of the primary tooth. Significant space loss is most influenced by the stage of eruption of the first permanent molars, with the potential particularly high if a primary molar is lost just before or during eruption of the first permanent molars. The amount of space closure is usually less if the permanent molars are fully erupted into occlusal interdigitation at the time of primary tooth loss. A similar situation exists if the first primary molar has been lost prematurely and the permanent lateral incisor is in an active state of eruption. The eruption of the permanent lateral incisor may result in distal movement of the primary canine and encroachment on space available. This condition is frequently accompanied by a shift in the midline toward the area of the loss. In the mandibular arch, a lingual “collapse” of the anterior segment may occur, with a resulting increased overbite. Another factor is in terms of available abutments for securing a space maintainer at the time of the primary tooth loss. A second primary molar lost at 5 years of age requires different abutment considerations than one lost during

the mixed dentition when first permanent molars have erupted. Also, teeth actively erupting adjacent to the edentulous area have a greater effect on the amount of space lost than do fully erupted teeth. For example, if the first primary molar is lost during the time of active eruption of the first permanent molar, a strong forward force will be exerted on the second primary molar that causes it to tip into the space required for eruption of the first premolar. Changes may extend anteriorly with shift of the dental midline and retrusion of the anterior segment after early loss of a first primary molar.

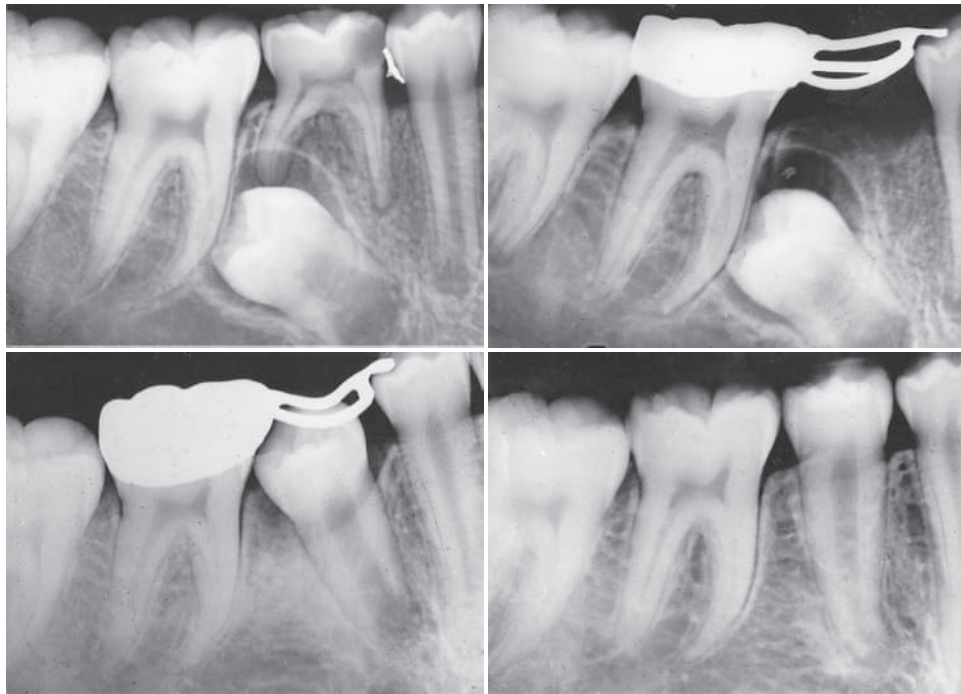
4. *Amount of space closure:* Loss of maxillary second primary molars results in the greatest amount of closure—up to 8 mm of space loss in a quadrant (Fig. 23.4B). Loss of mandibular second primary molars shows the next greatest amount—up to 4 mm in a quadrant (Fig. 23.3A and C). Loss of upper or lower first primary molars shows almost equal amounts of space closure when compared with one another; the amount is most affected by timing of the first primary molar loss (Fig. 23.4A). Space loss potential is particularly high if the primary molar loss occurs in approximation to first permanent molar eruption, irrespective of which primary molar is lost and in which arch the loss occurs. After the first permanent molars have erupted into occlusion, loss of second primary molars may still result in significant space closure. Loss of the first primary molar with retention of the second primary molar shows minimal amounts of space closure because the second primary molar serves to buttress the first permanent molar positions after occlusion is established.
5. *Direction of closure:* Maxillary posterior spaces close predominantly by mesial bodily movement and mesiolingual rotation around the palatal root of the first permanent molars. Only minimal mesial crown tipping of the first molar is usually noted. In contrast, mandibular spaces close primarily by mesial tipping of the first permanent molars, along with distal movement and retroclination of teeth anterior to the space (Fig. 23.3C). Bodily movement of first molars is not typically notable in the lower arch as seen in the upper arch. Lower molars also tend to roll lingually in conjunction with their mesial crown tipping during space loss movements.
6. *Eruption timing of permanent successors:* On evaluating the emergence of permanent teeth, Grøn<sup>16</sup> found that teeth normally erupt when three-fourths of the root is developed, regardless of the child's chronologic age. However, the eruption timing of a permanent successor may be delayed or accelerated after premature loss of a primary tooth depending on the developmental status, bone density of the area, and nature of the primary tooth loss. Very early loss before significant root formation of the permanent successor usually results in delayed eruption timing that may alter normal transitional adjustments in the arch length, arch width, and arch circumference. Several studies have indicated that loss of a primary molar before 7 years of age leads to delayed emergence of the succedaneous tooth, whereas loss after 7 years of age leads to early emergence. The magnitude of any timing change in eruption is affected by age at the time of tooth loss. If a primary molar is lost

at 4 years of age, the emergence of the premolar could be delayed by as much as 1 year, with emergence occurring at root completion. If the loss occurs at 6 years of age, a delay of about 6 months is more likely, with emergence seen when root development approaches completion. Primary tooth loss within 6 to 12 months of normal exfoliation time may result in acceleration in eruption timing of the underlying permanent tooth. Individual permanent teeth are often observed to be delayed in their development and, consequently, in their eruption timing. Impacted permanent teeth or deviations in eruption paths may be reflected in abnormally delayed eruption times. In such cases, it is generally necessary to extract the primary tooth, construct a space maintainer, and allow the permanent tooth to erupt and assume its normal position (Fig. 23.5). The exact timing of permanent tooth eruption is less important in overall occlusal development compared with its greater significance relative to sequencing, site of eruption, and adequate space for subsequent eruption.

7. *Amount of bone covering the nonerupted tooth:* Prediction of eruption based on the timing of primary tooth loss and stage of root development is not reliable if the bone covering the permanent tooth has been destroyed by infection. Emergence is then usually accelerated. If there is bone covering the tooth, it can be predicted that eruption will not readily occur. A guide is that premolars usually require about 4–6 months to move through 1 mm of bone, as measured on bitewing radiographs.
8. *Abnormal oral musculature:* Strong mentalis muscle patterns may have a pronounced negative effect after the loss of mandibular primary molars or canines, with collapse of the arch and the distal drifting of the anterior segment that is often exhibited. Thumb or finger habits may similarly produce abnormal forces in initiating collapse of the dental arches after untimely loss of primary teeth.
9. *Congenital absence of the permanent tooth:* Before space maintenance, the presence of a normal successor must be ensured before space maintenance through radiographic evaluation. Should the succedaneous tooth be congenitally absent or significantly malformed, it is challenging to decide whether to hold the space for many years until a permanent prosthesis can be provided or to allow space closure with the likelihood of orthodontic treatment to achieve proper alignment.

When utilized, a space maintainer must fulfill the fundamental role of preventing untoward mesial migration of buccal segments and lingual collapse of anterior segments in maintaining the mesiodistal dimensions of the prematurely lost primary tooth. The appliance should neither interfere with masticatory function nor inhibit/deflect normal growth changes. It should be simple to construct and maintain; durable, strong, and stable; passive in not imposing pressures on remaining teeth that might affect orthodontic movements; and easily cleanable without enhancing dental caries or soft tissue pathology. Beyond these fundamental roles, space maintainers may be designed to prevent supra-eruption of teeth opposing the space, improve a esthetics, and assist in speech (i.e., anterior space maintainers in control of oral habits).

When a primary tooth is lost prematurely, a space maintainer need not be automatically necessary or desirable.



**Fig. 23.5** Extraction of the second primary molar and space maintenance were indicated because of prolonged retention of the primary tooth and impaction of the second premolar. The second premolar eventually erupted into its normal position.

The decision to place a space maintainer and the choice of design to use are affected by the following: the specific tooth that was lost, from which arch, at what time, whether the permanent successor is present and developing normally, the patient's overall oral health status and motivation, and the status of existing arch length to accommodate the permanent teeth. If analysis indicates a positive arch length or deficiency of less than 1–2 mm per quadrant, a space maintainer may be beneficial in holding tooth positions. If the space is not held, the total arch length may be further decreased and lead to possible premolar extraction requirements. Holding the space may allow the permanent premolars and canines to erupt and utilize leeway space to alleviate anterior crowding. However, if the arch length deficiency is 2–3 mm or more per quadrant, a significant discrepancy exists where space regaining, serial extraction, and/or comprehensive orthodontic treatment may be indicated. If there is no question that permanent teeth will have to be removed to obtain a favorable occlusion, space maintenance may not be desirable because the space would need to be closed during orthodontic treatment anyway. In less obvious extraction cases, holding the space to allow teeth to erupt and prevent impactions can be a valuable service. As related to the premature loss of specific primary teeth, the arch involved, and developmental timing, the following recommendations are made with regard to placement and design of space maintainers.

## SPECIFIC TOOTH LOSS STRATEGIES

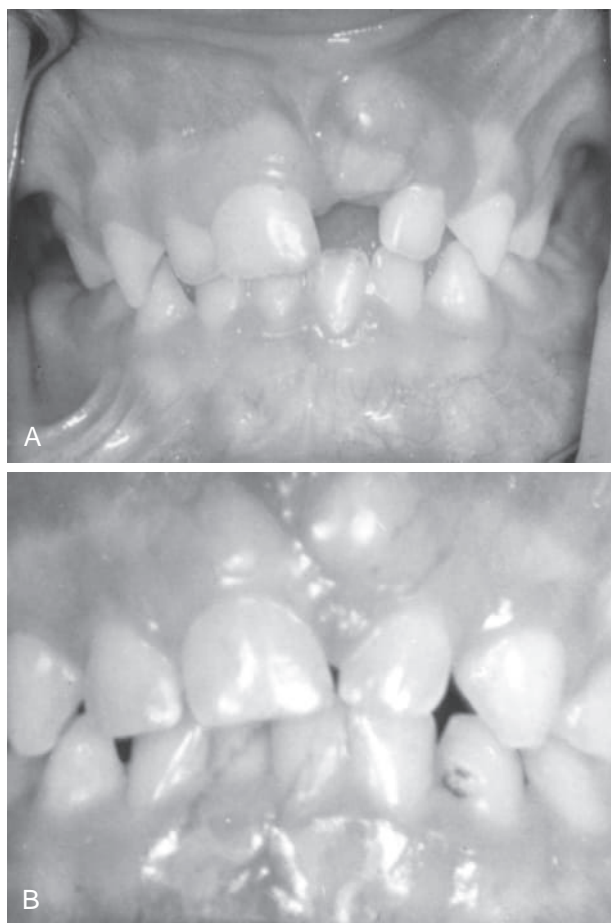
### Loss of Primary Incisors

Early loss of lower primary incisors is generally due to ectopic eruption of the permanent incisors in reflecting excessive incisor liability. Given the potential for increased

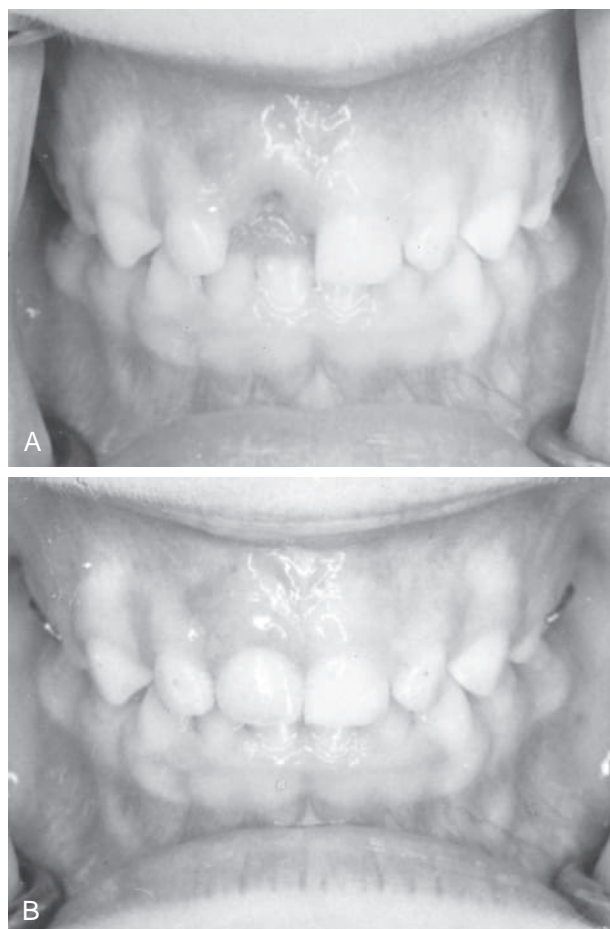
intracanine width during permanent incisor eruption, the clinician should monitor development in the lower incisor area and generally not intervene. Individual circumstances may indicate extraction of the antimere primary incisor to enhance incisor positioning and midline symmetry. The loss of lower incisors in other circumstances, such as trauma, advanced caries, or extraction of a neonatal tooth, may result in anterior space loss if it occurs before primary canine stabilization is realized.

Premature loss of maxillary primary incisors does not generally result in decreased upper intracanine dimensions if the incisor loss occurs after the primary canines have erupted into occlusion at approximately 2 years of age. The support of the mandibular occlusion “holds” the maxillary anterior intracanine width dimensions. Baume type I spaced primary dentitions have significant latitude to resist arch dimensional changes. If the anterior primary teeth were in contact before the loss or there is evidence of an arch length inadequacy in the anterior region, space adjustments in alignment after the loss of one of the primary incisors is a potential factor in space maintenance (Fig. 23.6). The major consequence of early loss of maxillary primary incisors is most likely delayed eruption timing of the permanent successors as reparative bone and dense connective tissue cover the site. In addition, unattractive appearance and potential development of deleterious habits (e.g., tongue-thrust swallow, forward resting posture of the tongue, improper pronunciation of fricative sounds such as “s” and “f”) may be of concern following premature loss of primary maxillary incisors. An anterior appliance incorporating artificial primary teeth may be considered to satisfy aesthetic and functional needs. Acrylic partial dentures have been successful in the replacement of single (Fig. 23.7) and multiple (Fig. 23.8) maxillary primary incisors. Given the demands of cooperation in wear and frequent appliance





**Fig. 23.6** (A) Child with some loss of space in the primary incisor area that was observed at the time of the first examination. (B) Space closure continued and was accompanied by drifting of teeth throughout the anterior area, including the canines.



**Fig. 23.7** (A) This 3½-year-old child has lost a primary incisor as the result of trauma. (B) A removable palatal retainer with a primary central incisor pontic has been constructed to prevent space closure and to restore normal appearance.

loss or damage, such removable appliances can be problematic in preschool-aged children.

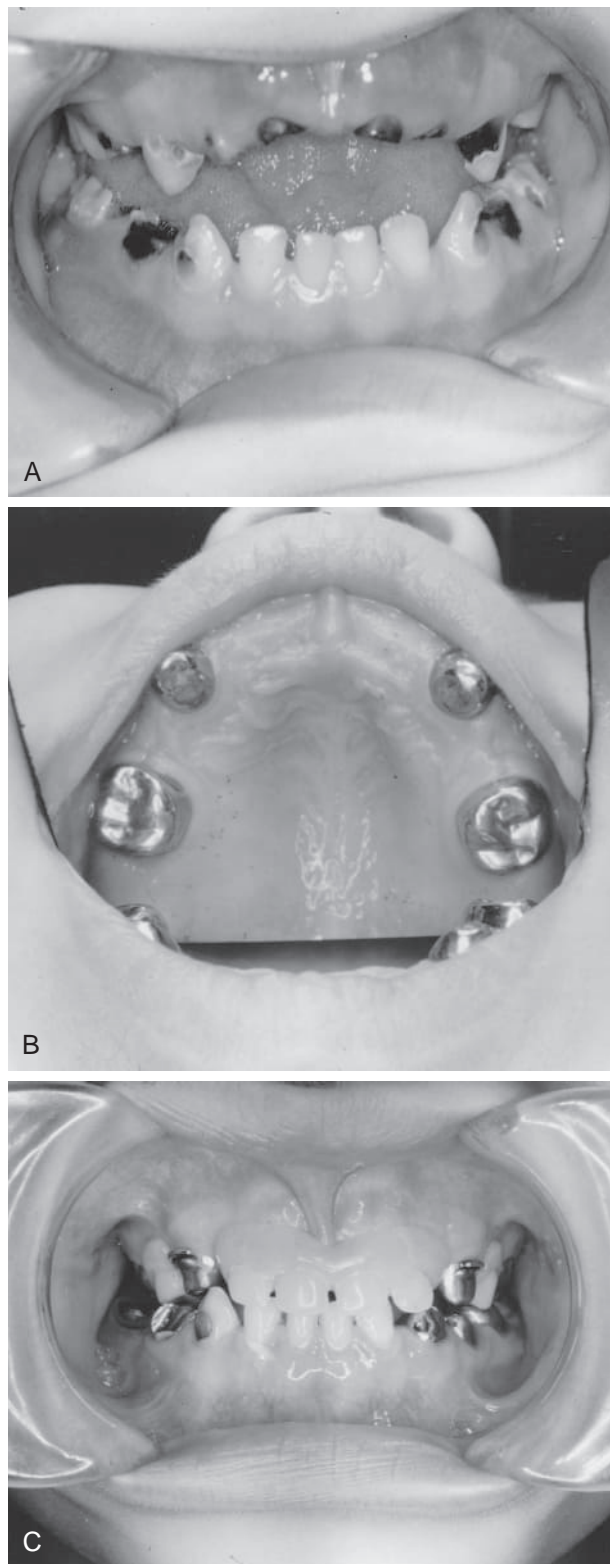
A fixed option using primary incisor denture teeth secured from a rigid stainless-steel wire (0.036 or 0.040 inch) extended to bands or stainless-steel crowns on the primary molars, a so-called “Hollywood” bridge, may be a more predictable option (Fig. 23.9). One can obtain additional stabilization in keeping the wire from flexing by placing an occlusal rest on the first primary molar, using a Nance button, or by covering the ridge with acrylic resin. Use of such an appliance incorporating artificial primary anterior teeth is an option for addressing primarily aesthetic demands rather than specific space or functional management concerns.

### Loss of Primary Canines

Most often due to ectopic eruption of permanent lateral incisors, early loss of a mandibular primary canine is a significant indicator of a tooth size–arch size discrepancy. Unilateral loss of a lower primary canine is frequently followed by a shift in the dental midline toward the side of loss, lingual collapse of the incisor segment, and possibly deepening of the bite (Figs. 23.10A and B). The asymmetric disruption in arch integrity complicates normal eruption of the permanent canines and premolars toward the affected side.

If ectopic eruption involves bilateral loss of both the lower primary canines, pronounced lingual inclination and distal drifting of the permanent incisors, deepening of the overbite, increased overjet, and significant loss of arch perimeter are likely to be the alignment results (Fig. 23.10C and D).

If one primary canine is lost during incisor eruption, it may be desirable to extract the contralateral primary canine to help maintain arch symmetry. Although extraction of the contralateral primary canine may improve the appearance of incisor alignment and midline integrity, crowding problems requiring such intervention strongly indicate a significant arch length deficiency that will likely become grossly evident upon permanent canine and premolar eruption. Some clinicians recommend a lingual holding arch with spur attachments to control incisor positioning and prevent encroachment on permanent canine eruption positions when primary canines are lost prematurely. Even though this may be feasible in some cases, the asymmetric positioning and displacement of the incisors typically contradict simple placement of a lingual holding arch at this stage without first aligning the incisors with active appliance therapy. The inherent questionable prognosis relative to arch length–tooth size considerations brings into question simple appliance therapy at this point in development. Regardless of the individual decision, the prognosis related



**Fig. 23.8** (A) This 4-year-old child required removal of nonrestorable maxillary primary incisors and first primary molars. (B) Stainless-steel crowns were placed on the primary canines and second molars. (C) A maxillary removable partial retainer with incisor pontics maintains space, improves appearance, and reduces the possibility of a tongue thrust.

to ectopic loss of primary canines is generally not good concerning the status of long-range occlusion.

The ectopic loss of maxillary primary canines occurs less frequently than does mandibular loss, given more favorable space adjustments for incisor liability. When it occurs, the ectopic loss of a maxillary primary canine typically reflects a very distal eruptive displacement of the permanent lateral incisor and not necessarily a significant tooth mass problem. Atypical upper anterior alignment may occur, with resultant crowding and blockage of the permanent canine because it erupts so late in normal transition. Early loss of maxillary primary canines is an indicator for early orthodontic treatment with an understanding that the child is a definite candidate for comprehensive orthodontic intervention.

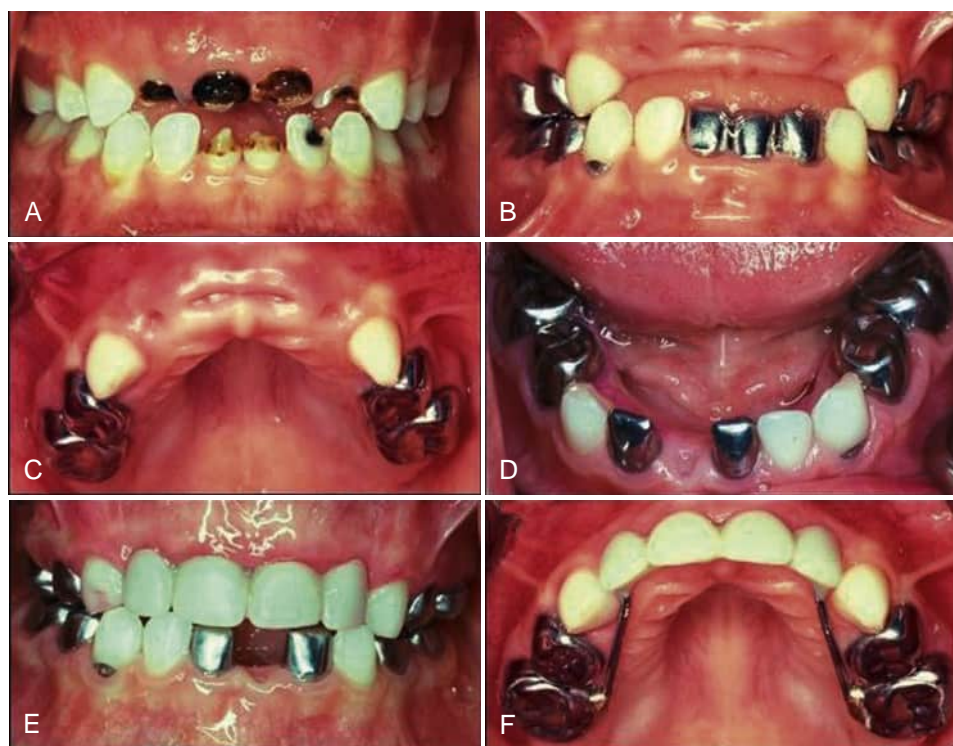
### Loss of First Primary Molars

The effect of premature loss of first primary molars in both arches is mostly dependent on the state of eruption of the first permanent molars. If the primary first molar is lost during the primary dentition from 3 to 5 years of age, there should be little or no space loss associated with mesial movement of the second primary molar. However, as first permanent molars erupt from 5 to 7 years of age, a strong force is exerted that pushes the second primary molar forward into the first primary molar space (Fig. 23.3B). This results in a loss of posterior arch length within the quadrant that can lead to crowding as the canines and premolars erupt in later stages. In addition to posterior effects, the mandibular arch length may be further compromised by distal and lingual shifting of anterior teeth toward the side of first primary molar tooth loss. Therefore the loss of a first primary molar in either arch, approximating eruption of first permanent molars, indicates that the use of a space maintainer is generally desirable to stabilize second primary molar and canine positioning.

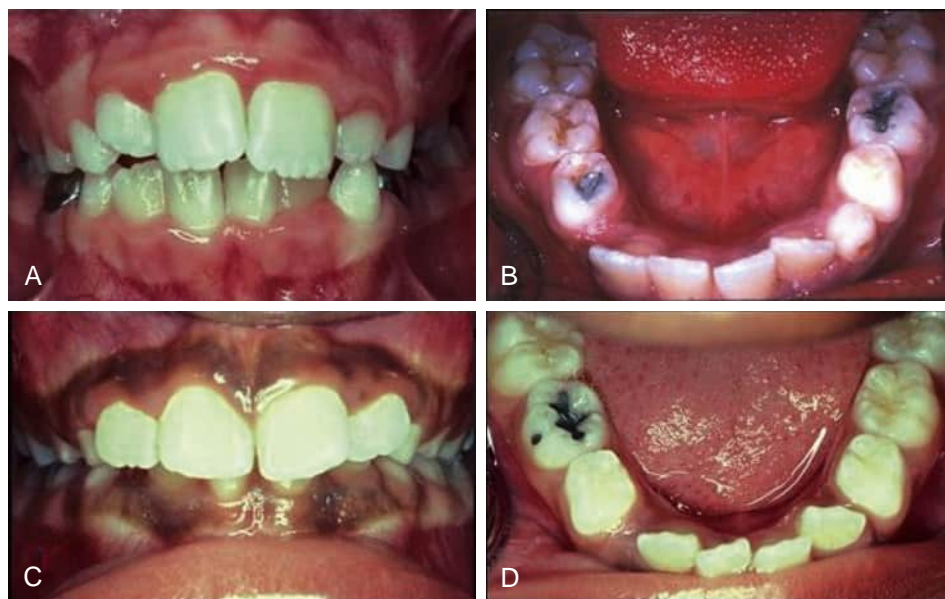
If the first primary molar is lost after first permanent molars have erupted into occlusion and the second primary molar is still in position, minimal space loss should be evidenced in either arch. This is particularly applicable when the first permanent molars are positioned in a full Class I or Class II cuspal interdigitation. If the first permanent molars are in an end-to-end relationship, the location, by arch, of the missing first primary molar may be a factor in potential molar adjustments. If the first primary molar loss occurs in the upper arch, untoward shifting from the end-to-end occlusion may result in Class II molar positioning. To ensure that this does not happen, a space maintainer for the upper arch may be considered. If the first primary molar loss occurs in the lower arch, any molar shift would be in the direction of a Class I relationship. Space maintenance would be less likely unless absolute preservation of leeway space was indicated until permanent canines and premolars erupt.

A unilateral fixed space maintainer called a *band and loop* is usually the appliance of choice for early loss of first primary molars (Video 23.1). The appliance incorporates a band or crown on the second primary molar with a soldered wire-loop extension extending forward to come into contact with the distal-cervical surface of the primary canine in the





**Fig. 23.9** Early loss of maxillary primary incisors in a 4½-year-old child. (A) Pretreatment caries with nonrestorable maxillary primary incisors. (B), (C), and (D) Postrestorative appearance with multiple stainless-steel crowns. While interdigitation should hold anterior intercanine space, the parents and patient requested cosmetic incisor replacement. (E) and (F) A fixed space maintainer with a “Hollywood” bridge fulfills aesthetic demands as an elective treatment. Appliance used one-size-larger crowns fitted over restorative crowns on second primary molars as abutments.

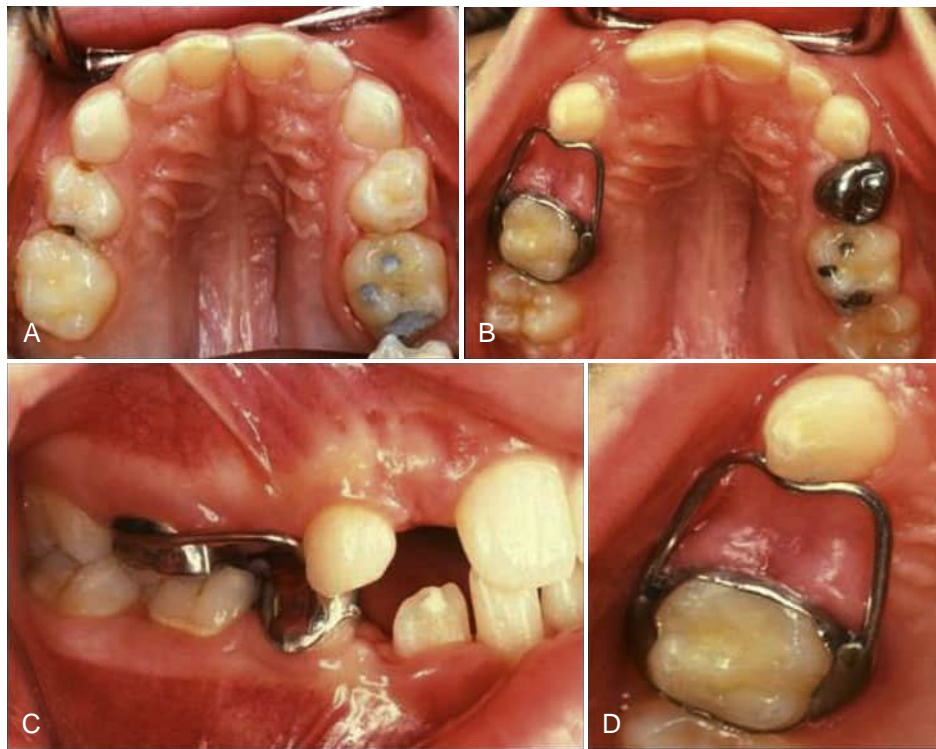


**Fig. 23.10** Ectopic loss of lower primary canines in association with permanent lateral incisor eruption. (A) and (B) Unilateral canine loss results in asymmetric arch dimensions as the incisors shift toward the side of loss and lingualize their positioning. (C) and (D) Bilateral ectopic loss of canines allows for maintenance of arch symmetry, but results in significant lingual retroclination and supraeruption of lower incisors, increased overjet, deepened overbite, and reduction in lower arch dimensions.

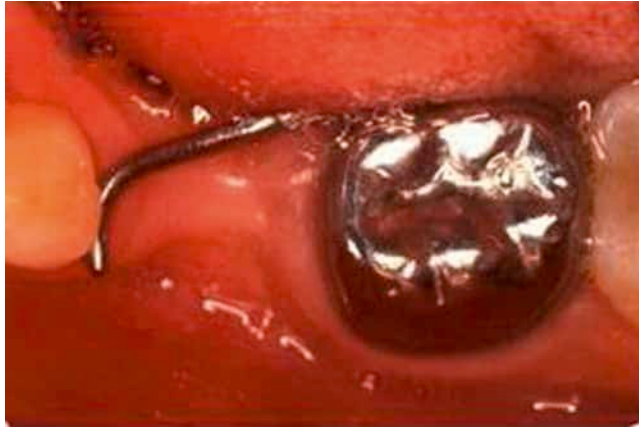
quadrant (Fig. 23.11). The loop uses 0.036- or 0.040-inch stainless-steel wire strong enough to withstand biting forces while ensuring a rigid abutment contact in stopping forward movement of the second primary molar and distal movement of the primary canine. Wire design approximates the gingival contour of the extraction space to avoid occlusal

interference and is wide enough to allow the permanent tooth to erupt. A modification of the design is use of a single-wire extension “arm” rather than a full loop from the posterior abutment to come into contact with the anterior abutment (Fig. 23.12). The single arm of a 0.036- or 0.040-inch stainless-steel wire is rigid enough to hold the space while reducing





**Fig. 23.11** (A) and (B) Pretreatment at 4½ years of age and follow-up at 7 years showing value of properly fitted and designed band-and-loop appliance to hold space for an extracted first primary molar. (C) Buccal occlusion showing proper relationship of erupted first permanent molars. (D) Close-up of design shows that loop is sufficiently large to allow for the eventual eruption of the permanent tooth.



**Fig. 23.12** Close-up of unilateral crown and arm space maintainer.

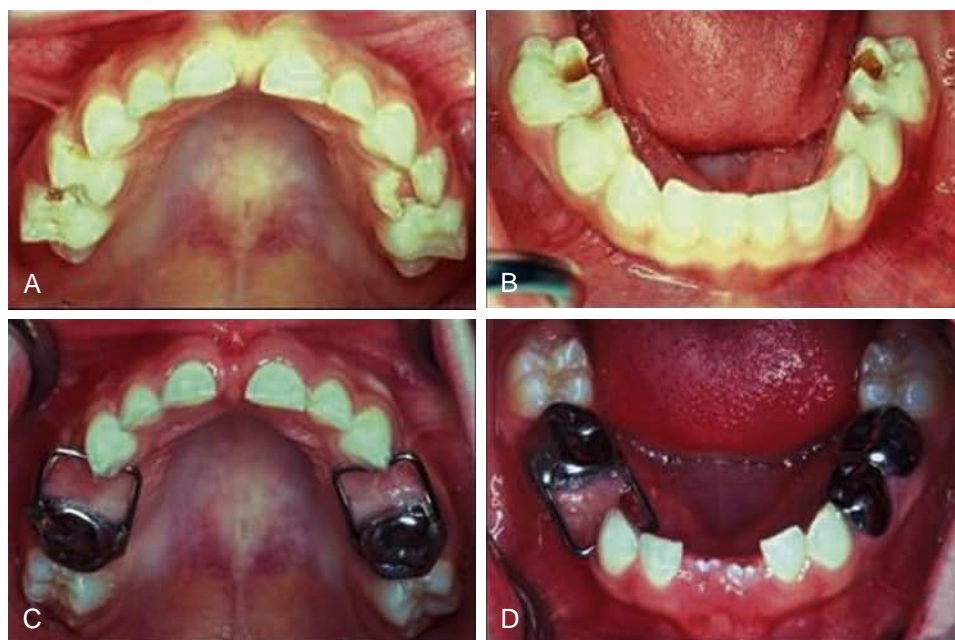by half possible interference with eruption of the underlying tooth. Neither the loop nor the arm design restores chewing function or prevents eruption of opposing teeth, a possible consideration in some cases. Furthermore, the wire may inhibit primary canine distolateral movement as permanent incisors erupt, particularly in association with lower lateral incisor eruption. Therefore, the status of permanent incisor eruption sequencing, symmetry, and positioning should be monitored and guidance steps taken to optimize normal incisor eruption.

**Video 23.1** Space Maintenance: fabrication of immediate band and loop

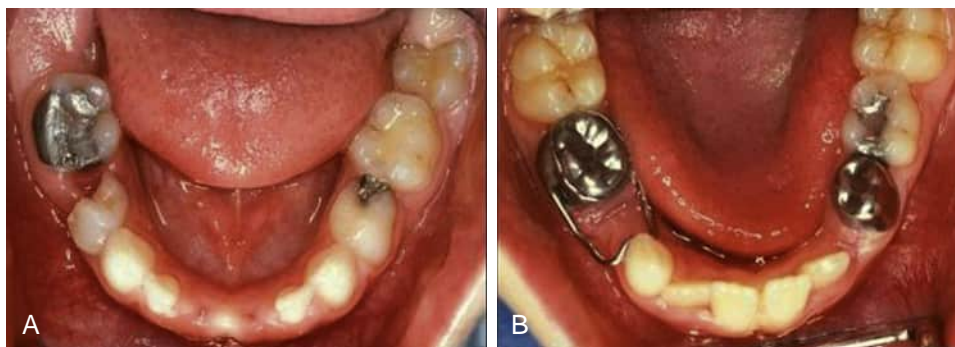
The use of a band as the abutment attachment makes it easy and economical to construct, takes little chair time, and adjusts readily to accommodate the changing

dentition. The use of a stainless-steel crown as the abutment base (Fig. 23.13) offers the advantage of increased stability and retention. A crown is used if the second primary molar has extensive caries or if the tooth has had vital pulp therapy. The steel crown should be prepared as described in Chapter 12: an impression is made, the crown removed from the tooth and seated in the impression, and a working model prepared on which to fabricate the loop. Because it is difficult to remove the crown (converted to a band) to make adjustments, adapting a band or crown one size larger over a cemented crown restoration or constructing a conventional band-and-loop appliance is another alternative to address unilateral space maintenance (Fig. 23.14).

If the first primary molars are lost bilaterally within a lower arch and the second primary molars are retained, two separate unilateral loop appliances are generally indicated until the first permanent molar and incisor eruption is complete. Bilateral lingual holding arch designs should not be placed before eruption of the permanent incisors because the lingual wire may interfere with incisor positioning during eruption. Additionally, primary incisors as anterior stops do not offer sufficient anchorage to prevent loss of arch length in most cases. Either of the loop or arm designs is relatively effective as long as the clinician realizes that the appliances are dependent on abutment teeth that may exfoliate before the need for space maintenance is complete. After the permanent incisors have fully erupted and as the primary canines and molars exfoliate, a second appliance that stabilizes final permanent molar position and arch length may be necessary to prevent subsequent space loss.



**Fig. 23.13** (A) and (B) Pretreatment of upper and lower arches with caries and pulp involvement of primary molars. (C) and (D) Same upper and lower arches with crowns and loops placed for early loss of three first primary molars. Note the erupted first permanent molars with proper positioning.



**Fig. 23.14** (A) Pretreatment of lower arch with caries and pulp involvement of primary molars. (B) Same lower arch with band and loop placed over a restored crown on the second primary molar for early loss of right first primary molars. The band was fabricated from the next-larger-sized crown by removing the occlusal surface and shortening the cervical portion of the crown. Note the erupted first permanent molars with proper positioning.

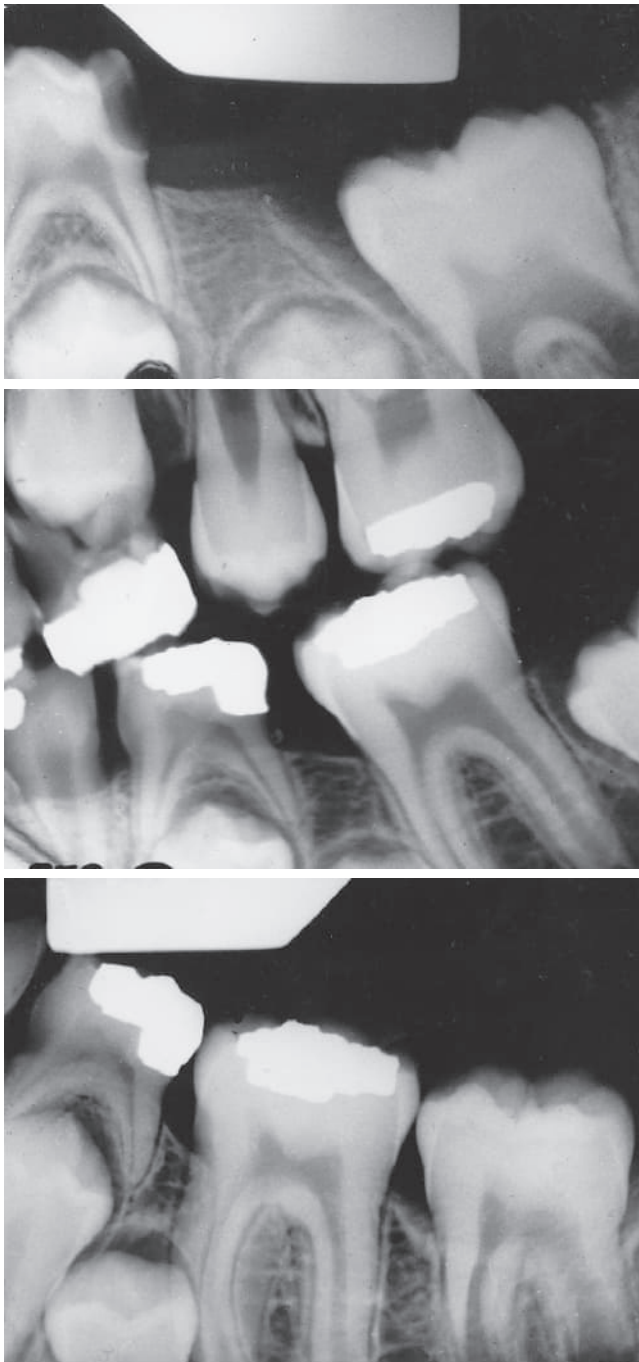
### Loss of Second Primary Molars

If a second primary molar is lost in a child 2–5 years of age, no space loss should occur while the first permanent molar is in the basal bone. The options for managing such early loss are very limited due to lack of retention elements for fixed appliances and difficulties with patient cooperation in the use of appliances at this age. As first permanent molars erupt, however, considerable loss in arch length can occur if no second primary molar is present as an eruptive guide (Fig. 23.15). Space loss of as much as 8 mm in a maxillary quadrant has been documented as the first permanent molar displaces forward through bodily crown-root movement and mesiolingual rotation around the palatal root. Early loss of lower second primary molars in conjunction with first permanent molar eruption timing results in up to 4–6 mm of space loss during transition. The lower first molars move forward by pronounced mesial tipping of the crown, with more modest bodily tooth movement expressed in molar adjustments. Distal movement and retroclination

of teeth anterior to the space are also a likely consequence of early loss in the lower arch. If the loss of the second primary molar occurs after the first permanent molars have fully erupted and normal cuspal interdigitation has been established, the degree of space loss should be less dramatic than earlier during molar transition, regardless of the arch involved. However, mesial movement of the permanent molar through lack of buttressing support from the missing second primary molar usually results in space loss that may be significant. Quadrant space loss of 2–3 mm without the buttressing support of the second primary molar may be realized—easily enough to compromise positioning of the permanent canines and premolars.

Given the findings regarding space loss with second primary molars, a space maintainer is generally indicated in most patients to control permanent molar positions. If the loss occurs just before eruption of the first permanent molar, that is, when the first molar crown is still covered with oral mucosa and a thin partial covering of bone, a space maintainer to guide the positioning of the first permanent molar





**Fig. 23.15** A sequence of three radiographs showing early loss of a lower second primary molar and mesial movement of the first permanent molar before eruption. Eventually there was complete closure of the space needed for the second premolar.

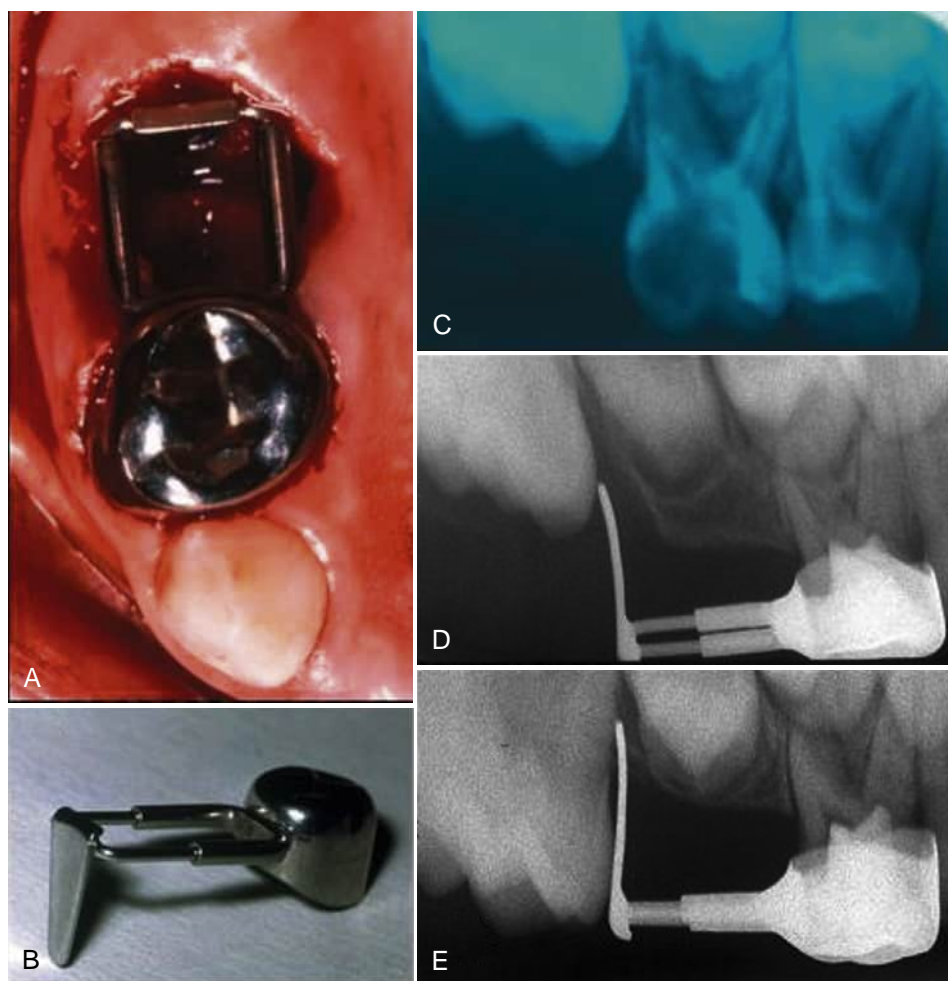
into normal occlusion is desirable. The appliance of choice is a distal shoe for both the maxillary (Fig. 23.16) and mandibular arches. The appliance incorporates a posterior wire-loop extension from the first primary molar that supports a vertical tissue blade positioned to come into contact with and guide the erupting permanent molar into normal position. The depth of the intragingival extension should be about 1.0–1.5 mm beyond the mesial marginal ridge of the molar to “capture” the surface as the tooth erupts vertically. Gauged in length to represent the missing second

molar, accurate placement is critical to ensure that the distal shoe neither extends too far distally over the first molar and block its eruption nor be too short and not maintain the space occupied by the lost second primary molar. It has been observed that the soft tissue tolerates the blade extension well, although a small metallic “tattoo” in the gingiva may result.

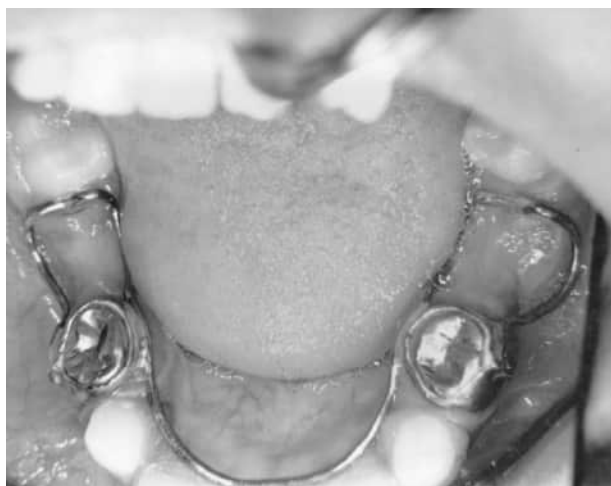
The first primary molar is first prepared with a stainless-steel crown or well-adapted band that provides a retentive base for the distal shoe. An impression is made to prepare a working model. If the primary second molar has not yet been extracted, it is cut off the model and a hole made with a bur that simulates the position of the distal root of the tooth. If the second primary molar has been removed previously, the positioning of the tissue extension may be determined with measurements on bitewing or periapical radiographs or by measurement of the mesiodistal width of the contralateral second molar. The extension blade is contoured and extended distally into the prepared opening on the model, and the loop is soldered to the band or crown. An alternative design is the use of an adjustable Gerber extension involving a trombone-type attachment with the sleeve portion tack welded or soldered to the band or crown (Fig. 23.16). The sliding extension can be positioned into the tube sleeve and the posterior length adjusted to the proper spacing with the blade extension positioned directly into the extraction space or a surgical incision made just at the mesial contact area of the erupting first permanent molar. Crimping of the sleeve tube holds the length of the established extension loop. Ideally, the tack-welded area should be supported with additional solder to reinforce the appliance’s resistance to occlusal forces. Before final placement, a radiograph of the distal shoe in position should be made to determine whether the extension is in proper relationship with the unerupted first permanent molar. Final adjustments in length and contour may be made to ensure that mesial contact of the first permanent molar is provided. In describing chairside fabrication procedures, Brill<sup>16,17</sup> presents the distal shoe as an efficient and cost-effective appliance for guiding the unerupted permanent first molar into position, with success rates relatively equal to those reported from studies of the longevity of other space maintainers.

Several conditions contraindicate the use of distal shoe appliances. Given the extent of caries involvement, there may be lack of abutments to support a cemented appliance. Poor oral hygiene or lack of patient and parental cooperation greatly reduces the possibility of a successful clinical result. Histologic studies show that the distal shoe does not become lined with the epithelium and is associated with a chronic inflammatory response. Therefore certain medical conditions such as blood dyscrasias, immunosuppression, congenital heart defects, history of rheumatic fever, and diabetes contraindicate the use of the appliance. If the distal shoe is contraindicated, two possibilities for treatment exist: (1) allow the tooth to erupt and regain space later, or (2) use a removable or fixed appliance that does not penetrate the tissue but places pressure on the ridge mesial to the unerupted permanent molar (Fig. 23.17). Carroll and Jones<sup>18</sup> reported regarding a pressure-type appliance successfully used to guide the permanent molar as it erupted. Given that the first permanent molars are guided in their eruption by the distal-cervical aspect of the second primary molar, the acrylic or pressure extension usually serves as an ineffective guide for eruptive positioning. The removable





**Fig. 23.16** (A) The second primary molar is nonrestorable and must be extracted. A crown with a distal shoe extension to help guide the first permanent molar has been placed. (B) Picture of a prefabricated crown with Gerber-type distal shoe extension as used in the case. (C), (D), and (E) Progress can be seen on radiographs in guiding the eruption of the permanent molar over 12 months.

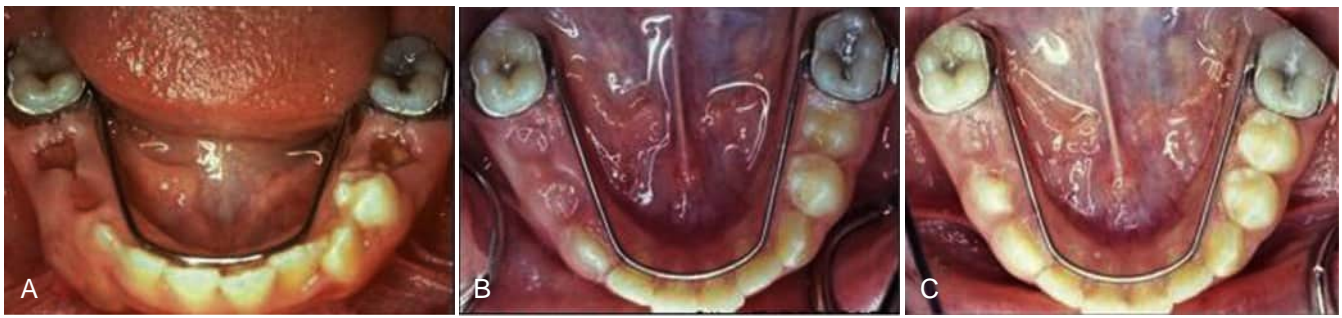

**Fig. 23.17** A modified distal shoe "pressure" appliance to provide bilateral space maintenance and eruption guidance for the first permanent molars. The permanent molars are erupting properly, and the intragingival extensions may be removed.

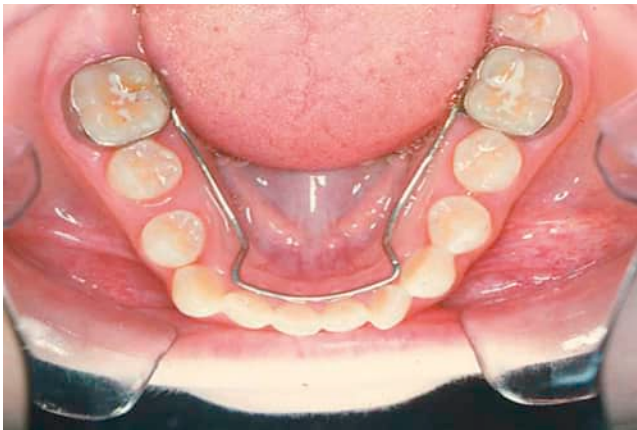extension is more likely to work in the lower arch if the eruption bulge area of the first permanent molar can be engaged with the acrylic. If several teeth are missing, the removable appliance can serve to restore function and prevent supereruption of the opposing teeth.

After the first permanent molar has been guided into position, a distal shoe is usually indicated for replacement with a different appliance. Continued vertical development will usually result in tipping of the permanent first molar over the top of the blade extension, with resulting space loss and tissue complications. One option is to remove the intragingival extension and replace it with a reverse band and loop using an occlusally directed extension to prevent the molar from tipping over the wire. Exfoliation of the first primary molar as an abutment may also occur before eruption of the second premolars. Therefore once the first permanent molars have erupted sufficiently to be banded, a more preferred option for the replacement of a distal shoe is the use of a bilateral space maintainer such as a mandibular lingual holding arch, maxillary transpalatal bar, or maxillary Nance appliance. These same bilateral space maintainers are the method of choice to provide stability to the first permanent molar positions whenever the second primary molars are lost and first permanent molars have erupted into occlusion. Even after first permanent molar occlusion is established, the loss of second primary molars will potentially result in significant amounts of closure without the buttressing effect of the primary second molar.

The classic bilateral mixed dentition space maintainer in the mandibular arch is the soldered lingual holding



**Fig. 23.18** Lingual holding arch for bilateral space maintenance and guidance of buccal segment eruption patterns. (A) Initial appliance placement in conjunction with primary molar extractions. (B) Eruption transition at 6 months after extractions. (C) Eruption status at 1 year. Note the improvement in anterior and buccal segment alignment.



**Fig. 23.19** Proper design of a passive mandibular soldered lingual holding arch positioned with wire contact at the cingulum area of the permanent incisors. The wire offsets and contours to position the wire away from the eruption path of buccal segment teeth and to avoid tongue irritation. Note the excess “leeway” space in the premolar area secondary to the appliance, preventing a late mesial shift of the permanent molars.

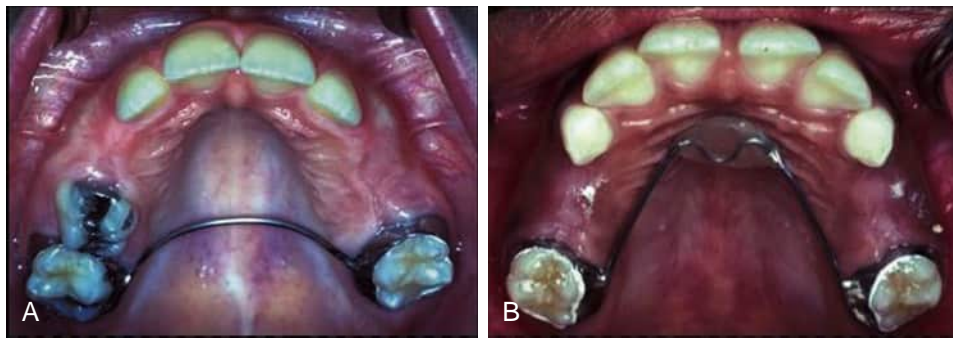
arch (Fig. 23.18). With bands fitted to the first permanent molars, a 0.036- or 0.040-inch stainless-steel wire is contoured to the arch and extended forward to make contact with the cingulum area of the incisors (Fig. 23.19). The design stabilizes lower molar positions from moving mesially and incisor relationships from retroclining lingually in sustaining the canine-premolar segment space (i.e., leeway space). The lingual wire must simply be contoured not to interfere with normal eruption paths and provide an anterior arch form so that the incisors have an opportunity for alignment. In the mixed dentition, the soldered lingual holding arch should present minimal problems with breakage, minimal oral hygiene concerns, minimal interference in eruptive movements of permanent canines and premolars, and no concerns about whether the child is wearing the appliance. Importantly, the bilateral design and use of permanent teeth as abutments allow for application during the full transitional dentition period of the buccal segments. As stated earlier, lower lingual arches should not be placed before the eruption of the permanent incisors because of their frequent lingual eruption path. The lingual wire may interfere with normal incisor positioning if the appliance is in position before lateral incisor eruption. Additionally, abutting against primary incisors as anterior stops

does not offer sufficient anchorage to prevent significant loss of arch length.

Used in the maxillary arch to stabilize molar positions bilaterally, the soldered transpalatal bar incorporates a transverse palatal wire of 0.036- or 0.040-inch stainless-steel wire soldered to molar abutments (Fig. 23.20A). The rigid transverse wire prevents the two main space loss patterns of upper first permanent molars: mesiobuccal rotation and anterior bodily displacement. While the appliance may allow some minor mesial tipping of the upper molars, this is generally considered insignificant in terms of overall space loss in the maxillary arch. The simple transpalatal contour of the connector wire offers the main argument for this appliance: It is easy to fabricate and offers minimal irritation to the palatal tissue or tongue. The Nance appliance uses a contoured rigid wire with an acrylic “button” in contact with the palatal shelf as an anterior stop for bilateral molar stabilization in the maxillary arch (Fig. 23.20B). Providing the same molar rotation and bodily movement control as transpalatal bars, the added bracing of the acrylic button against the anterior palatal vault offers some additional resistance against forward tipping movements of the molars. Although the bilateral stability of the transpalatal appliance appears adequate in most situations, the resistance of the Nance with its acrylic palatal stop is preferred by some clinicians. Tissue irritation beneath the button does not appear to be a clinical problem in most cases if proper hygiene is performed.

The fixed space maintainers as described have the distinct advantage that they are stable, not easily broken, and wear is not dependent on the child. Ensuring that the appliance is passive and does not cause unwanted tooth movement is generally the greatest concern. Proper design should minimize eruption interference and the effects of unfavorable abutment loss or impingement of soft tissues. Poor band fit or defective cement may serve as a locus for debris accumulation and subsequent decalcification. Steps to prevent this include adapting a band that contours tightly to the tooth surface and extends beneath the gingival margins, providing a thorough prophylaxis before cementation, keeping the tooth thoroughly dry during cementation, using glass-ionomer cements, and teaching the child and parent proper oral hygiene practices to include the use of fluoride rinses. Closely checking the appliance at 6-month intervals to monitor potential problems is the standard protocol.





**Fig. 23.20** Bilateral fixed space maintainers for maxillary molar control. (A) Soldered transpalatal bar with 0.036-inch stainless-steel wire contoured to traverse the palatal contour. The appliance prevents forward bodily movement and rotation of molars around palatal roots. (B) Nance appliance incorporates a 0.036-inch stainless-steel wire that traverses the arch with a midline acrylic button positioned against the anterior palatal contour. The design prevents molars from forward bodily movement, rotation around the palatal roots, and mesial tipping.

### Areas of Multiple Primary Molar Loss

Loss of multiple primary molars may lead to mutilation of the developing dentition unless an appliance is constructed to maintain relationships of the remaining teeth and to guide eruption of the developing teeth. In addition to arch dimension concerns, reduced masticatory function is undesirable from a nutritional standpoint. Removable acrylic partial dentures have been used successfully in either arch after the loss of multiple teeth. If artificial teeth are included, an essentially normal degree of function and acceptable aesthetics can be restored. The disadvantages lie in their unpredictability outside the clinician's control because the appliances require patient cooperation and can be easily lost or broken during wear. During the transitional stages of exfoliation and eruption, stability of removable appliances is often difficult to sustain with the loss of abutments. The wire clasps and resin contact areas may present "food traps" for plaque accumulation, with increased potential for soft tissue irritation and dental caries.

If the loss of one or both of the second primary molars occurs a short time before the eruption of the first permanent molars, the acrylic removable appliance may be considered in preference to one of the distal shoe maintainers described previously. An acrylic partial denture with a distal extension may be used to guide the first permanent molars into position (Fig. 23.21). The teeth to be extracted are cut away from the stone cast, and a depression is cut into the stone model to allow for fabrication of the acrylic extension. The acrylic will extend into the alveolus after removal of the primary teeth. The extension may be removed after eruption of the permanent tooth. It is occasionally necessary to recommend extraction of all the primary teeth in a preschool child. Although this was more common in the prefluoridation era, some children even today must have all of their teeth removed because of widespread oral infection and because the teeth are nonrestorable. Preschool children can wear complete dentures successfully before the eruption of permanent teeth (Fig. 23.22).

### Loss of First Permanent Molars

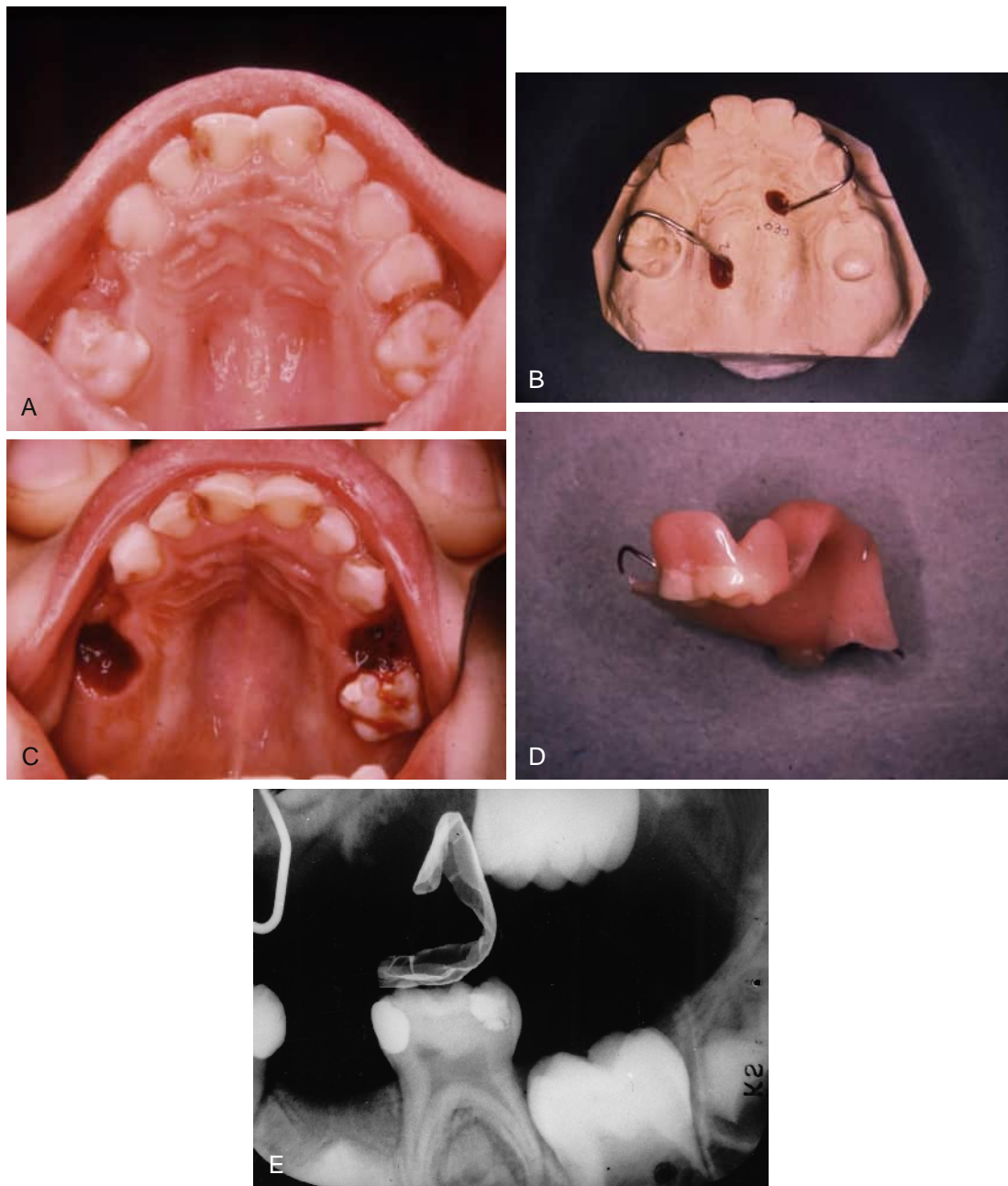
The first permanent molar is unquestionably the most important unit of mastication and is essential in the development of a functionally desirable occlusion. A caries lesion may develop rapidly in the first permanent molar

and occasionally progress from an incipient lesion to a pulp exposure in a 6-month period. The loss of a first permanent molar in a child can lead to changes in the dental arches that can be traced throughout the child's life. Unless appropriate corrective measures are instituted, these changes include diminished local function, drifting of teeth, and continued eruption of opposing teeth.

The second molars, even if unerupted, start to drift mesially after the loss of the first permanent molar. A greater degree of forward bodily movement will occur with loss of the first permanent molar in 8- to 12-year-old children. In older children, if the loss occurs after eruption of the second permanent molar, more exaggerated mesial tipping of the second molar can be the expected outcome. Although the premolars undergo the greatest amount of distal drifting, all the teeth anterior to the space, including the central and lateral incisors on the side where the loss occurred, may show evidence of movement. Contacts open and the premolars, in particular, rotate as they fall distally. There is a tendency for the maxillary premolars to move distally in unison, whereas those in the lower arch may move separately. When the maxillary first permanent molar loses its opponent, it erupts at a faster rate than the adjacent teeth. The alveolar process is also carried along with the molars and causes problems when prosthetic replacements are needed. The treatment of patients with the loss of first permanent molars must be approached on an individual basis. A superimposed existing malocclusion, abnormal musculature, or the presence of deleterious oral habits can affect the result, as in the case of the premature loss of primary molars.

Loss of a first permanent molar before the eruption of the second permanent molar presents problems in both anteroposterior space control and vertical eruption control of opposing molars. Although it is possible to prevent overeruption of a maxillary first permanent molar by placing a lower partial denture, there is no completely effective way to influence the path of eruption of the developing second permanent molar other than the use of an acrylic distal shoe extension on a partial denture as described previously. The second molar drifts mesially before eruption when the first permanent molar has been extracted. Repositioning this tooth orthodontically is possible after its eruption. However, the child must then be considered for prolonged space maintenance until the time when a more





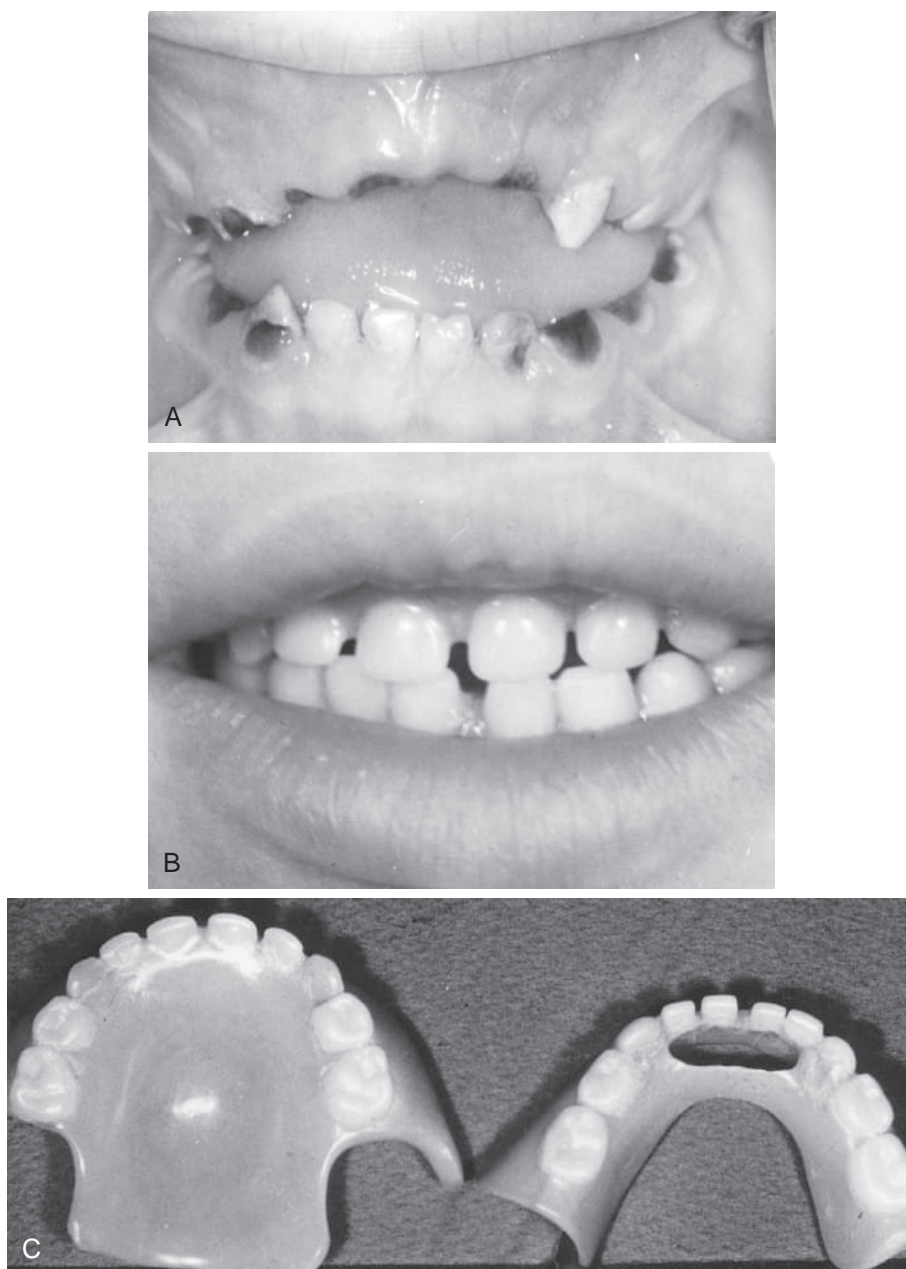
**Fig. 23.21** (A) Clinical and radiographic examination revealed the need for extraction of both maxillary first primary molars and the left second primary molar at 6 years of age. (B) The teeth indicated for extraction are cut away from the stone model, and a depression is made in the second molar area for an acrylic distal shoe-type extension. (C) The primary teeth have been extracted in preparation for the placement of the partial denture. (D) The acrylic distal shoe extension. (E) Lead foil has been placed over the tissue extension to determine, with the aid of a radiograph, whether the acrylic is positioned properly to guide the eruption of the first permanent molar. (Courtesy Dr. Paul E. Starkey.)

permanent tooth replacement can be inserted. The removal of the opposing first permanent molar, even when the tooth appears to be sound and caries-free, is sometimes recommended in preference to allowing it to extrude or to subjecting the child to prolonged space maintenance and eventual fixed replacement.

If the first permanent molars are removed several years before eruption of the second permanent molars, there is an excellent chance that the second molars will erupt in an acceptable position (Fig. 23.23). However, the axial inclination of the second molars, particularly in the lower arch, may be greater than normal.

The decision whether to allow the second molar to drift mesially or to guide it forward in an upright position may be influenced by the presence of a third molar of normal size. If there is a question regarding the favorable development of a third molar on the affected side, repositioning the drifted second molar and holding space for a replacement prosthesis are usually the treatment of choice.

When the first permanent molar is lost after the eruption of the second permanent molar, orthodontic evaluation is indicated, and the following points should be considered: Is the child in need of corrective treatment other than in the first permanent molar area? Should the space be maintained



**Fig. 23.22** (A) Primary teeth with rampant gross caries and pulpal involvement. (B) Complete dentures in place after the extraction of all primary teeth. (C) Modification of the dentures after eruption of the upper first permanent molars and lower permanent incisors.

for replacement prosthesis? Should the second molar be moved forward into the area formerly occupied by the first molar? The latter choice is often the more satisfactory, even though there will be a difference in the number of molars in the opposing arch. A third molar can often be removed to compensate for the difference. Without treatment, the second molar will tip forward within a matter of weeks (Fig. 23.24).

Another option to consider is autotransplantation of a third molar into the first molar position (Fig. 23.25).<sup>19</sup> According to Bauss et al.,<sup>20</sup> autotransplantation has become a well-established treatment modality in cases of early tooth loss or aplasia. For third molars with partly developed roots, transplantation success rates have been reported to range from 74% to 100%.

## Oral Habits in Children

### BRUXISM

Defined as nonfunctional grinding or gnashing of teeth, bruxism has been reported in up to 15% of children and young adults. Usually occurring at night, bruxism can result in significant abrasion of primary and permanent teeth if continued over a prolonged period (Fig. 23.26). A vinyl bite guard that covers occlusal surfaces of all teeth can be worn at night to prevent continued abrasion. The occlusal surface of the bite guard should be flat to avoid occlusal interference. A mouth guard of the type described in Chapter 25 may also help in overcoming the habit. Ramfjord<sup>21</sup> believes that occlusal interference may trigger bruxism if

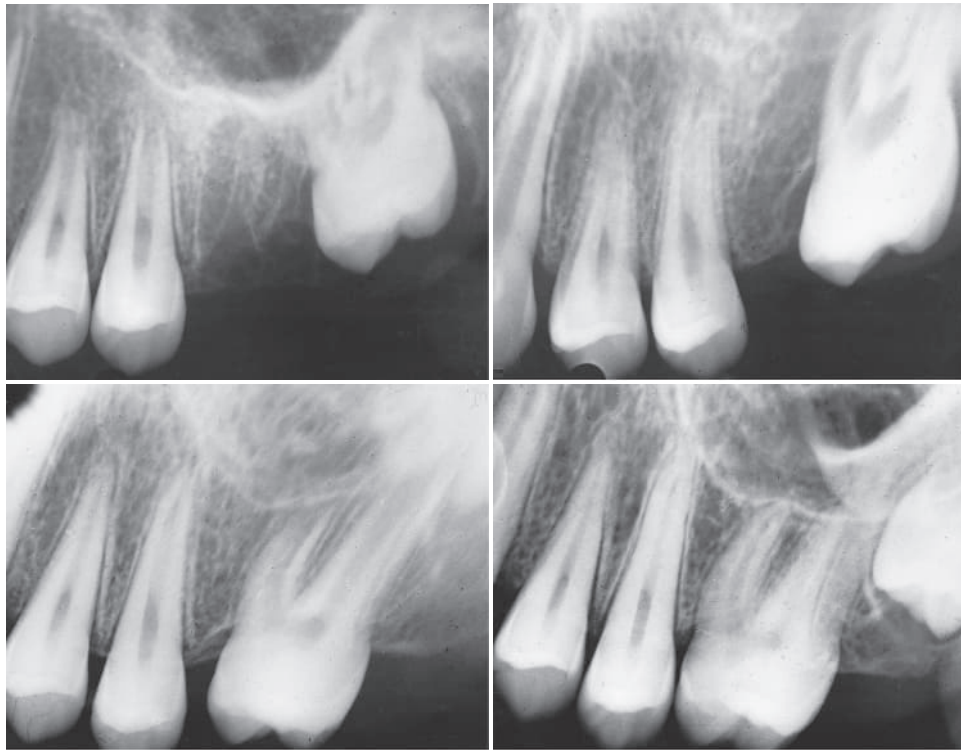


Fig. 23.23 Radiographs taken at 6-month intervals after a maxillary first permanent molar was lost before the eruption of the second permanent molar.

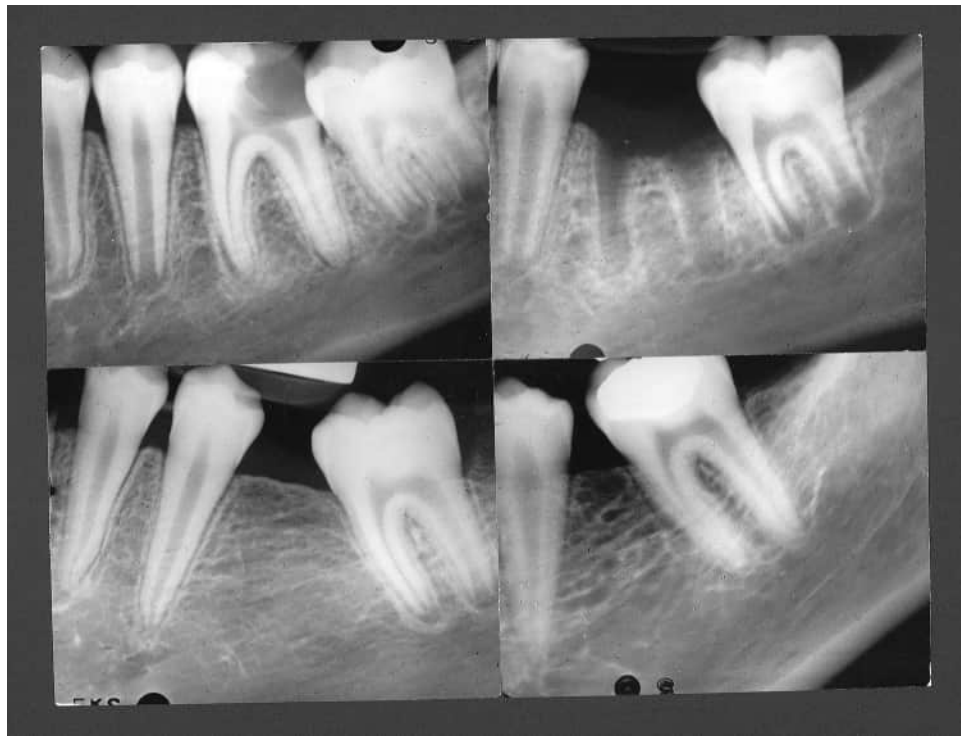

Fig. 23.24 Radiographs taken at 6-month intervals after the loss of a mandibular first permanent molar. Notice the degree of tipping of the second molar and distal drifting of the premolars.



combined with nervous tension. Therefore occlusal equilibration can be used to help the problem if obvious interference is present. Sheppard<sup>22</sup> recommends construction of an anterior bite plate that allows for continued eruption of the posterior teeth if they have been abraded by the habit. When bruxism continues into adulthood, periodontal disease and/or temporomandibular joint disturbances can result. Finally, there is a comorbidity between obstructive sleep apnea (OSA) and nocturnal bruxism, and bruxism is included among the sleep-related movement disorders in the International Classification of Sleep Disorders (see section on Obstructive Sleep Apnea later in this chapter).

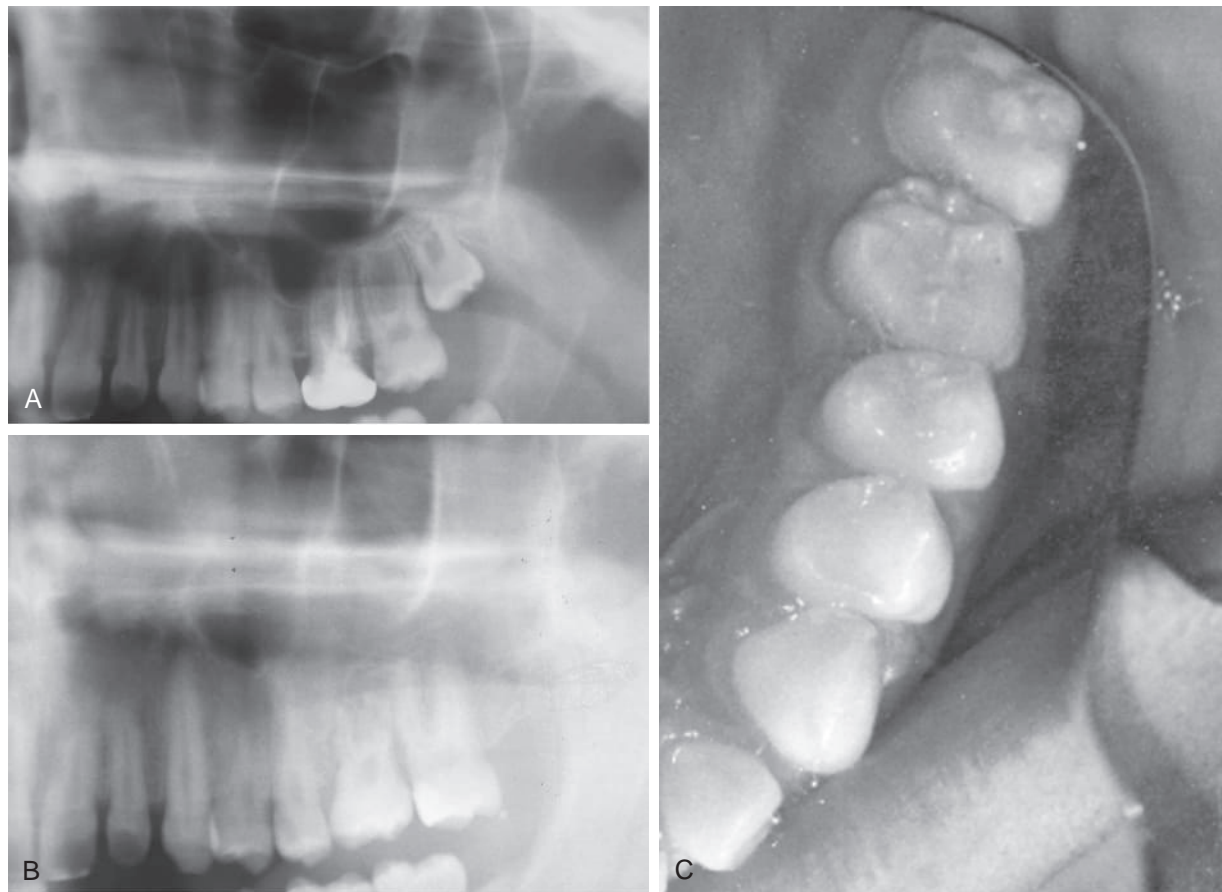### NON-NUTRITIVE SUCKING

Many children suck their thumbs or fingers for short periods during infancy or early childhood, with the habit considered normal during the first 2 years of life. If present at such an early age, parents should be advised to periodically observe the nature and intensity of the habit. If the child demonstrates gradually diminishing activity, it is probable that the habit will cease without intervention. Traisman and Traisman<sup>23</sup> reported that the average age at which digit sucking stopped was 3.8 years, although other studies indicate a persistent incidence of up to 20% at 4 years of age. These studies indicate that changes in the anterior

occlusion caused by digit sucking are temporary, with little likelihood of long-term effects if the habit is discontinued by the age of 3–4 years.

If the intensity of the habit persists or increases and adverse dental and skeletal changes are noted beyond 4 years of age, corrective measures may be needed to avoid undesirable occlusal problems (Fig. 23.27). By the age of 6–7 years, estimates indicate that approximately 10%–15% of children have a persistent digit-sucking habit that runs the gamut from incidental sucking at bedtime to pronounced habits that seems to be almost constant. Almost all authorities recognize that persistent digit-sucking habits extending into the incisor transition period can cause a malocclusion or aggravate an already existing one (Box 23.1).

On evaluating 34 children with digit-sucking habit by cineradiography, Subtelny<sup>24,25</sup> reported that 82% children exhibited tongue-thrust activity during swallowing. Dental findings included protruded maxillary incisors, anterior open bite, and increased maxillary arch length as a result of atypical muscular forces from the thumb, the perioral musculature, and forward positioning of the tongue. The child with a persistent digit-sucking habit that results in an open bite typically exhibits a convex profile with hypotonic upper lip, hypertonic lower lip with marked mentalis muscle activity, and tongue thrusting.



**Fig. 23.25** Third molar autotransplantation. (A) Radiograph showing failed attempt at maintaining first permanent molar and minimal root development of third permanent molar. (B) Radiographic and (C) clinical views of third molar 15 months after autotransplantation. Note the continued root development.

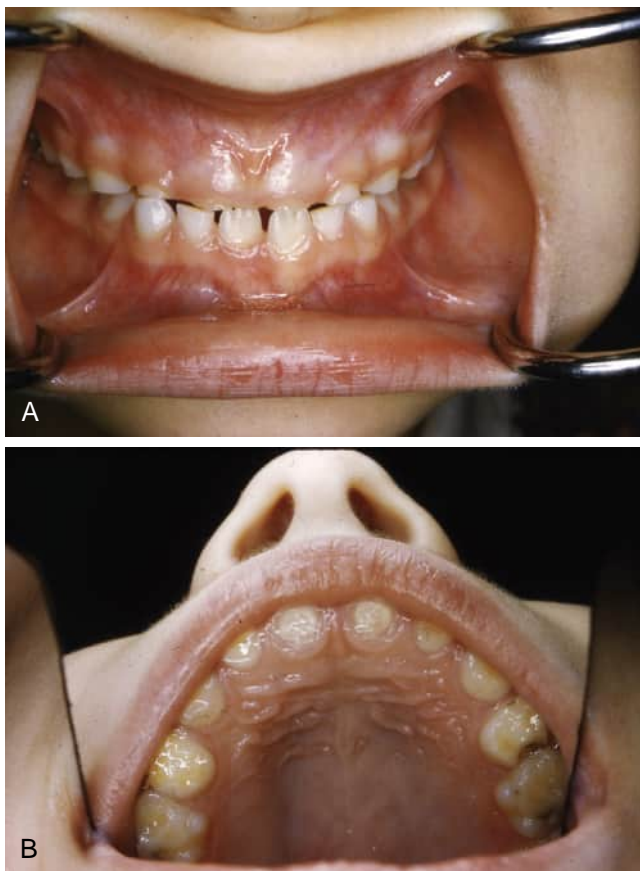


Fig. 23.26 Bruxism resulting in severe abrasion of the maxillary primary anterior teeth. (A) Frontal view. (B) Occlusal view.

The effect of prolonged digit sucking on posterior relationships is less clear. Strong muscle contractions of the circumoral musculature with the highest force levels approximating the maxillary canine area have been documented with extraoral habits. These may result in a relative constriction in maxillary arch width that has been associated with an increased development of functional posterior crossbites in children whose habits persist beyond the age of 4–5 years. While not as profound, associations between distal-step primary molars and Class II permanent molars have been suggested in children whose habits extend into the transitional dentition period. Popovich and Thompson<sup>26</sup> observed 1258 children at the Burlington Growth Centre, representing approximately 90% of the pediatric population of Burlington, Ontario. Many of the children were seen annually from 3 to 12 years of age, with their oral habits and occlusal status recorded at 3, 6, 9, and 12 years of age. There was a significant association between

#### Box 23.1 Occlusal changes secondary to persistent non-nutritive sucking

1. Labial flaring and protrusive spacing of maxillary anterior teeth
2. Lingual inclination of the lower incisors
3. Increased overjet
4. Maxillary alveolar process remodeling and anterior open bite
5. Increased open bite and overjet may lead to tongue protrusion during swallowing as an adaptation to the anterior space
6. Class II malocclusion

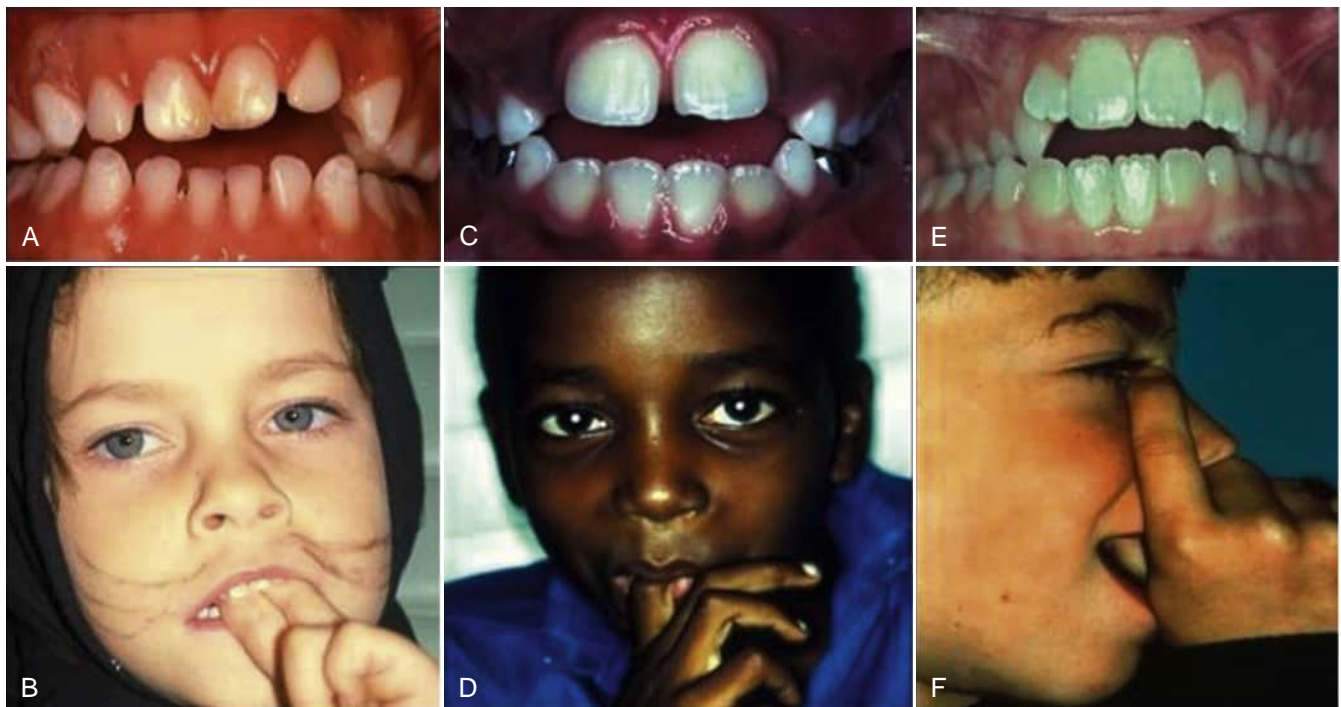
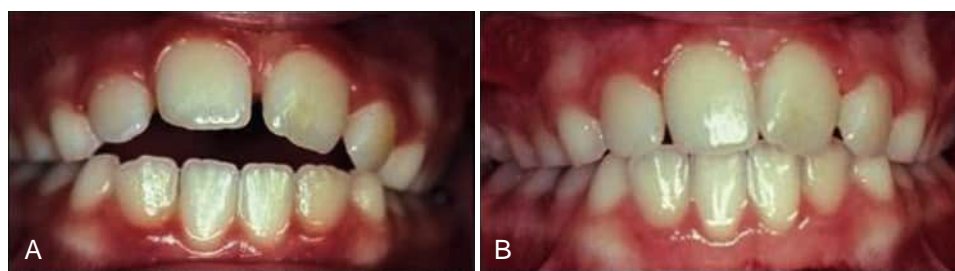

Fig. 23.27 Occlusion of three children with different patterns of digit-sucking habits. (A) and (B) An open bite in the primary dentition caused by the child placing two fingers between the anterior teeth. (C) and (D) An open bite with flared maxillary incisors in the mixed dentition caused by an index finger-sucking habit. (E) and (F) An open bite with maxillary constriction produced by thumb-sucking as presented. The maxillary constriction resulted in a posterior crossbite with a functional shift of the mandible on closure.





**Fig. 23.28** (A) Open bite with some maxillary constriction evident in the mixed dentition of an 8-year-old child with a persistent thumb-sucking habit. (B) The child was encouraged to discontinue the habit through a positive rewards system. There was self-correction of the open bite and transverse relationships by 9 years of age, when the dysfunctional habit was discontinued.

the prevalence of Class II malocclusion and persisting digit sucking in the different age groups. Class II malocclusion increased from 21.5% at 3 and 4 years of age to 41.9% at 12 years of age, and the probability of a Class II malocclusion increased as the duration of the habit increased. If the habit was stopped before 6 years of age, the effects on occlusion were often transitory. In contrast, no child who stopped a habit after 6 years of age had a normal occlusion at 12 years of age. Interestingly, children who used a pacifier had a significantly lower rate of digit sucking. However, del Conte Zardetto et al.<sup>27</sup> pointed out that similar occlusal and myofunctional alterations have been detected among children who have prolonged pacifier habits (either conventional or physiologic pacifiers) compared with those who have no sucking habits. Children who used a pacifier were significantly more likely to show open bite, posterior crossbite, increased overjet, and alteration in cheek mobility than habit-free children.

Interceptive treatments to stop a digit-sucking habit depend upon the patient's age, emotional and psychological state, cooperative motivation of the parents and child, nature of occlusal changes, and associated functional adaptations. An age-based approach provides a foundation for treatment, although individual patient findings may result in a more aggressive approach to intervention or, more likely, may cause greater caution and actually delay or defer treatment. These age-based concepts are as follows:

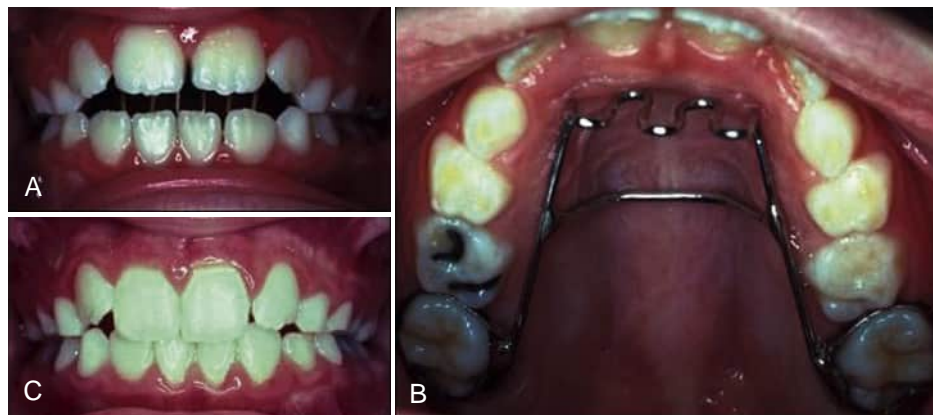
1. *Before 4 years of age:* If one accepts the premise that a digit-sucking habit will usually stop by 4 years of age, and that the effects on the occlusion are probably not permanent, then direct intervention before this age has questionable merit. Additionally, the child's level of understanding complicates cooperation with any of the intervention options.
2. *4–6 years of age:* Psychological ploys and reward systems may help some children to cease digit sucking in this age group. In conversation with the child, the dentist discusses the problem and its effect on the teeth. The parent and child are asked to keep a daily record of episodes of digit sucking and to report on the child's progress in stopping the habit. A decrease in the number of times the habit is practiced is evidence of progress and indicates that the child will likely discontinue the habit. A positive approach involves cooperation of the parents who are often overanxious about the habit. This anxiety may result in nagging or punishment which often creates greater tension and may even intensify the habit.

The parents should consent to disregard the habit and not mention it to the child for a more successful outcome. A timed reward system may also help. For each day the child refrains from the habit for a set period of time, a star is placed on a calendar. In week 1, the child receives some reward or prize predetermined by the parent if the child refrains from non-nutritive sucking for say, 10 minutes. With each day of success during this timed period, the child is praised individually and also through positive comments to family friends and relatives. In week 2, the goal is increased to 20 minutes each period without non-nutritive sucking. In weeks 3 and 4, the time is increased to 30 minutes or longer each day. The prizes are progressively enhanced in value for the child. The goal is positive reinforcement of the child's control over the urge to suck. If the child continues to successfully control the habit for 3 months, the long-term chances of stopping the habit and enhancing occlusal development are good (Fig. 23.28).

Negative reinforcers such as mittens, bandages, and bitter-tasting medicaments applied directly to the offending digit can occasionally affect a stoppage of the habit. Many practitioners have been successful using "thumb guards" that the child wears on the thumb as a reminder not to use the thumb. These approaches meet greater success in children who express a desire to quit and just need a little help—the "reinforcers" are viewed as reminders rather than punishment.

3. *The school-age years:* Although reward techniques may work in some children aged 6 years or older, the persistent habit may be so ingrained as to present unlikely successful stoppage with such ploys. This is the child who has "tried to stop, but just cannot get it done." The transition of the permanent incisors and the ingrained nature of the habit often require direct appliance therapy, not only to stop the habit but also to enhance proper tooth eruption and alignment by influencing any acquired muscular patterns. A palatal crib appliance that prevents the offending digit from being placed in the sucking position and acts to restrain the tongue from forward positioning is a valuable adjunct in habit therapy during the mixed dentition years (Fig. 23.29). Palatal crib designs generally use the first permanent molars as anchorage abutments with a major connecting wire of standard 0.040-inch stainless-steel orthodontic wire, ensuring a strong and stable appliance that is resistant to both digit and tongue pressures. The crib approximates the cross-arch level of the upper canines, with





**Fig. 23.29** Palatal crib appliance in the mixed dentition to help the child stop a thumb-sucking habit, control forward tongue positioning, and allow for eruptive “self-correction” of the anterior open bite. (A) Pretreatment incisor open bite at time of appliance placement. Note crib appliance’s vertical extension to level of lower incisors. (B) Palatal crib appliance of 0.040-inch stainless steel. (C) Posttreatment closure of open bite after 6 months of crib therapy. The habit stopped within 1 week of appliance placement.

the “fence” extending vertically to about the level of and just lingual to the lower incisors. Positioning should ensure no occlusal interference in all functional excursions and allow clearance for upper incisors to lingualize into normal inclinations. The posterior transpalatal wire provides further rigidity and prevents constriction of maxillary intermolar width through pressures placed on the “fence” by the tongue or digit.

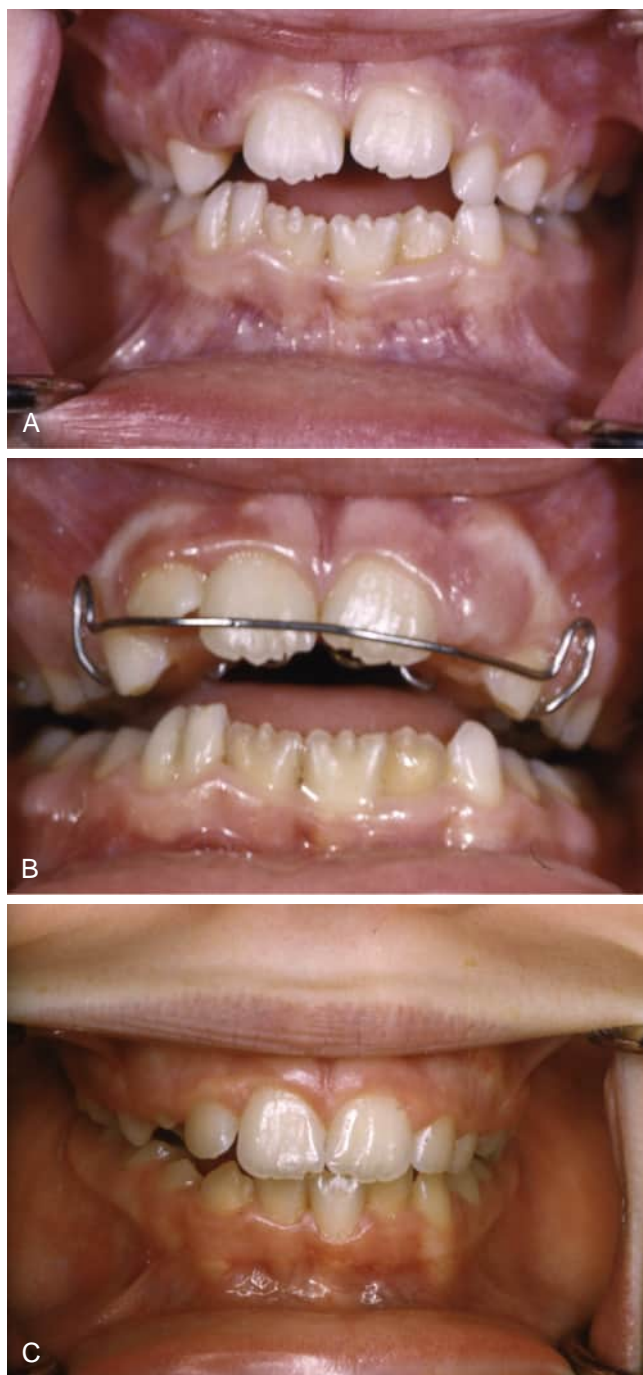
Palatal crib appliances are particularly effective in promoting a favorable environment for self-correction of incisor open bite if applied when incisors are in active eruption phases. Labial flaring of the incisors should be reduced by the action of the upper lip when the digit and the tongue are no longer acting as opposing forces. Most children accommodate to the palatal crib in a short time, and rarely are any problems lasting ones. Haryett et al.<sup>28</sup> reported that, upon insertion of palatal crib appliances, nearly 80% of patients stopped sucking their thumbs within 7 days after insertion of the appliance. They also reported that if the appliance was removed 3 months after insertion, the chance of the habit recurring was likely. The best chance of lasting success occurred when the appliance was left in place for 6–10 months. Therefore it is recommended that treatment planning must include the fixed palatal crib to be worn for a period of 6–8 months.

The child’s cooperation should be obtained when a palatal crib appliance is placed. The function of the appliance is to “help” and to “remind” the patient—the appliance cannot break the habit by itself without the child’s cooperation. Failure to gain at least tacit cooperation will usually result in failure because the child resorts to new habit postures, complains, and causes such a commotion that the parent demands removal or the child even physically removes or distorts the appliance deliberately. Because cooperation and motivation are critical to success, the child should be told that the appliance is being used to help him/her to stop sucking the thumb that has affected the position of the teeth. Some temporary difficulty with speech and eating should also be anticipated upon placement, with most children accommodating in a short time. Some patients present with palatal irritation of the crib at about a month into

appliance wear. This is usually attributable to pressures from the tongue pushing the appliance upward and is more common if second primary molars are used as anchorage abutments. Simple adjustment with intraoral three-pronged pliers can be used to bend the anterior crib away from the tissue. This adjustment is usually necessary only at the initial first-month check because the tongue soon adapts and “reprograms” from forward positioning.

Positive changes in open bite and overjet should be notable by 3 months into treatment, and self-correction should be achieved by 6 months of the appliance protocol. If protrusion of the maxillary incisors and anterior open bite have not “self-corrected” after the habit and tongue thrust are controlled, the discrepancy should be reevaluated to ensure that other problems (e.g., lip sucking) are not factors. In these situations, additional orthodontic treatment may be indicated to align the protruded and flared incisors into normal overbite and overjet positions. Older children in the late mixed or young permanent dentition stage, with more established occlusal relationships, prolonged atypical functional patterns, and less eruptive potential, are less likely to demonstrate self-correction. They usually require corrective orthodontic treatment with Edgewise bracketing techniques.

Variations of the palatal crib, ranging from simple wires contoured to the palate without vertical extensions, to appliances incorporating reminder aspects (e.g., rollers on the Bluegrass appliance, a removable Hawley-type appliance), to the use of “rakes,” “spurs,” or “spikes” extending from the crib wire or bands, have been advocated by various clinicians. A removable partial retainer with a series of smooth loops placed lingual to the incisors has proved successful in helping a child overcome a habit (Fig. 23.30). However, because a child may have a strong physical and emotional urge to continue the habit and not a strong resolve to quit, the use of a removable crib appliance is much less likely to succeed compared with a fixed palatal crib. The Bluegrass appliance (Fig. 23.31) incorporates a modified, six-sided roller constructed to spin around a 0.045-inch stainless-steel wire when rolled by the tongue. Haskell and Mink<sup>29</sup> reported successful stoppage of thumb sucking in children using the appliance with a program of positive reinforcement. The use of rakes and spurs in habit therapy has also



**Fig. 23.30** (A) Anterior open bite caused by a thumb-sucking habit. (B) A Hawley-type reminder appliance was constructed after other problems in the patient's life were recognized and treated. (C) The occlusion 18 months after the child had overcome the habit.

been reported with success; however, Haryett et al.<sup>28</sup> found that 27% of children wearing a “rake” had transitory sleep disturbances compared with only 8% of children wearing a palatal crib. They also found that 14 (21.2%) of 66 children being treated developed mannerisms that persisted even after appliance therapy was discontinued. These included nail biting, chewing of hair or clothing, scratching of the body, and cracking of knuckles, but no enuresis. Thus there was no greater substitution of mannerisms when a habit was treated with an appliance than when a habit was not treated. With no considerable advantages in treatment

effectiveness seen by other designs in the context of early intervention, the basic palatal crib appliance remains the recommended appliance design of choice for treating digit-sucking habits in the transitional dentition.

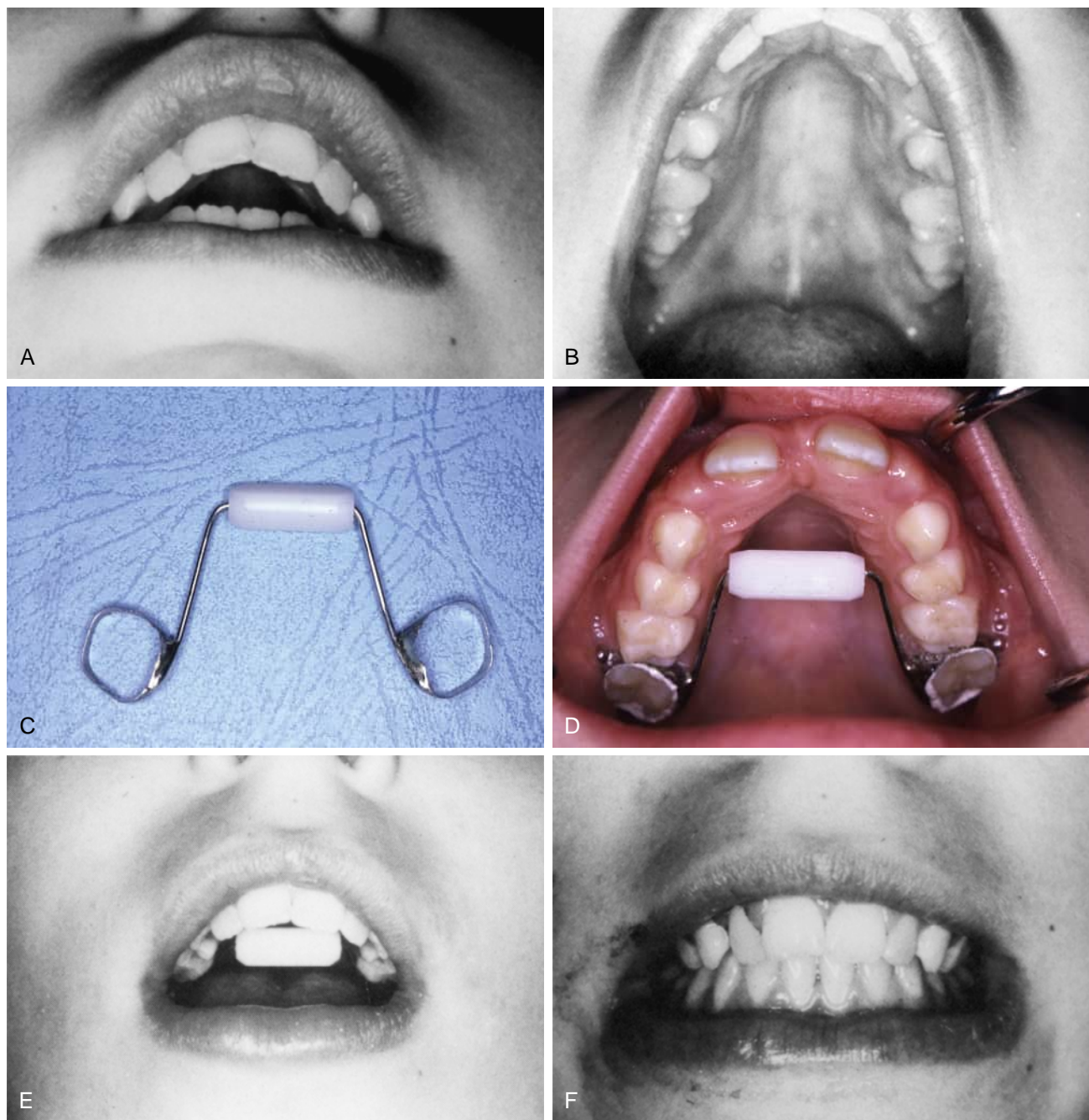
### TONGUE-THRUST SWALLOWING

Three major problems are usually associated with abnormal forward tongue positioning—anterior open bite, protrusion of the incisors, and lisping. Proffit et al.<sup>30</sup> suggest two major reasons for a relatively high prevalence of anterior tongue positioning in children, related to physiology (maturation) and to anatomy (growth). Infants normally position the tongue forward and down in the mouth at rest and during swallowing to help establish an airway for respiration. An infant's swallow is characterized by strong lip activity, placement of the tongue tip against the lower lip, and relaxation of the elevator muscles of the mandible. Physiologic transitions in swallowing patterns begin during the first year of life as teeth erupt and continue over the next several years as oral function matures. There is a gradual activation of the elevator muscles of the mandible in swallowing so that a mature swallowing pattern is characterized by relaxation of the lips, placement of the tongue behind the maxillary incisors, and elevation of the mandible until posterior teeth come into contact in occlusion. This is usually observed before a child is 4 or 5 years of age.

An abnormal swallowing pattern prolonged into the mixed and permanent dentitions is characterized by protrusion of the tongue between the anterior dentition, lack of molar contact, and excessive circumoral muscle activity. Studies have shown the prevalence of tongue thrust to be much greater than the prevalence of anterior open bite. Using cineradiography, Subtelny<sup>24,25</sup> demonstrated that tongue-thrust activity between the incisors with incomplete contact of the molars during swallowing occurs in as many as 40% of adults with clinically acceptable occlusion. Fletcher<sup>31</sup> reported that in 1615 children from ages 6 to 18 years, 52.3% of the 6- and 7-year-old children thrust their tongue. The incidence rates reduced with age; 34% of the 10-year-olds and almost 25% of the 16- to 18-year-olds showed tongue-thrust patterns. Hanson and Cohen<sup>32</sup> found a similar incidence and age distribution of the tongue protruding between the teeth during swallowing. Despite these high numbers for tongue-thrust patterns, random samples of 8000 schoolchildren show an overall open-bite incidence of 5.7% in US schoolchildren. African Americans have a much higher prevalence of an open bite greater than 2 mm than whites (9.6% and 1.4%, respectively). From the data, it becomes obvious that tongue thrust does not necessarily coincide with open-bite malocclusion, and deviations from “normal” swallowing are not necessarily detrimental to the occlusion.

Given the high percentages of tongue thrust in children, the decreasing prevalence in older age groups, and the lack of direct cause-and-effect relationships with open-bite malocclusions, it seems reasonable to conclude that most tongue-thrust patterns are normal transitional occurrences. The adaptation to the more typical adult swallowing pattern appears to be related to an increase in the functional space for tongue activity during adolescent growth changes. The mandible follows skeletal growth patterns that allow space





**Fig. 23.31** (A) and (B) Anterior open bite and palatal configuration in the mixed dentition associated with a thumb-sucking habit. (C) Bluegrass appliance with occlusal view of the appliance in place. (D) Anterior view of the appliance in place. (E) Frontal view of appliance in place. (F) Correction of the anterior open bite. (Courtesy Dr. John R. Mink)

for a downward and backward accommodation of the tongue. Concurrently, the tonsillar and adenoid lymphoid tissue mass is reduced to allow greater oropharyngeal air space. Vertical growth of the dentoalveolar structures of the mandible and maxilla contributes to an increase in the oropharyngeal space that allows the tongue to assume a more posterior position as the child proceeds through puberty.

Transition toward adult swallowing patterns may be affected by a prolonged digit-sucking habit or by a skeletal malocclusion in which anterior open bite or incisor protrusion exists between the dental arches (e.g., Class II division 1). In these individuals, continued functional tongue protrusion during deglutition is viewed as an adaptation that maintains the anterior open bite and is not a primary

etiological factor in causing the open bite. Proffit<sup>33</sup> has shown that there is no “equal balance” of forces on the dentition produced by the tongue versus the lip musculature during functional activity. The expansive forces of the tongue are significantly greater than and not balanced by the containing forces of the lips. The shape of the dental arches and position of the teeth do not appear to be overwhelmingly influenced by the horizontally directed pressures of the lips and tongue during normal functional activities such as swallowing and speaking. Proffit<sup>33</sup> reported that tongue pressures decrease as the size of the arch increases, patients with protruding incisors have fewer lingual tongue pressures than do those with normal occlusion, and when incisors are retracted, the tongue pressures increase to normal



values. These findings are the reverse of what would be expected if tongue pressure had pushed the teeth into protruded positions. However, stronger relationships with the patient's arch form and the resting pressures of the tongue and lips have been found. An anteriorly positioned tongue "at rest" can impede vertical eruption of the teeth and result in an open bite. This may be reflected in the findings that most habit-related open bites are self-correcting when digit sucking is eliminated and tongue positioning is controlled.

The controversy concerning tongue-thrust swallowing extends into treatment approaches that include palatal crib-type appliances, full orthodontic therapy, myofunctional therapy, or combinations of the above. The occurrence of an open bite is often initially related to a thumb- or finger-sucking habit and then retained by the tongue being thrust forward or the tongue merely occupying the space. In appliance therapy for digit-sucking habits, a vertical crib "fence" helps modify forward tongue positioning associated with the anterior open bite. With stoppage of the habit, the tongue assumes more normal swallowing patterns as muscular functions reflect adaptation to the corrected anterior open bite. But what about the child who presents with an anterior open bite and does not have a history of a digit-sucking habit? Will this child benefit from a palatal crib appliance to restrain the tongue? Or should other approaches be taken in managing the open bite? The answer lies in understanding our previous discussion on normal swallowing patterns and the implications of tongue thrust to occlusion. In the school-aged child without a documented digit-sucking habit, palatal crib therapy directed specifically toward tongue-thrust swallowing as a "causative" factor seems questionable. This is based on the reasoning that, without a documented extraoral habit, the most likely causative factors would be either a significant airway obstruction with habitual mouth breathing or a skeletal open-bite pattern. Both of these situations require a much more comprehensive approach than simple interceptive appliance therapy. In fact, placement of a tongue-restricting palatal crib appliance could exacerbate airway problems by forcing the child to keep the mandible open to accommodate the appliance. The palatal crib design could actually make things worse. The same applies to a skeletal open bite with the usual implications of a vertical growth pattern. Moreover, the variability of normal swallowing patterns in relation to malocclusion, coupled with the spontaneous improvement in tongue-thrusting patterns and anterior open bite that is evidenced in 80% of children by the age of 12 years, argues against tongue thrust-directed therapy as a stand-alone treatment for open bite.

Myofunctional therapy is the conscious retraining of the tongue and strengthening of the lip muscles through a specially designed exercise program. Promoted with the expectation that training muscles to function properly will reduce abnormal pressures, successive steps in the training program include acquainting the patient with the abnormal swallowing pattern, teaching the correct pattern of swallowing using various exercises, and reinforcing the correct patterns. While all are admirable goals, myofunctional therapy remains controversial. Koletsi et al.<sup>34</sup> conducted a systematic review and meta-analysis regarding the effect of orthodontic management and oral facial muscle training protocols on the correction of myofunctional and myoskeletal problems in developing dentitions. Of the 265 initial search articles, 15 were included in the review, 8 were randomized controlled trials, and 7 were

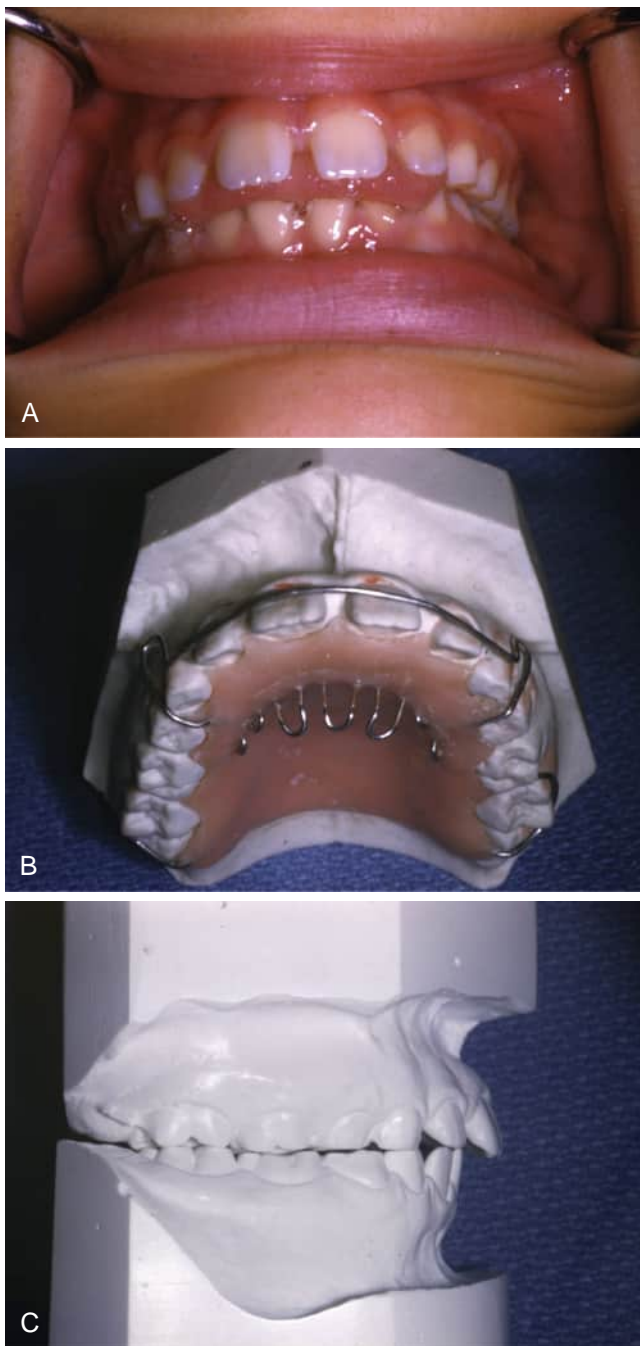
controlled clinical trials. Only two of the included randomized controlled trials allowed for quantitative synthesis. The authors concluded that although early orthodontic management and myofunctional treatment in the primary and mixed dentition appears to be a promising approach, the quality of the existing evidence is questionable.<sup>34</sup>

Regardless, training exercises involve proper tongue tip placement against the roof of the mouth and not between the teeth, masseter muscle isometrics to ensure swallowing with the molar teeth in contact, and lip exercises to correct mentalis and facial muscle activities. One technique requires the patient to practice swallowing correctly 20 times before each meal. Holding a glass of water in one hand and facing a mirror, the child takes a sip of water, closes the teeth into occlusion, places the tip of the tongue against the incisive papilla, and swallows. This is repeated, followed each time by the relaxation of the muscles until the swallowing progresses smoothly. The use of a sugarless mint may also help in muscle training. The child is instructed to use the tip of the tongue to hold a mint against the roof of the mouth until it melts. As the mint is held, saliva flows and makes it necessary for the child to swallow. Treatments are usually programmed to take 7–10 weeks of exercises until the oral environment is stabilized. Most therapists prefer to wait until the child is about 9 years of age before beginning treatment because normal developmental changes occurring around this same time allow for more favorable positioning of the tongue. After the patient has trained the tongue and muscles to function properly during swallowing, an acrylic palatal retainer with a "fence" may be constructed as a reminder to position the tongue properly during swallowing (Fig. 23.32).

In patients with tongue-thrust swallowing and a speech problem, referral to a speech therapist is the most appropriate course of action. If a malocclusion is also present, the coordinated use of myofunctional therapy by the speech therapist and orthodontic treatment may be undertaken to take advantage of each service. Generally, any therapy aimed at altering the tongue positions during swallowing and speech should be done in conjunction with or after the orthodontic treatment rather than preceding it. If mouth-breathing postures are identified with clinical symptoms of airway blockage, the dentist should refer the child to an otolaryngologist for appropriate medical consideration. Patients who are obligate mouth breathers secondary to hypertrophic adenoid tissue or allergic conditions can have corresponding poor postural relationships that can influence the developing skeletal face. With proper diagnosis and management, the airway interference may be reduced or eliminated to influence occlusal development and orofacial musculature in a positive direction. In patients with tongue thrust alone and no malocclusion, speech, or airway problems, there is no reason to recommend any interceptive orthodontic treatment.

## Anterior Crossbite in Primary and Mixed Dentitions

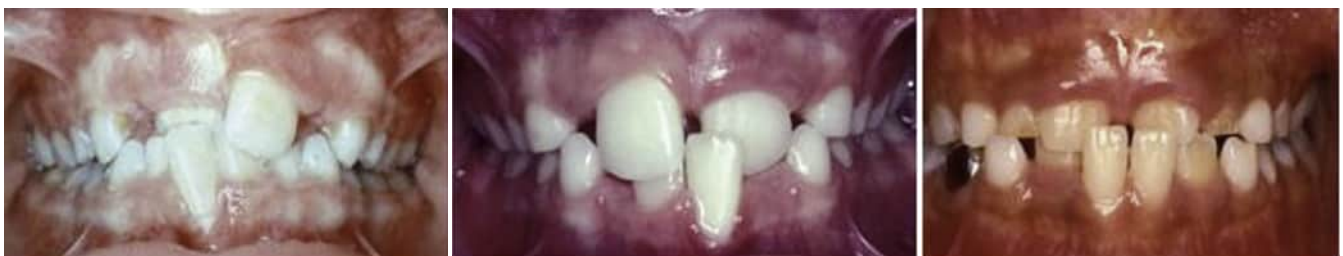Dentoalveolar anterior crossbite represents a linguoversion of one or more maxillary anterior teeth with resultant "locking" behind the opposing mandibular teeth in full closure (Fig. 23.33). The anterior crossbite is usually an acquired malocclusion resulting from local etiological factors (e.g.,



**Fig. 23.32** (A) Anterior open bite resulting from a tongue-thrust swallowing pattern. (B) A removable retainer with a crib like component helped “retrain” the tongue from being thrust forward during the swallowing process. (C) The tongue-thrust pattern has been overcome and the occlusion is greatly improved.

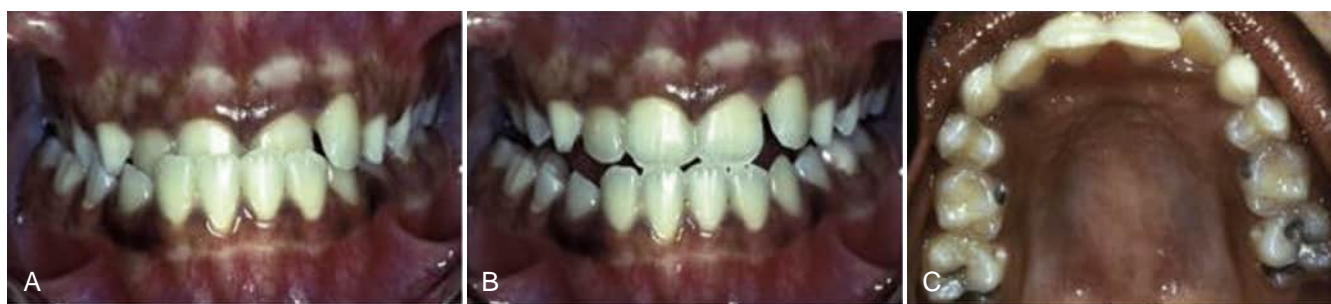arch crowding) that interfere with the normal eruptive positioning of the maxillary anterior teeth. In some cases during closure movements, premature contacts due to the lingual malpositioning may result in a forward mandibular deviation to effect full closure that “locks” the anterior segment in a crossbite posture involving multiple teeth. Such an acquired muscular pattern is referred to as a pseudo-Class III malocclusion as the mandible shifts from Class I to Class III relationships during closure (Fig. 23.34). In most cases, localized dentoalveolar anterior crossbites with or without mandibular displacement should be treated as soon as they are discovered. Delayed treatment can lead to serious complications such as loss of arch dimensions and asymmetric midlines, traumatic occlusion with stripping of gingival tissue on the labial aspect of the lower tooth, wear facets on involved incisors, and untoward growth patterns if a functional shift is involved. Importantly, at later developmental stages, not only does differential diagnosis become more difficult, but also the mechanics for correction become more complex with less predictable results. Simple appliance designs are usually adequate to achieve correction of dentoalveolar anterior crossbites. Diagnoses should be made with consideration of the following clinical findings.

1. *Number of teeth involved:* Involvement of one or two incisors usually represents a dental crossbite, although the chance of functional displacement is increased as more teeth are involved. Suspicion of a skeletal malocclusion grows in proportion to the number of teeth in crossbite.
2. *Inclinations of maxillary and mandibular incisors:* Dentoalveolar and functional crossbites usually exhibit lingual labioversion of the maxillary incisors and normal to slight labioversion of the lower incisors in response to incisal interference. In a true skeletal Class III malocclusion, lower incisors are retroclined, whereas maxillary incisors usually exhibit normal to proclined inclinations.
3. *Mandibular closure pattern and facial profile:* In a dentoalveolar crossbite, the facial profile and buccal occlusion should present a neutroclusion at rest, first contact, and full closure, with the soft tissues masking the dental malpositioning. Any displacement of the mandible should be observable because a shift from neutroclusion to Class III buccal patterns “worsens” a normative profile at rest to an apparent prognathism in full closure. If the child can readily bite to an edge-to-edge incisor position without directed jaw manipulation, evidence of a forward shift of the mandible is confirmed. A Class III skeletal malocclusion should close in a smooth pattern without anteroposterior disruption. A mesioclusion of molar positioning and prognathism of the profile should persist at all times.



**Fig. 23.33** Examples of dentoalveolar anterior crossbites with lingually locked maxillary central incisors. The malpositioning with traumatic occlusion results in forward displacement of the lower incisor and stripping of the gingival tissues.





**Fig. 23.34** Lingually displaced central incisors may produce occlusal interference on closure that results in a functional anterior shift of the mandible (pseudo-Class III malocclusion). (A) Maximum intercuspation after anterior shift of mandible. (B) First contact with edge-to-edge incisor interference. (C) Maxillary incisors malpositioned lingual to arch form.

**TABLE 23.1** Anterior Crossbite Correction Methods: Pros (+) and Cons (–)

	Cost	Compliance	Fabrication Ease	Practitioner Control	Effectiveness	Efficiency
Tongue Blade	++	--	++	--	-	++
Inclined Guideplane	+	-	-	+	-	+
Removable Spring	-	-	--	-	+	+
Fixed Spring	-	++	--	++	++	++
Anterior Brackets (2" × 6")	--	++	-	+	++	++

4. *Familial appearance*: If similar dentofacial conditions exist, the probability increases that the case involves a skeletal problem that is genetic in origin rather than a localized malocclusion.
5. *Cephalometric analysis*: Assessment of lateral cephalograms can usually confirm impressions of the clinical examination (see [Chapter 22](#)). Realizing that anterior displacement may demonstrate cephalometric measurements indicating mandibular prognathism when the cephalogram is obtained in full occlusion, the clinician should analyze centric relation cephalograms or overlay analysis of rest position and full occlusal tracings to determine true skeletal relationships. The inclination patterns of the upper and lower incisors are key factors in this assessment.

Diagnosed in the transitional dentition, dentoalveolar anterior crossbites with or without mandibular displacement are usually approached from the viewpoint that the primary discrepancy involves one or more maxillary anterior teeth in linguoversion. Any labial inclination of lower incisors is in response to the upper malpositioning. This simplifies treatment in that correction is directed toward labial movement of displaced maxillary incisors to “jump” the bite. After normal maxillary incisor positions are achieved, the proclination of lower incisors is usually self-correcting with the establishment of normal overbite and overjet. Studies have shown that gingival recession in the lower anterior segment improves spontaneously after crossbite correction. In most cases, removal of the traumatic occlusion allows normal attachment levels to be sustained without the need for specific periodontal treatment procedures. If it can be assumed that local etiologic factors such as over-retained primary incisors have been eliminated, one of several treatment methods may be selected. This is done after an evaluation of biomechanical decision factors such as the following:

1. *Incisor positioning and available space*: If space is available, options can be directed toward simple labially directed

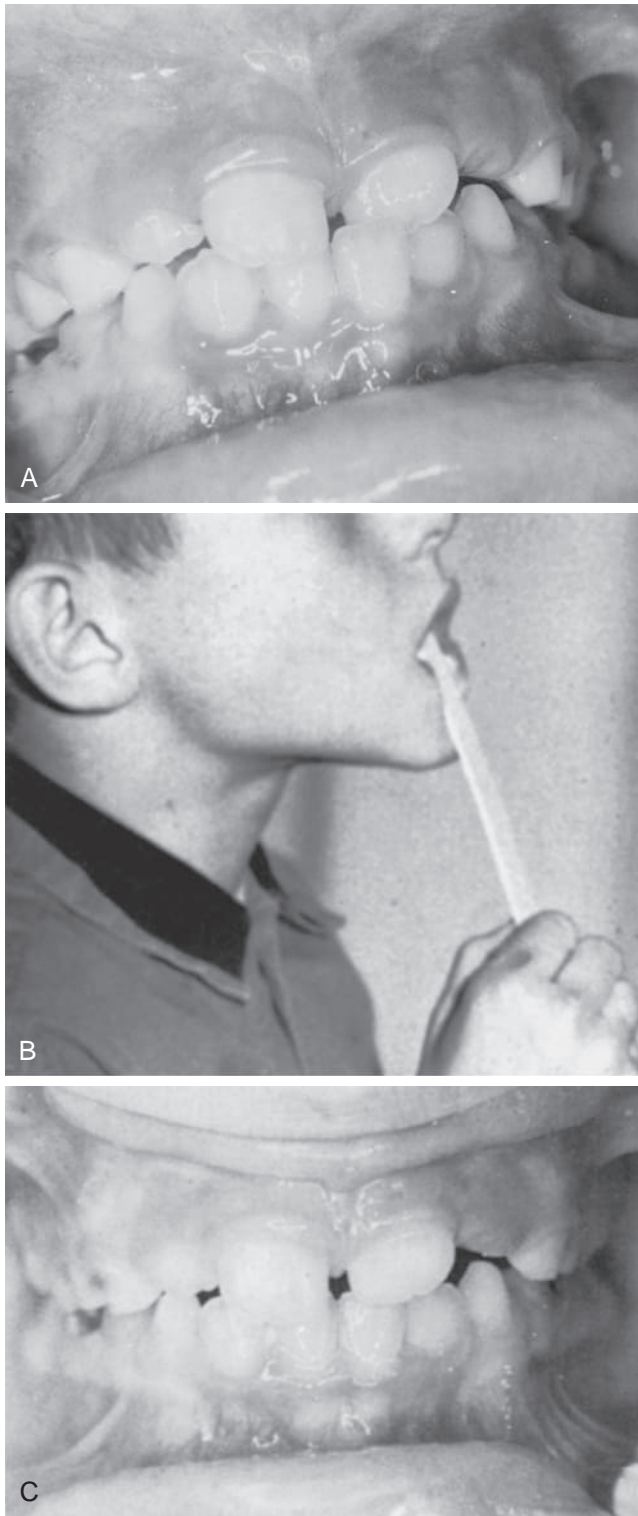
- tipping movements of the involved maxillary incisors. This particularly applies if the root of the lingual tooth is in the same relative position as it would occupy in normal occlusion. If space is not available or with greater bodily tooth displacement, Edgewise appliances may be required to create space and provide controlled orthodontic movements.
2. *Stage of eruption*: If the displaced maxillary incisor is in active eruption, the treatment may use simple leveraging techniques to redirect the tooth forward into acceptable position. If the tooth is fully erupted, the forces of occlusion will usually not allow simple leveraging of eruption paths. Directed forces to effect labial repositioning of the involved maxillary anterior teeth will be required.
3. *Degree of overbite*: During treatment, occlusal bite planes are often proposed to remove overbite interference during labial movement. Whereas this is desirable in the use of removable appliances and those incorporating labial bracketing of involved teeth, the 3- to 4-mm freeway space at rest position and the use of directed lingual applied forces from fixed appliances negate the need for bite opening to achieve successful labial movement in most clinical situations. The overbite has greater impact on retention; positive overbite will maintain positioning of the incisors once corrected.

In addition to these factors, cooperation of the patient and parent and personal preference of the clinician are considerations in treatment mechanics. Treatment approaches are of two general types: (1) passive incisal guides that, during mandibular closure, redirect or “leverage” maxillary anterior inclinations in a labial orientation; and (2) active appliances that use directed orthodontic forces to achieve labial repositioning of the maxillary anterior teeth ([Table 23.1](#)).

### TONGUE BLADE/POPSICLE STICK THERAPY

Cooperative children can often correct a localized anterior crossbite using the wedging effect of a tongue blade





**Fig. 23.35** (A) Partially erupted central incisor with a minimal degree of overbite and lingual locking. (B) A tongue blade was used to exert labially directed pressure on the lingually locked incisor. (C) Correction of the crossbite accomplished with the tongue blade.

or popsicle stick (Fig. 23.35). Teeth in initial eruption with a minimal degree of locking can often be repositioned within 24 to 72 hours. The child is instructed to place the stick behind the locked tooth and, using the chin as a fulcrum, exerts pressure on the tooth in the labial direction.

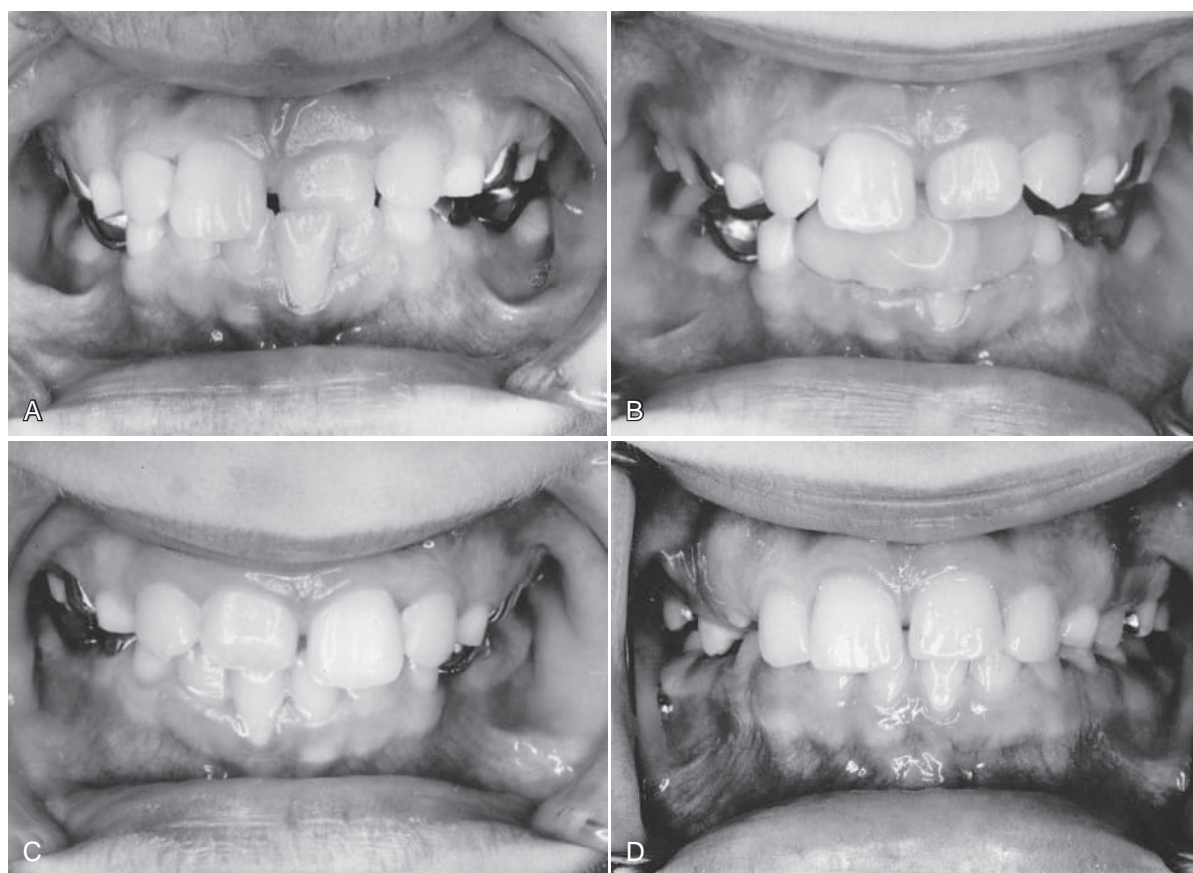
The procedure is done in 15- to 30-minute increments at a time for at least several hours of engagement. The obvious advantage of the technique is that “self-correction” avoids the expense and time involved with appliance therapy. The technique is highly dependent upon the frequency, duration, and accuracy with which the child uses the leverage stick against an erupting incisor. While it is still possible to correct an established crossbite with intense tongue blade therapy, the treatment is very unlikely if the tooth is erupted into full crossbite.

### LOWER INCLINED PLANE

An acrylic extension from the lower anterior teeth designed to engage the incisal edges of lingual displaced maxillary teeth during closure applies pressure upon patient closure that will direct the engaged tooth labially into normal bite position (Fig. 23.36). Prerequisites for an inclined plane are adequate space in the maxillary arch, a normal or excessive overbite, and sufficient mandibular teeth for retention of the acrylic. The inclined plane is constructed using self-curing resin on a working model to enclose the lower canine-to-canine anterior segment. This maximizes stability while preventing excessive lingual movement of the lower incisors. The acrylic should engage only the upper tooth or teeth in crossbite and incorporate approximately a 45-degree incline to the long axis of the lower incisors. The inclined portion should extend about  $\frac{1}{4}$  inch posteriorly such that the patient cannot readily bite behind the inclined plane.

At placement, the inclined plane is tried in the child's mouth before cementation to ensure that only the locked upper incisor is in contact with the acrylic and the plane does not touch palatal tissue. The posterior “bite opening” should be slightly beyond the rest position (not more than 2–3 mm) to avoid excessive muscle fatigue. This bite opening limits the time the appliance can be worn because eruption of posterior teeth may occur within 2 weeks and a tendency to an anterior open bite may result. The physical activities of children with bite planes should be restricted to minimize the possibility of avulsion or luxation of the teeth that occlude on the plane from a blow to the chin. Follow-up should be made at 1 week, with adequate bite jumping usually achieved within this time. If not “jumped” after 1 week, the inclined plane may be continued no more than an additional week. The appliance design and upper spacing should be evaluated for any interference to correction before the therapy is continued. If the situation is not corrected in this time, either the original diagnosis may be in error or more controlled mechanics are indicated. Once correction is achieved, the appliance should be carefully removed to allow for final positional adjustments with the natural vertical overlap providing retention of the corrected positions.

The advantages of the inclined plane lie in ease of fabrication, simplicity of action, rapid correction time, and possible use when there is insufficient eruption to engage active appliances. Disadvantages include discomfort associated with forced bite opening, poor aesthetics, limitations on diet, potential for gingival irritation, possibility of creating an open bite, and, of particular concern, the risk of traumatic injury if the child hits his/her chin while the inclined



**Fig. 23.36** (A) Essentially normal occlusion except for the central incisor crossbite. (B) A lower cemented acrylic bite plane was used to reposition the lingually locked incisor. (C) The tooth has moved into correct position with sufficient overbite to maintain the new relationship. (D) Four years after the correction of the crossbite. Notice improvement in the appearance of the tissue on the labial surface of the lower left central incisor.

plane is positioned in the mouth. In addition, the inclined plane may be dislodged by occlusal stress and require recementation. Given these disadvantages and the availability of other options that are more predictable and safer, the use of acrylic inclined planes is generally to be avoided except when other options are simply not feasible.

### PALATAL SPRING APPLIANCES (REMOVABLE HAWLEY OR FIXED PALATAL WIRE)

A fixed or removable appliance incorporating palatal springs provides the best option for dental anterior crossbites that are not amenable to tongue blade guidance. Properly oriented springs exert targeted, labially directed pressures against the teeth from the palatal side and are not affected by the reverse overjet. The major disadvantages are technical: the finesse needed in engaging the spring to the involved tooth or teeth, adjustments if breakage occurs, modification for retention if overbite is not adequate, and untoward movements. These disadvantages may be readily overcome with proper fabrication and management of the appliance.

A removable Hawley-type retainer modified with auxiliary springs can reduce lingual displacement of maxillary incisors, with correction usually achieved in 6–12 weeks (Fig. 23.37). A conventional Hawley retainer incorporating a labial bow and Adams clasps on the molars provides the base for the spring component. Although usually

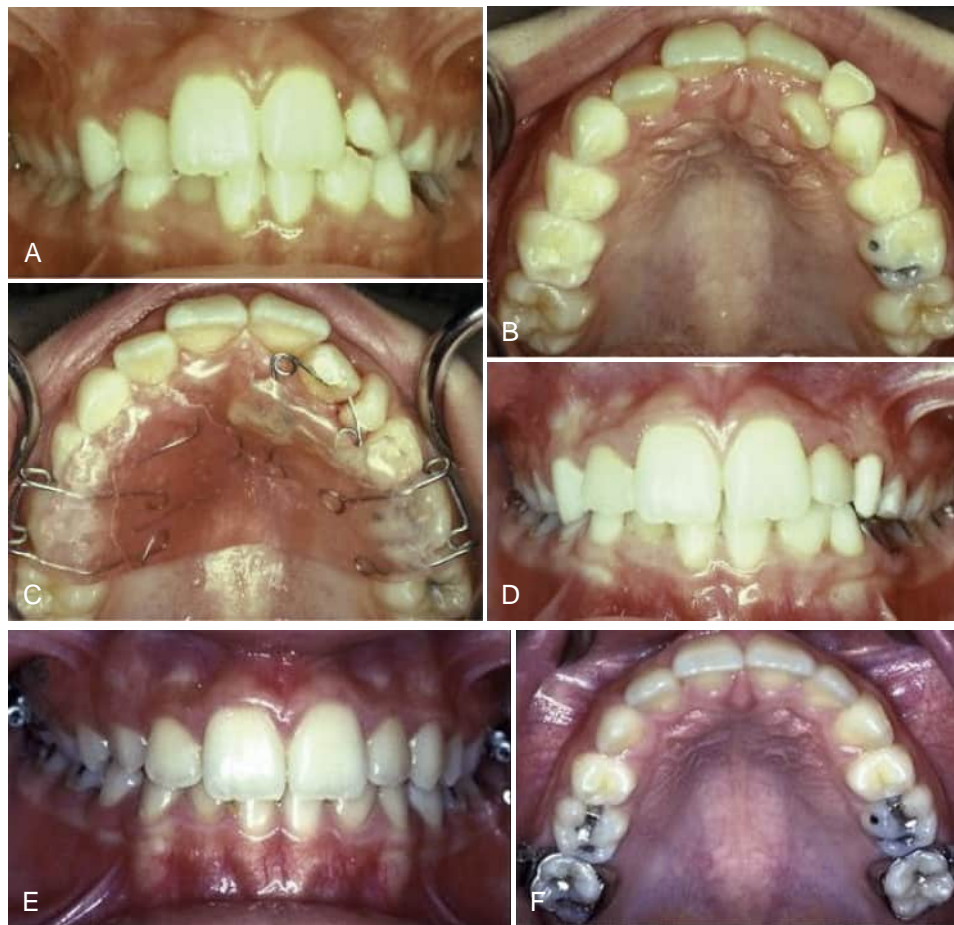
not necessary, the use of full posterior occlusal coverage enhances the effectiveness of a removable approach by minimizing any overbite interference to labial movement. Appliance action is enhanced if the appliance is seated when teeth are in occlusion to engage the finger spring more fully in counterbalancing the displacement effects of spring engagement.

With a helical loop finger spring of 0.020- or 0.022-inch stainless-steel wire, activation should represent 2–3 mm of helical loop closing from passive spring positioning that approximates the incisal edge of the contacted tooth. When activated, the spring tends to slide along the sloping lingual surface of the incisor to exaggerate tipping effects. This problem can be overcome by the bonding of a small “button” of flowable composite on the lingual surface to create a retentive undercut for maintaining a cervical orientation of the spring. This optimizes labial movement with less tipping by orienting the force vector closer to the center of rotation of the engaged tooth. The composite should not interfere with vertical closure after the malposed tooth is moved out of crossbite (i.e., not placed too far incisally), while ensuring spring engagement by extending the mesiodistal width of the tooth.

### FIXED TRANSPALATAL WIRES WITH SPRINGS

A transpalatal connector wire of 0.036- or 0.040-inch stainless-steel soldered to banded molars that incorporates





**Fig. 23.37** Removable Hawley-type finger spring appliance. (A) and (B) Lingual locked permanent lateral incisor with retained primary lateral incisor and insufficient space for the lateral to move forward. (C) A removable Hawley-type appliance with finger spring designed to correct the condition. Note that the retained primary incisor was extracted and the mesial surface of the primary canine was disked to allow space for tooth movement. Activation of the spring with engagement under the lingual composite “button” resulted in labial movement of the tooth. (D) The corrected occlusion at the time the appliance was discontinued. (E) and (F) Same patient 3 years later without any intervening retention or other treatments. Bands have just been placed in preparation for phase 2 braces.

a helical loop spring of 0.020-inch stainless-steel wire provides a very effective method to labialize maxillary incisors involved in anterior crossbite (Fig. 23.38). The orientation of the spring essentially mirrors the procedures outlined for the removable Hawley appliance. With the lingual composite button used to engage the spring, the increased stability and rigidity of the fixed anchorage system dramatically enhance directed forces toward the center of rotation of the engaged incisors. The fixed approach results in significantly less tooth tipping in offering a more bodily applied tooth movement and provides continuous force application that is not dependent on the child’s cooperation. These factors combine to effect correction of dental anterior crossbites by means of a fixed spring approach with average treatment times ranging from 1 to 3 weeks.

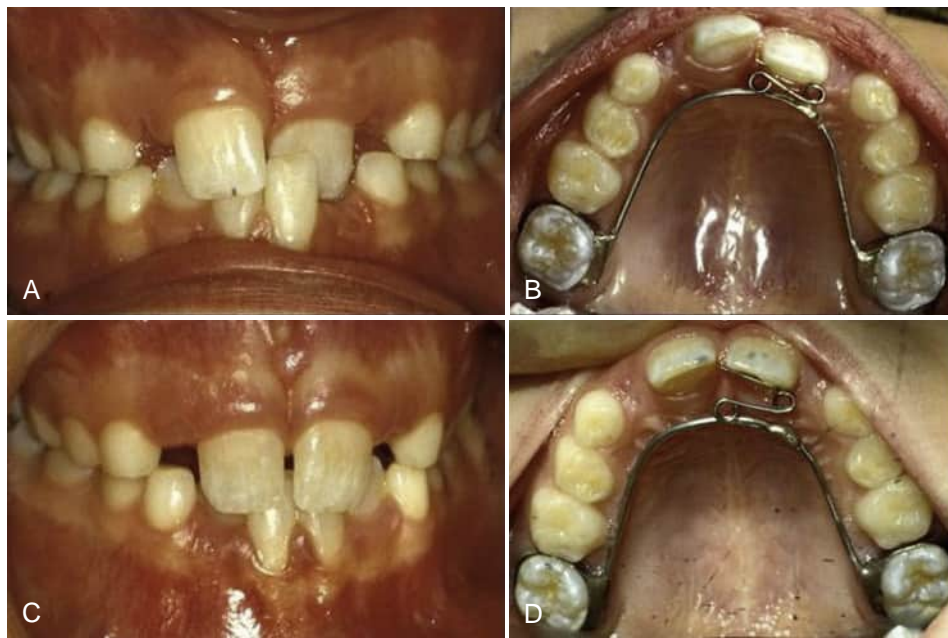Abutment support may be from either second primary molars or first permanent molars depending on developmental and eruptive status, condition of the crown, and clinician choice. After bands are fitted to selected abutments and a working model is prepared, the anchor wire is bent to approximate the palatal arch form about 5 mm lingual to the anterior teeth in crossbite. This positioning provides accurate space for bending a compact double helical loop spring as the active component. The maxillary incisors to

be engaged should be cut off horizontally on the working model at the cingulum level to create a “table” to position the spring horizontally with proper length. Passively, the helical loop extends from the anchor wire to rest on the cut-off incisal table, with the free end of the spring at the labial surface. The original positioning of the palatal anchor wire about 5 mm behind the crossbite teeth provides this distance in a double helical design. Careful soldering of the spring to the palatal wire completes the appliance in preparation for polishing.

### Labial Edgewise Brackets and Archwires

Edgewise mechanics are used when multiple incisors are in crossbite, palatal displacement and rotations are severe, and adjacent tooth movements are needed to adjust anterior spacing. While the clinician who wisely applies Edgewise techniques can achieve greater control in tooth positioning, their use presents major disadvantages in the early mixed dentition when most anterior crossbites are corrected. Disadvantages include increased chair time in placement, adjustment, and removal; need for special equipment and supplies; increased soft tissue irritation; decalcification of teeth; risk of injury to developing teeth with excessive biomechanical movements; and the expectations and expenses





**Fig. 23.38** Fixed palatal finger spring appliance. (A) Lingual locked permanent central incisor with significant overbite. (B) Fixed palatal appliance at delivery with double helical loop finger spring designed to labialize the single incisor. Initial activation of the spring from a passive position at the labial surface to engage the lingual composite “button” resulted in directed movement of the tooth. (C) The corrected occlusion at 17 days of treatment time. (D) The appearance of the spring at completion with the incisor out of crossbite. The lingual composite had been removed at 10 days of treatment time to eliminate vertical interference with positioning.

associated with “braces.” The discussion of Edgewise archwire techniques falls beyond the concepts of interceptive management and is illustrated in the section Comprehensive Orthodontics (pages 519–528).

Finally, it is worth mentioning that an interesting study by Rosa et al.<sup>35</sup> showed 84% spontaneous correction of anterior crossbites in conjunction with rapid palatal expansion treatment in the mixed dentition. This occurred whether or not the patients had an existing posterior crossbite because all 50 patients studied exhibited maxillary crowding, but only 20 had a posterior crossbite.

## Posterior Crossbite in Primary and Mixed Dentitions

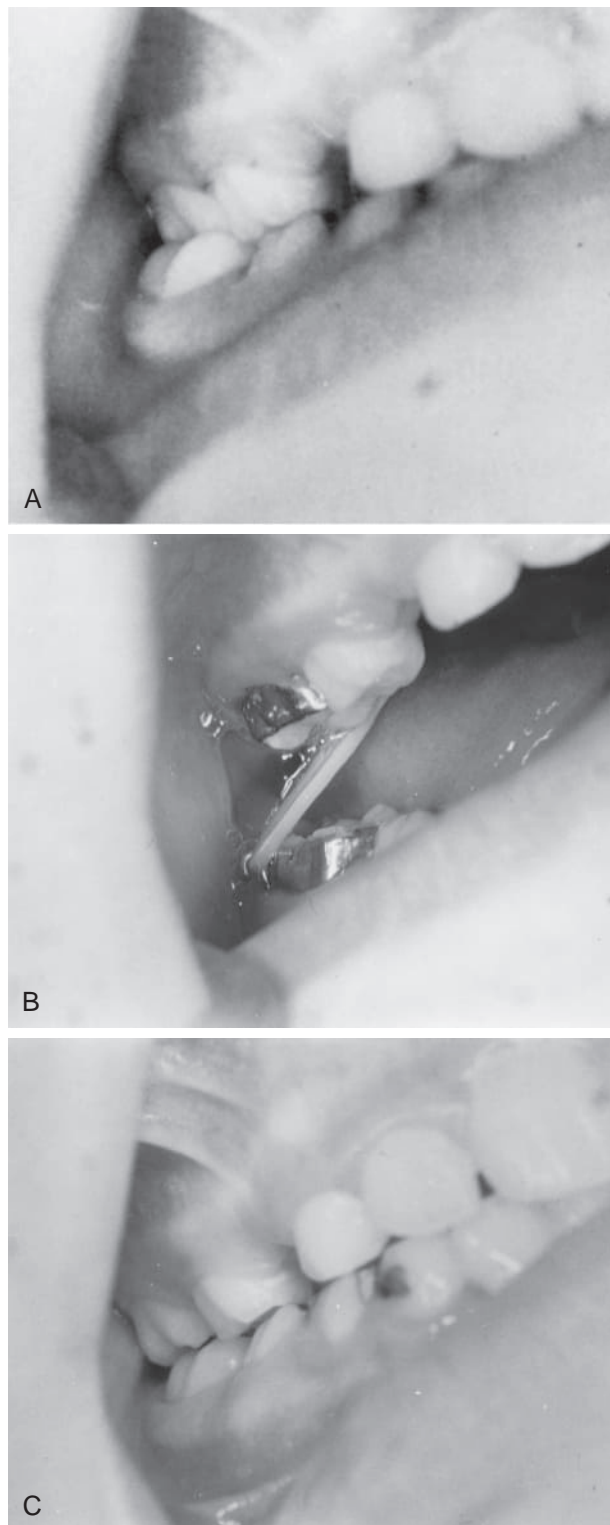
Before treatment, the type of posterior crossbites in children must be determined—whether the discrepancy is a localized problem in tooth eruption (dental crossbite), a gross basal disharmony between the maxilla and mandible (skeletal crossbite), or a transverse discrepancy in the upper to lower arch width that produces a lateral shift of the mandible on closure (functional crossbite).

Dental posterior crossbites involve atypical eruption and alignment with localized displacement of individual teeth into crossbite configurations. Most often involving isolated permanent maxillary first molars or premolars, dental crossbites are usually corrected in conjunction with comprehensive Edgewise orthodontics. Within an interceptive context, isolated first permanent molar cross-bites can be corrected by the use of cross-arch elastics (Fig. 23.39). A hook or button (either bonded to enamel or welded onto bands) on the lingual and buccal surfaces of the upper and lower molars, respectively, is used to secure elastics. The

elastics should be changed by the child or parent each day until the crossbite has been corrected. Typically, a crossbite involving isolated first molars can be corrected with cross-arch elastics in 4–8 weeks. If either of the opposing molars is in correct alignment before treatment, an anchorage appliance (lower lingual arch or upper Nance/transpalatal bar) may help prevent movement of that tooth. The corrected cuspal interdigitation usually holds the teeth in their new relationship, so there is no need for a retentive appliance.

Skeletal posterior crossbites present as gross discrepancies in basal relationships of the maxilla and mandible, usually presenting a full bilateral crossbite with severe constriction of the maxilla (Fig. 23.40). Midlines are generally coincident to the facial midline in occlusion, with no functional deviations observed on closure. The skeletal dysplasia is often complicated by other factors such as crowding of the maxillary teeth, anterior open bite, and environmental factors that impede normal growth patterns (e.g., severe airway problems, cleft palate). Kurol and Berglund<sup>36</sup> found 4 of 86 crossbites in children, a relatively low frequency, presenting as full bilateral crossbite.

Functional posterior crossbites involve a lateral shift of the mandible during closure in response to transverse occlusal interference between the maxillary and mandibular arch widths. The deviation of the mandible presents as a unilateral crossbite in centric occlusion involving multiple posterior teeth on one side, normal buccolingual occlusion of the contralateral side, and a deviation of the lower midline and chin toward the crossbite side (Figs. 23.41 and 23.42). While presenting a unilateral appearance in occlusion, functional posterior crossbites show cusp-to-cusp transverse contacts bilaterally, with a constricted maxillary arch of insufficient width to enclose the lower dentition at initial contact. Factors contributing to constriction in maxillary



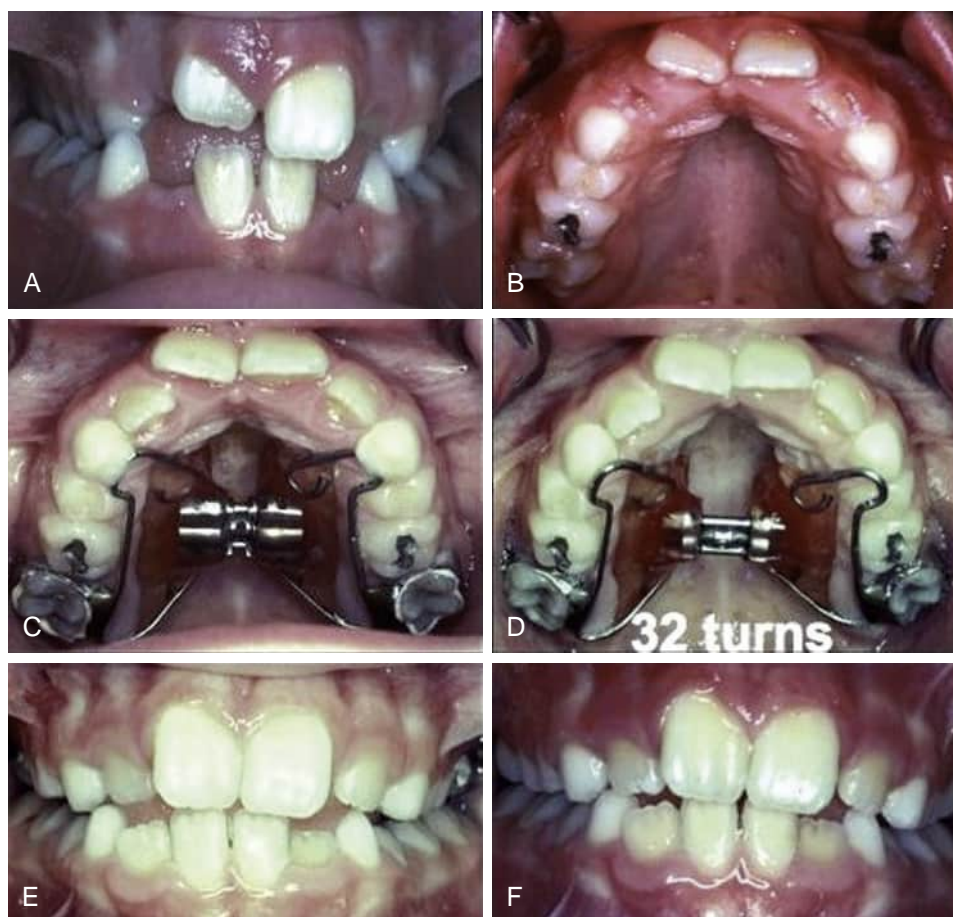
**Fig. 23.39** (A) Buccal crossbite limited to the first permanent molars on the right side. (B) Molar bands with hooks and cross-arch elastics from lingual side of upper to buccal side of lower are used to correct the crossbite. (C) The crossbite has been corrected in a 4-week period.

width include upright primary canine interference, thumb- and finger-sucking habits, and mouth breathing/airway problems. Studies demonstrate a direct linear progression between prolonged digit and pacifier habits beyond the age of 4 years and a higher incidence of posterior crossbites.

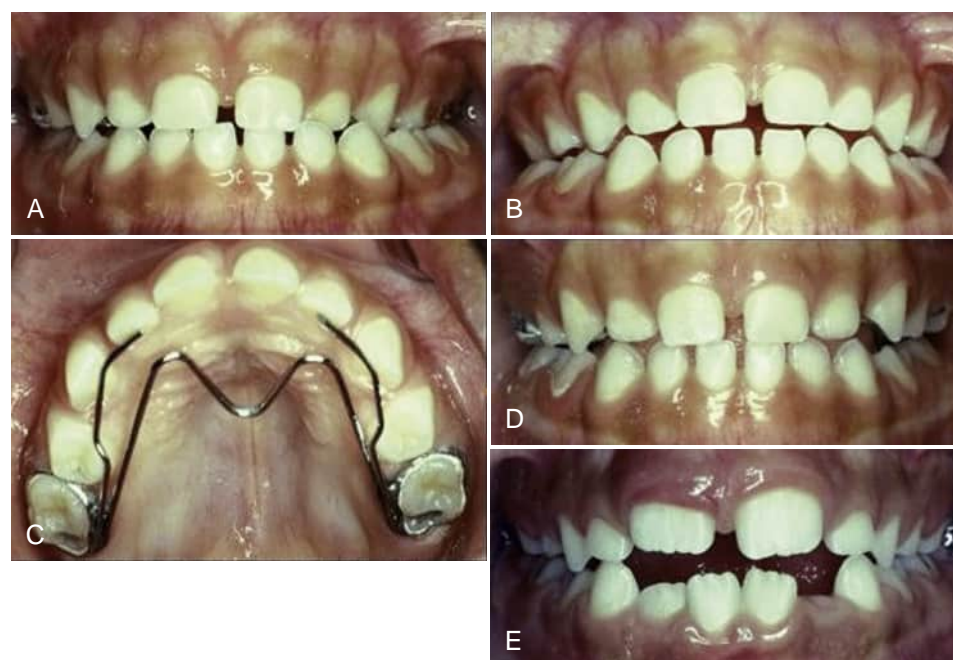
Functional posterior crossbites are among the more common occlusal problems observed in the primary and mixed dentitions, with an incidence rate of 5%–8% in children. Lindner and Mod er<sup>37</sup> documented patterns in 76 children with primary dentition and reported that three or more teeth (canines back) were involved in 85% of the crossbites, with two-thirds extended to include the primary lateral incisors. A lateral shift of the mandible was seen in 97% of the children, resulting in a lower midline discrepancy of about 2 mm on average. Other studies support the impression that more than 90% of posterior crossbites in children exhibit functional shifting of the mandible on closure as a component of the crossbite pattern. As a result of the functional shift, dental, skeletal, and neuromuscular adjustments likely result in further constriction of the maxillary arch, maldistribution of erupting teeth and alveolar bone, and asymmetric growth of the contralateral sides. In a study of 35 children with posterior crossbite in the primary dentition followed into the mixed dentition, Kutin and Hawes<sup>38</sup> reported that 32 of the children showed persistent crossbite of the first permanent molars after their eruption. Other studies have also suggested that posterior crossbites are generally not self-correcting because consistent incidence rates have been shown in children at 3, 6, 8, 10, and 12 years of age. It appears that less than 10% of posterior crossbites present in the primary dentition self-correct into the mixed dentition.

In conjunction with functional posterior crossbites, asymmetric condylar positioning has been demonstrated on tomograms and transcranial radiographs. Hesse et al.<sup>39</sup> documented condylar positioning using temporomandibular joint tomograms in 22 patients with functional posterior crossbite corrected with maxillary expansion at a mean age of 8½ years. The condyle on the noncrossbite side was positioned more anteriorly before treatment and moved posteriorly and superiorly after treatment. The condylar position was similar at pretreatment and posttreatment stages on the crossbite side. Importantly, correction of the crossbite with maxillary expansion established symmetry of condylar relationships in all planes of space. On comparing condylar path and mandibular length in 9 children with unilateral posterior crossbite treated with maxillary expansion between the ages of 5 and 8 years with a group of 13 individuals with untreated crossbites into young adulthood, Pirtiniemi et al.<sup>40</sup> reported that the condylar path evidenced asymmetry in both treated and untreated individuals, with greater steepness and condylar rotation on the crossbite side. The eminence was flatter in both groups on the noncrossbite side, whereas mandibular length was shorter on the crossbite side. The degree of mandibular asymmetric length was twice as great in untreated children as in those with treated posterior crossbites. Other studies confirm that displacement of the mandible in growing children produces asymmetric mandibular length, with the crossbite side shorter than the noncrossbite side. The mandibular rotation also results in a sagittal asymmetry of contralateral sides, with the crossbite side expressing a more distal step–Class II relationship and the noncrossbite side a more Class I to Class III pattern. Even though correction with maxillary expansion improves molar positioning toward Class I positions on the crossbite side and reduces the midline discrepancy, full establishment of symmetric relationships



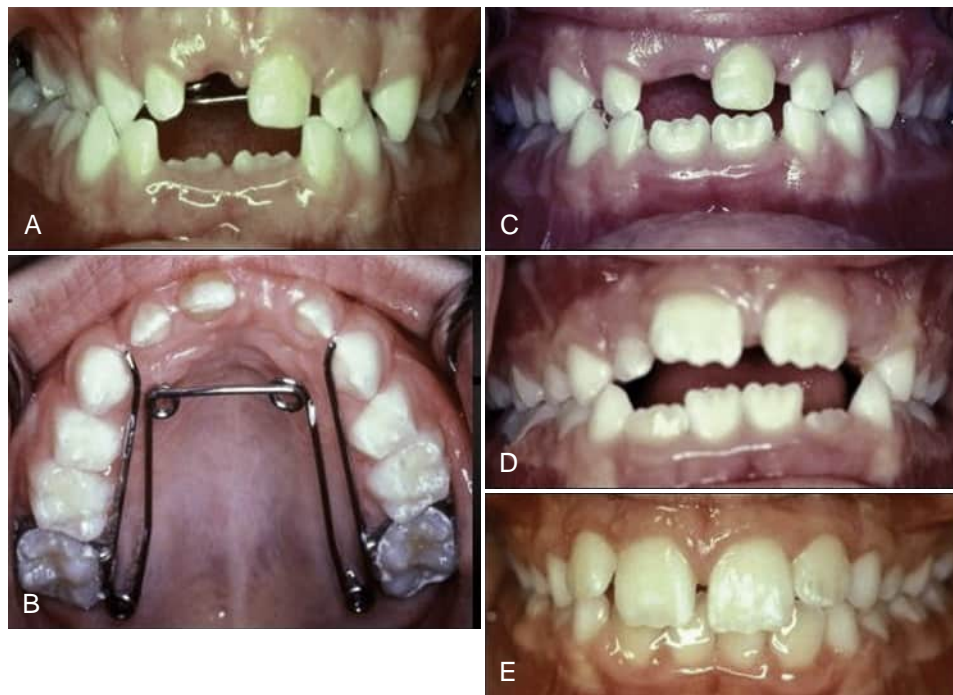


**Fig. 23.40** An acrylic jackscrew rapid palatal expander (Haas RPE) in the mixed dentition with bands on the permanent first molars and bonded composite on the primary canines. (A) and (B) The pretreatment bilateral posterior crossbite with constricted and tapering maxillary arch form. (C) and (D) The rapid palatal expansion appliance appearance at cementation and after expansion involving 32 turns on a once-a-day schedule. (E) The occlusion at 3 months with the appliance maintained for retention. (F) The occlusion 1 year after appliance removal.



**Fig. 23.41** W-arch appliance. (A) Functional posterior crossbite in the primary dentition in maximum intercuspation occlusion. Crossbite extends through buccal segment from the lateral incisor with a 2.5-mm mandibular midline shift to the affected side. (B) In rest to first contact position, the dental midlines are normal with the posterior segments edge-to-edge bilaterally in transverse width. (C) Soldered W-lingual arch appliance at cementation. (D) The crossbite was corrected in 6 weeks with 2- to 3-mm overexpansion; the appliance was left in place for 3 months. Notice that the dental midlines are properly aligned with the functional shift eliminated. (E) Two years posttreatment, the transverse posterior widths are in proper relationship with no mandibular shift evident during closure.





**Fig. 23.42** Quad-helix appliance. (A) Functional posterior crossbite in the early transitional dentition in maximum intercuspation occlusion. Crossbite extends through buccal segment with a 1.5-mm mandibular midline shift to the affected side. (B) Soldered quad-helix appliance at cementation. Note the symmetric and horizontal loop design for optimum expansion with minimal buccal tipping of molars. (C) Occlusion 2 weeks after appliance removal. The crossbite was corrected in 4 weeks, and the appliance was left in place for 2 months. Dental midlines are properly aligned with the functional shift eliminated. (D) Six months posttreatment, the transverse posterior widths remain in proper relationship with no mandibular shift evident during closure. (E) Two years after treatment into mid-mixed dentition with proper transverse relationships and no functional shift of mandible noted.

after correction is not a consistent finding. The continuation of some degree of asymmetry after correction suggests that unbalanced growth occurred up to the time of correction, more balanced symmetry of the growth patterns was expressed after correction, and any acquired pretreatment morphological asymmetry remained after correction.

Early correction of functional posterior crossbites has been shown to enhance developmental patterns by redirecting teeth into more normal positions, correcting asymmetries of condylar position, allowing for normal vertical closure without functional deviations, making beneficial dentoskeletal changes during periods of dynamic growth, and eliminating factors detrimental to dentofacial development.<sup>41</sup> Early treatment also allows for simplified approaches that are less complex, less time consuming, and more physiologically tolerable to structural tissues than are treatment demands in older patients. Delaying correction until the permanent dentition requires more complex mechanics to achieve basal arch corrections and may necessitate surgical approaches to achieving maxillary expansion.

### SELECTIVE EQUILIBRATION

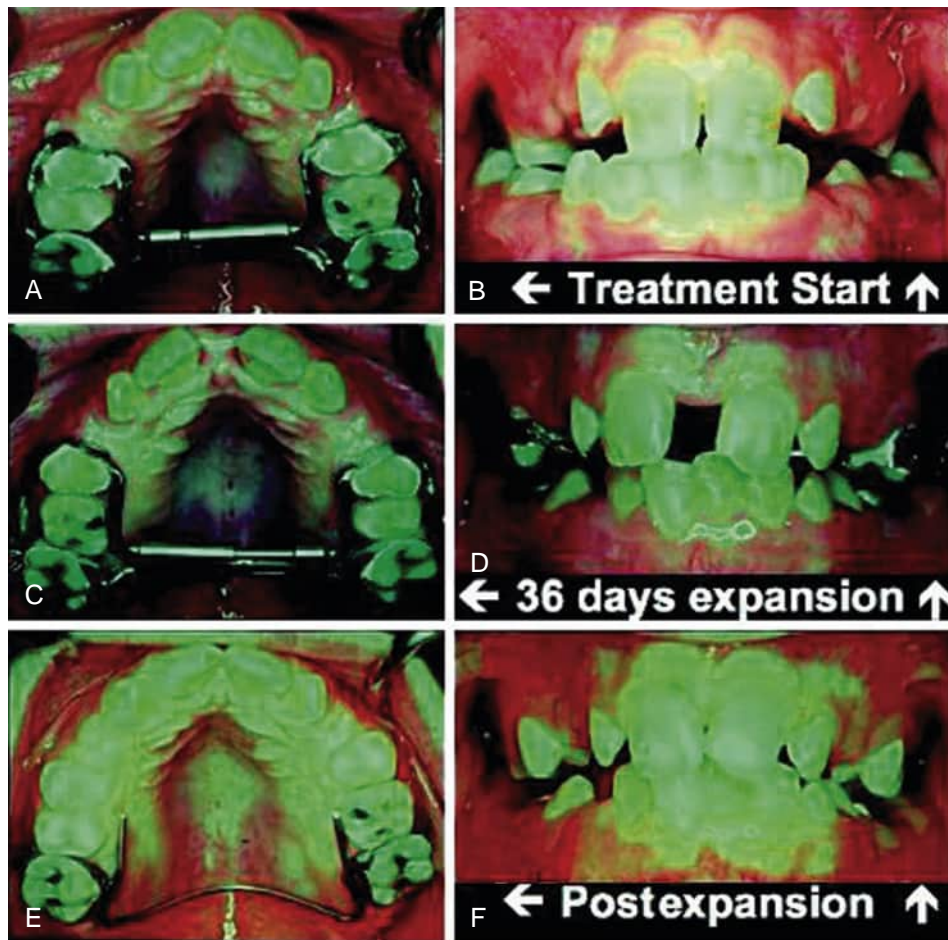
Selective equilibration of deflective interference, usually the primary canines, may enhance differences between the intercanine widths and offer some potential for functional crossbite correction without appliances. The equilibration involves selective reduction (i.e., slanting) of the lingual aspects of the upper primary canines and labial reduction of the lower primary canines. When the upper-to-lower intercanine width approximates the same width or the lower is

greater, selective grinding is not effective and upper canine expansion is required. In most full primary or mixed dentition cases, equilibration procedures alone are insufficient to eliminate a functional discrepancy associated with a constricted maxillary dentoalveolar width.

### MAXILLARY EXPANSION

Appliances used for maxillary expansion in the correction of posterior crossbites include fixed palatal wire designs (e.g., W-arch, quad-helix), fixed jackscrew expanders (e.g., Hyrax, Rapid Palatal Expander [RPE] of Haas), and removable split-acrylic plate appliances (e.g., Schwarz plate). Success rate for treatments during the primary and mixed dentitions have been documented at greater than 90% for the fixed approaches and 70% for removable appliances. Dimensional changes have documented that early expansion techniques to correct posterior crossbites in children require an average final overall increase of about 3–4 mm in intramolar width and 2–3 mm of intracanine width change for successful correction. The clinical reports further indicate that expansion protocols, regardless of the appliance used, should incorporate an overexpansion of about 2–3 mm beyond these final desired increments during the active phase in order to accommodate settling adjustments after treatment.

Transverse expansion of the maxillary arch is directed at a combination of dentoalveolar expansion and orthopedic separation of the midpalatal suture. It is considered desirable to optimize the opening of the midpalatal suture to provide more stable basal arch expansion than



**Fig. 23.43** Hyrax appliance in late-transitional dentition with bands on the permanent first molars and first premolars. (A) The Hyrax appliance at cementation. (B) The pretreatment bilateral posterior crossbite with symmetric but constricted maxillary arch form. (C) and (D) Appliance and occlusal appearance after expansion involving 36 turns on a once-a-day schedule. The large midline diastema reflects orthopedic separation of the mid-palatal suture. (E) and (F) The occlusion at 6 months postexpansion. The Hyrax was maintained for 5 months, and then replaced with the fixed transpalatal appliance for retention.

orthodontically oriented lateral expansion. In the consideration of appliance options, the nature of orthodontic and orthopedic movements is closely related to the rate of expansion, the magnitude of force application, and the patient's developmental stage. Fixed palatal jackscrew appliances, such as the RPE of Haas (Fig. 23.40) and the Hyrax (Fig. 23.43), are applied bilaterally to maxillary posterior teeth, with the midline screw generally expanded at a rate of one or two turns per day (one turn equals 0.25 mm of screw widening) during an active treatment time of 1–4 weeks. Single activations of fixed jackscrews produce high magnitude forces in the 3- to 10-pound range that maximize orthopedic separation by overwhelming suture tissues before substantial orthodontic movement can occur. The relative skeletal and dental components produced by rapid palatal expansion have been evaluated with standardized nonanatomic reference points (e.g., implants) and frontal cephalograms. Krebs<sup>42</sup> reported average arch width increases of 6 mm (range, 0.5–10.3 mm) for 23 individuals aged 8–19 years, with a total dental arch increase twice that of the skeletal segments. Analyzing the Krebs data, Hicks<sup>43</sup> estimated that skeletal separation accounted for approximately one-half of increased arch width in 8- to 12-year-olds and about

one-third of the increase in 13- to 19-year-olds. Retention periods of 6 months involving fixed appliances (e.g., expanded appliance, transpalatal bar) are recommended to allow for reorganization and stabilization of rapidly expanded maxillary sutures.

Compared with the jackscrew appliances, fixed palatal wire appliances (e.g., W-arch, quad-helix) accomplish maxillary expansion following “low-force” and “slow-expansion” procedures. Thomas et al.<sup>44</sup> determined that W-arch (Fig. 23.41) and quad-helix (Fig. 23.42) designs with 6–8 mm of expansion produced lateral forces in the range of 400–600 g (approximating 1 pound) at the molar positions and 200–300 g at the canine level. Some degree of sutural separation has been documented during the primary and mixed dentition stages with forces in these ranges. Using forces of less than 2 pounds to achieve maxillary arch width increases from 3.8 to 8.7 mm during treatment, Hicks<sup>43</sup> estimated that skeletal changes represented 24%–30% of the total arch width increase in 10- to 11-year-old children and 16% in 14- to 15-year-olds. Although they did not document the relative ratios of orthopedic versus orthodontic change, Harberson and Myers<sup>45</sup> reported radiographic evidence of suture opening during the deciduous and early mixed dentition in 8 of 10 posterior crossbites successfully



corrected with a W-arch appliance. Bell and Lecompte<sup>46</sup> reported suture separation on each of 10 children (mean age, 6 years 9 months) by means of quad-helix appliances with mean increases of maxillary intermolar width of 5.3 mm and maxillary intercanine width of 4.1 mm in successfully correcting functional posterior crossbites. The conceptual model of fixed palatal wire appliances in the primary and mixed dentitions is that favorable orthopedic and orthodontic ratios of expansion are realized with less disruption than with rapidly expanded sutures. Because of the “physiologic” nature of the expansion, the integrity of tissue elements is sustained to allow for enhanced stabilization of the changes, with retention periods of up to 3 months appearing adequate.

The palatal wire W-arch and quad-helix designs offer the advantages of increased molar rotational ability, relative comfort, minimal effect on speech and deglutition, reduced soft tissue irritation, and removal of adjustment responsibility from the patient-parent. Posterior crossbites in the full primary dentition are usually treated with banding of the deciduous second molars at ages 4–5 years. In the mixed dentition period (i.e., 6–11 years of age), the first permanent molars are generally banded for posterior crossbite correction. During the active eruption stage of the first permanent molars, from about 6 months before emergence until opposing occlusion is established, maxillary expansion procedures should usually be delayed. The first permanent molars may not be affected by expansion of the deciduous dentition during this transitional stage and may erupt into crossbite, thus requiring additional treatment. Delaying expansion until the first permanent molars are in occlusion results in no significant technical problems related to treatment. The Hyrax jackscrew appliance becomes the priority choice for maxillary expansion when gross discrepancies in basal relationships present as full bilateral crossbites, when there is pronounced maxillary constriction with severe crowding of the maxillary teeth, and when other factors suggest the use of a rapid palatal expansion to exaggerate orthopedic over orthodontic movements. True bilateral posterior crossbites require twice as much incremental expansion as needed in functional crossbites, bringing into play the greater increments achievable with fixed jackscrew appliances. Given an increasing resistance to sutural separation, older patients with late mixed or young permanent dentition (i.e., 10- to 16-year-olds) require higher force systems of rapid palatal expanders. Additionally, the transitional status of exfoliating primary and erupting permanent teeth in the late mixed dentition may complicate anchorage options in the use of palatal wire appliances. The Hyrax is used until growth is complete (girls, 16–17 years; boys, 18–21 years), with sutural separation anticipated during the earlier stages of this developmental period. After retention, regardless of whether jackscrew or palatal wire-type appliances were used in treatment, the laterally tipped dental elements will upright. This dental relapse must be factored into the active expansion and retention phases.

The soldered W-arch uses a 0.036- or 0.040-inch stainless-steel wire contoured to the arch from bands on the most distal teeth involved in the crossbite. The wire is expanded to the bilateral width of the central fossae of the banded molars before cementation, such that the appliance must be compressed 2–3 mm bilaterally for placement on

the banded teeth. It is reactivated by being removed for additional adjustment every 3 or 4 weeks if necessary until the crossbite has been corrected (Fig. 23.41). The appliance may be used as a retainer for 3–6 months after active treatment. The soldered W-arch is very stable, with its primary use in situations that require 4–5 mm of maxillary buccal expansion such as typically required in functional posterior crossbites. Some palatal expansion may occur with the W-arch.

The quad-helix appliance, by incorporating four helical loops into the W-arch design, provides refined adjustment capability for a longer range of force application (Fig. 23.42). For that reason, quad-helix treatment is emphasized, although the basic W-arch design follows similar protocols. The quad-helix is fabricated from 0.036-inch stainless-steel wire with the loops equal in size to optimize symmetric expansion and the “cosmetic” look of the appliance. The anterior loops should be at the level of the canines and approximate the palatal width to minimize the space between the crossbar and the palatal contour. All loops should be as horizontal as possible, with the anterior loops circling toward the palate at the level of the primary canines and the posterior loops away from the palate. This places the helical loop section and the lateral expansion forces in a more palatal position for enhanced expansion effects. The posterior loops should extend approximately 2–3 mm distal to the molar bands for enhanced molar rotation and expansion.

The progress of expansion is followed as described for the W-arch appliance, with a 2- to 3-week appointments interval. Adjustments are made only when progress between successive appointments is static and the amount of increased arch width is inadequate. Expansion is considered adequate when the occlusal aspect of the maxillary lingual cusps comes into contact with the occlusal slope of the mandibular buccal cusps in representing approximately 2–3 mm of overexpansion to compensate for later uprighting of laterally tipped teeth once appliances are removed. Successful expansion with slight overcorrection is usually achieved in 4–6 weeks. If an adjustment is necessary, the appliance should be removed for activations to ensure appropriate expansion increments in both amount and location. Activations consist of, again, opening with finger “accordion”-type action or incorporating strategic bends along the wire lengths to increase lateral expansion. Bends can be done intraorally but tend to create compensating adjustments such that multiple intraoral activations frequently produce untoward movements. The appliance is left in the expanded position to serve as a retainer with a recommended minimum retention period of at least 3 months, although longer periods are suggested, especially if the patient has a history of oral habits (e.g., thumb sucking, mouth breathing, tongue thrusting) or exhibits continued functional inconsistencies in mandibular closure. While using the appliance as its own retainer is convenient, the possibility of continued expansion into the buccal crossbite must be realized. Thus supervision during “retention” with a monthly monitoring schedule is desirable. Heat annealing of the appliance may also be considered, or the clinician may use a follow-up Hawley-type retainer.

Fixed Hyrax jackscrews are preferred for bilateral posterior crossbites with pronounced maxillary constriction that



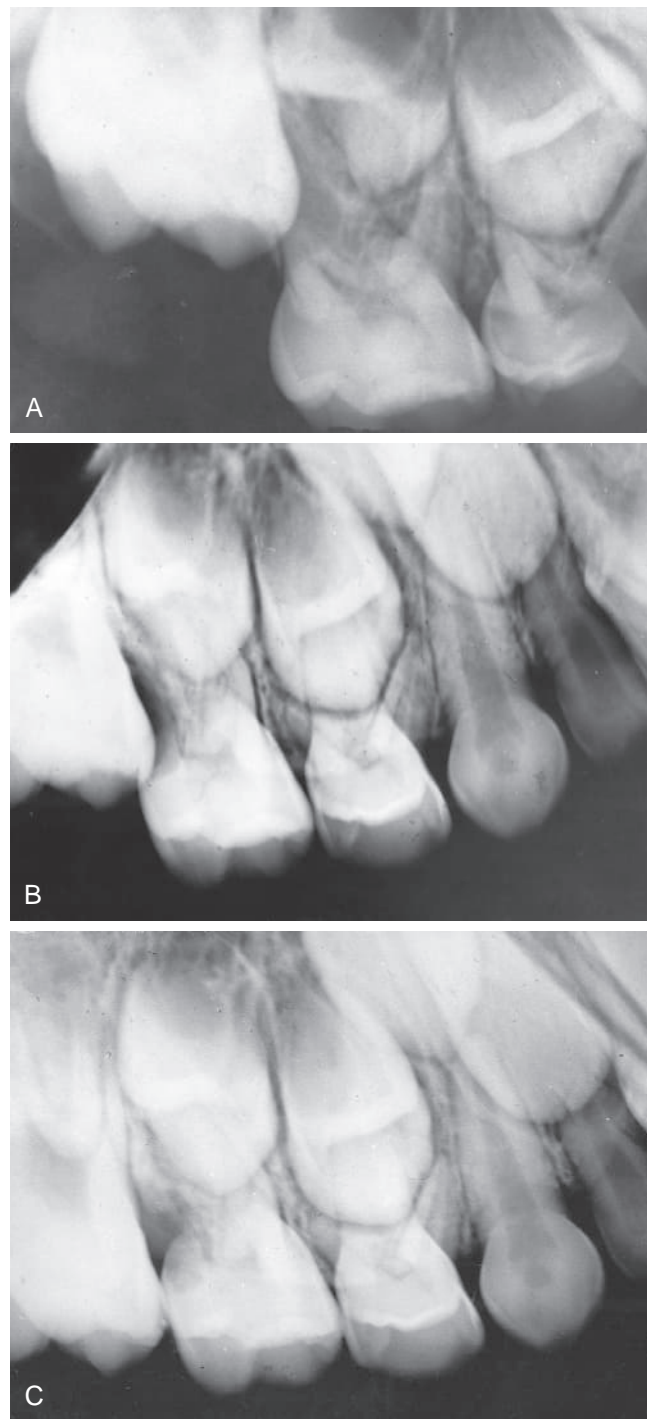
require 6–8 mm of expansion to correct the transverse discrepancy, and in older patients in whom sutural integrity requires greater force magnitudes to achieve basal arch changes (Fig. 23.43). Expansion effects with the Hyrax appliance are closely related to the rigidity of the appliance, positioning of the jackscrew relative to the palatal arch form, and resistance of the maxillary complex. Banded designs reinforced with buccal and lingual connector wires between multiple abutments demonstrate the most rigidity in design. If such a design is used in the mixed dentition, the first permanent molars and second primary molars provide excellent anchorage for the appliance. In the adolescent dentition, anchorage usually involves first permanent molars and either first or second premolars. These appliances have been shown to generate the greatest orthopedic response when positioned high in the palatal contour and as far posteriorly toward molar positions as possible. Given the force levels generated, an activation rate of one turn per day is advised to achieve expansion on the order of 6–8 mm (24–32 turns) during an active treatment time approximating 1 month. After sufficient expansion is obtained, the appliance is left in place for 6 months to allow for reorganization of the expanded suture and enhanced stability of the arch width achieved.

## Eruption Problems and Eruption “Guidance”

Abnormal eruption patterns with resultant ectopic displacement, asymmetry of alignment, disruption in arch integrity, and crowding are all benchmarks of a tooth size–arch size discrepancy. Furthermore, local factors such as supernumerary teeth, congenital absence or malformation of permanent successors, necrosis or dystrophic calcification of a primary tooth secondary to trauma or caries, and ankylosis of primary molars may present barriers to normal eruption and alignment. The watchword for evaluation should be in monitoring the sequence and symmetry of eruption patterns, with a basic rule that the transition should be about the same for contralateral segments.

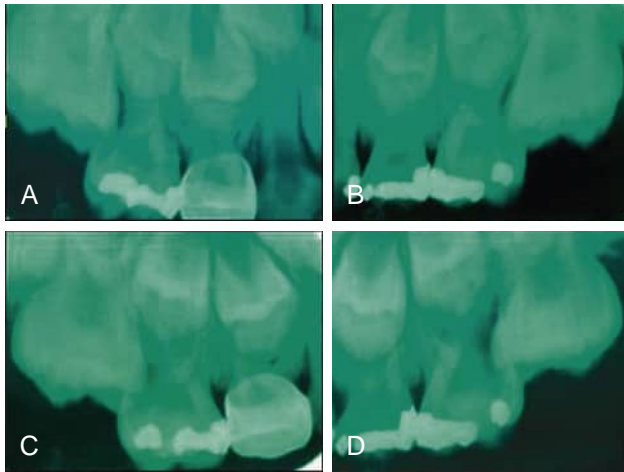
### ECTOPIC ERUPTION OF FIRST PERMANENT MOLARS

First permanent molars may be positioned too far mesially in their eruption path, with resultant ectopic resorption of the distal root of the second primary molar. Bjerklin and Kurol<sup>47</sup> distinguished two types of ectopic eruption—reversible and irreversible. In the reversible type, the molar frees itself from the ectopic position and erupts into normal alignment, with the second primary molar remaining in position (Fig. 23.44). Most permanent molars in children with reversible patterns had freed themselves by 7 years of age. In the irreversible type, the maxillary first molar remains unerupted and in contact with the cervical root area of the second primary molar (Fig. 23.45). By the age of 7 and 8 years, any ectopic eruption of a permanent first molar should be considered irreversibly locked. Young<sup>48</sup> observed that ectopic eruption of first permanent molars occurred 52 times in 1619 children (3%), more frequently in boys (33 times) than in girls (19 times). The ectopic



**Fig. 23.44** (A) Ectopic eruption of a maxillary first permanent molar with evidence of resorption of the distal buccal root of the second primary molar (B) and (C) Subsequent radiographs show continued resorption of the primary molar but “self-corrective” eruptive positioning of the first permanent molar. Approximately two-thirds of ectopic molars are reported to exhibit such a “reversible” pattern.

molar often occurred in more than one quadrant and was most often observed in the maxilla (only two ectopic lower first molars were noted). Young<sup>48</sup> further observed that two-thirds of ectopic molars erupted into their essentially normal positions without corrective treatment (reversible). Bjerklin and Kurol<sup>47</sup> also reported that children with irreversible ectopic eruption patterns had significantly larger



**Fig. 23.45** (A) and (B) Periapical radiographs demonstrating bilateral ectopic eruption of maxillary first permanent molars with resorption of the distal aspect of the second primary molars. (C) and (D) Subsequent radiographs obtained at 6-month recall showing “irreversible” pattern of ectopic eruption with continued resorption of the primary molars and greater mesial displacement of the first permanent molars.

permanent first molars, a more pronounced mesial angle path of eruption, and a tendency toward a shorter maxilla in relation to the cranial base. No significant differences in these variables were found between sides with reversible ectopic eruption and sides with normal eruption. Ectopic molars also show a significant familial tendency, with a prevalence of 19.8% in affected siblings versus the overall 2%–3% general occurrence. A frequent occurrence rate of ectopic first permanent molars at 25% in children with cleft lip and cleft palate again implicates maxillary positioning and basal arch size as etiologic factors.

Irreversible ectopic molars that remain locked, if untreated, can lead to premature loss of the primary second molar with a resultant decrease in quadrant arch length, asymmetric shifting of the upper first molar toward Class II positioning, and supraeruption of the opposing molar with distortion of the lower curve of Spee and potential occlusal interference. Early assessment with intraoral or panoramic films approximating the timing of first permanent molar eruption is thus critical to identification of the problem and provides an opportunity to intercept potential sequelae. If the problem is detected at 5–6 years of age, an observation approach of “watchful waiting” with appropriate monitoring may be indicated, given the two-thirds potential for self-correction. With self-correction being unlikely as the child approaches 7 years of age, continued “locking” of the first molar with advanced resorption of the primary second molar usually warrants intervention. Another timing clue is that when the opposing molar reaches the level of the lower occlusal plane, intervention is indicated to establish proper vertical control and prevent supraeruption. Because the anomaly often occurs bilaterally in conjunction with a tooth mass discrepancy, the finding should result in careful examination of other areas for similar conditions.

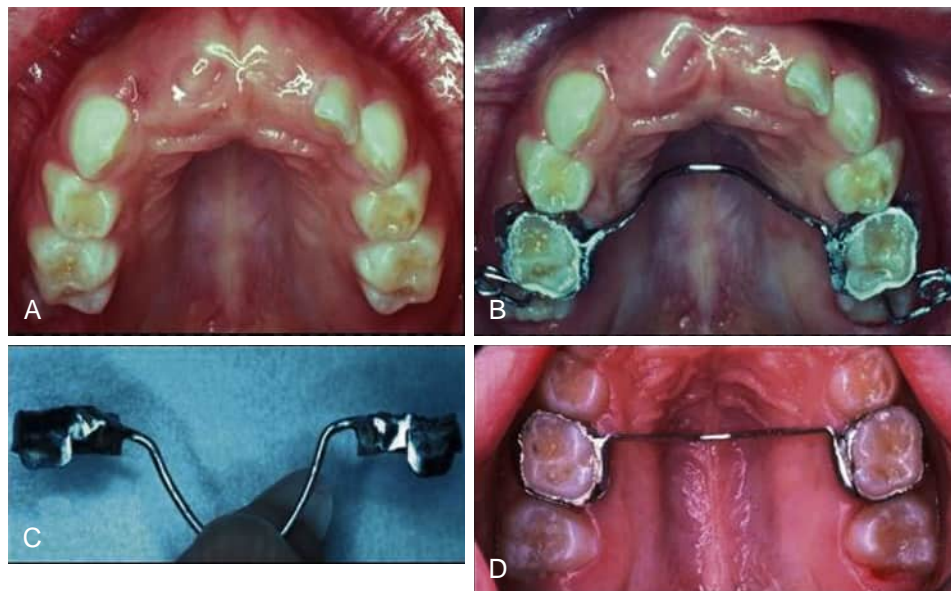
Interceptive correction involves guidance of the ectopic molar into normal position, retention of a favorable eruption sequence, and maintenance of arch length. Importantly, the resorptive process of the primary molar generally stops once the ectopic positioning is corrected and the tooth remains to stabilize arch integrity. One option is to restore

the second primary molar with pulpotomy and a stainless-steel crown supplemented with band material extending subgingivally to rest mesially to the ectopic molar. Designed to serve as a guide for eruption positioning, the extension must be carefully placed so as not to exaggerate molar entrapment. The technique seems simple but is actually very difficult to perform and should generally be avoided. Several other corrective procedures have been reported, with treatments varied by the extent of blockage, degree of primary tooth resorption, direction of displacement, timing, arch length status, and patient cooperation. Approaches include separators and distalizing appliances.

Orthodontic elastic separators are the first choice if access is sufficient to allow insertion in the contact areas of entrapment. The first placement is the most difficult and often requires a modified separator and floss engagement. This is done by looping floss through the separator, passing the floss through the contact area, pulling the doubled separator into the cervical area of contact, and then pulling one side of the separator through the contact with the floss. Progressive use of larger separators placed conventionally—from smaller, “stretchier” elastic types to more rigid plastic types—at subsequent visits facilitates this approach. Replacement at 1- to 2-week intervals usually accomplishes correction within 2 months. Separating springs can also be used provided there is sufficient eruption has taken place to allow for their insertion between the contact areas. However, separating springs tend to impinge upon tissues and are easily displaced, raising concerns for swallowing or aspiration. If springs are used, insertion is most easily achieved by the use of Howe or Weingart pliers to grasp the active arm of the spring. Floss looped through the helix serves as a safety device if the spring slips out of the pliers. The head of the spring is placed on the marginal ridge, while the active arm is directed below the contact point of the teeth. The spring may be inserted from the buccal or lingual side (whichever provides the greater access); the buccal approach is usually easier. The spring is left in place until the tooth is freed from contact with the adjacent tooth and is erupting. The patient should be seen every 2–3 weeks for evaluation of eruption progress and reactivation of the spring.

Brass ligature wire threaded between the contact areas of the affected teeth may facilitate distal movement of the permanent molar through periodic tightening of the looped wire as a separating force. The wire should be twisted or a new one placed at approximately 3- to 5-day intervals until the desired separation is achieved. Brass wire usage is uncomfortable and local anesthetic is often required; the brass wire usually has to be replaced one or more times before correction is achieved, relapses easily, and, in essence, is vastly overrated. Treatment with any of the separator techniques requires that only a minimal lock be evidenced and that minimal resorption of the primary second molar has occurred. Of the three, elastic separators are much easier to use and are much less problematic for minimal locks than separating springs or brass wire. Another technique of some value is to reach distal to the second primary molar with a high-speed bur angled back toward the offending “spicule” of enamel on the primary molar and slicing this “spicule” off. While technically a bit difficult, it can be worth the attempt, especially if it prevents use of the more involved and expensive techniques mentioned next.





**Fig. 23.46** Distalizing spring (Humphrey) appliance. (A) Bilateral ectopic eruption of the maxillary first permanent molars. (B) A Humphrey-type banded appliance with distalizing springs has been fabricated to reposition the ectopic first permanent molar. The ectopic molars were uncovered at the time of band fitting. At placement, composite ridges were bonded to the occlusal surfaces for spring engagement. (C) and (D) After distal repositioning of the first permanent molar was achieved, the appliance was removed, springs were cut off, and band material was tack welded to provide extensions to maintain first permanent molar eruption into favorable positions.

Irreversible ectopic eruptions may require the use of distally directed forces from the second primary molars to disengage and allow eruption of the first permanent molar. The Humphrey appliance uses a distally directed S-shaped loop that is actively engaged on the occlusal surface of the ectopically erupting permanent molar (Fig. 23.46). In original usage, it was often necessary to remove the appliance for activations of the loop, and a restoration was required in the first molar after correction. The advantages were stability and ability for severe locks of the 6-year molar to be corrected. Subsequent modifications to the original Humphrey design include the use of helical springs (0.018- to 0.022-inch wire) to provide more continual force and easier reactivations, added stability by the anchoring of banded molars bilaterally with a palatal wire, using springs from buccal and lingual aspects to minimize rotations of the permanent molar, and using bonded composite resins to engage the distalizing springs. Disadvantages include problems in activation and adjustment of the spring, possible occlusal interference distorting the wire, need for access to the occlusal surface of the first permanent molar, and possible reciprocal movement of primary molars. Once distalized, the spring needs to be removed to allow for vertical eruption of the molar to ensure correction. To prevent relapse of the molar into the undermined area, band extensions are tack welded to the distal aspect of the band and the appliance is recemented.

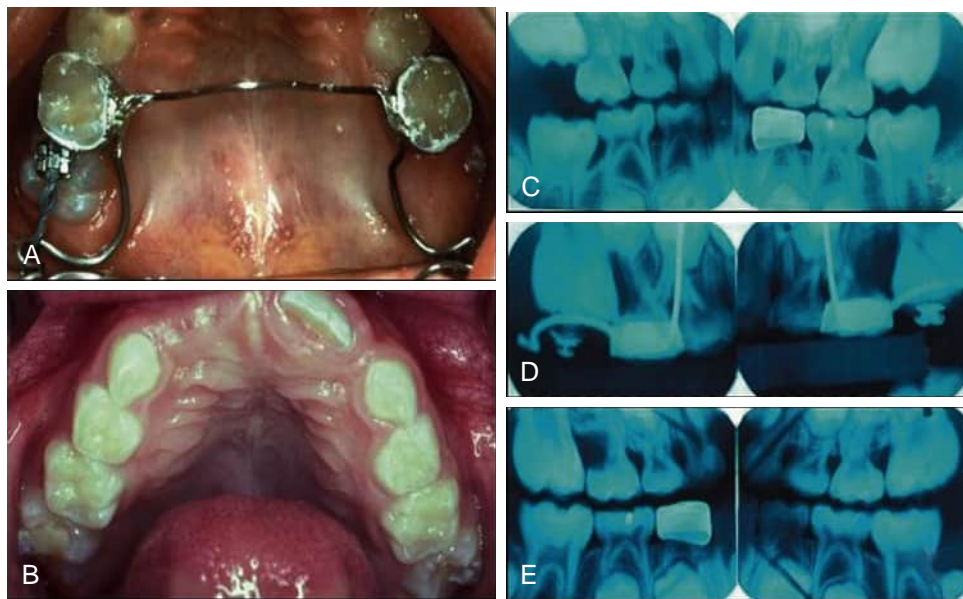
The Halterman appliance uses elastomeric chains rather than springs as the distalizing force (Fig. 23.47). With a rigid 0.036-inch stainless-steel wire “hook” extended distally from the lingual aspect of bands on the second primary molars, stretching of elastomeric chains from bonded buttons on the ectopic molar essentially “slingshots” the molar distally. Extending the wire from the lingual side of the primary molar avoids wire impingement with the anterior border of the ramus during opening. The wire should

approximate the palatal contour with the hook positioned horizontally to approximate the buccolingual midpoint of the desired molar location and about 5 mm beyond the distal marginal ridge of the involved permanent molar. This position provides adequate stretch of the elastic forces in a vertical and parallel orientation to normal arch alignment. An occlusal button, cleat, or bracket is bonded to the central fossae area of the ectopic first molar as far mesially as accessible. Clinician-preferred (i.e., self- or light-cured) resin bonding is used with success depending on avoidance of moisture contamination. Hybrid glass-ionomer cements that allow moisture exposure and do not require acid etching are an alternative if isolation is compromised. In placement, the elastomeric chain should already be secured to the button during the bonding process to ensure that composite material does not extend into undercut areas and block elastic engagement. After the button is bonded, the appliance is cemented and the elastomeric chain is stretched to the distal hook. A closed-loop chain is recommended for enhanced force application. Being relatively simple to apply as well as predictable and effective, the Halterman distalizing technique is currently the preferred method when elastic separators are not applicable.

### ERUPTION GUIDANCE IN THE LOWER INCISOR SEGMENT

Developmental patterns often find permanent lower incisors erupting into a lingual position behind the primary incisors as a “double row” of teeth. The majority of these cases self-correct via eventual exfoliation; however, if the problem does not self-correct by 8 years of age, extraction of the primary incisors may be necessary (see Chapter 20). The tongue usually positions the permanent incisor forward into normal alignment. In conjunction with eruption of lower lateral incisors, there is a normative increase





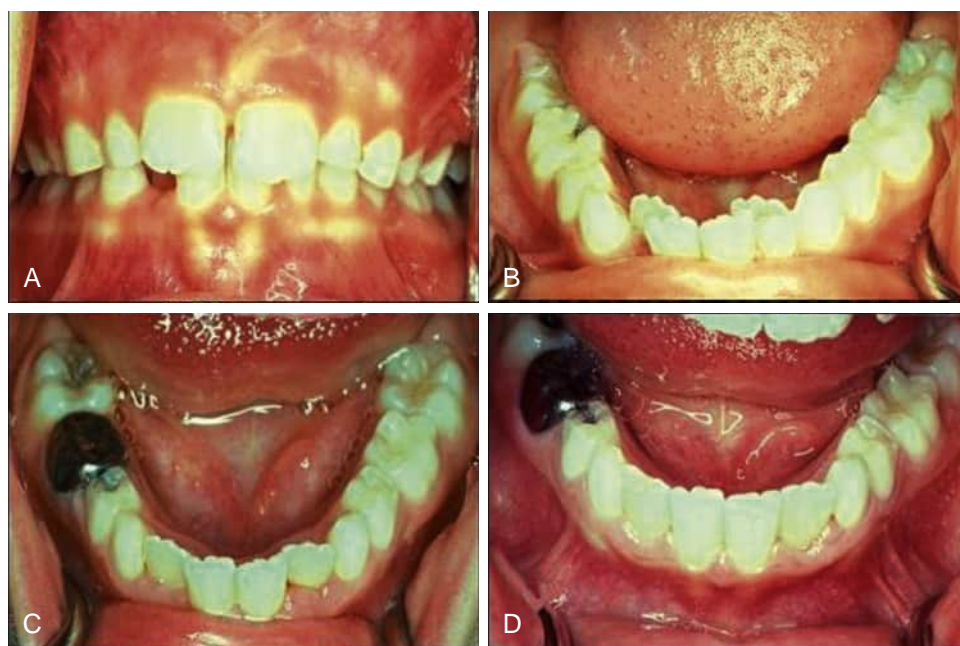**Fig. 23.47** Fixed maxillary Halterman appliance. (A) Bands on second primary molars with distal engagement arms for engaging elastomeric chains to bonded attachments on bilateral ectopic first permanent molars. (B) The first permanent molar has erupted into a favorable position after 6 weeks' treatment time. Radiographs showing distal repositioning of the first permanent molar from (C) pretreatment, (D) at 2 weeks of treatment, (E) to 1 year posttreatment.

in the lower intercanine width of 2–3 mm (range, 0–5 mm). This “growth” in lower anterior space helps compensate for the inherent tooth mass liability. After the lower permanent incisor transition is complete by 7–8 years of age, the “normative” finding presents almost 2 mm of incisor crowding. Studies document that no future increase in the lower intercanine width for relief of crowding will occur after this stage of incisor eruption is complete. However, extra space is available within the overall arch, as represented by the size difference between the primary canines and primary molars versus the permanent canines and premolars. This “leeway space” represents a +1.7 mm, on average, in each lower quadrant and provides potential for the relief of lower incisor crowding. Gianelly,<sup>11</sup> reporting on 100 consecutive mixed dentition children presenting for orthodontic needs, found that 85 of them had lower incisor crowding, with an average crowding discrepancy of –4.4 mm, a discrepancy significantly greater than population averages of approximately 2 mm. When leeway space was calculated into a space analysis, adequate room to accommodate an aligned dentition was indicated in 72% of the individuals with crowding. Given this potential, if an overall space analysis indicates that a child's arch perimeter is adequate to accommodate or be within 2–3 mm of relieving any incisor malalignment, the clinician should consider options to facilitate adjustments through guidance of eruption and timely use of the available leeway space.

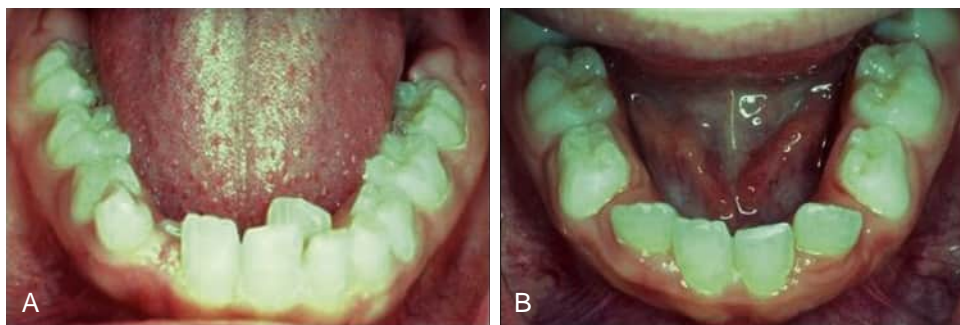The first option when incisor crowding is less than 3–4 mm involves “disking” the primary canines on their mesiolingual surfaces. Timely disking provides a “sluiceway” for lingual displaced incisors to slide forward toward the anterior arch form under the muscular pressure of the tongue (Fig. 23.48). Bilateral disking can provide up to 2–3 mm of space for “unraveling” of lingually displaced incisors. With proper slicing of the mesiolingual corner

at the gingival contact area, there is actually no measurable encroachment on overall leeway space in the individual quadrant. Movement of the incisors under tongue pressure potentially increases the midline arch length and overall arch circumference as the arch is rounded out in a forward direction. In the case of labial malpositioned incisors, while disking may provide additional room for alignment, the lips are a more significant factor in the balance between muscular forces. The result is lingual flattening of the anterior segment and a decrease in overall arch space. Disking must involve slicing the canine subgingivally to completely free the contact area. Disking just the crown is not enough. The use of a tapered bur of a size to allow access without injury to adjacent permanent teeth is required (#699 or #169). Local anesthesia or nitrous oxide support is frequently required because dentin exposure and periodontal insult are necessary to disk primary canines adequately. Placement of a wedge is sometimes necessary to protect the lateral incisor. Timing is critical to allow for optimal tooth positioning and ease of access. Given that the normative intercanine width increases 2–3 mm during lateral incisor eruption, disking should be delayed until eruptive “wedging” effects of the incisors are realized. If indicated, disking of lower primary canines is therefore recommended at around 7–8 years of age, near completion of lateral incisor eruption.

While excessive incisor liability may result in ectopic loss of lower primary canines (reviewed earlier in this chapter), more often the primary canines remain and the permanent incisors erupt significantly malpositioned. If disking of the canines is not an option due to the level of crowding or positioning of the incisors, elective extraction of the primary canines to maintain arch symmetry, coincident midlines, and incisor integrity may be considered (Fig. 23.49). Such intervention becomes more viable when the



**Fig. 23.48** Incisor guidance with disking of lower primary canines. (A) and (B) Presentation of approximately 4.5 mm of lower incisor crowding with lingual malpositioning of lateral incisors, retained lower left primary lateral, and 80% overbite. Given significant overbite and positioning of incisors, the decision was made to disk the lower primary canines bilaterally in conjunction with restorative appointments. (C) Same patient at 6-month recall appointment after disking. Slight additional disking of canines was done at recall. (D) Same patient at 1 year from start of first disking. Arch form is established as tongue pressure positioned the lingually displaced incisors forward into the spaces created by disking.



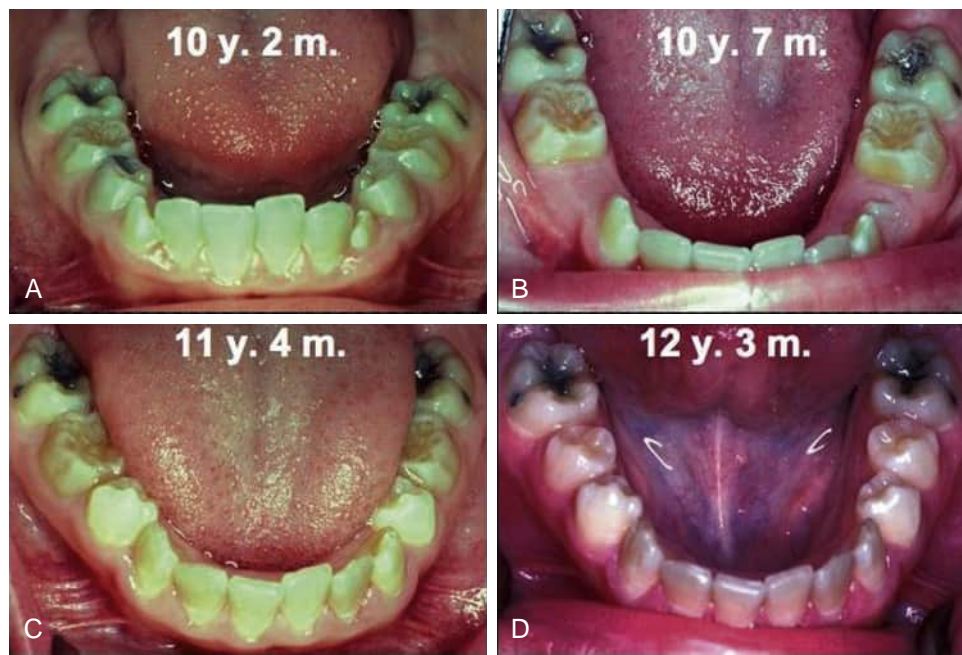
**Fig. 23.49** Elective extraction of lower primary canines. (A) Significant lower incisor crowding and malpositioning evidenced by advanced lower right primary canine resorption with ectopic positioning of adjacent lateral incisor, lower dental shifting toward right, and retained lower left primary lateral. Due to imminent loss of the lower right canine and malpositioning, a decision was made to extract the primary canines bilaterally. (B) Same patient 1 year later with symmetry and integrity of lower incisor alignment. Patient is on course for either serial extraction protocol or setup for arch development, depending upon other variables.

incisor liability and crowding are greater than 4 mm in the anterior segment. However, the clinician must remember that early loss of lower primary canines will likely result in significant lower arch collapse. Therefore the extraction of primary canines should not be undertaken without parental understanding of the consequences and, ideally, orthodontic consultation. Given the long-term implications, such intervention goes beyond the first step in guidance of eruption and actually represents the start of either a phased early treatment program or a serial extraction program. On a final note, some clinicians advocate primary canine extraction to aid in alignment of the lower permanent incisors for fear of increased caries risk secondary to the incisor malalignment. However, Alsulaiman et al.<sup>49</sup> found no association with maxillary and mandibular incisor irregularity, although it is well known that there is associated plaque retention.

### ERUPTION GUIDANCE IN THE MANDIBULAR CANINE AND PREMOLAR SEGMENT

For a child between 10 and 12 years of age, radiographic evaluation of the buccal segments provides particular consideration in eruption guidance relative to primary resorption patterns, eruption sequencing, molar adjustments to achieve Class I relationships, and usage of leeway space. Because the lower canine and first premolar often erupt nearly concurrently and are larger than their primary predecessors, they often take a mesial eruption path, with the canine overlapping the lateral incisors. To minimize such malpositioning, their timely transition along with concurrent disking of the mesial surface of the second primary molar may provide up to 2–3 mm of space for their distal positioning (Fig. 23.50). The second premolars usually erupt about 1 year later, frequently taking a path of





**Fig. 23.50** Eruption guidance with sequential disking and selective extraction of primary teeth. (A) Pretreatment alignment with mesial eruption path of permanent canines to overlap incisors. (B) Alignment at 5 months after elective extraction of primary first molars and disking of the mesial surfaces of the second primary molars. (C) Permanent canines and first premolars have erupted in distal orientation with reduction in anterior crowding. (D) After eruption of second premolars, good arch form is established, with overall adequate space and easily correctible minor rotations.

eruption along the distal root of the second primary molar. Extraction of the second primary molar is sometimes indicated to allow for normal eruption of the second premolar, if such an atypical pattern is noted. In addition to assessing eruption of the second premolars, the clinician should consider placement of a lingual holding arch concurrent with removal or exfoliation of the second primary molars (Fig. 23.18). If the available buccal segment space is tight, the optimal use of leeway space for crowding is desirable, and/or the second permanent molars are erupting before the second premolars, the lingual arch may be a critical element in controlling overall arch dimensions.

Treatment-based articles have documented positive alignment effects in the use of passive lingual holding arches for control of leeway space when used in the late mixed dentition. Dugoni et al.<sup>50</sup> published findings in 25 mixed dentition patients with reductions in lower incisor crowding of greater than 3 mm after placement of passive lingual arches and selected primary molar extractions. After an average postretention period of 10 years, 19 of the 25 patients continued to show clinically satisfactory lower anterior alignment. When compared with 10-year follow-up studies of orthodontically aligned patients, these results suggest that stability of the alignment with lingual arch therapy was greater than or at least equal to that of active orthodontic treatments. Using cephalograms, study models, and tomograms of the mandibular body, Rebellato et al.<sup>51</sup> reported dimensional changes in 14 mixed dentition patients with incisor crowding of 3 mm or more who were treated with passive lingual arches in comparison with 16 untreated control individuals. In lingual arch patients, the arch length did not measurably change through eruption of the succedaneous teeth compared with an average arch length decrease of 2.5 mm per side in the untreated

control individuals. Arch length changes were related to first molars moving forward +1.7 mm in the control group compared with only +0.3 mm in the lingual arch group. Concurrently, incisors tipped forward slightly in the lingual arch group (+0.4 mm), whereas uprighting of incisors in the controls reduced the arch length to 0.65 mm. In brief, the lingual arch reduced the mesial molar migration and incisor lingual movement in controlling arch length, with concurrent relief of 3–4 mm of lower incisor crowding in the treatment population. Brennan and Gianelly<sup>52</sup> quantified dimensional changes in 107 consecutive mixed dentition patients treated with passive lingual arches through eruption of all succedaneous teeth, with occasional extraction of second primary molars being the only other intervention. Arch length decreased an average of 0.4 mm, whereas width increased slightly in lingual arch patients. The resultant average +4.4 mm of total available leeway space produced an average decrease in lower incisor crowding from a pretreatment of –4.8 mm to +0.2 mm of space after treatment. The space adjustments were enough to resolve incisor crowding completely in 65 individuals (roughly 60%). An additional 16 individuals (1 in 6) had a final discrepancy of less than 1 mm, and 13 (1 in 10) had a final discrepancy of less than 2 mm. Only 14 patients (13%) had crowding greater than 2 mm after full buccal segment eruption was complete. Of note, the majority of patients with higher levels of postlingual arch crowding presented with initial ectopic loss of the lower primary canines. In sum, a passive lingual arch with selected removal of primary teeth provided adequate space and eruption guidance to relieve significant lower incisor crowding in 105 of the 107 individuals.

These studies consistently confirmed that arch length remains relatively constant or decreases minimally in

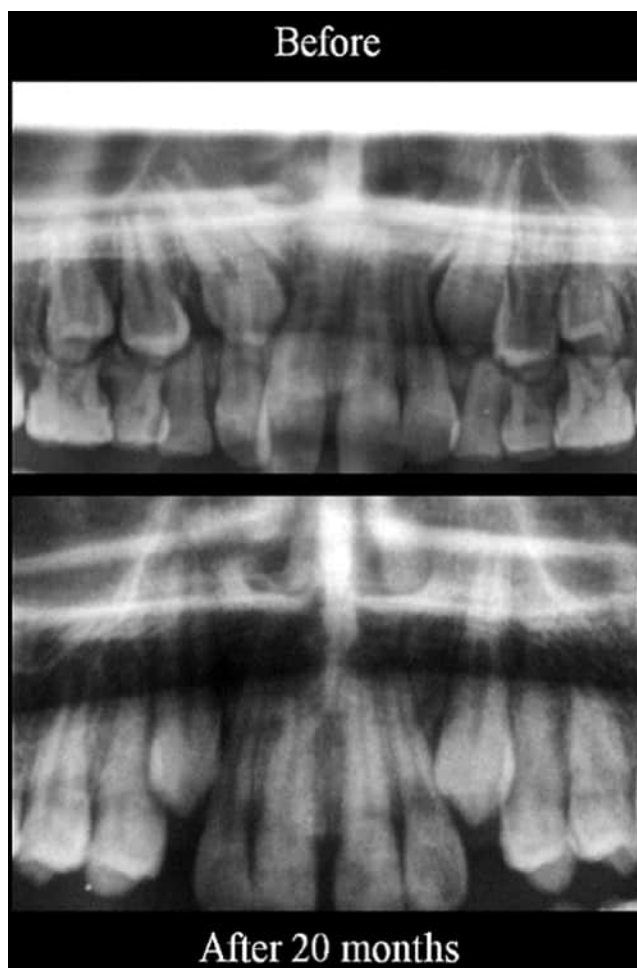

patients treated with a passive lingual arch by reducing forward movement of molars and lingual movement of lower incisors. Timely treatment not only maintains arch length but also allows for distal eruptive positioning of canines and premolars as a positive influence on relief of mixed dentition crowding in the 2- to 4-mm range, enough to relieve lower crowding in about two-thirds to three-fourths of patients.

### ERUPTION GUIDANCE IN THE MAXILLARY CANINE AND PREMOLAR SEGMENT













In the 7- to 8-year-old child, maxillary permanent canine positioning approximates the distal aspect of the root of the lateral incisor. This is associated with a normative distal tipping of the lateral incisor crowns under the fulcrum pressure of the canine at the lateral root area. The maxillary canine then normally deflects with a more vertical positioning toward the primary canine root area as eruption continues, with a concurrent more labial orientation of the canine. This labial orientation can be noted clinically by bulging in the vestibular aspect of the alveolar process. As resorption of the primary canine proceeds in normal patterns, the adjacent maxillary lateral incisor crown should tip mesially as vertical eruption of the permanent canine continues down the primary canine root length. With exfoliation of the primary canine, the maxillary permanent canines typically emerge with a slight labial orientation that tends to lingualize into the arch form as eruption proceeds under the balancing forces of the perioral tissues.

Given this tortuous and long journey, permanent maxillary canine eruption disturbances resulting in severe displacement and/or impaction are reported in 2% of the population, with females affected three times more frequently than males. As the final succedaneous tooth to erupt in the maxilla, mesiolabial displacement of the permanent canine is usually due to an arch length deficiency as the canine assumes whatever space is left over in the quadrant. In contrast to labial displacement, arch length deficiency appears to be less of a factor in palatal impactions because 85% demonstrate adequate arch length in the involved quadrant. An etiologic factor in true palatal impactions may actually be excessive space in the canine area rather than a lack of arch length. When maxillary lateral incisors are absent, peg-shaped, or smaller than the lower incisors, palatally displaced maxillary canines are noted in approximately 40%–45% of patients. When the ectopic permanent canine is close to the root of the lateral incisor, notable displacement of the incisor and idiopathic root resorption of the incisor may occur. The resorption is often difficult to diagnose because most of the lesions are located palatally toward the middle and apical thirds of the incisor, with the overlapping canine crown concealing radiographic visualization of the resorptive process. It has been reported that up to 12.5% of ectopic palatally positioned canines cause resorption of the adjacent incisors. In about half of the cases analyzed, the resorption extends into the pulp of the involved teeth, with the degree of resorption ranging from loss of one-fourth of the root to almost complete loss of root structure. The actual percentage of resorption occurrence may be much higher than reported due to inherent limitations of the two-dimensional radiographs used by most clinicians.



**Fig. 23.51** Example of bilateral impaction of the maxillary permanent canines corrected by bilateral extraction of the primary canines and first molars; before and after extractions. (Giulio AB, Serena IP, Matteo Z, et al. Double vs single primary teeth extraction approach as prevention of permanent maxillary canines ectopic eruption, *Pediatr Dent*. 2010;32(5):407–412.)

Screening for potential displacement and impaction of maxillary canines should start at 10–11 years of age with clinical and radiographic examinations to include evaluation of eruption trajectory, symmetry of positioning, status of root development, and orientation to the adjacent lateral incisor and primary canine. In cases of mesially displaced maxillary canines with overlap of adjacent permanent lateral incisor roots beyond 10 years of age, timely removal of the adjacent primary canines, and often simultaneously the first primary molars, greatly enhances the possibility for more distal and vertical eruptive directions (Fig. 23.51). This timing coincides with when eruptive forces are optimal, as the permanent canine attains approximately two-thirds root development. Once the apices of the canine are three-fourths or more formed, the eruptive force is reduced and the tooth will more likely have to be actively moved into the mouth. The clinical examination should involve palpation of the buccal aspect of the alveolar bone in the canine region slightly above the primary canine. A canine bulge should be evident, indicating the presence of the canine in a normal path of eruption at this stage of development. Although the presence of the buccal bulge does not necessarily preclude

Category	Good Prognosis	Average	Poor
Overlap of incisor	No horizontal overlap 	Up to half root width 	Complete overlap 
Vertical height	CEJ – halfway up root 	>half <full root length 	>full root length 
Angulation	0–15° 	16–30° 	>30 
Position of apex	Above canine position 	Above 1st premolar 	Above 2nd premolar 

**Table 1.** Prognosis for realignment depending on assessment in various categories. Key – Green:good prognosis;Yellow:average prognosis;:poor prognosis

**Fig. 23.52** Prognosis for realignment, depending on assessment in various categories. Green: good; Yellow: average; Pink: poor. (Guidelines for the assessment of the impacted maxillary canine, Kate Counihan, Ebrahim A. Al-Awadhi, Jonathan A. Butler Dental update 2013;40(9):770–772, 775–777.)

the possibility of impaction, the absence of such a clinical indicator by 10–11 years of age should warrant exploration. A major clinical clue to significant canine malpositioning involves excessive distal and labiolingual tipping of the lateral incisor crown. This suggests that the erupting canine is placing fulcrum-type pressure on the lateral root, “pushing” the root mesially to tip the crown in a distal direction. If the lateral crown is tipping labially, the permanent canine is probably displaced in front of the lateral root. If the lateral crown is tipping in a lingual direction, the canine crown is more likely to be displaced behind the lateral root. Other clinical signs include delayed eruption of the canine beyond 13–14 years of age, with prolonged retention of primary canines, and soft tissue bulging either too high in the vestibule or palatally.

Radiographic evaluation of the maxillary canine area should be particularly emphasized when lateral incisor inclinations are pronounced (as noted before), when small maxillary (pegged) lateral incisors are present, when primary canines are not appropriately mobile, and when the eruptive bulging of the canines is atypical. Although excessive mesial inclination resulting in overlap of the canine crown with the lateral incisor roots, as observed on radiographs, may suggest potential impaction, this prognostic

sign can be applied reliably only if the overlapping is present after root development of the lateral incisors is almost complete and the canine has attained approximately two-thirds root development (i.e., around 10–11 years of age). At that point, the degree of overlap of the canine crown with the lateral incisor root and the resorption pattern of the primary canine and first primary molars are key indicators for potential canine impaction and for the prognosis of successful interceptive guidance. Localization of the labial or lingual positioning of the tooth by special radiographic techniques is essential. (Procedure with specifically positioned periapicals or cone beam computed tomography described in [Chapter 2](#) help in this localization.) Studies indicate that if the displaced permanent canine overlap of the adjacent permanent lateral incisor is not beyond the midline long axis of the lateral (still toward the “distal” half of the root), the chances for the canine repositioning and erupting into normal position after primary canine extraction show roughly 85%–90% success. If the canine overlap is beyond the lateral incisor’s long axis (toward the mesial half of the root or beyond), successful repositioning drops to approximately 60% of cases, with extraction of the primary canine ([Fig. 23.52](#); Reprinted from: Counihan et al. 2013).

Follow-up at 1 year after the primary canine extraction should find significant improvement in canine positioning. If not improved, the canine is probably positioned toward the palate and will require complicated treatment options, including surgical exposure with removal of obstructing structures to allow “hoped-for” passive eruption, surgical exposure with active orthodontic traction to move the tooth into position, autotransplantation of the impacted canine into the proper position, or extraction of the impacted canine and substitution by the first premolars. Surgical exposure that allows for natural eruption is dependent on the displaced tooth having a reasonable axial inclination and incomplete root development to achieve eruptive potential. When conditions for “passive” eruption are not met, an active approach involving surgical exposure followed by active orthodontic traction applied to the tooth may be necessary. Orthodontic traction involves complex biomechanical force parameters of direction, duration, amount, and method of activation in positioning the tooth, which are beyond the scope of our discussion.

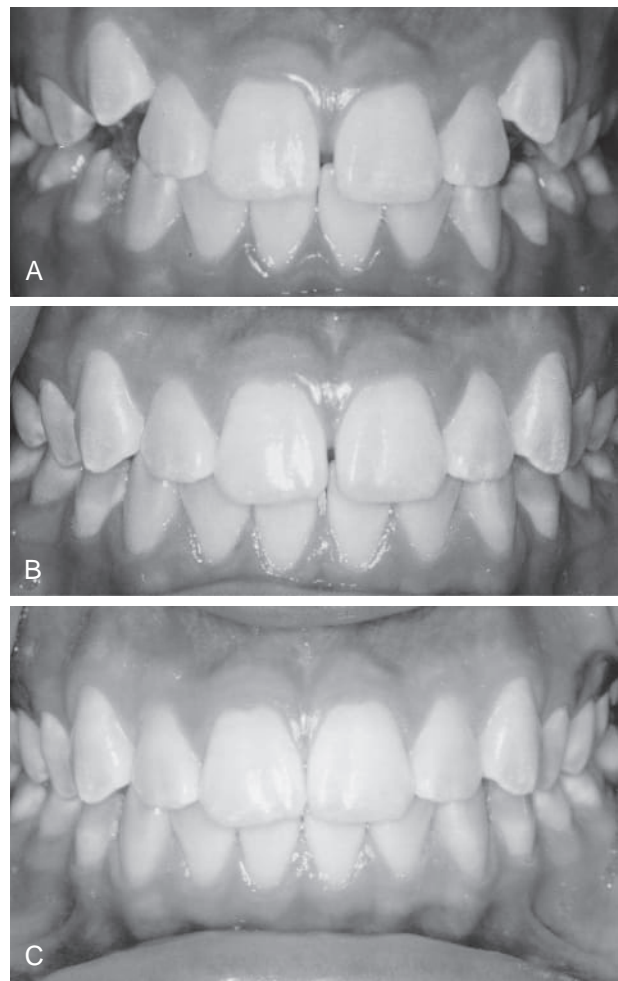
### Maxillary Anterior Diastemas

Parents are often concerned about anterior spacing that presents during eruption of the maxillary dentition. Unless there is a valid reason to intervene early, active treatment should be postponed until the complete eruption of the permanent canines because anterior spaces often close spontaneously as the lateral incisors and particularly the permanent canines erupt. After the canines erupt, the condition can be reevaluated and appropriate treatment taken as needed. Fig. 23.53 shows a patient whose parent wanted the diastema closed and was concerned about the high position of the canines. No treatment was begun. The 24-month follow-up image shows that diastema closed, with the canines in reasonably good alignment.

Valid reasons for early closure of excess maxillary spaces may be in consideration of atypical or asymmetric eruption patterns. Lateral incisors may be erupting lingually without sufficient space to be aligned labially into the arch. The maxillary incisors may be excessively flared and “splayed,” with lip interpositioning that puts the teeth at risk for traumatic injury. Adjusting the symmetry of alignment, consolidating spaces, and retracting excessively proclined incisors may be indicated to facilitate long-term development. An extremely heavy labial frenum may prevent natural closure of a diastema. If orthodontic closure is advocated, it should occur before the frenectomy to reduce the chance of scar tissue impeding tooth movement. If there is sufficient arch space for the eruption of incisors and canines, it is best to delay frenum surgery until these teeth have fully erupted.

### Supernumerary Teeth

Supernumerary teeth can be associated with delayed eruption of permanent teeth, overretention of primary teeth, deflection of roots with unusual inclinations, displacement of teeth, diastemas, abnormal root resorption, and formation of follicular or dentigerous cysts (Fig. 23.54). Occurring approximately eight times more frequently in the maxilla than in the mandible, supernumerary permanent teeth have been reported in up to 3.6% of children. The occurrence of supernumerary teeth in several members of the same family has been observed, indicating a familial

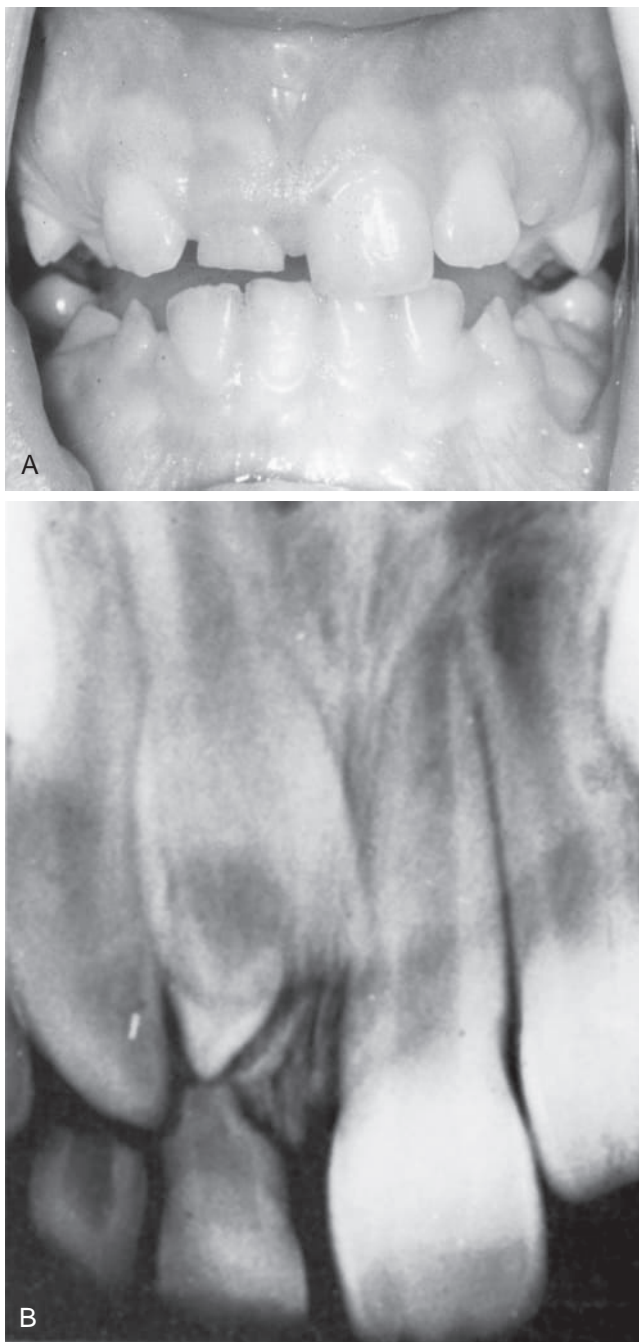


**Fig. 23.53** (A) Patient with midline diastema and highly positioned canines. No treatment was instituted. (B) After 24 months, the diastema has closed significantly and the canines are erupting into a more favorable position. (C) After 36 months, the diastema has closed completely, and the canines have assumed a near-ideal position.

pattern. The most frequent site is the maxillary anterior segment where atypically shaped accessory teeth of a conical tuberculated form, known as *mesiodens*, occur between the maxillary central incisors (Fig. 23.55). Reported in boys twice as often as in girls, 80% of mesiodens have a single occurrence, whereas 20% have two or more supernumerary teeth. The mesiodens usually presents a peg- or cone-shaped crown with a single root. More than 90% are palatally positioned. Approximately three of four mesiodens remain unerupted and commonly need surgical removal at some point during treatment because they often prevent eruption of adjacent permanent teeth or cause their ectopic eruption. Supernumerary primary teeth (Fig. 23.56) are apparently less common than supernumerary permanent teeth.

If a supernumerary tooth is identified through radiographic techniques (see Chapter 2), the decision whether to intervene surgically or keep the tooth under observation must be made. If the supernumerary tooth is not interfering with the symmetric development of adjacent teeth and there is no evidence of cyst formation, the correct decision may be to observe the tooth until the child is old enough to better tolerate the surgical procedure. Watchful waiting





**Fig. 23.54** (A) Patient with an unerupted maxillary permanent central incisor and retained primary central incisor. Permanent laterals are erupting. (B) Radiograph shows a supernumerary tooth (mesiodens), which has delayed the eruption of the permanent incisor.

until the development of the permanent incisors reaches approximately two-thirds to three-quarters root formation allows for less risk to the incisor development in the surgical procedures. Possible eruption of the supernumerary tooth and avoidance of surgical exposure are also potential benefits in delaying intervention. However, in the case of severe exfoliation and eruption irregularities, earlier removal of a supernumerary tooth and the over retained primary teeth may be desirable to lessen potential sequelae. The clinician must still consider the status of the adjacent permanent

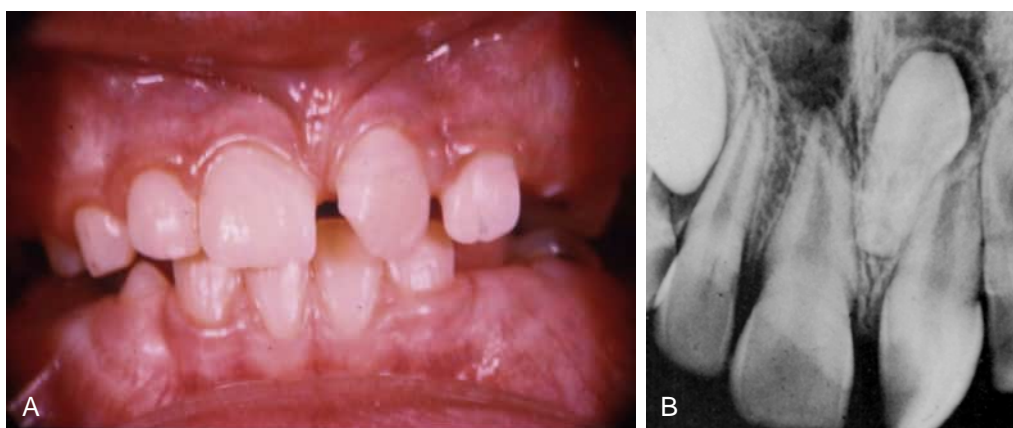
teeth and may prefer to wait until root development is preferably two-thirds established before surgically removing the supernumerary tooth.

When surgical removal is accomplished, exposure of the unerupted permanent tooth or teeth with provision of an eruption channel is recommended (Fig. 23.57). Reports suggest that up to 80% of permanent maxillary teeth will spontaneously erupt after the supernumerary is removed. During surgery, the bone and soft tissue should be removed from the incisal third of the tooth or teeth that are delayed in their eruption. If the permanent teeth are positioned extremely high, a prolonged period of watchful waiting may be necessary until they have migrated within the bone to a position that would allow for surgical intervention. An open pathway should be maintained, if possible, to hasten the eruption of the delayed tooth. A thin covering of dense scar tissue can delay eruption indefinitely. Ultimately, orthodontic treatment is often necessary to make adequate room for the unerupted tooth and to position it properly in the arch. Because of these considerations and the frequency with which supernumerary teeth are observed, radiographic surveys that include maxillary anterior views are essential for children at 5–7 years of age to allow for early detection and planning.

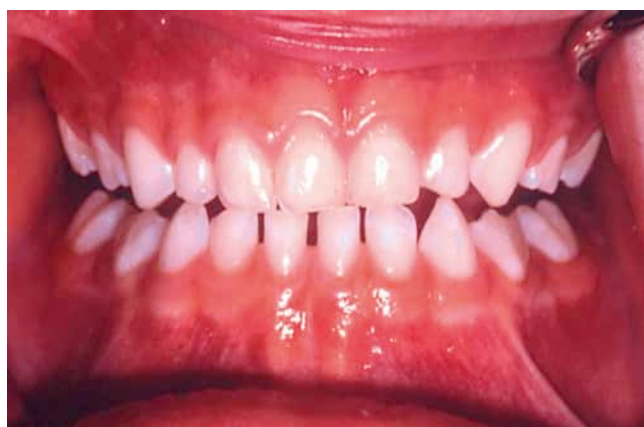### Congenitally Missing Teeth

Studies have reported that congenitally missing permanent teeth (excluding third molars) occur in 2.3%–9.6% of the population, with no significant gender differences. Oligodontia affects two or more teeth in about one-half of cases, frequently in a symmetric pattern involving antimeres. The most frequently missing permanent teeth are third molars (one to four wisdom teeth are absent in up to one-third of the population), mandibular second premolars, maxillary lateral incisors, and maxillary second premolars. Morphologic changes such as cone-shaped teeth are characteristically seen in association with missing permanent teeth—agenesis and peg-shaped maxillary lateral incisors approximate a 1:1 ratio. The congenital absence of primary teeth has a much lower prevalence than that of permanent teeth. The prevalence of missing primary teeth ranges between 0.1% and 0.7%, with absence usually located in the maxillary or mandibular incisor areas. When several primary teeth fail to develop, other ectodermal deficiencies are usually evident (e.g., ectodermal dysplasia). If the absence is localized to only one or two primary teeth, no specific treatment is generally needed. However, the long-term implications are significant because the analog of the permanent tooth is derived from the primary tooth bud. Therefore a missing primary tooth almost always means that the associated permanent tooth will be missing, with attendant occlusal factors.

The management of congenitally missing permanent teeth requires a thorough evaluation of arch length, occlusion, and facial growth patterns, given the long-term consequences to aesthetic and functional arch alignment in terms of which specific tooth is missing, adjacent teeth drifting into the space, the distribution of the space, and supraeruption of opposing teeth. Early consultation with the orthodontist and prosthodontist is important in determining appropriate care. If one or both of the permanent maxillary lateral incisors are missing, the dentist must



**Fig. 23.55** (A) Rotation and labioversion of a maxillary central incisor with midline diastema. (B) Radiographic assessment revealed a well-developed midline supernumerary tooth (mesiodens) with an inverted eruption path. Surgical removal of the tooth is indicated.



**Fig. 23.56** Supernumerary maxillary right primary lateral incisor positioned distal to the lateral incisor. There may be corresponding supernumerary permanent teeth. The teeth should be counted at the time of the clinical examination so that erupted supernumerary teeth will not be overlooked.

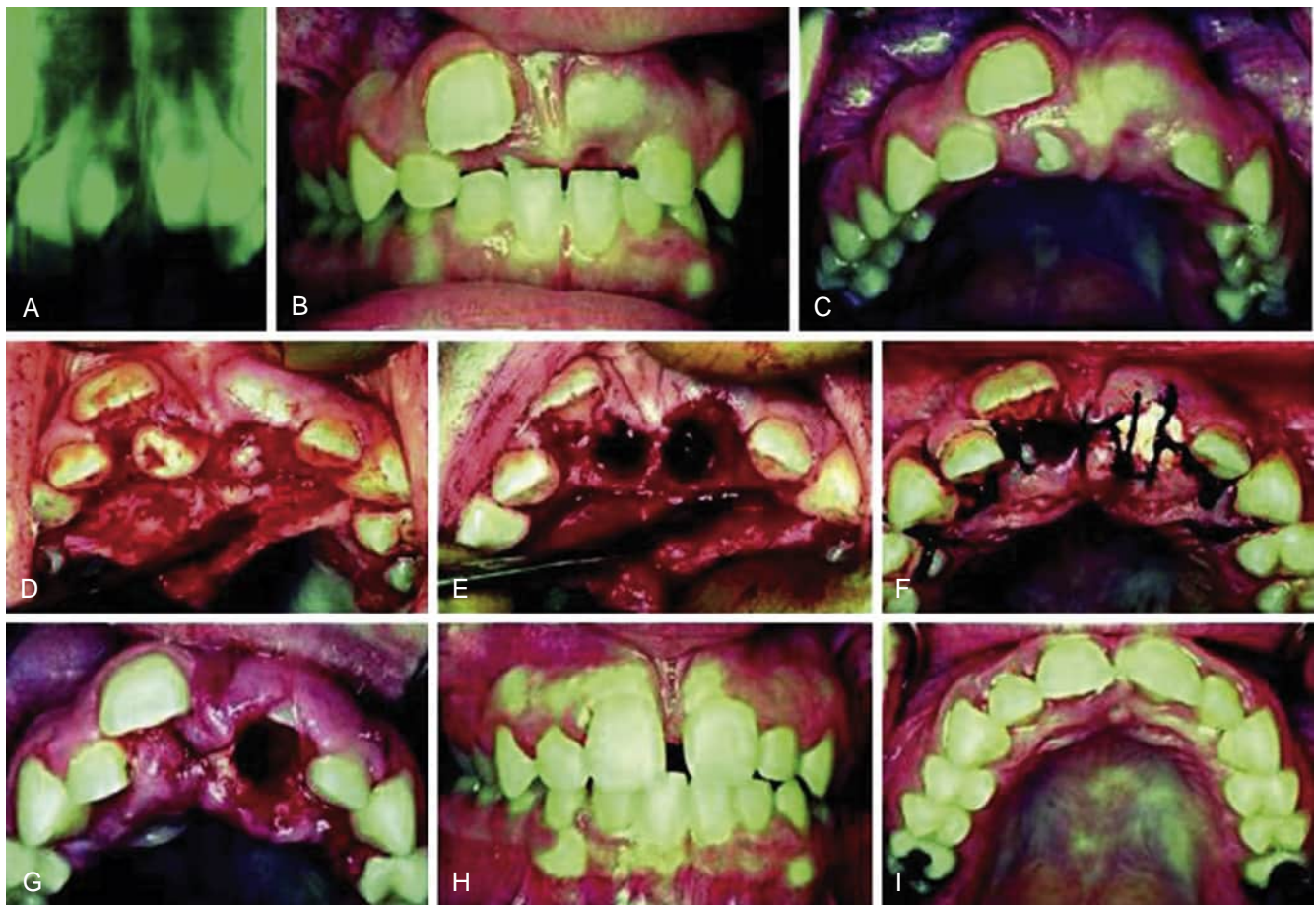decide whether to hold space for prosthetic replacements or to encourage the permanent canine to erupt mesially into the lateral incisor position. In the latter instance, the mesial eruption path of the adjacent permanent canines may erupt fully forward into the lateral space and naturally compensate for the missing lateral incisors. This pattern of “canine replacement” is particularly beneficial when the patient presents with excessive maxillary overjet and dental protrusion or a significant tooth size discrepancy that would benefit from an extraction protocol. Consolidation of the maxillary arch form with canine “replacement” leads to reduction of the protrusive overjet and compensation for a tooth mass discrepancy. Orthodontic treatment is generally needed to place the canine in the correct axial inclination before the crown is reshaped to resemble the lateral. In some instances, the shape of the canine may not be favorable to use as a lateral, even with extensive recontouring. In contrast, a patient with Class I or Class III relationships and more normal alignment spacing usually benefits from having the canines in their normal A-P positions and restoration of the missing lateral incisors with prosthodontic treatment (Fig. 23.58). If the canines are erupting too far

forward from their normal positions in this case, timely removal of the primary canines may enhance a more distal eruption path toward normal canine positions. However, with the advent of implants for replacement of lateral incisors, that recommendation has changed. According to Kokich,<sup>53</sup> the ideal situation is to encourage the canine to erupt adjacent to the permanent central incisor. After it has erupted, it can be moved distally into its normal position. By distal movement of the tooth, the bone is maintained in forming an alveolar ridge with adequate buccal lingual width to facilitate proper implant placement.

When one or more permanent premolars, usually the second premolars, are congenitally missing, should the space be maintained for fixed prostheses later or should it be closed? Many factors influence the decision whether to retain or extract the overlying second primary molar, including the degree of arch length deficiency, facial and skeletal patterns, molar relationships, vertical aspects of the malocclusion, anteroposterior incisor positioning, and stage of transitional dentition. For example, if just one premolar is absent and the rest of the occlusion is aesthetically and functionally sound, long-term retention of the primary molar is usually encouraged until growth is complete and prosthodontics can be used to replace the missing premolar. However, the larger mesiodistal width of the primary molar may cause incorrect occlusal relationships with the permanent teeth. Slicing the mesial and/or distal surfaces of the primary molar may allow for improved interdigitation, but often the bulbous, divergent roots of the primary molar prevent mesial movement of the permanent molar. Also, the roots of the primary molar may be resorbed, and the tooth may be lost eventually. To summarize, if the primary molar is maintaining vertical occlusion and arch length stability, then it should be retained for alveolar bone integrity and to allow for future implant prosthetics. An exception would be in a child with a significant tooth size–arch size discrepancy where a serial extraction protocol would provide successful aesthetic and functional outcomes. Early extraction would provide positive alignment factors without compromising long-term results because later orthodontic tooth movements will bring alveolar bone support.

The general concept of the primary molar being maintained when the underlying premolar is missing applies except when the retained primary molar exhibits significant





**Fig. 23.57** Surgical removal of supernumerary incisors with uncovering of blocked permanent incisors allows for normative eruption positioning of the involved incisors. (A) Radiograph showing two mesiodens associated with retained primary central incisors and delayed eruption of permanent central incisors at age 9 years and 6 months. The primary incisors were extracted at this time. (B) and (C) Same patient at age 11 years and 10 months. (D), (E), and (F) Surgical removal of two mesiodens with uncovering of unerupted incisor. (G) One week after surgery. (H) and (I) Same patient at age 13 years and 1 month. One year after surgical uncovering, no orthodontic appliances.

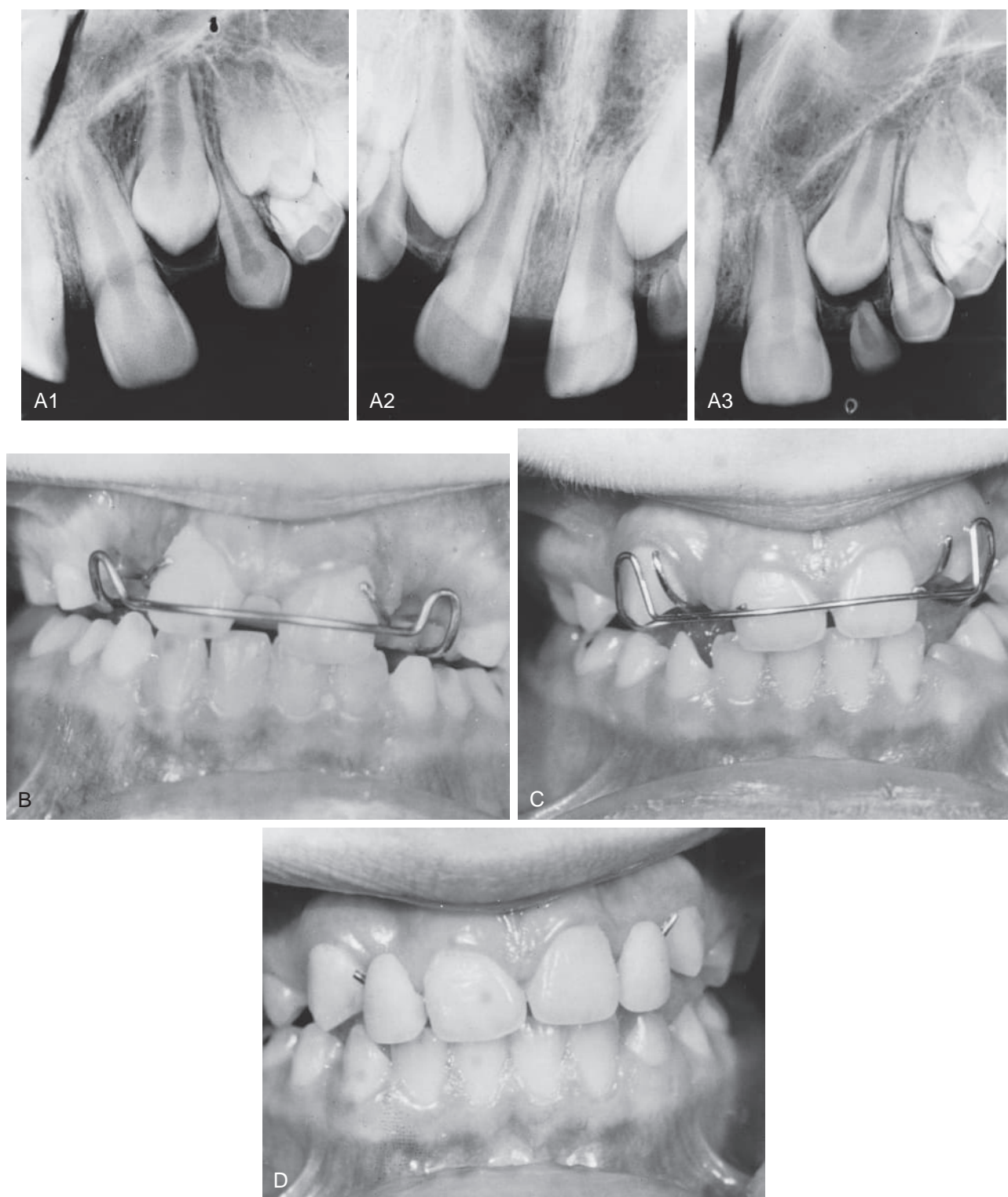
ankylosis. Restorative coverage (i.e., composite buildups, stainless-steel crowns) of the ankylosed primary molar may help maintain occlusal harmony if the vertical discrepancy is not extreme. In most cases, however, early extraction of the affected primary molar may enhance occlusal outcomes by avoiding excess vertical collapse and the loss of alveolar bone height that occurs secondary to early ankylosis. Even in cases of ankylosed second primary molars over missing premolars where future prosthetic replacement is planned, early extraction of the primary molar may be advisable. The consequence of leaving severely displaced ankylosed primary molars when the premolars are absent will likely result in vertically compromised alveolar heights of adjacent teeth because there is no erupting premolar to maintain alveolar ridge integrity. For these reasons, the early extraction of ankylosed second primary molars when the second premolars are congenitally absent should be an early treatment planning decision and is usually desirable. If such teeth are extracted early, the majority of alveolar ridge reduction secondary to the extraction will occur in the first year after removal, will represent about an overall one-third loss in width, and is not progressive. Adjacent tooth movements usually maintain adequate alveolar width for subsequent implant placement and establish better arch length adjustments for proper occlusion. Planning must

also consider whether to hold the space for future prosthetic replacement or allow “driftodontics” to start closing the space of the missing premolar. Early extraction is particularly indicated if the case can be handled long-term with a premolar extraction protocol and where multiple premolars are absent symmetrically. Given the long-term considerations, the treatment options available, and the multiple disciplines potentially involved, the clinician must take the lead role in coordinating treatment and utilizing the expertise of specialists.

## Obstructive Sleep Apnea and Orthodontics

An evolving area of interest to dentistry is the management of OSA in children. While the etiology for OSA is multifactorial, it seems clear that moderate to severe mandibular retrognathia may play a considerable role for some patients. While orthodontic interventions are not mentioned in the 2012 American Academy of Pediatrics Guidelines for Diagnosis and Management of Childhood Obstructive Sleep Apnea Syndrome, they are considered by some sleep medicine experts to be an alternative treatment option and are cautiously recommended in the 2016 American Academy





**Fig. 23.58** (A) Congenital absence of permanent lateral incisors shown on periapical radiographs. (B) The primary canines were extracted to encourage a more distal eruption path of the permanent canines. A Hawley-type appliance with springs was constructed to close the diastema between the central incisors. (C) Auxiliary wires were added to the appliance to guide the permanent canines into a more favorable position. (D) Space has been regained for eventual fixed prostheses to replace the lateral incisors. Meanwhile, the removable retainer with lateral pontics is worn.

of Pediatric Dentistry Policy on Obstructive Sleep Apnea (AAPD 2016 Policy on Obstructive Sleep Apnea).<sup>54</sup>

As discussed by Canto et al.,<sup>55</sup> sleep-disordered breathing is of significant relevance to practicing dentists because it has been associated with a variety of oral and craniofacial

problems including chin retrusion, Class II malocclusion, vertical growth direction, and sleep bruxism. While it seems clear that dentistry has an opportunity to contribute in this significant problem area for children, comprehensive diagnosis and management are beyond just the placement

of mandibular advancement appliances, such as those described in the following section. Therefore it seems reasonable that the team approach—involving a pediatrician, dental practitioners, sleep disorder centers that can provide definitive diagnostic techniques such as a polysomnogram, and others—is important to ensure that the problem is diagnosed and managed appropriately. Clearly, pediatric dentists can play a significant role in diagnosing breathing-related sleep disorders through evaluation of the skeletal factors such as small maxillas and small and/or retropositioned mandibles.<sup>56</sup> Finally, the 2019 AAO White Paper on Obstructive Sleep Apnea and Orthodontics<sup>56</sup> (AAO eBulletin, February 25, 2019; <https://www.aaoinfo.org/system/files/media/documents/sleep%20apnea%20white%20paper%20FINAL%202019.pdf>, accessed June 27, 2019) makes several significant statements:

1. Only a physician can definitively diagnose OSA.
2. Regardless of the presence of OSA, it is recommended that the orthodontist uses expansion devices only when there is an appropriate underlying skeletal condition. There is no indication in the literature that prophylactic application of maxillary expansion prevents the future development of OSA.
3. There is no clear indication in the literature that prophylactic use of mandibular anterior repositioning appliances prevents later development of OSA.
4. No guarantees of OSA resolution can be implied or stated emphatically by the treating orthodontist.

## Comprehensive Orthodontics for the Developing Occlusion

Comprehensive orthodontics can be defined as an in-depth evaluation of a patient's entire orofacial complex and the corrective treatments necessary to achieve optimal dental aesthetics, facial aesthetics, skeletal balance, and functional harmony. Comprehensive orthodontic treatment recognizes more broadly based malocclusion factors than those cited in interceptive orthodontics and guidance of eruption. Diplomates of the American Board of Orthodontics (ABO) listed the correction of skeletal Class II and Class III malocclusions, excess vertical development, and severe tooth size–arch size discrepancies presenting displaced permanent teeth as complex problems indicated for comprehensive levels of early treatment intervention.<sup>57</sup> The achievement of functional and aesthetic harmony requires the coordination of a multitude of factors, from the fine details of tooth positioning to the relationships of the maxilla and mandible.<sup>58</sup> Since “normality” encompasses a variable range, the fundamental goals of comprehensive orthodontic management of the occlusion may be delineated as the possession of:

1. *Dental aesthetics*: The tooth alignment and arch form are generally consistent with orthognathic Class I molar positioning, normal anterior overbite and overjet, integrity of dentitional alignment, and symmetric arches positioned over the basal bone. The details of these dental aesthetic descriptors are best defined in the context of the “six keys of occlusion,” as delineated by Andrews,<sup>58</sup> to include proper molar relationship, proper crown

angulation and inclination, no rotations, tight contacts, and a flat occlusal plane.

2. *Facial aesthetics*: Balanced facial profile and frontal symmetry with harmonious relationships among the jaws, teeth, and soft tissues are realized within the context of normal facial developmental patterns relative to patient age, ethnic/racial differences, and growth patterns.
3. *Optimally functional occlusion*: The interplay of gnathologic factors allows for comfortable and efficient actions of the orofacial components in a harmonious neuromuscular environment without deleterious stress on the teeth, periodontal structures, and temporomandibular joints.
4. *Stability of occlusion*: When applied to postorthodontic treatment, the interrelationships of the teeth, jaws, and soft tissues should not only meet the aesthetic and functional goals of treatment but also be sustained with long-lasting stability and retention of achieved goals.

Comprehensive orthodontic treatment usually requires complete fixed Edgewise appliances to achieve final positioning of all or nearly all of the permanent teeth into optimal aesthetic and functional harmony within the alveolar basal bone. If a practitioner decides to initiate comprehensive levels of orthodontic care, it is important that he or she accepts responsibility to provide the treatment to full completion standards. It is not appropriate to provide only one phase of treatment with the intention of referring the patient for the final and definitive phases of care unless the separate treatments were predetermined between consulting providers. If the practitioner recognizes the need for, but is unwilling or unable to provide, comprehensive care, it is appropriate to refer the patient to a practitioner able to address all of the orthodontic needs.

The interventions necessary to achieve comprehensive goals may be accomplished in one single phase or in specifically planned phases of treatment. To determine the approach in most patients, the preferred time for evaluating comprehensive orthodontic needs and implementing treatment is from the transitional mixed dentition into the young permanent (adolescent) dentition. The ABO Diplomates have stated that there are numerous advantages for both the patient and the practitioner in terms of early orthodontic treatment and, importantly, that the final results of early treatment tend to be better. The basis for these statements lies in the fact that the clinician has the ability, with mixed dentition timing, to control arch length adjustments in terms of leeway space and late mesial molar shifts for the relief of most levels of crowding, to utilize space gaining and arch expansion procedures in reducing extraction needs, to control incisor and buccal segment eruption patterns for adjustments in overbite, open bite, and leveling of the curve of Spee, to control deleterious habits and functional deviations in occlusion, and to use growth modification with dentofacial orthopedics for skeletal discrepancies. Most of the January 1998 and June 2002 issues of the *American Journal of Orthodontics and Dentofacial Orthopedics* are dedicated to a broad range of topics related to the rationale for common procedures used in early orthodontic treatment. These issues serve as excellent reference sources for review.

A convenient way to look at comprehensive orthodontics in the context of “early” treatment is to relate it in terms of

the developmental stage of the dentition. The dental stages in which comprehensive treatments are considered for growing patients involve the full primary to the mid-mixed dentition through transitional eruption of the first molars and incisors (4–10 years of age), the mid- to late mixed dentition overlapping the transition of the buccal segments (10–12 years of age), and the early permanent dentition (12–16 years of age). The general scope of interceptive orthodontic interventions in these stages is outlined earlier in this chapter. They serve as a focus for the presentation of case examples that illustrate the more comprehensive treatments necessary to address more complex needs in growing patients.

### PRIMARY TO MID-MIXED DENTITION (AGES 4–10 YEARS)

If not corrected early, abnormal dental, skeletal, and functional relationships that are notable in the primary dentition may have profound effects on the orofacial growth patterns. They can become increasingly difficult to correct as the child transitions toward the permanent dentition. Some of the more significant problems that can be treated effectively in the primary dentition involve functional and bilateral posterior crossbites along with deleterious oral habits. As illustrated in earlier sections, significant orthodontic and orthopedic changes can be affected with various “interceptive” appliances in this period. A further example of primary dentition intervention that potentially extends into more comprehensive concepts is shown in Fig. 23.59 with correction of a pseudo-Class III malocclusion. Without such early treatment, the functional aspects of the malocclusion could carry over into much more complex skeletal problems, as growth continues to compensate for the deviations. It is not necessarily the intent of an early phased treatment to prevent the need for full Edgewise appliances in the permanent dentition. The goal is to establish normal vertical, transverse, and sagittal relationships of the dentition with functional perioral balance. However, as illustrated in this interceptive case, it is possible to establish such a harmonious relationship of the dental units that further treatment is unnecessary. Such an outcome is also illustrated in Fig. 23.60, where more involved early treatment mechanics were used. Each of these cases supports the idea that the real goal of such treatment in developmental stages should be to minimize or eliminate the amount of orthodontic treatment needed in the permanent dentition, with more ideal outcomes. The remaining cases presented involve just such comprehensive treatments where Edgewise appliances were used to finish the treated occlusion toward optimal functional and aesthetic outcomes.

Correction of Class II skeletal relationships in the primary and early mixed dentition stages with functional appliances and extraoral headgear has been reported in the literature. In contemporary practice, however, Class II malocclusions are generally managed from the mid- to the late mixed dentition, extending on into the young permanent dentition, with positive outcomes. This later timing coincides with the pubertal growth period for enhanced dentofacial orthopedics and the transition of the buccal dentition to optimally affect sagittal dentoalveolar corrective changes.

In addition, later timing simplifies retention considerations of any achieved correction by reducing the time between the early treatment phase, the full Edgewise phase, and the completion of growth. In contrast, skeletal Class III relationships can be addressed in the primary and incisor transition periods to establish normative overbite and overjet relationships into the mixed and permanent dentitions. Class III corrections in this time frame with reverse-pull headgear have been consistently shown to present efficient and effective treatment outcomes compared with later treatment timing. This particularly applies if the Class III pattern involves a retruded maxillary complex as the causative factor or if the anteroposterior discrepancy is the result of a functional anterior displacement of the mandible (pseudo-Class III). If the major component of the Class III pattern is a severe skeletal overgrowth of the mandible, attempts at correction are more variable and often require retreatment as the lower jaw outgrows the correction. This is especially true if there is a strong genetic/familial component to the mandibular prognathia.

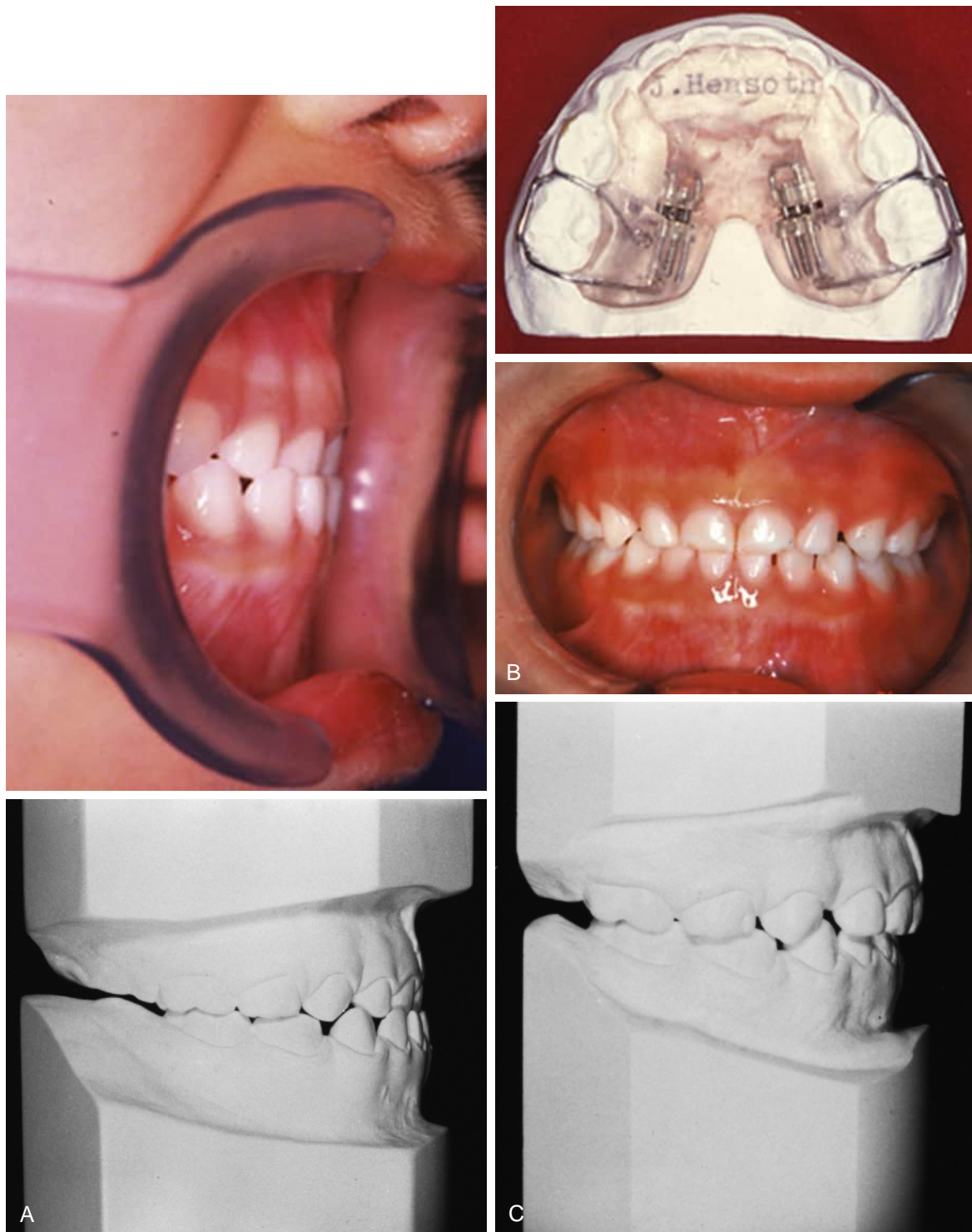
Vertical growth abnormalities can also be successfully managed in this early transitional period. Patients with deep overbites and a horizontal growth pattern (low mandibular plane angle) may benefit from a removable anterior bite plane to allow for supraeruption of the posterior dentition.

Because the permanent incisors and first molars have erupted by ages 8–9 years in both arches, fixed Edgewise appliances can be placed in a segmental fashion to accomplish specific dental orthodontic movements. Molar-to-incisor bracketing treatments ( $2 \times 4$  setup) generally last 6–12 months and are designed to correct severe and detrimental displacements in establishing normative overbite and overjet of the incisor segments. After the  $2 \times 4$  mechanics, the patient is typically placed in a resting retention phase until full eruption of the permanent dentition is established around ages 12–13 years. A first-phase approach involving a  $2 \times 4$  setup with a transpalatal bar for anchorage to help correct a Class II division 2 deep-bite malocclusion at age 9 years and 4 months is presented in Fig. 23.61. Lower arch development was enhanced with a mandibular lip bumper during the upper retention phase. Full Edgewise appliances followed in the permanent dentition to finalize alignments (age 12 years and 10 months).

### MID- TO LATE MIXED DENTITION (AGES 10–12 YEARS)

Given that the majority of patients present with Class I skeletal relationships and that any malocclusion requiring treatment most likely involves crowding, the incorporation of space supervision concepts with the control of leeway space is a major component of treatment in the late mixed dentition. Addressed in a sequential consideration of guidance in an earlier section of this chapter, Fig. 23.62 illustrates the value of a mandibular lingual holding arch in the relief of lower anterior crowding at 11 years and 8 months of age in controlling leeway space. Class I molar relationships were maintained with the lingual arch and selective primary extractions over 18 months of space supervision. Seventeen months of full Edgewise appliances completed the alignment (15 years and 5 months).





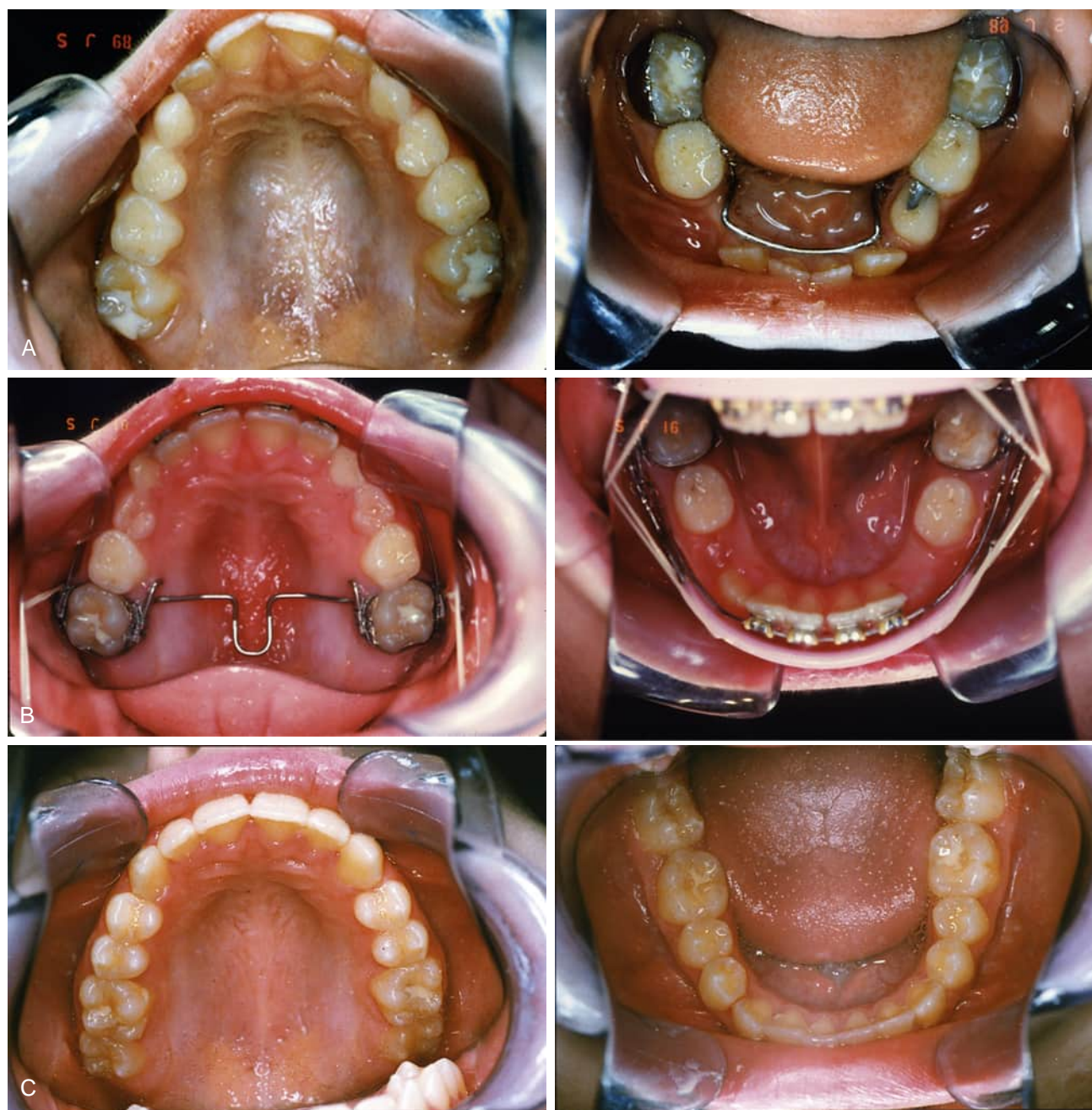
**Fig. 23.59** Primary dentition anterior crossbite with functional shift of mandible. (A) Pretreatment clinical and model view of occlusion. (B) Anterior sagittal appliance designed to labialize the primary incisors. (C) Posttreatment clinical and model view of occlusion.

Patients who present with skeletal Class II malocclusions often benefit from dentofacial orthopedics involving directed extraoral headgear mechanics and/or mandibular advancement (functional) appliances during the late mixed dentition period. The growth modification appliances, timed with pubertal growth, enhance maxillary to mandibular skeletal and dental relationships in preparation for full Edgewise appliances to finish and detail final alignment.

Mid- to late dentition treatments in managing the occlusion, with full Edgewise appliances to follow in the permanent dentition, typically involve:

*Space supervision:* To hold lower leeway space (lingual holding arch), hold upper leeway space, and derotate permanent first molars (transpalatal bar).

*Expansion appliances:* Transpalatal arch bars, Hyrax, lip bumpers.



**Fig. 23.60** Patient treated with phase I orthodontics only. (A) Pretreatment occlusal views; note tapered maxillary arch and arch length insufficiency in the mandibular arch. (B) Phase I treatment with fixed 2 × 4 Edgewise appliances, maxillary transpalatal bar, and mandibular lip bumper. Note arch length development, particularly in the lower arch. (C) Posttreatment occlusal views in permanent dentition without additional full Edgewise bracketing.

**Fixed Edgewise appliances and archwires:** Banded molars and bracketed incisors for 2 × 4 mechanics. Allows for molar derotation and uprighting, incisor leveling, incisor alignment, and incisor protraction or retraction.

**Extraoral headgear:** Directed cervical-pull, high-pull, or protraction reverse-pull headgear applications, with selection dependent on the vertical and sagittal facial growth patterns as well as the stage of development. Often used with anterior bite planes.

**Functional appliances:** Removable (e.g., Bionator) and fixed (e.g., Herbst) mandibular advancement appliances serve as examples of many options for Class II problems. Reverse-pull

facemasks and maxillary and mandibular miniplates with orthopedic traction are examples for Class III problems. The type of functional appliance and its design vary significantly depending on the facial growth pattern.

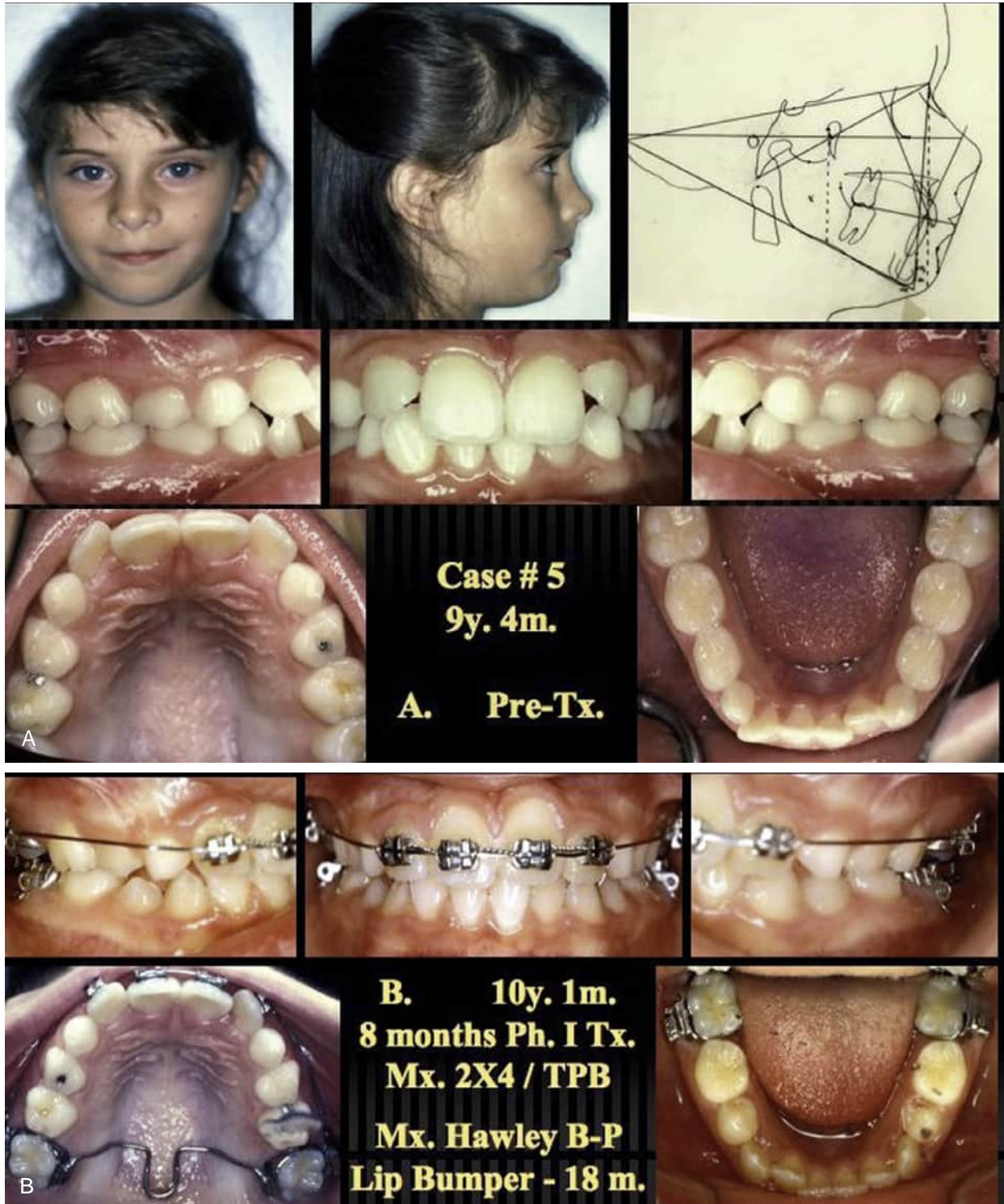
**Selected extractions:** Timely removal of both primary teeth and selected permanent teeth in guidance and serial extraction protocols optimizes the use of available space. The patient's diagnosis influences which "early" treatment modalities would be appropriate. One pervasive philosophy in early orthodontic treatment is that the simplest biomechanics necessary to achieve the desired treatment outcome is the best.



## EARLY PERMANENT DENTITION (AGES 12–16 YEARS)

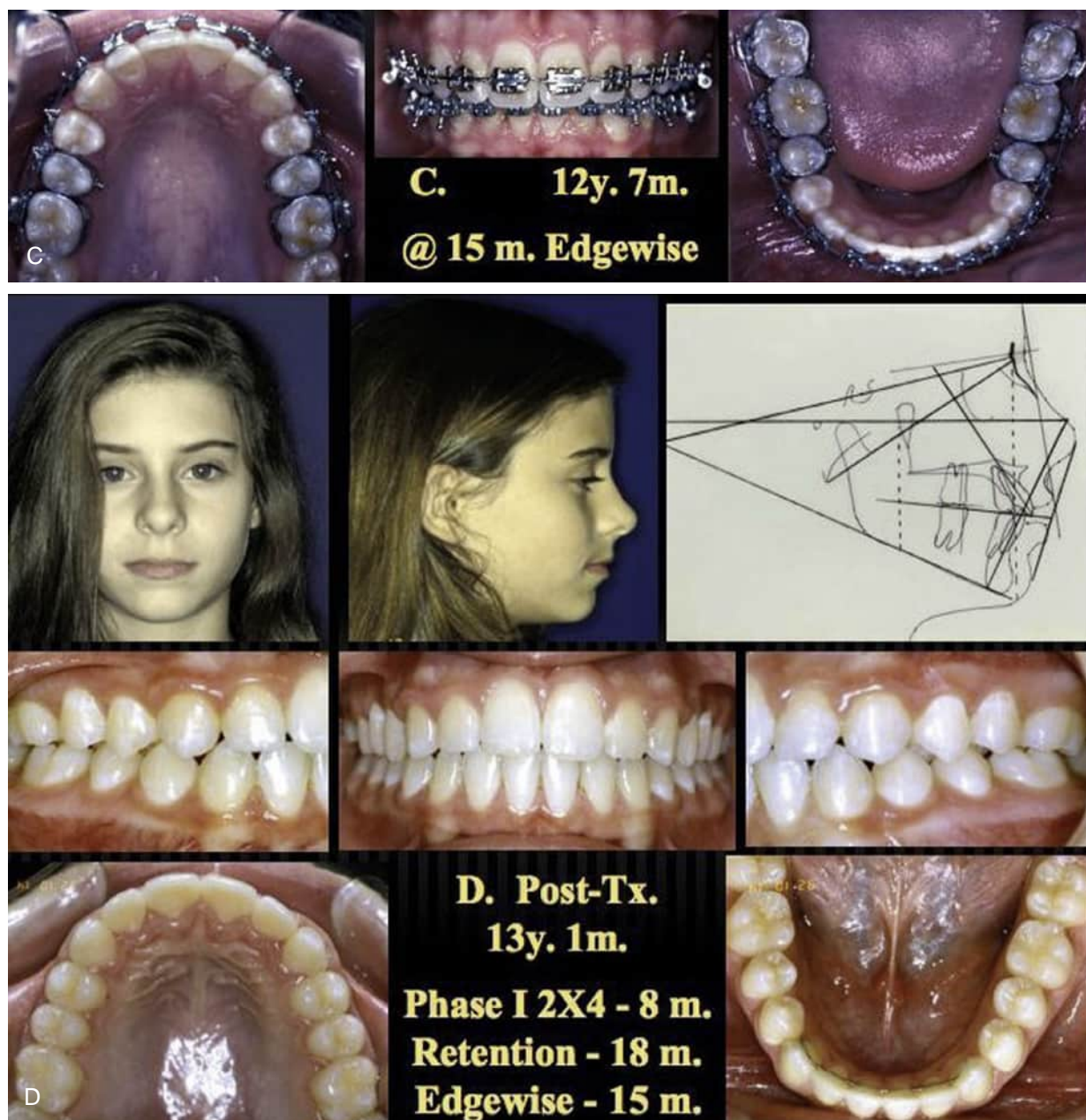
Comprehensive orthodontic care in the adolescent permanent dentition again includes both orthopedic and orthodontic components. Orthopedic components might involve continued applications of palatal expanders, headgear, and

functional appliances. Fig. 23.63 illustrates the correction of a Class II malocclusion with a functional appliance in the permanent dentition. An activator for mandibular advancement worn in combination with a high-pull headgear for restraint of maxillary growth addressed the skeletal Class II problem. The orthodontic component included full fixed Edgewise appliances to establish occlusal relationships as near to “ideal” as



**Fig. 23.61** (A) Class II division 2 deep-bite malocclusion in a child aged 9 years and 4 months with mesofacial growth pattern, retrognathic mandible, ANB = +6 degrees, moderate incisor crowding. (B) A maxillary 2 × 4 with a transpalatal bar was used along with a mandibular lip bumper for 8 months of phase I treatment. The upper was retained with a Hawley bite plane; the lip bumper was continued for an additional 18 months.





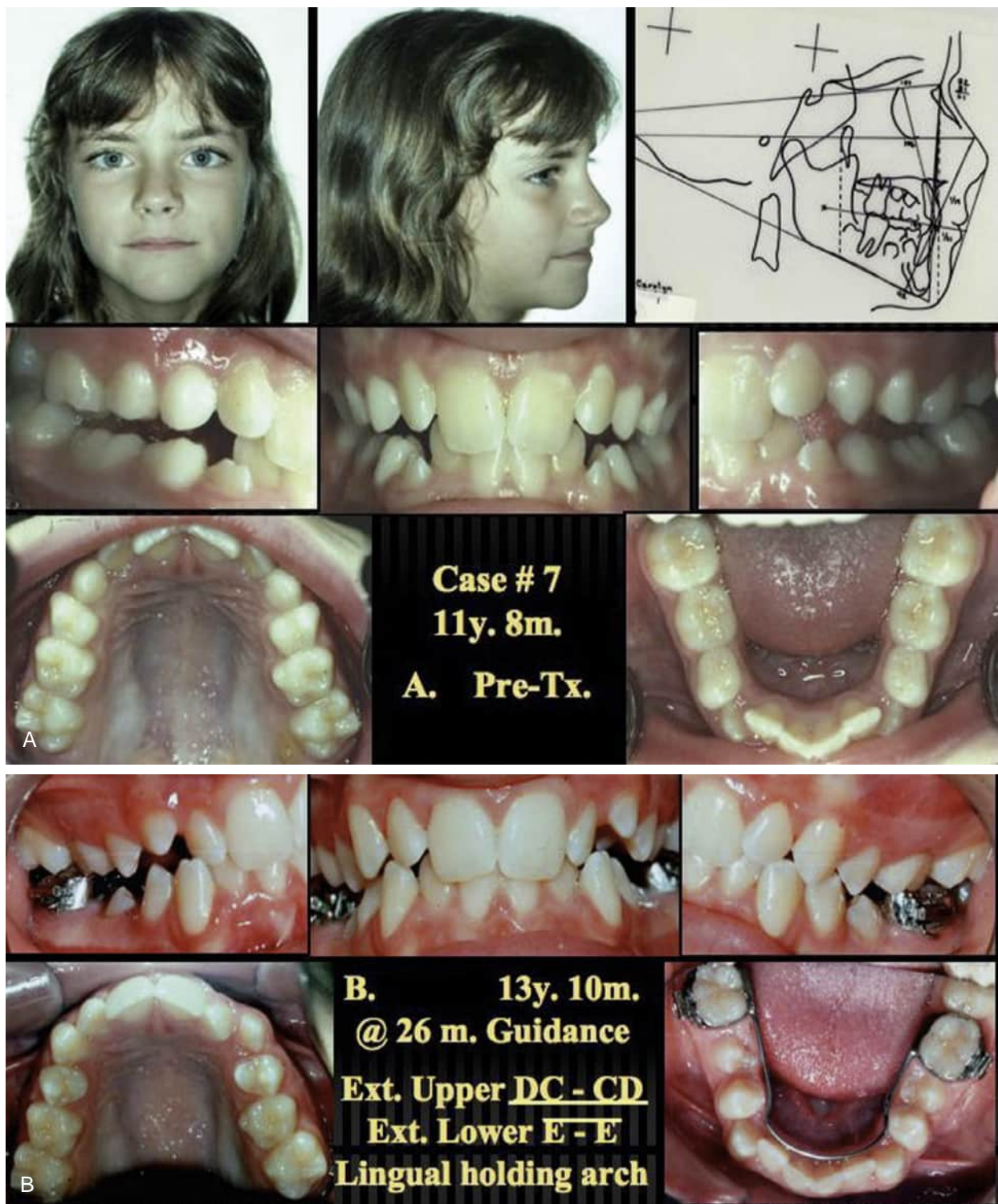
**Fig. 23.61 cont'd** (C) Patient started second Edgewise phase that continued for a total of 15 months until age 12 years and 7 months. (D) Final records obtained 3 months after removal of Edgewise appliances at age 12 years and 10 months.

possible. Extraction of a single maxillary first premolar was used in the full Edgewise phase to camouflage the midline asymmetry in finishing with a good buccal occlusion.

Localized tooth displacements such as maxillary canine impactions and significant genetic tooth size–arch size discrepancies not manageable with space supervision procedures are also commonly addressed in this period. The removal of selected permanent teeth in cases of significant tooth size–arch size discrepancies with severe tooth displacements or to camouflage Class II or Class III dental malocclusions often offers good options as part of a comprehensive treatment plan.

If a patient has undergone an earlier phase of treatment successfully, the Edgewise phase of treatment might take

as little as 12–18 months and, it is hoped, will involve few, if any, orthopedic needs. However, if this is the start of comprehensive care, more treatment time will likely be needed. Treatment with full Edgewise appliances includes leveling and alignment of the dentition, space consolidation, transverse coordination of upper to lower arch forms, sagittal arch coordination (Class II or III elastic wear), establishment of root parallelism over basal bone, finishing and detailing of intra- and interarch positioning (i.e., first-, second-, and third-order archwire bends), and buccal or anterior segmental finishing procedures to establish maximum interdigitation between arches. In selected patients, the Edgewise treatment may be more limited, unnecessary as determined by the dental practitioner, or unwanted as

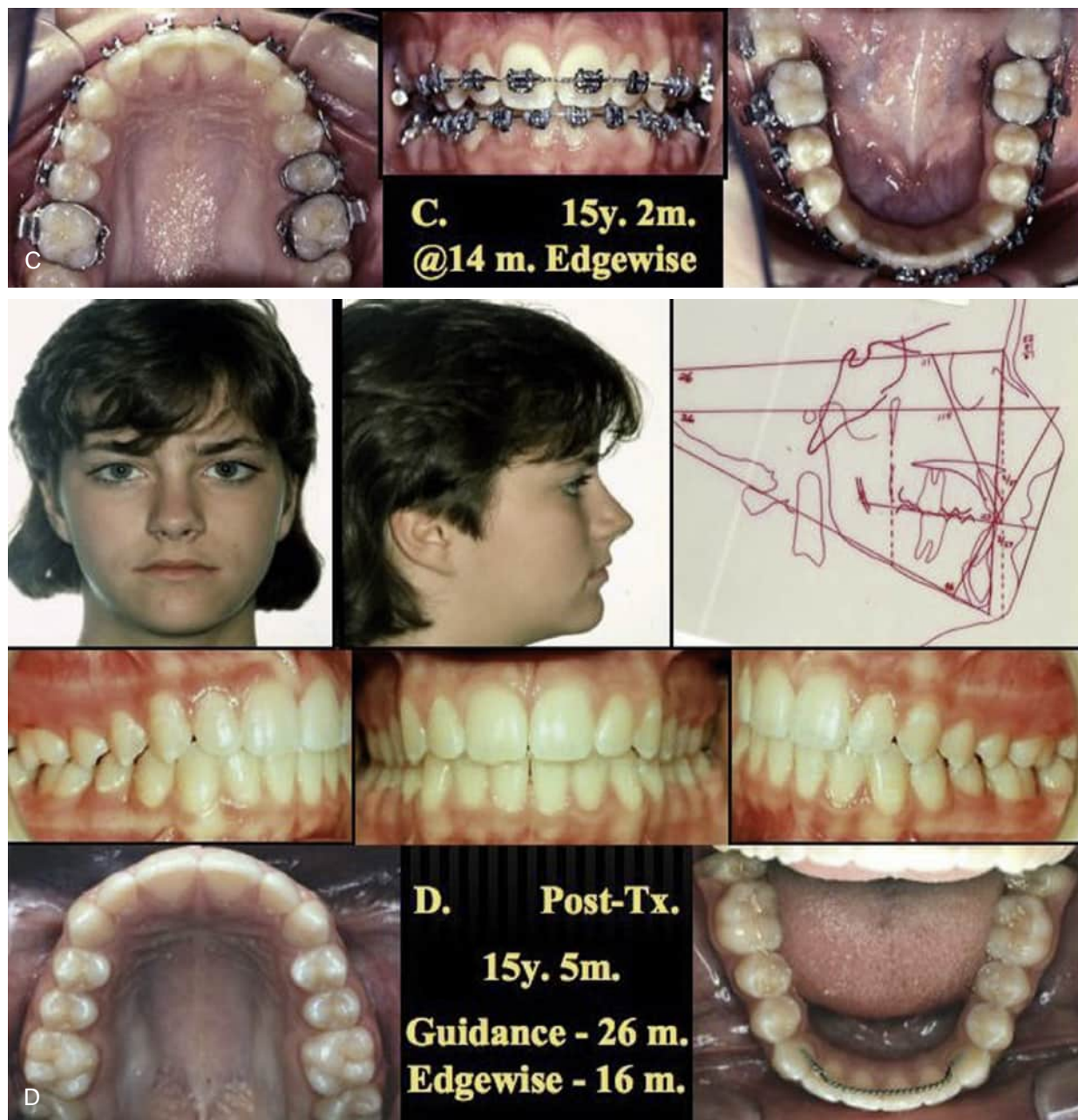


**Fig. 23.62** (A) Class I mixed dentition in a patient aged 11 years and 8 months with notable anterior crowding, delayed dental developmental timing, mesofacial growth pattern, and bilateral ankylosed lower primary molars. (B) Patient at age 13 years and 10 months after 26 months' guidance with selective extraction of upper primary canines and first molars, lower first and second primary molars, and passive lingual holding arch.

determined by the patient and/or parent. Limited treatment can involve segmented arch therapy in which only the teeth or arch needing attention is addressed. Occasionally the practitioner may be so satisfied with the result after an earlier phase that no further treatment is recommended. However, this is fairly uncommon. A more likely

occurrence is that the patient and/or parents decide that they are satisfied with the result, even though some finishing details are needed. It is critical to stress to parents before initiating early treatments that most children will benefit from a final period of full orthodontic appliances (phase II) to optimize aesthetic and functional outcomes. It





**Fig. 23.62 cont'd** (C) Full upper and lower Edgewise appliances were used for a total of 15 months. (D) Final records obtained after removal of Edgewise appliances at age 15 years and 5 months.

is particularly important to allow for final tooth positioning of the permanent second molars.

Retention following the definitive stage of comprehensive Edgewise treatment should involve the philosophy of "retention for a lifetime." There are many different types of retention schemes. Although no perfect retention scheme has been developed and periodic observation is warranted for all, the following retention schedule seems to provide for stable results:

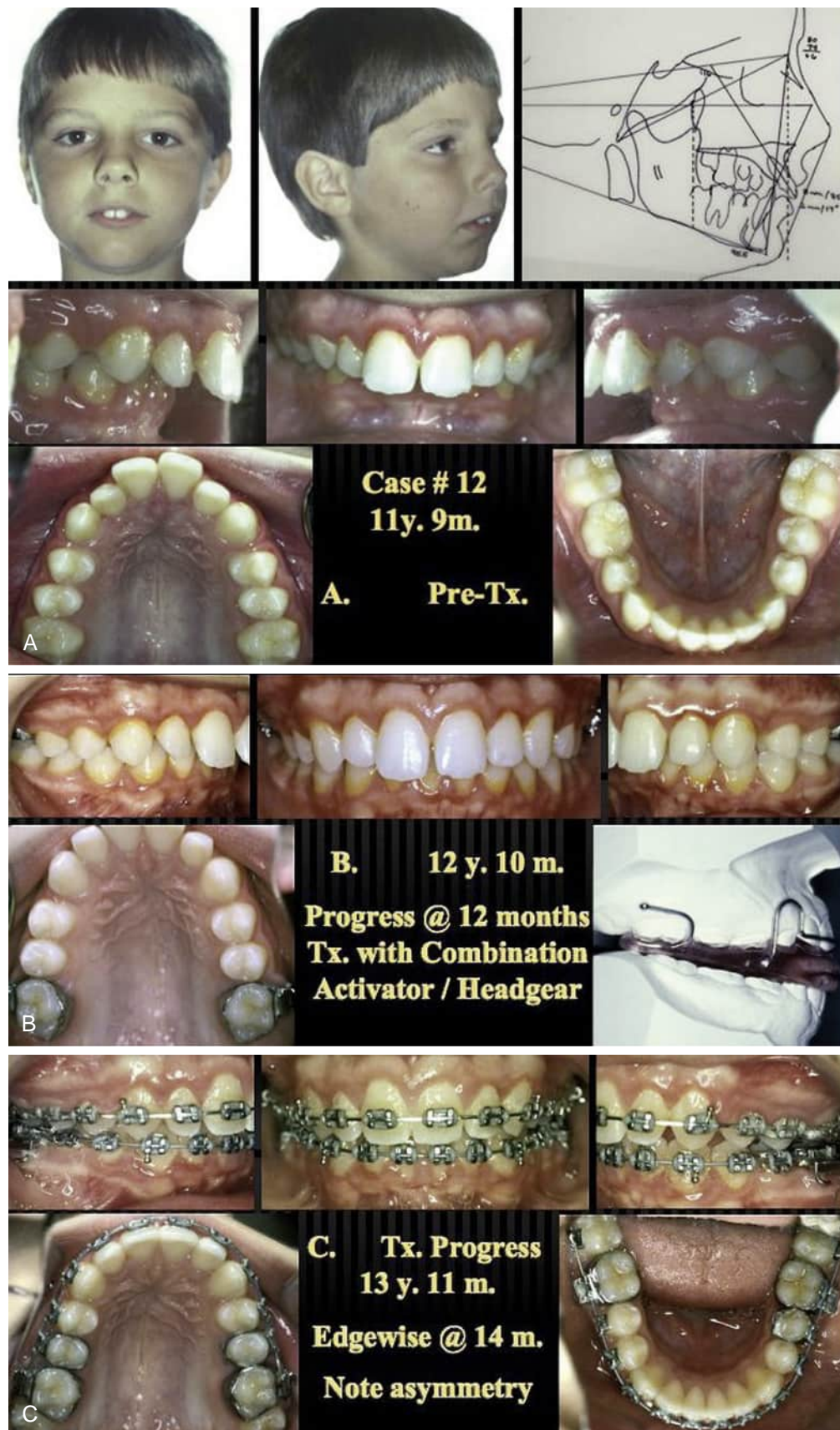
1. Maxillary and mandibular Hawley retainers to be worn 24 hours a day for 4–6 months, followed by worn at night only for 6–8 months.
2. After 1 year, reassess if wear can be reduced to 1 or 2 nights per week with the patient increasing wear as

needed if the retainers become tight from tooth movement.

3. Continue wear as above for "retention for a lifetime" or, at an absolute minimum, until 21 years of age, at which time the craniofacial growth rate has been reduced to that of an adult.

The use of a backup set of thin acrylic overlay retainers is a useful way of inexpensively giving the patient an emergency set of retainers if the Hawley retainers are lost or damaged. As an added benefit, they can be used for home bleaching of the teeth for those patients who are interested. Fixed retention may be necessary in special circumstances. A lower canine-to-canine fixed bonded wire can be helpful for severe rotations, and an upper lateral-to-lateral fixed





**Fig. 23.63** (A) Class II division 1 mixed dentition with profile, lip interpositioning, mesofacial growth patterns, ANB = +10 degrees, mandibular retrognathia, and maxillary dental protrusion in a patient aged 11 years and 9 months. (B) Patient after 12 months of wearing a mandibular functional advancement appliance (i.e., Activator) and cervical-pull headgear in combination with following a regimen of 12 to 14 hours of wear per day. (C) Patient started full Edgewise phase at age 12 years and 10 months. The treatment progress at 14 months of Edgewise use illustrates midline asymmetry with Class I right and Class II left buccal occlusion.

bonded wire is useful to prevent space opening for patients with initial diastemas.

One final thought that seems of particular interest to parents regards the effect of extraction of third molars on late lower incisor crowding. Although more studies will be necessary to corroborate the results, a nicely done prospective

randomized controlled clinical trial of orthodontic patients who had early extraction of third molars versus those who showed no clinically significant difference in incisor crowding between the two. The authors concluded that removal of third molars to reduce or prevent incisor crowding was not justified.<sup>59</sup>

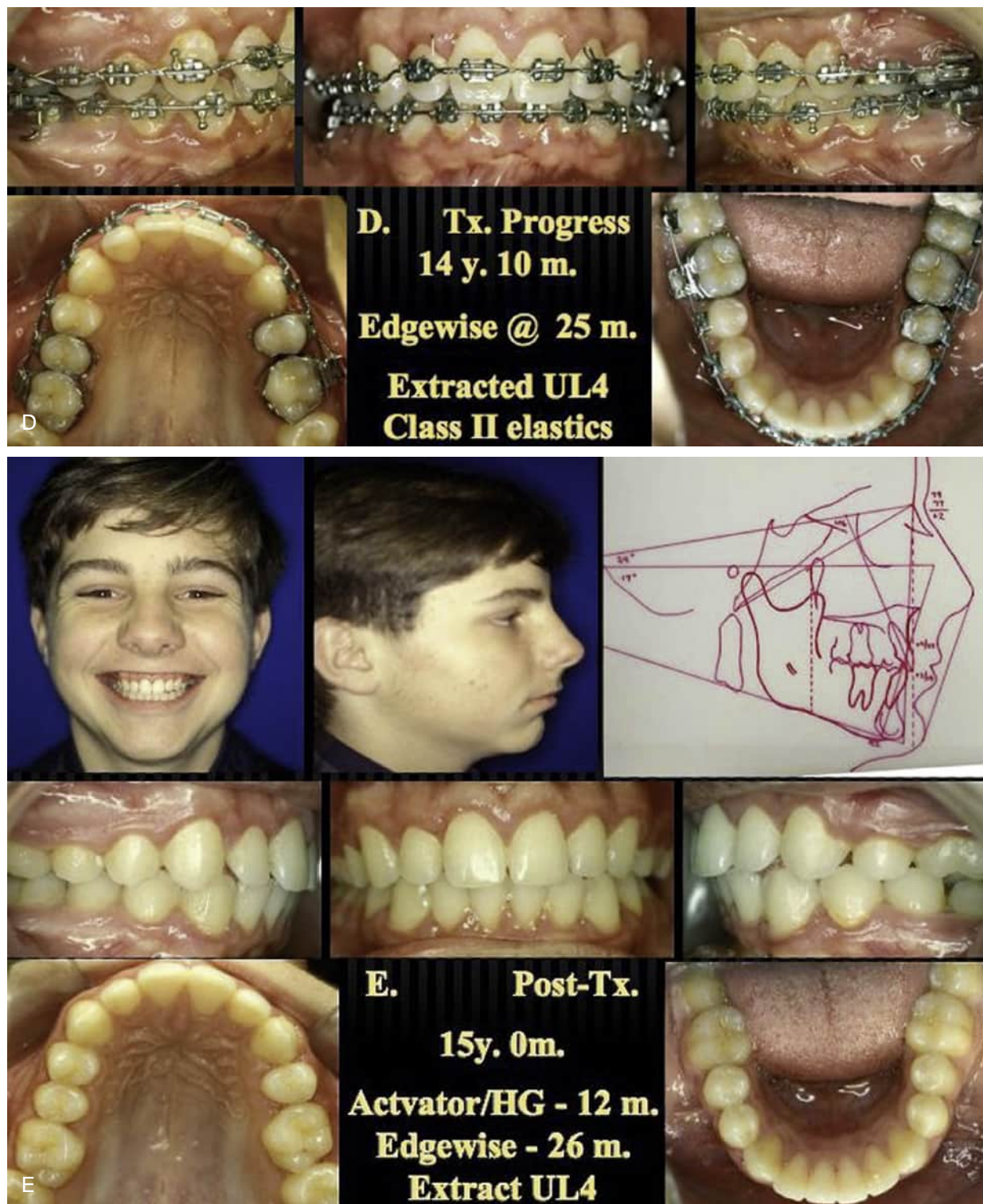


Fig. 23.63 cont'd (D) Treatment progress at 25 months of Edgewise treatment illustrates midline symmetry attained in conjunction with selective extraction of the upper left first premolar. (E) Final records obtained at age 15 years and 0 months after 12 months of growth modification and 26 months of Edgewise appliances.



## References

- American Academy of Pediatric Dentistry. Reference manual: Guideline management of the developing dentition and occlusion in pediatric dentistry. <https://www.aapd.org/research/oral-health-policies-recommendations/management-of-the-developing-dentition-occlusion-in-pediatric-dentistry/>, accessed June 6 2019.
- Ngan PW, Wei SH, Yen PK: Orthodontic treatment in the primary dentition. *J Am Dent Assoc* 116(3):336–340, 1988.
- Moyers RE. *Handbook of orthodontics*, ed 4, Chicago, CV Mosby, 1988.
- Baume LJ: Physiological tooth migration and its significance for the development of occlusion. *J Dent Res* 29(2):123–132, 1950.
- Moorrees CFA: Growth changes of the dental arches: a longitudinal study. *J Can Dent Assoc* 24(8):449–457, 1958.
- Moorrees CFA. *Dentition of the growing child*. Cambridge MA, Harvard University Press, 1959.
- Bishara SE, Ortho D, Jakobsen JR, et al.: Arch width changes from 6 weeks to 45 years of age. *Am J Orthod Dentofacial Orthop* 111(4):401–409, 1997.
- Moyers RE, Wainwright RL. Skeletal contributions to occlusal development. In McNamara JA, editor: *The biology of occlusal development, craniofacial growth series, monograph*, Michigan, University of Michigan: Ann Arbor, 1977, pp 89–111.
- Nance HN: The limitations of orthodontic treatment. I. Mixed dentition diagnosis and treatment. *Am J Orthod* 33(4):177–223, 1947.
- Allen TR, Trojan TM, Harris EF: Evidence favoring a secular reduction in mandibular leeway space. *Angle Orthod* 87(4):576–582, 2017.
- Gianelly AA: Crowding: timing of treatment. *Angle Orthod* 64(6):414–418, 1994.
- Gianelly AA: Leeway space and the resolution of crowding in the mixed dentition. *Semin Orthod* 1(3):188–194, 1995.
- Sonis A, Ackerman M: E-space preservation: is there a relationship to mandibular second molar impaction? *Angle Orthod* 81(6):1045–1049, 2011.
- Miyamoto W, Chung CS, Yee PK: Effect of premature loss of deciduous canines and molars on malocclusion of the permanent dentition. *J Dent Res* 55(4):584–590, 1976.
- Owen DG: The incidence and nature of space closure following the premature extraction of deciduous teeth—a literature survey. *Am J Orthod* 59(1):37–49, 1971.
- Grøn AM: Prediction of tooth emergence. *J Dent Res* 41(3):573–585, 1962.
- Brill WA: The distal shoe space maintainer: chairside fabrication and clinical performance. *Pediatr Dent* 24(6):561–565, 2002.
- Carroll CE, Jones JE: Pressure-appliance therapy following premature loss of primary molars. *J Dent Child* 49(5):347–351, 1982.
- Waldon K, Barber SK, Spencer RJ, et al.: Indications for the use of auto-transplantation of teeth in the child and adolescent. *Eur Arch Paediatr Dent* 13(4):210–216, 2012.
- Bauss O, Schilke R, Fenske C, et al.: Autotransplantation of immature third molars: influence of different splinting methods and fixation periods. *Dent Traumatol* 18(6):322–328, 2002.
- Ramfjord SP: Bruxism, a clinical and electromyographic study. *J Am Dent Assoc* 62(1):21–44, 1961.
- Sheppard IM: The treatment of bruxism. *Dent Clin North Am* 207–213, 1960.
- Traisman AS, Traisman HS: Thumb- and finger-sucking: a study of 2,650 infants and children. *J Pediatr* 52(5):566–572, 1959.
- Subtelny JD, Subtelny JD: Oral habits—studies in form, function, and therapy. *Angle Orthod* 43(4):349–383, 1973.
- Subtelny JD: Oral respiration: facial maldevelopment and corrective dentofacial orthopedics. *Angle Orthod* 50(3):147–164, 1980.
- Popovich F, Thompson GW: Thumb and finger sucking—its relation to malocclusion. *Am J Orthod* 63(2):148–155, 1973.
- del Conte Zardetto CG, Rodrigues CR, Stefani FM: Effects of different pacifiers on the primary dentition and oral myofunctional structures of preschool children. *Pediatr Dent* 24(6):522–560, 2002.
- Haryett RD, Hansen FC, Davidson PO: Chronic thumb-sucking—a second report on treatment and its psychologic effects. *Am J Orthod* 57(2):164–178, 1970.
- Haskell BS, Mink JR: An aid to stop thumb sucking—the “Bluegrass” appliance. *Pediatr Dent* 13(2):83–85, 1991.
- Proffit WR, Fields HW, Larson B, et al.: *Contemporary orthodontics*, ed 6, St. Louis, 2019, Mosby.
- Fletcher BT: Etiology of finger-sucking: review of literature. *J Dent Child* 42(4):293–298, 1975.
- Hanson ML, Cohen MS: Effects of form and function on swallowing and the developing dentition. *Am J Orthod* 64(1):63–74, 1973.
- Proffit WR: Equilibrium theory revisited—factors influencing position of the teeth. *Angle Orthod* 48(3):175–185, 1978.
- Koletsis D, Makou M, Pandis N: Effect of orthodontic management and orofacial muscle training protocols on the correction of myofunctional and myoskeletal problems in developing dentition. A systematic review and meta-analysis. *Orthod Craniofac Res* 21(4):202–215, 2018.
- Rosa M, Lucchi P, Mariani L, et al.: Spontaneous correction of anterior crossbite by RPE anchored on deciduous teeth in the early mixed dentition. *Eur J Paed Dent* 13(3):176–180, 2012.
- Kuroi J, Berglund L: Longitudinal study and cost-benefit analysis of the effect of early treatment of posterior crossbites in the primary dentition. *Eur J Orthod* 14(3):173–179, 1992.
- Lindner A, Modéer T: Relation between sucking habits and dental characteristics in preschool children with unilateral crossbite. *Scand J Dent Res* 97(3):278–283, 1989.
- Kutin G, Hawes RR: Posterior cross-bites in the deciduous and mixed dentitions. *Am J Orthod* 56(5):491–504, 1969.
- Hesse KL, Årtun J, Joondéph DR, et al.: Changes in condylar position and occlusion associated with maxillary expansion for correction of functional unilateral posterior crossbite. *Am J Orthod Dentofac Orthop* 111(4):410–418, 1997.
- Pirttiniemi P, Kantomaa T, Lahtela P: Relationship between craniofacial and condyle path asymmetry in unilateral crossbite patients. *Eur J Orthod* 12(4):408–413, 1990.
- Malandris M, Mahoney EK: Etiology, diagnosis and treatment of posterior cross-bites in the primary dentition. *Int J Paediatr Dent* 14(3):155–166, 2004.
- Krebs AA: Rapid expansion of mid-palatal suture by fixed appliance. An implant study over a 7-year period. *Trans Eur Orthod* 40:131–132, 1964.
- Hicks EP: Slow maxillary expansion—a clinical study of skeletal versus dental response to low magnitude force. *Am J Orthod* 73(2):121–141, 1978.
- Thomas GG, Bell RA, Mitchell R: Experimentally determined forces of maxillary lingual arch expansion appliances. *J Pedod* 7(1):3–7, 1982.
- Harberson VA, Myers DR: Mid-palatal suture opening during functional posterior crossbite correction. *Am J Orthod* 74(3):310–313, 1978.
- Bell RA, Lecompte EJ: The effects of maxillary expansion using a quad-helix appliance during the deciduous and mixed dentitions. *Am J Orthod* 79(2):152–157, 1981.
- Bjerklin K, Kuroi J: Ectopic eruption of the maxillary first permanent molar: etiologic factors. *Am J Orthod* 84(2):147–155, 1983.
- Young DH: Ectopic eruption of the first permanent molar. *J Dent Child* 24:153–162, 1957.
- Alsulaiman AA, Briss DS, Parsi GK, et al.: Association between incisor irregularity and coronal caries: a population-based study. *Am J Orthod Dentofacial Orthop* 155(3):372–379, 2019.
- Dugoni SA, Lee JS, Varela J, et al. Early mixed dentition treatment—post-retention evaluation of stability and relapse. *Angle Orthod*. 11995;65(5):311–320.
- Rebellato J, Lindauer SJ, Rubenstein LK, et al.: Lower arch perimeter preservation using the lingual arch. *Am J Orthod Dentofac Orthop* 112(4):449–456, 1997.
- Brennan MM, Gianelly AA: The use of the lingual arch in the mixed dentition to resolve incisor crowding. *Am J Orthod Dentofac Orthop* 117(1):81–85, 2000.
- Kokich VO: Congenitally missing teeth—orthodontic management in the adolescent patient. *Am J Orthod Dentofac Orthop* 121(6):594–595, 2002.
- Trossman I: Childhood obstructive sleep apnea syndrome: a review of the American Academy of Pediatrics Guidelines. *Pediatr Ann* 42(10):195–199, 2013.
- Canto GD, Singh V, Major MP, et al.: Capability of questionnaires and clinical examinations to assess sleep-disordered breathing in children: a systematic review and meta-analysis. *J Am Dent Assoc* 145(2):165–178, 2014.
- Paglia L: Respiratory sleep disorders in children and role of the paediatric dentist. *Eur J Paediatr Dent* 20(1):5, 2019. <https://doi.org/10.23804/ejpd.2019.20.01.01>



57. Bishara SE, Justus R, Graber TM: Proceedings of the workshop discussions on early orthodontic treatment. College of Diplomates of the American Board of Orthodontics, *Am J Orthod Dentofac Orthop* 113:5–6, 1998.
58. Andrews LF: The six keys to normal occlusion, *Am J Orthod* 62(3):296–309, 1972.
59. Harradine NW, Pearson MH, Toth B: The effect of extraction of third molars on late lower incisor crowding: a randomized controlled trial, *Br J Orthod* 25(2):117–122, 1998.

### Suggested Readings

- Baccetti T, Franchi L, McNamara Jr JA: Treatment and post-treatment craniofacial changes after rapid maxillary expansion and facemask therapy, *Am J Orthod Dentofac Orthop* 118(4):404–413, 2000.
- Bishara SE: Impacted maxillary canines, *Am J Orthod Dentofac Orthop* 101(2):159–171, 1992.
- De Clerck HJ, Cornelis MA, Cevidanes LH, et al.: Orthopedic traction of the maxilla with miniplates: a new perspective for treatment of midface deficiency, *J Oral Maxillofac Surg* 67(10):2123–2129, 2009.
- Dincer M, Haydar S, Unsal B, et al.: Space maintainer effects on intercanine arch width and length, *J Clin Pediatr Dent* 21(1):47–50, 1996.
- Ericson S, Kuroi J: Resorption of incisors after ectopic eruption of maxillary canines—a CT study, *Angle Orthod* 70(6):415–423, 2000.
- Foley TF, Wright GZ, Weinberger SJ: Management of lower incisor crowding in the early mixed dentition, *J Dent Child* 63(3):169–174, 1996.
- Halterman CW: A simple technique for the treatment of ectopically erupting permanent first molars, *J Am Dent Assoc* 105(6):1031–1033, 1982.
- Humphrey WP: A simple technique for correcting an ectopically erupting first permanent molar, *J Dent Child* 29:176–178, 1962.
- Kennedy DB, Turley PK: Clinical management of ectopically erupting first permanent molars, *Am J Orthod Dentofac Orthop* 92(4):336–345, 1987.
- Kluemper GT, Beeman CS, Hicks EP: Early orthodontic treatment—what are the imperatives? *J Am Dent Assoc* 131(5):613–620, 2000.
- Koroluk LD, Tulloch JC, Phillips C: Incisor trauma and early treatment for Class II Division I malocclusion, *Am J Orthod Dentofacial Orthop* 123(2):117–126, 2003.
- Moorrees CF, Chadha JM: Available space for the incisors during dental development: a growth study based on physiologic age, *Angle Orthod* 35(1):12–24, 1965.
- Moorrees CF, Grøn AM, Le Bret LM, et al.: Growth studies of the dentition—a review, *Am J Orthod* 55(6):600–613, 1969.
- Ngan P, Alkire RG, Fields Jr HE: Management of space problems in the primary and mixed dentitions, *J Am Dent Assoc* 130(9):1330–1339, 1999.
- Pancherz H, Bjerkin K, Lindskog-Stokland B, et al.: Thirty-two year follow-up study of Herbst therapy: a biometric dental cast analysis, *Am J Orthod Dentofacial Orthop* 145(1):15–27, 2014.
- Rajah LD: Clinical performance and survival of space maintainers—evaluation over a period of five years, *J Dent Child* 69(2):156–160, 2002.
- Tulloch JC, Proffit WR, Phillips C: Outcomes in a 2-phase randomized clinical trial of early Class II treatment, *Am J Orthod Dentofac Orthop* 125(6):657–667, 2004.
- Vizzotto MB, De Araújo FB, Dias da Silveira HE, et al.: The Quad-helix appliance in the primary dentition—orthodontic and orthopedic measurements, *J Clin Pediatr Dent* 32(2):165–170, 2007.

## 24

# Multidisciplinary Team Approach to Cleft Lip and Palate Management

LAQUIA A. WALKER VINSON, TASHA E. HALL, JAMES E. JONES and ROBERTO L. FLORES

## CHAPTER OUTLINE

### Classification of Cleft Lip and Palate Multidisciplinary Cleft Lip and Palate Team

#### General Responsibilities of Team Members

Dental Specialties

Medical and Allied Health Specialties

#### Multidisciplinary Sequencing of Treatment in Clefts

Stage I (Infant Appliance Stage: Birth to 18 Months of Age)

Stage II (Primary Dentition Stage: 18 Months to 5 Years of Age)

Stage III (Late Primary or Early Mixed Dentition Stage: 6 to 10 or 11 Years of Age)

Stage IV (Permanent Dentition Stage: 12 to 18 Years of Age)

Cleft lip and palate, the most common of the craniofacial anomalies, are severe congenital anomalies with a global incidence of 0.28–3.74 per 1000 live births. In the United States, cleft lip and palate occur in approximately 1 in 940 newborns with a male-to-female ratio of 2:1.<sup>1</sup> The incidence varies widely among races: about 1 in 800 white newborns, 1 in 2000 black newborns, and 1 in 500 Japanese or Navajo Indian newborns. Isolated cleft palate occurs in about 1 in 2000 newborns and demonstrates less racial variation. Cleft lip and palate together account for approximately 50% of all cases, whereas isolated cleft lip and isolated cleft palate each occurs in about 25% of cases. According to the International Perinatal Database of Typical Orofacial Clefts working group, a bilateral cleft lip and palate accounts for 30% of all cleft lip with palate cases.<sup>2</sup> Some of these congenital anomalies appear to be genetically determined, although the majority are of unknown cause or are attributable to teratogenic influences (see [Chapter 6](#)).

## Classification of Cleft Lip and Palate

There is a tendency to conceptualize cleft lip and palate as a homogenous anomaly. If that were true, a treatment plan applicable to all cases could be formulated. However, the reality is that clefts vary widely in their clinical presentations.

According to Harkins et al.,<sup>3</sup> to standardize the reporting of cleft lip and palate, the Nomenclature Committee of the American Association of Cleft Palate Rehabilitation devised a classification system that was later

adopted by the Cleft Palate Association. The complexity of this system, however, has made its acceptance less than overwhelming. In 1931, Veau<sup>4</sup> proposed the most frequently used system and classified clefts of the lip as follows:

- Class I—a unilateral notching of the vermilion not extending into the lip.
- Class II—a unilateral notching of the vermilion border, with the cleft extending into the lip but not including the floor of the nose.
- Class III—a unilateral clefting of the vermilion border of the lip extending into the floor of the nose.
- Class IV—any bilateral clefting of the lip, whether it be incomplete notching or complete clefting.

Veau<sup>4</sup> classified palatal clefts as follows ([Fig. 24.2](#)):

- Class I—involves only the soft palate.
- Class II—involves the soft and hard palates but not the alveolar process.
- Class III—involves both soft and hard palates and the alveolar process on one side of the premaxillary area.
- Class IV—involves both soft and hard palates and continues through the alveolus on both sides of the premaxilla, leaving it free and often mobile.

Veau<sup>4</sup> did not include submucous clefts of the palate in his classification system. Submucous clefts may be frequently diagnosed by physical findings, such as bifid uvula, palpable notching at the posterior portion of the hard palate, and a zona pellucida (thin, translucent membrane). Submucous clefts of the palate may be associated with an incomplete velopharyngeal mechanism or Eustachian tube dysfunction.

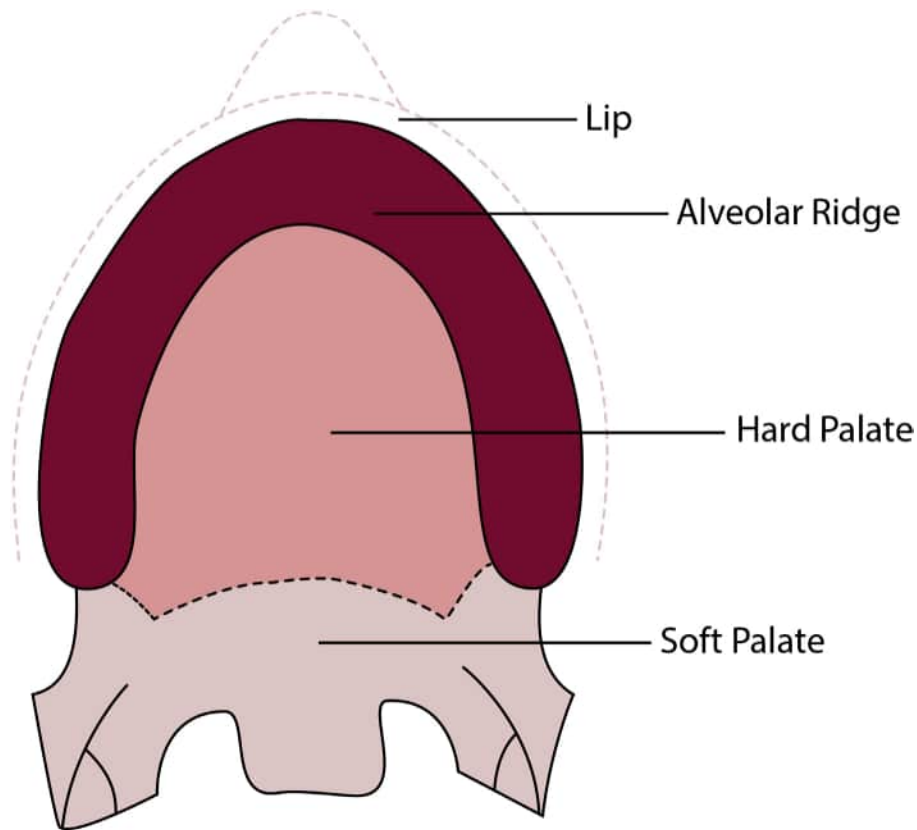


Fig. 24.1 Normal palate.

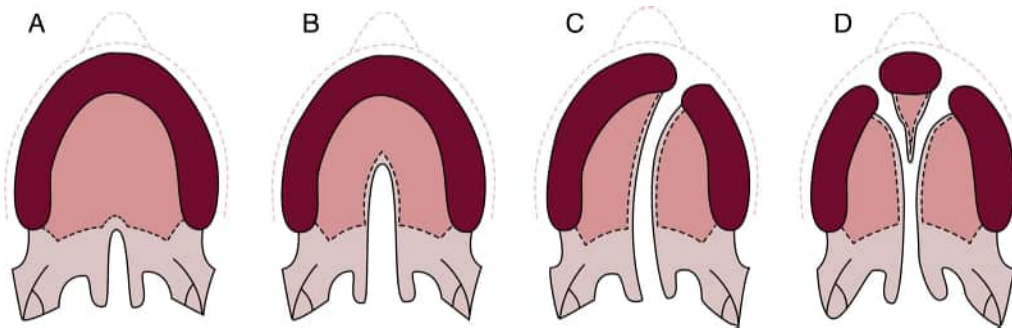


Fig. 24.2 Veau's classification of cleft lip and palate. Shaded area, extent of the cleft. (A) Class I, cleft of the soft palate only. (B) Class II, cleft of the soft and hard palates but not involving the alveolar process. (C) Class III, unilateral complete cleft of the lip and palate. (D) Class IV, bilateral complete cleft of the lip and palate. (C) IUSD Dental Illustrations, Created by Nicole Alderson.

## Multidisciplinary Cleft Lip and Palate Team

Children born with cleft lip and palate have many problems that need to be resolved for successful habilitation. The complexity of these problems requires that numerous health care practitioners cooperate in providing the specialized knowledge and skills necessary to ensure comprehensive care. The multidisciplinary cleft lip and palate team concept has evolved from that need.

To address the many treatment regimens and different care protocols, the American Cleft Palate–Craniofacial Association (<https://acpa-cpf.org>) convened a consensus conference on recommended practices for the care of patients with

craniofacial anomalies. This conference produced the document “Parameters for Evaluation and Treatment of Patients with Cleft Lip/Palate or Other Craniofacial Anomalies.”<sup>5</sup> This document serves as a guide for implementing the multidisciplinary approach to cleft and craniofacial care and is used by teams in the United States and Canada.

Because optimal care is best achieved by multiple types of clinical expertise, the teams may be composed of individuals in (1) dental specialties (orthodontics, oral surgery, pediatric dentistry, and prosthodontics), (2) medical specialties (genetics, otolaryngology, pediatrics, plastic surgery, and psychiatry), and (3) allied health care fields (audiology, nursing, psychology, social work, and speech pathology). (Table 24.1) The American Cleft Palate–Craniofacial Association<sup>5</sup> also created the Commission on Approval of Teams in order



**TABLE 24.1** Timetable of Team Member Intervention

Time period	Team member
<i>Prenatal visit</i>	Plastic surgeon Patient care coordinator Feeding specialist Social worker
<i>Initial postpartum visit through early childhood</i>	Feeding specialist Geneticist Developmental pediatrician Plastic surgeon Social worker Pediatric dentist Otolaryngologist Audiologist Speech-language pathologist Prosthodontist
<i>Early childhood through teenage years</i>	Patient care coordinator Orthodontist Oral surgeon Pediatrician Audiologist Otolaryngologist Speech-language pathologist Pediatric dentist Prosthodontist
<i>Early adulthood</i>	Patient care coordinator Plastic surgeon Oral surgeon Orthodontist Patient care coordinator

Based on "Parameters for Evaluation and Treatment of Patients with Cleft Lip/Palate or Other Craniofacial Differences" <https://doi.org/10.1177/1055665617739564>

to manage an approval process for teams that meet the Standards for Approval of Cleft Palate and Craniofacial Care. These standards delineate essential characteristics of a quality cleft palate team and facilitate the improvement of team care.

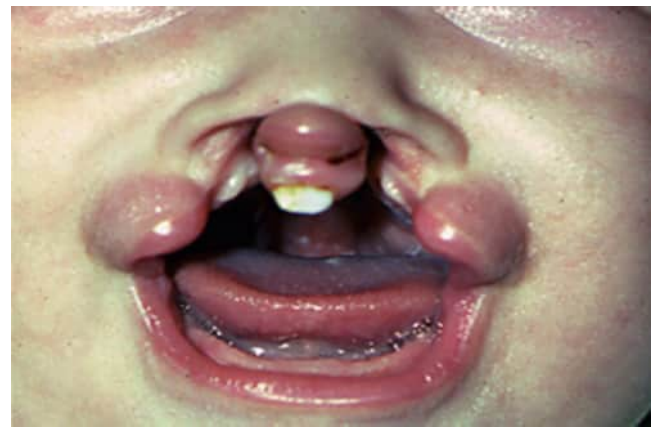These care providers assess the patient's medical status and general development, dental development, facial aesthetics, psychological well-being, hearing, and speech development. Team members must communicate effectively among themselves, with the child and parents, and with the primary care physician and dentist. Individuals on the team must respect one another's opinions and be flexible in planning and performing therapy. Periodic evaluation is necessary to assess the effect of previous therapy and to determine whether an alternative approach may be necessary. A team conference immediately after patient examination is a desirable way to discuss current problems and plan timely therapy.

Whitehouse<sup>6</sup> describes the clinical team as a "close, cooperative, democratic, multiprofessional union devoted to a common purpose—the best treatment of the fundamental needs of the patient."

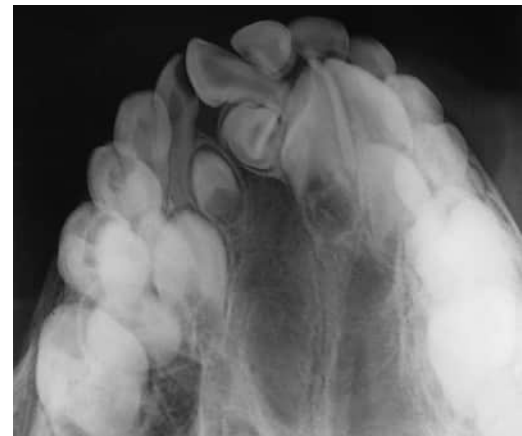
## General Responsibilities of Team Members

### DENTAL SPECIALTIES

The pediatric dentist is responsible for the overall dental care of the patient. Numerous dental anomalies and



**Fig. 24.3** Neonatal maxillary central incisor in a newborn infant with a bilateral complete cleft lip and palate.

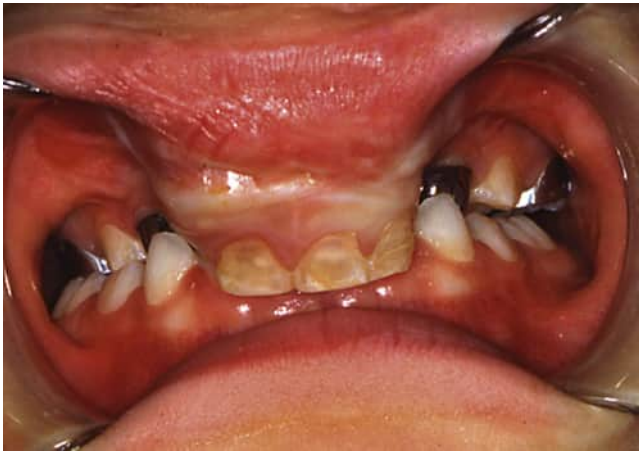

**Fig. 24.4** Maxillary occlusal radiograph demonstrating supernumerary maxillary central incisors.

malocclusions occur with a cleft lip or palate. These may be attributed to the congenital clefting itself or may be secondary to the surgical correction of the primary defects. A high correlation is found between the number and severity of dental problems and the type and severity of the cleft.

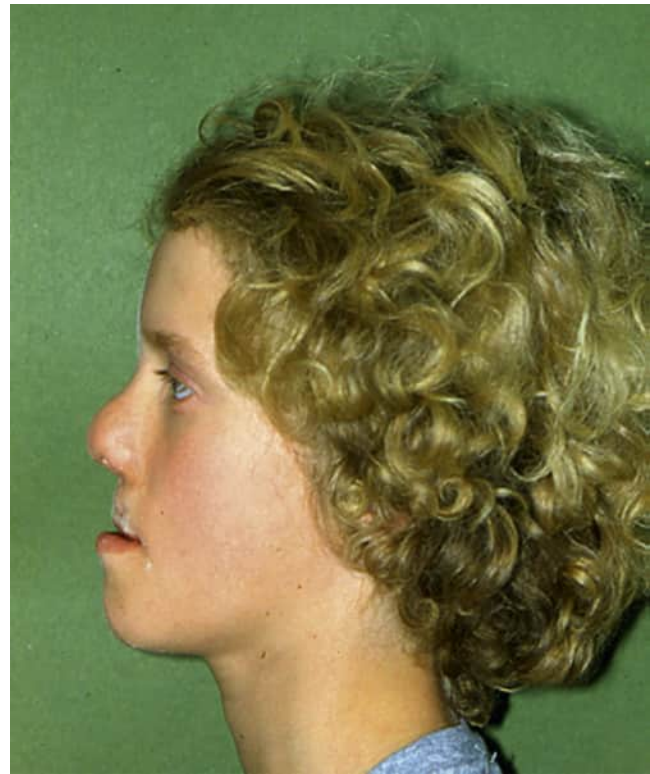The pediatric dentist should discuss with the patient and parents the traditional dental problems associated with clefting. Any one or several of the following conditions may occur with a significantly greater frequency than in the general population:

1. If there is a natal or neonatal tooth observed in a patient with a complete unilateral or bilateral cleft palate, it is usually a maxillary central incisor (Fig. 24.3).
2. There is a high incidence of congenitally absent teeth, especially the primary or permanent lateral incisor, adjacent to the alveolar cleft. There is also an increased incidence of congenitally missing second premolars.
3. There is a significant increase in the frequency of supernumerary teeth (Fig. 24.4), which are often seen in children with complete unilateral or bilateral clefts. Occasionally, there can be supernumerary teeth and congenitally missing teeth in patients with cleft lip only, with or without notching of the alveolus.



**Fig. 24.5** Bilateral complete cleft lip and palate demonstrating a greater than 100% overbite. Stripping of the labially attached gingiva of the mandibular central and lateral incisors is common in this presentation.

4. It is common to find ectopic primary lateral incisors located palatally, adjacent to, or within the cleft site. In the permanent dentition, canines on the side of the complete alveolar cleft may erupt palatally into the cleft.
5. Various anomalies of tooth morphology are frequently seen in association with complete unilateral and bilateral clefts of the palate. These include enamel hypoplasia, microdontia or macrodontia, fused teeth, and aberrations in crown shape. The teeth most often affected are the primary and permanent maxillary incisors.
6. Permanent teeth that erupt adjacent to a cleft alveolar ridge usually have a deficiency of supporting alveolar bone about the root surfaces. These teeth are susceptible to premature loss. A decrease in the alveolar bone support may be accentuated when periodontal disease is present or when orthodontic appliance therapy is used indiscriminately.
7. Permanent central incisors adjacent to an alveolar cleft frequently erupt in a rotated position and with deviations of axial root inclination.
8. Patients with a complete cleft palate and alveolus do not have a contiguous maxillary arch. External forces applied to the maxilla (e.g., by muscles of mastication or by the contraction of scar tissue after surgical repair of the cleft palate) can result in medial collapse of the posterior segments. A posterior crossbite may be observed unilaterally or bilaterally.
9. In an infant with a complete bilateral cleft lip and palate, the premaxilla is often protuberant and mobile. There may be a greater than 100% overbite, with subsequent stripping of the labially attached gingiva overlying the mandibular incisors (Fig. 24.5). Traumatic anterior end-to-end occlusion, or an anterior crossbite, is also common.
10. In a patient with a complete unilateral or bilateral cleft palate, the lateral facial profile may appear noticeably convex (Fig. 24.6). This may become more perceptible as the child grows older. The appearance may be attributed to a true mandibular or pseudomandibular



**Fig. 24.6** Lateral facial profile of an adolescent boy with a repaired bilateral complete cleft lip and palate. Maxillary hypoplasia, secondary to the cleft defect, often produces a greatly concave lateral facial profile.

prognathism. In pseudomandibular prognathism, the maxilla is in spatial disharmony with the mandible. This may be caused by a retrognathic maxilla or an attenuation of the anteroposterior and vertical growth of the maxilla.

### Pediatric Dentist

Preventive dental care is extremely important in these cases. Parents are often overwhelmed by other aspects of the cleft deformity and may give dental care a low priority or even neglect it altogether. The intact dental occlusion is the foundation upon which future orthodontic therapy takes place. Therefore, optimum dental health is essential for the total habilitation of the patient. Any compromise will lead to a less than optimal result. Routine prophylaxis and fluoride treatments are mandatory. Referral for preventive dental care should be made during the first year of life. Fluoride supplements, dentifrices, and rinses are indicated if the patient lives in a nonfluoridated community. The parents and patient should be instructed regarding proper dental hygiene techniques, especially around the defect. Close communication between the primary care dentist and the cleft team is important to ensure the continuity of care necessary during the extended treatment of such patients. Routine periodic reports from the cleft team should be forwarded to the child's primary care dentist, especially during orthodontic or surgical treatment. Pediatric dentists are often involved in the presurgical and postsurgical treatment phases of maxillary orthopedics. Both active and passive appliances are used to bring the



cleft segments into a more ideal alignment, thereby promoting a more favorable initial surgical outcome.

### Orthodontist

The orthodontist plays a key role in the diagnosis and treatment of a cleft condition by obtaining the records necessary for diagnosis and treatment planning. These include cephalometric and panoramic radiographs, study models, and diagnostic photographs. Analysis of these records enables the orthodontist to describe and quantitate the facial skeleton and soft tissue deformities. Using expertise in the growth and development of the facial skeleton, the orthodontist can identify problem areas and, with some limitations, predict growth and development. Many team members depend on the orthodontist's analysis and quantifications of the cleft anomaly for treatment planning.

The orthodontist also provides comprehensive orthodontic care for patients. Most orthodontic care can be considered conventional, but for difficult dental configurations, innovation and imagination are required for treatment. If surgical treatment is indicated, the orthodontist works closely with the surgeon to plan the most appropriate procedure. Immediate postoperative function, aesthetic result, and long-term stability are factors considered before the surgery.

### Oral and Maxillofacial Surgeon

The ability to surgically alter skeletal relationships of the maxillomandibular complex is the basis for participation by the oral and maxillofacial surgeon on the cleft team. This specialist evaluates all patients for facial form and function and jaw position. Many patients have significant skeletal malocclusions that cannot be treated by conventional orthodontics and require surgical correction.

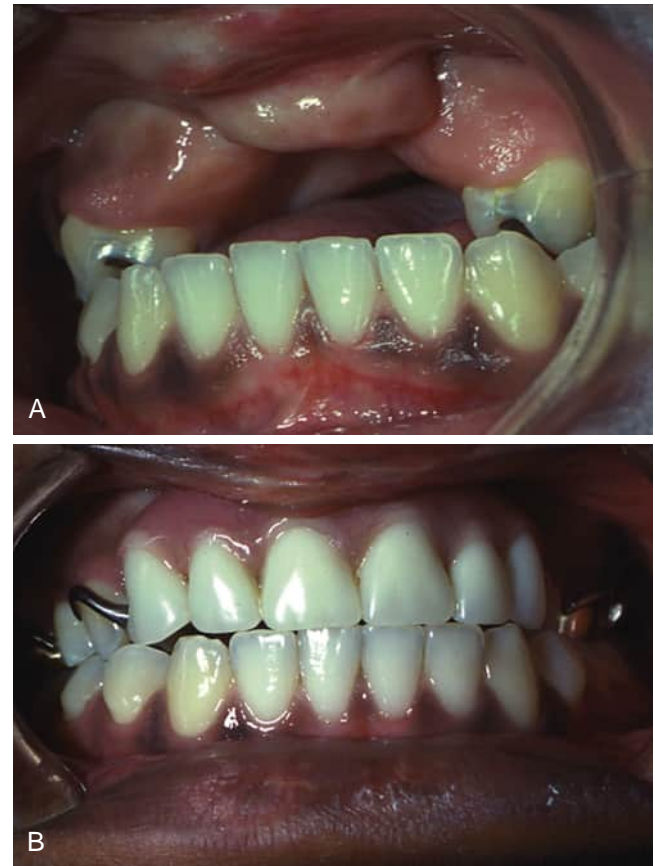The surgical placement of alveolar cleft bone grafts is another important role of the oral and maxillofacial surgeon. These grafts aid in dental habilitation. The grafted bone supports the teeth adjacent to the cleft site and provides bone through which teeth may erupt. A detailed discussion of these grafts follows later in this chapter.

### Prosthodontist

The maxillofacial prosthodontist replaces, restores, or rehabilitates orofacial structures that may be congenitally missing or malformed. Nonliving materials are used to restore and enhance form and anatomy. There is a special commitment to the oral cavity because this specialist fabricates prosthetic appliances to rehabilitate mastication, deglutition, speech, and oral aesthetics.

Many patients with clefts have congenitally missing teeth or malformed teeth that may need to be removed. In these cases, masticatory function, speech, and orofacial aesthetics are compromised and successful habilitation dictates that the missing teeth be replaced to achieve as nearly normal a condition as possible (Fig. 24.7). The maxillofacial prosthodontist may do this with fixed or removable appliances or with a combination of the two.

Occasionally, patients demonstrate aberrant speech patterns caused by failure of the soft palate to elevate properly. If surgical soft palate reconstruction and revision are unsuccessful, a palatal lift appliance can be fabricated to aid the speech mechanism. In other cases, the maxillofacial



**Fig. 24.7** (A) Bilateral complete cleft lip and palate in which the maxillary six permanent anterior teeth have been removed. (B) Removable prosthodontic appliance providing acceptable occlusal and aesthetic results.

prosthodontist may fabricate a speech bulb prosthesis to aid or augment the velopharyngeal mechanism. In patients with considerable escape of air through persistent palatal fistulas, the fistulas can be surgically repaired or obturated (Fig. 24.8).

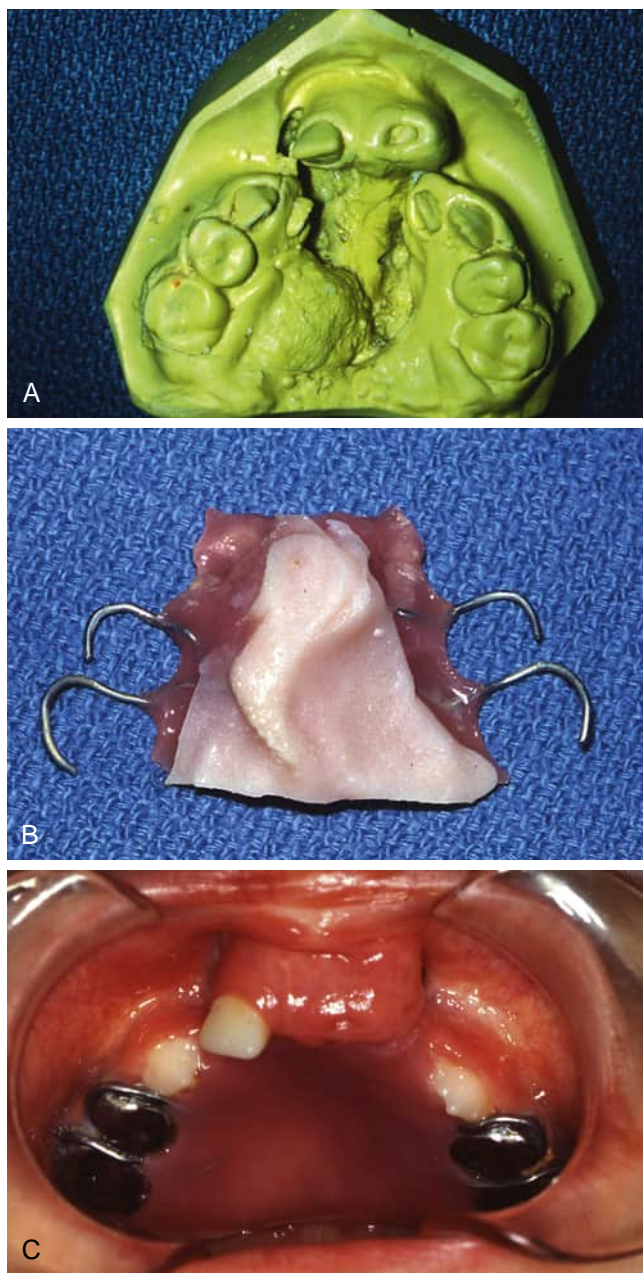
### MEDICAL AND ALLIED HEALTH SPECIALTIES

The patient care coordinator arranges appointments, maintains patient records, and monitors the interaction of the patient and family with the various team members. The coordinator corresponds with health and school personnel near the patient's home to help provide continuity of care for the cleft patients within the community. The coordinator is the most convenient point of contact with team members for the patients, their families, and health care practitioners outside the medical center complex.

The pediatrician, often the patient's own pediatrician or family physician, is responsible for maintenance of the patient's overall health. This specialist performs complete physical evaluations and helps assess the patient's physiologic status. Close attention is also directed to growth status and other developmental milestones.

The medical geneticist examines the patient to find characteristics of syndromes associated with cleft lip and palate. Consideration is given to the genetic basis for the anomaly, and this information is related to the parents. Genetic





**Fig. 24.8** (A) Diagnostic maxillary model of a bilateral complete cleft lip and palate. Notice the large patent oronasal fistula that resulted after several attempts to close the defect surgically. (B) Maxillary prosthesis constructed for the patient to obturate the palatal defect. (C) Palatal prosthesis in place. This closure provides a reduction in the amount of fluids and foods that enter the nasal cavity during eating. The closure also facilitates more normal speech production.

counseling is a very important function of the geneticist. Parents are vitally interested in risk assessment relative to future offspring, and other family members who may be at risk are often counseled (see [Chapter 6](#)).

The role of the plastic and reconstructive surgeon begins with a determination of the timing and method of lip closure. In addition, the plastic surgeon is responsible for cleft palate repair and secondary surgery to correct velopharyngeal incompetence and/or palatal fistulas. Internal and external cleft nasal deformities are corrected by the plastic surgeon.

The social worker acts as the patient's advocate in many cases and aids in psychosocial assessment. This team member assists the family by making referrals to persons or agencies at the local, county, and state levels for guidance regarding financial resources for medical care. During hospitalization, the social worker provides supportive counseling and facilitates communication between the family and medical or hospital personnel. The focus is on helping the family cope with stress during and after surgery and on dealing with emotional factors involved in forming realistic expectations of surgical outcomes and in adapting to problems of body image.

The psychiatrist and psychologist evaluate the patient for strengths and weaknesses in cognitive, interpersonal, emotional, behavioral, and social development. Emphasis is placed on the patient's ability to cope with the emotional and physical stress created by the cleft defect. Consultation with the parents and school regarding educational or behavioral management occurs when indicated.

The speech pathologist functions essentially as a monitor of speech output. All speech sounds are analyzed to determine deviations from normal, and the cause of any deviation is evaluated. To the extent that anatomic variations are corrected, the speech pathologist offers therapeutic options to enhance maturation of speech or to achieve satisfactory compensation in motor production for optimal speech.

The audiologist performs tests to identify any hearing difficulties. When neither the child nor the parents recognize hearing problems, the result can be a delay in speech and language development and poor performance in school. When hearing tests or impedance measures are abnormal, a referral is made to an otolaryngologist for an ear examination. The otolaryngologist coordinates audiology tests and any special studies that may be needed to evaluate middle ear structures. Any middle ear surgery required is performed by this team member. He or she may also perform a nasopharyngoscopic examination in coordination with the speech pathologist.

Nurses provide various functions that are valuable to the cleft lip and palate team. They actively communicate with other disciplines in relaying information regarding the special needs of each child and family. Nurses emphasize on total family involvement and not just treatment of the patient. They prepare patients and families for either outpatient or inpatient surgery and assist in the overall management process. Above all, they are extremely important in assessing the initial feeding issues and advising parents about ongoing nutritional concerns.

The presence of more complex craniofacial anomalies, such as Crouzon syndrome, Treacher Collins syndrome, or hemifacial microsomia, requires additional specialists on the team. Some of these care providers include anesthesiologists, diagnostic medical imaging radiologists, neurologists, neurosurgeons, and ophthalmologists in addition to aforementioned cleft team members.

## Multidisciplinary Sequencing of Treatment in Clefts

The following discussion focuses on major treatment procedures performed by members of the cleft team. For

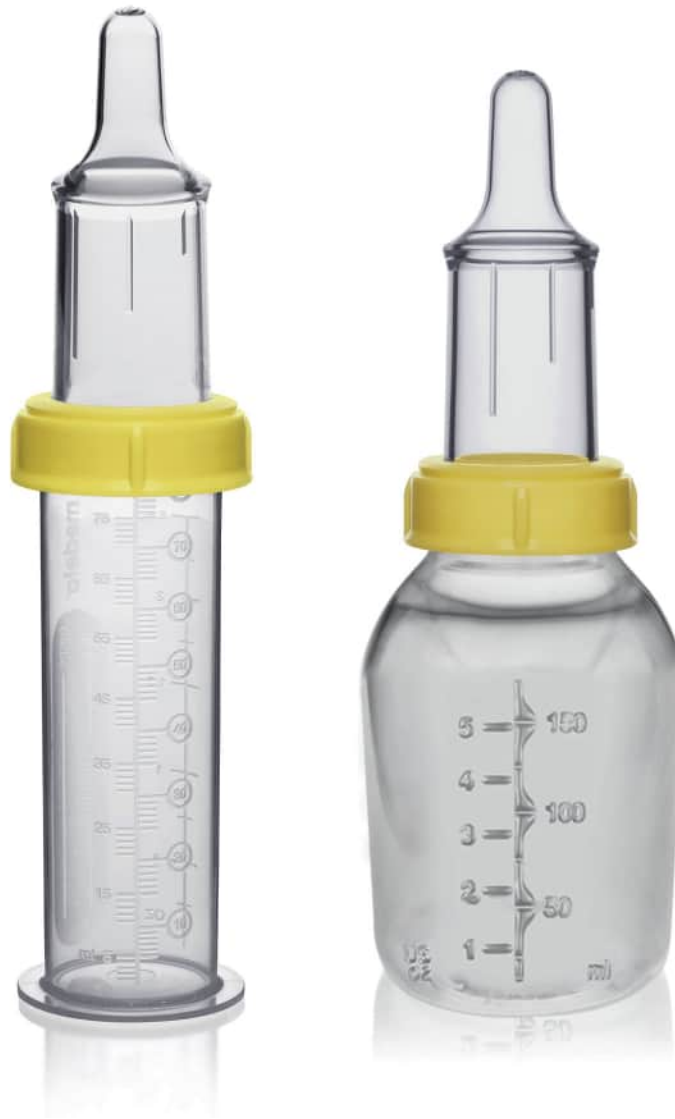

Fig. 24.9 Medela Special Needs feeder bottle.

convenience, the treatment is divided into four stages, which generally correspond to stages in the child's dental development.

### STAGE I (INFANT APPLIANCE STAGE: BIRTH TO 18 MONTHS OF AGE)

Management of the patient with a cleft begins with immediate attention to the needs of the newborn. Feeding problems are often associated with cleft anomalies, particularly clefting of the palate, which make it difficult for the infant to maintain adequate nutrition. These problems include insufficient suction to pull milk from the nipple, excessive air intake during feeding (requiring excessive burping), choking, nasal discharge, and excessive time required to take nourishment. The clinical nurse specialist on the cleft team or the feeding specialist is contacted to assess the feeding issues and offer advice and support. Various feeding techniques as well as feeding bottles/supplies have been advocated for use by infants with clefts.<sup>7</sup>

Specialized feeders for infants with cleft lip and palate come in a variety of shapes and sizes (Fig. 24.9; Table 24.2). There is currently no definitive evidence to guide which feeding equipment is most effective as the availability of evidence supporting strategies in the management of feeding and swallowing issues in patients with cleft lip and palate is limited.<sup>8</sup>

In the past, McNeil<sup>9,10</sup> and other authors since then have advocated various prosthetic appliances, both active and passive, for the treatment of infants born with unilateral and bilateral clefts of the lip and palate. One such prosthesis, an intraoral maxillary obturator, has proved beneficial by providing an artificial palate. The advantages of this prosthetic therapy include the following:

1. Provides a false palate against which the infant can suck, reduces the incidence of feeding difficulties in newborns, and helps maintain adequate nutrition
2. Provides maxillary cross-arch stability and prevents arch collapse after definitive cheiloplasty (surgical closure of the lip)



**TABLE 24.2** Specialized Feeders for Patients With Cleft Lip and Palate

Type	Brand	Purpose
NUK Orthodontic Nipple	Gerber	Expresses milk via compression of nipple
Special Needs Feeder (Haberman special needs feeder)	Medela	Assisted delivery bottle
Cleft Palatal Nurser Pigeon bottle	Mead Johnson Respiroics	Assisted delivery bottle Nonassisted delivery bottle that uses compression to express liquid

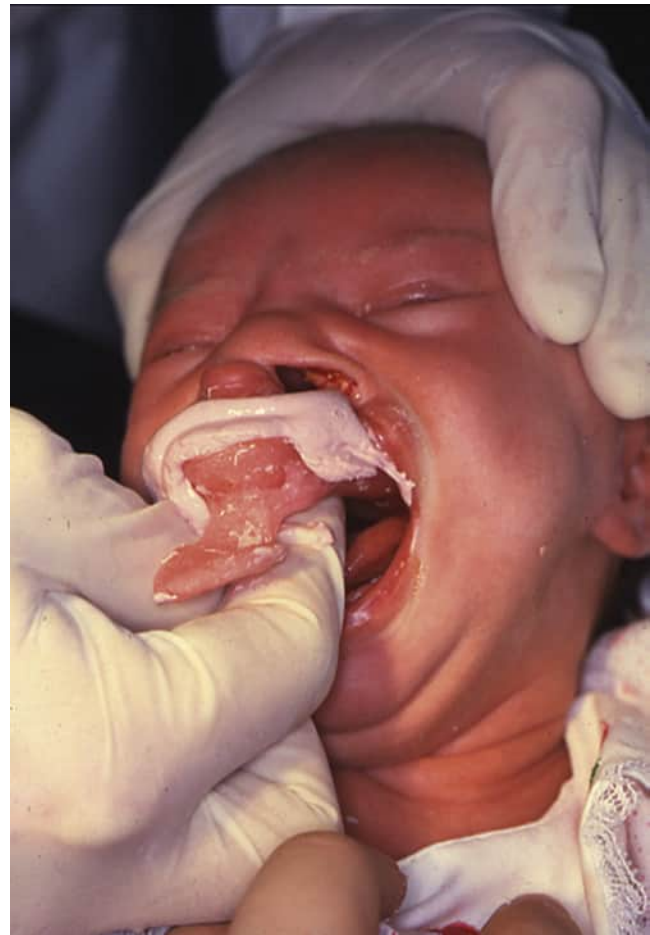- Provides maxillary orthopedic molding of the cleft segments into approximation before primary alveolar cleft bone grafting

In a study by Jones,<sup>11</sup> maxillary obturators were constructed to facilitate feeding for 51 infants with unilateral or bilateral cleft lip and palate. From birth, each infant had continuously experienced feeding difficulties before obturator therapy. After the infants had worn the obturator for at least 8 months, parents reported that they were more comfortable while feeding their infants and that nasal discharge was reduced. The time required for feeding and the difficulty experienced by the parents were also reduced. Of particular importance was the reported reduction of parental apprehension during feeding. All parents recommended the obturator for others who had infants with cleft lip and palate. It was also reported that the weights of the infants at 1, 3, and 6 months of age consistently remained at, or above, the 50th percentile compared with normative growth data. No fluctuation in weight was noted even after primary lip closure at about 3 months of age.

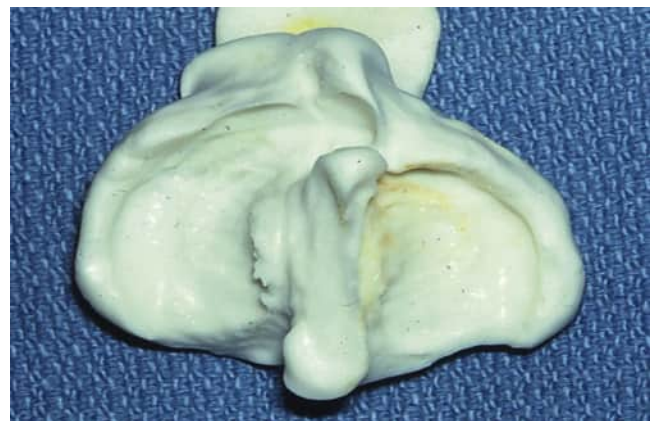
### Impression Technique and Feeding Obturator Construction

As soon as possible (usually within 2 weeks of birth), an impression is made of the infant's maxillary arch for construction of an intraoral obturator. An alginate impression of the infant's maxillary arch is made with a modified stock tray. Ideally, this is accomplished after birth as soon as possible. The infant is held upright during the impression process to prevent aspiration of excess material (Fig. 24.10). Appropriate emergency equipment, including forced oxygen, suction, and standard airway management equipment, should be available. The impression should exhibit good anatomic detail with coverage of the entire maxillary arch (Fig. 24.11). A stone model is then produced. The steps in obturator construction are as follows:

- Block out excessive undercuts with modeling dough or wax. Modeling dough is preferred because it is easy to remove from the finished prosthesis.
- Apply a tinfoil substitute over the entire surface of the maxillary model and let it dry.
- If necessary, place a dam of modeling dough on the back of the model to hold the resin in the palatal defect while it cures.



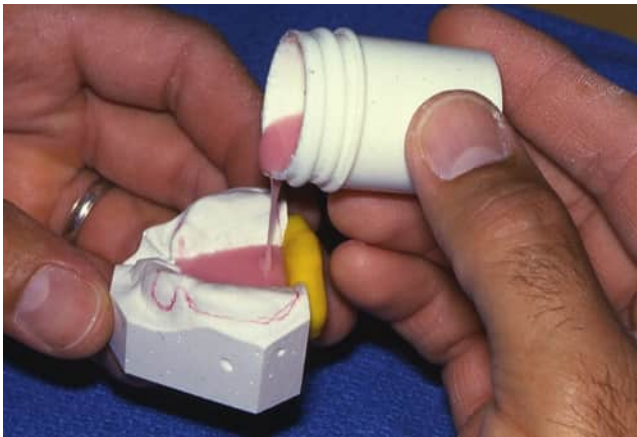
**Fig. 24.10** Maxillary impression for obturator construction on a newborn with a cleft lip and palate. The infant is held in an upright position to prevent aspiration of excess material.



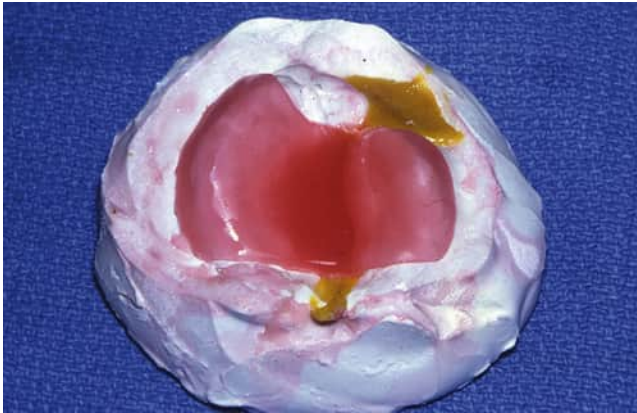**Fig. 24.11** Final impression of the infant's maxillary arch. Notice the extension of the material into the cleft defect, as well as the roll produced in the buccal fold. Attention to such detail ensures an excellent reproduction of the intraoral architecture for obturator construction.

- Pour a mixture of soft, autopolymerizing acrylic resin into the cleft to the level of the palate. This provides retention for the prosthesis by gently contouring into the available undercuts (Fig. 24.12).





**Fig. 24.12** Application of soft, autopolymerizing resin into the cleft to the level of the palate. This material provides increased retention of the obturator by contouring into the cleft. Notice the dam of modeling dough, which aids in the placement of the resin.

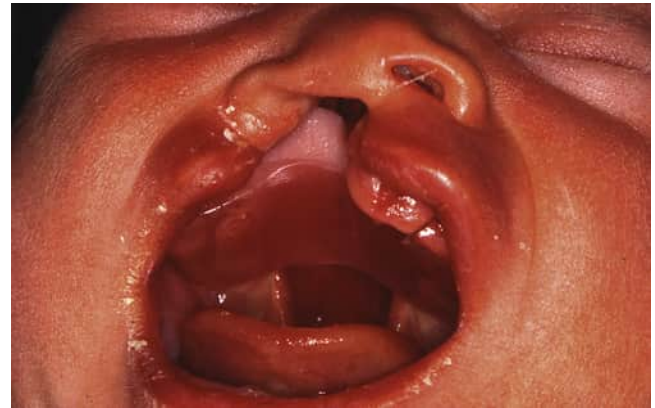

**Fig. 24.13** Maxillary model at the completion of the application of autopolymerizing acrylic resin. The obturator is allowed to cure for 20 minutes and is then trimmed and polished. Notice the extension of the resin into the mucobuccal fold. This extension further increases the retention of the prosthesis.

5. Place the model in a warm, moist environment to cure for 20 minutes.
6. Add autopolymerizing acrylic resin to the palate using a “salt-and-pepper” method, making sure the acrylic resin extends well into the mucobuccal fold area (Fig. 24.13).
7. Remove the appliance from the model, and rinse the wax and modeling dough off with hot water. Then trim and polish the appliance.

### Clinical Management of Initial Obturator Therapy

The appliance is positioned in the infant's mouth (Fig. 24.14). Areas of excessive pressure exerted by the acrylic resin on any intraoral tissues are identified by observation and then reduced. Care is taken to keep the acrylic resin from impinging on muscle attachments or extending to the depth of the buccal vestibule. Parents are instructed in placement and removal of the appliance and its daily cleaning. Infants are usually seen for adjustments 2 days after appliance delivery. After delivery of the obturator, the infant is allowed to become accustomed to the appliance



**Fig. 24.14** Obturator in place on the infant's maxillary arch. Notice the extension of the soft resin into the cleft defect, which provides increased retention. (From Jones JE, Kerkhof RL. Obturator construction for maxillary orthopedics in cleft lip and palate infants, *Quintessence Dent Technol.* 1984;8:583–586.)

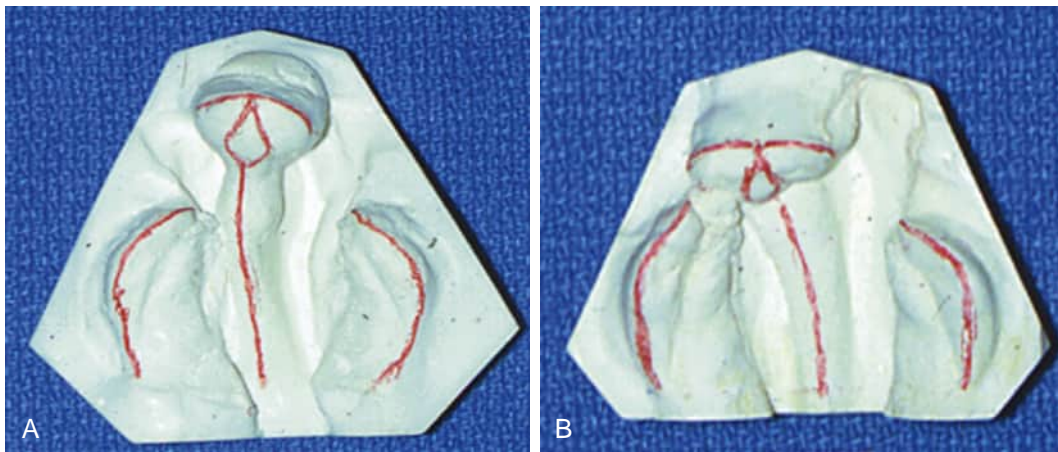
for 1 week. Monthly observations are then scheduled. In most cases, this appliance will serve until the time of initial lip closure at approximately 3 months of age. The major advantage of obturator use during this stage is to enhance the child's ability to obtain nourishment.

Not all clinicians who work with infants with cleft lip and palate advocate the use of prosthetic feeding appliances. Some believe that such appliances are not effective in facilitating feeding. Pashayan and McNab<sup>12</sup> recommend using a standard nipple that has been crosscut. This enlarged cut provides improved ejection of the milk into the infant's mouth with minimum effort. Although this recommendation is appropriate for many infants born with cleft lip and palate, obturator construction may be indicated for children born with more severe facial deformities. This is especially important in consideration of the maxillary orthopedic molding of the alveolar segments after surgical closure of the lip.

### Presurgical Orthopedics

In some cases of bilateral cleft lip and palate, the infant has a premaxillary segment positioned severely anterior to the maxillary arch segments or deviated laterally to one side of the cleft defect (Fig. 24.15). This presents a difficult clinical challenge for the surgeon before surgical closure of the lip. If lip surgery is undertaken with the premaxilla in such an abnormal position, the chances of lip dehiscence (i.e., lip separation caused by increased pressure at the suture lines) are increased. As early as 1686, Hofman<sup>13</sup> described the use of a head cap and premaxillary strap to reposition the premaxilla. Methods of presurgical orthopedics include lip taping across the upper lip.<sup>14</sup> The advantage of this method is its ease of use; however, it does not afford the same control of the force direction and therefore cannot be used in all instances. Newer methods include DynaCleft, which is a premade topical approximation device that has been successfully used to mold the upper lip and alveolus and to support the developing nasal tissues prior to cleft lip repair.<sup>15</sup>

Some researchers have recommended the use of active appliances for the normalization of cleft alveolar segments before initial lip surgery in infants. Latham et al.<sup>16</sup> used a dentomaxillary advancement appliance to bring unilateral cleft segments into approximation. In bilateral clefts,



**Fig. 24.15** Representative diagnostic models of two clinical presentations in bilateral complete cleft lip and palate. (A) Severe anteroposterior protrusion of the premaxillary segment. (B) Severe anteroposterior protrusion of the premaxillary segment with a lateral deviation.

they expanded collapsed lateral cleft segments and actively retracted the premaxilla into a more ideal arch form. They postulated that such presurgical maxillary orthopedic procedures make lip surgery easier and result in less soft tissue tension following closure. In addition, gingivoperiosteoplasty (GPP) can be facilitated at the time of cleft lip repair. This procedure is discussed later in the chapter.

More recently, Grayson and Cutting<sup>17</sup> have promoted the use of a nasolabial molding (NAM) appliance with a nasolabial extension to shape the nasal cleft cartilage. The objective of this presurgical effort is to reduce the severity of the cleft deformity, approximate the alveolar and lip segments, decrease the nasal base width, elongate the columella, and attempt to achieve symmetry of the nasal cartilages (Fig. 24.16). They demonstrated that the aesthetic and functional outcome of the primary lip and nose surgery is more favorable when NAM is used.<sup>18</sup> Critics point out that NAM is labor intensive and therefore not a feasible option for many patients and centers. The benefit of columellar lengthening for patients with bilateral cleft palate is a critical advantage of NAM to nasal reconstruction. With the use of bilateral nasal stents and taping techniques, the almost absent columella in bilateral clefts can be nonsurgically elongated before initial lip and nose surgery. Finally, NAM facilitates GPP at the time of cleft lip repair. This can be of particular advantage in patients with complete bilateral cleft lip and palate because osseous union of the premaxilla with the lesser segment can prevent further descent of the premaxilla or collapse of the lesser segments during subsequent facial development. Advocates of NAM also implement this therapy on patients with a unilateral cleft.

### Airway Obstruction

Infants with airway obstruction secondary to Pierre Robin sequence (micrognathia, glossoptosis, and cleft palate) may require intervention to aid breathing (Fig. 24.17A). An obturator with a posterior palatal extension may be used to reposition the tongue downward and forward out of the cleft site (Fig. 24.17B). Prone positioning, supplemental oxygen, nasopharyngeal tubes, and continuous positive airway pressure may also be helpful. If a nonsurgical approach is unsuccessful, lip-to-tongue adhesion, mandibular distraction, or tracheostomy may be necessary.

### Cheiloplasty

The appearance of an unrepaired wide cleft lip can be distressing. Some parents feel anxiety, depression, guilt, or rejection. Lip surgery will significantly improve the infant's appearance and may thereby relieve parental apprehensions and enhance their acceptance of the child.

Cleft lip repair is typically performed in infants at approximately 3 months of age. Primary nasal reconstruction is commonly performed at the time of lip repair. Prior to the start of surgery when the infant is under general anesthesia, if an obturator has been necessary, an impression is made of the maxillary arch for construction of a new obturator. This is necessary to accommodate craniofacial growth during the first few months of life.

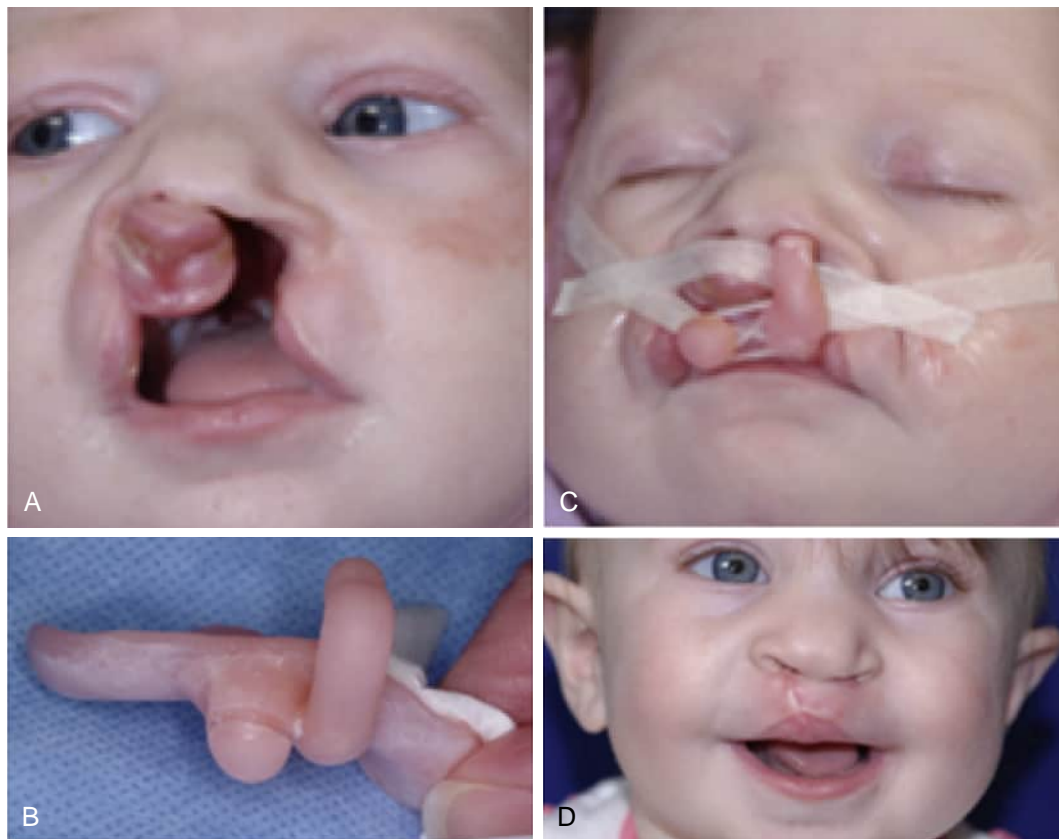### Maxillary Orthopedics

After definitive lip closure, maxillary arch collapse in the unilateral or bilateral complete cleft may occur. This is attributed to the increased tension placed on the segments by the repaired lip. To prevent this collapse, an obturator may be used to provide cross-arch stability and support. As pressure is exerted on the anterior segments of the maxilla by the repaired lip, orthopedic molding of the segments can be achieved. In unilateral cases, the force applied to the greater segment by the intact lip molds that segment around to approximate the lesser segment (Fig. 24.18). This molding is facilitated by the obturator, which provides a fulcrum around which the anterior portion of the greater segment rotates. At the same time, the appliance resists any tendency for the greater and lesser segments to collapse toward the midline. In bilateral cleft cases, the repaired lip provides further retraction at the premaxilla, positioning it between the two lateral maxillary segments. When the maxillary segments are in good alignment and abut across the cleft sites, a primary cleft bone graft can be considered.

### Bone Grafting of Alveolar Cleft Defects

Bone grafting of alveolar cleft defects has been a confusing issue to many patients and practitioners. This stems in part from the lack of unanimity concerning terminology and technique. The following definitions, which have been reasonably accepted by practitioners, will be used in this discussion.





**Fig. 24.16** (A) A 6-week-old infant with a bilateral cleft lip and palate. There is complete bilateral clefting of the palate, an incomplete cleft lip on the right side, and a complete cleft lip on the left side. The premaxilla is displaced anteriorly and to the right side. (B) A nasolabial molding (NAM) that has a left nasal extension designed to give better shaping to the left naris. The acrylic portion that fits over the palate and premaxilla is designed to bring the premaxilla to the center and back into alignment with the right and left alveolar segments. This is accomplished with selective addition and removal of acrylic. (C) The infant with the NAM appliance in place and active at almost 3 months of age. (D) The infant after lip repair. The premaxilla has been brought into good arch alignment with the alveolar segments. (Photos courtesy of Jennifer Kugar, DDS, MSD, James Whitcomb Riley Hospital for Children, Craniofacial Anomaly Team.)

Primary bone grafting refers to bone grafting procedures involving alveolar cleft defects in children younger than 2 years of age; this term implies nothing about technique. Secondary bone grafting is usually performed in the mixed dentition stage, between 9 and 12 years of age.

### Primary Alveolar Cleft Bone Grafting

Primary alveolar cleft bone grafting is controversial. The concept fell into disfavor in the early 1970s amid numerous reports of significant attenuation in midfacial growth. Use of a primary alveolar cleft bone graft does not necessarily preclude a later secondary alveolar cleft bone graft if it is indicated. The objectives of a secondary cleft bone graft can be somewhat different, as will be seen. Although a recent survey of cleft and craniofacial teams conducted by the American Cleft Palate–Craniofacial Association reported that only 3% of teams perform primary alveolar cleft bone grafting, continued critical evaluation of early alveolar bone grafting and outcomes from cleft centers utilizing this technique is necessary.

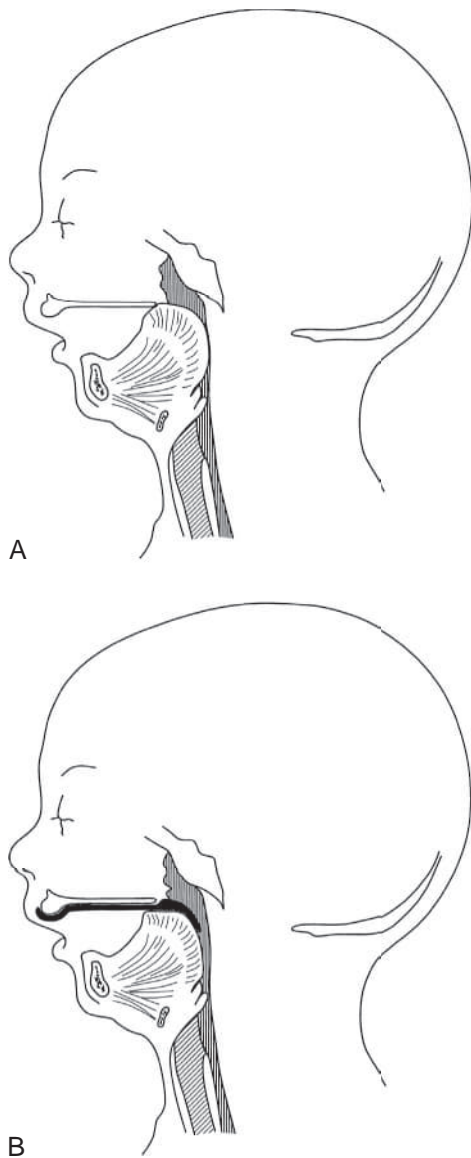
### Alternatives to Primary Alveolar Cleft Bone Grafting

A different approach to normalizing the cleft alveolar segment relationships has been advocated by Huebener and

Marsh.<sup>19</sup> In their treatment protocol, which uses the forces created by either lip adhesion or primary lip closure, a passive alveolar molding appliance similar to that used by Rosenstein<sup>20</sup> is used. The passive appliance does not have an acrylic extension over the alveolar ridges, and it is placed on the day of the lip surgery. The tension created by lip closure acts over time on the anterior alveolar cleft segments (in both unilateral and bilateral clefts) and shapes these cleft segments around the anterior portion of the molding appliance. The appliance is worn by the infant until palatoplasty. Usually at that time, the cleft segments are abutting and the torqued maxillary frenum has returned to the midsagittal plane. In this protocol, no primary alveolar bone grafting is performed.

Another technique that has gained favor in some cleft centers is GPP. This technique takes advantage of the osteogenic properties of infants rather than grafts to bridge the bony cleft of the alveolus. Originally described by Skoog,<sup>21</sup> GPP has the potential of restoring the alveolar arch at the time of infancy through “boneless bone grafting.” Mucoperiosteal flaps are raised, usually at the time of cleft lip repair, and then sealed over the alveolar cleft without the use of a primary bone graft. This procedure requires closure of the nasal floor during cleft lip repair and anatomic realignment of the alveolar segments by presurgical orthopedics prior to reconstruction. Typically, the Latham device or



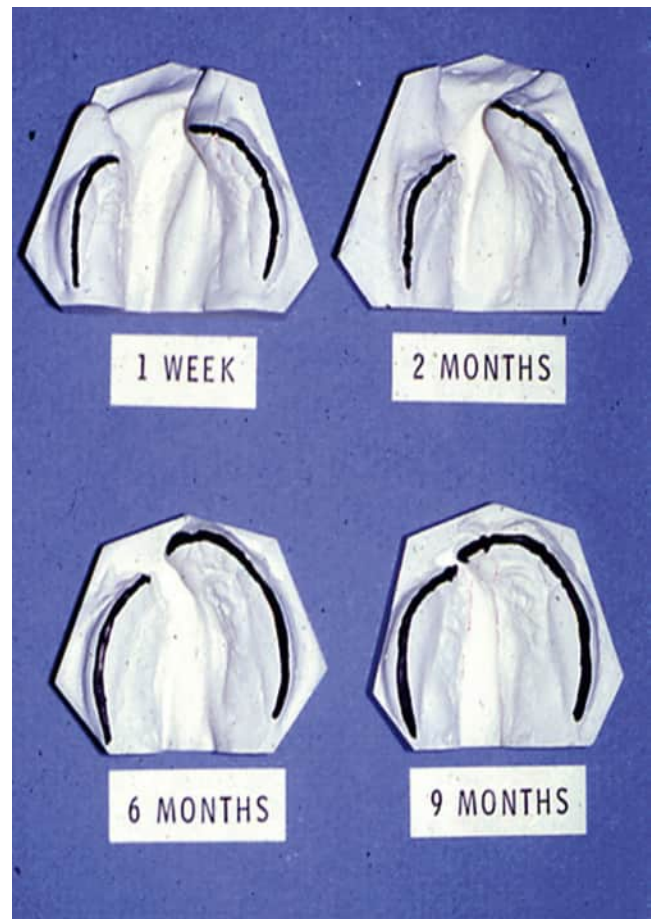


**Fig. 24.17** (A) Infant with airway obstruction secondary to Pierre Robin sequence. Notice the closure of the oral airway related to the retroposition of the tongue. (B) Infant with obturator in position. Notice the anterior placement of the tongue, which allows the oral airway to remain open.

NAM is used. Although bone formation is possible through GPP, the consistency of bone formation and the avoidance of secondary bone grafting remain areas of active debate. Furthermore, the potential detriment to facial growth and tooth formation has not been entirely elucidated. Despite these limitations, GPP has been embraced in several institutions and remains an area of active research.

### Palatoplasty

Closure of the palate is accomplished by 1 year of age, primarily to facilitate the acquisition of normal speech because this correlates with the age at which most children begin to talk. The procedure may also improve hearing and swallowing by aligning the cleft palatal musculature. Dedicated speech therapy is critical in the years following surgery to optimize palatal function.



**Fig. 24.18** Sequential maxillary arch dental models demonstrating maxillary orthopedic molding in an infant with a unilateral complete cleft lip and palate. Notice that as the cleft defect closes with time, lateral arch dimension is maintained, which produces optimal maxillary arch symmetry. (From Jones JE, Kerkhof RL, Nelson CL, et al, Maxillary arch expansion in cleft lip and palate infants prior to primary autogenous alveolar bone graft surgery, *Quintessence Int.* 1986;17(4):245–248.)

After primary closure of the cleft palate, some patients may demonstrate velopharyngeal insufficiency requiring secondary surgery. A persistent inability to close the nasopharynx may result in unsatisfactory speech (nasality and articulation problems), regurgitation of fluids from the nose, and facial grimacing. At Indiana University, of the various surgical approaches to correct velopharyngeal insufficiency, the pharyngeal flap is most commonly used. Velopharyngeal insufficiency is definitely diagnosed by nasoendoscopy, which is generally performed before the child begins school.

### Dental Care

One of the most important aspects of cleft lip and palate care is infant oral health care. At this time, the American Academy of Pediatric Dentistry advocates the “age one” dental visit.<sup>22</sup> During this visit, the pediatric dentist examines the oral cavity, notes any abnormalities in the soft and hard tissues, and provides anticipatory guidance to the parents regarding oral health care. Also, during this visit, emphasis is placed on the prevention of oral disease. In particular, this first visit offers parents an opportunity to discuss the many developmental issues unique to the cleft deformity (Table 24.3).

**TABLE 24.3** Oral Health Risk Factors for Children With Oral Facial Clefting<sup>22</sup>

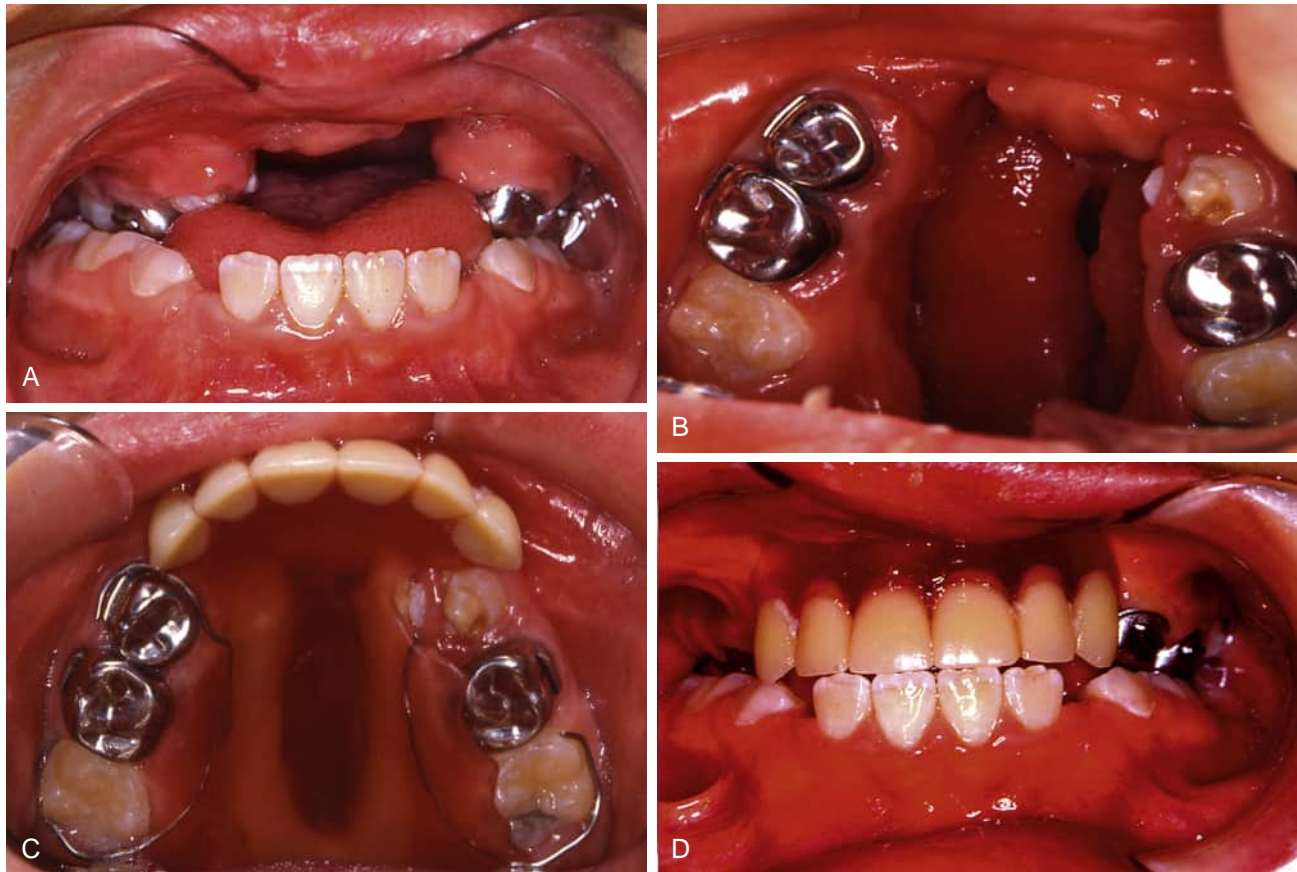
Caries Risk Factors	Periodontitis Risk Factors
Enamel defects (hypoplasia) of teeth adjacent to the cleft site	Poorly developed osseous supports and lack of proper connective attachment of teeth associated with the cleft
Parents who are overwhelmed with numerous medical needs of the child such that oral health has a comparatively low priority	Abnormalities of size, shape, and number and malalignment of teeth associated with the cleft
Use of an acrylic obturator	Inadequate oral hygiene
Longer oral clearance times	Orthodontic appliances
Permissive parenting, which may allow a highly cariogenic diet and less-than-adequate oral hygiene home care	Subgingival restorations
Orthodontic appliances, which impede adequate hygiene	Discontinuous and infrequent periodontal maintenance
Significant lip scarring and/or malalignment of teeth, which make the cleft area more difficult to clean	
Oral aversion and/or fear of toothbrushing	
Cognitive or motor impairment, which may lead to ineffective oral hygiene	

**STAGE II (PRIMARY DENTITION STAGE: 18 MONTHS TO 5 YEARS OF AGE)**

Treatment during the primary dentition stage of dental development is initially focused on establishing and maintaining oral health. Meticulous daily oral hygiene for the child, with emphasis on direct assistance from the parents, is established to reduce the possibility of the development of dental caries. Ectopic eruption of the primary maxillary anterior dentition is common around the cleft defect.

Special care should be taken to keep these teeth free from caries because food is often lodged in and around the cleft defect. An increase in the frequency of periodic recall examinations, possibly to 3- to 4-month intervals, enables the dentist to intercept areas of decalcification. This preventive regimen is continued throughout all subsequent stages in the management of the cleft.

In some extensive cases of unilateral and bilateral complete clefts of the lip and palate, surgical closure is postponed beyond the usual 12 months of age. In these cases, because of the development of speech at this age, maxillary prosthetic appliances are constructed to provide normal maxillary arch integrity (Fig. 24.19). As the child grows, more tissue will become available to close the palate.



**Fig. 24.19** (A) Intraoral view of a unilateral complete cleft lip and palate. Because of the extensive cleft of the hard and soft palates, the treatment of choice was prosthodontic obturation of the defect until growth was sufficient to allow for definitive surgical closure. (B) Maxillary arch demonstrating extensive cleft palate requiring an interim prosthesis. (C) Interim maxillary prosthesis in place. This effectively closes the oral cavity from the nasal cavity and facilitates mastication and speech. The appliance is removed daily for cleaning. (D) Interim prosthesis in occlusion. The prosthetic anterior teeth provide support of the upper lip and improve aesthetics.



### STAGE III (LATE PRIMARY OR EARLY MIXED DENTITION STAGE: 6 TO 10 OR 11 YEARS OF AGE)

Many problems encountered during the late primary and mixed dentition stages of dental development arise from ectopically erupting permanent central and lateral incisors or crossbites of the posterior dental segments. Treatment therefore concentrates on correction of a developing traumatic occlusion and posterior segmental alignment. Interceptive correction of a traumatic occlusion is essential to prevent destruction of enamel in the involved dentition (Fig. 24.20). Maxillary expansion to correct posterior segmental collapse is accomplished by routine palatal expansion (Fig. 24.21). This is especially important in patients who have not undergone primary alveolar cleft bone grafting. Once the condition is corrected, retention can be maintained by passive holding appliances.

#### Secondary Alveolar Cleft Bone Graft

A successful alveolar cleft bone graft satisfies several objectives. In addition to giving bony support for the teeth adjacent to the cleft and providing bone through which teeth can erupt, it offers maxillary arch continuity and aids in closure of the oronasal fistula. It also supports the alar base of the nose.

Conceptually, the technique is not difficult, but technically it can be tedious. There are several approaches to developing the required soft tissue flaps, but all seem to be variations of the technique described by Boyne and Sands.<sup>23</sup> The soft tissue in and adjacent to the cleft side is incised and elevated so that labial and palatal mucosal leaflets are everted to obtain labial and palatal closure. The tissues lining the cleft are elevated and inverted into the nose for nasal floor closure. Particulate marrow and cancellous bone harvested from the iliac crest are placed into the cleft defect, filling it from the piriform rim to the alveolar crest before closure of the labial tissues (Fig. 24.22).

Providing bony support to teeth adjacent to the cleft site is of paramount importance (Fig. 24.23). In most cases, bone should be grafted into the cleft before orthodontic tooth alignment is begun. When the cleft is filled with normal, viable bone, the orthodontist can proceed with tooth alignment without fear of exposing a root surface into the cleft site. In fact, after a 2-month healing period, a tooth can be moved into the newly grafted bone with the expectation that the bone will respond to the tooth movement as any normal bone would. Orthodontic tooth movement completed prior to alveolar bone grafting must be completed with awareness of root proximity to the cleft site.

As a related consideration, grafted bone that obliterates the alveolar cleft also provides bone through which teeth can erupt. When canines and, in some cases, central or lateral incisors are allowed to erupt before bone grafting, they often lack adequate periodontal bone support. When the bone graft precedes permanent tooth eruption, compromised periodontal situations can often be prevented. El Deeb et al.<sup>24</sup> studied the eruption patterns of canines through the grafted bone in alveolar cleft defects. They found that canine teeth erupted spontaneously through the grafted bone, but that this eruption may be later than normal and takes longer. In their study, 27% of the

canines erupted spontaneously. The remainder required surgical uncovering and orthodontic forces to accomplish eruption and alignment in the arch. Turvey et al.<sup>25</sup> found the rate of spontaneous eruption to be 95%, which represents a significant difference. However, the point is that canines can and do erupt through the grafts. If eruption seems greatly delayed, surgical and orthodontic intervention is appropriate.

El Deeb et al.<sup>24</sup> have recommended that the graft be placed between 9 and 12 years of age when the canine root is one-quarter to half formed. They reported that the canine subsequently has normal root development and that morphologic conditions will be unaffected by the surgical procedure.

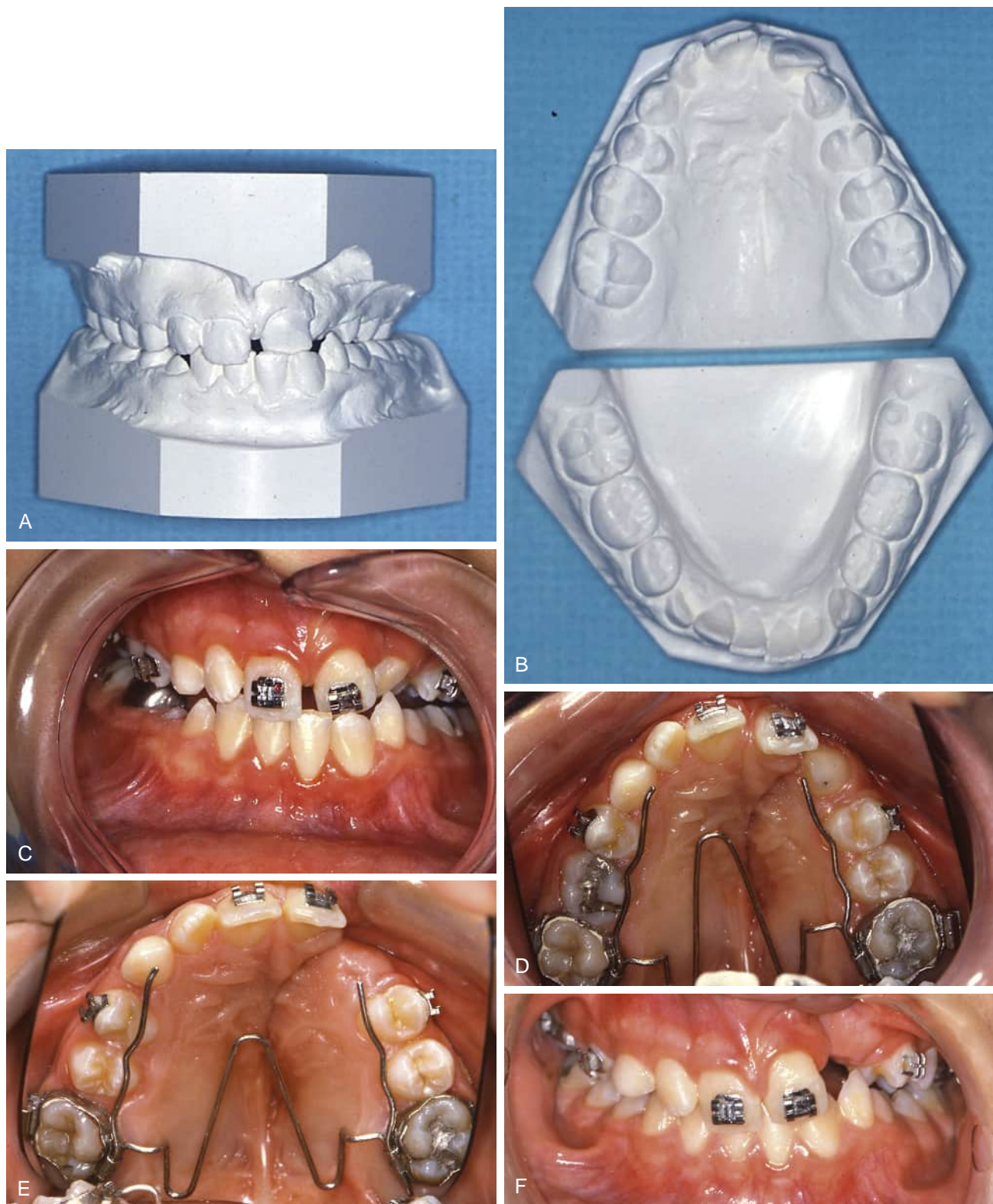
Restoring maxillary arch continuity and stabilizing the maxillary segments represent other major objectives. In the case of a bilateral cleft, the premaxilla is stabilized as the bone grafts are incorporated between the premaxilla and the lateral maxillary segments. In the process, the alveolar ridge contour is restored so that the ability to provide a stable, aesthetic prosthesis is enhanced. There is often some degree of collapse of the maxillary arch form. It is possible to expand the arch after grafting, as pointed out by Boyne and Sands<sup>26</sup>; however, it is preferable to expand these collapsed segments to as optimal an arch form as possible before grafting. Pregraft expansion also widens the cleft site, which allows better access for nasal floor closure. After the arch expansion has occurred, the bone graft can be placed. After the graft has been incorporated, it can be expected to maintain a good arch form.

Closure of the oronasal fistula is often the most significant result of bone graft surgery, according to patients who often experience fluid regurgitation into the nose and mucus drainage from the nose into the oral cavity through the fistula. Depending on its size, the fistula can produce significant speech problems because air escapes when the patient phonates. Although closure of this fistula can be effected with only soft tissue closure, Enemark et al.<sup>27</sup> have indicated that closure is more successful when combined with a bone graft.

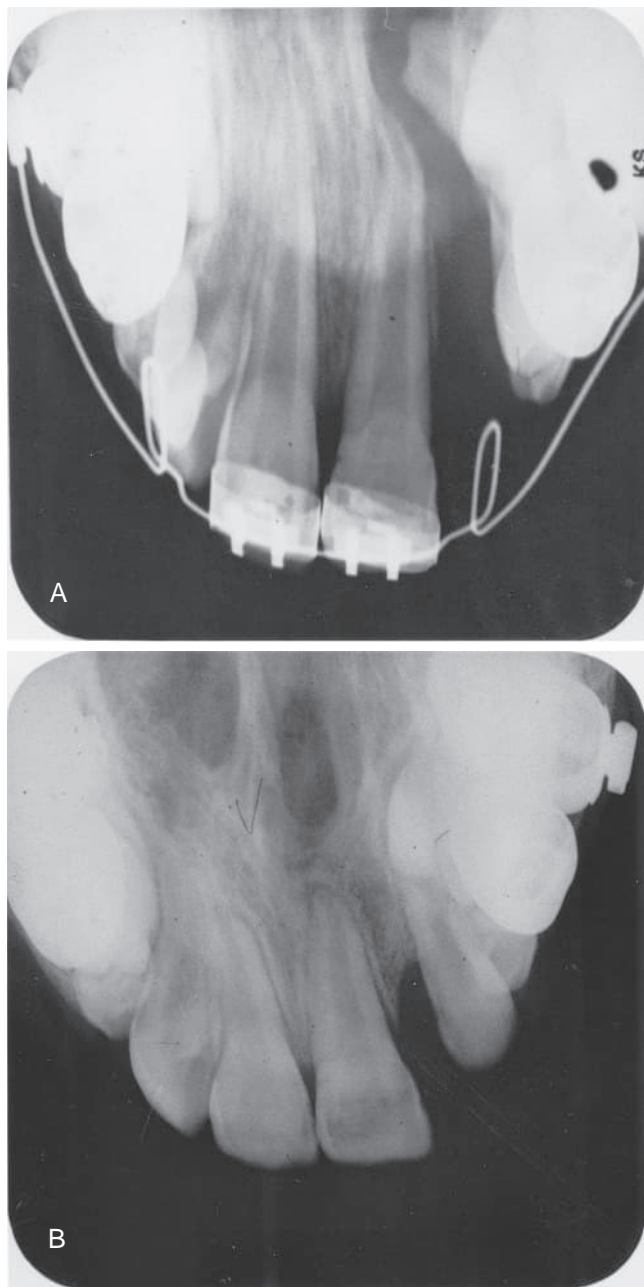
With a cleft maxilla, the cleft extends through the piriform rim beneath the alar base of the nose. As a result, the alar base on the cleft side is often depressed because of lack of underlying bony support. Filling the cleft with bone provides underlying bony support that often elevates the alar base of the nose. Although this may not entirely correct any existing nasal deformity, it does provide good support over which nasal reconstructive and revision surgery can be accomplished.

Secondary alveolar cleft bone grafting has been widely accepted. According to several researchers,<sup>26,28-32</sup> success rates are generally around 90%. Morbidity includes pain in the donor site, dehiscence of mucosal flaps, and partial or complete loss of grafted bone. Infection in the donor or recipient sites has been rare. There has been increasing interest in many cleft centers in decreasing the morbidity of secondary alveolar grafts by replacing iliac bone with growth factors such as bone morphogenetic protein combined with cadaveric bone or other nonautogenous implants.<sup>33,34</sup> The advantages to function and decreasing morbidity are topics of active debate. The potential morbidity of placing bone growth factors in the growing dental





**Fig. 24.20** Interceptive correction, in the mixed dentition, of a full maxillary left crossbite in a complete unilateral cleft lip and palate. (A) Diagnostic models for a unilateral complete cleft lip and palate. Notice the presence of a crossbite extending from the maxillary left central incisor to the maxillary first permanent molar. (B) Occlusal views of maxillary and mandibular models. Notice the pronounced asymmetry of the maxillary arch. (C) Occlusion with fixed appliances in place on the maxillary arch. (D) Occlusal view demonstrating removable W-arch to correct the posterior segmental crossbite. (E) Occlusal view demonstrating correction of posterior crossbite and improved alignment of the maxillary anterior segment. Notice the improved maxillary arch symmetry. (F) Occlusion at the end of interceptive therapy. Notice the correction of the anterior and posterior crossbites. At this time, the patient is ready for secondary alveolar bone grafting (see text for the description of secondary bone grafting procedure).



**Fig. 24.21** Interceptive correction, in the primary dentition, of a full maxillary left crossbite in a complete unilateral cleft lip and palate. (A) Occlusion demonstrating a crossbite from the maxillary left primary incisor extending to the second primary molar. (B) Fixed palatal expander in place on the maxillary arch at the completion of expansion. The left primary central incisor, loosened by traumatic occlusion before initiation of therapy, exfoliated during treatment. (C) Occlusion at the completion of interceptive therapy. Notice the correction of the posterior crossbite. (D) Placement of a passive maxillary arch-holding appliance to maintain optimal arch symmetry until the time of secondary alveolar bone grafting.

arch has prevented many surgeons from embracing this treatment option.<sup>35</sup> Secondary alveolar cleft bone grafting is an important procedure that greatly facilitates total habilitation. Not only is speech improved but dental, aesthetic, and psychosocial benefits are also to be gained. It is necessary, again, to emphasize the different objectives of primary and secondary grafting and to reiterate that they

are not mutually exclusive procedures. The primary graft, over time, may satisfy some or all the objectives of secondary grafting. However, due to risks to future facial growth and aesthetics, primary grafting has been abandoned by most cleft centers in favor of secondary grafting only.

### Effect of Facial Aesthetics on Self-Concept

Appearance helps determine how an individual interacts with society and, in turn, how society perceives and accepts that individual. Facial aesthetics is especially important to the development of self-concept. A child born with a serious congenital facial anomaly may find adaptation difficult. For example, Stricker et al.<sup>35</sup> have stated that the psychological sequelae of cleft lip and palate may have as great an impact on the individual as the physical aspects. MacGregor<sup>36</sup> stressed that because of society's emphasis on physical attractiveness and conformity, the role of the face in interactions with others is such that many problems associated with cleft lip and palate involve considerations of mental health. Revisional surgery to the lip and nose can be considered at this time to assist in psychosocial development.

Of special importance in the comprehensive dental management of cleft lip and palate is the dentist's ability to provide the young patient with interim prostheses to improve facial appearance (Fig. 24.24). These can be periodically adjusted to allow for eruption of the developing dentition. Such treatment, when possible, should begin before the child starts formal education.

### STAGE IV (PERMANENT DENTITION STAGE: 12 TO 18 YEARS OF AGE)

The majority of persons with cleft lip and palate require some degree of orthodontic management and can be treated conventionally. Some patients with clefts, however, will require a combined orthodontic-surgical approach in the permanent dentition to achieve optimal outcome. Before initiating the indicated therapy, the orthodontist completes a full diagnostic examination to determine the status of the patient's craniofacial development.

Most orthognathic surgical procedures involving the maxilla and mandible are deferred until the teenage years, when maximum growth of the jaws has been attained and all permanent teeth except the third molars have erupted. In boys, surgeons usually delay osteotomies until approximately 17–18 years of age, whereas because of earlier maturation in girls, surgery after 15 years of age is possible. The manner in which the maxilla and mandible relate to each other spatially after growth is frequently difficult to predict based on the patient's appearance as a child. An example is the patient with a complete bilateral cleft lip and palate who has a protuberant premaxilla at birth. In childhood, the lateral profile may appear severely convex, and the initial impression is that the patient will require a premaxillary segment surgical setback. This could be an erroneous assumption, and corrective surgery could be potentially deleterious if it is performed at an early age. With time, many of these persons acquire an essentially normal lateral facial profile. By the time maximum growth has been attained, a surprising number of these persons acquire a more normal convex profile.



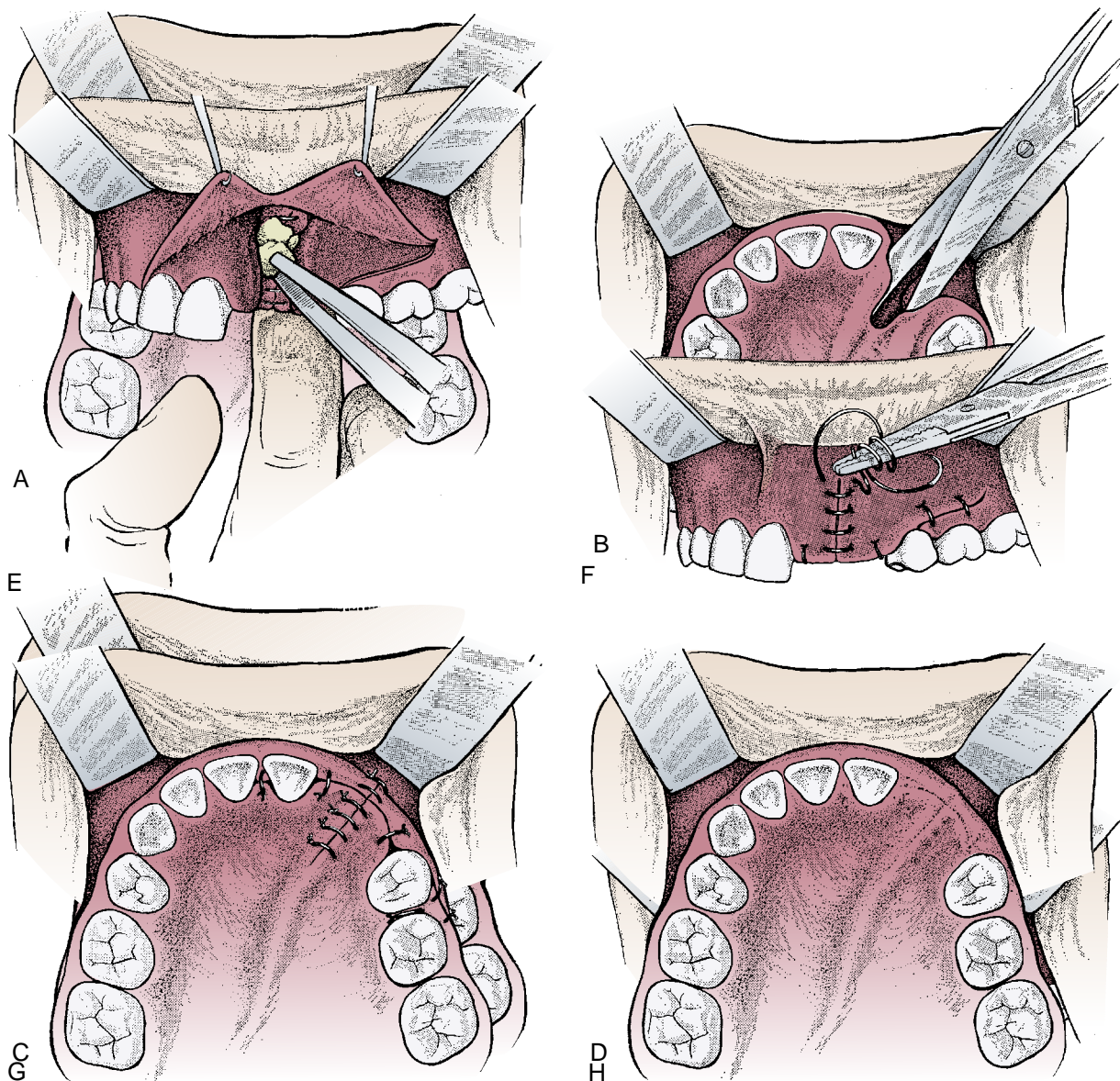


Fig. 24.22 Technique for secondary alveolar cleft bone graft. (A) Mucosal incisions outlined. (B) Development of palatal mucoperiosteal flap. (C) Closure of palatal mucosa. (D) Closure of nasal mucosa within cleft site. (E) Placement of fresh autogenous bone into the cleft defect. (F) and (G) Reapproximation and closure of mucoperiosteal flaps. (H) The reconstructed maxillary alveolus.

In some instances, children with a cleft with a severely retrusive maxilla cannot undergo orthodontic correction with conventional therapy. In these cases, the surgical procedure often used is the LeFort I maxillary advancement with or without setback of the lower jaw. This procedure is not technically feasible until the patient has a full complement of permanent dentition. The horizontal cuts to free the maxilla must necessarily be made above the apexes of the permanent dentition. At times the maxilla will require partition into two or three segments to achieve full dental restoration. Unerupted cuspids or bicuspid would make this procedure impractical. Therefore surgery must be deferred until the permanent dentition has erupted.

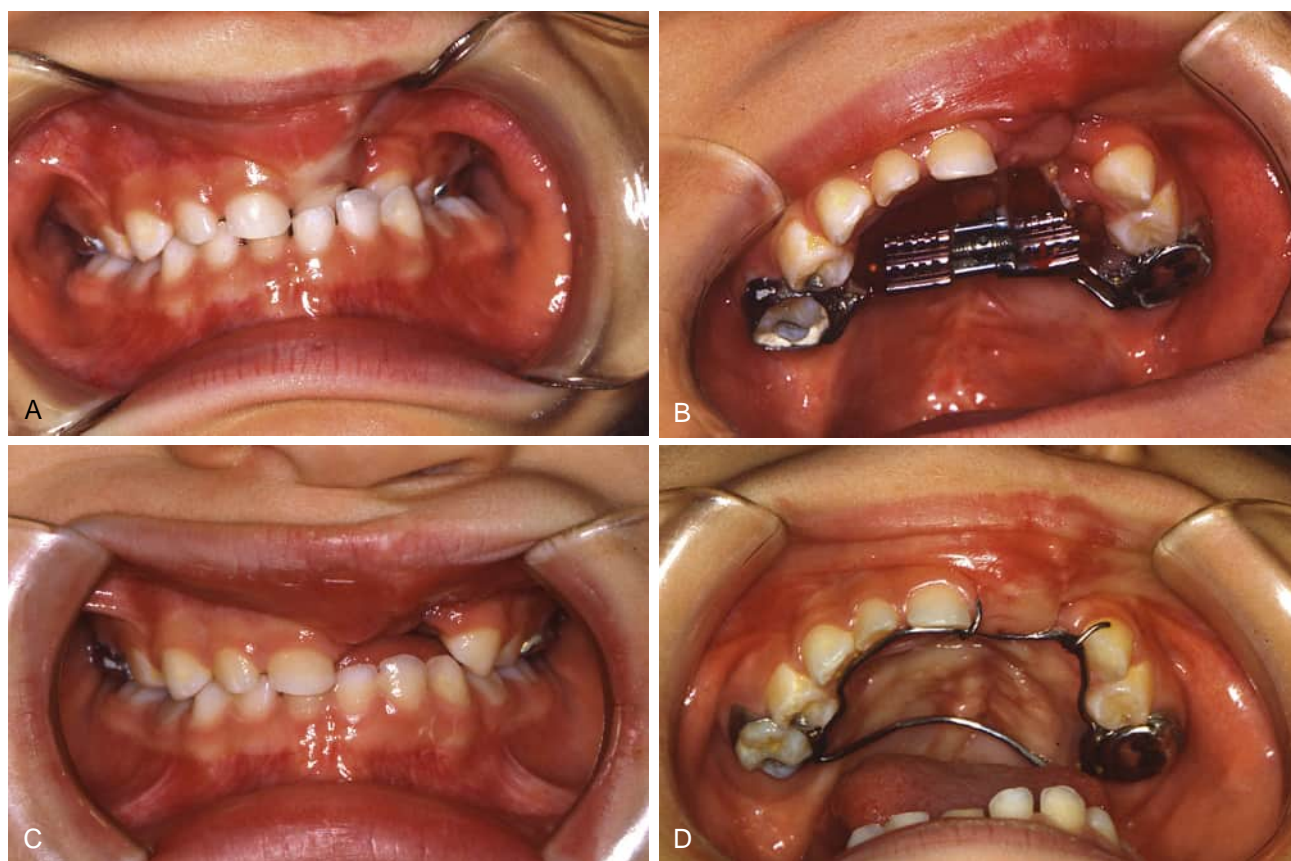
Notably, in nearly all end-stage orthognathic surgery patients, all comorbidities, including the risk of obstructive sleep apnea, must be taken into consideration prior to

surgical planning. Baseline apnea-hypopnea index should be evaluated prior to final orthognathic treatment planning. Furthermore, large maxillary advancement can cause velopharyngeal incompetence, in certain cases, as the soft palate is pulled anteriorly with the maxilla. If this occurs, secondary pharyngeal surgery may be required to correct nasal speech and patients should be aware of this possibility.

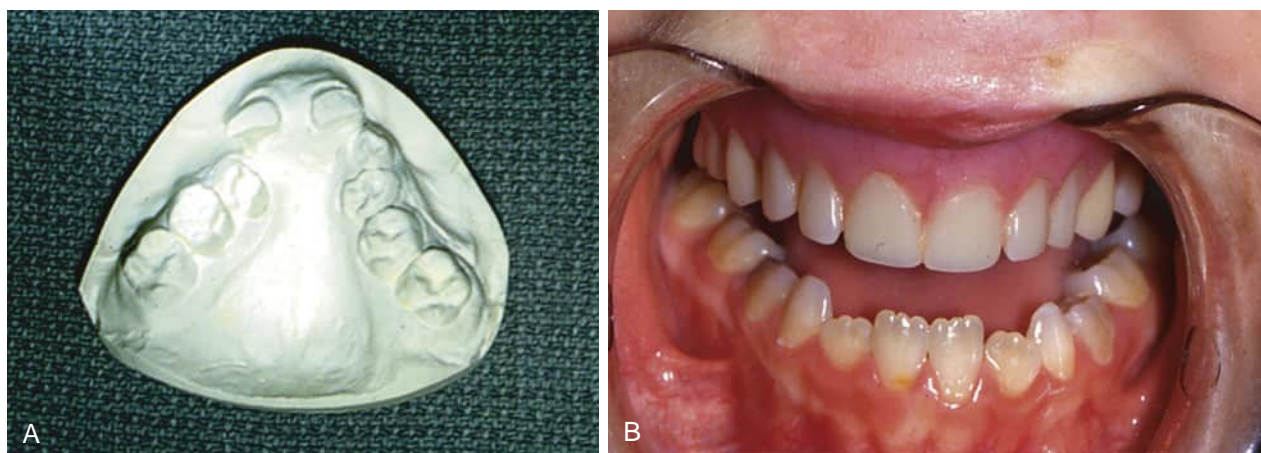
### Cosmetic Surgery

Major nasal bone surgery may be deferred until the patient is in the early teens and after orthognathic surgery. These procedures help restore projection, symmetry, refinement, and airflow to the nose. However, cartilaginous nasal tip asymmetries may be corrected at any time. Additional tip-cartilage revisions may be performed as needed.





**Fig. 24.23** (A) Pregraft maxillary occlusal radiograph demonstrating cleft defect with thin layer of bone over the distal root surface of the maxillary left central incisor. The canine has not started to erupt. (B) Postgraft maxillary occlusal radiograph demonstrating consolidation of bone across the cleft defect. Preliminary orthodontic alignment has been completed. The canine can be expected to erupt through the grafted area. (From Nelson CL, Jones JE, Sadove AM. Indiana's craniofacial anomalies team: dentists play an important role. *J Indiana Dent Assoc.* 1986;65(6):9-13.)



**Fig. 24.24** (A) Plaster model of patient's maxillary arch ready for construction of the interim denture. (B) Transitional maxillary complete overdenture. Such appliances may be used for several years without replacement. (C) Transitional maxillary overdenture in place. The patient's self-esteem is greatly enhanced by his essentially normal facial aesthetics.

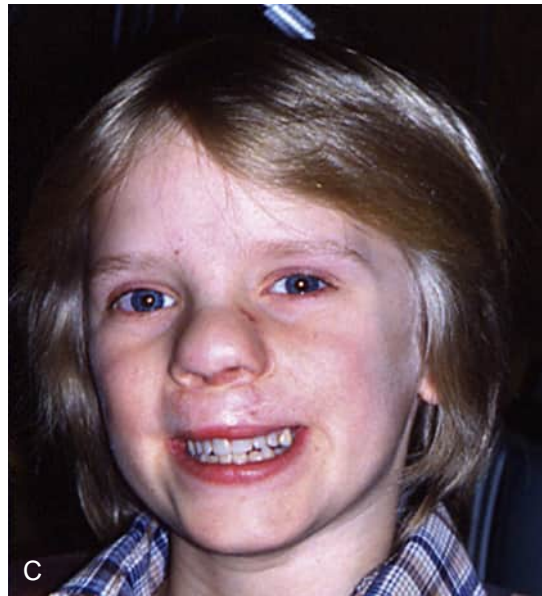

Fig. 24.24 Cont'd

Common secondary deformities of the repaired unilateral or bilateral cleft lip include an upper lip that is too long or short, a tight upper lip, a deficiency of the vermilion tissue, and residual clefts (or notching) of the lip. Final surgical revision is frequently deferred until the mid to late teens, to eliminate the variable of future facial growth on the surgical result. It is also prudent to defer final lip revisions until the completion of any surgical or orthodontic treatment that will change the osseous or dental support of the upper lip.

### References

- Mossey PA, Little J, Munger RG, et al.: Cleft lip and palate, *Lancet* 374(9703):1773–1785, 2009.
- Mastroiacovo P, Maraschini A, Leoncini E, et al.: Prevalence at birth of cleft lip with or without cleft palate: data from the International Perinatal Database of Typical Oral Clefts (IPDTC), *Cleft Palate Craniofac J* 48(1):66–81, 2011.
- Harkins CS, Berlin A, Harding RL, et al.: A classification of cleft lip and palate, *Plast Reconstr Surg Transplant Bull* 29(1):31–39, 1962.
- Veau V: Treatment of the unilateral harelip, *Int Dent Congress 8th Trans Paris* 126–131, 1931.
- American Cleft Palate-Craniofacial Association: Parameters for the evaluation and treatment of patients with cleft lip/palate or other craniofacial anomalies, *Cleft Palate Craniofac J* 30(Suppl 1), 2007.
- Whitehouse FA: Treatment as a dynamic system, *Cleft Palate J* 2(1):16–27, 1965.
- Chibbaro P, Barzilai J, Breen M: Nursing care of the patient with a cleft lip and palate. In Loose J, Kirschner R, editors: *Comprehensive Cleft Care*, New York, 2009, McGraw-Hill, pp 150–167.
- Miller CK: Feeding issues and interventions in infants and children with clefts and craniofacial syndromes, *Semin Speech Lang* 32(2):115–126, 2011.
- McNeil CK: *Oral and Facial Deformity*, London, 1954, Pittman.
- McNeil CK: Congenital oral deformities, *Br Dent J* 101:191–198, 1956.
- Jones JE: *The use and clinical effectiveness of the maxillary obturator appliance in cleft lip and palate infants: birth through six months of age [Doctoral dissertation]*, San Jose, Costa Rica, 2003, Empresarial University.
- Pashayan HM, McNab M: Simplified method of feeding infants with cleft palate with or without cleft lip, *Am J Dis Child* 133(2):145–147, 1979.
- Hofman JP: De labiis leoporinis/von Hasen-Scharten. Bergmann: Heidelberg.
- Pool R, Farnworth TK: Preoperative lip taping in the cleft lip, *Ann Plast Surg* 32(3):243–249, 1994.
- Monasterio L, Ford A, Gutiérrez C, et al.: Comparative study of nasoalveolar molding methods: nasal elevator plus DynaCleft® versus NAM-Grayson in patients with complete unilateral cleft lip and palate, *Cleft Palate Craniofac J* 50(5):548–554, 2013.
- Latham RA, Kusy RP, Georgiade NG: An extraorally activated expansion appliance for cleft palate infants, *Cleft Palate J* 13(3):253–261, 1976.
- Grayson BH, Cutting CB: Presurgical nasoalveolar orthopedic molding in primary correction of the nose, lip, and alveolus of infants born with unilateral and bilateral clefts, *Cleft Palate Craniofac J* 38(3):193–198, 2001.
- Barillas I, Dec W, Warren SM, et al.: Nasoalveolar molding improves long-term nasal symmetry in complete unilateral cleft lip-cleft palate patients, *Plast Reconstr Surg* 123(3):1002–1006, 2009.
- Huebener DV, Marsh JL: *A survey of early management of cleft lip and palate—the first 18 months*, Unpublished data presented at the American Cleft Palate-Craniofacial Annual Meeting, 2002.
- Rosenstein SW: Orthodontic and bone grafting procedures in a cleft lip and palate series: an interim cephalometric evaluation, *Angle Orthod* 45(4):227–237, 1975.
- Skoog T: The use of periosteum and Surgicel for bone restoration in congenital clefts of the maxilla, *Scand J Plast Surg* 1(2):113–130, 1967.
- American Academy of Pediatric Dentistry. Guideline on infant oral health care, In *American Academy of Pediatric Dentistry Reference Manual 2008-9*. American Academy of Pediatric Dentistry: Chicago.
- Boyne PJ, Sands NR: Secondary bone grafting of residual alveolar and palatal clefts, *J Oral Surg* 30(2):87–92, 1972.
- ElDeeb M, Messer LB, Lehnert MW, et al.: Canine eruption into grafted bone in maxillary alveolar cleft defects, *Cleft Palate J* 19(1):9–16, 1982.
- Turvey TA, Vig K, Moriarty J, et al.: Delayed bone grafting in the cleft maxilla and palate: a retrospective multidisciplinary analysis, *Am J Orthod* 86(3):244–256, 1984.
- Boyne PJ, Sands NR: Combined orthodontic surgical management of residual palato-alveolar cleft defects, *Am J Orthod* 70(1):20–37, 1976.
- Enemark H, Krantz-Simonsen E, Schramm JE: Secondary bone grafting in unilateral cleft lip and palate patients: indications and treatment procedure, *Int J Oral Surg* 14(1):2–10, 1985.
- Bertz JE: Bone grafting of alveolar clefts, *J Oral Surg* 39:874–877, 1981.

29. Hall HD, Posnick JC: Early results of secondary bone grafts in 106 alveolar clefts, *J Oral Maxillofac Surg* 41(5):289–294, 1983.
30. Kortebein MJ, Nelson CL, Sadove AM: Retrospective analysis of 135 secondary alveolar cleft bone grafts, *J Oral Maxillofac Surg* 49(5):493–498, 1991.
31. Kwon HJ, Waite DE, Stickel FR, et al.: The management of alveolar cleft defects, *J Am Dent Assoc* 102(6):848–853, 1981.
32. Troxell JB, Fonseca RJ, Osbon DB: A retrospective study of alveolar cleft grafting, *J Oral Maxillofac Surg* 40(11):721–725, 1982.
33. Canan Jr LW, da Silva Freitas R, Alonso N, et al.: Human bone morphogenetic protein-2 use for maxillary reconstruction in cleft lip and palate patients, *J Craniofac Surg* 23(6):1627–1633, 2012.
34. Dickinson BP, Ashley RK, Wasson KL, et al.: Reduced morbidity and improved healing with bone morphogenetic protein-2 in older patients with alveolar cleft defects, *Plast Reconstr Surg* 121(1):209–217, 2008.
35. Stricker G, Clifford E, Cohen LK, et al.: Psychosocial aspects of craniofacial disfigurement: a “state of the art” assessment conducted by the Craniofacial Anomalies Program Branch, the National Institute of Dental Research, *Am J Orthod* 76(4):410–422, 1979.
36. MacGregor FC: Social and psychological implications of dentofacial disfigurement, *Angle Orthod* 40(3):231–233, 1970.



## 25

# Prosthodontic Treatment of the Adolescent Patient

MATHEW T. KATTADIYIL and POOYA SOLTANZADEH

## CHAPTER OUTLINE

### Restoration of Single Malformed, Discolored, or Fractured Teeth

Direct Restoration of Discolored Teeth  
Teeth With Pulpal Involvement  
All-Ceramic and Metal-Ceramic Crowns  
Conservative Indirect Restorations

### Fixed Partial Dentures

Resin-Bonded Retainers  
Complete Crown Retainers  
Fixed Partial Denture Pontics

### Removable Partial Dentures Overdentures

### Implant Prosthesis

### Recare Program

### Protective Mouthguards

Fabrication of Mouthguard Using Digital Workflow

Occlusal Guards for Therapeutic Effect

CAD-CAM Applications in Pediatric Dentistry

Scientific advancements in the areas of preventive dentistry, access to and use of dental services, water fluoridation, topical application of fluorides, and new commercial preventive dentistry products have led to substantial reductions in the incidence of dental diseases in developed countries. However, Caplan and Weintraub<sup>1</sup> determined that adolescents are still affected by caries, particularly those who are minorities, are rural inhabitants, have minimal fluoride exposure, and are from less educated and less affluent families. Results of a health and nutrition survey reported by Vargas et al.<sup>2</sup> also support a higher prevalence of caries among lower-income children and minorities. Assessments of periodontal health by Barmes and Leous<sup>3</sup> show a decrease in the severity of periodontal disease.

Dental trauma continues to be a significant problem among adolescents, as supported by the assessment of orofacial injury by Gift and Bhat<sup>4</sup> and estimates of the incidence and consequences of tooth fracture by Bader et al.<sup>5</sup> In addition, bulimia, anorexia, and dietary habits have led to an increase in the erosion of tooth structure among teenagers, particularly in girls.

Some of the aesthetic treatment needs resulting from these conditions can be managed with resin-bonding procedures and porcelain laminate veneers, and, whenever possible, these should be considered as first-choice treatments. When these procedures have not provided a satisfactory result or when teeth are missing, then prosthodontics such as single crowns, fixed partial dentures, implant prostheses, or removable prostheses are indicated.

Because adolescents are often affected psychologically by the unacceptable appearance of diseased, damaged, or missing teeth, one should not allow chronologic age to preclude performance of whatever treatment is necessary to provide proper function and aesthetics.<sup>6</sup> If the teeth involved are fully erupted, have achieved complete root formation, and may be prepared without causing irreversible damage to the pulp, successful prosthodontic treatment can often

be provided for patients as young as 12–14 years of age. Patient cooperation, however, is mandatory during and after treatment. Adolescent patients must be able to tolerate long appointments and remain still for extended periods while teeth are being prepared and impression materials are setting. Also, they must be able to achieve and maintain good oral hygiene around both the provisional and definitive restorations, as well as in the rest of the mouth. All these conditions make it highly desirable for the necessary treatment to be performed as expeditiously as possible. Finally, it must be understood that an adolescent is more likely to sustain trauma to the oral structures than an adult; thus there is a greater risk of damage to restorations and prostheses in an adolescent than in an adult patient.

Prosthodontic treatment of the adolescent patient often requires highly intricate procedures that go beyond the scope of this chapter. The goal of this chapter is to offer the reader an opportunity to develop a better appreciation of the achievable and available solutions for the young patient with a prosthodontic need. The interested reader should consult the prosthodontic literature and current textbooks on fixed, removable, and implant prosthodontics for more detailed information in this area of dentistry.

## Restoration of Single Malformed, Discolored, or Fractured Teeth

When single tooth pathology due to a malformed tooth and defects due to tooth discoloration and fracture occurs in an adolescent patient, the first line of treatment is to focus on developing a conservative option while a more comprehensive approach is assessed. Direct and indirect restorations can be this option for the patient with contemporary tooth-colored composite resin or ceramic materials due to their excellent shade-matching properties and strength.

## DIRECT RESTORATION OF DISCOLORED TEETH

Direct restorations can be an effective conservative option to veneer discolored teeth with small defects from fractures especially due to the conservative site preparation required. The pulp chamber is prone to exposure in the adolescent patient and a conservative approach with minimal tooth preparation is the first consideration.

**Resin infiltration:** Whitish discolorations of the enamel can occur due to fluorosis, hypocalcification, and hypomineralization. Discoloration resulting from caries are referred to as white spot lesions. For anterior teeth discolorations, conservative treatment options can be used, such as topical application of remineralizing agents, airborne particle abrasion, and bleaching techniques. Reversing enamel demineralization to improve tooth appearance by a technique called resin infiltration is another conservative treatment modality.

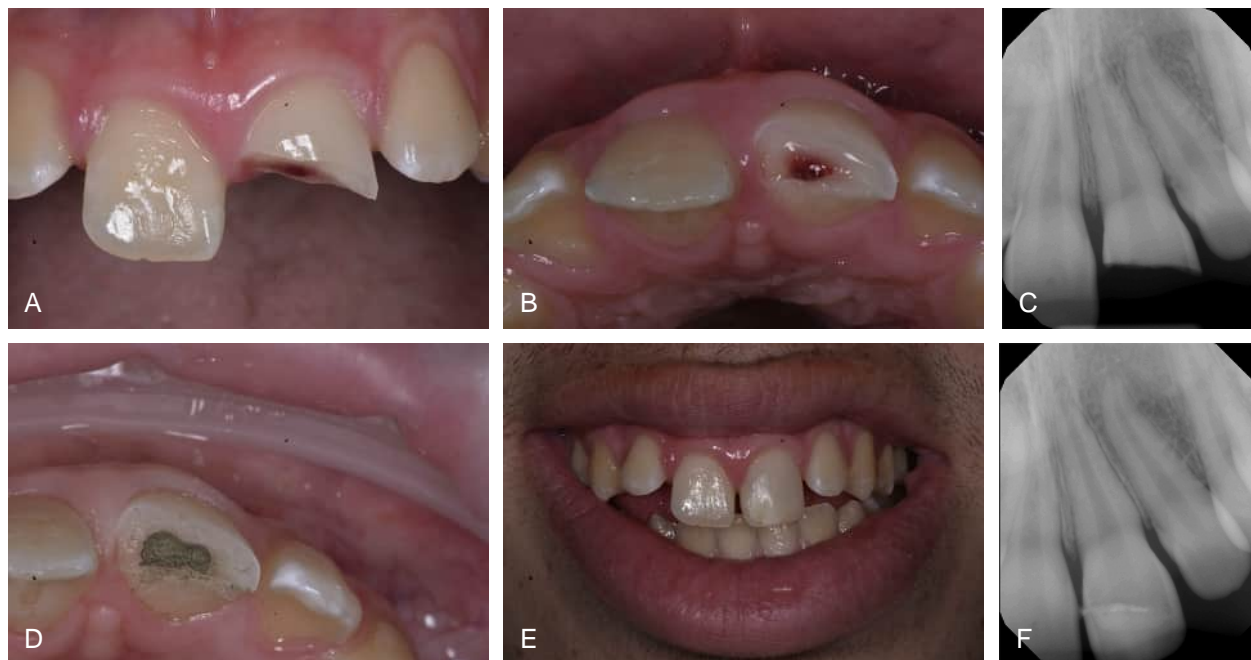Resin infiltration is based on the acid erosion of the lesion surface and posterior infiltration of low-viscosity resin into the intercrystalline spaces of demineralized enamel. This alters the refractive index (RI) of the enamel which is porous and filled with air (RI = 1.00) or water (RI = 1.33) since the infiltrated resin material shows RI (1.52) closer to that of hydroxyapatite (1.62). The optical properties or characteristics of the enamel are altered, thereby creating a “chameleon effect” on the enamel shade. However, there is a lack of evidence concerning the clinical efficacy of the technique for camouflaging enamel whitish discolorations.

The systematic review by Borges et al.<sup>7</sup> concluded that the resin infiltration technique seems to be a feasible option for color masking of enamel whitish discolorations, resulting from both white spot lesions and enamel development defects. Nevertheless, they reported that there is no strong evidence supporting the clinical recommendation of the technique.

## TEETH WITH PULPAL INVOLVEMENT

When tooth fracture or caries involves the pulp and root development is complete, a routine pulpectomy and gutta-percha root canal filling should be completed. Because posts and cores do not strengthen endodontically treated teeth, their use is indicated only when the remaining coronal tooth structure does not provide adequate retention for definitive restoration. Restorations that do not use a post should be used whenever possible to replace missing tooth structure and serve as a retentive foundation. It is particularly important that the teeth in the mouths of accident-prone adolescents or in whom athletic trauma has previously occurred be restored without a post, if possible. This practice helps avoid irreparable damage in the form of root fracture in case the restored tooth is once again subjected to trauma. Even though trauma may result in restoration dislodgement or perhaps even fracture of the tooth, the tooth will have survived at least one more traumatic experience.

In the case of pulpal involvement when the root is incompletely formed, a pulpotomy followed by placement of an appropriate restoration is indicated. Subsequently, when root formation is completed, a pulpectomy is performed, followed by placement of the definitive restoration or crown, if needed. Fig. 25.1 shows treatment rendered for a 13-year-old male patient who reported with a fractured maxillary left central incisor as a result of a basketball-related traumatic injury. Exposed pulp area was isolated and gently rinsed with saline and 0.12% chlorhexidine gluconate. It was determined not to perform partial pulpotomy for this situation. Instead, after thorough cleaning, mineral trioxide aggregate (MTA) was placed and a liner applied above to secure the MTA. The fractured segment of the tooth was bonded to the remaining tooth structure with flowable composite resin and light polymerized. Fig. 25.1F shows



**Fig. 25.1** (A) Fractured maxillary left central incisor. (B) Occlusal view of fractured maxillary incisor showing pulpal exposure. (C) Periapical radiograph. (D) Mineral trioxide aggregate placed over exposure. (E) Restored tooth. (F) Postoperative radiograph.

postplacement radiograph. The patient was placed on a periodic evaluation protocol, instructions given to parents regarding the need for orthodontic treatment to reduce teeth proclination, future possibility for root canal therapy, foundation build-up, and an all-ceramic crown.

### ALL-CERAMIC AND METAL-CERAMIC CROWNS

Crowns are indicated only when more conservative treatments cannot be performed or have proven to be unsuccessful. All-ceramic crowns are the most aesthetic full-coverage crown restorations currently available in dentistry. The achievement of optimal longevity with all-ceramic crowns requires normal tooth preparation form because the prepared tooth must provide support for the restoration. Therefore, if a large portion of tooth structure is missing because of trauma or caries, or if previous restorations become dislodged during tooth reduction, then a separate restoration that is well retained in remaining tooth structure should be placed to establish an ideal preparation form (Fig. 25.2). Also, the fracture resistance of all-ceramic crowns is enhanced when other characteristics are present. Occlusal forces should be average or below average. The centric occlusal contacts should ideally be located over the concave lingual portion of the prepared tooth and not cervical to the cingulum, where fracture of the crown is more likely to occur. The prepared tooth should possess average or greater incisocervical length and should not be short, round, or overtapered.

The tooth preparation for an all-ceramic crown (Fig. 25.3) should possess a well-defined, smooth finish line that is approximately 0.8 mm deep around the entire tooth, with the axial surfaces reduced to a depth of 0.8 mm. The lingual reduction for occlusal clearance should be 1 mm. An incisal edge reduction of 1.5–2 mm is required and is biologically acceptable even in the presence of large pulps. The use of resin cement and associated dentin bonding is recommended because crown strength is significantly improved. Both chamfer and round shoulder finish lines can be used in conjunction with resin cement without compromising restoration strength.

When the ideal tooth preparation form is seriously compromised or the magnitude of occlusal forces contraindicates restoration with an all-ceramic crown, use of the stronger zirconia or metal-ceramic crown is indicated. The tooth preparation design and reduction depths for a metal-ceramic crown are shown in Fig. 25.4. When cervical aesthetics must be optimized in a metal-ceramic restoration, one can use a collarless design that eliminates facial cervical metal and uses a porcelain facial margin (Figs. 25.5 and 25.6).

Whenever possible, cervical margins should not be extended into the gingival sulcus of an adolescent patient. If oral hygiene is inadequate, subgingival margins may produce accelerated gingival recession or interfere with the normal cervical relocation of the gingival tissues as the patient matures. Both the occurrences produce an aesthetic liability (Figs. 25.7 and 25.8). The aesthetic comparison between all-ceramic and metal-ceramic crowns is clearly visible (Fig. 25.9A and B).

### CONSERVATIVE INDIRECT RESTORATIONS

Conservative teeth preparations for indirect restorations are intended to retain tooth structure without sacrificing

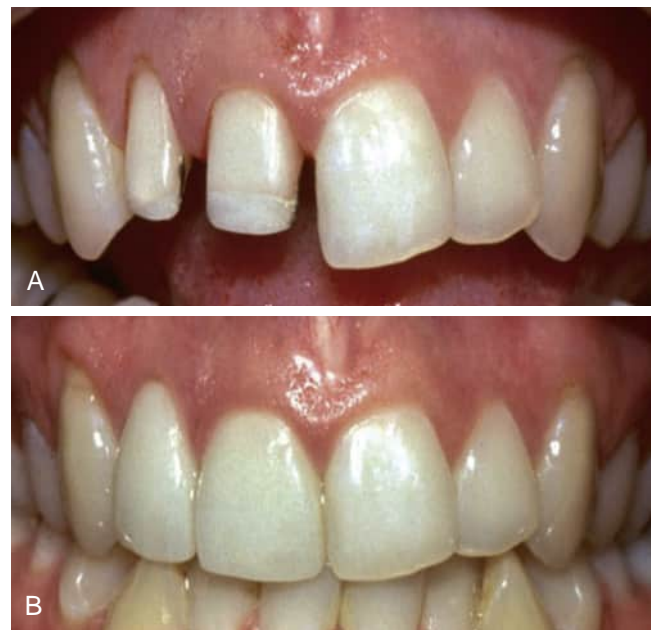

Fig. 25.2 (A) Traumatically injured central and lateral incisors that have been restored with bonded resins and then prepared to receive all-ceramic crowns. (B) All-ceramic crowns have been cemented.

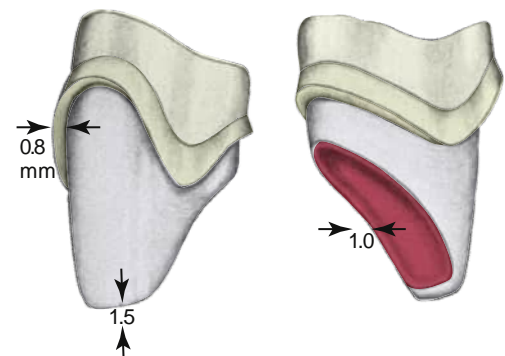


Fig. 25.3 Two views of all-ceramic (porcelain jacket crown) preparation showing recommended reduction depths and shoulder finish line.

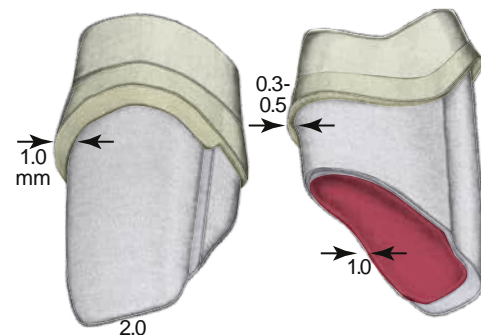
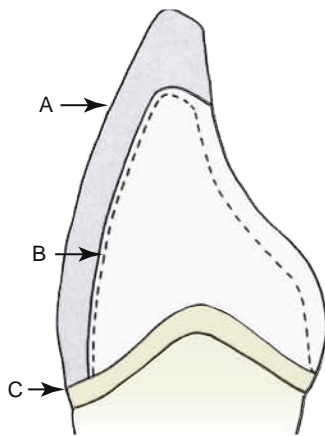


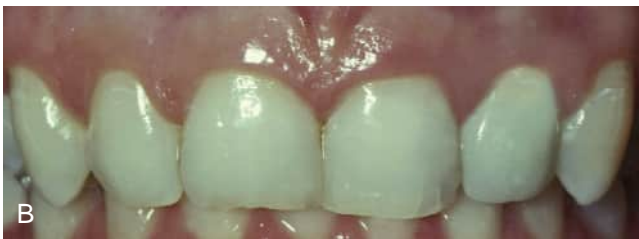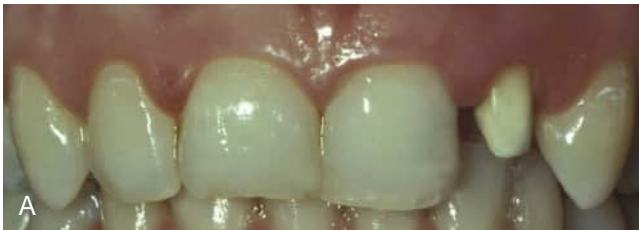Fig. 25.4 Two views of metal-ceramic crown preparation showing minimal facial reduction and shoulder finish line, minimal incisal reduction, lingual axial reduction depth and chamfer finish line, and lingual reduction for occlusal clearance.

resistance and retention form while eliminating any pathology. These indirect restorations are minimally extended and mostly prepared to retain enamel surfaces as much

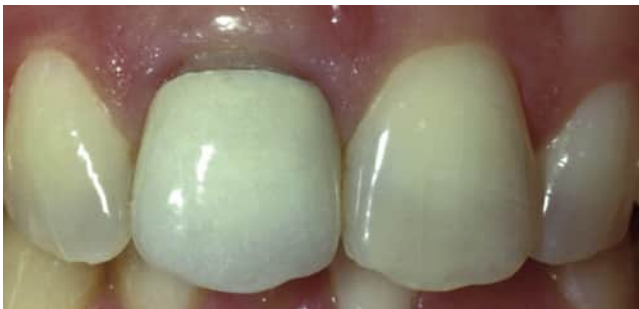



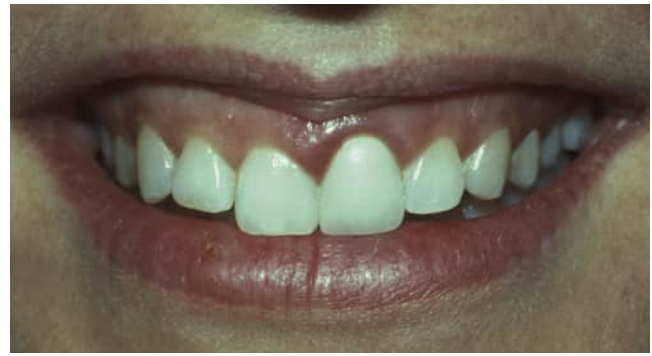**Fig. 25.5** Collarless metal-ceramic framework design that eliminates visible cervical metal. *A* indicates porcelain; *B* indicates the underlying metal framework that does not cover the shoulder finish line; and *C* is the margin where porcelain comes into contact only with the prepared tooth.



**Fig. 25.6** (A) The maxillary lateral incisor was traumatically injured, resulting in loss of the incisal one-third and much of the lingual surface. The tooth has been prepared for a metal-ceramic crown with a porcelain margin (collarless metal-ceramic crown). (B) The lateral incisor crown has been cemented.



**Fig. 25.7** Gingival contour in a 25-year-old patient resulting from placement of subgingival crown on maxillary right central incisor at 8 years of age. The gingival crest is not positioned as far apically on the restored central incisor, and its form is rounded and thick rather than the normal form of the gingival margin, which is thinner and sharper.



**Fig. 25.8** Accelerated gingival recession around maxillary left central incisor resulting from metal-ceramic crown with subgingival margins placed at a young age. The gingiva is edematous and red, and the gingival margin is rounded and thick.

as possible for maintaining tooth integrity and to achieve maximum bond strength with the ceramic restoration.

**Inlay:** a fixed intracoronal restoration made outside of a tooth to correspond to the form of the prepared cavity, which is then luted into the tooth.<sup>8</sup>

**Onlay:** is a partial-coverage restoration that restores one or more cusps and adjoining occlusal surfaces or the entire occlusal surface and is retained by mechanical or adhesive means (Fig. 25.10A and B).<sup>8</sup>

**Porcelain laminate veneer:** It is a thin, bonded ceramic restoration that restores the facial surface (reduction depth can be as low as 0.2 mm), incisal, and part of the proximal surfaces of teeth requiring esthetic restoration (Fig. 25.11A and B).<sup>8</sup> Indications for porcelain laminate veneers include restoring minor facial and incisal fracture, stained teeth that cannot be bleached, unaesthetic tooth shape (peg lateral), canine-guided occlusion, poorly aligned teeth, and diastema.

Sailer et al.<sup>9</sup> reported that all-ceramic restorations have a comparable survival rate with metal-ceramic restorations (97%) over a 10-year period. All-ceramic single crowns exhibit similar survival rates as metal-ceramic single crowns after a mean observation period of at least 3 years.

Morimoto et al.<sup>10</sup> reported that failures were related to fractures/chipping (4%), followed by endodontic complications (3%), secondary caries (1%), debonding (1%), and severe marginal staining (0%). According to the same authors, ceramic inlays, onlays, and overlays showed high survival rates at 5 years and 10 years, and fractures were the most frequent cause of failure. This meta-analysis indicates that the survival rate of inlays, onlays, and overlays remains high, regardless of the follow-up time (5 years and 10 years), ceramic material, study design, and study setting.

## Fixed Partial Dentures

When a tooth is lost, space maintenance should be provided immediately after extraction to prevent tipping, tilting, or rotation of the abutment teeth or eruption of the opposing teeth. Space maintenance should be continued until the fixed prosthesis is completed. If the abutment teeth

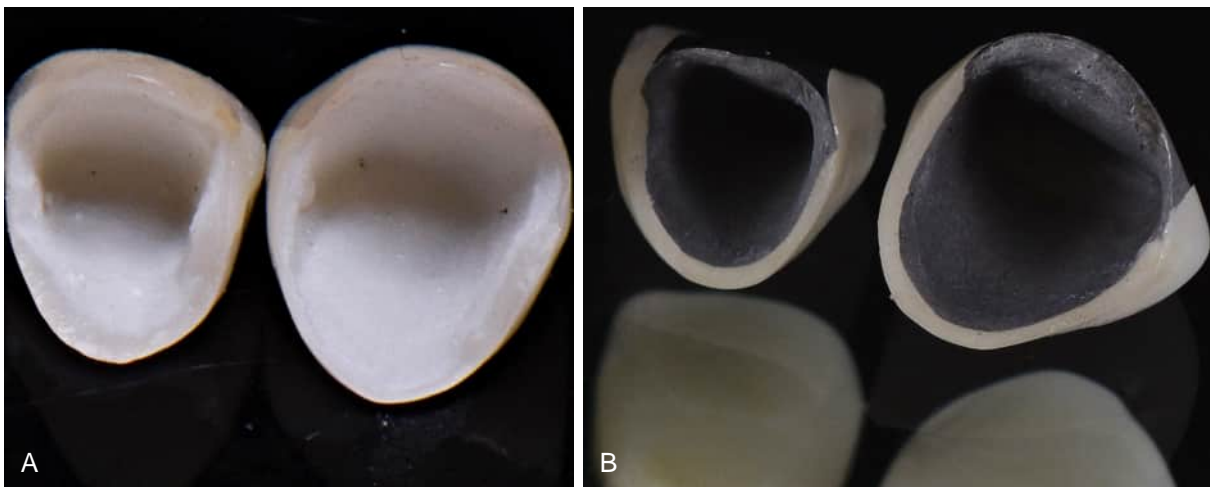


Fig. 25.9 Intaglio view of (A) all-ceramic crowns and (B) metal-ceramic crowns.

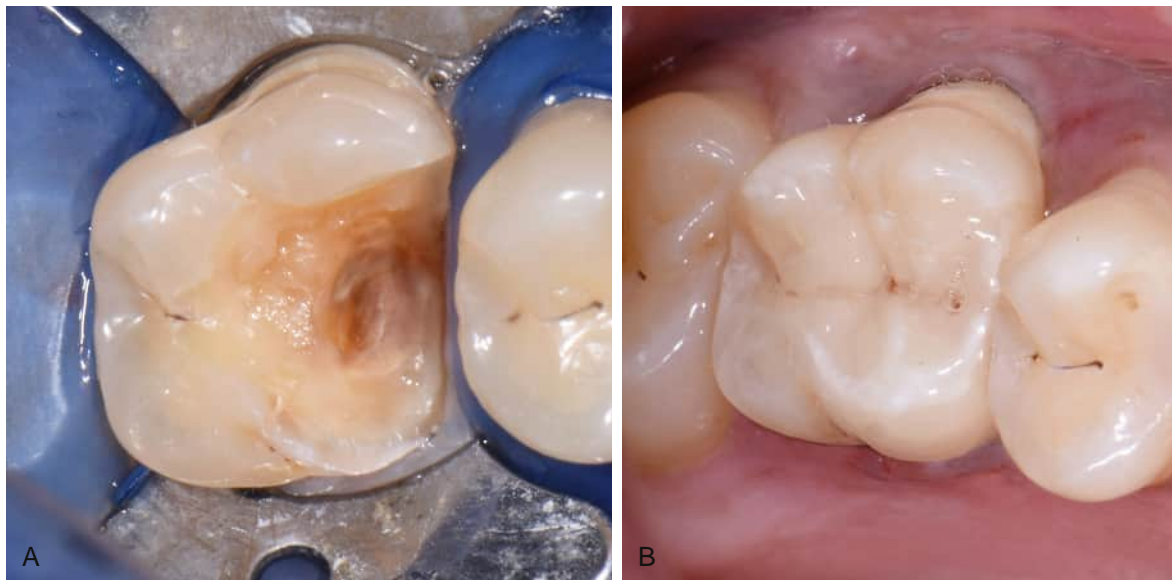


Fig. 25.10 (A) Tooth preparation for an onlay for maxillary molar. (B) View of bonded all-ceramic onlay.

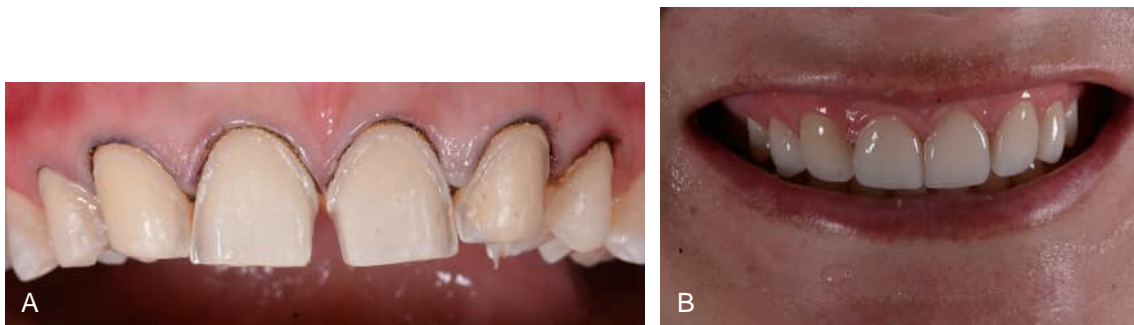


Fig. 25.11 (A) Teeth preparation for veneers for malformed anterior teeth. (B) Veneers bonded to teeth restoring proportion and aesthetics.

are malaligned and pulp size does not permit the amount of tooth reduction necessary to align the preparations, orthodontic repositioning of the abutment teeth should be initiated. Sometimes adolescents may require periodontal procedures, particularly to increase the crown length for

crown or fixed partial denture retention, or to improve tissue contours so that more ideal results can be achieved. The use of conventional fixed partial dentures requiring complete crown tooth preparations is decreasing in adult patients owing to the use of dental implants and occurs only

sparingly in adolescents. Contemporary treatment planning more frequently indicates that an interim fixed or removable prosthesis must be used until such time as growth is completed and dental implants can be placed. Application of dental implant therapy is not recommended for everyone. Minimum age for dental implant placement is a controversial topic, but the authors strongly believe that it is prudent to wait till the patient has completed growth and is at least 21 years old before implant therapy is initiated. In short, the placement of dental implants should not be attempted until the accelerated phase of peripubertal growth is complete.

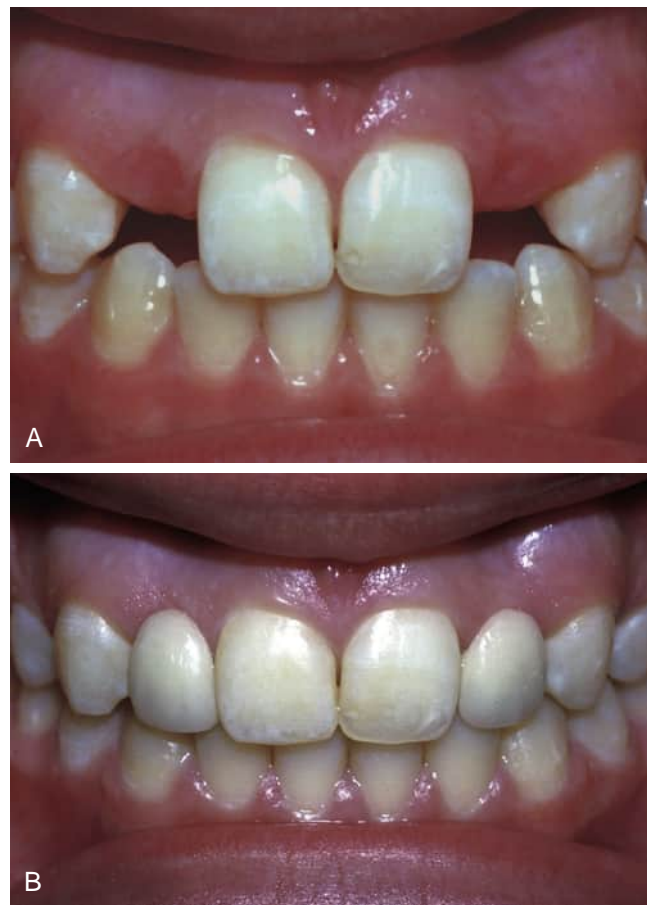Furthermore, patients should be informed about the potential implant prosthodontic complications that arise from continuous jaw growth.<sup>11</sup> These include but are not limited to interproximal contact loss and intruded appearance of the implant crown.<sup>12</sup> When an interim fixed prosthesis is needed, resin-bonded fixed partial dentures are a good choice. When implants will not be used or have not been successful, fixed partial dentures become an appropriate definitive treatment. These fixed partial dentures can use conventional complete crown retainers, or they can use resin-bonded retainers designed for long-term service.

### RESIN-BONDED RETAINERS

For reasons of pulpal and periodontal health and conservation of tooth structure, resin-bonded retainers are frequently used to replace congenitally missing teeth since dental implants are not applicable in a young patient (Fig. 25.12). Retention and resistance form is achieved through tooth preparations, terminating in enamel, coupled with acid etching of the enamel and fixation with resin cement. The conservative approach of using resin-bonded retainers, however, does require that the abutment teeth be intact or minimally restored, with substantial enamel present for bonding procedures. To produce an adequate area for resin bonding, the existing crown should be of average or greater length. A maximal amount of the invisible portions of the lingual and proximal surfaces should be covered by the retainers to increase the bonding surface area. The existing crown form, color, and axial alignment must be satisfactory because this prosthesis design does not permit the incorporation of changes in the facial enamel of abutment teeth. When abutment crown contours or color requires aesthetic changes, then complete crown retainers may produce a superior result.

These prostheses can be successful for many years, but suitable attention must be paid to four factors: (1) appropriate diagnosis and treatment planning, (2) correct tooth preparation, (3) good-fitting castings, and (4) meticulous adherence to the required resin-bonding procedures.

Several factors important to diagnosis and treatment planning have been identified. Prostheses with only one pontic have much higher success rates, so the use of long-span prostheses should be avoided. Multiple splinted retainers are associated with higher failure rates. The use of resin-bonded cantilevered prostheses (with only one retainer) has been reported, and analysis of data from Hussey et al.<sup>13</sup> and Leempoel et al.<sup>14</sup> indicates that this type of design can be successfully used in certain situations such as a missing maxillary lateral incisor (Fig. 25.13).

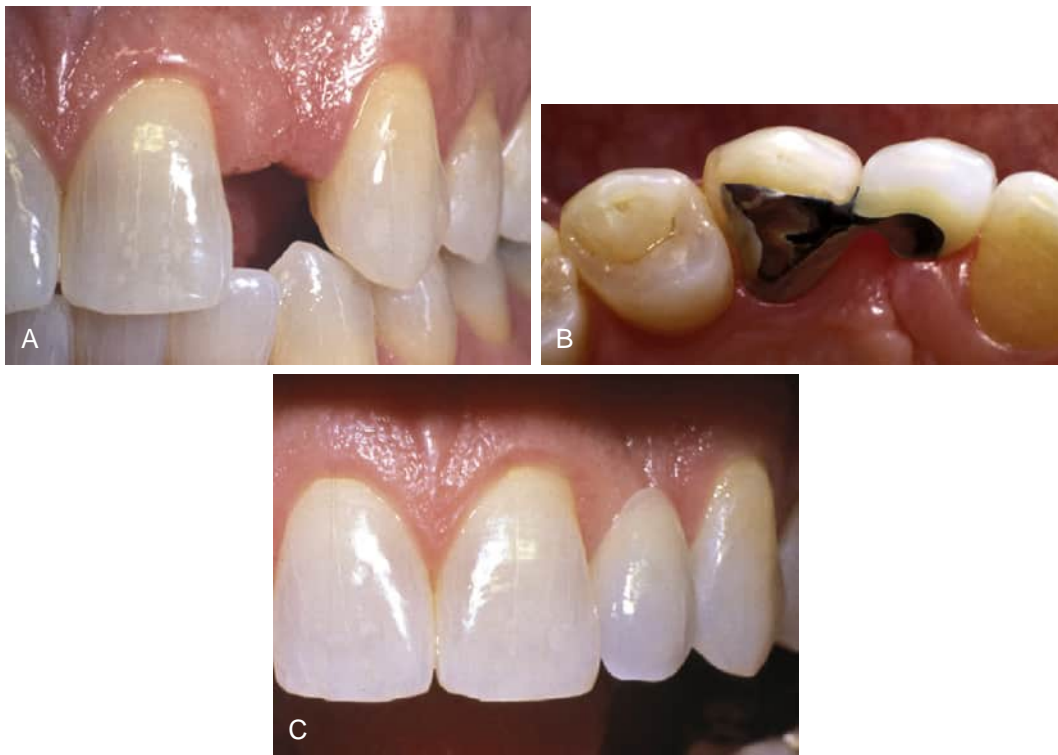

**Fig. 25.12** (A) Congenitally missing maxillary lateral incisors. (B) Resin-bonded prostheses were used instead of conventionally cemented prostheses to preserve as much tooth structure as possible on the central incisor and canine abutments.

Preparation of abutment teeth for resin-bonded prostheses is not recommended for prostheses that will be used only on an interim basis. However, when long-term service is needed, tooth preparation has been found to substantially reduce debonding of retainers.

Barrack and Bretz<sup>15</sup> determined that the successful use of resin-bonded prostheses requires establishment of retention and resistance form through tooth preparation (Fig. 25.14). Because the tooth preparation is limited principally to enamel, these retainers can be used without pulpal damage and the teeth can often be prepared without anesthesia. The proximal surfaces adjacent to the edentulous area should be reduced to remove interproximal undercuts and to provide parallel surfaces that aid retention. One or two proximal grooves must be placed to enhance the resistance and retention form (Fig. 25.14A). Proximal grooves have been identified as a key factor in the resistance to debonding.<sup>16</sup> The tooth preparation should include a small peripheral chamfer finish line (Fig. 25.14B) formed with the tip of a rounded-end diamond instrument. The lingual surfaces of anterior teeth are reduced to create occlusal clearance with the opposing teeth. The minimal occlusal clearance space for short-span (three-unit) prostheses with normal occlusal forces is 0.5 mm. It may not be necessary to reduce the abutment teeth lingually when there is existing occlusal clearance, whereas





**Fig. 25.13** (A) Congenitally missing maxillary lateral incisor. (B) Incisal view of the bonded two-unit prosthesis where the lateral incisor pontic has been cantilevered from the maxillary canine. (C) Facial view of the completed prosthesis.

reduction of opposing teeth may be necessary when occlusal contact occurs over broad areas of the lingual surfaces. Multiple ledges prepared across the reduced lingual surface (Fig. 25.14C) increase the casting rigidity and, along with the proximal grooves, aid in retention and resistance form and in orientation of the casting during cementation.

The preparation of posterior abutment teeth should include reduction of the proximal surfaces to eliminate undercuts and to produce minimal occlusal convergence for retention and resistance form. The reduction should also include lingual surfaces and at least 180 degrees of circumferential reduction, as determined by Creugers et al.<sup>17</sup> One or two proximal grooves are placed, one or two occlusal rest seats are prepared,<sup>15</sup> and a small chamfer finish line is formed. The use of an inlay-like occlusal rest has been advocated to increase resistance and retention form. The occlusal aspect of the lingual cusp can also be slightly reduced and covered with metal to increase the bonding area and prosthesis retention (Fig. 25.15).

A metal-ceramic alloy is used for the prosthesis framework, which allows porcelain to be bonded over the visible facial surfaces of pontics to meet aesthetic requirements. Several design variations are used for the retainer castings, differing in the manner in which the resin mechanically interlocks with the surface of the casting that comes into contact with the prepared teeth.

The first prosthesis design featured retainer castings that were perforated lingually, which allowed resin to encompass the casting. Subsequently, a technique was introduced that used a base metal alloy and thereby took advantage of the ability of the alloy to be acid-etched to provide microscopic areas of retention (Fig. 25.16). This technique is not

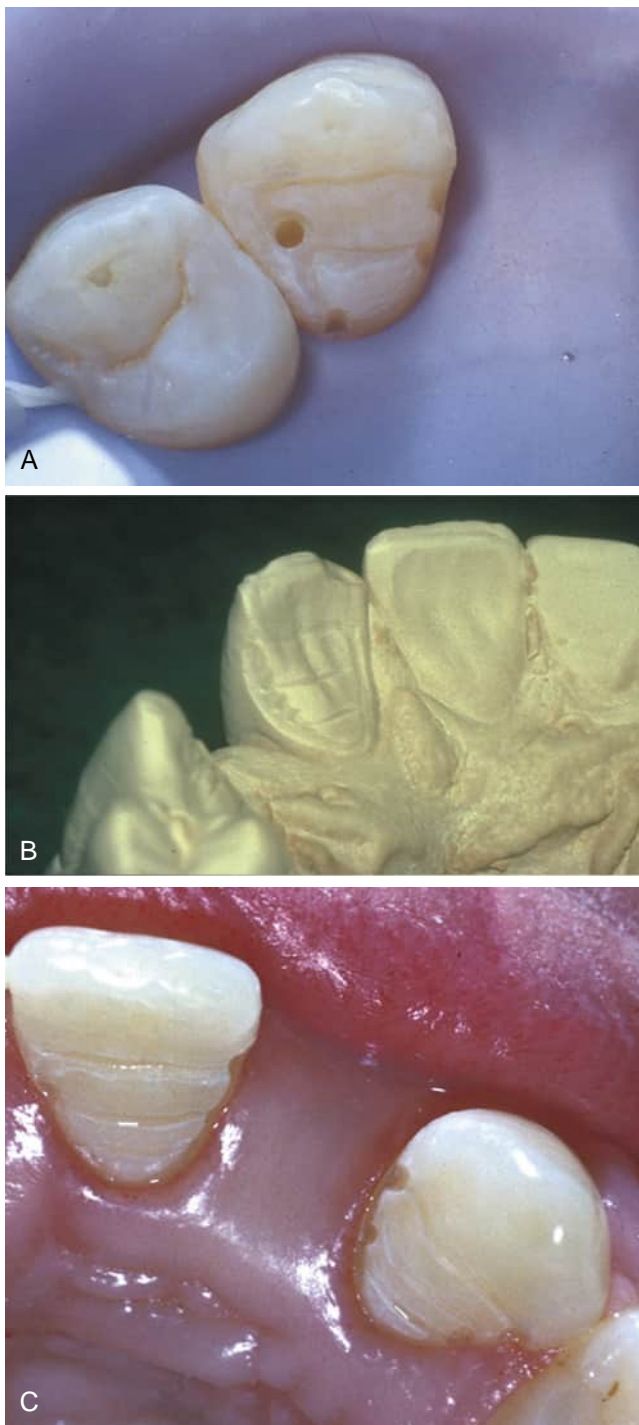
suitable for use with gold-containing alloys because they cannot be etched in this manner.

An alternative method of treating the metal surface to provide retention for the resin is to subject the bonding surface to airborne-particle abrasion with 50- $\mu$ m aluminum oxide. This method provides retention comparable with that of chemically etched metal and can be used with any casting alloy.<sup>18</sup>

The completed prosthesis is first trial-seated so that any required adjustments of form, color, occlusion, and glaze can be completed. The prosthesis should then be cleaned ultrasonically to remove debris that may be present in the retentive areas and dried thoroughly with clean, dry, compressed air.

Cementation of the prosthesis with the acid-etching and resin procedure requires optimal moisture control, which is best obtained with use of a rubber dam. Composite resins specially designed for cementation of this type of prosthesis are used. After isolation of the prepared teeth (Fig. 25.17A), the enamel is acid-etched in the usual manner, rinsed, and dried. The resin is applied to the casting and the prosthesis seated (Fig. 25.17B). Excess cement is quickly removed, and the prosthesis is held motionless until polymerization is complete. Resin cement left in interproximal undercut areas until hard can be very difficult to remove.

Opaque resins can be used to help mask the metal when abutment teeth are very translucent. This procedure helps reduce the darkening effect of lingual metal showing through the incisal aspect of a tooth. Also, when adequate bonding area is present lingually, it may be possible to reduce the area of retainer coverage by cutting away lingual metal before cementation so that none is located behind thin translucent areas of the tooth.



**Fig. 25.14** (A) The maxillary canine has been isolated for prosthesis cementation with the use of a rubber dam, which affords a good view of the well-defined proximal grooves. (B) Cast of prepared maxillary central incisor and canine. Note the small peripheral chamfer, the lingual ledges, and the small proximal grooves. (C) Another patient in whom the maxillary central incisors and canine have been prepared with multiple lingual ledges and multiple proximal grooves.

Fiber-reinforced composite-resin fixed partial dentures have also proved to be a predictable aesthetic treatment alternative to metal-ceramic resin-bonded retainers and are worthy of consideration as interim long-term restorations when aesthetics is a priority.<sup>19</sup>

## COMPLETE CROWN RETAINERS

When a resin-bonded retainer cannot be used because of the tooth condition, crown form, crown length, axial alignment, occlusal forces, or conditions requiring maximal retention and resistance form, use of complete crown retainers is indicated.

Cast metal retainers should be used posteriorly wherever aesthetically possible because they require less tooth reduction than a metal-ceramic retainer. When short clinical crowns are encountered, it may be necessary to use auxiliary grooves or boxes in the axial surfaces to achieve the required degree of retention and resistance form. It may also be necessary to perform a gingivoplasty so that more tooth structure is exposed.

When aesthetic requirements demand and pulp size permits, metal-ceramic restorations are indicated. When complete crown retainers are indicated but pulp size allows only minimal reduction, an all-resin fixed prosthesis may be the best choice. The all-resin restoration offers good aesthetics initially and requires only minimal axial tooth reduction (0.5 mm), but because it has less wear resistance, strength, and color stability than porcelain, it must be replaced periodically. All-resin prostheses rarely last more than a few years without significant wear, color change, or fracture. If the casts and records are retained, however, additional replacement prostheses can be made, and several additional years of service obtained. Subsequent treatment may permit the use of metal-ceramic retainers because enough pulpal recession may have occurred facilitating safe additional tooth reduction. The development of new resins and fiber reinforcement may extend the longevity of such prostheses.

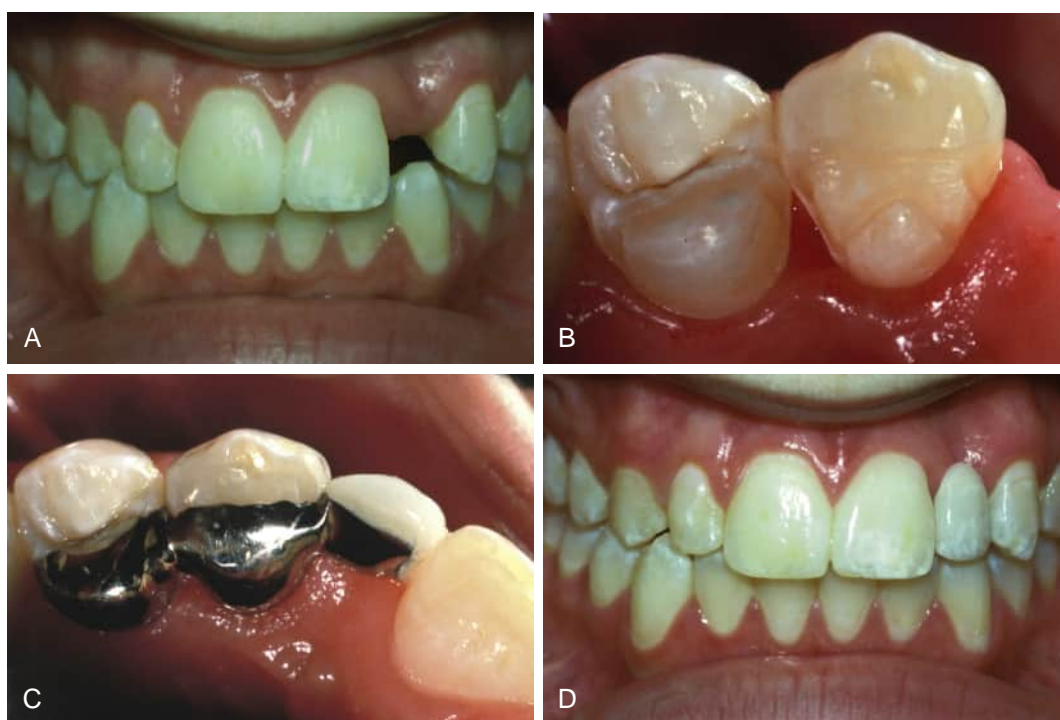
Complete crown retainers can also be used in conjunction with cantilevered prostheses so that tooth preparation is limited to one tooth. Schwartz et al.<sup>20</sup> and Foster<sup>21</sup> have demonstrated the use of the cantilever design to be a viable treatment alternative. The absence of a maxillary lateral incisor, which is encountered in adolescents because of congenital abnormality, is a situation well suited to this design. A two-unit fixed prosthesis can be fabricated with a lateral incisor pontic cantilevered from the canine retainer. The positional stability of the canine is important to the success of this design. The canine should not be mobile, and the arch form should be stable (i.e., teeth have not shifted and are not shifting position). The canine should not have recently undergone orthodontic repositioning that involved significant rotation. A final note: while these are for the primary dentition, the availability of commercially available pre-veneered aesthetic stainless-steel crowns has added an additional potential restorative option when aesthetics is a concern and full coverage is necessary.<sup>22,23</sup>

## FIXED PARTIAL DENTURE PONTICS

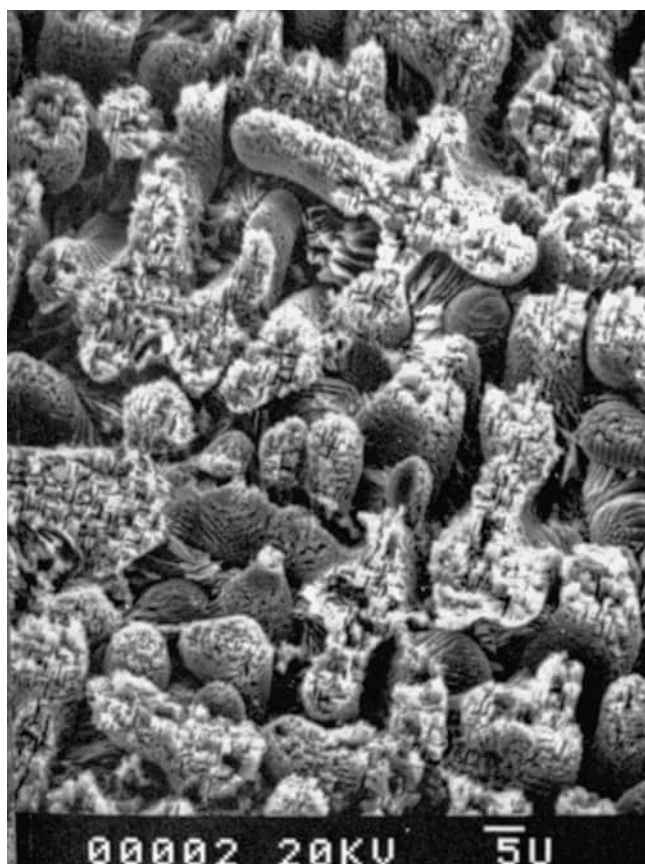
Pontics are usually of an all-metal or metal-ceramic design depending on the aesthetic requirements. The metal-ceramic pontic is a highly versatile replacement, combining the aesthetic benefits of porcelain with the strength of metal, and is widely adaptable to edentulous spaces of various sizes.

Pontic design must include meticulous attention to the amount of ridge coverage; the area of contact must be minimized, and the embrasures must be as large as possible while meeting aesthetic demands. These procedures are mandatory to provide soft tissue access for oral hygiene aids.

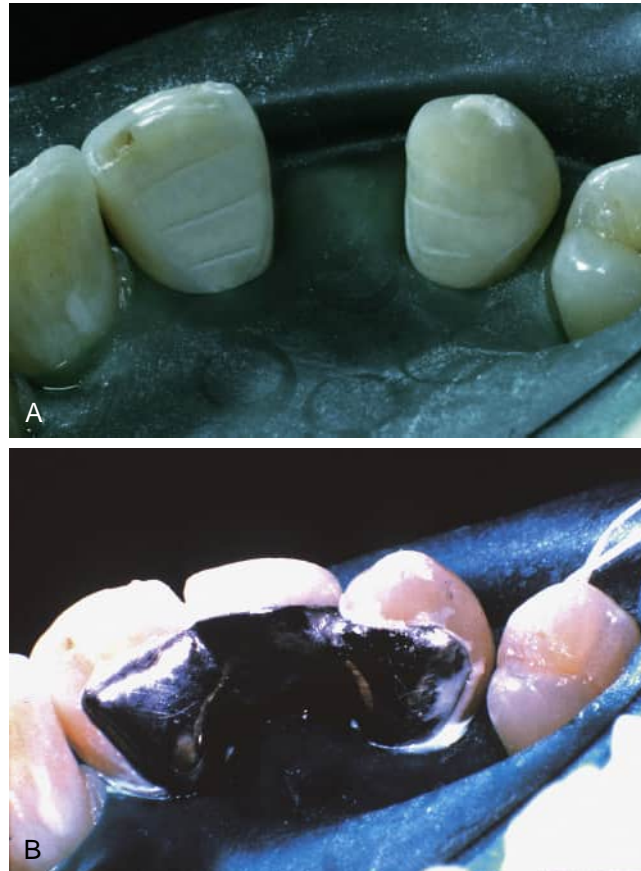




**Fig. 25.15** (A) Congenitally missing maxillary lateral incisor. (B) Mirror view of the canine and first premolar, which have been prepared for a resin-bonded prosthesis. The lingual cusp of the premolar has been reduced so the retainer can be bonded over the cusp. (C) Mirror view of bonded prosthesis showing coverage of the premolar lingual cusp. (D) Facial view of completed prosthesis.



**Fig. 25.16** Scanning electron micrograph of etched base metal (x1000). (Courtesy of B. K. Moore.)



**Fig. 25.17** (A) Teeth isolated with rubber dam in preparation for resin-bonding procedures. (B) Prosthesis bonded with resin.



## Removable Partial Dentures

When the number of missing teeth prevents the use of a fixed partial denture, a removable partial denture (RPD) becomes a restoration of necessity. Indications for RPD include excessive span length, the inability to achieve adequate retention for a fixed prosthesis, congenital malformations that result in only a few widely spaced permanent teeth, and injuries that have caused multiple teeth and often alveolar bone to be lost (Fig. 25.18).

When treatment is planned for an adolescent patient who needs RPD, there are three major objectives: (1) the restoration of the functions of mastication and speech, (2) the restoration of dental and facial aesthetics, and (3) the preservation of the remaining teeth and their supportive tissues.

The function of mastication can be restored when correct, harmonious, and nondestructive occlusal relationships are provided between the supplied teeth and the opposing remaining natural dentition. The development of proper speech can be ensured if the parts of the partial denture are given correct form, dimension, and position in their relationships to the tongue, cheek, and lips.

The restoration of aesthetics is often the most important personal consideration for adolescent patients. Artificial teeth of compatible color, size, and form, naturally arranged and positioned, enhance dental aesthetics. In addition, the form and size of the base of a partial denture must be correct to ensure the restoration of normal facial contours.

The preservation of the remaining teeth and their supportive tissues is the most important objective of all but cannot be achieved without adequate mouth preparation, correct partial denture design, accurate fabrication of that design, periodic professional follow-up care, and continued proper home care by the patient.

Additional dental procedures may be required to create an oral environment that will furnish proper support and retention for the RPD and will prevent the development of forces or processes harmful to the remaining teeth and their supportive tissues. These preparatory procedures may involve all phases or branches of dentistry.

Moreover, RPDs can also be used in maxillofacial deformities caused by trauma, cancers, or congenital defects. This clinical report described the fabrication of a definitive RPD obturator using computer-aided design (CAD) and selective laser sintering (SLS) technology for a 17-year-old patient who had undergone hemimaxillectomy.<sup>24</sup> The young patient had received treatment for leukemia which resulted in a significant infection of the right side of the maxillary arch. The treatment rendered resulted in hemimaxillectomy. A maxillary removable obturator was using a digitally designed and 3D-printed cobalt-chromium framework and conventionally processed with heat polymerizing acrylic resin. (Fig. 25.19).<sup>24</sup>

The CAD and computer-aided manufacturing (CAD-CAM) technology has been implemented in the fabrication of dental prostheses for many years. The technology has also advanced to removable prosthodontics and has been used in the fabrication of RPD frameworks. Current digital technologies enable the design of RPD components on 3D representations of the patient instead of on gypsum casts by using geometric analysis tools that create designs of micrometer-level accuracy that can be viewed in cross section. The virtual model

can then be used to design and print the framework design in resin followed by casting metal frameworks or to print the metal or resin frameworks directly.

The application of CAD and SLS technology in direct printing of the RPD metal framework potentially reduces further errors compared with the conventional method of fabrication.<sup>25</sup> Clinically acceptable fit has been reported for RPD frameworks fabricated with rapid prototyping.<sup>26</sup> Studies have also reported improved mechanical properties, higher patient satisfaction in terms of denture cleaning, speaking, mastication, and comfort, reduced laboratory time, and availability of saved data for future prosthesis reproduction as some of the other advantages of the SLS technique.<sup>8,27</sup>

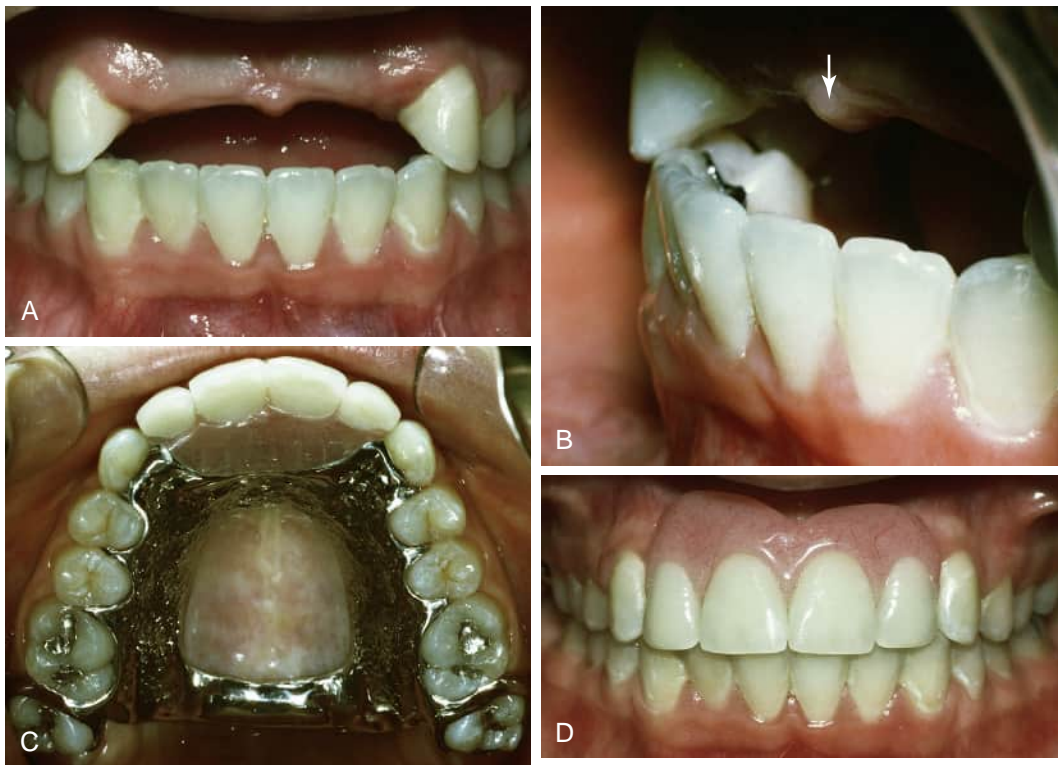## Overdentures

Occasionally, congenital abnormalities or trauma results in the loss of multiple teeth, and the resulting interarch relationship does not allow a conventional RPD to reestablish proper occlusion with opposing teeth. This situation may necessitate fabrication of a prosthesis that overlays all or part of the remaining teeth so that proper function and facial aesthetics can be established (Fig. 25.20).<sup>28</sup>

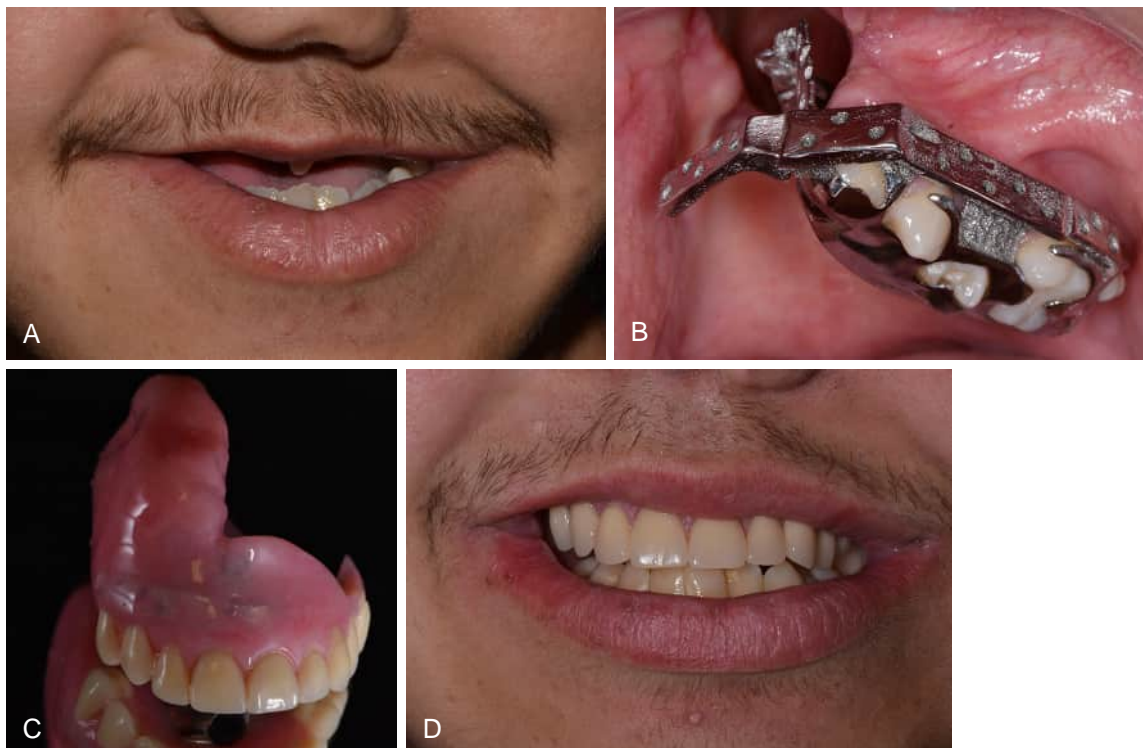
## Implant Prostheses

An understanding of dental development and craniofacial growth is certainly a prerequisite for anyone anticipating the use of dental implants in growing patients. Growth and development in the maxilla and mandible are quite different, as are growth and development in the specific areas of each arch.<sup>29–31</sup> In the maxilla, growth is intimately associated with the growth of the cranial base in early childhood, whereas later growth occurs primarily by enlargement of the maxilla. This growth is extremely variable and can be observed as vertical growth, transverse growth, and anteroposterior growth. Transverse growth occurs primarily at the midpalatal suture of the maxilla. The sutural growth site is extremely important and poses a risk to the placement of an implant-supported prosthesis that crosses this suture and could limit its growth potential. The maxilla also grows vertically by passive displacement as well as by alveolar appositional growth. It is the vertical component of maxillary growth that causes the most concern in the long-term positional stability of the individual implant and its effect on restorative function and aesthetics.

Mandibular growth differs greatly from the complex growth in the maxilla. Not closely associated with major cranial passive growth, mandibular growth is primarily downward and forward, mediated by appositional condylar growth. This growth is not purely linear but can be rotational secondary to the precise direction of condylar growth patterns. The appositional growth is also refined by certain areas of resorption, primarily seen on the anterior aspect of the ramus. As the mandible increases in length, it also increases in width, secondary to the flaring of posterior growth direction. This allows the mandible to accommodate to the increased maxillary width caused by the growth in the palatal suture area. Anterior stabilization is

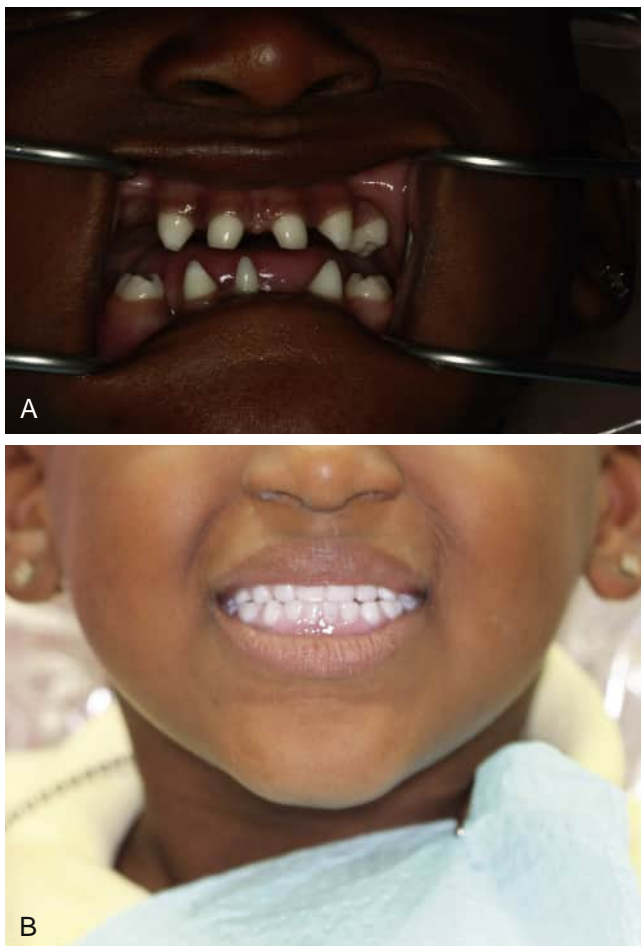


**Fig. 25.18** (A) The four maxillary incisors have been lost as a result of traumatic injury. Note the long span, short clinical crowns, and facial flare to the canines, which make retention and resistance form difficult to achieve for a conventional fixed partial denture. (B) Lateral view showing the relationship of the mandibular incisors to the residual alveolar ridge. The trauma caused substantial bone loss, and the ridge is located lingual to the mandibular incisors (arrow indicates the position of the incisive papilla on the crest of the residual alveolar ridge), which necessitates the use of a removable partial denture base for lip support and proper aesthetics. (C) Occlusal view of maxillary removable partial denture. (D) Facial view of completed prosthesis.



**Fig. 25.19** (A) Frontal extraoral smile view of patient. (B) Intraoral view of the defect and printed framework for obturator. (C) View of the maxillary obturator. (D) Smile view of patient with the maxillary obturator.





**Fig. 25.20** (A) Facial view of maxillary and mandibular teeth showing significant malformation and spacing in a patient with ectodermal dysplasia. (B) Facial view of maxillary and mandibular overdentures showing improved aesthetics. (Photos courtesy of Dr. Adriana Diaz Backer.)

accomplished by the early closure of the mandibular symphysis. Although less dynamic than maxillary growth, mandibular growth can create many complexities that could place dental implants at positional risk, especially in the posterior mandible, secondary to vertical changes and resorptive processes.

In addition to understanding growth and development, the clinician must also comprehend the dynamics of the positional relationship between the dental implant and its biological environment in the growing patient. A wealth of dental literature from *in vivo* evidence-based studies attests to the long-term success of dental implants and their associated prostheses in adults. Such a wealth of knowledge does not exist, however, for the growing patient. The behavior of an osseointegrated dental implant essentially resembles that of an ankylosed tooth, and the latter therefore provides an accurate model of the behavior of an implant in a growing patient. Two facets of the relationship of ankylosed teeth to their actively growing environment must be understood. First, the ankylosed tooth, lacking the adaptive mechanisms of a healthy tooth, does not erupt normally and becomes buried. Second, failing to participate in vertical growth, it often creates severe malocclusions secondary to tipping and associated growth changes in normal teeth adjacent to the affected ankylosed tooth. It seems logical that an

osseointegrated implant placed prematurely could elicit the same negative growth effects.

Replacement of congenitally missing teeth with implants can often be accomplished in an aesthetic manner that preserves the integrity of adjacent teeth. However, dental and skeletal growth is a major confounding variable related to the use of dental implants in adolescent patients.<sup>32</sup>

## Recare Program

The prosthodontic treatment of an adolescent does not end with the placement of the prosthesis. Periodic recare appointments for inspection, maintenance, repair, or replacement are a necessity. For patients who have RPDs, relining or rebasing should be performed when indicated. When all-ceramic crowns or metal-ceramic restorations are used in an adolescent patient, replacement may be needed periodically as the gingival tissue assumes its adult position. Patients with fixed partial dentures should be examined periodically for soft tissue health, evidence of occlusal wear, and responses of the supportive tissues to the added stress loads.

Every adolescent patient must be taught proper oral hygiene and home care for his or her prosthodontic restorations and must be motivated until adequate performance is routinely achieved. Each patient with fixed or implant-supported prostheses should be taught the use of aids such as the floss threader and interproximal brush to enhance oral hygiene efforts. Only with regular recare programs can maximum longevity of service be realized.

## Protective Mouthguards


Although this chapter is concerned with the prosthodontic treatment of adolescents, emphasis should always be laid on the prevention of oral disease and injury. The number and severity of injuries to the teeth and jaws can be significantly reduced through the faithful use of protective mouthguards by athletes who are engaged in contact sports.<sup>33,34</sup>

A recent evidence-based review of the prevention of dental injuries noted, however, that there are only a few epidemiological studies on protectiveness of mouthguards and that most of them have a low level of evidence.<sup>35</sup>

Effective and relatively inexpensive prefabricated mouthguards are available at sporting goods stores. A custom-made mouthguard can be fabricated, however, by vacuum molding a sheet of thick, clear material over a stone cast of the maxillary arch. Seals and Dorough<sup>36</sup> have reviewed the advantages of custom-made mouthguards.

Studies comparing custom-made (laboratory) mouthguards with standard (manufactured) or intraorally formed mouthguards have shown that the custom-made mouthguards provide better fit and comfort, are less likely to affect the player's speech adversely, and are less likely to become loose.<sup>37</sup> Several materials have been suggested for use in mouthguards, including poly(vinyl acetate-ethylene) copolymer thermoplastic, polyurethane, and laminated thermoplastic.<sup>38</sup> Chaconas et al.<sup>39</sup> demonstrated that the laminated thermoplastic underwent significantly less dimensional change compared with other materials. McGlumphy et al.<sup>40</sup>





**Fig. 25.21** (A) Clear material (0.150 inch) used to fabricate a mouthguard. (B) Material clamped in machine and heated until it softens and droops. (C) Material vacuum-adapted to dry stone cast. (D) Guard being trimmed with scissors. (E) Appearance of borders after being trimmed with acrylic bur and polished with pumice. (F) Completed mouthguard on cast.

recently evaluated the use of 3D imaging to assess the strain and deformation of mouthguard materials.

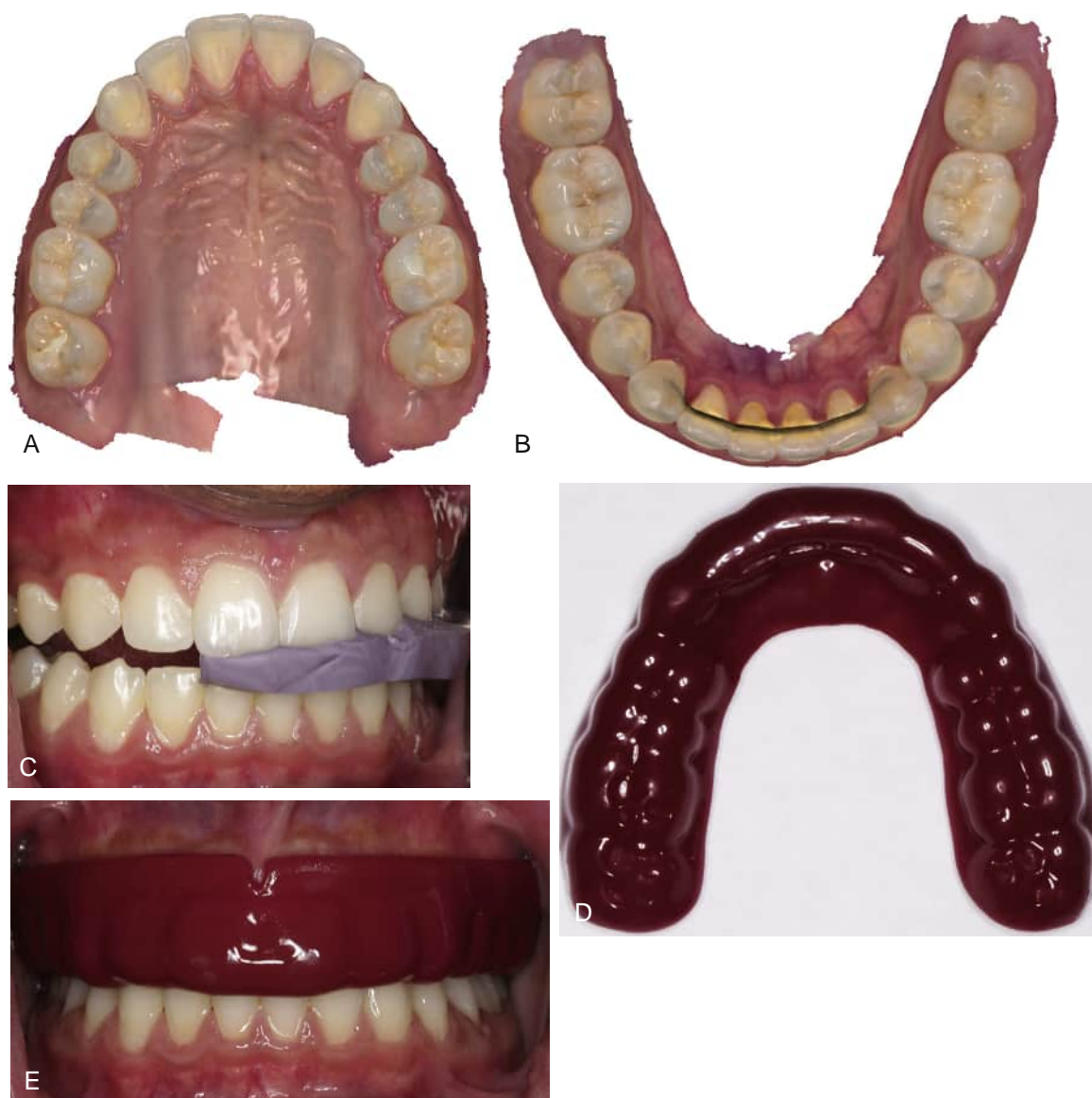Because a custom-made mouthguard accurately fits individual tooth and arch form, it affords maximal resistance to dislodgement. The technique of fabrication involves placing the mouthguard material (Fig. 25.21A) in a molding machine, which softens the material by heat (Fig. 25.21B) and closely adapts it to a dry stone cast by vacuum (Fig. 25.21C). After the adapted material has cooled, the guard is removed from the cast and the excess peripheral material is trimmed off with scissors (Fig. 25.21D). The borders are rounded when the material is trimmed with a resin trimming bur and flamed with a torch or polished with wet pumice on a rag wheel (Fig. 25.21E and F).

Maximum retention is obtained when the entire hard palate is covered. If the guard interferes with speech, however, a portion of the palatal area of the guard can be removed.

The successful use of mouthguards by many young athletes has proven that they can be worn with comfort and serve as effective safeguards against injuries to the teeth.<sup>41,42</sup>

### FABRICATION OF MOUTHGUARD USING DIGITAL WORKFLOW

A 15-year-old patient requested a custom-made mouthguard (occlusal appliance) to protect his teeth during sports-related activities. Due to an exaggerated gag reflex, an intraoral scanner was used to make definitive impressions of the maxillary and mandibular teeth (Fig. 25.22A and B) followed by an interocclusal record captured in centric relation with adequate teeth separation (Fig. 25.22C) to provide thickness for the mouthguard. Instructions along with the captured digital data were sent electronically for mouthguard fabrication. Fig. 25.22D and E shows the occlusal mouthguard appliance and the guard placed intraorally.



**Fig. 25.22** (A) Scanned image of maxillary arch. (B) Scanned image of mandibular arch. (C) Frontal view of scanned image showing separation of teeth to allow sufficient thickness for athletic guard. (D) Extraoral photograph of the 3-D printed mouthguard. (E) Frontal view of seated athletic guard.

### OCCLUSAL GUARDS FOR THERAPEUTIC EFFECT

Temporomandibular joint disorders (TMDs) are prevalent in children as they are in the adult population. TMDs are multifactorial in origin. They could be caused due to trauma, either micro- (parafunctional habits such as bruxism) or macro- (accidents, head trauma, and even after third molar extractions). They can also manifest as a result of malocclusion, psychological issues, systemic factors, and could be even hormonal in origin.

Treatment options for TMD are many and beyond the scope of this chapter. However, occlusal splints can provide stability to the temporomandibular joint. These alter the patient's occlusal scheme and can reduce the parafunctional activity.

### CAD-CAM APPLICATIONS IN PEDIATRIC DENTISTRY

The evolution of CAD-CAM technology and use of ceramics in dentistry allow industrial production following secondary

milling. The CAD-CAM prosthetic treatment has become a popular alternative to traditional techniques because of the ease and increased speed of chairside fabrication of the final restoration. Despite the fact that the CAD-CAM technology has considerably improved over time and has been shown to be approximately 16% more time efficient in ceramic prosthesis fabrication than the conventional method, ceramic adaptation, the differences in the ceramic material and restoration location (anterior versus posterior) should be considered in the treatment planning process.<sup>43,44</sup>

Intraoral scanners are closely associated with the CAD-CAM technology especially in data acquisition and have been available for over 30 years, with a rapid increase in the number of commercially available systems in the last decade. The objective of the evolving direct digital impression technique with intra oral scanners is to avoid the potentially error-prone multistep and therefore volatile process of conventional impression, gypsum cast, and extraoral indirect digitalization, by a more standardized, reliable, and predictable approach.<sup>45,46</sup> However, the accuracy of digital impression for different clinical applications is still controversial,



even though several studies show that digital and conventional impressions produce restorations of comparable accuracy and quality.<sup>47</sup> It has been reported that digital scanning for partial arches is more predictable and accurate compared with full-arch scanning, as it pertains to tooth-supported scenarios. Intraoral scanners can also be very effective for the adolescent age group (Fig. 25.22). Some of the advantages with intra oral scanners include reduced gag reflex, easier impression making when fixed orthodontic retainers and brackets are present, faster scanning time, reduced cost, higher patient acceptance, and efficient work flow for appliance or prosthesis fabrication.<sup>48</sup>

## References

- Caplan DJ, Weintraub JA: The oral health burden in the United States: a summary of recent epidemiologic studies, *J Dent Educ* 57(12):853–862, 1993.
- Vargas CM, Crall JJ, Schneider DA: Sociodemographic distribution of pediatric dental caries: NHANES III, 1988–1994, *J Am Dent Assoc* 129(9):1229–1238, 1998.
- Barnes DE, Leous PA: Assessment of periodontal status by CPTN and its applicability to the development of long-term goals on periodontal health of the population, *Int Dent J* 36(3):177–181, 1986.
- Gift HC, Bhat M: Dental visits for orofacial injury: defining the dentist's role, *J Am Dent Assoc* 124(11):92–98, 1993.
- Bader JD, Martin JA, Shugars DA: Preliminary estimates of the incidence and consequences of tooth fracture, *J Am Dent Assoc* 126(12):1650–1654, 1995.
- Oliveira BH, Salazar M, Carvalho DM, et al.: Biannual fluoride varnish application and caries incidence in preschoolers: a 24-month follow-up randomized placebo-controlled clinical trial, *Caries Res* 48(3):228–236, 2014.
- Borges AB, Caneppele TM, Masterson D, et al.: Is resin infiltration an effective esthetic treatment for enamel development defects and white spot lesions? A systematic review, *J Dent* 56:11–18, 2017.
- Ferro KJ, Morgano SM, Driscoll CF, et al.: The glossary of prosthodontic terms: ninth edition, *J Prosthet Dent* 117(55):e1–e105, 2017.
- Sailer I, Makarov NA, Thoma DS, et al.: All-ceramic or metal-ceramic tooth-supported fixed dental prostheses (FDPs)? A systematic review of the survival and complication rates. Part I: Single crowns (SCs), *Dent Mater* 31(6):603–623, 2015.
- Morimoto S, Rebello de Sampaio FB, Braga MM, et al.: Survival rate of resin and ceramic inlays, onlays, and overlays: a systematic review and meta-analysis, *J Dent Res* 95(9):985–994, 2016.
- Daftary F, Mahallati R, Bahat O, et al.: Lifelong craniofacial growth and the implications for osseointegrated implants, *Int J Oral Maxillofac Implants* 28(1):163–169, 2013.
- Varthis S, Tarnow DP, Randi A: Interproximal open contacts between implant restorations and adjacent teeth. Prevalence—causes—possible solutions, *J Prosthet Dent* 28(2):e806–e810, 2019.
- Hussey DL, Pagni C, Linden GJ: Performance of 400 adhesive bridges fitted in a restorative dentistry department, *J Dent* 19(4):221–225, 1991.
- Leempoel PJ, Käyser AF, Van Rossum GM, et al.: The survival rate of bridges: a study of 1674 bridges in 40 Dutch general practices, *J Oral Rehabil* 22(5):327–330, 1995.
- Barrack G, Bretz WA: A long-term prospective study of the etched-cast restoration, *Int J Prosthet Dent* 6(5):428–434, 1993.
- Hansson O, Bergström B: A longitudinal study of resin-bonded prostheses, *J Prosthet Dent* 76(2):132–139, 1996.
- Creugers NH, Snoek PA, Van't Hof MA, et al.: Clinical performance of resin-bonded bridges: a 5 year prospective study. Part II: the influence of patient-dependent variables, *J Oral Rehabil* 16(6):521–527, 1989.
- Atta MO, Smith BG: The bond strength of a new adhesive bridge cement to sand-blasted nickel-chromium alloy compared with composite to acid-etched alloy, *J Dent Res* 65(Spec Iss):496(abst no 74), 1986.
- Spinas E, Aresu M, Canargiu F: Prosthetic rehabilitation interventions in adolescents with fixed bridges: a 5-year observational study, *Eur J Paediatr Dent* 14(1):59–62, 2013.
- Schwartz NL, Whittsett LD, Berry TG, et al.: Unserviceable crowns and fixed partial dentures: life-span and causes for loss of serviceability, *J Am Dent Assoc* 81(6):1395–1401, 1970.
- Foster LV: Failed conventional bridge work from general dental practice: Clinical aspects and treatment needs of 142 cases, *Br Dent J* 168(5):199–201, 1990.
- Leith R, O'Connell AC: A clinical study evaluating success of 2 commercially available preveneered primary molar stainless steel crowns, *Pediatr Dent* 33(4):300–306, 2001.
- Beattie S, Taskonak B, Jones J, et al.: Fracture resistance of 3 types of primary esthetic stainless steel crowns, *J Can Dent Assoc* 77(77):b90, 2011.
- Soltanzadeh P, Suprono MS, Kattadiyil MT, et al.: An in vitro investigation of accuracy and fit of conventional and CAD/CAM removable partial denture frameworks, *J Prosthet Dent* 28(5):547–555, 2019.
- Williams RJ, Bibb R, Eggbeer D, et al.: Use of CAD/CAM technology to fabricate a removable partial denture framework, *J Prosthet Dent* 96(2):96–99, 2006.
- Williams RJ, Bibb R, Eggbeer D: CAD/CAM in the fabrication of removable partial denture frameworks: a virtual method of surveying 3D scanned dental casts, *Quintessence J Dent Technol* 2:268–276, 2004.
- Kattadiyil MT, Mursic Z, AlRumaih H, et al.: Intraoral scanning of hard and soft tissues for partial removable dental prosthesis fabrication, *J Prosthet Dent* 112(3):444–448, 2014.
- Vergo Jr TJ: Prosthodontics for pediatric patients with congenital/developmental orofacial anomalies: a long-term follow-up, *J Prosthet Dent* 86(4):342–347, 2001.
- Cronin JR, Oesterle LJ: Implant use in growing patients: treatment planning concerns, *Dent Clin North Am* 42(1):1–34, 1998.
- Cronin Jr RJ, Oesterle LJ, Ranly DM: Mandibular implants and the growing patient, *Int J Oral Maxillofac Implants* 9(1):55–62, 1994.
- Oesterle LJ, Cronin Jr RJ, Ranly DM: Maxillary implants and the growing patient, *Int J Oral Maxillofac Implants* 4(3):377–387, 1993.
- Bergendal B, Ekman A, Nilsson P: Implant failure in young children with ectodermal dysplasia: a retrospective evaluation of use and outcome of dental implant treatment in children in Sweden, *Int J Oral Maxillofac Implants* 23(3):520–524, 2008.
- Matalon V, Brin I, Moskovitz M, et al.: Compliance of children and youngsters in the use of mouthguards, *Dent Traumatol* 24(4):462–467, 2008.
- Knapik JJ, Marshall SW, Lee RB, et al.: Mouthguards in sport activities: history, physical properties and injury prevention effectiveness, *Sports Med* 37(2):117–144, 2007.
- Sigurdsson A: Evidence-based review of prevention of dental injuries, *Pediatr Dent* 35(2):184–190, 2013.
- Seals Jr RR, Dorough BC: Custom mouth protectors: a review of their applications, *J Prosthet Dent* 51(2):238–242, 1984.
- Stokes AN, Croft GC, Gee D: Comparison of laboratory and intraorally formed mouth protectors, *Endodent Traumatol* 3(5):255–258, 1987.
- Geary JL, Kinirons MJ: Post thermoforming dimensional changes of ethylene vinyl acetate used in custom-made mouthguards for trauma prevention—a pilot study, *Dent Traumatol* 24(3):350–355, 2008.
- Chaconas SJ, Caputo AA, Bakke NK: A comparison of athletic mouthguard materials, *Am J Sports Med* 13(3):193–197, 1985.
- McGlumphy KC, Mendel DA, Yilmaz B, et al.: Pilot study of 3D image correlation photogrammetry to assess strain and deformation of mouthguard materials, *Dent Traumatol* 30(3):236–239, 2014.
- Gawlak D, Mierzwińska-Nastalska E, Mańka-Malara K, et al.: Comparison of usability properties of custom-made and standard self-adapted mouthguards, *Dent Traumatol* 30(4):306–311, 2014.
- Tuna EB, Ozel E: Factors affecting sports-related orofacial injuries and the importance of mouthguards, *Sports Med* 44(6):777–783, 2014.
- Joda T, Brägger U: Digital vs. conventional implant prosthetic workflows: a cost/time analysis, *Clin Oral Implants Res* 26(12):1430–1435, 2015.
- Kassardjian V, Varma S, Andiappan M, et al.: A systematic review and meta analysis of the longevity of anterior and posterior all-ceramic crowns, *J Dent* 55:1–6, 2016.
- Nedelcu R, Olsson P, Nyström I, et al.: Finish line distinctness and accuracy in 7 intraoral scanners versus conventional impression: an in vitro descriptive comparison, *BMC Oral Health* 18(1):27, 2018.
- Güth JF, Runkel C, Beuer F, et al.: Accuracy of five intraoral scanners compared to indirect digitalization, *Clin Oral Investig* 21(5):1445–1455, 2017.
- Ender A, Attin T, Mehl A: In vivo precision of conventional and digital methods of obtaining complete-arch dental impressions, *J Prosthet Dent* 115(3):313–320, 2016.
- Horacci C, Franchi L, Vichi A, et al.: Accuracy, reliability, and efficiency of intraoral scanners for full-arch impressions: a systematic review of the clinical evidence, *Eur J Orthod* 38(4):422–428, 2016.



## 26

# Dental Problems of Children with Special Health Care Needs

BRIAN J. SANDERS, LAQUIA A. WALKER VINSON and JAMES E. JONES

## CHAPTER OUTLINE

### Dental Access

#### First Dental Visit

#### Radiographic Examination

#### Preventive Dentistry

#### Home Dental Care

#### Diet and Nutrition

#### Fluoride Exposure

#### Preventive Restorations

#### Regular Professional Supervision

### Management of a Child With Special Health Care Needs During Dental Treatment

#### Protective Stabilization

#### Intellectual Disability

#### Dental Treatment of a Person With Intellectual Disability

#### Down Syndrome (Trisomy 21 Syndrome)

### Learning Disabilities

#### Fragile X Syndrome

#### Fetal Alcohol Spectrum Disorder

#### Autism Spectrum Disorder

#### Cerebral Palsy

#### Spina Bifida

#### Respiratory Diseases

#### Asthma (Reactive Airway Disease)

#### Bronchopulmonary Dysplasia

#### Cystic Fibrosis

#### Hearing Loss

#### Visual Impairment

#### Heart Disease

#### Congenital Heart Disease

#### Acquired Heart Disease

#### Dental Management

#### Cardiac Surgery Patients

Over 60 million children and adults in the United States have disabling conditions.<sup>1</sup> The American Academy of Pediatric Dentistry defines individuals with special health care needs (SHCN) as those with “any physical, developmental, mental, sensory, behavioral, cognitive, or emotional impairment or limiting condition that requires medical management, health care intervention, and/or use of specialized services or programs.”<sup>2</sup> Individuals with SHCN are at an increased risk for oral diseases.<sup>3</sup>

Many children with SHCN are evaluated by a multidisciplinary team that includes a dentist. A diagnosis is established, and recommendations for future care are determined. Coordination of dental care with the multidisciplinary team prepares the family for the child’s future care and establishes oral health as a vital part of the child’s well-being and general health.<sup>3</sup>

Children with SHCN may present challenges that require preparation before the dentist and office staff can provide acceptable care. In addition, parental anxiety concerning the problems associated with a child’s SHCN frequently delays dental care until significant oral disease has developed. Kane et al.<sup>4</sup> reported failure to obtain routine medical care as well as income below 400% of federal poverty guidelines as barriers to the receipt of dental care for children with SHCN. Financing and reimbursement issues are other barriers for families of children with SHCN and for dental

practitioners. Nonfinancial barriers such as language and psychosocial, structural, and cultural considerations also interfere with access to oral care.<sup>5</sup>

## Dental Access

Improving access to oral health care for those deprived of needed services should be of great concern to the dental profession. Large segments of the population do not have access to dental care. Children with SHCN, such as those who are chronically ill, homebound, and have developmental disabilities and emotional impairments, fall into this group. Although a majority of children with SHCN receive the needed medical and dental services, 24% report at least one unmet need. Preventive dental care is the most common of those unmet needs.<sup>6</sup> Furthermore, these groups have been identified as a substantial portion of the 20% of the US population who exhibit 80% of all caries.

The rapid expansion of the elderly population, the presence of children with SHCN, and the emergence of legislative guidelines for people of all ages with SHCN are three important factors that should prompt dentists to make their office facilities and operatory areas accessible for persons with SHCN. In August 1984, another federal-level cornerstone was laid for barrier-free facility access with

**TABLE 26.1** Accessibility Guidelines

External/Internal Building Features	Gradient	Length	Width	Surface, Other Specifics
Parking space	1:50 max slope	Standard	Auto: 96 inches Van: 144 inches	Nonskid, paved, sign-posted, adjacent to walkway
Walkway	1:12 max slope	Not applicable	36 inches	Nonskid, no obstructions, overhangs, smooth
Passenger loading zone	Flat	20 feet	60 inches	Same as above
Curb ramps	1:12 max slope		36 inches	Nonskid, side flair <1:10 slope
Door	5-foot entrance and exit platform area	Standard	32-inch minimum; preferably 36 inches	Away from prevailing winds, lever with 10-lb pull, auto-assisted door available, kick plate
Interior ramp	1:20 max slope	72-inch minimum length if rise >6 inches	36 inches	Nonskid, handrails
Wheelchair lift	Bilevel	8-foot max drop	36 × 48 inches	Nonskid, dependent on specific chair
Corridor		Standard	48 inches/64 inches	New facility, no obstacles
Flooring	Flat, firm carpet	Not applicable	½-inch maximum thickness	No doormats, level thresholds
Signs	Braille, raised letters	Above 5 feet	Readable	Near latch of office door
Waiting room	Flat	Standard	36-inch aisle; one cleared area: 36 × 52 inches	No carpet pad, well-insulated, minimum low-frequency background noise
Restrooms	Flat		32-inch stall min., preferably 36 inches	Nonskid, magnetic catch door
Public telephone	No higher than 4 feet	3 feet above floor	26-inch clearance	Phone directory near phone, adjustable volume control
Elevator	Flat		54 × 68 inches	Nonskid, call and control box 48 inches high, include Braille or incised letters
Operatory	Flat 8 × 10 feet	Standard	32- to 36-inch door	Nonskid, rotating or movable chair, drill, and suction

Adapted from Bill DJ, Weddell JA. Dental office access for patients with disabling conditions. *Spec Care Dentist*. 1986;6(6):246–252.

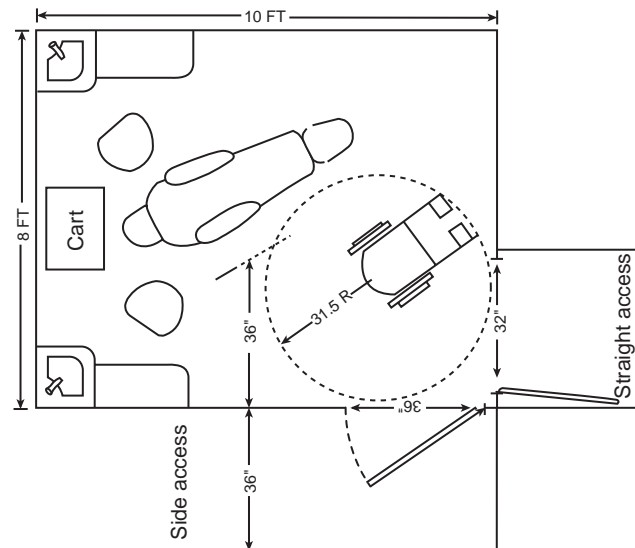
the passage of the Uniform Federal Accessibility Standards.<sup>7</sup> Enacted in 1990, the Americans with Disabilities Act defines the dental office as a place of public accommodation.<sup>8</sup> Dental consumer populations are becoming more sensitive to the service needs and desires of people with SHCN by improving family conditions and public education. Table 26.1 enlists common minimum requirements needed to gain access.

In the dental suite, aisle passage in the operatory area should be planned with the dimensions shown in Fig. 26.1. The required wheelchair turning space and top space under furniture and fixtures may be more readily accommodated if the operatory is designed with a movable dental chair, instrument control unit, and suction system. If possible, a wider radius for turning space is desirable to accommodate the wheelchair extensions and adaptations. Dental chairs should be adjustable for height to match different wheelchair designs.

## First Dental Visit

The establishment of a dental home for a patient with SHCN is the first step in addressing the needs of the family and the child. A thorough medical and dental health history is essential; it may be necessary to consult with the physician(s) to best manage the patients and optimize the outcome.

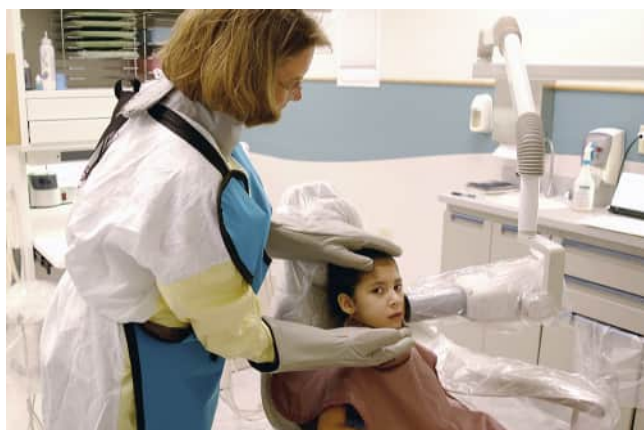The first dental appointment is very important and can set the stage for subsequent appointment. The dentist should schedule sufficient time to speak with the family and answer any questions prior to initiating dental care. It is important to establish a relationship that will help throughout the treatment process.



**Fig. 26.1** An accessible dental operatory floor plan designed for either a straight or side access doorway. (From Bill DJ, Weddell JA. Dental office access for patients with disabling conditions. *Spec Care Dentist*. 1986;6(6):246–252.)

## Radiographic Examination

Adequate radiographic records are often necessary in planning dental treatment for the child with SHCN. Through appropriate behavior management of the child, a dentist can usually perform a radiographic examination of the teeth when indicated. Assistance from the parent and dental staff and the use of protective stabilization may be necessary to obtain the films. In some instances, delaying radiographs until the second visit may be necessary, when



**Fig. 26.2** Extra assistance in holding the patient's head steady to prevent movement while a radiograph is being made.

the patient and family are more comfortable in the dental office (Fig. 26.2).

For patients with limited ability to cooperate, radiographs may not always be possible or as frequent and should be documented in the patient records. Often, the radiographs are obtained while the patient is sedated or undergoing general anesthesia. In all instances, the principles of radiation safety must be adhered to when exposing radiographs.

## Preventive Dentistry

Preventing oral disease before it starts is the most desirable way of ensuring good dental health. An effective preventive dentistry program is important for a child with SHCN because of the predisposing factors that make restorative dental care harder to obtain when it is necessary, and those who make preventive dental visits will have fewer unmet needs.<sup>9</sup> Once the patient has received a complete evaluation that may include a caries risk assessment, the dentist needs to formulate an individualized plan that best fits the patient. A successful preventive program needs good communication and engages the family in the decision process.

### HOME DENTAL CARE

It is important for families with a child with SHCN to recognize that poor dental health may negatively impact the overall health of their child and they have a role in establishing good oral hygiene at home. The dentist or the hygienist is responsible for consulting with the caregiver of the child with SHCN (i.e., parent, guardian, or nursing home attendant) when continued oral hygiene problems occur. Regular follow-up supervision at home and in the dental office is essential for effective implementation of the preventive dental treatment plan.

Home dental care should begin in infancy; the dentist should teach the parents to gently cleanse the incisors daily with an infant toothbrush. For older children who are unwilling or physically unable to cooperate, the dentist should teach the parent or guardian to clean teeth twice a day using correct toothbrushing techniques, safely

immobilizing the child when necessary. Fig. 26.3 shows several positions for toothbrushing that permit firm control and support of the child, adequate visibility, and convenient positioning of the adult, with reasonable comfort for both adult and child. Positions most commonly used for children requiring oral care assistance are as follows:

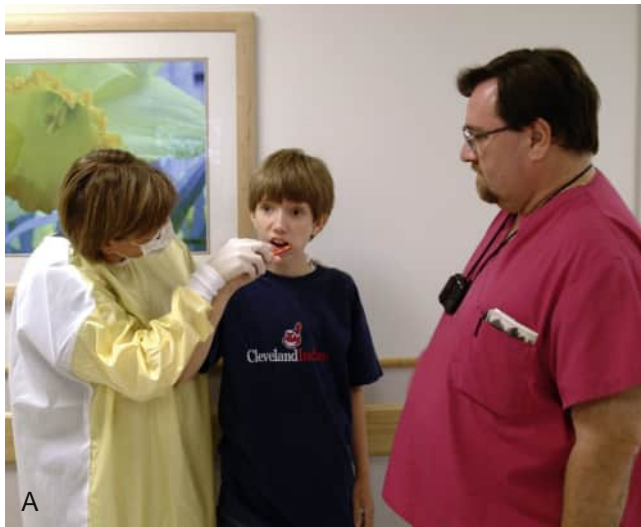- The standing or sitting child is placed in front of the adult so that the adult can cradle the child's head with one hand while using the other hand to brush the teeth.
- The child reclines on a sofa or bed with the head angled backward on the parent's lap and the child's head is stabilized with one hand while the teeth are brushed with the other hand.
- The parents face each other with their knees touching. The child is placed on one parent's lap, with the child facing that parent while the child's head and shoulders lie on the other parent's knees; this allows the first parent to brush the teeth.
- The extremely difficult patient is isolated in an open area and reclined in the brusher's lap. The patient is then immobilized by an extra attendant while the brusher institutes proper oral care. If a child cannot be adequately immobilized by one person, a family member or a second person may be needed to complete the home dental care procedures.
- The standing and resistive child is placed in front of the caregiver so that the adult can wrap his or her legs around the child to support the torso while using the hands to support the head and brush the teeth.

Patients with SHCN who live in institutionalized settings may need the caregivers at the facilities to assist with their daily oral health care. These staff members should receive education in the provision of proper dental care to ensure that patients with SHCN are able to maintain optimal oral health. Wrapped tongue blades or foam bite sticks may be of benefit in helping to keep a child's mouth open while brushing. Stabilization of the child's head prevents unnecessary trauma from sudden movements (Fig. 7A and B). Follow-up observation is conducted by the dentist or the hygienist, and it is appropriate to offer in-service training sessions and to check with the staff periodically to identify and solve the problems associated with an oral hygiene program in the institution.

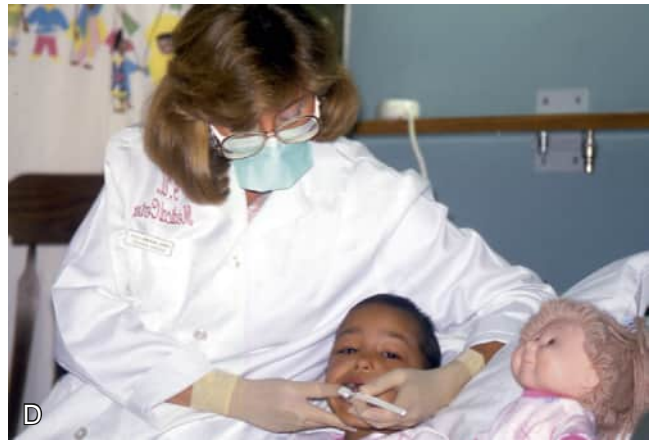Some parents and health care centers have encouraged children with SHCN to assume the responsibility for their own oral hygiene. Although independent brushing is not contraindicated, parents and staff should be aware that, without their follow-up, unsupervised oral hygiene procedures in children with SHCN can have serious dental consequences. The amount of supervision and assistance provided by the parents or staff should depend on the child's willingness to cooperate and ability to maintain good oral hygiene twice a day.

A plaque control program is essential in monitoring oral hygiene in the child with SHCN and determining the level of success achieved by each patient. The brushing technique for patients with SHCN who have fine or gross motor deficiencies limiting their ability to brush should be effective and yet simple for the person performing the brushing. One technique often recommended is the horizontal scrub method

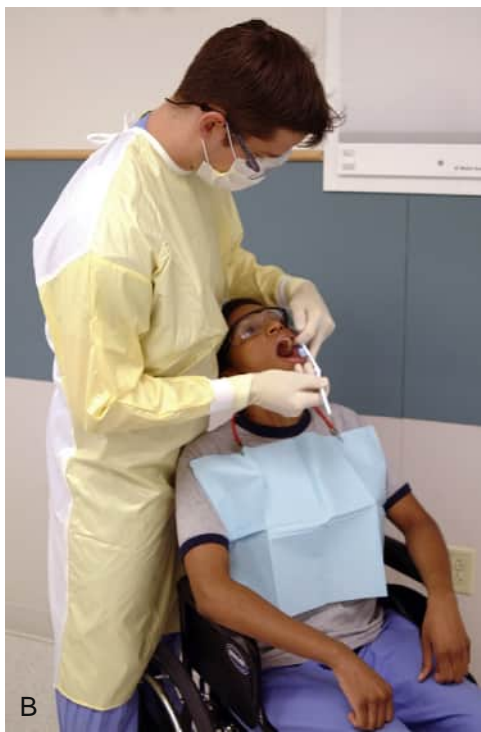



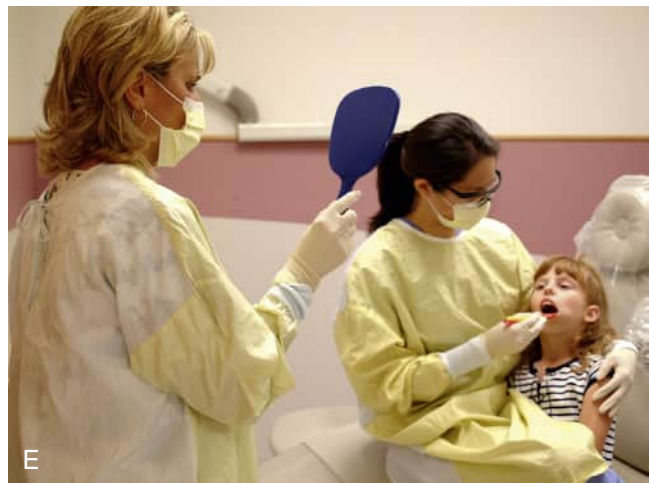A



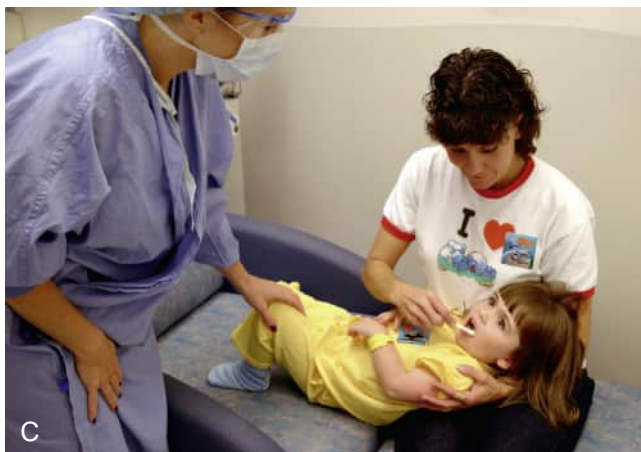D



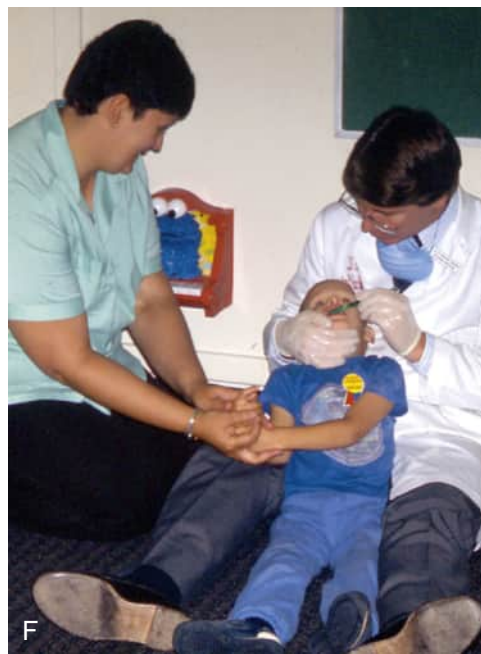B



E



C



F

**Fig. 26.3** Common positions for plaque removal. (A) Standing. (B) Upright wheelchair. (C) Reclining on couch. (D) Reclining in bed. (E) "Leg-lock" position. (F) Reclining on floor.

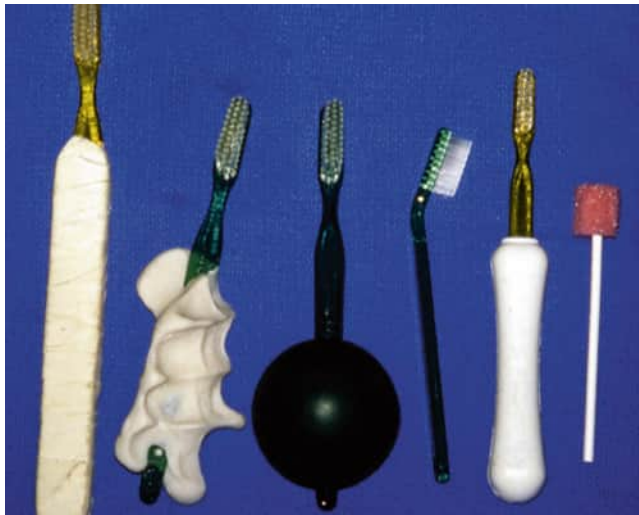

Fig. 26.4 Various toothbrush handle modifications.

because it is easy to perform and can yield good results. This technique consists of performing gentle horizontal strokes on the cheek, tongue, and biting surfaces of all teeth and gums. Other patients with SHCN without such motor problems can use the age-appropriate techniques previously discussed in Chapter 8. A soft, multitufted nylon brush should be used.

Fig. 26.4 illustrates some modifications that may be made to a toothbrush to help persons with poor fine motor skills improve their brushing techniques. Although many types of grips are available, using the patient's hand to custom-design a handle has often had good results (Fig. 26.5). Electric toothbrushes have also been used effectively by children with SHCN. The vibration and noise may desensitize the patient for future dental appointments, while the design and color are motivational for the child. Commercial toothbrush products are also available with suction abilities built into the brush (Sage Products, Cary, IL, USA; <https://sageproducts.ca/product-oral-hygiene/>; accessed Nov 22, 2019). The suction is advantageous in the event that the patient has excess saliva or an aspiration risk. Daily flossing, with supervision or the use of floss holders, is essential to maintain optimal gingival health.

## DIET AND NUTRITION

Diet and nutrition influence dental caries by affecting the type and virulence of the microorganisms in dental plaque, the resistance of teeth and supporting structures, and the properties of saliva in the oral cavity. A proper noncariogenic diet, as outlined in Chapter 9, is essential to a good preventive program for a child with SHCN. A diet survey is helpful and should be reviewed to make allowances for patients who have dietary modification due to their medical history. For example, patients with certain metabolic disturbances or syndromes, such as phenylketonuria, diabetes, or Prader-Willi syndrome, have diets that restrict specific foods or total caloric consumption, while patients with severe cerebral palsy may have a pureed diet secondary to swallowing difficulties. Dietary recommendations should be made individually after proper consultation with the patient's primary physician or dietitian, along with early

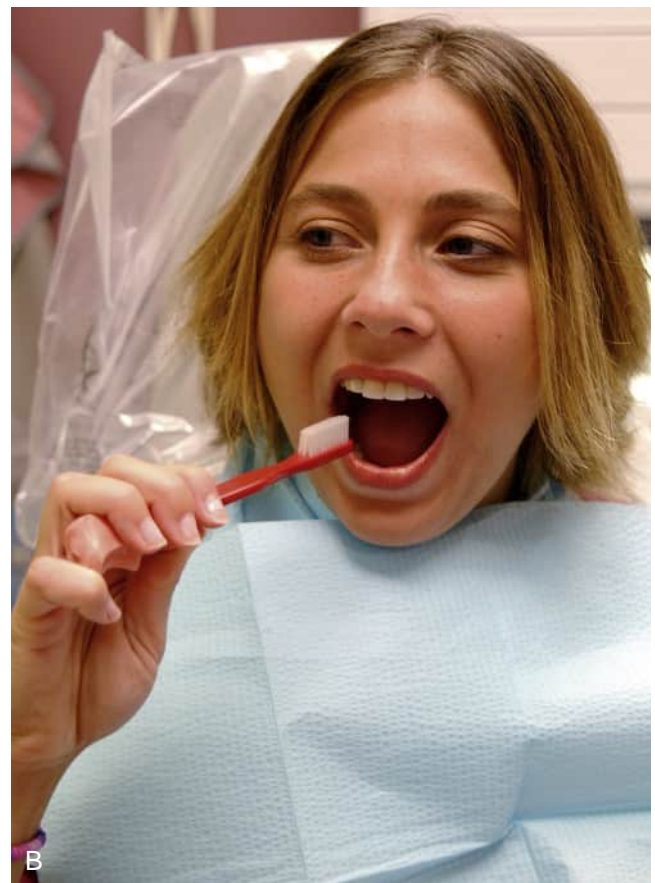
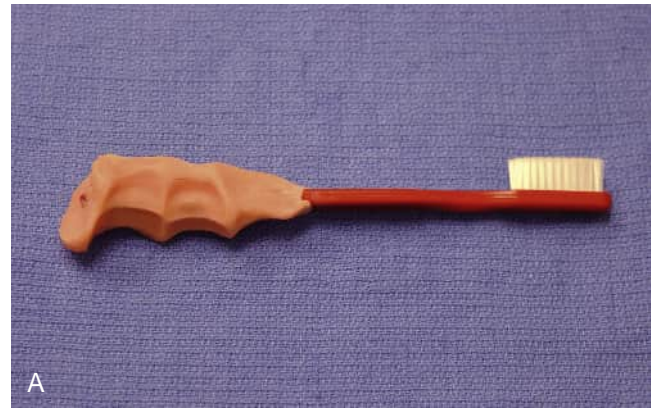
Fig. 26.5 (A) Custom-designed acrylic handle. (B) Patient using the custom-handle toothbrush.

intervention and aggressive preventive care based on the child's caries risk.<sup>10</sup> Many medications have a high sugar content and oral side effects. The parent or guardian may not be aware of the potential impact on the dentition and therefore need to be reviewed and addressed on a regular interval. Particular emphasis should be placed on discontinuation of the nursing bottle by 12 months of age and cessation of at-will breast-feeding after teeth begin to erupt to decrease the likelihood of early childhood caries.

## FLUORIDE EXPOSURE

Fluoride is an essential component in the comprehensive management of the dental patient, and it must be



determined if the patient with SHCN is receiving adequate level of systemic fluoride. The dentist should evaluate all the patient's sources of drinking water to determine if it is adequate and documented. The amount of systemic fluoride supplementation necessary, along with the various forms available (i.e., drops, tablets, and rinses), is outlined in [Chapter 10](#).

Whether the patient lives in an area with a fluoridated or nonfluoridated water supply, a topical fluoride should be applied after a regularly scheduled professional prophylaxis. Also, 5% neutral sodium fluoride varnishes have been shown to be beneficial.<sup>11</sup> An American Dental Association-accepted dentifrice containing a therapeutic fluoride compound should also be used daily. Some clinicians treating patients with SHCN who have chronically poor oral hygiene and high decay rates suggest a daily regimen of rinsing with 0.05% sodium fluoride solution. Nightly application of a 0.4% stannous fluoride or 1.1% sodium fluoride brush-on gel has also been successfully used to decrease caries incidence in children.

### PREVENTIVE RESTORATIONS

Pit-and-fissure sealants have been shown to reduce occlusal caries effectively. Sealants are appropriate in patients with SHCN. For a patient who requires dental work under general anesthesia, deep occlusal pits and fissures should be restored with amalgam or long-wearing composites to prevent further breakdown and decay. Patients with severe bruxism and interproximal decay may need their teeth restored with stainless-steel crowns to increase the longevity of the restorations.

### REGULAR PROFESSIONAL SUPERVISION

Close observation of caries-susceptible patients and regular dental examinations are important in the treatment of patients with SHCN. Although most patients are seen semiannually for professional prophylaxis, examination, and topical fluoride application, certain patients benefit from being seen on a more frequent interval based on caries risk, periodontal health, and adequate home care. Transferring the “dental home” of an adult patient with SHCN to a knowledgeable general dentist is encouraged when dental care needs go beyond the scope of a pediatric dentist.

## Management of a Child With Special Health Care Needs During Dental Treatment

The principles of behavior management discussed in [Chapter 17](#) are even more important in the treatment of a child with SHCN. Frequent medical appointments or hospitalizations may result in the development of greater apprehension in the patient and will require more time and frequent visits to desensitize to establish rapport and dispel the child's anxiety. If patient cooperation cannot be obtained, the dentist must consider alternatives including protective stabilization, conscious sedation, or general

anesthesia to allow the necessary dental procedures to be performed.

### PROTECTIVE STABILIZATION

Partial or complete protective stabilization of the patient is sometimes a necessary and effective way to diagnose and deliver dental care to patients who need help controlling their extremities, such as infants or patients with certain neuromuscular disorders. Protective stabilization is also useful for managing combative, resistant patients so that the patient, practitioner, and/or dental staff may be protected from injury while care is being provided. This can be performed by the dentist, staff, or parent, with or without the aid of a stabilization device.

Informed consent and documentation must be obtained prior to the use of protective stabilization. The parent or guardian should have a clear understanding of the type of stabilization to be used, the rationale, and the duration of use.

In October 1990, the Omnibus Budget Reconciliation Act of 1987 became effective. It provided recommended guidelines to reduce the risk of injury and death from the use of patient restraints. The American Academy of Pediatric Dentistry's *Behavior Guidance for the Pediatric Dental Patient Reference Manual* indicates that the need to diagnose and treat, as well as to protect the safety of the patient, parent, staff, and practitioner, must justify the use of stabilization.<sup>12</sup> This decision should take into consideration a careful review of the patient's emotional development, physical and medical conditions (e.g., asthma-compromised respiratory function), dental needs, other alternative behavioral modalities, and quality of dental care. Although the benefits and importance of protective stabilization have been documented, the use of behavioral management or sedation, as discussed in [Chapter 18](#), may reduce the amount of stabilization required.

The use of protective stabilization ([Video 26.1](#)) is indicated in the following situations:

- A patient requires immediate diagnosis and/or limited treatment and cannot cooperate because of lack of maturity or mental or physical disability.
- A patient requires diagnosis or treatment and does not cooperate after other behavior management techniques have failed.
- The safety of the patient, staff, parent, or practitioner would be at risk without the use of protective stabilization.

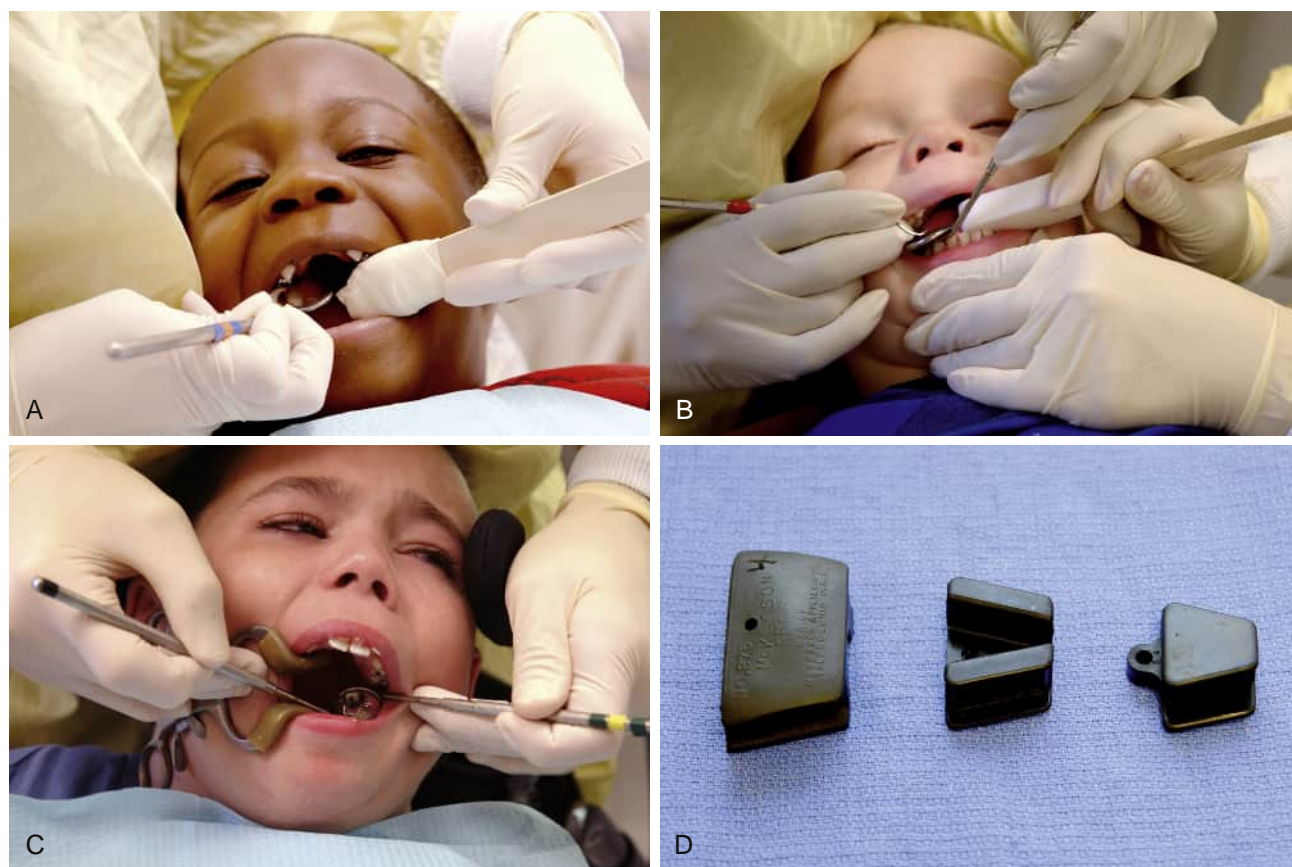**Video 26.1** Protective Stabilization: placement of a sedated child in a papoose board.

The use of stabilization is contraindicated in the following situations:

- A cooperative nonsedated patient.
- Patients who cannot be safely stabilized due to medical or physical conditions.
- Patients who have experienced previous physical or psychological trauma from protective stabilization (unless no other alternatives are available).
- Nonsedated patients with nonemergent treatment requiring lengthy appointments.

Protective stabilization should not be used as punishment and should not be used solely for the convenience of the staff. The patient's record should display an informed





**Fig. 26.6** Protective stabilization aids to keep the patient's mouth open. (A) Wrapped tongue blades. (B) Open Wide (Specialized Care Co.) disposable mouth prop in proper position. (C) Molt Mouth Prop (Hu-Friedy) in proper position. (D) McKesson bite blocks.

consent, the indications for use, the type of stabilization used, and the duration of application. The tightness and duration of stabilization must be monitored and reassessed at regular intervals; stabilization around the extremities or chest must not actively restrict circulation or respiration. Stabilization should be terminated as soon as possible in a patient who is experiencing severe stress to prevent possible physical or psychological trauma.

Common mechanical aids for maintaining the mouth in an open position are shown in Fig. 26.6. Padded and wrapped tongue blades are easy to use, disposable, and inexpensive. There are several brands of disposable mouth props; for example, Open Wide (Specialized Care Co., Hampton, NH, USA) disposable mouth props are made of a durable foam core to aid in the office setting or with home dental care. The Molt Mouth Prop (Hu-Friedy, Chicago, IL, USA) can be very helpful to manage a difficult patient for a prolonged period. It is made in both adult and child sizes, allows access to the opposite side of the mouth, and operates by a “reverse scissors” action. Its disadvantages include the possibility of lip and palatal lacerations and luxation of teeth if not used correctly. Caution must be exercised to prevent injury to the patient, and the prop should not be allowed to rest on anterior teeth. The patient's mouth should not be forced beyond its natural limits because it will cause discomfort and further resistance which may compromise the patient's airway.

Rubber bite blocks can be purchased in various sizes to fit on the occlusal surfaces of the teeth and stabilize the mouth in

an open position. The bite blocks should have floss attached for easy retrieval if they become dislodged in the mouth.

Body control is gained through a variety of methods and techniques. For children who have a severe intellectual disability or are very young, parents and dental assistants can help control movements during dental procedures (Fig. 26.7). Usually, however, for a child who has a severe intellectual disability, better working conditions and a more predictable patient response are obtained through the combined use of psychological management techniques, parental assistance, pharmacologic aids, and stabilization.

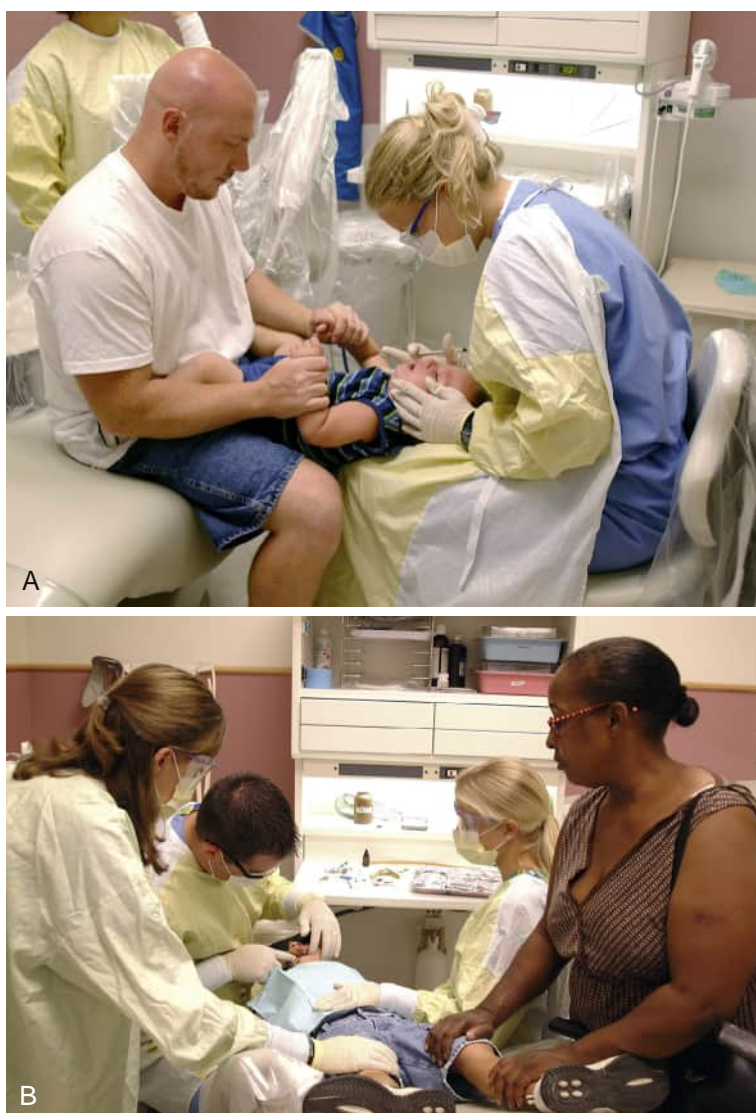The following are commonly used for protective stabilization:

#### Body

- Papoose Board (Olympic Medical Corp., Seattle, Washington, United States)
- Triangular sheet
- Pedi-Wrap (The Medi-Kid Co., Hemet, CA, United States)
- Beanbag dental chair insert
- Safety belt
- Extra assistant

#### Extremities

- Posey straps (Posey Co., Arcadia, CA, United States)
- Velcro straps
- Towel and tape
- Extra assistant



**Fig. 26.7** Assistance for protective stabilization. (A) Parental aid during an examination. (B) Additional assistance during the dental procedure.

## Head

Forearm-body support  
 Head positioner  
 Plastic bowl  
 Extra assistant

The Papoose Board (Fig. 26.8) has several advantages; it is simple to store and use, reusable, and available in sizes to hold both large and small children and has attached head stabilizers. Because it covers the patient's diaphragm, it is recommended that a pretracheal stethoscope be used to monitor respiration if the board is used in combination with sedation. A restrained patient requires constant attendance and supervision especially if the patient is restrained for any significant period of time to minimize any irritation to the skin or potential hyperthermia.

The triangular sheet technique can be utilized to control an extremely resistant child (Fig. 26.9A). This economical method allows the patient to sit upright during radiographic examinations. Its disadvantages include the frequent need for straps to maintain the patient's position in the chair, the difficulty of its use with small patients, and the possibility of

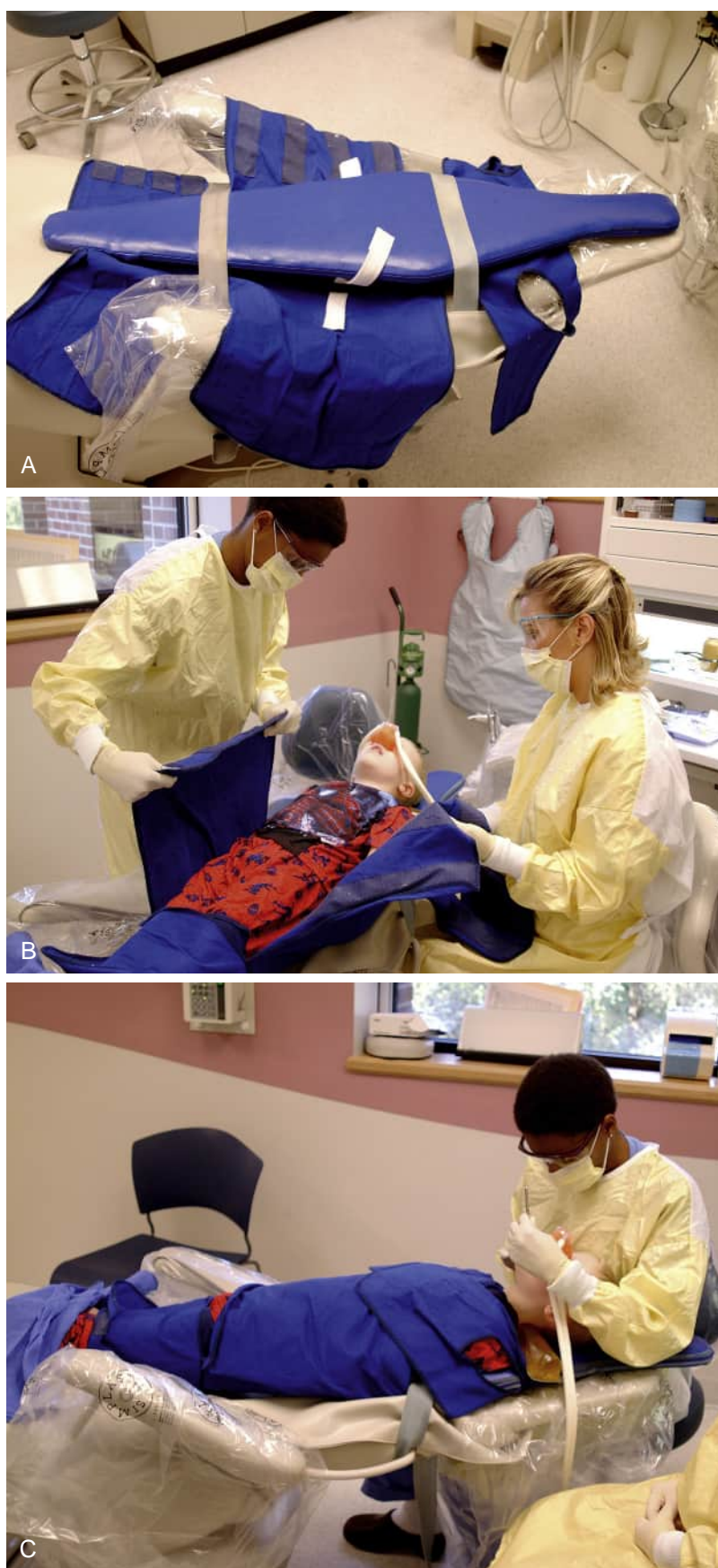airway impingement if the patient slips downward unnoticed. Again, the need for constant supervision is emphasized so that these problems may be avoided.

The Rainbow Stabilizing System (Specialized Care Co.; Fig. 26.9B), which is available with or without the backboard, also comes in various sizes and allows the patient some movement while still being confined. Its mesh fabric permits better ventilation, lessening the chances of the patient developing hyperthermia. It, too, requires straps to maintain body position in the dental chair and supervision to prevent the patient from rolling out of the chair.

The beanbag dental chair insert was developed to help comfortably accommodate hypotonic and severely spastic persons who need more support and less stabilization in a dental environment (Fig. 26.9C). It is reusable and washable, and one size fits most people.

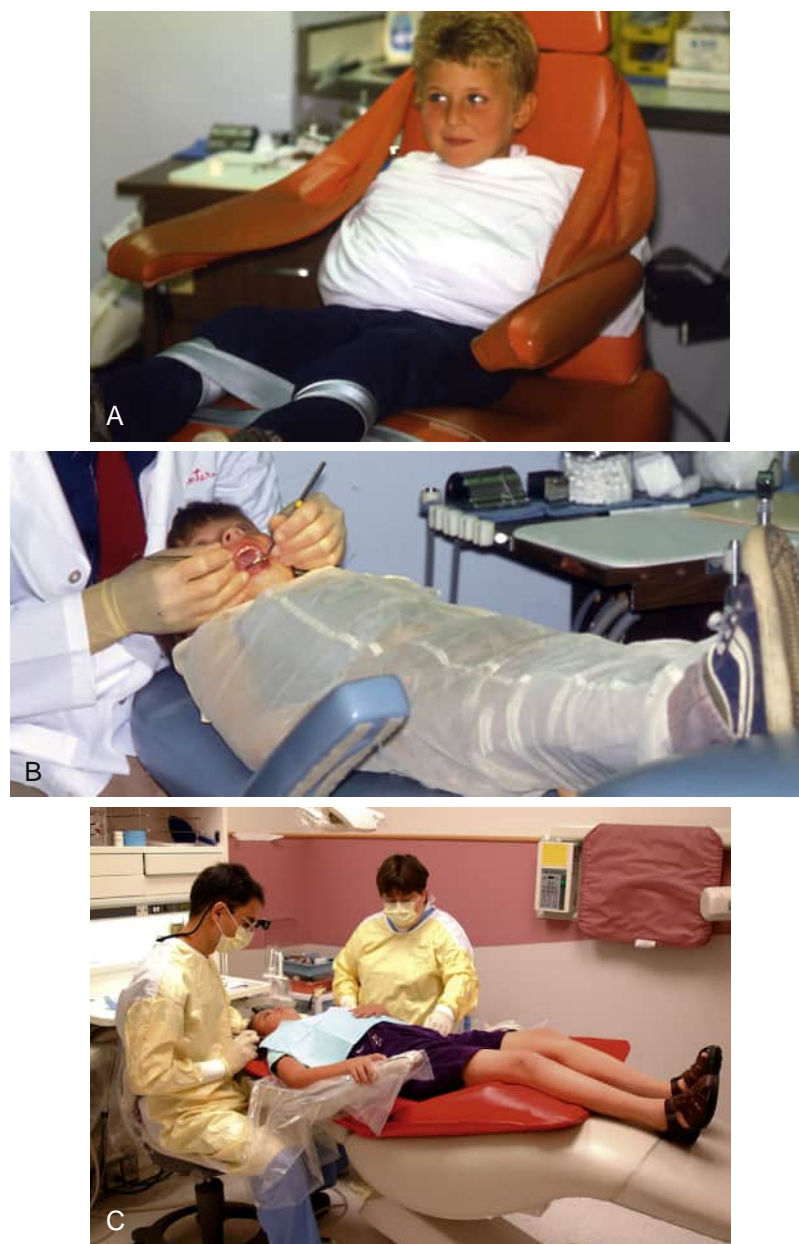The child's arms and legs can be stabilized with help from the parent or the dental assistant, with Posey straps, or with a towel and adhesive tape (Fig. 26.10). If movement of the extremities is the only problem, having a dental assistant stabilize the child is very helpful. Posey straps fasten to the





**Fig. 26.8** (A) The Olympic Papoose Board (Olympic Medical Corp.) secured to a dental chair. (B) Patient being placed in Papoose Board. (C) Papoose Board in use.





**Fig. 26.9** Protective stabilization for control of body and extremities. (A) Patient confined in a triangular sheet with leg straps. (B) Patient in a Pedi-Wrap. (C) Patient lying in a beanbag dental chair insert. (C, Courtesy Dr. Priscilla John Bond.)

arms of the dental chair and allow limited movement of the patient's forearm and hand. Wrapping a towel around the patient's forearms and fastening it with adhesive tape (without impeding circulation) is often helpful for an athetoid-spastic cerebral palsy patient to control body movements. Protective stabilization actually encourages relaxation and prevents undesired reflexes by keeping the patient's arms in the midline of the body.

A patient's head position can usually be successfully maintained through the use of forearm-body pressure by the dentist. Other options include the presence of an additional assistant to stabilize the child's head or use of a Papoose Board head positioner to provide position guidance (Fig. 26.11).

The patient and/or guardian should be carefully explained about how protective stabilization allows the needed dental work to be done while minimizing the possibility of

accidental injury to the patient, parent, staff, or dentist. The mouth prop can be identified as a "tooth chair," the Pedi-Wrap as a "safety robe," and a stabilization strap as a "safety belt," which allows the patient to feel secure rather than threatened. If a child requires extensive dental treatment and cooperation cannot be achieved by routine psychological, physical, or pharmacologic measures, the use of general anesthesia in a controlled atmosphere, as discussed in Chapter 19, is recommended.

## Intellectual Disability

Intellectual disability is a general term used when an individual's intellectual development is considerably lower than average and his or her ability to adapt to the environment is

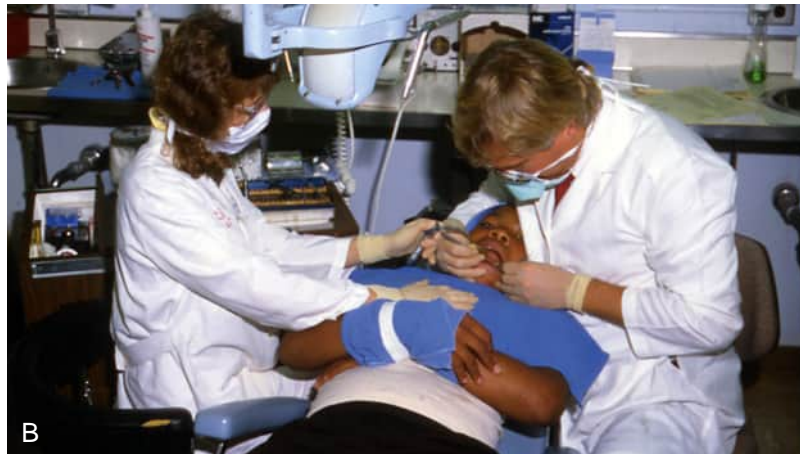
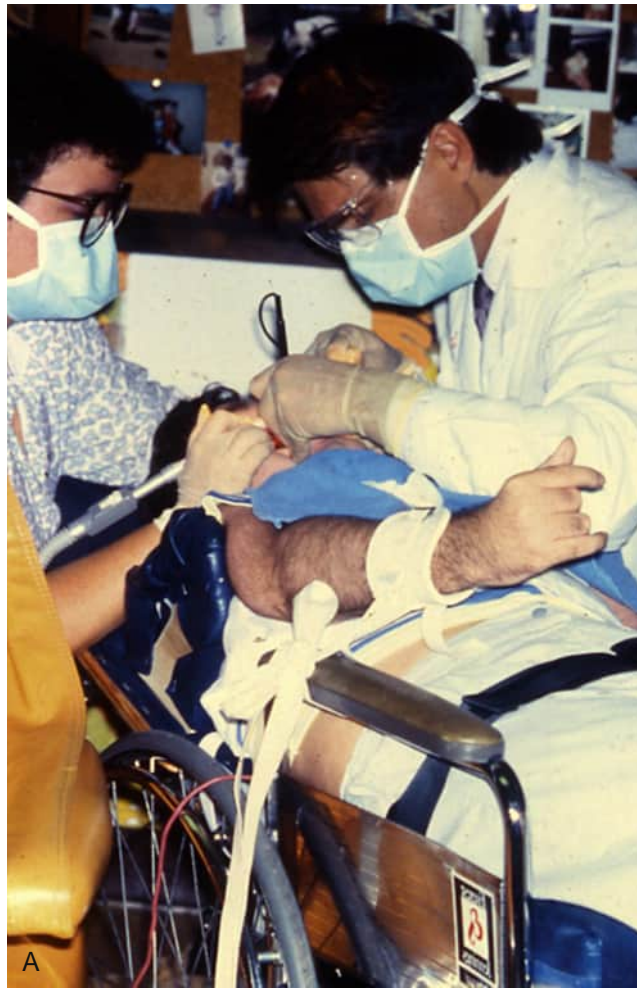
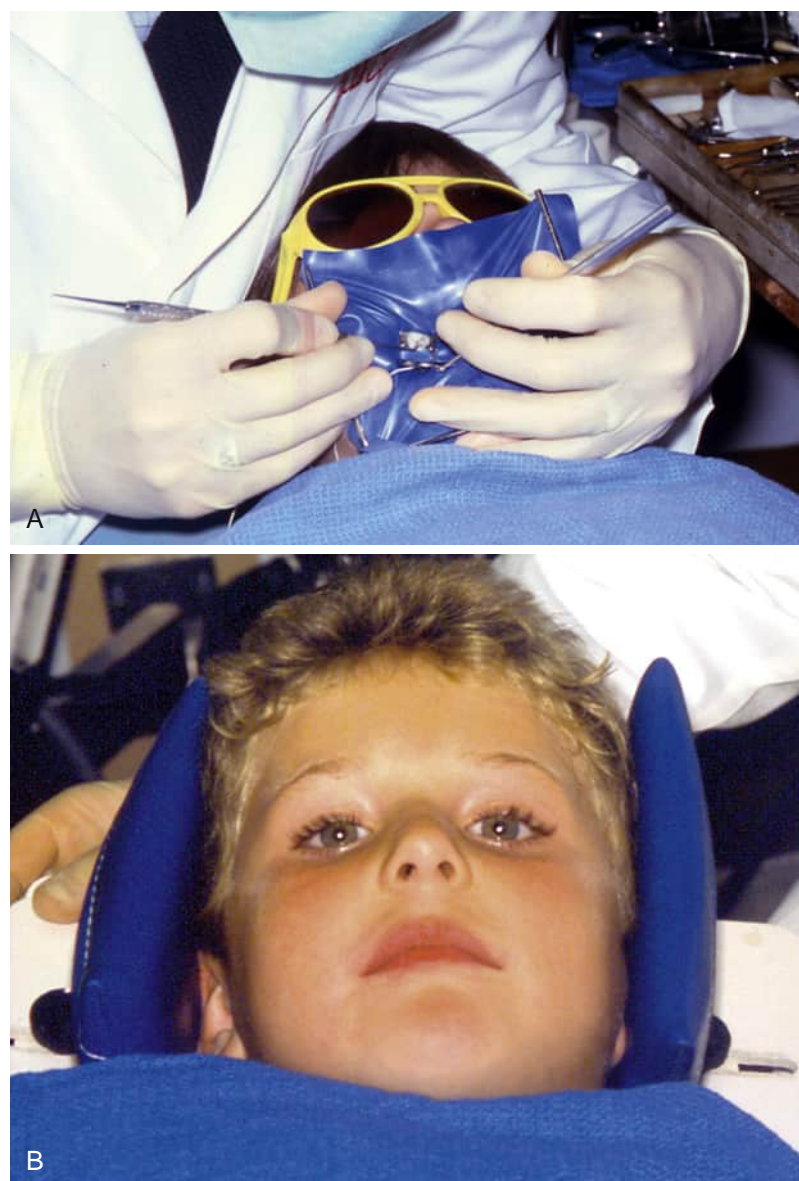Fig. 26.10 Protective stabilization for the extremities. (A) Posey strap (Posey Co.) on wrist. (B) Towel and tape on forearm.

consequently limited.<sup>13</sup> The condition varies in severity and cause. A classification of intellectual disability is presented in Table 26.2. Intellectual disability has been identified in approximately 3% of the US population. For many years, the potential abilities of people with intellectual disabilities were poorly understood, and such individuals were often treated as inferior. They were described using the terms *idiot* (IQ [intelligence quotient] <25), *imbecile* (IQ 25–50), and *moron* (IQ 50–70). With the formation of the President's

Committee on Mental Retardation in 1968, emphasis was placed on education of individuals with intellectual disabilities to increase their social and civic responsibilities, motor skills, and independence within society.

Although a child who scores 2 standard deviations below the mean on the Stanford-Binet Intelligence Scale or the Wechsler Intelligence Scale for Children may have some degree of mental limitations, a diagnosis of intellectual disability is not made based on IQ alone. Both inadequate



**Fig. 26.11** Protective stabilization aids for the head. (A) Proper positioning of the dentist's hands, forearm, and body. (B) Use of the Olympic Papoose Board head positioner.

**TABLE 26.2** Classification of Intellectual Disability

Degree of Mental Disability	SB-IV	WISC-III	Communication	Special Requirements for Dental Care
Mild	67-52	69-55	Should be able to speak well enough for most communication needs	Treat as normal child; mild sedation or nitrous oxide–oxygen analgesia may be beneficial
Moderate	51-36	54-40	Has vocabulary and language skills such that the child can communicate with others at a basic level	Mild to moderate sedation may be beneficial; use restraints and positive reinforcement; general anesthesia may be indicated in cases of severe generalized dental decay
Severe or profound	35 and below	39 and below	Mute or communicates in grunts; little or no communication skills	Same as for moderately intellectually disabled

*SB-IV*, Stanford-Binet Intelligence Scale, 4th ed; *WISC-III*, Wechsler Intelligence Scale for Children, 3rd ed.

adaptive functioning and intellectual deficiency are required to fulfill a diagnosis of intellectual disability.

A child with mild intellectual disability is one who, because of low intelligence, requires special supports in the

school environment. In the academic environment, these children may be eligible for special education services for students with mild intellectual disability. Educational programs for such children are generally simplified versions



of regular school programs and usually lead to literacy and attainment of skills necessary for employment. Most children in this group, which accounts for approximately 80% of all persons with intellectual disability, will function acceptably as adults.

Children who are capable of some education and partial independence but who are not expected to experience full independence as adults may be eligible for special education services for students with moderate intellectual disability. Classroom activities may focus on attainment of daily living skills. Classrooms are often designed and furnished like a home, and the curriculum includes dressing, grooming, cooking, table setting, feeding, and cleaning. Individuals with moderate intellectual disability can be expected to master many vocational, leisure, and self-help skills within a supportive environment with trained personnel who help them with problems with which they may not be able to cope on their own.

A child with severe or profound intellectual disability may present a significant challenge and may be grouped in special education programs. A student with severe to profound intellectual disability can achieve success with self-help, leisure, and some vocational skills if given sufficient training and support. Group home placement can allow individuals with severe to profound intellectual disability a measure of independence while providing sufficient support for safety and continuing reinforcement.

### DENTAL TREATMENT OF A PERSON WITH INTELLECTUAL DISABILITY

Children with intellectual disability may have a higher incidence of poor oral hygiene, gingivitis, malocclusion, and untreated caries. As the severity of intellectual disability increases, typical oral signs of clenching, bruxism, drooling, pica, trauma, and self-injurious behaviors increase. Providing dental treatment to a person with intellectual disability requires adjusting to social, intellectual, and emotional delays. A short attention span, restlessness, hyperactivity, and erratic emotional behavior may characterize patients with intellectual disability undergoing dental care. The dentist should assess the degree of intellectual disability by consulting the patient's physician for frequent medical assessment and coordinate care when appropriate.

The following procedures have proved beneficial in establishing dentist-patient-parent-staff rapport and reducing the patient's anxiety about dental care:

1. Have the family take a tour of the office before attempting treatment. Introduce the patient and family (parent/caretaker/guardian) to the office staff. This will familiarize the patient with the personnel and facility and reduce the patient's fear. Suggest that the patient bring a favorite item (stuffed animal, blanket, or toy) to hold for the visit.
2. Be repetitive; speak slowly and in simple terms. Make sure explanations are understood by asking the patient if there are any questions. If the individual has an alternative communication system, such as a picture board or electronic device, be sure it is available to assist with dental explanations and instructions.
3. Give only one instruction at a time. Reward the patient after the successful completion of each procedure.

4. Actively listen to the patient. People with intellectual disability often have trouble with communication, and the dentist should be particularly sensitive to gestures and verbal requests.
5. Invite the parent/guardian into the operatory for assistance and to aid in communication with the patient.
6. Keep appointments short. Gradually progress to more difficult procedures (e.g., anesthesia and restorative dentistry) after the patient has become accustomed to the dental environment.
7. Maintain a lighter schedule to better accommodate the needs of the patient.

### Down Syndrome (Trisomy 21 Syndrome)

Down syndrome is the best-known chromosomal disorder and is caused by the presence of an extra copy of chromosome 21 (trisomy 21). Medical conditions that occur more frequently in infants and children with Down syndrome and increase the mortality of these individuals include cardiac defects, leukemia, and upper respiratory infections. The incidence of congenital cardiac defects is about 40%, and because of these patients' high susceptibility to periodontal disease, knowledge of a heart condition is essential for dental treatment. Children with Down syndrome have a 10- to 20-fold greater incidence of leukemia during infancy compared with the general population. This increased incidence of leukemia is not maintained later in life.

Skeletal findings are an underdeveloped midface, creating a prognathic occlusal relationship. Oral findings include mouth breathing, open bite, appearance of relative macroglossia, fissured lips and tongue, angular cheilitis, delayed eruption times, missing and malformed teeth, oligodontia, small roots, microdontia, crowding, and a low level of caries. Children with Down syndrome experience a high incidence of rapid, destructive periodontal disease, which may be related to local factors such as tooth morphology, bruxism, malocclusion, and poor oral hygiene. Certain systemic factors are also believed to contribute to periodontal disease, including poor circulation and decreased cellular motility of gingival fibroblasts,<sup>14</sup> decreased humoral response, general physical deterioration at an early age, and genetic influences. Bell et al.<sup>15</sup> reported that severity of tooth wear (both attrition and erosion) was significantly greater in children with Down syndrome than in children without the syndrome.

Many children with Down syndrome are cooperative, and dental procedures may be provided without compromise if the dentist works at a slightly slower pace. Emphasis should be placed on preventive dental care with frequent follow-up visits to monitor oral hygiene. A recent study by Cheng et al.<sup>16</sup> documented periodontal healing responses in adult patients with Down syndrome using nonsurgical periodontal therapy in conjunction with the use of chlorhexidine rinse twice a day and chlorhexidine gel and monthly recalls. Comprehensive dental care is an overall goal with alteration based on the individual's level of functioning. Light sedation and immobilization may be indicated in those children who are moderately apprehensive. Severely resistive patients may require general anesthesia.

## Learning Disabilities

Learning disabilities are neurological conditions that interfere with the individual's ability to store, process, or produce information. They can affect a person's ability to read, write, count, speak, or reason. In addition, they may affect memory, attention, coordination, social skills, and emotional maturity. Learning disabilities affect 3%–15% of the population and occur four times more frequently among boys than among girls.

Learning disabilities may have a possible genetic factor and are sometimes confused with intellectual disabilities, autism, deafness, and behavioral disorders. They include conditions that have been referred to as perceptual handicaps, brain injury, minimal brain dysfunction, dyslexia, and developmental aphasia. The cause of learning disabilities remains unclear. Physiologic factors, such as minimal brain injury or damage to the central nervous system, have also been implicated. Early diagnosis and treatment of learning disabilities can minimize the possible severe emotional disturbances.

Most children with learning disabilities accept dental care and cause no unusual management problems for the dentist. If a child is resistant, behavioral management and conscious sedation techniques may be used with success.

## Fragile X Syndrome

Fragile X is an X-linked developmental disorder, accounting for 30%–50% cases of X-linked mental disability. The defect is an abnormal gene on the terminal portion of the long arm of an X chromosome. Because males have only one X chromosome, they are more vulnerable and significantly more affected than females. Numerous studies have investigated fragile X syndrome in males, but fragile X syndrome in females has not been investigated as extensively because the physical and cognitive deficits in females are usually less severe. It is one of the most common genetic causes of learning disability, but because it is less phenotypically recognizable, reports of orofacial findings are limited.

A history of developmental delay and hyperactivity, and physical features such as prominent ears, long face, prominent jaw, flattened nasal bridge, hyperextensible joints, flat feet, mitral valve prolapse, simian creases of the palms, and postadolescent macroorchidism in males should be considered potential indicators for fragile X syndrome. A higher incidence of malocclusions including an open bite and cross-bites has been reported.

Behavioral features such as hand slapping, hand biting, and poor eye contact are frequently observed. Fragile X syndrome may be diagnosed in individuals with another diagnosis such as Down syndrome or cerebral palsy.

Treatment of children with fragile X syndrome is multidisciplinary, and speech, language, and occupational therapy is required to address the cognitive, language, and sensory integration problems. Medical intervention can be useful in decreasing the hyperactivity and improving the attention span. Females with fragile X syndrome have a more favorable outcome with appropriate intervention than males with fragile X syndrome.

The mode of dental treatment depends on the level of developmental delay, cognitive ability, and degree of hyperactivity. Children with mild cases may be treated by scheduling short appointments and using immobilization and/or conscious sedation. Severely affected patients must be treated in the operating room under general anesthesia.

## Fetal Alcohol Spectrum Disorder

Fetal alcohol spectrum disorder (FASD) is an umbrella term that describes the range of effects that may occur with maternal consumption of alcohol during pregnancy. It occurs in about 40,000 babies per year, and it is likely that the alcohol affects the normal development of the neural crest cells. The Centers for Disease Control and Prevention requires three facial findings, growth deficits, and central nervous system abnormalities to make the diagnosis, but even in the absence of the characteristic findings, FASD should be suspected in children with growth deficits, central nervous system abnormalities, and a history of prenatal alcohol exposure. Physical findings may include moderate to severe growth retardation with persistent microcephaly. There are often eye abnormalities, short palpebral fissures, a smooth philtrum, and a thin vermilion border. Cardiac malformations include ventricular septal defects, pulmonary artery hypoplasia, and interruption of the aortic arch. Hearing and vestibular problems are also seen, and because the development of speech is dependent upon an intact hearing apparatus, children with FASD may have slurred speech and poor receptive and language skills. The vestibular damage may result in postural disturbances. Other associated abnormalities, such as skeletal, urinary, and immune system impairment, have also been reported.

Craniofacial features include midface underdevelopment, small teeth, absent teeth, high-arched palate, delayed dental development, enamel anomalies, cleft lip or palate, crowded incisors, excessive maxillary overjet, and open bite. The dentist must be aware of the physical, emotional, and mental conditions because these may affect dental management and treatment planning.

## Autism Spectrum Disorder

Autism spectrum disorder (ASD) includes three neurodevelopmental disorders: autism disorder, Asperger syndrome, and pervasive development disorder. The prevalence is estimated to be 6 per 1000 children, with greater frequency of occurrence in boys than in girls. The rise in the rates of ASD has been attributed to increased awareness and better diagnostic tools.

Although genetic factors and environmental factors may play a role, the exact cause of ASD remains unclear. Majority of cases are idiopathic, but a small proportion of cases have a known inheritance such as fragile X syndrome, tuberous sclerosis, Rett syndrome, and Angelman syndrome. Many children with ASD present with a typical developmental period followed by regression in the second year.

There are three levels of impairment noted. The first notable impairment is social, which in some cases is extreme, with lack of eye contact and not responding to one's name.

The second is an impairment in communication, which can result in the delay or complete lack of spoken language. Children with Asperger syndrome do not have a general delay in language or cognitive development; however, they often have communication difficulties, especially in sustaining conversations.

The third area of impairment in ASD is repetitive behaviors. They may include staring, floppy hands, an odd interest in or preoccupation with specific objects. There is great variability in presentation in children with ASD, and the diagnosis is made based upon the number of symptoms involved.

Children with ASD have multiple medical and behavioral problems that may make dental treatment difficult. These children often have poor muscle tone, poor coordination, drooling, a hyperactive knee jerk, and strabismus; 30% children eventually develop epilepsy. Children with ASD may have strict routines and prefer soft and sweetened foods. Because of poor tongue coordination, children with ASD tend to “pouch” food instead of swallowing. This habit, combined with the desire for sweetened foods, leads to increased susceptibility to caries.

Because of their tendency to adhere to routines, children with ASD may require several dental visits to acclimate to the dental environment. The use of a Papoose Board or Pedi-Wrap may be necessary and in some instances has a calming effect on the child.

## Cerebral Palsy

Cerebral palsy is one of the primary handicapping conditions of childhood. The incidence of cerebral palsy in the United States for all ages is 1.5–3 cases per 1000 individuals. One newborn in approximately 200 live births will be affected with this condition. Cerebral palsy is not a specific disease entity but rather a collection of disabling disorders caused by insult and permanent damage to the brain in the prenatal and perinatal periods, during which time the central nervous system is still maturing. This disability might involve muscle weakness, stiffness or paralysis, poor balance or irregular gait, and uncoordinated or involuntary movements.

Although many recognized conditions result in damage to the motor centers of the brain, no discernible cause is found in at least one-third of the cases of cerebral palsy. It has been well established that any factor contributing to decreased oxygenation of the developing brain can be responsible for brain damage. In addition, causal relationships have been established between cerebral palsy and complications of labor or delivery; infections of the brain, such as meningitis and encephalitis; toxemias of pregnancy; congenital defects of the brain; kernicterus; poisoning with certain drugs and heavy metals; and accidents resulting in trauma to the head. There is a high correlation between premature birth and cerebral palsy. (Approximately one-third of all infants born prematurely have a demonstrable nervous system abnormality.)

There are various types of cerebral palsy which are distinguished according to the neuromuscular dysfunctions observed and the extent of anatomic involvement. Some persons may have almost imperceptible symptoms. Others

are severely disabled, with no appreciable use of the muscles of their limbs and other voluntary muscles. It is imperative to keep in mind that two patients with the same type of cerebral palsy may show very disparate symptoms. The following terms are commonly used to designate involved areas of the body:

1. Monoplegia—involvement of one limb only.
2. Hemiplegia—involvement of one side of the body.
3. Paraplegia—involvement of both legs only.
4. Diplegia—involvement of both legs with minimum involvement of both arms.
5. Quadriplegia—involvement of all four limbs.

The following outline provides a classification of cerebral palsy according to the type of neuromuscular dysfunction and lists a few of the basic characteristics of each type:

- I. *Spastic* (approximately 70% of cases)
  - A. Hyperirritability of involved muscles, resulting in exaggerated contraction when stimulated.
  - B. Tense, contracted muscles (e.g., spastic hemiplegia) affect one-third of all children with cerebral palsy. The hand and arm are flexed and held in against the trunk. The foot and leg may be flexed and rotated internally, which results in a limping gait with circumduction of the affected leg.
  - C. Limited control of neck muscles, which results in head rolling.
  - D. Lack of control of the muscles supporting the trunk, which results in difficulty in maintaining upright posture.
  - E. Lack of coordination of intraoral, perioral, and masticatory musculature; possibility of impaired chewing and swallowing, excessive drooling, persistent spastic tongue thrust, and speech impairments.
- II. *Dyskinetic* (athetosis and choreoathetosis; approximately 15% of cases)
  - A. Constant and uncontrolled motion of involved muscles.
  - B. Succession of slow, twisting, or writhing involuntary movements (athetosis) or quick, jerky movements (choreoathetosis).
  - C. Frequent involvement of neck musculature, which results in excessive movement of the head. Hypertonicity of these muscles may cause the head to be held back, with the mouth constantly open and the tongue positioned anteriorly or protruded.
  - D. Possibility of frequent, uncontrolled jaw movements, causing abrupt closure of the jaws or severe bruxism.
  - E. Frequent hypotonicity of perioral musculature, with mouth breathing, tongue protrusion, and excessive drooling.
  - F. Facial grimacing.
  - G. Chewing and swallowing difficulties.
  - H. Speech problems.
- III. *Ataxic* (approximately 5% of cases)
  - A. Inability of involved muscles to contract completely so that voluntary movements can be only partially performed.
  - B. Poor sense of balance and uncoordinated voluntary movements (e.g., stumbling or staggering gait or difficulty in grasping objects.)



- C. Possibility of tremors and an uncontrollable trembling or quivering when attempting voluntary tasks.
- IV. *Mixed* (approximately 10% of cases)
- A. Combination of characteristics of more than one type of cerebral palsy (e.g., mixed spastic-athetoid quadriplegia).

Two additional forms of cerebral palsy have been described but occur infrequently. In hypotonia, the muscles are flaccid (i.e., there is an inability to elicit muscle activity on volitional stimulation). In rigidity, the muscles are in a constant state of contraction. The condition is characterized by prolonged periods in which the muscles of the extremities or trunk remain rigid, resisting any effort to move them.

In many patients with cerebral palsy, certain neonatal reflexes may persist long after the age at which they normally disappear. These primitive reflexes are usually modified or are progressively replaced as the subcortical dominance of the infant's behavior is suppressed by higher centers of the maturing central nervous system. Three of the most common reactions, which a dentist should recognize, are the following:

1. *Asymmetric tonic neck reflex*. If the patient's head is suddenly turned to one side, the arm and leg on the side to which the face is turned extend and stiffen. The limbs on the opposite side flex.
2. *Tonic labyrinthine reflex*. If the patient's head suddenly falls backward while the patient is supine, the back may assume the position known as *postural extension*; the legs and arms straighten out, and the neck and back arch.
3. *Startle reflex*. This reflex, which is frequently observed in persons with cerebral palsy, consists of sudden, involuntary, often forceful bodily movements. This reaction is produced when the patient is surprised by stimuli, such as sudden noises or unexpected movements by other people.

Because the motor involvement in cerebral palsy results from irreversible damage to the developing brain, other symptoms of organic brain damage may also be present. The fact that these other symptoms are frequently seen underscores the premise that cerebral palsy does not denote one specific disease entity. Rather, it is a complex of disabling conditions, the clinical manifestations of which depend on the extent and location of damage to the brain. The following are some common manifestations:

1. *Intellectual disability*. Approximately 60% of persons with cerebral palsy demonstrate some degree of intellectual disability.
2. *Seizure disorders*. Seizures are an accompanying condition in 30%–50% of cases; they occur primarily during infancy and early childhood. Most seizures can be controlled with anticonvulsant medications.
3. *Sensory deficits or dysfunctions*. Impairment of hearing is more common than in the normal population, and eye disorders affect approximately 35% of persons with cerebral palsy. The most common visual defect is strabismus.
4. *Speech disorders*. More than half of patients with cerebral palsy have some speech problem—usually dysarthria, an inability to articulate well because of lack of control of the speech muscles.

5. *Joint contractures*. Persons with spasticity and rigidity demonstrate abnormal limb postures and contractures during growth and at maturity, primarily because of disuse of muscle groups.

No intraoral anomalies are unique to persons with cerebral palsy. However, several conditions are more common or more severe than in the general population. These conditions are as follows:

1. *Periodontal disease*. Periodontal disease and poor oral hygiene occur with increased frequency in persons with cerebral palsy. Often the patient will not be physically able to brush or floss adequately. When oral hygiene measures must be provided for the person by another individual, they may be performed infrequently and inadequately. Diet may also be significant; children who have difficulty chewing and swallowing tend to eat soft foods, which are easily swallowed and are high in carbohydrates. Patients with cerebral palsy and who take phenytoin to control seizure activity may have a degree of gingival hyperplasia.
2. *Dental caries*. The data are conflicting regarding the incidence of dental caries in patients with cerebral palsy compared with its incidence in the general population. Except among institutionalized patients, the incidence of caries does not seem to be considerably greater among persons with cerebral palsy.
3. *Malocclusions*. The prevalence of malocclusions in patients with cerebral palsy is approximately twice that in the general population. Commonly observed conditions include noticeable protrusion of the maxillary anterior teeth, excessive overbite and overjet, open bites, and unilateral crossbites. A primary cause may be a disharmonious relationship between intraoral and perioral muscles. Uncoordinated and uncontrolled movements of the jaws, lips, and tongue are observed with greater frequency in patients with cerebral palsy. This may result in impaired chewing and swallowing, excessive drooling, tongue thrust, and speech impairment.
4. *Bruxism*. Bruxism is commonly observed in patients with athetoid cerebral palsy. Severe occlusal attrition of the primary and permanent dentition may be noted, with the resulting loss of vertical interarch dimension. Temporomandibular joint disorders may be sequelae of this condition in adult patients.
5. *Trauma*. Persons with cerebral palsy are more susceptible to trauma, particularly to the maxillary anterior teeth. This situation is related to the increased tendency to fall, along with a diminished extensor reflex to cushion such falls, and the frequent increased flaring of the maxillary anterior teeth. Susceptibilities also include aspiration and ingestion of a foreign body.

A patient with cerebral palsy who has involuntary movements of the limbs and head might be perceived as an uncooperative and unmanageable. Moreover, if they have unintelligible speech, uncontrollable jaw movements, and spastic tongue, they are often erroneously assumed to be intellectually delayed.

In providing treatment for children with cerebral palsy, it is imperative that a dentist evaluate each patient thoroughly

in terms of personal characteristics, symptoms, and behavior and then proceed as conditions and needs dictate.

Taking a thorough medical and dental history is very important, and the parent or guardian should be interviewed before the initiation of any treatment. It may also be beneficial to consult the patient's physician regarding the patient's medical status.

A patient with cerebral palsy and who has involuntary head movements may be cognizant of the need to minimize these movements while receiving dental care. Paradoxically, the patient's own endeavors to control these movements may only exacerbate the problem. Therefore it is imperative that all dental personnel be empathic about the fears and frustrations that such a person experiences. The importance of maintaining a calm, friendly, and professional atmosphere cannot be overemphasized.

The following suggestions are offered to the clinician as being of practical significance in treating a patient with cerebral palsy:

1. Consider treating a patient who uses a wheelchair in the wheelchair. Many patients express such a preference, and it is frequently more practical for the dentist. For a young patient, the wheelchair may be tipped back into the dentist's lap.
2. If a patient is to be transferred to the dental chair, ask about a preference for the mode of transfer. If the patient has no preference, the two-person lift is recommended.
3. Make an effort to stabilize the patient's head throughout all phases of dental treatment.
4. Try to place and maintain the patient in the midline of the dental chair, with arms and legs as close to the body as feasible.
5. Keep the patient's back slightly elevated to minimize difficulties in swallowing. (It is advisable not to have the patient in a completely supine position.)
6. When the patient has been placed in the dental chair, determine the patient's degree of comfort and assess the position of the extremities. Do not force the limbs into unnatural positions. Consider the use of pillows, towels, and other measures for trunk and limb support.
7. Use stabilization judiciously to control flailing movements of the extremities.
8. For control of involuntary jaw movements, choose from a variety of mouth props. Patient preference should weigh heavily because a patient with cerebral palsy may be very apprehensive about the ability to control swallowing. Such appliances may also trigger the strong gag reflex that many of these patients possess. Allow frequent time-outs for the patient to regroup, relax, and breathe normally.
9. To minimize startle reflex reactions, avoid presenting stimuli such as abrupt movements, noises, and lights without forewarning the patient.
10. Introduce intraoral stimuli slowly to avoid eliciting a gag reflex or to make it less severe.
11. Consider the use of the rubber dam, a highly recommended technique, for restorative procedures.
12. Work efficiently and quickly and minimize patient time in the chair to decrease fatigue of the involved muscles.
13. Sedation or general anesthesia may be an option for more complex patients.

## Spina Bifida

Although the etiology of spina bifida is unknown, it is thought to be the result of a genetic predisposition whose manifestation is triggered by the environment. There are two common forms of this neural tube defect, spina bifida occulta and myelomeningocele. Spina bifida occulta (i.e., closed) presents with the skin covering an area where tissue protrudes through a bony cleft in the vertebral column. These children may develop foot weakness or bowel and bladder sphincter disturbances. Myelomeningocele (spina bifida aperta, i.e., open) is the most severe because the spinal cord, spinal fluid, and membranes protrude in a sac through the defect. These children can suffer from hydrocephalus, paralysis, orthopedic deformities, and genitourinary abnormalities. If the mother takes folic acid during the first 6 weeks of pregnancy, over 50% of neural tube defects can be prevented.

Children with neural tube defects are at higher risk for caries secondary to poor hygiene, poor nutritional intake, and long-term drug therapy. They are also at higher risk for latex allergy because they are frequently exposed to latex as a result of undergoing procedures in which latex products are used. Therefore Nettis et al.<sup>17</sup> recommend that all patients be screened for conditions such as spina bifida and exposure to recurrent surgical procedures, and for a history of atopy, crossreactive food allergies (i.e., allergies to banana, avocado, kiwi, and chestnuts, which may sensitize allergic patients to latex exposure), and previous reactions to natural rubber latex.

For all patients with a latex allergy or latex allergy risk factors, all equipment that comes in intimate contact with the patient should be made of nonlatex substitutes. Nettis et al.<sup>17</sup> suggest that the ideal time to schedule dental appointments for such individuals is at the beginning of a working session, such as in the morning or after a vacation when the office has been closed. This will allow for settling of airborne latex particles. Another good scheduling time is after the office has been professionally vacuumed and cleaned to remove latex-tainted cornstarch. Mild irritant reactions to latex can be managed with immediate removal of the rubber object and administration of an antihistamine. However, acute systemic reactions (anaphylaxis) require immediate treatment with epinephrine injection 1:1000 USP and may necessitate emergency resuscitation (call 911).

## Respiratory Diseases

### ASTHMA (REACTIVE AIRWAY DISEASE)

Asthma is a common childhood disease, affecting 1 in 10 children. Although often thought of as acute respiratory distress brought on by environmental factors, asthma is a chronic airway disease characterized by inflammation, increased mucus production, and bronchial constriction.

Asthma is a diffuse obstructive disease of the airway caused by edema of the mucous membranes, increased mucous secretions, and spasm of smooth muscle. It is twice as common in prepubertal boys but affects both genders equally during adolescence and adulthood. The etiology includes biochemical, immunologic, infectious, endocrine, and psychological factors. The typical symptoms of asthma

include coughing, wheezing, chest tightness, and dyspnea. The clinical onset of an episode may occur over minutes (acute) or hours and days. An acute attack is associated with exposure to irritants such as cold air, fumes, or dust, and it may develop in minutes. An attack developing over days is usually precipitated by a viral respiratory infection. Severe bronchial obstruction results in labored breathing, wheezing, tachypnea, profuse perspiration, cyanosis, hyperventilation, tachycardia, and sometimes chest pain. A dental procedure constitutes an acute irritant to the airways of the asthmatic child and may precipitate an attack.

Fortunately, three-fourths of childhood asthma is mild, with minimal daily symptoms and short-lived exacerbations. Before initiating dental treatment, the dentist should know what are the frequency and severity of the attacks, what are the triggering agents, when the patient was hospitalized and/or in the emergency department, when the last attack occurred, what medications the patient takes, and what limitations on activity the patient may have. Patients taking systemic corticosteroids and those who were hospitalized or in the emergency department in the preceding year should be treated with caution because they are at higher risk of morbidity and mortality. Sometimes, deferring the dental visit until the patient's asthma is well controlled is recommended.

Patients who use bronchodilators should take a dose before their appointment and bring their inhalers or nebulizers into the dental office. Acute symptoms may be prevented by the use of the child's bronchodilator (inhaled  $\beta_2$  receptor agonist such as albuterol). Behavioral methods are used to reduce anxiety, and nitrous oxide–oxygen analgesia may be helpful. Hydroxyzine hydrochloride (Vistaril) and diazepam (Valium) have been successful in alleviating anxiety. Barbiturates and narcotics are not indicated because of their potential for histamine release, leading to a bronchospasm. Aspirin compounds and nonsteroidal antiinflammatory agents are contraindicated because about 4% of patients experience wheezing after taking these drugs. Acetaminophen is recommended. Positioning a child with mild asthmatic symptoms in an upright or semi-upright position for the dental procedure may be beneficial.

Oral findings of children with moderate to severe asthma include higher caries rates, decreased salivary rates, increased prevalence of oral mucosal changes characteristic of chronic mouth breathers, and increased levels of gingivitis. Increased incidence of orofacial abnormalities such as high palatal vault, more posterior crossbites, greater overjet, and increased facial height is also seen.

Dental goals are similar to those for other patients, with care taken to avoid the potential for dental materials and products to exacerbate the asthma. The patient's pulmonary function, propensity for developing an attack, immune status, and adrenal status should be evaluated prior to dental treatment. Emergency treatment for a person with asthma and who is in respiratory distress requires discontinuing the dental procedure, reassuring the patient, and opening the airway. Staff should administer 100% oxygen while placing the patient in an upright or comfortable position. Keeping the airway open, administer the patient's  $\beta_2$  agonist with an inhaler or nebulizer. If there is no improvement, administer subcutaneous epinephrine (0.01 mg/kg of 1:1000 solution) and obtain medical assistance immediately.

## BRONCHOPULMONARY DYSPLASIA

Bronchopulmonary dysplasia is a chronic lung disease usually resulting from the occurrence during infancy of respiratory distress syndrome that requires prolonged ventilation with a high concentration of inspired oxygen. Chronic lung changes are more likely to occur in the premature infant. The incidence is approximately 60% in infants weighing less than 1000 g at birth. With the increased survival of low-birthweight infants, the prevalence of bronchopulmonary dysplasia has increased. The lung pathology of children with bronchopulmonary dysplasia shows evidence of bronchial ulceration, necrosis with plugging of bronchiolar lumina, and inflammatory cells. This bronchiolar injury compromises further lung development. Inflammatory changes and bronchiolar fibrosis lead to increased airway resistance and contribute to the hypoxemia seen in infants with bronchopulmonary dysplasia. Some children with bronchopulmonary dysplasia develop right ventricular hypertrophy (cor pulmonale). Other significant pulmonary complications include tracheal stenosis, upper airway obstruction secondary to subglottic cysts, and hoarseness because of partial or complete vocal cord paralysis. About 20% of infants with bronchopulmonary dysplasia die within the first year of life. The major causes of death are cor pulmonale, respiratory infections, and sudden death.

An increased oxygen supply must be provided to prevent hypoxic pulmonary vasoconstriction and to decrease the work of breathing. The nasal cannula provides continuous oxygen delivery, which results in fewer fluctuations in oxygen tension. Weaning the child off oxygen is possible with improved lung function and lung size. Children who develop cor pulmonale may require diuretic therapy to prevent congestive heart failure.

Dental care for children with bronchopulmonary dysplasia requires more chair time than usual. These children often spend a significant part of their early lives in the hospital and exhibit marked oral defensiveness.

After the initial dental evaluation, consultation with a pulmonologist is beneficial to plan safe dental treatment for the patient. If the dental patient is taking oxygen continuously via a nasal cannula, short appointments with frequent breaks are necessary to prevent the development of pulmonary vasoconstriction. Parents of children with bronchopulmonary dysplasia may need to provide additional oral hygiene for their children when these children are required to eat frequent small meals to maintain the proper caloric intake. Any nonemergent dental care should be avoided when the patient is not doing well medically.

## CYSTIC FIBROSIS

Cystic fibrosis (CF) is an autosomal recessive disorder occurring in 1 of every 2000 births and is the most common lethal genetic disease in Caucasians. Approximately 70,000 individuals are diagnosed with CF worldwide with about 30,000 in the United States.<sup>18</sup> About 1000 individuals are diagnosed with CF in the United States each year. Because CF is caused by an autosomal gene mutation, males and females are equally affected, although the disease incidence varies by race. The reported prevalence is of



**TABLE 26.3** Implications of Auditory Disability Relative to International Standards Organization (ISO) Reference Levels\*

ISO (DB)	Disability	Speech Comprehension	Psychological Problems in Children
0	Insignificant	Little or no difficulty	None
25	Slight	Difficulty with faint speech; language and speech development within normal limits	Child may show a slight verbal deficit.
40	Mild-moderate	Frequent difficulty with normal speech at 3 feet (91.4 cm); language skills are mildly affected	Psychological problems can be recognized.
55	Marked	Frequent difficulty with loud speech at 3 feet (91.4 cm); difficulty understanding with hearing aid in school situation	Child is likely to be educationally retarded, with more pronounced emotional and social problems than in children with normal hearing.
70	Severe	May understand only shouts or amplified speech at 1 foot (30.5 cm) from ear	The prelingually deaf show pronounced educational retardation and evident emotional and social problems.
90	Extreme	Usually no understanding of speech even when amplified; child does not rely on hearing for communication.	The prelingually deaf usually show severe intellectual disability and emotional underdevelopment.

\*Reference levels are in decibels relative to threshold in young patients with normal hearing.

Adapted from Goetzinger CP. The psychology of hearing impairment. In: Katz J, ed. *Handbook of clinical audiology*. ed 2, Baltimore, 1978, Williams & Wilkins.

1 in 7000 among Hispanics, 1 in 15,000 among African Americans, and 1 in 31,000 among Asian Americans.<sup>19</sup>

The genetically altered protein affects exocrine gland function. The defective exocrine gland function leads to micro-obstruction of the pancreas, which results in cystic degeneration of the pancreas and, ultimately, a digestive enzyme deficiency producing malabsorption of nutrients. The defective gene products cause abnormal water and electrolyte transport across epithelial cells, which results in a chronic disease of the respiratory and gastrointestinal system, elevated levels of electrolytes in sweat, and impaired reproductive function.

In the lungs, retention of mucus occurs, which causes obstructive lung disease and increased frequency of infections. As the progressive lung disease develops, there is an increase in the chest diameter, clubbing of the fingers and toes, decreased exercise tolerance, and a chronic productive cough. Before advances in antibiotic therapy, physical therapy, and nutritional supplementation, these individuals rarely survived childhood. Improvements in screening and treatments indicate that individuals with CF may live into their mid- to late 30s, on average, and some are living into their 40s and 50s. The median life expectancy has increased to 39 and 41 years for women and men, respectively. Death is most frequently the result of pneumonia and anoxia after a long period of respiratory insufficiency. CF-related diabetes is becoming more common as patients live longer.

Children with CF have a high incidence of tooth discoloration when systemic tetracyclines are taken during tooth formation. With the advent of alternative antibiotics, the incidence of tooth discoloration is decreasing. The incidence of dental caries in children with CF is low secondary to long-term antibiotic therapy, buffering capacity of excess calcium in the saliva, and pancreatic enzyme replacement therapy. There is a high incidence of mouth breathing and open-bite malocclusion associated with chronic nasal and sinus obstruction. Patients with CF may prefer to be treated in an upright position to allow them to clear secretions more easily. The use of sedative agents that interfere with pulmonary function should be avoided, and the patient's physician should be contacted before nitrous oxide-oxygen sedation is used in a patient exhibiting evidence of severe emphysema.

## Hearing Loss

Hearing loss (deafness) is a disability that is often overlooked because it is not obvious. Total hearing loss affects 1.8 million people, and there are 14 million hearing-impaired individuals in the United States. About 1 in 600 neonates has a congenital hearing loss. During the neonatal period, many more acquire hearing loss from other associated conditions. Almost inevitably, speech is affected. If an impairment is severe enough that dentist and child cannot communicate verbally, the dentist must use sight, taste, and touch to communicate and to allow the child to learn about dental experiences. Table 26.3 shows how speech and psychological problems relate to various degrees of hearing loss. Many times, mild hearing losses are not diagnosed, which leads to management problems because of the child's misunderstanding of instructions; children with more severe hearing losses already have psychological and social disturbances that make dental behavior management more complex. Parents may suspect profound hearing loss if their infant does not respond to ordinary sounds or voices. Early identification and correction of hearing loss are essential for the normal development of communication skills. No abnormal dental findings are associated with hearing loss.

The following are known causes of hearing loss:

- Prenatal factors
- Viral infections, such as rubella and influenza
- Ototoxic drugs, such as aspirin, streptomycin, neomycin, kanamycin
- Congenital syphilis
- Heredity disorders (e.g., Alport, Arnold-Chiari, Crouzon, Hunter, Klippel-Feil, Stickler, Treacher Collins, and Waardenburg syndromes)
- Perinatal factors
- Toxemia late in pregnancy
- Prematurity
- Birth injury
- Anoxia
- Erythroblastosis fetalis
- Postnatal factors
- Viral infections, such as mumps, measles, chickenpox, influenza, poliomyelitis, meningitis
- Injuries

The following should be considered in the treatment of a hearing-impaired patient:

1. During the initial appointment, determine how the patient desires to communicate (i.e., interpreter, lip reading, sign language, note writing [for child who can read], or a combination of these). Look for ways to improve communication. It is useful to learn some basic sign language. Face the patient and speak slowly at a natural pace and directly to the patient. Exaggeration of facial expressions and the use of slang make lip reading difficult. Even the best lip readers comprehend only 30%–40% of what is said.
2. Assess speech, language ability, and degree of hearing impairment when taking the patient's complete medical history. Identify the age of onset, type, degree, and cause of hearing loss, and determine whether any other family members are affected.
3. Enhance visibility for communication. Watch the patient's expression. Make sure the patient understands what the dental equipment is, what is going to happen, and how it will feel. Have the patient use hand gestures if a problem arises. If appropriate, write out and display information.
4. Reassure the patient with physical contact; hold the patient's hand initially, or place a hand reassuringly on the patient's shoulder while the patient maintains visual contact. Without visual contact, the child may be startled.
5. Use the tell-show-feel-do approach. Use visual aids and allow the patient to see the instruments, and demonstrate how they work. Hearing-impaired children may be very sensitive to vibration.
6. Display confidence; use smiles and reassuring gestures to build up confidence and reduce anxiety. Allow extra time for all appointments.
7. Avoid blocking the patient's visual field, especially with a rubber dam.
8. Adjust the hearing aid (if the patient has one) before the handpiece is in operation because a hearing aid amplifies all sounds. Many times the patient will prefer to have it turned off.
9. Make sure the parent or patient understands explanations of diagnosis, treatment, and payment. Deaf persons have different levels of skill with English. Use of an interpreter is extremely helpful.

## Visual Impairment

Total visual impairment (blindness) affects more than 30 million people. The list that follows gives some of the known causes of visual impairment; however, in more than 35% of those affected, the cause is either unknown or unreported. Blindness is not an all-or-nothing phenomenon; a person is considered to be affected by blindness if the visual acuity does not exceed 20/200 in the better eye with corrective lenses, or if the acuity is greater than 20/200 but is accompanied by a visual field of no greater than 20 degrees.

The following are known causes of visual impairment:

- Prenatal causes
- Optic atrophy
- Microphthalmos

- Cataracts
- Colobomas
- Dermoid and other tumors
- Toxoplasmosis
- Cytomegalic inclusion disease
- Syphilis
- Rubella
- Tuberculous meningitis
- Developmental abnormalities of the orbit
- Postnatal causes
- Trauma
- Retrorenal fibroplasia
- Hypertension
- Premature birth
- Polycythemia vera
- Hemorrhagic disorders
- Leukemia
- Diabetes mellitus
- Glaucoma

Visual impairment may be only one aspect of a child's disability. For example, a patient with congenital rubella may have deafness, intellectual limitations, congenital heart disease, and dental defects, as well as blindness resulting from congenital cataracts. Total visual impairment is one disorder that may result in frequent hospitalizations, separation from family, and slow social development. Because the capabilities of a child with blindness are difficult to assess, the child may be considered developmentally delayed.

Consideration must be given to every developmental aspect of a child with blindness. Early in development, the parents may experience guilt and either overprotect or reject the child; this can result in a lack of development of self-help skills and delayed development in general, which is often misinterpreted as intellectual disability. Assessment of parental attitudes is of primary importance in behavioral management. In addition, children with blindness may exhibit self-stimulating activities, such as eye pressing, finger flicking, rocking, and head banging. Therefore assessment of the child's socialization is useful in the management of dental behavior.

A distinction should be made between children who at one time had sight and those who have not and thus cannot form visual concepts. More explanation is needed for children in the latter category to help them discern the dental environment. Although explanation is accomplished through touching and hearing, reinforcement takes place through smelling and tasting. The modalities of listening, touching, tasting, and smelling are extremely important in helping these children learn coping behavior. Reports indicate that, once speech is developed, the other senses assume heightened importance and other development can occur that is comparable with that in children with sight.

Reports also reveal that motor activity affects the development of language and perception. Visually impaired children tend to have more accidents than other children during the early years while they are acquiring motor skills.

Hypoplastic teeth and trauma to the anterior teeth have been reported to occur with greater frequency in visually

impaired children. Such children are also more likely to have gingival inflammation because of their inability to see and remove plaque. Other dental abnormalities occur with the same frequency as in the general population.

Before initiating dental treatment for a visually impaired child, the dentist should keep the following points in mind:

1. Determine the degree of visual impairment.
2. If the patient is accompanied by a companion, find out if the companion is an interpreter. If he or she is not, address the patient.
3. Establish rapport; afterward offer verbal and physical reassurance.
4. In guiding the patient to the operatory, ask if the patient desires assistance. Do not grab, move, or stop the patient without verbal warning. Encourage the parent to accompany the child.
5. Paint a picture in the mind of the visually impaired child by describing the office setting and treatment. Give the patient adequate descriptions before performing treatment procedures and use the same office setting when possible for every dental visit.
6. Introduce other office personnel.
7. When making physical contact, holding the patient's hand often promotes relaxation.
8. Allow the patient to ask questions during the course of treatment, keeping in mind that the patient is highly individual, sensitive, and responsive.
9. Rather than using the tell-show-do approach, invite the patient to touch, taste, or smell, recognizing that these senses are acute.
10. Describe in detail the instruments and objects to be placed in the patient's mouth.
11. The patient may have a heightened sensitivity to taste and require introducing smaller quantities initially to gain acceptance.
12. Some patients may be photophobic and need to wear sunglasses.
13. Explain the procedures of oral hygiene and then place the patient's hand over yours as you slowly guide the toothbrush. Use of Braille dental pamphlets and available technology, including cell phone, tablets, and magnifying screens for example can help explain specific dental procedures to supplement information and decrease chair time.
14. Keep distractions to a minimum, and avoid unexpected loud noises.
15. Limit providers of the patient's dental care to one dentist whenever possible.

The provision of dental care to a visually impaired child is facilitated by an in-depth understanding of the patient's background. A team approach by all health professionals involved in the care of the child is optimal.

## Heart Disease

Heart disease can be divided into two general types: congenital and acquired. Individuals with heart disease may require special precautions during dental treatment, such as antibiotic coverage for prevention of infective endocarditis (IE); a dentist should closely evaluate the medical

histories of all patients to ascertain their cardiovascular status. In April 2007, the American Heart Association (AHA) presented recommendations to conserve the use of antibiotics for the prevention of IE to minimize the risk of developing resistance to current regimens.<sup>20</sup>

## CONGENITAL HEART DISEASE

The incidence of congenital heart disease is approximately 8 in 1000 births.<sup>21</sup> The following is the relative incidence of congenital heart defects (Toronto Heart Registry):

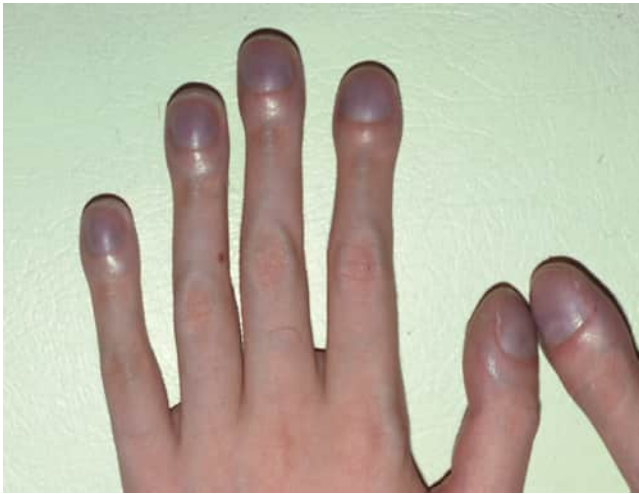Defect	Percent
Ventricular septal defect	22
Patent ductus arteriosus	17
Tetralogy of Fallot	11
Transposition of the great vessels	8
Atrial septal defect	7
Pulmonary stenosis	7
Coarctation of the aorta	6
Aortic stenosis	5
Tricuspid atresia	3
All others	14

The cause of a congenital heart defect is obscure. Generally, it is a result of aberrant embryonic development of a normal structure or the failure of a structure to progress beyond an early stage of embryonic development. Only rarely can a causal factor be identified in congenital heart disease. Maternal rubella and chronic maternal alcohol abuse are known to interfere with normal cardiogenesis. If a parent or a sibling has a congenital heart defect, the chances that a child will be born with a heart defect are about 5–10 times greater than average. Congenital heart disease can be classified into two groups—acyanotic and cyanotic.

Common Risk Factors for Congenital Heart Disease.<sup>22</sup>

Risk Factor	Absolute Risk, percent of live births
Pregestational diabetes	3–5
Gestational diabetes (hemoglobin A <sub>1c</sub> < 6%)	<1
Phenylketonuria 10–12 (preconception metabolic control may affect risk)	12–14
Vitamin K antagonists	<1
Lupus or Sjögren syndrome only if SSA/SSB autoantibody positive	1–5
Lithium	<2
Use of assisted reproduction technology	1.1–3.3
Maternal structural cardiac disease	3–7
Paternal structural cardiac disease	2–3
Sibling with structural cardiac disease	3
	8 for hypoplastic left heart syndrome





**Fig. 26.12** The hand of a 9-year-old boy with tetralogy of Fallot. Clubbing of the terminal phalanges is apparent.

### Acyanotic Congenital Heart Disease

Acyanotic congenital heart disease is characterized by minimal or no cyanosis and is commonly divided into two major groups. The first group consists of defects that cause left-to-right shunting of blood within the heart. This group includes ventricular septal defect and atrial septal defect. Clinical manifestations of these defects can include congestive heart failure, pulmonary congestion, heart murmur, labored breathing, and cardiomegaly.

The second major group consists of defects that cause obstruction (e.g., aortic stenosis and coarctation of the aorta). The clinical manifestations can include labored breathing and congestive heart failure.

### Cyanotic Congenital Heart Disease

Cyanotic congenital heart disease is characterized by right-to-left shunting of blood within the heart. Cyanosis is often observed even during minor exertion. Examples of such defects are tetralogy of Fallot, transposition of the great vessels, pulmonary stenosis, and tricuspid atresia. Clinical manifestations can include cyanosis, hypoxic spells, poor physical development, heart murmurs, and clubbing of the terminal phalanges of the fingers (Fig. 26.12).

## ACQUIRED HEART DISEASE

### Rheumatic Fever

Rheumatic fever is a serious inflammatory disease that occurs as a delayed sequela to pharyngitis caused by group A streptococcus (GAS). Most children affected by GAS pharyngitis are 5–15 years of age.<sup>23</sup> Rheumatic fever is a commonly diagnosed cause of acquired heart disease in patients under 40 years of age. The mechanism by which GAS strains initiate the disease is unknown. The infection can involve the heart, joints, skin, central nervous system, and subcutaneous tissue. In general, the incidence of rheumatic fever is decreasing. However, the incidence after exudative pharyngitis in epidemics is approximately 3%. (The incidence is much lower when the streptococcal pharyngitis is less severe.)

Although rheumatic fever can occur at any age, it is rare in infancy. It appears most commonly in children between

the ages of 6 and 15 years. Rheumatic fever is most prevalent in temperate zones and at high altitudes and is more common and severe in children who live in substandard conditions. The clinical symptoms of rheumatic fever vary.

Cardiac involvement is the most significant pathologic sequela of rheumatic fever; carditis develops in approximately 50% of patients. Cardiac involvement can be fatal during the acute phase or can lead to chronic rheumatic heart disease as a result of scarring and deformity of heart valves.

### Infective Endocarditis

Infective endocarditis (IE) is one of the most serious infections of humans. It is characterized by microbial infection of the heart valves or endocardium in proximity to congenital or acquired cardiac defects. IE has been classically divided into acute and subacute forms. The acute form is a fulminating disease that usually occurs when microorganisms of high pathogenicity attack a normal heart, causing erosive destruction of the valves. Microorganisms associated with the acute form include *Staphylococcus*, group A *Streptococcus*, and *Pneumococcus*. In contrast, subacute IE usually develops in persons with preexisting congenital cardiac disease or rheumatic valvular lesions. Surgical placement of prosthetic heart valves can also predispose a patient to IE; heart valve infections occur in 1%–2% of such patients. The subacute form is commonly caused by viridans streptococci, microorganisms common to the flora of the oral cavity.

Embolization is a characteristic feature of IE. Microorganisms introduced into the bloodstream may colonize the endocardium at or near congenital valvular defects, valves damaged by rheumatic fever, or prosthetic heart valves. These vegetations, composed of microorganisms and fibrous exudate, may separate and, depending on whether the endocarditis involves the left or right side of the heart, be propelled into the systemic or pulmonary circulation.

The clinical symptoms of IE include low, irregular fever (afternoon or evening peaks) with sweating, malaise, anorexia, weight loss, and arthralgia. Inflammation of the endocardium increases cardiac destruction, and murmurs subsequently develop. Painful fingers and toes and skin lesions are also important symptoms. Laboratory findings can include leukocytosis and neutrophilia and normocytic normochromic anemia. The erythrocyte sedimentation rate is elevated.

### Infective Endocarditis Prophylaxis

Transient bacteremia is an important initiating factor in IE. Procedures known to precipitate transient bacteremias in dentistry and for which IE prophylaxis is or is not recommended are included in Box 26.1.

Certain heart conditions are associated with the highest risk of adverse outcomes from IE (Box 26.2). Any dental patient who has a history of congenital heart disease or rheumatic heart disease or who has a prosthetic heart valve should be considered susceptible. The AHA's antibiotic recommendations for the prevention of bacterial endocarditis are presented in Box 26.3.

The recent AHA revision concluded that only a small number of cases of IE might be prevented by antibiotic prophylaxis for dental procedures, even if such prophylactic therapy were 100% effective. IE prophylaxis for invasive dental procedures involving the manipulation of

### Box 26.1 Dental procedures for which endocarditis prophylaxis is reasonable for highest-risk patients

All dental procedures that involve manipulation of the gingival tissue or the periapical region of teeth or perforation of the oral mucosa<sup>1</sup>

<sup>1</sup>PRN prophylaxis: routine anesthetic injections through noninfected tissue, taking dental radiographs, placement of removable prosthodontic or orthodontic appliances, adjustment of orthodontic appliances, placement of orthodontic brackets, shedding of deciduous teeth, and bleeding from trauma to the lips or oral mucosa.

Reprinted with permission: *Circulation*. 2007;116:1736-1754. ©2007 American Heart Association, Inc.

### Box 26.2 Cardiac conditions associated with the highest risk of adverse outcome from endocarditis for which prophylaxis with dental procedures is reasonable<sup>1</sup>

Prosthetic cardiac valve or prosthetic material used for cardiac valve repair

Previous infective endocarditis

Congenital heart disease (CHD)<sup>2</sup>

Unrepaired cyanotic CHD, including palliative shunts and conduits

Completely repaired congenital heart defect with prosthetic material or device, whether placed by surgery or by catheter intervention, during the first 6 months after the procedure<sup>3</sup>

Repaired CHD with residual defects at the site or adjacent to the site of prosthetic patch or prosthetic device (which inhibits endothelialization)

Cardiac transplantation recipients who develop cardiac valvulopathy

<sup>1</sup>PRN prophylaxis: routine anesthetic injections through noninfected tissue, taking dental radiographs, placement of removable prosthodontic or orthodontic appliances, adjustment of orthodontic appliances, placement of orthodontic brackets, shedding of deciduous teeth, and bleeding from trauma to the lips or oral mucosa.

<sup>2</sup>Except for the conditions listed above, antibiotic prophylaxis is no longer recommended for any other form of CHD.

<sup>3</sup>Prophylaxis is reasonable because endothelialization of prosthetic material occurs within 6 months after the procedure.

Reprinted with permission: *Circulation*. 2007;116:1736-1754. ©2007 American Heart Association, Inc.

gingival tissue or the periapical region of teeth or perforation of the oral mucosa is only for patients with the highest risk of adverse outcome (Box 26.2). Prophylaxis is not recommended.<sup>20</sup>

## DENTAL MANAGEMENT

Parents of patients with cardiac risks typically lack knowledge about IE even after being informed during routine cardiology visits. Hayes and Fasules<sup>24</sup> report a deficiency of knowledge among dentists regarding the indications for prophylaxis and the antibiotic regimen required to prevent IE. Before initiating care, the dentist should obtain a thorough medical and dental history, perform a physical examination, formulate a complete treatment plan, and discuss the treatment with the child's physician or cardiologist. Behavior management techniques are useful, and conscious sedation and nitrous oxide-oxygen analgesia have

### Box 26.3 Regimens for a dental procedure

SITUATION	AGENT	REGIMEN: SINGLE DOSE 30–60 MINUTES BEFORE PROCEDURE	
		ADULTS	CHILDREN
Oral	Amoxicillin	2 g	50 mg/kg
Unable to take oral medication	Ampicillin	2 g IM or IV	50 mg/kg IM or IV
	or Cefazolin or ceftriaxone	1 g IM or IV	50 mg/kg IM or IV
Allergic to penicillins or ampicillin—oral	Cephalexin <sup>a,b</sup>	2 g	50 mg/kg
	or	600 mg	20 mg/kg
	Clindamycin	500 mg	15 mg/kg
	or Azithromycin or clarithromycin		
Allergic to penicillin or ampicillin and unable to take oral medication	Cefazolin or ceftriaxone <sup>b</sup>	1 g IM or IV	50 mg/kg IM or IV
	or Clindamycin	600 mg IM or IV	20 mg/kg IM or IV

IM, Intramuscular; IV, intravenous.

<sup>a</sup>Or other first- or second-generation oral cephalosporin in equivalent adult or pediatric dosage.

<sup>b</sup>Cephalosporins should not be used in an individual with a history of anaphylaxis, angioedema, or urticaria with penicillins or ampicillin

also been proven beneficial in reducing anxiety in such patients. Conscious sedation monitoring and cardiopulmonary resuscitation equipment should be readily available during the appointment. If general anesthesia is indicated, the dental procedures should be completed in a hospital setting, where adequate supportive care is available if needed.

Following other considerations are especially important in treating patients who are susceptible to IE:

- Pulp therapy is not recommended for primary teeth with a poor prognosis because of the high incidence of associated chronic infection. Extraction of such teeth with appropriate fixed-space maintenance is preferred.
- Endodontic therapy in the permanent dentition can usually be accomplished successfully if the teeth to be treated are carefully selected and the endodontic therapy is adequately performed.
- A dentist who feels uncomfortable in treating patients who are susceptible to IE has a responsibility to refer them to someone who will adequately care for them.

## CARDIAC SURGERY PATIENTS

Patients who are to undergo cardiac surgery should first have a careful dental evaluation done so that oral infections can be properly diagnosed and treated. This practice, along with an implemented preventive dental program, will decrease the incidence of postoperative IE from oral sources, improve surgical outcomes, and improve the patient's overall health.<sup>25</sup>

After dental radiographs are obtained and an evaluation is performed, a consultation with the patient's cardiologist must be made to plan the required dental treatment before surgery. The cardiologist will indicate the specific desired

antibiotic prophylaxis needed before the dental treatment. The dental examination and preventive dental program should be implemented before the child reaches 6 months of age when possible. Ideally, dental treatment should be completed within 3 or 4 weeks of the planned surgery to allow for healing and the return of normal flora.

## References

1. US Department of Health and Human Services. Delivering on the promise: self-evaluation to promote community living for people with disabilities: report to the President on Executive Order 13217. US Department of Health and Human Services: Washington, DC, [www.hhs.gov/newfreedom/final/hhs.html](http://www.hhs.gov/newfreedom/final/hhs.html). Accessed March 19, 2014.
2. American Academy of Pediatric Dentistry: Guideline on management of dental patients with special health care needs, *Pediatr Dent* 40(6):237–242, 2018-2019.
3. US Department of Health and Human Services. Oral health in America: a report of the Surgeon General, Rockville, MD: US Dept of Health and Human Services, National Institute of Dental and Craniofacial Research. National Institutes of Health: Bethesda.
4. Kane D, Mosca N, Zotti M, et al.: Factors associated with access to dental care for children with special health care needs, *J Am Dent Assoc* 139(3):326–333, 2008.
5. Chen AY, Newacheck PW: Insurance coverage and financial burden for families of children with special health care needs, *Ambul Pediatr* 6(4):204–209, 2006.
6. National survey of children with special health care needs: NS-CSHCN 2009.10. Data query from the Child and Adolescent Health Measurement Initiative, Data Resource Center for Child and Adolescent Health website. Retrieved [03/19/2014] from [www.childhealthdata.org](http://www.childhealthdata.org).
7. Uniform Federal Accessibility Standards, part II, *Fed Reg* 153(49):31528–31613, 1984.
8. US Department of Health and Human Services: Health Insurance Portability and Accountability Act (HIPAA). Available at: <http://aspe.hhs.gov/admsimp/pl104191.htm>. Accessed Feb. 17, 2009.
9. Van Cleave J, Davis MM: Preventive care utilization among children with and without special health care needs: associations with unmet need, *Ambul Pediatr* 8(5):305–311, 2008.
10. Moursi AM, Fernandez JB, Daronch M, et al.: Nutrition and oral health considerations in children with special health care needs: implication for oral health care providers, *Pediatr Dent* 32(4):333–342, 2010.
11. Beltrán-Aguilar ED, Goldstein JW, Lockwood SA: Fluoride varnishes: a review of their clinical use, cariostatic mechanisms, efficacy, and safety, *J Am Dent Assoc* 131(5):589–596, 2000.
12. American Academy of Pediatric Dentistry: Behavior guidance for the pediatric dental patient, *Pediatr Dent* 40(6):254–267, 2018-2019.
13. Schalock RL, Luckasson RA, Shogren KA, et al.: The renaming of mental retardation: understanding the change to the term intellectual disability, *Intellect Dev Disabil* 45(2):116–124, 2007.
14. Murakami J, Kato T, Kawai S, et al.: Cellular mobility of Down syndrome gingival fibroblasts is susceptible to impairment by *Porphyromonas gingivalis* invasion, *J Periodontol* 79(4):721–727, 2008.
15. Bell EJ, Kaidonis J, Townsend GC: Tooth wear in children with Down syndrome, *Aust Dent J* 47(1):30–35, 2002.
16. Cheng RH, Leung WK, Corbet EF: Non-surgical periodontal therapy chlorhexidine use in adults with Down syndrome, *J Periodontol* 79(2):379–385, 2008.
17. Nettis E, Colanardi MC, Ferrannini A, et al.: Reported latex allergy in dental patients, *Oral Surg Oral Med Oral Pathol Oral Radiol Endod* 93(2):144–148, 2002.
18. LiPuma JJ: The changing microbial epidemiology in cystic fibrosis, *Clin Microbiol Rev* 23(2):299–323, 2010.
19. Cystic Fibrosis Foundation. Patient Registry Annual Data Report 2017. Available at: <https://www.cff.org/Research/Researcher-Resources/Patient-Registry/2017-Patient-Registry-Annual-Data-Report.pdf>. Accessed August 15, 2019.
20. Wilson W, Taubert KA, Gewitz M, et al.: Prevention of infective endocarditis: guidelines from American Heart Association, *Circulation* 116(15):1736–1754, 2007.
21. Bernier PL, Stefanescu A, Samoukovic G, et al.: The challenge of congenital heart disease worldwide: epidemiologic and demographic facts, *Semin Thorac Cardiovasc Surg Pediatr Card Surg Annu* 13(1):26–34, 2010.
22. Data from Donofrio MT, Moon-Grady AJ, Hornberger LK, et al.: Diagnosis and treatment of fetal heart disease: a scientific statement from the American Heart Association, *Circulation* 129(21):2183–2242, 2014.
23. Garcia RU, Peddy SB: Heart disease in children, *Prim Care* 45(1):143–154, 2018.
24. Hayes PA, Fasules J: Dental screening of pediatric cardiac surgical patients, *J Dent Child* 68(4):255–258, 2001.
25. Yasney JS, White J: Dental considerations for cardiac surgery, *J Cardiac Surg* 24(1):64–68, 2009.

## Suggested Readings

- Abman SH, Mourani PM, Sontag M: Bronchopulmonary dysplasia: a genetic disease, *Pediatrics* 122(3):658–659, 2008.
- Aps JK, Van Maele GO, Martens LC: Oral hygiene habits and oral health in cystic fibrosis, *Eur J Paediatr Dent* 3(4):181–187, 2002.
- Barnett ML, Press KP, Friedman D, et al.: The prevalence of periodontitis and dental caries in the Down syndrome population, *J Periodontol* 57(5):288–293, 1986.
- Clark CA, Cangelosi-Williams PA, Lee MA, et al.: Dental treatment for deaf patients, *Spec Care Dentist* 6(3):102–106, 1986.
- Goetzinger CP: The psychology of hearing impairment. In Katz J, editor: *Handbook of clinical audiology*, ed 2, Baltimore, 1978, Williams & Wilkins.
- Hagerman RJ, Jackson C, Amiri K, et al.: Girls with fragile X syndrome: physical and neurocognitive status and outcome, *Pediatrics* 89(3):395–400, 1992.
- Hennequin M, Faulks D, Roux D: Accuracy of estimation of dental treatment need in special care patients, *J Dent* 28(2):131–136, 2000.
- Hudson ME: Dental surgery in pediatric patients with spina bifida and latex allergy, *AORN J* 74(1):56–78, 2001.
- Itthagaran A, Nair RG, Epstein JB, et al.: Fetal alcohol syndrome: case report and review of the literature, *Oral Surg Oral Med Oral Pathol Oral Radiol Endod* 103(3):e20–e25, 2007.
- Jaber MA: Dental caries experience, oral health status and treatment needs of dental patients with autism, *J Appl Oral Sci* 19(3):212–217, 2011.
- Kliegman RM, Behrman RE, Jenson HB, Stanton B: Nelson textbook of pediatrics, ed 18, Philadelphia: WB Saunders, 2007.
- Learning Disabilities Foundation of America: <http://ldafdn.org>.
- Newschaffer CJ, Croen LA, Daniels J, et al.: The epidemiology of autism spectrum disorders, *Annu Rev Public Health* 28:235–258, 2007.
- Pope JE, Curzon ME: The dental status of cerebral palsied children, *Pediatr Dent* 13(3):156–162, 1991.
- Sant'Anna LB, Tosello DO: Fetal alcohol syndrome and developing craniofacial and dental structures: a review, *Orthod Craniofac Res* 9(4):172–185, 2006.
- Shellhart WC, Casamassimo PS, Hagerman RJ, et al.: Oral findings in fragile X syndrome, *Am J Med Genet* 23(1-2):179–187, 1986.
- Simko A, Hornstein L, Soukup S, et al.: Fragile X: recognition in young children, *Pediatrics* 83(4):547–551, 1989.
- Steinbacher DM, Glick M: The dental patient with asthma: an update and oral health consideration, *J Am Dent Assoc* 132(9):1229–1239, 2001.
- Stensson M, Wendt LK, Koch G, et al.: Oral health in preschool children with asthma, *Int J Paediatr Dent* 18(4):243–250, 2008.
- Terzian EC, Schneider RE: Management of the patient with cystic fibrosis in oral and maxillofacial surgery, *J Oral Maxillofac Surg* 66(2):349–354, 2008.
- Waldman HB, Swerdloff M, Perlman SP: Children with mental retardation and epilepsy: demographics and general concerns, *J Dent Child* 67(4), 2000. 274–268.
- Wandera A, Conry JP: Aspiration and ingestion of a foreign body during dental examination by a patient with spastic quadriplegia: case report, *Pediatr Dent* 15(5):362–363, 1993.
- Zhu JF, Hidalgo HA, Holmgren WC, et al.: Dental management of children with asthma, *Pediatr Dent* 18:363–370, 1996.



## 27

# Management of the Medically Compromised Patient

BRIAN J. SANDERS, AMY D. SHAPIRO, J. CHARLES NAKAR, KERRY HEGE, and JOHN J. MANALLOOR

## HEMATOLOGIC DISORDERS, CANCER, HEPATITIS, AND AIDS

### CHAPTER OUTLINE

#### **Congenital Bleeding Disorders**

Introduction  
 Von Willebrand Disease  
 Hemophilia  
 Complications of Bleeding Disorders  
 Women With Bleeding Disorders  
 Other Rare Congenital Bleeding Disorders  
 Dental Care for Patients With Bleeding Disorders  
 Pain Control  
 Local Anesthesia  
 Risks to Dental Staff  
 Summary

#### **Sickle Cell Disease**

Background  
 Dental Management  
**Childhood Cancers**  
 Leukemia  
 Solid Tumors  
 Management of Childhood Cancer Survivors  
**Viral Hepatitis**  
**Acquired Immunodeficiency Syndrome**  
 Oral Manifestations of HIV Infection  
 Severe Acute Respiratory Syndrome  
 Coronavirus 2 (Sars-Cov-2) and COVID-19

## Congenital Bleeding Disorders

### INTRODUCTION

Hemostasis involves a large number of complex and finely balanced processes including vasoconstriction, primary and secondary hemostasis, and fibrinolysis. In response to vascular injury, vasoconstriction reduces blood flow at the site of injury to limit initial bleeding prior to clot formation. The processes involved in the formation of the initial platelet plug (primary hemostasis) include the interactions between collagen in the extracellular matrix, von Willebrand factor (VWF), platelets, and fibrinogen.<sup>1</sup> The initial platelet plug is then stabilized by the formation of cross-linked fibrin (secondary hemostasis) to form an insoluble fibrin clot.<sup>2</sup> This fibrin clot is subsequently broken down by the fibrinolytic system (fibrinolysis) primarily by the conversion of the zymogen plasminogen to plasmin.<sup>2</sup>

In patients with coagulation disorders, these processes may be impaired, resulting in a variety of symptoms. The pattern of symptoms and the time of onset can serve as a clue in distinguishing between disorders of primary and secondary hemostasis, and fibrinolysis; for example, impaired formation of the primary platelet plug can result in early bleeding from the skin and mucosa, bruising, epistaxis, prolonged bleeding after surgical procedures, and heavy

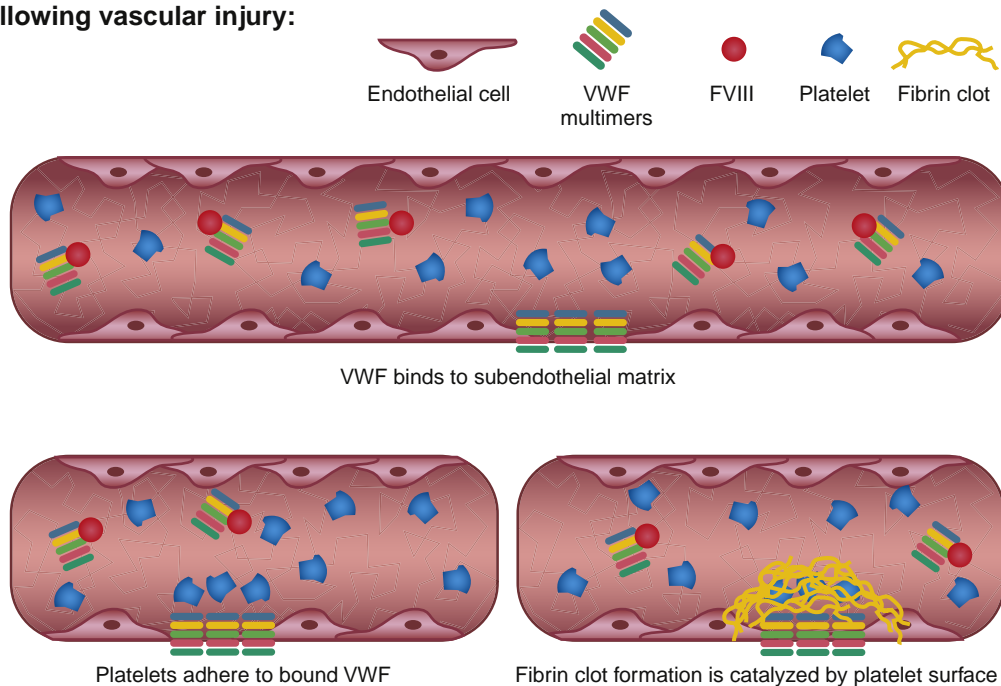
menstrual bleeding (Fig. 27.1). In contrast, common symptoms of disorders of secondary hemostasis (which involve coagulation factor deficiencies such as hemophilia) include bleeding into the muscles and joints (Fig. 27.2). Defects in fibrinolysis commonly result in delayed bleeding after trauma, surgery, and dental procedures or in areas with high fibrinolytic activity, including menstrual bleeding and epistaxis.<sup>3–5</sup>

Inherited defects in hemostasis may have a significant impact on patient's health and quality of life. This chapter introduces two genetic bleeding disorders, von Willebrand disease and hemophilia, as examples of defects in primary and secondary hemostasis, respectively. It then discusses the impact of bleeding disorders on routine dental care and oral surgery, and techniques to avoid complications of bleeding.

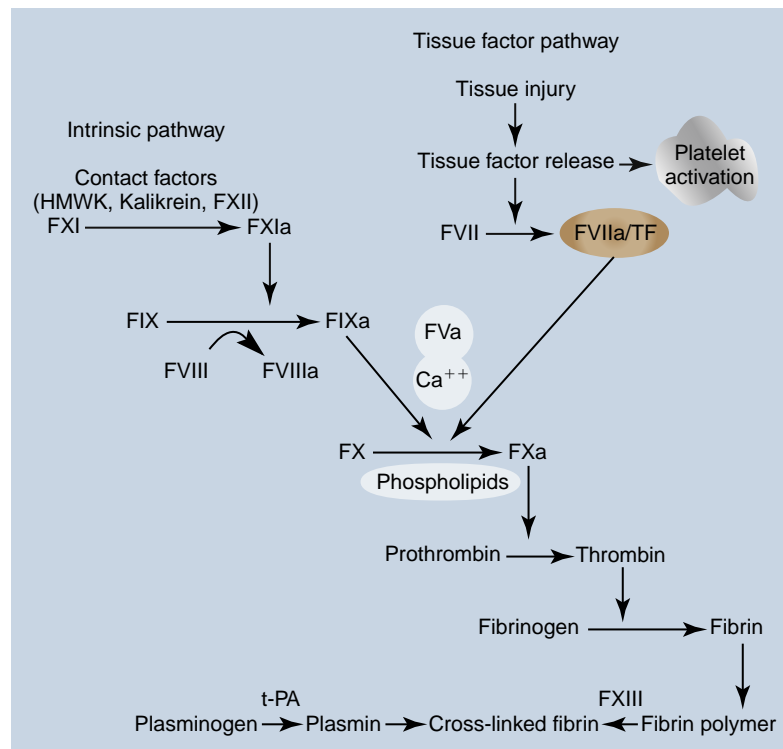
### VON WILLEBRAND DISEASE

Von Willebrand disease (VWD) is the most common hereditary bleeding disorder; the estimated prevalence of symptomatic individuals is 0.1%.<sup>6</sup> VWD results from an abnormality in VWF, a protein found in plasma, platelets, megakaryocytes, and endothelial cells; it is composed of units (multimers) that vary in size from dimers to large polymers. VWF binds to exposed collagen at the site of

## Following vascular injury:



**Fig. 27.1** Primary hemostatic response to vascular injury with evolution into secondary hemostasis. This figure shows the primary hemostatic response to vascular injury involving the endothelial cell and platelet; primary hemostasis leads to and is an integral part of secondary hemostasis involving coagulation factors, including von Willebrand factor (VWF) and factor VIII (FVIII), culminating in the generation of fibrin. (With permission from CSL Behring and Robert Montgomery.)



**Fig. 27.2** Coagulation cascade. This figure shows the complex interplay between plasma coagulation factors and fibrinolytic pathway (plasminogen and end enzyme plasmin) responsible for clot lysis after healing. The importance of the role of the tissue factor pathway and cellular systems (platelets) in initiating physiologic hemostasis is highlighted. The factors deficient in hemophilia A and B (factors VIII and IX, respectively) are shown in relationship to their role in the coagulation pathway. (Courtesy Anjali Sharathkumar.)

**TABLE 27.1** Classification of von Willebrand Disease

Type	Description
1	Partial quantitative deficiency of VWF
2	Qualitative VWF defects
2A	Decreased VWF-dependent platelet adhesion and a selective deficiency of high-molecular-weight VWF multimers
2B	Increased affinity for platelet glycoprotein Ib
2M	Decreased VWF-dependent platelet adhesion without a selective deficiency of high-molecular-weight VWF multimers
2N	Markedly decreased binding affinity for factor VIII
3	Virtually complete deficiency of VWF

VWF, von Willebrand factor.  
Adopted from Sadler et al.<sup>8</sup>

injury, which in turn enhances platelet adhesion at the sub-endothelium and drives the formation of the primary platelet plug. Moreover, VWF and factor VIII circulate in plasma as a noncovalent, tightly bound complex; this complex protects factor VIII from proteolytic degradation in plasma, thereby prolonging its half-life.

### Genetics and Epidemiology

Type 1 and 2 VWD are commonly inherited in an autosomal dominant trait, whereas type 3 VWD is an autosomal recessive disorder. As such, women and men are equally affected; however, women may experience additional complications due to gynecological and obstetric concerns.<sup>7</sup>

### Classification

The cause of VWD is attributed to a quantitative or qualitative defect in VWF. VWD is classified into three main subtypes<sup>7,8</sup> (Table 27.1) and requires a panel of tests for accurate diagnosis.<sup>9</sup> Type 1 VWD, characterized by a partial quantitative deficiency primarily due to abnormal protein synthesis, is the most common (~85%). Clinically, type 1 VWD is considered a mild bleeding disorder; however, severity can range from mild to severe with a severe phenotype observed in a minority of patients due to increased clearance (i.e., VWD 1C) or decreased secretion. Type 2 VWD, characterized by qualitative deficiency, may present with a moderate to severe clinical bleeding phenotype. Type 3 VWD, characterized by total deficiency, may present with a severe bleeding phenotype.<sup>10</sup> Optimal treatment for VWD is dependent upon the subtype.<sup>7,11–13</sup>

### Bleeding Symptoms

Bleeding symptoms in patients with VWD are commonly mucocutaneous in nature and include easy bruising, epistaxis, oral cavity bleeding, heavy menstrual bleeding, postpartum bleeding, and bleeding after dental extraction or other procedures. In patients with more severe phenotypes, symptoms may resemble bleeding seen in severe hemophilia (i.e., deep tissue bleeding such as hemarthrosis). As most affected patients have a mild form of VWD, many remain asymptomatic unless hemostatically challenged, such as during surgery or childbirth. Young patients, regardless of phenotype severity, may also present with a negative bleeding history due to the lack of hemostatic challenge.<sup>7,14</sup>

Oral cavity bleeding can vary based on the severity of VWD; patients with a more severe bleeding phenotype may

experience oral bleeding similar to that observed in patients with hemophilia (see the hemophilia section for more details).

### Treatment

Determination of the specific VWD subtype in a patient is essential to provide an optimal therapeutic intervention. DDAVP (desmopressin acetate; Ferring Pharmaceuticals Inc., Parsippany, NJ, USA) may be administered to achieve hemostasis in most patients with type 1 VWD. Desmopressin acetate is a synthetic analog of the natural pituitary hormone 8-arginine vasopressin (antidiuretic hormone) that affects renal water conservation. This drug, when administered intravenously, subcutaneously, or intranasally (Stimate; CSL Behring LLC, King of Prussia, PA, USA) releases stored VWF from endothelial cells (Weibel-Palade bodies) resulting in an increase in the factor VIII and VWF activity. Peak factor VIII and VWF levels are obtained approximately 1 hour after intravenous or subcutaneous administration and 90 minutes following intranasal administration. The low-dose DDAVP intranasal spray used to treat diabetes insipidus or enuresis is ineffective to treat bleeding associated with VWD; a prescription should be written for the brand name product (Stimate) or with the stated concentration of 1.5 mg/mL desmopressin acetate.

Repeated administration of desmopressin acetate may result in tachyphylaxis, a reduction in expected response with sequential dosing due to depletion of storage sites. Use of desmopressin acetate to treat hemorrhagic disorders may also be associated with water retention, hyponatremia, and rarely seizures; therefore, monitoring of electrolytes may be required, especially in surgical situations.<sup>15,16</sup>

When desmopressin acetate is first used subcutaneously or intranasally, a test dose should be administered under medical supervision to document adequate hemostatic response. If the test dose is tolerated by the patient and an adequate hemostatic response is documented (i.e., factor levels peak within or above the normal range), desmopressin acetate may be utilized in different clinical settings: subcutaneous injections should be administered only with medical supervision; however, patients may administer the intranasal preparation, Stimate, at home. The Stimate dose is based on weight: 1 puff for patients weighing 20 kg to <50 kg; 2 puffs for patients >50 kg; each puff delivers 0.1 mL of solution (150 mcg). A subsequent administration of Stimate after 24 hours is usually not recommended and requires the approval of patient's hematology provider and close clinical and laboratory monitoring. Prior to initial use, the 2.5-mL spray pump bottle should be primed to ensure correct drug delivery.

Other therapeutic modalities may be required (including replacement therapy using a VWF concentrate) in patients with less common VWD subtypes, those who do not respond to DDAVP, patients for whom DDAVP is contraindicated, and in bleeding episodes where DDAVP is contraindicated. Interventions and therapeutic approaches should be discussed with an experienced hematologist at a hemophilia treatment center (HTC).<sup>11,12,17,18</sup> Several plasma-derived VWF concentrates are commercially available (Table 27.2), and a single recombinant VWF concentrate (Vonvendi; Baxalta US Inc., Lexington, MA, USA) was approved for use in adults with VWD in 2015.<sup>19</sup> Clinical trials examining Vonvendi in pediatric patients are ongoing.



**TABLE 27.2** Systemic Hemostatic Therapies in von Willebrand Disease

Products	Administration Route	VWF:Factor VIII Ratio	Indications
Antifibrinolytic* □ ε-aminocaproic acid □ Tranexamic acid	IV, PO IV, PO		<ul style="list-style-type: none"> <li>□ Minor bleeding</li> <li>□ Adjunctive hemostatic therapy for prevention of surgical bleeding in VWD</li> <li>□ Hemostatic agent for prevention of surgical bleeding in very mild type 1 VWD</li> </ul>
Desmopressin acetate □ DDAVP® □ Stimate®*	SQ, IV Intranasal		<ul style="list-style-type: none"> <li>□ Minor bleeding</li> <li>□ Hemostatic agent for prevention of surgical bleeding in type 1 VWD (not including severe type 1 VWD)</li> <li>□ Can be used in type 2 VWD based on subtype and documented hemostatic response</li> </ul>
VWF Concentrates □ Plasma-derived (examples) ■ Alphanate® ■ Humate-P® ■ Wilate® □ Recombinant ■ Vonvendi®	IV	1.3:1 2:1 1:1  VWF only	<ul style="list-style-type: none"> <li>□ For all types of VWD</li> <li>□ Where inadequate response to desmopressin demonstrated/expected</li> <li>□ Where desmopressin is contraindicated due to an underlying condition, side effects, fluid restriction not possible, or other risks for hyponatremia</li> <li>□ Long periods of hemostatic VWF levels are required (e.g., major surgery)</li> </ul>

IV, Intravenous; PO, oral; SQ, subcutaneous; VWD, von Willebrand disease; VWF, von Willebrand factor.

\*Instructions for the use and recommended dosing regimen are described in the text.

## HEMOPHILIA

Hemophilia is a disorder of secondary hemostasis that results from a deficiency or dysfunction of the clotting factors, factor VIII (also known as antihemophilic factor) or factor IX (also known as plasma thromboplastin component). Factor VIII deficiency is known as hemophilia A or classic hemophilia. Factor IX deficiency is known as hemophilia B or Christmas disease.

### Genetics

Hemophilia is an inherited bleeding disorder that affects approximately 1 in 5000 males.<sup>20</sup> Hemophilia A is the most common form of hemophilia and is inherited as an X-linked recessive trait in which males are affected, females are carriers, and there is no male-to-male transmission. If a normal male has children with a carrier of hemophilia, there is a 50% chance that a male offspring will inherit hemophilia and a 50% chance that a female offspring will be a carrier. If a male with hemophilia has children with a normal female, all male offspring will be normal, and all female offspring will be carriers. Hemophilia B, is also inherited as an X-linked recessive trait; it is one fourth as prevalent as hemophilia A.<sup>21</sup> Approximately one-third of patients with hemophilia have no family history; their disease is presumed to result from a new mutation.

### Classification

Hemophilia A and B forms are subcategorized based on the procoagulant present; normal levels range from 50% to 150%:

- Severe deficiency: levels less than 1%
- Moderate deficiency: levels between 1% and 5%
- Mild deficiency: levels greater than 5% to less than 50%

Ambiguity exists in the maximal factor VIII or IX activity level (40% or 50%) used as a cutoff to classify a patient as having a mild deficiency. As such, the classification of individuals with factor VIII or IX levels between 40% and 50% may vary<sup>22</sup>; most clinicians continue to use <50% as the cutoff.

## Bleeding Symptoms

Patients with a severe deficiency may experience frequent bleeding episodes, often occurring two to four times per month; bleeding episodes are often spontaneous in nature without a specific history of injury or trauma. Common sites of bleeding include joints, muscles, and skin. Hemarthroses (joint bleeding) are frequently observed, with symptoms including pain, stiffness, and limited range of motion. Repeated episodes of hemarthrosis or muscle bleeding result in chronic musculoskeletal disease including muscle wasting and hemophilic arthropathy, a degenerative joint disease that culminates in debilitating painful arthritis and disability; commonly affected joints include the knees, elbows, ankles, hips, and shoulders.<sup>21</sup> The term target joint refers to an affected joint which is prone to frequent bleeding episodes. Pseudotumors (hemorrhagic pseudocysts) may occur in several locations including the jaw, in which case curettage is indicated.<sup>23,24</sup>

Patients with moderate deficiency experience less frequent bleeding episodes (approximately four to six times per year); however, if a target joint develops in a patient with moderate deficiency, spontaneous and frequent bleeding may occur.

Patients with mild deficiency bleed infrequently, only in association with surgery or injury. The diagnosis of a mild deficiency may occur if an abnormal screening coagulation test is obtained as part of a presurgical evaluation, or if bleeding occurs in association with surgery or trauma.

## Oral Cavity Bleeding

Mouth lacerations are a common cause of bleeding in children with all severities of hemophilia. Sonis and Muselman<sup>25</sup> evaluated 132 patients with hemophilia A of all severities and noted that persistent oral bleeding resulted in the diagnosis of hemophilia in 18 patients (13.6%). Approximately 29% (11/38) of patients with mild hemophilia were discovered as a result of bleeding from the oral cavity; only 7% (7/94) of patients with severe or moderate hemophilia were diagnosed following oral bleeding. Furthermore, 78% of the cases diagnosed secondary to oral bleeding were the

result of bleeding from the maxillary frenum; the remaining 22% resulted from tongue bleeds. Thus initial diagnosis of hemophilia, especially in moderate or mild disease, may directly involve the dentist.<sup>25</sup>

Figs. 27.3 to 27.8 are examples of oral cavity bleeding complications in patients with bleeding disorders.

### Treatment

The mainstay of therapy for patients with hemophilia is prophylactic and/or on-demand use of purified replacement factor concentrates isolated from pooled plasma or manufactured using recombinant techniques; currently, genetically engineered products are the most common replacement factor products.<sup>26</sup> Factor concentrates are advantageous as they are generally accessible, easily handled and stored, virally inactivated, and result in consistent hemostatic results. The dosage, frequency of administration, and duration of therapy depend on the location and severity of the bleeding episode, activity level required, half-life of the procoagulant, and in the case of perioperative care, the intervention or procedure planned. For routine

bleeding episodes, such as early joint, soft tissue, and oral bleeds, an initial correction to an approximate level of 40% to 50% commonly achieves hemostasis and resolution of the bleeding episode<sup>27</sup>; however, some care providers may use higher doses for initial treatment and follow-up doses, especially in hemarthroses.<sup>28</sup>

One international unit (IU) of factor VIII concentrate per kilogram of body weight will increase factor VIII activity by 2% (e.g., to achieve factor VIII activity of 50% in a patient with severe hemophilia A, the required dose is 25 IU/kg). In hemophilia B, the number of units required to achieve this level is different as the volume of distribution of factor IX is greater than that for factor VIII (0.5) and varies by product. Calculation of factor IX concentrate dose is based on age, product, and individual patient volume of distribution; measurement of activity levels may be required to document a hemostatic level.<sup>21,26,29</sup>

The half-life of endogenous factor VIII is approximately 12 hours and that of endogenous factor IX is approximately 18 hours.<sup>21,30</sup> Extended half-life (EHL) factor concentrates were first introduced in 2014 and are available as replacements for both factors VIII and IX. In general, EHL factor IX products have half-life three to five times longer than that of endogenous factor IX, whereas EHL factor VIII products have half-life approximately 1.5 times that of the native protein due to the short plasma half-life of VWF (VWF functions to protect factor VIII from proteolytic degradation in plasma).<sup>31,32</sup> The half-life of the factor concentrate depends not only on the product but also on the patient. Younger individuals tend to have increased clearance and interpatient variability exists within the same age group; therefore, treatment recommendations should be individualized to the patient. Table 27.3 lists examples of factor concentrates utilized for hemophilia A and B.

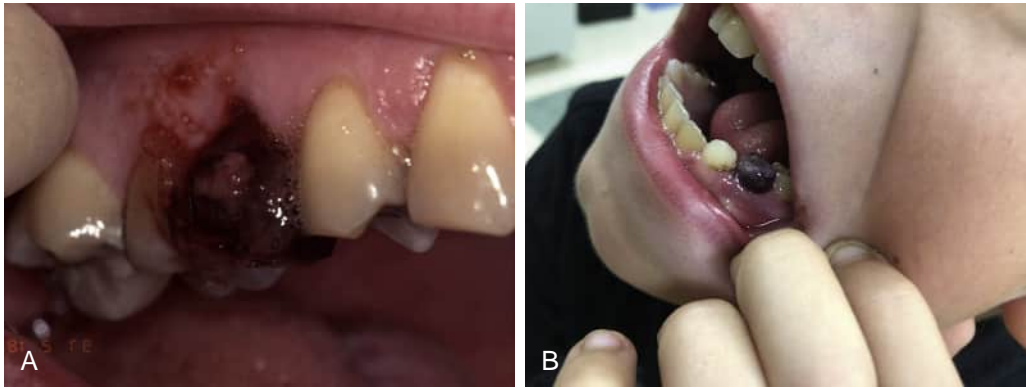
**On-Demand Versus Prophylaxis Regimens.** Treatment regimens may be divided into on-demand therapy (replacement therapy administered after a bleeding episode has occurred) and prophylactic therapy (where the

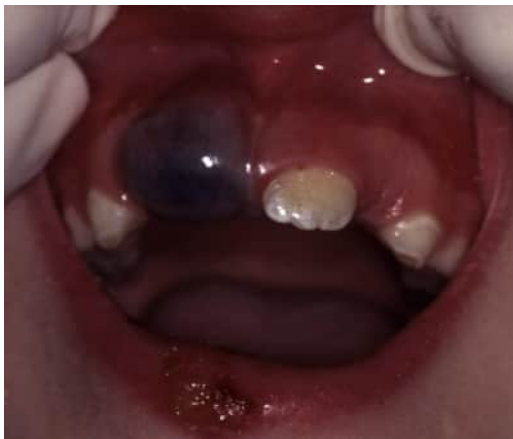

Fig. 27.3 Eruption hematoma.

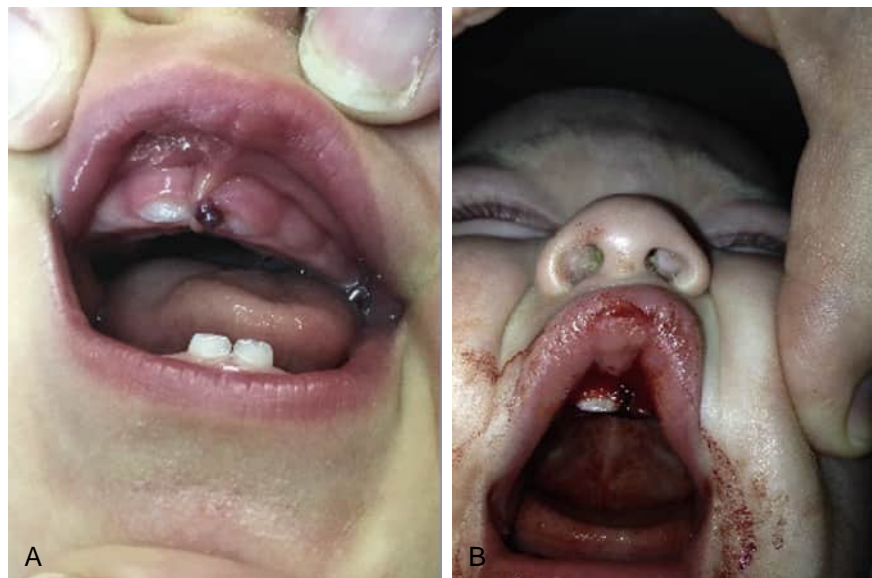

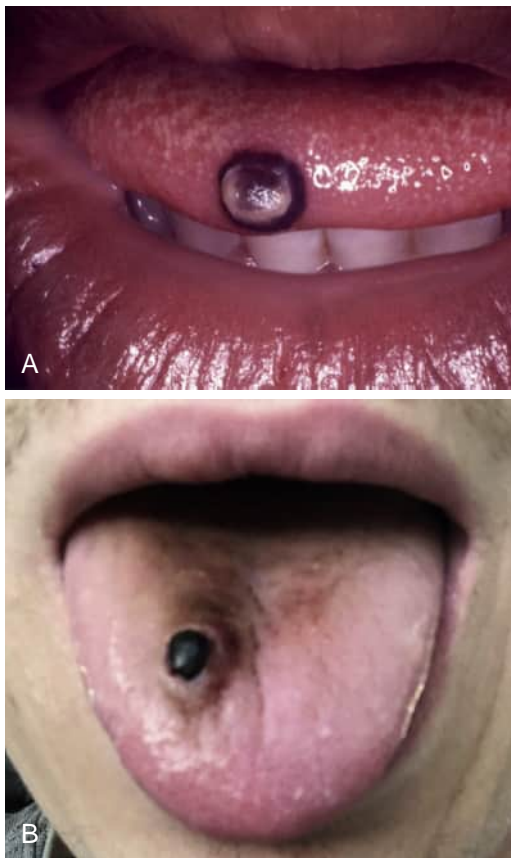Fig. 27.4 Frenulum injury in patients with bleeding disorder may result in life-threatening bleeding. (A) Frenulum injury with liver clot formation in a 1-year-old male with moderate hemophilia A. (B) Frenulum injury in a 16-month-old male with severe hemophilia A.



**Fig. 27.5** “Liver clot” post dental extraction in patients partially adhering to the recommended hemostatic regimen. (A) A 20-year-old male with mild hemophilia A. (B) A 9-year-old male with mild hemophilia A 8 days post deciduous tooth extraction. This liver clot is a persistent dry-looking clot compared with fresh and wet-looking liver clot in (A).



**Fig. 27.6** Tongue hematomas. (A) Trauma to tongue in a male with moderate hemophilia A. (B) Trauma to tongue in a 26-year-old male with moderate hemophilia B.

factor concentrate is administered on a regular schedule to prevent or reduce bleeding episodes). The regimen prescribed is dependent on the patient’s disease severity, annualized bleeding rate, severity of the acute bleeding episode, factor concentrate half-life, and physician recommendation.

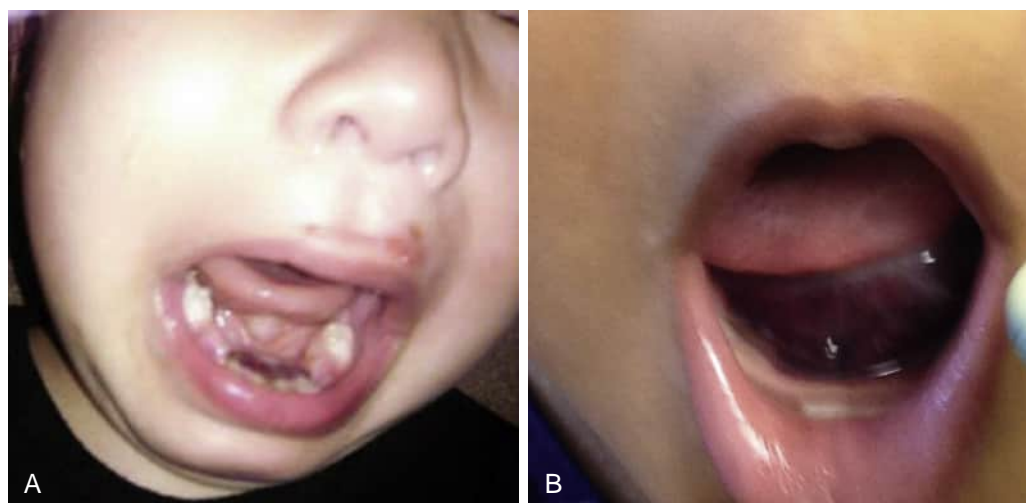Prophylactic regimens are further subdivided into primary, secondary, and tertiary. Primary prophylaxis is a long-term treatment for prevention of joint disease instituted in the absence of documented joint disease, and

before the second clinically evident joint bleed; secondary prophylaxis may be long- or short-term, and is instituted after two or more joint bleeds but before the onset of joint disease; tertiary prophylaxis is defined as regular continuous replacement therapy started after the onset of joint disease.<sup>22</sup> Primary prophylaxis has been shown in a prospective randomized study to be the most effective regimen to prevent joint disease in patients with severe hemophilia; it is now considered the standard of care for these patients.<sup>33</sup>

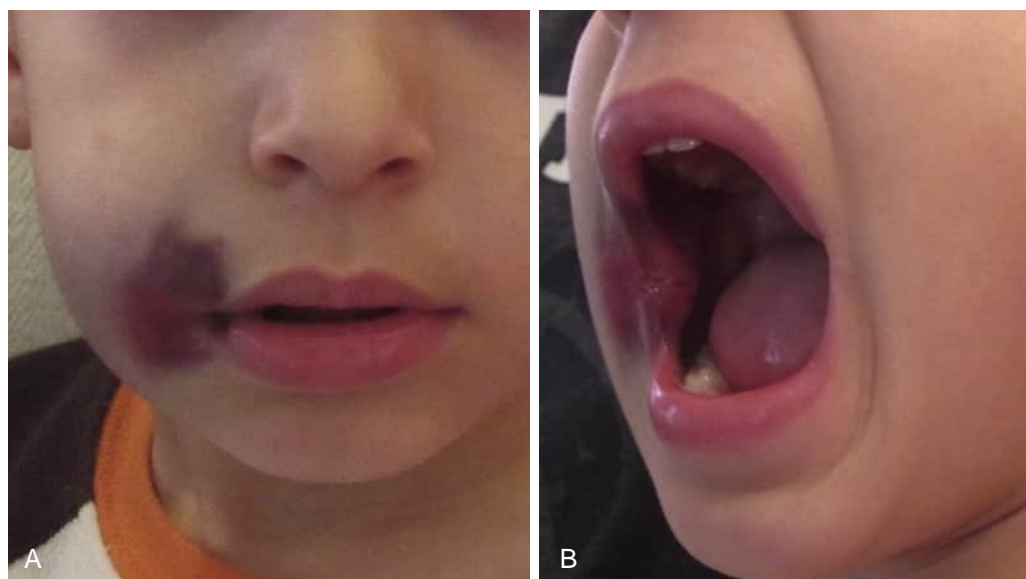**Hemophilia A—Specific Treatment Aspects.** Desmopressin acetate (subcutaneous DDAVP or intranasal Stimate) may be used for minor hemorrhagic episodes to achieve hemostasis in patients with mild hemophilia A. An appropriate rise in factor VIII activity to hemostatic levels should be documented for any given patient before routine therapeutic use as response varies among individuals. (See additional important information regarding utilization of desmopressin acetate in the previous section on VWD treatment).<sup>15,16,34</sup>

Emicizumab (Hemlibra; Genentech, Inc., South San Francisco, CA, USA) is a humanized monoclonal bispecific antibody that mimics the role of activated factor VIII in the coagulation cascade; it binds factor IXa and factor X to promote thrombin generation. The Food and Drug Administration approved the use of Hemlibra as a nonfactor prophylactic agent for patients with hemophilia A with and without inhibitors in 2017 and 2018, respectively (see inhibitor development section later). It is administered subcutaneously and requires fewer injections (administered weekly, or once every 2 or 4 weeks) compared with traditional factor concentrates due to its long half-life (approximately 4 weeks). Hemlibra is effective as a prophylactic agent for patients with and without inhibitors and provides a continuous hemostatic coverage due to its pharmacokinetic profile; it essentially changes the bleeding phenotype in patients with severe hemophilia A to that of mild hemophilia A. As such, it can potentially deliver hemostatic coverage for minor procedures.<sup>35</sup> While Hemlibra is an effective prophylactic agent, it cannot be used for the treatment of acute bleeds; likewise, it cannot be used in patients with hemophilia B.





**Fig. 27.7** Mouth floor and sublingual hematoma in patients with bleeding disorders may result in life-threatening airway obstruction. (A) Mouth floor hematoma post injury in a 2-year-old female with type 1 von Willebrand disease. (B) Mouth floor hematoma post injury in a 10-month-old male with severe hemophilia A.



**Fig. 27.8** (A) and (B) Cheek hematoma post injury in a 5-year-old male with moderate hemophilia B.

**TABLE 27.3** Examples of Recombinant Factor Concentrates for Hemophilia

Hemophilia A	Hemophilia B
Standard Half-Life	Standard Half-Life
Advate	BeneFIX
NovoEight	Rixubis
Xyntha	Ixinity
Kovaltry	
Nuwiq	
Extended Half-Life	Extended Half-Life
Eloctate	Alprolix
Adynovate	Idelvion
Afstyla	Rebinyon

## COMPLICATIONS OF BLEEDING DISORDERS

### Hemophilia—Inhibitor Development

Inhibitors are antibodies, commonly IgG, that are directed against and neutralize endogenous and/or replacement

coagulation factor. Inhibitors are one of the most severe complications for patients with hemophilia. Inhibitors may develop in approximately 30% of patients with severe hemophilia A and in 3% to 5% of patients with severe hemophilia B.<sup>36</sup>

Inhibitor levels are measured in Bethesda units (BU), a measurement that reflects the ability of the antibody to neutralize a specific amount of factor VIII or IX.<sup>36,37</sup> Successful treatment of patients with inhibitors requires accurate knowledge of the inhibitor classification (high responder vs. low responder) and current inhibitor level. Low responders have peak levels at any time  $\leq 5$  BU and may continue to be treated with factor concentrate at higher than normal doses; high responders have peak titers  $> 5$  BU<sup>22</sup> and require the use of bypassing agents [activated prothrombin complex concentrate (aPCC; FEIBA; Baxalta US Inc., Lexington, MA, USA) or recombinant factor VIIa (NovoSeven; Novo Nordisk, Bagsvaerd, Denmark)].

The use of Hemlibra for prophylaxis in patients with hemophilia A with inhibitors significantly decreases the annualized bleeding rate and provides continuous hemostatic coverage due to its long half-life. Hemlibra has also been shown to significantly improve a patient's quality of life.<sup>38</sup> Although prophylaxis with bypassing agents is effective,<sup>39</sup> Hemlibra has been shown to be superior in this population.<sup>40</sup>

Currently, bypassing agents remain the hemostatic agent of choice for acute bleeding episodes and for surgical management in patients with hemophilia A with inhibitors; they are the only treatment option for patients with hemophilia B with inhibitors as Hemlibra is ineffective in this patient population. Patients with hemophilia with inhibitors pose considerable treatment challenges and should be managed only in conjunction with an experienced hematologist at an HTC; hemostasis in this patient population is often difficult to achieve and maintain, and patient response to bypassing agent therapy can be variable.<sup>41</sup>

### Blood-Borne Infections

Prior to the availability of effective viral inactivation techniques, patients with hemophilia receiving blood-derived products were at high risk of developing transfusion-borne viral infections. Hepatitis B (HBV) and C (HCV) were a significant source of morbidity and mortality in this patient population prior to the availability of vaccinations and effective treatments.<sup>42,43</sup> Between 1979 and 1985, there was also a high risk of human immunodeficiency virus (HIV) transmission that resulted in considerable morbidity and mortality (prior to 1985 there was no antibody test for HIV and no reliable viral inactivation technique for the purification of plasma-derived factor concentrates). Approximately 90% of hemophilic patients with severe hemophilia A, and 30% of those with severe hemophilia B who received plasma concentrates during this at-risk period may have become infected with HIV. HIV infection is a sensitive issue for these individuals who may now bear the burden of two chronic conditions.<sup>44</sup> The transmission of HIV and HBV/HCV has been eliminated in currently available factor concentrates (manufactured using recombinant techniques or pooled plasma). Nevertheless, universal precautions should be followed in the treatment of all hemophilic patients with a history of receiving factor concentrates.

### WOMEN WITH BLEEDING DISORDERS

Female carriers of hemophilia A and B may have decreased levels of factors VIII and IX, respectively, with levels in the mild deficient range. To determine bleeding risk, it is recommended that all carriers of hemophilia be evaluated to determine their baseline factor VIII or factor IX activity level. All women who are carriers of hemophilia should be treated as potential mild-deficient patients, and their hematologist should be contacted before specific dental interventions to determine the baseline factor level and potential need for hemostatic treatment.<sup>45-48</sup>

As previously discussed, VWD is inherited as an autosomal dominant trait affecting males and females equally. Very rare bleeding disorders such as deficiencies of factors VII, IX, and XIII are autosomal recessive and affect females and males equally. Therefore, women with bleeding disorders are not uncommon. An appropriate personal and family history is required to determine if women are or could be affected.<sup>17,47,48</sup>

### OTHER RARE CONGENITAL BLEEDING DISORDERS

In comparison to hemophilia A and B, deficiency of factor XI (plasma thromboplastin antecedent), historically referred to as *hemophilia C* or *Rosenthal syndrome*, is inherited as an autosomal recessive trait affecting male and female offspring equally. This disorder is most frequently observed in those of Ashkenazi Jewish descent, but it is found in many other populations.

Other factor deficiencies, such as factors II, V, and XIII (one case per 1 million population) and factor VII (one case per 500,000 population), are rare and are inherited as autosomal recessive traits.<sup>49,50</sup>

Hemophilia A and B were the first congenital bleeding disorders for which plasma-derived and recombinant factor concentrates were made available. Treatment options for other rarer congenital factor deficiencies lagged hemophilia for many years, and blood products (e.g., fresh frozen plasma, preferably from solvent-/detergent-treated pooled human plasma) were often the only appropriate hemostatic agents. Currently in the United States, specific factor concentrates are available for many rare bleeding disorders. [Table 27.4](#) summarizes replacement therapies in the United States for rare bleeding disorders.

**TABLE 27.4** Rare Bleeding Disorders: Available Therapy in the United States

Factor Deficiency	Recombinant Concentrate	PD Concentrate	PCC	Cryo	S/D Pooled Plasma
Fibrinogen (I) (afibrinogenemia & hypofibrinogenemia)		RiaSTAP Fibryga		✓	
Prothrombin (II)			Profilnine Debulin		
Factor V					Octaplas
Factor VII	NovoSeven				
Factor X		Coagadex	Profilnine Bebulin		
Factor XI					Octaplas
Factor XIII				✓	
- A or B subunit		Corifact		✓	
- A subunit	Tretten	Corifact		✓	

Cryo, Cryoprecipitate; PCC, prothrombin complex concentrate; PD, plasma derived; S/D, solvent/ detergent treated.

## DENTAL CARE FOR PATIENTS WITH BLEEDING DISORDERS

Routine dental care (including primary preventative care) is essential to maintain oral hygiene and should be made available for patients with bleeding disorders, as it may reduce the incidence of additional costly procedures. This patient group does not have higher inherent risk of developing oral health issues; however, oral hygiene and oral health status among patients with congenital bleeding disorders is generally not as good as that in the general population (it should be noted that reports vary between age groups and countries).<sup>51–53</sup> Fear of bleeding with daily dental brushing and flossing and limited access to experienced dental care may add to the psychological concerns of patients with chronic bleeding diseases.<sup>54</sup>

To provide comprehensive care (physical, psychological, social, and financial) for patients with congenital bleeding disorders, HTC were established. Likewise, dentists and oral surgeons fulfill an important role in the overall well-being of patients with congenital bleeding disorders, and dental care should be co-managed by a hematologist and a dentist or an oral surgeon.

A recent survey among 102 HTCs in the United States revealed inconsistent levels of oral health services available to patients. Only 29 HTCs had a dentist on staff, whereas the remaining 73 centers (71.6%) had no dentist on staff (71.6%); however, 57 out of these 73 centers (78%) reported having a dental team to whom they would refer patients. Oral health education was offered in 88 (86.3%) of the participating HTCs. Sixty of the HTCs (59%) reported being satisfied or extremely satisfied with the dental care available to their patients; 30% were neutral; and 11% were dissatisfied or extremely dissatisfied.<sup>55</sup> The HTCs ranked five potential barriers to dental treatment: finance was identified as the main issue (58%), followed by lack of specialized dental care (22%) and fear/anxiety (11%). The study noted the financial obstacle to patients, even among children covered with state-funded programs (Medicaid). The authors estimated that about 4000 patients with bleeding disorders under the care of an HTC had no access to dental care through the center.<sup>55</sup>

### Dental Management

It is recommended that most patients with bleeding disorders receive routine regular outpatient dental care. Appointments should be planned so that maximum amount of dental care may be accomplished in a single visit so as to minimize the need for unscheduled factor infusions and associated cost.<sup>56–58</sup> Patients with inhibitors are optimally treated at a center experienced in dealing with this complication. Dental procedures to treat a patient with a bleeding disorder do not differ significantly from those used for unaffected individuals. The patient must be provided specific and detailed postoperative instructions.

**Exfoliation of Deciduous Teeth.** The normal exfoliation of primary teeth does not usually result in bleeding or require factor replacement. Bleeding in these circumstances can generally be controlled with direct finger and gauze pressure maintained for several minutes; the direct topical application of an adjunctive agent may also help with local

hemostasis. If there is continuous slow bleeding, antifibrinolytic therapy may be initiated. In rare circumstances, most commonly when the gingival tissue is repeatedly traumatized during exfoliation, use of factor replacement therapy may be required; in such situations, a dental evaluation should be performed and the removal of the exfoliating tooth should be considered if repeated trauma cannot be avoided.

**Prevention of Dental Disease.** A program that includes brushing, flossing, appropriate topical fluoride exposure, adequate systemic fluoride administration, proper diet, and professional examination at regular intervals is an effective approach to the prevention of dental problems. Rubber cup prophylaxis and supragingival scaling may be safely performed without prior factor replacement therapy. Minor bleeding is often controlled with local measures, such as direct pressure with a moistened gauze square. If bleeding persists for several minutes, the topical application of recombinant thrombin (RECOTHROM; ZymoGenetics, Inc., Seattle, WA, USA),\* microfibrillar collagen (Avitene; Davol Inc., subsidiary of C.R. Bard, Inc., Warwick, RI, USA), and local fibrin glue may be of value.

**Periodontal Therapy.** Patients who require deep scaling due to gross calculus should initially undergo supragingival scaling. The tissue should be allowed to heal for 7 to 14 days, during which time the gingiva recedes as edema and hyperemia diminishes; subsequent treatments to remove calculus and irritants then have a decreased risk of tissue bleeding. If subgingival scaling is planned, replacement therapy may be considered depending on the anticipated amount of bleeding and the severity of the factor deficiency. Periodontal patients must be placed on a prophylactic regimen for optimal management.<sup>58–60</sup>

An abnormal frenum attachment may cause gingival recession and pocket formation; early treatment is indicated to prevent continued gingival recession and alveolar bone loss. All appropriate frenectomy techniques are surgically acceptable for patients with bleeding disorders; both factor concentrate replacement and antifibrinolytic therapy are required before frenum or other periodontal surgery. If a large amount of bleeding is anticipated, these procedures should be performed in a hospital environment, with the requisite preparation. The hematologist or attending physician must be contacted to determine the appropriate factor correction required and the possible need for subsequent hospital or outpatient management.

**Restorative Procedures.** Patients with bleeding disorders should be allowed to consider all restorative procedures. Most restorative procedures on primary teeth are successfully completed using periodontal ligament (PDL) injections of local anesthesia or local infiltration and do not require factor concentrate replacement; small lesions may be restored under nitrous oxide–oxygen inhalation analgesia alone. The use of acetaminophen with codeine may decrease discomfort in a child during the procedure.

\* Although not reported in the dental literature, bovine thrombin–induced acquired factor V deficiency—a rare, acquired coagulopathy—has been reported; therefore, recombinant thrombin is recommended.



Most operative procedures for adults may be completed under local anesthesia; these usually do not require factor concentrate replacement. If a mandibular block or a posterior superior alveolar injection is anticipated, factor concentrate replacement to a level of 40% and antifibrinolytic therapy are required before injection.

A rubber dam or dental isolation system should be used to isolate the operating field and protect the cheeks, lips, and tongue. These soft tissues are highly vascular and accidental laceration may present a difficult management problem. A thin rubber dam is preferred as there is a decreased tendency to torque the rubber dam retainer and cause gingival tissue abrasion. The retainer should be placed carefully so that it is stable; if a retainer slips, it may lacerate the gingival papilla. Retainers with subgingival extensions should be avoided.

Wedges and matrices can be used conventionally; during proximal preparation, the wedge retracts the papilla, thus protecting it. A properly placed matrix should not cause bleeding.

High-speed vacuum and saliva ejectors must be used with caution to prevent sublingual hematomas. Care must also be used in the placement of intraoral radiographic films, particularly in highly vascular sublingual tissues.

The preparation of a tooth for a cast crown requires careful gingival preparation, as does the placement of the retraction cord and impression material. Periphery wax should be used on the impression tray to prevent possible intraoral laceration during tray placement. Excess trauma should be avoided in cementing or finishing a crown.

**Pulpal Therapy.** Pulp exposure in primary and permanent teeth may be avoided if some of the carious dentin is left remaining (i.e., not all the carious dentin is removed in a single procedure) (indirect pulp therapy). A pulpotomy or pulpectomy is preferable to extraction as the treatment and expense associated with the extraction of a tooth in an individual with a bleeding disorder is increased. Most vital pulpotomy and pulpectomy procedures can be successfully completed with local infiltration anesthesia; nitrous oxide–oxygen inhalation analgesia may also help alleviate discomfort. If the pulp of a vital tooth is exposed, an intrapulpal injection may be used safely to control pain. Bleeding from the pulp chamber does not present a significant issue, as it may be readily controlled with pressure from a cotton pellet. If pulp tissue is necrotic, local anesthetic is usually unnecessary.

### Oral Surgery

Preoperative evaluation and postoperative management of a patient with a bleeding disorder undergoing a dental extraction must be coordinated with the hematologist. The dentist should discuss the surgical procedure with the hematologist, including the anesthetic technique, degree of anticipated surgical trauma, and expected time required for healing. The hematologist should then determine the quantity and duration of factor concentrate replacement and any adjunct therapy required for surgery and postoperative management. It is now possible for oral surgery to be performed in a patient with a bleeding disorder on an outpatient basis<sup>61,62</sup>; requirements include an experienced dentist and hematologist, the availability of a facility for the patient to receive factor infusions if home infusion is not

routinely performed, and a coagulation laboratory capable of timely laboratory evaluations. Patients with inhibitors should be treated only by those experienced in their management and in a safe and suitably equipped setting.

A 30% to 40% factor correction should be administered (within 1 hour prior to dental treatment) for simple extractions of erupted permanent teeth and multirrooted primary teeth. Antifibrinolytic therapy should be started immediately before or following the procedure and should be continued for 5 to 10 days. The patient should be placed on a clear liquid diet for the first 72 hours and for the next 7 days, a soft, pureed diet is recommended; during this period, the patient should not use straws, metal utensils, pacifiers, or bottles. After 10 days the patient may resume a more normal diet; specific postoperative instructions should be provided to the patient and/or caregiver.

Following the completion of an extraction, direct topical application of hemostatic agents such as thrombin or microfibrillar collagen hemostat (Avitene; Darvol Inc.) may assist with local hemostasis. The socket should be packed with an absorbable gelatin sponge (e.g., Gelfoam; Pharmacia and Upjohn Co., Kalamazoo, MI, USA); microfibrillar collagen or topical thrombin or fibrin glue may then be placed in the wound, followed by direct pressure with gauze.

Stomahesive (ConvaTec Inc., Skillman, NJ, USA), a skin hydrocolloid base barrier adhesive, may be placed over the wound for additional protection from the oral environment. In general, the use of sutures should be avoided unless suturing is expected to markedly enhance healing; in such cases absorbable sutures are recommended.

For surgical extractions of impacted, partially erupted, or unerupted teeth, a higher factor activity level may be targeted before surgery due to the increased likelihood of surgical trauma and the extended healing period. This should be discussed with the hematologist who may also elect to administer factor replacement to the patient postoperatively. Antifibrinolytic therapy should be started immediately before or following the procedure and continued for 7 to 10 days.

For simple extractions of single-rooted primary teeth (i.e., incisors and canines), the extent of root development must be evaluated to determine whether factor replacement therapy is required. If there is complete root development, factor replacement therapy is likely required; whereas if there is only partial root formation, antifibrinolytic therapy along with local hemostatic agents may be sufficient.

**Surgical Complications.** Despite all precautions, bleeding may occur 3 to 4 days postoperatively when the clot begins to resorb. If bleeding does occur, both systemic and local treatment should be used for hemostatic control; sufficient replacement factor should be administered to control any recurrent bleeding.<sup>63</sup>

It is not recommended to protect a loose abnormal clot. The typical clot in this situation is characterized as a “liver clot” and is dark red, usually protruding from the surgical site and often covers the surfaces of several teeth. Following adequate replacement with factor concentrate (usually 30% to 40% activity level), the abnormal clot should be removed and the area cleansed to help isolate the source of bleeding. The socket should then be repacked and the use of antifibrinolytic agents considered.

## Antibiotic Prophylaxis

Patients routinely using a prophylactic factor infusion regimen may have a central venous catheter placed for frequent venous access.<sup>64</sup> Antibiotic prophylaxis to protect the central venous access device may be performed if recommended by the hematologist based on the patient's unique circumstances (e.g., status of oral hygiene and dental caries as other additional health issues); however, the use of antibiotic prophylaxis is not currently recommended by the Centers for Disease Control and Prevention.

Total joint replacement, usually of the hip or knee, is often performed in adult patients with severe hemophilia to restore function and alleviate pain associated with degenerative arthritis due to recurrent hemarthroses. The American Dental Association and American Academy of Orthopedic Surgeons advocate in favor of antibiotic prophylaxis for patients with artificial joints prior to invasive dental procedures; however, there is limited evidence to support this recommendation.<sup>65,66</sup> In such cases, the dentist should consult with the orthopedic surgeon prior to dental treatment; the 2007 American Heart Association recommendations for bacterial endocarditis prophylaxis are commonly followed.<sup>67</sup>

If the patient is immunocompromised because of HIV infection, antibiotic prophylaxis may be considered in coordination with the HIV specialist.

## Orthodontic Treatment

Early recognition of an orthodontic problem is important to diminish or eliminate complex orthodontic concerns. Both interceptive and full-banded orthodontics may be performed if required; however, care must be taken in the adaptation and placement of bands, and protruding sharp edges and wires should be eliminated to prevent laceration of the oral mucosa. The use of preformed orthodontic bands and brackets, which can be bonded directly to the tooth, will almost totally eliminate contact of orthodontic appliances with gingiva during placement. Longer-acting wires and springs require less frequent adjustment of orthodontic appliances. Any bleeding caused by an accidental scratch or minor laceration of the gingiva usually responds to applied pressure for 5 minutes.

Regular oral hygiene is particularly important to avoid inflamed, edematous, and hemorrhagic gingival tissues; a water irrigation device may be helpful for home dental care.

## Dental Emergencies

Oral trauma is a common occurrence during childhood. Management of bleeding injuries, including hematomas, in the oral cavity of the patient with a bleeding disorder may require a combination of factor replacement and antifibrinolytic therapy, as well as treatment with local hemostatic agents. Blood loss from the oral cavity may be easily underestimated or overestimated; the patient's hemoglobin (Hb) level should be determined to confirm the absence of anemia in the case of blood loss.

It is important to address bleeding and/or the potential risk of bleeding (e.g., by infusion of factor concentrate) before any additional dental evaluations are performed (e.g., scans or evaluation in the operating room.)

## Development of a Treatment Plan

With recent advances in treatment, most patients with bleeding disorders routinely receive outpatient dental care. With a thorough understanding of the patient's hemostatic disorder, the dentist, in conjunction with the hematologist, is able to make safe and appropriate treatment decisions.

The dentist must be aware of procedures that can be performed safely and those where complications may arise. The dentist should confer with the patient's physician and hematologist to formulate an appropriate treatment plan and be aware of the specific type of bleeding disorder, severity, frequency, and treatment for bleeding episodes, as well as the patient's inhibitor status. Many individuals with hemophilia self-administer infusion products at home and are, therefore, able to treat themselves as required. If a patient is on a prophylactic regimen, dental evaluations and interventions should occur on the day of a regularly scheduled infusion; if a patient is on an on-demand regimen, additional discussion regarding the need for replacement therapy is required, specifically for dental interventions. If factor concentrate replacement is required, then preferably all restorative treatments or extractions should be completed in one visit to minimize the number of costly infusions. The dentist should be prepared to discuss with the hematologist the anticipated anesthetic, invasiveness of the dental procedure, anticipated amount of bleeding, and time required for oral wound healing in order to establish an appropriate treatment plan, including the need for factor replacement and adjunctive therapies.<sup>58</sup>

In addition to the use of factor replacement and/or adjunctive therapies, early clinical data utilizing prophylactic emicizumab for minor procedures is promising. During the HAVEN clinical trials designed to evaluate the efficacy of emicizumab prophylaxis in patients with hemophilia A, 215 procedures were performed, of which 64 (29.8%) were dental procedures. Of these 64 dental procedures, 42 were performed without additional treatment; 29/42 (69%) had no bleeding complications, 9/42 (21%) required treatment for postoperative bleeding, and 4/42 (10%) experienced postoperative bleeding, but did not require factor infusions. Overall, approximately 79% of patients who underwent dental procedures did not require additional hemostatic therapy while on Hemlibra prophylaxis.<sup>40,68-71</sup>

## Use of Antifibrinolytic Agents

Patients with bleeding disorders may utilize antifibrinolytic agents as an adjunct therapy for the prevention and/or treatment of oral bleeding in dental management. These agents include  $\epsilon$ -aminocaproic acid (Amicar; Xanodyne Pharmaceuticals, Florence, KY, USA) and tranexamic acid (Lysteda; Ferring Pharmaceuticals and Cyklokapron; Pfizer, New York, NY, USA).

Antifibrinolytics prevent clot lysis and are often used as an adjunct therapy to factor concentrates, particularly in patients with hemophilia, where loose, friable clots can occur in the oral cavity that are easily dislodged or rapidly dissolved. Antifibrinolytics may be recommended as the sole hemostatic agent in dental procedures where minimal bleeding is anticipated.

**Dosing.** In children,  $\epsilon$ -aminocaproic acid is administered immediately prior to dental treatment using an optional initial loading dose of 200 mg/kg by mouth (maximum dose of

3 g). Subsequent 50–100 mg/kg doses (up to a maximum individual dose of 3 g) should be administered orally every 6 hours for 5–7 days. The availability of  $\epsilon$ -aminocaproic in both tablet and liquid form provides different options for use in children. For adults and pediatric patients heavier than 30 kg, a regimen of 3 g orally, four times daily without a loading dose may be used.

The maximum oral dose of tranexamic acid is 25 mg/kg every 8 hours; doses of 10–15 mg/kg have been reported to be effective depending on the location and severity of bleeding. Dosing should be repeated every 8 hours for 5–7 days. In the United States, an oral preparation of tranexamic acid (Lysteda; Ferring Pharmaceuticals) is approved for use in cyclic menorrhagia; the recommended adult dose is 1.3 g every 8 hours. Physicians have utilized this agent off-label for oral bleeding and during dental procedures. An intravenous formulation (Cyklokapron) is available in the United States and may also be administered orally if required.<sup>56,58</sup>

**Side Effects.** The common side effects associated with the use of antifibrinolytics include headache, nausea, and dry mouth; these side effects are usually tolerable. Other less common side effects have been reported. Antifibrinolytics should not be used when renal or urinary tract bleeding is present or when there is evidence of disseminated intravascular coagulation due to the risk of thrombosis. Repeated use of aPCC (i.e., FEIBA) in hemophilia patients with inhibitors should also be avoided during a course of antifibrinolytic therapy as this combination may result in thrombotic episodes.

## PAIN CONTROL

### Analgesia

If patient apprehension is significant, sedation or nitrous oxide–oxygen inhalation analgesia may be considered; hypnosis has also proven beneficial for some individuals. Intramuscular injections of hypnotic, tranquilizing, or analgesic agents are contraindicated in patients who have not received replacement therapy and in patients with inhibitors not covered with bypassing agents due to the risk of hematoma formation. Hemlibra prophylaxis may provide adequate hemostatic coverage, but caution and monitoring is advised.

Acute pain of moderate intensity is frequently managed with acetaminophen. Analgesics containing aspirin (e.g., Darvon Compound 65) or nonsteroidal antiinflammatory drugs (NSAIDs; e.g., ibuprofen) may affect platelet function and should be avoided. Celecoxib (e.g., Celebrex, Pfizer) is a cyclooxygenase-2 (COX-2) selective inhibitor NSAID that does not affect platelet function; a systematic review and meta-analysis noted no significant increase in the risk of intraoperative or postoperative bleeding, or blood loss with this product.<sup>72</sup> COX-2 inhibitors have been used in adults with hemophilia with acute and chronic pain; they have been used to a lesser extent for acute and chronic pain in pediatrics possibly due to the lack of clinical data.<sup>73,74</sup> Although additional data in pediatrics is needed, celecoxib should be considered as an alternative to other NSAIDs for acute pain management in patients with bleeding disorders. For severe pain, narcotic analgesics may be required; these are not contraindicated in a patient with a bleeding disorder.

## LOCAL ANESTHESIA

In the absence of factor replacement, PDL injections may be used. The anesthetic is administered along the four axial surfaces of the tooth by placement of the needle into the gingival sulcus and the PDL space. Infiltration anesthesia can generally be administered without  $\epsilon$ -aminocaproic acid or replacement therapy pretreatment; however, if the infiltration anesthesia is injected into loose connective tissue or a highly vascularized area, then factor replacement to achieve a level of approximately 30% to 40% activity is required.

Caution must be exercised when considering block anesthesia: the loose, connective, nonfibrous, and highly vascularized tissue at the sites of inferior alveolar nerve injection and posterior superior alveolar injections is predisposed to the development of dissecting hematomas; these may cause airway obstruction and result in a life-threatening bleeding episode. Therefore a minimum of 40% factor correction is mandatory with block anesthesia. The dentist must carefully aspirate to ensure that the needle has not entered a blood vessel; if bloody aspirate is present, further factor replacement may be required, and the attending hematologist should be notified immediately following the operative procedure. All patients should be observed for development of such a hematoma; if one develops following the administration of local anesthesia, the patient should be referred for treatment immediately.

## RISKS TO DENTAL STAFF

Virtually all surgical trainees will experience at least one needle-stick injury, and nurses are at significant risk for multiple needle-stick injuries, given their frequent handling of sharps. The risk for acquiring HBV, HCV, or HIV infections following an accidental needle stick are 30%, 3%, and 0.3%, respectively.<sup>75</sup>

A study by Klein et al.<sup>76</sup> demonstrated a quantifiable occupational risk for HCV infection among dental professionals; higher rates were observed among oral surgeons than among conventional dentists. Investigators at a dental teaching hospital noted that injury from sharps occurred while they were being cleared away after direct patient care.<sup>75,77</sup> These observations support recommendations that dental personnel be vaccinated against HBV and adopt appropriate universal precautions during and after all patient encounters, especially as many patients may not know their infection status.

## SUMMARY

Persons with congenital bleeding disorders represent a unique group of patients who optimally should be treated by specially trained dentists and oral surgeons. A multidisciplinary team including co-management by a hematologist at an HTC and a dentist/oral surgeon (for both outpatient and hospital-based dental care) is preferred; the goal is to improve access and coverage, provide routine preventative dental care, and plan surgical procedures to eliminate the risk of bleeding-related complications and unnecessary expense associated with replacement factor therapy.



## Sickle Cell Disease

### BACKGROUND

Sickle cell disease (SCD) is the most common inherited blood disorder and affects up to 100,000 Americans. SCD results in an autosomal recessive hemolytic disease with systemic consequences. Patients with SCD are homozygous for hemoglobin S (HbS) and produce HbS instead of the normal HbA. HbS has a decreased oxygen-carrying capacity, and decreased oxygen tension causes sickling of red blood cells. Precipitating factors may include dehydration, acidosis, hypoxia, extreme temperatures, hypotension, stress, menstruation, fever, and infection. These sickle-shaped cells become trapped and block the flow in blood vessels. This results in painful episodes, severe or recurrent infections, splenic sequestration, pulmonary complications, and stroke. Over time, there is a progressive deterioration of cardiac, pulmonary, and renal function.

Patients with SCD typically have Hb levels of 6–9 g/dL (normal, 12–18 g/dL). Patients with SCD are treated with hydroxyurea in an attempt to increase their fetal Hb and prevent the formation of the HbS polymer. Patients may also benefit from monthly red cell exchange where the sickle-prone red cells containing HbS are removed and replaced with healthy donor red cells. Hematopoietic stem cell transplantation (HSCT) is the only available curative therapy.

Sickle cell trait is the result of a heterozygous state for HbS. Unlike SCD, sickle cell trait is usually benign with no restrictions on medical treatment or dental interventions. However, if sickle cell trait is co-inherited with another beta globin defect, the clinical course may match the severity seen in SCD.

### DENTAL MANAGEMENT

In addition to the acute and chronic manifestations already described, SCD also leads to complications of the dentition, jaw, and facial area. Management of dental disease is an important part of sickle cell care. The pediatric dental professional is a vital part of the multidisciplinary approach to the care of children and adolescents with SCD; however, very little guidance on dental care for this population has been published. Common dental complications include dental caries, dental hypomineralization, orofacial pain, neuropathy, facial swelling, malocclusions, infections, pulpal necrosis, cortical erosions, medullary hyperplasia, and abnormal trabecular spacing.<sup>78</sup> Pulp necrosis is the death of the dental pulp as a result of vascular occlusion of the dental microcirculation. Blood pigments are deposited in the dentin leading to discoloration of the affected teeth.

Radiographic changes are associated with SCD, particularly a generalized radiolucency and loss of trabeculae with prominent lamina dura, caused by increased erythropoietic demands that result in expansion of the marrow spaces. Bone growth may be decreased in the mandible, resulting in retrusion, and the teeth may be hypomineralized. There is a high incidence of malocclusions in patients with SCD. There is an increased incidence of overjet, higher angulation, and diastemas secondary to the compensating expansion of their bone marrow.<sup>79</sup> Occasionally, patients with

SCD have painful vaso-occlusions in the jaw, which may be mistaken for a toothache or osteomyelitis. Patients with SCD can experience dental pain with the absence of dental pathology.

The importance of an aggressive preventive program cannot be understated, and such a program should aim to maintain excellent oral health, decrease the possibility of oral infection, improve patient comfort, and increase the education of the patient, family, and health care team.

A small body of mid-level evidence on dental intervention suggests some guidance.<sup>78,80,81</sup> Dental treatment should not be initiated during a vaso-occlusive sickle cell crisis. If emergency treatment is necessary during a crisis, only treatment that will make the patient more comfortable should be provided. Patients with SCD may have skeletal changes that make orthodontic treatment beneficial. Special care must be taken to avoid tissue irritation, which may induce bacteremias, and the disease process may compromise the proposed treatment. Careful monitoring is a necessity when elective orthodontic treatment is proposed for patients with SCD.

Many patients with SCD have defective spleen function or undergo a splenectomy, which leaves them more vulnerable to infection because immunoglobulin production is decreased and phagocytosis of foreign antigens is thus impaired. Most patients with SCD are taking low-dose daily prophylactic antibiotics, and the need for additional antibiotics for dental procedures is debatable. Some authors have recommended the use of antibiotics for all dental procedures, whereas others recommend the administration of additional antibiotics when there is obvious dental or periodontal infection. The selection of an antibiotic is usually similar to that in cases of heart defect.

The use of local anesthetics with a vasoconstrictor is not contraindicated in patients with SCD. Some textbooks do recommend against the use of vasoconstrictors, although there is no evidence to support this practice. Similarly, the use of nitrous oxide is not contraindicated in these patients. Care must be taken in treating patients with SCD to avoid diffusion hypoxia at the completion of the dental procedure.

The restoration of teeth, including pulpotomies, is preferable to extraction. A pulpectomy in a nonvital tooth is reasonable if the practitioner is fairly confident that the tooth can remain noninfected. If the tooth is likely to persist as a focus of infection, then extraction is indicated.

The use of general anesthesia for dental procedures must be approached cautiously in consultation with the hematologist and anesthesiologist. The use of preoperative blood transfusion in patients with SCD to prevent perioperative complications has been controversial. Previously, the standard protocol was to perform a direct red blood cell transfusion or an exchange transfusion (repetitive withdrawal of small amounts of blood and replacement with donor blood until a large portion of the patient's blood has been exchanged) before general anesthesia. The goal of the transfusion is to increase the patient's Hb level to >10 g/dL and to decrease the HbS level below 40%. Transfusions do not provide complete protection against venous complications, but they may temporarily improve the patient's condition and reduce the hazards of surgery.

Current opinion is to weigh the risks associated with transfusion prior to anesthesia induction. Suggested

guidelines for performing a prophylactic transfusion before general anesthesia have been proposed. Patients with Hb level of <7 g/dL and a hematocrit of <20% may require a transfusion. Pediatric patients are usually less likely to have posttransfusion complications than are adults. A high frequency of hospitalizations is indicative of a more severe anemia, and such patients may require transfusion before surgery. Minor surgeries may not require a transfusion.<sup>80</sup>

## Childhood Cancers

Malignancy is the leading cause of death by disease in children past infancy, following injury (unintentional and intentional) in overall leading causes of death.<sup>82</sup> It is estimated that 15,590 children and adolescents will be diagnosed with cancer in 2018 and 1780 will die of their disease in the United States. Most common types of cancer in US children include leukemias, brain and central nervous system (CNS) tumors, and lymphomas, followed by soft tissue sarcomas, neuroblastoma, kidney tumors, germ cell tumors, and melanoma. Cancer treatments include chemotherapeutic agents, surgical resection, radiation, immunotherapy, and/or hematopoietic stem cell transplant. Management of dental disease and dental-related treatment complications is an important part of care during cancer treatment and through survivorship. As of January 1, 2015 (the most recent date for which data exist), about 429,000 survivors of childhood cancers were alive in the United States. This number will continue to rise as treatment of childhood cancers improves. Outcomes for children and adolescents with cancer have improved significantly. In the mid-1970s, 58% of children and 68% of adolescents with cancer survived at least 5 years after diagnosis. With improvement, in 2014, 83.4% of children and 84.6% of adolescents survived 5 years after diagnosis.<sup>83</sup> The most dramatic improvements in recent decades have been achieved in the treatment of leukemia, which is the most common childhood cancer.

### LEUKEMIA

Leukemias are hematopoietic malignancies in which abnormal leukocytes (blast cells) proliferate in the bone marrow, replacing normal cells, and disseminate into the peripheral blood, accumulating in other tissues and organs of the body.

Leukemia is classified according to the morphology of the predominant abnormal leukocytes in the bone marrow (Table 27.5). These types are further categorized as acute or chronic, depending on the clinical course and the degree of differentiation, or maturation, of the predominant abnormal cells.

Acute leukemia is the most common malignancy in children and adolescents, with about 4000 new cases diagnosed annually in the United States. Thus acute leukemia accounts for about one-third of all childhood malignancies; of these, approximately 75% are lymphocytic (acute lymphocytic leukemia, or ALL) and 25% are acute myelogenous leukemia (AML). Chronic leukemia in children is rare, accounting for less than 2% of all cases. The peak incidence of childhood leukemia is between 2 and 5 years of age. Although the cause of leukemia is unknown, ionizing

radiation, certain chemical agents, and genetic factors have been implicated. For example, children with chromosomal abnormalities (Down syndrome and Bloom syndrome), children with an identical twin who has leukemia, and children with immunologic disorders have an increased risk for leukemia.<sup>83</sup>

Clinical manifestations of acute leukemia are caused by the infiltration of leukemia cells into the tissues and organs. Infiltration and proliferation of leukemia cells in the bone marrow lead to anemia, thrombocytopenia, and granulocytopenia. Because these cytopenias develop gradually, the onset of the disease is frequently insidious. The history at presentation may reveal increased irritability, lethargy, persistent fever, vague bone pain, and easy bruising. Some of the more common findings on initial physical examination are pallor, fever, tachycardia, adenopathy, hepatosplenomegaly, petechiae, cutaneous bruises, gingival bleeding, and evidence of infection. In approximately 90% of the cases of acute leukemia, a peripheral blood smear reveals anemia and thrombocytopenia. In about 65% of cases the white blood cell count is low or normal, but it may be >50,000 cells/mm<sup>3</sup>.

When a new case of leukemia is diagnosed, the patient is hospitalized and therapy is directed toward stabilizing the patient, transfusing blood products to correct anemia and control bleeding, identifying and eliminating infection, evaluating renal and hepatic functions, and preparing the patient for chemotherapy. These interventions proceed while the definitive studies to determine the exact type of leukemia are undertaken, including a bone marrow aspiration for microscopic analysis, special cytochemical staining, immunophenotyping by flow cytometry, and cytogenetic analysis. The goal of treatment is to induce and maintain a complete remission, which is defined as lack of evidence of leukemia following treatment including resolution of signs and symptoms (e.g., adenopathy, hepatosplenomegaly, and petechiae), <5% blasts in the bone marrow, and normalization of peripheral blood counts. A complete molecular remission is the absence of leukemia cells after treatment using very sensitive laboratory techniques such as flow cytometry or polymerase chain reaction (PCR). Remission by this minimal residual disease (MRD) evaluation is a better prognostic factor than the previous definition of remission. Patients not in remission by MRD evaluation are more likely to experience leukemia relapse. Current clinical trials are investigating whether these patients could benefit from more intensive treatment.

The basic principle of treatment of ALL is substantially different from that for AML. In general, the treatment of AML is very intense and results in profound bone marrow hypoplasia, but the treatment duration is usually short (<1 year). The treatment of ALL is less intense but more prolonged (2.5–3.5 years).

Overall, the treatment regimens vary considerably depending on prognostic factors and the parameters being evaluated by the strategists' cooperative group (e.g., Children's Oncology Group). The initial phase of ALL treatment, *induction*, incorporates the use of a combination of antileukemic drugs at staggered intervals during a 4-week regimen (Table 27.6). This combination of drugs should rapidly destroy the leukemic cells yet maintain the regenerative potential of the nonmalignant hematopoietic cells within the bone marrow. About 95% of patients with ALL will be in

**TABLE 27.5** Childhood Leukemias

Type	Age and White Blood Cell Count (WBC) at Onset	Prognosis	Treatment
Acute lymphocytic leukemia	Peak age, 3–6 years	>95% remission induction, varies with age and presenting WBC count	Vincristine, L-asparaginase, prednisone, dexamethasone, 6-mercaptopurine, 6-thioguanine, methotrexate, daunomycin, doxorubicin, cytosine arabinoside [araC], cyclophosphamide
Standard risk	1–9 years with WBC <50,000/mm <sup>3</sup>	80%–90% EFS at 60 months	
Poor risk	>10 years or any age with WBC >50,000/mm <sup>3</sup>	50%–60% EFS at 60 months	
Infants	<1 year, any WBC	20%–30% EFS at 60 months	
Acute myelogenous (AML)		80% remission induction; 40% EFS at 36 months; >95% EFS in children with Down syndrome younger than 2 years	Cytosine arabinoside, daunomycin, etoposide, mitoxantrone,, 6-thioguanine, idarubicin, dexamethasone; hematopoietic stem cell transplantation*
Myelocytic (AML)	Older children and adolescents	Presence of favorable cytogenetic abnormality yields better outcome ~70% survival, whereas abnormalities of unfavorable cytogenetic abnormalities portend poor prognosis (20%)	
Monocytic or myelomonocytic (AmoL; AMML)	Infants and young children more common	~70% survival	
Promyelocytic	Uncommon; seen in older children	~70% survival	Responds to all transretinoic acid, idarubicin, and arsenic trioxide
Erythroleukemia	Very rare	Generally very poor	
Megakaryocytic leukemia	Very rare	Generally very poor, in young Down syndrome patients—excellent prognosis	
Chronic myelocytic leukemia (CML)			
Philadelphia chromosome-positive CML	Rare	Chronic phase about 2–4 years, then death in blast cell crisis, usually of AML, which is resistant to therapy; great improvement with dasatinib and imatinib	Dasatinib, imatinib, hydroxyurea; interferon alpha; hematopoietic stem cell transplantation†
Chronic lymphocytic	Not seen in children		

EFS, Event-free survival.

\*Sibling HLA-matched hematopoietic stem cell transplantation (HSCT) is considered the treatment of choice for most subtypes of acute myelogenous leukemia (AML). Each sibling has one chance in four of being a good match for transplantation. The patient is put into remission by standard chemotherapy before bone marrow transplantation. Of AML patients undergoing transplantation in first remission, 60% show no evidence of disease after 2 years.

†Hematopoietic stem cell transplantation has been the treatment of choice for adult and juvenile chronic myelocytic leukemia. Response to standard chemotherapy is generally poor. Dasatinib and imatinib, selective inhibitors of tyrosine kinase at the breakpoint cluster region on the *ABL* gene (causative abnormality in CML), are highly effective and well tolerated in all phases of CML when taken orally. Because long-term oral imatinib has been successful in children, the role and timing of HSCT is somewhat controversial in the treatment of childhood Philadelphia chromosome-positive CML. Transplantation for adult-type CML in the first chronic phase using a matched sibling donor gives 60% disease-free survival at 2 years.

Courtesy Dr. Kerry Hege, Dr. Randy Hock.

**TABLE 27.6** Major Chemotherapeutic Agents With Risk for Mucositis**AGENT**

Methotrexate  
Daunorubicin  
Doxorubicin  
Idarubicin  
Actinomycin D  
Cytosine arabinoside (AraC)  
Fluorouracil  
Melphalan

complete remission at day 28 of therapy. The second phase, *consolidation*, attempts to consolidate remission and intensify prophylactic CNS treatment. Prevention of CNS relapse uses intrathecally administered chemotherapy (methotrexate with or without cytosine arabinoside and hydrocortisone) to destroy leukemic cells within CNS. Methotrexate is

instilled directly into the lumbar spinal fluid because most antileukemic drugs do not readily cross the blood-brain barrier. Intensive intrathecal chemotherapy to prevent CNS relapse has replaced cranial irradiation for patients in the good and intermediate-risk groups of patients with ALL. However, both cranial irradiation and intrathecal chemotherapy are still used to prevent CNS relapse in high-risk patients with ALL. The third phase, *interim maintenance*, uses a combination of agents that are relatively nontoxic and requires only monthly visits to the outpatient clinic. In most cases, a fourth phase, *delayed intensification*, follows interim maintenance. This serves to intensify antileukemic therapy again after a short period of less intensive therapy. The addition of a late phase of intensive therapy substantially improves survival in patients with ALL. Following delayed intensification, a maintenance phase of therapy continues for 2 years for girls and 3 years for boys with a combination of oral and intravenous chemotherapeutic agents.



The prognosis for a child with acute leukemia has improved dramatically over the past several decades. About 35 years ago, there would have been little need to discuss dental treatment for a child with leukemia because the disease was invariably fatal—in most cases within 6 months of diagnosis. Today, with the development of new and better antileukemia drugs, advent of targeted therapies, use of intensive combination drug therapy, selective incorporation of radiation therapy for certain patients, and improvements in diagnostic techniques and general supportive care, the overall survival for children with standard risk ALL is now over 95%.

Pretreatment prognostic factors identify patients who are likely to benefit from either standard or more intensive therapy. Factors that identify patients who are likely to benefit from the type of therapy just outlined, which causes relatively minimal toxicity, are patient age between 1 and 10 years, a white blood cell count of  $<50,000/\text{mm}^3$ , favorable lymphoblast morphology, and absence of unfavorable cytogenetic abnormalities.

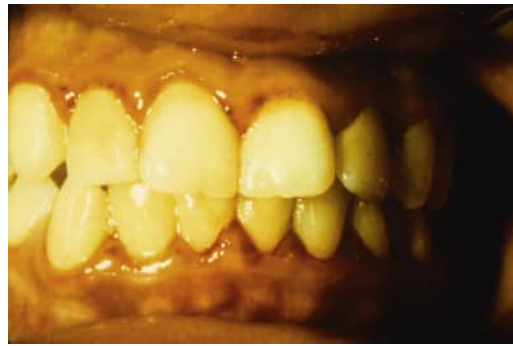Children with ALL, particularly those at high risk, are those who are younger than 1 year or older than 10 years of age at diagnosis, have a high initial white blood cell count, have unfavorable cytogenetic abnormalities, or have a persistence of identified disease after induction therapy. More aggressive treatment regimens are used for these patients.

The prognosis for children with AML has also improved significantly over the past several years, particularly for patients undergoing allogeneic HSCT from a matched sibling after achieving remission with chemotherapy. The treatment regimens are intrusive and result in profound bone marrow suppression. These patients have severe, prolonged neutropenia, necessitating long hospitalizations. They often have serious infections and severe mucositis.

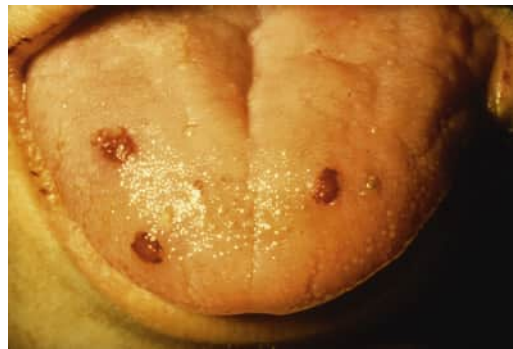### Oral Manifestations of Leukemia

Pathologic changes in the oral cavity as a result of leukemia occur frequently. Oral signs or symptoms suggestive of leukemia have been reported in as many as 75% of adults and 29% of children with leukemia. The lower incidence of oral manifestations in children can be attributed in part to the early age at diagnosis and the high percentage of ALL in the pediatric age group. The incidence of ALL peaks at 3 years of age, when preexisting oral inflammatory and degenerative changes are comparatively less frequent.

Abnormalities in or around the oral cavity occur in all types of leukemia and in all age groups. These abnormalities may be the result of direct invasion of tissue by leukemia cells or the result of anemia and thrombocytopenia resulting from the replacement of normal bone marrow elements by leukemia cells in the bone marrow. The most frequently reported oral abnormalities attributed to the leukemic process include regional lymphadenopathy, mucous membrane petechiae and ecchymoses, gingival bleeding, gingival hypertrophy, pallor, and nonspecific ulcerations. Manifestations seen occasionally are cranial nerve palsies, chin and lip paresthesias, odontalgia, jaw pain, loose teeth, extruded teeth, and gangrenous stomatitis. Regional lymphadenopathy is the most frequently reported finding. Gingival abnormalities, including hypertrophy and bleeding, are more common in patients with AML, whereas petechiae and ecchymoses are more common in those with ALL.



**Fig. 27.10** Petechiae along the gingival sulcus in a 14-year-old female with acute lymphocytic leukemia. (Courtesy Dr. Bruce W. Vash.)



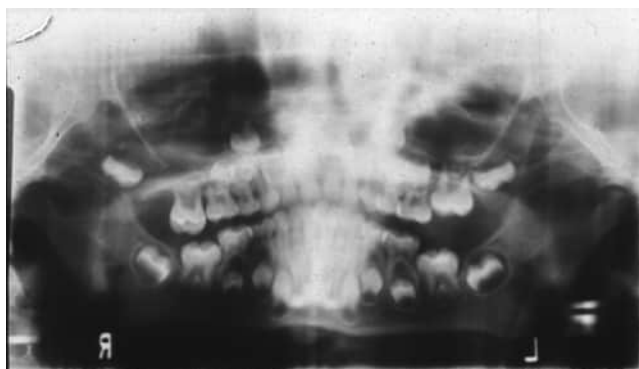**Fig. 27.9** Several small ecchymoses on the dorsal surface of the tongue in a 10-year-old female with acute lymphocytic leukemia. (Courtesy Dr. Bruce W. Vash.)

A person with severe thrombocytopenia, having lost the capacity to maintain vascular integrity, is likely to bleed spontaneously. Clinical manifestations are petechiae or ecchymoses of the oral mucosa or frank bleeding from the gingival sulcus (Figs. 27.9 and 27.10). The propensity for gingival bleeding is greatly increased in persons with deficient oral hygiene because accumulated plaque and debris are significant local irritants.

Direct invasion of tissue by an infiltrate of leukemic cells can produce gingival hypertrophy. Such gingival changes can occur despite excellent oral hygiene. Infiltration of leukemic cells along the vascular channels can result in strangulation of the pulpal tissue and spontaneous abscess formation as a result of infection or focal areas of liquefaction necrosis in the dental pulp of clinically and radiographically sound teeth. In a similar fashion, the teeth may rapidly loosen as a result of necrosis of the PDL.

Skeletal lesions caused by leukemic infiltration of bone are common in childhood leukemia. The most common finding is a generalized osteoporosis caused by enlargement of the Haversian and Volkmann canals. Osteolytic lesions resulting from focal areas of hemorrhage and necrosis and leading to loss of trabecular bone are also common.

Evidence of skeletal lesions is visible on dental radiographs in up to 63% of children with acute leukemia. Manifestations in the jaws include generalized loss of trabeculation, destruction of the crypts of developing teeth, loss of lamina dura, widening of the PDL space, and displacement of teeth and tooth buds (Fig. 27.11). Because none of the



**Fig. 27.11** Panoramic radiograph of a patient with acute myelocytic leukemia resulting in the displacement of the maxillary right permanent molar. (Courtesy Dr. Bruce W. Vash.)

### Box 27.1 Goals of Dental Care for Children with Leukemia

- Decrease morbidity and mortality due to infection
- Decrease morbidity due to hemorrhage
- Facilitate the patient's nutritional status
- Improve the patient's comfort
- Increase the education of the patient, family, and health care team

oral changes is a pathognomonic sign of leukemia and all can be associated with numerous local or systemic disease processes, a diagnosis of leukemia cannot be based on oral findings alone. Such changes should, however, alert the clinician to the possibility of malignancy as the underlying cause.

### Dental Management of Patients with Leukemia

The pediatric dental professional is a vital part of the multidisciplinary approach to the care of children and adolescents with cancer. The American Academy of Pediatric Dentistry supports this role on the treatment team and updates guidelines on the dental management of pediatric patients receiving chemotherapy, HSCT, and/or radiation therapy.<sup>84</sup> Appropriate dental management aims to decrease morbidity and mortality due to infection, decrease morbidity due to hemorrhage, facilitate the patient's nutritional status, improve patient comfort, and increase the education of the patient, family, and health care team, see [Box 27.1](#). A dental examination prior to the start of cancer therapy will identify and treat any existing dental concerns and offer an opportunity to educate the patient and family on the importance of basic oral care. Preventative strategies include oral hygiene, a noncariogenic diet, and the use of fluoride. If dental work is required for a child with leukemia, the child's hematologist/oncologist or primary care physician should be consulted. The following information should be ascertained:

1. Primary medical diagnosis.
2. Anticipated clinical course and prognosis.
3. Present and future therapeutic modalities.
4. Present general state of health.
5. Present hematologic status.

**TABLE 27.7** Clinical Importance of Platelet Count\*

Count (cells/mm <sup>3</sup> )	Significance
150,000–400,000	Normal
50,000–150,000	Bleeding time is prolonged, but patient would tolerate most routine procedures
20,000–50,000	At moderate risk for bleeding; defer elective surgical procedures
<20,000	At significant risk for bleeding; defer elective dental procedures

\*An absolute indication for platelet transfusion is significant bleeding. If the count is <20,000 cells/mm<sup>3</sup>, the patient should be given prophylactic platelet transfusion before dental procedures. Indiscriminate use of platelet therapy may lead to the development of antiplatelet antibodies. Courtesy Dr. Thomas D. Coates.

It is also important to establish, by consultation with the patient's physician, when dental treatment may be most propitious and to schedule the patient's treatment accordingly.

For a child whose first remission has not yet been attained or one who is in relapse, all elective dental procedures should be deferred. However, it is essential that potential sources of systemic infection within the oral cavity be controlled or eradicated whenever they are recognized (e.g., immediate extraction of carious primary teeth with pulpal involvement).

Routine preventive, restorative, and surgical procedures can usually be provided for a patient who is in complete remission yet is still undergoing chemotherapy. The time when such procedures may be completed without complications will depend on the specific agents administered and the time of administration. Prior to the appointment, preferably the same day, a blood cell profile (complete blood count) and platelet count should be obtained to confirm that the patient is not unexpectedly at undue risk for hemorrhage or infection. A patient who has been in complete remission for at least 2 years and no longer requires chemotherapy may be treated in an essentially normal manner. A preappointment blood workup is not necessary.

Pulp therapy in primary teeth is not usually recommended in a patient with a history of leukemia.<sup>85</sup> Endodontic treatment for permanent teeth is not recommended for any patient on therapy for leukemia due to suppression of granulocytes. Even with the most exacting technique, an area of chronic inflammatory tissue may remain in the periapical region of endodontically treated teeth. An area of low-grade, chronic inflammation in a healthy patient is generally well tolerated, but in an immunosuppressed, neutropenic patient, the same area can act as an anachoretic focus with devastating sequelae. The decision to perform an endodontic procedure on a patient who has been in prolonged complete remission and who is not undergoing chemotherapy must be made by the dentist in collaboration with the child's hematologist/oncologist.

A platelet level of 100,000/mm<sup>3</sup> is adequate for most dental procedures ([Table 27.7](#)). Routine preventive and restorative treatment, including nonblock injections, may be considered when the platelet count is at least 50,000/mm<sup>3</sup>. With inadequate oral hygiene, unhealthy periodontal tissues, and the presence of local irritants, hemorrhage from the gingival sulcus may be

**TABLE 27.8** Clinical Importance of White Blood Cell Count

ANC	Significance
>1500	Normal
500–1000	Patient at some risk for infection; defer elective procedures that could induce significant transient bacteremia
200–500	Patient must be admitted to hospital if febrile and given broad-spectrum antibiotics; at moderate risk for sepsis; defer all elective dental procedures
<200	At significant risk for sepsis

ANC, Absolute neutrophil count.

ANC is computed as follows:  $ANC = (\% \text{ of polymorphonuclear leukocytes} + \% \text{ of bands}) \times \text{total white blood cell count} \div 100$ .

Courtesy Dr. Thomas D. Coates.

observed when platelet counts are between 20,000 and 50,000/mm<sup>3</sup>. Such hemorrhaging is usually noted only after manipulation of the tissues, such as during toothbrushing. If the platelet count is lower than 20,000/mm<sup>3</sup>, all the intraoral mucosal tissues may show clinical evidence of spontaneous hemorrhaging (e.g., petechiae, ecchymoses, or frank hemorrhage). No dental treatment should be performed at such a time without a preceding prophylactic platelet transfusion. Good oral hygiene must be maintained while the platelet count is at this level, but it may be necessary to discontinue the use of a toothbrush and to substitute cleaning with moist gauze wipes, supplemented by frequent saline rinses.

The absolute neutrophil count (ANC) is an indicator of the host's ability to suppress or eliminate infection. It is calculated by the following formula:

$$ANC = (\% \text{ of neutrophils} + \% \text{ of bands}) \times \text{total white blood cell count} \div 100$$

The clinical significance of ANC is presented in [Table 27.8](#). If ANC is <1000/mm<sup>3</sup>, elective dental treatment should be deferred. A leukemic patient with a low ANC may require prophylactic broad-spectrum antibiotic therapy before certain dental procedures. The patient's physician should be consulted regarding the appropriate drugs and dosages.

Infection and hemorrhage are the primary causes of death other than resistant disease or relapse in children with leukemia. Therefore, the primary objective of dental treatment in a child with leukemia should be the prevention, control, and eradication of oral inflammation, hemorrhage, and infection.

Frequently, initial oral manifestations of bleeding or infection are observed in association with an unhealthy periodontium. In patients with leukemia who are neutropenic or who are being treated with corticosteroids, the true degree of periodontal inflammation or infection may be masked because the cardinal signs of inflammation, such as redness, swelling, or warmth, may not be apparent. There is a much greater propensity for gingival bleeding when the periodontium is unhealthy. When oral hygiene is neglected and local irritants are present, spontaneous hemorrhaging from the gingival sulcus may be observed if the patient is thrombocytopenic.

It is imperative that a patient who is diagnosed with leukemia be enrolled in a good preventive dental care program in which special emphasis is placed on the initiation and maintenance of a comprehensive oral hygiene regimen. The use of a soft nylon toothbrush for the removal of plaque is recommended, even if the patient is thrombocytopenic. As long as the gingiva remains in a healthy state and its manipulation by brushing does not induce significant hemorrhage, it is not appropriate to discontinue the use of a toothbrush because of the platelet level alone. The practicality of flossing must be assessed on an individual basis.

Significant local irritants, including orthodontic appliances, should be considered for removal. Scaling and subgingival curettage should not necessarily be perceived as elective dental treatment in all patients. This is especially true if the anticipated clinical course may place the patient at high risk for hemorrhage and infection. Patients with classic leukemic gingivitis experience various degrees of discomfort. The use of warm saline rinses several times each day may assist in the relief of symptoms.

### Prevention and Management of Mucositis

Erosive or ulcerative lesions called mucositis are common in children with leukemia. These lesions are often associated with granulocytopenia and the use of certain chemotherapeutic agents ([Table 27.6](#)), especially methotrexate and the anthracycline antibiotics daunomycin and doxorubicin. The lesions may be an early indicator of drug toxicity. After administration of the drug is discontinued and ANC has recovered, these lesions usually disappear within a few days. Treatment is directed toward palliation and the prevention of secondary infection and may include the use of topical obtundents and/or systemic analgesics.

An expert panel has recently reviewed the literature evaluating basic oral care interventions and management approaches to prevent and treat oral mucositis in cancer patients. The resulting guideline includes support for multimodality basic oral care. It supports regular assessment of the oral cavity, continued tooth brushing during cancer therapy, and the use of bland rinses to increase clearance of oral debris, promote oral hygiene, and provide comfort during cancer care. The panel also finds patient education on oral care an integral component of overall patient care. Evidence from high-quality studies, however, is limited, and the panel failed to find clear evidence to support the use of chlorhexidine for the prevention of mucositis in patients receiving head and neck radiotherapy, or to support the use of antimicrobials and sucralfate for the prevention of radiation- or chemotherapy-induced mucositis.<sup>86</sup> Nor could the panel comment on the benefits of cryotherapy; however, some evidence shows benefits of oral cold therapy with ice chips, popsicles, and cold drinks to vasoconstrict during rapid infusion of chemotherapeutics known to cause oral mucositis.<sup>87</sup> This same expert panel could not develop guidelines for the use of mixed-medication mouthwashes (such as Mary's Magic Mouthwash; [Table 27.9](#)). However, many clinicians believe that using these customized medication mouthwashes can provide comfort. The efficacy of each will vary among patients, and in some cases only potent systemic analgesics will provide relief.

Oral candidiasis can be seen in children with leukemia. They are especially susceptible to this fungal infection



**TABLE 27.9** Topical Obtundents for Oral Pain (Frequently Used at Riley Hospital for Children at IU Health)

Combination	Administration	Indications
<b>BENACORT-TETRASTAT (MARY'S MAGIC MOUTHWASH)</b>		
Hydrocortisone powder 60 mg Tetracycline 1.5 g Nystatin suspension 100,000 U/ mL 60 mL Benadryl elixir qs 240 L	Swish 5–10 mL for 1 minute; then expectorate	Generalized stomatitis and mild discomfort
<b>PHILADELPHIA MOUTHWASH*</b>		
Benadryl elixir 90 mL Maalox suspension 90 mL Viscous lidocaine 2% 90 mL Distilled water 180 mL Cherry or vanilla flavoring to taste	Swish 5–10 mL for 1 minute; then expectorate	Generalized stomatitis and mild discomfort

\*Use should be supervised to prevent lidocaine toxicity.

because of (1) general physical debilitation, (2) immunosuppression, (3) prolonged antibiotic therapy, (4) chemotherapy, and (5) poor oral hygiene. The following topical use of nystatin can be particularly beneficial:

- Nystatin oral suspension, 100,000 units/mL
- Swish 5 mL for 5 minutes and then swallow (2 mL for neonates and infants)
- Repeat every 6 hours; continue for 48 hours after lesions disappear.

In more resistant cases of oral candidiasis, fluconazole may be useful, administered once daily either orally or intravenously (in young children, 6 mg/kg/dose on day 1, then 3 mg/kg/dose; in older children and adults, 200 mg on day 1, then 100 mg daily).

For patients who are thrombocytopenic or at risk for intermittent episodes of thrombocytopenia because of chemotherapy or active disease, the dentist should avoid prescribing drugs that may alter platelet function, such as salicylates (aspirin) and NSAIDs.

### Hematopoietic Stem Cell Transplantation

The transplantation of hematopoietic stem cells can be curative for a variety of disorders, including aplastic anemia, thalassemia, SCD, metabolic disorders, immunodeficiencies, and disorders of immune dysregulation. HSCT has also been shown to be effective as rescue therapy for patients undergoing extremely aggressive treatment for leukemia in which both lethal doses of chemotherapy and total body irradiation (TBI) are used to destroy all bone marrow elements, including normal marrow cells. Intensive chemotherapy, TBI, and stem cell rescue are being used in the treatment of very aggressive malignancies (e.g., advanced neuroblastoma and Ewing sarcoma).

As with any organ transplantation, HSCT candidates must have a compatible donor. Suitable stem cell donors may include HLA-compatible siblings or parents, or matched unrelated donors. In some situations, placental cord blood can be used. In certain cases, autologous transplantation is performed in which the patient's own bone marrow or peripheral blood stem cells are harvested, stored, and then returned to the patient after intensive treatment has been provided.

During and after HSCT, the most common cause of serious morbidity and mortality is infection. Despite multiagent antibacterial, antifungal, and antiviral therapy, endogenous opportunistic organisms are usually the cause of life-threatening infection in HSCT patients; because of ablated bone marrow function, these patients are unable to mount protective inflammatory and immune responses before engraftment of donor bone marrow.

### Oral Complications of Bone Marrow Transplantation

The oral complications of bone marrow transplantation differ from those seen during conventional therapy for malignant disease only in degree and duration. Oral ulceration, mucositis, and transient salivary gland dysfunction are frequent consequences of stomatotoxic chemotherapy and TBI. Minor trauma to atrophic mucous membranes often results in self-induced ulceration of the buccal mucosa, lips, and tongue. Thrombocytopenic gingival bleeding and bleeding from oral ulcerations are also frequently encountered.

Oral bleeding responds well to platelet transfusions and intravenous aminocaproic acid (Amicar). Topical application of Avitene (bovine corium collagen hydrochloride), powdered thrombin, and pressure are often effective for control of localized bleeding and often must be relied on in those cases in which the patient fails to respond to transfused platelets.

### Graft-Versus-Host Disease

A major problem of allogeneic bone marrow transplantation is the development of graft-versus-host disease (GvHD). This disorder appears to result from an interaction between donor immunocompetent cells and recipient cells that display disparate antigens. The acute form of the disease involves the lymphoid system, skin, liver, and gastrointestinal tract. Cutaneous and oral mucosal involvement in chronic GvHD is common and is manifested as painful overt mucosal erythema, reticular or lichenoid eruptions, or desquamation and ulceration. Treatment with dexamethasone oral rinses may be helpful in cases of severe mucosal involvement in chronic GvHD. Mucosal involvement may be accompanied by salivary gland dysfunction with xerostomia, dysphagia, and dysgeusia.

Treatment of both acute and chronic GvHD is directed at correcting, masking, or preventing disordered immune regulation. Therapies with low- and high-dose steroids (prednisone, dexamethasone), antithymocyte globulin, cyclosporin, azathioprine, or methotrexate have been attempted with mixed results. Although severe acute GvHD can be rapidly fatal, chronic GvHD is usually transient and controllable with systemic therapy. The goals of therapy for mucosal and salivary gland manifestations, which relies on abundant rinses, are palliation and the prevention of secondary infection. Of note, the positive side of GvHD is an associated graft-versus-leukemia effect. In both acute and chronic GvHD, the immune response associated with GvHD appears to affect leukemia cells in that there is an inverse relationship between the severity of GvHD and the incidence of relapse.

### Pretransplantation Preparation

Bone marrow transplantation programs place a high priority on pretransplantation dental care and daily mouth care in the transplant unit. The primary goal of this oral health care protocol is to prevent, reduce in severity, or palliatively relieve oral problems involved in the oral care of patients receiving oncologic therapy. The integrity of the oral cavity is maintained by keeping the oral structures, both hard and soft tissues, clean, moist, and free of infection. The resultant decrease in septic episodes in the oral cavity should diminish the patient's morbidity and mortality because the mouth is the most common source of infection in these patients.

Four weeks before bone marrow transplantation, all candidates for this procedure should receive a thorough clinical and radiographic oral examination during the workup phase initiated from the oncology physician's consult. The resultant dental treatment plan, along with the primary goals of oral health care, is discussed with the patient's oncologist, the patient, and the parents. Each patient is also informed of all potential oral complications of bone marrow transplantation and GvHD.

Along with professional preventive dental care, each patient should receive instruction in daily mouth care, including brushing and flossing. The daily use of self-applied topical fluoride gel and Peridex rinse (every 12 hours) is recommended. Dental appointments are scheduled for any necessary periodontal, restorative, or oral surgery treatment, if indicated, to eliminate and control oral infections or conditions that may lead to episodic problems. Potential foci of infection or bleeding, such as pulpally involved teeth, periodontally involved teeth, partially erupted teeth, exfoliating primary teeth and carious teeth, or teeth with defective restorations, must be treated before the patient's admission to the transplant unit. Recommended treatment should ideally be completed at least 2 weeks before admission to allow for healing of violated tissues and the reestablishment of optimal oral hygiene.

Unfortunately, there are times when the patient's medical status necessitates admission for transplantation before all dental treatment can be completed. Therefore, the minimum preadmission dental requirement is a mouth free of foci of acute infection and free of physical irritants. Each patient must receive thorough supragingival and subgingival scaling and prophylaxis; open caries lesions and caries lesions approaching the pulp must be restored, and abscessed teeth, teeth with severe periodontal involvement, and exfoliating primary teeth causing gingival irritation must be removed.

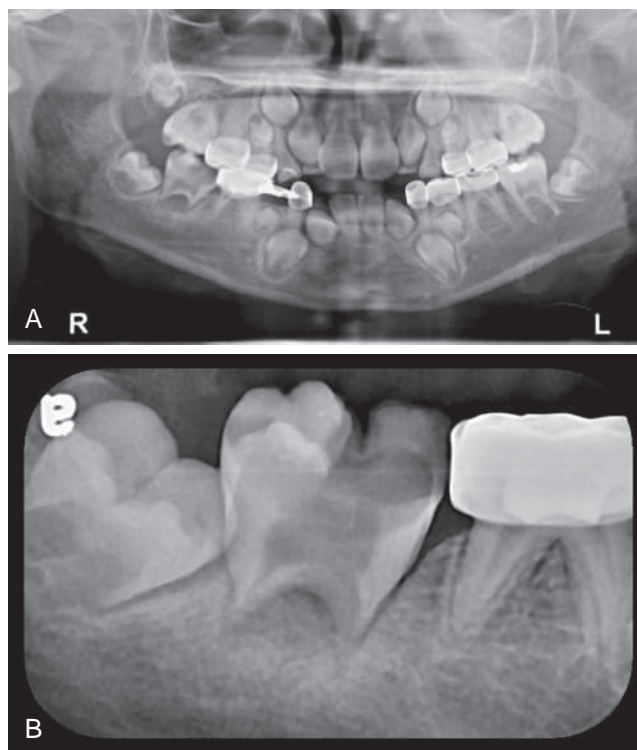
### SOLID TUMORS

Solid tumors account for approximately half of the cases of childhood malignancy. The most common tumors include brain tumors, lymphoma, neuroblastoma, Wilms' tumor, osteosarcoma, and rhabdomyosarcoma. Because many of the malignancies can involve bone marrow and their treatment with chemotherapy and radiation can suppress marrow function, many of the complications seen in acute leukemia are also seen with these patients. Bleeding diatheses and the propensity to infection are the most notable medical complications seen. In general, the dental management of patients with solid tumors is similar to that of patients with acute leukemia.

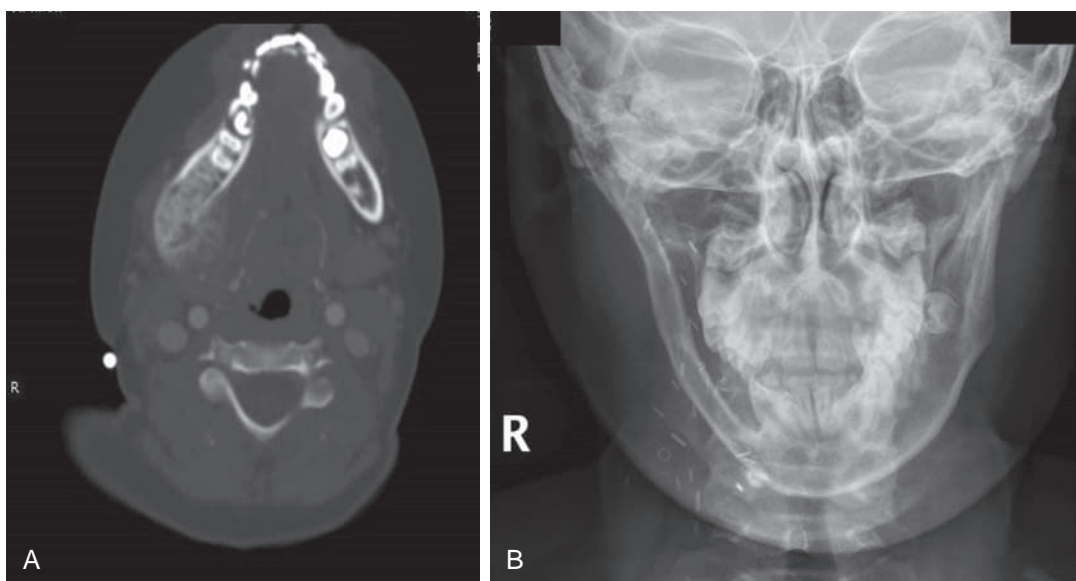
### MANAGEMENT OF CHILDHOOD CANCER SURVIVORS

Childhood cancer survivor rate has drastically improved and continues to increase with improvements in early diagnosis, treatment advances, and improved supportive care. Many patients are still in childhood when they become childhood cancer survivors. As mortality outcomes improve, research focus shifts to minimizing toxicity and adverse effects of therapy. Chemotherapeutic agents, surgery, and radiation result in dental defects for many childhood cancer survivors. Systematic review of the literature on late effects of chemotherapy and radiation on dental structures of childhood cancer survivors found treatment effects on both the root and the crown of teeth, with root defects being more common. The most common crown defect in this review was microdontia. Defects such as microdontia, V-shaped roots, and taurodontism were associated with younger age at diagnosis. The location and dose of radiation were the only treatment characteristics that affected the prevalence of dental defects.<sup>88</sup> Treatments may also lead to tooth/root agenesis, root thinning/blunting, enamel dysplasia, dental agenesis, ectopic molar eruption, dental caries, periodontal disease, malocclusion, xerostomia, temporomandibular joint dysfunction, osteoradionecrosis of the jaw, or oral cancer.

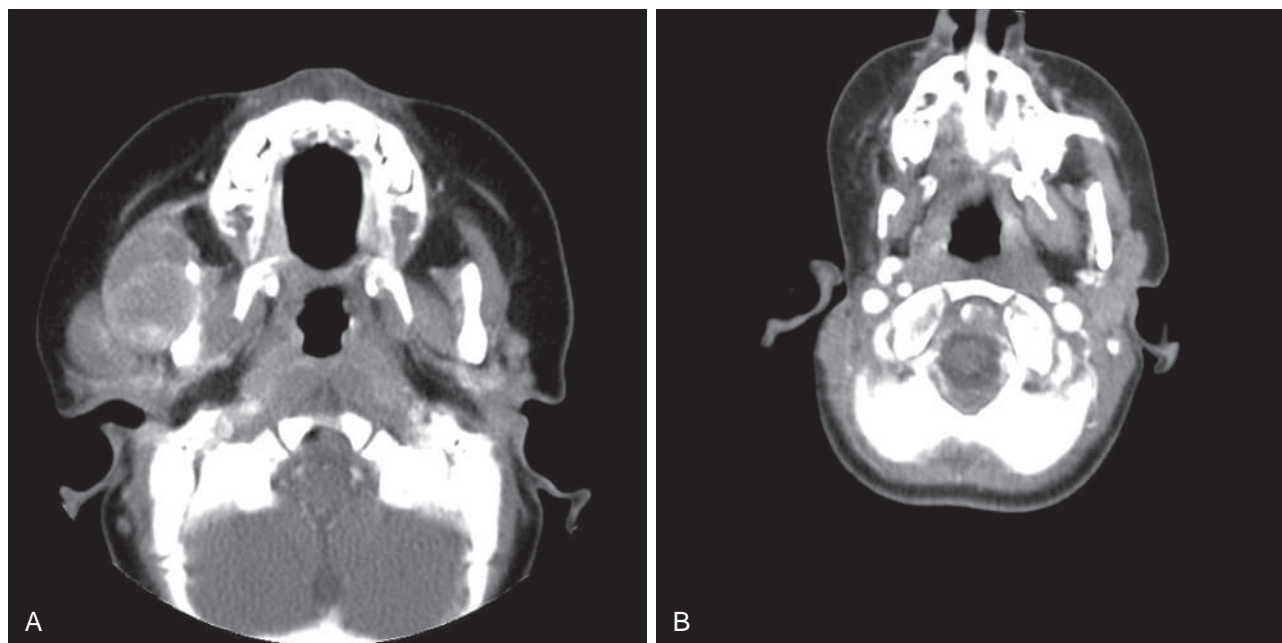
Fig. 27.12A and B shows late effects of chemotherapy with panoramic and periapical radiograph of a pediatric survivor of high-risk neuroblastoma with arrested blunted roots. Fig. 27.13A and B shows late effects of surgery in a child with a tumor of the right mandible before and



**Fig. 27.12** Late effects of chemotherapy. (A) Panoramic radiograph of a survivor of high-risk neuroblastoma showing arrested, blunted roots. (B) Periapical radiograph of the same patient highlighting the blunted roots. (Courtesy Dr. Terry Vik.)



**Fig. 27.13** Late effects of surgery. (A) Computed tomography image showing tumor of the right mandible. (B) Radiograph of the same patient taken after tumor resection and mandible replacement with a resected rib. (Courtesy Dr. Terry Vik)



**Fig. 27.14** Late effects of radiation. (A) Computed tomography (CT) image showing rhabdomyosarcoma of the right masseter muscle. (B) CT image of the same patient 3 years after chemotherapy and radiation showing hypoplasia of the right mandible. (Courtesy Dr. Terry Vik)

after tumor resection and mandible replacement with a resected rib. **Fig. 27.14A and B** shows late effects of radiation with hypoplasia of the mandible following therapy for rhabdomyosarcoma.

The Children's Oncology Group sets evidence-based and expert panel consensus guidelines on the long-term follow-up and surveillance of childhood cancer survivors. In addition to dental examination and cleaning every 6 months, guidelines recommend a thorough oral exam annually, regular dental care including fluoride applications, and baseline imaging prior to any dental procedure to evaluate root development. Any patient who had not yet developed

permanent dentition at the time of cancer therapy, younger age at treatment, any radiation treatment involving the oral cavity or salivary gland, and patients experiencing GvHD are at increased risk of adverse dental effects.<sup>89</sup> Osteoradionecrosis is a unique complication of impaired bone healing in patients who have received high doses of radiation (>40 Gy, especially >50 Gy), particularly to the mandible. Osteoradionecrosis is uncommon but most often occurs following dental extraction or other surgery involving the mandible. This can occur months to years following radiation exposure. Radiation can decrease a bone's blood supply leading to impaired healing and necrosis of



the bone tissue. Symptoms may include jaw pain, swelling, trismus, or signs of infection. Imaging studies may assist in making the diagnosis; biopsy may be required to confirm the diagnosis. Treatment is mainly symptom control of pain; antibiotics may be needed if an infection is present, and hyperbaric oxygen therapy may increase the oxygen delivery to healing tissues. [Table 27.10](#) outlines risk-based, exposure-related clinical practice guidelines for screening and management of late effects in survivors of pediatric malignancies.

## Viral Hepatitis

Infection by the various strains of viral hepatitis causes inflammation of the liver parenchyma, which may lead to necrosis or cirrhosis. Acute hepatitis classically presents with lethargy, loss of appetite, nausea, vomiting, and abdominal pain, but may not be recognized until jaundice ultimately develops.

Acute viral hepatitis may be caused by any of the following: hepatitis A virus (HAV), HBV, HCV, hepatitis delta virus (HDV), or hepatitis E virus (HEV).

HAV infection results in an acute febrile illness with jaundice, anorexia, nausea, and malaise. Most HAV infections in infants and children cause mild, nonspecific symptoms

without jaundice. HAV is spread by the fecal-oral route and is endemic in developing areas. Spread occurs readily in households and daycare centers, where symptomatic illness occurs primarily among adult contacts with children. No HAV carrier state exists, and the presence of immunoglobulin G–anti-HAV indicates past infection and lifelong immunity to HAV. The risk for transmission in a dental setting is low. A two-dose vaccination series separated by 6 months can be given to anyone older than 1 year.

The transmission of HBV is of major concern to the dentist. Members of the dental profession assume a risk for acquiring HBV that may be 10 times greater than that of the general population.<sup>90</sup> An additional concern is the potential of becoming an asymptomatic yet infectious carrier of HBV and of having the capability of transmitting the disease to patients and dental staff members and family. HBV is transmitted from person to person by parenteral, percutaneous, or mucous membrane inoculation. It can be transmitted by the percutaneous introduction of blood, administration of certain blood products, or direct contact with secretions contaminated with blood containing HBV. Infection may also result from inoculation of mucous membranes, including sexual transmission. Wound exudates contain HBV, and open-wound to open-wound contact can transmit infection. There can also be vertical transmission from an infected mother to her baby, which frequently leads to chronic infection.

**TABLE 27.10** Risk-Based, Exposure-Related Clinical Practice Guidelines for Screening and Management of Late Effects in Survivors of Pediatric Malignancies. Adapted from Children's Oncology Group (reference G)

Therapy Exposure	Potential Late Effects	Periodic Evaluation	Further Considerations
Any Chemotherapy	Tooth/root agenesis Root thinning/blunting Enamel dysplasia Microdontia Ectopic molar eruption Dental caries	Physical Examination: Oral examination Yearly Screening: Dental examination and cleaning Every 6 months	Regular dental care including fluoride applications Baseline panorex prior to dental procedures to evaluate root development
Radiation Head/brain Neck Spine (cervical, whole) Total body irradiation (TBI)	Xerostomia Salivary gland dysfunction	Physical Examination: Oral examination  Yearly Screening: Dental examination and cleaning Every 6 months	Regular dental care including fluoride applications Supportive care with saliva substitutes, moistening agents, and sialagogues
	Tooth/root agenesis Root thinning/blunting Enamel dysplasia Microdontia Ectopic molar eruption Dental caries Periodontal disease Malocclusion Temporomandibular joint dysfunction	Physical Examination: Oral examination Yearly Screening: Dental examination and cleaning Every 6 months	Regular dental care including fluoride applications Baseline panorex prior to dental procedures to evaluate root development Special attention for dental procedures involving irradiated mandible (see below)
(this section is not applicable to patients who received TBI alone)	Osteoradionecrosis of the jaw	Physical Examination: Radiation dose >40 Gy Impaired healing following dental work Jaw pain or swelling Trismus	Imaging studies may assist in making the diagnosis Biopsy may be required to confirm the diagnosis Hyperbaric oxygen treatments before or after mandibular surgery may facilitate oxygen delivery and healing
Hematopoietic Stem Cell Transplantation (especially with any history of chronic graft-versus-host disease)	Xerostomia Salivary gland dysfunction Dental caries Periodontal disease Oral cancer (squamous cell carcinoma)	Physical Examination: Oral examination Yearly Screening: Dental examination and cleaning Every 6 months	Regular dental care including fluoride application and screening for intraoral malignancy Supportive care with saliva substitutes, moistening agents, and sialagogues

A medical history is unreliable in identifying patients who have HBV infection because approximately 80% of all HBV infections are undiagnosed. However, the medical history is useful in identifying groups of patients who are at higher risk of being undiagnosed carriers. Among populations at high risk for HBV infection are patients undergoing hemodialysis, patients requiring frequent large-volume blood transfusions or administration of clotting factor concentrates, residents of institutions for those with mental disabilities, and users of illicit injectable drugs.

In 2016 an estimated 20,000 people in the United States became infected with HBV, and an estimated 1–2 million chronically infected people live in the United States. Overall, chronic HBV claims nearly 1700 lives per year in the United States.<sup>91</sup> Chronic active hepatitis develops in more than 25% of carriers and often progresses to cirrhosis. Furthermore, HBV carriers have 12–300 times higher risk of developing primary liver cancer than uninfected individuals.

For detection of acute or chronic HBV infection, the serologic test for hepatitis B surface antigen (HBsAg) is most commonly used. The antibody to surface antigen (anti-HBs) is protective and indicates a resolved natural infection or successful vaccination. Antibody to the core antigen (anti-HBc) indicates exposure to natural HBV but can be present in either resolved or chronic infection. The hepatitis B “e” antigen (HBeAg) is a useful marker for infectivity. Patients who test positive for anti-HBe and HBsAg are most likely to transmit the disease. If the patient still shows a positive test result for HBsAg 6 months after an acute HBV infection, the patient is considered to be chronically infected. Chronic infection is less likely the older the patient at the time of exposure, hence the mandate to vaccinate children shortly after birth.

The availability of a safe, effective HBV vaccine affords the dentist and staff additional protection against acquiring HBV infection. HBV vaccine is recommended for all health care personnel. The vaccine is derived using recombinant DNA and therefore does not have the potential to transmit the disease. When administered in a three-dose injection regimen (0, 1, 6 months), the recombinant DNA vaccine induces protective antibody (anti-HBs) in 95% to 100% of adults.

A fulminant type of hepatitis occurs with infection by HDV but only with coexisting or simultaneous infection with HBV. HDV is defective in that it requires HBV for outer coat proteins (HBsAg) as well as for replication. Like HBV, the transmission of HDV is by parenteral, percutaneous, or mucous membrane inoculation.

As there is no available immunization against HCV, it is of similar concern for the dentist because of its transmission via exposure to infectious body fluids. Patients at risk for HCV include those who received blood transfusions or organ transplants before 1992, those who received clotting factors before 1987, those on long-term dialysis, and most commonly those who have experimented with illicit intravenous drugs, regardless of how many times or how long ago. Infection associated with injection drug use accounts for more than 50% of the new cases in the United States. Of those infected, chronic infection develops in 70% to 85%, and chronic liver disease develops in about 70%. Although only 3% of infected people die of liver failure, HCV is the leading reason for liver transplantation in adults in the United States.<sup>92</sup>

In 1989, parenterally transmitted non-A non-B (NANB) was identified as HCV. Subsequently, six genotypes have

been identified. Diagnosis is made by detection of antibody to HCV (anti-HCV) in the serum and can be confirmed by radio-immunoblot assay. PCR testing can be done qualitatively to confirm diagnosis or quantitatively to assess the response to treatment. Treatment historically included administration of interferon or pegylated interferon with or without ribavirin, with response rates varying based on the viral genotype. Newer agents such as simeprevir, a NS3/4A protease inhibitor, and sofosbuvir, a nucleotide analog NS5B polymerase inhibitor, have been shown to be effective agents in combination, and are transforming care for patients with HCV, especially for those not eligible for interferon.<sup>93</sup> In 2014, the Centers for Disease Control and Prevention estimated that there were 30,000 new cases of infection with HCV in the United States, down from 240,000 per year in the 1980s.<sup>94</sup> There are nearly 4 million people infected with HCV in the United States (1.6%). Of the chronically infected, approximately 16,000 patients die per year. Enterically transmitted NANB has been identified as the HEV. Transmission is by the fecal-oral route. Large, well-documented outbreaks have been seen worldwide and can be found in the returning traveler.<sup>95</sup> There appears to be a 6- to 8-week incubation period and a low incidence of carrier state after infection. However, a high fatality rate (10%–20%) is seen in women who contract this virus in their third trimester of pregnancy.<sup>96</sup> There is no immunization available against this pathogen.

## Acquired Immunodeficiency Syndrome

Acquired immunodeficiency syndrome (AIDS) is a clinically defined condition caused by infection with HIV type 1 or, much less commonly, type 2. In 2015, it was estimated that nearly 1.1 million people in the United States are infected with HIV and approximately 57% of them do not know their status.<sup>97</sup>

The period of time from HIV infection to the appearance of symptoms consistent with AIDS can be approximately a decade in many adults. Consequently, HIV-infected individuals can unknowingly spread the virus to their sexual or needle-sharing partners or, in the case of infected mothers, to their children.

HIV infects cells of the immune system, specifically lymphocytes and macrophages. These leukocytes contain the greatest number of CD4 cell-surface receptors (glycoproteins), which permit attachment with viral surface proteins (GP120). Under the control of the HIV *pol* gene, the virus produces the enzyme reverse transcriptase, which is essential for incorporating viral RNA into host nuclear DNA. The viral genome is integrated into the host-cell genome and leads to progressive and eventually irreversible immunosuppression by producing more viruses and further killing the CD4 lymphocytes that are important modulators of the immune system. The subsequent immunodeficiency results in various opportunistic infections, malignancies (e.g., Kaposi sarcoma and lymphoma), and autoimmune diseases. Diagnosis is made by screening the serum for antibodies to HIV and is confirmed by a second methodology such as Western blot analysis or PCR. Ongoing management is guided by the patient's CD4<sup>+</sup> cell count and viral load as measured by PCR. The former is an indication of the patient's immune status, whereas a higher viral load is associated with a more

accelerated disease. The current antiretroviral drugs target the virus at several steps: (1) the adhesion of the virus to the chemokine receptor CCR5, (2) the fusion of the virus to the host cell (fusion inhibitors), (3) the integration of viral genes into the target cell (integrase inhibitors), (4) the transcription of DNA from viral RNA by reverse transcriptase (nucleoside, nonnucleoside, and nucleotide reverse transcriptase inhibitors), and (5) the cleavage of viral proteins by the viral protease enzyme (protease inhibitors). The most effective treatment strategies use a combination of several drugs to inhibit the virus at several steps.

In the United States, nearly 82% of newly infected men diagnosed in 2017 acquired HIV through homosexual contact, infections through illicit drug use accounted for 4% of new cases, and 9% of infections were acquired through heterosexual contact.<sup>98</sup> Among infected women in the United States, 80% acquired HIV through heterosexual contact and 19% through intravenous drug use. Almost 30% of newborns of untreated HIV-infected mothers can acquire HIV through vertical transmission. However, treatment of pregnant women with antiretroviral medications, including zidovudine, has decreased the rate of transmission by 70%. The onset of symptoms is shortened in children who have acquired their infection prenatally and go untreated. Only 75% of untreated babies survive to age 5 years, and by that age 50% have severe symptoms. Now individuals infected with HIV are treated with highly active antiretroviral therapy (HAART), providing a combination of agents to target different stages of the viral life cycle concomitantly, making what was once a terminal diagnosis into a manageable infection.<sup>99</sup>

Infants and children with AIDS have clinical findings similar to those in adults. Early manifestations of untreated HIV infection include weight loss and failure to thrive, hepatomegaly or splenomegaly, generalized lymphadenopathy, and chronic diarrhea. Unlike in adults, recurrent and severe bacterial infections are more common in pediatric patients with untreated HIV infection, especially *Pneumocystis jirovecii*.

## ORAL MANIFESTATIONS OF HIV INFECTION

The types of oral lesions seen in HIV infection may be caused by fungal, viral, or bacterial infections, as well as neoplastic and idiopathic processes. HIV infection predisposes this population of patients to a greater severity of conventional periodontal problems. On review of the charts of some 2500 adult patients living with HIV, Fox et al.<sup>100</sup> found that a slim majority had not received dental care in more than 2 years, and that at the time of dental care, nearly half had an unmet oral need and had detectable viral loads despite having been connected with HIV specialists.<sup>60</sup> Antibacterial therapy and, even more so, antifungal therapy should be discussed with HIV specialists, with the understanding that these therapeutics, though indicated, may be detrimental to HAART efficacy.<sup>101,102</sup>

### Fungal Infection

Pindborg stated that the most common HIV-associated infection of the mouth is caused by the fungus *Candida albicans*.<sup>103</sup> Oral candidiasis is frequently present and may lead to esophageal or disseminated candidiasis. There are four major types of oral candidiasis: (1) pseudomembranous, (2) hyperplastic, (3) erythematous (atrophic), and (4) angular cheilitis.

The pseudomembranous lesion is characterized by the presence of creamy white or yellow plaque that can easily be removed from the mucosa, leaving a red, bleeding surface. The most common locations for these lesions are the palate, buccal, and labial mucosa, and dorsum of the tongue.

The hyperplastic lesion is characterized by white plaque that cannot easily be removed. The most common location is the buccal mucosa. The erythematous (atrophic) lesion is characterized by a red appearance. Common locations are the palate and the dorsum of the tongue. The lesions may also appear as spotty areas on the buccal mucosa. Angular cheilitis is characterized by fissures radiating from the commissures of the mouth, often associated with small, white plaque.

The treatment of *C. albicans* infection can be either systemic or topical. Topical therapy involves the use of nystatin (Mycostatin) rinses (100,000 U; three to five times daily) or clotrimazole (Mycelex) troches for 1 to 2 weeks. Systemic therapy calls for ketoconazole (Nizoral), 200 or 400 mg daily with food, or fluconazole (Diflucan), 100 mg daily. Amphotericin B and its lipid preparations, azoles such as fluconazole (administered intravenously), and echinocandins are used for systemic infection.

Oropharyngeal candidal infections are common and can frequently recur.<sup>104</sup> Therefore patients may remain on antifungal medication indefinitely. As an adjunctive measure, mouth rinses with Peridex (0.12% chlorhexidine digluconate; Zila Pharmaceuticals, Phoenix, AZ, USA) may be used. Chronic oral candidiasis, given the available armamentarium of HAART agents, may be a poor prognostic sign indicating a phase of more rapid decline of immune function to the terminal phase of AIDS.

### Viral Infection

In the same way that fungi can cause oral disease because of the immune dysfunction induced by HIV infection, several viruses can produce lesions in the mouth following colonization or reactivation. According to Greenspan,<sup>104</sup> these include herpes group viruses and papillomaviruses.

Oral warts may be seen in the HIV-infected patient, with human papillomavirus as the etiologic agent. Some warts have a raised, cauliflower-like appearance, whereas others are well circumscribed, have a flat surface, and almost disappear when the mucosa is stretched.

Herpes simplex virus can produce recurrent episodes of painful ulceration. Intraorally, the lesions appear most commonly on the palate. Typically, these lesions present as vesicles that break open to form ulcers. However, they may also have an atypical appearance as slitlike lesions on the tongue or may mimic other diseases. Diagnosis can be made from culture, PCR, or fluorescent antibody testing.

Herpetic lesions may be treated with oral acyclovir and its relatives, valacyclovir and famciclovir. Acyclovir may also be administered intravenously (750 mg/m<sup>2</sup> in divided doses three times a day until lesions clear) in individuals with more severe oropharyngeal lesions or in those unable to swallow.

Herpes zoster (shingles) is caused by varicella-zoster virus (VZV), the chickenpox virus. VZV can produce oral ulcerations, which are usually accompanied by skin lesions generally restricted to one side of the face. These lesions are also treated with acyclovir.

Oral hairy leukoplakia (HL) is a white lesion that does not rub off, located on the lateral margins of the tongue. The surface



may be smooth, corrugated, or markedly folded. HL is seen only in HIV-infected patients. HL is a virally induced lesion caused by the Epstein-Barr virus (EBV). Treatment may include the use of high-dose acyclovir. However, the lesions usually recur.

### Bacterial Infections, Gingivitis, and Periodontitis

Progressive and premature periodontal disease is seen relatively frequently in HIV-infected individuals and may even be the first sign of HIV infection. Unlike conventional periodontal disease, these lesions do not respond effectively to standard periodontal therapy. There may be a rapid progression from mild gingivitis to advanced, painful, spontaneously bleeding periodontal disease in a few months. Treatment includes aggressive curettage, Peridex (0.12% chlorhexidine digluconate) rinses three times daily, and possibly antibiotic treatment.

Bacteria causing oral lesions may include *Mycobacterium avium-intracellulare* and *Klebsiella pneumoniae*, among others. Well-described conditions include linear gingival erythema and necrotizing ulcerative periodontitis, which likely represent dysbiosis of the microflora. Many of the oral lesions seen in association with HIV infection are not new entities; rather, they are known diseases that either follow an atypical course or show an unusual response to treatment. This is frequently the case with neoplasms as well.

### Neoplasms

Kaposi sarcoma, secondary to transformation induced by human herpes virus (HHV)-8 infection, is the most common malignancy seen in AIDS; as per the report by Silverman<sup>106</sup>, it occurs in 15% to 20% of adult patients with AIDS. Intra-oral lesions may occur alone or along with skin, visceral, and lymph node lesions. The first lesions of Kaposi sarcoma often appear in the mouth. They may be red, blue, or purple, flat or raised, and solitary or multiple. The most common oral site is the hard palate, although lesions may be found on any part of the oral mucosa. Treatment for aggressive lesions involves radiation, laser surgery, or chemotherapy. Conventional surgery may be appropriate for small lesions.

The group of malignancies whose incidence is growing the fastest among patients with AIDS is the lymphomas, most commonly the non-Hodgkin lymphomas. The first manifestation may be a firm, painless swelling in the mouth. Biopsies of these growths are indicated to establish a diagnosis. Treatment includes multidrug chemotherapy and radiation. Less than 20% of patients survive 2 years; the mean survival time is approximately 6 months from diagnosis.

Oral squamous cell carcinomas also occur more frequently in the HIV-infected population. In patients with HIV/AIDS who develop malignancies, their HAART should be optimized while definitive oncologic therapy is pending.<sup>99</sup>

### Idiopathic Lesions

Greenspan described oral ulcers of unknown etiology that are being reported with increasing frequency in people with HIV infection.<sup>105</sup> The ulcers resemble aphthous lesions, appearing as well-circumscribed ulcers with an erythematous margin. Patients sometimes exhibit extremely large and painful necrotic ulcers that may persist for several weeks. These ulcers are more common among pediatric patients. The serum and oral secretions are not uncommonly positive if screened by PCR

for HHVs (EBV, HHV6, and HHV7); however, this more likely represents asymptomatic shedding rather than identification of an untreated co-infection. In the patient on appropriate HAART therapy, topical steroids are reasonable and safe.

Salivary gland swelling has been observed in both HIV-infected adults and children. The cause of swelling is unknown and may be combinational. It usually involves the parotid glands, accompanied by xerostomia. These patients may be best evaluated with fine-needle aspiration, especially if there is a focal mass.

Patients infected with HIV may develop oral manifestations of autoimmune disorders, including immune thrombocytopenic purpura. Oral lesions appear as small, blood-filled purpuric lesions or petechiae. Spontaneous gingival bleeding may also occur.

## SEVERE ACUTE RESPIRATORY SYNDROME CORONAVIRUS 2 (SARS-COV-2) AND COVID-19

In late 2019, a novel coronavirus emerged out of Wuhan Province, China, and rapidly spread globally, leading to a “pandemic,” as it infects people easily and spreads from person to person in an efficient and sustained way. Named by the World Health Organization as COVID-19 (corona virus disease 2019), its symptoms may appear in 2–14 days after exposure to the virus and include cough, shortness of breath, fever, chills, muscle pain, sore throat, and new loss of taste or smell (accessed May 9, 2020: <https://www.cdc.gov/coronavirus/2019-ncov/symptoms-testing/symptoms.html>). The virus is spread among people via airborne droplets from infected individuals via exhaled expulsion from coughing, sneezing, etc. Death rate estimates vary from 1% to 7%, with respiratory failure being the primary cause of death. Children have similar symptoms, but generally have a mild illness. However, there has been a significant increase of a Kawasaki-like disease with multisystem inflammation frequently associated with circulatory failure and myocarditis that has been named multisystem inflammatory syndrome in children or MIS-C. Universal precautions must be followed in the dental setting, along with enhanced environmental, administrative, respiratory precautions, among others.<sup>107</sup> This is especially important when aerosol-generating procedures are performed, such as those associated with high-speed handpieces (Accessed May 9, 2020: <https://www.osha.gov/Publications/OSHA3990.pdf>), and enhanced facial protection via an N95 mask and a face shield are recommended.

### References

1. van Ommen CH, Peters M: Clinical Practice: The bleeding child. Part I: primary hemostatic disorders, *Eur J Pediatr* 171(1):1–10, 2012.
2. van Herrewegen F, Meijers JCM, Peters M, et al.: Clinical practice: The bleeding child. Part II: disorders of secondary hemostasis and fibrinolysis, *Eur J Pediatr* 171(2):207–214, 2012.
3. Seligsohn U: Treatment of inherited platelet disorders, *Haemophilia* 18:161–165, 2012.
4. Curnow J, Pasalic L, Favaloro EJ: Why do patients bleed? *Surg J* 2(1):e29–e43, 2016.
5. Saes JL, Schols SE, Van Heerde WL, et al.: Hemorrhagic disorders of fibrinolysis: a clinical review, *J Thromb Haemost* 16(8):1498–1509, 2018.
6. Bowman M, Hopman WM, Rapson D, et al.: The prevalence of symptomatic von Willebrand disease in primary care practice, *J Thromb Haemost* 8(1):213–216, 2010.

7. Nichols WL, Hultin MB, James AH, et al.: von Willebrand disease (VWD): evidence-based diagnosis and management guidelines, the National Heart, Lung, and Blood Institute (NHLBI) Expert Panel report (USA), *Haemophilia* 14(2):171–232, 2008.
8. Sadler JE, Budde U, Eikenboom JC, et al.: Update on the pathophysiology and classification of von Willebrand disease: a report of the Subcommittee on von Willebrand Factor, *J Thromb Haemost* 4(10):2103–2114, 2006.
9. Kessler DA, Flood VH: Current issues in diagnosis and treatment of von Willebrand disease, *Res Pract Thromb Haemost* 2(1):34–41, 2018.
10. Sharma R, Flood VH: Advances in the diagnosis and treatment of von Willebrand disease, *Blood* 130(22):2386–2391, 2017.
11. Berntorp E, Peake I, Budde U, et al.: von Willebrand's disease: a report from a meeting in the Åland islands, *Haemophilia* 18:1–13, 2012.
12. Berntorp E, Fuchs B, Makris M, et al.: Third Åland islands conference on von Willebrand disease, 26–28 September 2012: meeting report, *Haemophilia* 19:1–18, 2013.
13. O'Brien SH, Saini S: von Willebrand disease in pediatrics: evaluation and management, *Hematol Oncol Clin North Am* 33(3):425–438, 2019.
14. Sanders YV, Fijnvandraat K, Boender J, et al.: Bleeding spectrum in children with moderate or severe von Willebrand disease: relevance of pediatric-specific bleeding, *Am J Hematol* 90(12):1142–1148, 2015.
15. Gill JC, Ottum M, Schwartz B: Evaluation of high concentration intranasal and intravenous desmopressin in pediatric patients with mild hemophilia A or mild-to-moderate type 1 von Willebrand disease, *J Pediatr* 140(5):595–599, 2002.
16. Rodeghiero F, Tosetto A, Castaman G: How to estimate bleeding risk in mild bleeding disorders, *J Thromb Haemost* 5:157–166, 2007.
17. Byams VR: Women with bleeding disorders, *J Womens Health* 16(9):1249–1251, 2007.
18. Federici AB, Mannucci PM: Management of inherited von Willebrand disease in 2007, *Ann Med* 39(5):346–358, 2007.
19. Franchini M, Mannucci PM: von Willebrand factor (Vonvendi®): the first recombinant product licensed for the treatment of von Willebrand disease, *Expert Rev Hematol* 9(9):825–830, 2016.
20. Soucie JM, Evatt B, Jackson D: Occurrence of hemophilia in the United States. The hemophilia surveillance system project investigators, *Am J Hematol* 59:288–294, 1998.
21. Berntorp E, Shapiro AD: Modern haemophilia care, *Lancet* 379(9824):1447–1456, 2012.
22. Blanchette VS, Key NS, Ljung LR, et al.: Definitions in hemophilia: communication from the SSC of the ISTH, *J Thromb Haemost* 12(11):1935–1939, 2014.
23. Srinivasan K, Gadodia A, Bhalla AS, et al.: Magnetic resonance imaging of mandibular hemophilic pseudotumor associated with factor IX deficiency: report of case with review of literature, *J Oral Maxillofac Surg* 69(6):1683–1690, 2011.
24. Thronsdon RR, Baker D, Kennedy P, et al.: Pseudotumor of hemophilia in the mandible of a patient with hemophilia A, *Oral Surg Oral Med Oral Pathol Oral Radiol* 113(2):229–233, 2012.
25. Sonis AL, Musselman RJ: Oral bleeding in classic hemophilia, *Oral Surg Oral Med Oral Pathol* 53(4):363–366, 1982.
26. Escobar MA: Advances in the treatment of inherited coagulation disorders, *Haemophilia* 19(5):648–659, 2013.
27. World Federation of Hemophilia: *WFH guidelines for the management of hemophilia*, ed 3, Table 7-1, 2020.
28. Simpson ML, Valentino LA, Soucie, et al.: Management of joint bleeding in hemophilia, *Expert Rev Hematol* 5(4):459–468, 2012.
29. Björkman S, Shapiro AD, Berntorp E: Pharmacokinetics of recombinant factor IX in relation to age of the patient: implications for dosing in prophylaxis, *Haemophilia* 7(2):133–139, 2001.
30. MASAC Document #253: MASAC recommendation concerning products for the treatment of hemophilia and other bleeding disorders; Table 1: Products licensed in the US to treat hemophilia; Revised September 2020.
31. Pipe SW: New therapies for hemophilia, *Hematology* 2016(1):650–656, 2016.
32. Weyand AC, Pipe SW: New therapies for hemophilia, *Blood* 133(5):389–398, 2019.
33. Manco-Johnson MJ, Abshire TC, Shapiro AD, et al.: Prophylaxis versus episodic treatment to prevent joint disease in boys with severe hemophilia, *N Engl J Med* 357(6):535–544, 2007.
34. Castaman G: Desmopressin for the treatment of haemophilia, *Haemophilia* 14:15–20, 2008.
35. Rodriguez-Merchan EC, Valentino LA: Emicizumab: review of the literature and critical appraisal, *Haemophilia* 25(1):11–20, 2019.
36. DiMichele DM: Inhibitor treatment in haemophilias A and B: inhibitor diagnosis, *Haemophilia* 12:37–41, 2006. discussion 41–2.
37. Astermark J: Overview of inhibitors. *Semin Hematol* 200;43(2 Suppl 4):S3–S7.
38. Oldenburg J, Mahlangu JN, Bujan W, et al.: The effect of emicizumab prophylaxis on health-related outcomes in persons with haemophilia A with inhibitors: HAVEN 1 Study, *Haemophilia* 25(1):33–44, 2019.
39. Carpenter SL, Khair K, Gringeri A, et al.: Prophylactic bypassing agent use before and during immune tolerance induction in patients with haemophilia A and inhibitors to FVIII, *Haemophilia* 24(4):570–577, 2018.
40. Oldenburg J, Levy GG: Emicizumab prophylaxis in hemophilia A with inhibitors, *N Engl J Med* 377(22):2194–2195, 2017.
41. Ljung RC: How I manage patients with inherited haemophilia A and B and factor inhibitors, *Br J Haematol* 180(4):501–510, 2018.
42. Goedert JJ, Brown DL, Hoots K, et al.: Human immunodeficiency and hepatitis virus infections and their associated conditions and treatments among people with haemophilia, *Haemophilia* 10:205–210, 2004.
43. Goedert JJ: Second Multicenter Hemophilia Cohort Study. Prevalence of conditions associated with human immunodeficiency and hepatitis virus infections among persons with haemophilia, 2001–2003, *Haemophilia* 11(5):516–528, 2005.
44. Evatt BL: The tragic history of AIDS in the hemophilia population, 1982–1984, *J Thromb Haemost* 4(11):2295–2301, 2006.
45. Plug I, Mauser-Bunschoten EP, Bröcker-Vriends AH, et al.: Bleeding in carriers of hemophilia, *Blood* 108(1):52–56, 2006.
46. Street AM, Ljung R, Lavery SA: Management of carriers and babies with haemophilia, *Haemophilia* 14:181–187, 2008.
47. Hermans C, Kulkarni R: Women with bleeding disorders, *Haemophilia* 24:29–36, 2018.
48. McLintock C: Women with bleeding disorders: clinical and psychological issues, *Haemophilia* 24:22–28, 2018.
49. Peyvandi F, Cattaneo M, Inbal A, et al.: Rare bleeding disorders, *Haemophilia* 14:202–210, 2008.
50. Duga S, Salomon O: Congenital factor XI deficiency: an update, *Semin Thromb Hemost* 39(6):621–631, 2013.
51. Žalūnienė R, Aleksejūnienė J, Brukienė V, et al.: Do hemophiliacs have a higher risk for dental caries than the general population? *Medicina* 51(1):46–56, 2015.
52. Othman NA, Sockalingam SN, Mahyuddin A: Oral health status in children and adolescents with haemophilia, *Haemophilia* 21(5):605–611, 2015.
53. Yazicioglu I, Devenci C, Çiftçi V, et al.: Parent's report on oral health-related quality of life of children with haemophilia, *Haemophilia* 25(2):229–235, 2019.
54. Sartori MT, Saggiorato G, Pellati D, et al.: Contraceptive pills induce an improvement in congenital hypoplasminogenemia in two unrelated patients with ligneous conjunctivitis, *Thromb Haemost* 89(01):86–91, 2003.
55. Schaffer R, Duong ML, Wachter B, et al.: Access to dental care for people with bleeding disorders: survey results of hemophilia treatment centers in the U.S., *Spec Care Dentist* 36(6):295–299, 2016.
56. Lee AP, Boyle CA, Savidge GF, et al.: Effectiveness in controlling haemorrhage after dental scaling in people with haemophilia by using tranexamic acid mouthwash, *Br Dent J* 198(1):33–38, 2005. discussion 26.
57. Dalati MH, Kudsı Z, Koussayer LT, et al.: Bleeding disorders seen in the dental practice, *Dent Update* 39(4):266–268, 2012. 270.
58. Anderson JA, Brewer A, Creagh D, et al.: Guidance on the dental management of patients with haemophilia and congenital bleeding disorders, *Br Dent J* 215(10):497–504, 2013.
59. Azhar S, Yazdanie N, Muhammad N: Periodontal status and IOTN interventions among young hemophiliacs, *Haemophilia* 12(4):401–404, 2006.
60. Correa ME, Annicchino-Bizzacchi JM, Jorge Jr J, et al.: Clinical impact of oral health indexes in dental extraction of hemophilic patients, *J Oral Maxillofac Surg* 64(5):785–788, 2006.
61. Brewer AK: Advances in minor oral surgery in patients with congenital bleeding disorders, *Haemophilia* 14:119–121, 2008.
62. Piot B, Sigaud-Fiks M, Huet P, et al.: Management of dental extractions in patients with bleeding disorders, *Oral Surg Oral Med Oral Pathol Oral Radiol Endod* 93(3):247–250, 2002.

63. Reich W, Kriwalsky MS, Wolf HH, et al.: Bleeding complications after oral surgery in outpatients with compromised haemostasis: incidence and management. *Oral Maxillofac Surg* 13(2):73–77, 2009.
64. Wilson W, Taubert KA, Gewitz M, et al.: Prevention of infective endocarditis: guidelines from the American Heart Association: a guideline from the American Heart Association Rheumatic Fever, Endocarditis and Kawasaki Disease Committee, Council on Cardiovascular Disease in the Young, and the Council on Clinical Cardiology, Council on Cardiovascular Surgery and Anesthesia, and the Quality of Care and Outcomes Research Interdisciplinary Working Group. *J Am Dent Assoc* 139:S3–S24, 2008.
65. Association AD, American Academy of Orthopaedic Surgeons: Antibiotic prophylaxis for dental patients with total joint replacements. *J Am Dent Assoc* 134(7):895–899, 2003.
66. Olsen I, Snorrason F, Lingaas E: Should patients with hip joint prosthesis receive antibiotic prophylaxis before dental treatment? *J Oral Microbiol* 2(1), 2010.
67. Lockhart PB, Hanson NB, Ristic H, et al.: Acceptance among and impact on dental practitioners and patients of American Heart Association recommendations for antibiotic prophylaxis. *J Am Dent Assoc* 144(9):1030–1035, 2013.
68. Guy y, Liesner R, Chang T, et al.: A multicenter, open-labeled phase 3 study of emicizumab Prophylaxis in children with hemophilia with inhibitors. *Blood* 134(24):2127–2138, 2019.
69. Mahlangu J, Oldenburg J, Paz-Priel I, et al.: Emicizumab prophylaxis in patients who have hemophilia A without inhibitors. *N Engl J Med* 379(9):811–822, 2018.
70. Pipe SW, Shima M, Lehle M, et al.: Efficacy, safety, and pharmacokinetics of emicizumab prophylaxis given every 4 weeks in people with haemophilia A (HAVEN 4): a multicentre, open-label, non-randomised phase 3 study. *Lancet Haematol* 6(6):e295–e305, 2019.
71. Santagostino E, Oldenburg J, Chang T, et al. Surgical Experience from Four Phase III Studies (HAVEN 1-4) of Emicizumab in Persons with Haemophilia A (PwHA) With or Without FVIII Inhibitors. ISTH Presented at the International Society on Thrombosis and Haemostasis (ISTH) 2019 congress OC 60.1.
72. Teerawattananon C, Tantayakom P, Suwanawiboon B, et al.: Risk of perioperative bleeding related to highly selective cyclooxygenase-2 inhibitors: a systematic review and meta-analysis. *Semin Arthritis Rheum* 46(4):520–528, 2017.
73. Arachchilage DR, Makris M: Choosing and using non-steroidal anti-inflammatory drugs in haemophilia. *Haemophilia* 22(2):179–187, 2016.
74. Auerswald G, Dolan G, Duffy A, et al.: Pain and pain management in haemophilia. *Blood Coagul Fibrinolysis* 27(8):845–854, 2016.
75. Wicker S, Cinatl J, Berger A, et al.: Determination of risk of infection with blood-borne pathogens following a needlestick injury in hospital workers. *Ann Occup Hyg* 52(7):615–622, 2008.
76. Klein RS, Freeman K, Taylor PE, et al.: Occupational risk for hepatitis C virus infection among New York City dentists. *Lancet* 338(8782-8783):1539–1542, 1991.
77. Hughes A, Davies L, Hale R, et al.: Adverse incidents resulting in exposure to body fluids at a UK dental teaching hospital over a 6-year period. *Infect Drug Resist* 5:155–161, 2012.
78. Mulimani P, Ballas S, Abas A, et al.: Treatment of dental complications in sickle cell disease. *Cochrane Database Syst Rev* 4, 2016. <https://doi.org/10.1002/14651858.CD011633.pub2>
79. Alves e Luna AC, Godoy F, De Menezes VA: Malocclusion and treatment in children and adolescents with sickle cell disease. *Angle Orthod* 84(3):467–472, 2014.
80. Yawn BP, Buchanan GR, Afeniyi-Annan AN, et al.: Management of sickle cell disease: summary of the 2014 evidence-based report by expert panel members. *JAMA* 312(10):1033–1048, 2014.
81. Chekroun M, Cherifi H, Fournier B, et al.: Oral Manifestations of sickle cell disease. *Br Dent J* 226(1):27–31, 2019.
82. National Vital Statistics System, National Center for Health Statistics, CDC. [http://cdc.gov/injury/images/lc-charts/leading\\_causes\\_of\\_death\\_by\\_age\\_group\\_2017](http://cdc.gov/injury/images/lc-charts/leading_causes_of_death_by_age_group_2017). Accessed July 15, 2019.
83. Noone AM, Howlander N, et al. SEER Cancer Statistics Review, 1975–2016. National Cancer Institute: Bethesda, MD. <http://seer.cancer.gov.csr/1975-2016> (based on November 2016 SEER data submission, data released April 15, 2019).
84. American Academy of Pediatric Dentistry, Review Council: Guideline on dental management of pediatric patients receiving chemotherapy, hematopoietic stem cell transplantation, and/or radiation therapy. *Pediatric Dentistry* 38(6):334–342, 2016.
85. American Academy of Pediatric Dentistry. Dental management of pediatric patients receiving immunosuppressive therapy and or radiation therapy. In: *The Reference Manual of Pediatric Dentistry*. American Academy of Pediatric Dentistry: Chicago, IL, 422–430, 2019.
86. Hong CH, Gueiros LA, Fulton J, et al.: Support Care Cancer, 2019. <https://doi.org/10.1007/s00520-019-04848-4> epub ahead of print. Accessed July 15, 2019.
87. Marchesi F, Tendas A, Giannarelli D, et al.: Cryotherapy reduces oral mucositis and febrile episodes in myeloma patients treated with high-dose melphalan and autologous stem cell transplant: a prospective, randomized study. *Bone Marrow Transplant* 52:154–156, 2017.
88. Seremidi K, Kloukos D, Polychronopoulou A, et al.: Late effects of chemo and radiation treatment on dental structures of childhood cancer survivors. A systematic review and meta-analysis. *Head Neck*, 2019. <https://doi.org/10.1002/hed.25840> epub ahead of print. Accessed July 15, 2019.
89. Children's Oncology Group: *Long term follow-up guidelines for survivors of childhood, adolescent and young adult cancers, Version 5.0*. Monrovia, CA, 2018, Children's Oncology Group. [www.survivorshipguidelines.org](http://www.survivorshipguidelines.org). Accessed July 15, 2019.
90. Araujo MW, Andreana S: Risk and prevention of transmission of infectious diseases in dentistry. *Quintessence Int* 33(5):376–382, 2002.
91. Centers for Disease Control and Prevention: *Viral hepatitis: statistics & surveillance*. Centers for Disease Control and Prevention, 2018. <http://www.cdc.gov/hepatitis/statistics/index.htm>.
92. Razavi H, ElKhoury AC, Elbasha E, et al.: Chronic hepatitis C virus (HCV) disease burden and cost in the United States. *Hepatology* 57(6):2164–2170, 2013.
93. American Association for the Study of Liver Diseases and the Infectious Diseases Society of America: *HCV guidance: recommendations for testing, managing, and treating hepatitis C*. Author, 2020. <http://hcvguidelines.org/>.
94. Centers for Disease Control and Prevention: *The ABCs of hepatitis—for health professionals*. Author, 2020. <http://www.cdc.gov/hepatitis/Resources/Professionals/PDFs/ABCTable.pdf>.
95. Herrera JL: Hepatitis E as a cause of acute non-A, non-B hepatitis. *Arch Intern Med* 153(6):773–775, 1993.
96. Borkakoti J, Hazam RK, Mohammad A, et al.: Does viral load of hepatitis E virus influence the severity and prognosis of acute liver failure during pregnancy? *J Med Virol* 85(4):620–626, 2013.
97. Centers for Disease Control and Prevention: *HIV in the United States: at a glance*. Author, 2020. <http://www.cdc.gov/hiv/statistics/basics/ataglance.html>.
98. Centers for Disease Control and Prevention: *HIV: men*. Author, 2020. <http://www.cdc.gov/hiv/group/gender/men/index.html>.
99. Panel on Antiretroviral Guidelines for Adult and Adolescents: Guidelines for the use of antiretroviral agents in HIV-1-Infected adults and adolescents. Department of Health and Human Services. <http://aidsinfo.nih.gov/contentfiles/lvguidelines/AdultandAdolescentGI.pdf>
100. Fox JE, Tobias CR, Bachman SS, et al.: Increasing access to oral health care for people living with HIV/AIDS in the U.S: baseline evaluation results of the Innovations in Oral Health Care Initiative. *Public Health Rep* 127(Suppl 2):5–16, 2012.
101. Iacovou E, Vlastarakos PV, Papacharalampous G, et al.: Diagnosis and treatment of HIV-associated manifestations in otolaryngology. *Infect Dis Rep* 4(1):e9, 2012.
102. Reznik DA: Oral manifestations of HIV disease. *Top HIV Med* 13(5):143–148, 2005.
103. Pindborg JJ. Oral candidiasis in HIV infection. In: Robertson PB, Greenspan JS (eds). Perspectives on oral manifestations of AIDS. Diagnosis and management of HIV-associated infections. PSG Publishing: Littleton, MA, USA.
104. Patton LL: Oral lesions associated with human immunodeficiency virus disease. *Dent Clin N Am* 57(4):673–698, 2013.
105. Greenspan D. Oral manifestations of HIV infection. In: Robertson PB, Greenspan JS (eds). Perspectives on oral manifestations of AIDS. Diagnosis and management of HIV-associated infections. PSG Publishing: Littleton, MA, USA.
106. Silverman S. AIDS. HIV infection and dentistry. Part I: Epidemiology, pathogenesis and transmission. Part II: Oral manifestations, diagnosis and management. In: Fairfax (VA), California, and American Dental Institutes for Continuing Education. Vol 7, 1991.
107. Mallineni SK, Innes NP, Raggio DP, Araujo MP, Robertson MD, Jayaraman J: Coronavirus disease (COVID-19): Characteristics in children and considerations for dentists providing their care. *Int J Paediatr Dent* 30(3):245–250, 2020. <https://doi.org/10.1111/ipd.12653>



## 28

# Management of Trauma to the Teeth and Supporting Tissues

JAMES E. JONES, KENNETH J. SPOLNIK and GHAETH H. YASSEN

## CHAPTER OUTLINE

### History and Examination

History of the Injury

Clinical Examination

Radiographic Examination

### Emergency Treatment of Soft Tissue Injury

### Emergency Treatment and Temporary Restoration of Fractured Teeth Without Pulp Exposure

Fragment Restoration (Reattachment of Tooth Fragment)

Temporary Bonded Resin Restoration

### Treatment of Vital Pulp Exposures

Direct Pulp Cap

Apexogenesis

Pulpectomy With Endodontic Treatment

### Therapy to Stimulate Root Growth and Apical Repair in Immature Teeth With Pulpal Necrosis

Apexification

Regenerative Endodontic Procedures

### Reaction of the Tooth to Trauma

Pulpal Hyperemia

Internal Hemorrhage

Calcific Metamorphosis of the Dental Pulp (Progressive Canal Calcification or Dystrophic Calcification)

Internal Resorption

Peripheral (External) Root Resorption

Pulpal Necrosis

Ankylosis

### Restoration of Fractured Teeth

Aesthetic Bonded Composite Resin Restoration

### Reaction of Permanent Tooth Buds to Injury

Hypocalcification and Hypoplasia

Reparative Dentin Production

Dilaceration

### Displacement of Primary and Permanent Anterior Teeth (Luxation)

Intrusion and Extrusion of Teeth

Avulsion and Replantation

Management of Root Fractures

Other Displacement Injuries of Teeth Requiring Stabilization

### Management of Oral Burns

Nature of the Injury

Treatment

### Trauma Prevention

Injuries to the teeth of children or adults present unique problems in diagnosis and treatment. The diagnosis of the extent of the injury after a blow to a tooth, regardless of loss of tooth structure, is difficult and often inconclusive. Trauma to a tooth is invariably followed by pulpal hyperemia, the extent of which cannot always be determined by available diagnostic methods. Congestion and alteration in the blood flow in the pulp may be sufficient to initiate irreversible degenerative changes which, over time, can cause pulpal necrosis. In addition, the apical vessels may have been severed or damaged enough to interfere with the normal reparative process. Treatment of injuries causing pulp exposure or tooth displacement is particularly challenging because the prognosis of the involved tooth is often uncertain.

The treatment of fractured teeth, particularly in young patients, is further complicated by the often difficult but extremely important restorative procedure. Although the dentist may prefer to delay the restoration because of

a questionable prognosis for the pulp, a malocclusion can often develop within a matter of days because of a break in the normal proximal contact with adjacent teeth. Adjacent teeth may tip into the area created by the loss of tooth structure. This loss of space will create a problem when the final restoration is contemplated. There must often be a compromise of an ideal aesthetic appearance, at least in the initial restoration, because the prognosis is questionable or because the tooth is young and has a large pulp or is still in the stage of active eruption.

The likelihood of success often depends on the rapidity with which the tooth is treated after the injury, regardless of whether the procedure involves protecting a large area of exposed dentin or treating a vital pulp exposure. Several factors can be considered common to all types of injury to the anterior teeth. These important considerations should become a checklist that is used consistently by the dentist in the diagnosis of and treatment planning for traumatic injuries.

The International Association of Dental Traumatology reports that one of every two children sustains a dental injury, most often between the ages of 8 and 12 years. They suggest that, in most cases of dental trauma, a rapid and appropriate treatment can reduce its impact from both an oral and aesthetic standpoint. To that end, the Association has developed guidelines for the evaluation and management of traumatic dental injuries (<http://www.dentaltraumaguide.org>).

## History and Examination

The routine use of a clinical evaluation sheet for injured anterior teeth is helpful during the initial and subsequent examinations of an injured tooth (Fig 28.1). The form, which becomes a part of the patient's record, serves as a checklist of important questions that must be asked and

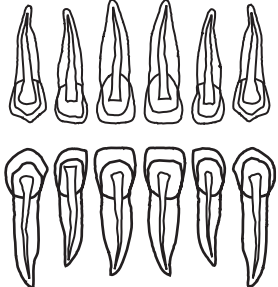
ASSESSMENT OF ACUTE TRAUMATIC INJURIES		PATIENT NAME: _____ DATE OF BIRTH: _____		
DATE:	TIME:	REFERRED BY:		
HISTORY	MEDICAL HISTORY:			
	ALLERGIES:	DATE OF LAST TETANUS INNOCULATION:		
	DATE AND TIME OF INJURY:	TIME LAPSED SINCE INJURY:		
	WHERE INJURY OCCURRED:			
	HOW INJURY OCCURRED:			
	Check if present and describe		MANAGEMENT PRIOR TO EXAM By whom: Describe:	
	<input type="checkbox"/> Nondental injuries			
	<input type="checkbox"/> Loss of consciousness			
	<input type="checkbox"/> Altered orientation/mental status			
	<input type="checkbox"/> Hemorrhage from nose/ears			
<input type="checkbox"/> Headache/nausea/vomiting				
<input type="checkbox"/> Neck pain				
<input type="checkbox"/> Spontaneous dental pain				
<input type="checkbox"/> Pain on mastication				
<input type="checkbox"/> Reaction to thermal changes				
<input type="checkbox"/> Previous dental trauma				
<input type="checkbox"/> Other complaints				
EXTRAORAL EXAM	Check if present and describe		OTHER FINDINGS/COMMENTS:	
	<input type="checkbox"/> Facial fractures			
	<input type="checkbox"/> Lacerations			
	<input type="checkbox"/> Contusions			
	<input type="checkbox"/> Swelling			
	<input type="checkbox"/> Abrasions			
	<input type="checkbox"/> Hemorrhage/drainage			
	<input type="checkbox"/> Foreign bodies			
	<input type="checkbox"/> TMJ deviation/asymmetry			
INTRAORAL EXAMINATION	Check if injured and describe		DIAGRAM OF INJURIES  	
	<input type="checkbox"/> Lips			
	<input type="checkbox"/> Frenae			
	<input type="checkbox"/> Buccal mucosa			
	<input type="checkbox"/> Gingivae			
	<input type="checkbox"/> Palate			
	<input type="checkbox"/> Tongue			
	<input type="checkbox"/> Floor of mouth			
	Occlusion			
	Molar classification R ___ L ___			
	Canine classification R ___ L ___			
	Overbite (%) _____			
	Overjet (mm) _____			
	Crossbite Y N			
Midline deviation Y N				
Interferences Y N				

Fig. 28.1 Assessment of acute traumatic injuries. (Adapted from American Academy of Pediatric Dentistry. *Pediatr Dent.* 2002;24(7 suppl):95–96.)

<b>DENTAL INJURIES</b>	<b>TOOTH NUMBER</b>									
	AVULSION	Extraoral time								
		Storage medium								
	INFRACTION									
	CROWN FRACTURE									
	PULP EXPOSURE	Size								
		Appearance								
	COLOR									
	MOBILITY (mm)									
	PERCUSSION									
	LUXATION	Direction								
		Extent								
	PULP TESTING	Electric								
		Thermal								
CARIES/PREVIOUS RESTORATIONS										
<b>RADIOGRAPHS</b>	PULP SIZE									
	ROOT DEVELOPMENT									
	ROOT FRACTURE									
	PERIODONTAL LIGAMENT SPACE									
	PERIAPICAL PATHOLOGY									
	ALVEOLAR FRACTURE									
	FOREIGN BODY									
	DEVELOPMENTAL ANOMALY									
	OTHER									
	<b>TREATMENT</b>	Check if performed and describe								
Soft-tissue management										
Medication										
Pulp therapy										
Repositioning										
Stabilization										
Restoration										
Extraction										
Prescription										
Referral										
Other										
<b>INSTRUCTIONS AND DISPOSITION</b>	Check if discussed									
	Diet									
	Hygiene									
	Pain									
	Swelling									
	Infection									
	Prescription									
	Complications:									
	Damage to developing teeth									
	Abnormal position/ankylosis									
Tooth loss										
Pulp damage to injured teeth										
Other:										
Follow-up:										
Other										
<b>SUMMARY</b>										
<table style="width: 100%; border: none;"> <tbody> <tr> <td style="width: 50%; vertical-align: top;"> <p><b>Subsequent visit No. 1</b>      Date _____</p> <p>1. Pulpal response      7 8 9 10  <input type="checkbox"/> <input type="checkbox"/>   <input type="checkbox"/> <input type="checkbox"/></p> <p>2. Radiographic exam      <input type="checkbox"/> <input type="checkbox"/>   <input type="checkbox"/> <input type="checkbox"/>  2625 2423</p> <p>3. Treatment and comments: _____</p> </td> <td style="width: 50%; vertical-align: top;"> <p><b>Subsequent visit No. 3</b>      Date _____</p> <p>1. Pulpal response      7 8 9 10  <input type="checkbox"/> <input type="checkbox"/>   <input type="checkbox"/> <input type="checkbox"/></p> <p>2. Radiographic exam      <input type="checkbox"/> <input type="checkbox"/>   <input type="checkbox"/> <input type="checkbox"/>  2625 2423</p> <p>3. Treatment and comments: _____</p> </td> </tr> <tr> <td style="vertical-align: top;"> <p><b>Subsequent visit No. 2</b>      Date _____</p> <p>1. Pulpal response      7 8 9 10  <input type="checkbox"/> <input type="checkbox"/>   <input type="checkbox"/> <input type="checkbox"/></p> <p>2. Radiographic exam      <input type="checkbox"/> <input type="checkbox"/>   <input type="checkbox"/> <input type="checkbox"/>  2625 2423</p> <p>3. Treatment and comments: _____</p> </td> <td style="vertical-align: top;"> <p><b>Subsequent visit No. 4</b>      Date _____</p> <p>1. Pulpal response      7 8 9 10  <input type="checkbox"/> <input type="checkbox"/>   <input type="checkbox"/> <input type="checkbox"/></p> <p>2. Radiographic exam      <input type="checkbox"/> <input type="checkbox"/>   <input type="checkbox"/> <input type="checkbox"/>  2625 2423</p> <p>3. Treatment and comments: _____</p> </td> </tr> </tbody> </table>							<p><b>Subsequent visit No. 1</b>      Date _____</p> <p>1. Pulpal response      7 8 9 10  <input type="checkbox"/> <input type="checkbox"/>   <input type="checkbox"/> <input type="checkbox"/></p> <p>2. Radiographic exam      <input type="checkbox"/> <input type="checkbox"/>   <input type="checkbox"/> <input type="checkbox"/>  2625 2423</p> <p>3. Treatment and comments: _____</p>	<p><b>Subsequent visit No. 3</b>      Date _____</p> <p>1. Pulpal response      7 8 9 10  <input type="checkbox"/> <input type="checkbox"/>   <input type="checkbox"/> <input type="checkbox"/></p> <p>2. Radiographic exam      <input type="checkbox"/> <input type="checkbox"/>   <input type="checkbox"/> <input type="checkbox"/>  2625 2423</p> <p>3. Treatment and comments: _____</p>	<p><b>Subsequent visit No. 2</b>      Date _____</p> <p>1. Pulpal response      7 8 9 10  <input type="checkbox"/> <input type="checkbox"/>   <input type="checkbox"/> <input type="checkbox"/></p> <p>2. Radiographic exam      <input type="checkbox"/> <input type="checkbox"/>   <input type="checkbox"/> <input type="checkbox"/>  2625 2423</p> <p>3. Treatment and comments: _____</p>	<p><b>Subsequent visit No. 4</b>      Date _____</p> <p>1. Pulpal response      7 8 9 10  <input type="checkbox"/> <input type="checkbox"/>   <input type="checkbox"/> <input type="checkbox"/></p> <p>2. Radiographic exam      <input type="checkbox"/> <input type="checkbox"/>   <input type="checkbox"/> <input type="checkbox"/>  2625 2423</p> <p>3. Treatment and comments: _____</p>
<p><b>Subsequent visit No. 1</b>      Date _____</p> <p>1. Pulpal response      7 8 9 10  <input type="checkbox"/> <input type="checkbox"/>   <input type="checkbox"/> <input type="checkbox"/></p> <p>2. Radiographic exam      <input type="checkbox"/> <input type="checkbox"/>   <input type="checkbox"/> <input type="checkbox"/>  2625 2423</p> <p>3. Treatment and comments: _____</p>	<p><b>Subsequent visit No. 3</b>      Date _____</p> <p>1. Pulpal response      7 8 9 10  <input type="checkbox"/> <input type="checkbox"/>   <input type="checkbox"/> <input type="checkbox"/></p> <p>2. Radiographic exam      <input type="checkbox"/> <input type="checkbox"/>   <input type="checkbox"/> <input type="checkbox"/>  2625 2423</p> <p>3. Treatment and comments: _____</p>									
<p><b>Subsequent visit No. 2</b>      Date _____</p> <p>1. Pulpal response      7 8 9 10  <input type="checkbox"/> <input type="checkbox"/>   <input type="checkbox"/> <input type="checkbox"/></p> <p>2. Radiographic exam      <input type="checkbox"/> <input type="checkbox"/>   <input type="checkbox"/> <input type="checkbox"/>  2625 2423</p> <p>3. Treatment and comments: _____</p>	<p><b>Subsequent visit No. 4</b>      Date _____</p> <p>1. Pulpal response      7 8 9 10  <input type="checkbox"/> <input type="checkbox"/>   <input type="checkbox"/> <input type="checkbox"/></p> <p>2. Radiographic exam      <input type="checkbox"/> <input type="checkbox"/>   <input type="checkbox"/> <input type="checkbox"/>  2625 2423</p> <p>3. Treatment and comments: _____</p>									

Fig. 28.1 cont'd



observations that must be made by the dentist and the auxiliary personnel during the child's examination.

## HISTORY OF THE INJURY

The time of the injury should be established first. Unfortunately, many patients do not seek professional advice and treatment immediately after an injury. Occasionally, the accident is so severe that dental treatment cannot be started immediately because other injuries have higher priority. Davis and Vogel<sup>1</sup> emphasized that a force strong enough to fracture, intrude, or avulse a tooth is also strong enough to result in cervical spine or intracranial injury. The dentist must be particularly alert to such potential problems, be prepared ahead of time to make a neurologic assessment, and make timely appropriate medical referral when indicated. The patient should be assessed for nausea, vomiting, drowsiness, or possible cerebral spinal fluid leakage from the nose and ears, which would indicate a skull fracture. In addition, the patient should be evaluated for lacerations and facial bone fractures. Obtaining a baseline temperature, pulse, blood pressure, and respiratory rate should be considered prior to addressing the dental needs of the patient. Finally, Davis<sup>2</sup> recommends a quick cranial nerve evaluation involving the following four areas:

1. Extraocular muscles are intact and functioning appropriately; that is, the patient can track a finger moving vertically and horizontally through the visual field with the eyes remaining in tandem.
2. Pupils are equal, round, and reactive to light with accommodation.
3. Sensory function is normal as measured through light touch to various areas of the face.
4. Symmetry of motor function is present, as assessed by having the patient frown, smile, move the tongue, and perform several voluntary muscular movements.

The prognosis of an injured tooth depends logically, often largely, on the time that has elapsed between the occurrence of the accident and the initiation of emergency treatment. This is particularly true in cases of pulp exposure, for which pulp capping or pulpotomy would be the procedure of choice. Rusmah<sup>3</sup> treated 123 traumatized permanent incisors and monitored them over a 24-month period. His findings suggest that the interval between trauma and emergency treatment is directly related to the severity of the injury and the dental awareness of the patients. Furthermore, the prognosis of the injured teeth maintaining pulp vitality diminished when treatment was delayed. The loss of vitality of some injured teeth occurred as early as 3 months and as late as 24 months after the injury, which justifies a long follow-up period after injury.

For practical and especially economic reasons, Andreasen et al.<sup>4</sup> attempted to classify pulpal and periodontal healing of traumatic dental injuries based on the effect of treatment delay. They developed three major categories of treatment timing: acute treatment (within a few hours), subacute treatment (within the first 24 hours), and delayed treatment (after the first 24 hours).

Unfortunately, there is limited knowledge available in the literature regarding the effect of treatment delay on wound healing.

Taking a complete dental history can help the dentist learn of previous injuries to the teeth in the area. Repeated injuries to the teeth are not uncommon in children with protruding anterior teeth and in those who are active in athletics. In these patients, the prognosis may be less favorable. The dentist must rule out the possibility of a degenerative pulp or adverse reaction of the supporting tissues because of previous trauma.

The patient's complaints and experiences after the injury are often valuable in determining the extent of the injury and in estimating the ability of the injured pulp and supporting tissues to overcome the effects of the injury. Pain caused by thermal change is indicative of significant pulpal inflammation. Pain occurring when the teeth are brought into normal occlusion may indicate that the tooth has been displaced. Such pain could likewise indicate an injury to the periodontal and supporting tissues. The likelihood of eventual pulpal necrosis increases if the tooth is mobile at the time of the first examination. The greater the mobility, the greater the chance of pulpal death.

Trauma to the supporting tissues may cause sufficient inflammation to initiate external root resorption. In instances of severe injury, teeth can be lost because of pathologic root resorption and pulpal degeneration.

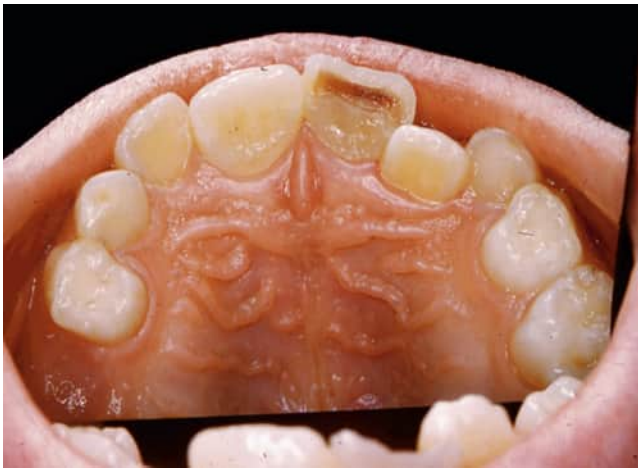## CLINICAL EXAMINATION

The clinical examination should be conducted after the teeth in the area of injury have been carefully cleaned of debris. When the injury has resulted in a fracture of the crown, the dentist should observe the amount of tooth structure that has been lost and should look for evidence of pulp exposure. With the aid of a good light, the dentist should carefully examine the clinical crown for cracks and craze lines, the presence of which could influence the type of permanent restoration used for the tooth. With light transmitted through the teeth in the area, the color of the injured tooth should be carefully compared with that of adjacent uninjured teeth. Severely traumatized teeth often appear darker and reddish, although not actually discolored, which indicates pulpal hyperemia (Fig 28.2). This appearance suggests that the pulp may later undergo degenerative change, terminating in pulpal necrosis.

Diangelis et al.<sup>5</sup> have advocated the following classification of crown fractures in describing the extent of damage to the crown of the tooth:

- Crown fracture—uncomplicated: an enamel fracture or an enamel-dentin fracture that does not involve the pulp.
- Crown fracture—complicated: an enamel-dentin fracture with pulp exposure.

A vitality test of the injured tooth should be performed, and the teeth in the immediate area, as well as those in the opposing arch, should be tested. The best prediction of continued vitality of the pulp of a damaged or traumatized



**Fig. 28.2** The reddish appearance of the exposed dentin is evidence of severe hyperemia within the pulp tissue. The prognosis for retaining vitality of the pulp is poor.

tooth is the vital response to electric pulp testing at the time of the initial examination. A negative response, however, is not a reliable evidence of pulp death, because some teeth that give such a response soon after the injury may recover vitality after a time. When the electric pulp tester is used, the dentist should first determine the normal reading by testing an uninjured tooth on the opposite side of the mouth and recording the lowest number at which the tooth responds. If the injured tooth requires more current than a normal tooth, the pulp may be undergoing degenerative change, whereas if it requires less current, pulpal inflammation is usually indicated.

Many practitioners question the need for the electric vitality test immediately after the injury. Because the electrical stimulus has been shown to produce negligible additional pulpal irritation, its use is not contraindicated on this basis. However, the patient's measured responses to the test may be almost meaningless. The reliability of the electric pulp test depends on eliciting valid responses from the patient. The mere presence of this new, unknown instrument may create anxiety in children that hampers their ability to respond accurately to the test. Since an unscheduled emergency appointment for treatment of an injury is a new experience, it seems reasonable to introduce the child to the instrument during the first emergency visit, when the child does not know what to expect. This gives the dentist an opportunity to allay the child's anxiety about the instrument during a time when the responses are not as important as they will be on subsequent visits. Furthermore, the electric pulp test is frequently unreliable, even on normal teeth when apices are incompletely formed.

The thermal test is also somewhat helpful in determining the degree of pulpal damage after trauma. Although there are difficulties with the thermal test, it is probably more reliable than the electric pulp test in testing primary incisors in young children. Failure of a tooth to respond to heat indicates pulpal necrosis. The response of a tooth to a lower degree of heat than is necessary to elicit a response in adjacent teeth is an indication of inflammation. Pain occurring when ice is applied to a normal tooth

will subside when the ice is removed. A more painful and often lingering reaction to cold indicates a pathologic change within the pulp, the nature of which can be determined when the reaction is correlated with other clinical observations.

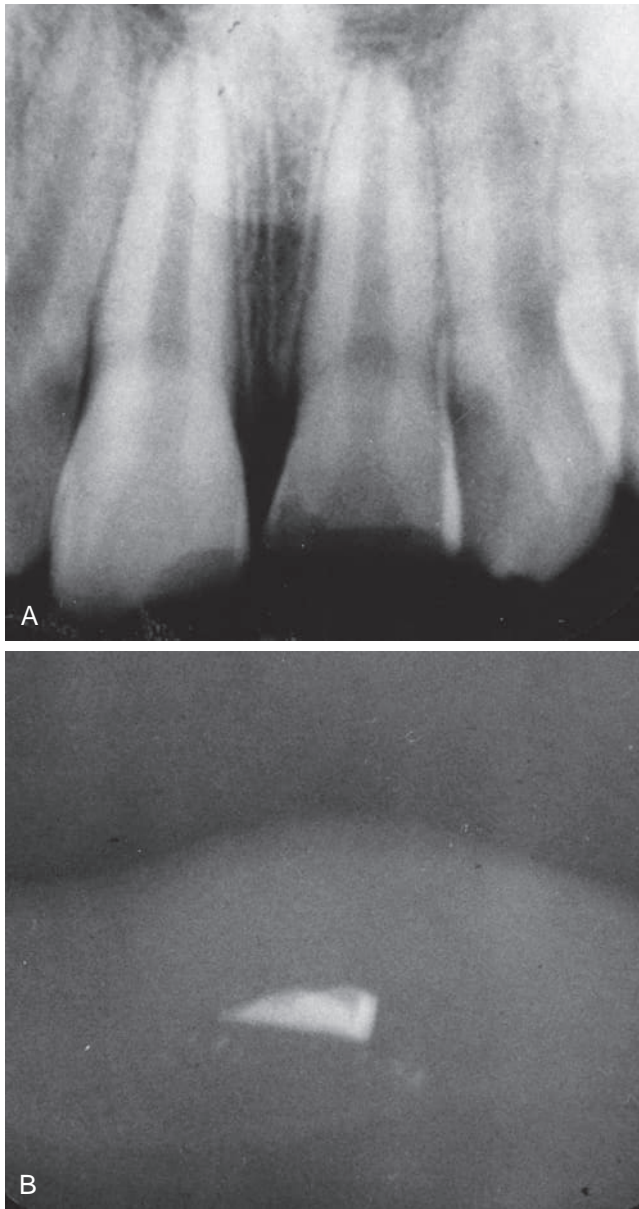
Failure of a recently traumatized tooth to respond to the pulp test is not uncommon and may indicate a previous injury with a resulting necrotic pulp. However, the traumatized tooth may be in a state of shock and as a result, may fail to respond to the accepted methods of determining pulp vitality. The failure of a pulp to respond immediately after an accident is not an indication for endodontic therapy. Instead, emergency treatment should be completed, and the tooth should be retested at the next follow-up visit.

## RADIOGRAPHIC EXAMINATION

The examination of traumatized teeth cannot be considered complete without a radiograph of the injured tooth, the adjacent teeth, and sometimes the teeth in the opposing arch. In search of a fractured tooth fragment, it may even be necessary to obtain a radiograph of the soft tissue surrounding the injury site (Fig. 28.3). The relative sizes of the pulp chamber and canal should be carefully examined. Irregularities or an inconsistency in the size of the chamber or canal compared with that of adjacent teeth may be evidence of a previous injury. This observation is important in determining the immediate course of treatment. In young patients, the stage of apical development often indicates the type of treatment, just as the size of the coronal pulp and its proximity to the area of fracture influence the type of restoration that can be used. A root fracture as a result of the injury or one previously sustained can be detected by a careful examination of the radiograph. However, the presence of a root fracture may not influence the course of treatment, particularly if the fracture line is in the region of the apical third. Teeth with root fractures in this area rarely need stabilization, and a fibrous or calcified union usually results. If teeth have been discernibly dislocated, with or without root fracture, two or three radiographs of the area at different angles may be needed to clearly define the defect and aid the dentist in deciding on a course of treatment.

Another value of the radiograph is that it provides a record of the tooth immediately after the injury. Frequent, periodic radiographs reveal evidence of continued pulp vitality or adverse changes that take place within the pulp or the supporting tissues. In young teeth in which the pulp recovers from the initial trauma, the pulp chamber and canal decrease in size coincident with the normal formation of secondary dentin. After a period of time, an inconsistency in the true size or contour of the pulp chamber or canal compared with that of adjacent teeth may indicate a developing pathologic condition.

When more complex facial injuries have occurred or jaw fractures are suspected, extraoral films may also be necessary to identify the extent and location of all injury sequelae. Oblique lateral jaw radiographs and panoramic films are often useful adjuncts to this diagnostic process.



**Fig. 28.3** (A) Radiograph of fractured teeth. (B) Radiograph with a reduced exposure time (25% of the usual time) was useful for detection of the location of this fractured tooth fragment within the patient's lip.

## Emergency Treatment of Soft Tissue Injury

Injury to the teeth of children is often accompanied by open wounds of the oral tissues, abrasion of the facial tissues, or even puncture wounds. The dentist must recognize the possibility of the development of tetanus after the injury and must carry out adequate first-aid measures.

Children with up-to-date active immunization are protected by the antibody levels in their circulation, produced by a series of injections of tetanus toxoid. Primary immunization is usually a part of medical care during the first 2 years of life. However, primary immunization cannot be assumed; it must be confirmed by examination of the child's medical record.

When the child who has had primary immunization receives an injury from an object that is likely to have been contaminated, the antibody-forming mechanism may be activated with a booster injection of toxoid. An unimmunized child can be protected through passive immunization or serotherapy with tetanus antitoxin (tetanus immune globulin, or TIG).

The dentist examining the child after an injury should determine the child's immunization status, perform adequate debridement of the wound, and, when indicated, refer the child to the family physician. Tetanus is often fatal, and preventive measures must be taken if there is a possibility that an injured child is not adequately immunized.

Debridement, suturing, and/or hemorrhage control of open soft tissue wounds should be carried out as indicated. Working with an oral and maxillofacial surgeon or a plastic surgeon may also be indicated.

## Emergency Treatment and Temporary Restoration of Fractured Teeth Without Pulp Exposure

A trauma to a tooth that causes a loss of only a small portion of enamel should be treated as carefully as one in which greater tooth structure is lost. The emergency treatment of minor injuries in which only the enamel is fractured may consist of no more than smoothing the rough, jagged tooth structure. However, without exception, a thorough examination should be conducted as previously described. The patient should be reexamined at 2 weeks and again at 1 month after the injury. If the tooth appears to have recovered at that time, continued observation at the patient's regular recall appointments should be the rule.

Sudden injuries with a resultant extensive loss of tooth structure and exposed dentin require an immediate temporary restoration or protective covering in addition to the complete diagnostic procedure. In this type of injury, initial pulpal hyperemia and the possibility of further trauma to the pulp by pressure or by thermal or chemical irritants must be reduced. Furthermore, if normal contact with adjacent or opposing teeth has been lost, temporary restoration or protective covering can be designed to maintain the arch integrity. Because providing an adequate permanent restoration may depend on maintaining the normal alignment and position of teeth in the area, this part of the treatment is as important as maintaining the vitality of the teeth. Several restorations that will satisfy these requirements can easily be fabricated.

### FRAGMENT RESTORATION (REATTACHMENT OF TOOTH FRAGMENT)

Occasionally the dentist may have the opportunity to reattach the fragment of a fractured tooth using resin and bonding techniques. Successful reattachment of tooth fragments is reportedly stable and is an option to be considered by the dentist.<sup>6,7</sup>

This procedure is atraumatic and seems to be the ideal method of restoring the fractured crown. Sealing the injured tooth and aesthetically restoring its natural contour and



color are accomplished simply and constitute an excellent service to the patient. The procedure provides an essentially perfect temporary restoration that may be retained a long time in some cases.

It is not often that the fractured tooth fragment remains intact and is recovered after an injury, but when this happens, the dentist may consider the reattachment procedure. The tooth requires no mechanical preparation because retention is provided by enamel etching and bonding techniques. If little or no dentin is exposed, the fragment and the fractured tooth enamel are etched and reattached with bonding agents and materials. Farik et al.<sup>8</sup> tested the use of the new single-bottle dentin adhesives with and without unfilled resins in the fragment-bonding technique. Their hypothesis was that the amount of resin in single-bottle dentin adhesives might not be sufficient to secure an adequate fragment bond. The results of their study showed that all but one of the seven dentin adhesive systems tested should be used with an additional unfilled resin when fractured teeth are restored by reattachment.

For cases in which considerable dentin is exposed or a direct pulp cap is indicated, some controversy exists about the best treatment to enhance the likelihood of maintaining pulp vitality. Some believe that the meticulous use of bonding agents and materials to directly cap the exposed dentin and the pulp, if exposed, (i.e., the total-etch technique) is best, whereas others believe that calcium hydroxide should be applied to the exposed dentin and pulp before the bonding procedure is completed.

Fig. 28.4 illustrates the successful management of an uncomplicated fracture of the maxillary right central incisor in a 6-year-old boy who was treated approximately 1 hour after the injury. After the fragment was trial-seated to confirm a precise fit, the exposed dentin of the fractured tooth was covered with a thin layer of hard-setting calcium hydroxide that was allowed to remain as a sedative dressing between the tooth and restored fragment. A portion of the dentin in the fragment was removed to provide space for the calcium hydroxide. The fragment was then soaked in etchant, and the fractured area of the tooth was also etched well beyond the fracture site. After thorough rinsing and drying of all etched enamel, the fragment and the etched portion of the tooth were painted with a light-curing sealant material. Although no bonding agent was used here, its use is currently recommended. The selected shade of composite resin was used to fill the prepared void in the fragment, and it was then carefully seated into its correct position and held firmly while the material was light cured. Subsequent radiographs and vitality tests indicated that the tooth had probably responded favorably. Kanca<sup>9</sup> reported regarding reattachment of a fragment that successfully capped the pulp using the total-etch technique. The restoration was more than 5 years old (replaced once) and was still in place at the time of the report.

Ludlow and LaTurno<sup>10</sup> reported the success of a fragment restoration for a 13-year-old patient in whom essentially the entire clinical crown of a maxillary incisor was fractured away period. The remaining tooth was first treated with a root canal filling, and then the pulp canal of the tooth and the enlarged pulp chamber in the fragment crown were used as retentive internal cavities to strengthen the reattached crown.

## TEMPORARY BONDED RESIN RESTORATION

The excellent marginal seal and retention derived from the application of aesthetic restorative materials to etched enamel surfaces have revolutionized the approach to the restoration of fractured anterior teeth. These bonding techniques are highly successful and versatile in many situations involving anterior trauma.

It may not be advisable to restore an extensive crown fracture with a finished aesthetic resin restoration on the day of the injury because it is usually best not to manipulate the tooth more than is absolutely necessary to make a diagnosis and provide emergency treatment. Moreover, such emergencies are usually treated at unscheduled appointments, and this treatment should be carried out as efficiently as possible to prevent significant disruption of the dentist's scheduled appointments. A temporary restorative resin restoration can be placed efficiently and is often the treatment of choice.

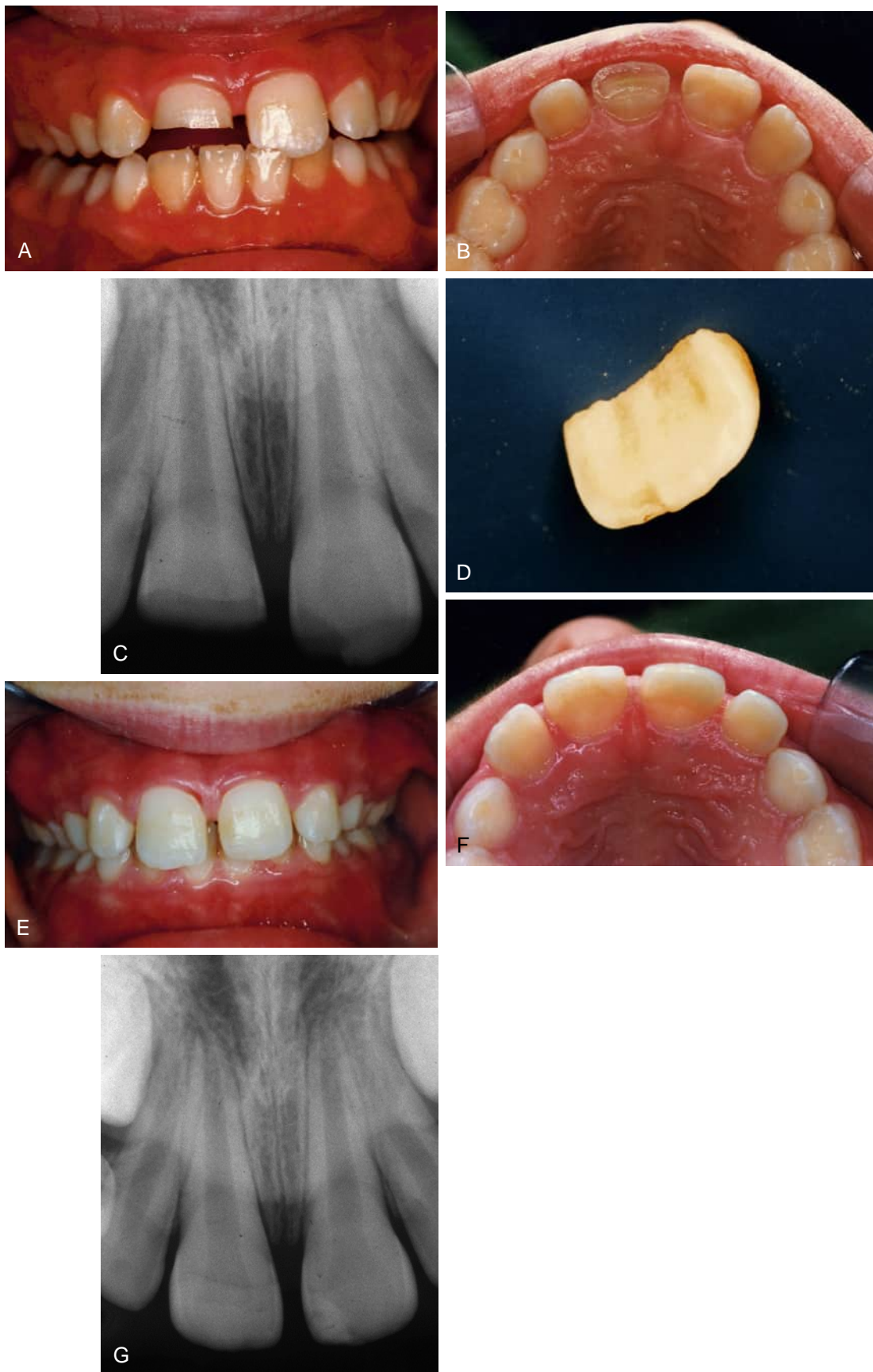
Conventional bonding procedures are used for application of the restorative resin material as a protective covering at the fracture site. As a short-term temporary restoration, it requires little or no finishing and does not need to restore the tooth to normal contour. However, the restoration should cover the fractured surfaces and maintain any natural proximal contacts the patient may have had before the injury (Fig 28.5). After an adequate recovery period, an aesthetic resin restoration may be completed, often without removal of all the temporary resin material. However, the outer surfaces of the temporary restoration should be removed superficially before the new material is applied. The margins of the new restoration should extend beyond the margins of the temporary restoration and onto newly etched enamel. The aesthetic bonded resin restoration is discussed and illustrated later in this chapter.

## Treatment of Vital Pulp Exposures

Injury resulting in an exposure of the pulp in young patients often presents a challenge in diagnosis and treatment even greater than that of a pulp exposed by caries. In addition to treating the pulp at the exposure site, the dentist must keep in mind that, because of the blow, conditions may be present for many unpredictable reactions in the pulp or supporting tissues. The immediate objective in treatment, however, should be the selection of a procedure designed to maintain the vitality of the pulp whenever possible. In the management of vital pulp exposure, at least three choices of treatment are available: direct pulp cap, pulpotomy, and pulpectomy with endodontic therapy.

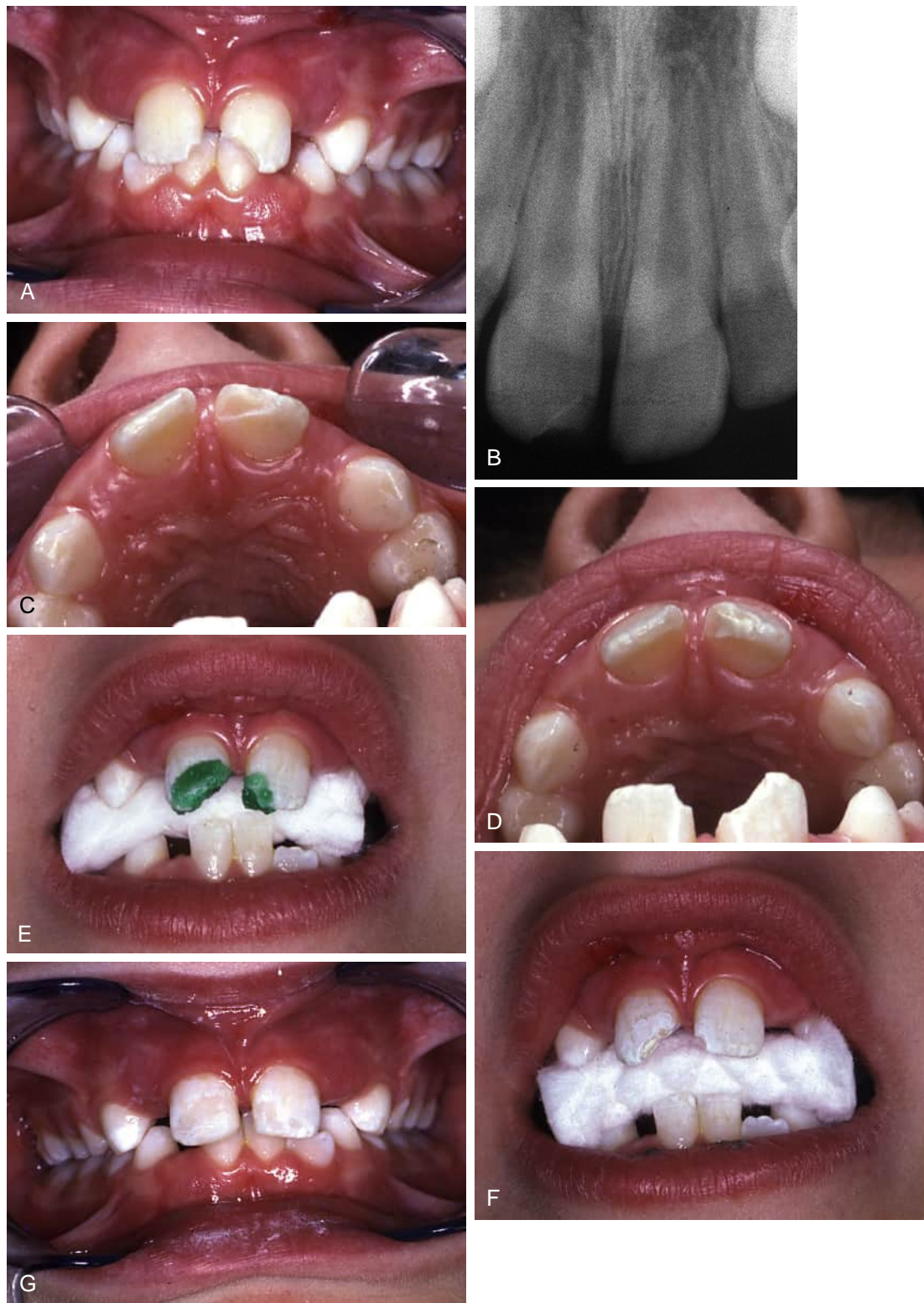### DIRECT PULP CAP

If the patient is seen within an hour or two after the injury, if the vital exposure is small, and if sufficient crown remains to retain a temporary restoration to support the capping material and prevent the ingress of oral fluids, the treatment of choice is direct pulp capping (Fig. 28.6). If the final restoration of the tooth will require the use of the pulp chamber or pulp canal for retention, a pulpotomy or a pulpectomy is the treatment of choice.



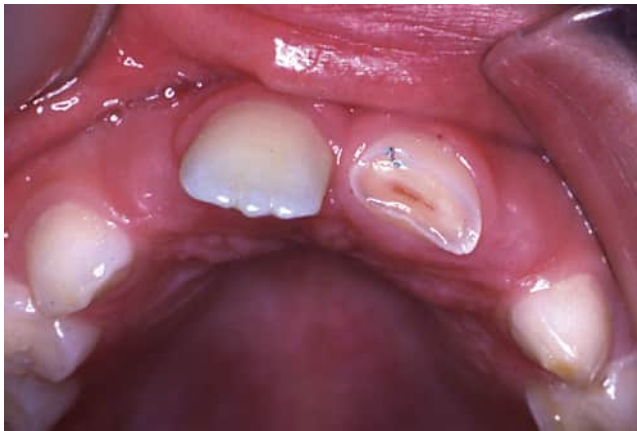**Fig. 28.4** (A) Significant uncomplicated fracture (not involving the dental pulp) of a maxillary right central incisor. (B) The exposed dentin was closely examined to ensure that no exposure of the pulp was present. Next, all exposed dentin was covered with hard-setting calcium hydroxide; all fractured enamel remained exposed. (C) Radiograph of fractured incisor demonstrating stage of root-end development and the absence of root fracture. (D) Fractured part of central incisor. Part of the dentin was removed from the tooth fragment; the enamel was not disturbed. (E) Facial review of restored tooth 12 months after injury. (F) Incisal view of the restored tooth 12 months after injury. (G) Radiograph of the restored tooth 12 months after injury.





**Fig. 28.5** (A) Uncomplicated crown fracture (not involving the dental pulp) of the maxillary right central incisor and maxillary left central incisor. (B) Radiograph obtained after the traumatic incident. (C) Maxillary occlusal view of traumatized central incisors. The maxillary left central incisor has been minimally prepared for a temporary restoration. Note that no pulpal exposure is evident. (D) Calcium hydroxide has been applied, covering all exposed dentin. (E) Etchant is being applied, per manufacturer's instructions, to the involved teeth. (F) Involved teeth after the etching process. Note the etched "snow-capped" appearance of the enamel. (G) Involved teeth after application of the temporary restoration. The occlusion has been checked to make sure that there is no contact with the opposing dentition. After an appropriate amount of observation time, a more aesthetic restoration will be completed.





**Fig. 28.6** Complicated crown fracture (involving the dental pulp) to a permanent central incisor. A small pulp exposure is evident that should be capped and protected with a bonded restoration.

Even though the pulp at the exposure site has been exposed to oral fluids for a period of time, the tooth should be isolated with a rubber dam, and the treatment procedure should be completed in a surgically clean environment. The healthy pulp may survive and repair small injuries even in the presence of a few bacteria, the same as any other connective tissue. The crown and the area of the actual exposure should be washed free of debris, and the pulp should be kept moist before the placement of the pulp-capping material.

As mentioned in [Chapter 14](#), numerous pulp-capping materials have been studied. Pulp capping with conventional bonding materials is now accepted by many, although the procedure is also considered inadvisable by others. Reports of the use of both mineral trioxide aggregate (MTA) and bone morphogenetic proteins are significant not only for pulp capping but also for general use in endodontic therapy for vital and nonvital teeth.

The prime requisite of pulpal healing is an adequate seal against oral fluids. Therefore, a restoration should be placed immediately to protect the pulp-capping material until the healing process is well advanced. A thin layer of dentin-like material should cover the vital pulp tissue in at least 2 months.

If the injured tooth presents a good indication for direct pulp capping, there is a definite advantage in providing this treatment. The pulp will remain functional and reparative, and dentin will develop and allow the tooth to be restored without loss of normal pulp vitality.

## APEXOGENESIS

Apexogenesis, especially as it relates to dental trauma, is the preservation of vital pulp tissue so that continued root development with apical closure may occur. If the pulp exposure in a traumatized, immature permanent (open apex) tooth is large, if even a small pulp exposure exists and the patient did not seek treatment until 48 hours after the injury, or if there is insufficient crown remaining to hold a temporary restoration, the immediate treatment of choice is a shallow pulpotomy or a conventional pulpotomy ([Fig. 28.7](#)). A shallow or partial pulpotomy is preferable if coronal pulp inflammation is not widespread and

if a deeper access opening is not needed to help retain the coronal restoration. It also allows pulp testing since there is still vital pulp tissue in the pulp chamber.<sup>11</sup> Apexogenesis is also indicated for immature permanent teeth if necrotic pulp tissue is evident at the exposure site with inflammation of the underlying coronal tissue, but a conventional or cervical pulpotomy would be required. Another indication is trauma to a more mature permanent (closed apex) tooth that has caused both a pulp exposure and a root fracture. In addition, a shallow pulpotomy may be the treatment of choice for a complicated fracture of a tooth with a closed apex when definitive treatment can be provided soon after the injury ([Fig. 28.8](#)).

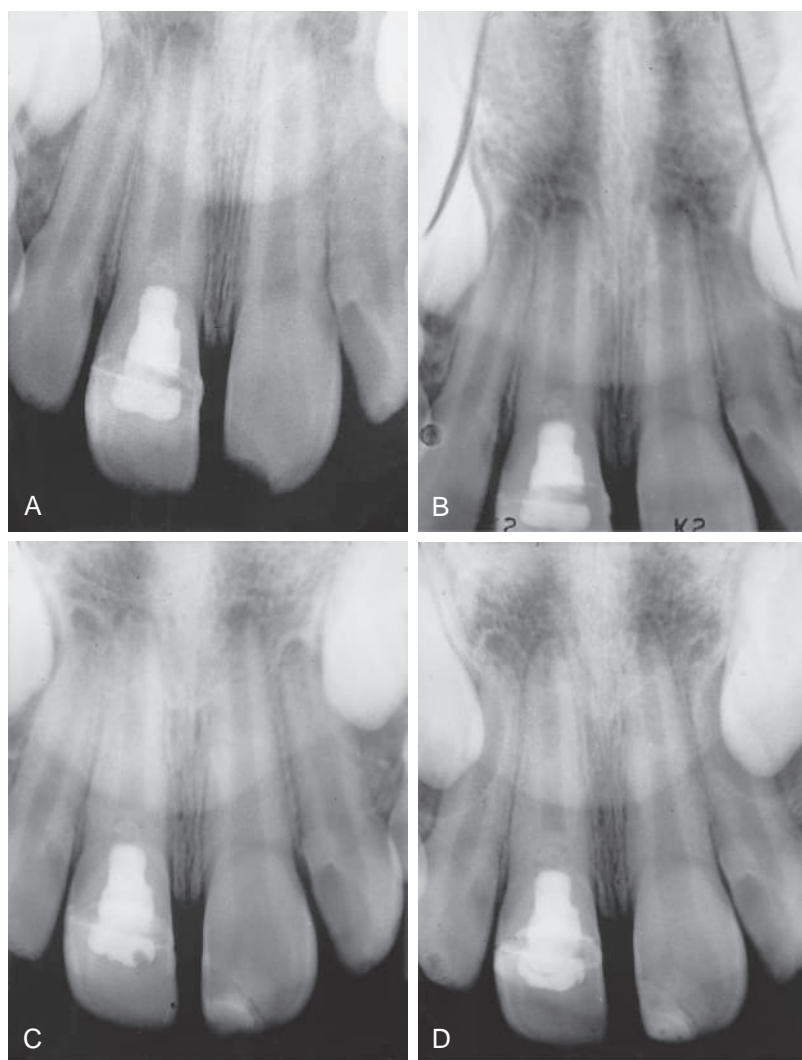
The exposure site should be conservatively enlarged, and 1–2 mm of coronal tissue should be removed for the shallow pulpotomy or all pulp tissue in the pulp chamber should be removed for the conventional pulpotomy. When pulp amputation has been completed to the desired level, the pulp chamber should be thoroughly cleaned with copious irrigation with saline and a cotton pellet dampened with 1.5% NaOCl is used to swab the dentin for disinfection. No visible dentin chips or pulp tissue tags should remain. If the remaining pulp is healthy, hemorrhage will be easy to control with a pledget of moist cotton lightly compressed against the tissue. The pulp should also have a bright reddish-pink color and a concave contour (meniscus). A deeper amputation may be necessary if the health of the pulp is questionable. A dressing of calcium hydroxide, MTA, or Biodentine is gently applied to the vital pulp tissue so that it is in passive contact with the pulp. The remaining access opening is filled with a layer of a light-cured resin-modified glass ionomer with excellent marginal sealing capability. The crown may then be restored with a separate bonding procedure.

Some experts on pulp therapy recommend conventional pulpectomy and root canal fillings for all teeth treated with calcium hydroxide pulpotomies soon after the root apices close. They view the calcium hydroxide pulpotomy as an interim procedure performed solely to achieve normal root development and apical closure. They justify the pulpectomy and root canal filling after apical closure as necessary to prevent an exaggerated calcific response that may result in total obliteration of the root canal (calcific metamorphosis or calcific degeneration).

We have observed this calcific degenerative response and agree that it should be intercepted with root canal therapy if possible after apical closure. However, long-term successes can be achieved after calcium hydroxide pulpotomy in which no calcific metamorphosis has been observed. If healthy pulp tissue remains in the root canal, if the coronal pulp tissue is cleanly excised without excessive tissue laceration and tearing, if the calcium hydroxide is placed gently on the pulp tissue at the amputation site without undue pressure, and if the tooth is adequately sealed, there is a high probability that long-term success can be achieved without follow-up root canal therapy.<sup>12,13</sup>

## PULPECTOMY WITH ENDODONTIC TREATMENT

One of the most challenging endodontic procedures is the treatment and subsequent filling of the root canal of a tooth with an open apex. The lumen of the root canal of such an immature tooth is largest at the apex and smallest in the cervical area and



**Fig. 28.7** (A) Radiographic appearance of the restored maxillary right central incisor 10 days after a complicated crown fracture occurred and the calcium hydroxide pulpotomy was performed. A fragment restoration was also used to restore the Class II fracture of the maxillary left central incisor at this same appointment, but after this radiograph was obtained. (B) This radiograph, made 7½ weeks after the pulpotomy, shows evidence of a calcified bridge developing at the level of the pulpal amputation. (C) Eight months after initial treatment, it appears that root development is progressing normally for both maxillary central incisors. (D) Root completion has been achieved on both maxillary central incisors 20 months after the original injury. The root canals exhibit normal anatomic configuration.

is often referred to as a *blunderbuss canal*. Hermetic sealing of the apex with conventional endodontic techniques is usually impossible without apical surgery. This surgical procedure is traumatic for the young child and should be avoided if possible.

In instances of complicated fractures of young permanent teeth with incomplete root growth and a vital pulp, the pulpotomy technique (as just described) is the procedure of choice. The successful pulpotomy allows the pulp in the root canal to maintain its vitality and allows the apical portion to continue to develop (apexogenesis). For complicated fractures, the eventual restoration may require a post in the root canal. Before this type of restoration is completed, the dentinal bridge that has formed after the pulpotomy can be perforated and routine endodontic procedures can be undertaken in a now completely developed root canal.

Occasionally a patient has an acute periapical abscess associated with a traumatized tooth. The trauma may have caused a very small pulp exposure that was overlooked, or the pulp may have been devitalized because of injury or actual severing of the apical vessels. A loss of pulp vitality may have

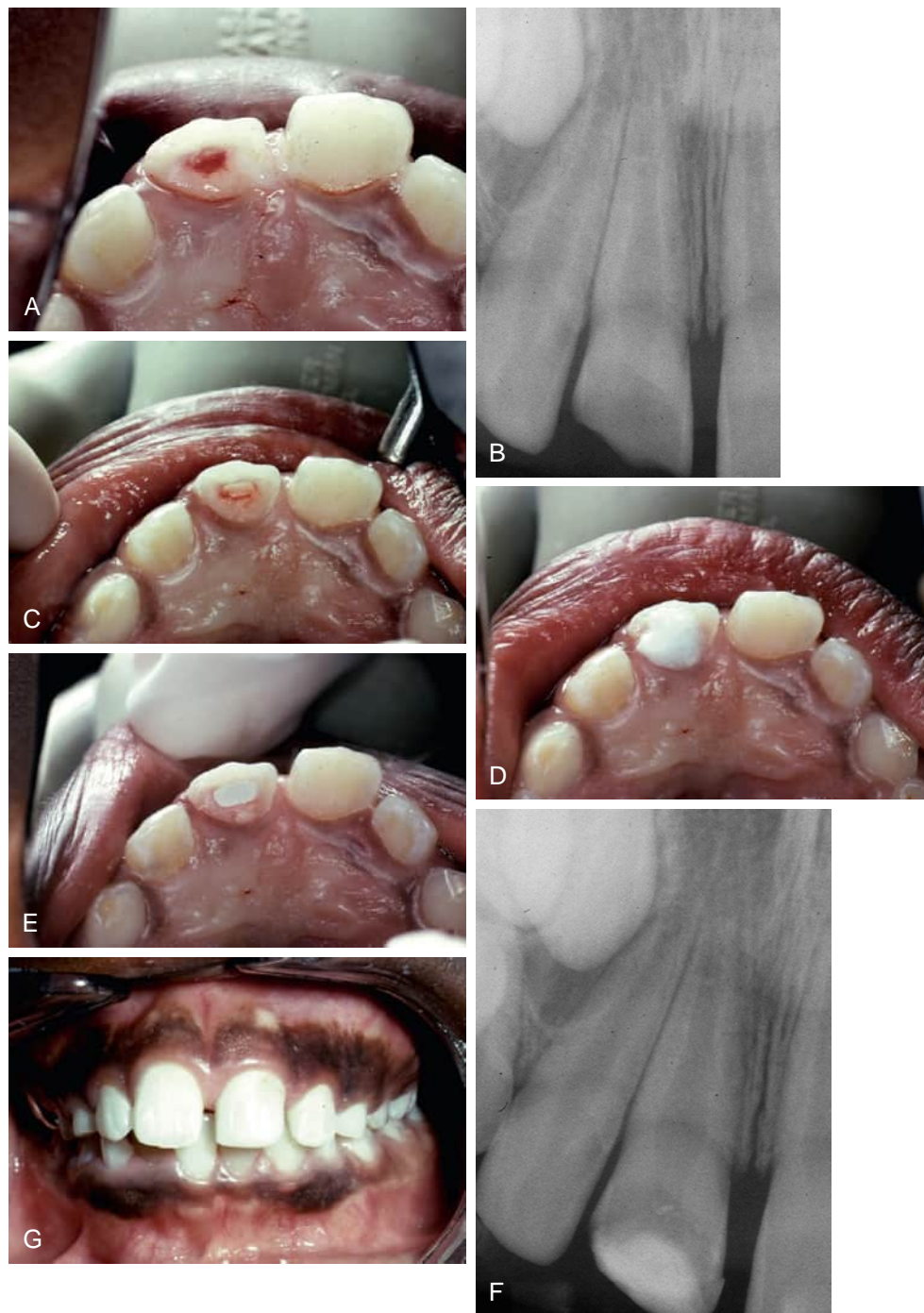
caused interrupted growth of the root canal, and the dentist is faced with the task of treating a canal with an open apex.

If an abscess is present, it must be treated first. If there is acute pain and evidence of swelling of the soft tissues, drainage through the pulp canal will give the child almost immediate relief. A conventional endodontic access opening should be made into the pulp chamber. If pain is caused by the pressure required to make the opening into the pulp, the tooth should be supported by the dentist's fingers. Antibiotic therapy is also generally indicated.

## Therapy to Stimulate Root Growth and Apical Repair in Immature Teeth With Pulpal Necrosis

### APEXIFICATION

The conventional treatment of pulpless anterior teeth usually requires apical surgery if the teeth have open apices. Many

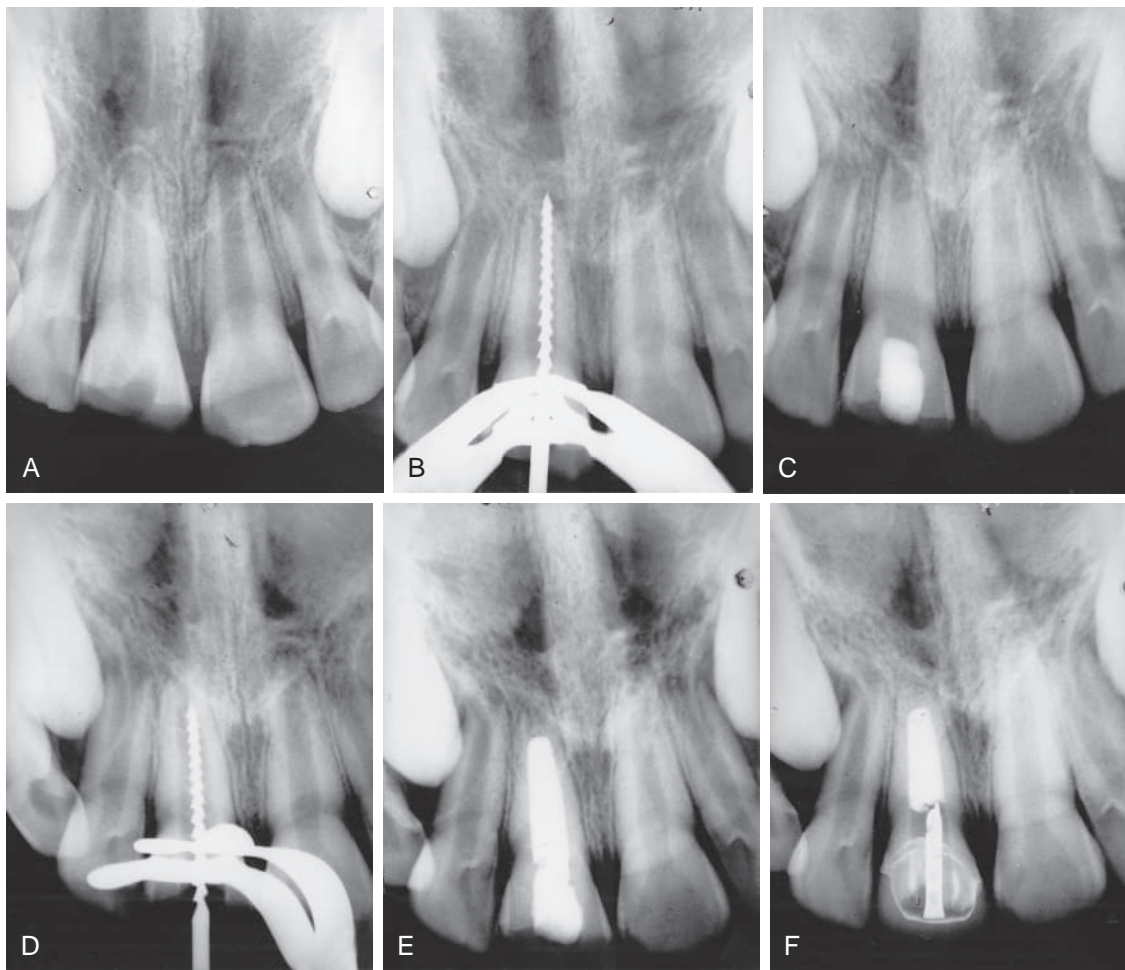


**Fig. 28.8** (A) Severe complicated fracture of the maxillary right central incisor. The trauma occurred approximately 60 minutes earlier. (B) Maxillary periapical radiograph of traumatized incisor. Note the apical closure of the root tip. (C) After appropriate infiltration of local anesthesia (no local anesthesia was injected into the pulp tissue at the fracture site), approximately 2 mm of pulp tissue at the fracture was removed by means of a number 4 round diamond with gentle water irrigation. This created an undercut in tooth structure, facilitating retention of calcium hydroxide to be placed later during the procedure. Note the excellent hemostasis of the amputated pulp tissue. (D) A cotton pellet, moistened with sterile saline, was placed over the pulp tissue for 5 minutes. (E) After verification of excellent hemostasis following use of the moistened cotton pellet, calcium hydroxide was used to fill the area created during pulp removal. (F) Maxillary radiograph after placement of the calcium hydroxide. (G) Clinical picture of incisor 3 months after the traumatic event. Normal responses to both electric and cold pulp testing were obtained at 1-, 2-, and 3-month observation intervals. A permanent restoration is planned.

young teeth have been saved in this manner. However, a less traumatic endodontic therapy called *apexification* has been found to be effective in the management of immature, necrotic permanent teeth. The apexification procedure should precede conventional root canal therapy in the management of teeth with irreversibly diseased pulps and open apices.

Frank<sup>14</sup> described a technique based on the normal physiologic pattern of root development that brings about the resumption of apical development so that the root canal can be obliterated by conventional canal-filling techniques. The procedure has been demonstrated to be successful in repeated clinical trials stimulating the process of root end





**Fig. 28.9** Series of radiographs demonstrating treatment to stimulate root-end development of a pulpless young anterior permanent central incisor. (A) An injury several months before had resulted in a pulp exposure. An acute abscess was present at the beginning of treatment. An opening to the pulp chamber was made to allow for drainage. (B) Four days after the initial treatment, the canal length was established. Files were used to clean the canal. After cleansing and irrigation of the canal, calcium hydroxide and camphorated mono parachlorophenol were used to fill the canal. (C) One month after initial treatment. (D) Six months after initial treatment, a definite calcified stop was encountered when the file was introduced. The canal was cleansed thoroughly, and gutta-percha was used to fill the canal. (E) Five months after the placement of the gutta-percha canal filling. (F) A 6-month postoperative radiograph. A tube and resin core was placed, and the tooth was restored with a jacket crown. Currently, an aesthetic bonded composite resin restoration (or a fragment restoration if possible) would probably be the preferred interim restoration until the patient has attained adulthood. (Courtesy Drs. Paul E. Starkey and Joe Camp.)

development, which was interrupted by pulpal necrosis, so that it continues to the point of apical closure (Fig. 28.9). Often a calcific bridge develops just coronal to the apex. When the closure occurs, or when the calcific “plug” is observed in the apical portion, routine endodontic procedures may be completed; the possibility of recurrent periapical pathosis is thus prevented.

The following steps are included in the technique:

1. The affected tooth is carefully isolated with a rubber dam, and an access opening is made into the pulp chamber.
2. A file is placed in the root canal, and a radiograph is made to establish the root length accurately. It is important to avoid placing the instrument through the apex, which might injure the epithelial diaphragm.
3. After the remnants of the pulp have been removed using barbed broaches and files, the canal is flooded with hydrogen peroxide to aid in the removal of debris. The canal is then irrigated with sodium hypochlorite and saline.
4. The canal is dried with large paper points and loose cotton.
5. A thick paste of calcium hydroxide is transferred to the canal. An endodontic plugger may be used to push the material to the apical end, but excess material should not be forced beyond the apex.
6. A cotton pledget is placed over the calcium hydroxide, and the seal is completed with a layer of reinforced zinc oxide-eugenol cement.

Weine<sup>15</sup> recommends that the apexification procedure be completed in two appointments. After instrumentation, irrigation, and drying of the canal during the first appointment, he advises sealing a sterile, dry, cotton pellet in the pulp chamber for 1–2 weeks. Placing a calcium hydroxide dressing in the canal is optional at the first appointment. During the second appointment, the debridement procedures are repeated before the canal is filled with a thick paste of calcium hydroxide and camphoric p-monochlorophenol (CMCP) or calcium hydroxide in a methylcellulose paste.

Whether the tooth is filled in one or two appointments (or more) should be determined largely by the clinical signs and symptoms present and to a lesser extent by operator convenience. All signs and symptoms of active infection should be eliminated before the canal is filled with the treatment paste. Absence of tenderness to percussion is an especially good sign before the canal is filled. Because of the wide-open access to periapical tissues, it is not always possible to maintain complete dryness in the root canal. If the canal continues to weep, but other signs of infection seem to be controlled after two or three appointments, the dentist may elect to proceed with the calcium hydroxide paste treatment.

As a rule, the treatment paste is allowed to remain for 6 months. The root canal is then reopened to determine whether the tooth is ready for a conventional gutta-percha filling, as determined by the presence of a “positive stop” when the apical area is probed with a file. Often, there is also radiographic evidence of apical closure. Frank<sup>14</sup> has described four successful results of apexification treatment: (1) continued closure of the canal and apex to a normal appearance, (2) a dome-shaped apical closure with the canal retaining a blunderbuss appearance, (3) no apparent radiographic change but a positive stop in the apical area, and (4) a positive stop and radiographic evidence of a barrier coronal to the anatomic apex of the tooth.

If apical closure has not occurred in 6 months, the root canal is re-treated with the calcium hydroxide paste. If weeping in the canal was not controlled before the canal was filled, re-treatment is recommended 2 or 3 months after the first treatment.

Ideally, the postoperative radiographs should demonstrate continued apical growth and closure as in a normal tooth. However, any of the other three previously described results is considered successful. When closure has been achieved, the canal is filled in the conventional manner with gutta-percha.

Currently, there seems to be a trend away from the incorporation of antibacterial agents, such as CMCP, into the calcium hydroxide treatment paste. It is generally agreed that calcium hydroxide is the major ingredient responsible for stimulating the desired calcific closure of the apical area. Calcium hydroxide is also an antibacterial agent. It may be that CMCP does not enhance the repair; on the other hand, its use as described here has not been shown to be detrimental. Certainly more than one treatment paste has been employed with success. Giuliani et al.<sup>16</sup> have demonstrated the use of MTA to form an apical plug for apexification in three clinical cases (Fig. 28.10). The root canals of central incisors that had suffered premature interruption of root development because of trauma were rinsed with 5% sodium hypochloride. Calcium hydroxide was then placed in the canals for 1 week. Following this, the apical portion of the canal (4 mm) was filled with MTA and the remaining portions of the root canals were closed with thermoplastic gutta-percha. At the 6-month and 1-year follow-ups, the clinical and radiographic appearance of the teeth showed resolution of the periapical lesions. These researchers suggest that MTA is a valid option for apexification. Teeth treated by the apexification method are susceptible to fracture because of the brittleness that results from nonvitality and from the relatively thin

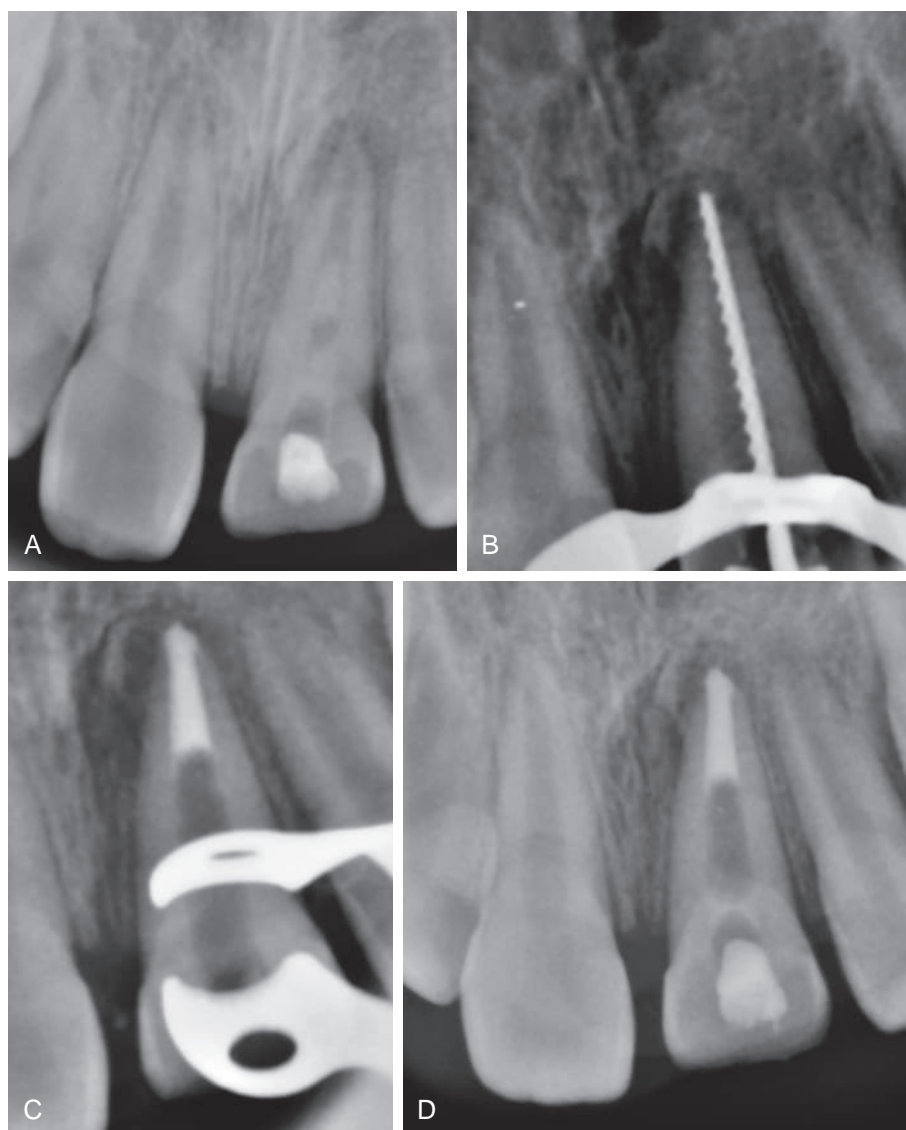
dental walls of the roots. In addition, another important problem with the calcium hydroxide apexification technique is the duration of therapy, which often lasts many months.

## REGENERATIVE ENDODONTIC PROCEDURES

Regenerative endodontic procedures (REPs) can be defined as biologically based procedures designed to replace damaged structures, which include dentin, root structures, and cells of the pulp–dentin complex.<sup>17</sup> These procedures provide a biological alternative to induce continuous root development and reduce the risk of fracture associated with traditional treatments of immature teeth with necrotic pulps, such as calcium hydroxide or MTA apexification, where the root remains thin and weak (Fig. 28.11). The premise of endodontic regeneration was suggested in 1961, when Nygaard-Östby<sup>18</sup> evaluated the role of blood clots in endodontic therapy. In 1971, Nygaard-Östby and Hjørt-dal<sup>19</sup> discussed the use of growth-promoting substances to help in the healing process after partial root canal filling. Following this, REPs were largely ignored for 30 years, until the first clinical case of contemporary REPs was published by Iwaya et al.<sup>20</sup> in 2001. In the last two decades, numerous case reports and retrospective clinical studies have demonstrated notable improvements in some clinical outcomes after REP treatment of immature teeth with pulpal necrosis. These improvements include healing of periapical pathology, continued development of the root apex, and increased thickness of the root canal wall.

Nakashima and Akamine<sup>21</sup> described three key ingredients for tissue engineering: stem cells, scaffolds, and growth factors. Stem cells are undifferentiated cells that continuously divide. Numerous types of multipotent adult stem cells have been identified from teeth and were hypothesized to play an important role in endodontic regeneration, such as stem cells from apical papilla, dental pulp stem cells, and periodontal ligament stem cells. The second key element is the scaffold, which provides a matrix for cell organization, proliferation, differentiation, and revascularization. Contemporary REPs have used dentin and blood clots to provide scaffolds in the root canal. However, various scaffolds made of natural or synthetic materials have been proposed in an attempt to create more controlled three-dimensional scaffolds inside the root canal.<sup>22</sup> The third key element is growth factors. These are biological signaling proteins that regulate cellular proliferation, differentiation, and maturation. Current REPs rely mainly on the ability of root canal dentin to release important signaling molecules that may play an important role in regenerative procedures.

Most contemporary REPs rely on the chemical debridement of the root canal, as there is minimal or no mechanical instrumentation. The main objective of chemical debridement is the elimination of microorganisms and necrotic tissues from the root canal system, and this step has been suggested to be the essential factor in successful REPs. Root canal irrigation with sodium hypochlorite has been suggested to disinfect the root canal and to eliminate the necrotic organic materials from the canal system during REPs. However, higher concentrations of sodium hypochlorite have harmful effects on the differentiation and survival of dental pulp stem cells.<sup>23</sup> Therefore, 1.5% sodium

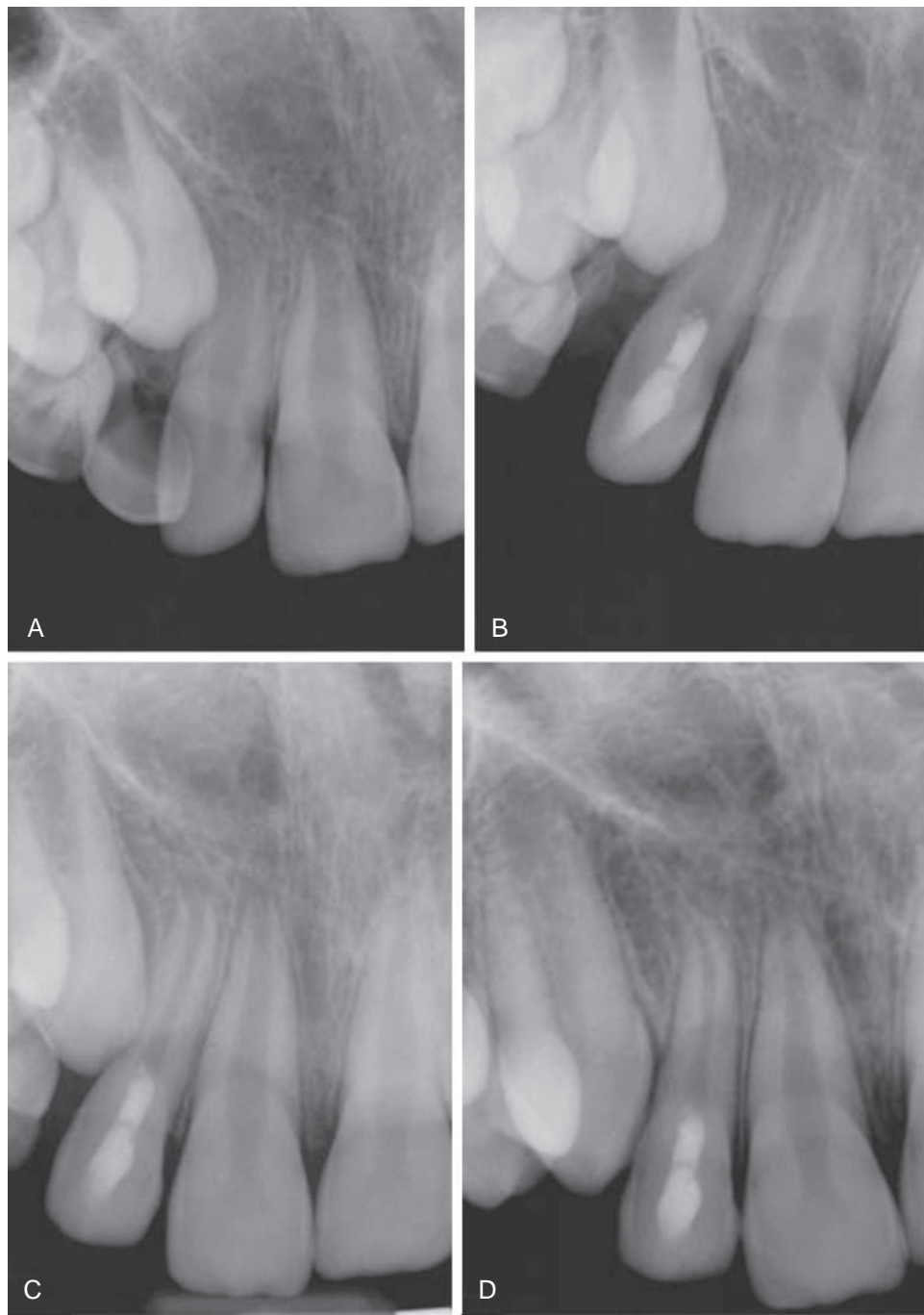


**Fig. 28.10** (A) Maxillary right central incisor with periapical pathology secondary to trauma. The canal has been opened, rinsed with 5% sodium hypochlorite, dried, and filled with calcium hydroxide. (B) Approximately 7 days after initial treatment with calcium hydroxide, the incisor was instrumented to remove all remaining tissue before further treatment. (C) The apical 4–5 mm of the incisor root has been filled with mineral trioxide aggregate (MTA). (D) The incisor has completed initial treatment with MTA. A temporary restoration has been placed to seal the canal opening. It was thought that several months of observation would be desirable before the final gutta-percha placement on top of the MTA apical seal. (Courtesy Dr. Joseph Legan.)

hypochlorite has been suggested for use in REPs due to its minimal toxic effects on the dental pulp stem cells. On the other hand, root canal irrigation with 17% ethylenediaminetetraacetic acid (EDTA) has been recommended as a final irrigation step during REPs. EDTA was suggested to condition the superficial root canal walls, expose the dentin protein matrix, and improve dental pulp stem cell proliferation. However, intracanal medicaments used in REPs, such as various antibiotic mixtures and calcium hydroxide, have also been suggested to have a role in exposing various dentinal proteins.<sup>24</sup> The application of intracanal medicaments has been adopted in all suggested REPs. The most widely used intracanal medicament in endodontic regeneration is the triple antibiotic paste described by Hoshino et al.,<sup>25</sup> which is a mixture of water and equal parts of metronidazole, ciprofloxacin, and minocycline. However, significant tooth discoloration after the application of triple antibiotic

paste has been reported to occur due to staining of the dentin by the minocycline present in the paste. Sealing the pulp chamber with flowable composite resin before the triple antibiotic paste application and maintaining the paste below the cemento-enamel junction have been suggested to minimize the staining effect of the paste.<sup>26</sup> Other authors proposed eliminating the minocycline and keeping only metronidazole and ciprofloxacin in the antibiotic paste or substituting the minocycline with another antibiotic, such as clindamycin, cefaclor, or amoxicillin.<sup>23</sup> Recent in vitro studies raised some concerns regarding the cytotoxic effects of various antibiotic combinations used in REPs on the dental pulp stem cells. Therefore lower concentrations of these antibiotic mixtures (0.1 mg/mL) have been recommended to avoid stem cell toxicity.<sup>27</sup> It is noteworthy that the short-term application of calcium hydroxide paste has also been successfully used in REPs.<sup>28</sup> Indeed, the effects of





**Fig. 28.11** Series of radiographs demonstrating the case of an immature necrotic tooth treated with the endodontic regeneration approach according to the recent guidelines of the American Association of Endodontists. (A) Immature permanent upper right lateral incisor with pulpal necrosis and periapical abscess secondary to dental trauma. The pulp chamber was accessed, canal length was established, and pus was drained from the canal via small capillary tubes connected to high-speed suction. The canal was rinsed with 20 mL of 1.5% sodium hypochlorite, followed by 20 mL of sterile saline, and dried with paper points. Triple antibiotic paste composed of clindamycin, ciprofloxacin, and metronidazole was prepared and placed into the canal by means of a special syringe. (B) Four weeks after the initial treatment, no negative clinical signs and symptoms were observed. The canal was accessed, irrigated with 17% EDTA, and dried with paper points. A size 60 endodontic file was used to lacerate the apical papilla and induce bleeding into the canal up to the cemento-enamel junction. A small piece of CollaTape was placed over the clot, and 3 mm of white MTA was applied to seal the access opening, followed by a composite resin permanent restoration. (C) Six-month follow-up radiograph shows the start of root maturation with an increase in root length. (D) Thirteen-month follow-up radiograph indicates complete root formation with an increase in length and thickness of the root. There was a positive EPT reading.

calcium hydroxide paste were found to be less detrimental to stem cells of the apical papillae compared with effects of various antibiotic mixtures.<sup>27</sup> A biocompatible disinfection protocol utilizing both irrigation solutions and intracanal

medicament to effectively eradicate a root canal infection and create an environment conducive to the proliferation and differentiation of dental pulp stem cells is an important aim to improve the outcomes of REPs.

### Box 28.1 Summary box of clinical protocol of endodontic regeneration procedure recommended by American Association of Endodontists

#### First Visit

- Administer anesthesia and apply rubber dam.
- Establish working length.
- Gently irrigate with 1.5% sodium hypochlorite followed by 17% EDTA.
- Dry the canal and apply calcium hydroxide or double antibiotic paste (1–5 mg/mL).
- Apply temporary restoration and dismiss the patient for 1–4 weeks.

#### Second Visit

- Repeat steps in the first visit if there are clinical signs or symptoms of persistent infection.
- Administer epinephrine-free anesthesia and apply rubber dam.
- Access root canal and irrigate gently with 17% EDTA.
- Induce bleeding into the canal by overinstrumentation with an endodontic file.
- Stop bleeding 3 mm from the cemento-enamel junction and apply collagen matrix.
- Apply 3–4 mm layer of white MTA or other tricalcium silicate cement.
- Apply a layer of glass ionomer followed by permanent coronal restoration.

Currently, there is no standardized clinical protocol regarding REPs. Indeed, several variations of REPs have been suggested. The American Association of Endodontists has recommended the following treatment protocol based on the best evidence level from clinical case studies and preclinical translational investigations (Box 28.1; Fig. 28.11).<sup>29</sup>

#### First Appointment

1. After administration of adequate local anesthesia, the affected tooth is carefully isolated with a rubber dam, and an access opening is made into the pulp chamber.
2. A file is placed 1 mm from the root end in the root canal, and a radiograph is made to establish the root length accurately.
3. Each root canal is slowly irrigated with 20 mL of 1.5% sodium hypochlorite for 5 minutes followed by irrigation with 20 mL of saline for 5 minutes. A closed-end needle or the EndoVac negative pressure irrigation system should always be used to deliver the irrigation solutions during REP to minimize the possibility of extrusion of irrigants into the periapical space.
4. The canal is dried with large paper points.
5. Antibiotic or calcium hydroxide paste is applied into the canal via a lentulo spiral or Centrix syringe. For antibiotic paste, mix equal portions of metronidazole, ciprofloxacin, and minocycline with sterile water to create a pasty consistency. However, a lower concentration of antibiotics is preferable (0.1 mg/mL).
6. Seal the root canal with 3- to 4-mm Cavit, followed by a temporary restorative material, and dismiss the patient for 1–4 weeks.

#### Second Appointment

1. Evaluate the affected tooth response to initial treatment. If there are no clinical signs or symptoms of persistent infection, proceed with step 2. If there is evidence (e.g., sinus tract, percussion sensitivity), consider additional treatment with NaOCl irrigation and the antibiotic intracanal medicament and recall the patient after 1–4 weeks.
2. After administration of adequate local anesthesia, 3% mepivacaine (no epinephrine), the affected tooth is isolated with a rubber dam.
3. The root canal is accessed, and the intracanal paste is removed by gentle irrigation with 20 mL of 17% EDTA followed by normal saline using a closed-end needle or the EndoVac system.
4. The canal is dried with large paper points.
5. Bleeding is induced into the root canal by overinstrumentation with an endodontic file.
6. Bleeding is stopped 3 mm from the cemento-enamel junction.
7. A collagen matrix such as CollaPlug is placed at 3 mm below the cemento-enamel junction.
8. A 3- to 4-mm layer of white MTA is placed, followed by reinforced glass ionomer and permanent coronal restoration. Glass ionomer may be an alternative to MTA in cases where crown discoloration is a potential aesthetic concern.

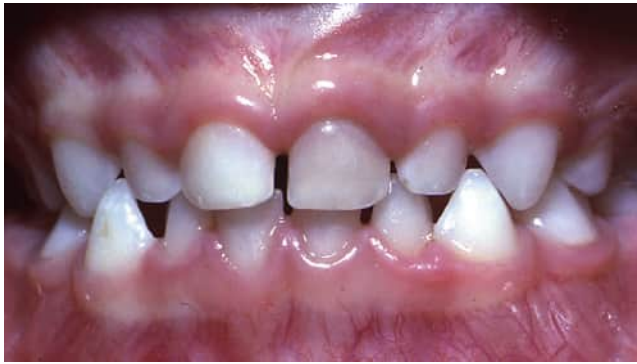Cases treated with REPs need to be followed up at 3 months, 6 months, and annually thereafter for 4 years. Absence of signs and symptoms of pathosis, as well as radiographic evidence of bony healing within 2 years of treatment, should be expected. However, the clinical expectations for REPs are not well defined. Geisler<sup>30</sup> suggested that the degree of success of REPs can be measured by the achievement of a primary goal, which is the absence of symptoms and radiographic evidence of periapical healing. Secondary desirable yet not essential goals are increases in the thickness of the root walls and/or increases in the length of the immature root. Tertiary goals, indicating a high level of success, include regaining the vitality of the tooth. Clinical signs and symptoms after REPs, such as swelling, pain, or an increase in radiolucency, indicate failure of REPs, and more traditional treatment modalities should be initiated, such as MTA apical plug.<sup>31</sup>

## Reaction of the Tooth to Trauma

### PULPAL HYPEREMIA

The dentist must be cognizant of the inadequacies of present methods of determining the initial pulpal reaction to an injury and of the difficulty in predicting the long-range reaction of the pulp and supporting tissues to the insult. A trauma of even a so-called minor nature is immediately followed by pulpal hyperemia.

Congestion of blood within the pulp chamber a short time after the injury can often be detected in the clinical examination. If a strong light is directed to the labial surface of the injured tooth and the lingual surface is viewed in a mirror, the coronal portion of the tooth will often appear reddish compared with the adjacent teeth. The color change may be evident for several weeks after the accident and often indicates a poor prognosis.



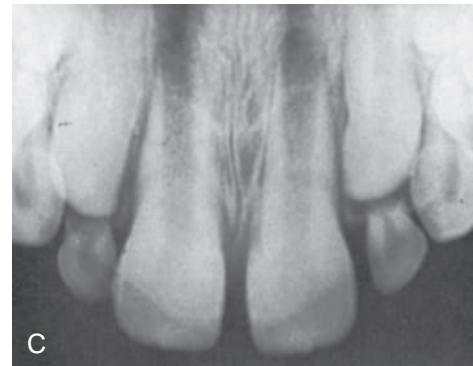
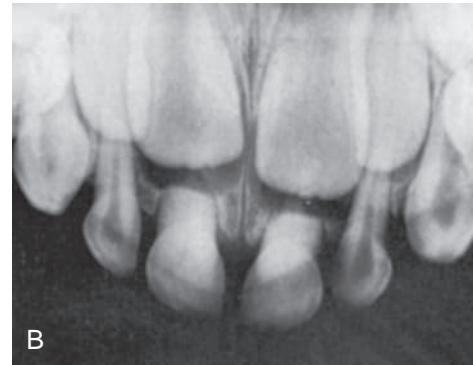
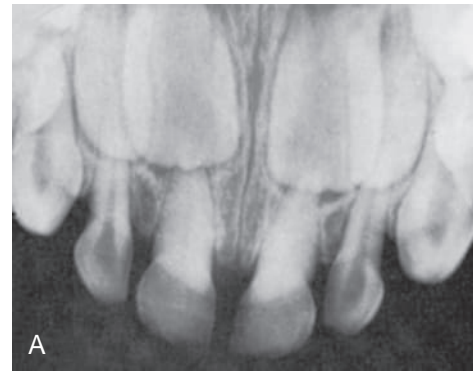
**Fig. 28.12** Maxillary left primary central incisor became discolored within 2 weeks after trauma. A pulp test indicated that the pulp was vital.

### INTERNAL HEMORRHAGE

The dentist will occasionally observe temporary discoloration of a tooth after injury. Hyperemia and increased pressure may cause the rupture of capillaries and the escape of red blood cells, with subsequent breakdown and pigment formation. The extravasated blood may be reabsorbed before gaining access to the dentinal tubules, in which case little if any color change will be noticeable and what does appear will be temporary (Fig. 28.12). In more severe cases, there is pigment formation in the dentinal tubules. The change in color is evident within 2–3 weeks after the injury, and although the reaction is reversible to a degree, the crown of the injured tooth retains some of the discoloration for an indefinite period. In such cases, there is some chance that the pulp will retain its vitality, although the likelihood of vitality is apparently low in primary teeth with dark-gray discoloration. Croll et al.<sup>32</sup> found that 33 of 51 traumatized teeth (65%) with gray-black discoloration were necrotic. Holan and Fuks<sup>33</sup> conducted a retrospective study of 88 pulpectomized primary incisors, 48 of which met their nine clinical and radiographic criteria for further investigation. Briefly, their criteria included dark-gray coronal discoloration as the primary diagnostic sign before pulpectomy. The remaining criteria were indicative of normal conditions or conditions only somewhat suggestive of a pulpal problem. They found that 47 (98%) of the teeth included in the study were either necrotic (37, or 77%) or partially necrotic (10, or 21%). Because all of these teeth were previously determined to need pulpectomy, the 98% confirmation is not surprising. However, the fact remains that all the teeth exhibited dark-gray discoloration and few, if any, other minor signs or symptoms of a problem. Discoloration that becomes evident for the first time months or years after an accident, however, is evidence of a necrotic pulp.

### CALCIFIC METAMORPHOSIS OF THE DENTAL PULP (PROGRESSIVE CANAL CALCIFICATION OR DYSTROPHIC CALCIFICATION)

A frequently observed reaction to trauma is the partial or complete obliteration of the pulp chamber and canal (Fig. 28.13). Although the radiograph may give the illusion of complete obliteration, an extremely fine root canal and remnants of the pulp will persist.



**Fig. 28.13** (A) Radiograph demonstrates almost complete obliteration of the pulp chambers and canals. (B) Normal root resorption of the primary incisors has occurred. (C) The permanent incisors have erupted.

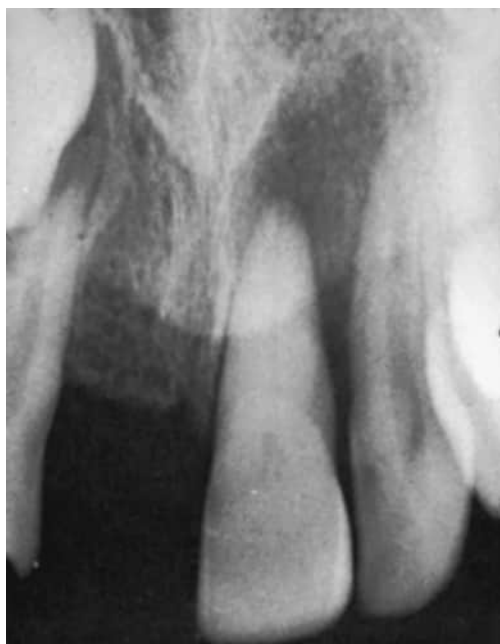The crowns of teeth that have undergone this reaction may have a yellowish, opaque color. Primary teeth demonstrating calcific metamorphosis will usually undergo normal root resorption; however, Peterson et al.<sup>34</sup> have reported observing one patient who exhibited calcific metamorphosis of a maxillary primary central incisor that subsequently showed evidence of significant internal resorption in the root. They emphasize the need for careful monitoring of traumatized teeth that have undergone calcific metamorphosis.

Permanent teeth will often be retained indefinitely. However, a permanent tooth showing signs of calcific changes because of trauma should be regarded as a potential focus of infection. A small percentage of such teeth demonstrate pathologic change many years after the injury (Fig. 28.14).

### INTERNAL RESORPTION

Internal resorption is a destructive process generally believed to be caused by odontoclastic action. It may be



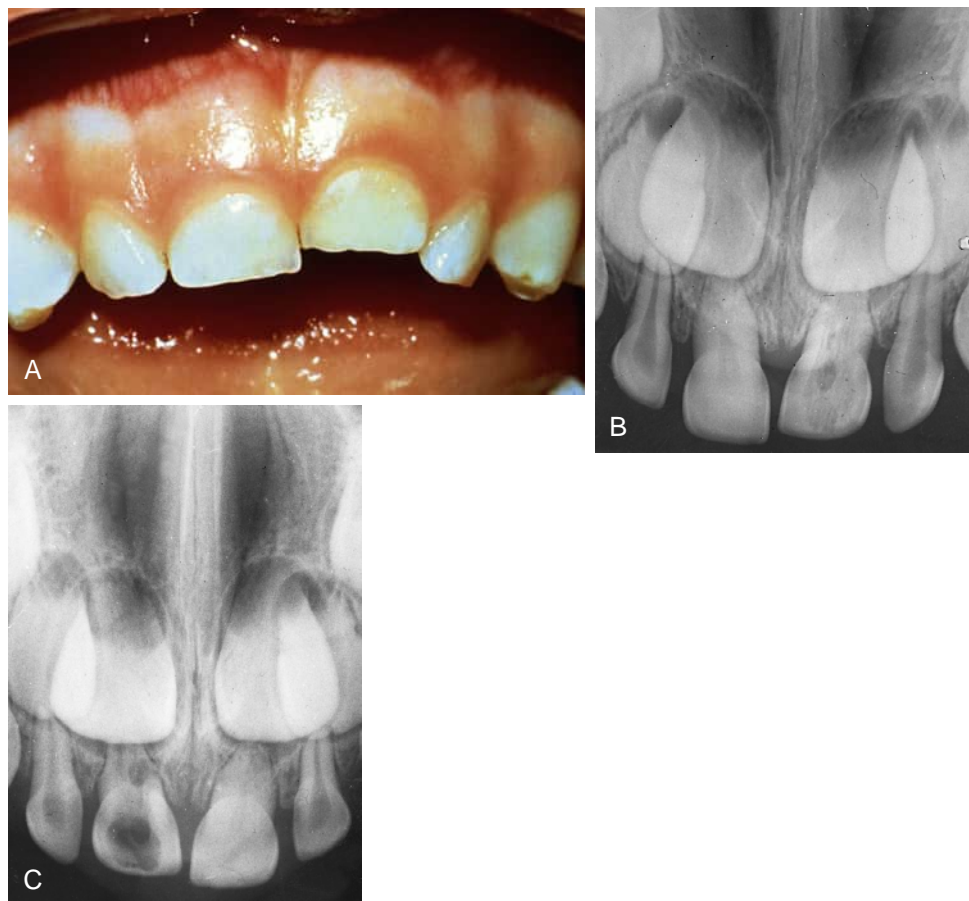

**Fig. 28.14** Trauma occurred 10 years before acute symptoms developed in the left central incisor. An apical lesion area may be seen. The right central incisor was lost at the time of the injury.

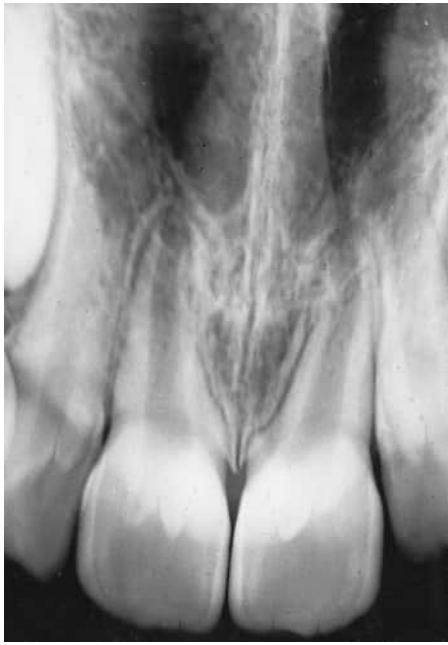observed radiographically in the pulp chamber or canal within a few weeks or months after an injury. The destructive process may progress slowly or rapidly. If progression is rapid, it may cause a perforation of the crown or root within a few weeks (Fig. 28.15). Mummery<sup>35</sup> described this condition as “pink spot” because when the crown is affected, the vascular tissue of the pulp shines through the remaining thin shell of the tooth. He referred to the occurrence of a perforation as “perforating hyperplasia of the pulp.” If evidence of internal resorption is detected early, before it becomes extensive with resulting perforation, the tooth may possibly be retained when endodontic procedures are instituted.

### PERIPHERAL (EXTERNAL) ROOT RESORPTION

Trauma with damage to the periodontal structures may cause peripheral root resorption (Fig. 28.16). This reaction starts from without, and the pulp may not become involved. Usually the resorption continues unabated until gross areas of the root have been destroyed. This resorption reaction starts without pulp involvement and the pulp may not become involved. Peripheral root resorption is most often observed in cases of severe trauma in which there has been some degree of displacement of the tooth.



**Fig. 28.15** Internal resorption in a traumatized left primary incisor. (A) The tooth 6 months after injury. The tooth has a slight color change as compared with the nontraumatized maxillary right primary incisor. (B) A later radiograph shows internal resorption in the pulp chamber and canal and some evidence of attempted repair. (C) This radiograph shows the subsequent degree of resorption. The tooth was extracted.



**Fig. 28.16** Radiographic evidence of peripheral root resorption. In these teeth, the pulp vitality was retained and root resorption did not continue.

## PULPAL NECROSIS

Little relationship exists between the type of injury to the tooth and the reaction of the pulp and supporting tissues. A severe blow to a tooth causing displacement often results in pulpal necrosis. The blow may cause a severance of the apical vessels, in which case the pulp undergoes autolysis and necrosis. In a less severe type of injury, the hyperemia and slowing of blood flow through the pulpal tissue may cause eventual necrosis of the pulp. In some cases, the necrosis may not occur until several months after the injury.

A tooth receiving an injury that causes coronal fracture may have a better pulpal prognosis than a tooth that sustains a severe blow without fracturing the crown. Rather than all of the energy of the blow being absorbed by the tooth's supporting tissues, part of the energy dissipates as the crown fractures. Thus, the periodontium and the pulp of the injured tooth sustain fewer traumas when the crown fractures. The prognosis for long-term retention of the tooth and for maintenance of pulp vitality may then improve. However, because some teeth do not recover from traumatic blows that seem relatively minor, all injured teeth should be closely monitored.

Injured teeth with subsequent pulpal necrosis are commonly asymptomatic, and the radiograph is essentially normal. It should be realized, however, that these teeth are probably infected and that acute symptoms and clinical evidence of infection will inevitably develop at a later date. The tooth with a necrotic pulp should therefore be extracted or treated with endodontic procedures, whichever is indicated.

A necrotic pulp in an anterior primary tooth may be successfully treated if no extensive root resorption or bone loss has occurred (Fig. 28.17). The treatment technique is essentially the same as that for permanent teeth. However, trauma to the periapical tissues during canal

instrumentation must be carefully avoided. After the canal has been properly prepared via a facial access in this example, it is filled with a nonreinforced zinc oxide eugenol or alternatively, iodoform-based paste (KRI) or a combination paste of iodoform and calcium hydroxide (Vitapex, Endoflax). The canal walls are first lined with a thin mix of the canal-filling material. A thicker mix should then be placed in the pulp chamber. Over this is placed a cotton pellet, and the material is forced into the canal with a small amalgam plugger.

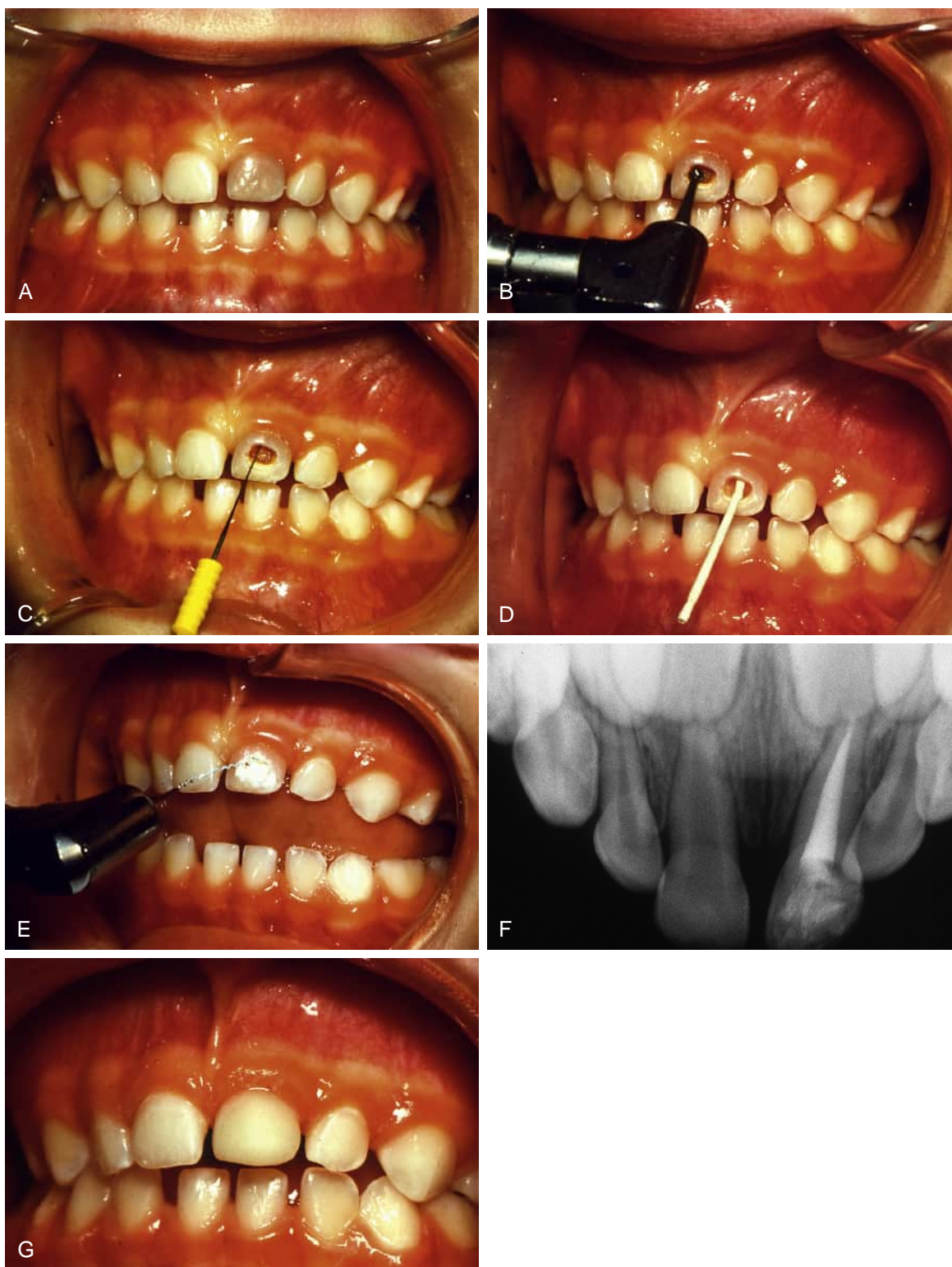## ANKYLOSIS

Another reaction observed after trauma to anterior primary or permanent teeth is ankylosis, a condition caused by injury to the periodontal ligament and subsequent inflammation, which is associated with invasion by osteoclastic cells. The result is irregularly resorbed areas on the peripheral root surface. In histologic sections, repair can be seen that may cause a mechanical lock or fusion between alveolar bone and the root surface. Clinical evidence of ankylosis is seen as a difference in the incisal plane of the ankylosed tooth and adjacent teeth. The adjacent teeth continue to erupt, whereas the ankylosed tooth remains fixed in relation to surrounding structures. The radiograph may show an interruption in the periodontal membrane of the ankylosed tooth, and often the dentin may appear to be continuous with alveolar bone.

The ankylosed anterior primary tooth should be removed if there is evidence of its causing delayed or ectopic eruption of the permanent successor. If ankylosis of a permanent tooth occurs during active eruption, eventually a discrepancy between the position of this tooth and its adjacent ones will be obvious. The uninjured teeth will continue to erupt and may drift mesially, with a loss of arch length. Therefore, either surgical repositioning or the removal of a permanent tooth that becomes ankylosed is often necessary, especially if the ankylosis occurs during the preteen or early teen years.

## Restoration of Fractured Teeth

The restoration of a fractured tooth is as important as the emergency treatment designed to aid in the recovery of the pulp after the trauma. Several restorations have been advocated; although the dentist has a wide choice of techniques and types of restorations, the circumstances surrounding the case often dictate the type of restoration for a given patient. The prognosis of pulp healing, the amount of tooth structure remaining, the stage of eruption of the tooth and adjacent teeth, the size of the dental pulp and degree of root closure, the normalcy of the occlusion, and the wishes of the patient must all be considered in the selection of a temporary restoration, an intermediate restoration, or the permanent restoration. In the young patient, although it is often desirable to wait for continued eruption of the tooth or to determine the outcome of a vital pulp procedure, a delay of even a few weeks is often sufficient to allow the tipping of adjacent teeth, overeruption of opposing teeth, or other undesirable changes in the occlusion.



**Fig. 28.17** (A) Evidence of dark crown for the maxillary left central incisor, demonstrating possible pulpal necrosis. A pulp test indicated that the pulp was nonvital. (B) A conservative facial access was used to enter the pulp chamber. This access helped maintain tooth structure for the final restoration. (C) The canal was instrumented to remove all necrotic tissue. Special care was taken not to traumatize the periapical tissue during instrumentation. (D) A paper point was used to dry the canal thoroughly before placement of the filling material. (E) A nonreinforced zinc oxide–eugenol mix was gently spun into the canal by rotary instrumentation. (F) Postoperative radiograph showing excellent filling of the canal to the apex of the tooth. (G) Final restoration after the necrotic pulp was addressed. A facial composite restoration was used as a conservative restoration in this clinical presentation. (Courtesy Dr. James Weddell.)



## AESTHETIC BONDED COMPOSITE RESIN RESTORATION

The feathered-edge restorative technique without mechanical tooth preparation is appropriate in some situations, but it requires excessive contour in the restoration. It offers the advantage of creating less irritation to the pulp because little or no enamel modification is required. In some cases, the excess contour is relatively insignificant, but it may be more significant if the restoration is large (50% or more of the crown) or the fracture extends near or below the gingival tissue. Excessive contour on the lingual surface of a maxillary anterior tooth may interfere with normal occlusion.

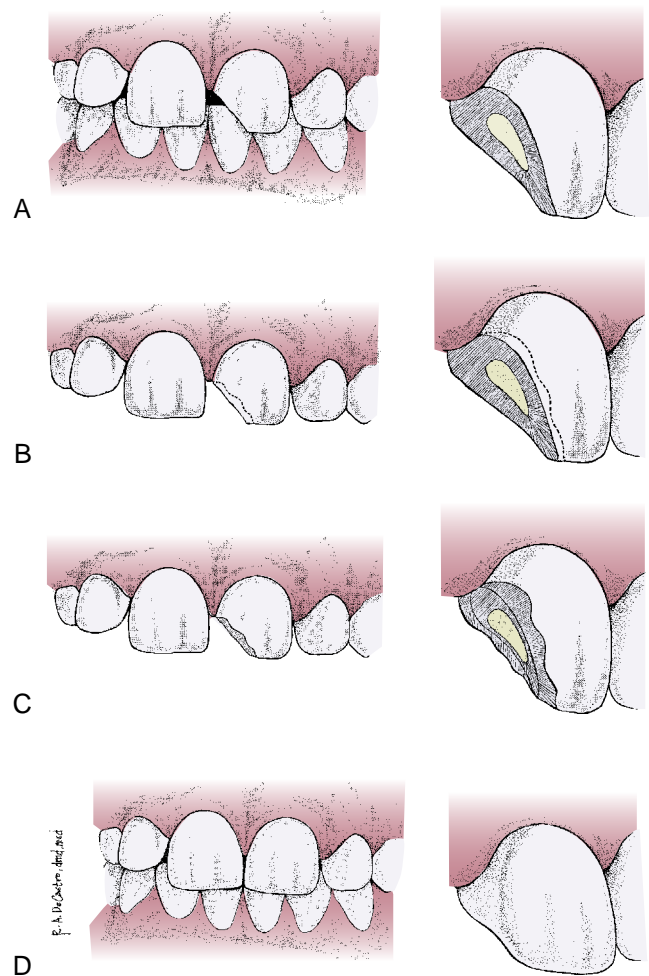
A beveled preparation affords the dentist the opportunity to reduce the amount of overcontouring of larger restorations, and it reduces contour in areas where the occlusion prohibits overcontouring. The dentist may elect the feathered-edge technique (no preparation) on the labial tooth surface and the beveled preparation on the proximal or lingual surface, or both. Both techniques are described in the following discussion.

When a beveled preparation is desired, the bevel is made in the enamel around the entire circumference or the selected part of the fracture (Fig. 28.18). The bevel should be about 1–2 mm incisocervically and about halfway (or more) through the thickness of the enamel at the fracture margins. The labial enamel margin should be irregular to provide a better aesthetic blending of the resin with the tooth structure. This sequence may be altered if the practitioner uses some of the latest bonding adhesive systems.

The exposed dentin from a recent injury may be covered with a calcium hydroxide liner. Dilute phosphoric acid (etchant or tooth conditioner) is applied to the enamel surface of the preparation for about 20 seconds (longer for primary teeth). The tooth is then thoroughly flushed with water, and excess moisture is removed with air. The etched area should appear frosty and opaque. Alternatively, the total-etch technique may be used. In either case, a bonding agent is applied to all etched tooth structures. Again, this sequence may be altered using some of the latest bonding adhesive systems.

A celluloid matrix strip may be placed interproximally and wedged for close adaptation at the gingival margin. In large restorations, a custom-cut celluloid crown form matrix may be used to help contour the restoration.

Often, little or no mechanical preparation of the fractured incisor is necessary with the feathered-edge technique. Instead, the resin margins are allowed to overlap the fractured edges to become feathered-edge margins on the etched sound enamel cervical to the fracture (Fig. 28.19). This procedure requires a slightly overcontoured restoration and therefore has limitations. The dentist should be alert to potential undesirable changes in gingival health or the creation of traumatic occlusion. Slight beveling of the fractured enamel margins is usually recommended with the feathered-edge technique to remove loose enamel rods and ensure a fresh surface for etching. The exposed dentin may be protected with a layer of hard-setting calcium hydroxide, and etching should extend 2 or 3 mm beyond the fracture to allow an adequate surface for feather-edging of the resin restorative materials. Most manufacturers supply a kit, which usually includes an etchant, a bonding agent, the



**Fig. 28.18** (A) Typical uncomplicated crown fracture of a permanent incisor. (B) Dotted line represents the approximate location of the irregular enamel margin to be placed on the labial surface in the bevel preparation. (C) Bevel preparation complete and ready for etching. (D) Bonded composite material restored natural contour and color.

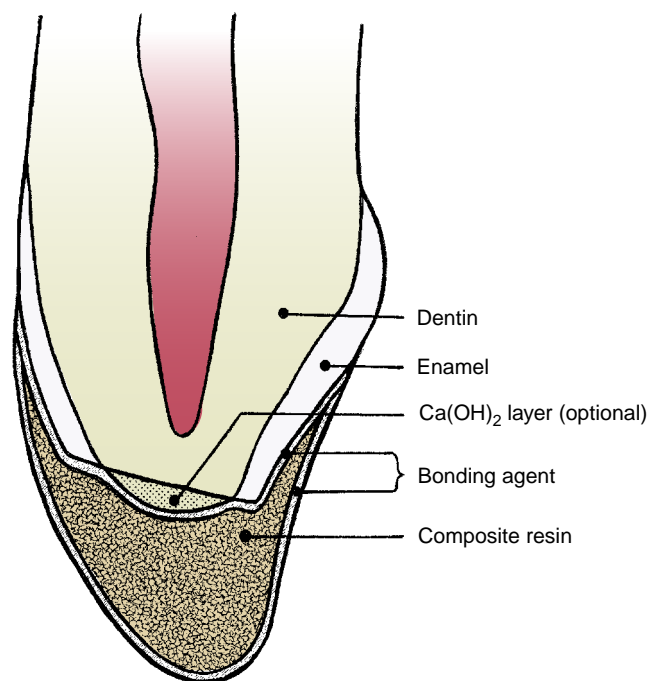
restorative materials, and a shade guide. The bonding agent is applied to the etched surfaces.

The light-polymerized materials offer the advantage of allowing the clinician to build or sculpt the restoration in small increments and minimize finishing time. Clinical studies have confirmed that excellent and durable restorations may be obtained. Finishing disks and large, round finishing burs or diamonds may be used to contour the labial and lingual surfaces.

## Reaction of Permanent Tooth Buds to Injury

The dentist who provides emergency care for a child after an injury to the anterior primary teeth must be aware of the possibility of damage to the underlying developing permanent teeth.

Andreasen et al.<sup>36</sup> have reported regarding the effects of injuries to primary teeth on their permanent successors. In a clinical and radiographic study of 213 teeth, these investigators reported that more than 40% of their young patients



**Fig. 28.19** This sagittal drawing illustrates the application of a feathered-edge restoration on a fractured incisor. Little or no tooth preparation is required before calcium hydroxide (optional) is placed on the exposed dentin and the tooth is etched. Slight beveling of the fractured enamel margins is suggested. The drawing also illustrates the need for overcontouring of the labial and lingual surfaces with the feathered-edge restoration.

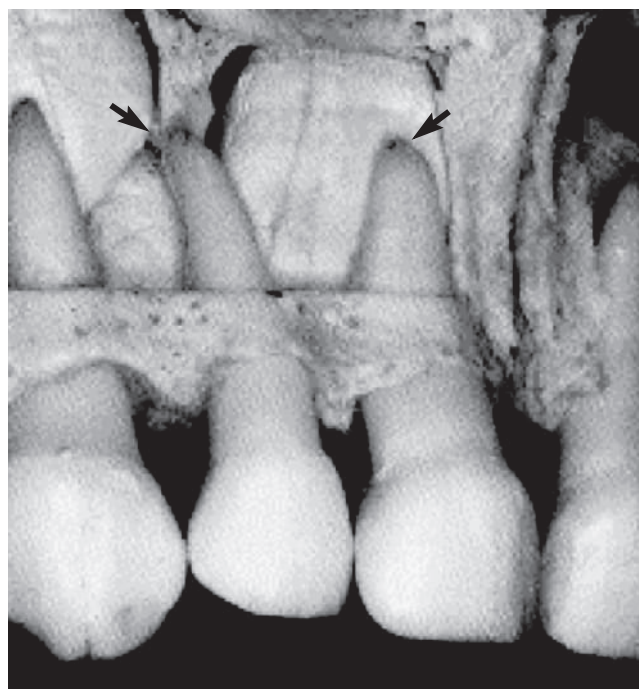had changes in the permanent teeth that could be traced to injury to the primary dentition. The close anatomic relationship between the apices of primary teeth and their developing permanent successors explains why injuries to primary teeth may involve the permanent dentition (Fig. 28.20).

The dentist and the physician should also be aware of the possibility of trauma to permanent tooth buds from other unusual injuries so that parents may be informed of the possibility of defective permanent tooth development. Some injuries to the face and jaws may not appear to have caused any dental injuries initially, but the problem may be noticed several months or years later (Fig. 28.21).

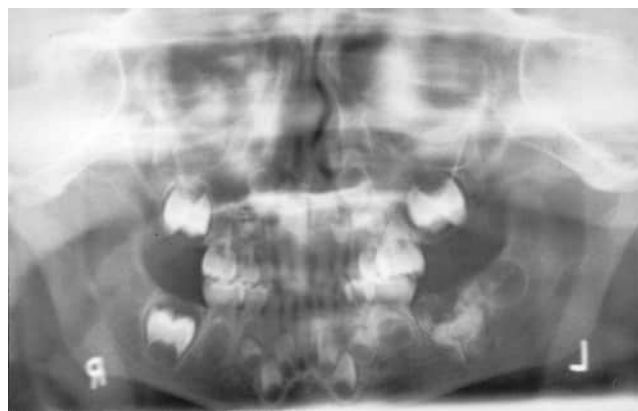### HYPOCALCIFICATION AND HYPOPLASIA

Cutright's<sup>37</sup> experiments with miniature pigs have shown many lesions similar to those seen in permanent human teeth because of trauma, infection, or both. He observed small areas that showed destruction of the ameloblasts and a pitted area where a thin enamel layer had been laid down before the injury. In other teeth, there was evidence of destruction of the ameloblasts before any enamel had been laid down, resulting in hypoplasia that clinically appeared as deep pitting.

Permanent teeth in humans may show a variety of these defects, including gross malformations of the crown (Fig. 28.22). The presence of a small, pigmented hypoplastic area has been referred to as *Turner's tooth*. Small hypoplastic defects may be restored by the resin-bonding technique.



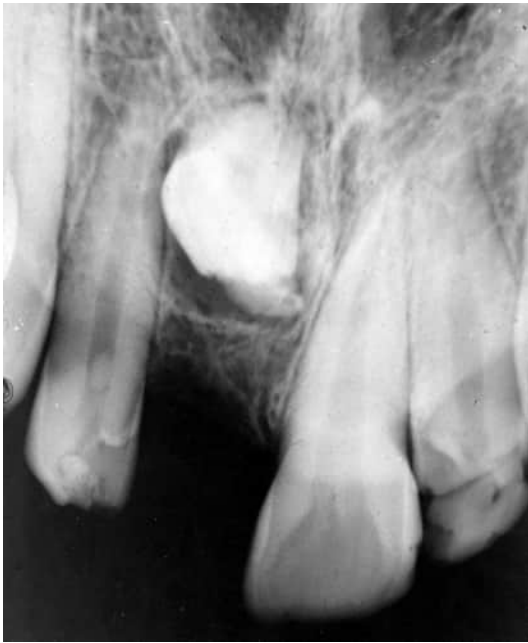**Fig. 28.20** Skull of a 5-year-old child demonstrating the relationship between the position of the roots of the primary central and lateral incisors and the crowns of their permanent successors (see arrows).



**Fig. 28.21** This radiograph of a 4-year-old child reveals improper formation of the mandibular left first permanent molar. At 18 months, the child had been viciously attacked by a dog. There had been a severe puncture wound of the lower left jaw from the dog's canines, although it was not known then that the injury involved the permanent molar tooth bud. The calcified lesion was removed and microscopically diagnosed as a developing tooth with displaced enamel matrix into follicular tissue. Early removal enhanced the potential of the normally developing second permanent molar to eventually acquire an acceptable first permanent molar position.

### REPARATIVE DENTIN PRODUCTION

In cases in which the injury to the developing permanent tooth is severe enough to remove the thin covering of developing enamel or cause destruction of the ameloblasts, the subjacent odontoblasts have been observed to produce a reparative type of dentin. The irregular dentin bridges the gap where there is no enamel covering to aid in protecting the pulp from further injury.



**Fig. 28.22** Radiograph of malformed central incisor. This condition can be traced to a severe trauma to the primary teeth.

## DILACERATION

The condition referred to as dilaceration occasionally occurs after the intrusion or displacement of an anterior primary tooth. The developed portion of the tooth is twisted or bent on itself, and growth of the tooth progresses in this new position. Cases have been observed in which the crown of a permanent tooth or a portion of it develops at an acute angle to the remainder of the tooth (Fig. 28.23). Kilpatrick et al.<sup>38</sup> reported regarding a dilacerated root of a primary central incisor in a 6-year-old boy. The tooth was necrotic, the root had not resorbed, and the apex of the root was exposed in the labial sulcus and was associated with a draining sinus. No specific history of trauma could be confirmed, but the child was prone to accidents. The authors speculate that this unusual dilaceration may have been due to injury soon after initial eruption of the tooth.

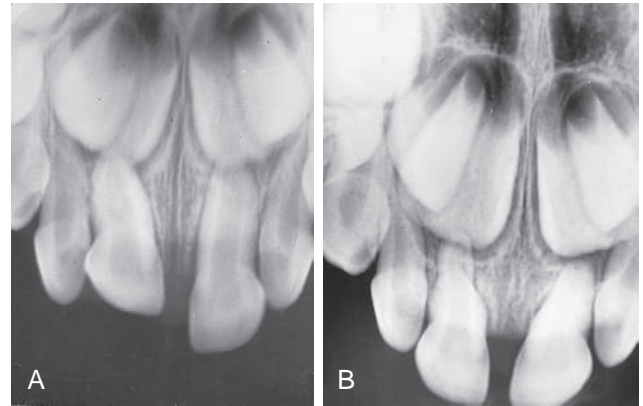
## Displacement of Primary and Permanent Anterior Teeth (Luxation)

### INTRUSION AND EXTRUSION OF TEETH

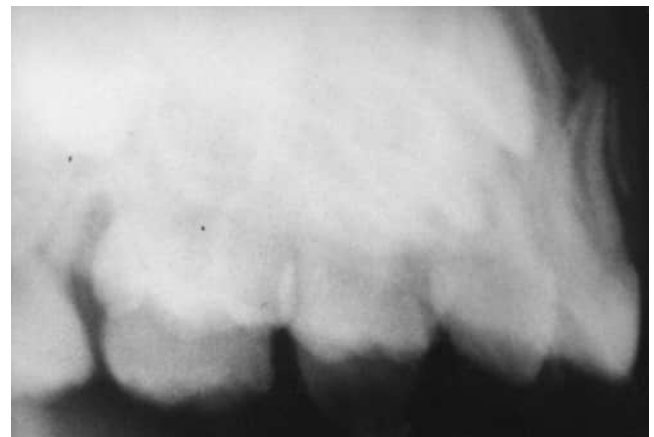The displacement of anterior primary and permanent teeth presents a challenge in diagnosis and treatment for the dentist. Relatively few studies have been reported that can be used as a guide for the treatment of injuries of this type.

#### Primary Teeth

Intrusion by forceful impaction of maxillary anterior primary teeth is a common occurrence in children during the first 3 years of life. Frequent falls and striking of the teeth on hard objects may force the teeth into the alveolar process to the extent that the entire clinical crown becomes buried in the bone and soft tissue. Although there is a difference of opinion



**Fig. 28.23** (A) The degree of intrusion of the primary tooth. Damage to the permanent teeth often results from an injury of this type. (B) Radiograph obtained 8 months after the injury shows that the injured tooth has re-erupted. The pulp has retained its vitality, although there is evidence of partial obliteration of the pulp canal. External root resorption has occurred on the adjacent central incisor.



**Fig. 28.24** Radiograph of intruded primary central incisor with its root apex lying labial to the permanent central incisor.

regarding treatment of injuries of this type, it is generally agreed that immediate attention should be given to soft tissue damage. Intruded primary teeth should be observed; with few exceptions, no attempt should be made to reposition them after the accident. Most injuries of this type occur at an age when it would be difficult to construct a splint or a retaining appliance to stabilize the repositioned teeth.

Normally, the developing permanent incisor tooth buds lie lingual to the roots of the primary central incisors. Therefore, when an intrusive displacement occurs, the primary tooth usually remains labial to the developing permanent tooth (Fig. 28.24). If the intruded primary tooth is found to be in a lingual or encroaching relationship to the developing permanent tooth, it should be removed. Such a relationship may be confirmed from a lateral radiograph of the anterior segment.

The examination should be performed as previously described, and radiographs should be made to detect the evidence of root fracture, fracture of the alveolar bone, and damage to permanent teeth. However, predicting whether the permanent successors will show evidence of interrupted growth and development is impossible unless actual encroachment of their space can be seen radiographically.



Primary anterior teeth intruded because of a blow may often re-erupt within 3 to 4 weeks after the injury. In a study of the results of 248 traumatic episodes to primary incisors, Ravn<sup>39</sup> reported 88 cases of intrusion. Of these 88 teeth, 4 were extracted within 2 weeks because of infection and 4 did not re-erupt and were extracted several months later, but the remaining 80 teeth fully re-erupted within 6 months. Incipient re-eruption was observed 14 days after the injury in a few instances. These teeth may even retain their vitality and later undergo normal resorption and be replaced on schedule by their permanent successors. During the first 6 months after the injury, however, the dentist often observes one or more of the reactions of the pulp and supporting tissues that have been mentioned previously in this chapter, the most common of which is pulpal necrosis. Even after re-eruption, a necrotic pulp can be treated if the tooth is sound in the alveolus and no pathologic root resorption is evident.

Primary teeth that are displaced but not intruded should be repositioned by the dentist or parent as soon as possible after the accident to prevent interference with occlusion. The prognosis for severely loosened primary teeth is poor. Frequently, the teeth remain mobile and undergo rapid root resorption.

Skeller<sup>40</sup> observed 60 children treated for looseness of one or more young teeth. Loosened teeth were divided into three groups: simple looseness, dislocation with impaction, and dislocation with extrusion. He concluded that the immediate and future prognosis for the pulp was more favorable if root formation was still incomplete at the time of the accident. Root resorption, which was observed in all three groups of loosened teeth, was most common in impaction cases. Teeth with complete root formation seemed to undergo resorption more frequently than those with incomplete root formation. However, when resorption did occur, it was more extensive and progressed more rapidly in teeth with incomplete root development.

### Permanent Teeth

Intruded permanent teeth apparently have a poorer prognosis than similarly injured primary teeth. The tendency for the injury to be followed by rapid root resorption, pulpal necrosis, or ankylosis is greater.

For a permanent tooth with a closed root end and intruded less than 3 mm, the treatment is to allow the tooth to erupt without intervention. If no movement is evident after 2–4 weeks, the tooth may be repositioned either orthodontically or surgically before ankylosis can occur. If the tooth is intruded 7 mm or more, the tooth is repositioned surgically and stabilized for 4–8 weeks by means of a flexible splint. In most instances, the pulp will become necrotic with intrusive injuries in teeth with complete root formation. Root canal treatment should be initiated, with calcium hydroxide as a temporary canal-filling material, 2–3 weeks after stabilization.<sup>5</sup>

For an intruded permanent tooth with incomplete root formation, the treatment is to allow it to erupt spontaneously. If no movement is seen within a few weeks, orthodontic repositioning should begin. If the tooth is intruded 7 mm or more, the tooth can be repositioned surgically and stabilized by means of a flexible splint. Endodontic therapy is often required, however, and the tooth should be monitored closely while a decision on endodontic therapy is pending.<sup>5</sup>

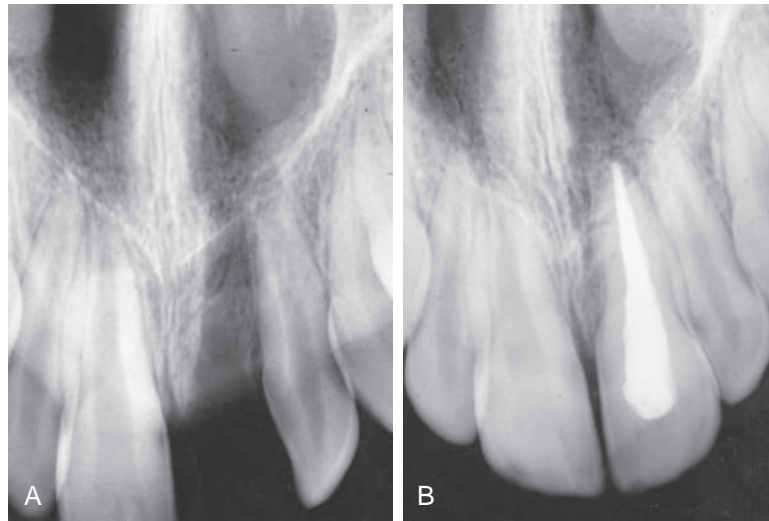
Alkhalifa and Alazemi<sup>41</sup> conducted a literature review to assess the current strength of evidence of factors important in the choice of treatment for intrusive luxation of permanent teeth. Only cohort studies comparing spontaneous eruption and surgical and orthodontic extrusion were assessed. Of the 117 studies identified, only 3 were suitable for inclusion in their analysis; these studies were not meta-analyzed because of methodological and clinical heterogeneity. Given that the infection can be controlled by endodontic therapy, the authors concluded that spontaneous eruption results in the fewest complications in immature teeth regardless of the degree of intrusion. There appear to be no significant differences between surgical and orthodontic extrusion in terms of adverse outcomes. Spontaneous eruption had a low failure rate of 5%–12%. They believe that guidelines for treatment are currently not based on strong evidence.

Wang et al.<sup>42</sup> evaluated 603 teeth with uncomplicated crown fractures followed for 6 months or longer, of which 104 suffered luxation at the same time. The frequency of pulpal necrosis was higher in teeth with complete root development than in teeth with incomplete root development. Teeth with uncomplicated crown fractures with luxation and crown-fractured teeth with intrusion had a higher incidence of pulpal necrosis than any other types of concurrent luxation. The incidence of pulpal necrosis was significantly higher within 3 months than in other time periods evaluated. They concluded that a concurrent luxation injury and complete root development are important risk factors of pulpal necrosis with uncomplicated crown fractures.

Tronstad et al.<sup>43</sup> have reported regarding the management of severely intruded mature maxillary central incisors in an 11-year-old patient in whom spontaneous re-eruption occurred. Rather than repositioning the teeth to gain endodontic access, they performed a palatal gingivectomy and endodontic treatment 10 days after the injury while the teeth remained in their intruded position. At 8 weeks after the injury, the teeth had re-erupted naturally and were judged to be near their original position. Similar management of severely intruded immature central incisors has been reported by Shapira et al.<sup>44</sup> In these cases, the palatal gingivectomies and endodontic treatment were performed 8–10 weeks after injury, when periapical rarefactions and root resorption were noted radiographically. Accelerated spontaneous re-eruption of all treated teeth was noted soon after the gingivectomies and calcium hydroxide endodontic treatments were performed. Complete re-eruption of the teeth and apparent periapical and periodontal healing had occurred 2–3 months after the surgical intervention.

It seems that both treatment approaches for the treatment of severely intruded permanent teeth (early repositioning or waiting for spontaneous re-eruption) have demonstrated reasonably successful results. However, the affected teeth seem to benefit by early calcium hydroxide endodontic therapy with either treatment approach. The decision to reposition mechanically or hope for spontaneous re-eruption of intruded permanent teeth remains a matter of clinical judgment that may be based on several conditions associated with the particular case.

The extrusive luxation of a permanent tooth usually results in pulpal necrosis. The immediate treatment involves the careful repositioning of the tooth and stabilization



**Fig. 28.25** (A) Radiograph of a patient who lost a central incisor as the result of trauma. Replantation was performed. (B) After the replantation procedure, peripheral root resorption is evident along the mesial surface.

following the technique described later in this chapter. If mature repositioned teeth do not respond to pulp vitality tests within 2 to 3 weeks after being repositioned, endodontic treatment should be undertaken before there is evidence of root resorption, which often occurs after severe injuries of this type. The need for endodontic intervention is virtually certain in cases of significant extrusion (more than 2 mm) of mature teeth. With extruded immature teeth, the clinician should monitor the situation frequently and be prepared to intervene with endodontic therapy, as described later, if conditions warrant.<sup>5</sup>

## AVULSION AND REPLANTATION

Replantation is the technique in which a tooth, usually one in the anterior region, is reinserted into the alveolus after its loss or displacement by accidental means. Few reports in the literature have proven this technique to be successful for indefinite periods of time. For example, Barry<sup>45</sup> reports regarding functioning teeth that were replanted 42 years earlier. However, slow or even rapid root resorption often occurs with even the most precise and careful technique. Replantation of permanent teeth continues to be practiced and recommended, however, because prolonged retention is also achieved in many cases, especially when replantation occurs soon after the accident. The replanted tooth serves as a space maintainer and often guides adjacent teeth into their proper position in the arch, a function that is important during the transitional dentition period. The replantation procedure also has psychological value. It gives the unfortunate child and parents hope for success; even though they are told of the possibility of eventual loss of the tooth, the early result often appears favorable and softens the emotional blow of the accident (Figs. 28.25 and 28.26).

The success of the replantation procedure is undoubtedly related to the length of time that elapses between the loss of the tooth and its replacement in the socket. The condition of the tooth and particularly the condition of the periodontal ligament tissue remaining on the root surface are also important factors that influence the success of replantation.

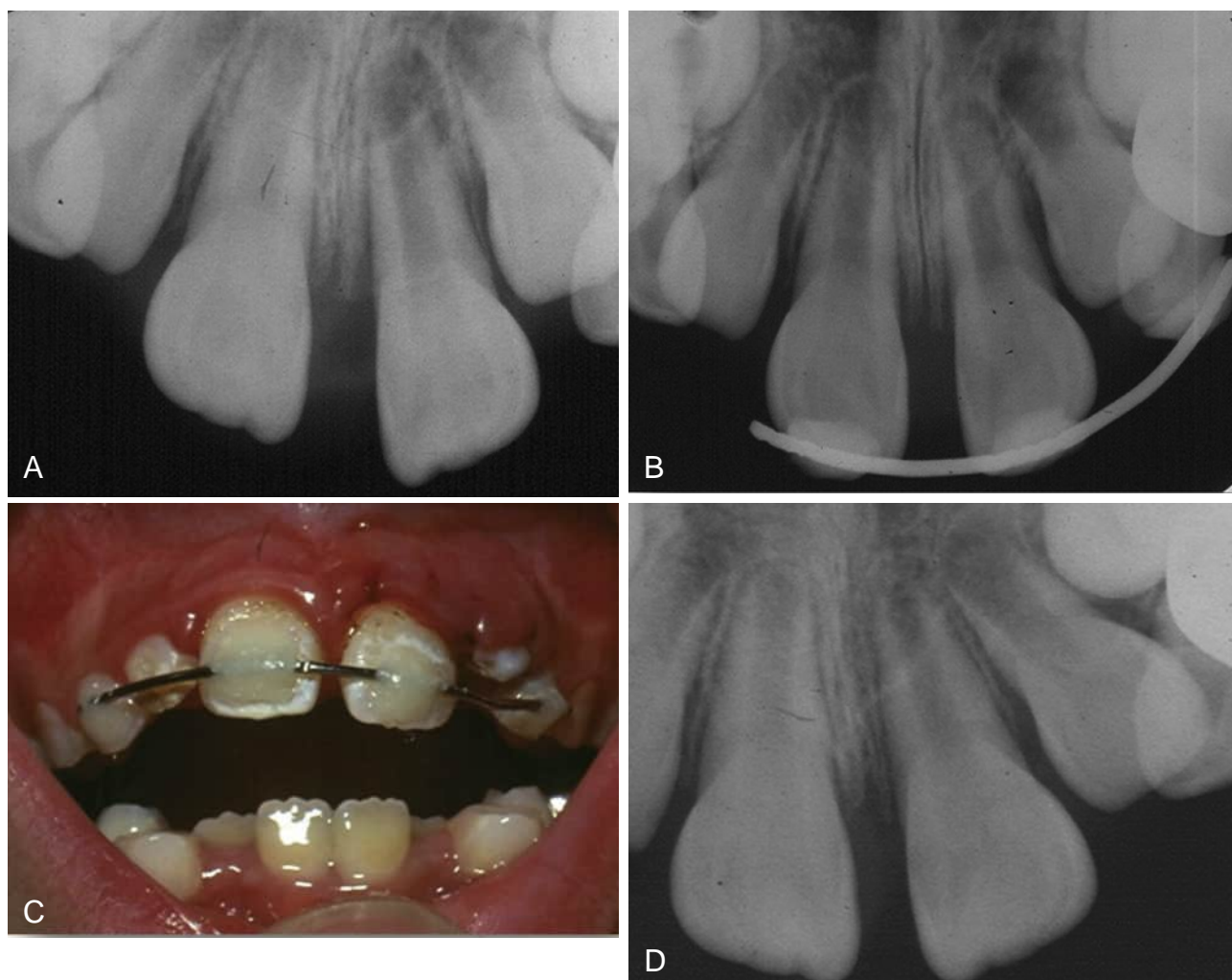
See [Box 29.2](#). There have been reports that immediate replacement of a permanent tooth occasionally results in the maintenance of vitality and indefinite retention. However, replantation should generally be viewed as a temporary measure. Under favorable conditions, many replanted teeth are retained for 5 or 10 years and a few for a lifetime. Others, however, fail soon after replantation.

Camp<sup>46</sup> reports that the tooth most commonly avulsed in both the primary and permanent dentition is a maxillary central incisor. Most often, an avulsion injury involves only a single tooth. Avulsion injuries are three times more frequent in boys than in girls and occur most commonly in children 7 to 9 years of age, when permanent incisors are erupting. Andreasen<sup>47</sup> suggests that the loosely structured periodontal ligament surrounding the erupting teeth favors complete avulsion.

The sooner a tooth can be replanted in its socket after avulsion, the better the prognosis will be for retention without root resorption. Andreasen and Hjørtting-Hansen<sup>48</sup> reported a follow-up study of 110 replanted teeth. Of those replanted within 30 minutes, 90% showed no discernible evidence of resorption 2 or more years later. However, 95% of the teeth replanted more than 2 hours after the injury showed root resorption. If the tooth has been out of the mouth for under 30 minutes, the prognosis is therefore more favorable. In addition, if the apical end of the tooth is incompletely developed at the time of the injury, there is a greater chance of regaining pulp vitality after replantation. If the apex is closed, the dentist should proceed with a pulpectomy a few days after the replantation, even if the extraoral time for the tooth was brief.

If a parent calls to report that a tooth has been avulsed, and it can be determined that the injury is without other oral, neurologic, or higher-priority physical complications, the dentist may instruct the parent to do the following (primary teeth should not be replanted)<sup>5</sup>:

1. Keep the patient calm.
2. Find the tooth and pick it up by the crown (the white part). Avoid touching the root.



**Fig. 28.26** (A) Radiograph of an avulsed maxillary left central incisor, with incomplete root development, that was positioned into the canal immediately upon arrival at the office. The patient was seen within 20 minutes after tooth avulsion. Note the degree to which the tooth was repositioned to approximate its original position. Gentle pressure was exerted to place the apex of the root in the ideal position. (B) Radiograph of the avulsed central incisor showing that it is now at the desired position and has been stabilized with a section of 0.028-inch stainless steel wire. Note that at least one non-traumatized tooth, on either side of the avulsed incisor, was used to anchor the splint. The splint will remain in place for at least 7 to 10 days. (C) Splint in place at the end of the initial appointment. (D) Radiograph at the conclusion of 10 days of splint therapy. The incisor tested vital to both electric and cold pulp-testing.

3. If the tooth is dirty, wash it briefly (10 seconds) under cold running water and reposition it. Try to encourage the patient/parent to replant the tooth. Bite on a handkerchief to hold the tooth in position.
4. If repositioning is not possible, place the tooth in a suitable storage medium (see below).
5. Seek emergency dental treatment immediately, unless the patient was knocked unconscious. If the child was unconscious for a period of time, first seek emergency medical evaluation for a concussion.

If the parent cannot or will not replant it, the tooth must be kept moist during the trip to the dental office. Allowing the avulsed tooth to dehydrate before replantation is damaging to a favorable prognosis. Hanks' buffered saline, isotonic saline, and pasteurized bovine milk may be the most favorable known storage media. Although tap water has been a commonly recommended storage solution (and its use would be preferable to dehydration of the tooth), it is

hypotonic, and its use leads to rapid cell lysis and increased inflammation on replantation.

The patient should receive immediate attention after arriving at the dental office. If the tooth has not already been replanted, the dentist should make every effort to minimize the additional time that the tooth is out of the socket. The patient's general status should be quickly assessed to confirm that there are no higher-priority injuries.

If an evaluation of the socket area shows no evidence of alveolar fracture or severe soft tissue injury, the tooth is intact, and only a few minutes have elapsed since the injury, the dentist should replant the tooth immediately. Under the conditions just described, every effort should be directed toward preserving a viable periodontal ligament. Trope<sup>49</sup> correctly asserts that treatment should be directed at avoiding or minimizing the resultant inflammation that occurs as a direct result of the two main consequences of tooth avulsion: attachment damage and pulpal infection. If the tooth was cleanly avulsed, it can probably be replanted



## Box 28.2 Categories for treatment of avulsed teeth

1. Closed apex, tooth replanted prior to the patient's arrival at the dental office

### Treatment

- Leave the tooth in place.
- Clean the area with water spray, saline, or chlorhexidine.
- Suture gingival lacerations if present.
- Verify normal position of the replanted tooth both clinically and radiographically.
- Apply a flexible splint for up to 2 weeks.
- Administer systemic antibiotics. Tetracycline is the first choice (doxycycline twice a day for 7 days at appropriate dose for patient age and weight). The risk of discoloration of permanent teeth must be considered before systemic administration of tetracycline in young patients. (In many countries, tetracycline is not recommended for patients under 12 years of age.) In young patients, phenoxymethylpenicillin (Pen V) or amoxicillin, at an appropriate dose for age and weight, is an alternative to tetracycline.
- If the avulsed tooth has been in contact with soil and if tetanus coverage is uncertain, refer to physician for a tetanus booster.
- Initiate root canal treatment 7–10 days after replantation and before splint removal.

### Patient instructions

- Avoid participation in contact sports.
- Eat only soft food for up to 2 weeks.
- Brush teeth with a soft toothbrush after each meal.
- Use a chlorhexidine (0.1%) mouthrinse twice a day for 1 week.

### Follow-up

- Splint removal and clinical and radiographic control after 2 weeks
- Root canal treatment 7–10 days after replantation
- Clinical and radiographic control after 4 weeks, 3 months, 6 months, 1 year, and then yearly thereafter

2. Closed apex, extraoral dry time less than 60 minutes: The tooth has been kept in physiologic storage media or osmolality-balanced media (milk, saline, saliva, or Hanks' Balanced Salt Solution) and/or stored dry for less than 60 minutes.

### Treatment

- Clean the area with water spray, saline, or chlorhexidine.
- Reimplant the tooth in the socket.
- Suture gingival lacerations if present.
- Verify normal position of the replanted tooth both clinically and radiographically.
- Apply a flexible splint for up to 2 weeks.
- Administer systemic antibiotics (see previous comments).
- If the avulsed tooth has been in contact with soil and if tetanus coverage is uncertain, refer to physician for a tetanus booster.
- Initiate root canal treatment 7–10 days after replantation and before splint removal.

### Patient instructions (see previous comments)

### Follow-up (see previous comments)

3. Closed apex, extraoral dry time greater than 60 minutes, suggesting nonviable cells: Delayed replantation has a poor long-term prognosis. The periodontal ligament will be necrotic and cannot be expected to heal. The goal in delayed replantation is, in addition to restoring the tooth for aesthetic, functional, and psychological reasons, to maintain alveolar bone contour. However, the expected eventual outcome is ankylosis and resorption of the root, and the tooth will be lost eventually.

### Treatment

- Clean the area with water spray, saline, or chlorhexidine.
- Reimplant the tooth in the socket.
- Suture gingival lacerations if present.
- Verify normal position of the replanted tooth both clinically and radiographically.
- Apply a flexible splint for up to 2 weeks.
- Administer systemic antibiotics (see above).

- If the avulsed tooth has been in contact with soil and if tetanus coverage is uncertain, refer to physician for a tetanus booster.
- Initiate root canal treatment 7–10 days after replantation and before splint removal.
- To slow osseous replacement of the tooth, treatment of the root surface with fluoride prior to replantation has been suggested (2% sodium fluoride solution for 20 minutes).

### Patient instructions (see previous comments)

### Follow-up (see previous comments)

- Ankylosis is unavoidable after delayed replantation and must be taken into consideration. In children and adolescents, ankylosis is frequently associated with infraposition. Careful follow-up is required and good communication is necessary to assure the patient and guardian of this likely outcome. Decoronation may be necessary when infraposition (>1 mm) is seen. For more detailed information on this procedure, the reader is referred to textbooks.

1. Open apex, tooth replanted prior to the patient's arrival at the dental office or clinic

### Treatment

- Leave the tooth in place.
- Clean the area with water spray, saline, or chlorhexidine.
- Suture gingival laceration if present.
- Verify normal position of the replanted tooth both clinically and radiographically.
- Apply a flexible splint for up to 1–2 weeks.
- Administer systemic antibiotics (see previous comments).
- If the avulsed tooth has been in contact with soil and if tetanus coverage is uncertain, refer to physician for a tetanus booster.
- The goal for replanting still-developing (immature) teeth in children is to allow for possible revascularization of the tooth pulp. If that does not occur, root canal treatment is recommended.

### Patient instructions (see previous comments)

### Follow-up (see previous comments)

2. Open apex, extraoral dry time less than 60 minutes: The tooth has been kept in physiologic storage media or osmolality-balanced media (milk, saline, saliva, or Hanks' Balanced Salt Solution) and/or stored dry for less than 60 minutes:

### Treatment

- Clean the root surface and apical foramen with a stream of saline.
- Topical application of antibiotics has been shown to enhance chances for revascularization of the pulp and can be considered if available (minocycline or doxycycline 1 mg per 20 mL saline for 5-minute soak).
- Administer local anesthesia.
- Examine the alveolar socket. If there is a fracture of the socket wall, reposition it with a suitable instrument.
- Irrigate the socket with saline.
- Replant the tooth slowly with slight digital pressure.
- Suture gingival lacerations, especially in the cervical area.
- Verify normal position of the replanted tooth clinically and radiographically.
- Apply a flexible splint for up to 2 weeks.
- Administer systemic antibiotics (see previous comments).
- If the avulsed tooth has been in contact with soil and if tetanus coverage is uncertain, refer to physician for a tetanus booster.

### Patient instructions (see previous comments)

### Follow-up (see previous comments)

- The goal for replanting still-developing (immature) teeth in children is to allow for possible revascularization of the pulp space. The risk of infection-related root resorption should be weighed against the chances of revascularization. Such resorption is very rapid in children. If revascularization does not occur, root canal treatment may be recommended.

### Box 28.2 Categories for treatment of avulsed teeth—cont'd

3. Open apex, extraoral dry time greater than 60 minutes, suggesting nonviable cells: Delayed replantation has a poor long-term prognosis. The periodontal ligament will be necrotic and is not expected to heal. The goal in delayed replantation is to restore the tooth to the dentition for aesthetic, functional, and psychological reasons and to maintain alveolar contour. The eventual outcome will be ankylosis and resorption of the root.

#### Treatment

- Remove attached nonviable soft tissue with gauze.
- Root canal treatment can be carried out prior to replantation or later.
- Administer local anesthesia.
- Irrigate the socket with saline.
- Examine the alveolar socket. If there is a fracture of the socket wall, reposition it with a suitable instrument.

- Replant the tooth slowly with slight digital pressure.
- Suture gingival lacerations if present.
- Verify normal position of the replanted tooth clinically and radiographically.
- Stabilize the tooth for 4 weeks using a flexible splint.
- Administer systemic antibiotics (see previous comments).
- If the avulsed tooth has been in contact with soil or if tetanus coverage is uncertain, refer to physician for evaluation of the need for a tetanus booster.

To slow osseous replacement of the tooth, treatment of the root surface with fluoride prior to replantation has been suggested (2% sodium fluoride solution for 20 minutes).

**Patient instructions** (see previous comments)

**Follow-up** (see previous comments)

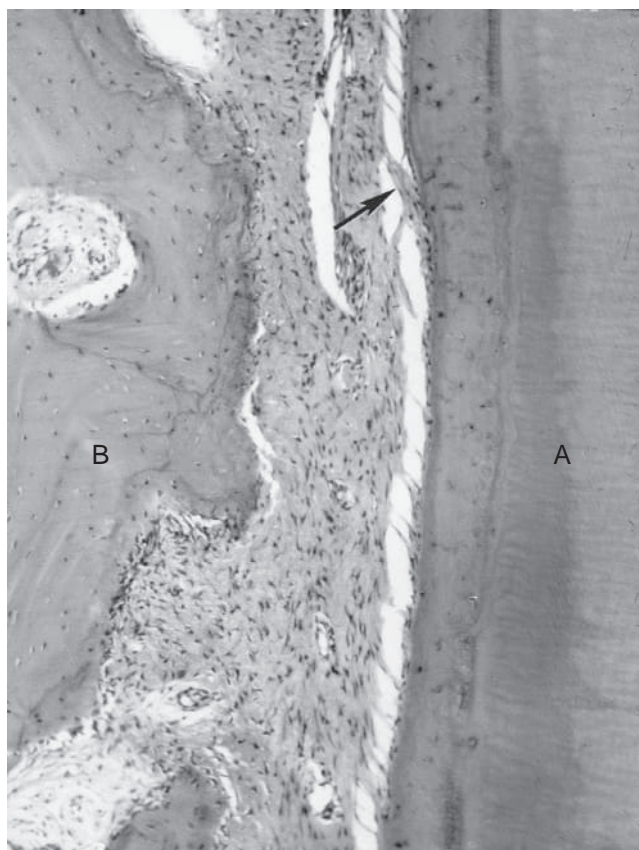Ankylosis after delayed replantation (see previous comments)

Adapted from *The Dental Trauma Guide: Avulsion-First Aid for Avulsed Teeth*, International Association of Dental Traumatology, <http://www.dentaltrauma.org>

without local anesthetic, and obtaining the initial radiograph can also be delayed until the tooth is replaced in the socket and held with finger pressure. The minutes saved may contribute to a more successful replantation. If a clot is present in the socket, it will be displaced as the tooth is repositioned; the socket walls should not be scraped with an instrument. If the tooth does not slip back into position with relative ease when finger pressure is used, local anesthesia and a radiographic evaluation are indicated. Local anesthetic should also be administered when fractured and displaced alveolar bone must be repositioned before the tooth is replanted. Soft tissue suturing may be delayed until the tooth has been replaced in the socket; however, the suturing should be performed to control hemorrhage before the tooth is stabilized with a bonded splint. Splinting techniques are discussed in the next section of this chapter.

Sherman<sup>50</sup> studied the mechanism by which the replanted tooth becomes secured in the alveolus. Intentional replantation was performed on 25 incisors in dogs and monkeys. The root canals were hermetically sealed with gutta-percha, and the teeth were splinted for 1 month. Subsequent microscopic examination under fluorescent and incandescent light revealed deposition of secondary cementum and new alveolar bone, which entrapped the periodontal fibers (Fig. 28.27).

The preservation of an intact and viable periodontal ligament is the most important factor in achieving healing without root resorption. Delicate handling of the tooth, storage in an appropriate moist environment, quick replantation, and appropriate stabilization are all important in preserving the periodontal ligament. Undesirable periodontal ligament reactions may result in replacement resorption (ankylosis) or inflammatory resorption of the root. Either reaction may cause eventual loss of the tooth unless the resorption can be controlled. Use of an enamel matrix derivative (Emdogain; Biora AB, Chicago, IL, and Malmö, Sweden) has been shown to increase the incidence of healed periodontal ligament when this gel is applied to the root surface of the avulsed tooth and/or inserted directly into the alveolar socket before implantation. It



**Fig. 28.27** Microscopic section of a tooth replanted with the periodontal ligament intact. The reattachment of the periodontal fibers is illustrated by their crossing the tear in the periodontal ligament. (A) Tooth. (B) Alveolar bone. (Courtesy Dr. Philip Sherman Jr.)

appears to aid in preventing or retarding resorption and ankylosis.

#### Stabilization of Replanted Teeth

After replantation of a tooth that has been avulsed, a splint is required to stabilize it during at least the first week of

healing. Camp<sup>46</sup> has stated that an acceptable splint should meet the following criteria:

1. It should be easy to fabricate directly in the mouth without lengthy laboratory procedures.
2. It should be able to be placed passively without causing forces on the teeth.
3. It should not touch the gingival tissues, causing gingival irritation.
4. It should not interfere with normal occlusion.
5. It should be easily cleaned and allow for proper oral hygiene.
6. It should not traumatize the teeth or gingiva during application.
7. It should allow an approach for endodontic therapy.
8. It should be easy to remove.

The splint should also allow mobility of the replanted tooth that is comparable with the normal mobility of a tooth. Rigid stabilization seems to stimulate replacement resorption of the root. Hurst<sup>51</sup> demonstrated that rigid stabilization of a replanted tooth is detrimental to proper healing of the periodontal ligament.

The bonded resin and wire splint satisfies all the criteria just described. It can be used in most situations requiring the stabilization of one or more teeth if sufficient sound teeth remain for anchorage. Rectangular or round orthodontic wire is bent to approximate the arch configuration along the midportion of the labial surfaces of the teeth to be incorporated into the splint. At least one sound tooth on each side of the tooth to be stabilized is included. The size of the wire is not too critical, but rectangular wire should be at least 0.016 × 0.022 inch and round wire at least 0.018 inch. If three or four teeth must be stabilized, a stiffer wire (e.g., 0.028-inch round wire) is required. If round wire is used, a right-angle bend should be made near each end of the wire to prevent rotation of the wire in the resin. A 20- to 30-pound-test monofilament nylon line is an acceptable substitute for wire in the splint.

If the labial enamel surfaces to be etched are not plaque-free, they should be cleaned with a pumice slurry, rinsed, thoroughly dried, and isolated with cotton rolls. The enamel surfaces are etched with a phosphoric acid etchant; the gel form is convenient. The enamel surfaces are thoroughly washed and dried again. The wire is then attached to the abutment teeth by the placement of increments of the resin material over the wire and onto the etched enamel. The resin should completely surround a segment of the wire, but it should not encroach on the proximal contacts or embrasures. The replanted tooth is then held in position while resin is used to bond it to the wire. The resin may be lightly finished if necessary after polymerization. The splint is easily removed (usually 7–10 days later) by cutting through the resin with a bur to uncover the wire. The remaining resin may then be removed with conventional finishing instruments. If the splint is used to stabilize lower teeth, it may be necessary to affix the wire to the lingual surfaces if placing it on the labial surfaces will interfere with natural occlusion. Because lingual surfaces are more likely to be contaminated with saliva during the procedure, however, labial placement is preferred whenever possible.

Direct-bonded orthodontic brackets may also be placed on the teeth, and a light labial archwire bent to conform

accurately to the natural curvature of the arch is then ligated to the brackets. The brackets are properly aligned on the archwire and bonded to the abutment teeth first. The avulsed tooth is then ideally positioned, and additional bonding material is placed, if necessary, to fill any remaining small space between the tooth and the bracket before being bonded to the splint. If performed properly, this technique results in an excellent splint (Fig. 28.28). However, it requires much more accurate and precise wire bending than the bonded resin and wire technique (without brackets) to achieve a passive appliance.

If the patient has mental disabilities or immature behavior and does not tolerate foreign objects in the mouth well, or if there are insufficient abutment teeth available for the bonded resin and wire splint, the suture and bonded resin splint advocated by Camp<sup>46</sup> may be an acceptable alternative (Fig. 28.29). The titanium trauma splint was developed by von Arx et al.<sup>52</sup> to ease the application and removal of the splint and to increase comfort for the patient.

In general, stabilization for replanted teeth without other complications is required for 7–14 days. The periodontal ligament fibers should have healed sufficiently after the first week to allow the splint to be removed. However, the patient should be advised not to bite directly on the replanted tooth for 3–4 weeks after the injury and then gradually to return to normal use of the tooth. During this time, food may be cut into bite-size pieces and chewed carefully with unaffected teeth. The patient should maintain good oral hygiene by brushing and flossing normally and using chlorhexidine mouthrinses.

We recommend that systemic antibiotic therapy begin immediately and continue for at least a week following replantation. If the apex is closed, extending the antibiotic therapy until the pulp is extirpated seems to be a good way to determine the duration of antibiotic coverage. Research by Sae-Lim et al.<sup>53</sup> demonstrated that antibiotic therapy is effective in preventing the development of external inflammatory root resorption of replanted teeth in which the pulps were not extirpated. This finding suggests that antibiotic therapy may also be helpful in those cases in which the pulps of immature replanted teeth are allowed to remain while revitalization remains a possibility. Additional studies in this area are indicated.

Krasner and Rankow<sup>54</sup> have published detailed recommendations for replanting a tooth based on its status as judged by the clinician's determination of the physiologic

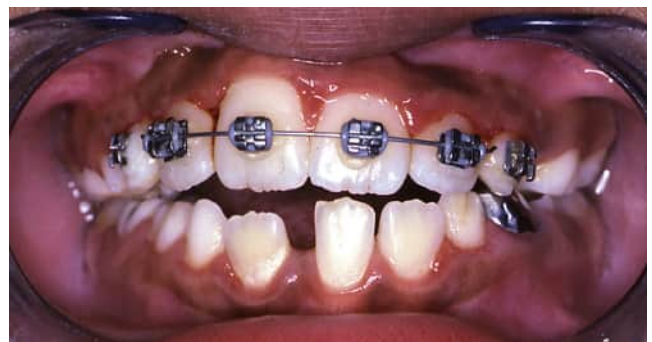
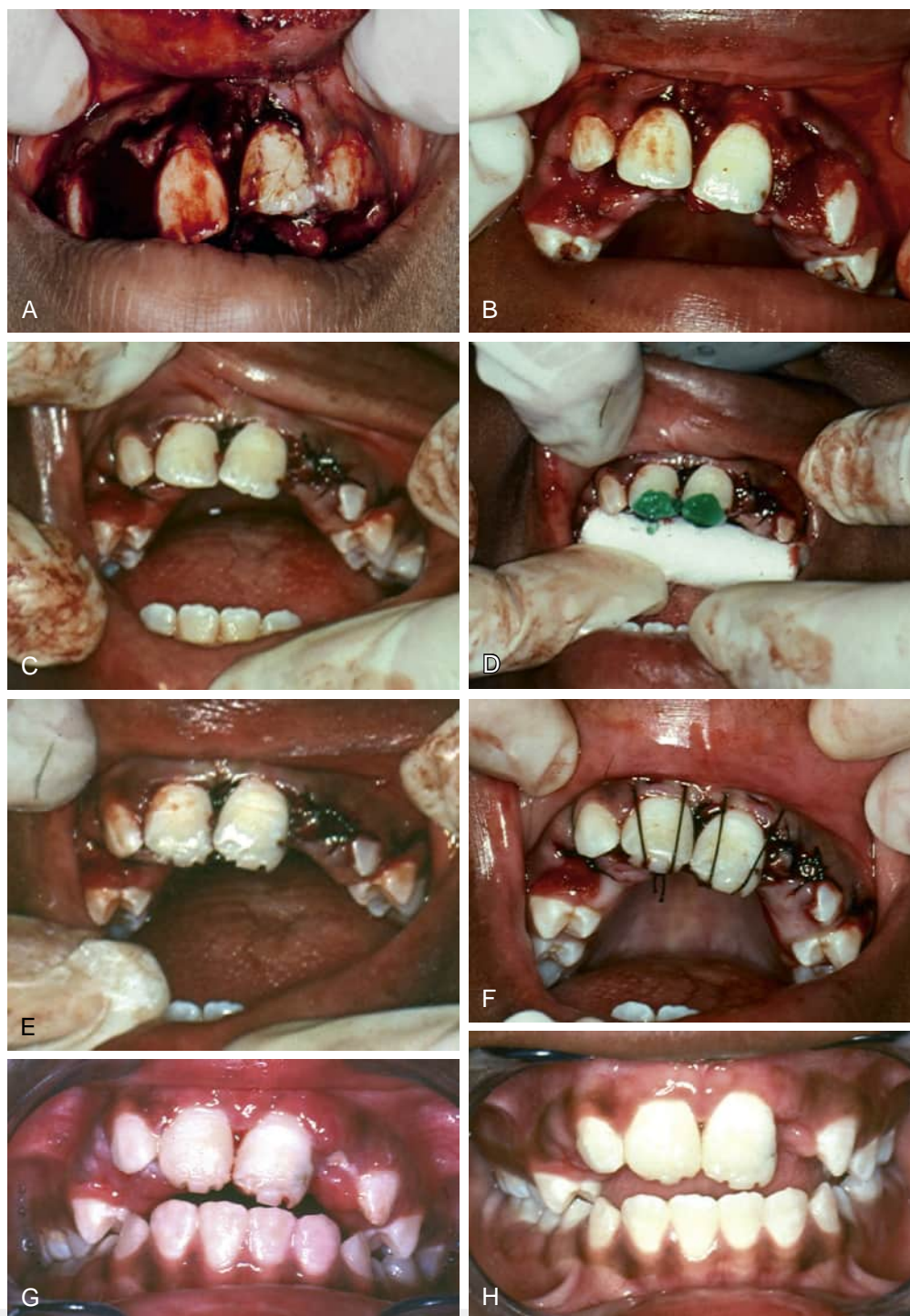
Fig. 28.28 Bonded brackets and archwire splint.





**Fig. 28.29** Suture and bonded resin splint. (A) The maxillary central incisors as seen at the initial presentation at the office. The maxillary left central incisor was avulsed and placed in its socket by the parent (approximately 30 minutes after being avulsed) after being instructed to do so by the front desk staff on the way to the office. (B) and (C) The area has been initially cleansed, and suturing has been accomplished to reapproximate the lacerated gingival tissue. There are not sufficient teeth to provide adequate anchorage adjacent to the replanted maxillary central incisors. (D) The incisal edges of the maxillary central incisors are etched, per manufacturer's instructions, before resin placement. (E) Retention grooves have been created in the resin on the incisal edges of the maxillary central incisors. (F) A suture is placed over each tooth. Starting at the labial tissue, each suture crosses the incisal edge, enters and exits the lingual tissue, recrosses the incisal edge, and reenters the labial tissue. The ends are then tied. Care is taken to ensure that no contact with the opposing occlusion is present. (G) and (H) Clinical presentation at 7 (sutures removed) and 21 days after initial replantation. Both teeth are stable in their respective sockets, with minimal mobility, and gingival tissue health is improved. Pulp testing demonstrated necrosis in both maxillary central incisors, and root canal therapy was scheduled.

condition of the root periodontal ligament cells, the development of the root apex, and the length of extraoral time. Their recommendations recognize 10 different categories of avulsed teeth and detail a specific treatment regimen for each category. A modified version of Guidelines for the

Management of Avulsed Permanent Teeth from the International Association of Dental Traumatology is shown in [Box 28.2](#)<sup>55</sup> Of course, the dentist should confirm at the time of replantation that the patient is adequately immunized against tetanus.

### Endodontic Management of Replanted Teeth

All replanted permanent teeth with complete apical root development should undergo a pulpectomy soon after replantation regardless of the length of time the tooth was out of the mouth. Even though a few reports of revitalization exist, the chances for revitalization are remote at best. Moreover, adverse reactions are virtually certain if degenerating pulp tissue is allowed to remain in the canals for more than a few days. The risk-benefit ratio for the patient favors pulpal extirpation.

Because replantation should be done as soon as possible after the injury, the dentist should not take time to extirpate the pulp before replantation. The pulp should be extirpated before the splint is removed, however, and preferably within 1 week after the injury. A sterile, dry cotton pellet or one dampened with CMCP and blotted on sterile gauze may be sealed in the pulp chamber after debridement and irrigation. The canal should be filled approximately 2 weeks after the injury. When the canal is filled, calcium hydroxide paste is the material of choice. However, Trope<sup>49</sup> suggests that the pulp contents be removed at the emergency visit and a tetracycline-corticosteroid combination (Ledermix; Sigma Pharmaceuticals Pty Ltd., Croydon, Victoria, Australia) be placed in the root canal. He believes that this combination decreases the inflammatory response after replantation to allow for more favorable healing than in those teeth that do not receive the medicament.

Root canal treatment should be initiated 7–10 days after replantation. Early extirpation of the pulp may help to control the early onset of inflammatory root resorption.<sup>55</sup> Filling the root canal with calcium hydroxide also controls and may even arrest external inflammatory root resorption. If calcium hydroxide is placed in the canal too soon (before adequate healing of the periodontal ligament), it may stimulate replacement root resorption. Andreasen suggested that 2 weeks after replantation is the ideal time to fill the canal with calcium hydroxide.<sup>55</sup> The use of calcium hydroxide as a root-canal-filling material was described previously in the discussion of apexification.

If the avulsed permanent tooth has immature root formation with an open apex, the chances of pulpal revitalization after replantation improve considerably, especially if replantation occurs within 30 minutes after avulsion. If the avulsed tooth has been cared for properly, there is a small chance for revitalization even if the tooth is replanted within 1 hour after the injury. However, many teeth do not revitalize. Those that do respond favorably may still require root canal treatment several months later. During the time beyond 1 week that the pulp tissue is allowed to remain, evaluation of the tooth is recommended at weekly intervals until favorable signs of healing without pulpal pathosis are conclusive (vitality tests are unreliable) or until a decision is made to extirpate the pulp. The pulp should be extirpated when the first signs of degeneration appear.

Rubber dam isolation is always desirable when pulp therapy is performed. It can usually be used even during the pulp extirpation procedure, while several teeth are splinted together. Instead of separate holes in the rubber dam for each tooth, a slit is made so that the rubber can be placed over all teeth in the splinted segment. This does not afford

ideal isolation, but it is generally better than the use of cotton rolls. In addition, the rubber dam helps prevent the swallowing or aspiration of foreign objects during treatment. If small endodontic instruments are used without rubber dam protection, they should be secured with a length of dental floss to facilitate retrieval in the unlikely event that they are dropped in the patient's mouth.

The calcium hydroxide material used to fill the root canal should be replaced every 3–6 months until a decision is made to fill the canal with gutta-percha. The optimum duration of the calcium hydroxide treatment is unknown, but generally calcium hydroxide should be kept in the canal for at least 6 months or until root end closure (apical plug) occurs beyond 1 year. In cases in which an adjacent tooth is still unerupted, calcium hydroxide treatment is recommended until eruption of the adjacent tooth.<sup>56</sup> It is believed that eruption may stimulate or accelerate the resorptive process in a nearby replanted root.

### MANAGEMENT OF ROOT FRACTURES

Root fracture of primary teeth is relatively uncommon because the more pliable alveolar bone allows for displacement of the tooth. When root fracture does occur, it should be treated in the same manner as recommended for permanent teeth; however, the prognosis is less favorable. The pulp in a permanent tooth with a fractured root has a better chance to recover.

Root fractures that occur in the apical half of the tooth are more likely to undergo repair (Fig. 28.30). Fractures in the apical third are often repaired without treatment. In fact, many apparently are undetected until evidence of a calcified repair is seen radiographically sometime after the injury.

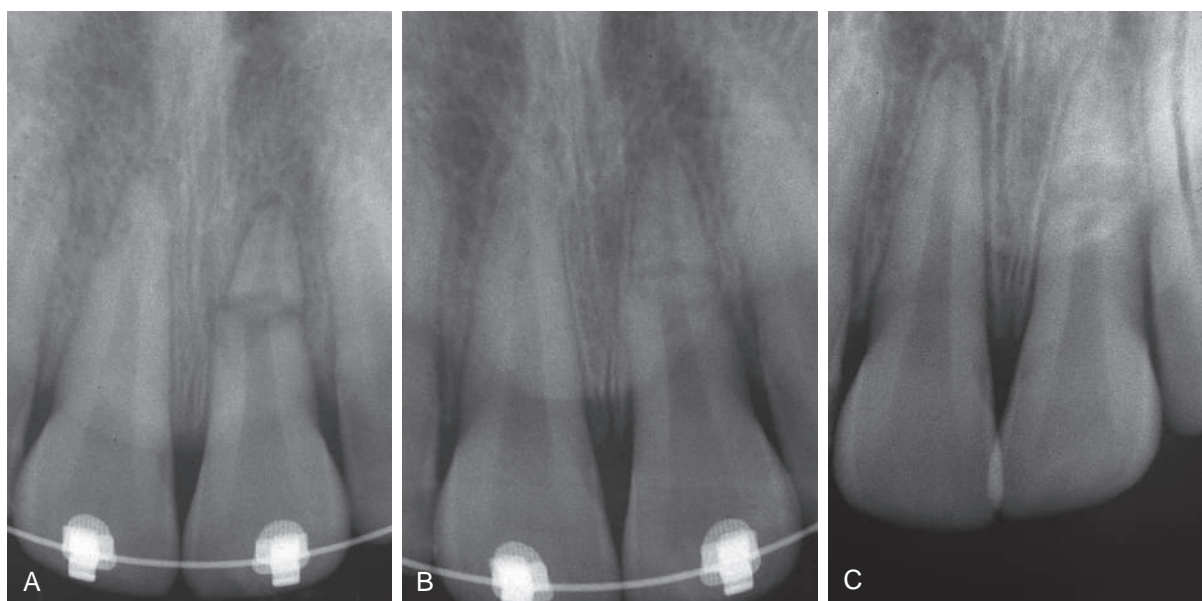
Andreasen<sup>57</sup> has described four tissue reactions after root fracture: (1) healing with calcified tissue, which is characterized by a uniting callus of hard tissue that may consist of dentin, osteodentin, or cementum; (2) healing with interposition of connective tissue, in which the fractured root surfaces are covered by cementum with connective tissue fibers joining the two fragments; (3) healing with interposition of bone and connective tissue, in which a bony bridge and connective tissue are positioned between the fragments; and (4) interposition of granulation tissue.

The last is the least favorable form of attempted repair, and the fracture will not heal spontaneously. The teeth usually present unfavorable symptoms that may be accompanied by fistulas resulting from necrosis of the coronal portion and sometimes the apical portion of the pulp. These teeth require follow-up endodontic treatment or extraction.

Gross separation of the root fragments invariably causes inflammation in the area and subsequent resorption of the approximating fractured surfaces. For repair to take place, the fragments must be maintained in apposition. Therefore splinting is usually necessary, particularly if the coronal fragment is mobile.

Although a relatively long stabilization period (3 months) has been previously recommended for teeth with fractured roots, Cvek et al.<sup>58,59</sup> have cast doubts on the efficacy of long-term splinting and the types of splints used for root fracture healing. Previously, a longer stabilization period seemed necessary to encourage a more favorable type of healing of calcified





**Fig. 28.30** (A) Root fracture is evident in the apical one-third of the maxillary left central incisor. A splint was placed the day of the fracture. The patient reported that both teeth received trauma (via a baseball to the area), although only the root of the maxillary left central incisor was fractured. (B) One month after initial splint placement. Both central incisors responded favorably to pulp testing, and the splint was removed. Periodic evaluation and pulp testing were maintained. (C) More than 2 years had elapsed when this radiograph revealed a normal periapical appearance to the maxillary left central incisor with the fractured root. Pulp testing for the incisor was normal. The patient complained of pain associated with the maxillary right central incisor (see developing periapical lesion) and was referred for endodontic evaluation.

tissue; however, their study showed no significant difference in the frequency of healing when short periods (<60 days) and long periods (60–90 days) of splinting were compared. They found that hard tissue healing also occurred in teeth that were not even splinted. A comparison between nonsplinted and splinted teeth showed no difference in frequency of healing. They suggest that optimal positioning of dislocated fragments significantly increases the frequency of healing, particularly in mature teeth. Their study showed that, in immature teeth, healing occurred even after suboptimal repositioning of dislocated coronal fragments and persistent diastases between the fragments after splinting. They concluded that teeth with no or slight loosening of the fragment may not require splinting.

There is a general agreement that splints for root fractures should be more rigid than the splints used for stabilization after other types of displacement injuries. Application of a more rigid splint is also believed to enhance the opportunity for calcified tissue repair. Therefore, the use of heavier wires is recommended (0.032- to 0.036-inch) when one is stabilizing teeth with fractured roots.

The occlusion should be adjusted so that the injured tooth is not further traumatized during normal masticatory function. Follow-up radiographs should be obtained and pulp tests performed at frequent intervals during the first 6 months after the injury.

#### OTHER DISPLACEMENT INJURIES OF TEETH REQUIRING STABILIZATION

Teeth subjected to less severe luxation injuries may also benefit from stabilization with a bonded resin and wire splint during the recovery period. The severity of the injury will help determine the length of time the splint should remain in place. Splinting times may vary from 1 to 2 weeks, for teeth that have been discernibly loosened (subluxation), to

4 to 6 weeks, for teeth that have been laterally displaced, fracturing the alveolar process. As with all tooth injuries, frequent periodic evaluation is required for at least the first 6 months to afford the dentist the opportunity for early intervention if adverse sequelae develop; subsequently, evaluation at regular recall appointments should continue.

Nearly all significantly displaced teeth with closed apices and many with open apices will require follow-up endodontic therapy. As with many of the other injuries already discussed, calcium hydroxide paste is the currently recommended material for initial canal filling (2–4 weeks), and the canal should be recleaned and refilled with calcium hydroxide periodically if signs or symptoms warrant re-treatment. If indicated, additional root end closure can often be obtained with an apical barrier such as MTA.<sup>60</sup> Gutta-percha can be used to fill the remaining canal space. Placement of a permanent gutta-percha filling should be delayed for at least 1 year (arbitrarily determined), and the calcium hydroxide should be replaced at least once (again, arbitrarily determined) during this time. If the injured tooth had an open apex when endodontic therapy was initiated, the calcium hydroxide filling material should be used until the apexification process is complete or at least 1 year has elapsed, whichever is longer.

### Management of Oral Burns

Because of secondary wound healing and scar contracture, burns involving the perioral and intraoral tissues can cause various degrees of microstomia. A common cause of oral burns is electrical trauma. The most frequently encountered electrical injury to children is the electrical burns of the mouth. These burns occur most often in children between 6 months and 3 years of age and are equally common among boys and girls.



Oral electrical burns occur when: (1) the child places the female end of a “live” extension cord into the mouth, (2) the child places the female end of a “live” appliance cord (e.g., that for a hot plate, shaver, or portable radio) into the mouth, or (3) the child sucks or chews on exposed or poorly insulated electrical wires.

How does the burn occur? One plausible theory is that an electric arc is produced between a source of the current, such as the female end of an extension cord, and oral tissues. The electrolyte-rich saliva provides a short circuit between the cord terminals and the mouth, which results in the arc phenomenon. This type of burn characteristically involves intense heat that causes coagulation tissue necrosis.

### NATURE OF THE INJURY

The clinical appearance of electrical burns is variable and depends on several factors: (1) the degree and duration of contact, (2) the source and magnitude of electric current, (3) the state of grounding, and (4) the relative degree of resistance at the point of contact. The wound may be superficial, involving only the vermillion border of one or both lips, or it may be a very destructive, full-thickness, third-degree burn. The more serious burns generally involve portions of the upper and lower lips and the commissure. Damage with more serious burns may extend intraorally to the tongue, labial vestibule, floor of the mouth, or buccal mucosa. There have also been reports of damage to the hard tissue, such as the mandible and the primary and permanent teeth.

With third-degree burns, subcutaneous tissues may be damaged. The tissue destruction may be much more extensive than is initially evident. Because nerves are frequently damaged, the patient will probably have paresthesia or anesthesia. Therefore, pain is generally not a significant problem. Hemorrhage is usually inconsequential because blood vessels are cauterized when the injury is sustained. However, spontaneous arterial bleeding may occur anytime during the first 3 weeks of healing. The hemorrhage may be caused by the rupture of blood vessel walls weakened by the passage of current. Bleeding can also occur with sloughing of necrotic tissue that overlies regenerating granulation tissue.

The clinical appearance of an electrical burn involving the lips and commissures is characteristic of a wound caused by intense, localized heat, perhaps as high as 3000°C. Necrosis is evident, with heat-induced coagulation of protein, liquefaction of fats, and vaporization of tissue fluids.

During the first few days after the accident, the center of the lesion is generally composed of grayish or yellowish tissue that may be depressed relative to a slightly elevated, narrow, erythematous margin of tissue that surrounds it (Fig. 28.31).

Within a few hours after the injury, there may be a great increase in edema. The margins of the wound may become ill defined and the lips protuberant. The patient may drool uncontrollably because of loss of sensation. In 7–10 days, the edema begins to subside. The delineation between the central nonviable tissue and the surrounding viable tissue becomes more apparent. The necrotic tissue, known as *eschar*, becomes charred or crusty in appearance and begins to separate from the surrounding viable tissue (Fig. 28.32). The eschar sloughs off 1–3 weeks after the burn incident. Healing occurs by secondary intention as granulation tissue proliferates and matures.

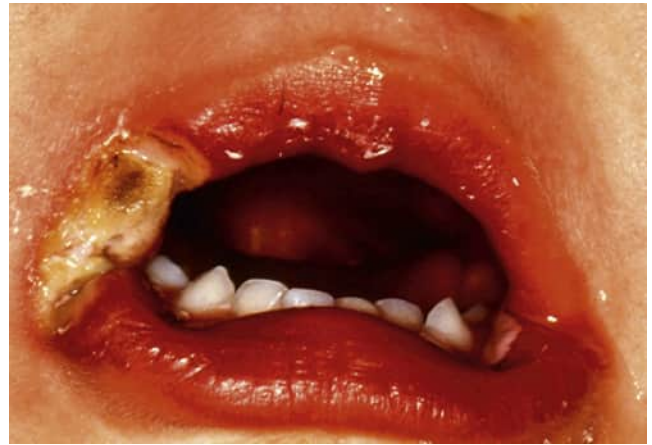

Fig. 28.31 Appearance of injury to the upper lip and commissure 5 days after electrical burn. (Courtesy Dr. Theodore R. Lynch.)

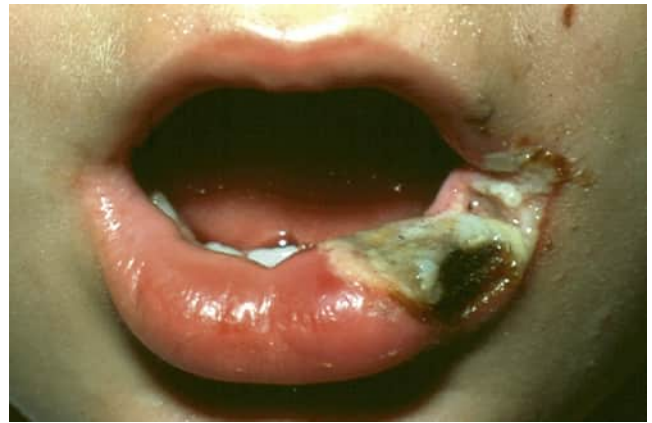

Fig. 28.32 Appearance of injury to the lower lip and commissure 10 days after electrical burn. The dark lesion on the lower lip is an eschar. (Courtesy Dr. Theodore R. Lynch.)

About 2 or 3 months after the accident, the wound becomes indurated because of fibrous tissue formation. For an additional 6 months, the immature fibrotic scar tissue may bind the lips, alveolar ridges, and other involved structures. If such tissue is not treated, its contraction results in unaesthetic and functionally debilitating microstomia. The scar tissue softens as it matures, and by 9 months to 1 year after the injury, the potential for tissue contraction is greatly decreased. The duration of the healing process and the selected course of treatment depend on the extent and severity of tissue destruction. Because of the variable nature of burn injuries, surgery or appliance therapy may be used, or no treatment may be needed.

### TREATMENT

Assessing the general physical status of a patient who has sustained an electrical burn to the mouth is the first priority. Subsequently, the extent of the burn is carefully evaluated and local measures are initiated, such as control of minor hemorrhage or conservative debridement of nonviable tissue.

The immunization status of the patient must be ascertained, and tetanus toxoid or depot triple antigen (diphtheria-pertussis-tetanus vaccine) administered when appropriate. Many physicians prescribe a broad-spectrum

antibiotic as prophylaxis. However, it may not be necessary or prudent to prescribe antibiotics in the absence of infection.

The parents should be informed of the possibility of spontaneous arterial hemorrhage that can occur during the first 3 weeks. They should be instructed to place firm pressure, with gauze, on the bleeding area for 10 minutes. If bleeding persists, they should take the child to the emergency department. Usually, hemorrhage is not a significant problem and does not warrant prophylactic hospitalization except for the most severe and extensive injuries.

The surgical management of burn injuries to the mouth, especially with regard to the time when such surgery should be performed, is controversial. Initially, no surgical intervention is generally warranted. Instead, the treatment of choice is the use of a prosthetic appliance. The primary functions of such an appliance are to prevent contracture of the healing tissue and to serve as a framework on which a more normal-appearing commissure may be created and preserved after completion of the healing process. Many patients at James Whitcomb Riley Hospital for Children have been successfully treated with these appliances. Moreover, surgical procedures have not been needed in cases with good patient compliance in appliance use.

The major components of the burn appliance are illustrated in Fig. 28.33. The appliance is removed when the patient eats, when the teeth and appliance are cleaned, or when modifications of the wings are necessary. The appliance is a static base with wings extending laterally to provide contact with both commissures. If symmetry relative to the midline is to be maintained during the healing process, the wings must come into contact with the commissures equidistant from the midline and must exert essentially equal pressure at these points.

The shape and location of the wings are important in not only preventing contracture or cohesion of the lips during healing but also in shaping the affected commissure to duplicate the unaffected side. Each wing is contoured so that it is thickest in its occlusocervical dimension on the labial aspect. It is tapered as thinly as possible at the point of contact with the commissure (Fig. 28.34). The wings should be just large enough to maintain the correct shape of the commissure. Wings of the proper size will look more pleasing during wear and will enhance acceptance and compliance by the child and parent.

If compliance is a problem with an acrylic appliance, a modified fixed appliance can be constructed and ligated in the mouth. Bands are adapted on the upper second primary molars, and an impression is made. Headgear tubes are welded onto the bands, and a Nance appliance is constructed from a 0.036- or 0.040-inch wire. If the Nance button is not used, the wire is contoured along the gingival portion of the teeth.

After the stabilizing framework is made, the outer portion of the appliance is formed. The anterior arch form is established with a 0.045-inch wire. Horizontal loops are placed in the area approximating the location of the commissures, as determined by clinical measurements. The wire is continued posteriorly, and omega loops are placed mesial to the headgear tubes. Adjustments are made in the acrylic in one or both of the omega loops to achieve the correct fit. With the omega loops used as tiebacks, the appliance is ligated

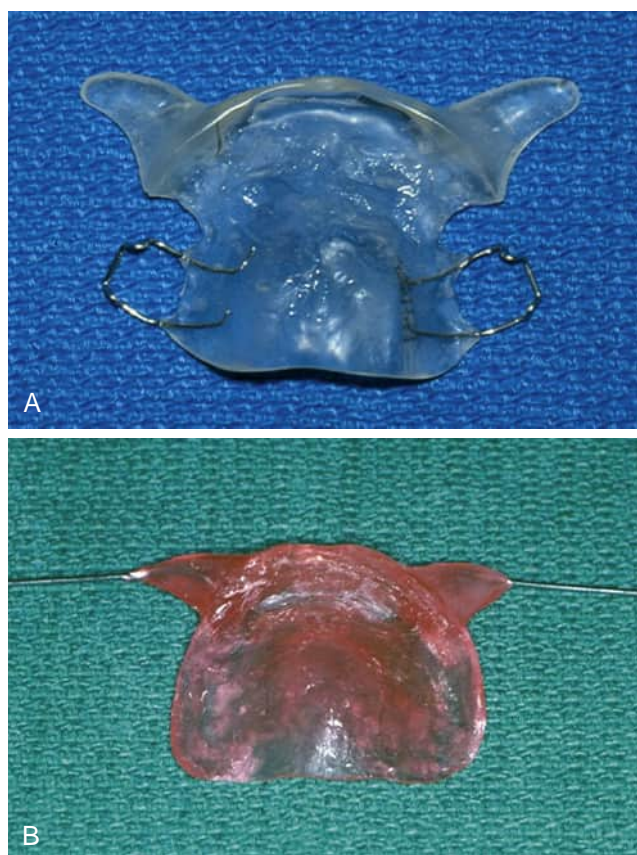


Fig. 28.33 (A) Example of a burn appliance designed for intraoral retention. (B) Example of a burn appliance designed for intraoral and extraoral retention in combination with headgear.

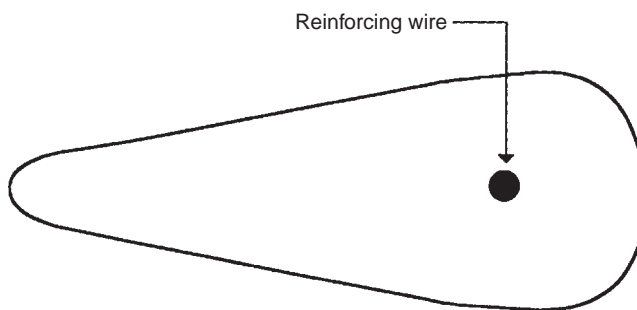
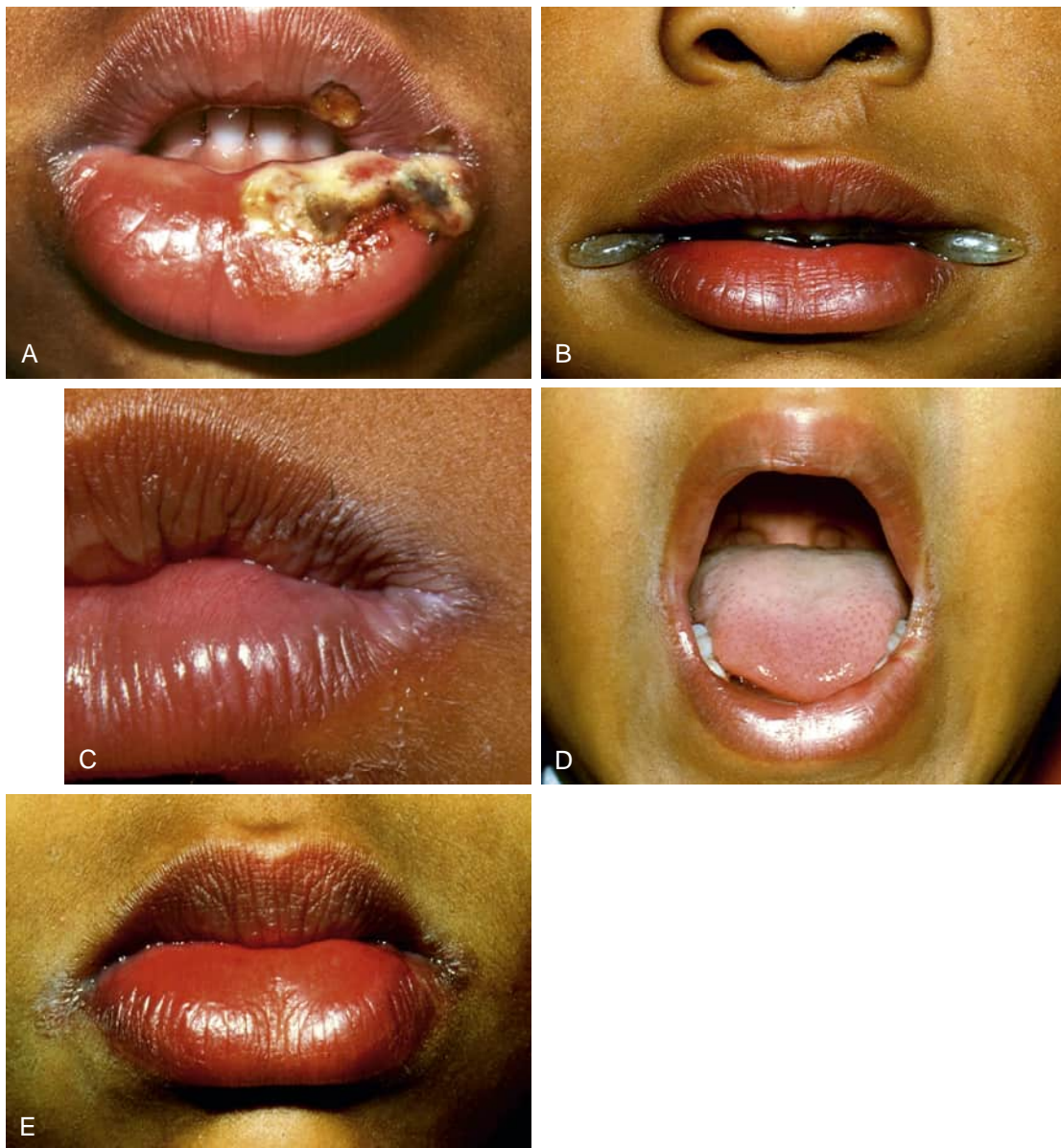

Fig. 28.34 Cross-sectional view of the commissure wing of the burn appliance.

in the mouth. The patient should be evaluated as often as needed during the first month so that necessary adjustments can be made. The patient should be seen at least once a month thereafter.

Ideally, the patient with an oral electrical burn should be seen by the dentist between the 5th and 10th day after the accident. The initial appointment is probably the most crucial to the success or failure of treatment with the burn appliance. Parental apprehension and feelings of guilt are often high, and the trust and confidence of both the parents and the child must be acquired as soon as possible. They should be told in detail what they can expect from the dental services offered and what is expected of them. The parents and the child should be





**Fig. 28.35** (A) Patient the day of the oral burn. There is considerable tissue damage with accompanying swelling at the patient's left lower lip, extending from the midline to the commissure. (B) Properly fitted burn appliance in place (see Fig. 28.33A) for specific appliance type used). (C) Six-month result of appliance usage. Note the contour of the patient's left commissure. (D) Nine-month result of appliance usage. Note that, at maximum opening, there is symmetry of the perioral area without noticeable constriction at the left commissure. (E) One year after the oral burn and optimal appliance usage.

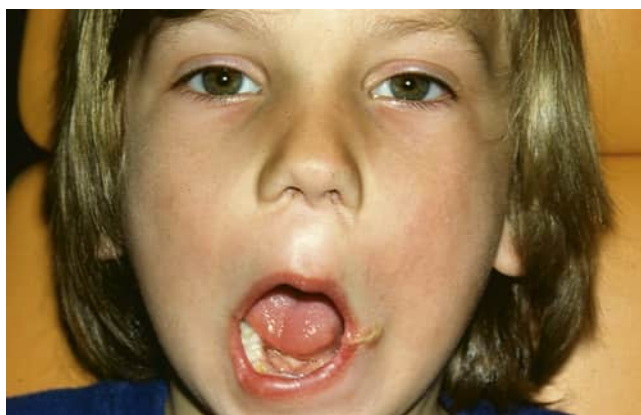shown pictures from previous cases. This not only demonstrates the appearance and purpose of the appliance but also emphasizes that they are not the only ones who have experienced the physical and psychological trauma associated with such an accident. Pictures of patients who did not have an appliance or who did not wear their appliance as instructed are also shown. The impact of such illustrative materials is dramatic.

After the consultation session, the initial data are recorded, photographs are taken, and alginate impressions are obtained for fabrication of the appliance. The appliance is generally delivered between the 10th and 14th day after the injury. At the delivery appointment and at each subsequent appointment, the information and instructions given in the initial consultation

session are reinforced. Constant encouragement and positive reinforcement are important psychological aids in enhancing compliance.

After delivery of the appliance, the patient is seen as often as needed during the first week, but at least once during that time. The patient is checked again at 4 and 8 weeks after appliance delivery. During this period, most of the major modifications to the wings and other components of the appliance are made, and the patient's compliance is closely monitored. Once the appliance is properly modified and the patient is wearing the appliance as instructed, the appointments can be spaced out over 4- to 6-week intervals. The appliance should be worn 24 hours a day for 9–12 months except when the patient is eating and when the appliance is being cleaned (Fig. 28.35).





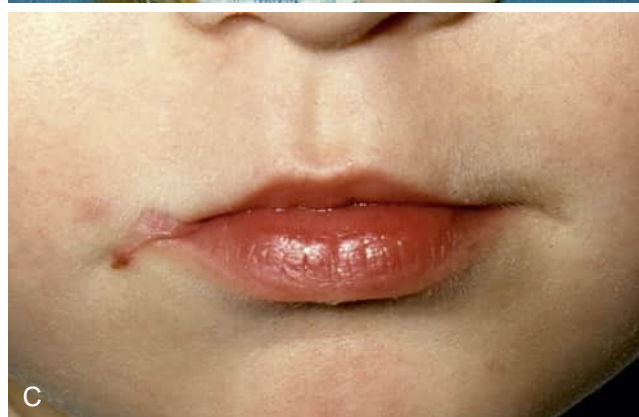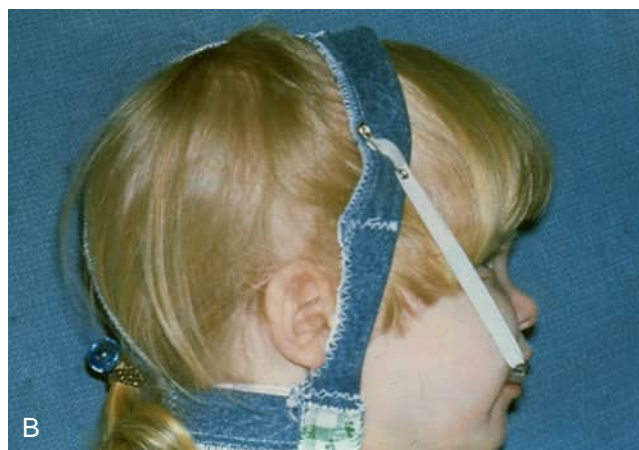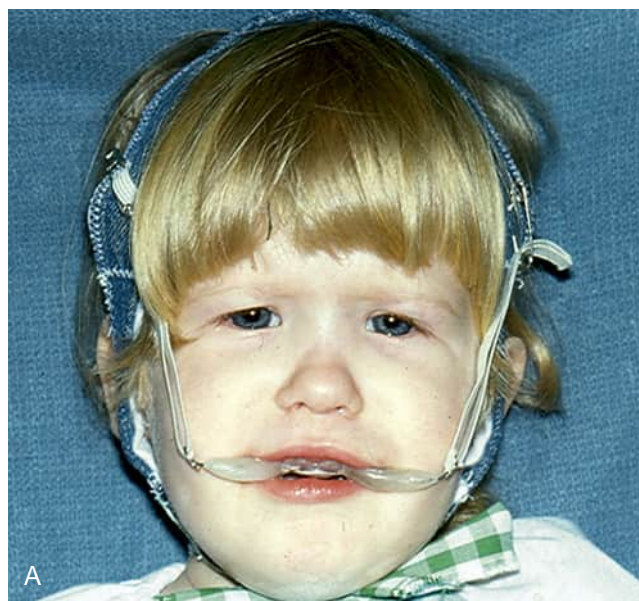**Fig. 28.36** Burn patient who did not wear the appliance as recommended, shown 10 months after the injury. Surgical correction will be considerably more difficult in this patient.

The burn appliance may not eliminate the need for minor surgical revisions of the lips or surrounding cutaneous tissues. Its purpose is to obviate the necessity for more difficult surgical procedures, because good results are difficult to achieve and maintain when one is surgically restoring the shape and location of the oral commissure. The appliance can prevent asymmetry of the commissures resulting from tissue cohesion and scar contracture. It can provide a more normal-appearing commissure after healing. The successful use of this appliance ultimately depends on patient compliance (Fig. 28.36).

Infants or toddlers who do not have primary molars that can be used for intraoral anchorage will not be able to retain the burn appliance without extraoral stabilization. Fig. 28.37 illustrates a headgear type of extraoral anchorage apparatus. It is made of durable cloth, such as denim lined with gingham, and provides a static base from which elastic material extends to the wings of the burn appliance. A well-fitted bonnet may also be used.

Patients with burns to the mouth and who did not have access to appliance therapy or were noncompliant in wearing the burn appliance may have tissue cohesion, contraction, and deformation as a result of healing. Such patients may require a commissurotomy to re-establish the original dimensions and symmetry of the mouth. Unfortunately, with healing of the commissurotomy, there is again a tendency for wound contraction and distortion. Therefore, it may be necessary for the patient to undergo more than one such surgical procedure unless surgery is followed by appliance therapy.

Clinical management of the burn appliance after a commissurotomy differs from management of the appliance after a burn injury. First, the appliance must be delivered by the time the sutures are removed. By the second week after surgery, there may already be a decrease in the lateral extension of the primary incision as a result of wound healing. Second, the total time the patient needs to wear the appliance may be less than 1 year, depending on the clinical course of the healing process. The patient still wears the appliance 24 hours a day, except when eating and when the appliance is being cleaned.<sup>61,62</sup>



**Fig. 28.37** (A) and (B) Properly fitted burn appliance with headgear to enhance stability and retention of the appliance. (C) Nine-month result with appliance therapy.

## Trauma Prevention

Dental practitioners should be proud that we are a prevention-oriented profession. Prevention is especially predominant in dentistry for children. We strive to prevent dental caries, periodontal disease, malocclusion, and anxiety about dental care. If disease is present, our treatment becomes part of an overall

prevention plan designed to halt the progress of disease and prevent its recurrence. The success of the prevention plan, provided that there is parent and patient cooperation, is reasonably predictable.

Unfortunately, our ability to prevent injuries to oral structures is limited. Living and growing carry a high risk of trauma. A child will not learn to walk without falling, and few children reach 4 years of age without having received a blow to the mouth. We cannot totally prevent trauma. Moreover, the results of treatment for trauma are often less predictable than those of other types of dental treatment.

On the brighter side, there are preventive measures that have been proved to reduce the prevalence of traumatic episodes in certain environmental situations. For example, because the prevalence of fractured incisors is higher among those with protrusive anterior teeth, many dentists are recommending early reduction of excessive protrusion to reduce the susceptibility of such teeth to injury. The use of car safety seats and restraining belts has prevented many injuries to infants and young children. The protective mouthguard described in [Chapter 25](#) has prevented or reduced the severity of countless injuries to the teeth of youngsters participating in organized athletic activities; active youngsters should be encouraged to wear their mouthguards during high-risk unsupervised athletic activities as well.

Parents should be reminded that accessible “live” electric cords are potentially dangerous, especially to small children who still use their mouths to evaluate their environment. In addition, anticipatory guidance and education are necessary to advise our patients regarding the negative health effects of intraoral and perioral body piercing. Possible problems that can occur include scar tissue formation, fracture of the dentition, allergic reactions, and bacterial endocarditis in susceptible patients. When we have the opportunity to save a child from pain and suffering, an ounce of prevention is worth a pound of cure.

## References

- Davis MJ, Vogel L: Neurological assessment of the child with head trauma, *J Dent Child* 62:93–96, 1995.
- Davis MJ. Orofacial trauma management. Patient assessment and documentation. *N Y State Dent J*. 995;61(7):42–46.
- Rusmah M: Traumatized anterior teeth in children: a 24-month follow-up study, *Aust Dent J* 35(5):430–433, 1990.
- Andreasen JO, Andreasen FM, Skeie A, et al.: Effect of treatment delay upon pulp and periodontal healing of traumatic dental injuries—a review article, *Dent Traumatol* 18(3):116–128, 2002.
- Diangelis AJ, Andreasen JO, Ebeleseder KA, et al.: International Association of Dental Traumatology guidelines for the management of traumatic injuries: 1. Fractures and luxations of permanent teeth, *Dent Traumatol* 28(1):2–12, 2012.
- Vilela EA, Baratieri LN, Caldeira de Andrada MA, et al.: Tooth fragment reattachment: Fundamentals of technique and two case reports, *Quintessence Int* 34(2):99–107, 2003.
- Macedo GV, Diaz PI, Carlos CA, et al.: Reattachment of anterior teeth fragments: A conservative approach, *J Esthet Restor Dent* 20(1):5–18, 2008.
- Farik B, Munksgaard EC, Andreasen JO, et al.: Fractured teeth bonded with dentin adhesives with and without unfilled resin, *Dent Traumatol* 18(2):66–69, 2002.
- Kanca III J: Replacement of a fractured incisor fragment over pulpal exposure: a long-term case report, *Quintessence Int* 27(12):829–832, 1996.
- Ludlow JB, LaTurno SA: Traumatic fracture—one-visit endodontic treatment and dentinal bonding reattachment of coronal fragment: report of a case, *J Am Dent Assoc* 110(3):341–343, 1985.
- Bimstein E, Rotstein I: Cvek pulpotomy-revisited, *Dent Traumatol* 32(6):438–442, 2016.
- Fong CD, Davis MJ: Partial pulpotomy for immature permanent teeth, its present and future, *Pediatr Dent* 24(1):29–32, 2002.
- American Academy of Pediatric Dentistry: Reference manual 2018–2019, Guidelines on Pulp Therapy for Primary and Immature Permanent Teeth, *Pediatr Dent* 40(6 suppl):343–351, 2018.
- Frank AL: Therapy for the divergent pulpless tooth by continued apical formation, *J Am Dent Assoc* 72(1):87–93, 1966.
- Weine FS: *Endodontic therapy*, ed 6, St. Louis, 2004, Mosby, pp 528–529.
- Giuliani V, Baccetti T, Pace R, et al.: The use of MTA in teeth with necrotic pulps and open apices, *Dent Traumatol* 18(4):217–221, 2002.
- Murray PE, Garcia-Godoy F, Hargreaves KM: Regenerative endodontics: a review of current status and a call for action, *J Endod* 33(4):377–390, 2007.
- Nygaard-Östby B: The role of the blood clot in endodontic therapy. An experimental histologic study, *Acta Odontol Scand* 19(3-4):324–353, 1961.
- Nygaard-Östby B, Hjortdal O: Tissue formation in the root canal following pulp removal, *Scand J Dent Res* 79(5):333–349, 1971.
- Iwaya SI, Ikawa M, Kubota M: Revascularization of an immature permanent tooth with apical periodontitis and sinus tract, *Dent Traumatol* 17(4):185–187, 2001.
- Nakashima M, Akamine A: The application of tissue engineering to regeneration of pulp and dentin in endodontics, *J Endod* 31(10):711–718, 2005.
- Hargreaves K, Law A: Regenerative endodontics. In Hargreaves K, Cohen S, editors: *Cohen's pathways of the pulp*, ed 10, St. Louis, 2010, Mosby Elsevier, pp 602–620.
- Diogenes A, Henry MA, Teixeira FB, et al.: An update on clinical regenerative endodontics, *Endodontic Topics* 28(1):2–23, 2013.
- Yassen GH, Chu TM, Eckert G, et al.: Effect of medicaments used in endodontic regeneration technique on the chemical structure of human immature radicular dentin: an in vitro study, *J Endod* 39(2):269–273, 2013.
- Hoshino E, Kurihara-Ando N, Sato I, et al.: In-vitro antibacterial susceptibility of bacteria taken from infected root dentine to a mixture of ciprofloxacin, metronidazole and minocycline, *Int Endod J* 29(2):125–130, 1996.
- Reynolds K, Johnson JD, Cohenca N: Pulp revascularization of necrotic bilateral bicuspid using a modified novel technique to eliminate potential coronal discoloration: a case report, *Int Endod J* 42(1):84–92, 2009.
- Ruparel NB, Teixeira FB, Ferraz CC, et al.: Direct effect of intracanal medicaments on survival of stem cells of the apical papilla, *J Endod* 38(10):1372–1375, 2012.
- Cehreli ZC, Isbitiren B, Sara S, et al.: Regenerative endodontic treatment (revascularization) of immature necrotic molars medicated with calcium hydroxide: a case series, *J Endod* 37(9):1327–1330, 2011.
- American Association of Endodontists. Considerations for regenerative procedures. Available at: <https://www.aae.org/specialty/clinical-resources/regenerative-endodontics/> Accessed May 15, 2019.
- Geisler TM: Clinical considerations for regenerative endodontic procedures, *Dent Clin North Am* 56(3):603–626, 2012.
- Almutairi W, Yassen GH, Aminoshariae A, et al.: Regenerative endodontics: a systematic analysis of the failed cases, *J Endod* 45(5):567–577, 2019.
- Croll TP, Pascon EA, Langeland K: Traumatized primary incisors: a clinical and histological study, *J Dent Child* 54(6):401–422, 1987.
- Holan G, Fuks AB: The diagnostic value of coronal dark-gray discoloration in primary teeth following traumatic injuries, *Pediatr Dent* 18(3):224–227, 1996.
- Peterson DS, Taylor MH, Marley JF: Calcific metamorphosis with internal resorption, *Oral Surg* 60(2):231–233, 1985.
- Mummery JH: Some further cases of chronic perforating hyperplasia of the pulp, the so-called “pink spot”, *Br Dent J* 47:801–811, 1926.
- Andreasen JO, Sundström B, Ravn JJ: The effect of traumatic injuries to the primary teeth on their permanent successors, *Scand J Dent Res* 79(3):219–283, 1972.
- Cutright DE: The reaction of permanent tooth buds to injury, *Oral Surg Oral Med Oral Pathol Oral Radiol* 32(5):832–839, 1971.
- Kilpatrick NM, Hardman PJ, Welbury RR: Dilaceration of a primary tooth, *Int J Paediatr Dent* 1(3):151–153, 1991.



39. Ravn JJ: Sequelae of acute mechanical traumata in the primary dentition, *J Dent Child* 35:281–289, 1968.
40. Skjeller V: The prognosis for young teeth loosened after mechanical injuries, *Acta Odontol Scand* 18(2):171–181, 1960.
41. Alkhalifa JD, Alazemi AA: Intrusive luxation of permanent teeth: a systematic review of factors important for treatment decision-making, *Dent Traumatol* 30(3):169–175, 2014.
42. Wang C, Qin M, Guan Y: Analysis of pulp prognosis in 603 permanent teeth with uncomplicated crown fracture with or without luxation, *Dent Traumatol* 30(5):333–337, 2014.
43. Tronstad L, Trope M, Bank M, et al.: Surgical access for endodontic treatment of intruded teeth, *Endod Dent Traumatol* 2(2):75–78, 1986.
44. Shapira J, Regev L, Liebfeld H: Reeruption of completely intruded immature permanent incisors, *Endod Dent Traumatol* 2(3):113–116, 1986.
45. Barry GN: Replanted teeth still functioning after 42 years: report of a case, *J Am Dent Assoc* 92(2):412–413, 1976.
46. Camp JH: Replantation of teeth following trauma. In McDonald RE, et al.: *Current therapy in dentistry*, Vol 7. St. Louis, 1980, Mosby.
47. Andreasen JO: Effect of extra-alveolar period and storage media upon periodontal and pulpal healing after replantation of mature permanent incisors in monkeys, *Int J Oral Surg* 1(10):43–53, 1981.
48. Andreasen JO, Hjørting-Hansen E: Replantation of teeth. I. Radiographic and clinical study of 110 human teeth replanted after accidental loss, *Acta Odontol Scand* 24(3):263–286, 1966.
49. Trope M: Clinical management of the avulsed tooth: present strategies and future directions, *Int Endod J* 18(1):1–11, 2002.
50. Sherman Jr P: A histologic study of intentional replantation of teeth in dogs and monkeys, *J Dent Res* 47(6):1066–1071, 1968.
51. Hurst RV: Regeneration of periodontal and transseptal fibers after autografts in rhesus monkeys: a qualitative approach, *J Dent Res* 51(5):1183–1192, 1972.
52. von Arx T, Filippi A, Buser D: Splinting of traumatized teeth with a new device: TTS (titanium trauma splint), *Dent Traumatol* 17:180–184, 2001.
53. Sae-Lim V, Wang CY, Trope M: Effect of systemic tetracycline and amoxicillin on inflammatory root resorption of replanted dogs' teeth, *Endod Dent Traumatol* 14(5):216–220, 1998.
54. Krasner P, Rankow HJ: New philosophy for the treatment of avulsed teeth, *Oral Surg Oral Med Oral Pathol Oral Radiol Endod* 9(5):616–623, 1995.
55. Andersson L, Andreasen JO, Day P, et al.: International Association of Dental Traumatology guidelines for the management of traumatic dental injuries: 2. Avulsion of permanent teeth, *Dent Traumatol* 28(2):88–96, 2012.
56. Waterhouse PJ, Whitworth JM, Camp JH, et al.: Pediatric endodontics: Endodontic treatment for the primary and young permanent dentition. In Cohen S, Hargreaves KM, editors: *Pathways of the pulp*, ed 10, St. Louis, 2010, Mosby, pp 808–857.
57. Andreasen FM, Andreasen JO, Cvek M: Root fractures. In Andreasen JO, Andreasen FM, Andersson L, editors: *Textbook and color atlas of traumatic injuries to the teeth*, ed 4, Oxford, 2007, Blackwell, pp 337–371.
58. Cvek M, Andreasen JO, Borum MK: Healing of 208 intra alveolar root fractures in patients age 7-17 years, *Dent Traumatol* 17(2):53–62, 2001.
59. Cvek M, Mejère I, Andreasen JO: Healing and prognosis of teeth with intraalveolar fractures involving the cervical part of the root, *Dent Traumatol* 18(2):27–65, 2002.
60. Torabinejad M, Chivian N: Clinical applications of mineral trioxide aggregate, *J Endod* 25(3):197–201, 1999.
61. Palin Jr WE, Sadove AM, Jones JE, et al.: Oral electrical burns in a pediatric population, *J Oral Med* 42(1):17–21, 1987.
62. Sadove AM, Jones JE, Lynch TR, et al.: Appliance therapy for perioral electrical burns: a conservative approach, *J Burn Care Rehabil* 9(4):391–395, 1988.

### Suggested Readings

- Glendor U: Epidemiology of traumatic dental injuries, *Dent Traumatol* 24(6):603–611, 2008.
- Jones JE, Cooper MD: Tooth avulsion: a protocol for improved success, *Contemp Oral Hygiene* 2(4):40–43, 2002.
- Jones KB, Greenwell A, E Jones J: Intrusion and lateral luxation of permanent incisors in pediatric patient secondary to dental trauma: Case Report, *Adv Dent & Oral Health*. 4(1):555628, 2017, <https://doi.org/10.19080/ADOH.2017.04.555628>.
- Martins-Júnior PA, Franco FA, De Barcelos RV, et al.: Replantation of avulsed primary teeth: a systematic review, *Int J Paediatr Dent* 24(2):77–83, 2014.
- Taylor LB, Walker J: A review of selected microstomia prevention appliances, *Pediatr Dent* 19(6):413–418, 1997.



## 29

# Oral Surgery for the Pediatric Patient

CARRIE A. KLENE, ELIE M. FERNEINI and JEFFREY D. BENNETT

## CHAPTER OUTLINE

### Simple Exodontia

#### Impacted Teeth

Impacted Third Molars

Impacted Teeth Other than Third Molars

#### Associated Hard Tissue Lesions

Pediatric Odontogenic Tumors

Pediatric Odontogenic Cysts

### Soft Tissue Procedures

Mucocele and Ranulas

Fibromas and Pyogenic Granulomas

#### Infection of the Head and Neck Region

Fracture of the Mandible

#### Summary

Office-based pediatric oral surgical procedures include dentoalveolar surgery (primarily consisting of exodontia), intraoral soft tissue procedures (e.g., frenectomy), medical and surgical management of odontogenic infections, and intraoral surgical procedures involving the alveolar ridge (e.g., enucleation of an odontoma). The basic principles employed in the management of these surgical conditions are essentially identical to those used by the pediatric dentist in the management of various other dental diagnoses encountered.

The initial step in patient management is to develop a diagnosis through a process involving taking patient history, physical examination, and imaging. Once the surgery is decided, the practitioner should visualize the various steps and their sequence as well as the potential complications and their management as they develop their comprehensive treatment plan.

For the pediatric patient, there must be consideration to the patient's ability to cooperate. Depending on the patient's age, systemic health, and planned surgery, the practitioner may consider using nitrous oxide inhalational sedation, oral sedation, intramuscular sedation, intravenous sedation, or a combination of these modalities. Regardless of the route of agent administration or the selection of pharmacologic agent, the primary consideration in sedating a pediatric patient is the safety and depth of sedation achieved. Oral sedation and nitrous oxide are most commonly used in the pediatric dental office. Nitrous oxide is advantageous in that it can be titrated achieving both rapid onset and recovery from the effect of the nitrous oxide. The practitioner must be aware that nitrous oxide when combined with an oral agent (e.g., benzodiazepine) can potentiate the effect of the oral agent, producing a more profound depth of sedation and at times producing a depth of sedation equal to general anesthesia.<sup>1,2,3</sup>

General principles that apply to both the adult and pediatric patient include profound anesthesia, aseptic technique, visibility, and surgical site stability. Achieving profound anesthesia is dependent on knowledge of the anatomy of

the second and third division of the trigeminal nerve. This is discussed in [Chapter 16](#).

Most office-based oral surgical procedures do not dictate adherence to sterile technique, but require a clean technique. The clean technique requires that the dentist scrubs his or her hands with an antiseptic soap. The hands may be dried off using a nonsterile disposable towel. The hands are then gloved. The dentist does not need to wear a sterile gown but should wear a gown covering his or her arms. A mask and eye protection are also used by the dentist. The gown, mask, and eye protection are as much for the protection of the dentist as they are for the protection of the patient. The perioral region and oral cavity do not need to be decontaminated for a clean technique. However, only sterile water or sterile saline should be used for irrigating a surgical wound. Surgical drills that are self-irrigating can accommodate the use of sterile irrigating solutions. Last, the dentist may opt to drape the patient and place protective eyewear on the patient. Draping and eyewear maintain sterility in the sterile surgical field, as well as protect the patient from soiling of clothes or from having debris or a suture injure the eye. The clean technique strives to achieve the basic premise of a sterile technique, which is to prevent any organism from the surgical staff, other patient, instrumentation, or equipment from contaminating the patient.

Adequate visibility is required for all dental procedures. For oral surgical procedures, this entails adequate access, adequate light, and a good suction to create a debris-free surgical field. Adequate access requires appropriate mouth opening. Opening the patient's mouth and maintaining its opening can be facilitated with a bite block ([Fig. 29.1](#)) or a Molt mouth prop. A small bite block may be used and the degree of mouth opening varied by its placement in the mouth. For maximal mouth opening, the bite block is placed more posteriorly. A piece of floss may be attached to the bite block. The knot securing the floss to the bite block must be secure so that it does not loosen. If the bite block is displaced into the pharynx, the floss attached to the bite block extends out of the mouth, assisting in retrieval of the bite block. The



Fig. 29.1 Two views of a bite block.



Fig. 29.2 Austin retractor.

Molt mouth prop has a ratchet-type action and can be used to assist in opening the patient's mouth. This can be beneficial when managing the uncooperative patient. Excessive force could be applied with the Molt mouth prop, causing iatrogenic injury such as displacement of teeth or injury to the temporomandibular joint (TMJ). In addition to keeping the mouth open for the surgical procedure, the bite block stabilizes the mandible. When extracting a mandibular tooth, using the bite block minimizes mandibular movement and the resultant transmission of excessive forces to the TMJ.

Adequate access also requires appropriate retraction. Commonly used retractors in oral surgery include the Austin retractor (Fig. 29.2), the Minnesota retractor (Fig. 29.3), and the Weider retractor (Fig. 29.4). The Austin and Minnesota retractors are usually used to retract the cheek and surgical flaps. Tongue retraction is usually performed using a Weider retractor. The Weider retractor is a heart-shaped retractor with a serrated edge. Retraction of the tongue with the Weider retractor is best achieved by placing the lateral aspect of the retractor firmly against the alveolus. A gauze or sponge packing may be placed just medial to the retractor. This packing provides a barrier between the surgical site and the pharynx preventing the tooth, surgical debris, or irrigating solution from potentially being swallowed, aspirated or irritating the pharynx. If the tongue is retracted medially, the



Fig. 29.3 Minnesota retractor.

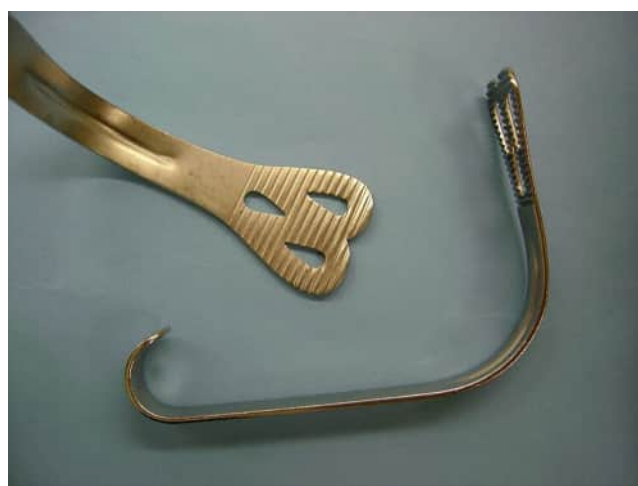

Fig. 29.4 Weider "sweetheart" retractor.

pharyngeal barrier is displaced medially, opening up a passage between the mouth and the pharynx and there is the potential to stimulate the gag reflex. Care must also be taken not to position the retractor too far posteriorly into the pharynx, which also stimulates the gag reflex. Retraction may be performed either by the dentist using his or her nondominant hand or by the assistant.

Adequate visibility depends on establishing a debris-free surgical field. This requires a good surgical assistant using high-speed surgical suction. The surgical tray should have a Fraser suction tip (Fig. 29.5), which is available in various sizes. The Fraser tip has an opening in the handle that allows regulation of the suction power. The operator of the suction places his or her thumb over the hole in the handle when the suction is placed on the bone and maximal suction power is desired. When less suction power is desired (e.g., when suctioning soft tissue), the operator leaves the opening in the handle open, which decreases the suction power. The practitioner should also have a Yankauer or tonsillar suction available (Fig. 29.6). This suction removes significant quantities of debris and, with its blunt tip, it can be passed blindly down the throat.

## Simple Exodontia

Indications for extractions in children are much the same as that in adult patients: nonrestorable caries, apical disease,



Fig. 29.5 Fraser suction tip.



Fig. 29.6 Yankauer or tonsillar suction.

fractures of crowns or roots, prolonged retention of primary teeth because of improper root resorption or ankylosis, impacted teeth, and supernumerary teeth. The dentist must have an understanding of the growth and development of the pediatric patient in order to assess and diagnose the situations that will be encountered in the pediatric patient. For example, the dentist should have knowledge of the eruption pattern of the primary and permanent teeth. Delayed eruption, especially when asymmetric, is frequently an indication of an abnormality.

Radiographic surveys of teeth to be extracted are of prime importance. The dentist should observe the size and contour of the primary roots, the amount and type of resorption, the relation of the roots to the succedaneous teeth, and the extent of disease (Fig. 29.7).

Simple exodontia in the pediatric patient requires minimal modification from that used in the adult (Video 29.1). Concepts that may dictate slight modification include the following: (1) the dentist must be cognizant of the proximity of the deciduous tooth to the succedaneous tooth and (2) the roots on primary teeth with nonresorbed roots will be long, slender, and potentially divergent.

The patient must be appropriately positioned for the surgical procedure. For the extraction of a maxillary tooth, the patient is positioned in the dental chair such that the maxillary occlusal plane is at an angle between 60 and 90 degrees to the floor. For the extraction of a mandibular tooth, the patient is positioned in the dental chair such that the mandibular occlusal plane is parallel to the floor. The height of the chair should be such that the patient's mouth is at or slightly below the level of the dentist's elbow level. The surgeon's elbow of their dominant arm should be against their body. When performing surgery in the dental office in a dental chair (compared with the operating room

on an operating room bed), the patient is usually semisupine rather than completely supine. Patients are generally more reclined for extractions of maxillary teeth. There is an advantage for the sedated patient to be positioned more upright and not fully supine. The pediatric patient's ribs are angled more horizontally relative to the vertebral column and the accessory muscles are less developed, resulting in less effective thoracic expansion and a greater dependence on diaphragmatic breathing. Diaphragmatic breathing is compromised when the patient is supine; thus maintaining a more upright position is respiratorily favorable, especially in the sedated patient.

The basic details are eloquently illustrated in more detail in the seventh edition of *Contemporary Oral and Maxillofacial Surgery*. The first step in extracting a tooth is to separate the soft tissue attachment from the cervical aspect of the tooth. This is most commonly achieved with a #9 Molt elevator (Fig. 29.8). The Molt elevator is a dual-ended instrument; one end is sharply pointed and is used to initiate the separation of the soft tissue attachment from the tooth. The sharp pointed end of this instrument is placed interproximally on the mesial aspect of the papillae. The concave aspect of the instrument faces the tooth. Using a twisting motion, the dentist elevates the papillae. The tip of the elevator is then slid through the sulcus along the crest of the alveolar bone, completely separating the buccal soft tissue attachment from the tooth. The same can be done on the lingual or palatal aspect of the tooth. If a flap is reflected, the broad, rounded end of the instrument may be used in a pushing (concave aspect of instrument against the bone) or a pulling motion (instrument more perpendicular to the bone with the concave aspect of the instrument facing the direction of movement) to reflect a full-thickness mucoperiosteal flap.

Extracting a tooth is an exercise in administering a controlled force in a slow and deliberate fashion to expand the alveolus and disrupt the periodontal ligaments, such that the tooth can be atraumatically removed from the jaw. The second step in extracting a tooth is to use a dental elevator to luxate the tooth. A straight elevator (Fig. 29.9) is most commonly used. The straight elevator has a concave blade that is placed toward the tooth being luxated. The blades are available in various sizes. The edge of the blades may be serrated to better grasp the tooth. The separation and reflection of the dental papillae facilitates placement of the elevator such that it rests on the alveolus. The elevator is initially inserted perpendicular to the tooth in the axial plane, and either parallel or with the blade of the elevator angled toward the alveolar crest up to 45 degrees from the alveolar crest in the coronal plane. The elevator is then turned such that the portion of the blade resting on the alveolus acts as a fulcrum and the coronal portion of the blade rotates toward the tooth being extracted. This action expands the alveolus, disrupts the periodontal ligament, and establishes initial mobility of the root. The degree of mobility need not be great to achieve benefit from an elevator. Indeed, only limited movement can be achieved when there are adjacent teeth. Excessive force can fracture the tooth being extracted, converting a simple, closed extraction into an open extraction, or damage adjacent teeth or restorations. The straight elevator may in selected situations be used as a wedge. In this situation, once a space has been created between the bone surrounding the tooth socket



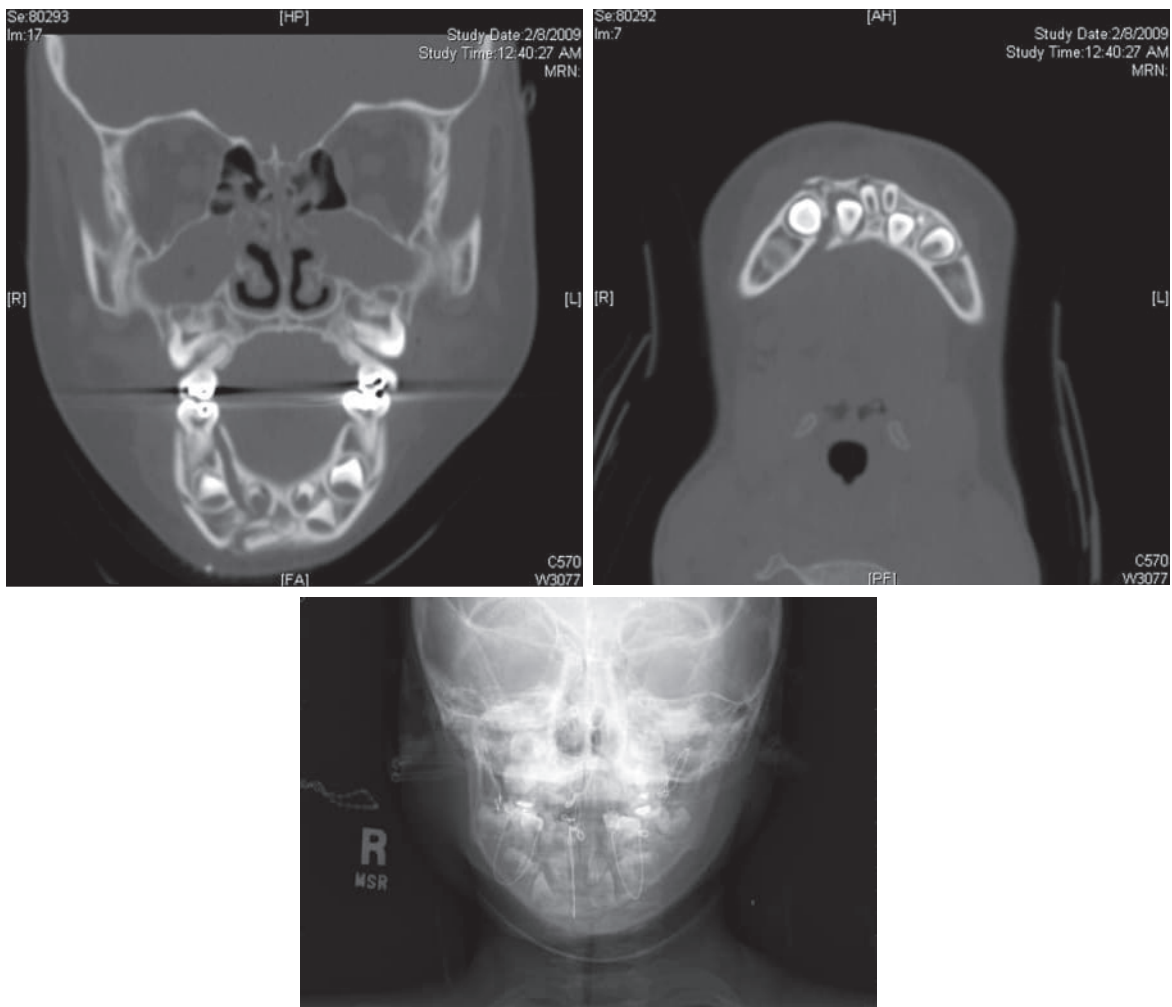


Fig. 29.7 Proximity of succedaneous teeth to roots of deciduous teeth.



Fig. 29.8 9 Molt elevator.

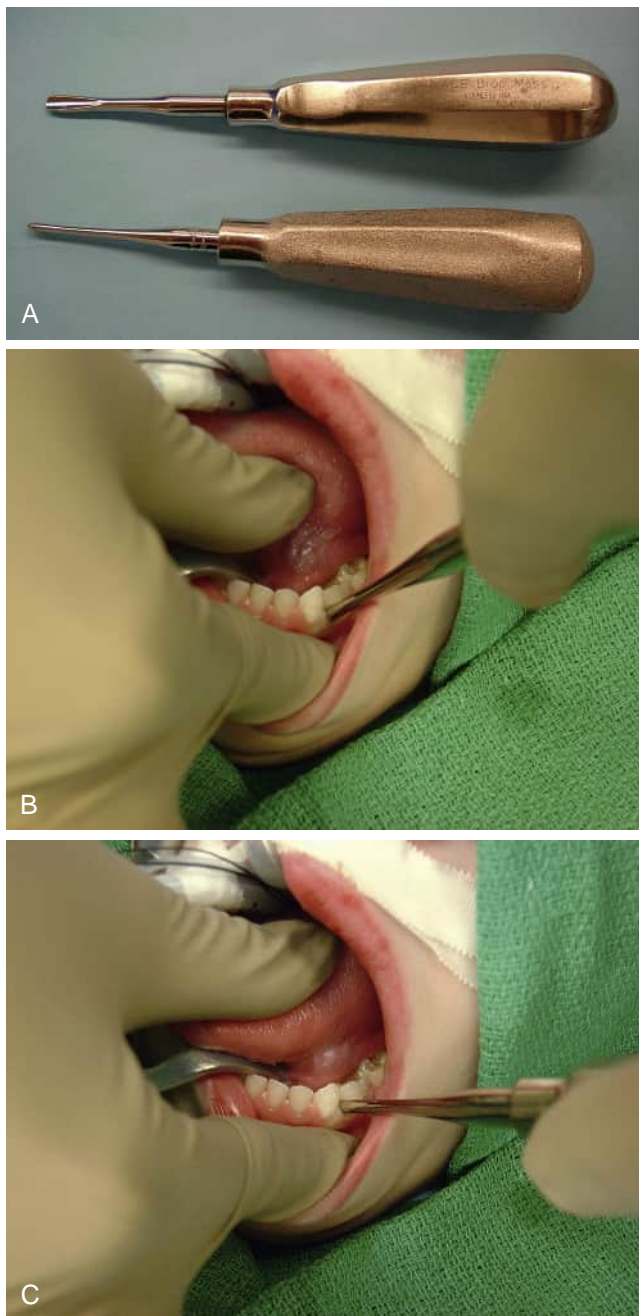
and the tooth, the elevator is “wedged” between the alveolar bone and the tooth. Wedging the elevator inferiorly expands the alveolus, which facilitates extracting the tooth with forceps. Alternatively, as the elevator is “wedged” apically and medially into the space between the bone and the tooth, the tooth is displaced coronally.

The last step in extracting a tooth is to remove the tooth with forceps, which must be appropriately selected. Several forceps are available in smaller sizes for the pediatric patient (Fig. 29.10). The following are basic principles in selecting forceps:

1. The beaks of the forceps should adapt to the root surface of the tooth.
2. The beaks of the forceps when positioned and engaging the tooth should be parallel to the long axis of the tooth.
3. The size of the beaks of the forceps should be small enough not to engage the adjacent teeth during luxation

and removal of the tooth. The beaks of the forceps should be placed under the separated and reflected soft tissue and the tooth firmly engaged.

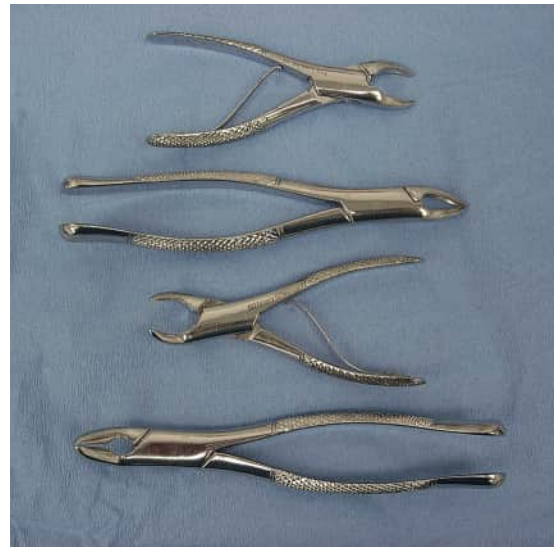The first force applied by the dentist when using forceps is apically directed. The apically directed force positions the center of rotation as close to the root apex of the tooth as possible. The more apical the center of rotation and the closer it is to the apex of the tooth, the less the apical third of the root is subjected to translational movement, and the less likely an apical third root fracture will occur. The apically directed force also disrupts the periodontal ligaments. With apically directed force maintained, the tooth is luxated toward the buccal and lingual/palatal aspect. Luxation is slow. Movement is in one direction, and then stopped while the alveolus is allowed to expand before movement begins in the opposite direction. With each deliberate movement, the force is increased expanding the alveolus. Rapid, jerky movements are ineffective and not recommended. Rotational forces may be applied for selected roots that are conical (anterior teeth, cuspids, mandibular premolars, maxillary second premolar). The opposite hand may be placed such that the index finger or thumb is positioned on either the buccal and/or lingual/palatal aspect of the alveolus and can feel the expansion of the alveolus. Finally, once



**Fig. 29.9** (A) Straight elevator. (B) The straight elevator can be placed at 45 degrees to the occlusal plane or (C) parallel to the occlusal plane.

the alveolus is sufficiently expanded and the periodontal ligament disrupted, slight coronal tractional forces are applied and the tooth is removed.<sup>4</sup>

In general, deciduous anterior teeth should be luxated to the labial aspect during the extraction procedure because of the lingual position of the permanent teeth, and posterior teeth should be luxated with buccal and lingual pressures. However, the dentist may know the direction of least resistance and may deliver the tooth based on the individual situation. Although rare, the dentist must know when the roots of the deciduous molars are configured such that they could engage the succedaneous tooth and possibly cause the succedaneous tooth to be extracted with the deciduous tooth. If



**Fig. 29.10** The armamentarium for exodontic procedures in pediatric patients is much the same as in adults, even though all anatomic structures are smaller. Several forceps for primary teeth offer some convenience; however, they are not necessary to perform any of the extractions. Large adult forceps such as the “cowhorn” are contraindicated in the pediatric patient.

this is recognized radiographically or becomes noted during the extraction, then sectioning the deciduous tooth with a surgical handpiece under irrigation may be indicated.

**Video 29.1** Exodontia: extraction of a primary molar and incisors. 

A traditional dental drill should not be used for surgical procedures. The surgical drill must vent its air away from the surgical field. If a drill vents its air toward the surgical site, there is considerable risk for development of air emphysema or an air embolism. Air emphysema is the result of air being forced into the tissue planes under the periosteal flap. This can cause a significant dissection of the tissue planes, resulting in crepitus and swelling, and potentially cause airway problems. When drilling on the bone, air could be forced into the vascular channels within the bony canals. Air that is forced into these vascular channels can travel through the bloodstream and cause an embolus in more distant and vital organs.

A root tip from a primary tooth may fracture during the procedure. The dentist should attempt to remove the root tip. Proper use of an elevator will ideally have loosened the root of the tooth, which facilitates root tip removal. However, if the dentist thinks that the attempt to remove the root tip poses a significant risk to the adjacent tooth or the succedaneous tooth, then the residual root tip should be left in the bone. Usually, these root tips do not cause adverse sequelae. They may eventually resorb or migrate toward the gingiva and become exposed with the eruption of the permanent tooth. A posttreatment radiograph should be obtained and the child’s parent should be informed. Informing the parent before the extraction and obtaining a written consent listing the various potential complications avoids having to present the complication as an unlikely and unexpected sequelae of surgery with the perception of “poor quality” treatment.

A primary tooth may be submerged or ankylosed. Ankylosed teeth may be slightly out of occlusion (Fig. 29.11) or

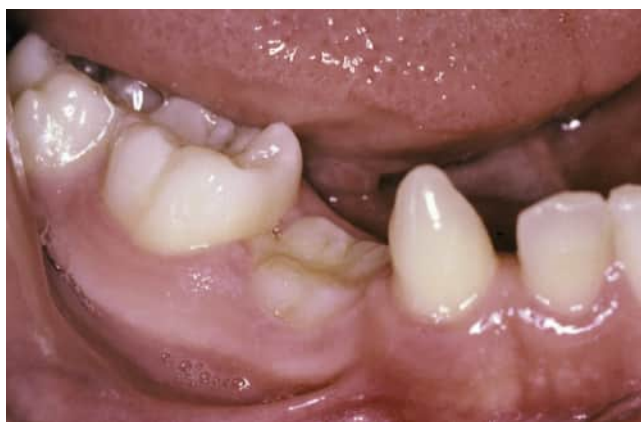

Fig. 29.11 Ankylosed tooth.

they may be completely within the alveolar process yet show evidence of having once been in the mouth. A submerged tooth may have nonresorbed divergent roots, or may have all or nearly all the root resorbed. Despite having the root significantly resorbed, the tooth may show no signs of mobility when pressure or leverage is applied and exhibit a solid sound on percussion. These teeth may be virtually welded to the surrounding bone. The radiographic and clinical examination may not entirely predict the considerable difference in the degree of ankylosis and what difficulties may be encountered in the removal of the tooth. The basic principles pertaining to extraction are followed. A tooth with nonresorbed divergent roots in which the potential for a root fracture is high and the path of draw is inadequate may be best extracted by sectioning the tooth. If luxation is not accomplished with reasonable forceps pressure when extracting the ankylosed tooth, a surgical approach is required.

One such technique to surgically remove an ankylosed tooth entails (1) using a bur to judiciously and conservatively remove the bone around the tooth until it can be removed or (2) using a bur to carefully “drill away” the tooth. Frequently the difference between the tooth structure and bone cannot be determined clinically. Care must be taken to minimize excessive bone removal and avoid injury to another tooth or vital structure. An intraoperative or postoperative radiograph may be indicated to assess the situation. The dentist may decide to leave a portion of the residual root, which is rarely associated with any adverse sequelae.

## Impacted Teeth

An impacted tooth is one that fails to erupt. This may be secondary to insufficient space in the dental arch (e.g., dental crowding or aberrant tooth development), mechanical obstruction secondary to a pathologic lesion (e.g., odontoma), a supernumerary tooth, or malposed tooth germs. Failure of a tooth to erupt may also be associated with genetic abnormalities.

### IMPACTED THIRD MOLARS

The extraction of third molars is the most common surgical procedure in dentistry. It is, therefore, critical for the pediatric dentist to understand the standard of care for the treatment of the impacted third molar. Refer to the position paper

published by *American Association of Oral and Maxillofacial Surgeons*. There are multiple reasons for extracting a third molar; however, the primary reason for the pediatric dentist to refer the patient to a surgeon for the extraction of an impacted third molar is the presence of disease. Reasons to extract third molars include third molars with disease (caries, periodontal disease or pathology), a nonfunctional tooth, justified for orthodontic reasons and planned orthognathic surgery.<sup>5,6</sup> Although Ash et al.<sup>7</sup> raised this issue almost 50 years ago, the concept of prophylactically extracting third molars to prevent disease versus extracting them when pathology develops remains a controversial subject.

The extraction of third molars in the young patient, however, is not necessarily deemed as preventive. Several publications from the *Oral and Maxillofacial Surgery Foundation* and *American Association of Oral and Maxillofacial Surgeons* jointly sponsored Third Molar Clinical Trials have demonstrated that “absence of symptoms does not indicate absence of disease or pathology.” Data from these studies have “demonstrated that periodontal pathology initiates in the mandibular third molar region” and spreads throughout the mouth.<sup>5,6</sup> Additionally, the prevalence of caries in the erupted third molars increases with increasing age. Recent literature has also demonstrated an association between periodontal disease and systemic manifestations, further supporting the indications for extracting third molars. One controversial issue regarding mandibular third molars is their influence on anterior crowding of mandibular teeth, especially after orthodontic therapy. Multiple studies have been reported that support both sides of this controversy. Even though it is likely that third molars play an etiology in crowding, their role may not be clinically significant.<sup>8,9</sup>

If it is advantageous to extract third molars, the timing of this procedure should be such that is performed with the intent to optimize health and minimize potential risks and complications. Optimal bone healing with improvement of intrabony defects on second molars adjacent to third molars has been shown to occur when surgery is performed in individuals younger than 25 years of age.<sup>10</sup> Risks associated with surgery, such as alveolar osteitis, injury to the inferior alveolar nerve, and oroantral communication, have also been demonstrated to be higher in individuals aged 25 years and older.<sup>11</sup> Health-related quality-of-life indicators are also better for younger individuals.<sup>12</sup>

### IMPACTED TEETH OTHER THAN THIRD MOLARS

The most commonly impacted tooth is the third molar. While any tooth could be impacted, other commonly impacted teeth (in this frequency) seen by the dentist include the maxillary canine, second premolar, mandibular second molar, and maxillary incisors. The prevalence of impaction or failure of eruption of a primary tooth is rare. The latter is commonly associated with pathology, such as an odontoma or supernumerary tooth. Commonly impacted supernumerary teeth managed by the pediatric dentist include the mesiodens and supernumerary mandibular premolars.

The prevalence of impaction of the permanent maxillary canine is up to 2% (Fig. 29.12), and 8% of canine impactions occur bilaterally. The occurrence of an impacted canine is greater in female patients, with a predilection for individuals with a familial history.<sup>13</sup> The impacted maxillary canines are labially positioned 15% of the time and



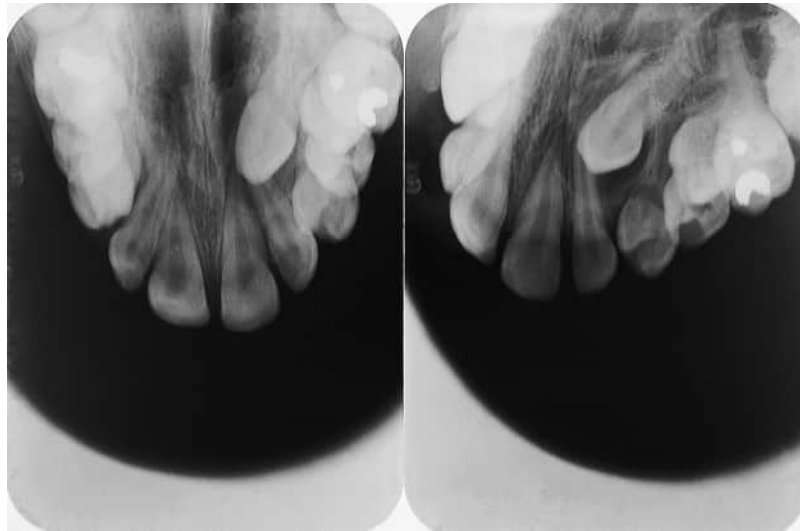


Fig. 29.12 Impacted cuspid.

palatally positioned 85% of the time. Arch length deficiency probably contributes to the impaction of the labially positioned canine, while it may not be a contributing factor with the palatally positioned canine.<sup>14</sup>

The second premolar is reported as the next most frequently impacted tooth. The mandibular premolar is more commonly impacted than the maxillary premolar. The impacted mandibular premolar is usually located lingually or midalveolus and the maxillary premolar is located palatally. However, Kaban and Troulis<sup>15</sup> have reported the maxillary incisors as the tooth impacted most frequently after the maxillary canine. They suggested that the frequency of impaction of the maxillary incisors is most likely secondary to injury, infection, or loss of the deciduous incisors. If the deciduous incisors are lost prematurely, a dense, hyperplastic, fibrous tissue may form over the alveolus, which impedes eruption and contributes to the impaction of the permanent maxillary incisors.

Ideally, early recognition of an altered eruption pattern and, if possible, interceptive serial extractions of deciduous teeth and/or orthodontics can facilitate eruption. However, regardless of early recognition, a tooth may become impacted. Once an altered eruption pattern is recognized, the dentist must perform a clinical and radiographic examination. Palpation of the buccal, lingual, or palatal aspects may reveal a bulge, suggesting the location of the impacted tooth. When the tooth is not palpable, radiographic imaging is indicated to determine the location of the impacted tooth. Several radiographic techniques can be used to assist in locating an impacted tooth. These are discussed in [Chapter 2](#).

Management of an impacted tooth may include: (1) observation, (2) extraction of the impacted tooth, (3) surgical exposure and assisted eruption, (4) surgical uprighting, or (5) autotransplantation. Several factors must be considered while deciding the management of the impacted tooth. These include age and health of the patient, the potential pathology associated with the impacted tooth, location and angulation of the impacted tooth, the benefit of surgery, the frequency and severity of the risks of surgery, the risks and consequences of no surgical intervention as well as the economic consequences of surgical versus nonsurgical intervention, and the quality of life associated with each of these decisions.

This chapter does not discuss the treatment planning decisions pertaining to whether to perform an extraction versus a surgical exposure or surgical uprighting. If the decision is made to surgically expose the tooth and facilitate eruption, care must be coordinated between the appropriate dental colleagues. The first step is to create and ensure that there is adequate space to accommodate the eruption of the impacted tooth. Surgical exposure should not be performed until adequate space is obtained. For example, if a premolar is to be extracted to establish space for the exposure and eruption of a canine, the orthodontic appliances should be in place before the extraction of the premolar tooth. Although it is likely that orthodontic tooth movement may not be initiated until after the premolar tooth is extracted, the application of orthodontic appliances establishes a commitment by the patient to the planned treatment before the irreversible extraction of the premolar tooth.

### Surgical Exposure

The ideal time to surgically intervene to expose an impacted tooth is when the root of the impacted tooth is almost completely formed and the apex is not yet closed. Exposure of a palatally impacted tooth is frequently accomplished by making a sulcular incision between the palatal tissue and the teeth and reflecting a full-thickness mucoperiosteal flap or via an open technique. The anterior and posterior extent of the mucoperiosteal flap is dependent on the access required. Frequently a prominence or bulge is evident where the impacted tooth's crown lay. The bone overlying this bulge may be thin and easily removed with a curette or periosteal elevator. For thicker bone, a surgical handpiece with bur and copious irrigation or a chisel is used to remove the bone in a controlled manner, with care taken not to damage the tooth. The bone is removed to expose enough of the palatal surface of the tooth's crown to which an orthodontic bracket can be attached to aid in eruption. Depending on the impaction and path of eruption, additional bone may be removed to facilitate eruption. The exposed dental follicle is removed with a curette. Care must be exercised to maintain the integrity of the bone around the crestal margins of the adjacent teeth. Additionally, an impacted tooth may be in close proximity to the roots of the adjacent

teeth and care must be exercised not to damage or devitalize these adjacent roots. The mucoperiosteal flap is repositioned into its original position and the soft tissue overlying the impacted tooth's crown may be excised, exposing the crown and orthodontic bracket. The gold chain attached to the orthodontic bracket is passed through this window of soft tissue and frequently secured to the orthodontic arch wire with silk suture. The palatal mucoperiosteal flap is anatomically aligned and secured with a resorbable suture. The soft tissue window overlying the crown of the impacted tooth can be left open or packed with a periodontal dressing for approximately 4 days. If the tooth is deeply impacted within the palate, no overlying tissue may be excised and the gold chain is brought through the soft tissue at the crestal margin, frequently corresponding with the incision.

When exposing a labially impacted canine, a critical component of the surgery outcome is the maintenance of a cervical margin of attached mucosa on the erupted impacted tooth. Two surgical techniques exist: apical positioned flap technique and closed technique. The apical positioned flap technique consists of a horizontal crestal incision that is made in the edentulous region with two vertical releasing incisions on the mesial and distal aspects of this edentulous region. The flap is reflected and the tooth is exposed, removing the bone as necessary to the cervical margin. The bracket is attached and the flap is repositioned apical to the bracket ideally at the level of the cervical margin of the tooth. The premise of the apical positioned flap is to maintain a collar of attached gingiva that will advance coronally as the tooth erupts (Fig. 29.13). The closed technique consists of a crestal-sulcular incision with or without a vertical release that allows the development of a full-thickness mucoperiosteal flap. The tooth is exposed, removing the necessary bone, and a bracket is attached. The gold chain attached to the bracket is attached to the orthodontic arch bar generally with silk suture, and the flap is closed with resorbable suture. The gold chain generally exits the wound through the crestal incision. The closed technique can be used for all labially impacted canines; however, it is indicated for high impactions or midalveolar impactions when the apical positioned flap is contraindicated. There may also be a disadvantage with the apical positioned flap technique in that it can contribute to increased crown length and intrusive relapse.<sup>16</sup> These basic principles are used for the surgical exposure of most impacted teeth.

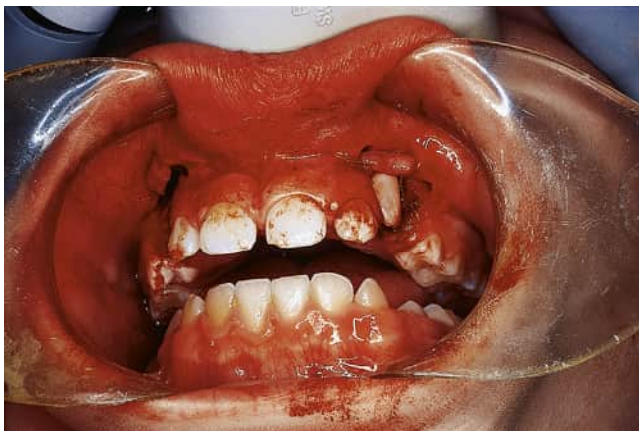

Fig. 29.13 Apically positioned flap.

Autotransplantation is an alternative to positioning the impacted tooth into occlusion when surgical exposure and orthodontic-assisted eruption of a canine tooth is not a viable option. This technique should only be used in the pediatric patient as an alternative to an extraction and not as a routine alternative to surgical exposure and orthodontic-assisted eruption. The autotransplantation technique has also been used when a nonrestorable first molar is extracted and a third molar is transplanted into the first molar site. The technique entails first creating a recipient site that can accommodate the transplantation and then atraumatically extracting the impacted tooth. Damage to the periodontal ligament of the extracted impacted tooth must be avoided. Optimal results mandate that the transplanted tooth be inserted into the recipient site within minutes. The tooth once positioned into the recipient site is stabilized with a segmental orthodontic arch wire. Future endodontic treatment may be indicated.<sup>17</sup> The success rate for a transplanted tooth is reported to be successful.<sup>18,19</sup>

Surgical uprighting is a technique that has most commonly been used for bringing an impacted mandibular second molar into occlusion (Fig. 29.14). The optimal time for performing the procedure is when the root is two-thirds formed and the apex is open. The tooth should have a mesial inclination not to exceed 90 degrees and should be neither labially or lingually inclined for optimal results.<sup>20</sup> Excessive mesial inclination has an increased risk for devascularizing the tooth. In this situation, the surgical procedure would be more consistent with an autotransplantation than with a surgical uprighting. Excessive labial or lingual inclination is associated with diminished crestal bone on the respective surface, compromising initial stability and ultimate bone height on that respective surface of the tooth.

The surgical technique entails making a sulcular incision that extends from the mesial of the first molar to the distal buccal of the second molar. The incision is then extended distally along the alveolar crest, angling into the buccal sulcus along the external oblique ridge. A full-thickness mucoperiosteal flap is reflected. Adequate space must be created distal to the impacted second molar tooth. Prophylactic

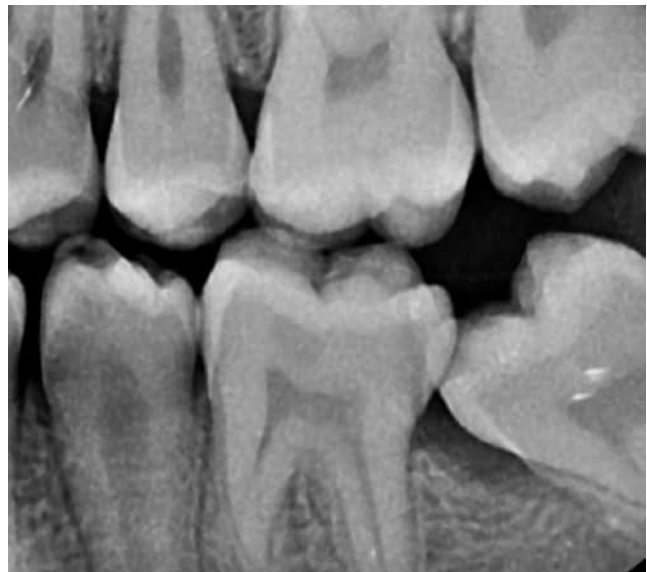

Fig. 29.14 Mesially impacted mandibular second molar.

removal of the third molar is commonly performed. Using a surgical drill with a bur, it may be necessary to remove the bone on the distal aspect of the second molar to the level of its greatest concavity. This ensures that there is adequate space for the impacted second molar to be moved into. An elevator is then used to elevate and reposition the tooth. The repositioned tooth should be slightly out of occlusion. Most frequently, the surgically uprighted tooth is stable in its new position and requires no additional stabilization. If the tooth is mobile, it should be splinted with an orthodontic arch wire for approximately 2 weeks. The mucoperiosteal flap is approximated into position, taking into consideration the newly uprighted tooth, and sutured. Antibiotics are generally prescribed for the first week. Prophylactic endodontic therapy generally is not required.

### Extraction of Impacted Teeth Other Than Third Molars

The extraction of impacted teeth other than third molars entails many of the techniques described pertaining to the exposure of the impacted tooth. However, a few critical points may differ. The supernumerary impacted tooth or the unerupted succedaneous tooth that is scheduled to be extracted may be deeply impacted. Complications associated with extraction may include injury to adjacent tooth roots or vital structures, such as the inferior alveolar nerve. Localization of the deeply impacted tooth may be achieved with cone beam computed tomography (CBCT). CBCT may provide a better image, demonstrating the exact location of the tooth and its proximity to adjacent roots and vital structure. The CBCT imaging may also be beneficial for localizing teeth that will be exposed. The mesiodens is an example of a supernumerary tooth often times in need of extraction. Treatment recommendations for the removal of a mesiodens include if the eruption of the adjacent teeth has been delayed or inhibited and the eruption pattern is altered, displacement occurs of the adjacent teeth, associated pathology exists, needed for orthodontic treatment, or if they spontaneously erupt into the arch. If these teeth are left untreated, delayed eruption, cyst formation, rotations and diastemas, caries and periodontal disease, and root resorption and crowding may occur.<sup>21</sup>

To remove an impacted non-third molar tooth, a full-thickness mucoperiosteal envelope flap is created with or without a vertical release. If a vertical release is used to facilitate access, the vertical releasing incision should be made away from the planned extraction. Usually, the crown of the tooth is exposed. When extracting the impacted tooth, the objective is to minimize the amount of bone removal. To facilitate extraction of the tooth with minimal bone removal, the tooth may be sectioned such that the crown and root are removed separately.

## Associated Hard Tissue Lesions

### PEDIATRIC ODONTOGENIC TUMORS

The World Health Organization (WHO) classifies these odontogenic tumors as benign or malignant. Histopathologically, they are classified as epithelial, mesenchymal, or mixed. Odontogenic tumors account for one-third of all

pediatric tumors in the maxillofacial region, most common being odontomas and the ameloblastoma.

Odontomas are the most frequently occurring odontogenic tumors in pediatric patients (Fig. 29.15). They are frequently discovered when the patient presents for evaluation of an unerupted tooth or incidentally during routine radiographic examination. There are two types of odontomas: compound and complex. A compound odontoma represents multiple tooth like structures. A complex odontoma has irregularly shaped masses of enamel with no anatomic resemblance to a tooth. Treatment for an odontoma involves simple enucleation and curettage.

Establishing a diagnosis is key prior to discussing treatment with a family. Aspiration is first performed to rule out a vascular etiology. An excisional or incisional biopsy is performed. Oftentimes, as in the odontoma, the excisional biopsy via enucleation is the definitive treatment. Although even in pediatric patients, an incisional biopsy may be indicated based on the size and suspicion of the lesion. Enucleation is usually conducted intraorally. A mucoperiosteal flap of sufficient size is elevated to expose the tumor. If required, the overlying bone is removed using a round or tapered fissure bur. The odontoma is well encapsulated and can be curetted from the surrounding bone. The specimen is sent for biopsy. The surgical site is irrigated with normal saline and the wound is reapproximated using resorbable sutures.

### PEDIATRIC ODONTOGENIC CYSTS

These odontogenic cysts demonstrate three main characteristics per the WHO: presence of an epithelial lining, centrally located lumen, and a surrounding connective tissue wall. They are subclassified as inflammatory or developmental. Pediatric odontogenic cysts are predominantly radicular (periapical) cysts, eruption cysts, dentigerous cysts, and odontogenic keratocysts. The dentigerous cyst is the most common odontogenic cyst in the pediatric population. It is

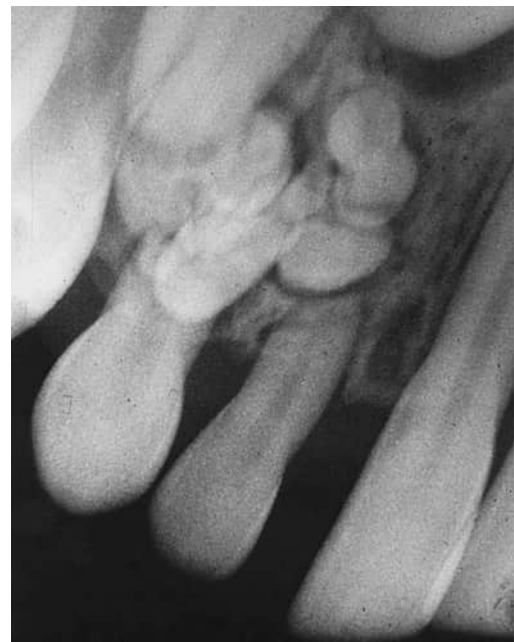

Fig. 29.15 Odontoma.



usually associated with an unerupted permanent tooth or a supernumerary tooth. A biopsy is preferable prior to definitive surgery. However, if a general anesthetic is required to manage the pediatric patient for a lesion in which the dentist is most confident about the diagnosis, it is usually preferable to perform the definitive procedure and obtain histological evaluation on this specimen with the intent that only one general anesthetic will be necessary. Aspiration is always advised before biopsy to rule out a vascular lesion.

The initial step in managing a suspected cystic lesion is to aspirate the wound. Aspiration of the cystic cavity assists the dentist with differential diagnosis and allows the dentist to rule out a vascular entity. In the example of the dentigerous cyst, complete enucleation of the cyst and its epithelial lining is recommended. If an impacted third molar is involved with the cyst, removal of the tooth is indicated. Otherwise, an effort should be made to save the involved permanent tooth to help preserve the integrity of the dental arch. Although a dentigerous cyst is a benign cyst lined by squamous epithelium, this epithelium has a potential to undergo neoplastic change (e.g., ameloblastoma). Postoperative observation should continue until the permanent tooth has erupted and complete healing has occurred.

An eruption cyst is a cyst like lesion caused by eruption trauma of either primary or permanent teeth. Usually seen in erupting molar areas, it usually resolves spontaneously when the involved tooth penetrates the gingival tissue.

## Soft Tissue Procedures

The pediatric dentist is frequently involved in the management of several minor intraoral soft tissue lesions. This section discusses commonly seen soft tissue pathologic conditions: mucocele, ranula, fibroma, and pyogenic granuloma. Lingual and labial frenectomies are discussed in [Chapters 7 and 20](#), respectively.

### MUCOCELES AND RANULAS

A mucocele or mucous retention cyst is a benign pathologic lesion. The lesion is a result of the extravasation of saliva from an injured minor salivary gland. The collection of extravasated fluid develops a fibrous wall around itself forming a pseudocyst. The lesion can fluctuate in size depending on its fluid-filled state. A decrease in the lesion size is frequently associated with a history of drainage of a thick viscous fluid. The lesion is nonpainful, soft, doughy, and fluctuant to palpation. Clinically, the overlying mucosa may have the same coloration as the lower lip or have a bluish hue. Lesions of longer duration may appear firmer and fibrotic and may be difficult to distinguish from a fibroma. A mucocele most likely results secondary to a traumatic event that in most situations goes unrecognized. The lower lip is the most common location.

The basic premise in excising a mucocele is to remove the fibrous capsule and any associated minor salivary glands. For a lesion within the lip, the lip is frequently everted and stretched. This stabilizes the lesion. A Kazanjian retractor can be used to isolate and stabilize the lesion. An elliptical incision (staying within the confines of the lesion) is made in the lip perpendicular to the fibers of the orbicularis oris muscle. Using a combination of sharp and blunt dissection, the

fibrous capsule of the lesion is separated from the surrounding tissue. If done properly, the mucocele can be removed intact. All minor salivary glands surrounding the lesion and within the surgical field should be removed. Removal of the surrounding minor salivary glands minimizes the potential for recurrence. Hemostasis is controlled and closure is accomplished with a 4-0 resorbable suture. The lip is a prominent area and it may be challenging for the smaller child to not disturb the wound during healing. The suture knots should be buried, and an extra suture to ensure integrity of the closure may prevent the wound from dehiscing ([Fig. 29.16](#)).

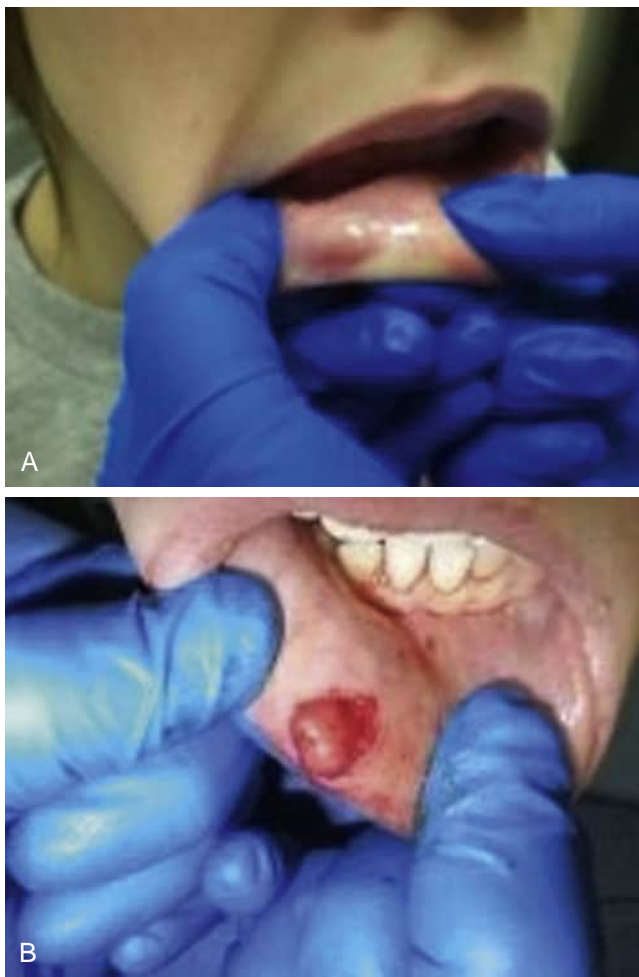A ranula is a mucous retention cyst that occurs in the floor of the mouth and is associated with the sublingual gland. A ranula in a young pediatric patient needs to be differentiated from a lymphatic malformation. A ranula may be managed by marsupialization or excision of the sublingual gland. Many surgeons initially manage a ranula with excision of the sublingual gland as their primary surgical intervention. The first step before performing either of the two procedures is to identify and cannulate the ipsilateral submandibular duct. The mucosa overlying the lesion is then excised. When performing a marsupialization, the lining of the pseudocyst cavity is then sutured to the overlying mucosa of the floor of mouth. A Penrose drain may be sutured in place to maintain the definitive communication between the pseudocyst and the oral cavity. If the intent is to excise the sublingual gland, once the overlying mucosa is excised, blunt dissection is used to identify and isolate the sublingual gland. Extraoral pressure elevating the floor of mouth can facilitate this process. Anterior traction of the gland may also facilitate dissection. The lingual nerve and submandibular duct, which are in close proximity to the deep surface of the sublingual gland, should be identified before definitive excision to minimize iatrogenic injury. The wound is loosely closed. (insert a mucocele if you can get one).

### FIBROMAS AND PYOGENIC GRANULOMAS

The pediatric patient may present with other soft tissue lesions. Common lesions found in the pediatric patient include both the fibroma and the pyogenic granuloma. Oral pathology is discussed elsewhere in this text. If the lesion is small, it may be excised completely and the specimen submitted for histological evaluation. This can usually be accomplished by making an elliptical incision within normal tissue around the lesion. The depth of the dissection is determined by the appearance and feel of the lesion. Minor modifications to this basic technique are dependent on the differential diagnosis. For example, removal of interproximal tissue and scaling of teeth may be indicated when excising a pyogenic granuloma to ensure complete removal and to minimize recurrence.

## Infection of the Head and Neck Region

This section focuses on infections of odontogenic etiology. However, whereas the etiology of head and neck infections may be odontogenic, the etiology may also be secondary to sinus, salivary gland, skin, or middle ear conditions. Defining the etiology is critical to the management of the infection because the infection may persist and potentially worsen if the cause is not removed and the appropriate antibiotic is



**Fig. 29.16** Mucocele and stages of surgical excision. (A) An elliptical incision made with a combination of blunt and sharp dissection. (B) The mucocele sac is separated from the surrounding mucosa.

not selected based on the etiology. Infections can progress rapidly in both the pediatric and the adult patient; however, the pediatric patient is especially susceptible to rapidly becoming dehydrated and systemically ill from what may appear to be a relatively minor infection.

This discussion provides a protocol for management of the pediatric patient with a head and neck infection. Similar to cardiopulmonary resuscitation (CPR)/basic life support, which provides an algorithm and a sequence for managing the airway, breathing, and circulation, this section provides a logical sequence for assessing and treating the patient. An experienced individual can assess the situation and perform CPR simultaneously; likewise, the experienced dentist may perform several of these assessments and interventions simultaneously.

The first step in managing the pediatric patient with a head and neck infection is to obtain a history including details about both the patient's present illness and the past medical and surgical history. The history of the present illness must include: (1) onset, (2) rate of progression, (3) history of preceding odontogenic pain, upper respiratory infection, sinus pain, otitis media, (4) airway compromise (dysphagia, dyspnea, change in voice), (5) trismus, and (6) ophthalmic complaints (e.g., photophobia, changes in visual acuity). It may be difficult to elicit a complete history from a younger

patient when neither the patient nor the parent is able to provide a history of preceding odontogenic pain. The dentist must obtain a complete past medical history. In managing a patient with an infection, it is important to identify diseases that compromise the immune system (e.g., diabetes) as well as diseases that compromise the patient's ability to withstand stress (e.g., congenital heart disease). The latter is important because a severe infection can impose a severe physiologic stress on the patient, and the patient's ability to respond to the infection may be dependent on his or her systemic reserve.

The second step in managing the pediatric patient with a head and neck infection is to examine the patient. The clinical examination includes visual inspection identifying the (1) patient's respiratory compromise, distress, or lack of distress, (2) involved swelling and the severity of the swelling, (3) palpation of the tissues discerning their tenderness and consistency (cellulitic or fluctuant), (4) assessment of maximal mouth opening, and (5) examination of the dentition. The radiographic examination may consist of a periapical or panoramic radiograph, which can be obtained in the office to evaluate if the source is likely odontogenic. The panoramic radiograph is a good screening radiograph. A periapical radiograph may provide more discerning information; however, this may be difficult to obtain if the child's head and neck is swollen. Moderate to severe fascial space infections require a CT scan with contrast taken in a hospital setting to delineate the full involvement of the infection. A differential diagnosis is developed from the history and examination.

The dentist must be knowledgeable with the anatomic spaces of the head and neck and the routes in which the infection can spread. The routes of dissemination of an infection are dependent on the position of the roots of the teeth relative to anatomic considerations such as the muscles, maxillary sinus, and root angulation relative to their respective jaws. For example, a vestibular space infection is the result of an infection dissecting through the lateral maxillary or mandibular bone and perforating the buccal bone inferior (maxilla) or superior (mandible) to the buccinator muscle attachment. The maxillary teeth can result in a canine space infection, which can extend and ultimately involve the periorbital tissues. The proximity of the maxillary teeth to the maxillary sinus can produce a maxillary sinusitis. Posterior spread of a maxillary infection can involve the infratemporal space and have direct spread into the orbital tissues through the inferior orbital fissure. Mandibular molar infections can spread above or below the mylohyoid muscle resulting in a sublingual space or submandibular space infection, respectively. An infection of the sublingual space displaces the tongue superiorly and posteriorly. Posteriorly, a mandibular infection may spread either lateral to the ramus or medial to the ramus, resulting in either a submasseteric space or a pterygomandibular and/or lateral pharyngeal space infection, respectively. The submasseteric space, the pterygomandibular space, and the infratemporal space make up the masticator space. Infections of the masticator space result in trismus. Infections of the sublingual, submandibular, submental, and masticator space can compromise airway integrity. Although rare, infections of the head and neck may have hematogenous spread via the valveless veins of the face and cause central neurologic infections.

The third step in managing the pediatric patient with a head and neck infection is to develop a plan of intervention. The first step in this interventional plan entails an assessment of the airway. Because airway assessment is so critical, it is a step unto itself. Urgent airway intervention may be indicated based on the involved fascial spaces, their severity, the patient's signs and symptoms, and the progression of the infection. Managing a patient with a compromised airway requires a team approach between the surgeon (capable of performing a tracheostomy, if necessary) and the anesthesiologist. This is a challenging situation in the adult patient wherein inducing a sedative state or general anesthetic may worsen an already compromised airway. In situations where the airway is compromised, the adult patient may be fiberoptically intubated with minimal sedation. The fearful pediatric patient lacks the ability to cooperate, necessitating a more profound depth of sedation, which potentially makes airway management a more challenging and dangerous situation.

Once the airway is assessed and controlled, the practitioner must continue with the interventional plan development. The components of intervention include: (1) determining whether the infection should be treated in an outpatient or inpatient setting, (2) establishing the appropriate antibiotics to use, and (3) undertaking surgery (incision and drainage and removal of the etiology). Indications for admitting a pediatric patient to the hospital include fever (temperature  $\geq 101.5^{\circ}\text{F}$ ), lymphadenopathy, elevated white blood cell count, poor oral intake, dehydration, involved fascial spaces, associated findings (e.g., dysphagia), and the appearance of being ill (i.e., looking sick). The latter item should not be disregarded; this is one situation in which the general appearance of the patient provides significant guidance.

Odontogenic infections are polymicrobial. There is a significant increase in resistance to antibiotics that has developed over the past couple of decades, especially to beta lactamase-producing organisms. The antibiotic for a less severe odontogenic infection that is to be managed in an outpatient setting is penicillin VK (25–50 mg/kg per day in divided doses every 6–8 hours) or clindamycin (10–20 mg/kg per day in divided doses every 6 hours).<sup>22</sup> Because of the increase in beta lactamase-producing organisms, the first-line antibiotics for infections requiring hospitalization are intravenous ampicillin-sulbactam (Unasyn) or intravenous clindamycin. Hospitalization facilitates supportive care, such as providing hydration, nutritional support, and fever management.

Surgery includes incision and drainage and removal of the source of infection (which may involve pulpectomy or extraction). In our opinion, if hospitalization is required, the offending tooth should be extracted. The following are basic principles for performing an incision and drainage. If the patient is not going to have a general anesthetic, the site must be anesthetized with local anesthesia. Regional block anesthesia without infiltrating the infective site is recommended. A Gram stain and culture and sensitivity (C&S) test is indicated for all fascial space infections (this does not include a vestibular space infection), immunocompromised patients, or infections that have failed multiple courses of antibiotic treatment. Ideally, an aspirate for a Gram stain and C&S is obtained before making the incision

and drainage. Before incising the infection, a needle on a syringe is inserted into the wound and its contents aspirated. The aspirate is submitted for Gram stain and C&S. When draining a vestibular space infection, an incision is made frequently centered within the swelling. The incision is carried through the mucosa down and through the periosteum. There must be knowledge of the anatomy to avoid vital structures, such as the mental nerve and facial artery. A small hemostat (mosquito) is inserted with the beaks closed. Blunt dissection is performed with the beaks closed. The beaks are opened and withdrawn. The hemostat beaks are never blindly closed when the instrument is in the wound to prevent injury to vital structures. A Penrose drain may be placed into the incision and drainage site and secured with a nonresorbable suture for a few days. The drain keeps the wound open and patent, facilitating irrigation (if necessary) and spontaneous drainage of the wound and preventing a recurrent collection from developing. Refer to a surgical text for more detailed information pertaining to draining fascial spaces.<sup>22</sup>

## FRACTURE OF THE MANDIBLE

The pediatric dentist may encounter pediatric patients who have suffered a traumatic event and injured the soft and/or hard tissue of the face. These injuries can include soft tissue lacerations, dentoalveolar injuries, and facial fractures of the maxilla, mandible, nose, and cheek. Probably the most common injury that the pediatric dentist sees is the dentoalveolar injury, which includes displacement and avulsion of teeth, crown and tooth fractures, and alveolar fractures. Diagnosis and assessment of these injuries is discussed elsewhere.<sup>23</sup> The mandibular fracture is the most common skeletal injury that occurs in the pediatric age group that is seen within the hospital. However, the patient with a mandibular fracture may initially present to the pediatric dentist who must be able to recognize the injury and make the appropriate referral.

When assessing a patient who presents with a facial injury, the treating doctor must recognize that the patient can have associated injuries. A history of the events contributing to the event and a comprehensive physical evaluation are important and must be completed. The treating doctor must also be cognizant that the force required to cause a facial fracture is directed to the head and neck and could result in neurologic or cervical injury. Understanding the mechanism of injury may present some insight. The doctor should inquire as to loss of consciousness or symptoms suggestive of neurologic injury (e.g., dizziness, lightheadedness, amnesia of the event, nausea, and vomiting). In the awake adult individual, cervical trauma is assessed frequently by clinical examination and the patient's ability to relate whether or not neck pain is present. In the younger patient who cannot reliably relate whether or not neck pain is present, radiographic assessment may be indicated. The pediatric dentist must be cognizant that the pediatric patient may sustain cervical injuries as well as other injuries secondary to the mechanism of injury and manage the patient to minimize those potential adverse consequences. For example, if there is any question that the patient has sustained a cervical injury, cervical spine stabilization should be utilized and EMS contacted for transportation to the emergency department.



The first step in assessing the patient who presents with a facial injury is to obtain a comprehensive history. The younger patient may be less able to provide reliable answers. These questions include:

1. "Where does it hurt?" "What makes it hurt?"
2. "Can you open your mouth?" (Does the patient have any limitation of jaw movement? Is the bite different?)
3. "Do you have any loose teeth?"
4. "Do your lips feel different?" "Are your lips numb?"

The answer to these questions may reveal the patient's diagnosis. A patient may complain of pain in the TMJ. This is suggestive of a hemarthrosis or a fracture of the condyle. On clinical examination, the patient may have a chin abrasion or laceration. The force of a blunt trauma to the region of the chin that results in an abrasion or laceration may be transmitted to the condylar region. Thus a chin abrasion or laceration in a patient complaining of pain in the TMJ may support the suspicion of an injury to the joint. Alternatively, a patient who presents with a chin abrasion or laceration secondary to blunt force should be assessed for pain in the joint that may be suggestive of a condylar fracture.

Bony or muscular injury can result in limited mobility of the jaw because of pain, bony mechanical obstruction, joint or soft tissue swelling, or muscular inflammation or irritability. A unilateral condylar injury may result in deviation to the ipsilateral side with opening in the occlusion secondary to the action of the contralateral lateral pterygoid muscle.

Fractures of the mandible can result in a malocclusion. Unilateral condylar fractures usually result in an ipsilateral premature bite. Bilateral condylar fractures may result in bilateral shortened rami with a resultant anterior open bite and mandibular retrognathia. A hemarthrosis of the condyle may result in an ipsilateral posterior open bite secondary to the joint swelling and inferior displacement of the rami. Because of the elasticity of the pediatric mandible, a fracture may not always result in displacement and a resultant malocclusion. The practitioner must be diligent and assess for tenderness of the region which may be an indication of an injury. Hemorrhage into the tissue associated with the fracture may result in localized ecchymosis in the buccal or lingual vestibule. A fracture may result in gingival tearing. The findings may be more subtle with slight evidence of sulcular blood along the teeth adjacent to the fracture. Teeth adjacent to the fracture may be loose. This must be distinguished from an avulsive-type injury, an alveolar fracture, or the normal resorptive pattern present in a mixed dentition. Palpation of the mandible may identify a step along the inferior border. Bimanual palpation may demonstrate segmental mobility or elicit discomfort.

The bony canal of the inferior alveolar nerve traverses the rami and the body of the mandible. A fracture of the mandible may result in hemorrhage into the canal with a resultant compressive-type injury, or the nerve may sustain a contusion, a stretching-type lesion, or a partial or complete transection. Paresthesia occurs as a result of the nerve injury. In most situations in which the fracture segments are not grossly displaced, the paresthesia is transient and recovery occurs over the next several weeks to months. Pediatric patients are less able to report various symptoms and may not be able to express that they are paresthetic.

Radiographic examination of the mandible in the office usually includes a panoramic radiograph. This image is useful and reliable in visualizing the entire mandible, including the condyles, rami, angle, body, and symphysis. Radiographic assessment ideally should occur in two planes. A condylar/subcondylar fracture may not always be recognized on a panoramic radiograph. Additionally, the panoramic radiograph does not demonstrate the lateral/medial displacement of the fracture segments in the coronal plane as demonstrated on a Towne's view. A fracture that is not clearly visualized on the panoramic radiograph may be identified on the Towne's view. The symphysis may be outside the ideal trough of the panoramic radiograph and a nondisplaced or greenstick fracture may not be clearly seen on a panoramic image. A mandibular occlusal radiograph at 90 degrees to the mandible should be obtained when a mandibular symphyseal fracture is suspected and is not seen on a Panorex. If a patient has a suspected mandible fracture, they should be evaluated by a surgeon. For the patient who presents to the emergency department, CT without contrast imaging should be performed. The CT scan provides images in the axial, coronal, and sagittal views. Three-dimensional reconstruction is also available and should be requested. It is important to have all of these images available because a fracture may be easily visible and recognized on only one of the views.

The discussion of managing the pediatric patient focuses on the patient with a mixed dentition. Treatment of a mandible fracture includes reduction of the fractured segments, re-establishment of a stable occlusion, and stabilization of the fractured segments. Fractures in pediatric patients can heal rapidly, and treatment should ideally be initiated within the first days. If for various medical conditions or associated injuries fracture reduction is not initiated within the first few days, the bony segments may begin to heal and reduction may become difficult, if not impossible. One advantage in managing pediatric patients with mixed dentition is that minor malocclusions usually self-correct with growth.

Condylar fractures can be classified as intracapsular or extracapsular. A pediatric patient who has sustained an intracapsular fracture or injury is at increased risk of ankylosis or growth disturbance. Treatment is frequently dictated by the degree of malocclusion and jaw opening/function. If the occlusion is grossly normal, the fracture may be managed with a blenderized diet, analgesics if necessary, and observation. Physiotherapy to ensure symmetric opening may be indicated. If the pediatric patient has a malocclusion or significant pain, a short period of 1–2 weeks of maxillomandibular fixation may be warranted. The risk of rami shortening and an anterior open bite is a concern in a patient who has sustained a bilateral condylar fracture and the practitioner may more readily consider a period of maxillomandibular fixation. Guiding elastics for 1–2 weeks after the release of maxillomandibular fixation may be beneficial to facilitate symmetric opening. Open reduction and fixation, even for a displaced condylar fracture in the pediatric patient, is rarely indicated. Slight malocclusions usually self-correct with growth.

Management of a nondisplaced body or symphysis fracture may also be managed with a blenderized diet and observation. When maxillomandibular fixation is required (for either a nondisplaced or displaced fracture), the patient is frequently placed into fixation for approximately 3 weeks.

An alternative to maxillomandibular fixation for a body or symphysis fracture is to place a lingual splint which is secured to the teeth with either circumdental or circummandibular wires. The advantage of the splint is that it does not require the patient's jaws to be wired closed. This facilitates respiratory care as well as nutritional support in the seriously injured patient. A disadvantage of a lingual splint is that it may require a separate anesthetic to take the impression in order to make the splint. If the patient is having multiple injuries managed during the same operation, the dental surgical team may take the maxillary and mandibular impression at the beginning of the operation, fabricate the splint, and have it ready to be placed before termination of the anesthetic. Angle fractures or fractures posterior to the teeth require maxillomandibular fixation for 3 weeks. Open reduction and internal fixation is an option in managing the pediatric patient, especially in severely displaced or comminuted fractures as seen in high-velocity injuries. Care must be taken to avoid the succedaneous developing teeth.

Maxillomandibular fixation is traditionally achieved by ligating an arch bar to the teeth in each arch with circumdental wires placed around the cervical collars of the teeth. The shape and shortness of the deciduous teeth may make this difficult at times. The arch bar provides hooks (with the opening apically positioned) that can be used to secure wires or elastics to achieve either tight maxillomandibular fixation with absolute lack of movement or place elastics that allow limited function and guide the patient's opening and occlusion. If the patient's dentition does not facilitate circumdental wiring, the practitioner may opt to use skeletal wiring either alone or in combination with circumdental wiring. Skeletal fixation consists of circummandibular wires, piriform wires, and zygomatic buttress wires. A circummandibular wire is placed around the mandible. The wire is inserted extraorally using a Keith needle or an awl. The inferior border of the mandible is palpated and the first end of the wire is passed along the lingual aspect of the mandible and enters the mouth in the lingual vestibule adjacent to the mandible. Care must be taken to pass the wire along the lingual surface of the mandible; if the wire is passed too far medially, it may injure various structures such as Warthin's duct. The other end of the wire is passed through the same extraoral puncture site in the skin inferior to the border of the mandible. This end of the wire is passed buccally and enters the mouth in the depth of the vestibule just adjacent to the buccal surface of the mandible. Each wire end is grabbed individually and the wire is sawed back and forth until the inferior aspect of the looped wire passes through the soft tissue and lies firmly against the inferior aspect of the mandible. The pediatric mandibular cortex is thin and aggressive sawing action can result in pulling the wire through the mandible, resulting in a new fracture. Piriform and buttress wires are achieved by making an incision over the respective site and creating a hole to pass a wire through with a bur. The practitioner must be cognizant where the developing tooth buds are.

This discussion focuses on management of the mandible fracture in the pediatric patient with mixed dentition.

Patients with permanent dentition have less capacity for the bone to adapt and remodel.

## Summary

This chapter outlines basic principles used in the management of basic oral and maxillofacial surgical procedures. Many of the principles discussed can be used in various aspects of dental practice.

## References

1. Litman RS, Kottra JA, Berkowitz RJ, et al.: Breathing patterns and levels of consciousness in children during administration of nitrous oxide after oral midazolam premedication, *J Oral Maxillofac Surg* 55(12):1372–1377, 1995.
2. Litman RS: Airway obstruction after oral midazolam, *Anesthesiology* 85(5):1217–1218, 1996.
3. Done V, Kotha R, Vasa AA, et al.: A comparison of the effectiveness of oral midazolam-N2O versus oral ketamine-N2O in pediatric patients—an in-vivo study, *J Clin Diagn Res* 10(4):ZC45–ZC48, 2016.
4. Kademani D, Tiwana P: *Atlas of oral and maxillofacial surgery*, ed 1, Philadelphia, 2015, Saunders, Elsevier.
5. AAOMS: *Management of third molar teeth*, 2016.
6. AAOMS: *White paper on third molar data*, 2007.
7. Ash MM, Costich ER, Hayward JR: A study of periodontal hazards of third molars, *J Periodont* 33(3):209–219, 1962.
8. Harradine NW, Pearson MH, Toth B: The effect of the extraction of third molars on later lower incisor crowding: a randomized controlled trial, *Br J Orthod* 25(2):117–122, 1998.
9. Zawawi KH, Melis M: The role of mandibular third molars on lower anterior teeth crowding and relapse after orthodontic treatment: a systematic review, *Sci World J* 615429, 2014.
10. Kugelberg CF, Ahlström U, Ericson S, et al.: Periodontal healing after impacted lower third molar surgery in adolescents and adults. A prospective study, *Int J Oral Maxillofac Surg* 20(1):18–24, 1991.
11. Chiapasco M, Crescentini M, Romanoni G: Germectomy or delayed removal of mandibular third molars: the relationship between age and incidence of complications, *J Oral Maxillofac Surg* 53(4):418–422, 1995.
12. Phillips C, White Jr RP, Shugars DA, et al.: Risk factors associated with prolonged recovery and delayed healing after third molar surgery, *J Oral Maxillofac Surg* 61(12):1436–1448, 2003.
13. Bishara SE, Ortho D: Impacted maxillary canines: a review, *Am J Orthod Dentofacial Orthop* 101(2):159–171, 1992.
14. Jacoby H: The etiology of maxillary canine impaction, *Am J Orthod* 84(2):125–132, 1983.
15. Kaban LB, Troulis MJ: Dentoalveolar surgery. In Kaban LB, Troulis MJ, editors: *Pediatric oral and maxillofacial surgery*, Philadelphia, 2004, WB Saunders, p 131.
16. Kokich VG: Surgical and orthodontic management of impacted maxillary canines, *Am J Orthod Dentofacial Orthop* 126(3):278–283, 2004.
17. Sagne S, Thilander B: Transalveolar transplantation of maxillary canines. A follow up study, *Eur J Orthod* 12(2):140–147, 1990.
18. Pogrel MA: Evaluation of over 400 autogenous tooth transplants, *J Oral Maxillofac Surg* 45(3):205–211, 1987.
19. van Westerveld KJ, Verweij JP, Toxopeus EE, et al.: Long-term outcomes 1–20 years after autotransplantation of teeth: clinical and radiographic evaluation of 66 premolars and 8 molars, *Br J Oral Maxillofac Surg* 57(7):666–671, 2019.
20. Pogrel MA: The surgical uprighting of mandibular second molars, *Am J Orthod Dentofacial Orthop* 108(2):180–183, 1995.
21. Bereket C, Çakır-Özkan N, Şener İ, et al.: Analyses of 1100 supernumerary teeth in a nonsyndromic Turkish population: a retrospective multicenter study, *Niger J Clin Pract* 18(6):731–738, 2015.
22. Topazian RG, Goldberg MH, Hupp JR: *Oral and maxillofacial infections*, ed 4, Philadelphia, 2002, WB Saunders.
23. Fonseca RJ, VW W, Bett NJ, Barber HD: *Oral and maxillofacial trauma*, ed 2, Philadelphia, 1997, WB Saunders.

## 30

# Pediatric Oral Health and Dental Care: From Demography to Advocacy

BURTON L. EDELSTEIN and HANNAH L. MAXEY

## CHAPTER OUTLINE

**Children in the United States**  
**Pediatric Oral Disease Characteristics**  
**Pediatric Dental Care**  
 Pediatric Dental Workforce  
 Pediatric Dental Delivery Systems

Pediatric Dental Financing, Payment, and Coverage  
 Pediatric Dental Utilization  
**Advocacy Action in Support of Pediatric Oral Health**  
**Advocacy Case Study**

According to the World Health Organization, “health is a state of complete physical, mental and social well-being and not merely the absence of disease or infirmity.” Oral health, then, is the state of complete well-being of the mouth that supports an individual’s multiple oral functions, appearance, and self-confidence. Like health in general, oral health is acquired and maintained primarily by quotidian salutary behaviors that are facilitated or inhibited by social, environmental, and genetic determinants of health as well as health care. For oral health specifically, dental care contributes to oral health by promoting oral health literacy, encouraging healthful behaviors, delivering preventive stratagems, and, when necessary, repairing damage from disease or injury. It is most important for the dental professional to recognize how limited is the role of dental care in oral health, at least compared to individuals’ day-to-day oral hygiene and dietary practices. It is estimated that no more than 10%–15% of health attainment and maintenance can be attributed to health care (including dental care).

Over recent decades there has been increasing recognition within the US health system that oral health is critical to the overall health of patients and populations. Although this may seem intuitive when we consider our own health or that of our patients, the structure of the health system does not reflect this truth. As the health system developed, oral health care was carved out from medical care academically, administratively, and clinically. This fostered a culture which values oral health as separate from overall health and often conflates oral health with dental aesthetics. We are now in an era where many organizations are working to overcome this historical separation through public health, policy, and advocacy efforts.

This chapter describes the US child and adolescent population and then considers dental caries from a public health perspective as the predominant oral health problem for US children and youth. The chapter next explores access to dental care by examining its three critical components—dental workforce, dental delivery sites and organizations, and sources of payment for care—before addressing factors that influence the utilization of dental care by US families

when care is available and accessible. The chapter concludes with a call to advocacy action that details how dentists who treat children can actively engage in promoting all children’s oral health and equitable dental care.

## Children in the United States

Understanding the characteristics of children as a subpopulation is helpful to contextualize public health, policy, and advocacy discussions. Children represent about a quarter of the overall population in the United States and are disproportionately high consumers of dental care. While the total number of children and adolescents has increased since the 1960s to approximately 72 million, the percentage of the total US population that they comprise has decreased from its peak at 36% in the 1960s to 23% in 2017 as a result of declining birth rates and growing numbers of longer-living “baby boomers.” As a rough rule of thumb, there are about 4–4.5 million births per year in the United States.

Over time, the US child and adolescent subpopulation has become more and more racially and ethnically diverse. [Fig. 30.1](#) provides an excellent graphic of this increasing racial/ethnic diversity from 1980 to 2017. Meanwhile, the proportion of children and adolescents who are themselves immigrants (“first generation”) or are the children of immigrants (“second generation”) has also increased significantly. The immigrant pediatric population increased by 51% between 1994 and 2017; by 2017, one-quarter of all US children were either first- or second-generation immigrants.<sup>2</sup> Despite the growing numbers of minority and immigrant children, the proportion of those under age 18 who are poor has steadily declined from 38% in 1980 to 31% in 2017.<sup>3</sup>

The terminology around race and ethnicity has been evolving. In the 2010 Census, the “Some Other Race” group was the third largest category after “Black” and “White,” and the fastest growing “race” category across US Censuses is “some other race.” This suggests that people are finding it increasingly difficult to categorize themselves as the numbers of ethno-racially mixed families increase.



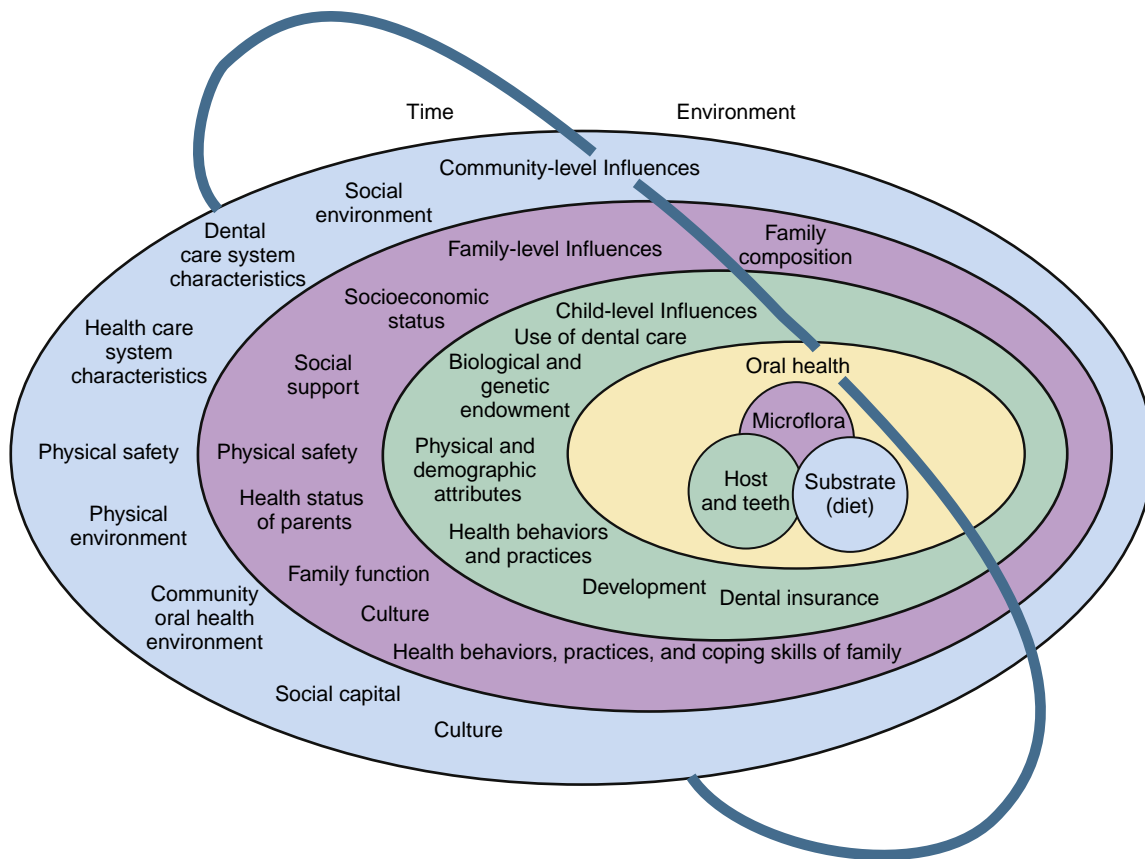


Fig. 30.1 Pediatric caries experience reflects social, environmental, genetic, and healthcare determinants at the child, family, and community levels.

Child and adolescent diversity and economic status are important to oral health and dental care because they are strongly correlated with each other<sup>4</sup> and with children's health,<sup>5</sup> including oral health.

An in-depth examination of the complex relationship between race, ethnicity, and income is beyond the scope of this chapter. However, from a dental epidemiologic perspective, it is important to note that a greater proportion of minority children reside in lower-income communities, have parents with less education, and are covered under government-sponsored insurance programs: Medicaid and the Children's Health Insurance Program (CHIP). To achieve oral health for all children, it will be essential to elevate the status of minority children especially as the face and voice of US children are rapidly changing. As the country moves toward a "majority minority," driven by high minority birth rates and immigration, oral health disparities can be expected to increase. Reflecting this population shift and the impact of immigration, the proportion of children living in a non-English language household is increasing. As of 2016, one-third of US children lived in non-English-speaking households, with Spanish being the most prevalent.<sup>6</sup>

Pediatric oral health also tracks closely with income levels and children's experience of adverse family events. There are profound income disparities among US families by race and ethnicity with

white middle- and low-income families in 2016 having four times the wealth of black families and three times the wealth of Hispanic families.<sup>7</sup> The occurrence of adverse childhood experiences (ACEs) also correlate with income and with health outcomes, including oral health.<sup>8</sup> With each additional ACE—specifically family financial hardship, divorce, death, incarceration, mental illness, domestic or neighborhood violence, drugs/alcohol, or discrimination—the odds of a child having poor oral health increases.

When combined with families' household size, income is used by the federal government to annually establish the federal poverty level (FPL). Families with household size-adjusted incomes under the FPL are considered poor, while those with incomes between the poverty level and twice the poverty level are considered low income or working poor. Families with incomes between twice and four times the FPL are considered middle class, and those with incomes over four times the FPL are considered affluent. The following table shows the income levels for each income strata and the distribution of US children by family income. It illustrates the substantial portion of US children who are poor and working poor at one point in time. Because families' incomes vary over time, particularly among seasonal workers, an even larger proportion of US children (more than half) are enrolled in Medicaid or CHIP at some time during any 12-month period.

Income Strata	FPL (%)	Household Income for a Family of 4 in 2019 (in US\$)	US Children by Income Strata (%) <sup>9</sup>
Poor	<100	0–25,570	19
Low income	100–200	25,571–51,500	22
Middle class	200–400	51,501–103,000	30
Affluent	>400	103,001 and above	19

Overall, the economic status of US children has improved somewhat in recent decades although the country's youngest children are the poorest. Fewer children live in poverty today that 10 years ago, but income inequality is growing. This has direct implications for the distribution of resources across the population that contribute to perpetuating disparities. Like distribution to quality foods, the distribution of health care facilities, including dental practices, is directly correlated to community income. It is common for dental practices to be clustered in higher-income communities, whereas low-income urban and rural communities are commonly recognized as areas with dental health profession shortage.<sup>10</sup> In addition to better geographic access to dental care, people residing in higher-income communities are also more likely to have private employer-sponsored health insurance and expendable income to purchase dental care, whereas those residing in low-income communities are more likely to have public insurance or be uninsured and have constrained expendable income. Therefore, the value proposition for private dental practices under the current delivery and payment arrangements is not sufficient to promote equitable distribution of dental care resources.

Income and social status “get under the skin” to influence health outcomes through a variety of mechanisms. Low-income level is associated with lack of access to healthy foods, health care, educational attainment, and many other social and environmental factors that impact health. For example, residents of low-income communities (those with a significant portion of poor and working poor residents) often lack full-service grocery stores and have very limited sources of fresh fruits and vegetables. In these “food deserts,” families rely on either convenience stores or fast food restaurants with their higher sugar and fat offerings or they must travel to access healthy food options. Their travel is often constrained by lack of financial, time, and logistic resources.

For the clinician and public health practitioner alike, these various demographic descriptors and trends suggest that the pediatric caries burden is likely to increase and that action is needed to promote equitable oral health and dental care.

## Pediatric Oral Disease Characteristics

Evident from the breadth of topics covered in this textbook, children and adolescents experience a wide range of infectious, developmental, heritable, idiopathic, and physiological diseases and conditions. The leading oral condition of US children remains ordinary tooth decay: the damage that results from the caries process. Caries, measured as dental cavities, persists as the single most prevalent chronic disease of children in the United States and globally. Despite being largely preventable before doing dental damage and despite being suppressible after the disease has become established, caries is

too often neither prevented nor suppressed. The majority of US children encounter only mild to moderate caries experience, whereas a significant minority have caries experience that is consequential in dysfunction, disfigurement, distraction, and pain. While caries experience is epidemic, the extent of caries and its more severe consequences are skewed toward socially vulnerable, poor and low-income, minority, and immigrant children, thereby further inhibiting their capacity to maximize their growth and development and economic success.

From the perspectives of public health, public policy, and oral health advocacy, dental caries is, therefore, *the* pediatric oral health condition that demands significant and ongoing attention. When these nonclinical disciplines address diseases of all types, they begin by characterizing the very nature of the disease in question as they search for effective child-, family-, and population-level interventions. These disciplines “go upstream” to root causes of diseases and disparities in their efforts to identify opportunities for disease prevention and control. While these disciplines are often involved in health care services, they are grounded in an appreciation for the full range of health determinants: behavioral, social, environmental, as well as genetic and health care (Fig. 30.1).<sup>10a</sup>

What, then, are the key characteristics of the pediatric caries experience and how do those characteristics shape a public health approach to addressing this disease? Caries is a prevalent, consequential, and disparately distributed chronic disease. It is a microecological biofilm disease that is progressive but reversible, diet dependent, and fluoride mediated.

**Prevalent and consequential:** *More than 45% of children aged 2–19 years have experienced dental cavities (treated or untreated), and more than one in five children aged 5–11 years and more than one in seven children aged 12–19 years have untreated cavities. Untreated decay can lead to pain and infection and cause dysfunctions in eating, speaking, and learning.<sup>11</sup> From a public health perspective, these characteristics suggest that pediatric dental caries is of sufficient importance and impact that it needs to be prioritized for ongoing policy and programmatic action. Being four times more prevalent than pediatric asthma, caries negatively impacts enough children and families to warrant interventions that range from community water fluoridation and public education campaigns to policies that promote components of dental care including workforce, delivery systems, and financing adequacy.*

**Disparately distributed:** *Children living in poverty are more than twice as likely to have untreated decay as children in higher-income families,<sup>11</sup> and children from racial and ethnic minority groups, such as non-Hispanic black children, have the highest rate of untreated dental caries.<sup>12</sup> From a public health perspective, the existence of disparities suggests opportunities to allocate resources more efficiently and effectively by targeting subpopulations with greatest disease experience. Prioritizing socially vulnerable children, including those who are from poor and low-income families, immigrant families, distressed*

families, and children and adolescents dealing with chronic medical and developmental disabilities, facilitates maximizing health return on each dollar spent.

**Chronic and progressive but reversible:** From a public health perspective, these characteristics suggest the need to prioritize early interventions that involve all parties who interact with young children and their families, leverage the most current cariology and behavioral sciences, and develop approaches that empower families to manage caries-associated risks.

**Diet dependent and fluoride mediated:** From a public health perspective, these characteristics suggest that primary and secondary prevention require strategies that provide ready access to healthy foods (e.g., by addressing “food deserts”), community water fluoridation, and oral hygiene supplies including fluoridated toothpastes.

Understanding caries treatment as a chronic disease management challenge rather than as an acute surgical reparative problem requires rethinking all aspects of pediatric dental care. It requires that: (1) pediatric dental care be grounded in caries risk assessment; (2) clinical interventions be tailored to each child’s idiosyncratic level of risk and exposure to risk factors; (3) dental visit frequencies vary by need; (4) the dental team attends to social, behavioral, and environmental health determinants by incorporating liaisons with social workers, health educators, and behavioral nutritionists; and (5) care be organized and financially rewarded with a primary goal of disease prevention and suppression rather than repair alone.

Combining a public health approach with a clinical approach creates opportunities to advance population oral health management in collaboration with evolving health systems such as accountable care organizations and patient-centered medical homes. These emerging health care organizational models address patients holistically while working to achieve specified and measurable health outcomes. These types of organizations (and others yet to be invented) are increasingly supported by alternative payment mechanisms (APMs) that financially reward health outcomes over health services to achieve health equity.

## Pediatric Dental Care

For children to appropriately use dental care services, there must exist sufficient, competent, and available workforce and delivery sites complemented by payment mechanisms that ensure financial access to care. Once these are in place, families decide how to best utilize care to meet their perceived needs and desires. This section details workforce, delivery systems, and payment programs that support the pediatric dental care before considering the range of factors that influence utilization when pediatric dental care is available.

### PEDIATRIC DENTAL WORKFORCE

Dental care delivery requires the availability of a skilled workforce. The US dental workforce largely comprises dentists, dental hygienists, and dental assistants together with support staff. The number of dentists in the United States

has increased steadily over the last several decades (from about 163,000 in 2001 to 200,000 in 2018), as has the dentists to population ratio (from approximately 57 dentists per 100,000 population in 2001 to 70 in 2018). Despite the growth of many dental specialties, including pediatric dentistry, general dentists account for about 80% of dentists. Pediatric dentistry, the second largest dental specialty by 2019 (behind orthodontics), has experienced the largest growth of any dental specialty, almost doubling from 4213 pediatric dental specialists in 2001 to 8033 in 2018. This remarkable growth resulted from expansion of federal financial support for the development and maintenance of pediatric dentistry postdoctoral programs. It also reflected expanded public insurance coverage for children through the CHIP and the Affordable Care Act (ACA) that provided financial access for millions more children.

Dental hygienists are considered among the group of allied health professionals. They are trained at either the Associate or Baccalaureate degree level. The nation’s nearly 200,000 dental hygienists are primarily employed in private dental practice with more than one in six employed by more than one practice. States, through their dental licensure authority, determine the scopes of practice and supervision requirements for dental professionals. These vary more substantially between states for dental hygienists than for dentists. Consequently, dental hygiene ranges from limited to expansive scope and from direct supervision by a licensed dentist to independent practice. Over the last decade, an increasing number of states have responded to calls for increased dental access by adopting less restrictive regulatory schemes for dental hygienists. More expansive dental hygiene practice is correlated with increased access to care for underserved populations in safety net settings.<sup>13</sup> Child advocates have also promoted new delivery models that increase direct access to dental hygiene services, place dental hygienists in medical and community settings,<sup>14,15</sup> and expand hygienists’ practice to include dental reparative procedures in addition to preventive procedures.

Dental therapists, long established as school-based pediatric dental providers in New Zealand and adopted globally, were first introduced in North America by the US Indian Health Service (IHS) in Alaska as “Dental Health Aide Therapists (DHATs).” Almost immediately, the IHS experienced a dramatic shift away from emergency dental services to basic preventive and restorative services and expansion of pediatric dental care where DHATs were engaged.<sup>16</sup> As midlevel providers, dental therapists are trained and licensed to deliver selected restorative dental services which had previously been solely within the scope of dentists. They also provide preventive services to individuals and populations. Dental therapists may be initially trained as therapists or may be dental hygienists who obtain additional training in restorative dentistry. As with dental hygienists, therapists’ scopes of practice and supervision requirements are established independently in each state that sanctions them. Starting with Minnesota in 2009, states as varied as Arizona, Maine, Vermont, Oregon, and Washington had adopted dental therapy by 2019<sup>17</sup> and additional states were actively promoting their adoption.<sup>18</sup>

As a profession, dental assistants are more challenging to define and quantify. Whereas dentists, dental hygienists, and dental therapists are regulated by states through dental



licensing boards, regulation of dental assistants varies by state and by scope of services. The over 300,000 dental assistant jobs in the United States are held by people whose experience ranges from limited on-the-job training to the 37,000 assistants who have voluntarily satisfied requirements of the Dental Assisting National Board. Through licensure of dentists, states mandate “expanded functions” for dental assistants which vary considerably across the United States.<sup>19</sup>

## PEDIATRIC DENTAL DELIVERY SYSTEMS

Dental care delivery systems evolved apart from the already fragmented health care delivery systems in the United States. The structure of health professions education/training, traditional practice models, and insurance reimbursement are all factors that have contributed to the “Dental-Medical Divide.” Unfortunately, this division fostered a culture in which medical providers have largely abdicated responsibility for oral health, assuming it is the responsibility of the dental care delivery system. Oral health is part of overall health; therefore oral health care (or the care of a patient’s oral health) is part of overall health care services. Dental services are specialized health care procedures, critical to protecting, maintaining, and/or restoring oral health.

Over several decades, there have been numerous public health and advocacy initiatives that seek to increase awareness and bridge this divide. Most seek to extend oral health services outside the dental office. At the federal level, the Health Resources and Services Administration has funded projects focused on integrating dental care with primary medical care. Nationally, community health centers are developing solutions to extend oral health care services to their medical patients.<sup>15,20</sup> Training programs are being developed to “skill up” practicing medical professionals in oral health care delivery techniques, and education reforms seek to embed oral health across the curriculum for selected health professions.<sup>21</sup>

In addition to being siloed from the overall health system, the dental care delivery system itself is subdivided into two parallel systems—public and private—that tend to function independently. These systems are defined by the delivery site and payer mix. The much larger private system consists of privately owned dental practices that treat patients who pay out-of-pocket or have employer-sponsored dental insurance. In contrast, the public delivery system, often called the “dental safety net” comprises community health centers, free clinics, dental education and training programs in schools and hospitals, and volunteer programs as well as private dentists who serve substantial numbers of publicly insured patients. The advent of large Medicaid-only privately owned dental management organizations (DMOs) has complemented and supplemented the traditional dental safety net so that by 2012 about one in five publicly insured children were served by pediatric Medicaid DMOs.<sup>22</sup> Similarly, as the numbers and proportion of children covered by public insurance have increased, driven by demographic and public coverage trends, private pediatric dentists have become a mainstay of the dental safety net. One established approach to bridging the private and public delivery systems is contracting of private dentists by Federally Qualified Health Centers to provide care in their private offices

to Center patients. This contracting approach, approved by the federal government, the American Dental Association, and the National Association of Community Health Centers, allows private dentists to contract for specified numbers of hours, patients, or services. As new value-based holistic delivery systems, like patient-centered medical homes, accountable care organizations, and aggregated practices continue to evolve, the public and private dental delivery systems may become increasingly integrated.

## PEDIATRIC DENTAL FINANCING, PAYMENT, AND COVERAGE

Dental care for children is financed by one or more of three payers: employers, government, and families. The vast majority of children have insurance coverage with about 50% having private employer-sponsored insurance (ESI) and 40% having government-sponsored public insurance through Medicaid or CHIP. The small proportions of children who do not qualify for public insurance and are not covered by their parent’s ESI are eligible for private dental coverage through the ACA marketplaces. Expansions in public insurance, combined with demographic shifts driving increased numbers of children eligible for public coverage, have dramatically decreased the numbers of uninsured children from one in four in 2000 to one in ten by 2015. Despite high levels of coverage, about one-third of dental care is financed by families’ out-of-pocket dollars because private insurance, unlike public insurance, involves deductibles, copayments, and a variety of coverage and dollar limits. In 2015, the average pediatric dental expenditure for all US children (utilizers and nonutilizers) was \$636. Private ESI insurance funded about half of this expenditure, whereas out-of-pocket dollars funded about one-third and public insurance about one-sixth expenditure.<sup>23</sup>

A child’s eligibility for public insurance depends on their family’s income, the child’s age, and the family’s state of residence. Because states, rather than the federal government, determine eligibility, there is very wide variation between states regarding children’s eligibility for Medicaid and CHIP. For example, in 2017, Medicaid was available to children of middle-class families earning up to \$80,000 in District of Columbia and Vermont while limited to those in near poverty in nine other states. Public insurance offers comprehensive dental coverage for children and adolescents at no cost to families but not for adults in most states. Consequently, many parents of publicly insured children are apparently unaware that their children have both medical and dental coverage. One in four parents who report that their child has Medicaid or CHIP medical coverage also report, incorrectly, that their child has no dental coverage.<sup>24</sup>

Children account for one-quarter of the US population but their total medical, dental, and behavioral personal health costs consume less than one-tenth of the total US health care expenditures, which in 2017 exceeded \$3.5 trillion, nearly one-fifth of the US gross domestic product. Children’s dental care alone (at \$26.9B in 2014) accounts for less than 1% of this massive national health care cost. But within all of pediatric personal health care, dental care is the second most costly health service. Only newborn well care costs more than dental care (\$27.9B in 2014).

National dental care costs for children (11.5%) are three times greater than costs of medical well-child care (3.6%). From a condition perspective, dental care also exceeds treatment of attention-deficit and hyperactivity disorder (8.8%), asthma (3.9%), upper respiratory infections (3.6%), falls (3.3%), and congenital anomalies (3.2%) among other common pediatric health conditions.<sup>25</sup>

Despite extensive dental coverage for children, affordability remains an issue for many families. More people report that their children face a financial barrier to dental care than to medical, prescription, eyeglass, or mental health care, and more adults than children face financial barriers to health care.<sup>26</sup> If a parent does not use dental services in a year, their child has three times the risk of lacking a dental visit. If the parent lacks dental coverage, the child has seven times increased risk of lacking dental coverage, even if it is available. If a parent defers care due to cost, their child has nearly 10 times increased risk of having their care deferred because of cost.<sup>27</sup>

With little exception, US private-sector dentists are paid fee-for-service based either on their idiosyncratic fee schedules or accepted contractual rates with insurers. In contrast, federally financed health centers are funded on an annually negotiated cost-reimbursement basis and pay their health care providers by salary. Capitation, in which dentists are paid a fixed dollar amount annually for each patient assigned to their care, has had little impact in dentistry. These traditional payment approaches are increasingly being complemented or replaced by APMs that seek to reward health outcomes (“value”) instead of procedures (“volume”).<sup>28</sup> APMs build on the “triple aim” of better health outcomes at lower cost with enhanced population experience of health care.<sup>29</sup>

While each payment mechanism has inherent benefits and risks to both the provider and patient, APMs are designed to drive new delivery systems that are holistic, comprehensive, and accountable to patient outcomes. For example, some of the APM approaches place health care systems and health care providers at financial risk and reward for attainment of measureable outcomes. From a public health perspective, driving health care innovation through APMs holds promise to reduce oral health disparities, integrate dental care with overall health care and with family- and community-health promotion interventions, and maximize dental care efficiency. Shifting from volume to value better integrates clinical practice with public health practice as dentists leverage public health principles, interventions, and skills to produce the best possible patient and population oral health outcomes.

Organized dentistry has prepared for APMs through its Dental Quality Alliance (DQA) that develops performance measures and its Health Policy Institute (HPI) that tracks evolving delivery systems. By 2019, the DQA had defined three pediatric dental utilization measures, eight pediatric dental quality measures, and one pediatric dental cost measure. The HPI regularly updates its website with information on new delivery systems, for example reporting on the penetration of dental care in accountable care organizations.<sup>30</sup>

New delivery systems and APMs provide novel opportunities for rethinking the design of pediatric dental care with an orientation toward health outcomes. For example, by financially incentivizing dentists to reduce caries

progression in high-risk children, dentists may seek to prioritize care of high-risk children for whom caries risk can be reduced over low-risk children with little or no past caries experience. This payment reward would incentivize dentists to consider a child’s caries risk holistically, within the contexts of families’ day-to-day health behaviors. Since dentists are not as well qualified to deal with families’ capacities to adopt effective oral health behaviors as are social workers, behavioral nutritionists, and community health workers, pediatric dental care would evolve to include these helping professionals.

## PEDIATRIC DENTAL UTILIZATION

Dental utilization is distinctly different than dental access although the two terms are often confused and conflated. Access to care is about the availability of care (a supply-side concern), whereas utilization is about the use of care when it is available (a demand-side concern). Access considers whether the door to care is open, whereas utilization considers whether people elect to walk through the open door. Access requires the workforce, delivery systems, and payment supports described above, whereas utilization requires a family that is informed and motivated to seek care when available.

With expanded public and private coverage, dental utilization by US children increased moderately (from 42% to 48%) while dental utilization by publicly insured children nearly doubled (from 28% to 50%). This dramatic increase significantly closed the gap in dental care between privately and publicly insured children, although children in Medicaid and CHIP continued to use less dental care than privately insured children.<sup>31</sup> By 2016, for the first time since Medicaid dental coverage was established in 1967, half of publicly insured children obtained a dental visit in the year. Nonetheless, the absolute level of dental utilization remains a public health and professional concern because half of publicly insured children and one-third of privately insured children do not utilize dental care in a year. The gap in utilization between privately and publicly insured children is also an ongoing concern because publicly insured children have greater dental needs than their higher-income privately insured peers; therefore publicly insured children should have higher utilization than their socially advantaged peers.

The dynamic improvements in dental utilization since 2000 reflect concerted federal efforts to increase dental utilization by poor and low-income children. The federal Center for Medicaid and CHIP Services (CMCS) mounted a “Children’s Oral Health Initiative” that pressed states to increase by 10 percentage points the proportion of publicly insured children with a dental visit and the proportion of children who received a sealant.<sup>32</sup> It developed an Oral Health Strategy,<sup>33</sup> a guide,<sup>34</sup> and various social media tools, a “Find a Dentist Widget,”<sup>35</sup> and also provided extensive technical support to states. It promoted state oral health performance improvement plans, action plans, and a “Learning Lab” to share best practices.<sup>36</sup> Simultaneously, the federal Center for Medicare and Medicaid Innovation (CMMI) funded demonstration projects in South Dakota targeting Native Americans, New York targeting young Latino immigrants, and Michigan targeting primary care medical providers.

States, in turn, built utilization requirements, rewards, and sanctions into their dental vendor contracts that encourage or require Medicaid managed care organizations to promote dental utilization and sealant applications, encourage general dentists to increase care of children, and contact parents of nonutilizing children to facilitate care. Many states also reformed their dental Medicaid programs by raising fees, simplifying paperwork, providing beneficiaries with case management and care coordination services (e.g., transportation, translation, and appointment assistance), and restructuring programs, for example by reducing the numbers of vendors with which dentists need to contract. The Children's Oral Health Initiative Director reported that by 2018 states achieved a nearly 8% increase in these preventive service goals and that in 2019 CMCS was developing a second set of goals.<sup>37</sup> All of these governmental endeavors were complemented by private and safety net dentists through liaison with Head Start, WIC, Give Kids a Smile, and other programs that serve poor and low-income young children.

Dental utilization varies by child age. Utilization is lowest among 1- to 5-year-olds, peaks among 6- to 11-year-olds, and declines among older children and adolescents.<sup>38,39</sup> Low utilization rates among the youngest children are problematic because they represent missed opportunities for primary prevention. Declining utilization rates among adolescents are problematic because oral conditions accumulate with age. By ages 19 and 20, Medicaid and CHIP beneficiaries experience the highest rates of presentations to hospital emergency rooms for treatment of preventable dental conditions.

Dental utilization also varies by geography as it correlates with dentist density, rates of dentist participation in Medicaid/CHIP, and reimbursement rates offered by Medicaid/CHIP.<sup>39</sup> Dentist density reflects rurality, transportation system availability and adequacy, and area-level economic prosperity. For privately<sup>40</sup> and publicly insured children,<sup>41</sup> utilization rates are lower in rural areas than in urban and suburban areas. However, low utilization in inner-city areas parallels low utilization in rural areas when access is constrained by a lack of Medicaid/CHIP providers and dentists who provide care to children.

Dental utilization varies by children's overall health conditions. Children with special health care needs experience higher rates of insurance and are more likely than well children to receive preventive dental services. However, those who have more severe medical conditions are from low-income families, or those who are publicly insured have far higher rates of unmet dental treatment needs.<sup>42</sup> One promising approach to increasing dental utilization and decreasing unmet dental need is coordination of all health care services through a medical home.<sup>43</sup> Young children with special needs whose care is coordinated and who use more preventive medical services also use more preventive dental services.<sup>44</sup> As with well children, the drop-off in dental utilization among adolescents with special needs is significant and compounded by race, ethnicity, and income status.<sup>45</sup>

Surprisingly, children's dental needs—both subjectively perceived by children and families and objectively assessed by dentists—do not correlate with dental utilization although perceived needs correlate more strongly with episodic care.<sup>46</sup> This finding suggests either that access to

dental care is not sufficient for all children or that parents of affected children are not pursuing dental care when needed. Further improvements in dental utilization will require attention to both the supply side—by maintaining and enhancing access—and the demand side—through outreach, education, and improvements in oral health literacy. Factors well outside of dentistry can impact utilization even among motivated families: for example, a late-2019 federal policy that limits access to citizenship by legal immigrants who utilize public services, including Medicaid or CHIP, limits families' use of dental services even when accessible.

Dental utilization alone does not correlate with improved oral health. While dental care is essential to oral health, it is but one of multiple factors that influence oral health status. Other more powerful oral health determinants are daily oral health behaviors and social and environmental determinants. These determinants are more challenging for dentists to address because patient education alone does not change oral health behaviors<sup>47</sup> and because dental providers are not as prepared or positioned to address social and environmental health determinants as social and behavioral professionals. Even when publicly insured children gain equivalent utilization as privately insured children, their oral health status is worse, thereby suggesting that the care they receive is either inadequate despite being equivalent or that unaddressed behavioral, social, and environmental determinants are responsible for poorer oral health.<sup>48</sup>

In an expanding era of accountable value-based care that rewards health care providers for their patients' health outcomes rather than procedures,<sup>49</sup> dentists and other health care providers will need to tailor preventive care more specifically to children's levels of disease risk and address nonclinical determinants by engaging nontraditional professionals including social workers, dietitians, and community health workers.<sup>50</sup> Risk-based individualized care will encourage dentists to better tailor frequencies of preventive visits to children's individual levels of risk and orient their care toward caries prevention and suppression over one-size-fits-all prevention and dental repair. For publicly insured children, this risk-based approach to care was promoted in a 2018 federal CMCS policy bulletin to states that called for highly tailored individualized care plans, additional services for children at high risk for caries, and alignment of fee schedules with risk-based care.<sup>51</sup> For privately insured children, this fundamental shift to paying for outcomes is well underway for medical providers and increasingly being adapted for dentistry.<sup>52</sup>

## Advocacy Action in Support of Pediatric Oral Health

Policymakers make decisions about how things are done, formulate programs, allocate resources, and provide oversight to evaluate the impact of their actions. Policymakers important to children's oral health and dental care are found in a wide range of spheres including state and federal government agencies, state and local legislators and legislative staff, professional associations, dental industry, dental education, health care systems, and insurance. These policymakers, in turn, are influenced by advocates who seek to



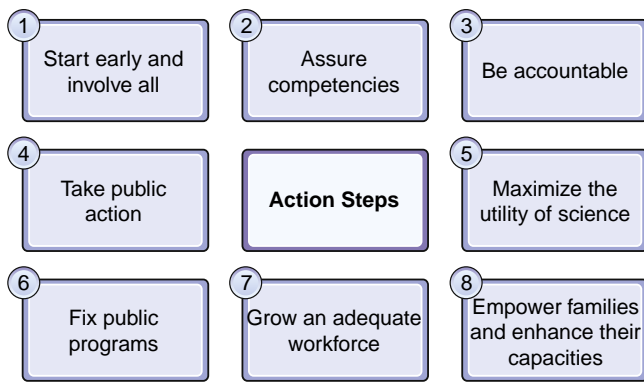


Fig. 30.2 Systemic approaches to improving children's oral health and dental care advanced by the 2002 U.S. Surgeon General's Workshop on Children's Oral Health.

support, modify, or oppose policy actions to promote their own interests and the interests of those they represent. The dynamic push-and-pull between policymakers and advocates ultimately results in a *status quo* under which all parties operate until policies change. In this sense, policymaking and advocacy are continuous actions that require active engagement of dentists who treat children in partnership with others who support children's health and welfare.

The policy process can be conceived as having sequential steps that ultimately lead back to the beginning. It starts with defining the problem to be solved. For pediatric dental care, it may be a problem related to the various access and utilizations considerations previously discussed. For pediatric oral health, it may be a problem related to health literacy, availability of healthful foods, or access to dental hygiene supplies. Once the problem is identified by policymakers or advocates, multiple solutions are proposed by competing interests. Reconciling these multiple solutions into a single workable intervention requires compromise through which competing interests sacrifice some of their desires to the possibility of a policy solution that is attainable. That solution is typically expressed as a policy or program which is then implemented and evaluated. Evaluation of policy frequently reveals some new problem that initiates the cycle again.<sup>53</sup>

Dental professionals who care for children assume an advocacy role on behalf of their pediatric patients as well as all children and adolescents who do not have access to or utilize dental care. Taking a systemic approach, the U.S. Surgeon General's 2002 Workshop on Children and Oral Health advanced eight approaches to improving pediatric oral health and dental care (Fig. 30.2). As the core definition of a professional is one who utilizes specialized knowledge to advance the interest of others ahead of their own interests, a child advocate consistently promotes children's interests over their own self-interests. Nonetheless, in practice, the most effective oral health policies are those that support both children and the dentists who serve them.

There are a myriad of ways that dentists can advocate for children, such as by establishing policies for their own practices that promote equity, by engaging governmental policymakers, or by joining with others who advocate for children's health and welfare from perspectives of social justice. Engaging with others includes participating in professional dental associations' advocacy endeavors when those endeavors represent the best interests of children and families.

Dental professionals may engage as child advocates within their own practices, for example in establishing office policies that range from who they treat to the content of care they provide as well as developing supportive policies on payment, employment, facilities, appointment management, safety, quality, and accountability. They can express their commitment to children's health and welfare, for example, by:

- promoting risk-based care that supports a more equitable distribution of services;
- implementing office-based programs to assess the quality of their care measured by patients' oral health outcomes and patient satisfaction;
- engaging nontraditional professionals such as health educators and nutritionists who can assist with patient education and care facilitation;
- integrating their care with advanced delivery systems like accountable care organizations and patient-centered medical homes;
- representing the health and oral health interests of special child populations including immigrant groups, children with special health care needs, children in juvenile justice systems, and socially disadvantaged groups; and
- experimenting with APMs that support value-based care.

Dental professionals may engage as child advocates in their local communities, for example, by:

- influencing their area school boards to establish school-based medical and dental services and oral health education programs;
- initiating or sustaining community water fluoridation
- working with child welfare agencies to include provision of dental care;
- engaging federally qualified health centers in their area to adopt a policy allowing referral of children to local dentists;
- assisting local Head Start, WIC, and other federally sponsored early childhood programs in implementing oral health policies and requirements;
- supporting local child advocacy groups with time and/or money; and
- engaging their local dental society in advocacy action.

Dental professionals may engage as child advocates with state and federal governments, for example, by:

- educating themselves about the policymaking process,
- building personal relationships with policymakers and their staff to become responsive and authoritative resources,
- participating with state and national child, health, and dental organizations in their advocacy and lobbying efforts,
- engaging their state- and federal-elected legislative officials to educate them about children's oral health and dental care and to explain how governmental policies impact care and health outcomes, and
- reaching out to state- and federal-appointed executive officials who implement policies to promote favorable policy actions and demote policies that are unfavorable to children and their families.

Dental professionals may also engage as child advocates with the public health community since public health addresses the needs of all. They can do so by working with their city, county, or state health officials, particularly their state dental directors to learn about and influence governmental priorities and opportunities. Dentists can also align with academic dental public health professionals in dental schools to learn about their efforts to improve the public's oral health. In an environment of rapid health system reform, dentists who care for and advocate for children can also become actively engaged in the development and administration of evolving health care and payment systems to ensure that children's interests are recognized and attended to.

Regardless of where and how dental professionals engage in advocacy, fundamental principles apply. The successful child oral health advocate:

1. places interests of children and families above competing interests.
2. distinguishes oral health from dental care, seeking firstly to promote oral health through redress of social inequities and environmental constraints.
3. recognizes that improving dental care alone will not improve the oral health of all children.
4. pursues multiple strategies to attain desired outcomes.
5. partners effectively with others who share their goals and develops relationships built on collaboration and trust.
6. keeps informed and updated about options and opportunities to address children's oral health.
7. provides complete and authoritative information to policymakers so that they can make decisions based on evidence.
8. is determined, persistent, open to compromise, and protective of gains when attained.
9. actively advances innovation.
10. leverages public health principles of addressing the entire population of children, maximizing scarce resources by allocating them where they can be most impactful, and targeting the greatest benefit for the largest numbers of people.

Advocacy, the active support for a cause or policy, is as rewarding as it is frustrating. Its outcome, improved health and welfare for all children, are commensurate with the rewards of treating individual children but on a far larger scale. It is not for everyone. But for those who elect to engage in it, who feel a calling to it, who can tolerate its pace and its procedures, its advances and its setbacks, it holds profound rewards for advocates and those they benefit.

## References

1. Frey WH: *Less than half of US children under 15 are white, census shows*, Metropolitan Policy Program, 2019.
2. Trends C: *Immigrant children*, 2018. Available at: <https://www.childtrends.org/?indicators=immigrant-children>.
3. Uunited States Census Bureau. Table 16. Distribution of the Poor, by Age and Race. In. Historical Poverty Tables: People and Families - 1959 to 2018 2019.
4. Population Reference Bureau. Analysis of data from U.S. Census Bureau - 2005, 2008, 2010 and 2013 to 2017 American Community Survey. In: 2019.
5. Dubay L, Clemans-Cope L, Anderson N: *The link between income and the environments that promote child health*, 2015.
6. *Child trends. Dual language learners*, 2019. <https://www.childtrends.org/indicators/dual-language-learners>.
7. Kochhar R, Cilluffo A: *How wealth inequality has changed in the U.S. since the Great Recession, by race, ethnicity and income*, Pew Research Center, 2017 <https://www.pewresearch.org/fact-tank/2017/11/01/how-wealth-inequality-has-changed-in-the-u-s-since-the-great-recession-by-race-ethnicity-and-income/>. Accessed on October 29, 2020.
8. Halfon N, Larson K, Son J, et al.: Income inequality and the differential effect of adverse childhood experiences in US children. *Acad Pediatr* 17(7S):S70–S78, 2017.
9. Koball H, Jiang Y: *Basic Facts about low-income children: children under 18 years, 2016*, Columbia University Mailman School of Public Health, 2018.
10. Voinea-Griffin A, Solomon ES: Dentist shortage: an analysis of dentists, practices, and populations in the underserved areas, *J Public Health Dent* 76(4):314–319, 2016.
- 10a. Fisher-Owens SA, Gansky SA, Platt LJ, et al.: Influences on children's oral health: a conceptual model. *Pediatrics*. 120(3):e510–e520, 2007.
11. U.S. Department of Health and Human Services: *Oral health in America: a report of the Surgeon general*, Rockville, MD, 2000, U.S. Department of Health and Human Services, National Institute of Dental and Craniofacial Research, National Institutes of Health.
12. National health nutrition examination survey, 2015–2016. In Statistics NCH, editor: *Nhanes 2015–2016*, Centers for Disease Control and Prevention, 2018.
13. Maxey HL, Norwood CW, Liu Z: State policy environment and the dental safety net: a case study of professional practice environments' effect on dental service availability in Federally Qualified Health Centers, *J Public Health Dent* 76(4):295–302, 2016.
14. Braun PA, Cusick A: Collaboration between medical providers and dental hygienists in pediatric health care, *J Evid Based Dent Pract* 16(Suppl):59–67, 2016.
15. Maxey HL, Norwood CW, Weaver DL: Primary care physician roles in health centers with oral health care units, *J Am Board Fam Med* 30(4):491–504, 2017.
16. Lenaker D: The dental health Aide therapist program in Alaska: an example for the 21st century, *Am J Public Health* 107(S1):S24–S25, 2017.
17. Grant J: *Michigan becomes 8th state to authorize dental therapists*, 2018.
18. *Community Catalyst. Dental access project*, 2019. <https://www.communitycatalyst.org/initiatives-and-issues/initiatives/dental-access-project>.
19. Dental Assisting National Board: *Missouri state requirements*, 2019. <https://www.danb.org/Meet-State-Requirements/State-Specific-Information/Missouri.aspx>.
20. Maxey H: *Integration of oral health with primary care in health centers: Profiles of five innovative models*, 2015.
21. Dolce MC, Haber J, Shelley D: Oral health nursing education and practice program, *Nurs Res Pract* 2012:149673, 2012.
22. *Children's dental health project. Dental visits for Medicaid children: analysis and policy recommendations*, 2012.
23. Manski R, Rohde F: *Dental services: use, expenses, sources of payments, Coverage and Procedure Type*, 2017, pp 1996–2015.
24. Strane D, Kanter GP, Matone M, et al.: Growth of public coverage among working families in the private sector, *Health Aff* 38(7):1132–1139, 2019.
25. Bui AL, Dieleman JL, Hamavid H, et al.: Spending on children's personal health care in the United States, 1996–2013, *JAMA Pediatr* 171(2):181–189, 2017.
26. Vujicic M, Buchmueller T, Klein R: Dental care presents the highest level of financial barriers, compared to other types of health care services, *Health Aff* 35(12):2176–2182, 2016.
27. Edelstein B, Rubin M, Clouston S, et al.: *Children's dental experience reflects their parents' utilization, coverage, and affordability: a 2-Gen analysis for policymakers*. In: 2019.
28. Health Care Payment Learning & Action Network: *Alternative payment model: APM Framework*, 2017.
29. Institute for Healthcare Improvement: *The IHI triple aim. initiatives*, 2019. <http://www.ihl.org/Engage/Initiatives/TripleAim/Pages/default.aspx>.

## Advocacy Case Study

Chapter:	Edelstein/Maxey
Population:	Children under age of 6 covered by Medicaid in a local community
Characteristics:	70% Latino Majority Spanish as first language Average age 4 years 6 months 88% well children; 11% with asthma; 1% with developmental special needs 5% severe early childhood caries (ECC); 15% moderate-to-minor ECC; 80% caries-free Fluoridated community Single Medicaid managed care plan
Problems:	1. Low utilization of dental care (20% utilizers) 2. Recurrent caries after dental rehabilitation under general anesthesia
Scenario:	You are a practicing dentist in a small multicultural community. You have enrolled as a Medicaid provider in your state. You have joined the managed care network administered by the only Medicaid managed care plan that serves your locale. Although your doors are open to all children in your community, you note that utilization is two times greater for privately insured children than publicly insured children. You also note that the most common presentation is for relief of pain and infection secondary to extensive ECC. You are also disappointed that children you have treated under general anesthesia have a high incidence of additional decay and return to the operating room.

- Which of the following are potential partners in your immediate area to address the low utilization and high caries recurrence rates you have identified? (Check all that apply.)
  - State Medicaid
  - Medicaid Managed Care Company
  - Local preschool programs including Early Head Start/Head Start Programs
  - Area WIC Nutrition Program
  - Local chapters of Child Advocacy Groups
  - Hispanic Churches
  - County/state dental public health offices
  - Local dental associations
  - Local pediatric medical association
  - Local library children's programming
  - City Council members and local state representatives
  - Local Hispanic parent groups
  - Local community-based organizations serving the Latino population
  - Local federally qualified health center

Answer: All of the above may potentially partner to address oral health and dental care of low-income minority children. Each provides one or more services to the target population. They may provide the population with information on why and how to obtain dental care; with translation, appointment making, and care facilitation services; with wraparound support for healthy eating and oral hygiene maintenance; and with culturally and language-appropriate support. The US Surgeon General's Workshop on Children and Oral Health suggests that a critical action step for oral health of children is to "involve all" who engage families.
- Which of the following strategies might you *not* consider to increase utilization?
  - Reduce copayments and other charges for these patients.
  - Contract with a local federally qualified health center to accept their young dental patients on referral.
  - Work with the Medicaid managed care plan to develop and implement a performance improvement project aimed at increasing utilization.
  - Hire a Spanish-speaking dental therapist if allowable in your state.

Answer: a. Medicaid does not allow health care providers to charge families for covered pediatric services.
- From public health and population health management perspectives, which of the following is not true?
  - ECC in this population is sufficiently prevalent and consequential to be a public health concern.
  - Early preventive intervention should be prioritized and incentivized.
  - All children should have the same frequency of preventive care regardless of caries risk.
  - ECC is a chronic disease management challenge more than a dental repair challenge.

Answer: c. From a public health perspective, resources including dental visits should be allocated according to risk to achieve the greatest good for the largest numbers of children.
- Which of the following actions might you work with your community partners to pursue to reduce caries incidence?
  - Check the local community water supply to ensure that it is properly fluoridated.
  - Survey target families to determine whether their children are drinking municipal water.
  - Assess the families' neighborhoods for food deserts.
  - Determine whether local bodegas are promoting candy and sugar drinks at impulse checkouts.
  - Distribute oral hygiene supplies including fluoridated toothpaste.

Answer: All of the above



30. Colla CH, Stachowski C, Kundu S, et al.: *Dental care within accountable care organization: challenges and opportunities*, American Dental Association Health Policy Institute, 2016.
31. Health Policy Institute: *Dental care use among children*, American Dental Association, 2016.
32. Mann C. Update of CSM oral health initiative and other oral health related items. Center for Medicare & Medicaid Services, Center for Medicare & Medicaid Services, 2014.
33. Center for Medicare & Medicaid Services: *Improving access to and utilization of oral health services for children in Medicaid and CHIP programs: CMS oral health Strategy*, 2011.
34. Center for Medicare & Medicaid Services, NORC: *Keep Kids Smiling: promoting oral health through the Medicaid benefit for children & adolescents*, 2013.
35. *InsureKidsNow.gov. Improving oral health initiatives*, 2019. <https://www.insurekidsnow.gov/initiatives/oral-health/index.html>.
36. Medicaid.gov: Dental care, *Benefits*, 2019. <https://www.medicaid.gov/medicaid/benefits/dental/index.html>.
37. Norris L: *Children's oral health initiative*. In Edelman B, editor: 2019.
38. *Indicator 4.2: dentist visit, age 1-17 years*, Data Resource Center for Child & Adolescent Health, 2017. <https://www.childhealthdata.org/browse/survey/results?q=5436&r=1&g=647>.
39. Chalmers NI, Wislar JS, Hall M, et al.: Trends in pediatric dental care use, *Dent Clin North Am* 62(2):295–317. e212, 2018.
40. Bhagavatula P, Xiang Q, Szabo A, et al.: Rural-urban differences in dental service use among children enrolled in a private dental insurance plan in Wisconsin: analysis of administrative data, *BMC Oral Health* 12:58, 2012.
41. Byck GR, Walton SM, Cooksey JA: Access to dental care services for Medicaid children: variations by urban/rural categories in Illinois, *J Rural Health* 18(4):512–520, 2002.
42. Lewis CW: Dental care and children with special health care needs: a population-based perspective, *Acad Pediatr* 9(6):420–426, 2009.
43. Akobirshoev I, Parish S, Mitra M, et al.: Impact of medical home on health care of children with and without special health care needs: update from the 2016 National Survey of Children's Health, *Matern Child Health J*, 2019.
44. Craig MH, Scott JM, Slayton RL, et al.: Preventive dental care use for children with special health care needs in Washington's Access to Baby and Child Dentistry program, *J Am Dent Assoc* 150(1):42–48, 2019.
45. Parasuraman SR, Anglin TM, McLellan SE, et al.: Health care utilization and unmet need among youth with special health care needs, *J Adolesc Health* 63(4):435–444, 2018.
46. Vargas CM, Ronzio CR: Relationship between children's dental needs and dental care utilization: United States, 1988-1994, *Am J Public Health* 92(11):1816–1821, 2002.
47. Albino J, Tiwari T: Preventing childhood caries: a review of recent behavioral research, *J Dent Res* 95(1):35–42, 2016.
48. Shariff JA, Edelstein BL: Medicaid meets its equal access requirement for dental care, but oral health disparities remain, *Health Aff* 35(12):2259–2267, 2016.
49. Glassman P: *Oral health quality improvement in the era of accountability*, Authur A. Dugoni School of Dentistry, 2011.
50. Edelstein BL: Pediatric dental-focused Interprofessional interventions: rethinking early childhood oral health management, *Dent Clin North Am* 61(3):589–606, 2017.
51. Hill T: *Aligning dental payment policies and Periodicity schedules in the Medicaid and CHIP programs*, 2018.
52. Voinea-Griffin A, Fellows JL, Rindal DB, et al.: Pay for performance: will dentistry follow? *BMC Oral Health* 10:9, 2010.
53. Azline A, Khairul Anuar A, Iszaid I, et al.: Policy Arena of health policy-making process in developing Countries, *International Journal of Public Health and Clinical Sciences* 5(3):32–48, 2018.

## 31

# Practice Management

LILLY CORTES-PONA and JULIE WEIR

**CHAPTER OUTLINE****The Five Parts of a Successful Dental Practice****Part 1: Doctor's Vision for the Practice****Part 2: Mission Statements: Practice and Team****Part 3: Fiscal Management**

Business Plan

Monitor Goal Numbers

Monitoring Schedule

Setting a Budget

Reports That Should be Monitored Regularly

Fees

Accounts Payable

Retirement Planning

**Part 4: Team Dynamics**

Doctor Leadership

Employee Management

**Part 5: Systems**

New-Patient Appointment

Effective Scheduling

Surgical Referrals

Managing Collections

Managing Insurance

Treatment Tracking

Internal and External Marketing

Dental Office Technology

Compliance

Clinical Organization

Inventory Control

**▶ For additional resources, please visit the website.**

It is important that practitioners have a thorough understanding of what it takes to operate a successful private pediatric dental practice. In addition to excellent clinical dentistry and behavior management skills, strong leadership, business, and practice management knowledge are also necessary. Now more than ever, a dental practice must run like a business because of decreasing profit margins due to increased competition and lower managed care reimbursement.

An owner-doctor should feel confident in handling the following challenges:

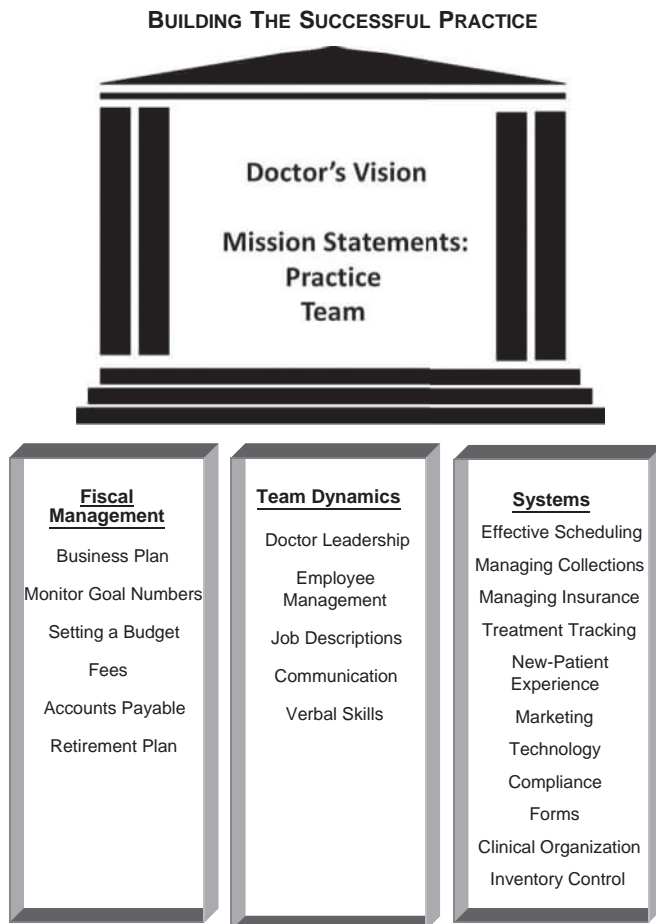
- Handling multiple business issues while also spending most of the business hours “on the line” making the product. A dentist must also be the Chief Executive Officer or CEO, Chief Financial Officer or CFO, Chief Operating Officer or COO, Chief Information Officer or CIO, and run the Human Resources department.
- Engage, motivate, and lead the team to endorse the doctor's vision and help the doctor create the type of practice he/she desires.
- Create loyal relationships with parents and patients so they stay in the practice long-term and accept and complete the treatment plans that are presented.
- Successfully go out into the community and meet other health care providers, creating loyal referring relationships.
- Address poor job performance issues in a timely manner directly with the team member to keep practice systems running efficiently and smoothly.
- Make tough decisions that are for the greater good of the team and practice but may not be popular with all team members.

Limited leadership and business skills are taught in dental school, and the average dental student is unable to assimilate this information without hands-on application. Therefore, the dental practitioner must acquire these skills through books, continuing education programs, trade journals, newsletters, and good advisors: accounting, legal, marketing, and practice management. The wise doctor who desires financial success will start educating himself/herself about leadership, business principles, and practice management systems early on and surround himself/herself with experts who can help shorten the learning curve and increase profits more quickly. It is beyond the scope of this chapter to give detailed steps for each practice management area; however, it aims to create an awareness of what should be in place in a practice to establish a framework for success.

## The Five Parts of a Successful Dental Practice

It can be overwhelming to understand what must be in place to create a successful practice. Think of it as building a structure with the doctor as the architect. First, the architect must create a set of plans, so others will know what the structure will look like and how to build it. The doctor's vision and the practice's mission statements are the “plan” for the practice.

All structures need to be built on a strong foundation. The foundation of a dental practice rests on three strong pillars: fiscal management, team dynamics, and systems. If a doctor successfully builds these five practice parts and consistently works to keep them strong, the practice will take form and be prosperous (Fig. 31.1). In his book *Good*



**Fig. 31.1** Building a successful dental practice: the five parts that go together. (©Julie Weir & Associates Management Consulting, ©LCP Dental Team Coaching)

to Great, Jim Collins<sup>1</sup> wrote, “The real path to greatness, it turns out, requires simplicity and diligence. It requires clarity, not instant illumination. It demands each of us to focus on what is vital—and to eliminate all of the extraneous distractions.”

## Part 1: Doctor's Vision for the Practice

A doctor should define what is in his/her head and heart about the practice to be created and then share that vision with team members. A vision cannot be realized until it is shared. When all team members are working toward a common vision and goal, the probability of success greatly increases. The team's energy becomes synergistic.

## Part 2: Mission Statements: Practice and Team

Each day, team members serve two customers: the parent/patient and each other, including the doctor. Therefore, it is necessary for the team to create two mission statements, one for each customer they serve:

1. Patient mission statement (for serving patients)

2. Team mission statement (for serving each other)

The two mission statements express what the team is working to achieve and serve as leadership accountability tools. Each mission statement sets the standard of performance for team members.

## Part 3: Fiscal Management

Fiscal management concerns the way in which the finances of a business are managed and includes goal setting, accounts receivable (money owed to the practice), accounts payable (money owed by the practice), budgeting, fee structure, and monitoring methods.

### BUSINESS PLAN

A doctor should have a strong understanding of the business numbers in his/her practice. Every practice should have an annual business plan with goals that meet the financial needs of the practice and the doctor. Monitoring these goals on a daily and monthly basis will show if any goal number is not being met. This indicates exactly where a doctor and team need to focus their actions for the practice to be financially successful. These goal numbers should also be used as a benchmark of performance and accountability for the employee who is in charge of the system that produces the numbers. Calculating the practice break-even point (BEP), goals, and budget can be outsourced if desired.

A business plan should identify the following numbers:

- Break-Even Point (BEP) = total dollars needed to meet overhead expenses, capital improvements, new equipment, raises, inflation adjustment, loan payments, doctor salary, and retirement contributions. Typically, practitioners will work with their accountant or practice management consultant to calculate the BEP.
- Monthly collection goal = BEP total ÷ 12 months
- Collection ratio = previous year's collection ÷ previous year's production = collection ratio %
- Monthly production goal = monthly collection goal ÷ practice collection ratio
- Producer work days/month goal defines the average number of “restorative,” “recare,” “in-office general anesthesia (GA) or sedation,” and “hospital” work days per month. There can be four different areas of productivity in pediatric dentistry (restorative, recare, in-office IV sedation or GA, and hospital) that should be monitored separately.
  - a) Procedures for one “doctor” work day are typically scheduled in two columns.
  - b) Procedures for one “recare” work day are scheduled in one column. A good benchmark is that for every pediatric “doctor” work day, there should be at least two “recare” work days scheduled (two columns). At least 13 recare appointments are completed per day in each column.
  - c) If a doctor who sees patients 4 days per week × 4 weeks per month (i.e., 16 doctor days per month) schedules two columns of recare every day, then there would be 32 recare work days per month. If a doctor does hospital and/or in-office IV sedation or



GA dentistry, then the average number of hospital, in-office IV sedation, and/or GA work days per month should also be determined.

- Daily production goals for each producer = the amount of production that the doctor should complete each day in restorative work and the amount of production that the hygienist/coronal polishing assistant should complete in each recare column.
  - a) The daily production by each producer can be monitored separately by the use of different producer codes in the practice management system.
  - b) The producer's (doctor, recare, hospital, and/or in-office IV sedation/GA) work days per month multiplied by the producer's daily production goal must equal the monthly production goal.
  - c) Practice recare should continue to grow until it becomes 50%–75% of the total practice production, depending upon the decay level of the patient population.
  - d) All procedures performed on the recare patient or in the recare chairs should be included in the recare production total to accurately reflect the level of productivity generated from recare patients: recare examination, prophylaxis, radiographs, fluoride treatments, and sealants.
- Daily scheduling goals for each producer = the producer's daily production goal ÷ 95%.

Example of calculations for practice goals:

- For illustration purposes, the example in [Box 31.1](#) shows calculations for a sample practice that has a BEP of \$1,147,776.
- Notice that in this example when the BEP is calculated, the practice's new desired BEP requires a 17% increase over the previous year's total collections. ( $[\$1,147,776 - \$975,000] \div \$975,000 = 17\%$ ).
- At this point, the doctor must either take action to achieve this 17% growth through marketing for more new-patients, filling open appointments in the schedule, or increase efficiency with the current schedule, facility, and team to produce the 17% increase in collections.
- If the doctor is unable to meet the 17% increase in collections, then adjustments must be made to the practice's financial needs by decreasing expenses or income expectations.

## MONITOR GOAL NUMBERS

Monitoring practice goal numbers is a system that should be a part of every practice. The universal law of business is that people pay attention to what gets measured. The purpose of monitoring is to *measure and improve*. Some goal numbers are monitored on a daily basis so that immediate actions can be taken for improvement. Other numbers are not as time sensitive and are reviewed on a monthly basis. Numerous goal monitoring tools are available in the marketplace, or a doctor can track goals in an Excel spreadsheet.

Meeting the practice goals month to month can vary depending on the time of the year, so monthly totals should also be tracked on a year-to-date basis. Goal numbers should be discussed monthly as a team, and if any goal is not met, the team can decide what they can do differently to help the

### Box 31.1 Sample calculations for setting practice goals

Annual Break-Even Point  $\$1,147,776 \div 12 =$  Monthly Collection Goal  $\$95,648$   
 Previous Year's Annual Collection  $\$975,000 \div$  Previous Year's Annual Production  $\$994,898 = 98\%$  Collection Ratio  
 Monthly Collection Goal  $\$95,648 \div$  Practice Collection Ratio  $98\% =$  Monthly Production Goal  $\$97,600$   
 Average Restorative Work Days/Month  $16 \times$  Daily Restorative Production Goal  $\$2700 =$   $\$43,200$  Restorative Monthly Production Goal  
 Average Recare Work Days/Month  $32 \times$  Daily Recare Production Goal  $\$1550 =$   $\$49,600$  Recare Monthly Production Goal  
 Average Hospital Work Days/Month  $1 \times$  Daily Hospital Production Goal  $\$5000 =$   $\$5000$  Hospital Monthly Production Goal  
 The three Monthly Producer Production Goals above should equal the Total Monthly Production Goal  $\$97,600$

practice meet that particular goal number. A team can easily increase production by 10% when using a goal monitoring system because of a better team focus on the end result.

## MONITORING SCHEDULE

There are various monitoring tools available in the marketplace in addition to dental software reports that a team can use to monitor important practice numbers and statistics.

### Daily

- Production versus goal for each producer
  - Average restorative production per day—\$2500 to \$6500 usual and customary rate (UCR) fee, depending on the fee level and the use of expanded function assistants
  - Average recare production per column—\$1800 to \$2200 UCR fee, depending on the fee level
- Month-to-date production versus goal for each producer and the total practice
- Show rate of patients: number of patients who appeared for their appointment/number of patients scheduled
- Treatment acceptance ratio: case acceptance/case presentations = 80% to 90%

### Monthly

- Total practice production
- Total producer production (doctor, recare, in-office IV sedation or GA, and hospital)
- Average daily producer production
- Producer work days (doctor, recare, in-office IV sedation or GA, and hospital)
- Total practice collections
- Collection ratio: 96%–98% of collectable fees, depending upon how much charitable dentistry is performed
- Show rate of patients: 95% show rate is preferred
- Accounts receivable total: 1:1 ratio of total accounts receivable: monthly production
- Total of accounts receivable in 61+ days: not more than 18%–25%
- Collection at the time of service: 35%–45%
- Adjustments to production: 2%–4%

- Adjustments to collection: insurance/patient refunds and insufficient funds checks = less than 1%
- New patients: from 55 to 65+ new patients/month are needed to maintain and grow an average one-doctor pediatric dental practice. Count only Current Dental Terminology (CDT) code D0150 (Comprehensive Oral Examination) and CDT code D0145 (Oral evaluation for a patient under 3 years of age) the first time it is used on a new patient.
- Percentage of patients in recare: goal is 75%

### Quarterly

- Overhead expenses from the profit and loss statement against budget amounts

### Yearly

Do a comparative analysis of all goal numbers to see if there is a decrease or increase and if the practice is growing correctly. A dental practice should grow 2%–4% *above* the national inflation rate each year to stay even, and higher than this to experience true practice growth. The costs of dental supplies and services can be greater than those for regular consumer products.

## SETTING A BUDGET

There are two ways to increase profitability in any practice: earn more or spend less. Control of expenses (savings) is one of the most underused yet valuable tools to increase profitability. Unspent dollars can go directly to the bottom line in the form of profit. The most effective way to save is to control spending through budgeting.

Create an annual overhead budget by taking the practice BEP amount and multiplying it by the following expense category percentages. Then, divide that number by 12 to get the monthly budget amount for each category. Budgets should be tracked at the end of each fiscal quarter to see if expenses are in line and to make adjustments in a timely manner.

- Miscellaneous, 4%–6%: advertising, business insurance, property taxes, misc.
- Office, 3%: bank charges, credit card fees, billing and collections, office supplies, postage, printing
- Professional development, 1%: dues and subscriptions, employee continuing education
- Dental supplies: 4%–6% (if practice has limited reduced fee patients), 7%–10% (if practice has a high volume of reduced fee patients)
- Lab, 25% (will be higher if there is a large volume of ortho)
- Facilities, 8%–10%: rent, repairs, janitorial, laundry, telephone, utilities
- Professional advisors, 2%–4%: legal, consulting, accounting, payroll service
- Labor, 18%–24%
- Employee benefits, 2%–3%
- Employee payroll tax, 2%
- Owner benefits, 1%–3%: payroll tax, auto, continuing education, travel, dining, retirement, insurance
- Owner income, 30%–48%
- Equipment, depreciation, and debt service, 3%–10%

- Associate doctor wages, 5%–10%

## REPORTS THAT SHOULD BE MONITORED REGULARLY

Using the reports in the dental software can help the practice operate more efficiently. Following are some of the major reports your office manager (OM)/front office coordinator should be completing and the doctor should be reviewing.

- Day sheet: Printed daily and reviewed to make sure that all services are included and have been accurately posted to the patient's ledger. Practice revenue is lost when additional procedures completed on the patient are not communicated to the front office team before the patient checks out.
- Daily deposit report: Your bank account should reflect the same amounts on the daily deposit slip. Often, with electronic fund transfers (EFTs), it is difficult to track whether the money that was deposited into your bank account was entered into patient accounts in your software. Make sure each day that your bank account deposits match the amounts on your previous daily deposit slip. That means that all EFT payments, credit card charges, checks, cash, and CareCredit payments need to be entered into the software the day they are received. The doctor should go online, log on to the bank account in the morning, and let the team know what EFT payments arrived and whether the amount deposited matches the credit card amounts that were settled the previous evening.
- Outstanding claims report: The outstanding claims report should be completed weekly to ensure that claims are paid in a timely manner or resubmitted for payment with corrected information, if necessary. Some offices lose thousands of dollars each year on claims that the insurance carrier denied because they were not submitted within the time limit for payment or they were sent with incorrect information.
- Procedures not attached to insurance claims: This report will show all procedures that were never submitted to insurance for payment. This report should be reviewed at the end of each day before sending insurance claims. These procedures should be submitted for payment immediately.
- Secondary insurance report: Many offices also lose money by not submitting the secondary claims. Even if the primary insurance company paid 100%, you still should submit to the secondary insurance. In some cases where the primary is a preferred provider organization (PPO) and the secondary is a traditional indemnity, there is a possibility for additional payment on those services up to your UCR fees.
- Unscheduled treatment plans, broken appointments, and overdue recare reports: Don't let your patients get lost! This is untapped potential revenue to quickly fill your schedule and create production. These reports should be printed monthly, and your OM should assign a team member who will be accountable for working these reports and tracking the results.
- New-patient referral report: Review monthly with the marketing team and decide on appropriate marketing actions to take place in the next month.

Profit Margin	5% Fee Increase	10% Fee Increase	15% Fee Increase	20% Fee Increase
20%	25%	50%	75%	100%
25%	20%	40%	60%	80%
30%	16.6%	33%	50%	66.6%
35%	14.3%	28.6%	42.9%	57.2%
40%	12.5%	25%	37.5%	50%
45%	11.1%	22.2%	33.3%	44.4%
50%	10%	20%	30%	40%

Fig. 31.2 Increase in net income related to fee increase.

## FEES

Fees should be reviewed annually and, if necessary, raised at least by the inflation rate to generate an adequate margin of profit. Most patients expect, accept, and may not even notice small adjustments in fees. Problems arise when a dentist who is reluctant to increase fees does not do so for several years and then must implement a significant increase. A hiatus in raising fees while costs of operations continue to increase means lower profits. If this pattern is allowed to continue, a practice can have significant financial difficulties that force a fee increase of 20%–30% or more in 1 year. Because most patients will notice and complain about such a large increase, it is better to raise fees gradually year to year to adjust for inflation and to cover increases in expenditures.

Fee increases should not be announced to patients; an increase simply becomes effective on a certain date. The dentist and team who take pride in the quality of their care and services will seldom feel defensive about fee increases, and that feeling will be imparted to patients and parents. Most people are willing to pay for care that they value and services that exceed the norm. When customer service expectations are met and exceeded, fees are never an issue. When expectations fall short, fees are always an issue. To support a well-deserved fee, excellent customer service is paramount.

Team members should be informed about why regular fee increases are necessary. With no concept of overhead costs, the team may assume that all fee increases go directly into the dentist's pocket, which is not true. Explain that the fee increases are there to keep up with the increasing costs of supplies, services, and updating equipment.

The following factors must be considered when fees are set:

- Professional fees in the area, although collusion with other dental practices is illegal
- Level of desired fees for the practice (high, mid-, or low range) and the type of patient the doctor desires to treat
- Cost of operations
- Profit after debt service

Fee increases or fee cuts have a significant impact on practice income and profit, as demonstrated in Figs. 31.2–31.4.

## ACCOUNTS PAYABLE

Accounts payable is the total amount of money the practice owes for goods and services received. Bills should be paid no

Profit Margin	Fee Increase	% Loss of Production
25%	5%	17%
25%	10%	29%
25%	20%	45%
30%	5%	14%
30%	10%	25%
30%	20%	40%
35%	5%	13%
35%	10%	22%
35%	20%	36%
40%	5%	11%
40%	10%	20%
40%	20%	33%

Fig. 31.3 Percent loss of production related to fee increase to maintain profitability.

Profit Margin	Fee Cut	% Production Increase Required
25%	10%	67%
25%	20%	400%
25%	30%	not realistic
30%	10%	50%
30%	20%	200%
30%	30%	not realistic
35%	10%	40%
35%	20%	133%
35%	30%	600%
40%	10%	33%
40%	20%	100%
40%	30%	300%

Fig. 31.4 Fee decrease related to increase in production to maintain profitability.

more frequently than twice a month after statements are checked against invoices.

An *invoice* is an itemized list of goods received with each supply shipment, and a *statement* is a summary of all invoices for that month. Paying accounts regularly from statements rather than from invoices can help avoid mistakes, such as paying the same bill twice, and ensure that the practice maintains an excellent credit rating.

Utilize a well-organized chart of accounts in an accounting software program to track expense categories and an overhead budget.

## RETIREMENT PLANNING

The time for a dentist to begin planning retirement is the day he/she begins to practice, because the only financial benefits he/she can count on in retirement will be what he/she has saved and Social Security. Monies from a practice sale can be unpredictable depending on the timing of the sale and the state of the economy.

A financial advisor can help the dentist choose from among many plans with various tax benefits, such as an individual retirement account, a 401K, pension and/or profit-sharing plan, and so on. The earlier one begins, the greater the accumulation of wealth at retirement, due in large measure to compound interest. Compound interest is the concept of adding accumulated interest to the



principal.<sup>2</sup> The rule of 72, a simple way of illustrating the growth potential of compound interest, is a useful tool for calculating an approximation of the time needed to retain an investment before it doubles in value. You can find an example of the rule online.<sup>3</sup>

## Part 4: Team Dynamics

### DOCTOR LEADERSHIP

Leadership is a great challenge for many doctors and is a skill that requires development. Many doctors are unaware of how their leadership actions impact their level of stress, job satisfaction, and profits. Well-developed leadership skills create more efficient teams, positive practice cultures, and higher employee satisfaction. To be a great leader, a doctor must consistently and successfully perform the following leadership actions:

- Define practice vision and share with the team
- Identify 3–5 core practice values
- Empower and encourage the team
- Communicate efficiently and effectively
- Provide strong fiscal management
- Monitor practice goals and budget

### Assume the Leadership Role

All teams need a leader or they will not know where to go or what to do. A doctor can delegate some leadership responsibilities but cannot abdicate the leadership role. In the book *The Leadership Challenge* by Kouzes & Posner,<sup>4</sup> leadership is defined as:

- A process ordinary people use to bring forth the best from themselves and others
- A set of distinct practices that leaders exhibit when they are doing their best
- An understandable and a universal process
- The authors also go on to say that success depends on your ability to lead people:
  - To set and communicate a clear direction
  - To motivate
  - To provide coaching and feedback so that they will succeed in their goals

A strong commitment to good leadership is an essential ingredient for practice success.

### Constantly Evaluate if Things Can Be Done Better. Do Not Settle For the Status Quo

Strive to improve efficiency, systems, and the team. There will always be new and better technology and systems.

### Have Excellent Advisors, Mentors, and a Support System

- Advisors include an accountant, attorney, banker, insurance advisor, practice management consultant, computer/technology expert, and investment counselor/retirement planner.
- Good mentors are invaluable and usually free. Find successful professionals who would be willing to share their knowledge. Create a support system with colleagues

with whom you can meet regularly for lunch or call for advice.

- The American Dental Association (ADA, [www.ada.org](http://www.ada.org)) has a variety of publications pertinent to practice management issues. Of particular interest is *Frequently Asked Legal Questions*, available through ADA Member Services.<sup>5</sup>
- The American Academy of Pediatric Dentistry (AAPD, [www.aapd.org](http://www.aapd.org)) has a Leadership Institute.

### Lead by Example and Create a Healthy Practice Culture

Many doctors are unaware of the importance of company culture and employee engagement. Great company culture happens intentionally. A deliberate culture shift creates a more meaningful place to work and better patient and parent experiences. This leads to increased productivity, and therefore, an increase in profits. A doctor's behavior sets the standard and defines this culture; therefore, he/she must hold him/herself to high standards and always behave in ways that set a good example for the team.

### Healthy Practice Culture.

- Team shares the doctor's values and live them each day in the office.
- Team members feel supported, encouraged, and confident in themselves and their positions.
- Open and honest communication; team members give feedback to each other.
- Expressing a different opinion is not feared. A discussion between parties can take place and a solution or compromise can be reached.
- Employees are not afraid to take risks and try new things. They are not fearful of severe admonition, but are comfortable in taking ownership of the mistake and learning from it.
- Employees praise and support each other.
- Gossip is not tolerated.
- Problem employees are held accountable in a timely manner to improve their behavior, or they are removed.
- Problem patients/parents are removed from the practice.
  - Each state and/or dental board has certain laws that govern the dismissal and/or transfer of a patient, including charging for radiographs and records. The dentist must weigh the advantages and disadvantages of his or her actions and responses in each individual case and seek legal advice if necessary. Everything should be documented because any notes written into a patient's chart could, in case of a lawsuit, be read aloud in court. A dentist or team member should never argue with or belittle a patient or parent. In addition to concerns regarding the doctor/patient relationship, such actions can lead to negative public relations, may well cause the patient to leave the practice, or could trigger a lawsuit.

### Be "People Smart": Understand People's Different Behavioral Traits and Strengths

Managing team members effectively and with low stress is one of the biggest challenges doctors face.

Being “people smart” is a powerful leadership tool that helps a doctor be a better leader, manager, and employer by understanding:

- People possess different mixtures of behavioral traits and how this affects their job performance
- A person’s strengths and limitations to be able to hire and coach correctly
- Each person’s motivators that will empower him/her to be more productive and experience greater job satisfaction.

After extensive research, Professional DynaMetric Programs (PDP; [www.pdpglobal.com](http://www.pdpglobal.com)),<sup>6</sup> a worldwide leader in top-of-the-line behavioral assessment solutions for businesses, has defined the four behavior traits as *Dominance* (take charge), *Extroversion* (people), *Pace* (patience), and *Conformity* (systems). Each trait has high and low behavioral intensities. One of these four high traits will be a person’s strongest and will dictate 50%–70% of his/her natural behavior and responses. It is almost like people come from four different “planets,” with each “planet” having its own natural way of behaving and communicating.

After learning about the four “planets” and work style approaches, a doctor has a better insight as to why employees function the way they do.

#### **High Dominance (Take Charge Trait).**

- Can take charge, likes to accomplish goals, and is comfortable with risks.
- Communication style is short and to the point, can often be interpreted as blunt.

#### **Low Dominance.**

- Does not want to be in charge, looks for strong leadership.
- Agreeable.

#### **High Extroversion (People Trait).**

- Outgoing, enthusiastic, motivating, prefers to interact with people, and makes others feel welcomed and comfortable.
- Communication style is persuasive and enjoys talking.

#### **Low Extroversion.**

- Does not mind working alone.
- Quiet with people he/she does not know.

#### **High Pace (Patience Trait).**

- Focuses on work output. Prefers routines and working on one thing at a time, does not like changes.
- Communication style is warm and friendly and is careful to avoid confrontation.

#### **Low Pace.**

- Likes change and fast pace.
- Can easily multitask.

#### **High Conformity (Systems Trait).**

- Prefers structured and standard operating procedures, concerned with accuracy.

- Communication style is guarded, cautious, and exacting.

#### **Low Conformity.**

- Can see the big picture and does not need a pre-set structure in which to work.
- Independent, wants to live by his/her own rules.

#### **Work-Style Approaches**

There are three ways people approach getting a job done. Many times doctors do not understand why their employees wait to be told what to do. This can easily be explained by understanding the three work-style approaches. It is wise to hire a person with a thrust work style for the leadership positions in your office.

#### **Thrust.**

- An inner drive to push quickly to get the job done.
- Initiates and completes a project or task.

#### **Steadfast.**

- A coined word of PDP, from steadfast and tenacious.
- An inner drive that gets the job done in a steady, persistent manner.
- Initiates and completes a project or task.

#### **Allegiance.**

- Looks to an outer-directed source (supervisor) to be told what needs to be done.
- Supports completing a project or task, rarely initiates.

#### **Hold Employees Accountable**

Many doctors find it difficult to talk to an employee about poor job performance issues, such as skill level, attitude, tardiness, absenteeism, and/or teamwork. Most doctors either avoid this necessary leadership skill or do it poorly because it feels confrontational, and they simply do not have a format to follow, thus missing a valuable coaching opportunity with their employees.

When a doctor does not hold employees accountable for proper job performance and attitudes, it becomes demoralizing, and the good workers will lose respect for the doctor. Team morale and productivity drop, and eventually the good workers get frustrated and leave for other jobs. Consequently, this causes the team to “dumb down” to the manipulative, low-functioning employees with bad attitudes and poor work ethics, which makes coming to work each day a nightmare of endless problems. However, when employees are promptly held accountable for proper job performance, the doctor’s reward will be an enjoyable, high-functioning team that supports the practice vision, and everyone looks forward to coming to work each day.

#### **Motivate with Praise, Appreciation, and Recognition**

- Encourage employee development and growth. Know what each employee’s goals and motivators are and try to create them in the workplace.

- Make employees feel that they are part of the team and that they matter and make a positive difference.
- Give recognition and a praise/strength compliment for a job well done at least once a week to each employee.
- Keep a gratitude jar in the employee break room for team members to write down positive actions they see in the office and share one with the team each day during morning meeting.

### Conflict Resolution

Conflict, negative attitudes, and poor behaviors weigh heavily on dental practices. Unresolved conflict causes tension, anxiety, poor productivity, and interferes with patient care. Conflict becomes harder to resolve the longer it is ignored, so it is important to address conflict situations immediately before they escalate. The most impactful way to handle conflict situations is early and directly. To handle conflict effectively, the doctor must follow these actions:

- Identify there is a problem. The doctor is typically the last to know there is a problem in the office. Once a problem reaches the doctor, it has likely been occurring for a while.
- Meet one-on-one with the team member(s) involved in the conflict and address the situation. Identify if this behavior is the root of a bigger issue. Is the employee feeling frustrated or unappreciated?
- Explain how their behavior affects others in the office and document this encounter as a verbal request for performance change and place this documentation in the employee's file.
- If a team member is unable to meet the expectations outlined in the verbal request for performance change, present them with a written request for performance change. Depending on the situation, a team member may immediately be placed on probation, or should be notified that if this were to happen again, termination could be the next step.
- Extreme behaviors, such as bullying, are not to be tolerated and those team members should be removed immediately.
- A positive, productive team creates a healthy and profitable practice. A positive attitude is contagious and helps to create a vibrant practice culture. Set clear standards and guidelines from the beginning with an up-to-date employee Manual. Keep open communication with your team and ensure they possess the necessary training and resources required to be successful.

### Hold Regular Meetings

Clear and consistent communication is the only tool a team has to improve how its members work together. Therefore, teams should meet regularly to discuss the status of the practice—what is working, what is not working, and how they are going to fix it—resulting in increased productivity and reduced stress.

Meetings should take place in the office and not in a restaurant over lunch. It is more difficult to discuss confidential practice information (production and collection status) and/or address team issues in a public atmosphere.

### Types of Meetings to Hold

- Morning meetings
  - Set the tone and level of productivity for the day.
  - Help the team focus on how to get through the day's schedule with reduced stress and increased production by exchanging important team and patient information relating to the schedule (Fig. 31.5).
- Monthly team meetings
  - Discuss work patterns between departments and team members.
  - Practice monitors are discussed to see if goals are met and problem solve what new actions will be taken if they are not.
  - Educate team members on any new information pertaining to the practice specifically or pediatric dentistry generally.
- Quarterly department meetings
  - There can be up to four departments in a pediatric dental office: front office, clinical, marketing, and leadership (if there is an OM, a leadership team, and/or more than one doctor). Each department meets quarterly with the doctor and OM to discuss and problem solve department-specific issues, job duties, and system changes.
- Monthly marketing meeting
  - Evaluate marketing efforts and decide on new actions.

### Celebrate Success

It is important to recognize the team's efforts and celebrate achieving milestones and goals. Celebration activities can be a dinner or lunch or a surprise shopping afternoon (doctor gives everyone a cash amount that he/she must spend on him/herself or return the unspent money at the end of the afternoon).

## EMPLOYEE MANAGEMENT

### Personnel Needs

A personable, professional team is vitally important for practice success. The dentist must invest time, effort, and money to hire, train, and retain quality individuals who can be developed into a high-performing team. A team of committed professionals, working together, focused on the patients and the practice, can make the difference between an excellent and a mediocre practice. Therefore, team development is a sound investment in any practice.

Before becoming an employer, the dentist must be aware of state and federal regulations concerning hiring, employment policies, including Occupational Safety and Health Administration (OSHA) requirements, employee records maintenance and retention, employee discipline and dismissal, and so on. All employment applications, other forms and tests used in the hiring process, and employment policies described in the office manual should be reviewed by an attorney who is familiar with state and federal laws.

Initially, the new practitioner may need to hire only one or two team members. If only one individual is hired at first, a second employee should be added when patient flow increases to the point where this person can no longer assist at the chair and handle the front office (e.g., collect fees, make appointments, answer the telephone by the third ring, prepare and send statements on time, marketing, and pursue broken/unscheduled appointments). When the dentist treats recare patients more than



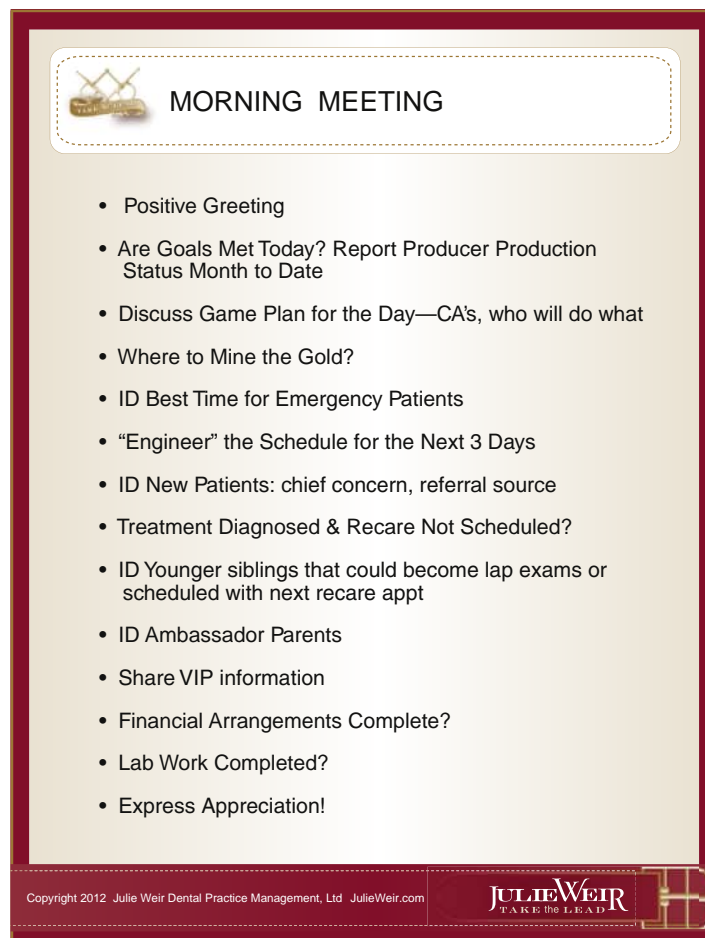


Fig. 31.5 Morning meeting agenda. (©Julie Weir & Associates Management Consulting.)

8 hours per week, a hygienist or coronal polishing assistant, depending on the state practice act, should be hired. Many dentists will eventually make the first person who helped them open their practice their OM. This is not wise as these people often do not exhibit the leadership skills necessary to manage a successful dental practice. Be sure that the person you hire to manage your investment is good with numbers and people.

### Office Manual

An office manual should be completed before employees are hired so that there is no confusion about the rules the employees are expected to follow and the benefits they will receive. An office manual outlines the duties, obligations, and mutual expectations of the employee and employer and clarifies office policies, employment procedures, benefits, training methods, and office paperwork. Each employee should read the manual and sign a form attesting to the fact that he/she has read and agreed to the policies to prevent misunderstandings. This document should be placed in the employee's file. The manual should be updated as policies and benefits change in the practice, along with documentation confirming that employees have read the updated version. Prototypes of office manuals are available in electronic versions to assist in the process and can be customized to the practice and the state's labor laws. The

attorney for the practice should review the manual before it is implemented.

### Personnel Records

Personnel records are important documents, charting the history of the employee-employer relationship, just as a patient's chart is a documentation of the patient-dentist relationship. If a problem arises with an employee (e.g., a charge of wrongful dismissal in case of termination), the record will serve as proof that the dentist correctly discharged employer responsibilities.

Personnel records for all employees should be identical in appearance, consistently maintained, kept confidential in locked files, and maintained for the duration of employment plus at least 30 years following an auxiliary's departure. Employee medical records (see below) must be maintained in individual locked files separate from other personnel records for the duration of employment plus 30 years and include all appropriate forms with pertinent data.

A comprehensive employee record could include the following:

- Employee's name, address, telephone number, and Social Security number
- Completed job application, résumé, and interviewing notes

- Authorization for a background check and reference checks
- Offer of employment
- Employment tests given as part of the hiring process
- Date of employment, wage and benefits information
- Licenses or certifications
- Federal and state income tax and employment eligibility verification; W-4 and I-9 forms
- Spouse's name, employer, and telephone number
- Person to contact in case of emergency
- Training records, including dates of training, contents of the session, and the name and qualifications of the trainer for OSHA training and cardiopulmonary resuscitation training
- Logs of unsafe incidents
- Employee medical records, including injury or exposure to harmful substances, and record of hepatitis inoculation, or signed and dated refusal of the vaccine, must be maintained in separate locked files
- Performance appraisal forms and notes from one-on-one discussions, signed and dated by the employee and the dentist; verbal and written requests for performance changes
- Absentee records
- Continuing education course records
- Record of termination, including last date of employment, and the employee's letter of resignation or notes from the dismissal conversation if the employee was fired.

### Standard Operating Procedures Manual

The standard operating procedures, or SOP, manual defines each important task, including what it is and how to do it, that takes place in the practice so that the task can be successfully repeated by others. This becomes a good training tool with new team members or a reference if a team member leaves and the task must be completed.

### Interviewing, Hiring, and Training

Jim Collins'<sup>1</sup> quote from *Good to Great* is famous and powerful in its logic: "Get the right people on the bus, the wrong people off the bus, and the right people in the right seats." Successful entrepreneurs find the right people by following an organized systematic approach for hiring. Many wrong hires occur because important steps are left out. Statistics show that it costs a business a minimum of one and a half times an employee's annual salary when an employee has to be replaced. Therefore, it is imperative to do the best job possible when hiring.

Improve your chances of hiring the right person by following these steps:

#### Create a Job Description.

- Identify the specific job duties and traits/strengths needed for the job to be performed effectively. Use behavioral assessment surveys to help put the right person in the right job by picking the candidate with the right strengths.

#### Write an Effective Ad.

- Realize that the best workers may often already be working for someone else, but they may not be

satisfied. Rather than placing the standard ad that is worded like everyone else's, write an ad that includes motivators for the type of person you would like to hire.

#### Have Applicants Email Their Resumes to Your Office.

- Having applicants email their resumes allows you to prescreen applicants and provides an indication of their ability to follow directions.

#### Narrow Your List of Applicants Through Telephone Interviews to Save Time.

- Applicants can look good on paper, but they can have poor interpersonal and verbal skills, manners, etc.
- Review job requirements and the applicants' skills and experiences.
- Discuss their salary and benefits requirements, geographic location, and available work hours to see if they are compatible.

#### Interview.

- To maximize efficiency, a well-trained team member, preferably your OM, may conduct the initial interview. If the candidate is promising, employment tests, a tour of the office, an introduction to other team members, and a brief conversation with the dentist should be a part of the first interview.
- Ask the applicant to complete the following:
  - Employment application
  - Behavioral assessment survey (trait profiling)
  - Authorization for background check
  - Authorization for reference check
- Show him/her a written job description and discuss the duties.
- Prepare a list of interviewing questions.
  - These questions should explore the following traits: initiative, organization, conscientiousness, effective communication, ability to work well with others, technical or business training and experience, and ability to apply previous training and experience to the job. If questions are skillfully posed, an applicant's answers will indicate strengths or weaknesses in these areas.
  - The interviewer should talk less than 25% of the time. The purpose of the interview is to understand the applicant and his or her potential for the job. Excessive talking by the interviewer limits the time and opportunity that the applicant has to tell about personal abilities and experiences.
  - Do not help the interviewee answer questions. Let pauses happen. The applicant may be thinking during the silences, and the interviewer can see how well and quickly the person responds.
  - Ask open-ended questions. Do not ask questions that can be answered with "yes" or "no." If the interviewee begins answering "yes" or "no," ask him or her to explain or expand on the answer.
  - Never argue with an applicant. Maintain poise and remember that you, the interviewer, are in control.

**Hire Based on Behavioral Strengths and Traits, Not Just Skills.** This is one of the most important guidelines when a new employee is hired. You can train a new employee for specific job skills, but it is very difficult to change someone's "personality" if it is not the right match for the position available.

- Ask applicants who pass the initial interview to take a behavioral assessment survey so you can determine if they have the strengths and traits needed to be successful in the job. The PDP has very informative surveys and hiring tools ([www.pdpglobal.com](http://www.pdpglobal.com)).

### Check References.

- Checking references is absolutely essential. Many people know how to "package" themselves to cover up past problems. While employers might be willing to confirm employment dates only, you can often determine their overall satisfaction with the employee by their tone of voice and other comments.
- If the applicant has worked in a dental office, be sure to speak with the doctor. Describe your perceptions and observations of the applicant to determine if they are correct. Ask the doctor if there is anything else he/she would like to share with you. One of the most effective questions to ask the previous employer is: "If you had a position open up in your office, would you rehire this person?" This almost always provides a strong indication of the employer's level of satisfaction with the employee.
- Always have signed permission to call references. Never call an applicant's current employer unless he/she has given permission. Not only could it cost an applicant his/her job, it is also illegal.

### Perform a Background Check.

- If the applicant's references are positive, be sure to complete a federal criminal background check. Embezzlers move around from office to office.

### Conduct Working Interview.

- Ask the applicant to come in for a half-day working interview. If the applicant will be answering phones, interacting with patients or using the software, then you must classify the applicant the same as you would for a new hire. This includes filling out employment documents, such as an I-9 and W-4, and you will be required to pay all appropriate payroll taxes. This does not apply for candidates coming to your office to observe only.
- Observing the applicant in the office will provide an indicator of the applicant's current skills, ability to work with others, ability to follow directions, speed of work, and adaptability to your unique work environment.

### Lunch Out and the Doctor Pays.

- If the working interview goes well, suggest that the applicant have lunch with the team members with whom they would be working most closely to get to know each other better. The doctor should pay for this lunch but not attend. Ask the team to observe and give feedback on the applicant's politeness, manners, and personality outside the office. They should also assess the applicant's interest in the job itself, not just the paycheck and benefits.

### Ask the Team's Opinion About Hiring the Applicant.

- Is the team comfortable with this person and willing to let him/her into the "dental family?" No matter how qualified the applicant, there will be problems in the office, and the new hire will eventually leave if the team is unsupportive of him/her.

### Proper Certification.

- Make verification a condition for employment. It is not uncommon to find dentists using assistants who had indicated they were licensed to take x-rays but who actually are not.

### Offering the Applicant a Position.

- If the applicant is to be hired, the dentist should offer the job using the term *full-time* or *part-time* employment and should avoid using the word *permanent*, either orally or in writing. Use of the term *permanent* denotes continuous work with a contractual understanding, regardless of problems that might develop later. If dismissal should become necessary, the employee might claim wrongful dismissal if promised permanent employment.
- If the applicant will not be hired following the first or second interview, he or she may be told at that time or notified within 1 week of either interview. If an applicant is rejected, maintain all applications, test forms, and other paperwork for at least 1 year in case a complaint concerning unfair hiring practices is filed by the rejected applicant.
- If testing is part of the application and interviewing process, testing must be standardized, that is, all applicants must be given identical tests.

**Orientation and Training.** In *The One Minute Manager*, a book long-favored by business managers, Blanchard and Johnson<sup>7</sup> wrote, "Most companies spend 50% to 70% of their money on people's salaries, and yet spend less than 1% of their budget to train their people. Most companies, in fact, spend more time and money on maintaining their buildings and equipment than they do on maintaining and developing people." A new employee must be made to feel welcome and a part of the team. Orientation on the first day of employment and a written training schedule to be followed the first 6–8 weeks should be part of this process.

**Orientation.** A training/benefits waiting period may be the first 60–90 days of employment, during which time the dentist determines whether there is a match between office needs and a new employee's skills and personal style. Use of the term *training/benefits waiting period* rather than *probationary* or *trial period* denotes the importance of performance to the new employee, emphasizing that this is considered a time to work diligently, to strive to learn as much as possible.

- Ask the employee to read the office manual and sign a statement that he/she has read and agrees with the office policies.
- Review salary and benefits package.
- Share and discuss the practice's patient and team mission statements, what they mean, and how to "live" them in the office.



- Communicate your “practice culture”—who is in charge of what, to whom the new employee reports, attitudes and communication (those expected and those that are not), as well as your practice philosophy and beliefs.
- Review the written job description.
- Create a list of duties in which the new employee must be proficient. Mark the duties off as the employee demonstrates acceptable ability.
- Introduce the new employee to all team members.

### Encourage Team Relationships.

- Arrange to have different team members who will be working closely with the new employee go to lunch with him/her.

**Training Method: Tell-Show-Do.** Much of the responsibility for training new employees can be delegated to current team members. A well-trained veteran team member may become a training coordinator, available to instruct the new employee, answer questions, and check progress. Although one person may efficiently coordinate training, all other team members and the dentist should also be involved in the process.

- What do you know about this?
- What are your strengths and areas in which you can improve?
- How can I best teach you?
- How do you like to learn something new?
- Tell them what the “importance” of each function is and how it fits into the “big picture.”
- Tell them the “benchmark” of acceptable performance for each job function they have.
- Ask them to role-play as much as possible. They will not “own” the new behavior until they have done it themselves a number of times.

**Regular Coaching.** Conduct a 5- to 10-minute debriefing with the employee at the end of each day for the first 2 weeks (every other day is sufficient for weeks 3 and 4). Finally, the supervisor should conduct a 30-day review.

- Tell him/her the following:
  - What he/she did well that day
  - What he/she needs to do differently and how
  - Where his/her focus should be the next day
- Ask him/her the following:
  - What was your biggest struggle today?
  - What would you like me to help you with tomorrow?
  - What did you learn today that affected you the most?

### Job Descriptions

- Office Manager or Practice Coordinator
- Front Office Coordinator
- Clinical Coordinator
- Front Office Team
- Clinical Assistant
- Flow Coordinator
- Sterilization Assistant
- Hygienist
- Hygiene Assistant

**Office Manager or Practice Coordinator.** The doctor of a small practice can perform many of the employee management and business administrative duties. Once a team reaches a level of five to six or more employees or has more than one location, a doctor should consider having an OM. Sometimes the same person can function as the OM and the front office coordinator. A good OM has the mindset that he/she is an extension of the doctor and is vested in the success of the practice. Doctors should realize they are putting their financial security and future in the hands of their OM; therefore this person must be strong and effective to help run the practice efficiently. The following outlines may be edited to fit the need of any office. See Fig. 31.6 for a schedule of front office tasks.

#### GENERAL DUTIES.

- Represent office and doctor
- Make sure the facility presents well and is in working order
- Help the doctor with administrative duties
- Handle patient/parent issues and complaints
- Order necessary front office supplies
- Make sure that computer backup is done daily
- Oversee that bills are paid in a timely manner
- Answer parents’ or patients’ questions concerning office procedures, financial matters, and so on
- Maintain office calendar
- Work to free the dentist from administrative details
- Handle correspondence for the dentist when requested

#### SYSTEMS MANAGEMENT.

- Understand all of the goal numbers of the practice and how to monitor them
- Work toward meeting production goals; monitor total practice and individual producers
- Work toward meeting collection goals
- Work toward meeting new-patient goals
- Oversee the daily and monthly production monitor
- Oversee all front desk systems and hold the appropriate front office team member accountable for the performance of each system
- Oversee the clinical coordinator
- Step in as a front office team member when needed
- Communicate the status of practice operations with the doctor weekly
- Oversee that month-end reports are run and review them for accuracy
- Make sure that each month is closed out in the practice management software
- Print end-of-year reports
- Oversee that deposits are made daily
- Oversee internal/external marketing tasks

#### EMPLOYEE MANAGEMENT.

- Hold employees accountable for proper job performance and appearance
- Manage employee requests for time off
- Enforce office policies
- Maintain a file for each employee
- Maintain updated personnel/office manual
- Give verbal praise and appreciation to employees
- Encourage employees’ growth and development
- Conduct timely performance reviews of employees

## Front Office Tasks

### Basic Tasks

Answering the phones	Greeting patients	Checking patient eligibility	Reviewing patient paperwork
Oversee office equipment/supplies	Scheduling next appointments	Checking out patients	Entering patient insurance
Sorting the mail	Cleaning the office	Manage telephone greetings; Change the voicemail message when needed	

### Daily Tasks

Balancing deposit	Sending out claims	Entering insurance payments	Processing CareCredit
Sending out new-patient packets	Sending out thank you notes to new patients	Sending out thank-you notes to the patients who have referred patients	Sending out thank-you notes for online reviews
Settling the credit card machine	Pre-authorizations for insurance	Answer e-mails	Confirm patients
Adjust the schedule accordingly	Checking for EFT payments	Checking patient communication software reports/markings patients confirmed	Daily Monitor
Track treatment diagnosed			

### Weekly Tasks

Check outstanding claims	Send out statements	Collection calls	Collection letters
Call on unscheduled treatment plans	Call past due recare patients	Check supplies	Enter new-patient paperwork
Scan in paperwork	Office walk-through inspection		

### Monthly Tasks

Month-end reports	Purge magazines	Send out recare cards	Patient purge
Patient credit report and letters	Enter and update PPO fee schedules	Monthly team meeting	

**Fig. 31.6** Front office tasks. (©Julie Weir & Associates Management Consulting.)

- Maintain appropriate staffing coverage
- Manage new hires and exiting employees
- Oversee employee time cards and payroll distribution
- Administer and interpret employee benefits

#### **LEADERSHIP DUTIES.**

- Model leadership behavior
- Support doctor leadership
- Exhibit professional behavior
- Set appropriate example for employees to follow
- Keep stress level low in office
- Keep morale high in office
- Direct the morning meeting, a brief meeting to plan the day

**COORDINATORS.** If the practice is large enough, it can also have a clinical coordinator and a front office coordinator. A coordinator is an experienced team member who also shows leadership skills and enjoys using her or his initiative. The following outlines may be edited to fit the needs of any office.

#### **FRONT OFFICE COORDINATOR DUTIES.**

- Overall, coordinate the front office; oversee scheduling, collections, insurance, customer service, running and working reports
- Meet regularly with the doctor and OM
- Suggest front office staffing needs
- Help evaluate front office team performance
- Help monitor practice statistics
- Monitor daily deposits

#### **CLINICAL COORDINATOR DUTIES.**

- Overall, coordinate clinical area
- Meet regularly with the doctor and OM
- Suggest clinical staffing needs
- Help evaluate clinical team performance
- Coordinate office-wide OSHA training
- Direct and maintain clinical team work schedules
- Assign collateral duties to clinical team members
- Help schedulers with scheduling questions
- Direct flow of patients through the clinical area

- Make certain that all systems are consistent, e.g., data entry, paperwork, laboratory delivery, etc.
- Help plan and maintain clinical area budget
- Supervise clinical supply inventory and ordering

### Front Office Team Duties

#### PATIENT MANAGEMENT.

- Greet each patient by name
- Answer phone by third ring
- Check messages, return calls
- Announce patients to back office
- Tell patients that the practice always welcomes new patients
- Promote the practice outside of the office, as appropriate

#### SCHEDULING.

- Schedule to goal, fill openings, and keep the schedule productive
- Confirm all patients' appointments 2 days in advance
- Review patients' charts (electronic health records or EHR) as necessary the day before their appointment
- Print schedule for next day and 3 days out for the morning meeting; write the producer production totals on each schedule
- Enter treatment plans, discuss with patient, secure financing, sign consent form(s), and schedule appointment(s)

#### COLLECTIONS.

- Collect all estimated portions, deductibles, and fees
- Verify insurance benefits for patients and send predeterminations, as needed
- File claims with insurance
- Follow up with outstanding insurance and accounts
- Post all payments received
- Process statements

#### TREATMENT TRACKING OF RECARE AND UNSCHEDULED RESTORATIVE TREATMENT.

- Manage the patient communication software (PCS), e.g., Yapi, RevenueWell, etc.
- Make phone calls to parents of children who are due for recare visits and keep the overdue recare report current
- Ensure that the PCS mails the recare postcards to those who are due for an appointment but for whom there are no email addresses since email contact is not possible.
- Make phone calls to parents of children who have an unfinished treatment plan and keep the report current

#### MISCELLANEOUS.

- Check patients in/out
- Note changes to patients in chart
- Inactivate charts as needed
- Keep the front office, reception area, and bathroom in order
- Close out the preceding day (deposit, day sheet, credit cards)
- Initiate computer backup

#### MONTHLY DUTIES.

- Generate billing statements
- Print month-end reports, production/collection, referral
- Close out the month in the computer

### Clinical Assistant Duties.

- Patient care
- Chart review
- Set up rooms for procedure

- Seat patient and prepare patient for treatment
- Assist dentist during any procedures
- Provide patient education and postoperative instruction
- Dismiss patient to front office team
- Take x-rays
- Follow infection control procedures
- Perform basic sterilizing techniques for instruments
- Sterilize treatment room after use
- Stock treatment rooms with supplies
- Pour and trim models
- Perform lab work
- Maintain equipment
- Assist other team members
- Tell patients that the practice always welcomes new patients
- Promote the practice outside of the office, as appropriate

**Flow Coordinator Duties.** A flow coordinator is a clinical assistant who also watches the overall schedule and directs the doctor and other assistants to keep the schedule flowing on time.

### Sterilization Assistant.

- Turns over chairs and sterilizes instruments
- Provides backup for the restorative and hygiene assistants

### Dental Hygienist Duties.

- Provides patient care: prophylaxis, radiographs, fluoride treatments, sealants, impressions
- Reviews radiographs, teeth, and soft tissue for decay and anomalies and informs the doctor of findings
- Charts results
- Reviews charts
- Sets up room for procedure
- Seats patient and prepares patient for treatment
- Assists dentist during examinations
- Provides patient education
- Dismisses patient to front office team
- Follows infection control procedures
- Performs basic sterilizing techniques for instruments
- Sterilizes treatment room after use
- Stocks treatment rooms with supplies
- Maintains equipment
- Assists other team members
- Assists front office with the recare system as needed, if time allows
- Tells patients that the practice always welcomes new patients
- Promotes the practice outside of the office, as appropriate

**Hygiene Assistant Duties.** A hygiene assistant assists the hygienist and/or coronal polishing assistant with the flow of recare patients. For every two columns of recare scheduled for 30-minute appointments, one hygiene assistant is needed to help keep the schedule on time.

- Greets patient and parent
- Confirms medical history and treatment
- Takes radiographs
- Seats patient
- Turns over chairs and instruments
- Assists doctor with examination and charting



- Works to educate patient
- Escorts parent/patient to front desk

**Performance Reviews.** A well-done performance review is a powerful leadership tool for the doctor and a great learning experience for the employee. Team members must know what they are expected to do, how to do it, and what the criteria are for an acceptable or, better yet, outstanding job performance. Employees want to feel that their presence is valued and contributes a positive difference that is recognized.

The following steps will make the performance review a positive learning experience:

- Set aside 1 day per year for all annual reviews instead of trying to do a review on each employee's employment anniversary.
- Treat the review like any other important business meeting. Set aside at least 45 minutes. Do not reschedule this meeting; this is a significant event on your employee's calendar.
- Prepare for the meeting ahead of time. An evaluation form is completed, and talking points are prepared by the doctor on the following:
  - Employee accomplishments since the last review
  - Employee strengths that the doctor appreciates
  - New duties and levels of job performance
- Two weeks before the review date, the employee is given the review form for self-evaluation of his/her performance and then returns the form to the doctor 1 week prior to review. This advance information gives the doctor time to understand the employee's view of his/her level of performance and helps the doctor prepare their discussion points and coaching for improvement.
- It is also beneficial to use a form that asks the employee to identify goals and challenges for the next year. Discussing the team member's opinion of his or her own performance often makes the appraisal more meaningful. Each job should have understandable benchmarks of acceptable performance, which must be communicated to the employee. For example, the person in charge of collections should be collecting 98% or more of collectable fees with an "accounts receivable to collectable fees" ratio of 1:1, and not more than 18%–25% of the accounts receivable should be over 90 days. If any one of these criteria is not being met, then the employee will know exactly where to concentrate his/her efforts to improve. Benchmarks can also be set for scheduling to goal, working recare and unfinished treatment plans reports, and clinical performance.
- Job skills and work performance should be reviewed separately from salary. A conversation that combines performance review with news of a raise interferes with the team member's concentration. An employee may be so interested in hearing about a salary increase that setting goals for performance improvement is relegated to a secondary level of importance.
- It should be clearly communicated to employees that annual raises and/or bonuses are given for making themselves more valuable to the practice through improved skills and a motivated attitude, not for just being there another year.
- During periods of economic difficulty, instead of annual raises, quarterly bonuses can be tied to increased practice

performance over the previous year, or monthly bonuses on a 3-month rolling average.

### Coach to Improve Performance

1. Ask yourself: As their leader, have I provided the appropriate training, time, and tools for them to perform adequately? If not, provide these items and see if the desired job performance is achieved.
2. Speak directly to the employee. Do *not* complain to other employees about the poor performer. This is gossip and destructive to the team.
3. Tell them what they are doing well or what you value in their performance. People listen better when they feel that the appraiser recognizes their strengths rather than only their deficiencies. Use the term *opportunities for growth* rather than weaknesses when discussing areas to be improved.
4. Tell them specifically what you want done differently.
5. Tell them specifically how you want it done differently.
  - Most people respond best when asked to concentrate on no more than three or four areas for development.
6. Ask them, "Is this something you think you can do?"
  - If they answer no, ask them why.
  - The dentist may offer to help the employee improve in certain areas through additional training and continuing education courses, thereby giving the team member a sense of support.
7. Ask them, "Is this something you want to do?"
  - If they answer no, ask them why. Determine if you are dealing with insubordination or lack of motivation in seeing the importance of the task.
8. Establish a time frame for improvements; between 1 and 3 months is usually appropriate. The dentist and the team member should meet frequently in the interim to assess improvements.
9. If the behavior/job performance is strongly lacking (e.g., consistently arriving late, abusing sick leave, breaching confidentiality requirements, or unable to perform at required skill levels), tell the employee:
  - He/she needs to know that his/her job is in jeopardy and that he/she is on probation until job performance improves.
  - If the requested change does not take place, he/she will be terminated.
  - Your goal is to help every employee reach his/her full potential, but it is up to the individual to choose to be successful in your practice.
10. *Document all conversations*, including dates, times, and information exchanged at all meetings with employees, when job performance is discussed. This is important for reference in the event the employee is terminated.

### Dismissal

Dismissal of an employee is one of the most difficult tasks a dentist may face. There are, however, processes that can make a dismissal less stressful. Dismissal usually happens because of incompetence in job performance or unacceptable behavior such as patient abuse, sabotage, theft, harassment, or substance abuse on the premises. Problems often arise when an employee loses interest and therefore effectiveness and/or efficiency in her or his responsibilities. Behavior and performance problems must be addressed;

simply ignoring the situation will not make it go away. The dentist and team member should discuss the problems and ways they can be rectified. If the 10 steps outlined in the previous section “Coach to improve performance” have been reviewed and the employee will not or cannot improve behavior or achieve required skill levels, dismissal will be necessary.

- Prepare a document stating that the employee is being terminated and why. Check with an employment attorney to be sure you are following your state’s labor laws. After this statement is explained, the employee and the dentist should sign and date the statement, and it should be retained in that individual’s personnel file.
- If an employee refuses to sign and date notes from any discussion, the dentist should so note on the statement and sign and date the document him/herself. Such a note is an acceptable record that the discussion occurred.
- It is important for a dentist to avoid a wrongful termination lawsuit, which is why documentation of all meetings with the employee is important, even more so if the employee is in one of the following protected classes of employees:
  - Race
  - Religion
  - Age (40 years and over)
  - Pregnancy
  - Disability
  - Sexual orientation
- It is best to seek advice from a lawyer versed in labor relations if the dentist is unclear about the proper way to discipline or dismiss an employee. It is much less costly to pay an attorney than to be involved in a wrongful dismissal lawsuit with a disgruntled employee.
- In most states, no notice is necessary for dismissal related to unlawful behavior such as stealing, patient mistreatment, or deliberate property damage. The team member committing such actions can be dismissed immediately if such actions can be proved indisputably. It should be clearly stated in the office manual that such conduct will not be tolerated and will result in immediate dismissal.
- A dismissed employee should always leave immediately after the termination conversation. The dentist may pay severance wages, but payment is not mandatory in all states. (The dentist should check with an attorney about state law and write the policy in the office manual.) It is unwise for an employee who was fired to remain on the job. The dismissed person may sabotage the practice, even unconsciously, and bother other team members with the details of termination. Thus a dentist may pay a penalty for being kind-hearted enough to let a fired employee keep working until he or she finds another job.
- The dismissed employee should be given his/her final paycheck, return office keys, and be accompanied by the OM as he/she collects his/her belongings. The best safeguard is to change locks and all passwords.

### Wages, Raises, And Benefits

Fair salaries and good benefits are necessary to avoid job dissatisfaction; however, salary and benefits do not necessarily motivate an employee to perform better. Motivated team members are most often those to whom responsibility

is delegated. Their personal and professional growth is encouraged and recognized by the dentist. They are appreciated and told how valuable they are to the office, the dentist, and the patients. In short, motivated team members are recognized for the contributions they make to the practice, and money is only one way appreciation is shown.

There must be a balance among managing payroll costs, sharing practice income and profits equitably with team members, and maintaining careful control of expenses. Team members should understand that their actions have a direct impact on their raises and benefits. Increased productivity creates additional profits the doctor can share, and reduced productivity will delay raises and benefits.

- Hourly wages should be commensurate with community wage scales. The dentist should survey similar jobs in other practices in the area to determine minimum and maximum pay ranges. It is financially more prudent to pay employees hourly rather than pay them a salary.
- Wages and benefits should be reviewed yearly. Raises are based on merit (positive behavior and increased skills), increases in cost of living (inflation), and the overall economic status of the practice. If the practice has had increased profitability and raises are neglected, good employees may quit.
- The relative worth of each position—including business positions (e.g., receptionist, scheduling coordinator, patient accounts coordinator) and clinical positions (e.g., clinical assistant, hygienist, sterilization/laboratory assistant)—to the practice is determined based on answers to the following questions:
  1. How long would it take to find a replacement?
  2. Are there specific certification, education, or training requirements?
  3. What is the value of longevity in this position?
  4. How skilled is a certain individual?

The more competent, valuable, and difficult to replace the employee is, the higher the wage should be.

Employees receive more than wages; net pay is only one part of a total compensation package. Although higher take-home pay with fewer benefits may attract some employees, fair wages with expanded benefits generally help retain team members. Each employee should be given an annual total compensation statement listing gross wages, employer-paid taxes, and the dollar value of benefits such as vacation, personal leave, insurance, uniform allowance, and free or reduced-cost dental care. Receiving an actual statement of wages and benefits lets employees perceive their full value.

### Employee Retention

High retention of productive employees is one of the most critical benchmarks of a healthy dental practice. Employees want a sense of fulfillment in the workplace with opportunities that allow for and encourage personal and professional development, or they may look for opportunities elsewhere. To retain great employees, the doctor must:

- Share practice vision and values with the team. Understanding a common goal inspires employees to be engaged and driven by a greater purpose.

- Build trust and confidence. The team wants to trust their doctor as their leader. Lead by example and understand the doctor's attitude will set the mood/tone for the day.
- Be emotionally intelligent. The more emotionally intelligent a leader is, the happier and more productive the team will be because team members will feel recognized, heard, and appreciated.
- Appreciate, recognize, and give feedback. Offer guidance to the team and recognize positive behaviors immediately by telling employees how they are valued and how they make a positive impact.
- Create incentive/rewards program. Incentives can be put into place to encourage positive behaviors. Although everyone enjoys receiving financial rewards, money alone does not retain employees. Some ideas for rewards include: gift cards, bonuses, paid time off, notes of appreciation, catered lunches, advancement opportunities and continuing education.

There is a high financial cost to employee turnover. The integral components in employee retention are to understand and value each individual team member and help them to develop skills for growth that benefit themselves and the practice as a whole. Investing in employees is vital to an enjoyable and prosperous dental practice.

## Part 5: Systems

### NEW-PATIENT APPOINTMENT

The first impression that sets the foundation for a long-term relationship with parents and patients is established at the new-patient appointment. The website and social media sites are typically the parent's first contact with the office, and the telephone is the first contact with a team member. Therefore, it is paramount that the website be well done, social media be current and relevant, and that the telephone is answered by a friendly and helpful person who is great at building relationships quickly. The office must be represented as organized and knowledgeable. Speaking highly of the doctor and team will instill trust and confidence in the parent about your practice and give parents the impression that they are making a good decision to bring their child to your practice for dental care. Always remember that parents selected your office over other offices in the area, and if they are not treated well, they will go elsewhere.

#### Initial Telephone Call

- Gather information from the parent using a new-patient information form (Fig. 31.7).
- Refer the parent to your website for more information about the practice and ask them to complete the new-patient forms within 24 hours of scheduling their appointment. Many software programs can be set up for this information to download automatically into your dental software.
- Schedule the new patient within 1 week of the call—block time in your schedule for new patients.
- Send the parent an email with the links to your website and the new-patient paperwork. This is a marketing opportunity to thank them for scheduling and let them know that you are looking forward to seeing their child.

Including a link with a video of the dentist welcoming the parent and child is a great way to be relatable and instill trust. Customer service tip: if you make something easy to do, parents will be more likely to do it.

#### Before the New-Patient Appointment

- Verify eligibility and dental insurance coverage, if needed, and ensure that the new-patient paperwork has been received.

#### New-Patient Appointment in the Office

- New-patient appointments should always run on time.
- From the moment the new patient walks in the door, your team should be on target for excellent customer service. Team members should smile and make sure they connect with the patient and parents. Remember, people do not care how much you know until they know how much you care.
- The greeter should rise to greet the patient first, and then the parent, and introduce himself/herself with an outstretched arm to shake their hands. Let the parent and patient know you are glad that they chose your office.
- A well-trained team member should escort new-patient arrivals to a conference room or the operator. At this time, the team member should review with parents the child's health history and the anticipated treatment to be performed that day, recording pertinent notes for the dentist.
- The dentist should be introduced by the team member who interviewed the new patient and parents. After a short conversation addressed mainly to the patient, the dentist should again review the health history with the parents, reading notes made by the team member during the interview. This routine provides two opportunities to ensure that the health history has been correctly completed and that the review with parents is documented. If the initial conversation occurred in a conference room, the dentist should leave while the team member prepares to take the child to the operator. In this way, if the child is upset, the dentist, who must gain the child's full cooperation during the dental examination, is not involved.
- The transfer of the child from one team member to another should be very positive. The parent's name should also be used throughout the appointment. "Billy, I would like you to meet Ann. Billy, you are so lucky, you get to see my friend Ann today. And you know what? She is going to get your teeth sparkling clean! You will love her!" At check-out: "Wow, Ann did a fabulous job cleaning your teeth!"
- In many offices, parents accompany their child to the operator. Sometimes this can be a distraction for the child; however, the presence of parents in the operator is a reality in many pediatric dental offices in today's litigious society. The dentist can, however, wisely limit the number of adults accompanying each patient to the operator and also forbid their use of cell phones.
- At some point during the first appointment, an assistant or hygienist should give home care instructions utilizing a tell-show-do method. The team member should also impart information about recommendations if fluoride is not in the child's drinking water, healthy snacks, bottle



<p>Thank you for calling [dental office]. This is [your name]. How may I help you?          Parent states he or she is calling to make an appt. May I ask your name ... and the name of your child?          When did we see your child last?</p>		
_____	_____	
Parent's Name	Today's Date	
Who may we thank for referring you? Get the specifics.		
_____	_____	_____
Patient's Name	Age	Date of Birth
Tell me a little about [child's name] favorite interest, sport, toy, pet, or color.		
Any medical or dental concerns?		
Prior dental experiences?		
_____		
Patient's Address		
_____	_____	_____
Home Phone	Work Phone	Cell Phone
E-mail Address		
For your convenience we will confirm your appointment by text, e-mail, or both. Which would you prefer? T E B		
Will we be helping you file insurance? Y N - Enter Insurance info on the back.		
<b>If pt indicates dental problems, ask the five questions</b>		
What area is bothering pt?	_____	
How long has this been bothering pt?	_____	
Sensitive to hot or cold or pressure?	_____	
Does it keep pt up at night?	_____	
Is there any swelling?	_____	
<b>When was your last cleaning?</b>	_____	
<p>Now that we have collected all of your information, let's see when we can reserve an appointment for [child's name]. We have an appointment available on [date] at [time] or [date] at [time]. If parent objects, ask for his or her concern so you can overcome the objection. I understand [objection]. We have reserved time for our new patients at [indicate times] because this allows the doctor the appropriate amount of time to evaluate your child, and we find that children do best at these times. I have [date] at [time] or [date] at [time] available.</p> <p>[Patient Name] is going to love [Dr. Name] and our entire staff. Our office is decorated [describe theme], and we have great toys and games. You're welcome to come early so [patient name] can play before his/her scheduled appt. He/She will have a great experience. Thank you for choosing our office. We'll take great care of [patient name].</p> <p>Please visit our website at [website] and complete the registration paperwork. It would be ideal if you could do so within the next 24 hours. By completing the registration online, you won't need to do any paperwork when you arrive. Everything will be completed and we can see [patient] without delay.</p> <p>We look forward to meeting you and [child's name] on [date] at [time]. You will receive an electronic confirmation by [text, e-mail]. Simply click the Confirm option and the appointment will be confirmed. May I ask a favor? If for any reason you need to change this appointment please contact us at least 2 business days in advance. We appreciate your consideration, and we will look forward to meeting you. Is there anything else we can help you with?</p>		

Fig. 31.7 New-Patient Research Form.

habits (if appropriate), and the importance of maintaining regular preventive care visits.

- After the examination, the dentist should present the case to the parents who usually want answers to the following questions: What is wrong? Can it be fixed? How much will it cost?
  - The practitioner should answer “What is wrong and how it can be fixed?” when presenting the treatment plan using language that the parent can understand. Do not use excessive clinical terminology, which only intimidates and confuses the parent.
  - The front office team will answer the question, “How much will it cost?”
  - When explaining treatment, always tie the treatment to the benefits that will result, any motivators that the parent has shared, and the consequences of no treatment.
  - Utilize pictures and samples of recommended treatment to help the parent understand.
  - The doctor should close the case by asking the parent, “Mrs. Jones, If you do not have any other questions, is this the treatment plan you would like me to complete for Johnny?” If the parent has questions or objections, the doctor is the best person to address the parent’s concerns and not put this burden on the front office team to close the case.
  - The dentist may wish to rehearse case presentations with team members, seeking their critique and suggestions.
- The patient and parents are then escorted to a check-out area. The next appointment is usually scheduled before the fee is collected.
- A written treatment plan is presented to the parent.
  - The parent is told the total cost and his/her estimated portion that will be due at the appointment.
  - The patient/parent signs or initials the treatment plan on an electronic signature pad or a printed treatment plan. It is scanned into the document center and it is given to the parent.
- After check-out, a team member should express thanks to the parents for choosing the office and let them know that if any of their friends would enjoy the same experience, new patients are always welcome.
- The children and parents should leave the office feeling that the dentist and team are extraordinarily caring, thorough, skilled, and efficient. The lasting impression should make both the parents and the child look forward to their next visit and eager to recommend the practice to other family members and friends. Remember, a first impression is a lasting impression.

### Forms

Forms for the pediatric patient need to take into consideration the circumstances of multiple parents, multiple email addresses, dual insurances, as well as multiple mailing addresses. Add a consent to the new-patient paperwork for a list of people authorized to bring the patient to appointments and authorize treatment.

Many companies have designed forms for purchase to use in the dental office. It is always advised that forms be

reviewed by your liability insurance lawyer to ensure state and federal compliance. Often, organizations such as AAPD, ADA, and your liability insurance company can provide the office with sample forms for personalization. There are also companies that can integrate your forms into your website for parents to complete online.

List of patient forms required for the dental office:

- Medical history
- Patient demographics/information form
- HIPAA compliance forms
- Consent for Authorized Person form
- Perpetual release for photos and patient reviews
- Financial Agreement Form
- Appointment Agreement
- Consent for treatment/nitrous oxide use
- Oral sedation form
- Hospital forms

### EFFECTIVE SCHEDULING

Offices are more efficient and productive when there is a proactive approach to scheduling the “ideal day” by using block scheduling and daily restorative and recare producer goals. Block scheduling controls the work pace and productivity level of the day in contrast to a day in which appointments are haphazardly scheduled, which causes stress and chaos.

The telephone connects patients to the practice, and it must be answered in a cheerful and professional manner. The attitude of the front office team member answering the phone can give a positive impression, making contacting the office and scheduling an appointment a pleasant experience, or create a negative one, resulting in no appointment being made. The front office team member should listen carefully to each parent or patient and try to be accommodating while offering choices of appointment times that work with the block scheduling.

Since most offices have multiple people scheduling patients, it is essential that the block schedule be easy to follow and that blocks be clearly labeled for appointment types. Many software systems have the ability to set up block scheduling and producer goal monitoring.

Consider the following when scheduling:

- Not all procedures should be scheduled for the same amount of time. Consider classifying each treatment appointment as either an easy op or hard op, giving each one a specific amount of time for its respective category and alternating them in the schedule.
- Schedule to meet producer goals for restorative, recare, and hospital/GA.
- Monitor the number of doctor and recare work days each month to meet the monthly production goal.
- Schedule morning appointments for more complex treatments to accommodate patient behaviors.
- Allow for uninterrupted time with the doctor when sedation is involved.
- Block enough appointments for new patients.
- Accommodate short time slots for lap examinations, consultations, and postoperative appointments.

- Leave slots available for urgent procedures once your appointment schedule is at capacity.

If a patient fails to keep an appointment, a team member should telephone the parents within 5–7 minutes. If unsuccessful, call again within 24 hours. If the parents cannot be reached by telephone, a message, perhaps by email or, failing that, by regular mail, should be sent asking them to contact the office. If the appointment cannot be rescheduled, the patient must be listed or flagged in the computer. At the end of each month, a broken appointment list can be printed so that patients with failed appointments can be recontacted.

Efficiency must be maximized in the scheduling of patients with low reimbursement plans, or providing care to these patients may become cost-prohibitive. Consider the following:

- Schedule during the hardest times of the day to fill (if the plan allows the doctor to dictate appointment time). Normally this is between 10:00 AM and 2:00 PM.
- Understand the volume required. Typically, a procedure must be done three to five times more often to get the same dollar out as one full-fee procedure.
- Delegate as much as possible to the team within the constraints of state law.
- Track reduced fee/PPO new patients separately from fee for service patients. Put limits by age or number/month on reduced fee/PPO patients if necessary.
- Have a strict “no-show, short cancel” policy. Explain that if a no show/short cancel happens again, another appointment will not be reserved, and the patient will be put on the same day call list.
- Have parents sign an appointment agreement form. These policies can be different from fee for service patients.

## SURGICAL REFERRALS

Some pediatric dentists have instituted a section of their practice entitled Surgical Referrals, indicating care for patients who need dental treatment and meet AAPD Guidelines for General Anesthesia. This particular program is one in which a patient is treated under GA and then sent back to the referring doctor, mimicking the approach frequently used by some other specialties such as oral surgery.

These patients may be seen for an initial examination by the pediatric dentist, treated in the proper setting while under GA, seen for at least one postoperative visit, and, if appropriate, returned to the referring doctor.

## MANAGING COLLECTIONS

Prevention is the key to successful collections. A clearly stated financial agreement (Fig. 31.8), presented to parents in a professional manner, and insurance plan information correctly entered in the practice management software will prevent uncollected balances. In offices that accept the assignment of insurance, 1 month’s gross production is the recommended guideline for total accounts receivable. When the accounts receivable total is more than 1 month’s production, cash flow suffers and many accounts become uncollectible.

## Collect Accurate Insurance Information for Patients With Insurance Coverage

- Insurance company’s name, telephone number, and group number
- Employer’s name and telephone number
- Deductible requirements and amount
- Maximum annual and lifetime benefits
- Pre-estimate requirements
- Percent or scheduled amount paid on various procedures, including preventive and orthodontic treatment
- Any exclusions

## Collect all Patient Payments, Deductibles, and Copayments at the Time of Service

- Train parents to pay their estimated portion at the time of service by presenting accurate treatment plans and informing the parents of their estimated patient portion amount that will be due before they schedule their child’s next appointment.
- If a parent does not pay on the day of treatment because they forgot to bring their checkbook or credit card, a statement with a stamped envelope addressed to the office should be presented at check-out and request that the parent enclose a check and mail upon their return home.

## Preparing Deposits

Daily deposits should be compared with the reports generated from the software system. To prevent embezzlement, the team member preparing deposits should be different from the one who is entering payments into the system. Further, the doctor should take the office deposit to the bank.

## Sending Statements

Every software system has the capacity to either send statements directly or integrate with a vendor that offers electronic billing services, which is typically more cost effective by saving the cost of postage, envelopes, and labor. What once took 2 hours can be done in less than 5 minutes and pays for itself.

- Send statements at the end of each day only after all payments have been posted. Select all accounts with a balance and to which statements have not been sent within the preceding 21 days. This will also cover all balances after insurance payments have been posted. This is much easier than processing individual statements each time a balance is left after a claim has been paid. The default due date for payments should be set to 14 days.
- An account on which no payment has been made for 30–60 days is considered overdue. Sending an email reminder after 30 days is an effective way to contact patients when they are not responding to the traditional statements. The value of a dollar greatly diminishes over time (Fig. 31.9).
- If the guarantor has not responded in 75 days, the guarantor should be sent a 10-day demand letter for payment by certified mail.
- If there is no response to the certified letter or payment made by 90 days, the account may be forwarded for outside collection action only after the dentist reviews the account and gives approval.



## Financial Policy

We are pleased to welcome you to our practice. Our desire is to provide you with the highest quality dental care in a caring and enjoyable atmosphere. ***It is our policy to make definite financial arrangements with you before any treatment starts.*** Below is an explanation of our payment procedures. If you have any questions, please do not hesitate to ask.

1. Payment for services is due at the time services are rendered. We accept cash, checks, and credit cards.
2. For new-patient emergency visits we require payment in full at the time of the appointment.
3. As a courtesy, we will provide you with a copy of the charges to submit to your insurance carrier for your reimbursement or you may assign the payment to our office and we will file the insurance for you.
4. Our office will file your insurance claim a maximum of **two times** per appointment.
5. **If the claim is not paid by your insurance carrier within sixty days, you will be responsible for the full balance and further insurance appeal becomes your responsibility.** We will be happy to provide you with a claim form so that you can follow up on your insurance claims personally.
6. You must provide the office with a dental insurance card with the proper mailing address of the insurance company, or provide a dental claim form, which is provided by the employer. If one of these documents is not available at the time of the appointment, you will be responsible for payment of all fees and we will provide you with a claim form for you to submit for reimbursement.
7. If insurance benefits are assigned to the doctor, you will be responsible for paying your deductible and co-payments at the time of service. **You are responsible for paying all charges not covered by your insurance company.** Your insurance benefits are a contract between you and your employer. The amount of coverage you will receive will depend on the quality of the plan purchased by your employer, not the fees of the doctor.
8. **The office cannot carry balances longer than 60 days,** regardless if the insurance payment is still pending. A \$5.00 monthly re-billing charge will be added to your account if it is not paid within 60 days, regardless of balance amount.
9. After 60 days, we will inform you of the delinquent account by letter and if no action is taken to clear the account, this office will be required to employ a collection service to collect payment. The responsible party agrees to pay all reasonable, related collection fees.
10. There will be a \$30.00 service charge for all returned checks.
11. **The parent or guardian who brings the child for his or her initial visit is responsible for payment independent of what a divorce decree or custody arrangement may state. Reimbursement must be made between the divorced parents. We will not intervene.**

### AUTHORIZATION

I have read & accept the above Financial Policy, understand it, & agree to the terms set forth regarding payment.

<b>Signature of Responsible Party</b>	<b>Date</b>
---------------------------------------	-------------

Fig. 31.8 Financial agreement. (©Julie Weir & Associates Management Consulting.)

- Laws concerning techniques for collecting overdue accounts vary from state to state. Therefore, the dentist must make certain that his or her financial coordinator is aware of the legalities of pursuing delinquent accounts in that state.
- Have a signed financial agreement that allows you to collect all legal fees, interest, and collection agency fees from the patient.
- Consider using a pre-collect service, before a collection agency, which charges a flat fee per account. The accounts can then be transferred to a collection agency if payment is not recouped. Collection agencies typically charge about 50% of the balance for their collection fee.
- Once an account is sent to collections, write off the account balance and dismiss the patient from the

practice. The account balance should be written off with a code reflecting that it was sent to a collection agency.

- Send the patient a dismissal that includes the availability of emergency care for 30 days, to avoid accusations of patient abandonment.

Remove any scheduled appointments of the dismissed patient and his/her family members, and inactivate these patients in your system. If the patient's treatment is incomplete or the patient has an appliance or prosthetic device, the dentist should seek legal counsel before designating the patient's chart as inactive and sending the account for outside collection action. An attorney can provide best advice on patient abandonment issues so that potential legal problems are avoided.

### What happens to \$1.00 when you do not collect TODAY?

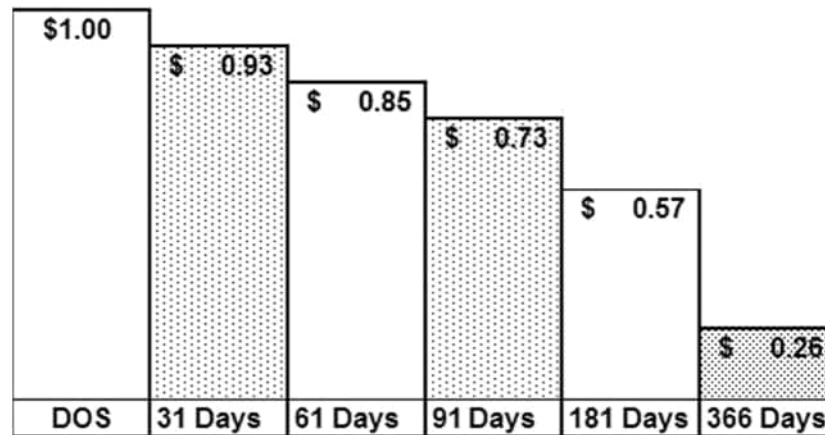


Fig. 31.9 Value of a dollar when not collected.

Follow all state debt collection laws regarding phone calls, written communication, and emails in attempts to collect the bad debt. It is essential that you document all collection activity. Make sure that every letter, every phone call, and every email is documented in your dental software. You want to be able to prove that you took every measure possible to collect payment before sending the account to collections.

#### Accounts Receivable Report

- Print monthly and review all accounts with balances past 30 days.
- Take the appropriate action to collect the balance:
  - Resubmit to the insurance company for payment.
  - Send the parent a statement.
  - Email the parent to contact the office regarding their account.
  - Call the parent.
  - Send the account to collections.

#### MANAGING INSURANCE

The acceptance of insurance assignment can be a good marketing tool because it attracts patients to the office. Parents are more likely to accept treatment for their child if they have additional financial assistance. However, to maintain healthy accounts receivable, it is essential to take a proactive approach with dental insurance by obtaining the patient's dental benefit coverage before he/she arrives for the appointment.

#### Steps for Effective Insurance Management

Practice management software programs are set up to calculate the patient's correct insurance coverage through the use of a coverage table and a payment table for each insurance plan when these tables are used correctly and consistently by the front office team.

The coverage table contains information on the insurance plan's deductible, maximum, and percentage of coverage for preventive, restorative, etc. The payment table, when utilized correctly, allows the software to build a history of the actual payment amounts received from the insurance

plan for each procedure. This creates a more accurate estimate of insurance coverage for the parent instead of relying only on the insurance plan's stated percent of coverage for a procedure. Utilizing these tables can also greatly reduce your accounts receivables and increase your cash flow.

1. Sign up for online management of insurance companies. Most insurance companies allow you to check patient eligibility, check claim status, and submit claims online through their websites.
2. Understand the latest CDT codes. The ADA's current handbook on CDT codes is available from <http://ebusiness.ada.org/>.<sup>8</sup> Periodically review the insurance company's fee schedules to understand the codes for benefits covered and the reimbursement levels, to maximize your coding and coverage.
3. Collect insurance information on the phone during the new-patient phone call and make a copy of the dental insurance card when new patients arrive in your office.
4. Contact the dental insurance company to confirm eligibility and use a detailed form for collecting information on insurance benefits coverage (Fig. 31.10).
5. Enter the patient's insurance information into the dental software. Benefits are based on the employer/group number, not the insurance company. (If two guarantors have Delta Dental and they work for different companies, their benefits will be different.)
6. Attach a fee schedule to the coverage table for each in-network plan. This will provide accurate estimates and will minimize time-consuming adjustments, refunds, and billing statements.
7. Attach a fee schedule to an employer only for PPO programs. Attaching a fee schedule will ensure that your accounts receivable numbers reflect the actual amount that you will receive from the services rendered, and it will also create accurate treatment plans and patient estimates.
8. The provider must submit a claim for all procedures performed, regardless of coverage for those procedures. Always submit claims with your full fees so the insurance company will have a record of the full fee amount for the procedures. This will also be reflected on the explanation of benefits.

INSURANCE VERIFICATION									
Patient Name				DOB		Relationship			
Name of Insured				ID # or SS # (as it appears on card)					
Employer				Insured's DOB		Group #			
Name of Insurance Company				Insurance Company Phone Number					
Address of Insurance Company									
Insurance Rep			Effective Date			Benefit Year - Renewal Month			
Yearly Max		Max Used			Ind Deduct			Deduct Met?	
Preventive %		Basic %			Major %			Family Deduct	
		Elig/Cov		Benefit Category					
Procedure	Y	N	Prev	Basic	Maj	Freq/Lim	Date of Last?	Comments	
Comp Rexam D0150									
Per Exam D0120									
Infant Exam D0145									
Child Prophy D1120									
Adult Prophy D1110									
Fluoride D1206									
2 BWX D0272									
4 BWX D0274									
Psno F0330									
BW/Pano Bundle as D0210									
Sealants D1351									
Sealants D1352									
Endo D3000									
Space Maintainers D1515									
Night Guard D9940									
SS Crowns									
Ortho									
Post Comp D2391/2/3									
In Off Sedation D9240									
Nitrous D9230									
Hospital Case D9420									
Waiting Periods									
Non-Duplication?									

Fig. 31.10 Insurance Verification Form. (©Julie Weir & Associates Management Consulting.)



9. Once the appointment is “set complete,” an insurance claim should be generated by the software system and batched. After the providers have reviewed daily services and deemed them accurate, send the batched claims electronically for payment. The insurance company will review the claim and send a payment. You can track the progress of the claims online through most insurance websites.
10. When the insurance claim is received, check to see what the insurance company paid, what the patient portion should be, and what the patient was charged. Do not make adjustments based on the explanation of benefits without checking to see how much the patient was charged. For instance: The patient’s account shows a cleaning for \$75, a new-patient exam for \$75, and an FMX for \$100, for a total of \$250. If the payment comes back and the insurance paid \$200, stating that the patient portion for this claim is \$0, then you know you have to “adjust off” the \$50. If the company paid \$200 and states that the patient portion is \$25, then the adjustment would be \$25.
11. Enter the insurance payments by each procedure instead of entering the bulk insurance payment for the total claim. This way the software “learns” the true coverage and the payment table will then override the coverage table as it builds this information and then be able to produce more accurate estimated portions on treatment plans. The payment table must be updated each time after insurance payments are entered.
12. Send preauthorizations for dental treatment to insurance companies only when the insurance company requires it or when services are expected to be over \$2000.
13. Each week, generate an outstanding insurance claims report so that overdue claims can be pursued. The insurance coordinator should call the insurance company to inquire about payment and carry out needed actions for payment to be received. Unpaid insurance claims should be called once the claim ages 14 days past the date of service.

It is important to help the parents understand that they, not the doctor, have the contract with the insurance company, and that the parents can call their insurance company at any time to discuss what their patient portion should be. Sometimes you will have to politely remind them that the insurance company, not the dental office, determines their patient portion.

### Coordination of Benefits

When a patient has more than one active dental insurance, a coordination of benefits must take place. Which insurance is primary and which insurance is secondary must be determined. Medicaid will almost always process as secondary insurance.

When checking insurance benefits, ask what the coordination of benefits is for the plan. There are some options: nonduplication of benefits, birthday rule, and biological benefits. Always send out claims out at UCR (office fees).

The office is not obligated to submit secondary claims if the doctor is not a provider with the secondary company.

### Dental Insurance Fraud

Insurance fraud can result in criminal prosecution of the dentist, even if they were not aware of how claims from the

office were being submitted by the team. You can submit only for completed procedures and only for the fee that is charged to the patient.

The dentist should not discount or disregard the portion of fees not paid by an insurance company (i.e., the patient’s portion). Doing so may constitute insurance fraud because the dentist has misrepresented actual charges. For example, if a fee for a procedure is \$100 and an insurance company pays only \$80, do not submit a claim for the full \$100 fee if \$80 has been accepted as payment in full. Submit the \$100 claim only if the parent is expected to pay the \$20 that is not covered.

### Different Types of Dental Insurance Programs

Most insurance companies provide some preventive and basic coverage, but the insurance coverage depends on the plan purchased by the employer or the individual.

### Indemnity Plans.

- Indemnity plans are considered “fee for service” plans where most of the UCR fee is covered. These plans require filing claims and may require the patients to accept assignment of benefits and receive payment directly from the insurance, which means that they will have to pay for all the services in your office in full. The advantage of an indemnity plan is that the policyholders are not typically restricted as to which dental care providers they can use.
- Almost all indemnity plans have a deductible.

### Managed Care.

- Dental benefit organizations fit under the umbrella term *managed care*, which is an insurance industry term for a system that curbs expenditures in benefit plans by cutting reimbursement levels and transferring financial risk to those providing care (in this case, the dentist).
- In managed care, it is the payment methods rather than the actual dental treatment modalities that are different. Each managed care system has a specific mechanism of payment for treatment, usually accompanied by some form of utilization review. Dentists who participate in managed care organizations surrender control of their fees for that part of their patient population enrolled in the managed care organization.
- The two most widely used types of dental managed care are the preferred provider organization (PPO, EPO, DPOs) and capitation contract dentistry (CCD, HMO, DMO). A PPO is a network of private practitioners who contract with a plan to provide specific services to a particular patient population at reduced fees. Patients enrolled in a certain PPO must choose a dentist from the organization’s list of providers. In CCD plans, the dentist contracts with a plan to provide specific services to enrollees in return for a monthly capitation amount, whether or not the enrollees-patients actually make and keep appointments. In other words, the dental office receives a monthly lump capitation payment based on the enrolled number of patients eligible for treatment in that office.
- Dentists must weigh many issues, options, and fiscal matters regarding managed care. The ADA has a comprehensive array of resources to help dentists understand and analyze the positive and negative aspects of managed

care. Among the services offered is contract analysis, which is available from the ADA through individual state dental societies. Any dentist who is considering signing a contract with a dental benefit organization is well advised to consult with the ADA and his or her own attorney, financial advisor, and management consultant.

- Being a managed care provider will help direct new patients to the practice. However, the doctor will be treating these patients at a fee schedule that is typically 20%–60% lower than the doctor's full fee. This can be a good way to get new patients and start cash flowing. It is better to make 50 cents on the dollar than 0 to help pay overhead costs when the practice opens. A doctor can always decrease his/her managed care involvement as the practice grows. The fee discount of a PPO plan can be viewed as a marketing expense to bring in new patients.

### Medicaid and Federally Funded Programs.

- These fees are typically 40%–60% of a doctor's full fee.
- Practitioners must decide how much dental service their practice can provide for public assistance patients. The positive for doing so is the personal and professional satisfaction of knowing that you, the dentist, have cared for some of the neediest patients in your community and have met some of your moral and ethical obligations as a professional. The negative for doing so is that many states' program reimbursement levels fall short of covering the actual cost of dentistry delivered to these patients. In this case, the dentist loses money on the services rendered to every public assistance patient he or she treats. Some pediatric dentists solve this quandary by treating a limited number of these patients by setting limits on the age of patients they will treat, the age they "graduate" from the practice, or the number of such patients seen per day.
- Medicaid (known by other titles in some states) is a state-administered program in which each state sets its own guidelines regarding eligibility and services, including reimbursement rates. The wise practitioner investigates his or her state program thoroughly before deciding to become a public assistance provider. One might begin seeking information at a variety of websites available through the US Department of Health and Human Services.

## TREATMENT TRACKING

### Treatment Plan Acceptance

Tracking diagnosed treatment on a daily basis has many advantages. Patients who are seen today should always have a future recare and/or restorative appointment. When a patient leaves without a future appointment, extra time and money must be spent to bring that patient back. By tracking who presented the cases and who assisted, the doctor can determine if there is a pattern for which patients accept or do not accept treatment.

### What to Track at the End of the Day

- Number of patients who have another appointment scheduled after today's visit
- Number of treatment plans diagnosed
- Number of treatment plans scheduled

- Number of treatment plans not scheduled; who presented the treatment plan and who assisted with the patient. Training should be provided for treatment acceptance.

### Actions

- Assign a team member to stay in contact with the parents who did not schedule restorative treatment to keep the importance of completing treatment fresh in their minds.
- Make the doctor aware of patients who did not schedule their restorative treatment, especially if it is a complex case or care has been neglected.
- Determine if case acceptance is 75% or higher.

### Unscheduled Treatment

Each software system will have reports for tracking unscheduled treatment.

1. Once a month, run an unscheduled treatment plan report with your software. Work to schedule patients from this report regularly throughout the month.
2. Go through the report and delete any treatment that is no longer necessary or has previously been completed. Often, if treatment changes from the original treatment plan, the old treatment may possibly stay on the report.
3. Contact parents to discuss the importance of returning for treatment. Communicate possible consequences of not scheduling treatment and the advantages of completing treatment.
4. Document all attempts to contact the parent.
5. Document all conversations with the parents regarding a child's past due treatment.
6. Once the treatment diagnosis is 6 months old, schedule the patient to come back for continuing care.
7. Make no more than three attempts by telephone or text to contact the parent over the course of 2 months. If a parent does not respond and schedule an appointment to complete treatment, send a letter explaining the dental consequences of not completing treatment or not having periodic adjustments and examination of an appliance or orthodontic treatment. Such letters should be mailed to the patient's last known address with a Certificate of Mailing (PS Form 3817), which can be obtained from the US Postal Service. A copy of the letter should be kept in the patient's chart with the Certificate of Mailing attached, to prove that the letter was mailed and that the dentist's professional responsibility was fulfilled. A Certificate of Mailing adds nominal cost to first-class postage.

### Recare

The foundation of any successful dental practice is the recare system. The recare system provides a constant source of recare and restorative appointments that safeguards children's oral health and emphasizes the fact that the dentist and team care a great deal about them. The term *recare* is preferable to the frequently used word *recall*. *Recare* denotes ongoing, continuous attention, whereas *recall* suggests an occasional check for problems (e.g., the recall of an automobile for the replacement of faulty parts).

The most effective and efficient recare systems that retain the most patients are those in which the next recare

appointment is scheduled 6 months in advance at the conclusion of the present appointment. A reminder email or text message should be sent 4 weeks before the appointment. Dental software systems and PCS are essential for helping to manage these messages. Run the unscheduled recare report once a month with your software. Send reminders by text messages and/or emails to patients without appointments that are past due, now due, and coming due. Place reminder phone calls to those who do not respond.

There are two types of preappointed recare systems: *preselected* and *preassigned*. When implementing either system, the scheduling coordinator should emphasize to parents and patients that the preappointed recare system is for their convenience and is more likely to allow them to choose an appointment 6 months hence at the time that they prefer.

In preselected systems, at check-out, the parent chooses the next recare appointment. In 5 months, a notification with the day, date, and time is generated and an email or text message reminder is sent.

In preassigned systems, the patient is automatically assigned a date and time for the next appointment. The appointment may be at approximately the same time as the present visit or it may alternate to be during or after school. Again, in 5 months, an appointment reminder is sent by email or text. This method is especially helpful in a busy practice because it speeds the check-out process.

For either a preselected or preassigned system, the appointment date is entered into the computer so that notifications can be generated when needed. If the recare appointment must be changed for any reason, such as a change in the dentist's schedule, rescheduling should be done by telephone.

On receipt of the recare card, parents who find the time inconvenient usually call to reschedule. A confirmation telephone call should be made 2 business days before the appointment. The front office team member calling to confirm should be prepared to reschedule appointments if changes are requested.

Flexibility to accommodate appointment changes initiated by the office can be built into the preappointed system by leaving 1 or 2 days unscheduled toward the end of each month. If the time is not needed for changed appointments, it may be scheduled 1 or 2 weeks ahead with regular restorative appointments, new examinations, and rescheduled appointments initiated by patients.

### Checking Recare System Effectiveness

The recare program is the life-support system for any practice. The recognized minimum goal is for at least 8 of 10 active patients to return regularly at the prescribed frequency for hygiene appointments (i.e., 80% effectiveness). The effectiveness of the recare system should be checked at least quarterly.

Accuracy of the check depends on a close count of patients who have been seen in the previous 18 months (active patients), except those whose treatments could be classified as single-visit emergencies (CDT code No. D0140) and who are not enrolled as regular patients.

The following example illustrates a quick, easy way to check the effectiveness of a recare system:

- $4000 \text{ active patients} \div 6 \text{ months (recare frequency)} = 667 \text{ recare appointments per month for a 100\% effective system}$

- Actual average for 3 months = 300 recare appointments per month
- $300 \text{ actual} \div 667 \text{ potential} = \text{a 45\% effective system}$
- Goal = 80% or more of active patients returning for regular recare appointments
- $4000 \text{ active patients} \times 0.80 = 3200 \text{ patients}$
- $3200 \text{ patients} \div 6 \text{ months (recare frequency)} = 533 \text{ recare appointments per month as 80\% goal}$
- $(533 \text{ recares per month as 80\% goal} = 300 \text{ recares per month actual average}) = 233 \text{ additional recares per month}$
- $233 \times \$155 \text{ average recare fee (child with and without BWX and fluoride)} = \$36,115 \text{ per month increased production}$
- $\$36,115 \text{ per month production} \times 12 \text{ months} = \$433,380 \text{ of additional income generated from current patients—plus better care and service to patients}$

After the current effectiveness rate is determined, the dentist and team can work toward the goal of 80% of active patients returning regularly for recare. Problems with the system should be listed and analyzed, and ways to improve the system must be planned and implemented. Many practitioners find that 60% or more of restorative and orthodontic treatment needs are diagnosed during hygiene examinations, which reinforces the importance of an effective recare system in any office.

### Purging Charts and Reactivating Patients

It is important to purge patients' charts at least once per year, preferably in September or October. As defined by the ADA, an active dental patient of record is any individual in either of the following two categories: Category I - patients of record who have had dental service(s) provided by the dentist in the past twelve (12) months; or Category II - patients of record who have had dental service(s) provided by the dentist in the past 24 months, but not within the past 12 months. An inactive patient is any individual who has become a patient of record and has not received any dental services(s) by the dentists in the past 24 months.

The front office team member can run a report of patients who have not been seen during that year and telephone or email the parents to stress the importance of regular hygiene appointments. Parents of children with incomplete treatment should be informed of the treatment yet to be rendered and the importance of completing it. Parents with dental insurance should be reminded that benefits for that year will be lost unless they schedule an appointment for their child before year's end. Many people will schedule an appointment to avoid losing insurance benefits. Individuals who refuse to reschedule should be contacted once more, and so noted in the patient chart, before their charts are placed in the inactive file. It costs the practice five times as much to attract a new patient as it does to keep an existing one. Practices need to invest time and effort in patient retention and reactivation.

Some state laws specify a minimum period after the last treatment date that dental records must be maintained. Regardless of the statutory requirement, it is best to maintain records for as long as possible but certainly no less than 10 years from the last treatment date for adults and up to age 28 for patients treated when they were children. Charts



should be kept as evidence against malpractice claims and to answer medical or dental questions that may arise in later years. If storage becomes a problem, records can be scanned into digital files. Such records are admissible in most state courts. Of course, a proper backup system for storage of inactive charts must be maintained if the office has only computerized charts.

For additional information regarding patient records, visit: [http://www.ada.org/sections/professionalResources/pdfs/dentalpractice\\_dental\\_records.pdf](http://www.ada.org/sections/professionalResources/pdfs/dentalpractice_dental_records.pdf). Steps for reactivation include:

- Print a list of patients who have not been seen for 12 or 18 months.
- Document all efforts to contact the parent.
- Place phone calls during times when you expect the phone to be answered.
- Leave a message: "I am calling about your child's dental health."
- Follow up the phone message with an email if the call is not returned.
- Send letters via US mail only after all other attempts have been unproductive.
- If at any time during this process, the parent states that the family has gone elsewhere for dental treatment, ask if there was anything that your office could have done differently, since you are striving to provide excellent customer service. Document reasons for their voluntary release from the practice in their ledger, and let the patients know that you will welcome them back into the office at any time.
- Once a patient has gone more than 24 months without an appointment or the contact information is no longer valid, the patient should be placed on inactive status.

## INTERNAL AND EXTERNAL MARKETING

Parents "buy" three "products" in a pediatric dental "store": procedures and information to help prevent dental disease, procedures to treat dental disease, and the dental team. There are two avenues through which these products are marketed: internal and external marketing. The extent as to where and how external marketing activities will occur depends on the doctor's desire and the available mix of full-fee, PPO, and Medicaid patients for the practice.

The doctor should create a marketing team (two to four team members) who will oversee and carry out internal and external marketing efforts round the year to ensure a continuous stream of new patients. The goal is to build a "marketing machine" of regularly repeated activities that results in creating and maintaining relationships with existing patients and their parents and an increased awareness of the importance of all children having a dental home by age 1, the specialty services that a pediatric dentist provides to infants and children versus a general dentist. Marketing expenses should be built into the budget and should be 1%–5%, depending on the number of unfilled appointments in the schedule. New patients should be counted by CDT code D0150, Comprehensive Exam, and a doctor who sees patients 4 days a week should strive for 55–75 new patients per month, depending on the level of decay in the community.

## Practice Branding

- Practice branding should reflect the identity of the practice. A logo starts the branding process and should be carried out in all things related to the practice: office décor, uniforms, business and appointment cards, stationery, note cards, referral forms, new-patient paperwork, website, social media pages, etc. It is important that the branding be easily recognizable by parents and communicates that the practice delivers specialized dentistry for children.

## Monthly Marketing Meeting

- Hold a monthly marketing meeting with the doctor and team members who are responsible for executing marketing actions. Monthly marketing meetings help create an atmosphere for open communication, accountability, and consistency. During this meeting, the doctor(s) and marketing team will create the marketing action plan list.
- Each month, print a new-patient referral report and examine it to determine the following:
  - What are your top referral sources; friends or family members, word of mouth, pediatricians, general dentists, obstetricians, Google, website, social media, online reviews or local ad?
  - How are you thanking the parents and offices that are referring new patients?
  - What marketing actions are working? What actions are not?
  - What new marketing actions should be carried out in the next month?
- Thank referral sources
  - All referral sources should be acknowledged with appreciation. (Always check your state's dental Practice act to be sure you are in compliance. Some states do not allow a referral gift to be given.)
  - Parents can be thanked with a handwritten note and a \$5 gift card.
  - Health care offices can be thanked with a box of treats or a variety of small gifts for team members. These can be dropped off monthly, bimonthly, or quarterly, depending upon the number of referrals sent.

## Internal Marketing

Internal marketing involves activities within the office that are focused on exceeding expectations and creating loyal relationships with the parent and child so they will come in for regular preventive appointments, accept treatment plans, and refer friends and family. Existing families should be your biggest referral source due to your excellent customer service.

## Prevention of Dental Disease

- Provide as much patient education as possible! The amount of patient education a parent/patient receives makes the difference between a "satisfied" parent/patient and a "highly satisfied" parent/patient. Parents are willing to pay more for services when they feel they have also received excellent preventive and postoperative education.

- Educate the caregiver on how to prevent and reduce early childhood caries (ECC) through providing information about proper brushing and flossing, healthy diet and snacks, fluoride, and preventive care visits.
- Provide educational materials
  - Give written material to the parent that reinforces caries prevention, oral hygiene instructions, and/or postoperative instructions.
  - Have pictures and models of the different dental procedures so parents can better understand what is being recommended and how it will benefit their child.
  - Utilize technology to educate caregivers. The Baby Oral Health Program website is an excellent resource that educates caregivers, team members, and expectant mothers about the prevention of ECC: <http://www.babyoralhealthprogram.org/>.

### Dental Team

Parents typically have a choice of pediatric dental practices where they can seek treatment for their child. Most often, their choice is based on who will be providing the care. Parents must **Trust**, **Like**, and have **Confidence** in the team before they will “buy” a treatment plan; therefore the most important “product” in the dental office is the team that provides the TLC. Each team member is just as important a “product” as the doctor. A great doctor can be tarnished by a front office team member who is unpleasant or a clinical team member who is rough and insensitive.

- The appearance of the team should reflect excellence; uniforms should look clean and crisp.
- Hair, appearance, and jewelry should be appropriate.
- Use good eye contact, smile as you shake the parent’s hand, and introduce yourself along with your position in the office.
- Ask the parent and child about themselves, their dental concerns, interests, hobbies, or sports. Show genuine interest in them.
- Find something on which to compliment them. Make them feel good about themselves.
- Listen well. Do not interrupt. Be empathetic, friendly, and polite.
- Laugh and have fun. People remember how you make them feel more than what you say.
- Make a personal note about the child and date it in the chart so this topic can be discussed at the next visit by anyone in the office.
- Review the personal notes before seeing the child.
- Send handwritten personal notes/cards to patients to welcome them to the practice or compliment them on being a good patient.
- Have a pleasant and educational “on hold” message.
- Ask for referrals. After a parent compliments the practice, say, “Thank you for appreciating what we do here. We are always welcoming new patients to the practice. If you know any families who would also enjoy this type of practice for their children, please tell them about us. We would enjoy helping them.”
- Offer more flexible financial options for payment.
- Become a preferred provider on higher-paying insurance plans.

- Increase the number of new Medicaid patients to fill open time.

### Facility

- The appearance of the facility should reflect excellence. Parents judge the quality of your clinical excellence on everything they see, touch, and hear. If the office looks out of date and shabby, with stained carpet and paint-chipped walls, then parents will think that the clinical dentistry is behind the times, of poor quality, and will have concerns about infection control.
- Create a good flow for check-in and check-out so that bottlenecks do not occur. Typically there is one check-in station and two check-out stations, separated for private financial conversations.
- Create a comfortable area for parents, play areas with electronic games and special toys for young patients, and perhaps a separate area for teenage patients.
- Keep the facility up to date by redecorating every 5 years.

### External Marketing

External marketing involves activities outside of the office to create an awareness of and need for your services. The AAPD has created several marketing programs for use by its members that can be found on the AAPD website.

### Marketing to Health Care Professionals

- Pediatricians should be one of your top referral sources. Other referring health care professionals are general practitioner physicians, general practitioner dentists, obstetricians, and school nurses.
- Educate health care professionals and their teams about the importance of a child having a dental home by age 1 year and what type of care a pediatric dentist can provide. This can be done by offering to arrange “lunch and learn” sessions in their office. Be aware that it is not just the physician who refers; parents ask nurses and front office team members where to take their child for dental care. Therefore, it is just as important to educate the team of referring offices as well as the physician.

### Dental Health Education Programs

Dental health education programs are a wonderful way to speak directly to children about oral health care. They can be scheduled in public and private schools, daycare centers, vacation Bible schools, and summer day camps. Alternatively, the above groups can be invited to your office for a field trip. Follow the tips below:

- The program will be more memorable if you include a team member dressed as a tooth fairy, mascot, super hero, or popular fictional movie character. The costumed character you choose should become part of your practice “branding.” Have a picture of your mascot on your website and in your reception room.
- Make your program interactive with the children. The more children interact with the information you share, the more they will remember.
- Include a letter to the parents in the child’s goody bag that has the following information: who you are, information about the presentation, what their child learned, information about ECC, and a “call to action” about

the importance of having preventive visits and a dental home by age one.

- Your mascot can also be in a booth at health fairs, especially health fairs for expectant mothers and mothers of newborns.

### Online Presence

- Most parents use the Internet or a mobile device to search for a children's dentist. Make your website mobile responsive and own multiple domain names that parents might use to find you/your practice name.
- Use a reputation management company that can also boost your search engine optimization to help you stay competitive.
- Set up your Google My Business Page with information that exactly matches what is on your website name, phone, and address. A Google My Business Page is a free tool to manage your digital footprint on Google. Create a strong online presence through an updated and optimized website and updated social media pages.

### Website

- Your website should be created or setup as a mobile responsive design. A mobile-responsive website is designed to adapt to each device (desktop, phone, and tablet), unlike previous user-friendly websites.
- Your website should be updated, professional, and fun. It is commonly the first impression you make on a potential parent/new patient. It reflects your overall branding and the experience your patients and parents will have in your office.
- Meet the dentist: introductory video of the doctor introducing him/herself and talking about their practice philosophy. Discuss your practice's unique qualities and why families love you.
- Meet the team: video of team members talking about the practice and why they like working there.
- Testimonials: video of satisfied parents and patients.
- Office tour: video of patients and parents interacting with your team in your office.
- Top header banner: include your phone number, address, all social media icons, and a call-to-action button that is linked to a fillable form to request an appointment or contact the office.
- Provide your location, including a Google Maps link.
- Page of dental topics.
- Include fillable new-patient paperwork. Parents can fill out paperwork directly on your website or print out and have it filled out and ready for their first dental visit.

### Social Media

Social media platforms are an inexpensive way to help maintain relationships and foster loyalty with your current patient base. Social media can also help create brand awareness in your community and greatly expand your reach to new patients. There are several social media platforms in which to promote your practice:

- Facebook—the “social” connection with families when they are not in your office.
- Instagram—the “video- and photo-centric” connection that helps you create your practice's “online magazine.”

- LinkedIn—the “professional” connection with colleagues and other business people.
- Blogging—the “educational” connection for you to share your professional knowledge and current thoughts regarding topics in the industry.
- Twitter—the “real time” connection. Ongoing discussion in real time.
- Pinterest—the “social bookmarking” site where users collect and share photos of their favorite events, interests, and hobbies.
- Manage your online reputation by interacting with parents/patients through posting fun and engaging content which increases your follower and response rates. If a parent tags you in a social media post, share it to your practice page. If someone comments on your social media post, politely respond. Social media gives you an opportunity to showcase your office and team and creates online relationships with parents before they walk into your office.
- Have policies in your employee manual related to social media that address the following issues:
  - Use of practice equipment and services
  - Protection of confidential and proprietary information
  - Protection of patient information
  - Use of the Internet to harass coworkers
  - Prohibition against criticizing patients and vendors
- Ensure that team members understand the detrimental effects of negative comments about their workplace on social media sites. There is little privacy on the Internet.
- The team should create positive in-office experiences for patients and parents so they will want to write positive online reviews and recommendations.
- Monitor doctor rating sites by setting up a Google Alert account at [www.Google.com/alert](http://www.Google.com/alert). Plan dedicated team member and doctor time to sustain a consistent online presence and monitor online review sites. Plan marketing efforts in advance and set time aside to gather content (photos and videos) and post consistently on social media platforms.

### DENTAL OFFICE TECHNOLOGY

Dental offices are increasingly using technology because it is efficient, convenient, and because practice management software systems are vital and give the doctor and OM good business information.

- Basic technology for the front office includes: dental practice management software system, PCS, scanners, printers, multiple computers, and multiline phone systems. Invest in a software system that allows for electronic statements and electronic claims submission and clinical charting.
- Regular cloud and mirror backup systems are imperative to ensure that data are not lost.
- Limits to employee access levels in the systems need to be adjusted to avoid changes in settings.
- Chartless offices require the use of scanners and digital radiography; they are also more efficient and cost-effective.
- Advanced technology for clinical teams would include Isolite, Diagnodent, Digital Radiography, Waterlase, and much more.



## COMPLIANCE

Pediatric dental practices should make compliance standards a top priority and must provide training to the team to ensure that compliance standards are followed and that mandatory forms are signed by each parent or guardian. The main categories for compliance standards are as follows:

1. Infection control—Centers for Disease Control and Prevention: Sterilization processes and routine spore-testing. <http://www.cdc.gov/oralhealth/infectioncontrol/guidelines/index.htm><sup>10</sup>
2. HIPAA Compliance: HIPAA privacy rule gives patients some rights over their dental records, billing ledgers, and other health information. <http://www.ada.org/8753.aspx> and <http://hipaanews.org/checklist.htm><sup>11</sup>
3. Patient records compliance: Check your state's dental practice act for information on record-keeping requirements in your state. [http://www.ada.org/sections/professionalResources/pdfs/dentalpractice\\_dental\\_records.pdf](http://www.ada.org/sections/professionalResources/pdfs/dentalpractice_dental_records.pdf)<sup>9</sup>
4. OSHA compliance: Follow all OSHA and state regulations. Maintain records of all training and all required documentation, including sports testing, sharps disposal, as well as CPR training. <https://www.osha.gov/Publications/OSHA3187/osh3187.html><sup>12</sup>
5. Many states require that labor laws be posted. Additional postings specifically for the dental office may be required in your state, such as pay date postings, what to do in case of injury on the job, etc. Check with your state labor board for compliance requirements.
6. Be sure that you are in compliance with parents' signing informed consents for treatment. The AAPD website, [www.aapd.org](http://www.aapd.org), has information on guidelines for informed consents.
7. Keep your credentials current.
  - Declarations pages from the insurance companies, CPR cards, DEA license, dental license, and certifications all must be kept current, and there are penalties if these expire.
8. Stay compliant with insurance company contracts.
  - Insurance companies often send reminders for updated paperwork.
  - Immediately update any doctor provider changes for credentialing with contracted insurance companies. Insurance companies will not pay for work performed by a doctor who is not credentialed.

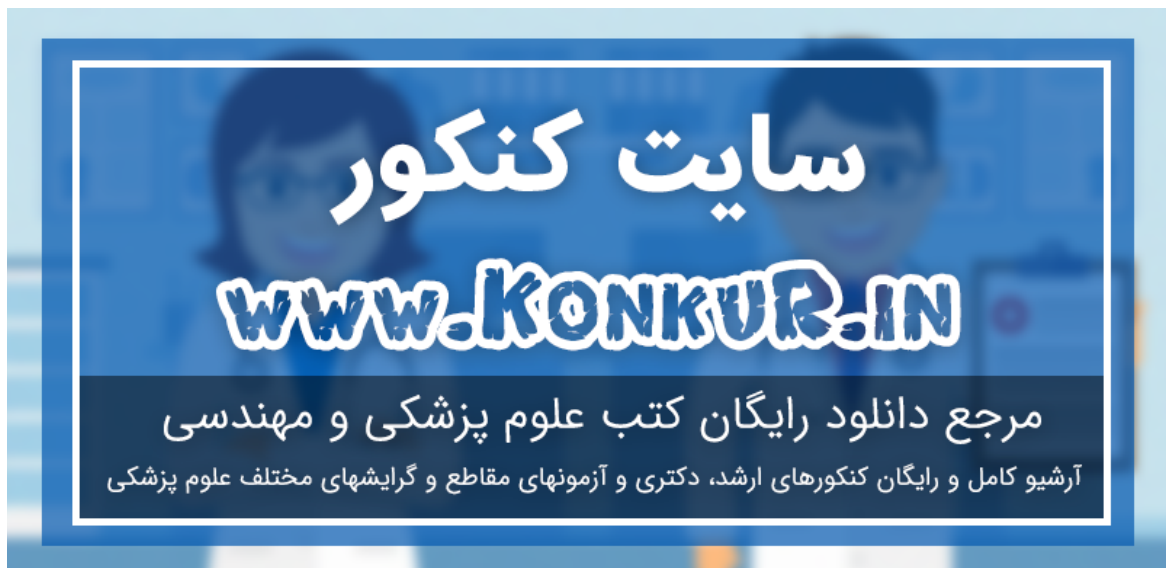## CLINICAL ORGANIZATION

- Clinical supplies stored in cabinets and carts should be identical in each room so that materials can be found quickly; this ensures efficiency.
- It is less expensive to maintain and service equipment than to replace it. Review all service manuals and follow the manufacturer's recommendations for service. Place notes on the schedule when service is due and document all service in a maintenance logbook (Fig. 31.11).
- Ensure that handpieces are oiled and maintained according to the recommendations.

## INVENTORY CONTROL

A well-organized inventory system will keep you from running out of necessary supplies and materials or being over-supplied and thus tying up excess cash.

- Create a list of all the materials used in the office and where these supplies are ordered. All items that are used in the practice should be assessed once a year, cataloged, and included in the systems manual.
- Work with your dental supply company to create a barcode scanner or a tag system for reordering supplies. Inventory control involves communication among all team members; it is not one person's responsibility to report supplies that are running low.
- Store dental materials in ideal conditions. Failure to store products as per the manufacturer's recommended conditions may lead to having to throw out materials and/or procedure failures/redos.
- A front office team member should be in charge of front office supplies, and a dental assistant should be in charge of clinical supplies.
- Each should work within the practice's monthly front office and clinical supply budget. Ask for the best deals possible and keep a log of supply orders.



**Clinical Maintenance Checklist**

<b>Daily</b>	
<input type="checkbox"/> Compressors turned on AM, off PM	<input type="checkbox"/> Turn vacuum on AM, off PM
<input type="checkbox"/> Turn water lines on AM, off PM	<input type="checkbox"/> Check fluid levels in sterilizer—always before a cycle
<input type="checkbox"/> Open nitrous and O2 tanks	<input type="checkbox"/> Fill ultrasonic/drain at end of the day
<input type="checkbox"/> Refill water bottles on all units	<input type="checkbox"/> Back up computer hard drives
<input type="checkbox"/> Clean out/change as needed vacuum traps and run vacuum system cleaner through all lines	<input type="checkbox"/> Purge water lines by blowing air through them at the end of the night
<b>Weekly</b>	
<input type="checkbox"/> Spore test sterilizer	<input type="checkbox"/> Clean outside and inside of the sterilizer
<input type="checkbox"/> Check traps on all dental units	<input type="checkbox"/> Check o-rings for wear and replace as needed
<input type="checkbox"/> Lubricate vacuum valves	<input type="checkbox"/> Clean ultrasonic
<input type="checkbox"/> Wipe down light reflectors and shields	<input type="checkbox"/> Check oil on oil-lubricated compressors and drain compressor tank
<input type="checkbox"/> Empty and clean out water bottles on all units	<input type="checkbox"/> Clean out boiling chamber of water distiller
<b>Monthly</b>	
<input type="checkbox"/> If using plaster trap, clean and check	<input type="checkbox"/> Check AED battery and emergency supplies such as med kit
<input type="checkbox"/> Lubricate joints on equipment	<input type="checkbox"/> Check all filters
<b>Quarterly</b>	
<input type="checkbox"/> Check filters on compressor	<input type="checkbox"/> Check filter on vacuum
<input type="checkbox"/> Check and/or change compressor oil	<input type="checkbox"/> Check tubing on the units and N2O
<input type="checkbox"/> Clean model trimmer wheel	<input type="checkbox"/> Check traps on model trimmer and drain lines
<input type="checkbox"/> Check hydraulic fluid on the chairs	<input type="checkbox"/> Check battery backup systems on all computers
<input type="checkbox"/> Check smoke alarms	<input type="checkbox"/> Verify computer backup
<b>Yearly</b>	
<input type="checkbox"/> At least yearly, change the oil in the compressor	<input type="checkbox"/> Change sterilizer gaskets
<input type="checkbox"/> Conduct staff OSHA training	<input type="checkbox"/> CPR (every 2 years if AHA)
<input type="checkbox"/> Check for worn cords	<input type="checkbox"/> Check equipment for leaks
<input type="checkbox"/> Conduct emergency drills	<input type="checkbox"/> Check AED for expired pads or battery
<input type="checkbox"/> Have x-ray equipment inspected, calibrated, and certified	<input type="checkbox"/>

**LOGBOOKS:**

A sample clinical area logbook should include:

<input type="checkbox"/> X-ray calibration and recertification of equipment logbook	<input type="checkbox"/> Fire extinguisher replenishment and fire inspections logbook
<input type="checkbox"/> Sharps and red bag contaminates disposal log	<input type="checkbox"/> Spore testing and documentation of sterilization equipment maintenance log
<input type="checkbox"/> MSDS logbook	<input type="checkbox"/> Dosimeter results log
<input type="checkbox"/> Staff training logbook	<input type="checkbox"/> Water line testing log
<input type="checkbox"/> Oil changing in the compressor log	<input type="checkbox"/> Other state-required mandated logs

Fig. 31.11 Clinical maintenance checklist.

**References**

- Collins J. *Good to great*. William Collins: New York, NY, 2001.
- Parker JF. *Do the right thing*. Pearson Education Inc: Upper Saddle River, NJ, 2008.
- The Rule of 72: Double your money, reduce your debt*. Available at: <http://www.investopedia.com/ask/answers/what-is-the-rule-72/> (Accessed October 28, 2020).
- Kouzes JM, Posner BW. *The leadership challenge*. Jossey-Bass Inc: San Francisco, 1995.
- American Dental Association. Member Services. Available at: <http://www.ada.org/en/member-center> by telephone 1-800-947-4746; or reference librarians at the ADA Library, 312-440-2653.
- Professional DynaMetric Programs (PDP), [www.pdpglobal.com](http://www.pdpglobal.com). (Accessed October 28, 2020).
- Blanchard K, Johnson S. *The one minute manager*. Harper Collins: New York, 2003.
- CDT. Dental Procedure Codes. <http://ebusiness.ada.org/>. (Accessed October 28, 2020).
- American Dental Association Council on Dental Practice. <https://ebusiness.ada.org/productcatalog/3273/Center-for-Professional-Success/Dental-Practice-Dental-Records/CPSPR180> (Accessed October 28, 2020).
- Centers for Disease Control and Prevention: <http://www.cdc.gov/oralhealth/infectioncontrol/guidelines/index.htm>. (Accessed October 28, 2020).
- U.S. Department of Health and Human Services. HIPAA Privacy Regulations. Available at: <http://www.hhs.gov/hipaa/index/html>. (Accessed October 28, 2020).
- Occupational Safety and Health Administration: <https://www.osha.gov/Publications/OSHA3187/osha3187.html>. (Accessed October 28, 2020).