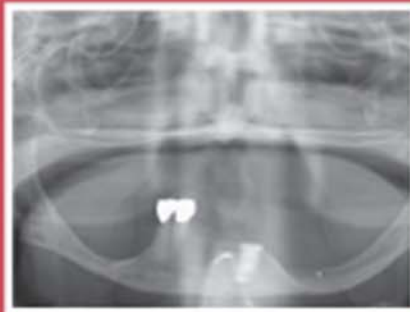
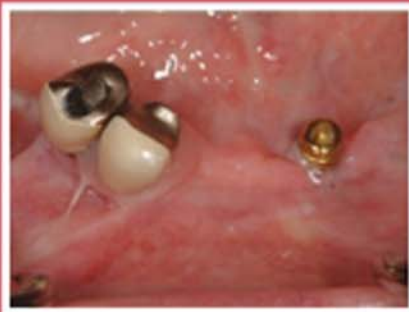
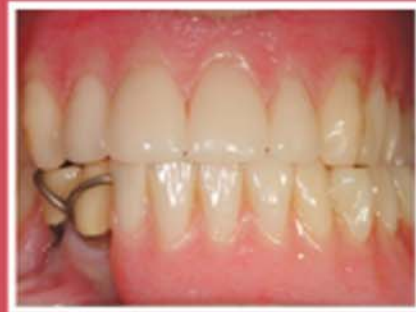
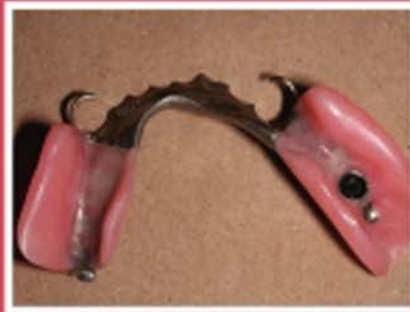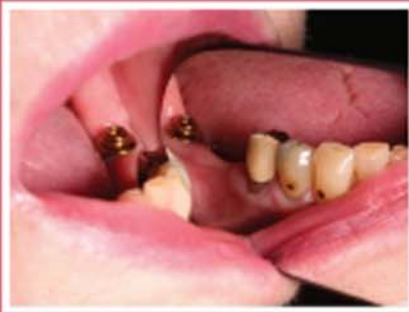Thirteenth Edition

McCracken's

# REMOVABLE PARTIAL PROSTHODONTICS



Alan B. Carr  
David T. Brown

ELSEVIER

McCracken's  
**REMOVABLE  
PARTIAL  
PROSTHODONTICS**

سایت کنکور

**WWW.KONKUR.IN**

مرجع دانلود رایگان کتب علوم پزشکی و مهندسی

آرشیو کامل و رایگان کنکورهای ارشد، دکتری و آزمونهای مقاطع و گرایشهای مختلف علوم پزشکی

This page intentionally left blank

Thirteenth Edition

**McCracken's**  
**REMOVABLE**  
**PARTIAL**  
**PROSTHODONTICS**

**Alan B. Carr, DMD, MS**

Professor  
Department of Dental Specialties  
Mayo Clinic  
Rochester, Minnesota

**David T. Brown, DDS, MS**

Chair  
Department of Comprehensive Care and General Dentistry  
Indiana University  
School of Dentistry  
Indianapolis, Indiana

ELSEVIER

ELSEVIER

3251 Riverport Lane  
St. Louis, Missouri 63043

McCRACKEN'S REMOVABLE PARTIAL PROSTHODONTICS,  
THIRTEENTH EDITION

ISBN: 978-0-323-33990-2

Copyright © 2016 by Elsevier, Inc. All rights reserved.

No part of this publication may be reproduced or transmitted in any form or by any means, electronic or mechanical, including photocopying, recording, or any information storage and retrieval system, without permission in writing from the publisher. Details on how to seek permission, further information about the Publisher's permissions policies and our arrangements with organizations such as the Copyright Clearance Center and the Copyright Licensing Agency, can be found at our website: [www.elsevier.com/permissions](http://www.elsevier.com/permissions).

This book and the individual contributions contained in it are protected under copyright by the Publisher (other than as may be noted herein).

Notices

Knowledge and best practice in this field are constantly changing. As new research and experience broaden our understanding, changes in research methods, professional practices, or medical treatment may become necessary.

Practitioners and researchers must always rely on their own experience and knowledge in evaluating and using any information, methods, compounds, or experiments described herein. In using such information or methods they should be mindful of their own safety and the safety of others, including parties for whom they have a professional responsibility.

With respect to any drug or pharmaceutical products identified, readers are advised to check the most current information provided (i) on procedures featured or (ii) by the manufacturer of each product to be administered, to verify the recommended dose or formula, the method and duration of administration, and contraindications. It is the responsibility of practitioners, relying on their own experience and knowledge of their patients, to make diagnoses, to determine dosages and the best treatment for each individual patient, and to take all appropriate safety precautions.

To the fullest extent of the law, neither the Publisher nor the authors, contributors, or editors, assume any liability for any injury and/or damage to persons or property as a matter of products liability, negligence or otherwise, or from any use or operation of any methods, products, instructions, or ideas contained in the material herein.

Previous editions copyrighted 1960, 1964, 1969, 1973, 1977, 1981, 1985, 1989, 1995, 2000, 2005, and 2011.

International Standard Book Number: 978-0-323-33990-2

Executive Content Strategist: Kathy Falk  
Content Development Manager: Jolynn Gower  
Content Development Specialist: Laura Klein  
Publishing Services Manager: Julie Eddy  
Senior Project Manager: Marquita Parker  
Designer: Ryan Cook

Printed in Canada

Last digit is the print number: 9 8 7 6 5 4 3 2 1



Working together  
to grow libraries in  
developing countries

[www.elsevier.com](http://www.elsevier.com) • [www.bookaid.org](http://www.bookaid.org)

# Preface

In response to the question, “What is the purpose of research?” a recent *Lancet* editorial suggests a redefinition of the purpose of research is critical due to an alarming lack of concordance between a reasoned research purpose and actual research reality.\* Ian Chalmers provides a clear reasoned purpose of research as being, “to help patients and their clinicians.”† He goes on to describe 85% waste associated with research meeting this target, and relates this to several root causes: choosing the wrong questions, conducting unnecessary or poorly designed studies, failure to publish in a timely manner or at all, and biased or unusable reports of research.

The editors of this textbook consider the related question each time the publisher requests an update. “What is the purpose of a textbook?” This question becomes increasingly important as technology shapes the behavior of learners and therefore the strategies for enhancing learning. As Chalmers and Glasziou state, we believe the purpose of a textbook is to help patients by helping their providers. A textbook may help providers at various stages of a career.

For first time learners, it helps by presenting a foundation for learning during a period of active and diverse information exposure for the developing clinician. Competing for learners’ attention during this phase, presenting content that can be directly applied to first time application scenarios is a challenge for teachers and compels texts be designed to add substance, not waste. For practicing clinicians, a textbook can provide reinforcement of principles useful for clinical decisions and their application; especially if the clinical challenges become more complex for the maturing provider. In this context, a text can serve as a source of continuing reference as clinical experience expands a clinician’s expertise in application of basic principles, allowing more in-depth understanding and application.

The editors also recognize that as providers of oral health care, we are part of a changing health care environment. It is evident that our contribution to overall health and well-being of society will be an increasing part of the United States health care value discussion, a discussion that stems from the recognition that care costs and quality are not aligned in the United States. The current “value care” transition

from “volume care” places a premium on patient-centered needs/desires, demonstration of beneficial outcomes, and cost containment in a context of care over time. This context fits the care needs addressed by tooth replacement interventions. Management of tooth loss must be considered as a life-long process. Each decision along a patient’s “life course” can substantially impact subsequent care opportunities and therefore the decisions made. What is critical to recognize is that the impact of decisions is not equivalent among options.

Consequently, we provide an argument that if removable partial denture-related decisions impart a high risk of comorbidity compared to other options, yet the specific patient situation disallows other options, selective implant utilization with removable partial dentures most often can reduce this detrimental impact. However, the current implant application must take the future potential for complete implant support for tooth replacements into account. In the last edition, we considered that selective use of implants to address movement control concerns for removable partial dentures to be laudable. This not only has not changed but also we stress in the current edition that helping patients understand the benefits of selective implant use to the functional stability is a discussion patients should hear.

*“Providing implants to support all teeth needing replacement is often preferable if indicated and if the patient can afford to do so. If the patient is unable to pursue an implant-only supported prosthesis, this should not keep him or her from considering an implant, because the patient still may benefit from a carefully selected implant used for critical clinical performance advantage when removable partial dentures are pursued. Additionally, implants can be used for removable partial dentures to allow future implant-only treatment options.”*

We continue the previous edition’s use of design features that provide a content distinction—shading text intended for more experienced clinicians. In Chapter 10, “Principles of Removable Partial Denture Design,” we have attempted to address the continued input from teachers that design of removable partial dentures is a major barrier to learners. In Chapter 10, we have added a basic design strategy for the major tooth loss classifications in the hope that providing a systematic approach with a baseline design protocol may assist this challenge.

\*Horton R: Editorial: what is the purpose of medical research? *Lancet* 381:347, 2013.

†Chalmers I, Glasziou P: Avoidable waste in the production and reporting of research evidence, *Lancet* 374:86-89, 2009.

# About the Book

## NEW TO THIS EDITION

---

- Updating of implant-related applications to removable partial dentures
  - Impact on design, care provision, and performance utility
- Removable partial denture design examples provided for basic/most common tooth loss distributions
  - Intending to establish a foundation of understanding and application
  - Stressing the need for *required* tooth modification
    - Suggesting that standardizing this process impacts care delivery efficiency for the provider and dental laboratory

## KEY FEATURES

---

- Content considered beyond the basic level is set within a shaded box
- A wide selection of relevant references is presented at the back of the textbook in Appendix B for quick-and-easy access
- Various philosophies and techniques are presented throughout, facilitating the selection and incorporation of the applicable techniques on a case-by-case basis
- Chapters presented in three logically-sequenced sections:
  - Part I: General Concepts/Treatment Planning
  - Part II: Clinical and Laboratory
  - Part III: Maintenance

# Acknowledgments

---

We would like to express our gratitude to many who contributed to this text in a variety of ways. Contributions to the text were provided by Dr. Tom Salinas, who assisted with the Implant chapter, and Dr. Vanchit John, who provided input regarding periodontal therapy in mouth preparation. We also would like to acknowledge the following contributors to the clinical images: Drs. Ned van Roekel, James Taylor, Miguel Alfaro, and Carl Andres. We also acknowledge the helpful work of a dedicated group of laboratory technicians who contributed to the updates of many laboratory procedure images: Mr. Joe Bly, Mr. Albert Evans, and Mr. Rick Lee. The clerical assistance of Mrs. Melanie Budihas and Mrs. Barbara Jarjoura is also acknowledged and greatly appreciated.

**Alan B. Carr**

**David T. Brown**

# About the Authors

**Dr. Alan B. Carr**, Chair of the Department of Dental Specialties at Mayo Clinic, is a consultant in the Division of Prosthodontics and a professor of dentistry at the Mayo Clinic College of Medicine. Dr. Carr received his prosthodontics training at Mayo. Following his training, he was an assistant professor at Marquette University and then became a full professor at The Ohio State University, where his clinical duties included Director of Maxillofacial Prosthetics at the James Cancer Hospital. He returned to Mayo in 2000. Dr. Carr is board certified by the American Board of Prosthodontics. He served in the Air Force and has degrees from the University of Southern Mississippi, University of Mississippi, and Mayo Graduate School of Medicine. He is also a member of the American Dental Association and the American College of Prosthodontists. He contributes to scholarly efforts nationally and internationally. His clinical practice focuses on combined prosthodontics and reconstruction of patients with disabling oral conditions. His research interests include patient management best practices, clinical practice

analytics using practice-specific outcome registries, and the impact of oral health on general health and well-being.

**Dr. David T. Brown**, Indiana University School of Dentistry, is the Chair of the Comprehensive Care and General Dentistry Department and Professor of Prosthodontics. Dr. Brown is a Summa Cum Laude graduate of The Ohio State University College of Dentistry and received his prosthodontic training at the Mayo Clinic/Mayo Graduate School of Medicine. He has been a full-time faculty member at Indiana University since 1986, teaching in both the predoctoral curriculum and the postgraduate prosthodontic program. Dr. Brown is board certified by the American Board of Prosthodontics. He has been a reviewer for a number of professional journals and is a member of several dental and prosthodontic organizations. He currently serves as a member of the Executive Council for the Academy of Prosthodontics. Dr. Brown maintains a part-time practice limited to prosthodontics.

# Contents

## PART I: GENERAL CONCEPTS/TREATMENT PLANNING

### 1 Partially Edentulous Epidemiology, Physiology, and Terminology 2

Tooth Loss and Age	4
Consequences of Tooth Loss	5
Functional Restoration with Prostheses	5
Current Removable Partial Denture Use	6
Need for Removable Partial Dentures	7

### 2 Considerations for Managing Partial Tooth Loss 8

Managing Tooth Loss Over Time	8
Tooth-Supported Prostheses	9
Tooth- and Tissue-Supported Prostheses	10
The Phases of Partial Denture Service	12
Reasons for Failure of Clasp-Retained Partial Dentures	14

### 3 Classification of Partially Edentulous Arches 16

Requirements of an Acceptable Method of Classification	17
Kennedy Classification	17
Applegate's Rules for Applying the Kennedy Classification	20

### 4 Biomechanics of Removable Partial Dentures 21

Biomechanics and Design Solutions	21
Biomechanical Considerations	22
Impact of Implants on Movements of Partial Dentures	22
Simple Machines	23
Possible Movements of Partial Dentures	24

### 5 Major and Minor Connectors 29

Role of Major Connectors in Control of Prosthesis Movement	30
Minor Connectors	45
Finishing Lines	50
Reaction of Tissue to Metallic Coverage	50
Major Connectors in Review	52

### 6 Rests and Rest Seats 56

Role of Rests in Control of Prosthesis Movement	56
Form of the Occlusal Rest and Rest Seat	58
Extended Occlusal Rest	59
Interproximal Occlusal Rest Seats	60
Internal Occlusal Rests	61

Implants as a Rest	61
Support for Rests	61
Lingual Rests on Canines and Incisor Teeth	63
Incisal Rests and Rest Seats	65

### 7 Direct Retainers 67

Direct Retainer's Role in Control of Prosthesis Movement	67
Basic Principles of Clasp Design	68
Types of Direct Retainers	70
Criteria for Selecting a Given Clasp Design	71
Types of Clasp Assemblies	71
Implants as Direct Retainers	81
Analysis of Tooth Contours for Retentive Clasps	83
Amount of Retention	84
Other Types of Retainers	89
Internal Attachments	90

### 8 Indirect Retainers 93

Role of Indirect Retainers in Control of Prosthesis Movement	93
Factors Influencing Effectiveness of Indirect Retainers	96
Auxiliary Functions of Indirect Retainers	96
Forms of Indirect Retainers	96

### 9 Denture Base Considerations 99

Functions of Denture Bases in Control of Prosthesis Movement	99
Methods of Attaching Denture Bases	102
Methods for Incorporating Dental Implants	103
Ideal Denture Base Material	103
Advantages of Metal Bases	104
Methods of Attaching Artificial Teeth	106
Need for Relining	109
Stress-Breakers (Stress Equalizers)	110

### 10 Principles of Removable Partial Denture Design 112

Difference in Prosthesis Support and Influence on Design	112
Differentiation Between Two Main Types of Removable Partial Dentures	113
Essentials of Partial Denture Design	115
Components of Partial Denture Design	117
Implant Considerations in Design	122
Examples of Systematic Approach to Design	122
Additional Considerations Influencing Design	125

<b>11 Surveying</b>	<b>127</b>	Periodontal Preparation	193
Description of Dental Surveyor	128	Optimization of the Foundation for Fitting and Function of the Prosthesis	200
Purposes of the Surveyor	129		
Factors that Determine Path of Placement and Removal	133	<b>15 Preparation of Abutment Teeth</b>	<b>206</b>
Step-by-Step Procedures in Surveying a Diagnostic Cast	135	Classification of Abutment Teeth	207
Final Path of Placement	138	Sequence of Abutment Preparations on Sound Enamel or Existing Restorations	207
Recording Relation of Cast to Surveyor	139	Abutment Preparations Using Conservative Restorations	207
Surveying the Master Cast	140	Abutment Preparations Using Crowns	209
Measuring Retention	140	Splinting of Abutment Teeth	213
Blocking out the Master Cast	141	Use of Isolated Teeth as Abutments	214
Relieving the Master Cast	142	Missing Anterior Teeth	215
Paralleled Blockout, Shaped Blockout, Arbitrary Blockout, and Relief	144	Temporary Crowns when a Removable Partial Denture is Being Worn	216
		Fabricating Restorations to Fit Existing Denture Retainers	216
<b>12 Considerations for the Use of Dental Implants with Removable Partial Dentures</b>	<b>146</b>	<b>16 Impression Materials and Procedures for Removable Partial Dentures</b>	<b>219</b>
Physiologic Distinction Between Prostheses	147	Elastic Materials	219
Replacing Anatomy and Functional Ability	147	Rigid Materials	221
Strategically Placed Implants for Removable Partial Denture Stability and Improved Patient Accommodation	148	Thermoplastic Materials	221
Movement Control With Selective Implant Placement	148	Impressions of the Partially Edentulous Arch	222
Treatment Planning	149	Individual Impression Trays	225
Clinical Examples	149		
Summary	149	<b>17 Support for the Distal Extension Denture Base</b>	<b>231</b>
Acknowledgment	149	Distal Extension Removable Partial Denture	232
		Factors Influencing the Support of a Distal Extension Base	232
		Anatomic form Impression	236
		Methods for Obtaining Functional Support for the Distal Extension Base	236
		<b>18 Occlusal Relationships for Removable Partial Dentures</b>	<b>242</b>
		Desirable Occlusal Contact Relationships for Removable Partial Dentures	243
		Methods for Establishing Occlusal Relationships	244
		Materials for Artificial Posterior Teeth	250
		Establishing Jaw Relations for a Mandibular Removable Partial Denture Opposing a Maxillary Complete Denture	251
		<b>19 Laboratory Procedures</b>	<b>253</b>
		Duplicating a Stone Cast	253
		Waxing the Removable Partial Denture Framework	254
		Spruing, Investing, Burnout, Casting, and Finishing of the Removable Partial Denture Framework	258
		Making Record Bases	266
		Occlusion Rims	268
<b>PART II: CLINICAL AND LABORATORY</b>			
<b>13 Diagnosis and Treatment Planning</b>	<b>155</b>		
Purpose and Uniqueness of Treatment	155		
Patient Interview	155		
Shared Decision Making	156		
Clinical Examination	156		
Objectives of Prosthodontic Treatment	156		
Oral Examination	157		
Diagnostic Casts	161		
Diagnostic Findings	169		
Interpretation of Examination Data	169		
Infection Control	177		
Differential Diagnosis: Fixed or Removable Partial Dentures	178		
Choice Between Complete Dentures and Removable Partial Dentures	183		
Clinical Factors Related to Metal Alloys used for Removable Partial Denture Frameworks	185		
Summary	187		
<b>14 Preparation of the Mouth for Removable Partial Dentures</b>	<b>188</b>		
Pre-Prosthetic Considerations in Partially Edentulous Mouths	189		

Making a Stone Occlusal Template from a Functional Occlusal Record	270	<b>23 Repairs and Additions to Removable Partial Dentures</b>	<b>304</b>
Arranging Posterior Teeth to an Opposing Cast or Template	271	Broken Clasp Arms	304
Types of Anterior Teeth	272	Fractured Occlusal Rests	306
Waxing and Investing the Removable Partial Denture Before Processing Acrylic-Resin Bases	273	Distortion or Breakage of Other Components—Major and Minor Connectors	306
Processing the Denture	276	Loss of a Tooth or Teeth not Involved in Support or Retention of the Restoration	307
Remounting and Occlusal Correction to an Occlusal Template	279	Loss of an Abutment Tooth Necessitating its Replacement and Making a New Direct Retainer	307
Polishing the Denture	280	Other Types of Repairs	307
<b>20 Work Authorizations for Removable Partial Dentures</b>	<b>283</b>	Repair by Soldering	307
Work Authorization	283	<b>24 Interim Removable Partial Dentures</b>	<b>310</b>
Definitive Instructions by Work Authorizations	285	Appearance	310
Legal Aspects of Work Authorizations	288	Space Maintenance	311
Delineation of Responsibilities by Work Authorizations	288	Reestablishing Occlusal Relationships	311
<b>21 Initial Placement, Adjustment, and Servicing of the Removable Partial Denture</b>	<b>289</b>	Conditioning Teeth and Residual Ridges	311
Adjustments to Bearing Surfaces of Denture Bases	290	Interim Restoration During Treatment	312
Occlusal Interference from Denture Framework	291	Conditioning the Patient for Wearing a Prosthesis	312
Adjustment of Occlusion in Harmony with Natural and Artificial Dentition	291	Clinical Procedure for Placement	313
Instructions to the Patient	294	<b>25 Removable Partial Denture Considerations in Maxillofacial Prosthetics</b>	<b>315</b>
Follow-Up Services	296	Maxillofacial Prosthetics	315
<b>PART III: MAINTENANCE</b>		Timing of Dental and Maxillofacial Prosthetic Care for Acquired Defects	316
<b>22 Relining and Rebasing the Removable Partial Denture</b>	<b>298</b>	Intraoral Prostheses: Design Considerations	322
Relining Tooth-Supported and Tooth Implant-Supported Denture Bases	299	Surgical Preservation for Prosthesis Benefit	322
Relining Distal Extension Denture Bases	300	Maxillary Prostheses	327
Methods of Reestablishing Occlusion on a Relined Removable Partial Denture	301	Mandibular Prostheses	330
		Jaw Relation Records for Mandibular Resection Patients	336
		Summary	336
		<b>Appendix A Glossary</b>	<b>337</b>
		<b>Appendix B Selected Reading Resources</b>	<b>340</b>

This page intentionally left blank

P A R T



# GENERAL CONCEPTS/ TREATMENT PLANNING



# CHAPTER 1

## Partially Edentulous Epidemiology, Physiology, and Terminology

### CHAPTER OUTLINE

#### Tooth Loss and Age

#### Consequences of Tooth Loss

Anatomic

Physiologic

#### Functional Restoration with Protheseses

Mastication

Food Reduction

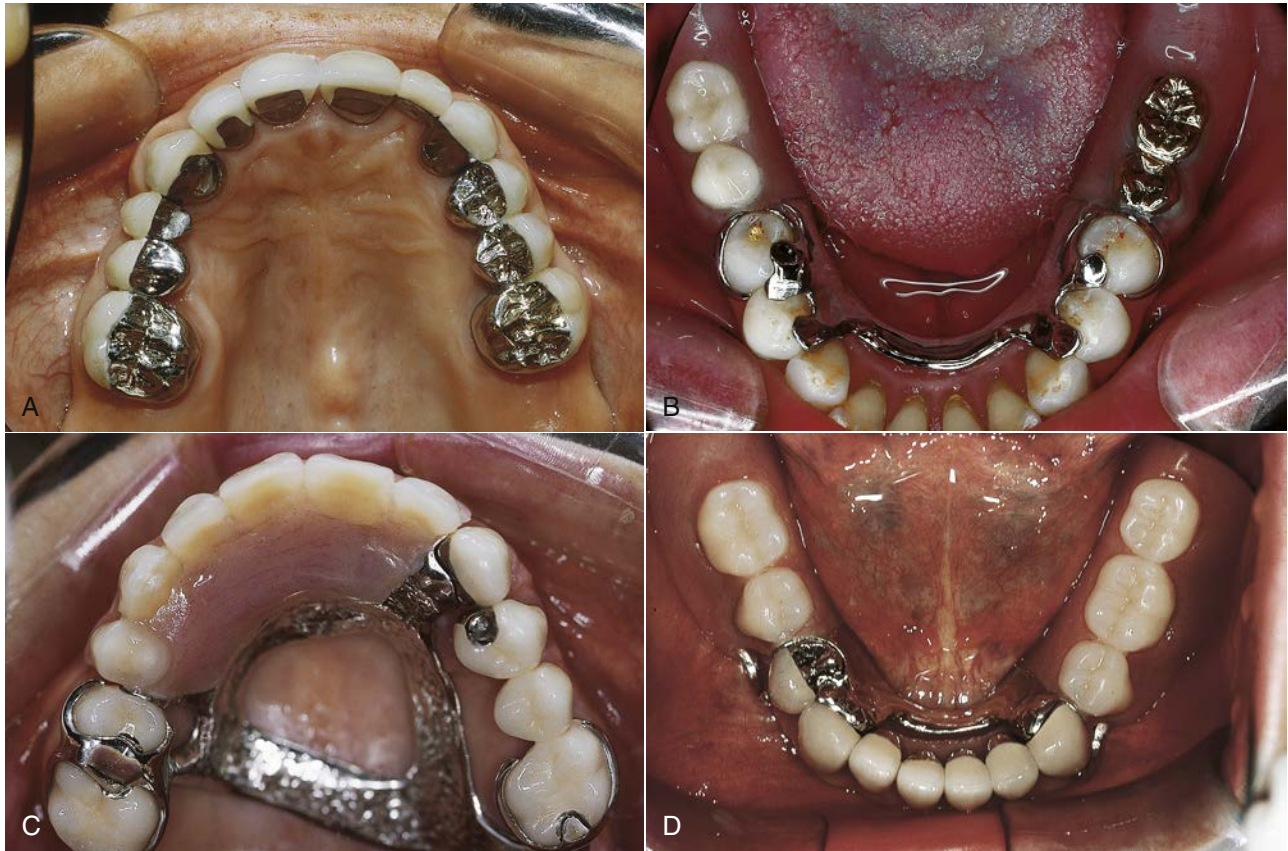
#### Current Removable Partial Denture Use

#### Need for Removable Partial Dentures

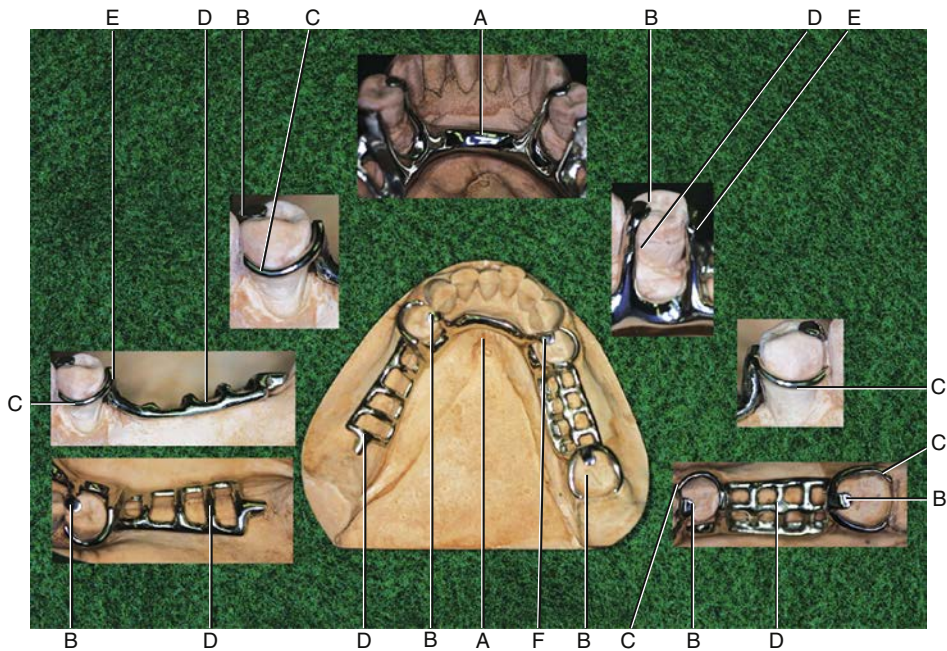
This textbook focuses on what the clinician should know about partially edentulous patients to appropriately provide comfortable and useful tooth replacements in the form of removable partial dentures. Removable partial dentures are a component of prosthodontics, the branch of dentistry pertaining to the restoration and maintenance of oral function, comfort, appearance, and health of the patient by the restoration of natural teeth and/or the replacement of missing teeth and craniofacial tissues with artificial substitutes.

Current practice in the management of partial tooth loss involves consideration of various types of protheseses ([Figure 1-1](#)). Each type of prosthesis requires the use of various remaining teeth, supporting soft tissues, and/or assigned implants, and consequently demands appropriate application of knowledge and critical thinking to ensure the best possible outcome given patient needs and desires. Although more than one prosthesis may serve the needs of a patient, any prosthesis should be provided as part of overall management that meets the basic objectives of prosthodontic treatment, which include (1) the elimination of oral disease to the greatest extent possible; (2) the preservation of the health and relationships of the teeth and the health of oral and paraoral structures, *which will enhance the removable partial denture design*; and (3) the restoration of oral functions that are comfortable, are esthetically pleasing, and do not interfere with the patient's speech. It is critically important to emphasize that the preservation of health requires proper maintenance of removable partial dentures. To provide a perspective for understanding the impact of removable partial denture prosthodontics, a review of tooth loss and its sequelae, functional restoration with protheseses, and prosthesis use and outcomes is in order.

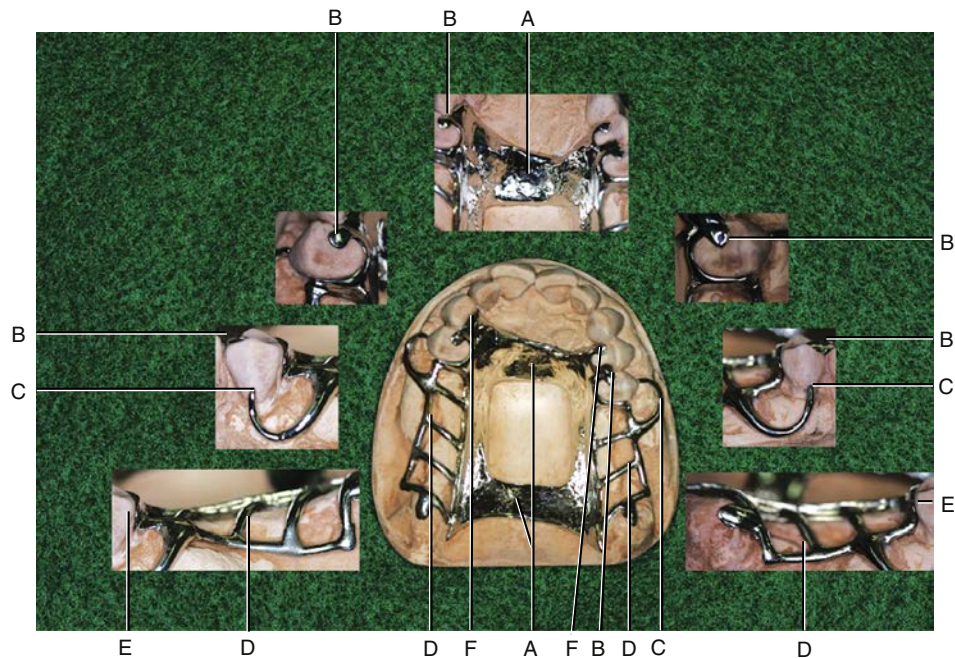
Familiarity with accepted prosthodontic terminology related to removable partial dentures is necessary. [Figures 1-2 and 1-3](#) provide prosthesis terms related to mandibular and maxillary frameworks, and Appendix A provides a review of



**FIGURE 1-1** A, Fixed partial dentures that restore missing anterior (#10) and posterior (#5, #13) teeth. Teeth bordering edentulous spaces are used as abutments. B, Clasp-type removable partial denture restoring missing posterior teeth. Teeth adjacent to edentulous spaces serve as abutments. C, Tooth-supported removable partial denture restoring missing anterior and posterior teeth. Teeth bounding edentulous spaces provide support, retention, and stability for restoration. D, Mandibular bilateral distal extension removable partial denture restoring missing premolars and molars. Support, retention, and stability are shared by abutment teeth and residual ridges.



**FIGURE 1-2** Mandibular framework designed for a partially edentulous arch with a Kennedy Classification II, modification 1 (see Chapter 3). Various component parts of the framework are labeled for identification. Subsequent chapters will describe their function, fabrication, and use. A, Major connector. B, Rests. C, Direct retainer. D, Minor connector. E, Guide plane. F, Indirect retainer.



**FIGURE 1-3** Maxillary framework designed for a partially edentulous arch with a Kennedy Classification I (see Chapter 3). As in [Figure 1-2](#), component parts are labeled for identification. A, Major connector. B, Rests. C, Direct retainer. D, Minor connector. E, Guide plane. F, Indirect retainer.

selected prosthodontic terms. Additional terminology can be reviewed in *The Glossary of Prosthodontic Terms*<sup>1</sup> and a glossary of accepted terms in all disciplines of dentistry, such as *Mosby's Dental Dictionary*, third edition.<sup>2</sup>

TOOTH LOSS AND AGE

In spite of improvements in preventive dental care, it should come as no surprise that tooth loss and age are linked. A specific tooth loss relationship has been documented with increasing age, because some teeth are retained longer than others. It has been suggested that, in general, an interarch difference in tooth loss occurs, with maxillary teeth demonstrating loss before mandibular teeth. An intra-arch difference has also been suggested, with posterior teeth lost before anterior teeth. These observations are likely related to respective caries susceptibilities, which have been reported ([Table 1-1](#)). Frequently, the last remaining teeth in the mouth are the mandibular anterior teeth, especially the mandibular canines, and it is a common finding to see an edentulous maxilla opposing mandibular anterior teeth.

If one accepts that tooth loss and age are linked, how will this affect current and future dental practice? Replacement of missing teeth is a common patient need, and patients will demand it well into their elderly years. Current population estimates show that 13% of the US population is 65 years of age or older. By the year 2030, this percentage is expected to double, with a significant increase also expected worldwide. These individuals are expected to be in better health, and health care strategies for this group should focus on

TABLE 1-1

Caries Risk Assessment\*

Risk Type	Tooth Location	Caries Susceptibility
High Risk	Lower 6 and 7	Mandibular first and second molars
	Upper 6 and 7	Maxillary first and second molars
	Lower 5	Mandibular second premolar
	Upper 1, 2, 4, 5	Maxillary central, lateral incisors Maxillary first and second premolars
Low Risk	Upper 3 and lower 4	Maxillary canine, mandibular first premolar
	Lower 1, 2, 3	Mandibular central, lateral incisors, canines

Data from Klein H, Palmer CE: Studies on dental caries: XII. Comparison of the caries susceptibility of the various morphological types of permanent teeth. *J Dent Res* 20:203-216, 1941.

\*If tooth loss parallels caries activity, caries risk may be a proxy for tooth loss.

maintenance of active and productive lives. Oral health care is expected to be a highly sought after and significant component of overall health care.

Tooth loss patterns associated with age are also evolving. The proportion of edentulous adults has been reported to be decreasing, although this varies widely by state. However, it has been reported that the absolute number of edentulous patients

who need care is actually increasing. More pertinent to this text, estimates suggest that the need for restoration of partially edentulous conditions will also be increasing. An explanation for this is presented in an argument that 62% of Americans of the “baby boomer” generation and younger have benefited from fluoridated water. The result of such exposure has been a decrease in caries-associated tooth loss. In addition, current estimates suggest that patients are keeping more teeth longer, demonstrated by the fact that 71.5% of 65- to 74-year-old individuals are partially edentulous (mean number of retained teeth = 18.9). It has been suggested that partially edentulous conditions are more common in the maxillary arch and that the most commonly missing teeth are first and second molars.

## CONSEQUENCES OF TOOTH LOSS

### Anatomic

With the loss of teeth, the residual ridge no longer benefits from the functional stimulus it once experienced. Because of this, a loss of ridge volume—both height and width—can be expected unless a dental implant is placed. The ridge volume loss is not predictable for all individuals with tooth loss, because the change in anatomy has been reported to be variable across patient groups. In general, bone loss is greater in the mandible than in the maxilla and more pronounced posteriorly than anteriorly, and it produces a broader mandibular arch while constricting the maxillary arch. These anatomic changes can present challenges to fabrication of prostheses, including implant-supported prostheses and removable partial dentures. Associated with this loss of bone is an accompanying alteration in the oral mucosa. The attached gingiva of the alveolar bone can be replaced with less keratinized oral mucosa, which is more readily traumatized.

### Physiologic

What are we replacing when we consider managing missing teeth? We are replacing both the physical anatomic tools for mastication and the oral capacity for neuromuscular functions to manipulate food. Chewing studies have shown that the oral sensory feedback that guides movement of the mandible in chewing comes from a variety of sources. The most sensitive input, which means the input that provides the most refined and precisely controlled movement, comes from periodontal mechanoreceptors (PMRs), with additional input coming from the gingiva, mucosa, periosteum/bone, and temporomandibular joint (TMJ) complex.

Chewing as a learned behavior has a basic pattern of movement that is generated from within the central nervous system. In typical function, this patterned movement is moderated on the basis of food and task needs by oral sensory input from various sources. With loss of the finely tuned contribution from tooth PMRs, the resulting peripheral receptor influence is less precise in muscular guidance, producing more variable masticatory function, and the type of prosthesis selected to replace missing teeth may potentially contribute to functional impediments.

The esthetic impact of tooth loss can be highly significant and may be more of a concern to a patient than loss of function. It is generally perceived that in today's society, loss of visible teeth, especially in the anterior region of the mouth, carries with it a significant social stigma. With loss of teeth and diminishing residual ridge, facial features can change as the result of altered lip support and/or reduced facial height caused by a reduction in occlusal vertical dimension. Restoring facial esthetics in a manner that maintains an appropriate appearance can be a challenge and is a major factor in restoration and maintenance decisions made for various prosthetic treatments.

## FUNCTIONAL RESTORATION WITH PROSTHESES

Individuals with a full complement of teeth report some variation in their levels of masticatory function. The loss of teeth may lead patients to seek care for functional reasons if they notice diminished function to a level that is unacceptable to them. The level at which a patient finds function to be unacceptable varies among individuals. This variability increases with accelerating tooth loss. This variability may be confusing to clinicians, who may perceive that they have provided prostheses of equal quality to different patients with the same tooth loss patterns, and yet have received different patient reports of success.

An understanding of these variations among individuals with a full complement of teeth and those with prostheses can help clinicians formulate realistic treatment goals that can be communicated to the patient. A review of oral function, especially mastication, may help interested clinicians better understand issues related to the impact of removable partial denture function.

### Mastication

Although functionally considered as a separate act, mastication as part of the feeding continuum precedes swallowing and is not an end in itself. The interaction of the two distinct but coordinated aspects of feeding suggests that some judgment of mastication termination or completeness precedes the initiation of swallowing. Although the mastication–swallowing sequence is obvious, the interaction of the two functions is not widely understood and may be important to prosthesis use when removable partial dentures are considered.

Mastication involves two discrete but well-synchronized activities: (1) subdivision of food by applied force; and (2) selective manipulation by the tongue and cheeks to sort out coarse particles and bring them to the occlusal surfaces of teeth for further breakdown. The initial subdivision or comminution phase involves the processes of selection, which refers to the chance that a particle is placed between the teeth in position to be broken, and breakage, which is the degree of fragmentation of a particle once selected. The size, shape, and texture of food

particles provide the sensory input that influences the configuration and area of each chewing stroke. Larger particles are selectively reduced in size more rapidly than fine particles in efficient mastication. The process of mastication is therefore greatly influenced by factors that affect physical ability to reduce food and to monitor the reduction process by neurosensory means.

### Food Reduction

Teeth or prostheses serve the role of reducing food to a point that it is ready for swallowing. An index of food reduction is described as *masticatory efficiency*, or the ability to reduce food to a certain size in a given time frame. A strong correlation has been shown between masticatory efficiency and the number of occluding teeth in dentate individuals, which would suggest variability of particle selection related to contacting teeth. Performance measures reveal a great deal of functional variability in patients with similar numbers of contacting teeth, and even greater variability is seen within populations with greater loss of teeth (increasing degrees of edentulousness).

Because occlusal contact area is highly correlated with masticatory performance, the loss of molar teeth would be expected to have a greater impact on measures of performance in that the molar has a larger occlusal contact area. This effect has been demonstrated in individuals with missing molars who reveal a greater number of chewing strokes required and a greater mean particle size before swallowing. The point at which an individual is prepared to swallow the food bolus is another measure of performance and is described as the *swallowing threshold*. Superior masticatory ability that is highly correlated with occlusal contact area also achieves greater food reduction at the swallowing threshold. Conversely, a diminished ability to chew is reflected in larger particles at the swallowing threshold.

These objective measures, which show a benefit to molar contact in dentate individuals, are in conflict with some subjective measures from patients who express no perceived functional problems associated with having only premolar occlusion. This shortened dental arch concept has highlighted that patient perceptions of functional compromise, as well as benefit, should be considered when it is decided whether to replace missing molars. When the loss of posterior teeth results in an unstable tooth position, such as distal or labial migration, tooth replacement should be carefully considered; this is a separate situation from the shortened dental arch concept.

It has been reported that prosthetic replacement of teeth provides function that is often less than that seen in the complete, natural dentition state. Functional measures are closest to the natural state when replacements are fixed partial dentures rigidly supported by teeth or implants, intermediate in function when replacements are removable and supported by teeth, lower in function

when replacements are removable and supported by teeth and edentulous ridges, and lowest in function when replacements are removable and supported by edentulous ridges alone.

Objective and subjective measures of a patient's oral function often are not in agreement. It has been shown that subjective measures of masticatory ability are often overrated compared with objective functional tests and that, for complete denture wearers, the subjective criteria may be more appropriate in monitoring perceived outcomes. Some literature reports that removable partial dentures can be described by patients as adding very little benefit over no prostheses. However, these findings may be related to a number of factors, including lack of maintenance of occluding tooth relationships, limitations of this form of dental prosthesis for patient populations that may be unreliable in maintaining follow-up visits, and intrinsic variation in patient response to prostheses.

Food reduction is also influenced by the ability to monitor the process required to determine the point at which swallowing is initiated. As was mentioned earlier, the size, shape, and texture of food are monitored during mastication to allow modification in mandibular movement for efficient food reduction. This has been demonstrated in dentate individuals given food particles of varying size and concentration suspended in yogurt, who revealed that increased concentrations and particle size required more time to prepare for swallowing (i.e., greater swallowing threshold). These findings suggest that the oral mucosa has a critical role in detecting characteristics necessary for efficient mastication. The influence of the removable partial denture on the ability of the mucosa to perform this role in mastication is not known.

## CURRENT REMOVABLE PARTIAL DENTURE USE

Given an understanding of the relationship between tooth loss and age, the consequences of tooth loss, and our ability to restore function with removable partial prostheses, what do we know about current prosthesis use for these conditions, and what are some common clinical outcomes? One study estimated 21.4% prosthesis use among individuals aged 15 to 74. In the 55- to 64-year-old group, 22.2% were found to wear a removable partial denture. This age group has the highest use of removable partial dentures among those reviewed. It has been suggested that the use of removable partial dentures among individuals aged 55 years or older is even greater.

Analysis of this study provides some useful information for consideration. Partially edentulous individuals not wearing a prosthesis were six times more likely to have missing mandibular teeth (19.4%) than missing maxillary teeth (2.2%). This might suggest greater difficulty in the use of a mandibular prosthesis. The distribution of prostheses used in this large patient group is shown in [Table 1-2](#). The prostheses in this large study were evaluated on the basis of five

TABLE 1-2

Distribution of Prostheses

Type of Prosthesis	Distribution	Distribution*
Removable partial dentures	RPD/RPD 9.0%	RPD/–15.3%, –/RPD 4.5%
Complete dentures	CU/CL 3.8%	CU/–20.7%
Combination	CU/RPD 11.5%	RPD/CL 0.3%

CL, Complete lower denture; CU, complete upper denture; RPD, removable partial denture.  
\*Natural teeth denoted with dash (–).

TABLE 1-3

Technical Quality Concerns for Removable Partial Dentures

	Lack Stability	Lack Integrity	Lack Retention	Reline Material/Adhesive	Excessive Wear
Maxillary RPD	43.9%	24.3%	6.2%	3.9%	21.6%
Mandibular RPD	38.2%	13.2%	21.2%	21.6%	7.1%

RPD, Removable partial denture.

technical quality characteristics: integrity, excessive wear of posterior denture teeth, presence of a temporary reline material, tissue conditioner or adhesive, stability, and retention. As seen in Table 1-3, lack of stability was the most common characteristic noted. In the maxilla, lack of stability was seven times more prevalent than lack of retention. In the mandible, lack of stability was 1.8 times more prevalent than lack of retention. In another study, rest form, denture base extension, stress distribution, and framework fit were identified as common flaws associated with poor removable partial dentures. These characteristics are directly related to the functional stability of prostheses, a vital characteristic to evaluate and the characteristic most benefited by the use of a strategically placed dental implant.

NEED FOR REMOVABLE PARTIAL DENTURES

What does all this information mean to us today? It means a number of things that are important to consider. The need for partially edentulous management will be increasing. Patient use of removable partial dentures has been high in the past and is expected to continue in the future as an aging population who retains more teeth will present with more partially edentulous conditions. Some patients who are

given the choice between a prosthesis entirely supported by implants or a removable partial denture are not able to pursue implant care. This contributes to higher use of removable partial dentures. Such patients should understand the benefit of a strategically placed implant for the performance of the removable partial denture. Additionally, provision of such implants must consider the usefulness of the placement to a future fixed implant prosthesis.

Finally, these findings suggest that we should strive to understand how to maximize the opportunity for providing and maintaining stable prostheses, because this is the most frequently deficient aspect of removable partial denture service. Consequently, throughout this text, the basic principles of diagnosis, mouth preparation, prosthesis design, fabrication, placement, and maintenance will be reinforced to improve the reader's understanding of care of removable partial denture prostheses.

REFERENCES

1. The glossary of prosthodontic terms, ed 8. From *The Journal of Prosthetic Dentistry* 94(1):10–92, 2005. Available online. <http://www.sciencedirect.com/science/article/pii/S0022391305001757>.  
2. *Mosby's dental dictionary*, ed 3, St Louis, 2013, Mosby/Elsevier.

# CHAPTER

# 2

## Considerations for Managing Partial Tooth Loss

### *Tooth Replacements from the Patient Perspective*

#### CHAPTER OUTLINE

##### Managing Tooth Loss Over Time

- Tooth Replacements from the Patient's Perspective
- Shared Decision Making

##### Tooth-Supported Prostheses

##### Tooth- and Tissue-Supported Prostheses

##### The Phases of Partial Denture Service

- Diagnosis and Education of the Patient
- Treatment Planning, Design, Treatment Sequencing, and Mouth Preparation
- Support for Distal Extension Denture Bases
- Establishment and Verification of Occlusal Relations and Tooth Arrangements
- Initial Placement Procedures
- Periodic Recall

##### Reasons for Failure of Clasp-Retained Partial Dentures

#### MANAGING TOOTH LOSS OVER TIME

Do we treat or do we manage tooth loss? Is the distinction important as we attempt to help our patients decide which type of prosthesis to choose? For patients who want to know what to expect now and in the future, it is helpful to make this distinction, because it helps them realize that the decision has implications for future needs that may be different between prostheses.

##### Tooth Replacements from the Patient's Perspective

Tooth loss is a permanent condition in that the natural order has been disrupted, and in this sense it is much like a chronic medical condition. Like hypertension and diabetes, two medical conditions that are not reversible and that require medical management to monitor care to ensure appropriate response over time, tooth replacement prostheses must be managed to ensure appropriate response over time.

The term *management* suggests a focus on meeting needs that may change over time. These needs may be expected or unexpected. Expected outcomes are those that accompany the common clinical course for a type of prosthesis that is related to the tooth-tissue response. This biological toll response is heavily influenced by the type of prosthesis chosen. In addition, various needs due to prosthesis degradation and related to expected time-to-retreatment concerns of life expectancy are seen. Unexpected needs are those that might involve factors related to our control of manipulations (such as tissue damage or abuse, material design flaws, or prosthesis design) or to those out of our control (such as parafunction or accidental trauma).

With this in mind, it is helpful to consider how we approach educating our patients about management of missing teeth from this current point in time over the remainder

of their lives. This perspective allows current decisions to be made with a long-term context in mind, and allows decisions to enhance future treatment options.

Most often, a typical sequence is used to discuss tooth replacement options with patients: dental implant-supported prostheses, fixed prostheses, and, finally, removable partial dentures. When removable partial dentures are suggested, they are seldom described in the detail in which fixed or implant prostheses are described, because generally they are considered less like teeth and not as desirable a replacement. The desirability of a prosthesis is important to consider, and because removable partial dentures are less like teeth than other replacements, it is important to recognize what this suggests from the patient's perspective. Additionally, for the patient desiring implant management but unable to elect their use when indicated, discussion for strategic implant use for the benefit of the removable partial denture is important.

For patients who have not had missing teeth replaced, their experiences have involved natural teeth, and discussion regarding their expectations of replacements would best be described within this context. The order with which we provide replacement prosthesis options for consideration is likely developed on the basis of numerous factors, including the following: we may believe that we know what is best for patients, our practice style may not include removable options, we may not have had good experience with removable prostheses and this lessens our confidence in their use, or removable partial dentures do not match our practice resources.

Although these are important factors, the reason to include removable partial dentures in the discussion is related to identifying whether such a prosthesis is viable, and, if so, whether it is the best option for the patient. We discover this only by interacting with our patients regarding their expectations and understanding their capacity to benefit from options of management that have trade-offs unique to each type of prosthesis.

Shared Decision Making

When patients are given information regarding their oral health status, which includes disease and functional deficits, as well as the means to address both, what do they need to hear? To achieve a state of oral health, they need to recognize behavioral issues related to plaque control so that once active disease is controlled, they have an understanding that best ensures future health. For tooth replacement decisions, complex trade-offs in care choice are often required. The “shared decision making” approach addresses the need to fully inform patients about risks and benefits of care, and ensures that the patient's values and preferences play a prominent role in the ultimate decision.

It is recognized that patients vary in their desire to participate in such decisions, thus our active inquiry is required to engage them in discussion. This becomes especially important when elective care, which involves potentially

high-burden, costly options with highly variable maintenance requirements, is considered.

When patients wish to participate, it is our responsibility to provide them with specific and sufficient information that they can use to decide between treatment options. Specific information ideally comes from our own practice outcomes, in that such information provides effectiveness information and is provider specific. Sufficient information describes exactly what aspects of care are important to the overall decision. Ultimately, it is our role to help patients consider important differences between different prosthesis types.

What then defines important differences? Multiple outcomes combine to describe the overall impact of prosthetic care for all patients. These include technical outcomes, physical outcomes, esthetic outcomes, various maintenance needs, initial and future costs, and even physiologic outcomes that suggest to what extent prostheses “feel” like teeth.

When tooth replacement prostheses are considered from a patient's perspective, it can be seen that the desire is to replace teeth that serve functional and social roles in everyday life. In considering how well various types of prostheses may meet patients' specific needs, it is helpful to note what features of the original dentition—the gold standard, in this instance—we strive to duplicate in the replacement. Although it is common to find that existing oral conditions do not easily allow complete restoration to the state of a fully dentate patient, considering the respective strengths and weaknesses of the prosthodontic options (compared with this “gold standard”) helps in identification of realistic expectations.

In this text, the focus is on a type of replacement prosthesis for patients with an arch with some, but not all, of the teeth missing. Ideally, the replacement prosthesis should provide function with a level of comfort as equivalent as possible to normal dentition. In achieving this, stability while chewing is a primary focus of attention, and we should strive to determine what is required to ensure it. For the patient without posterior teeth, a prosthesis replacing these teeth is at risk for instability due to the edentulous ridge compressible support, therefore consideration of a distal implant to support the posterior segment (the distal extension) can enhance functional stability.

If the prosthesis will be visible during casual speaking, smiling, and/or laughing, it is obvious that the replacement should look as natural as the surrounding environment. In summary, tooth replacement prostheses should provide a combination of several features of natural teeth: acceptable in appearance, comfortable and stable in function, and maintainable throughout their serviceable lifetime at a reasonable cost.

TOOTH-SUPPORTED PROSTHESES

For partially edentulous patients, available prosthetic options include natural tooth-supported fixed partial dentures, removable partial dentures, and implant-supported fixed partial dentures. How well these options restore and maintain

the features of natural teeth mentioned previously depends to a large extent on the numbers and locations of the missing teeth. The major categories of partial tooth loss (see Chapter 3) are those (1) with teeth both anterior and posterior to the space (a tooth-supported space), and (2) with teeth either anterior or posterior to the space (a tooth- and tissue-supported space). All prosthetic options listed are available for the tooth-bound space (although they are not necessarily indicated for every clinical situation), but only removable partial dentures and implant-supported prostheses are available for the distal extension (recognizing limited application of cantilevers).

Removable partial dentures can be designed in various ways to allow use of abutment teeth and supporting tissue for stability, support, and retention of the prosthesis. In terms of tooth-bound spaces, the removable partial denture is like a fixed partial denture because natural teeth alone provide direct resistance to functional forces. Because natural teeth support the prosthesis, it should not move under these functional forces. In this condition, the interface between, or relationship of, the removable partial denture framework and the abutment teeth should be designed to take advantage of tooth support—similar to the relationship between a fixed partial denture retainer and a prepared tooth. This means that it should provide positive vertical support (rest preparations) and a restrictive angle of dislodgment (opposing guide planes). Put another way, when the removable partial denture is selected for a tooth-bound situation, stability under functional load should be as well controlled as a fixed partial denture when appropriate tooth preparation is provided. Because removable partial denture clasps do not completely encircle the tooth, as a fixed partial denture retainer does, they must be designed to engage more than half the circumference to allow the prosthesis to maintain position under the influence of horizontal chewing loads. It should be obvious that careful planning and execution of the necessary natural tooth contour modifications are required to ensure movement control and functional stability for removable partial dentures supported by teeth. Similarities between the prosthesis-tooth interface for fixed partial dentures and for removable partial dentures are highlighted to emphasize the modification principles required to ensure stability for movement control in removable partial dentures. Over time, natural tooth support can be maintained as with the fixed partial denture. Chapter 14 helps to explain how this is accomplished when natural tooth modifications or surveyed crowns are produced.

## TOOTH- AND TISSUE-SUPPORTED PROSTHESES

For removable partial dentures that do not have the benefit of natural tooth support at each end of the replacement teeth (extension base removable partial dentures), it is necessary that the residual ridge be used to assist in the functional stability of the prosthesis. When a removable partial denture is

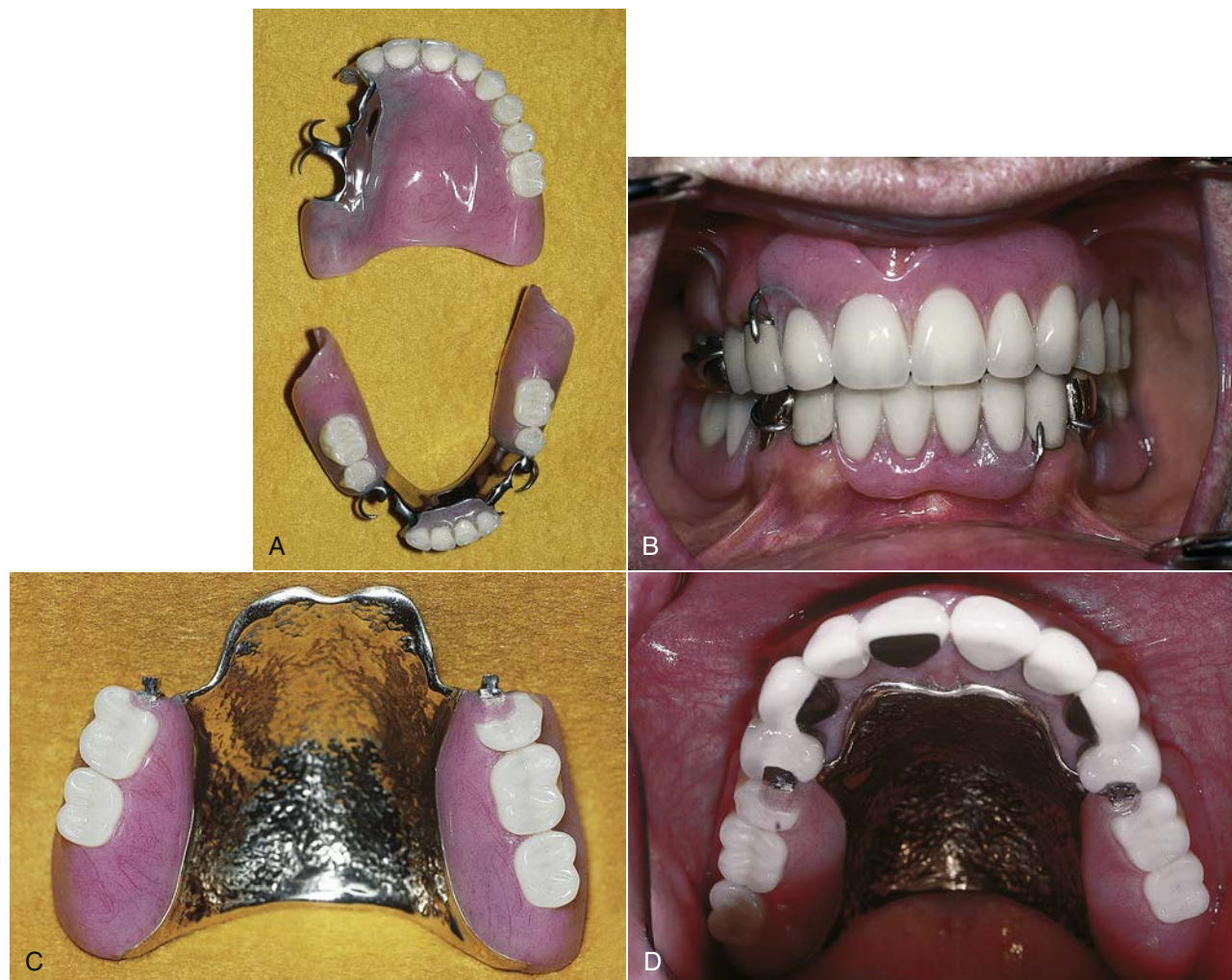
selected for a tooth- and tissue-supported arch, the prosthesis must be designed to allow functional movement of the base to the extent expected by the residual ridge mucosa. This mucosa movement is variable, but for healthy residual ridge (masticatory) mucosa, movement from 1 to 3 mm can be expected. Consequently, unlike with the tooth-bound space, tooth modification for the tooth- and tissue-supported prosthesis must be designed with the dual goal of framework tooth contact to allow appropriate functional stability from the tooth but with allowance for the anticipated vertical and/or horizontal movement of the extension base. This introduces the concept of anticipated movement with a prosthesis and the requirement that we have a role in designing prostheses to appropriately control movement. Additionally, because tissue support in the tooth- and tissue-supported removable partial denture predictably changes over time, to adequately manage partial tooth loss with a removable prosthesis, we must carefully monitor our patients to maintain support and ensure maximum prosthetic function.

The clasp-retained partial denture is the most commonly used removable partial denture (Figure 2-1). It is capable of providing physiologically sound treatment for most patients who need partial denture restorations. Although the clasp-retained partial denture has disadvantages, its advantages of lower cost and shorter fabrication time ensure that it will continue to be widely used. Following are some possible disadvantages of a clasp-retained partial denture:

1. Strain on the abutment teeth is often caused by improper tooth preparation or clasp design and/or loss of tissue support under the distal extension partial denture bases.
2. Clasps can be unesthetic, particularly when they are placed on visible tooth surfaces without consideration of esthetic impact.
3. Caries may develop beneath clasp and other framework components, especially if the patient fails to keep the prosthesis and the abutments clean.

Despite these disadvantages, the use of removable prostheses may be preferred when tooth-bounded edentulous spaces are too large to be restored safely with fixed prostheses, or when cross-arch stabilization and wider distribution of forces to supporting teeth and tissues are desirable. Fixed partial dentures, however, should always be considered and used when indicated.

The removable partial denture retained by internal attachments eliminates some of the disadvantages of clasps, but it has other disadvantages, one of which is higher cost, which makes it more difficult to obtain for a large percentage of patients who need partial dentures. However, when alignment of the abutment teeth is favorable and periodontal health and bone support are adequate, when the clinical crown is of sufficient length and the pulp morphology can accommodate the required tooth preparation, and when the economic status of the patient permits, an internal attachment prosthesis provides an unquestionable advantage for esthetic reasons. When this



**FIGURE 2-1** **A**, Maxillary and mandibular clasp-retained removable partial dentures. All clasps are extracoronal retainers (clasps) on abutments. **B**, Prostheses from (**A**) shown intraorally in occlusion. **C**, Maxillary prosthesis using intracoronal retainers and full palatal coverage. The male portions of the attachments are shown at the mesial position of the artificial teeth and will fit into intracoronal rests. **D**, Internal attachment prosthesis in the patient's mouth. Note the precise fit of male and female portions of the attachments.

situation exists, carefully weighing tooth attachment versus implant attachment options is required (see Removable Partial Dentures and Implants, Chapter 12).

In most instances, if the extracoronal clasp-retained partial denture is designed properly, the only advantage of the internal attachment denture is esthetic, because abutment protection and stabilizing components should be used with both internal and external retainers. However, economics permitting, esthetics alone may justify the use of internal attachment retainers, especially when a crown is indicated for non-removable partial denture reasons.

Injudicious use of internal attachments can lead to excessive torsional load on the abutments supporting distal extension removable partial dentures, especially in the mandible. The use of hinges or other types of stress breakers is discouraged in these situations. It is not that they are ineffective, but that they are frequently misused. As an example, in the mandibular arch, a stress-broken distal

extension partial denture does not provide for cross-arch stabilization and frequently subjects the edentulous ridge to excessive trauma from horizontal and torquing forces. Therefore a rigid design is preferred, and some type of extracoronal clasp retainer is still the most logical and the most frequently used. It seems likely that its use will continue until a more widely-acceptable retainer is devised.

As mentioned in Chapter 1, the most commonly cited problem associated with removable partial dentures is instability. Healthy natural teeth should not move when used; therefore we should strive to provide and maintain as stable a prosthesis as possible given the means available. How do we ensure functional stability? By understanding that a removable partial denture can move under function (because it is not cemented to teeth like a fixed partial denture). We should take steps to prescribe the necessary prosthetic fit to teeth (and tissue) to control movement as much as possible.

This entails providing appropriate natural tooth mouth preparations, ensuring an accurate frame fit at tooth and tissue, providing a simultaneous contacting relationship between natural and prosthetic opposing teeth, and providing and maintaining optimum support from the soft tissue and teeth. It also may require strategic use of implants to control distal extension movement.

As we will review in Chapter 4, control of the anticipated movement of your prosthesis is addressed by assigning the appropriate component part of the prosthesis to contact/engage the tooth or tissue in a manner that allows movement and removal of the prosthesis. Are there movements that we should control that are more important than others? Although we recognize the need to resist movement away from the teeth and tissue to keep prostheses from falling out of mouths, the most damaging forces are those resulting from functional closure during chewing (and in some patients, parafunction). Consequently, control of combined vertical (tissue-ward) and horizontal movement is most critical and places a premium on tooth modifications (rest and stabilizing component preparations) and verification of adequate fit of the frame to the teeth.

## THE PHASES OF PARTIAL DENTURE SERVICE

Partial denture service may be conceptually divided into phases. The first phase involves making the appropriate diagnosis, deciding a removable partial denture is indicated, and providing patient education regarding removable partial denture expectations over time. The second phase includes treatment planning, design of the partial denture framework, treatment sequencing, and execution of mouth preparations. The third phase is the provision of adequate support for the distal extension denture base. The fourth phase is establishment and verification of harmonious occlusal relationships and tooth relationships with opposing and remaining natural teeth. The fifth phase involves initial placement procedures, including adjustments to the contours and bearing surfaces of denture bases, adjustments to ensure occlusal harmony, and a review of instructions given the patient to optimally maintain oral structures and provided restorations. The sixth and final phase of partial denture service consists of follow-up services by the dentist through recall appointments for periodic evaluation of the responses of oral tissue to restorations and of the acceptance of restorations by the patient. The context of each phase is discussed in greater detail in the respective chapters of this book.

### Diagnosis and Education of the Patient

The term *patient education* is described in *Mosby's Dental Dictionary* as "the process of informing a patient about a health matter to secure informed consent, patient cooperation, and a high level of patient compliance."

The dentist and the patient share responsibility for the ultimate success of a removable partial denture. It is folly to assume that a patient has an understanding of the benefits of

a removable partial denture unless he or she is so informed. It is also unlikely that the patient has the knowledge to avoid misuse of the restoration or is able to provide the required oral care and maintenance procedures to ensure the success of the partial denture unless he or she is adequately advised.

The finest biologically-oriented removable partial denture is often doomed to limited success if the patient fails to exercise proper oral hygiene habits or ignores recall appointments. Preservation of the oral structures, one of the primary objectives of prosthodontic treatment, is compromised without the patient's cooperation in oral hygiene and regular maintenance visits.

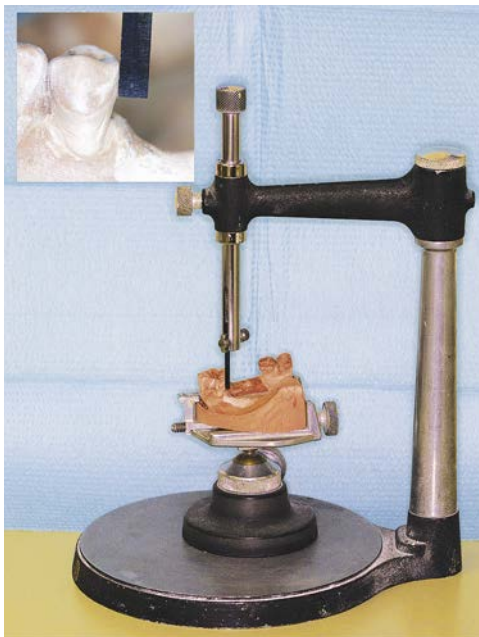
Patient education should begin at the initial diagnosis and should continue throughout treatment. This educational procedure is especially important when the treatment plan and prognosis are discussed with the patient. Limitations imposed on the success of treatment through failure of the patient to accept responsibility must be explained before definitive treatment is undertaken. A patient usually does not retain all the information presented in the oral educational instructions. For this reason, patients should be given written suggestions to reinforce the oral presentations.

### Treatment Planning, Design, Treatment Sequencing, and Mouth Preparation

Treatment planning and design begin with thorough medical and dental histories. The complete oral examination must include both clinical and radiographic interpretation of (1) caries, (2) the condition of existing restorations, (3) periodontal conditions, (4) responses of teeth (especially abutment teeth) and residual ridges to previous stress, and (5) the vitality of remaining teeth. In addition, evaluation of the occlusal plane, the arch form, and the occlusal relations of the remaining teeth must be meticulously accomplished by clinical visual evaluation and diagnostic mounting. After a complete diagnostic examination has been accomplished and a removable partial denture has been selected as the treatment of choice, a treatment plan is sequenced and a partial denture design is developed in accordance with available support.

The dental cast surveyor ([Figure 2-2](#)) is an absolute necessity in any dental office in which patients are being treated with removable partial dentures. The surveyor is instrumental in diagnosing and guiding the appropriate tooth preparation and verifying that the mouth preparation has been performed correctly. There is no more reason to justify its omission from a dentist's armamentarium than there is to ignore the need for roentgenographic equipment, the mouth mirror and explorer, or the periodontal probe used for diagnostic purposes.

Several moderately priced surveyors that adequately accomplish the diagnostic procedures necessary for designing the partial denture are available. In many dental offices, this most important phase of dental diagnosis is delegated to the commercial dental laboratory either because this invaluable diagnostic tool is absent or because the dentist feels



**FIGURE 2-2** Dental cast surveyor facilitates the design of a removable partial denture. It is an instrument by which parallelism or lack of parallelism of abutment teeth and other oral structures, on a stone cast, can be determined (*magnified view shows parallel guide plane surface*). Use of the surveyor is discussed in later chapters.

inexperienced or is apathetic. This situation places the technician in the role of diagnostician. Any clinical treatment based on the diagnosis of the technician remains the responsibility of the dentist. This makes no more sense than relying on the technician to interpret radiographs and to render a diagnosis.

After treatment planning, a predetermined sequence of mouth preparations can be performed with a definite goal in mind. It is mandatory that the treatment plan be reviewed to ensure that the mouth preparation necessary to accommodate the removable partial denture design has been properly sequenced. Mouth preparations, in the appropriate sequence, should be oriented toward the goal of providing adequate support, stability, retention, and a harmonious occlusion for the partial denture. Placing a crown or restoring a tooth out of sequence may result in the need to restore teeth that were not planned for restoration, or it may necessitate remaking a restoration or even seriously jeopardizing the success of the removable partial denture. Through the aid of diagnostic casts on which the tentative design of the partial denture has been outlined and the mouth preparations have been indicated in colored pencil, occlusal adjustments, abutment restorations, and abutment modifications can be accomplished.

### Support for Distal Extension Denture Bases

The third of the six phases in the treatment of a patient with a partial denture involves obtaining adequate support for

distal extension bases. Therefore it does not apply to tooth-supported removable partial dentures. With the latter, support comes entirely from the abutment teeth through the use of rests.

For the distal extension partial denture, however, a base made to fit the anatomic ridge form does not provide adequate support under occlusal loading (Figure 2-3). Neither does it provide for maximum border extension nor accurate border detail. Therefore some type of corrected impression is necessary. This may be accomplished by several means, any of which satisfy the requirements for support of any distal extension partial denture base.

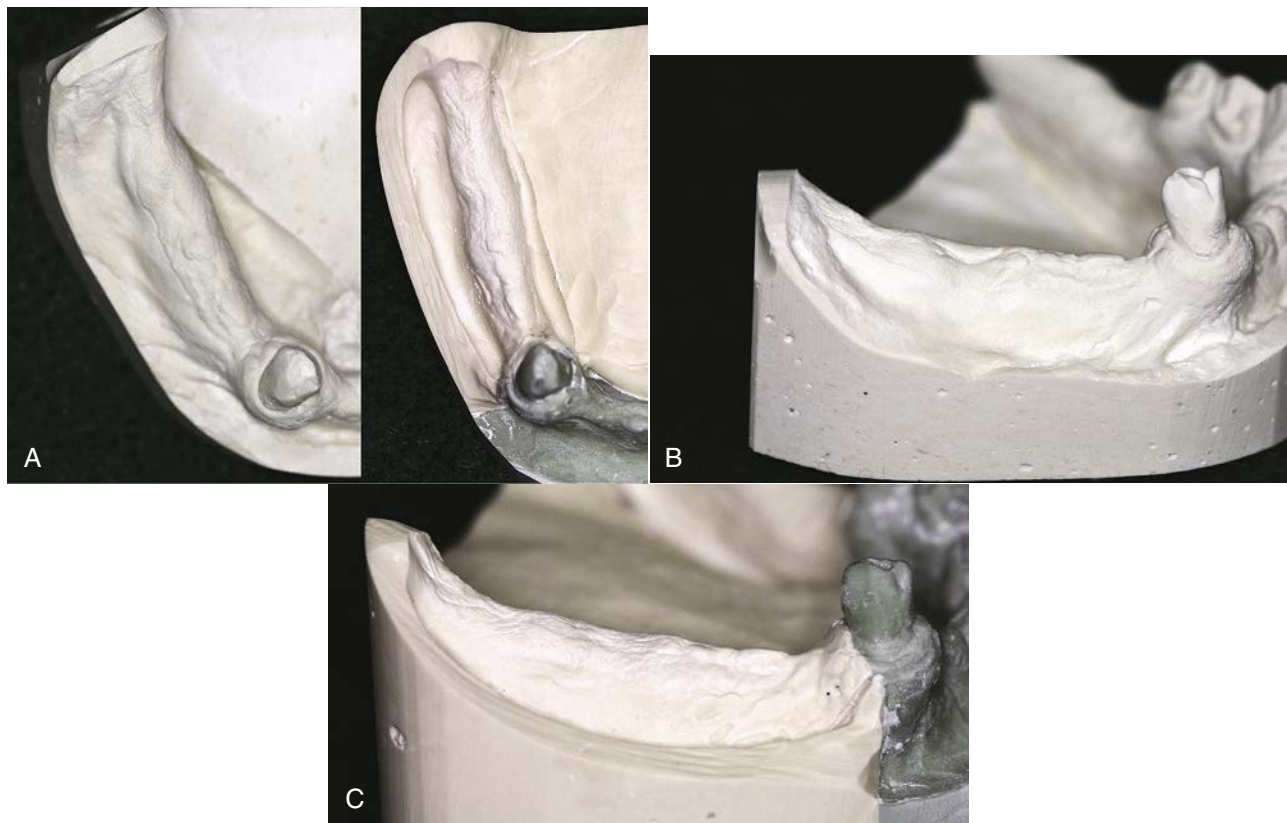
Foremost is the requirement that certain soft tissue in the primary supporting area should be recorded or related under some loading so that the base may be made to fit the form of the ridge when under function. This provides support and ensures maintenance of that support for the longest possible time. This requirement makes the distal extension partial denture unique in that support from the tissue underlying the distal extension base must be made as equal to and compatible with the tooth support as possible.

A complete denture is entirely tissue supported, and the entire denture can move toward the tissue under function. In contrast, any movement of a partial denture base is inevitably a rotational movement that, if toward the tissue, may result in undesirable torquing forces to the abutment teeth and loss of planned occlusal contacts. Therefore every effort must be made to provide the best possible support for the distal extension base to minimize these forces.

Usually no single impression technique can adequately record the anatomic form of the teeth and adjacent structures and at the same time record the supporting form of the mandibular edentulous ridge. A method should be used that can record these tissues in their supporting form or in a supporting relationship to the rest of the denture (see Figure 2-3). This may be accomplished by one of several methods that will be discussed in Chapter 16.

### Establishment and Verification of Occlusal Relations and Tooth Arrangements

Whether the partial denture is tooth supported or has one or more distal extension bases, the recording and verification of occlusal relationships and tooth arrangement are important steps in the construction of a partial denture. For the tooth-supported partial denture, ridge form is of less significance than it is for the tooth- and tissue-supported prosthesis, because the ridge is not called on to support the prosthesis. For the distal extension base, however, jaw relation records should be made only after the best possible support is obtained for the denture base. This necessitates the making of a base or bases that provide the same support as the finished denture. Therefore the final jaw relations should not be recorded until after the denture framework has been returned to the dentist, the fit of the framework to the abutment teeth and opposing occlusion has been verified and corrected, and a corrected impression has been made.



**FIGURE 2-3** **A**, Occlusal view of a cast from a preliminary impression, which produced an anatomic ridge form (*left*), and an altered cast of the same ridge showing a functional or supportive form (*right*). The altered cast impression selectively placed pressure on the buccal shelf region, which is the primary stress-bearing area of the mandibular posterior residual ridge. **B**, Buccal view of anatomic ridge form. **C**, Buccal view of functional or supportive ridge form. Note that the supportive form of the ridge clearly delineates the extent of coverage available for a denture base and is most different from the anatomic form when the mucosa is easily displaced.

Then a new resin base or a corrected base must be used to record jaw relations.

Occlusal records for a removable partial denture may be made by the various methods described in Chapter 18.

### Initial Placement Procedures

The fifth phase of treatment occurs when the patient is given possession of the removable prosthesis. Inevitably it seems that minute changes in the planned occlusal relationships occur during processing of the dentures. Not only must occlusal harmony be ensured before the patient is given possession of the dentures, but the processed bases must be reasonably perfected to fit the basal seats. It must be ascertained that the patient understands the suggestions and recommendations given by the dentist for care of the dentures and oral structures and understands about expectations (based on the “shared decision making” discussion) in the adjustment phases and the use of restorations. These facets of treatment are discussed in detail in Chapter 21.

### Periodic Recall

Initial placement and adjustment of the prosthesis certainly is not the end of treatment for the partially edentulous patient.

Periodic reevaluation of the patient is critical for early recognition of changes in oral structures to allow steps to be taken to maintain oral health. These examinations must monitor the condition of the oral tissue, the response to tooth restorations, the prosthesis, the patient’s acceptance, and the patient’s commitment to maintain oral hygiene. Although a 6-month recall period is adequate for most patients, more frequent evaluation may be required for some. Chapter 21 contains some suggestions concerning this sixth phase of treatment.

### REASONS FOR FAILURE OF CLASP-RETAINED PARTIAL DENTURES

Experience with the clasp-retained partial denture made by the methods outlined has proved its merit and justifies its continued use. The occasional objection to the visibility of retentive clasps can be minimized through the use of wrought-wire clasp arms. Few contraindications for use of a properly designed clasp-retained partial denture are known. Practically all objections to this type of denture can be eliminated by pointing to deficiencies in mouth preparation, denture design and

fabrication, and patient education. These include the following:

#### **Diagnosis and treatment planning**

1. Inadequate diagnosis
2. Failure to use a surveyor or to use a surveyor properly during treatment planning

#### **Mouth preparation procedures**

1. Failure to properly sequence mouth preparation procedures
2. Inadequate mouth preparations, usually resulting from insufficient planning of the design of the partial denture or failure to determine that mouth preparations have been properly accomplished
3. Failure to return supporting tissue to optimum health before impression procedures are performed
4. Inadequate impressions of hard and soft tissue

#### **Design of the framework**

1. Failure to use properly located and sized rests
2. Flexible or incorrectly located major and minor connectors
3. Incorrect use of clasp designs
4. Use of cast clasps that have too little flexibility, are too broad in tooth coverage, and have too little consideration for esthetics

#### **Laboratory procedures**

1. Problems in master cast preparation
  - a. Inaccurate impression
  - b. Poor cast-forming procedures
  - c. Incompatible impression materials and gypsum products
2. Failure to provide the technician with a specific design and necessary information to enable the technician to execute the design
3. Failure of the technician to follow the design and written instructions

#### **Support for denture bases**

1. Inadequate coverage of basal seat tissue
2. Failure to record basal seat tissue in a supporting form

#### **Occlusion**

1. Failure to develop a harmonious occlusion
2. Failure to use compatible materials for opposing occlusal surfaces

#### **Patient-dentist relationship**

1. Failure of the dentist to provide adequate dental health care information, including details on care and use of the prosthesis
2. Failure of the dentist to provide recall opportunities on a periodic basis
3. Failure of the patient to exercise a dental health care regimen and respond to recall

A removable partial denture designed and fabricated so that it avoids the errors and deficiencies listed is one that proves the clasp-type partial denture can be made functional, esthetically pleasing, and long lasting without damage to supporting structures. The proof of the merit of this type of restoration lies in the knowledge that (1) it permits treatment for the largest number of patients at a reasonable cost; (2) it provides restorations that are comfortable and efficient over a long period of time, with adequate support and maintenance of occlusal contact relations; (3) it can provide for healthy abutments, free of caries and periodontal disease; (4) it can provide for the continued health of restored, healthy tissue of the basal seats; and (5) it makes possible a partial denture service that is definitive and not merely an interim treatment.

Removable partial dentures thus made will contribute to a concept of prosthetic dentistry that has as its goal the promotion of oral health, the restoration of partially edentulous mouths, and elimination of the ultimate need for complete dentures.

# CHAPTER

# 3

## Classification of Partially Edentulous Arches

### CHAPTER OUTLINE

Requirements of an Acceptable Method of Classification  
Kennedy Classification  
Applegate's Rules for Applying the Kennedy Classification

Even though recent reports have shown a consistent decline in the prevalence of tooth loss during the past few decades, significant variation in tooth loss distribution remains. It would be most helpful to consider which combinations of tooth loss are most common and to classify these for the purpose of assisting our management of partially edentulous patients.

A classification that is based on diagnostic criteria has been proposed for partial edentulism.<sup>1</sup> The purpose of this system of classification is to facilitate treatment decisions on the basis of treatment complexity. Complexity is determined from four broad diagnostic categories that include location and extent of the edentulous areas, condition of the abutments, occlusal characteristics and requirements, and residual ridge characteristics. The advantage of this classification system over others in standard use has yet to be documented.

The Kennedy method is probably the most widely accepted classification of partially edentulous arches. In an attempt to simplify the problem and encourage more universal use of a classification, and in the interest of adequate communication, the Kennedy classification will be used in this textbook. The student can refer to the Selected Reading Resources section in Appendix B for information relative to other classifications.

Although classifications are actually descriptive of the partially edentulous arches, the removable partial denture that restores a particular class of arch is described as a denture of that class. For example, we speak of a Class III or Class I removable partial denture. It is simpler to say "a Class II partial denture" than it is to say "a partial denture restoring a Class II partially edentulous arch."

Several classifications of partially edentulous arches have been proposed and are in use. This variety has led to some confusion and disagreement concerning which

classification best describes all possible configurations and should be adopted.

The most familiar classifications are those originally proposed by Kennedy, Cummer, and Bailyn. Beckett, Godfrey, Swenson, Friedman, Wilson, Skinner, Applegate, Avant, Miller, and others have also proposed classifications. It is evident that an attempt should be made to combine the best features of all classifications so that a universal classification can be adopted.

REQUIREMENTS OF AN ACCEPTABLE METHOD OF CLASSIFICATION

The classification of a partially edentulous arch should satisfy the following requirements:

- 1. It should permit immediate visualization of the type of partially edentulous arch that is being considered.
- 2. It should permit immediate differentiation between the tooth-supported and the tooth- and tissue-supported removable partial denture.
- 3. It should be universally acceptable.

KENNEDY CLASSIFICATION

The Kennedy method of classification was originally proposed by Dr. Edward Kennedy in 1925. It attempts to classify the partially edentulous arch in a manner that suggests certain principles of design for a given situation (Figure 3-1).

Kennedy divided all partially edentulous arches into four basic classes. Edentulous areas other than those that determine the basic classes were designated as modification spaces (Figure 3-2).

The following is the Kennedy classification:

- Class I     Bilateral edentulous areas located posterior to the natural teeth
- Class II    A unilateral edentulous area located posterior to the remaining natural teeth
- Class III   A unilateral edentulous area with natural teeth remaining both anterior and posterior to it
- Class IV   A single, but bilateral (crossing the midline), edentulous area located anterior to the remaining natural teeth

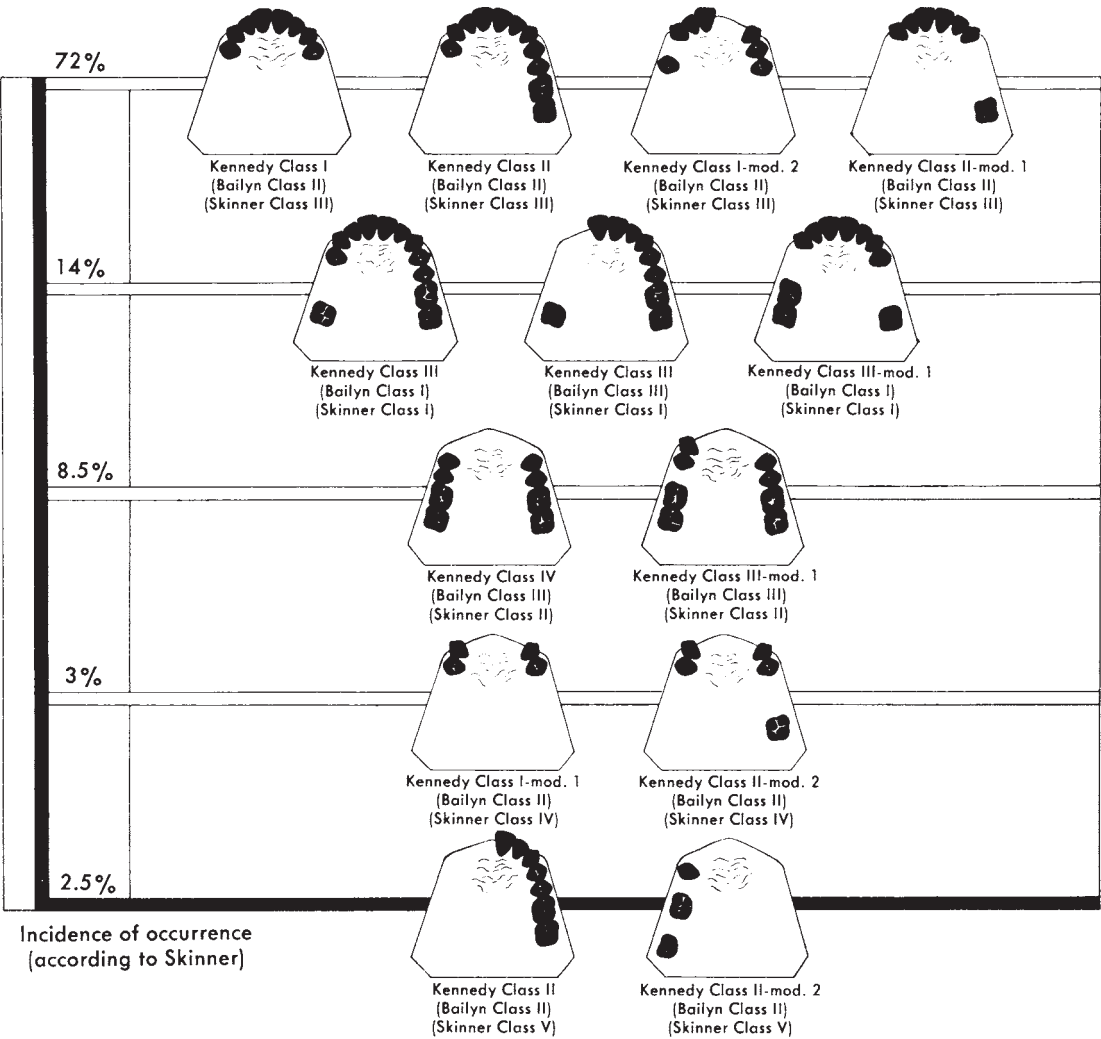
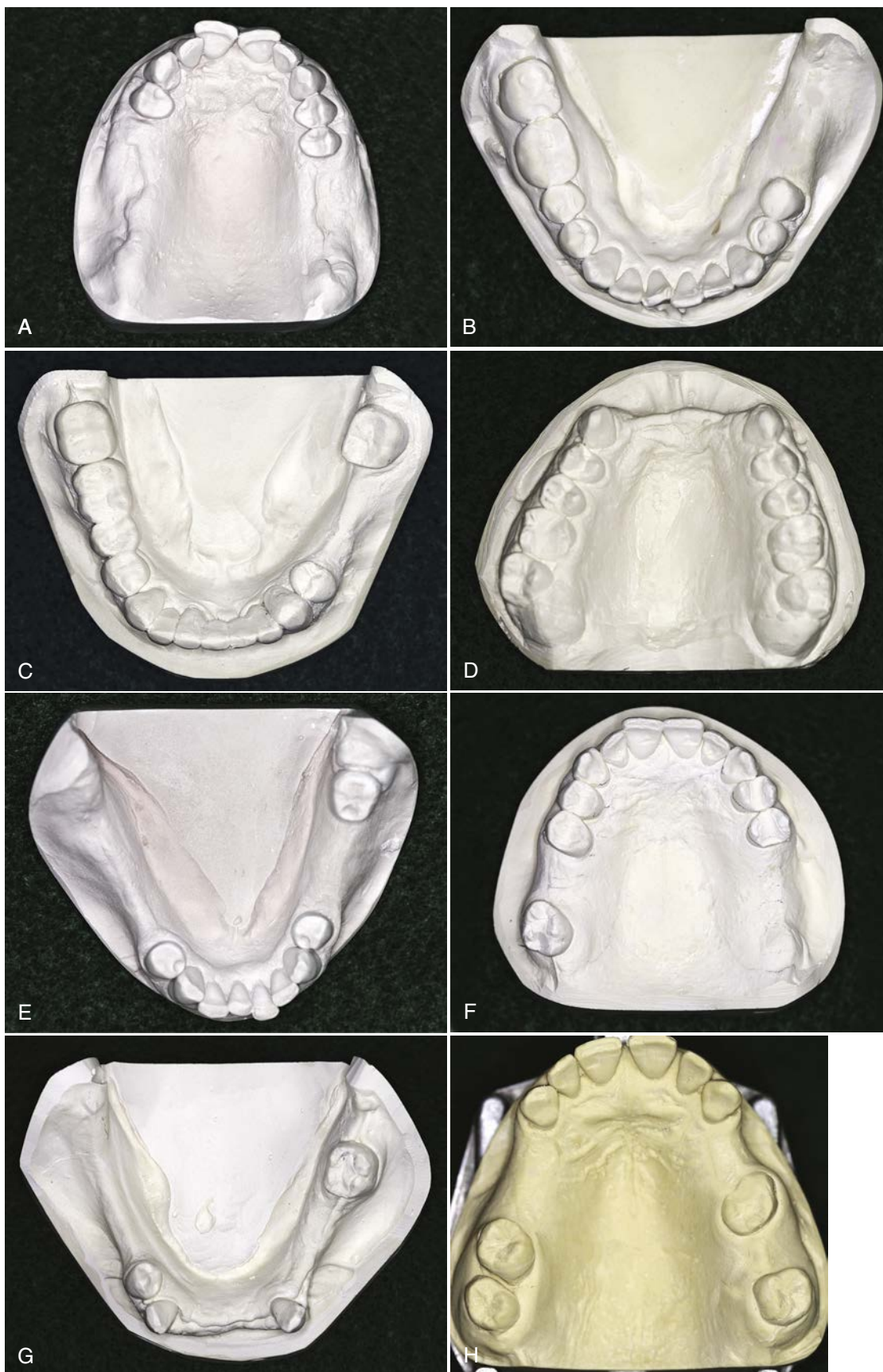


FIGURE 3-1 Representative examples of partially edentulous arches classified by the Kennedy method.



**FIGURE 3-2** Kennedy classification with examples of modifications. **A**, Class I maxillary arch. **B**, Class II mandibular arch. **C**, Class III mandibular arch. **D**, Class IV maxillary arch. **E**, Class II, modification 1 mandibular arch. **F**, Class II, modification 1 maxillary arch. **G**, Class II, modification 2 mandibular arch. **H**, Class III, modification 2 maxillary arch.

Box 3-1

RULES GOVERNING APPLICATION OF THE KENNEDY METHOD

Rule 1

Classification should follow rather than precede any extractions of teeth that might alter the original classification.

Rule 2

If a third molar is missing and is not to be replaced, it is not considered in the classification.

Rule 3

If a third molar is present and is to be used as an abutment, it is considered in the classification.

Rule 4

If a second molar is missing and is not to be replaced, it is not considered in the classification (e.g., if the opposing second molar is likewise missing and is not to be replaced).

Rule 5

The most posterior edentulous area (or areas) always determines the classification.

Rule 6

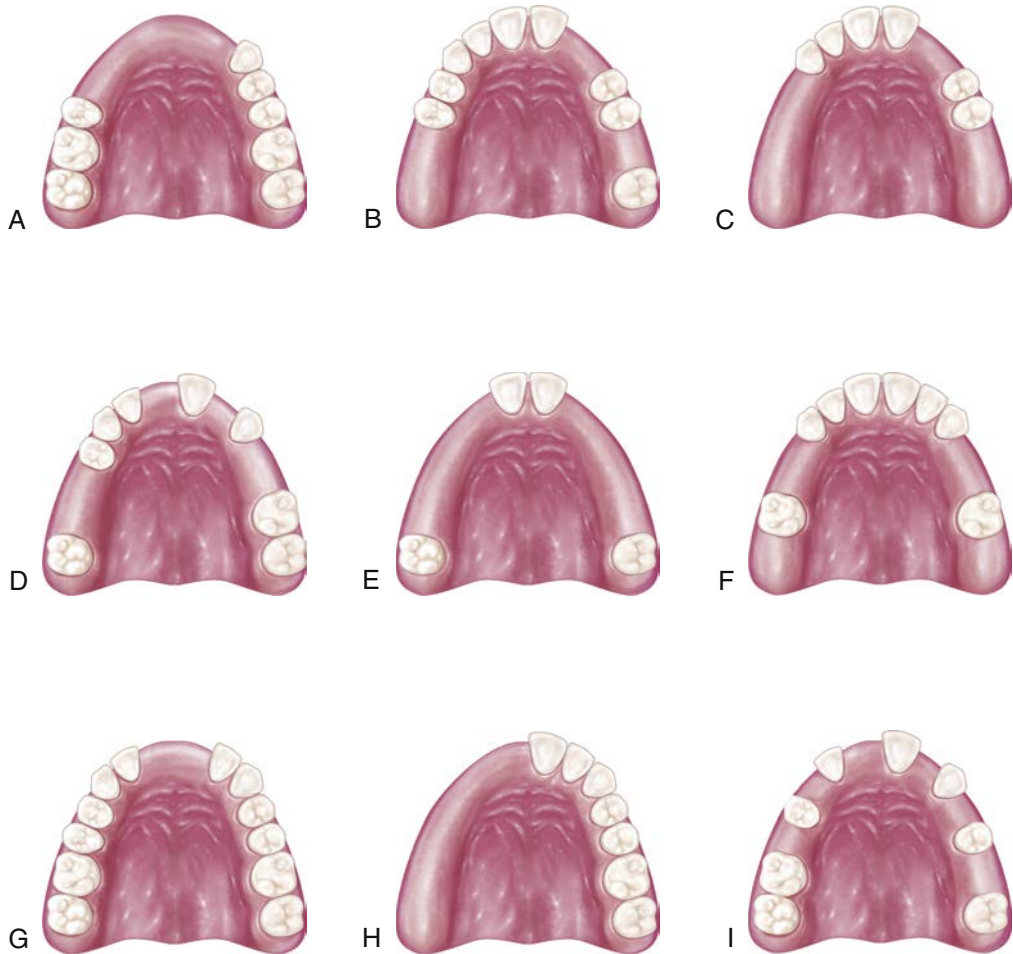
Edentulous areas other than those that determine the classification are referred to as *modifications* and are designated by their number.

Rule 7

The extent of the modification is not considered, only the number of additional edentulous areas.

Rule 8

No modification areas can be included in Class IV arches. (Other edentulous areas that lie posterior to the single bilateral areas crossing the midline would instead determine the classification; see Rule 5.)



**FIGURE 3-3** Nine partially edentulous arch configurations. Identify each. Answers can be found at the end of this chapter, after the Reference section.

One of the principal advantages of the Kennedy method is that it permits immediate visualization of the partially edentulous arch and allows easy distinction between tooth-supported versus tooth- and tissue-supported prostheses. Those schooled in its use and in the principles of partial denture design can readily relate the arch configuration design to be used in the basic partial denture. This method permits a logical approach to the problems of design. It makes possible the application of sound principles of partial denture design and is therefore a logical method of classification. However, a classification system should not be used to stereotype or limit the concepts of design.

Additionally, because the use of a strategically placed implant can provide an extension base (the support similar to a tooth in a tooth-born segment), it may be helpful to our understanding, communication, and design to consider implant designations in future classifications (Kennedy Class Ii/i, Class Ili, Class IVi, and so on).

### APPLEGATE'S RULES FOR APPLYING THE KENNEDY CLASSIFICATION

The Kennedy classification would be difficult to apply in every situation without certain rules for application. Applegate provided eight rules that govern application of the Kennedy method (Box 3-1).

Although some confusion may occur initially as to why Class I should refer to two edentulous areas and Class II should refer to one, the principles of design make this distinction logical. Kennedy placed the Class II unilateral distal extension type between the Class I bilateral distal extension type and the Class III tooth-supported

classification because the Class II partial denture must embody features of both, especially when tooth-supported modifications are present. Because it has a tissue-supported extension base, the denture must be designed similarly to a Class I partial denture. Often, however, a tooth-supported, or Class III, component is present elsewhere in the arch. Thus the Class II partial denture rightly falls between the Class I and the Class III, because it embodies design features common to both. In keeping with the principle that design is based on classification, the application of such principles of design is simplified by retaining the original classification of Kennedy.

Figure 3-3 presents a chance to assess your skills. Review the figure and classify the partially edentulous arches illustrated. The answers are provided at the end of this chapter.

### REFERENCE

1. McGarry TJ, Nimmo A, Skiba JF, et al.: Classification system for partial edentulism, *J Prosthodont* 11(3):181–193, 2002.

### Answer to Figure 3-3

- A. Class IV
- B. Class II, modification 2
- C. Class I, modification 1
- D. Class III, modification 3
- E. Class III, modification 1
- F. Class III, modification 1
- G. Class IV
- H. Class II
- I. Class III, modification 5

## CHAPTER

## 4

# Biomechanics of Removable Partial Dentures

## CHAPTER OUTLINE

Biomechanics and Design Solutions  
Biomechanical Considerations  
Impact of Implants on Movements of Partial Dentures  
Simple Machines  
Possible Movements of Partial Dentures

As was stated in Chapter 1, the goal is to provide useful, functional removable partial denture prostheses by striving to understand how to maximize every opportunity for providing and maintaining a stable prosthesis. Because removable partial dentures are not rigidly attached to teeth, the control of potential movement under functional load is critical to providing the best chance for stability and patient accommodation. The consequence of prosthesis movement under load is an application of stress to the teeth and tissue that are contacting the prosthesis. It is important that the stress not exceed the level of physiologic tolerance, which is a range of mechanical stimulus that a system can resist without disruption or traumatic consequences. In the terminology of engineering mechanics, the prosthesis induces stress in the tissue equal to the force applied across the area of contact with the teeth and/or tissue. This same stress acts to produce strain in the supporting tissue, which results in load displacement in the teeth and tissue. The understanding of how these mechanical phenomena act within a biological environment that is unique to each patient can be discussed in terms of biomechanics. In the design of removable partial dentures, with a focus on the goal of providing and maintaining stable prostheses, consideration of basic biomechanical principles associated with the unique features of each mouth is essential. Oral hygiene and appropriate prosthesis maintenance procedures are required for continued benefit of optimum biomechanical principles.

## BIOMECHANICS AND DESIGN SOLUTIONS

Removable partial dentures by design are intended to be placed into and removed from the mouth. Because of this, they cannot be rigidly connected to the teeth or tissue. This makes them subject to movement in response to functional loads, such as those created by mastication. It is important for clinicians who provide removable partial denture service

to understand the possible movements in response to function and to be able to logically design the component parts of the removable partial denture to help control these movements. Just how this is accomplished in a logical manner may not be clear to a clinician who is new to this exercise. One method of helping to organize design thought is to consider it as an exercise in creating a design solution.

Designing a removable partial denture can be considered similar to the classic, multifaceted design problem in conventional engineering, which is characterized by being open ended and ill structured. *Open ended* means that problems typically have more than one solution, and *ill structured* means that solutions are not the result of standard mathematical formulas used in some structured manner. The design process, which is a series of steps that lead toward a solution of the problem, includes identifying a need, defining the problem, setting design objectives, searching for background information and data, developing a design rationale, devising and evaluating alternative solutions, and providing the solution (i.e., decision making and communication of solutions) (Box 4-1).

The rationale for design should logically develop from analysis of the unique oral condition of each mouth under consideration. However, it is possible that alternative design “solutions” could be applied, and it is the evaluation of perceived merits of these various designs that seems most confusing to clinicians.

The following biomechanical considerations provide a background related to principles of the potential movement associated with removable partial dentures, and the subsequent chapters covering the various component parts describe how these components are applied in designs to control the resultant movements of prostheses.

Box 4-1

DESIGN PROCESS FOR REMOVABLE PARTIAL DENTURES

Need

Tooth replacement

Definition of Problem

Provision of stable removable prosthesis

Objectives

Limited functional movement within tooth-tissue tolerance

Background Information

Forces of occlusion, tissue “load-displacement” character and potential for movement, biomechanical principles applied to specific features of this unique mouth, removable partial denture component parts assigned to control movement

Choice of a Solution (among Alternatives) for Application

Based on prior experience, principles and concepts learned from school and textbooks, and applicable clinical research

BIOMECHANICAL CONSIDERATIONS

The supporting structures for removable partial dentures (abutment teeth and residual ridges) are living things that are subjected to forces. Whether the supporting structures are capable of resisting the applied forces depends on (1) what typical forces require resistance, (2) what duration and intensity these forces have, (3) what capacity the teeth, implant(s) and/or mucosae have to resist these forces, (4) how material use and application influence this teeth-tissue resistance, and (5) whether resistance changes over time.

Consideration of the forces inherent in the oral cavity is critical. This includes the direction, duration, frequency, and magnitude of the force. In the final analysis, it is bone that provides the support for a removable prosthesis (i.e., the alveolar bone by way of the periodontal ligament and the residual ridge bone through its soft tissue covering). If potentially destructive forces can be minimized, then the physiologic tolerances of the supporting structures are not exceeded and pathologic change does not occur. The forces that occur with removable prosthesis function can be widely distributed and directed, and their effect minimized by appropriate design of the removable partial denture. An appropriate design includes the selection and location of components in conjunction with a harmonious occlusion.

Unquestionably the design of removable partial dentures necessitates mechanical and biological considerations. Most dentists are capable of applying simple mechanical principles to the design of a removable partial denture. For example, the lid of a paint can is more easily removed with a screwdriver than with a half dollar. The longer the handle, the less effort (force) it takes. This is a simple application of the mechanics of leverage. By the same token, a lever system represented by a distal extension removable partial denture could magnify the applied force of occlusion to the terminal abutments, which would be undesirable. Use of a dental implant in such a case reduces, and may eliminate, the opportunity for such force magnification.

IMPACT OF IMPLANTS ON MOVEMENTS OF PARTIAL DENTURES

Similar to the process of considering how an individual tooth is best used in removable partial denture design to control prosthesis movement, use of an implant should be directed toward the most beneficial movement control. Although possible roles for implant use include all three desired principles demonstrated by prostheses—support, stability, and retention—the major functional demand is imposed by chewing, and therefore the greatest benefit of implant use involves resisting instability by improving support. Minimizing rotation about an axis in a Kennedy Class I or II arch, or any long modification span, is important to consider.

SIMPLE MACHINES

An understanding of simple machines applied to the design of removable partial dentures helps to accomplish the objective of preservation of oral structures. Without such understanding, a removable partial denture can be inadvertently designed as a destructive machine.

Machines may be classified into two general categories: simple and complex. Complex machines are combinations of many simple machines. The six simple machines are lever, wedge, screw, wheel and axle, pulley, and inclined plane (Figure 4-1). Of the simple machines, the lever, the wedge, and the inclined plane should be avoided in the design of removable partial dentures.

In its simplest form, a lever is a rigid bar supported somewhere along its length. It may rest on the support or may be supported from above. The support point of the lever is called the *fulcrum*, and the lever can move around the fulcrum (Figure 4-2; see Figure 6-6).

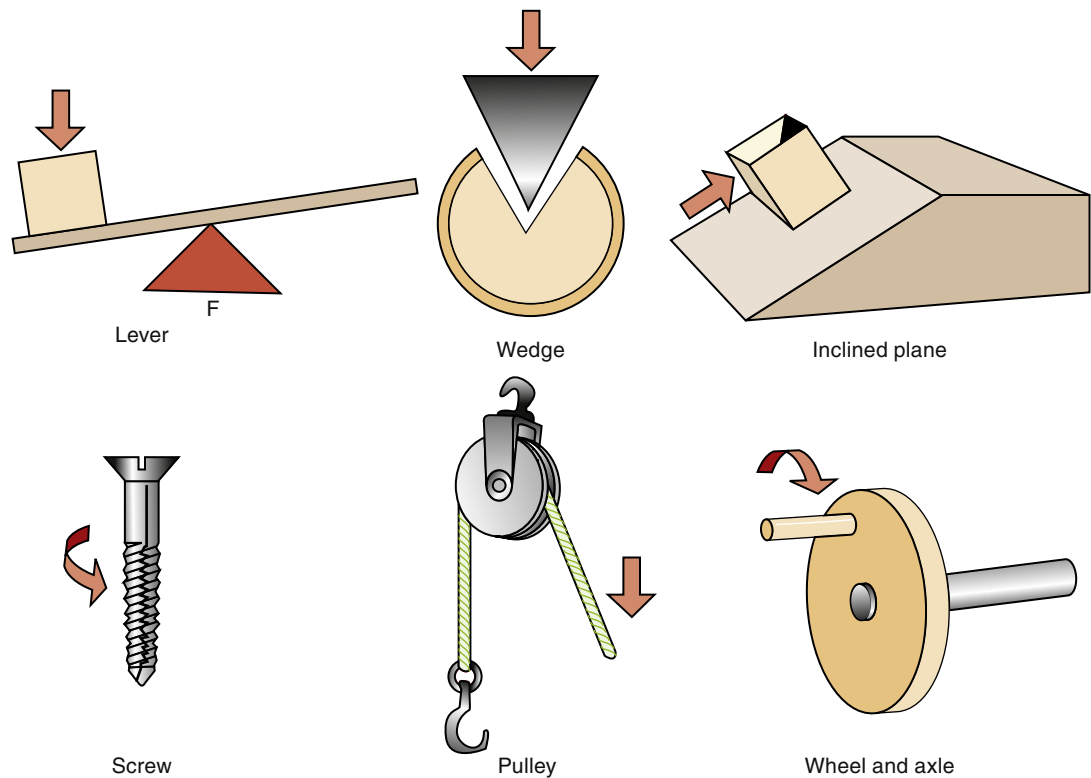
The rotational movement of an extension base type of removable partial denture, when a force is placed on the denture base, is illustrated in Figure 4-3. It rotates in relation to the three cranial planes because of differences in the support characteristics of the abutment teeth and the soft tissue covering the residual ridge. Even though the actual movement of the denture may be small, a lever force may be imposed on abutment teeth. This is especially

detrimental when prosthesis maintenance is neglected. Three types of levers are used: first, second, and third class (see Figure 4-2). The potential of a lever system to magnify a force is illustrated in Figure 4-4.

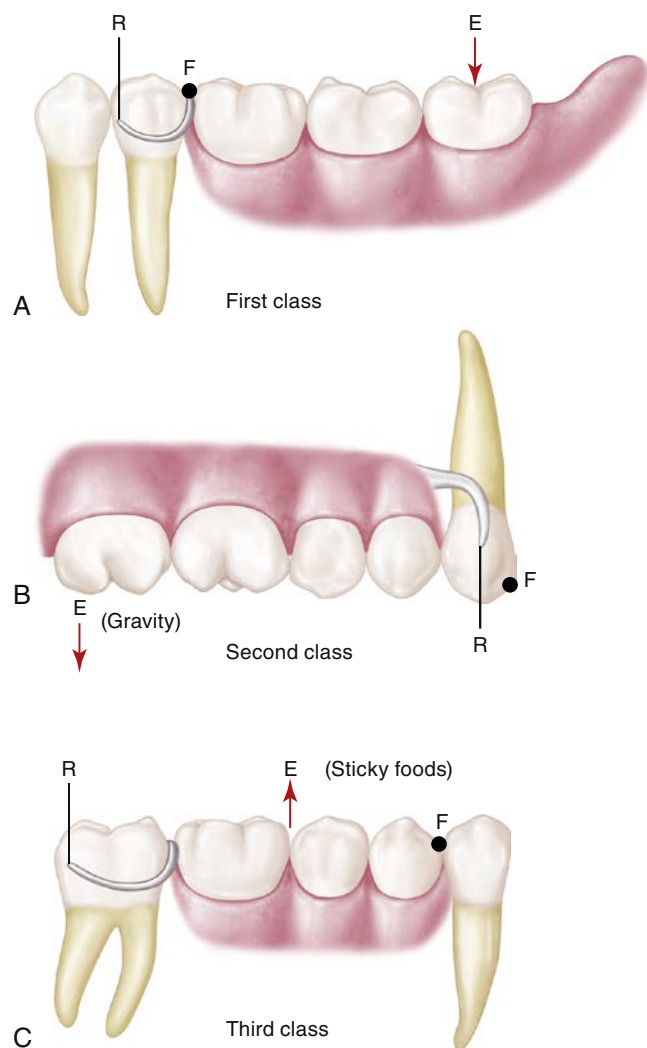
A cantilever is a beam supported at one end that can act as a first-class lever (Figure 4-5). A cantilever design should be avoided (Figure 4-6). Use of a dental implant is one strategy to provide tooth replacement and avoid the cantilever. Examples of other lever designs and suggestions for alternative designs to avoid or minimize their destructive potential are illustrated in Figures 4-7 and 4-8. The most efficient means of addressing the potential effects of a lever is to provide a rigid element at the unsupported end to disallow movement. This is the most beneficial use of dental implants in conjunction with removable partial dentures and should be considered when support capacity for a distal extension is considered significantly poor.

A tooth is apparently better able to tolerate vertically directed forces than nonvertical, torquing, or horizontal forces. This characteristic is observed clinically, and it seems rational that more periodontal fibers are activated to resist the application of vertical forces to teeth than are activated to resist the application of nonvertical forces (Figure 4-9).

Again, a distal extension removable partial denture rotates when forces are applied to the artificial teeth attached to the extension base. Because it can be assumed that this rotation must create predominantly nonvertical forces, the location of



**FIGURE 4-1** The six simple machines include lever, wedge, inclined plane, screw, pulley, and wheel and axle. The fulcrum, wedge, and inclined plane are matters of concern in removable partial denture designs because of the potential for harm if they are not appropriately controlled. F, Fulcrum.



**FIGURE 4-2** A to C, The three classes of levers. Classification is based on location of the fulcrum (F), resistance (R), and direction of effort (force) (E). In dental terms, E can represent the force of occlusion or gravity; F can be a tooth surface such as an occlusal rest; and R is the resistance provided by a direct retainer or a guide plane surface.

stabilizing and retentive components in relation to the horizontal axis of rotation of the abutment becomes extremely important. An abutment tooth will better tolerate nonvertical forces if these forces are applied as near as possible to the horizontal axis of rotation of the abutment (Figure 4-10). The axial surface contours of abutment teeth must be altered to locate components of clasp assemblies more favorably in relation to the abutment's horizontal axis (Figure 4-11).

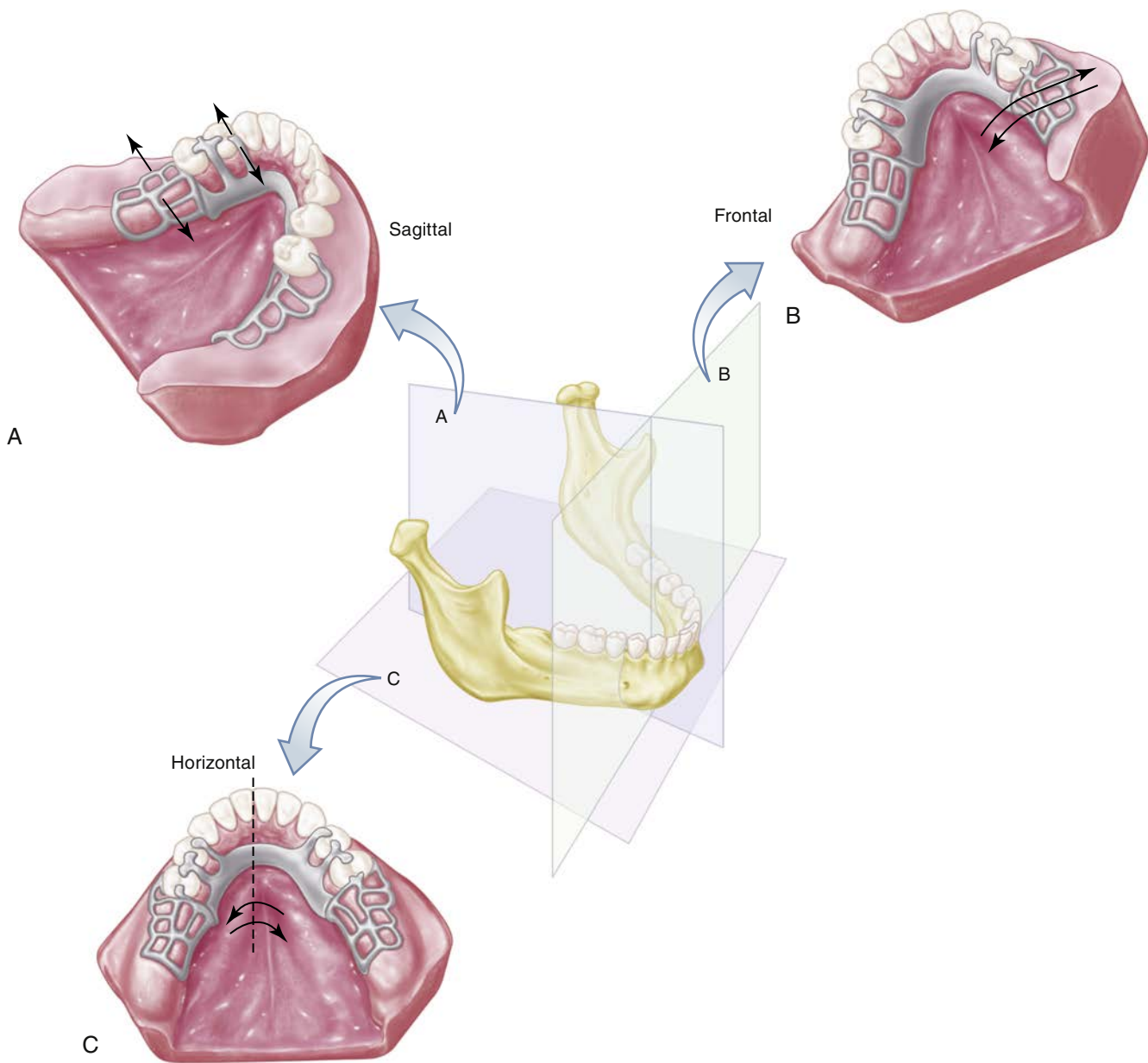
## POSSIBLE MOVEMENTS OF PARTIAL DENTURES

If it is presumed that direct retainers are functioning to minimize vertical displacement, rotational movement will occur about some axis as the distal extension base or bases

move toward, away, or horizontally across the underlying tissue. Unfortunately, these possible movements do not occur singularly or independently but tend to be dynamic and all occur at the same time. The greatest movement possible is found in the tooth/mucosal tissue-supported prosthesis because of reliance on the distal extension supporting tissue to share the functional loads with the teeth. Movement of a distal extension base toward the ridge tissue will be proportionate to the quality of that tissue, the accuracy and extent of the denture base, and the applied total functional load. A review of prosthesis rotational movement that is possible around various axes in the mouth provides some understanding of how component parts of removable partial dentures should be prescribed to control prosthesis movement.

One movement is rotation about an axis through the most posterior abutments. This axis may pass through occlusal rests or any other rigid portion of a direct retainer assembly located occlusally or incisally to the height of contour of the primary abutments (see Figures 4-6 and 4-7). This axis, known as the *fulcrum line*, is the center of rotation as the distal extension base moves toward the supporting tissue when an occlusal load is applied. The axis of rotation may shift toward more anteriorly placed components, occlusal or incisal to the height of contour of the abutment, as the base moves away from the supporting tissue when vertical dislodging forces act on the partial denture. These dislodging forces result from the vertical pull of food between opposing tooth surfaces, the effects of moving border tissue, and the forces of gravity against a maxillary partial denture. If it is presumed that the direct retainers are functional and that the supportive anterior components remain seated, rotation—rather than total displacement—should occur. Vertical tissue-ward movement of the denture base is resisted by the tissue of the residual ridge in proportion to the supporting quality of that tissue, the accuracy of the fit of the denture base, and the total amount of occlusal load applied. Movement of the base in the opposite direction is resisted by the action of the retentive clasp arms on terminal abutments and the action of stabilizing minor connectors in conjunction with seated, vertical support elements of the framework anterior to the terminal abutments acting as indirect retainers. Indirect retainers should be placed as far as possible from the distal extension base, affording the best possible leverage against lifting of the distal extension base.

A second movement is rotation about a longitudinal axis as the distal extension base moves in a rotary direction about the residual ridge (see Figure 4-3). This movement is resisted primarily by the rigidity of the major and minor connectors and their ability to resist torque. If the connectors are not rigid, or if a stress-breaker exists between the distal extension base and the major connector, this rotation about a longitudinal axis applies undue stress to the sides of the supporting ridge or causes horizontal shifting of the denture base.

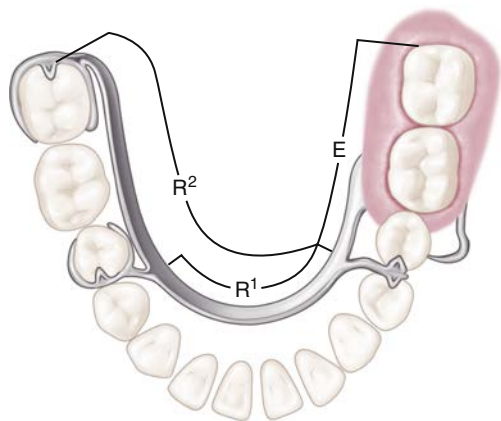


**FIGURE 4-3** Distal extension removable partial dentures will rotate when force is directed on the denture base. Differences in displacability of the periodontal ligament of the supporting abutment teeth and soft tissue covering the residual ridge permit this rotation. It would seem that rotation of the prosthesis occurs in a combination of directions rather than in a unidirectional way. The three possible movements of distal extension partial dentures are **(A)** rotation around a fulcrum line passing through the most posterior abutments when the denture base moves vertically toward or away from the supporting residual ridges; **(B)** rotation around a longitudinal axis formed by the crest of the residual ridge; and **(C)** rotation around a vertical axis located near the center of the arch.

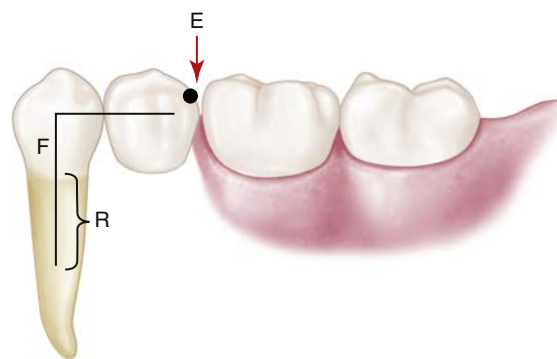
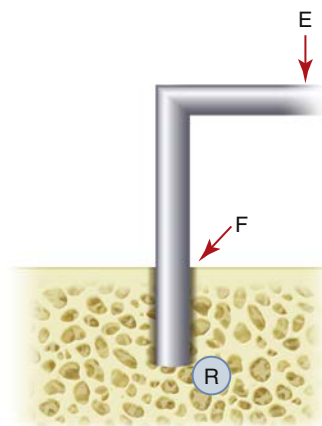
A third movement is rotation about an imaginary vertical axis located near the center of the dental arch (see Figure 4-4). This movement occurs under function because diagonal and horizontal occlusal forces are brought to bear on the partial denture. It is resisted by stabilizing components, such as reciprocal clasp arms and minor connectors that are in contact with vertical tooth surfaces. Such stabilizing components are essential to any partial denture design, regardless of the manner of support and the type of direct retention employed. Stabilizing components on one side of the arch act to stabilize the partial denture against horizontal forces applied from the opposite side. It is obvious that rigid connectors must be used to make this effect possible.

Horizontal forces always will exist to some degree because of lateral stresses that occur during mastication, bruxism, clenching, and other patient habits. These forces are accentuated by failure to consider the orientation of the occlusal plane, the influence of malpositioned teeth in the arch, and the effects of abnormal jaw relationships. Fabricating an occlusion that is in harmony with the opposing dentition and that is free of lateral interference during eccentric jaw movements may minimize the magnitude of lateral stress. The amount of horizontal movement occurring in the partial denture therefore depends on the magnitude of the lateral forces that are applied and on the effectiveness of the stabilizing components.

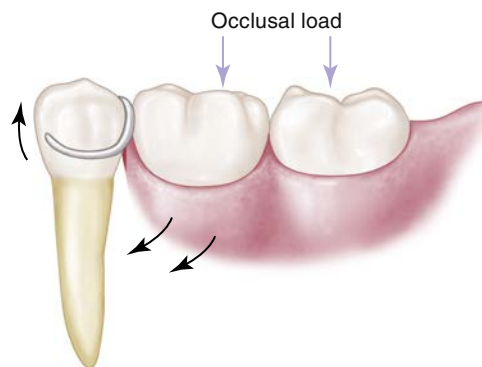
In a tooth-supported partial denture, movement of the base toward the edentulous ridge is prevented primarily by



**FIGURE 4-4** The length of a lever from fulcrum (F) (see Figure 4-7) to resistance (R) is called the *resistance arm*. That portion of a lever from the fulcrum to the point of application of force (E) is called the *effort arm*. Whenever the effort arm is longer than the resistance arm, mechanical advantage favors the effort arm, proportionately to the difference in length of the two arms. In other words, when the effort arm is twice the length of the resistance arm, a 25-lb weight on the effort arm will balance a 50-lb weight at the end of the resistance arm. The opposite is also true and helps illustrate cross-arch stabilization. When the resistance arm is lengthened (cross-arch clasp assembly placed on a second molar [R²] versus a second premolar [R¹]), the effort arm is more efficiently counteracted.

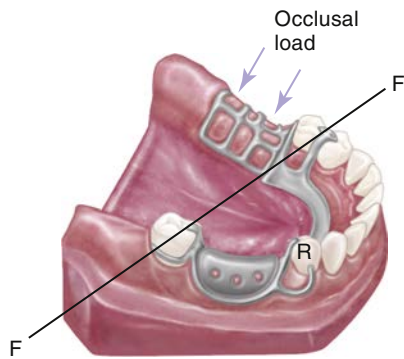


**FIGURE 4-5** A cantilever can be described as a rigid beam supported only at one end. When force is directed against the unsupported end of the beam (as in this rest placed on a cantilevered pontic), the cantilever can act as a first-class lever. The mechanical advantage in this illustration favors the effort arm.



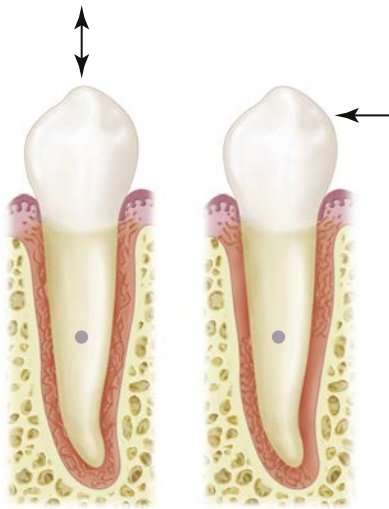
**FIGURE 4-6** Design often seen for a distal extension removable partial denture. A cast circumferential direct retainer engages the mesiobuccal undercut and is supported by the disto-occlusal rest. If it is rigidly attached to the abutment tooth, this could be considered a cantilever design, and detrimental first-class lever force may be imparted to the abutment if tissue support under the extension base allows excessive vertical movement toward the residual ridge.

the rests on the abutment teeth and to some degree by any rigid portion of the framework located occlusal to the height of contour. Movement away from the edentulous ridge is prevented by the action of direct retainers on the abutments that are situated at each end of each edentulous space and by the rigid, minor connector stabilizing components. Therefore

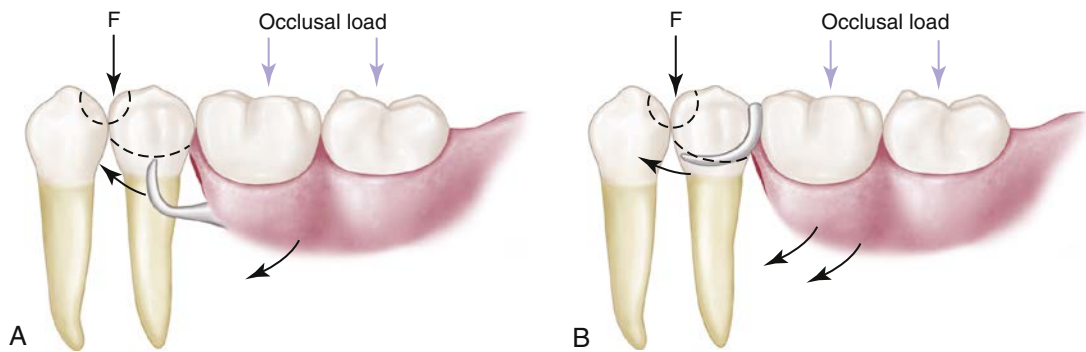


**FIGURE 4-7** As is shown in Figure 4-6, the potential for first-class lever action can also exist in Class II, modification 1 designs for removable partial denture frameworks. If a cast circumferential direct retainer with a mesiobuccal undercut on the right first premolar were used, force placed on the denture base could impart upward and posteriorly moving force on the premolar, resulting in loss of contact between premolar and canine. Tissue support from the extension base area is most important to minimize the lever action of the clasp. The retainer design could help accommodate more of an anteriorly directed force during rotation of the denture base in an attempt to maintain tooth contact. Other alternatives to the first premolar design of the direct retainer would include a tapered wrought-wire retentive arm that uses mesiobuccal undercut, or that just has a buccal stabilizing arm above the height of contour.

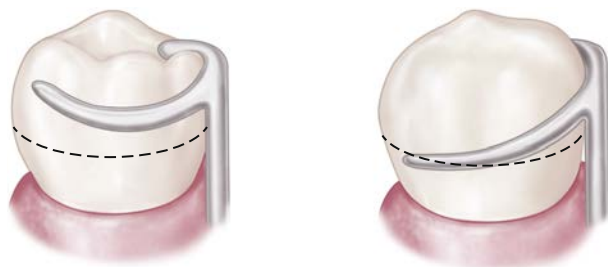
the first of the three possible movements can be controlled in the tooth-supported denture. The second possible movement, which occurs along a longitudinal axis, is prevented by the rigid components of the direct retainers on the abutment teeth and by the ability of the major connector to resist torque. This movement is much less in the tooth-supported denture because of the presence of posterior abutments. The third possible movement occurs in all partial dentures. Therefore stabilizing components against horizontal movement must be incorporated into any partial denture design.



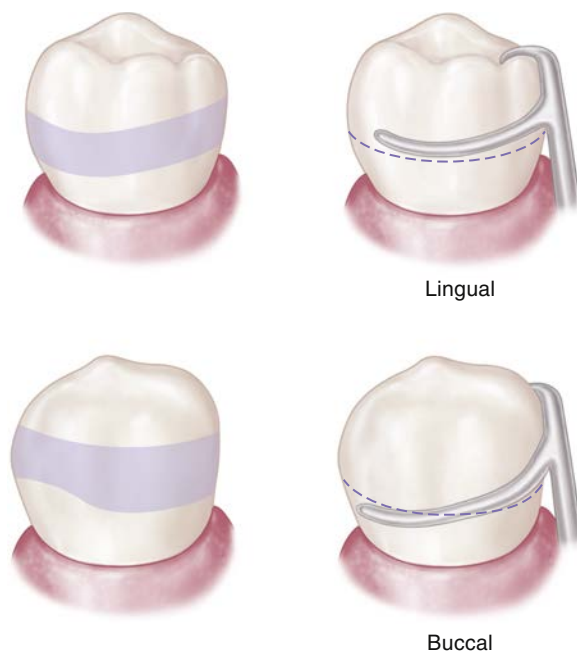**FIGURE 4-9** More periodontal fibers are activated to resist forces directed vertically on the tooth than are activated to resist horizontally (off-vertical) directed force. The horizontal axis of rotation is located somewhere in the root of the tooth.



**FIGURE 4-8** Mesial rest concept for distal extension removable partial dentures. With recognition that clasp movement occurs with functional displacement of the distal extension base, the primary aim of a mesial rest is to alter the fulcrum position and resultant clasp movement, disallowing harmful engagement of the abutment tooth. **A**, Bar type of retainer, minor connector contacting the guiding plane on the distal surface of the premolar, and mesio-occlusal rest used to reduce cantilever or first-class lever force when and if the denture rotates toward the residual ridge. **B**, Tapered wrought-wire retentive arm, minor connector contacting guiding plane on the distal surface of the premolar, and the mesio-occlusal rest. This design is applicable when the distobuccal undercut cannot be found or created or when the tissue undercut contraindicates placement of a bar-type retentive arm. This design would be kinder to the periodontal ligament than would a cast, half-round retentive arm. Again, tissue support of the extension base is a key factor in reducing the lever action of the clasp arm. *Note:* Depending on the amount of contact of the minor connector proximal plate with the guiding plane, the fulcrum point will change.



**FIGURE 4-10** Clasps placed closer to the occlusal/incisal surface have a greater likelihood of imparting tipping forces to the abutments.



**FIGURE 4-11** The abutment has been contoured (see shaded region) to allow rather favorable locations of retentive and reciprocal stabilizing components (mirror view).

For prostheses capable of movement in three planes, occlusal rests should provide occlusal support only to resist tissue-ward movement. All other movements of the partial denture should be resisted by components other than occlusal rests. Entrance of the occlusal rest into a stabilizing function would result in direct transfer of torque to the abutment tooth. Because movements around three different axes are possible in a distal extension partial denture, an occlusal rest for such a partial denture should not have steep vertical walls or locking dovetails. This rest design is characterized by lack of free movement, which could cause horizontal and torquing forces to be applied intracoronally to the abutment tooth.

In the tooth-supported denture, the only movements of any significance are horizontal, and these may be resisted by the stabilizing effects of components placed on the axial surfaces of the abutments. Therefore in the tooth-supported denture, the use of intracoronar rests is permissible. In these instances, the rests provide not only occlusal support but also notable horizontal stabilization.

In contrast, all Class I and Class II partial dentures, which have one or more distal extension bases, are not totally tooth supported. Neither are they completely retained by bounding abutments. Any extensive Class III or Class IV partial denture that does not have adequate abutment support falls into the same category. These latter dentures may derive some support from the edentulous ridge and therefore may have composite support from both teeth and ridge tissue.

# CHAPTER

# 5

## Major and Minor Connectors

### CHAPTER OUTLINE

#### Role of Major Connectors in Control of Prosthesis

##### Movement

##### Location

##### Mandibular Major Connectors

##### Maxillary Major Connectors

#### Minor Connectors

##### Functions

##### Form and Location

##### Tissue Stops

#### Finishing Lines

#### Reaction of Tissue to Metallic Coverage

#### Major Connectors in Review

The respective components parts of a removable partial denture are able to contribute to the overall performance of a prosthesis if they are joined through an effective connection. That is the role of the major connector.

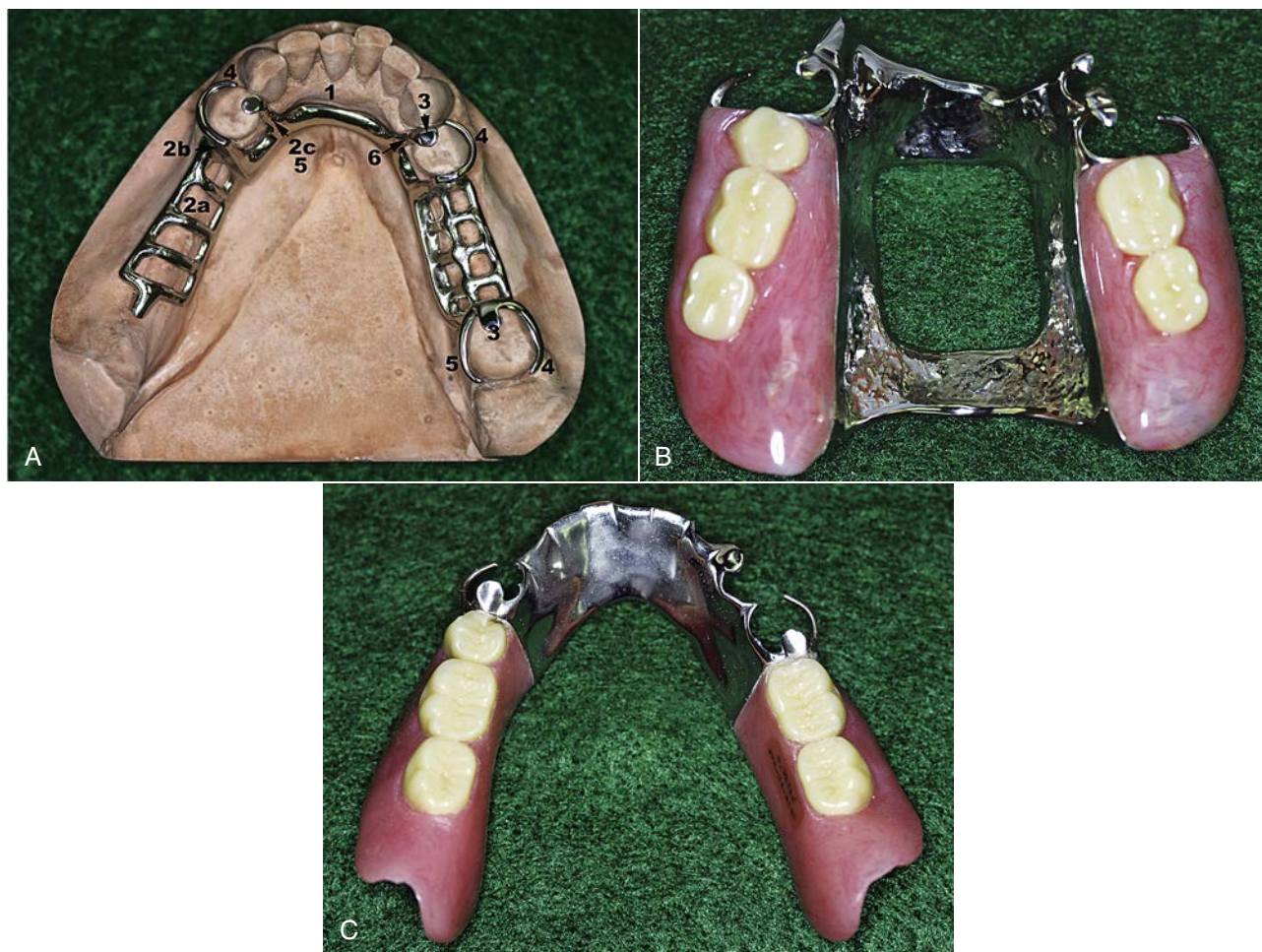Components of a typical removable partial denture are illustrated in [Figure 5-1](#).

1. Major connectors
2. Minor connectors
3. Rests
4. Direct retainers
5. Stabilizing or reciprocal components (as parts of a clasp assembly)
6. Indirect retainers (if the prosthesis has distal extension bases)
7. One or more bases, each supporting one to several replacement teeth (see [Figure 5-1](#))

When a prosthesis that can be removed from the mouth is used, the prosthesis must extend to both sides of the arch. This enables transfer of functional forces of occlusion from the denture base to all supporting teeth and tissues within an arch for optimum stability. It is through this cross-arch tooth contact, which occurs at some distance from the functional force, that optimum resistance can be achieved. This is most effectively accomplished when a rigid major connector joins the portion of the prosthesis receiving the function to selected regions throughout the arch.

The chief functions of a major connector include unification of the major parts of the prosthesis, distribution of the applied force throughout the arch to selected teeth and tissue, and minimization of torque to individual teeth. A properly designed rigid major connector effectively distributes forces throughout the arch and acts to reduce the load to any one area while effectively controlling prosthesis movement.

The principle of leverage is connected with this component part. A rigid major connector limits movement possibilities by acting as a counteracting lever. This phenomenon is referred to as *cross-arch stability*. Cross-arch stability becomes more important in situations associated with high potential for greater prosthesis movement (e.g., distal extensions).



**FIGURE 5-1** **A**, Framework for mandibular removable partial denture with the following components: 1, lingual bar major connector; 2a, minor connector by which the resin denture base will be attached; 2b, minor connector, proximal plate, which is part of clasp assembly; 2c, minor connector used to connect rests to major connectors; 3, occlusal rests; 4, direct retainer arm, which is part of the total clasp assembly; 5, stabilizing or reciprocal components of clasp assembly (includes minor connectors); and 6, an indirect retainer consisting of a minor connector and an occlusal rest. **B**, Maxillary removable partial denture with resin denture bases supporting artificial posterior teeth. Bases are attached to metal framework by ladderlike minor connectors similar to those seen in 2a. **C**, Mandibular bilateral distal extension removable partial denture with resin denture bases supporting artificial posterior teeth.

In this chapter, major and minor connectors are considered separately as to their function, location, and design criteria. Other components are presented in designated chapters.

### ROLE OF MAJOR CONNECTORS IN CONTROL OF PROSTHESIS MOVEMENT

A major connector is the component of the partial denture that connects the parts of the prosthesis located on one side of the arch with those on the opposite side. It is that unit of the partial denture to which all other parts are directly or indirectly attached. This component also provides cross-arch stability to help resist displacement by functional stresses.

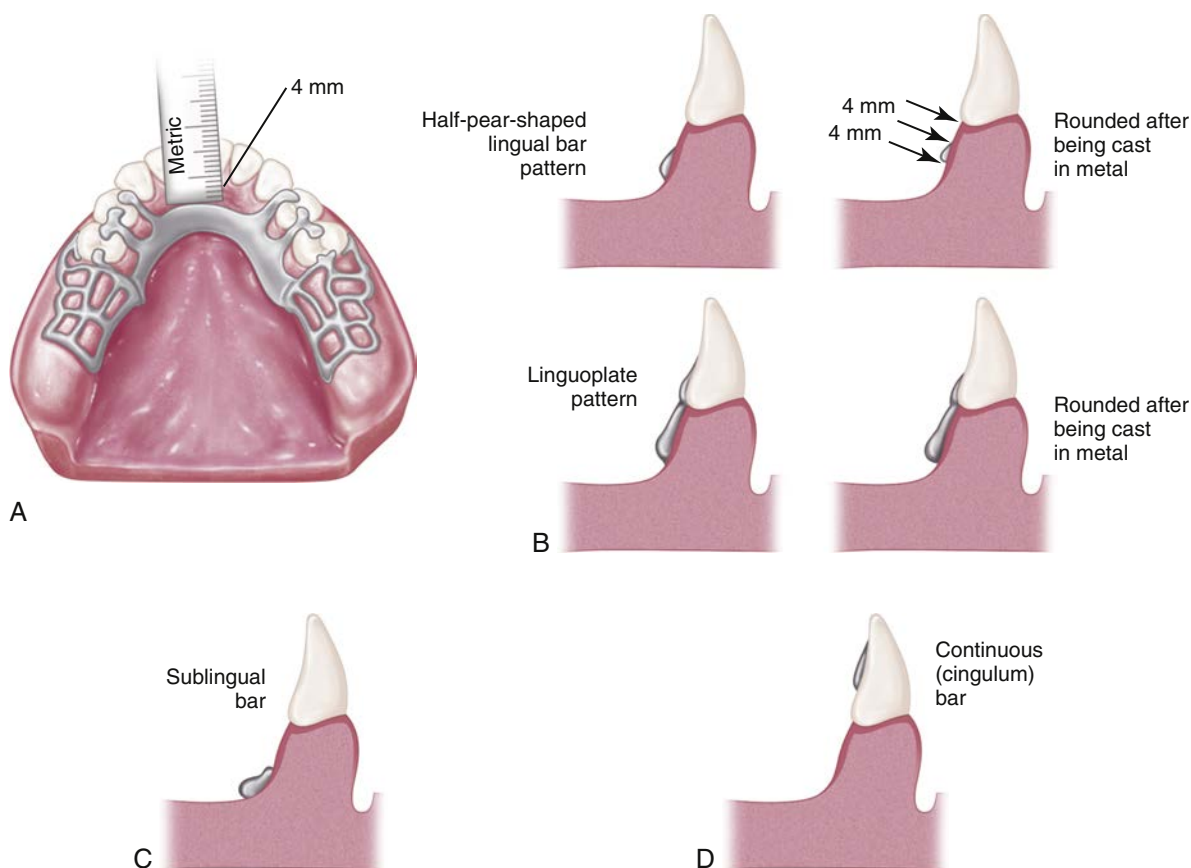
The major connector may be compared with the frame of an automobile or with the foundation of a building. It is through the major connector that other components of the

partial denture become unified and effective. If the major connector is flexible, the ineffectiveness of connected components jeopardizes the supporting oral structures and can be a detriment to the comfort of the patient. Failure of the major connector to provide rigidity may be manifest by traumatic damage to periodontal support of the abutment teeth, injury to residual ridges, or impingement of underlying tissue. It is the dentist's responsibility to ensure that appropriate design and fabrication of the major connector are accomplished.

#### Location

Major connectors should be designed and located with the following guidelines in mind:

1. Major connectors should be free of movable tissue.
2. Impingement of gingival tissue should be avoided.
3. Bony and soft tissue prominences should be avoided during placement and removal.



**FIGURE 5-2** A, Lingual bar major connector should be located at least 4 mm inferior to gingival margins and farther if possible. The vertical height of a finished lingual bar should be at least 4 mm for strength and rigidity. If less than 8 mm exists between gingival margins and the movable floor of the mouth, a linguoplate (B), a sublingual bar (C), or a continuous bar (D) is preferred as a major connector. Relief is provided for soft tissue under all portions of the mandibular major connector and at any location where the framework crosses the marginal gingiva. The inferior border of mandibular major connectors should be gently rounded after being cast to eliminate a sharp edge.

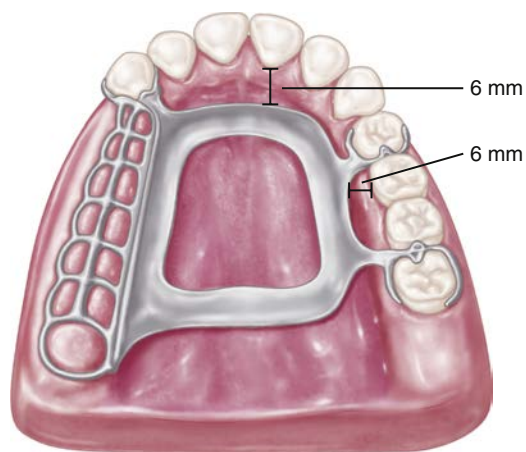
4. Relief should be provided beneath a major connector to prevent its settling into areas of possible interference, such as inoperable tori or elevated median palatal sutures.
5. Major connectors should be located and/or relieved to prevent impingement of tissue that occurs because the distal extension denture rotates in function.

Appropriate relief beneath the major connector avoids the need for its adjustment after tissue damage has occurred. In addition to being time consuming, grinding to provide relief from impingement may seriously weaken the major connector, which can result in flexibility or possibly fracture. Major connectors should be carefully designed for proper shape, thickness, and location. Alteration of these dimensions by grinding can only be detrimental. Relief is covered at the end of this chapter and is expanded in Chapter 11.

Margins of major connectors adjacent to gingival tissue should be located far enough from the tissue to avoid any possible impingement. To accomplish this, it is recommended that the superior border of a lingual bar connector be located a minimum of 4 mm below the gingival margin(s) (Figure 5-2). At the inferior border of the lingual

bar connector, the limiting factor is the height of the moving tissue in the floor of the mouth. Because the connector must have sufficient width and bulk to provide rigidity, a linguoplate is commonly used when space is insufficient for a lingual bar.

In the maxillary arch, because no moving tissue is present in the palate as in the floor of the mouth, the borders of the major connector may be placed well away from gingival tissue. Structurally, the tissue covering the palate is well suited for placement of the connector because of the presence of firm submucosal connective tissue and an adequate, deep blood supply. However, when soft tissue covering the midline of the palate is less displaceable than the tissue covering the residual ridge, varying amounts of relief under the connectors must be provided to avoid impingement of tissue. The amount of relief required is directly proportional to the difference in displaceability of the tissue covering the midline of the palate and the tissue covering the residual ridges. The gingival tissue, on the other hand, must have an unrestricted superficial blood supply to remain healthy. To accomplish this, it is recommended that the borders of



**FIGURE 5-3** Palatal major connector should be located at least 6 mm away from gingival margins and parallel to their mean curvature. All adjoining minor connectors should cross gingival tissues abruptly and should join major connectors at nearly a right angle.

the palatal connector be placed a minimum of 6 mm away from and parallel to the gingival margins. Minor connectors that must cross gingival tissue should do so abruptly, joining the major connector at nearly a right angle (Figure 5-3). In this way, maximum freedom is ensured for gingival tissue.

Except for a palatal torus or a prominent median palatal suture area, palatal connectors ordinarily require no relief. Intimate contact between the connector and the supporting tissue adds much to the support, stability, and retention of the denture. Except for gingival areas, intimacy of contact elsewhere in the palate is not detrimental to the health of the tissue if rests are provided on abutment teeth to prevent tissue-ward movement.

An anterior palatal strap or the anterior border of a palatal plate also should be located as far as possible posteriorly to avoid interference with the tongue in the area of the rugae. It should be uniformly thin and its anterior border should be located to follow the contours between the crests of the rugae. The anterior borders of such palatal major connectors therefore will be irregular in outline as they follow the contours between the rugae. The tongue may then pass from one ruga prominence to another without encountering the border of the connector. When the connector border must cross a ruga crest, this should be done abruptly, while avoiding the crest as much as possible. The posterior limitation of a maxillary major connector should be just anterior to the vibrating line. A useful rule applied to major connectors and throughout partial denture design is to try to avoid adding any part of the denture framework to an already convex surface.

Characteristics of major connectors that contribute to the maintenance of health of the oral environment and the well-being of the patient may be listed as shown in Box 5-1.

### Box 5-1

#### CHARACTERISTICS OF MAJOR CONNECTORS CONTRIBUTING TO HEALTH AND WELL-BEING

1. Are made from an alloy compatible with oral tissue
2. Are rigid and provide cross-arch stability through the principle of broad distribution of stress
3. Do not interfere with and are not irritating to the tongue
4. Do not substantially alter the natural contour of the lingual surface of the mandibular alveolar ridge or of the palatal vault
5. Do not impinge on oral tissue when the restoration is placed, is removed, or rotates in function
6. Cover no more tissue than is absolutely necessary
7. Do not contribute to retention or trapping of food particles
8. Have support from other elements of the framework to minimize rotation tendencies in function
9. Contribute to the support of the prosthesis

### Mandibular Major Connectors

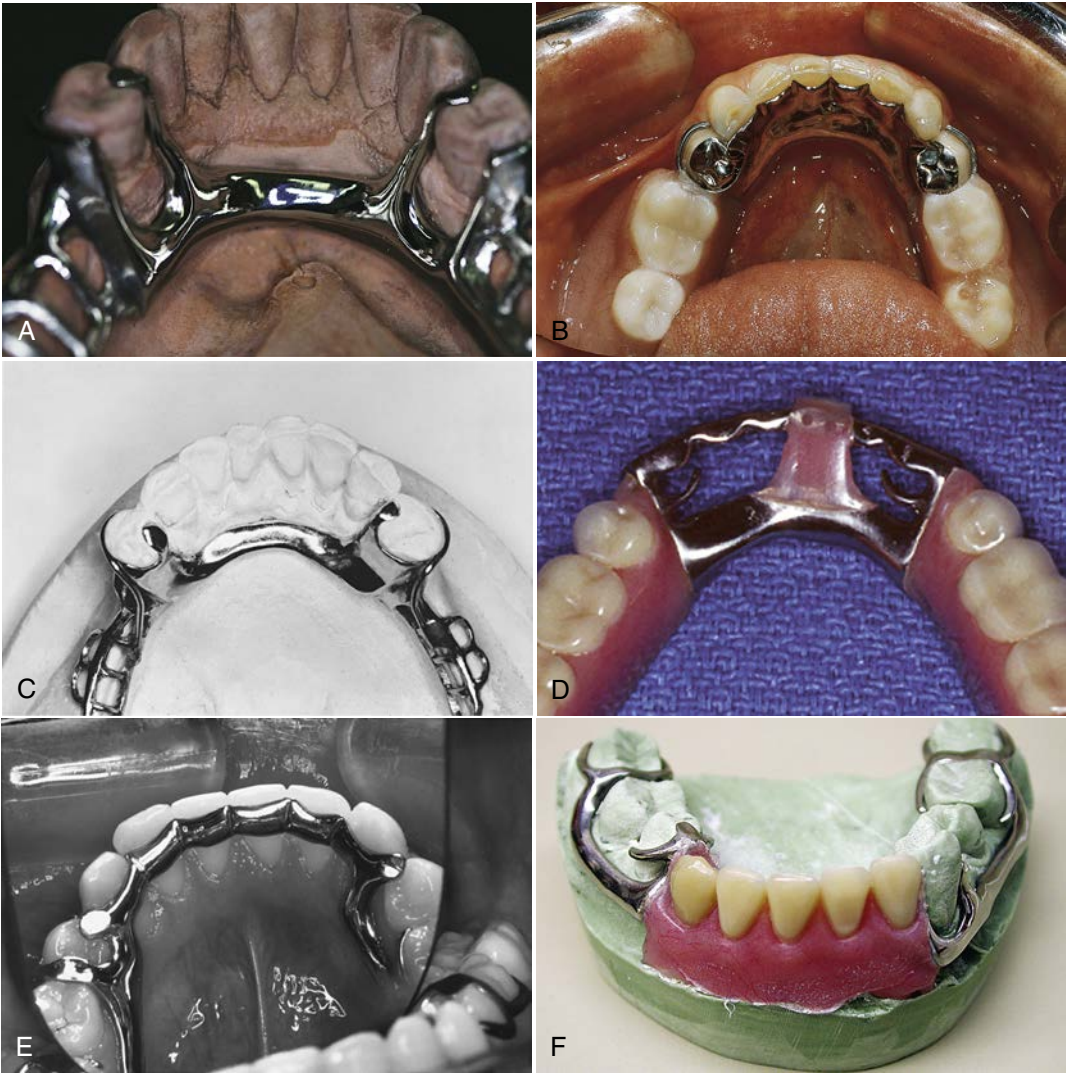
There are six types of mandibular major connectors described historically. Of these, the lingual bar and the linguoplate are used the majority of the time.

1. Lingual bar (Figure 5-4, A)
2. Linguoplate (see Figure 5-4, B)
3. Sublingual bar (see Figure 5-4, C)
4. Lingual bar with cingulum bar (continuous bar) (see Figure 5-4, D)
5. Cingulum bar (continuous bar) (see Figure 5-4, E)
6. Labial bar (see Figure 5-4, F)

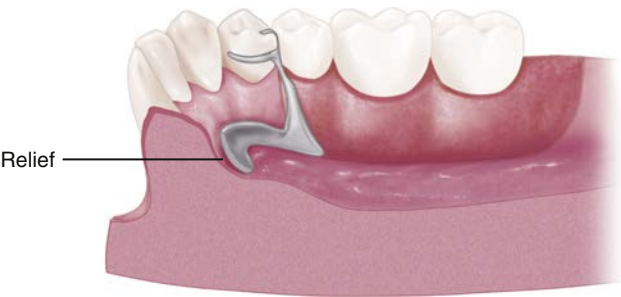
### Lingual Bar

The basic cross-section form of a mandibular major connector is a half-pear shape, located above moving tissue but as far below the gingival tissue as possible. It is usually made of reinforced, 6-gauge, half-pear-shaped wax or a similar plastic pattern (Figure 5-5).

The major connector must be contoured so that it does not present sharp margins to the tongue and cause irritation or annoyance by an angular form. The superior border of a lingual bar connector should be tapered toward the gingival tissue superiorly, with its greatest bulk at the inferior border, resulting in a contour that has a half-pear shape. Lingual bar patterns, both wax and plastic, are made in this conventional shape. However, the inferior border of the lingual bar should be slightly rounded when the framework is polished. A rounded border will not impinge on the lingual tissue when the denture bases rotate inferiorly under occlusal loads. Frequently, additional bulk is necessary to provide rigidity, particularly when the bar is long or when a less rigid alloy is used. This is accomplished by lining the ready-made form underneath with a sheet of 24-gauge casting wax rather than altering the original half-pear shape.



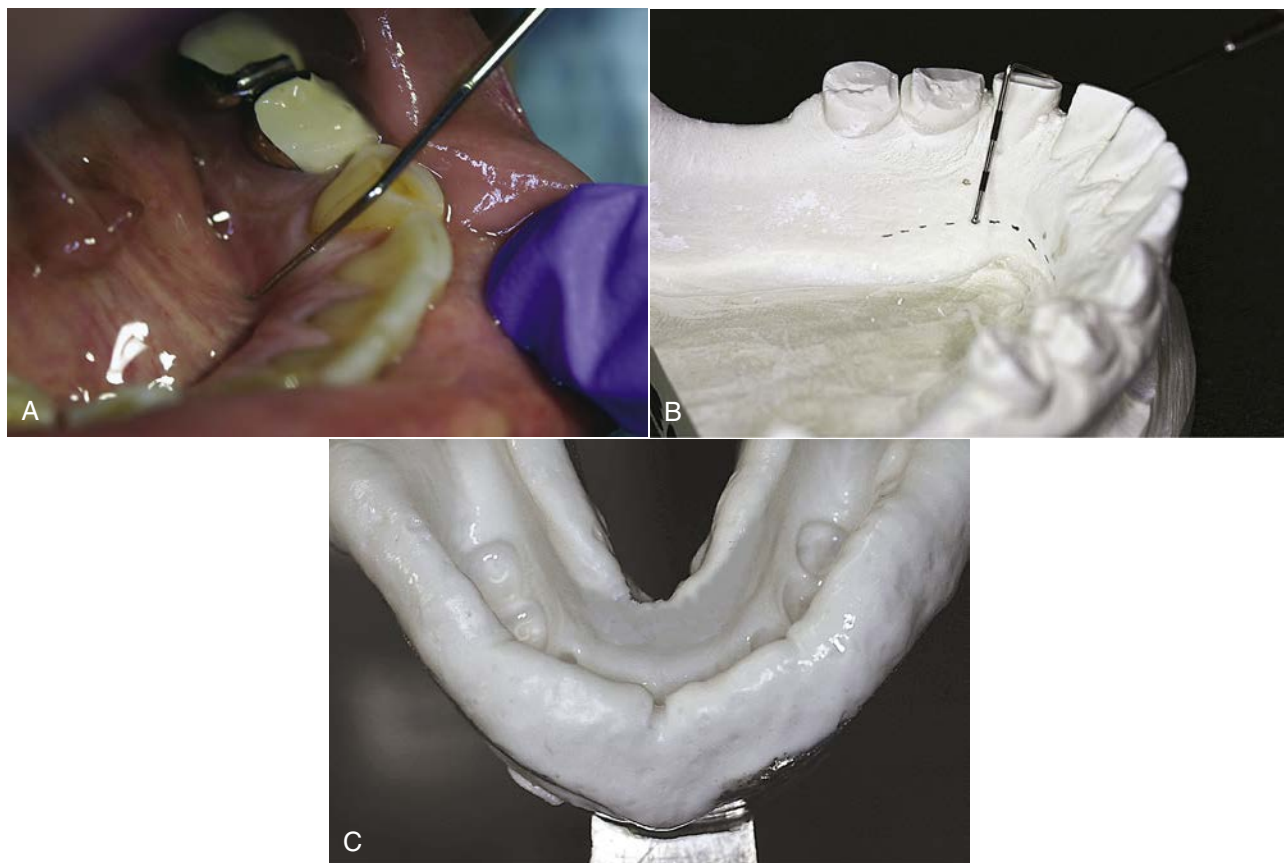
**FIGURE 5-4** Mandibular major connectors. **A**, Lingual bar. **B**, Linguoplate. **C**, Sublingual bar. **D**, Lingual bar with continuous bar (cingulum bar). **E**, Cingulum bar. **F**, Labial bar.



**FIGURE 5-5** Sagittal section showing half-pear shape of lingual bar. A taper of the superior border of the bar to the soft tissues above minimizes interference with the tongue and is more acceptable to the patient than a dissimilar contour. Tissue relief is necessary to protect the soft tissue of the floor of the mouth.

The inferior border of a lingual mandibular major connector must be located so that it does not impinge on the tissue in the floor of the mouth because it changes elevations during the normal activities of mastication, swallowing, speaking, licking the lips, and so forth. Yet at the same time, it seems logical to locate the inferior border of these connectors as far inferiorly as possible to avoid interference with the resting tongue and trapping of food substances when they are introduced into the mouth. In addition, the more inferiorly a lingual bar can be located, the farther the superior border of the bar can be placed from the lingual gingival crevices of adjacent teeth, thereby avoiding impingement on the gingival tissue.

At least two clinically acceptable methods may be used to determine the relative height of the floor of the mouth and locate the inferior border of a lingual mandibular major connector. The first method is to measure the height of the floor of

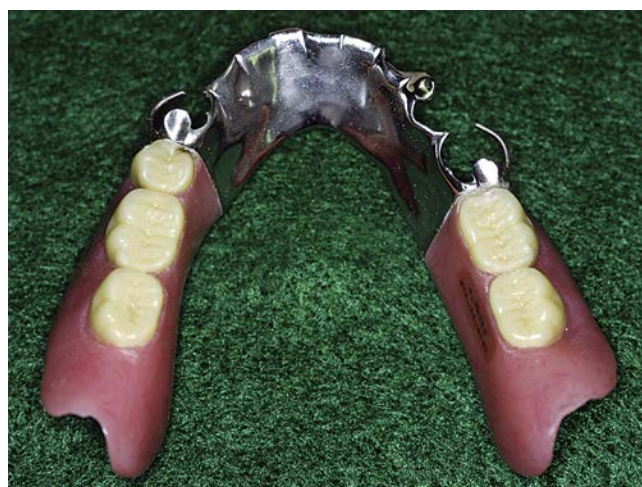

**FIGURE 5-6** **A**, Height of floor of the mouth (tongue elevated) in relation to lingual gingival sulci measured with a periodontal probe. **B**, Recorded measurements are transferred to a diagnostic cast and then to a master cast after mouth preparations are completed. The line connecting marks indicates the location of the inferior border of the major connector. If periodontal surgery is performed, the line on the cast can be related to incisal edges of teeth and the measurements recorded for subsequent use. **C**, Impression made with functional movement of the tongue to demonstrate maximum shortening of the floor of the mouth. This allows visualization of the anatomic feature that establishes the inferior extent of a major connector. If a stock tray causes impingement on this functional position, an individualized or custom tray may be used for the same purpose.

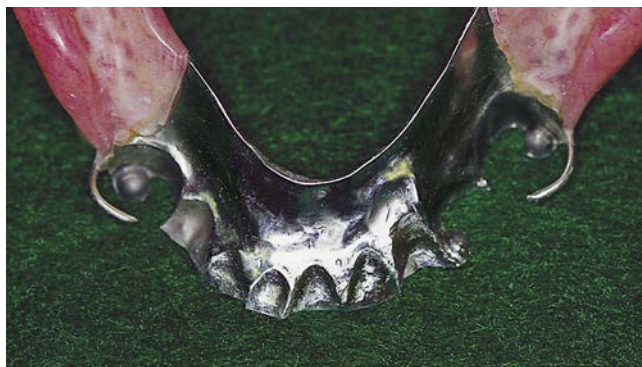the mouth in relation to the lingual gingival margins of adjacent teeth with a periodontal probe (Figure 5-6). When these measurements are taken, the tip of the patient's tongue should just lightly touch the vermilion border of the upper lip. Recording of these measurements permits their transfer to both diagnostic and master casts, thus ensuring a rather advantageous location of the inferior border of the major connector. The second method is to use an individualized impression tray for which lingual borders are 3 mm short of the elevated floor of the mouth, and then to use an impression material that will permit the impression to be accurately molded as the patient licks the lips. The inferior border of the planned major connector can then be located at the height of the lingual sulcus of the cast resulting from such an impression. Of the two methods, we have found measuring the height of the floor of the mouth to be less variable and more clinically acceptable.

### Linguoplate

If the rectangular space is bounded by the lingual bar, the anterior tooth contacts, and the cingula, and the bordering minor connectors are filled in, a linguoplate results (Figure 5-7).



**FIGURE 5-7** View of mandibular Class I design with contoured linguoplate. Linguoplate is made as thin as possible and should follow the lingual contours of the teeth contacted. Doing so will often result in a scalloped superior margin. In this example, the straight superior margin can be bulky at the cingulum region, causing tongue discomfort.



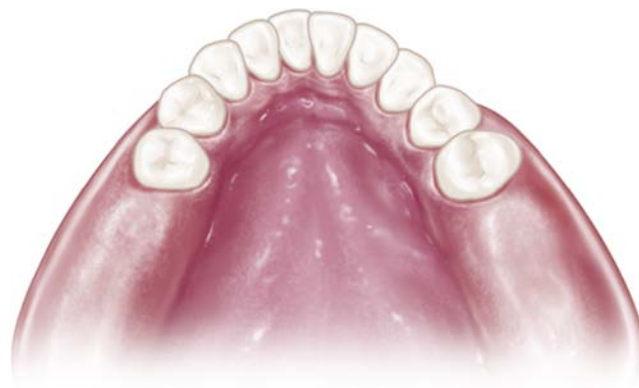**FIGURE 5-8** Apron of linguoplate (tissue side) is closely adapted to the teeth extending into nonundercut interproximal embrasures, resulting in a scalloped form. When well adapted, this form benefits from some anterior teeth acting together to help resist horizontal rotational tendencies of the prosthesis, especially if the posterior ridge form does not resist such movement.

A linguoplate should be made as thin as is technically feasible and should be contoured to follow the contours of the teeth and the embrasures (Figure 5-8). The patient should be aware of as little added bulk and as few altered contours as possible. The upper border should follow the natural curvature of the supracingular surfaces of the teeth and should not be located above the middle third of the lingual surface, except to cover interproximal spaces to the contact points. The half-pear shape of a lingual bar should still form the inferior border that provides the greatest bulk and rigidity. All gingival crevices and deep embrasures must be blocked out parallel to the path of placement to avoid gingival irritation and any wedging effect between the teeth. In many instances, judicious recontouring of the lingual proximal surfaces of overlapped anterior teeth permits closer adaptation of the linguoplate major connector, eliminating otherwise deep interproximal embrasures to be covered (Figure 5-9).

The linguoplate does not in itself serve as an indirect retainer. When indirect retention is required, definite rests must be provided for this purpose. Both the linguoplate and the cingulum bar ideally should have a terminal rest at each end, regardless of the need for indirect retention. However, when indirect retainers are necessary, these rests may also serve as terminal rests for the linguoplate or continuous bar.

Because no component part of a removable partial denture should be added arbitrarily, each component should be added to serve a definite purpose. Indications for the use of a linguoplate may be listed as follows:

1. When the lingual frenum is high or the space available for a lingual bar is limited: In either instance, the superior border of a lingual bar would have to be placed too close to the gingival tissue. Irritation could be avoided only by generous relief, which might be annoying to the tongue and create an undesirable food trap. When a clinical measurement from the free gingival margins to the slightly elevated floor of the mouth is less than 8 mm, a linguoplate is indicated in lieu of a lingual bar. The use

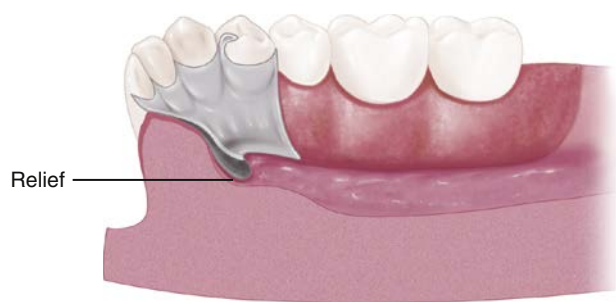


**FIGURE 5-9** If a linguoplate major connector is indicated for this patient with overlapped anterior teeth, judicious recontouring of the lingual proximal surfaces of right lateral, right central, and left lateral incisors eliminates excessive undercuts and permit closer adaptation of the lingual apron of the major connector.

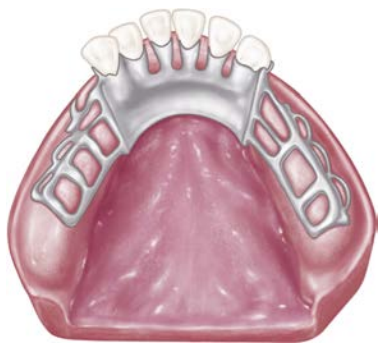of a linguoplate permits the inferior border to be placed more superiorly without tongue and gingival irritation and without compromise of rigidity.

2. In Class I situations in which the residual ridges have undergone excessive vertical resorption: Flat residual ridges offer little resistance to the horizontal rotational tendencies of a denture. The bracing effect provided by the remaining teeth must be depended upon to resist such rotation. A correctly designed linguoplate will engage the remaining teeth to help resist horizontal rotations.
3. For stabilizing periodontally weakened teeth, splinting with a linguoplate can be of some value when used with definite rests on sound adjacent teeth: As was described previously, a cingulum bar may be used to accomplish the same purpose because it actually represents the superior border of a linguoplate without the gingival apron. The cingulum bar accomplishes stabilization along with the other advantages of a linguoplate. However, it is frequently more objectionable to the patient's tongue and is certainly more of a food trap than is the contoured apron of a linguoplate.
4. When the future replacement of one or more incisor teeth will be facilitated by the addition of retention loops to an existing linguoplate: Mandibular incisors that are periodontally weak may thus be retained, with provisions for possible loss and future additions.

The same reasons for use of a linguoplate anteriorly apply to its use elsewhere in the mandibular arch. If a lingual bar alone is to be used anteriorly, there is no reason to add an apron elsewhere. However, when auxiliary splinting is used for stabilization of the remaining teeth or for horizontal stabilization of the prosthesis, or for both, small rectangular spaces sometimes remain. Tissue response to such small spaces is better when they are bridged with an apron than when they are left open. Generally, the apron is used to avoid gingival irritation or entrapment of food debris or to cover generously relieved areas that would be irritating to the tongue (Figure 5-10).



**FIGURE 5-10** Sagittal section through the linguoplate demonstrating a basic half-pear-shaped inferior border with the metallic apron extending superiorly. Extension of linguoplate to the height of contour on the premolar was accomplished to enclose a rather large triangular interproximal space inferior to the contact point between the canine and premolar. Such spaces may often be bridged to eliminate obvious food traps. Relief is provided for soft tissue under all portions of the mandibular major connector and at any location where the framework crosses the marginal gingiva.



**FIGURE 5-11** Interrupted linguoplate in the presence of interproximal spaces.

Sometimes a dentist is faced with a clinical situation wherein a linguoplate is indicated as the major connector of choice even though the anterior teeth are quite spaced and the patient strenuously objects to metal showing through the spaces. The linguoplate can then be constructed so that the metal will not appreciably show through the spaced anterior teeth (Figure 5-11). The rigidity of the major connector is not greatly altered. However, such a design may be as much of a food trap as the continuous bar type of major connector.

### Design of Mandibular Major Connectors

The following systematic approach to the design of a mandibular lingual bar and linguoplate major connectors can be readily used with diagnostic casts after the diagnostic data are considered and related to the basic principles of major connector design:

- Step 1: Outline the basal seat areas on the diagnostic cast (Figure 5-12, A)
- Step 2: Outline the inferior border of the major connector (see Figure 5-12, B)

Step 3: Outline the superior border of the major connector (see Figure 5-12, C)

Step 4: Connect the basal seat area to the inferior and superior borders of the major connector, and add minor connectors to retain the acrylic resin denture base material (see Figure 5-12, D)

### Sublingual Bar

A modification of the lingual bar that has been demonstrated to be useful when the height of the floor of the mouth does not allow placement of the superior border of the bar at least 4 mm below the free gingival margin is the sublingual bar. The bar shape remains essentially the same as that of a lingual bar, but placement is inferior and posterior to the usual placement of a lingual bar, lying over and parallel to the anterior floor of the mouth. It is generally accepted that a sublingual bar can be used in lieu of a lingual plate if the lingual frenum does not interfere, or in the presence of an anterior lingual undercut that would require considerable blockout for a conventional lingual bar. Contraindications include interfering lingual tori, high attachment of a lingual frenum, and interference with elevation of the floor of the mouth during functional movements.

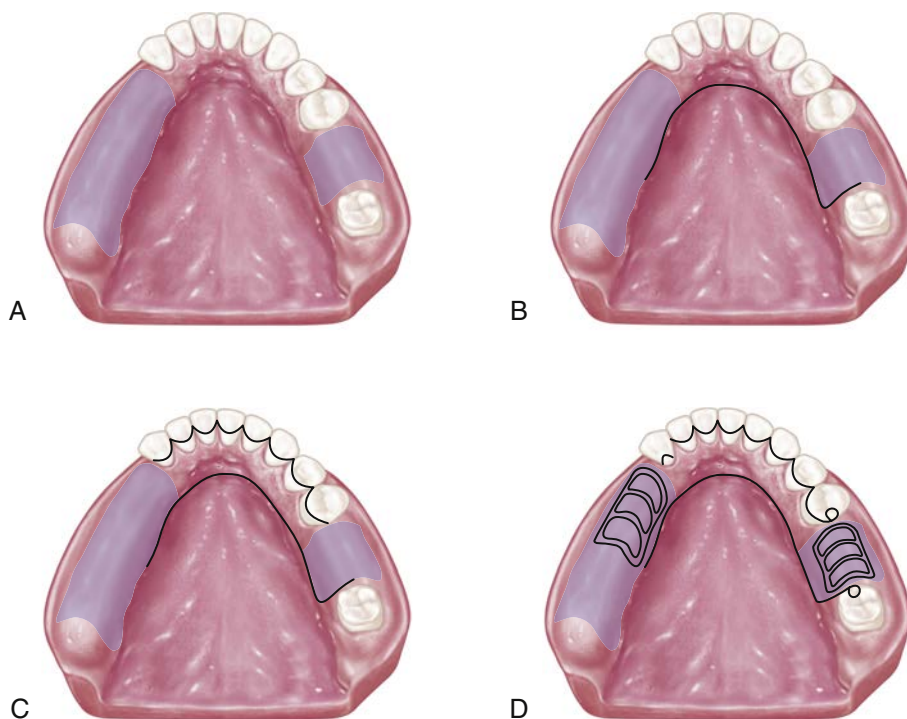
### Cingulum Bar (Continuous Bar)

When a linguoplate is the major connector of choice but the axial alignment of the anterior teeth is such that excessive blockout of interproximal undercuts must be made, a cingulum bar may be considered. A cingulum bar located on or slightly above the cingula of the anterior teeth may be added to the lingual bar or can be used independently (Figure 5-13). In addition, when wide diastemata exist between the lower anterior teeth, a continuous bar retainer may be more esthetically acceptable than a linguoplate.

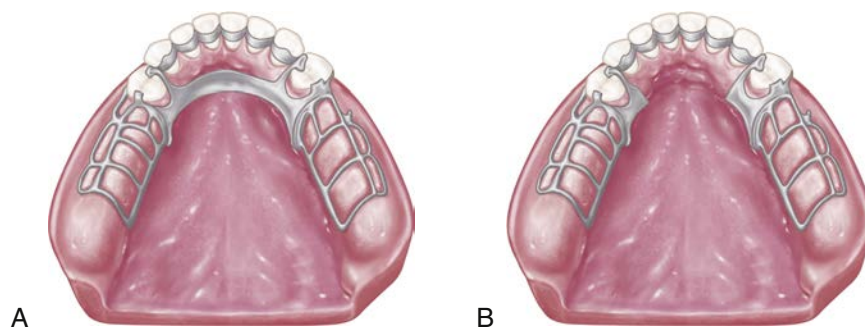
### Labial Bar

Fortunately, in only a few situations does extreme lingual inclination of the remaining lower premolar and incisor teeth prevent the use of a lingual bar major connector. With the use of conservative mouth preparations in the form of recontouring and blockout, a lingual major connector can almost always be used. Lingually inclined teeth sometimes may have to be reshaped by means of crowns. Although the use of a labial major connector may be necessary in rare instances, this should be avoided by resorting to necessary mouth preparations rather than by accepting a condition that is otherwise correctable (Figure 5-14). The same applies to the use of a labial bar when a mandibular torus interferes with placement of a lingual bar. Unless surgery is definitely contraindicated, interfering mandibular tori should be removed so that the use of a labial bar connector may be avoided.

A modification to the linguoplate is the hinged continuous labial bar. This concept is incorporated in the



**FIGURE 5-12** Sequence of design considerations for a mandibular major connector. **A**, Diagnostic cast with basal seat areas outlined. **B**, Inferior border of the major connector is outlined. Location of the inferior border was determined as suggested in Figure 5-6 and extends to the mesial of the mandibular right molar. **C**, Superior border of the major connector is outlined. Limited space for the lingual bar requires use of the linguoplate major connector. Linguoplate requires that rest seats be used on canines and the first premolar for positive support. **D**, Rest seat areas on the posterior teeth are outlined, and minor connectors for retention of resin denture bases are sketched.



**FIGURE 5-13** **A**, Lingual bar and cingulum bar (continuous bar) major connector. Upper portion of this major connector is located on the cingula of anterior teeth. The requirement of positive support by rest seats, at least as far anteriorly as the canines, is critical. Note that the superior border of the lingual bar portion is often placed objectionably close to the gingival margins if sufficient bulk for rigidity is to be obtained. This type of major connector easily traps food and is often more objectionable to patients than a linguoplate. **B**, Cingulum bar (continuous bar) major connector. Although this design may reduce the possibility of food entrapment, it may not provide adequate rigidity.

Swing-Lock\* design, which consists of a labial or buccal bar that is connected to the major connector by a hinge at one end and a latch at the other end (Figure 5-15).

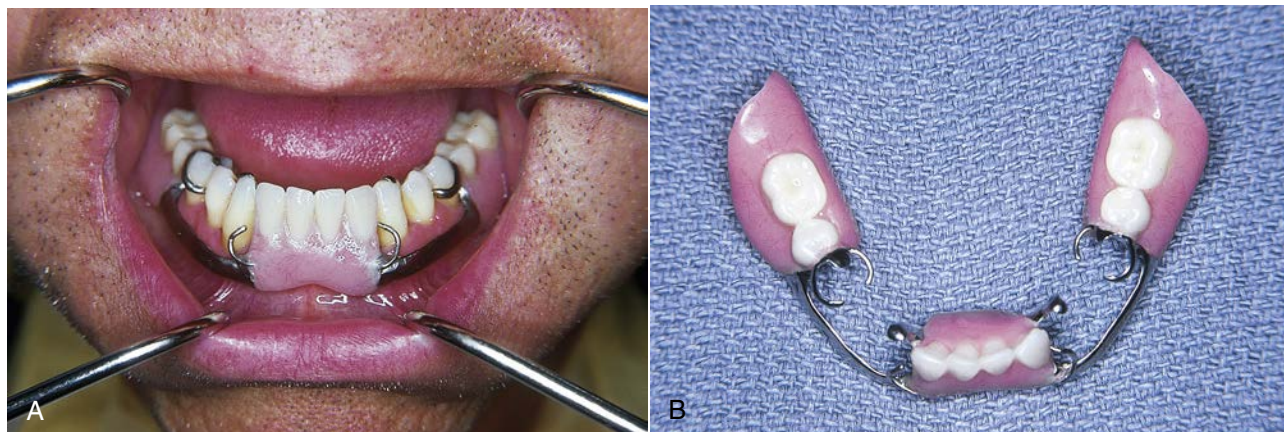
Support is provided by multiple rests on the remaining natural teeth. Stabilization and reciprocation are provided by a linguoplate that contacts the remaining teeth and are supplemented by the labial bar with its retentive

struts. Retention is provided by a bar type of retentive clasp with arms projecting from the labial or buccal bar and contacting the infrabulge areas on the labial surfaces of the teeth.

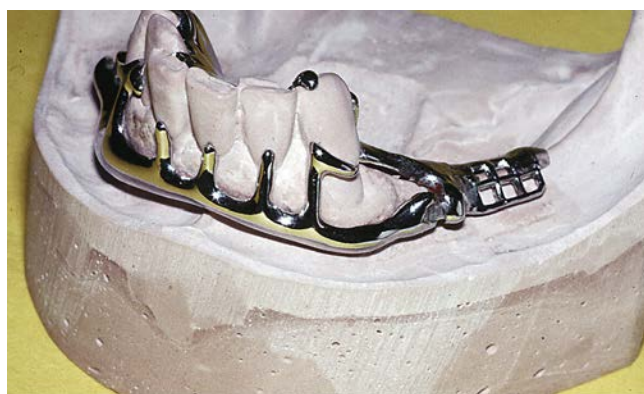Use of the Swing-Lock concept would seem primarily indicated when the following conditions are present:

1. Missing key abutments: When all remaining teeth are used for retention and stability, the absence of a key abutment (such as, a canine) may not present as

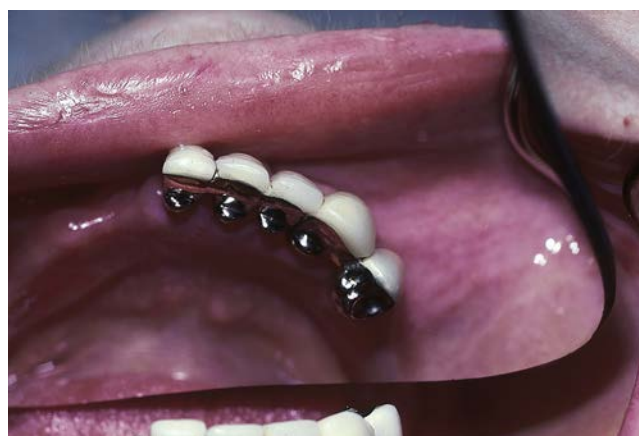\* Swing-Lock Inc., Milford, Texas.



**FIGURE 5-14** A, Lingual inclination of patient's canines and premolars precludes use of the lingual bar. B, Labial bar major connector was used in treatment. Retention was obtained on terminal abutments. Support and stabilization were gained by using rests, minor connectors arising from the labial bar, and well-fitting denture bases.



**FIGURE 5-15** The hinge for this continuous labial bar connector is located buccal and distal to the remaining dentition (area of tooth #21). The latching mechanism is opposite to the hinge, adjacent to tooth #28. In this location, it will be housed within the buccal flange of the denture.



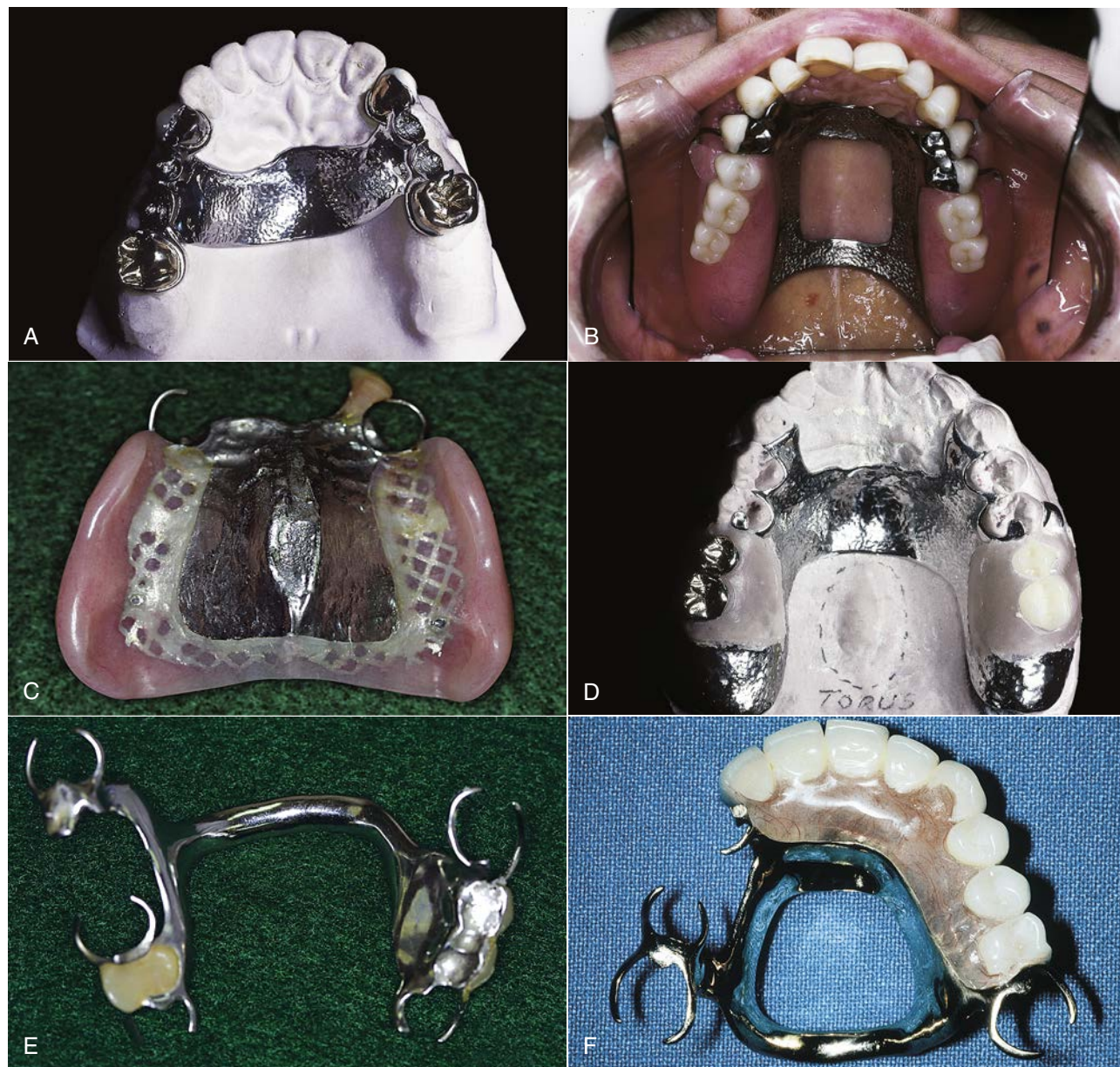
**FIGURE 5-16** Absence of the mandibular canine requires that all remaining anterior teeth be used for stabilization and retention of the replacement restoration. The Swing-Lock concept can be used to ensure that all remaining teeth share in stabilization and retention of the prosthesis.

serious a treatment problem with this concept as with more conventional designs (Figure 5-16).

2. Unfavorable tooth contours: When existing tooth contours (uncorrectable by recontouring with appropriate restorations) or excessive labial inclinations of anterior teeth prevent conventional clasp designs, the basic principles of removable partial design may be better implemented with the Swing-Lock concept.
3. Unfavorable soft tissue contours: Extensive soft tissue undercuts may prevent proper location of component parts of a conventional removable partial denture or an overdenture. The hinged continuous labial bar concept may provide an adjunctive modality to accommodate such unfavorable soft tissue contours.
4. Teeth with questionable prognoses: The possibility of losing a key abutment tooth with a guarded prognosis seriously affects the stability and retention of a conventional prosthesis. Because all remaining teeth

function as abutments in the Swing-Lock denture, it seems that the loss of a tooth would not compromise retention and stability to such a degree. The hinged labial bar type of restoration can be used satisfactorily in certain clinically compromised situations. As is true with any type of removable restoration, good oral hygiene, maintenance, regular recall, and close attention to details of design are paramount to successful implementation of this treatment concept.

Obvious contraindications to the use of this hinged labial bar concept are apparent. The most obvious is poor oral hygiene or lack of motivation for plaque control by the patient. Other contraindications include the presence of a shallow buccal or labial vestibule or a high frenal attachment. Any of these factors would prevent the proper placement of components of the Swing-Lock partial denture.



**FIGURE 5-17** Maxillary major connectors. A, Single palatal strap. B, Anterior-posterior palatal strap. C, Palatal plate. D, U-shaped. E, Single palatal bar. F, Anterior-posterior palatal bars.

### Maxillary Major Connectors

Six basic types of maxillary major connectors are considered:

1. Single palatal strap (Figure 5-17, A)
2. Combination anterior and posterior palatal strap-type connector (see Figure 5-17, B)
3. Palatal plate-type connector (see Figure 5-17, C)
4. U-shaped palatal connector (see Figure 5-17, D)
5. Single palatal bar (see Figure 5-17, E)
6. Anterior-posterior palatal bars (see Figure 5-17, F)

Whenever it is necessary for the palatal connector to make contact with the teeth for reasons of support, definite tooth support must be provided. This is best accomplished by establishing definite rest seats on the predetermined

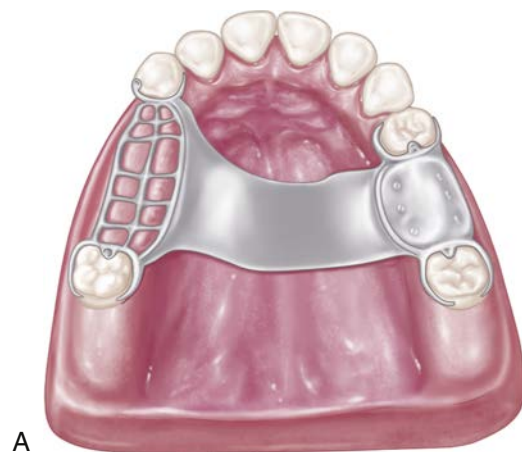abutment teeth. These should be located far enough above the gingival attachment to provide for bridging of the gingival crevice with blockout. At the same time, they should be low enough on the tooth to avoid unfavorable leverage and low enough on the maxillary incisors and canine teeth to avoid incisal interference of the opposing dentition.

Major connector components resting on unprepared inclined tooth surfaces can lead to slippage of the denture or to orthodontic movement of the tooth, or to both. In either situation, settling into gingival tissue is inevitable. In the absence of the required vertical support provided by rests, the health of the surrounding tissue is usually impaired. Similarly, interproximal projections of the major connector

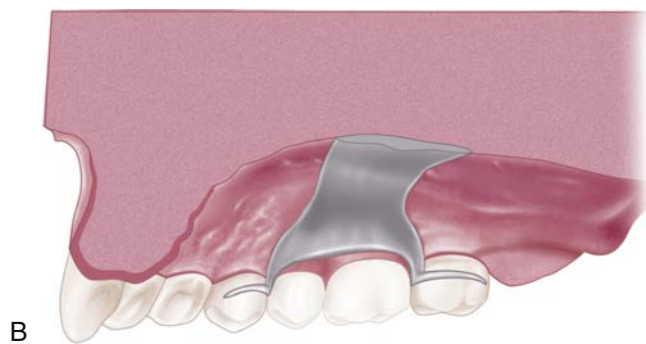
that rest on the gingival third of the tooth and on gingival tissues that are structurally unable to render support may be traumatized. To prevent these sequelae, one should support the major connector with definite rests on the teeth, provide adequate gingival relief, and/or locate the connector far enough away from the gingival margin to avoid any possible restriction of blood supply and entrapment of food debris. All gingival crossings should be abrupt and at right angles to the major connector. Creating a sharp, angular form on any portion of a palatal connector should be avoided, and all borders should be tapered toward the tissue.

### Single Palatal Strap

Bilateral tooth-supported prostheses, even those with short edentulous spaces, are effectively connected with a single, broad palatal strap connector, particularly when the edentulous areas are located posteriorly (Figure 5-18). Such a connector can be made rigid without objectionable bulk and



A



B

**FIGURE 5-18** **A**, This single palatal strap-type major connector is better suited for the restoration of short-span tooth-supported bilateral edentulous areas. It may also be used in tooth-supported unilateral edentulous situations with provision for cross-arch attachment by extracoronal retainers or internal attachments. Width of the palatal strap should be confined within the boundaries of supporting rests. **B**, Sagittal section. Midportion of the major connector demonstrates slight elevation to provide rigidity. Such thickness of the major connector does not appreciably alter palatal contours.

interference with the tongue, provided the cast framework material is distributed in three planes. Suitable rigidity, without excessive bulk, may be obtained for a single palatal strap by the laboratory technician by casting a 22-gauge matte plastic pattern.

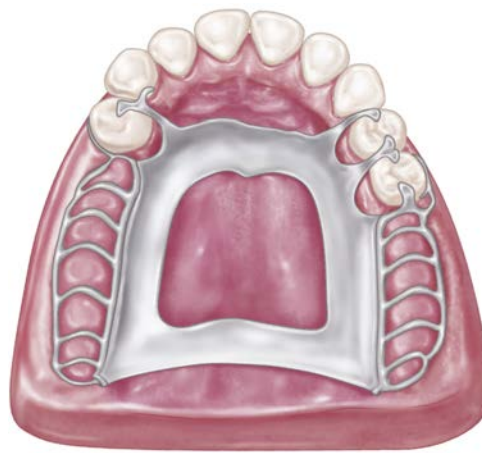For reasons of torque and leverage, a single palatal strap major connector should not be used to connect anterior replacements with distal extension bases. To be rigid enough to resist torque and to provide adequate vertical support and horizontal stabilization, a single palatal strap would have to be objectionably bulky. When placed anteriorly, this bulk would become even more objectionable to the patient because it could interfere with speech.

### Combination Anterior and Posterior Palatal Strap-Type Connector

Structurally, this is a rigid palatal major connector. The anterior and posterior palatal strap combination may be used in almost any maxillary partial denture design (Figure 5-19).

A posterior palatal strap should be flat and a minimum of 8 mm wide. Posterior palatal connectors should be located as far posterior as possible to avoid interference with the tongue but anterior to the line of flexure formed by the junction of the hard and soft palates. The only condition that prevents their use is an inoperable maxillary torus that extends posterior to the soft palate. In this situation, a broad, U-shaped major connector may be used, as described elsewhere in this chapter.

The strength of this major connector design lies in the fact that the anterior and posterior components are joined together by longitudinal connectors on either side, which form a square or rectangular frame. Each component braces



**FIGURE 5-19** Anterior-posterior palatal strap-type major connector. The anterior component is a flat strap located as far posteriorly as possible to avoid rugae coverage and tongue interference. The anterior border of this strap should be located just posterior to a rugae crest or in the valley between two crests. The posterior strap is thin, a minimum of 8 mm wide, and located as far posteriorly as possible, yet entirely on the hard palate. It should be located at right angles to midline rather than diagonally.

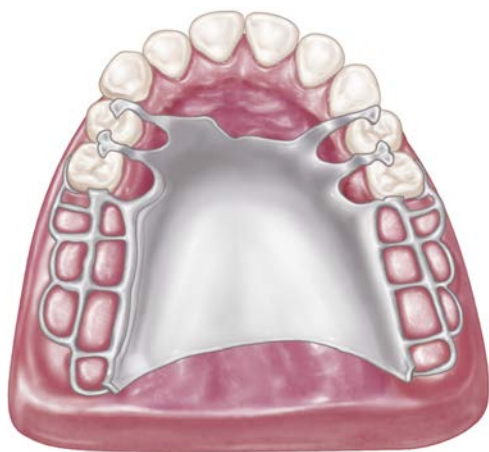the others against possible torque and flexure. Flexure is practically nonexistent in such a design.

The anterior connector may be extended anteriorly to support anterior tooth replacements. In this form, a U-shaped connector is made rigid by the horizontal strap that has been added posteriorly. If a maxillary torus exists, it may be encircled by this type of major strap-type connector without reduced rigidity.

The combination anterior-posterior connector design may be used with any Kennedy class of partially edentulous arch. It is used most frequently in Classes II and IV, whereas the single wide palatal strap is used more frequently in Class III situations. The palatal plate-type or complete coverage connector, described in this chapter, is used most frequently in Class I situations for reasons to be explained subsequently. All maxillary major connectors should cross the midline at a right angle rather than on a diagonal. It has been suggested that the tongue will accept symmetrically placed components far more readily than those placed without regard for symmetry.

### Palatal Plate-Type Connector

For lack of better terminology, the words *palatal plate* are used to designate any thin, broad, contoured palatal coverage used as a maxillary major connector and covering one half or more of the hard palate (Figure 5-20). Anatomic replica palatal castings have uniform thickness and strength by reason of their corrugated contours. Through the use of electrolytic polishing, uniformity of thickness can be maintained, and



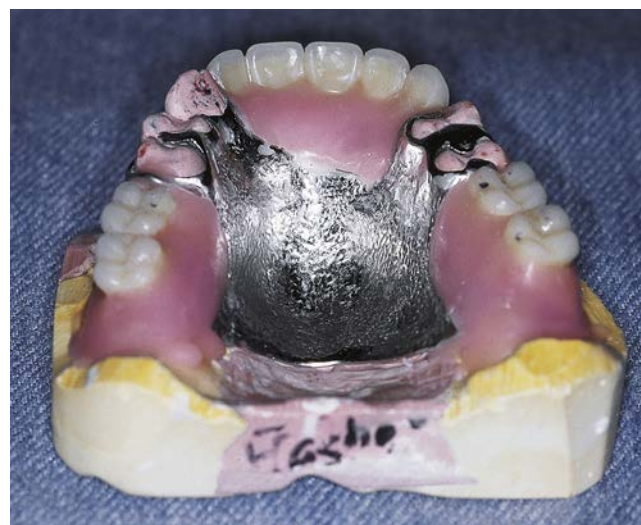**FIGURE 5-20** Palatal major connector covering two thirds of the palate. The anterior border follows valleys between rugae and does not extend anteriorly to indirect retainers on the first premolars. The posterior border is located at the junction of the hard and soft palates but does not extend onto the soft palate. In the bilateral distal extension situation illustrated, indirect retainers are a must to aid in resisting horizontal rotation of the restoration. Note that provisions have been made for a butt-type joint joining the denture bases and framework as the denture base on each side passes through the pterygomaxillary notch.

the anatomic contours of the palate will be faithfully reproduced in the finished denture.

The anatomic replica palatal major connector has several potential advantages:

1. It permits the making of a uniformly thin metal plate that reproduces faithfully the anatomic contours of the patient's own palate. Its uniform thinness and the thermal conductivity of the metal are designed to make the palatal plate more readily acceptable to the tongue and underlying tissue.
2. The corrugation in the anatomic replica adds strength to the casting; thus a thinner casting with adequate rigidity can be made.
3. Surface irregularities are intentional rather than accidental; therefore electrolytic polishing is all that is needed. The original uniform thickness of the plastic pattern is thus maintained.
4. By virtue of intimate contact, interfacial surface tension between metal and tissue provides the prosthesis with greater retention. Retention must be adequate to resist the pull of sticky foods, the action of moving border tissue against the denture, the forces of gravity, and the more violent forces of coughing and sneezing. These are all resisted to some extent by the retention of the base itself, which is proportional to the total area of denture base contact with supporting tissue. The required amount of both direct and indirect retention will depend on the amount of retention provided by the denture base.

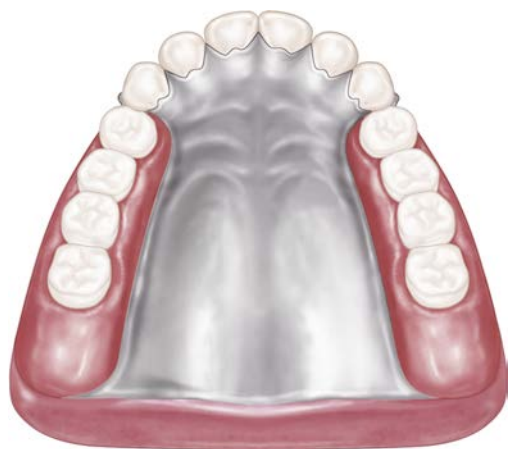The palatal plate may be used in any one of three ways. It may be used as a plate of varying width that covers the area between two or more edentulous areas, as a complete or partial cast plate that extends posterior to the junction of the hard and soft palates (Figures 5-21 and 5-22), or in the



**FIGURE 5-21** Palatal plate major connector for a Class I, modification 1 removable partial denture. The posterior border lies on the immovable hard palate and crosses the midline at a right angle. Total contact provides excellent support.

form of an anterior palatal connector with a provision for extending an acrylic resin denture base in a posterior direction (Figure 5-23).

The palatal plate should be located anterior to the posterior palatal seal area. The maxillary complete denture's typical posterior palatal seal is not necessary with a maxillary partial denture's palatal plate because of the accuracy and stability of the cast metal.



**FIGURE 5-22** Complete coverage palatal major connector. The posterior border terminates at the junction of the hard and soft palates. The anterior portion, in the form of the palatal linguo-plate, is supported by positive lingual rest seats on canines. The location of finishing lines is most important in this type of major connector. Anteroposteriorly, they should be parallel to a line along the center of the ridge crest and located just lingual to an imaginary line contacting the lingual surfaces of missing natural teeth. Alteration of the natural palatal contour should be anticipated with its attendant detrimental effects on speech if these contours are not followed.

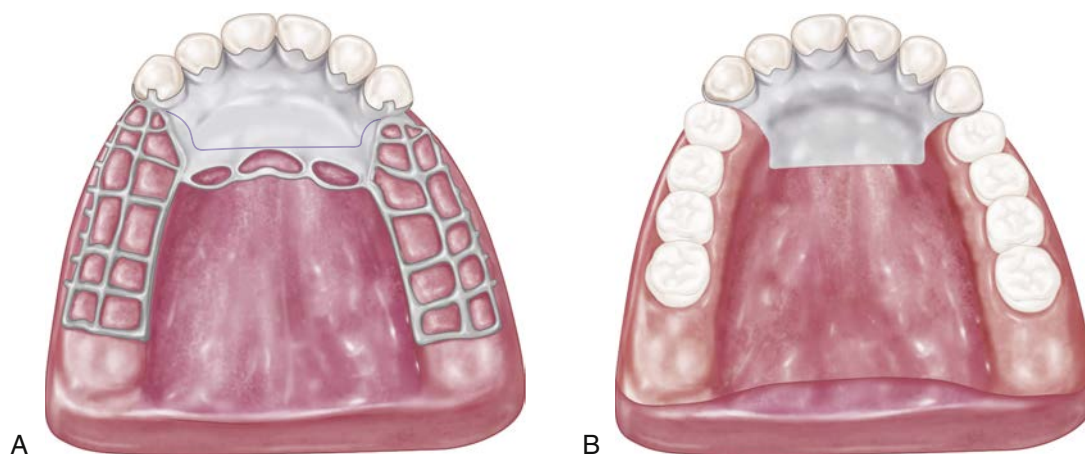
When the last remaining abutment tooth on either side of a Class I arch is the canine or first premolar tooth, complete palatal coverage is strongly advised, especially when the residual ridges have undergone excessive vertical resorption. This may be accomplished in one of two ways. One method is to use a complete cast plate that extends to the junction of the hard and soft palates (see Figure 5-22). The other method is to use a cast major connector anteriorly, with retention posteriorly, for the attachment of an acrylic-resin denture base that extends posterior to the anatomic landmarks previously described (see Figure 5-23).

Despite increased costs, the advantages of a cast palate make it preferable to an acrylic-resin palate. However, the latter method may be used satisfactorily when relining is anticipated or cost is a factor. The complete palatal plate is not a connector that has received universal use. It has, however, become accepted as a satisfactory palatal connector for many maxillary partial dentures. In all circumstances, the portion contacting the teeth must have positive support from adequate rest seats. The dentist should be familiar with its use and, at the same time, with its limitations, so that it may be used intelligently and to fullest advantage.

### Design of Maxillary Major Connectors

In 1953, Blatterfein described a systematic approach to designing maxillary major connectors. His method involves five basic steps and is certainly applicable to most maxillary removable partial denture situations. When using a diagnostic cast and knowledge of the relative displaceability of the palatal tissue, including that covering the median palatal raphe, he recommends the following basic steps:

**Step 1: Outline of primary bearing areas:** The primary bearing areas are those that will be covered by the denture base(s) (Figure 5-24, A and B).



**FIGURE 5-23** A, Maxillary major connector in the form of a palatal linguo-plate with provisions for attaching the full-coverage resin denture base. B, Completed removable partial denture with resin base. The palatal linguo-plate is supported by rests occupying lingual rest seats prepared in cast restorations on canines. This type of removable partial denture is particularly applicable when (1) residual ridges have undergone extreme vertical resorption, and (2) terminal abutments have suffered some bone loss and splinting cannot be accomplished.

**Step 2: Outline of nonbearing areas:** The nonbearing areas are the lingual gingival tissue within 5 to 6 mm of the remaining teeth, hard areas of the medial palatal raphe (including tori), and palatal tissue posterior to the vibrating line (see [Figure 5-24, C](#)).

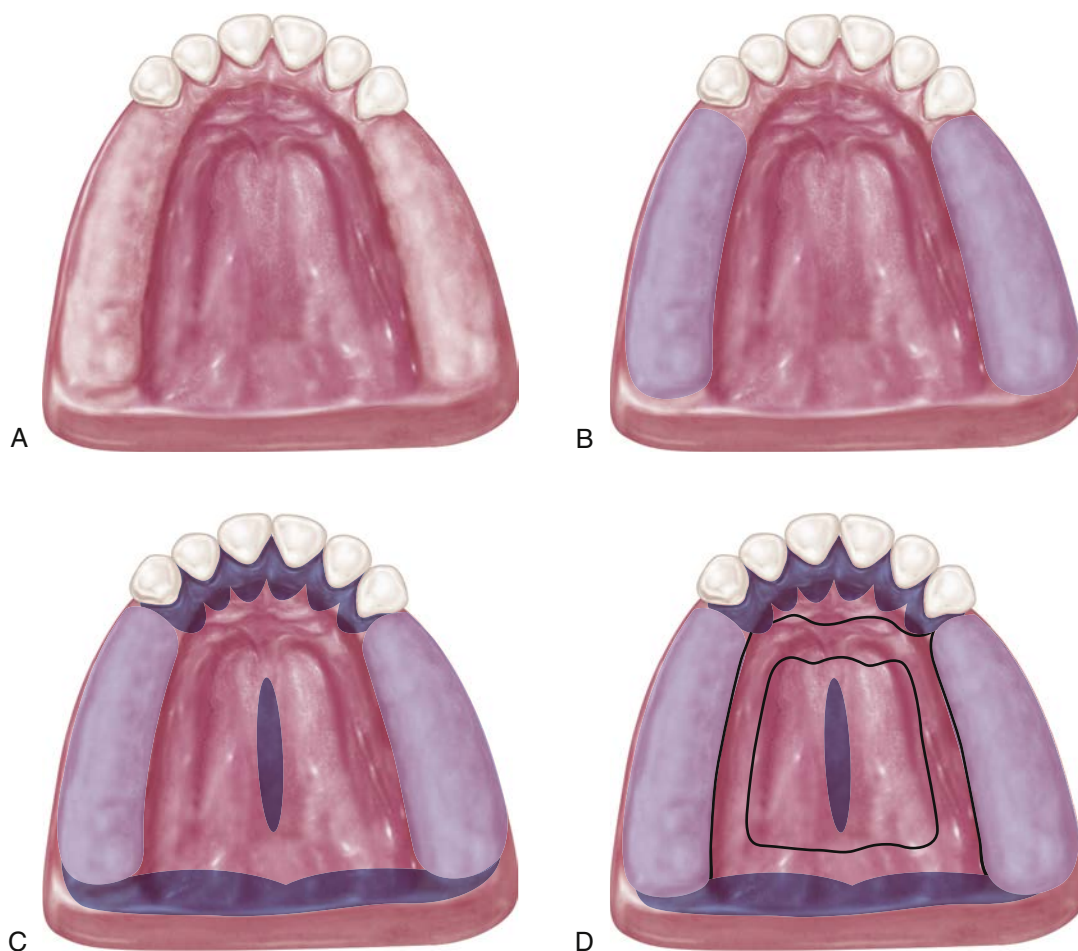
**Step 3: Outline of connector areas:** Steps 1 and 2, when completed, provide an outline or designate areas that are available to place components of major connectors (see [Figure 5-24, C](#)).

**Step 4: Selection of connector type:** Selection of the type of connector(s) is based on four factors: (1) mouth comfort, (2) rigidity, (3) location of denture bases, and (4) indirect retention. Connectors should be of minimum bulk and should be positioned so that interference with the tongue during speech and mastication is not encountered. Connectors must have a maximum of rigidity to distribute stress bilaterally. The double-strap type of major connector provides the maximum rigidity without bulk and total tissue coverage. In many

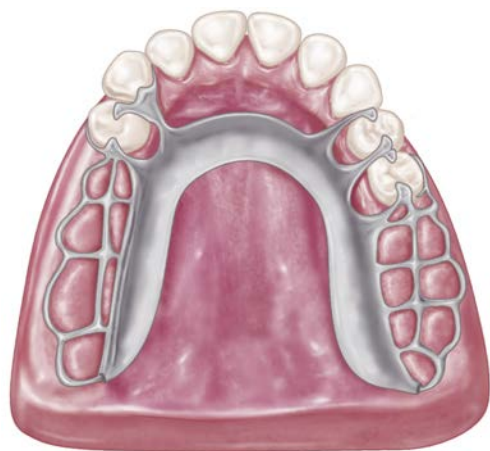instances, the choice of a strap type of major connector is limited by the location of the edentulous ridge areas. When edentulous areas are located anteriorly, the use of only a posterior strap is not recommended. By the same token, when only posterior edentulous areas are present, the use of only an anterior strap is not recommended. The need for indirect retention influences the outline of the major connector. Provision must be made in the major connector so that indirect retainers may be attached.

**Step 5: Unification:** After selection of the type of major connector based on considerations in Step 4, the denture base areas and connectors are joined (see [Figure 5-24, D](#)).

Indications for the use of complete palatal coverage have been previously discussed in this chapter. Although many variations in palatal major connectors have been noted, a thorough comprehension of all factors that influence their design will lead to the best design for each patient.



**FIGURE 5-24** **A**, Diagnostic cast of partially edentulous maxillary arch. **B**, The palatal extent of the denture base areas are located 2 mm from the palatal surface of the posterior teeth. **C**, Nonbearing areas outlined in black, which include lingual soft tissue within 5 to 6 mm of teeth, an unyielding median palatal raphe area, and the soft palate. The space bounded by bearing and nonbearing area outlines is available for placement of the major connector. **D**, The major connector selected will be rigid and noninterfering with the tongue and will cover a minimum of the palate.



**FIGURE 5-25** U-shaped palatal connector is probably the least rigid type of maxillary major connector and should be used only when a large inoperable palatal torus prevents the use of palatal coverage or combination anterior-posterior palatal strap-type designed framework.

### U-Shaped Palatal Connector

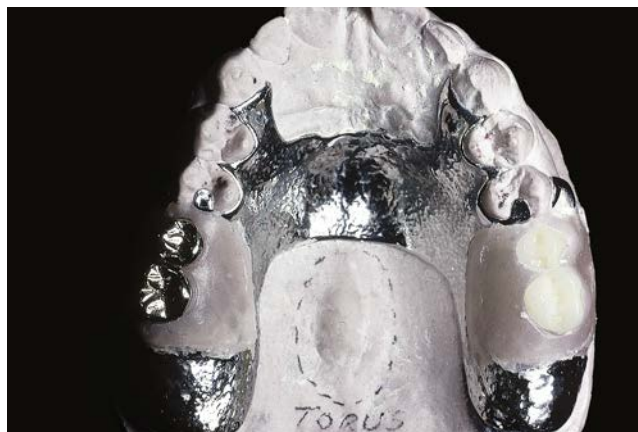
From both the patient's standpoint and a mechanical standpoint, the U-shaped palatal connector is the least desirable of maxillary major connectors. It should never be used arbitrarily. When a large inoperable palatal torus exists and occasionally when several anterior teeth are to be replaced, the U-shaped palatal connector may have to be used (Figure 5-25). In most instances, however, other designs will serve more effectively.

The following are the principal objections to use of the U-shaped connector:

1. Its lack of rigidity (compared with other designs) can allow lateral flexure under occlusal forces, which may induce torque or direct lateral force to abutment teeth.
2. The design fails to provide good support characteristics and may permit impingement of underlying tissue when subjected to occlusal loading.
3. Bulk to enhance rigidity results in increased thickness in areas that are a hindrance to the tongue.

Many maxillary partial dentures have failed for no other reason than the flexibility of a U-shaped major connector (Figure 5-26). To be rigid, the U-shaped palatal connector must have bulk where the tongue needs freedom the most—the rugae area. Without sufficient bulk, the U-shaped design leads to increased flexibility and movement at the open ends. In distal extension partial dentures, when tooth support posterior to the edentulous area is nonexistent, movement is particularly noticeable and is traumatic to the residual ridge. No matter how well the extension base is supported or how harmonious the occlusion, without a rigid major connector the residual ridge suffers.

The wider the coverage of a U-shaped major connector, the more it resembles a palatal plate-type connector with its several advantages. But when used as a narrow U design,



**FIGURE 5-26** Removable partial denture design that uses an objectionable U-shaped palatal major connector. Such a connector lacks necessary rigidity, places bulk where it is most objectionable to the patient, and impinges on gingival tissue lingual to remaining teeth.

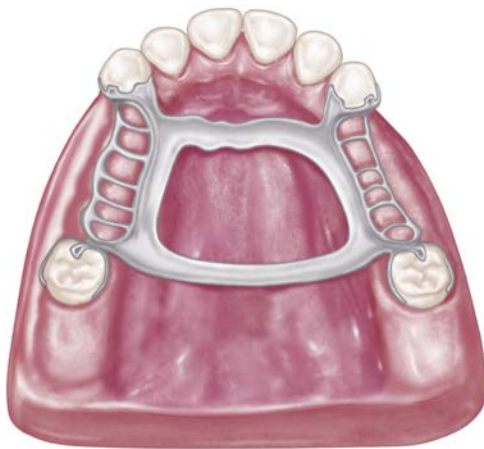the necessary rigidity is usually lacking. A U-shaped connector may be made more rigid with multiple tooth support through definite rests. A common error in the design of a U-shaped connector, however, is its proximity to, or actual contact with, gingival tissue. The principle that the borders of major connectors should be supported by rests in prepared rest seats or should be located well away from gingival tissue has been stated previously. Most U-shaped connectors fail to do either, with resulting gingival irritation and periodontal damage to the tissue adjacent to remaining teeth.

### Single Palatal Bar

To differentiate between a palatal bar and a palatal strap, a palatal connector component less than 8 mm in width is referred to as a *bar* in this textbook. The single palatal bar is perhaps the most widely used and yet the least logical of all palatal major connectors. It is difficult to say whether the bar or the U-shaped palatal connector is the more objectionable of palatal connectors.

For a single palatal bar to have the necessary rigidity for cross-arch distribution of stress, it must have concentrated bulk, which, unfortunately, is all too often ignored. For a single palatal bar to be effective, it must be rigid enough to provide support and cross-arch stabilization and must be centrally located between the halves of the denture. Mechanically, this practice may be sound enough. However, from the standpoint of patient comfort and alteration of palatal contours, it is highly objectionable.

A partial denture made with a single palatal bar is often too thin and flexible or too bulky and objectionable to the patient's tongue. The decision to use a single palatal bar instead of a strap should be based on the size of the denture-bearing areas that are connected and on whether



**FIGURE 5-27** Combination anterior-posterior palatal bar. To be sufficiently rigid to provide required support and stability, these major connectors must be excessively bulky. Because of its bulk and location, the anterior bar often interferes with the tongue.

a single connector located between them would be rigid without objectionable bulk.

### Combination Anterior and Posterior Palatal Bar-Type Connectors

Structurally, this combination of major connectors exhibits many of the same disadvantages as the single palatal bar (Figure 5-27). To be sufficiently rigid and to provide needed support and stability, these connectors could be too bulky and could interfere with tongue function.

### Beading of the Maxillary Cast

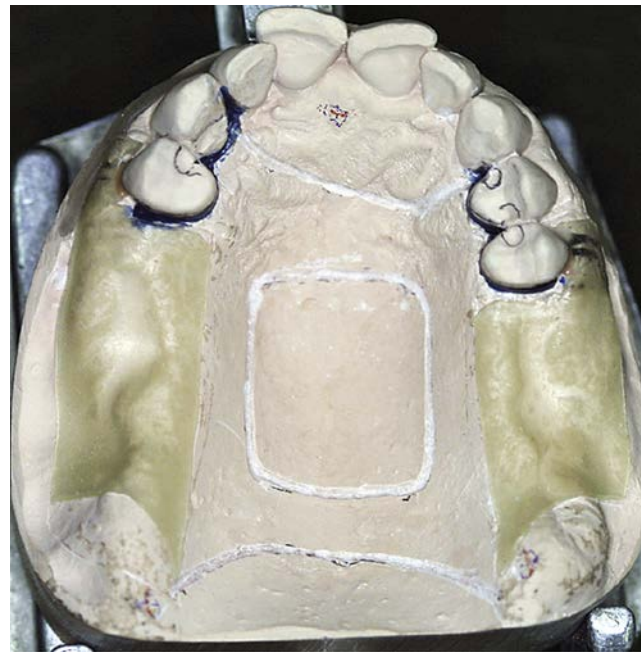*Beading* is a term used to denote the scribing of a shallow groove on the maxillary master cast outlining the palatal major connector exclusive of rugae areas (Figure 5-28). The purposes of beading are as follows:

1. To transfer the major connector design to the investment cast (Figure 5-29)
2. To provide a visible finishing line for the casting (Figure 5-30)
3. To ensure intimate tissue contact of the major connector with selected palatal tissue

Beading is readily accomplished by using an appropriate instrument, such as a cleoid carver. Care must be exercised to create a groove no larger than 0.5 mm in width or depth (Figure 5-31).

## MINOR CONNECTORS

Minor connectors are those components that serve as the connecting link between the major connector or the base of a removable partial denture and the other components of the prosthesis, such as the clasp assembly, indirect retainers, occlusal rests, or cingulum rests. In many instances, a minor



**FIGURE 5-28** Framework design on master cast before preparation for duplication in refractory investment. A shallow groove (0.5 mm) has been scribed on the outline of anterior and posterior borders of the major connector. The anterior outline follows the valleys of rugae. Beading is readily accomplished with a cleoid carver. A slightly rounded groove is preferred to a V-shaped groove.

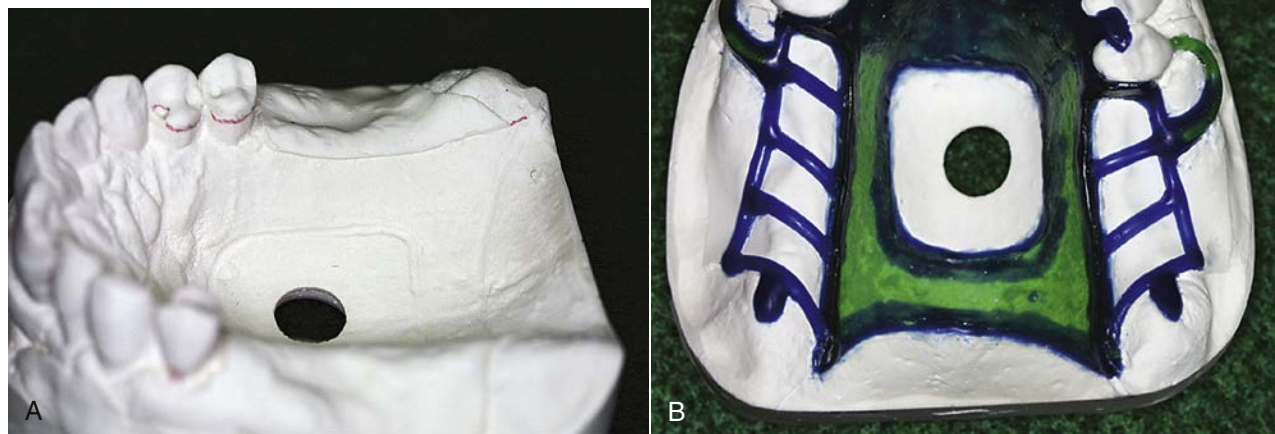
connector may be continuous with some other part of the denture. For example, an occlusal rest at one end of a linguoplate is actually the terminus of a minor connector, even though that minor connector is continuous with the linguoplate. Similarly the portion of a partial denture framework that supports the clasp and the occlusal rest is a minor connector, which joins the major connector with the clasp proper.

Those portions of a removable partial denture framework that retain the denture bases are also minor connectors. When dental implants are placed, modifications can be required in the denture base retaining minor connector and are dependent on how the implants will be engaged. Implants placed anteriorly to enhance retention by removing the need for a visible clasp must take into account retentive device bulk and connection requirements for joining to the prosthesis (i.e., direct to the metallic frame or via embedding within the acrylic resin denture base). Modifications required for implants placed more distal for purposes of support typically require designing space for embedding an attachment housing within the denture base (Figure 5-32).

### Functions

In addition to joining denture parts, the minor connector serves two other purposes:

1. Transfers functional stress to the abutment teeth: This is a prosthesis-to-abutment function of the minor connector. Occlusal forces applied to the artificial teeth are



**FIGURE 5-29** **A**, Refractory cast. Note the definitive outline of the major connector indicated by beading lines that were transferred in duplicating the master cast. **B**, The wax pattern for the major connector is accurately executed by following the beading lines. The major connector is confined to previously scribed beading.



**FIGURE 5-30** Cast and framework showing metal margin produced by the 0.5-mm beading line scribed on the cast. Such a margin is easily finished in the lab and provides intimate tissue contact, preventing food from easily dislodging the prosthesis. Care should be exercised in adapting such a beaded margin to non-displaceable tissue, such as the median palatal raphe.

transmitted through the base to the underlying ridge tissue if that base is primarily tissue supported. Occlusal forces applied to the artificial teeth are also transferred to abutment teeth through occlusal rests. The minor connectors arising from a rigid major connector make possible this transfer of functional stress throughout the dental arch.

2. Transfers the effects of the retainers, rests, and stabilizing components throughout the prosthesis: This is an abutment-to-prosthesis function of the minor connector. Thus forces applied on one portion of the denture may be resisted by other components placed elsewhere in the

arch for that purpose. A stabilizing component on one side of the arch may be placed to resist horizontal forces that originate on the opposite side. This is possible only because of the transferring effect of the minor connector, which supports that stabilizing component, and the rigidity of the major connector.

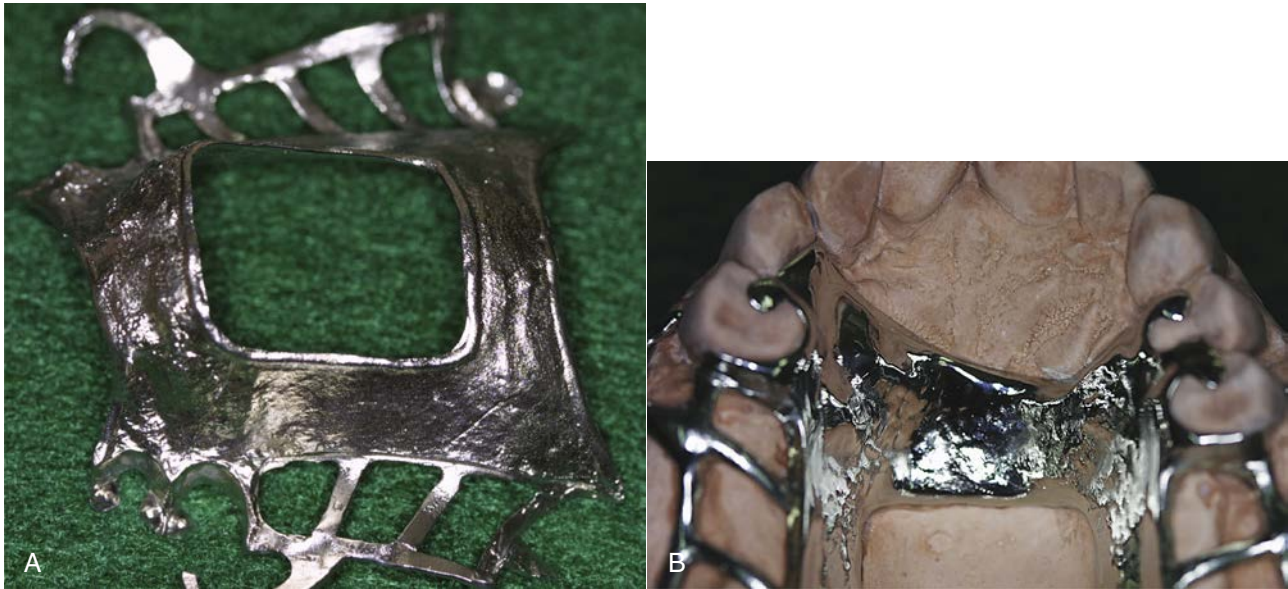
### Form and Location

Like the major connector, the minor connector must have sufficient bulk to be rigid; otherwise the transfer of functional stresses to the supporting teeth and tissue will not be effective. At the same time, the bulk of the minor connector should not be objectionable.

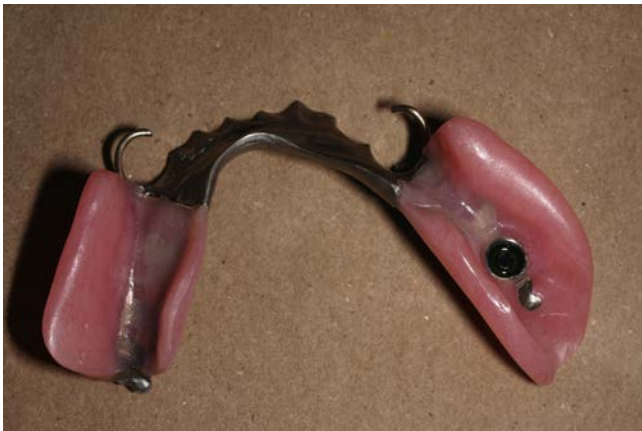A minor connector that contacts the axial surface of an abutment should not be located on a convex surface. Instead it should be located in an embrasure ([Figure 5-33](#)), where it will be least noticeable to the tongue. It should conform to the interdental embrasure, passing vertically from the major connector so that the gingival crossing is abrupt and covers as little of the gingival tissue as possible. It should be thickest toward the lingual surface, tapering toward the contact area ([Figure 5-34](#)).

The deepest part of the interdental embrasure should have been blocked out to avoid interference during placement and removal, and to avoid any wedging effect on the contacted teeth.

A modification of the conventional removable partial denture minor connector has been proposed. This application was suggested to be limited to the maxillary arch, with the minor connector located in the center of the lingual surface of the maxillary abutment tooth.



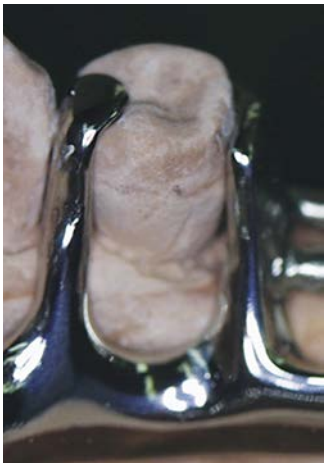**FIGURE 5-31** A, Tissue side of casting. Note slightly elevated ridges outlining anterior, posterior, and midpalatal opening regions of this anterior-posterior palatal strap major connector. B, Casting finished to a demarcated outline and seated on the master cast showing intimate adaptation.



**FIGURE 5-32** The Locator attachment in the posterior aspect of the distal extension base of the removable partial denture provides retention for the distal extension.

It is suggested that this modification reduces the amount of gingival tissue coverage, provides enhanced guidance for the partial denture during insertion and removal, and increases stabilization against horizontal and rotational forces. However, because of its location, such a design variation could encroach on the tongue space and create a greater potential space for food entrapment. The proposed variation should be used with careful application.

When a minor connector contacts tooth surfaces on either side of the embrasure in which it lies, it should be tapered to the teeth. This avoids sharp angles, which could hinder tongue movement, and eliminates spaces that could trap food (Figure 5-35).



**FIGURE 5-33** In an embrasure space, the minor connector is tapered to the tooth to avoid bulk and to accommodate the tongue.

It is a minor connector that contacts the guiding plane surfaces of the abutment teeth, whether as a connected part of a direct retainer assembly or as a separate entity (see Figure 5-34). Here the minor connector must be wide enough that the guiding plane can be used to fullest advantage. When it gives rise to a clasp arm, the connector should be tapered to the tooth below the origin of the clasp. If no clasp arm is formed (as when a bar clasp arm originates elsewhere), the connector should be tapered to a knife-edge the full length of its buccal aspect.

When an artificial tooth will be placed against a proximal minor connector, the minor connector's greatest bulk should be toward the lingual aspect of the abutment tooth.

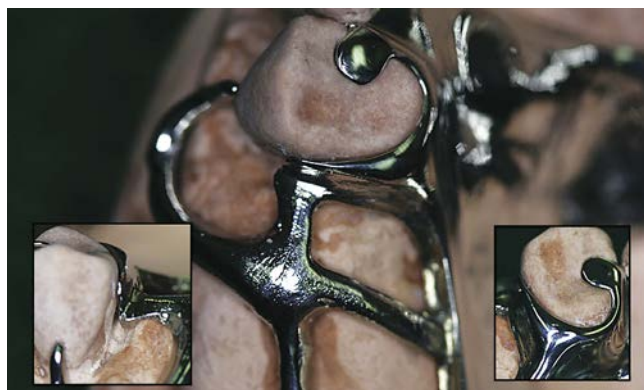
This way sufficient bulk is ensured with the least interference with placement of the artificial tooth. Ideally the artificial tooth should contact the abutment tooth with only a thin layer of metal intervening buccally. Lingually the bulk of the minor connector should lie in the interdental embrasure—the same as between two natural teeth.

As was stated previously, those portions of a denture framework by which acrylic-resin denture bases are attached are minor connectors. This type of minor connector should be so designed that it will be completely embedded within the denture base.

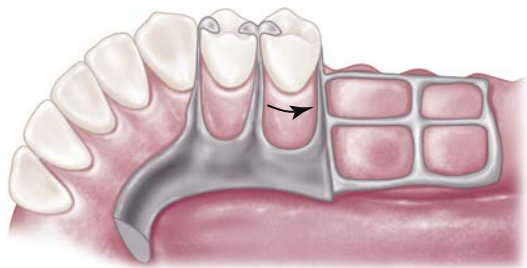
The junctions of these mandibular minor connectors with the major connectors should be strong butt-type joints but without appreciable bulk (see Figure 5-35). Angles formed at the junctions of the connectors should not be

greater than 90 degrees, thus ensuring the most advantageous and the strongest mechanical connection between the acrylic-resin denture base and the major connector.

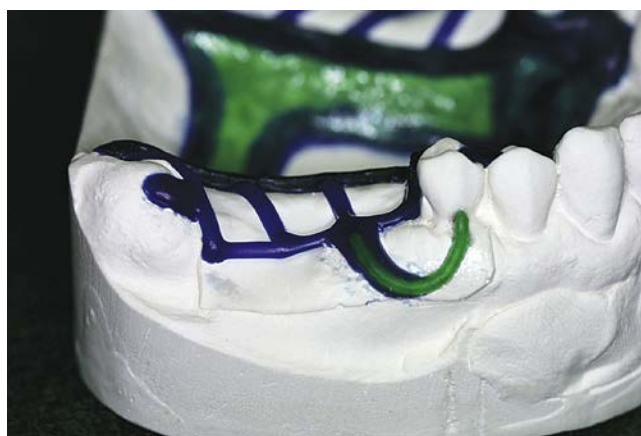An open latticework or ladder type of design is preferable and is conveniently made by using preformed 12-gauge half-round and 18-gauge round wax strips. The minor connector for the mandibular distal extension base should extend posteriorly about two-thirds the length of the edentulous ridge and should have elements on both lingual and buccal surfaces. Such an arrangement not only will add strength to the denture base but may minimize distortion of the cured base from its inherent strains caused by processing. The minor connector must be planned with care so that it will not interfere with the arrangement of artificial teeth (Figure 5-36).



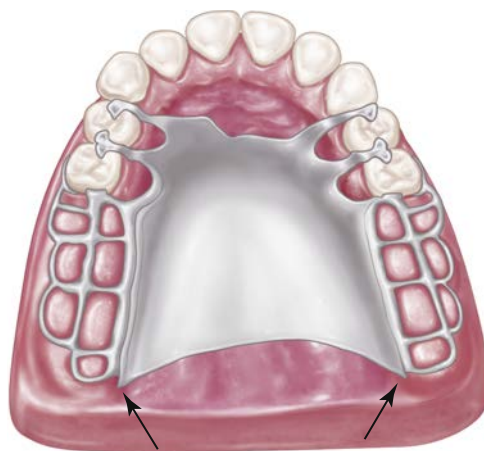**FIGURE 5-34** The minor connector that contacts the guiding plane is part of a clasp assembly. It can be separate from the other parts, or, as in this case, it can be connected to the lingual stabilizing portion of the clasp assembly. The proximal plate minor connector contact is about one-half the distance between tips of adjacent buccal and lingual cusps of the abutment tooth, and it extends gingivally, contacting an area of the abutment from the marginal ridge to two-thirds the length of the enamel crown. Viewed from above, it is triangular, the apex of the triangle being located buccally and the base of the triangle being located lingually. Less interference with the arrangement of the adjacent artificial tooth is encountered with minor connectors so shaped.



**FIGURE 5-35** Finishing line at the junction of the ladderlike minor connector and the major connector blends smoothly into the minor connector contacting the distal guiding plane on the second premolar. The framework is feathered toward tissue anterior to the finishing line to avoid as much bulk in this area as possible without compromising the strength of the butt-type joint.



**FIGURE 5-36** The minor connector for attaching the resin denture base should be designed so that denture tooth placement is not compromised. The minor connector design should not include a main lattice strut at the ridge crest or in a desired tooth location.

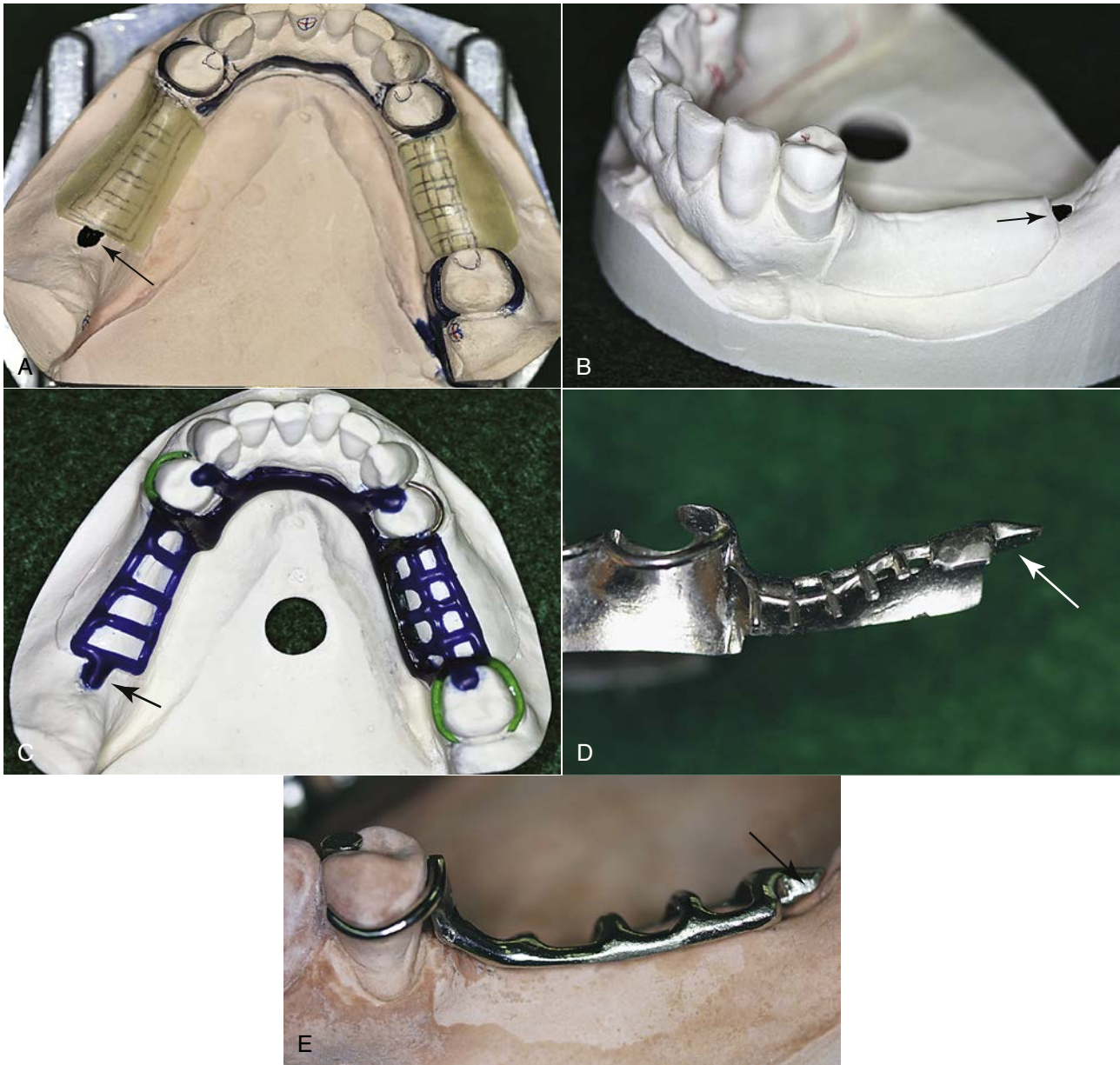


**FIGURE 5-37** Extension of the finishing line to the area of the pterygomaxillary notch provides a butt-type joint for attachment of the border portion of the resin base through the pterygomaxillary notch (arrows).

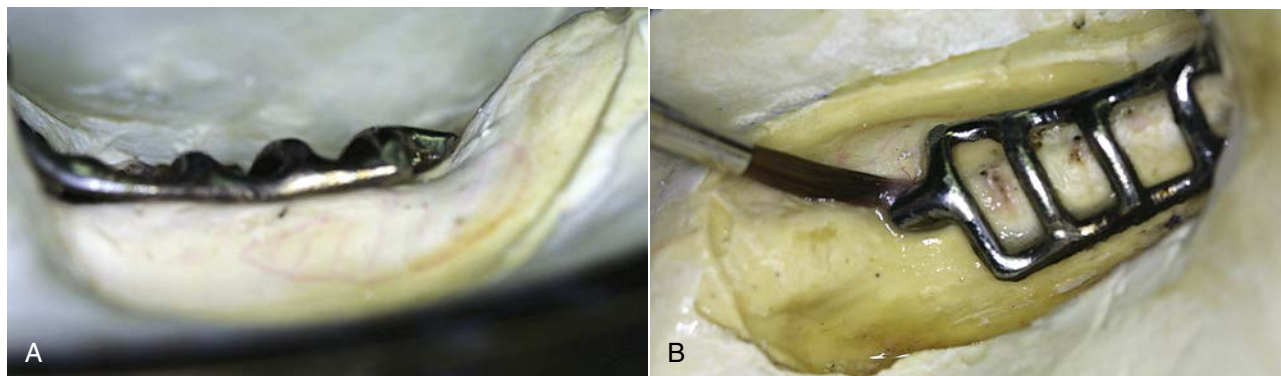
A means to attach acrylic-resin individualized trays to the mandibular framework when a corrected impression is planned must be arranged when the framework pattern is being developed. Three nailhead minor connectors fabricated as part of the denture base minor connector serve this purpose well. Unless some similar arrangement is made, the resin trays may become detached or loosened during impression-making procedures. Minor connectors for maxillary distal extension denture bases should extend the entire length of the residual ridge and should be of a ladderlike and loop design (Figure 5-37).

Tissue Stops

Tissue stops are integral parts of minor connectors designed for retention of acrylic-resin bases. They provide stability to the framework during the stages of transfer and processing. They are particularly useful in preventing distortion of the framework during acrylic-resin processing procedures. Tissue stops can engage buccal and lingual slopes of the residual ridge for stability (Figure 5-38).  
Altered cast impression procedures often necessitate that tissue stops be augmented subsequent to



**FIGURE 5-38** A, Arrow points to location of the tissue stop. B, Master cast partially prepared for duplication in refractory investment. Posterior to relief wax, at the distal of the residual ridge (arrow), a tissue stop will be waxed. C, Wax tissue stop placed distal to relief (arrow). After casting, this results in tissue stop contact of the framework. D, Tissue stop seen from labial position. E, Framework on cast shows tissue contact posterior to the minor connector with planned relief. Arrow points to the created tissue stop.



**FIGURE 5-39** **A**, Lower half of the flask in which the distal extension denture was invested. Note that the terminal portion of the minor connector (original tissue stop) is elevated from the residual ridge. The framework was developed on cast, with the residual ridge recorded in its anatomic form. The residual ridge was later recorded in its functional form by a corrected impression, thus the elevated tissue stop. **B**, Autopolymerizing resin is painted on between the tissue stop and the ridge to maintain the position of the minor connector during packing and processing procedures for a resin denture base.

the development of the altered cast. This can be readily accomplished with the addition of autopolymerizing acrylic resin (Figure 5-39).

Another integral part of the minor connector designed to retain the acrylic-resin denture base is similar to a tissue stop but serves a different purpose. It is located distal to the terminal abutment and is a continuation of the minor connector contacting the guiding plane. Its purpose is to establish a definitive finishing index tissue stop for the acrylic-resin base after processing (Figure 5-40).

### FINISHING LINES

The finishing line junction with the major connector should take the form of an angle not greater than 90 degrees, therefore being somewhat undercut (Figure 5-41). Of course the medial extent of the minor connector depends on the lateral extent of the major palatal connector. Too little attention is given to this finishing line location in many instances. If the finishing line is located too far medially, the natural contour of the palate will be altered by the thickness of the junction and the acrylic resin supporting the artificial teeth (Figure 5-42). If, on the other hand, the finishing line is located too far buccally, it will be most difficult to create a natural contour of the acrylic resin on the lingual surface of the artificial teeth. The location of the finishing line at the junction of the major and minor connectors should be based on restoration of the natural palatal shape, with consideration given to the location of the replacement teeth.

Equal consideration must be given to the junction of minor connectors and bar-type direct retainer arms. These junctions are 90-degree butt-type joints and should follow the guidelines for base contour and clasp length.

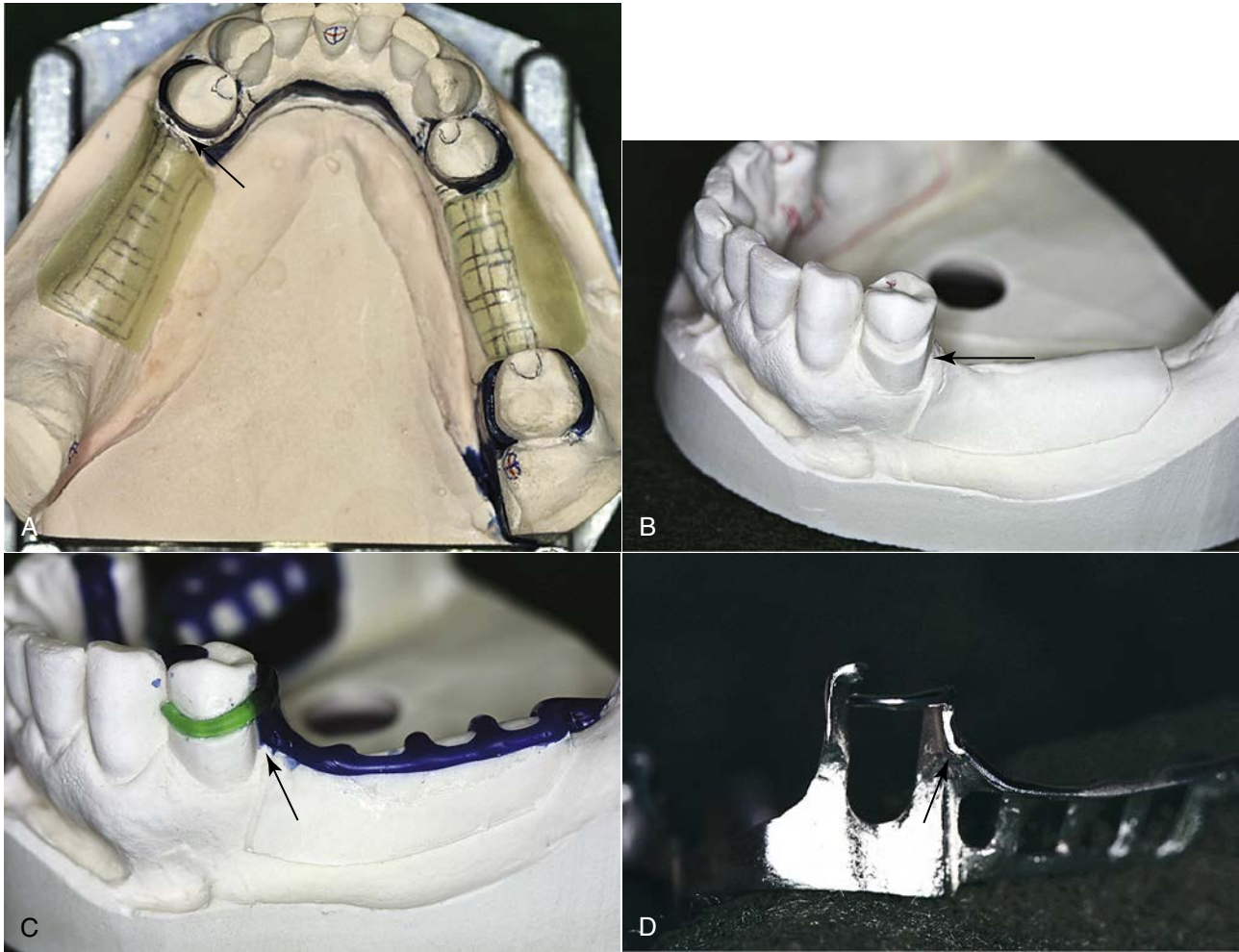
### REACTION OF TISSUE TO METALLIC COVERAGE

The reaction of tissue to coverage by the metallic components of a removable partial denture has been the subject of significant controversy, particularly in regions of marginal gingiva and broad areas of tissue contact. These tissue reactions can result from pressure caused by lack of support, lack of adequate hygiene measures, and prolonged contact through continual use of a prosthesis.

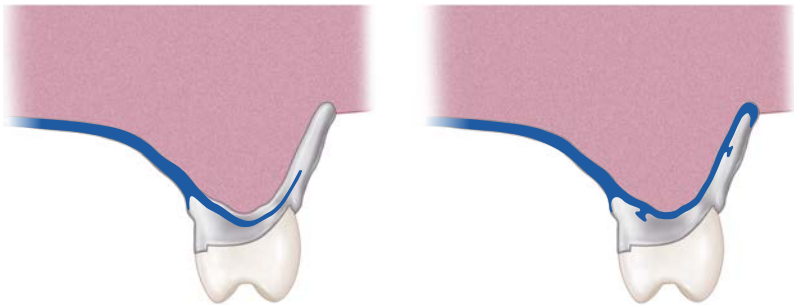
Pressure occurs at regions where relief over gingival crossings and other areas of contact with tissue that are incapable of supporting the prosthesis is inadequate. Impingement will likewise occur if the denture settles because of loss of tooth and/or tissue support. This may be caused by failure of the rest areas resulting from improper design, caries involvement, fracture of the rest itself, or intrusion of abutment teeth under occlusal loading. It is important to maintain adequate relief and support from both teeth and tissue. Settling of the denture caused by loss of tissue support may also produce pressure elsewhere in the arch, such as beneath major connectors. Settling of the prosthesis must be prevented or corrected if it has occurred. Excessive pressure must be avoided whenever oral tissue must be covered or crossed by elements of the partial denture.

Lack of adequate hygiene measures can result in tissue reactions caused by an accumulation of food debris and bacteria. Coverage of oral tissue with partial dentures that are not kept clean irritates those tissues because of an accumulation of irritating factors. This has led to misinterpretation of the effects of tissue coverage by prosthetic restorations. An additional hygiene concern is related to the problem of maintaining cleanliness of the tissue surface of the prosthesis.

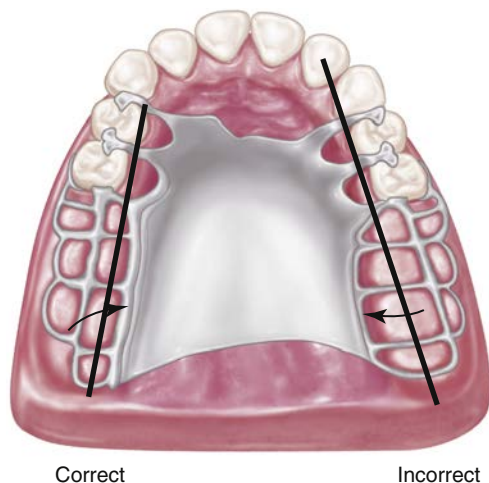
The first two causes of untoward tissue reaction can be accentuated the longer a prosthesis is worn. It is apparent that mucous membranes cannot tolerate this constant contact with a prosthesis without resultant inflammation and breakdown of the epithelial barrier. Some patients become so accustomed



**FIGURE 5-40** Finishing index tissue stop. **A**, Designed to facilitate finishing of the denture base resin at the region of the terminal abutment. Note the space at the anterior region of wax relief. Framework will be waxed to fill this space and provide positive tissue contact. **B**, Refractory cast shows space distal to the abutment. **C**, Wax pattern filling space for future tissue index contact. **D**, Framework index tissue stop anterior to relief beneath the minor connector of the distal extension base and posterior to the primary abutment.



**FIGURE 5-41** Frontal sections through lingual finishing lines of palatal major connectors. The *right image* is through the full cast metal base major connector; the *left image* is through the resin denture base. In both situations, the location of finishing lines minimizes the bulk of resin attaching the artificial teeth. Palatal contours are restored, enhancing speech and contributing to a natural feeling for the patient.



**FIGURE 5-42** Junction of the major connector and the minor connector at palatal finishing lines should be located 2 mm medial from an imaginary line that would contact the lingual surfaces of missing posterior teeth. The finish line on the right is too far toward midline of the palate. The natural contours of the palate will be altered.

to wearing a removable restoration that they neglect to remove it often enough to give the tissue any respite from constant contact. This is frequently true when anterior teeth are replaced by the partial denture and the individual does not allow the prosthesis to be out of the mouth at any time except in the privacy of the bathroom during toothbrushing. Living tissues should not be covered all the time, or changes in those tissues will occur. Partial dentures should be removed for several hours each day so that the effects of tissue contact can subside and the tissue can return to a normal state.

Clinical experience with the use of linguoplates and complete metallic palatal coverage has shown conclusively that when factors of pressure, cleanliness, and time are controlled, tissue coverage is not in itself detrimental to the health of oral tissue.

## MAJOR CONNECTORS IN REVIEW

### MANDIBULAR LINGUAL BAR

**Indications for Use:** The lingual bar should be used for mandibular removable partial dentures when sufficient space exists between the slightly elevated alveolar lingual sulcus and the lingual gingival tissue.

**Characteristics and Location:** (1) Half-pear shaped with bulkiest portion inferiorly located. (2) Superior border tapered to soft tissue. (3) Superior border located at least 4 mm inferior to gingival margins and farther if possible. (4) Inferior border located at the ascertained height of the alveolar lingual sulcus when the patient's tongue is slightly elevated.

**Blockout and Relief of Master Cast:** (1) All tissue undercuts parallel to the path of placement. (2) An additional

thickness of 32-gauge sheet wax when the lingual surface of the alveolar ridge is undercut or parallel to the path of placement (see Figures 11-23 and 11-24). (3) No relief is necessary when the lingual surface of the alveolar ridge slopes inferiorly and posteriorly. (4) One thickness of base-plate wax over basal seat areas (to elevate minor connectors for attaching acrylic-resin denture bases).

**Waxing Specifications:** (1) Six-gauge, half-pear-shaped wax form reinforced by 22- to 24-gauge sheet wax or similar plastic pattern adapted to the design width. (2) Long bar requires more bulk than short bar; however, cross-sectional shape is unchanged.

**Finishing Lines:** Butt-type joint(s) with minor connector(s) for retention of denture base(s).

### MANDIBULAR LINGUOPLATE

**Indications for Use:** (1) When the alveolar lingual sulcus so closely approximates the lingual gingival crevices that adequate width for a rigid lingual bar does not exist. (2) In those instances in which the residual ridges in Class I arch have undergone such vertical resorption that they will offer only minimal resistance to horizontal rotations of the denture through its bases. (3) For using periodontally weakened teeth in group function to furnish support to the prosthesis and to help resist horizontal (off-vertical) rotation of the distal extension type of denture. (4) When the future replacement of one or more incisor teeth will be facilitated by the addition of retention loops to an existing linguoplate.

**Characteristics and Location:** (1) Half-pear shaped with bulkiest portion inferiorly located. (2) Thin metal apron extending superiorly to contact cingula of anterior teeth and lingual surfaces of involved posterior teeth at their height of contour. (3) Apron extended interproximally to the height of contact points (i.e., closing interproximal spaces). (4) Scalloped contour of apron as dictated by interproximal blockout. (5) Superior border finished to continuous plane with contacted teeth. (6) Inferior border at the ascertained height of the alveolar lingual sulcus when the patient's tongue is slightly elevated.

**Blockout and Relief of Master Cast:** (1) All involved undercuts of contacted teeth parallel to the path of placement. (2) All involved gingival crevices. (3) Lingual surfaces of alveolar ridge and basal seat areas the same as for a lingual bar.

**Waxing Specifications:** (1) Inferior border: 6-gauge, half-pear-shaped wax form reinforced with 24-gauge sheet wax or similar plastic pattern. (2) Apron: 24-gauge sheet wax.

**Finishing Lines:** Butt-type joint(s) with minor connector(s) for retention of denture base(s).

### MANDIBULAR SUBLINGUAL BAR

**Indications for Use:** The sublingual bar should be used for mandibular removable partial dentures when the height of the floor of the mouth in relation to the free gingival margins will be less than 6 mm. It also may be indicated whenever it is desirable to keep the free gingival margins of the

remaining anterior teeth exposed and depth of the floor of the mouth is inadequate to place a lingual bar.

**Contraindications for Use:** Remaining natural anterior teeth severely tilted toward the lingual.

**Characteristics and Location:** The sublingual bar is essentially the same half-pear shape as a lingual bar, except that the bulkiest portion is located to the lingual and the tapered portion is toward the labial. The superior border of the bar should be at least 3 mm from the free gingival margin of the teeth. The inferior border is located at the height of the alveolar lingual sulcus when the patient's tongue is slightly elevated. This necessitates a functional impression of the lingual vestibule to accurately register the height of the vestibule.

**Blockout and Relief of Master Cast:** (1) All tissue undercuts parallel to path of placement. (2) An additional thickness of 32-gauge sheet wax when the lingual surface of the alveolar ridge is undercut or parallel to the path of placement. (3) One thickness of baseplate wax over basal seat areas (to elevate minor connectors for attaching acrylic-resin denture bases).

**Waxing Specifications:** (1) Six-gauge, half-pear-shaped wax form reinforced by 22- to 24-gauge sheet wax or similar plastic pattern adapted to design width. (2) Long bar bulkier than short bar; however, cross-sectional shape unchanged.

**Finishing Lines:** Butt-type joint(s) with minor connector(s) for retention of denture base(s).

**MANDIBULAR LINGUAL BAR WITH CONTINUOUS BAR (CINGULUM BAR)**

**Indications for Use:** (1) When a linguoplate is otherwise indicated but the axial alignment of anterior teeth is such that excessive blockout of interproximal undercuts would be required. (2) When wide diastemata exist between mandibular anterior teeth and a linguoplate would objectionably display metal in a frontal view.

**Characteristics and Location:** (1) Conventionally shaped and located same as lingual bar major connector component when possible. (2) Thin, narrow (3 mm) metal strap located on cingula of anterior teeth, scalloped to follow interproximal embrasures with inferior and superior borders tapered to tooth surfaces. (3) Originates bilaterally from incisal, lingual, or occlusal rests of adjacent principal abutments.

**Blockout and Relief of Master Cast:** (1) Lingual surfaces of alveolar ridge and basal seat areas same as for lingual bar. (2) No relief for continuous bar except blockout of interproximal spaces parallel to path of placement.

**Waxing Specifications:** (1) Lingual bar major connector component waxed and shaped same as lingual bar. (2) Continuous bar pattern formed by adapting two strips (3 mm wide) of 28-gauge sheet wax, one at a time, over the cingula and into interproximal embrasures.

**Finishing Lines:** Butt-type joint(s) with minor connector(s) for retention of denture base(s).

**MANDIBULAR CONTINUOUS BAR (CINGULUM BAR)**

**Indications for Use:** When a lingual plate or sublingual bar is otherwise indicated but the axial alignment of the anterior teeth is such that excessive blockout of interproximal undercuts would be required.

**Contraindications for Use:** (1) Anterior teeth severely tilted to the lingual. (2) When wide diastemata that exist between the mandibular anterior teeth and the cingulum bar would objectionably display metal in a frontal view.

**Characteristics and Location:** (1) Thin, narrow (3 mm) metal strap located on cingula of anterior teeth, scalloped to follow interproximal embrasures with inferior and superior borders tapered to tooth surfaces. (2) Originates bilaterally from incisal, lingual, or occlusal rests of adjacent principal abutments.

**Blockout and Relief of Master Cast:** No relief for cingulum bar except blockout of interproximal spaces parallel to the path of placement.

**Waxing Specifications:** Cingulum bar pattern formed by adapting two strips (3 mm wide) of 28-gauge sheet wax, one at a time, over the cingula and into interproximal embrasures.

**Finishing Lines:** Butt-type joint(s) with minor connector(s) for retention of denture base(s).

**MANDIBULAR LABIAL BAR**

**Indications for Use:** (1) When lingual inclinations of remaining mandibular premolar and incisor teeth cannot be corrected, preventing placement of a conventional lingual bar connector. (2) When severe lingual tori cannot be removed and prevent the use of a lingual bar or lingual plate major connector. (3) When severe and abrupt lingual tissue undercuts make it impractical to use a lingual bar or a lingual plate major connector.

**Characteristics and Location:** (1) Half-pear shaped with bulkiest portion inferiorly located on the labial and buccal aspects of the mandible. (2) Superior border tapered to soft tissue. (3) Superior border located at least 4 mm inferior to labial and buccal gingival margins and farther if possible. (4) Inferior border located in the labial-buccal vestibule at the juncture of attached (immobile) and unattached (mobile) mucosae.

**Blockout and Relief of Master Cast:** (1) All tissue undercuts parallel to path of placement, plus an additional thickness of 32-gauge sheet wax when the labial surface is undercut or parallel to the path of placement. (2) No relief necessary when the labial surface of the alveolar ridge slopes inferiorly to the labial or buccal. (3) Basal seat areas same as for lingual bar major connector.

**Waxing Specifications:** (1) Six-gauge, half-pear-shaped wax form reinforced with 22- to 24-gauge sheet wax or similar plastic pattern. (2) Long bar necessitates more bulk than short bar; however, cross-sectional shape unchanged. (3) Minor connectors joined with occlusal or other superior

components by a labial or buccal approach. (4) Minor connectors for base attachment joined by a labial or buccal approach.

**Finishing Lines:** Butt-type joint(s) with minor connector(s) for retention of denture base(s).

### SINGLE PALATAL STRAP-TYPE MAJOR CONNECTOR

**Indications for Use:** Bilateral edentulous spaces of short span in a tooth-supported restoration.

**Characteristics and Location:** (1) Anatomic replica form. (2) Anterior border follows the valleys between rugae as nearly as possible at right angles to median suture line. (3) Posterior border at right angle to median suture line. (4) Strap should be 8 mm wide or approximately as wide as the combined width of a maxillary premolar and first molar. (5) Confined within an area bounded by the four principal rests.

**Blockout and Relief of Master Cast:** (1) Usually none required except slight relief of elevated median palatal raphe or any exostosis crossed by the connector. (2) One thickness of baseplate wax over basal seat areas (to elevate minor connectors for attaching acrylic-resin denture bases).

**Beading:** See Figures 5-38 to 5-41.

**Waxing Specifications:** Anatomic replica pattern equivalent to 22- to 24-gauge wax, depending on arch width.

**Finishing Lines:** (1) Undercut and slightly elevated. (2) No farther than 2 mm medial from an imaginary line contacting lingual surfaces of principal abutments and teeth to be replaced. (3) Follow curvature of arch.

### SINGLE BROAD PALATAL MAJOR CONNECTOR

**Indications for Use:** (1) Class I partially edentulous arches with residual ridges that have undergone little vertical resorption and will lend excellent support. (2) V- or U-shaped palates. (3) Strong abutments (single or made so by splinting). (4) More teeth in arch than six remaining anterior teeth. (5) Direct retention not a problem. (6) No interfering tori.

**Characteristics and Location:** (1) Anatomic replica form. (2) Anterior border following valleys of rugae as near right angle to median suture line as possible and not extending anterior to occlusal rests or indirect retainers. (3) Posterior border located at junction of hard and soft palate but not extended onto soft palate; at right angle to the median suture line; extended to pterygomaxillary notches.

**Blockout and Relief of Master Cast:** (1) Usually none required except relief of elevated median palatal raphe or any small exostoses covered by the connector. (2) One thickness of baseplate wax over basal seat areas (to elevate minor connectors for attaching acrylic-resin denture bases).

**Beading:** See Figures 5-28 to 5-30.

**Waxing Specifications:** Anatomic replica pattern equivalent to 24-gauge sheet wax thickness.

**Finishing Lines:** (1) Provision for butt-type joint at pterygomaxillary notches. (2) Undercut and slightly elevated. (3) No farther than 2 mm medial from an imaginary line

contacting the lingual surfaces of the missing natural teeth. (4) Following curvature of arch.

### ANTERIOR-POSTERIOR STRAP-TYPE MAJOR CONNECTOR

**Indications for Use:** (1) Class I and II arches in which excellent abutment and residual ridge support exists, and direct retention can be made adequate without the need for indirect retention. (2) Long edentulous spans in Class II, modification 1 arches. (3) Class IV arches in which anterior teeth must be replaced with a removable partial denture. (4) Inoperable palatal tori that do not extend posteriorly to the junction of the hard and soft palates.

**Characteristics and Location:** (1) Parallelogram shaped and open in center portion. (2) Relatively broad (8 to 10 mm) anterior and posterior palatal straps. (3) Lateral palatal straps (7 to 9 mm) narrow and parallel to curve of arch; minimum of 6 mm from gingival crevices of remaining teeth. (4) Anterior palatal strap: Anterior border not placed farther anteriorly than anterior rests and never closer than 6 mm to lingual gingival crevices; follows the valleys of the rugae at right angles to the median palatal suture. Posterior border, if in rugae area, follows valleys of rugae at right angles to the median palatal suture. (5) Posterior palatal connector: Posterior border located at junction of hard and soft palates and at right angles to median palatal suture and extended to hamular notch area(s) on distal extension side(s). (6) Anatomic replica or matte surface.

**Blockout and Relief of Master Cast:** (1) Usually none required except slight relief of elevated median palatal raphe where anterior or posterior straps cross the palate. (2) One thickness of baseplate wax over basal seat areas (to elevate minor connectors for attaching acrylic-resin denture bases).

**Beading:** See Figures 5-28 and 5-29.

**Waxing Specifications:** (1) Anatomic replica patterns or matte surface forms of 22-gauge thickness. (2) Posterior palatal component: A strap of 22-gauge thickness, 8 to 10 mm wide (a half-oval form of approximately 6-gauge thickness and width) may also be used.

**Finishing Lines:** Same as for single broad palatal major connector.

### COMPLETE PALATAL COVERAGE MAJOR CONNECTOR

**Indications for Use:** (1) In most situations in which only some or all anterior teeth remain. (2) Class II arch with a large posterior modification space and some missing anterior teeth. (3) Class I arch with one to four premolars and some or all anterior teeth remaining, when abutment support is poor and cannot otherwise be enhanced; residual ridges have undergone extreme vertical resorption; direct retention is difficult to obtain. (4) In the absence of a pedunculated torus.

**Characteristics and Location:** (1) Anatomic replica form for full palatal metal casting supported anteriorly by positive

rest seats. (2) Palatal linguoplate supported anteriorly and designed for attachment of acrylic-resin extension posteriorly. (3) Contacts all or almost all of the teeth remaining in the arch. (4) Posterior border: Terminates at the junction of the hard and soft palates; extended to hamular notch area(s) on distal extension side(s); at a right angle to median suture line.

**Blockout and Relief of Master Cast:** (1) Usually none required except relief of elevated median palatal raphe or any small palatal exostosis. (2) One thickness of baseplate wax over basal seat areas (to elevate minor connectors for attaching acrylic-resin denture bases).

**Beading:** See [Figures 5-28 to 5-30](#).

**Waxing Specifications:** (1) Anatomic replica pattern equivalent to 22- to 24-gauge sheet wax thickness. (2) Acrylic-resin extension from linguoplate the same as for a complete denture.

**Finishing Lines:** As illustrated here and previously discussed.

### U-SHAPED PALATAL MAJOR CONNECTOR

This connector should be used only in those situations in which inoperable tori extend to the posterior limit of the hard palate.

The U-shaped palatal major connector is the least favorable design of all palatal major connectors because it lacks the rigidity of other types of connectors. When it must be used, indirect retainers must support any portion of the connector that extends anteriorly from the principal occlusal rests. Anterior border areas of this type of connector must be kept at least 6 mm away from adjacent teeth. If for any reason the anterior border must contact the remaining teeth, the connector must again be supported by rests placed in properly prepared rest seats. It should never be supported even temporarily by inclined lingual surfaces of anterior teeth.

Waxing specifications, finishing lines, and so forth, are the same as for full palatal castings or other previously discussed similar major connectors.

# CHAPTER

# 6

## Rests and Rest Seats

### CHAPTER OUTLINE

Role of Rests in Control of Prosthesis Movement  
 Form of the Occlusal Rest and Rest Seat  
 Extended Occlusal Rest  
 Interproximal Occlusal Rest Seats  
 Internal Occlusal Rests  
 Implants as a Rest  
 Support for Rests  
 Lingual Rests on Canines and Incisor Teeth  
 Incisal Rests and Rest Seats

Although the major connector joins all removable partial denture component parts, engaging the remaining teeth through appropriate use of rest seats and rests affords efficient resistance to functional chewing forces. The capacity for teeth to resist functional forces and remain stable over time is provided through their sophisticated support mechanisms. Studies have shown that displacement and recovery following loading are far better for natural teeth than for oral mucosa. Similarly the capacity of implants to resist the functional forces of chewing may exceed that of teeth.

Consequently, appropriate use of the teeth to help resist functional forces in removable prostheses is a critical strategy to control prosthesis movement and achieve functional stability. When situations of multiple missing teeth are seen in conjunction with less than ideal soft tissue support and opposing natural dentition, implant use should be strongly considered.

### ROLE OF RESTS IN CONTROL OF PROSTHESIS MOVEMENT

Appropriate use of teeth requires consideration as to how best to engage teeth for the supportive qualities they provide. Because the most effective resistance can be provided if the tooth is stressed along its long axis, the prosthesis framework should engage the tooth in a manner that encourages axial loading. The various forms of rests have as a main goal a form that allows for axial loading. It is important to realize that this goal can be achieved only through some form of tooth modification.

Vertical support must be provided for a removable partial denture. Any component of a partial denture on a tooth surface that provides vertical support is called a *rest* (Figure 6-1). Rests should always be located on properly prepared tooth surfaces. The prepared surface of an abutment to receive the rest is called the *rest seat*. Rests are designated by the surface of the tooth prepared to receive them (occlusal rest, lingual rest, and incisal rest). The topography of any

rest should generally restore the topography of the tooth that existed before the rest seat was prepared.

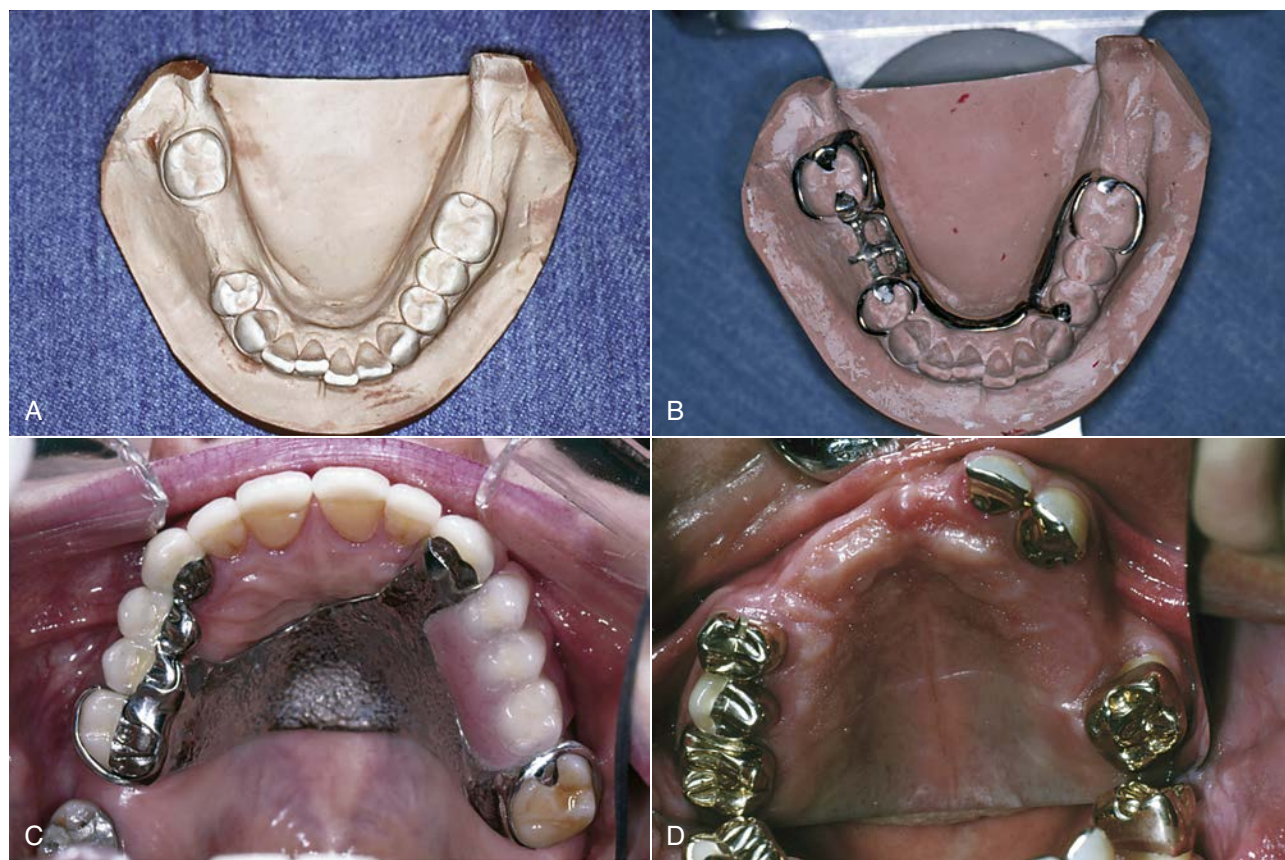
The primary purpose of the rest is to provide vertical support for the partial denture. In doing so, it also does the following:

1. Maintains components in their planned positions
2. Maintains established occlusal relationships by preventing settling of the denture
3. Prevents impingement of soft tissue
4. Directs and distributes occlusal loads to abutment teeth

Thus rests serve to support the position of a partial denture and to resist movement toward the tissue. They serve to transmit vertical forces to the abutment teeth and to direct those forces along the long axes of the teeth. In this respect, tooth-supported removable partial denture rests function in a manner similar to fixed abutment retainers. It is obvious that for this degree of stability to exist, the rests must be rigid and must receive positive support from the abutment teeth, which means that under occlusal loading, the rest and the tooth remain in stable contact and no independent movement or slippage occurs.

In a removable partial denture that has one or more distal extension bases, the denture becomes increasingly tissue supported as the distance from the abutment increases. Closer to the abutment, however, more of the occlusal load is transmitted to the abutment tooth by means of the rest. The load is thereby distributed between the abutment and the supporting residual ridge tissue.

When rests prevent movement of the denture in an apical direction, the position of the retentive portion of the clasp arms can be maintained in designated relation to the tooth undercuts. Although passive when it is in its terminal position, the retentive portion of the clasp arm should remain in contact with the tooth, ready to resist a vertical dislodging force. Then, when a dislodging force is applied, the clasp arm should immediately become actively engaged to resist vertical displacement. If settling of the denture results in clasp arms that stand away from the tooth, some vertical displacement is possible before the retainer can become functional. The rest serves to prevent such settling and thereby helps to maintain the vertical stability of the partial denture.



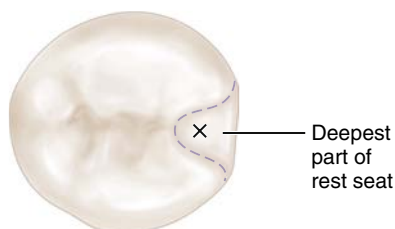
**FIGURE 6-1** A, Occlusal rest seats have been prepared on molar and premolar teeth to provide vertical support for the removable partial denture. B, Framework for tooth-supported removable partial denture. Rests on patient's right provide vertical support to the replacement dentition; rests on patient's left provide cross-arch support and stabilization. C, Tooth support for this prosthesis is provided by rests that occupy definite, prepared, rest seats on the canine and occlusal surfaces of selected posterior teeth. D, Kennedy Class III, modification 1, maxillary arch with rest seats prepared on the lingual surfaces of the canine and lateral incisor and on the occlusal surfaces of the premolar and molar.

The use of an implant as a rest can also be considered. In this application, the implant eliminates compression of supporting soft tissues, controls vertical movement of the denture base, eliminates or alters fulcrum lines, and serves to increase support and stability of the prosthesis.

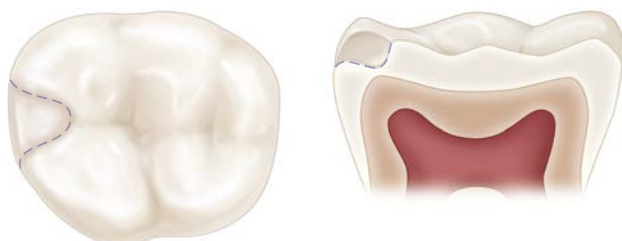
### FORM OF THE OCCLUSAL REST AND REST SEAT

The form of the occlusal rest seat should be designed and located with the following guidelines in mind:

1. The outline form of an occlusal rest seat should be a rounded triangular shape with the apex toward the center of the occlusal surface (Figure 6-2).
2. It should be as long as it is wide, and the base of the triangular shape (at the marginal ridge) should be at least 2.5 mm for both molars and premolars. Rest seats of smaller dimensions do not provide an adequate bulk of metal for rests, especially if the rest is contoured to restore the occlusal morphology of the abutment tooth.
3. The marginal ridge of the abutment tooth at the site of the rest seat must be lowered to permit a sufficient bulk of metal for strength and rigidity of the rest and the minor connector. This means that a reduction of the marginal ridge of approximately 1.5 mm is usually necessary.
4. The floor of the occlusal rest seat should be apical to the marginal ridge and the occlusal surface and should be concave, or spoon shaped (Figure 6-3). Caution should be exercised in preparing a rest seat to avoid creating sharp edges or line angles in the preparation.

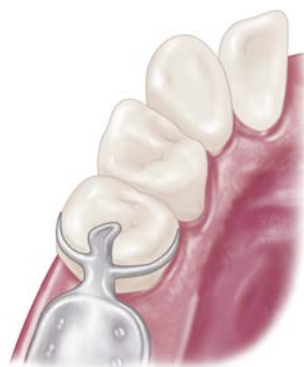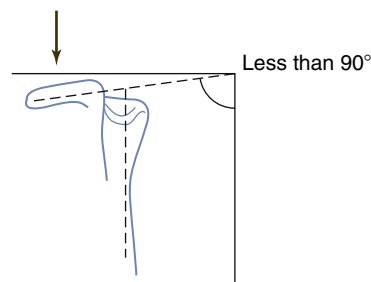


**FIGURE 6-2** The deepest part of an occlusal rest preparation should be inside the lowered marginal ridge at X. The marginal ridge is lowered to provide bulk and to accommodate the origin of the occlusal rest with the least occlusal interference.

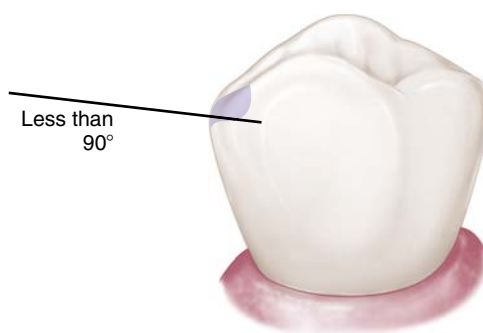


**FIGURE 6-3** Occlusal rest seat preparation on molar. The preparation is rounded, and the triangular concavity has smooth margins on the occlusal surface and a lowered, rounded marginal ridge.

5. The angle formed by the occlusal rest and the vertical minor connector from which it originates should be less than 90 degrees (Figures 6-4 and 6-5). Only in this way can the occlusal forces be directed along the long axis of the abutment tooth. An angle greater than 90 degrees fails to transmit occlusal forces along the supporting vertical axis of the abutment tooth. This also permits slippage of the prosthesis away from the abutment, which can result in orthodontic-like forces being applied to an inclined plane on the abutment, with possible tooth movement (Figure 6-6).

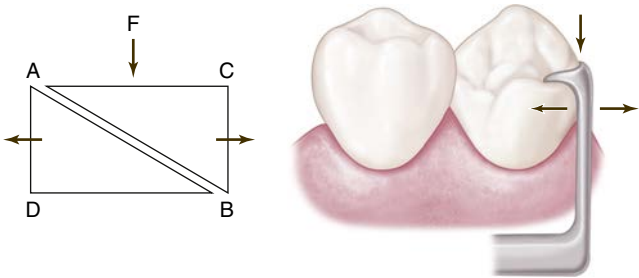


**FIGURE 6-4** The occlusal rest should be spoon shaped and slightly inclined apically from the marginal ridge. The rest should restore the occlusal morphology of the tooth that existed before preparation of the rest seat.

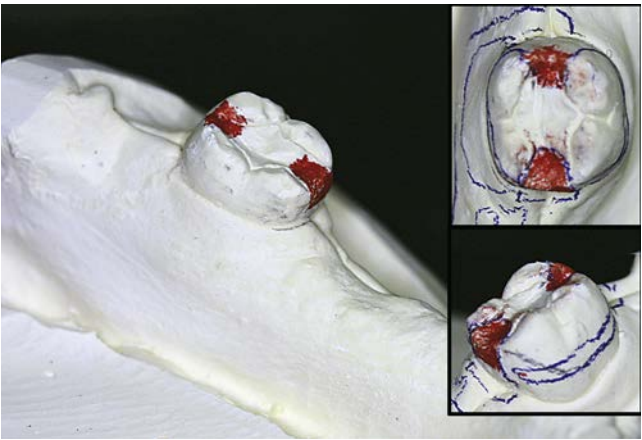


**FIGURE 6-5** The floor of the occlusal rest seat should be inclined apically from the lowered marginal ridge. Any angle less than 90 degrees is acceptable as long as the preparation of the proximal surface and lowering and rounding of the marginal ridge precede completion of the rest seat itself.

When an existing occlusal rest preparation is inclined apically toward the reduced marginal ridge and cannot be modified or deepened because of fear of perforation of the enamel or restoration, then a secondary occlusal rest must be employed to prevent slippage of the primary rest and orthodontic movement of the abutment tooth (Figure 6-7). Such a rest should pass over the lowered marginal ridge on the side of the tooth opposite the primary rest and should, if possible, be inclined slightly apically from the marginal ridge. However, two opposing occlusal rests on diverging tooth inclines will function to prevent unfavorable forces if all related connectors are sufficiently rigid. In any tooth-tissue-supported partial denture, the relation of the occlusal rest to the abutment should be that



**FIGURE 6-6** The result of force applied to an inclined plane when the floor of the occlusal rest preparation inclines apically toward the marginal ridge of the abutment tooth. F, Occlusal force applied to the abutment tooth. AB, Relationship of the occlusal rest to the abutment tooth when the angle is greater than 90 degrees. ABC, Removable partial denture framework. ABD, Abutment tooth.



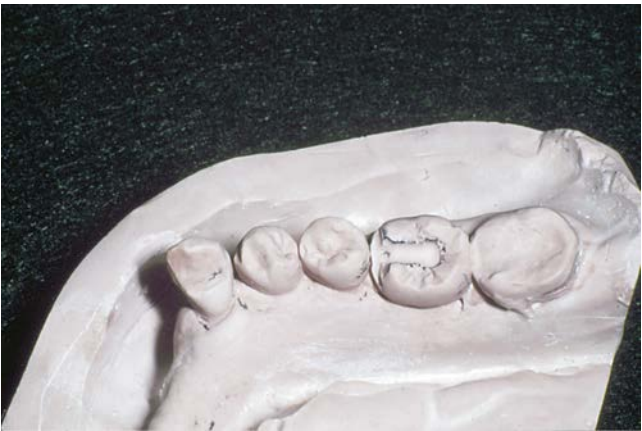**FIGURE 6-7** Diagnostic cast evaluation of mesially tipped molar abutment. Anterior tilt of molar precludes preparation of acceptable rest seat on the mesio-occlusal surface. The patient could not afford a crown to improve axial alignment or orthodontic treatment to upright the molar. Occlusal rests will be used on mesio-occlusal and disto-occlusal surfaces to support restoration and direct forces over the greatest root mass of the abutment. The proposed ring clasp design is outlined.

of a shallow ball-and-socket joint, to prevent a possible transfer of horizontal stresses to the abutment tooth. The occlusal rest should provide only occlusal support. Stabilization against horizontal movement of the prosthesis must be provided by other components of the partial denture rather than by any locking effect of the occlusal rest, which will cause the application of leverages to the abutment tooth.

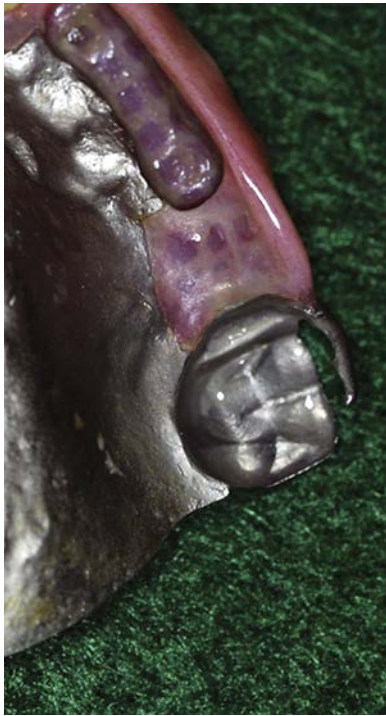**EXTENDED OCCLUSAL REST**

In Kennedy Class II, modification 1, and Kennedy Class III situations in which the most posterior abutment is a mesially tipped molar, an extended occlusal rest should be designed and prepared to minimize further tipping of the abutment and to ensure that the forces are directed down the long axis of the abutment. This rest should extend more than one-half the mesiodistal width of the tooth, should be approximately one-third the buccolingual width of the tooth, and should allow for a minimum of 1-mm thickness of the metal; the preparation should be rounded with no undercuts or sharp angles (Figure 6-8).

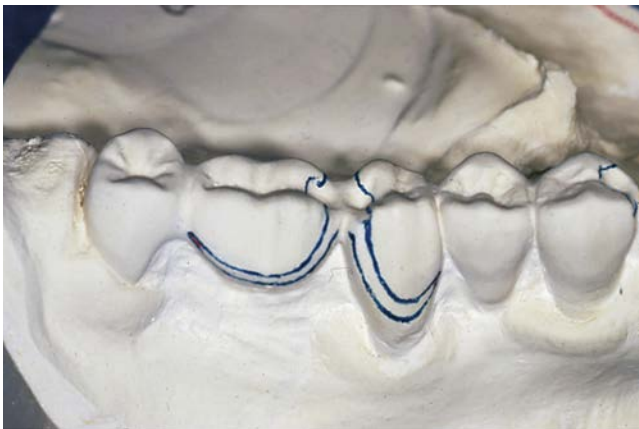
In situations in which the abutment is severely tilted, the extended occlusal rest may take the form of an onlay to restore the occlusal plane (Figure 6-9). The tooth preparation for this type of extended rest must include removing or restoring pits, fissures, and grooves; placing a 1- to 2-mm bevel on the buccal and lingual occlusal surfaces to allow the extended rest (onlay) to provide stabilization; allowing the rest to restore the contour and occlusion of the natural tooth; and ensuring that the rest directs the forces down the long axis of the tooth. Tooth preparation must also include a 1- to 2-mm guiding plane on the mesial surface of the abutment.



**FIGURE 6-8** Cast shows extended occlusal rest on the mandibular first molar, designed to ensure maximum bracing from the tooth. If placed on a mesially inclined molar next to a modification space (as in Figure 6-7), the extended rest would ensure that the forces are directed down the long axis of the abutment, and therefore the disto-occlusal rest would not have been needed.



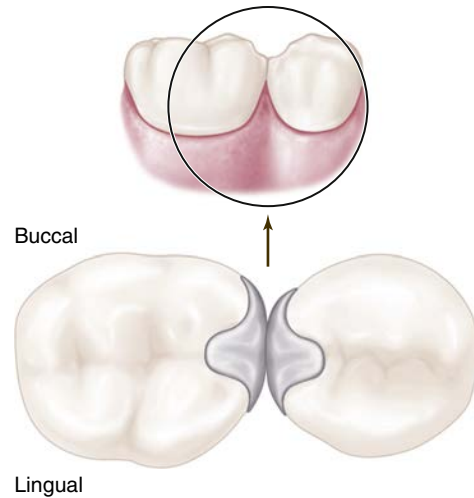
**FIGURE 6-9** The intaglio surface of an onlay occlusal rest restoring contour and occlusion for this maxillary molar.



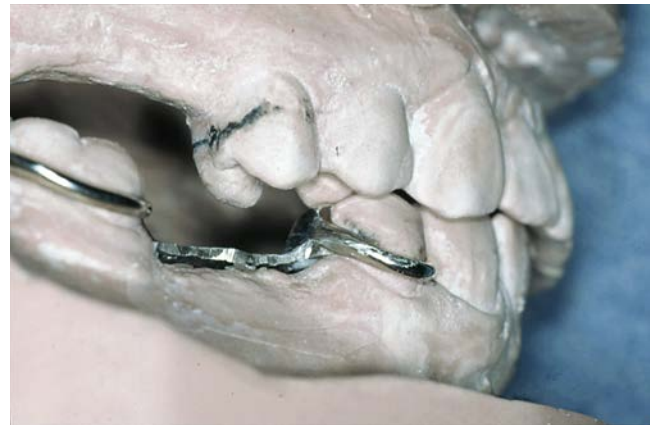**FIGURE 6-10** Drawing on cast shows the desired design of a direct retainer assembly on mandibular premolar and molar abutments that incorporates interproximal occlusal rests. The direct retainers on the distobuccal undercut of the molar and on the mesiobuccal undercut of the premolar are extended from the joined occlusal rests, which occupy specifically prepared adjoining rest seats.

### INTERPROXIMAL OCCLUSAL REST SEATS

The design of a direct retainer assembly may require the use of interproximal occlusal rests (Figure 6-10). These rest seats are prepared as individual occlusal rest seats, with the exception that the preparations must be extended farther lingually than is ordinarily accomplished (Figure 6-11). Adjacent



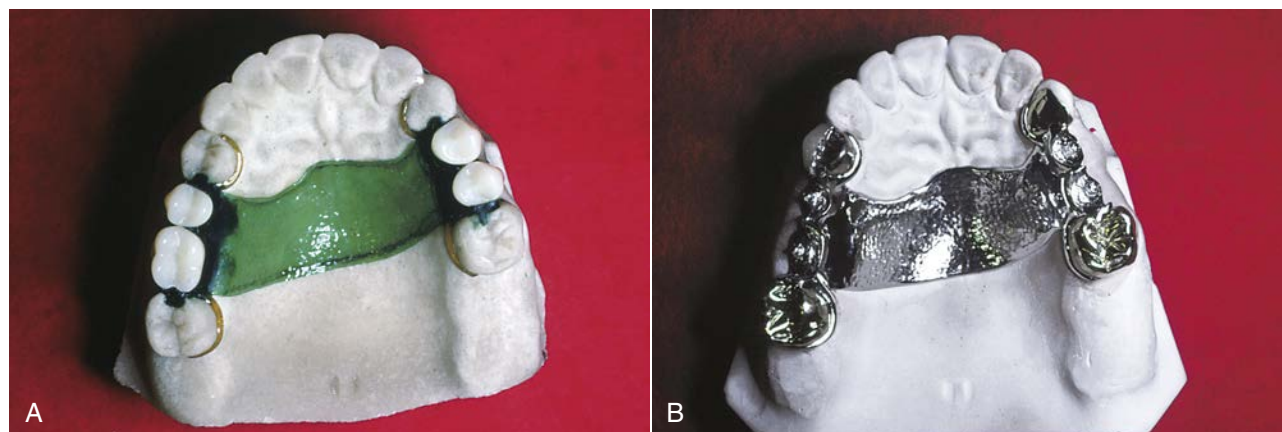
**FIGURE 6-11** Rest seat preparations on the premolar and molar fulfill requirements of properly prepared rest seats. Preparations are extended lingually to provide strength (through bulk) without overly filling the interproximal space with a minor connector. This type of preparation is challenging for natural tooth modification, and care must be exercised to avoid violation of contact points—yet the marginal ridge of each abutment should be sufficiently lowered (1.5 mm).



**FIGURE 6-12** View of mounted casts with the framework fully seated illustrates that interocclusal space was made available by a properly prepared rest seat.

rests, rather than a single rest, are used to prevent interproximal wedging by the framework. In addition, the joined rests are designed to shunt food away from contact points.

When such rest seats are prepared, care must be exercised to avoid reducing or eliminating contact points of abutment teeth. However, sufficient tooth structure must be removed to allow adequate bulk of the component for strength and to permit the component to be so shaped that occlusion will not be altered. Therefore analysis of mounted diagnostic casts is mandatory for assessment of interocclusal contact areas in which rests are to be placed. Sufficient space must be present or created to avoid interference with the placement of rests (Figure 6-12).



**FIGURE 6-13** Maxillary tooth-supported removable partial denture utilizing internal occlusal rests. **A**, Wax pattern developed utilizing internal rests on canine, premolar, and molars. **B**, Maxillary framework on cast with the internal rests fitted within surveyed crowns.

The lingual interproximal area requires only minor preparation. Creation of a vertical groove must be avoided to prevent a torquing effect on the abutments by the minor connector.

### INTERNAL OCCLUSAL RESTS

A partial denture that is totally tooth supported by means of cast retainers on all abutment teeth may use intracoronal rests for both occlusal support and horizontal stabilization (Figure 6-13).

An intracoronal rest is not a retainer and should not be confused with an attachment. Occlusal support is derived from the floor of the rest seat. Horizontal stabilization is derived from the near-vertical walls of this type of rest seat. The form of the rest should be parallel to the path of placement, slightly tapered occlusally, and slightly dovetailed to prevent dislodgment proximally.

The main advantages of the internal rest are that it facilitates the elimination of a visible clasp arm buccally and permits the location of the rest seat in a more favorable position in relation to the tipping axis (horizontal) of the abutment. Retention is provided by a lingual clasp arm, either cast or of wrought wire, lying in a natural or prepared infrabulge area on the abutment tooth.

Internal rests are carved in wax or spark eroded in abutment castings. Ready-made plastic rest patterns are readily available and can be waxed into crown or partial-veneer patterns, invested, and cast after having been positioned parallel to the path of placement with a dental cast surveyor. Future developments and techniques promise more widespread use of the internal occlusal rest but only for tooth-supported partial dentures.

### IMPLANTS AS A REST

Implants can also be considered to serve as a rest when one takes advantage of the vertical stiffness characteristic they possess. In this application, they can serve to resist

tissue-ward movement alone but may be considered useful for retentive needs as well. When a dual role is considered, selection of the retentive element requires consideration of how much stress from vertical movement resistance (the rest function) will affect the retentive function of the attachment mechanism.

When used as a rest, implants can serve to efficiently resist vertical movement and provide positive support. This use allows a low profile connection (i.e., close to the ridge), imparting less torque to the implant. Location can be prescribed for maximum advantage, and the implants can effectively alter rotation around a fulcrum line—eliminating it if applied to an unsupported end of a denture base, or reducing the effects by decreasing the effective lever arm. Because its position can be selected, it is important to consider (1) future use as a support to an implant fixed prosthesis, and (2) current placement at the distal-most tooth position to most effectively resist functional forces of occlusion.

### SUPPORT FOR RESTS

Rests may be placed on sound enamel or on any restoration material that has been proven scientifically to resist fracture and distortion when subjected to applied forces.

Rests placed on sound enamel are not conducive to caries in a mouth with a low-caries index, provided that good oral hygiene is maintained. Proximal tooth surfaces are much more vulnerable to caries attack than are the occlusal surfaces supporting an occlusal rest. The decision to use abutment coverage is usually based on needed mouth preparation, determined from the survey of diagnostic casts, to accommodate modifications of abutment teeth necessary to fabricate a removable partial denture (see Chapter 11). When precarious fissures are found in occlusal rest areas in teeth that are otherwise sound, they may be removed and appropriately restored without resorting to more extensive abutment protection. Although it cannot be denied that the best protection from caries for an abutment tooth is full coverage, it is imperative

that such crowns be contoured properly to provide support, stabilization, and retention for the partial denture.

When the decision of whether to use unprotected enamel surfaces for rests is made, the future vulnerability of each tooth must be considered because it is not easy to fabricate full crowns to accommodate rests and clasp arms after the partial denture has been made. In many instances, sound enamel may be used safely for the support of occlusal rests. In such situations, the patient should be advised that future susceptibility to caries is not predictable and that much depends on oral hygiene and possible future changes in caries susceptibility. Although the decision to use unprotected abutments logically should be left up to the dentist, economic factors may influence the final decision. The patient should be informed of the risks involved and of his or her responsibility for maintaining good oral hygiene and for returning periodically for observation.

Rest seat preparations should be made in sound enamel. In most instances, preparation of proximal tooth surfaces is necessary to provide proximal guiding planes and to eliminate undesirable undercuts that rigid parts of the framework must pass over during placement and removal. The preparation of occlusal rest seats always must follow proximal preparation, never precede it. Only after the alteration of proximal tooth surfaces is completed may the location of the occlusal rest seat in relation to the marginal ridge be determined. When proximal preparation follows occlusal rest seat preparation, the inevitable consequence is that the marginal ridge is too low and too sharp, with the center of the floor of the rest seat too close to the marginal ridge. Therefore it is often impossible to correct the rest preparation without making it too deep, which causes irreparable damage to the tooth.

Occlusal rest seats in sound enamel may be prepared with burs and polishing points that leave the enamel surface as smooth as the original enamel (Figure 6-14). The larger round bur is used first to lower the marginal ridge and to establish the outline form of the rest seat. The resulting occlusal rest seat is then complete except that the floor is not sufficiently concave.

A slightly smaller round bur then is used to deepen the floor of the occlusal rest seat. At the same time, it forms the desired spoon shape inside the lowered marginal ridge. The preparation is smoothed by a polishing point of suitable size and shape.


When a small enamel defect is encountered in the preparation of an occlusal rest seat, it is usually best to ignore it until the rest preparation has been completed. Then, with small burs, the remaining defect should be prepared to receive a small restoration. This may be finished flush with the floor of the rest preparation that was previously established.

A fluoride gel should be applied to abutment teeth following enamel recontouring. If the master cast will be fabricated from an irreversible hydrocolloid impression, application of the gel should be delayed until after impressions are made because some fluoride gels and irreversible hydrocolloids may be incompatible.

Occlusal rest seat preparations in existing restorations are treated the same way as those in sound enamel. Any proximal preparations must be done first, for if the occlusal rest seat is placed first and then the proximal surface is prepared, the outline form of the occlusal rest seat sometimes is irreparably altered.

The possibility that an existing restoration may be perforated in the process of preparation of an ideal occlusal rest seat is always present. Although some compromise is permissible, the effectiveness of the occlusal rest seat should not be jeopardized for fear of perforating an existing restoration. The rest seat may be widened to compensate for shallowness, but the floor of the rest seat should still be slightly inclined apically from the marginal ridge. When this is not possible, a secondary occlusal rest should be used on the opposite side of the tooth to prevent slipping of the primary rest.

When perforation does occur, it may be repaired, but occasionally the making of a new restoration is unavoidable. In such a situation, the original preparation should be modified to accommodate the occlusal rest, thereby avoiding the



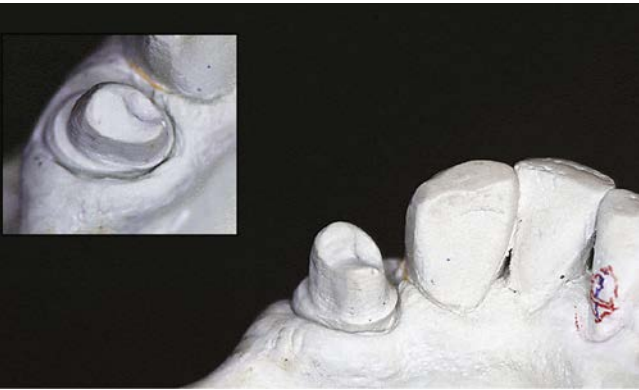
**FIGURE 6-14** Recontouring of axial surfaces and rest seat preparations in enamel may be readily accomplished with selected use of accessories. **A**, The two pear-shaped, multi-fluted burs (*two burs on the left*) can be used for cingulum rests and rounding marginal ridges; the longer straight, multi-fluted enamelplasty bur (*middle bur*) is ideal for height of contour adjustments and guide plane preparation; round multi-fluted or carbide burs (*three burs at right of middle*) are used for occlusal rest preparation; and the inverted cone (*far right bur*) can be used for cingulum rests as well. **B**, Various abrasive rubber polishing points are necessary to ensure a smooth surface finish following any enamelplasty procedure. Following the manufacturer's recommended sequence of abrasives should return the surface to smoothness comparable with the original condition. Diamonds are not recommended for this type of tooth reduction.

risk of perforating the completed restoration or fabricating a restoration with an inadequate rest seat.

Occlusal rest seat location in new restorations should be known when the tooth is prepared so that sufficient clearance may be provided for the rest seat within the preparation. The final step in the preparation of the tooth should be to make sure such clearance exists and, if not, to make a depression to accommodate the depth of the rest (Figure 6-15).

Occlusal rest seats in crowns and inlays generally are made somewhat larger and deeper than those in enamel. Those made in abutment crowns for tooth-supported dentures may be made slightly deeper than those in abutments that support a distal extension base; thus they approach the effectiveness of boxlike internal rests.

Internal rest seats also should be created first in wax, either with suitable burs in a handpiece holder or by waxing around a



**FIGURE 6-15** Preparation on mandibular premolar for surveyed crown incorporates space for mesio-occlusal rest seat. Adequate occlusal reduction was accomplished to accommodate the depth of the rest seat in the abutment crown. The modification for the rest seat is performed following the standard crown preparation.

lubricated mandrel, which is held in the surveyor. In either situation, the rest preparation must be finished on the casting with burs in a handpiece holder or with a precision drill press. Plastic and metal shoes that fit over a mandrel are also available for this purpose. Thus a smooth casting is ensured, and the need for finishing the inside of the internal rest with burs is eliminated. Sufficient clearance must be provided in the preparation of the abutment to accommodate the depth of the internal rest.

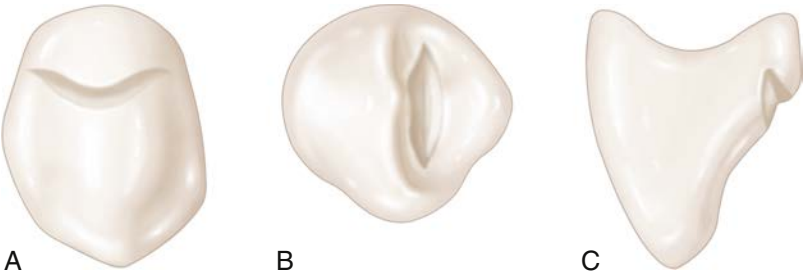**LINGUAL RESTS ON CANINES AND INCISOR TEETH**

Analysis of mounted diagnostic casts is mandatory in assessment of incisal and lingual contact areas where rests are to be placed. Sufficient space must be present or created to avoid interference with placement of rests.

Although the preferred site for an external rest is the occlusal surface of a molar or a premolar, an anterior tooth may be the only abutment available for occlusal support of the denture. Also an anterior tooth occasionally must be used to support an indirect retainer or an auxiliary rest. A canine is much preferred over an incisor for this purpose. When a canine is not present, multiple rests that are spread over several incisor teeth are preferable to the use of a single incisor. Root form, root length, inclination of the tooth, and ratio of the length of the clinical crown to the alveolar support must be considered when the site and form of rests placed on incisors are determined.

A lingual rest is preferable to an incisal rest because it is placed closer to the horizontal axis of rotation (tipping axis) of the abutment and therefore will have less of a tendency to tip the tooth. In addition, lingual rests are more esthetically acceptable than are incisal rests.

If an anterior tooth is sound and the lingual slope is gradual rather than perpendicular, a lingual rest sometimes may be placed in an enamel seat at the cingulum or just incisally to the cingulum (Figure 6-16). This type of lingual rest

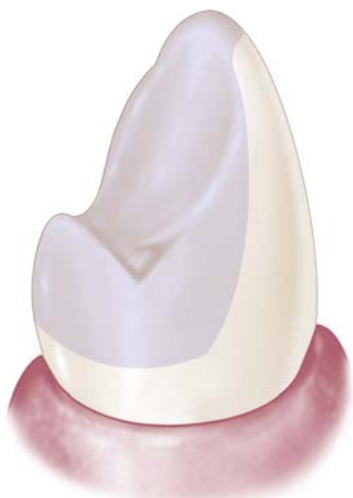

**FIGURE 6-16** Three views of lingual rest seat prepared in enamel of the maxillary canine. **A**, The rest seat, from the lingual aspect, assumes the form of a broad inverted V, maintaining the natural contour sometimes seen in a maxillary canine cingulum. An inverted V notch form is self-centering for the rest and at the same time directs forces rather favorably in an apical direction. **B**, From the incisal view, it will be noted that the rest seat preparation is broadest at the most lingual aspect of the canine. As the preparation approaches the proximal surface of the tooth, it is less broad than at any other area. **C**, The proximal view demonstrates correct taper of the floor of the rest seat. It also should be noted that the borders of the rest seat are slightly rounded to avoid line angles in its preparation. The mesiodistal length of the preparation should be a minimum of 2.5 to 3 mm, labiolingual width about 2 mm, and incisal-apical depth a minimum of 1.5 mm. It is a risky preparation and should not be attempted on lower anterior teeth.

is usually confined to maxillary canines that have a gradual lingual incline and a prominent cingulum. In a few instances, such a rest also may be placed on maxillary central incisors. The lingual slope of the mandibular canine is usually too steep for an adequate lingual rest seat to be placed in the enamel, and some other provision for rest support must be made. Lingual rest seat preparations in enamel are rarely satisfactory on mandibular anterior teeth because of lack of thickness of the enamel in which a seat of adequate form to be truly supportive is prepared.

The preparation of an anterior tooth to receive a lingual rest may be accomplished in one of two ways:

1. A slightly rounded V is prepared on the lingual surface at the junction of the gingival and the middle one third of the tooth. The apex of the V is directed incisally. This preparation may be started by using an inverted, cone-shaped diamond stone and progressing to smaller, tapered stones with round ends to complete the preparation. All line angles must be eliminated, and the rest seat must be prepared within the enamel and must be highly polished. Shaped, abrasive rubber polishing points, followed by flour of pumice, produce an adequately smooth and polished rest seat. A predetermined path of placement for the denture must be kept in mind when the rest seat is prepared. The lingual rest seat must not be prepared as though it was going to be approached from a direction perpendicular to the lingual slope. The floor of the rest seat should be toward the cingulum rather than the axial wall. Care must be taken not to create an enamel undercut, which interferes with placement of the denture (see Figure 6-16).
2. The most satisfactory lingual rest from the standpoint of support is one that is placed on a prepared rest seat in a cast restoration (Figure 6-17). This is done most effectively by planning and executing a rest seat in the wax pattern



**FIGURE 6-17** Rest seat preparation can be exaggerated for better support when it is prepared in cast restoration.

rather than by attempting to cut a rest in a cast restoration in the mouth. The contour of the framework may then restore the lingual form of the tooth.

When the cingulum in the wax pattern is accentuated, the floor of the rest seat is readily carved to be the most apical portion of the preparation. A saddlelike shape, which provides a positive rest seat located favorably in relation to the long axis of the tooth, is formed. The framework of the denture is made to fill out the continuity of the lingual surface so that the tongue contacts a smooth surface without the patient being conscious of bulk or irregularities.

The lingual rest may be placed on the lingual surface of a cast veneer crown (Figure 6-18), a three-quarter crown, an inlay, a laminate veneer, a composite restoration, or an etched metal restoration. The latter displays less metal than the three-quarter crown, especially on the mandibular canine, where the lingual rest that was placed on a cast restoration is frequently used, and it is a more conservative restoration. The three-quarter crown may be used if the labial surface of the tooth is sound and if the retentive contours are satisfactory. However, if the labial surface presents inadequate or excessive contours for placement of a retentive clasp arm or if gingival decalcification or caries is present, a veneered complete coverage restoration should be used.

In some instances, ball types of rests may be used in prepared seats. Such rest seats may be cautiously prepared in tooth surfaces with overly sufficient enamel thickness or may be prepared in restorations placed in teeth in which enamel thickness is inadequate. Conservative restorations (e.g., silver amalgam, pin inlays, or composite resin) in anterior teeth may be better suited for ball types of rest seats than are the less conservative inverted V types of rest seats.

Some scientific evidence demonstrates that individually cast chromium-cobalt alloy rest seat forms (attached to



**FIGURE 6-18** Positive vertical support for a prosthesis is furnished by rest seats prepared in splinted metal ceramic crowns. The cingulum rest seats are optimally placed as near the horizontal axis of rotation as possible to minimize tipping forces.

lingual surfaces of anterior teeth by the use of composite resin cements with acid-etched tooth preparation), laminates, and composite resins have been successfully used as conservative approaches to forming rest seats on teeth with unacceptable lingual contours (Figure 6-19). Sapphire ceramic orthodontic brackets have also been bonded to the lingual surfaces of mandibular canines and shaped as rest seats. These have advantages over the metal acid-etched retained rests in that a laboratory step is avoided and increased bond strengths are achieved. The major disadvantage of using orthodontic brackets is that removal of the rest seat would necessitate that they be ground off with the potential of heat generation and possible pulpal damage.

INCISAL RESTS AND REST SEATS

Incisal rests are placed at the incisal angles of anterior teeth and on prepared rest seats. Although this is the least desirable placement of a rest seat for reasons previously mentioned, it may be used successfully for selected patients when the abutment is sound and when a cast restoration is not otherwise indicated. Therefore incisal rests generally are placed on enamel (Figure 6-20). Incisal rests are used predominantly as auxiliary rests or as indirect retainers.

Although the incisal rest may be used on a canine abutment in either arch, it is more applicable to the mandibular canine. This type of rest provides definite support with relatively little loss of tooth structure and little display of metal. Esthetically it is preferable to the three-quarter crown. The same criteria may be applied when one is deciding whether to use unprotected enamel for an occlusal rest on a molar or premolar. An incisal rest is more likely than a lingual rest to lead to some orthodontic movement of the tooth because of unfavorable leverage factors.

An incisal rest seat is prepared in the form of a rounded notch at the incisal angle of a canine or on the incisal edge

of an incisor, with the deepest portion of the preparation apical to the incisal edge (Figure 6-21). The notch should be beveled both labially and lingually, and the lingual enamel should be partly shaped to accommodate the rigid minor connector connecting the rest to the framework. An incisal rest seat should be approximately 2.5 mm wide and 1.5 mm deep so that the rest will be strong without having to exceed the natural contour of the incisal edge (Figure 6-22).

In the absence of other suitable placements for incisal rests and rest seats, incisal rests on multiple mandibular incisors may be considered. Use of such rests may be justified by the following factors:

- 1. They may take advantage of natural incisal faceting.
- 2. Tooth morphology does not permit other designs.
- 3. Such rests can restore defective or abraded tooth anatomy.
- 4. Incisal rests provide stabilization.
- 5. Full incisal rests may restore or provide anterior guidance.

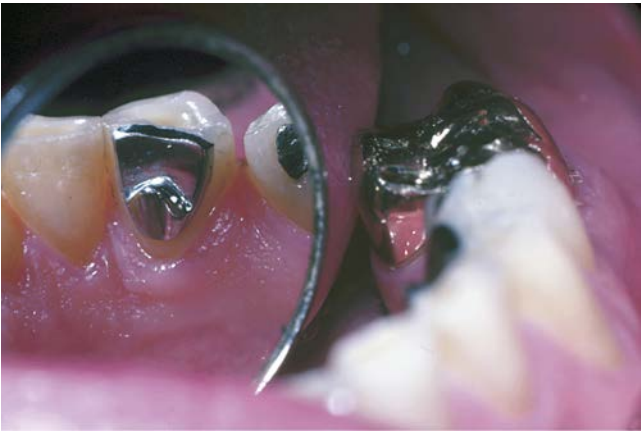

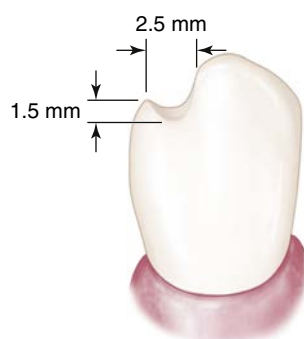
FIGURE 6-19 Chromium-cobalt lingual rest seat on mandibular canine retained by resin cement with acid-etched tooth preparation.

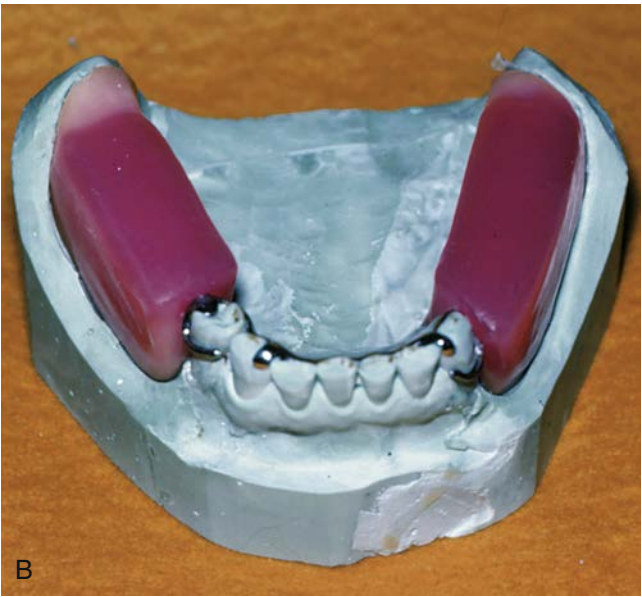
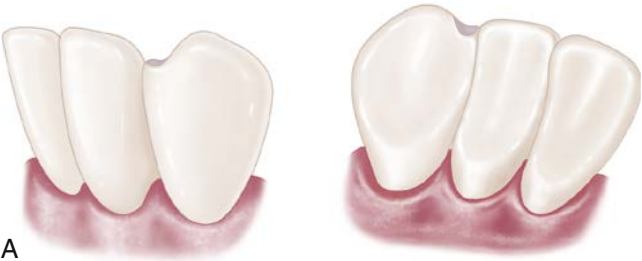
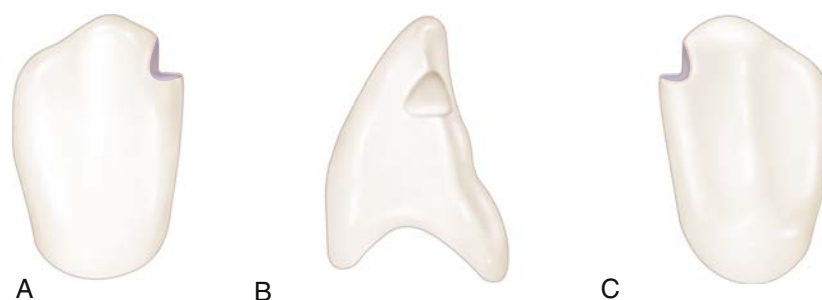FIGURE 6-20 A, Incisal rest seat placed in the mesial incisal edge of the lower canine. Note that the contact point is not involved in preparation of the rest seat. B, Mesial incisal rests on the canines furnish excellent vertical support and indirect retention for this prosthesis upon completion. The incisal rest on tooth #27 also provides a third point of reference when frame orientation is established during maintenance reline procedures.



**FIGURE 6-21** Three views of an incisal rest seat preparation on the mandibular canine adjacent to a modification space. **A**, The labial view demonstrates inclination of the floor of the rest seat, which allows forces to be directed along the long axis of the tooth as nearly as possible. Note that the floor of the rest seat has been extended slightly onto the labial aspect of the tooth. **B**, As can be seen from a proximal view, the proximal edge of the rest seat is rounded rather than straight. **C**, The lingual view shows that all borders of the rest seat are rounded to avoid sharp line angles. It is especially important to avoid a line angle at the junction of the axial wall of the preparation and the floor of the rest seat. The rest that occupies such a preparation should be able to move slightly in a lateral direction to avoid torquing of the abutment tooth.



**FIGURE 6-22** Dimensions given in the illustration for an incisal rest seat preparation will provide adequate strength of the framework at the junction of the rest and the minor connector. Rest seats of smaller dimension have proved unsatisfactory regardless of the metal alloy from which the framework is made.

In the event that full incisal rests are considered, the patient should be thoroughly informed regarding their location, form, and esthetic impact.

It is, of course, essential that both the master cast and the casting be accurate if rests are to seat properly. The incisal rest should be overcontoured slightly to allow for labial and incisal finishing to the adjoining enamel, in much the same manner as a three-quarter crown or inlay margin is finished to enamel. In this way, minimal display of metal is possible without jeopardizing the effectiveness of the rest.

Care taken in selecting the type of rest seat to be used, in preparing it, and in fabricating the framework casting does much to ensure the success of any type of rest. The topography of any rest should be such that it restores the topography of the tooth that exists before the rest seat is prepared.

# CHAPTER 7

## Direct Retainers

### CHAPTER OUTLINE

Direct Retainer's Role in Control of Prosthesis Movement

Basic Principles of Clasp Design

Reciprocal Arm Functions

Types of Direct Retainers

Criteria for Selecting a Given Clasp Design

Types of Clasp Assemblies

Clasps Designed to Accommodate Functional Movement

Clasps Designed Without Movement Accommodation

Implants as Direct Retainers

Analysis of Tooth Contours for Retentive Clasps

Amount of Retention

Size of and Distance into the Angle of Cervical Convergence

Length of Clasp Arm

Diameter of Clasp Arm

Cross-Sectional Form of the Clasp Arm

Material Used for the Clasp Arm

Relative Uniformity of Retention

Stabilizing-Reciprocal Cast Clasp Arm

Other Types of Retainers

Lingual Retention in Conjunction with Internal Rests

Internal Attachments

### DIRECT RETAINER'S ROLE IN CONTROL OF PROSTHESIS MOVEMENT

Retention of a removable prosthesis is a unique concern when compared with other prostheses. When one is dealing with a crown or fixed partial denture, the combined use of preparation geometry (i.e., resistance and retention form) and a luting agent can fix the prosthesis to the tooth in a manner that resists all forces to which the teeth are subjected. As was mentioned in Chapter 4, the direction of forces can be toward, across, or away from the tissue. In general, the forces acting to move prostheses toward and across the supporting teeth and/or tissue are the greatest in intensity. This is because most often they are forces of occlusion.

Forces acting to displace the prosthesis from the tissue can consist of gravity acting against a maxillary prosthesis, the action of adherent foods acting to displace the prosthesis on opening of the mouth in chewing, or functional forces acting across a fulcrum to unseat the prosthesis. The first two of these forces are seldom at the magnitude of functional forces, and the latter is minimized through the use of adequate support. The component part applied to resist this movement away from the teeth and/or tissue provides retention for the prosthesis and is called the *direct retainer*. A direct retainer is any unit of a removable dental prosthesis that engages an abutment tooth or implant to resist displacement of the prosthesis away from basal seat tissue. The direct retainer's ability to resist this movement is greatly influenced by the stability and support of the prosthesis provided by major and minor connectors, rests, and tissue bases. This relationship of the supportive and retentive components highlights the relative importance of these component parts. Although the forces working against a removable partial denture to move it away from the tissue generally are not as great as the functional forces causing stress toward the tissue, the removable partial denture must have retention appropriate to resist reasonable dislodging forces. Too often retention concerns are given greater importance than is appropriate, especially if such a focus detracts from more serious consideration of the resistance of typical functional forces.

Sufficient retention is provided by two means. Primary retention for the removable partial denture is accomplished mechanically by placing retaining elements (direct retainers) on the abutment teeth. Secondary retention is provided by the intimate relationship of the minor connector contact with the guiding planes and denture bases and of the major connector (maxillary) with underlying tissue. The latter is similar to the retention of a complete denture. It is proportionate to the accuracy of the impression registration, the accuracy of the fit of the denture bases, and the total involved area of contact. Retention can also be provided through engagement of an attachment mechanism on a dental implant.

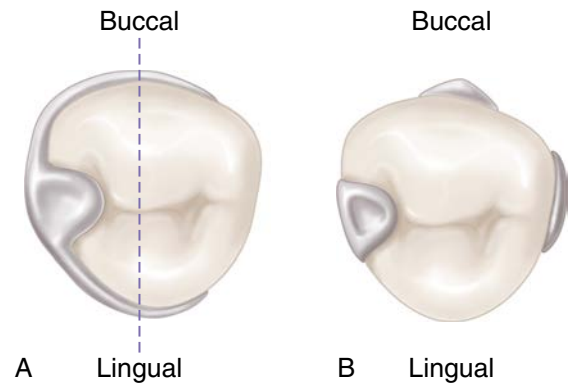
### BASIC PRINCIPLES OF CLASP DESIGN

The clasp assembly serves a similar function for a removable partial denture that a retainer crown serves for a fixed partial denture. Both must encircle the prepared tooth in a manner that prevents movement of the tooth separate from the retainer. To borrow from a fixed prosthodontic term, *limiting the freedom of displacement* refers to the effect of one cylindrical surface (the framework encircling the tooth) on another cylindrical surface (the tooth). It implies that the curve that defines the framework is properly shaped if it prevents movement at right angles to the tooth axis. This basic principle of clasp design offers a two-way benefit. First, it ensures the stability of the tooth position because of the restraint from encirclement, and second, it ensures stability of the clasp assembly because of the controlled position of the clasp in three dimensions.

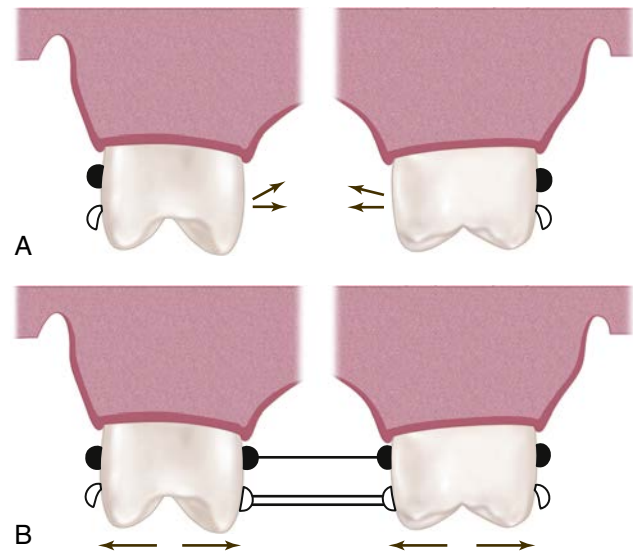
Therefore the basic principle of clasp design, referred to as the *principle of encirclement*, means that more than 180 degrees in the greatest circumference of the tooth, passing from diverging axial surfaces to converging axial surfaces, must be engaged by the clasp assembly (Figure 7-1). The engagement can occur in the form of continuous contact, such as in a circumferential clasp, or discontinuous contact, such as in the use of a bar clasp. Both provide tooth contact in at least three areas encircling the tooth: (1) the occlusal rest area, (2) the retentive clasp terminal area, and (3) the reciprocal clasp terminal area.

In addition to encirclement, other basic principles of clasp design are as follows:

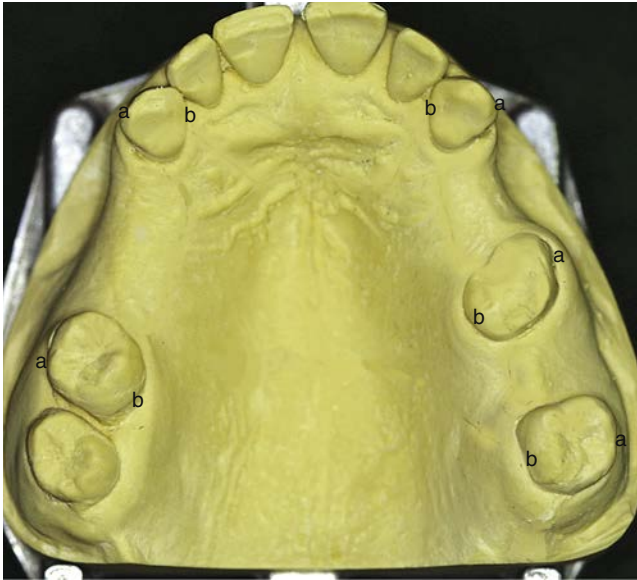
1. The occlusal rest must be designed to prevent movement of the clasp arms toward the cervical.
2. Each retentive terminal should be opposed by a reciprocal component capable of resisting any transient pressures exerted by the retentive arm during placement and removal. Stabilizing and reciprocal components must be rigidly connected bilaterally (cross-arch) to realize reciprocation of the retentive elements (Figure 7-2).
3. Clasp retainers on abutment teeth adjacent to distal extension bases should be designed so that they avoid direct transmission of tipping and rotational forces to the abutment. In effect, they must act as stress-breakers, either by their design or by their construction. This is accomplished



**FIGURE 7-1** A, Dashed line drawn through the illustration represents 180 degrees of greatest circumference of abutment from the occlusal rest. Unless portions of the lingual reciprocal arm and the retentive buccal arm are extended beyond the line, the clasp would not accomplish its intended purpose. If respective arms of the retainer were not extended beyond the line, the abutment tooth could be forced away from the retainer through torquing action of the clasp, or the removable partial denture could move away from the abutment. B, Bar-type clasp assembly engagement of more than 180 degrees of circumference of the abutment is realized by the minor connector for the occlusal rest, the minor connector contacting the guiding plane on the distal proximal surface, and the retentive bar arm.



**FIGURE 7-2** A, Flexing action of the retentive clasp arm initiates medially directed pressure on the abutment teeth as its retentive tip springs over the height of contour. B, Reciprocation to medially directed pressure is counteracted by rigid lingually placed clasp arms contacting the abutments simultaneously with the buccal arms, or by rigid stabilizing components of the framework contacting the lingual guiding planes when the buccal arms begin to flex.



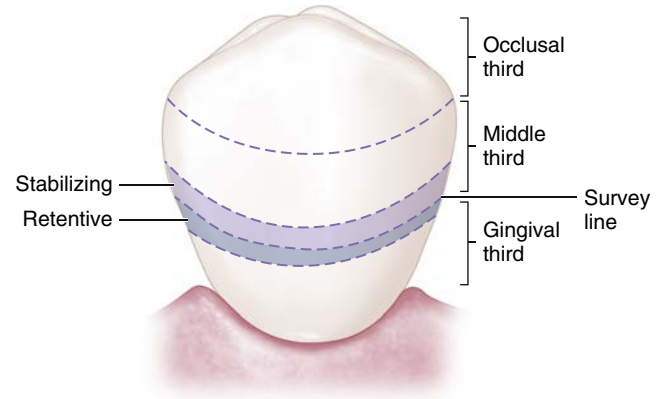
**FIGURE 7-3** Retentive clasps should be bilaterally opposed. This means bilateral buccal or bilateral lingual undercuts should be used, as shown on this Class III, modification 2 arch, in which the retention may be (a) bilaterally buccal or (b) bilaterally lingual.

through proper location of the retentive terminal relative to the rest, or by the use of a more flexible clasp arm in relation to the anticipated rotation of the denture under functional forces.

- Unless guiding planes will positively control the path of removal and will stabilize abutments against rotational movement, retentive clasps should be bilaterally opposed (i.e., buccal retention on one side of the arch should be opposed by buccal retention on the other, or lingual on one side opposed by lingual on the other). In Class II situations, the third abutment may have buccal or lingual retention. In Class III situations, retention may occur bilaterally or may be diametrically opposed (Figure 7-3).
- The path of escapement for each retentive clasp terminal must be other than parallel to the path of removal for the prosthesis to require clasp engagement with the resistance to deformation that is retention.
- The amount of retention should always be the minimum necessary to resist reasonable dislodging forces.
- Reciprocal elements of the clasp assembly should be located at the junction of the gingival and middle thirds of the crowns of abutment teeth. The terminal end of the retentive arm is optimally placed in the gingival third of the crown (Figures 7-4 through 7-6). These locations permit better resistance to horizontal and torquing forces caused by a reduction in the effort arm as described in Chapter 4.

### Reciprocal Arm Functions

As was mentioned earlier, reciprocal arms are intended to resist tooth movement in response to deformation of the retainer arm as it engages a tooth height of contour.

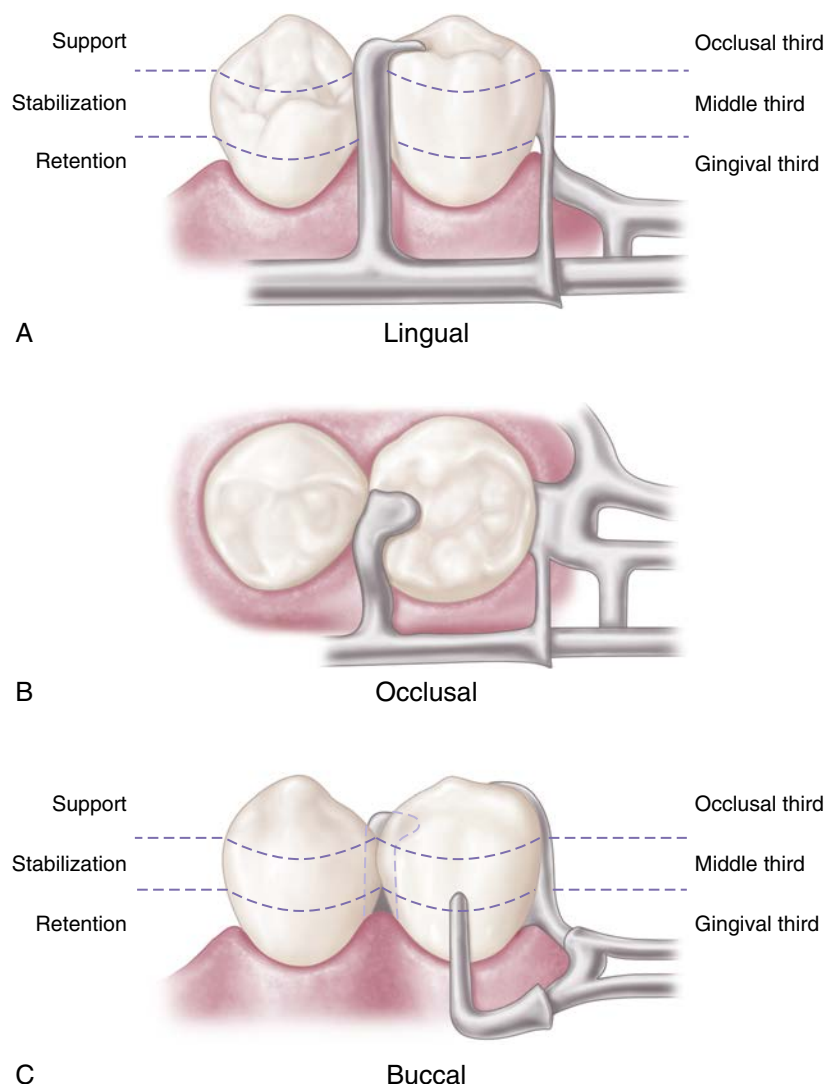


**FIGURE 7-4** Simple mechanical laws demonstrate that the nearer stabilizing-reciprocal and retentive elements of direct retainer assemblies are located horizontal to the axis of rotation of the abutment, the less likely it is that physiologic tolerance of the periodontal ligament will be exceeded. The horizontal axis of rotation of the abutment tooth is located somewhere in its root.

The opposing clasp arm reciprocates the effect of this deformation as it prevents tooth movement. For this to occur, the reciprocal arm must be in contact during the time of retainer arm deformation. Unless the abutment tooth has been specifically contoured, the reciprocal clasp arm will not come into contact with the tooth until the denture is fully seated and the retentive clasp arm has again become passive. When this happens, a momentary tipping force is applied to the abutment teeth during each placement and removal. This may not be a damaging force—because it is transient—so long as the force does not exceed the normal elasticity of the periodontal attachments. True reciprocation during placement and removal is possible only through the use of crown surfaces made parallel to the path of placement. The use of cast restorations permits the parallel surfaces to be contacted by the reciprocal arm in such a manner that true reciprocation is made possible. This is discussed in Chapter 15.

Reciprocal arms can have additional functions as well. The reciprocal clasp arm should be located so that the denture is stabilized against horizontal movement. Stabilization is possible only through the use of rigid clasp arms, rigid minor connectors, and a rigid major connector. Horizontal forces applied on one side of the dental arch are resisted by the stabilizing components on the opposite side, providing cross-arch stability. Obviously the greater the number of such components, within reason, the greater will be the distribution of horizontal stresses.

The reciprocal clasp arm also may act to a minor degree as an indirect retainer. This is true only when it rests on a supra-bulge surface of an abutment tooth lying anterior to the fulcrum line (see Figure 8-8). Lifting of a distal extension base away from the tissue is thus resisted by a rigid arm, which is not easily displaced cervically. The effectiveness of such an indirect retainer is limited by its proximity to the fulcrum line, which gives it a relatively poor leverage advantage, and by the



**FIGURE 7-5** A bar-type clasp on the mandibular premolar. **A**, Support is provided by the occlusal rest. **B**, Stabilization is provided by the occlusal rest and the mesial and distal minor connectors. **C**, Retention is provided by the buccal I-bar. Reciprocation is obtained through the location of the minor connectors. Engagement of more than 180 degrees of circumference of the abutment is accomplished by proper location of components contacting the axial surfaces. (The minor connector supports the occlusal rest, the proximal plate minor connector, and the buccal I-bar.)

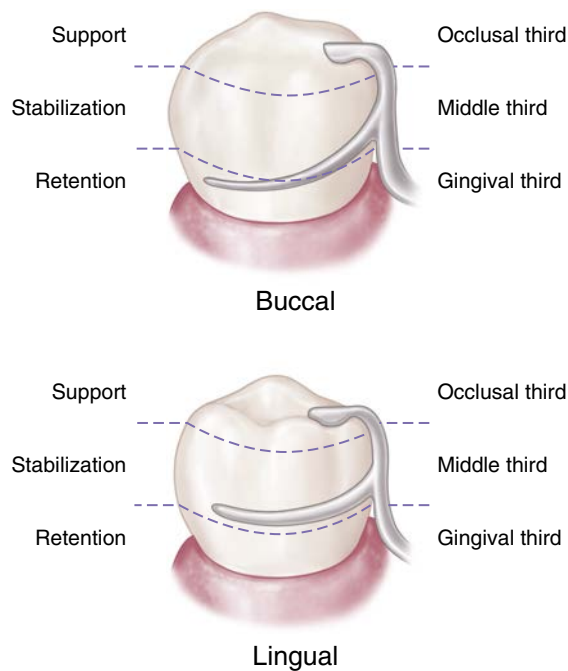
fact that slippage along tooth inclines is always possible. The latter may be prevented by the use of a ledge on a cast restoration; however, enamel surfaces are not ordinarily so prepared.

### TYPES OF DIRECT RETAINERS

Mechanical retention of removable partial dentures is accomplished by means of direct retainers of one type or another. Retention is accomplished by using frictional means, by engaging a depression in the abutment tooth, or by engaging a tooth undercut lying cervically to its height of contour. Two basic types of direct retainers are available: (1) the intracoronal retainer and (2) the extracoronal retainer. The extracoronal (clasp-type) retainer is the most commonly used retainer for removable partial dentures.

The intracoronal retainer may be cast or may be attached totally within the restored natural contours of an abutment tooth. It is typically composed of a prefabricated machined key and keyway with opposing vertical parallel walls, which serve to limit movement and resist removal of the partial denture through frictional resistance ([Figure 7-7](#)). The intracoronal retainer is usually regarded as an **internal**, or precision, attachment. The principle of the internal attachment was first formulated by Dr. Herman E.S. Chayes in 1906.

The extracoronal retainer uses mechanical resistance to displacement through components placed on or attached to the external surfaces of an abutment tooth. The extracoronal retainer is available in three principal forms. The clasp-type retainer ([Figures 7-8 and 7-9](#)), the form used most commonly, retains through a flexible clasp arm. This arm



**FIGURE 7-6** Circumferential clasp on the mandibular premolar. Support is provided by the occlusal rest; stabilization is provided by the occlusal rest, proximal minor connector, lingual clasp arm, and rigid portion of the buccal retentive clasp arm occlusal to the height of contour; retention is realized by the retentive terminal of the buccal clasp arm; reciprocation is provided by the nonflexible lingual clasp arm. Assembly engages more than 180 degrees of the abutment tooth's circumference.

engages an external surface of an abutment tooth in an area cervical to the greatest convexity of the tooth, or it engages a depression prepared to receive the terminal tip of the arm. The other forms both involve manufactured attachments and include interlocking components or the use of a spring-loaded device that engages a tooth contour to resist occlusal displacement. Another type is a manufactured attachment, which uses flexible clips or rings that engage a rigid component that is cast or attached to the external surface of an abutment crown.

In situations where support requirements are adequately met by available teeth and/or oral tissues, dental implants can be used for retention and provide the advantage of elimination of a visible clasp.

**CRITERIA FOR SELECTING A GIVEN CLASP DESIGN**

When a particular clasp design is selected for a given situation, its function and limitations must be carefully evaluated. Extracoronal direct retainers, as part of the clasp assembly, should be considered as components of a removable partial denture framework. They should be designed and located to perform the specific functions of support, stabilization, reciprocation, and retention. It does not matter whether the

direct retainer-clasp assembly components are physically attached to each other or originate from major and minor connectors of the framework (see Figures 1-2 and 1-3, B-E). If attention is directed to the separate function of each component of the direct retainer-clasp assembly, then selection of a direct retainer is simplified.

Although some rather complex designs are used for clasp arms, they all may be classified into one of two basic categories. One is the circumferential clasp arm, which approaches the retentive undercut from an occlusal direction. The other is the bar clasp arm, which approaches the retentive undercut from a cervical direction. A clasp assembly may comprise various retentive arms (i.e., a cast circumferential, a bar clasp arm, or a wrought-wire retainer), depending on the specific requirement for retainer construction, given the necessary adjustability, clasp approach position, and survey line location.

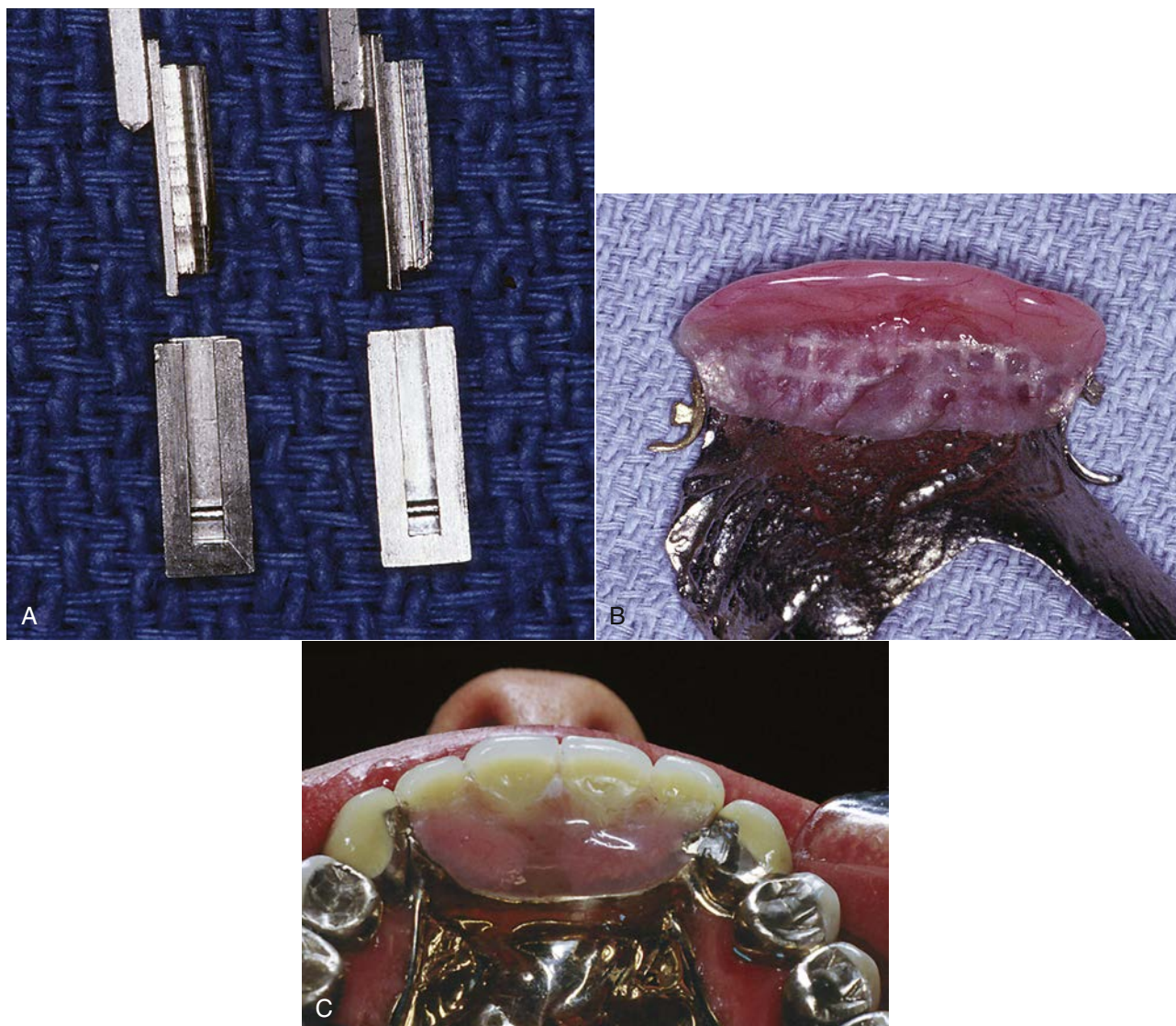
A clasp assembly should consist of four component parts. First, one or more minor connectors should be present, from which the clasp components originate. Second, a principal rest should be designed to direct stress along the long axis of the tooth. Third, a retentive arm should engage a tooth undercut. For most clasps, the retentive region is only at its terminus. Fourth, a nonretentive arm (or other component) should be present on the opposite side of the tooth for stabilization and reciprocation against horizontal movement of the prosthesis (rigidity of this clasp arm is essential to its purpose).

No confusion should exist between the choice of clasp arm and the purpose for which it is used. Either type of cast clasp arm (bar or circumferential) may be made tapered and retentive, or nontapered (rigid) and nonretentive. The choice depends on whether it is used for retention, stabilization, or reciprocation. An occlusal rest, such as in the rest, proximal plate, and I-bar (RPI) component parts of the clasp assembly concept, may be used rather than a reciprocal clasp arm to satisfy the need for encirclement, provided it is located in such a way that it can accomplish the same purpose (Figure 7-10; see also Figure 7-9). The addition of a lingual apron to a cast reciprocal clasp arm alters neither its primary purpose nor the need for proper location to accomplish that purpose.

**TYPES OF CLASP ASSEMBLIES**

A wide variety of clasp assemblies are available for clinicians to use. This variety exists largely because of the imagination of clinicians and technicians who provided prostheses when tooth modification was not or could not be provided. To simplify clasp design and to improve the functional predictability of prostheses, today's clinician must realize the need for tooth modification.

Some clasp assemblies are designed to accommodate prosthesis functional movement (as mentioned in the basic principles earlier), and others do not incorporate such design features. Although it has been demonstrated by Kapur and others that adverse outcomes are not always associated with



**FIGURE 7-7** A, The intracoronal retainer consists of a key and keyway with extremely small tolerance. Keyways are contained within abutment crowns, and keys are attached to the removable partial denture framework (B). C, Frictional resistance to removal and placement and limitation of movement serve to retain and stabilize the prosthesis.

the use of rigid clasp assemblies in distal extension classifications, the following clasp assemblies are described as clasps designed to accommodate distal extension functional movement and clasps designed without movement accommodation. The clinician should not interpret these categories as mutually exclusive because most any clasp assembly can be used to retain a well-supported and maintained prosthesis.

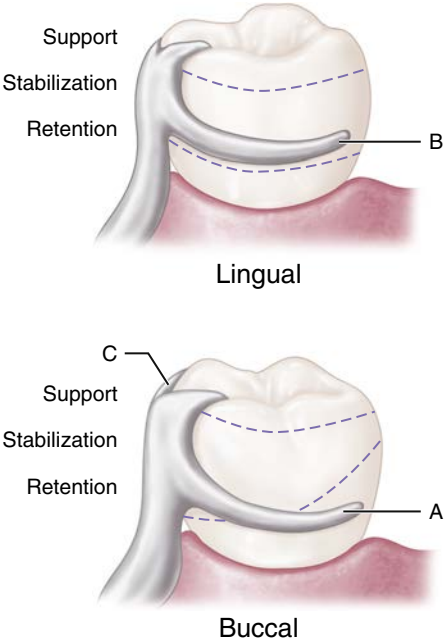
### Clasps Designed to Accommodate Functional Movement

#### RPI, RPA, and Bar Clasp

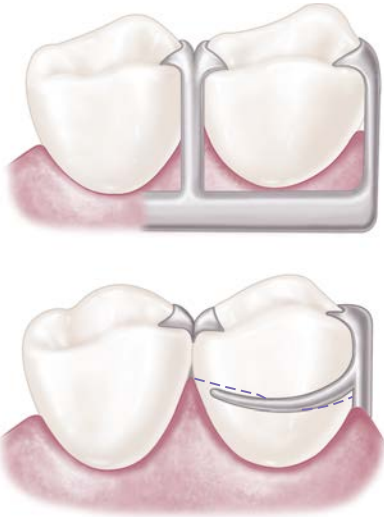Clasp assemblies that accommodate functional prosthesis movement are designed to address the concern of a Class I lever. The concern is that the distal extension acts as a long “effort arm” across the distal rest “fulcrum” to cause the clasp tip “resistance arm” to engage the tooth undercut. This

results in harmful tipping or torquing of the tooth, which is greater with stiff clasps and increased denture base movement. Two strategies may be adopted to change the fulcrum location and subsequently the “resistance arm” engaging effect (mesial rest concept clasp assemblies), or to minimize the effect of the lever through the use of a flexible arm (wrought-wire retentive arm).

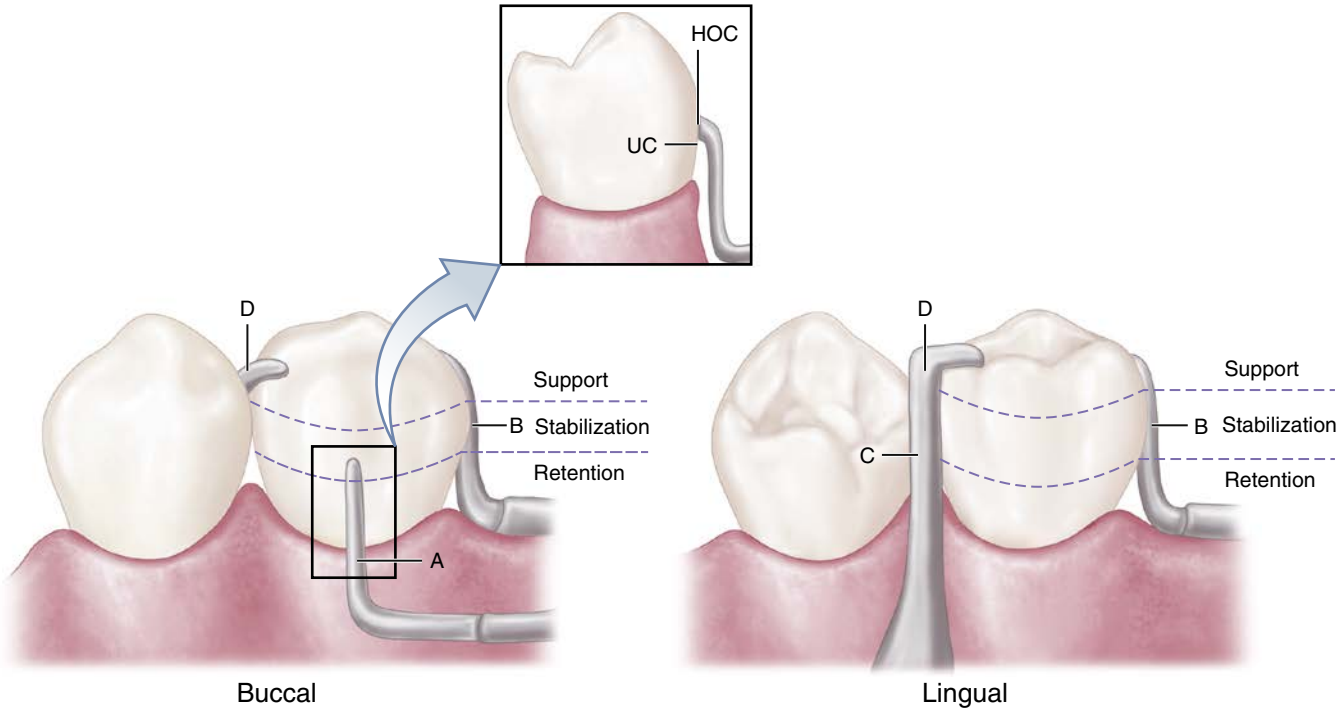
Mesial rest concept clasps have been proposed to accomplish movement accommodation by changing the fulcrum location. This concept includes the RPI and rest, proximal plate, Akers (RPA) clasps. The RPI is a current concept of bar clasp design that refers to the rest, proximal plate, and I-bar component parts of the clasp assembly. Basically, this clasp assembly consists of a mesio-occlusal rest with the minor connector placed into the mesiolingual embrasure, but not contacting the adjacent tooth



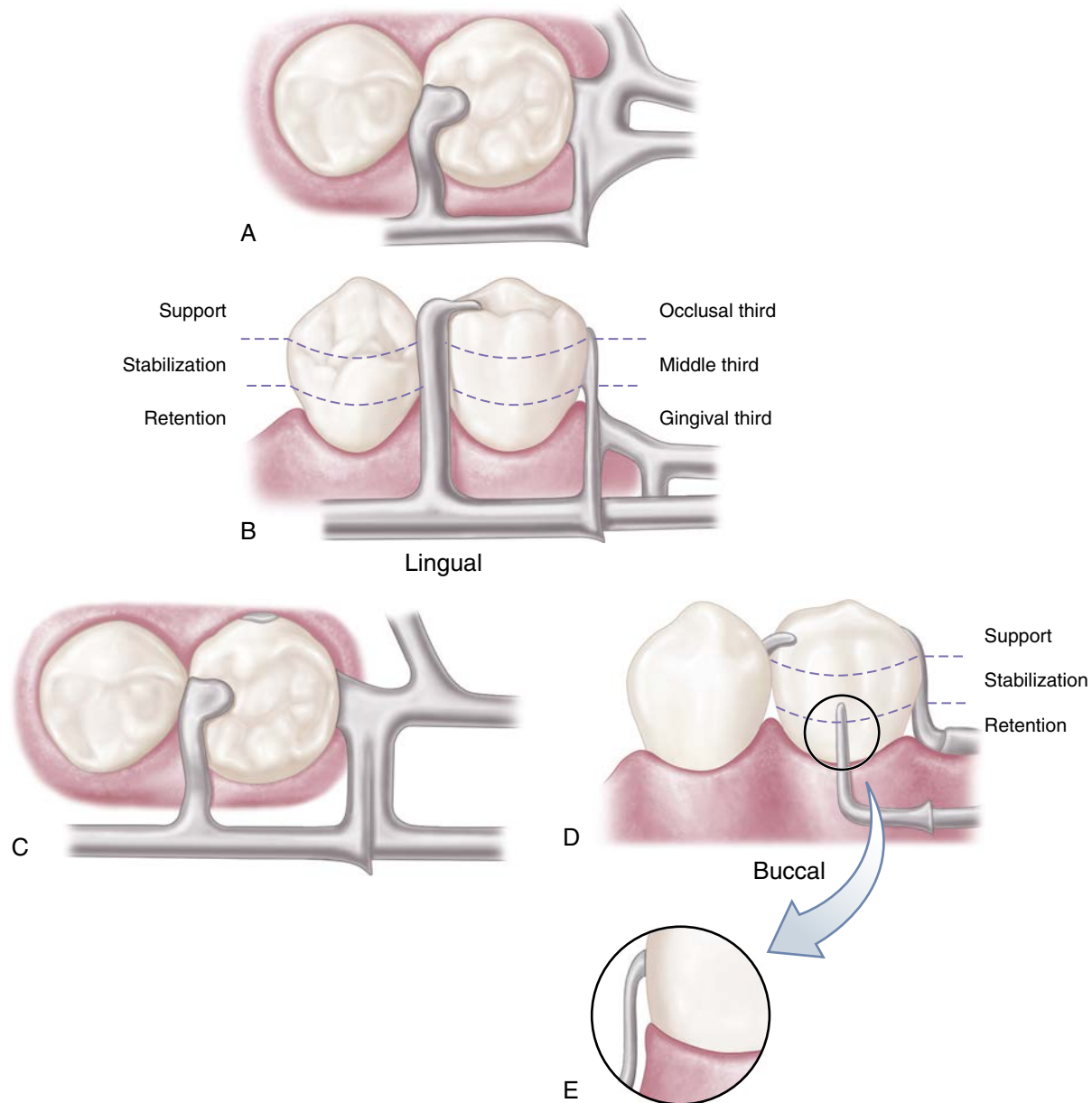
**FIGURE 7-8** Extracoronal circumferential direct retainer. Assembly consists of the buccal retentive arm (A); the rigid lingual stabilizing (reciprocal) arm (B); and the supporting occlusal rest (C). The terminal portion of the retentive arm is flexible and engages measured undercut. Assembly remains passive until activated by placement or removal of the restoration, or when subjected to masticatory forces that tend to dislodge the denture base.



**FIGURE 7-10** The auxiliary occlusal rest (*mirror view*) may be used rather than the reciprocal clasp arm without violating any principle of clasp design. Its greatest disadvantages are that the second rest seat must be prepared and that enclosed tissue space at the gingival margin can result in a food trap. The auxiliary occlusal rest is also sometimes used to prevent slippage when the principal occlusal rest seat cannot be inclined apically from the marginal ridge. Minor connectors used to close the interproximal space most often require rests on adjacent teeth to avoid a wedging effect when force is placed on the denture.



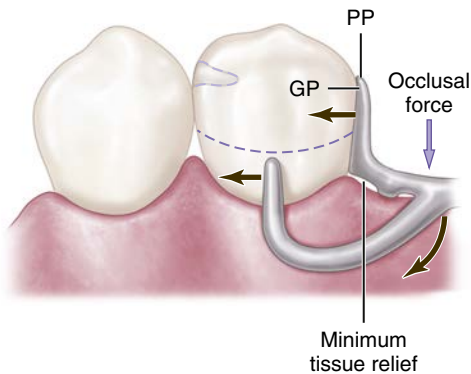
**FIGURE 7-9** Extracoronal bar-type direct retainer. Assembly consists of the buccal retentive arm engaging the measured undercut (A) (with slight occlusal extension for stabilization [see insert]); the stabilizing (reciprocal) elements, with the proximal plate minor connector on the distal (B); the lingually placed mesial minor connector for the occlusal rest, which also serves as a stabilizing (reciprocal) component (C); and the mesially placed supporting occlusal rest (D). Assembly remains passive until activated. HOC, Height of contour; UC, undercut.



**FIGURE 7-11** Bar-type clasp assembly. **A**, Occlusal view. Component parts (proximal plate minor connector, rest with minor connector, and retentive arm) tripod the abutment to prevent its migration. **B**, The proximal plate minor connector extends just far enough lingually so that it combines with the mesial minor connector to prevent lingual migration of the abutment. **C**, On narrow or tapered abutments (mandibular first premolars), the proximal plate should be designed to be as narrow as possible but still sufficiently wide to prevent lingual migration. **D**, I-bar retainer located at greatest prominence of tooth in the gingival third. **E**, Mesial view of I-bar illustrating the retentive tip relationship to the undercut and a region superior to the height of contour, which serves a stabilization function in encirclement.

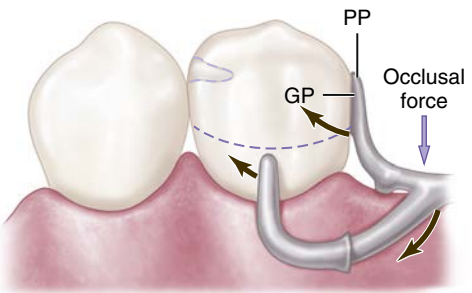
(Figure 7-11, A). A distal guiding plane, extending from the marginal ridge to the junction of the middle and gingival thirds of the abutment tooth, is prepared to receive a proximal plate (see Figure 7-11, B). The buccolingual width of the guiding plane is determined by the proximal contour of the tooth (see Figure 7-11, A and C). The proximal plate, in conjunction with the minor connector supporting the rest, provides the stabilizing and reciprocal aspects of the clasp assembly. The I-bar should be located in the gingival third of the buccal or labial surface

of the abutment in a 0.01-inch undercut (see Figure 7-11, D). The whole arm of the I-bar should be tapered to its terminus, with no more than 2 mm of its tip contacting the abutment. The retentive tip contacts the tooth from the undercut to the height of contour (see Figure 7-11, E). This area of contact, along with the rest and proximal plate contact, provides stabilization through encirclement (see Figure 7-11, C). The horizontal portion of the approach arm must be located at least 4 mm from the gingival margin and even farther if possible.

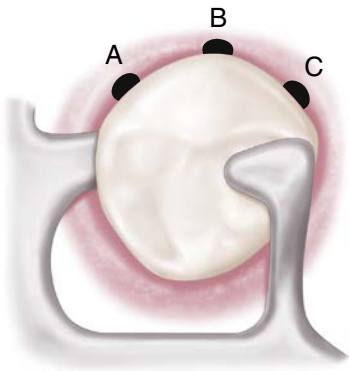


**FIGURE 7-12** Bar clasp assembly in which the guiding plane (GP) and the corresponding proximal plate (PP) extend the entire length of the proximal tooth surface. Physiologic relief is required to prevent impingement of the gingival tissues during function. Extending the proximal plate to contact a greater surface area of the guide plane directs functional forces in a horizontal direction, thus the teeth are loaded to a greater extent than the edentulous ridge.

Three basic approaches to the application of the RPI system may be used. The location of the rest, the design of the minor connector (proximal plate) as it relates to the guiding plane, and the location of the retentive arm are factors that influence how this clasp system functions. Variations in these factors provide the basis for differences among these approaches. All advocate the use of a rest located mesially on the primary abutment tooth adjacent to the extension base area. One approach recommends that the guiding plane and the corresponding proximal plate minor connector should extend the entire length of the proximal tooth surface, with physiologic tissue relief eliminating impingement of the free gingival margin (Figure 7-12). A second approach suggests that the guiding plane and the corresponding proximal plate minor connector should extend from the marginal ridge to the junction of the middle and gingival thirds of the proximal tooth surface (Figure 7-13). Both approaches recommend that the retaining clasp arm should be located in the gingival third of the buccal or labial surface of the abutment in a 0.01-inch undercut. Placement of the retaining clasp arm generally occurs in an undercut located at the greatest mesiodistal prominence of the tooth or adjacent to the extension base area (Figure 7-14, A and B). The third approach favors a proximal plate minor connector that contacts approximately 1 mm of the gingival portion of the guiding plane (Figure 7-15, A) and a retentive clasp arm located in a 0.01-inch undercut in the gingival third of the tooth at the greatest prominence or toward the mesial away from the edentulous area (see Figure 7-14, C). If the abutment teeth demonstrate contraindications for a bar-type clasp (i.e., exaggerated buccal or lingual tilts, severe tissue undercut, or a shallow buccal vestibule) and the desirable undercut is located in the gingival third of the tooth away from the extension base area, a modification should be considered for the RPI system (the RPA clasp) (see Figure 7-15, B). Application of each approach is predicated on the distribution of load to be applied to the tooth and edentulous ridge.



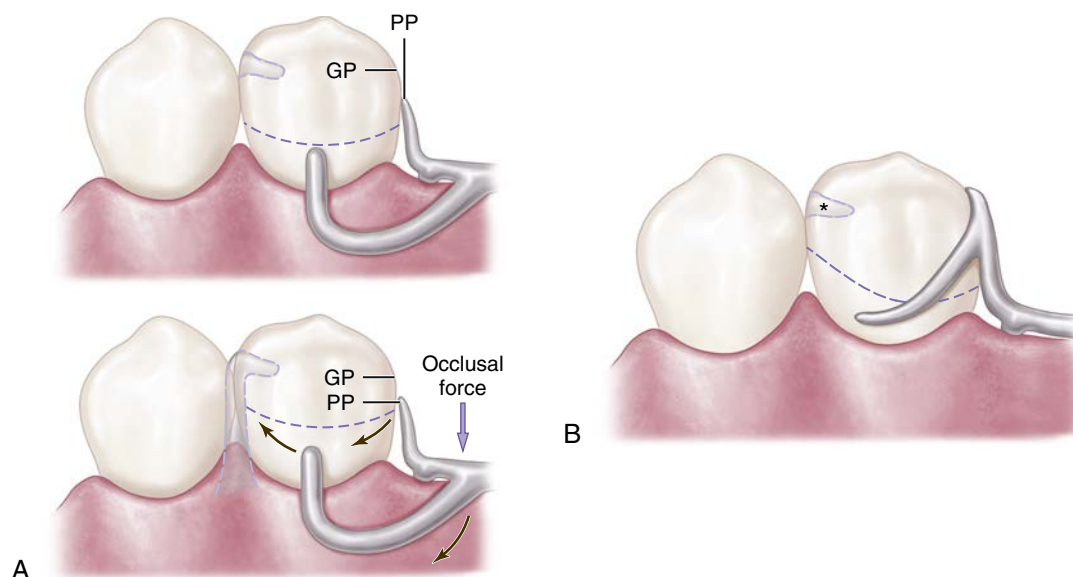
**FIGURE 7-13** Bar clasp assembly in which the guiding plane (GP) and the corresponding proximal plate (PP) extend from the marginal ridge to the junction of the middle and gingival thirds of the proximal tooth surface. This decrease (compared with Figure 7-23) in amount of surface area contact of the proximal plate on the guiding plane more evenly distributes functional force between the tooth and the edentulous ridge.



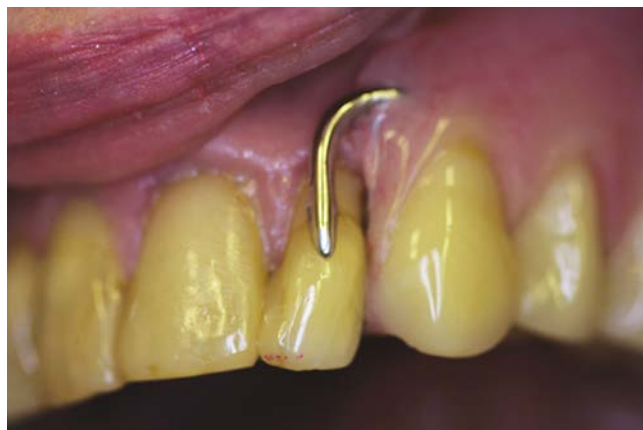**FIGURE 7-14** Occlusal view of the rest, proximal plate, and I-bar (RPI) component parts bar clasp assembly. Placement of the I-bar in a 0.01-inch undercut on the distobuccal surface (A); at the greatest mesiodistal prominence (B); and on the mesiobuccal surface (C).

The bar clasp, which gave rise to the RPI, is discussed here because of this association. It may not be configured to allow functional movement, but it can be. The term *bar clasp* is generally preferred over the less descriptive term *Roach clasp arm*. Reduced to its simplest term, the *bar clasp arm* arises from the denture framework or a metal base and approaches the retentive undercut from a gingival direction (see Figure 7-11). The bar clasp arm has been classified by the shape of the retentive terminal. Thus it has been identified as a T, modified T, I, or Y. The form the terminal takes is of little significance as long as it is mechanically and functionally effective, covers as little tooth surface as possible, and displays as little metal as possible.

In most situations, the bar clasp arm can be used with tooth-supported partial dentures, with tooth-supported modification areas, or when an undercut that can be logically approached with a bar clasp arm lies on the side of an abutment tooth adjacent to a distal extension base (Figure 7-16). If a tissue undercut prevents the use of a bar clasp arm, a mesially originating ring clasp, a cast, or a wrought-wire clasp or reverse-action clasp may be used. Preparation of adjacent



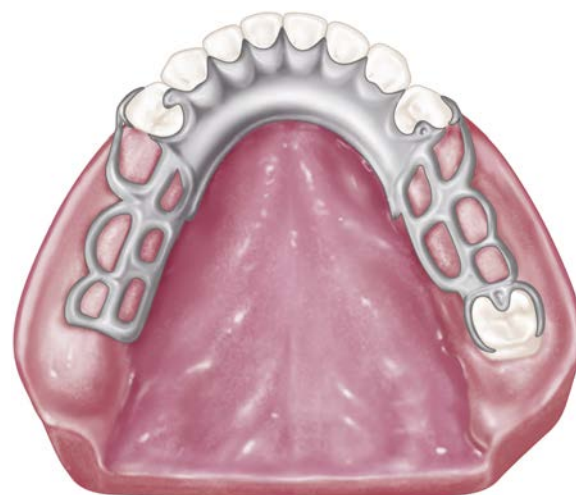**FIGURE 7-15** A, Bar clasp assembly in which the proximal plate (PP) contacts approximately 1 mm of the gingival portion of the guiding plane (GP). During function, the proximal plate and the I-bar clasp arm are designed to move in a mesiogingival direction, disengaging the tooth. Lack of sustained contact between the proximal plate and the guiding plane distributes increased functional force to the edentulous ridge. The asterisk (\*) indicates center of rotation. B, Modification of the rest, proximal plate, and I-bar (RPI) component parts system; rest, proximal plate, Akers (RPA) clasp is indicated when a bar-type clasp is contraindicated and a desirable undercut is located in the gingival third of the tooth away from the extension base area.



**FIGURE 7-16** Bar clasp arm properly used on the terminal abutment. The combination of rest, proximal plate, and bar clasp contacting the abutment tooth provides more than 180 degrees encirclement. A uniform taper to the bar ensures proper flexibility and internal stress distribution. Taper can originate from the minor connector junction or at a finishing line indicating the anterior extent of the denture base. Encirclement does not require that retentive tip modification (in the form of a T) be provided, and such a modification adds little to the clasp assembly.

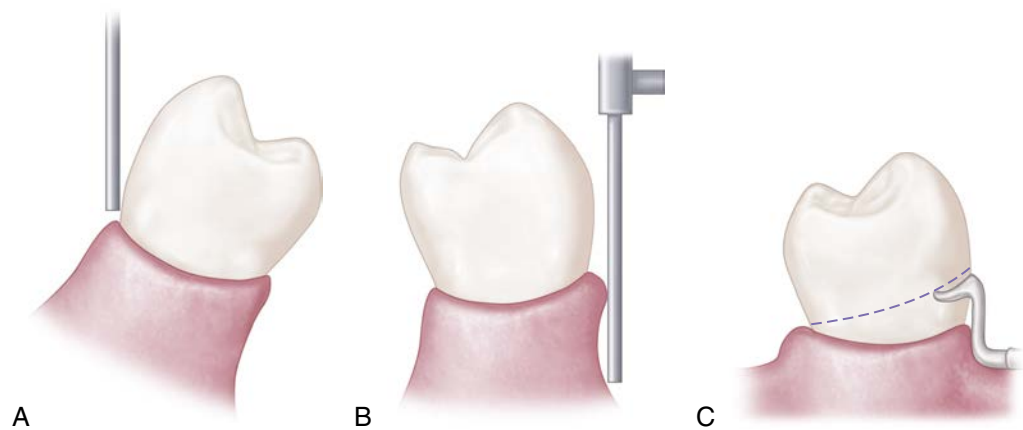
abutments (natural teeth) to receive any type of interproximal direct retainer, traversing from lingual to buccal surfaces, is most difficult to adequately accomplish. Inevitably the relative size of the occlusal table is increased, contributing to undesirable and additional functional loading.

Specific indications for use of a bar clasp arm include (1) when a small degree of undercut (0.01 inch) exists

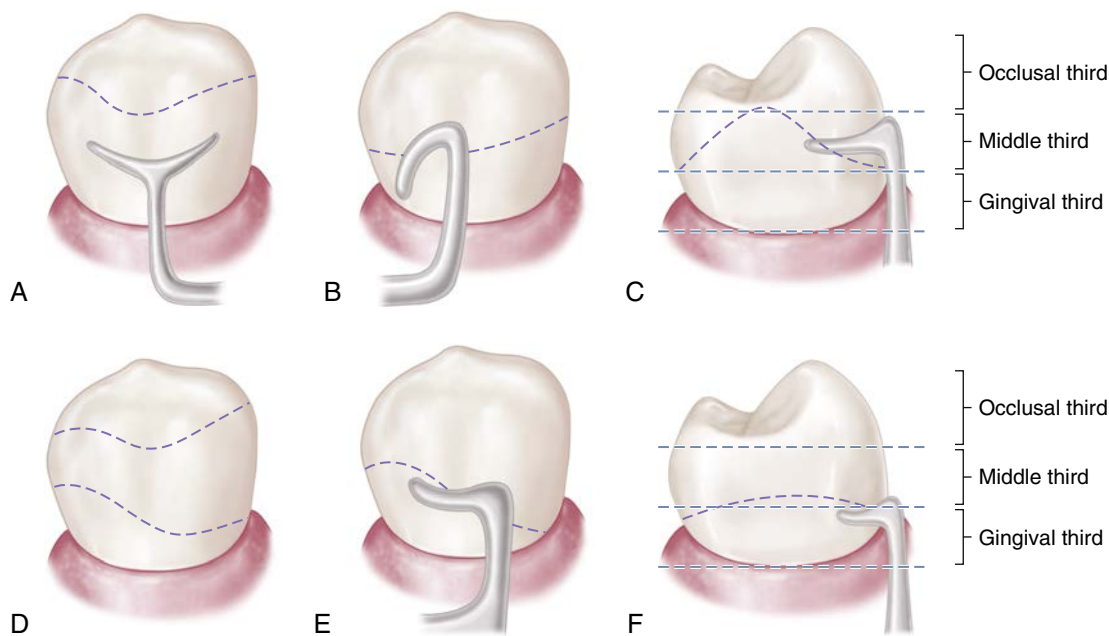


**FIGURE 7-17** A bar retainer is used on the anterior abutment of the modification space, and its terminus engages the distobuccal undercut. The denture is designed to rotate around the terminal abutments when force is directed toward the basal seat on the left. Such rotation would impart force on the right premolar directed superiorly and anteriorly. However, this direction of force is resisted in great part by mesial contact with the canine. A direct retainer on the right premolar engaging the mesiobuccal undercut would tend to force the tooth superiorly and posteriorly.

in the cervical third of the abutment tooth, which may be approached from a gingival direction, (2) on abutment teeth for tooth-supported partial dentures or tooth-supported modification areas (Figure 7-17), (3) in distal



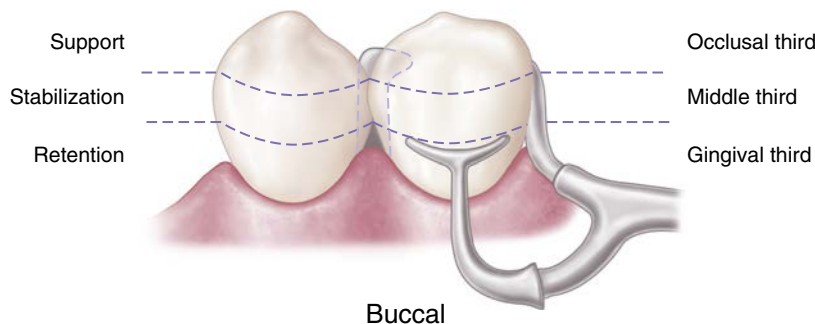
**FIGURE 7-18** Contraindications for selection of bar-type clasps. **A**, Severe buccal or lingual tilts of abutment teeth. **B**, Severe tissue undercuts. **C**, Shallow buccal or labial vestibules.



**FIGURE 7-19** Common errors and recommended corrections in the design of bar-type clasp assemblies. **A**, Survey line unsuitable for the bar clasp (too high). **B**, Retentive portion of the bar clasp arm improperly contoured to resist dislodging force in the occlusal direction. **C**, Retentive tip not located in the gingival third of the abutment. **D**, Contour of abutment correctly altered to receive bar clasp. **E** and **F**, Correct position of bar clasp assembly.

extension base situations, and (4) in situations in which esthetic considerations must be accommodated and a cast clasp is indicated. Thus use of the bar clasp arm is contraindicated when a deep cervical undercut exists or when a severe tooth and/or tissue undercut exists, either of which must be bridged by excessive blockout. When severe tooth and tissue undercuts exist, a bar clasp arm usually is an annoyance to the tongue and cheek and may traps food debris. Other limiting factors in the selection of a bar clasp assembly include a shallow vestibule or an excessive buccal or lingual tilt of the abutment tooth (Figure 7-18). Some common errors in the design of bar-type clasps are illustrated in Figure 7-19.

The bar clasp arm is not a particularly flexible clasp arm because of the effects of its half-round form and its several planes of origin. Although the cast circumferential clasp arm can be made more flexible than the bar clasp arm, the combination clasp is preferred for use on terminal abutments when torque and tipping are possible, because of engagement of an undercut away from the distal extension base. Situations often exist, however, in which a bar clasp arm may be used to advantage without jeopardizing a terminal abutment. A bar clasp arm swinging distally into the undercut may be a logical choice, because movement of the clasp on the abutment as the distal extension base moves tissue-ward is minimized by the distal location of the clasp terminal.



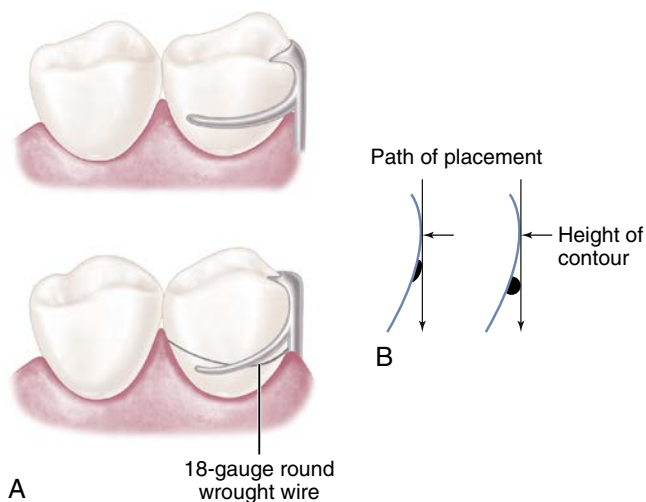
**FIGURE 7-20** Only one terminal of the retentive arm engages the undercut in the gingival third of the abutment. The suprabulge portion of the retentive clasp arm provides only limited stabilization and may be eliminated.

Some advantages attributed to the infrabulge clasp are (1) its interproximal location, which may be used to esthetic advantage; (2) increased retention without tipping action on the abutment; and (3) less chance of accidental distortion resulting from its proximity to the denture border. The wearer should be meticulous in the care of a denture so made, not only for reasons of oral hygiene but also to prevent cariogenic debris from being held against tooth surfaces.

The T and Y clasp arms are the most frequently misused. It is unlikely that the full area of a T or Y terminal is ever necessary for adequate clasp retention. Although the larger area of contact would provide greater frictional resistance, this is not true clasp retention, and only that portion engaging an undercut area should be considered retentive. Only one terminal of such a clasp arm should be placed in an undercut area (Figure 7-20). The remainder of the clasp arm may be superfluous unless it is needed as part of the clasp assembly to encircle the abutment tooth by more than 180 degrees at its greatest circumference. If the bar clasp arm is made to be flexible for retentive purposes, any portion of the clasp above the height of contour provides only limited stabilization, because it is also part of the flexible arm. Therefore in many instances, this suprabulge portion of a T or Y clasp arm may be removed, and the retentive terminal of the bar clasp should be designed to be biologically and mechanically sound rather than to conform to any alphabetical configuration.

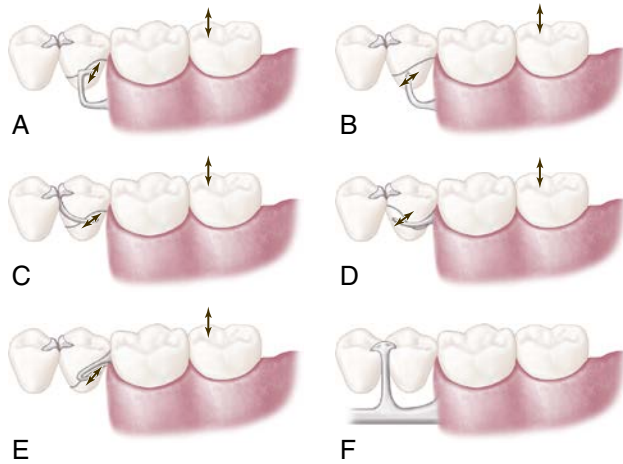
### Combination Clasp

Another strategy that may be used to reduce the effect of the Class I lever in distal extension situations includes a flexible component in the “resistance arm;” this strategy is employed in the combination clasp. The combination clasp consists of a wrought-wire retentive clasp arm and a cast reciprocal clasp arm (Figure 7-21). Although the latter may be seen in the form of a bar clasp arm, it is usually a circumferential arm. The retentive arm is almost always circumferential, but it also may be used in the manner of a bar, originating gingivally from the denture base.



**FIGURE 7-21** **A**, A combination clasp consists of a cast reciprocal arm and a tapered, round wrought-wire retentive clasp arm. The latter is cast to, or soldered to, a cast framework. This design is recommended for the anterior abutment of the posterior modification space in a Class II partially edentulous arch, where only a mesiobuccal undercut exists, to minimize the effects of a first-class lever system. **B**, In addition to the advantages of flexibility, adjustability, and appearance, a wrought-wire retentive arm makes only line contact with the abutment tooth, rather than broader contact with the cast clasp.

Advantages of the combination clasp include its flexibility and adjustability and the appearance of the wrought-wire retentive arm. It is used when maximum flexibility is desirable, such as on an abutment tooth adjacent to a distal extension base or on a weak abutment when a bar-type direct retainer is contraindicated. It may be used for its adjustability when precise retentive requirements are unpredictable and later adjustment to increase or decrease retention may be necessary. A third justification for its use is its esthetic advantage over cast clasps. Wrought in structure, it may be used in smaller diameters than a cast clasp, with less danger of fracture. Because it is round, light is reflected in such a manner that the display of metal is less noticeable than with the broader surfaces of a cast clasp.



**FIGURE 7-22** Five types of extracoronal direct retainer assemblies that may be used on abutments adjacent to the distal extension base to avoid or minimize the effects of the cantilever design. Arrows indicate the general direction of movement of retentive tips of retainer arms when the denture base rotates toward and away from the edentulous ridge. **A**, Distobuccal undercut engaged by one-half T-type bar clasp. The portion of the clasp arm on and above the height of contour might afford some stabilization against horizontal rotation of the denture base. **B**, I-bar placed in undercut at the middle (anteroposteriorly) of the buccal surface. This retainer contacts the tooth only at its tip. Note that the guiding plane on the distal aspect of the abutment is contacted by the metal of the denture framework, and that a mesial rest is used. **C**, Interproximal ring clasp engaging the distobuccal undercut. Bar-type retainer cannot be used because of tissue undercuts inferior to the buccal surface of the abutment. **D**, Round, uniformly tapered 18-gauge wrought-wire circumferential retainer arm engaging the mesiobuccal undercut. A wrought-wire arm, instead of a cast arm, should be used in this situation because of the ability of wrought wire to flex omnidirectionally. A cast half-round retainer arm would not flex edgewise, which could result in excessive stress on the tooth when rotation of the denture base occurs. **E**, A hairpin clasp may be used when the undercut lies cervical to the origin of the retainer arm. Both hairpin and interproximal ring clasps may be used to engage the distobuccal undercut on the terminal abutment of the distal extension denture. However, the distobuccal undercut on the terminal abutment should be engaged by a bar-type clasp in the absence of a large buccal tissue undercut cervical to the terminal abutment. Hairpin and interproximal ring clasps are the least desirable of the clasping situations illustrated here. **F**, Lingual view shows the use of double occlusal rests, connected to the lingual bar by the minor connector in illustrated designs. This design eliminates the need for a lingual clasp arm, places the fulcrum line anteriorly to make better use of the residual ridge for support, and provides stabilization against horizontal rotation of the denture base.

The most common use of the combination clasp is on an abutment tooth adjacent to a distal extension base where only a mesial undercut exists on the abutment or where a large tissue undercut contraindicates a bar-type retainer (Figure 7-22). When a distal undercut exists that may be approached with a properly designed bar clasp arm or with a

ring clasp (despite its several disadvantages), a cast clasp can be located so that it will not cause abutment tipping as the distal extension base moves tissue-ward. When the undercut is on the side of the abutment away from the extension base, the tapered wrought-wire retentive arm offers greater flexibility than does the cast clasp arm and therefore better dissipates functional stresses. For this reason, the combination clasp is preferred (see Figure 7-22, D).

The combination clasp has several disadvantages: (1) it involves extra steps in fabrication, particularly when high-fusing chromium alloys are used; (2) it may be distorted by careless handling on the part of the patient; (3) because it is bent by hand, it may be less accurately adapted to the tooth and therefore may provide less stabilization in the supra-bulge portion; and (4) it may distort with function and not engage the tooth. The disadvantages of the wrought-wire clasp are offset by its several advantages, which include (1) its flexibility; (2) its adjustability; (3) its esthetic advantage over other retentive circumferential clasp arms; (4) coverage of a minimum of tooth surface as a result of its line contact with the tooth, rather than having the surface contact a cast clasp arm; and (5) a less likely occurrence of fatigue failure in service with the tapered wrought-wire retentive arm versus the cast, half-round retentive arm.

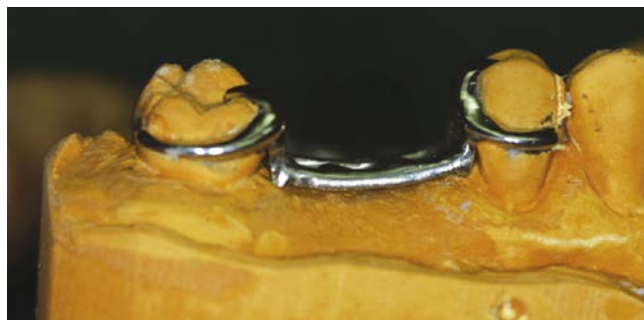The disadvantages listed previously should not prevent its use regardless of the type of alloy that is used for the cast framework. Technical problems are minimized by selecting the best wrought wire for this purpose, then casting to it or soldering it to the cast framework. Selection of wrought wire, attachment of it to the framework, and subsequent laboratory procedures to maintain its optimum physical properties are presented in Chapter 13.

The patient may be taught to avoid distortion of the wrought wire by the explanation that to remove a partial denture, the fingernail should always be applied to its point of origin, where it is held rigid by the casting, rather than to the flexible terminal end. Often, lingual retention may be used rather than buccal retention, especially on a mandibular abutment, so that the patient never touches the wrought-wire arm during removal of the denture. Instead, removal may be accomplished by lifting against the cast reciprocal arm located on the buccal side of the tooth. This may negate the esthetic advantage of the wrought-wire clasp arm, and esthetics should be given preference when the choice must be made between buccal and lingual retention. In most situations, however, retention must be used where it is possible, and the clasp designed accordingly.

### Clasps Designed Without Movement Accommodation

#### Circumferential Clasp

Although a thorough knowledge of the principles of clasp design should lead to a logical application of those principles, it is better when some of the more common clasp designs are considered individually. The circumferential clasp will be considered first as an all-cast clasp.



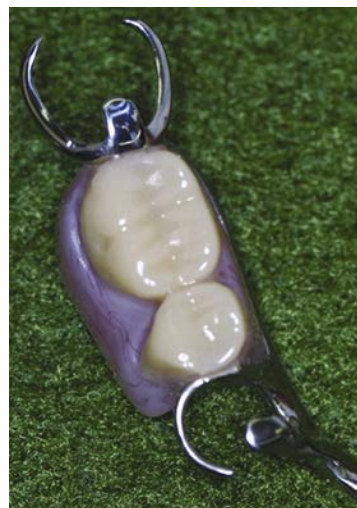**FIGURE 7-23** Cast circumferential retentive clasp arms properly designed. They originate on or occlusal to the height of contour, which they then cross in their terminal third, and engage retentive undercuts progressively as their taper decreases and their flexibility increases.

The circumferential clasp is usually the most logical clasp to use with all tooth-supported partial dentures because of its retentive and stabilizing ability (Figure 7-23). Only when the retentive undercut may be approached better with a bar clasp arm or when esthetics will be enhanced should the latter be used. The circumferential clasp arm has the following disadvantages:

1. More tooth surface is covered than with a bar clasp arm because of its occlusal origin.
2. On some tooth surfaces, particularly the buccal surfaces of mandibular teeth and the lingual surfaces of maxillary teeth, its occlusal approach may increase the width of the occlusal surface of the tooth.
3. In the mandibular arch, more metal may be displayed than with the bar clasp arm.
4. As with all cast clasps, its half-round form prevents adjustment to increase or decrease retention. Adjustments in the retention afforded by a cast clasp arm should be made by moving a clasp terminal cervically into the angle of cervical convergence or occlusally into a lesser area of undercut. Tightening a clasp against the tooth or loosening it away from the tooth increases or decreases frictional resistance and does not affect the retentive potential of the clasp. True adjustment is, therefore, impossible with most cast clasps.

Despite its disadvantages, the cast circumferential clasp arm may be used effectively, and many of these disadvantages may be minimized by mouth preparation. Adequate mouth preparation will permit its point of origin to be placed far enough below the occlusal surface to avoid poor esthetics and increased tooth dimension (see Figure 7-23). Although some of the disadvantages listed imply that the bar-type clasp may be preferable, the circumferential clasp is actually superior to a bar clasp arm that is improperly used or poorly designed.

Experience has shown that faulty application and design too often negate the possible advantages of the bar clasp arm, whereas the circumferential clasp arm is not as easily misused.

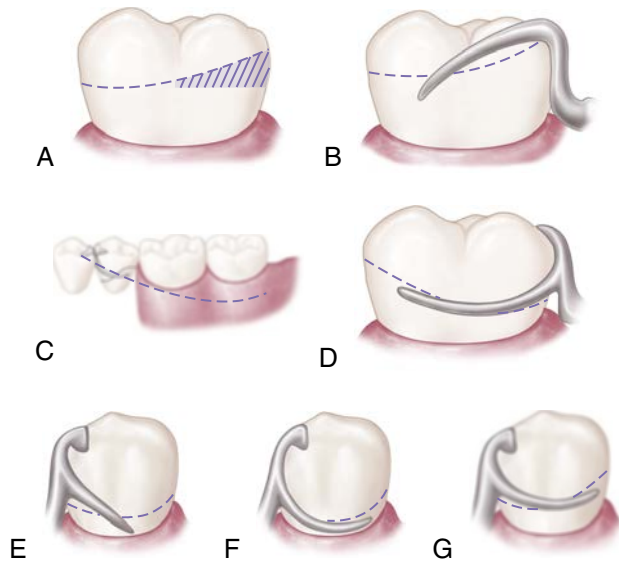


**FIGURE 7-24** Cast circumferential retentive clasp arm.

The basic form of the circumferential clasp is a buccal and lingual arm originating from a common body (Figure 7-24). This clasp is used improperly when two retentive clasp arms originate from the body and occlusal rest areas and approach bilateral retentive areas on the side of the tooth away from the point of origin. The correct form of this clasp has only one retentive clasp arm, opposed by a nonretentive reciprocal arm on the opposite side. A common error is to use this clasp improperly by making both clasp terminals retentive. This not only is unnecessary but also disregards the need for reciprocation and bilateral stabilization. Other common errors in the design of circumferential clasps are illustrated in Figure 7-25.

**Ring Clasp.** The circumferential type of clasp may be used in several forms. It appears as though many of these forms of the basic circumferential clasp design were developed to accommodate situations in which corrected tooth modifications could not be or were not accomplished by the dentist. One is the ring clasp, which encircles nearly all of a tooth from its point of origin (Figure 7-26). It is used when a proximal undercut cannot be approached by other means. For example, when a mesiolingual undercut on a lower molar abutment cannot be approached directly because of its proximity to the occlusal rest area and cannot be approached with a bar clasp arm because of lingual inclination of the tooth, the ring clasp encircling the tooth allows the undercut to be approached from the distal aspect of the tooth.

The clasp should never be used as an unsupported ring (Figure 7-27) because if it is free to open and close as a ring, it cannot provide reciprocation or stabilization. Instead the ring-type clasp should always be used with a supporting strut on the nonretentive side, with or without an auxiliary occlusal rest on the opposite marginal ridge. The advantage of an auxiliary rest is that further movement of a mesially inclined tooth is prevented by the presence of a distal rest. In any event, the supporting strut should be regarded as a minor connector from which the flexible retentive arm originates. Reciprocation



**FIGURE 7-25** Some improper applications of circumferential clasp design and their recommended corrections. **A**, Tooth with undesirable height of contour in its occlusal third. **B**, Unsuitable contour and location of retentive clasp arm on an unmodified abutment. **C**, More favorable height of contour achieved by modification of the abutment. **D**, Retentive clasp arm properly designed and located on a modified abutment. **E**, Unsuitable contour and location of the retentive arm in relation to the height of contour (straight arm configuration provides poor approach to the retentive area and is less resistant to dislodging force). **F**, Terminal portion of the retentive clasp arm located too close to the gingival margin. **G**, Clasp arm that is properly designed and located.

then comes from the rigid portion of the clasp lying between the supporting strut and the principal occlusal rest.

The ring-type clasp should be used on protected abutments, whenever possible, because it covers such a large area of tooth surface. Esthetics need not be considered on such a posteriorly located tooth.

A ring-type clasp may be used in reverse on an abutment located anterior to a tooth-bounded edentulous space (Figure 7-28). Although potentially an effective clasp, this clasp covers an excessive amount of tooth surface and can be esthetically objectionable. The only justification for its use is when a distobuccal or distolingual undercut cannot be approached directly from the occlusal rest area and/or tissue undercuts prevent its approach from a gingival direction with a bar clasp arm.

**Embrasure Clasp.** In the fabrication of an unmodified Class II or Class III partial denture, no edentulous spaces are available on the opposite side of the arch to aid in clasping. Mechanically, this is a disadvantage. However, when the teeth are sound and retentive areas are available, or when multiple restorations are justified, clasping can be accomplished by means of an embrasure clasp (Figure 7-29).

Sufficient space must be provided between the abutment teeth in their occlusal third to make room for the common

body of the embrasure clasp (Figure 7-30), yet the contact area should not be eliminated entirely. Historically, this clasp assembly demonstrates a high percentage of fracture caused by inadequate tooth preparation in the contact area. Because vulnerable areas of the teeth are involved, abutment protection with inlays or crowns is recommended. The decision to use unprotected abutments must be made at the time of oral examination and should be based on the patient's age, caries index, and oral hygiene, as well as on whether existing tooth contours are favorable or can be made favorable by tooth modification. Preparation of adjacent, contacting, uncrowned abutments to receive any type of embrasure clasp of adequate interproximal bulk is difficult, especially when it is opposed by natural teeth.

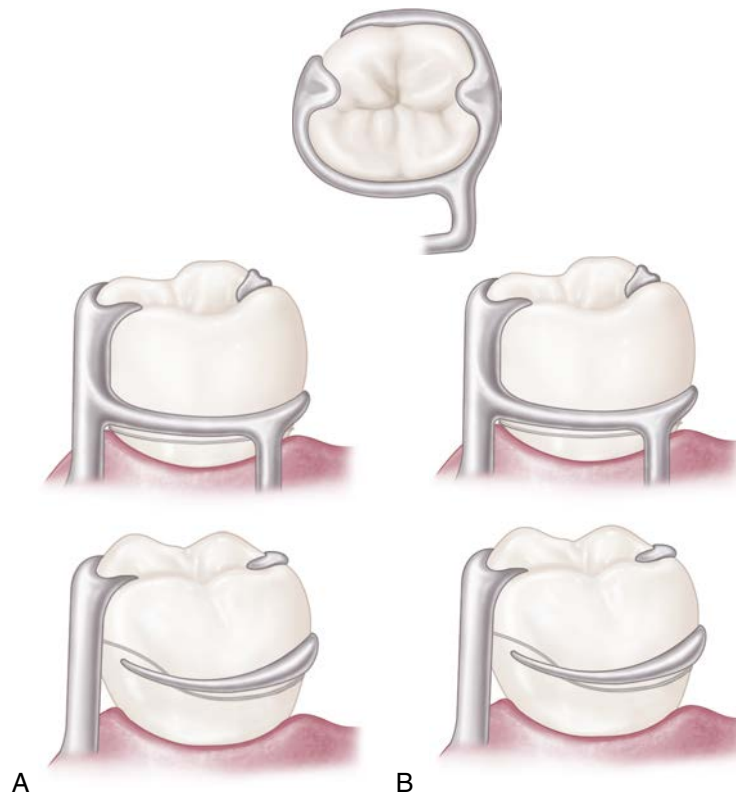
The embrasure clasp always should be used with double occlusal rests, even when definite proximal shoulders can be established (Figure 7-31). This is done to avoid interproximal wedging by the prosthesis, which could cause separation of the abutment teeth, resulting in food impaction and clasp displacement. In addition to providing support, occlusal rests serve to shunt food away from contact areas. For this reason, occlusal rests should always be used whenever food impaction is possible.

Embrasure clasps should have two retentive clasp arms and two reciprocal clasp arms that are bilaterally or diagonally opposed. An auxiliary occlusal rest or a bar clasp arm can be substituted for a circumferential reciprocal arm, as long as definite reciprocation and stabilization result. A lingually placed retentive bar clasp arm may be substituted if a rigid circumferential clasp arm is placed on the buccal surface for reciprocation, provided lingual retention is used on the opposite side of the arch. Other less commonly used modifications of the cast circumferential clasp that are of historical interest are the multiple clasp, the half-and-half clasp, and the reverse-action clasp.

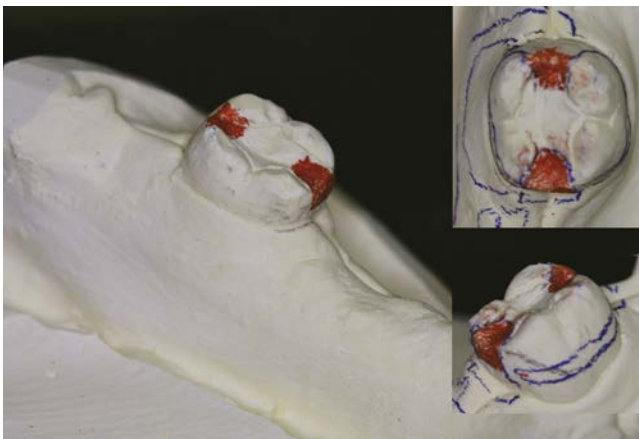
## IMPLANTS AS DIRECT RETAINERS

As was stated earlier, in situations where support requirements are adequately met by available oral tissues, dental implants can be used for retention and provide the advantage of eliminating a visible clasp. The unique aspect of implant use with removable partial dentures is that their location generally can be prescribed, meaning that the clinician selects the best location. The location within the modification space must first consider anatomic characteristics of bone availability. It would not be a great advantage to a patient if extensive augmentation procedures were required to allow implant placement in conjunction with a removable partial denture.

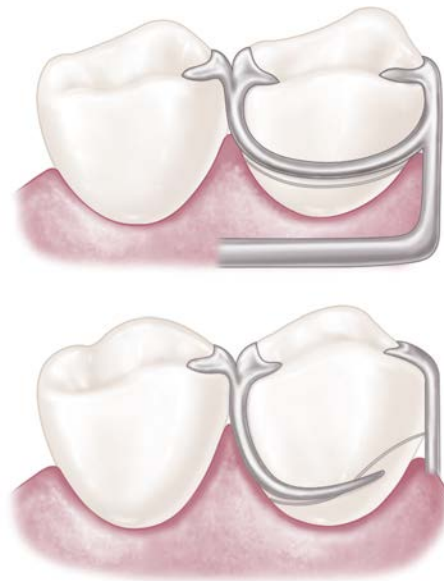If anatomic needs are met, placement of an implant within a modification space to the advantage of retentive needs requires consideration of anterior, mid, or distal placement. Because retainers utilizing teeth have always been restricted to tooth locations at either end of a span, the mid-span location typically is not considered. However, the application of



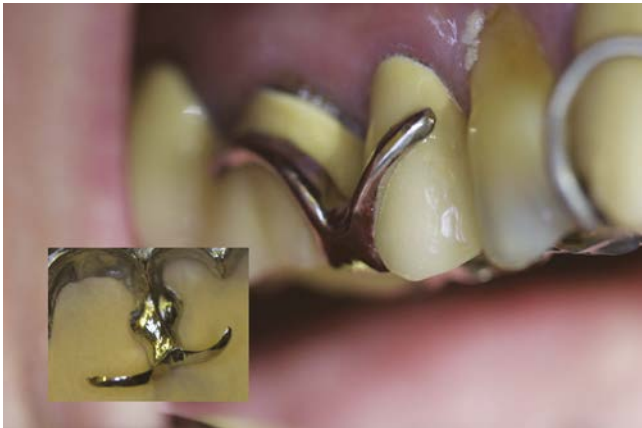**FIGURE 7-26** Ring clasp(s) encircling nearly all of the tooth from its point of origin. **A**, Clasp originates on the mesiobuccal surface and encircles the tooth to engage the mesiolingual undercut. **B**, Clasp originates on the mesiolingual surface and encircles the tooth to engage the mesiobuccal undercut. In either example, a supporting strut is used on the nonretentive side (*drawn both as direct view of near side of tooth and as mirror view of opposite side*).



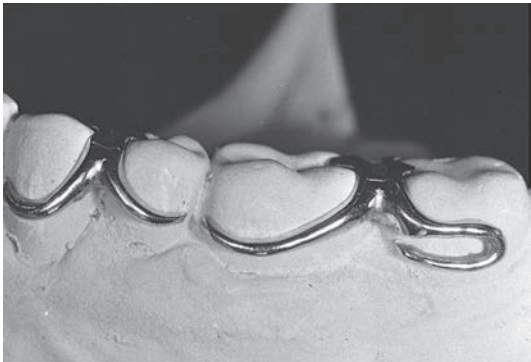**FIGURE 7-27** Improperly designed ring clasp lacking necessary support. Such a clasp lacks any reciprocating or stabilizing action because the entire circumference of the clasp is free to open and close. A supporting strut should always be added on the nonretentive side of the abutment tooth, which then becomes, in effect, a minor connector from which a tapered and flexible retentive clasp arm originates.



**FIGURE 7-28** Ring clasp may be used in reverse on the abutment located anterior to the tooth-bound edentulous space.



**FIGURE 7-29** Embrasure clasps extend through occlusal embrasures to engage facial undercuts when no modification spaces are present.

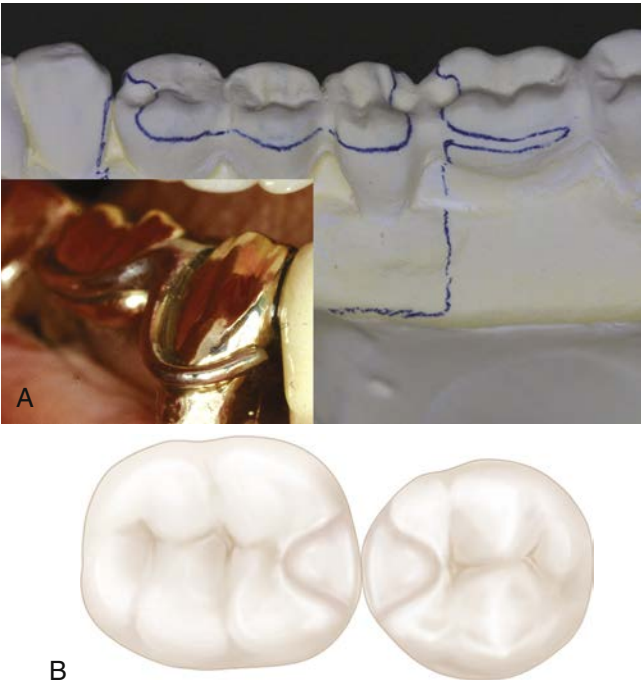


**FIGURE 7-30** Embrasure and hairpin circumferential retentive clasp arms. The terminus of each engages a suitable retentive undercut. Use of a hairpin-type clasp on the second molar is made necessary by the fact that the only available undercut lies directly below the point of origin of the clasp arm.

implants allows consideration of where the most beneficial location of retention can be provided, which forces consideration of where the most efficient resistance to movement away from the denture base can be provided. Placement at either extreme of the denture base may allow greater movement than placement at a midpoint and should be taken into consideration.

**ANALYSIS OF TOOTH CONTOURS FOR RETENTIVE CLASPS**

Although the extracoronal, or clasp-type, direct retainer is used more often than the internal attachment, it is commonly misused. It is hoped that a better understanding of the principles of clasp design will lead to more intelligent use of this retainer. To best gain this understanding, it is vitally important for the clinician to consider how tooth contour and removable partial denture components must interact (be related) to allow stable prosthetic function.



**FIGURE 7-31** **A**, Example of the use of an embrasure clasp for a Class II partially edentulous arch. Embrasure clasp on the two left molar abutments was used in the absence of posterior modification space. **B**, Occlusal and proximal surfaces of adjacent molar and premolar prepared for embrasure clasp. Note that rest seat preparations are extended both buccally and lingually to accommodate the retentive and reciprocal clasp arms. Adequate preparation confined to the enamel can rarely be accomplished for such a clasp, especially when clasped teeth are opposed by natural teeth.

Just as unaltered natural teeth are not appropriately contoured to receive fixed partial dentures without preparation, the teeth that are engaged by a removable partial denture must be contoured to support, stabilize, and retain the functioning prosthesis. Analysis and accomplishment of tooth modification when it is required for optimum stability and retention are necessary for the success of the prosthesis.

Critical areas of an abutment that provide for retention and stabilization (reciprocation) can be identified only with the use of a dental cast surveyor (Table 7-1). To enhance the understanding of direct retainers, an introduction of the dental cast surveyor is appropriate at this time. Surveying will be covered in detail in Chapter 11.

The cast surveyor (Figure 7-32) is a simple instrument that is essential for planning partial denture treatment. Its main working parts are the vertical arm and the adjustable table, which hold the cast in a fixed relation to the vertical arm. This relationship of the vertical arm to the cast represents the path of placement that the partial denture will ultimately take when inserted or removed from the mouth (Figure 7-33).

The adjustable table may be tilted in relation to the vertical arm of the surveyor until a path can be found that best

TABLE 7-1

Function and Position of Clasp Assembly Parts

Component Part	Function	Location
Rest	Support	Occlusal, lingual, incisal
Minor connector	Stabilization	Proximal surfaces extending from a prepared marginal ridge to the junction of the middle and gingival one third of the abutment crown
Clasp arms	Stabilization (reciprocation)	Middle one third of crown
	Retention	Gingival one third of crown in measured undercut



FIGURE 7-32 Essential parts of a dental surveyor (Ney Parallelometer, Dentsply Ceramco, Burlington, NJ), showing the vertical spindle in relation to an adjustable table.

satisfies all involved factors (Figure 7-34). A cast in a horizontal relationship to the vertical arm represents a vertical path of placement; a cast in a tilted relationship represents a path of placement toward the side of the cast that is on an upward slant. The vertical arm, when brought in contact with a tooth surface, identifies the location on the clinical crown where the greatest convexity exists. This line, called the *height of contour* (specific to the surveyor-defined path), is the boundary between (1) an occlusal or incisal region of

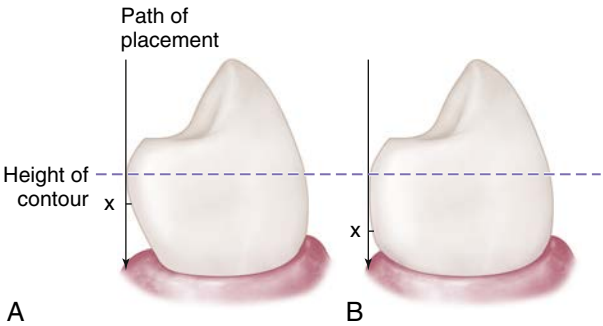


FIGURE 7-33 Angle of cervical convergence on two teeth presenting dissimilar contours. A greater angle of cervical convergence on tooth A necessitates placement of a clasp terminus, x, nearer the height of contour than when a lesser angle exists, as in B. It is apparent that uniform clasp retention depends on depth (amount) of the tooth undercut rather than on distance below the height of the contour at which the clasp terminus is placed.

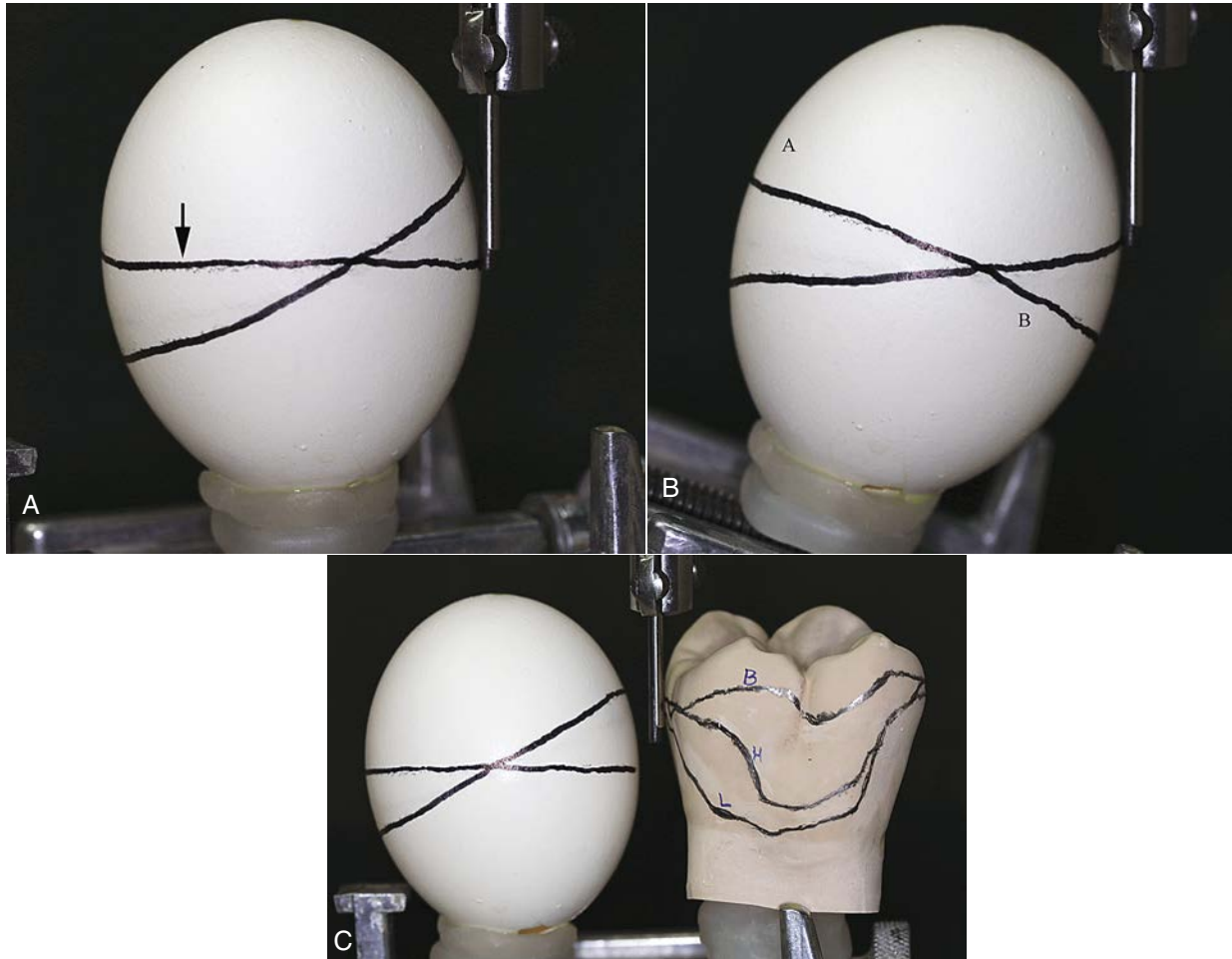
the tooth that is freely accessible to a prosthesis and (2) a gingival region of the tooth that can be accessed only when a portion of the prosthesis elastically deforms and recovers to contact the tooth. This surveyor-defined path and the subsequent tooth height of contour will indicate the areas available for retention and those available for support and stabilization, as well as the existence of tooth and other tissue interference with the path of placement.

When the surveyor blade contacts a tooth on the cast at its greatest convexity, a triangle is formed. The apex of the triangle is at the point of contact of the surveyor blade with the tooth, and the base is the area of the cast representing the gingival tissue (see Figure 11-18). The apical angle is called the angle of cervical convergence (see Figure 7-33). This angle may be measured as described in Chapter 11, or it may be estimated by observing the triangle of light visible between the tooth and the surveyor blade. For this reason, a wide surveyor blade rather than a small cylindrical tool is used so it is easier to see the triangle of light. The importance of this angle lies in its relationship to the amount of retention.

AMOUNT OF RETENTION

Clasp retention is based on resistance to deformation of the metal. For a clasp to be retentive, it must be placed in an undercut area of the tooth, where it is forced to deform upon application of a vertical dislodging force (Figure 7-35). It is this resistance to deformation along an appropriately selected path that generates retention (Figure 7-36). Such resistance to deformation is dependent on several factors and is also proportionate to the flexibility of the clasp arm.

The interaction of a number of factors under the control of the clinician combines to produce retention. These include both tooth (planned and executed by the clinician) and prosthesis (to be planned by the dentist and executed by the laboratory technician) factors.

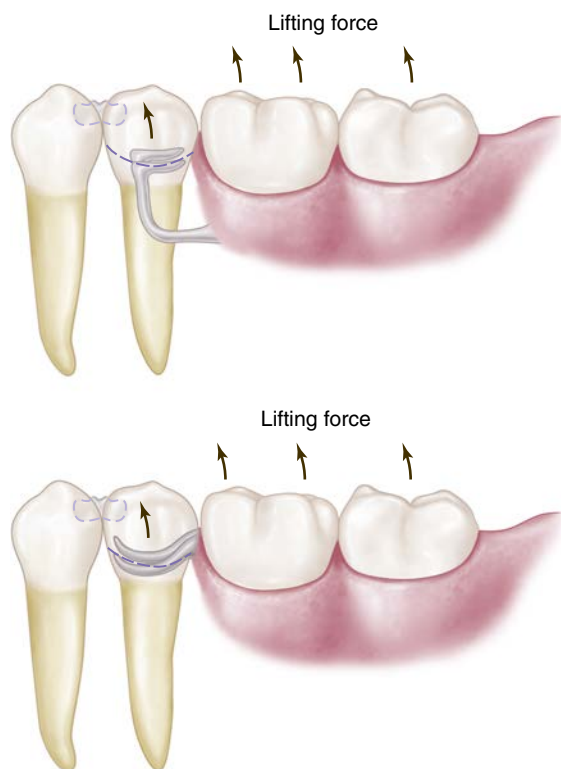


**FIGURE 7-34** Relationship of height of contour, suprabulge, and infrabulge. **A**, When an egg is placed with its long axis parallel to the surveying tool, the height of contour is found at its greatest circumference, here designated by the *arrow*. In this example, the second line is diagonal to the line outlining the height of contour and is either above the height of contour (*right side of egg*), referred to as the *suprabulge region*, or below the height of contour (*left side of egg*), referred to as the *infrabulge region*. **B**, If the long axis of the egg is reoriented so that the previous diagonal line is now at the greatest circumference, the original “height of contour line” no longer is at the greatest circumference. The line segment at *A* is in the suprabulge region, and the line segment *B* is in the infrabulge region. Changing the orientation alters the relationship of surfaces relative to the greatest circumference and consequently alters suprabulge and infrabulge locations. **C**, Just as the height of contour changes as orientation changes for the egg, when a tooth orientation changes, the height of contour is altered. For this molar, the line *H* was produced with a horizontal orientation. When the tooth was inclined buccally, the height of contour moved to *B*, relative to the horizontal location. Alternatively, when the tooth was inclined lingually, the height of contour moves to *L*, relative to the horizontal location.

Tooth factors include the size of the angle of cervical convergence (depth of undercut) and how far the clasp terminal is placed into the angle of cervical convergence. Prosthesis factors include the flexibility of the clasp arm. Clasp flexibility is the product of clasp length (measured from its point of origin to its terminal end), clasp relative diameter (regardless of its cross-sectional form), clasp cross-sectional form or shape (whether it is round, half-round, or some other form), and the material used in making the clasp. The retention characteristics of gold alloy, chrome alloy, titanium, or titanium alloy depend on whether it is in cast or wrought form.

#### Size of and Distance into the Angle of Cervical Convergence

To be retentive, a tooth must have an angle of convergence cervical to the height of contour. When it is surveyed, any single tooth has a height of contour or an area of greatest convexity. Areas of cervical convergence may not exist when the tooth is viewed in relation to a given path of placement. Also, certain areas of cervical convergence may not be usable for the placement of retentive clasps because of their proximity to gingival tissue.



**FIGURE 7-35** Retention is provided primarily by the flexible portion of the clasp assembly. Retentive terminals are ideally located in measured undercuts in the gingival third of abutment crowns. When force acts to dislodge the restoration in an occlusal direction, the retentive arm is forced to deform as it passes from the undercut location over the height of contour. The amount of retention provided by the clasp arm is determined by its length, diameter, taper, cross-sectional form, contour, type of alloy, and location and depth of undercut engaged.

This is best illustrated by mounting a spherical object, such as an egg, on the adjustable table of a dental surveyor (see Figure 7-34). The egg now represents the cast of a dental arch or, more correctly, one tooth of a dental arch. The egg first is placed perpendicular to the base of the surveyor and is surveyed so the height of contour can be determined. The vertical arm of the surveyor represents the path of placement that a denture would take, and conversely its path of removal.

With a carbon marker, a circumferential line has been drawn on an egg at its greatest circumference, as shown by the arrow in Figure 7-34, A. This line, which Kennedy called the *height of contour*, is its greatest convexity. Cummer spoke of it as the guideline, because it is used as a guide in the placement of retentive and nonretentive clasps. DeVan added the terms *suprabulge*, denoting the surfaces sloping superiorly, and *infrabulge*, denoting the surfaces sloping inferiorly.

Any areas cervical to the height of contour may be used for the placement of retentive clasp components, whereas areas occlusal to the height of contour may be used for the

placement of nonretentive, stabilizing, or reciprocating components. Obviously, only flexible components may be placed gingivally to the height of contour because rigid elements would not flex over the height of contour or contact the tooth in the undercut area.

With the original height of contour marked on the egg, the egg is now tilted from the perpendicular to an angular relation with the base of the surveyor (see Figure 7-34, B). Its relation to the vertical arm of the surveyor has now been changed, just as a change in the position of a dental cast would bring about a different relationship with the surveyor. The vertical arm of the surveyor still represents the path of placement. However, its relation to the egg is totally different.

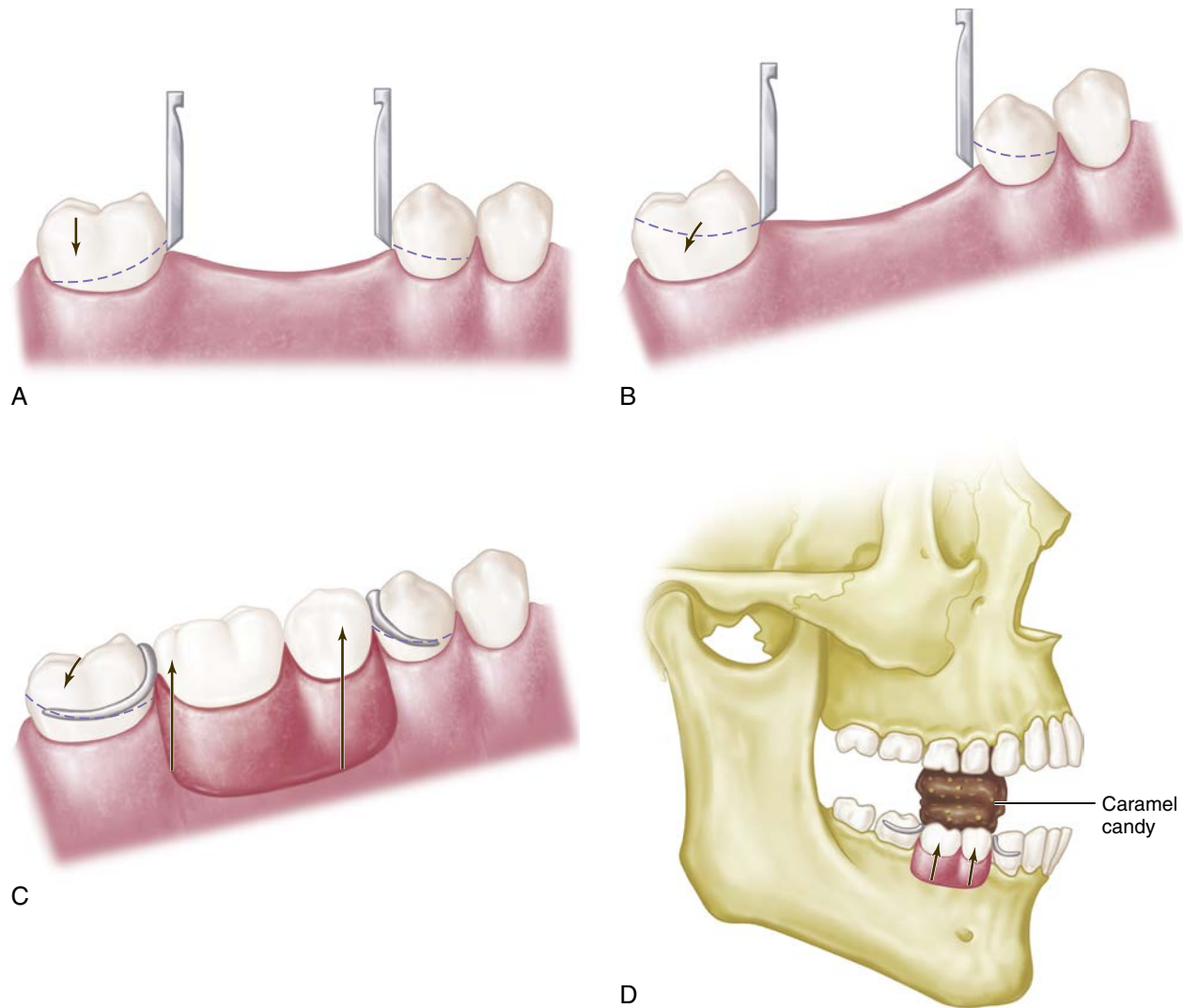
Again, the carbon marker is used to delineate the height of contour or the greatest convexity. It will be seen that areas that were formerly infrabulge are now suprabulge and vice versa. A retentive clasp arm placed below the height of contour in the original position may now be excessively retentive or totally nonretentive, whereas a nonretentive stabilizing or reciprocal arm that is located above the height of contour in the first position may now be located in an area of undercut. Figure 7-35, C, illustrates this principle compared with a tooth example showing that changes in tilt can significantly alter heights of contour.

The location and depth of a tooth undercut available for retention are therefore relative only to the path of placement and removal of the partial denture. At the same time, nonretentive areas on which rigid components of the clasp may be placed exist only for a given path of placement (see Figure 7-35).

If conditions are found that are not favorable for the particular path of placement under consideration, a study should be conducted for a different path of placement. The cast is merely tilted in relation to the vertical arm until the most suitable path is found. The most suitable path of placement is generally considered to be the path of placement that requires the least amount of mouth preparation necessary to place the components of the partial denture in their ideal position on the tooth surfaces and in relation to the soft tissue. Then mouth preparations are planned with a definite path of placement in mind.

It is important to remember that tooth surfaces can be recontoured through selective grinding or the placement of restorations (mouth preparations) to achieve a more suitable path of placement. The path of placement also must take into consideration the presence of tissue undercuts that would interfere with the placement of major connectors, the location of vertical minor connectors, the origin of bar clasp arms, and the denture bases.

When the theory of clasp retention is applied to the abutment teeth in a dental arch during surveying of the dental cast, each tooth may be considered individually and in relation to the other abutment teeth as far as the

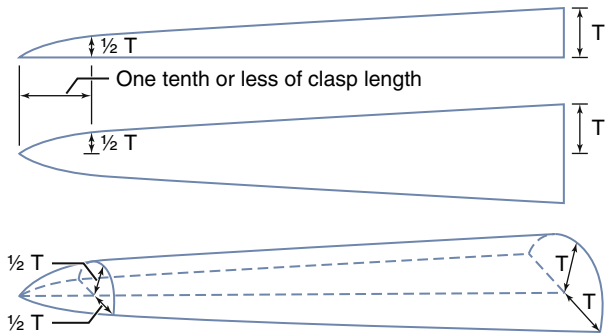


**FIGURE 7-36** **A**, Retentive areas are not sufficient to resist reasonable dislodging forces when a cast is surveyed at its most advantageous position (occlusal plane parallel to the surveyor table), even though guide planes could be established with minor tooth modification. **B**, Tilting cast creates functionally ineffective tooth contours, which are present only in relation to the surveying rod and do not exist when compared with the most advantageous position (position in which restoration will be subject to dislodging forces in an occlusal direction). **C** and **D**, Clasps designed at tilt are ineffective without the development of corresponding guide planes to resist displacement when the restoration is subject to dislodging forces in the occlusal direction.

designs of retentive and stabilizing (reciprocating) components are concerned. This is necessary because the relationship of each tooth to the entire arch and to the design of the whole prosthesis has been considered previously when teeth were selected or modified to achieve the most suitable path of placement. Once this relationship of the cast to the surveyor has been established, the height of contour on each abutment tooth becomes fixed, and the clasp design for each must be considered separately.

A positive path of placement and removal is made possible by the contact of rigid parts of the denture framework with parallel tooth surfaces, which act as guiding planes. Because guiding planes control the path of placement and removal, they can provide additional retention for the partial denture by limiting the possibilities that exist for its

dislodgment. The more vertical the walls (guiding planes) that are prepared parallel to the path of insertion, the fewer the possibilities that exist for dislodgment. If some degree of parallelism does not exist during placement and removal, trauma to the teeth and supporting structures and strain on the denture parts are inevitable. This ultimately results in damage to the teeth and their periodontal support or to the denture itself, or both. Therefore without guiding planes, clasp retention will be detrimental or practically nonexistent. If clasp retention is frictional only because of an active relationship of the clasp to the teeth, then orthodontic movement or damage to periodontal tissue, or both, will result. Instead a clasp should bear a passive relationship to the teeth, except when a dislodging force is applied. In addition to the degree of the angle of cervical convergence



**FIGURE 7-37** The retentive cast clasp arm should be tapered uniformly from its point of attachment at the clasp body to its tip. Dimensions at the tip are about half those at the point of attachment. The clasp arm so tapered is approximately twice as flexible as one without any taper. *T*, Clasp thickness. (Courtesy of The Argen Corporation, New York, NY.)

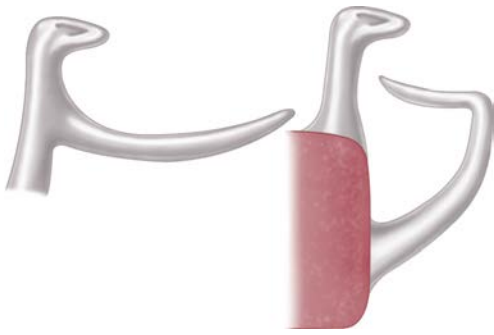
and the distance a clasp is placed into the angle of cervical convergence, the amount of retention generated by a clasp depends on its flexibility. This is a function of clasp length, diameter, taper, cross-sectional form, and material.

The amount of retention also depends on the flexibility of a clasp arm. This is a function of clasp length, diameter, cross-sectional form, and material.

**Length of Clasp Arm**

The longer the clasp arm is, the more flexible it will be, all other factors being equal. The length of a circumferential clasp arm is measured from the point at which a uniform taper begins. Tooth modification providing increased length to a suprabulge retentive clasp by allowing the retentive tip to approach the undercut from a gingival direction optimizes clasp retention (see Figure 7-8). The retentive circumferential clasp arm should be tapered uniformly from its point of origin through the full length of the clasp arm (Figure 7-37).

The length of a bar clasp arm also is measured from the point at which a uniform taper begins. Generally the taper of a bar clasp arm should begin at its point of origin from a metal base, or at the point at which it emerges from a resin base (Figure 7-38). Although a bar clasp arm usually will be longer than a circumferential clasp arm, its flexibility will be less because its half-round form lies in several planes; this prevents its flexibility from being proportionate to its total length. Tables 7-2 and 7-3 give an approximate depth of undercut that may be used for the cast gold and chromium-cobalt retentive clasp arms of circumferential and bar-type clasps. Based on a proportional limit of 60,000 psi and on the assumption that the clasp arm is properly tapered, the clasp arm should be able to flex repeatedly within the limits stated without hardening or rupturing because of fatigue. It has been estimated that alternate stress applications of the fatigue type are placed on a retainer arm during mastication and other force-producing functions about 300,000 times a year.



**FIGURE 7-38** Length of the tapered cast retentive clasp arm is measured along the center portion of the arm until it joins the clasp body (circumferential) or becomes part of the denture base or is embedded in the base (bar-type clasp).

**TABLE 7-2**

**Permissible Flexibilities of Retentive Cast Circumferential and Bar-Type Clasp Arms of Type IV Gold Alloys\***

CIRCUMFERENTIAL		BAR-TYPE	
Length (inches)	Flexibility (inches)	Length (inches)	Flexibility (inches)
0 to 0.3	0.01	0 to 0.7	0.01
0.3 to 0.6	0.02	0.7 to 0.9	0.02
0.6 to 0.8	0.03	0.9 to 1.0	0.03

\*Based on the approximate dimensions of Jelenko preformed plastic patterns (JF Jelenko, New York, NY).

**TABLE 7-3**

**Permissible Flexibilities of Retentive Cast Circumferential and Bar-Type Clasp Arms for Chromium-Cobalt Alloys\***

CIRCUMFERENTIAL		BAR-TYPE	
Length (inches)	Flexibility (inches)	Length (inches)	Flexibility (inches)
0 to 0.3	0.004	0 to 0.7	0.004
0.3 to 0.6	0.008	0.7 to 0.9	0.008
0.6 to 0.8	0.012	0.9 to 1.0	0.012

\*Based on the approximate dimensions of Jelenko preformed plastic patterns (JF Jelenko, New York, NY).

**Diameter of Clasp Arm**

The greater the average diameter of a clasp arm is, the less flexible it will be—all other factors being equal. If its taper is absolutely uniform, the average diameter will be at a point midway between its origin and its terminal end. If its taper is not uniform, a point of flexure—and therefore a point of weakness—will exist; this then will be the determining factor in its flexibility, regardless of the average diameter of its entire length.

Cross-Sectional Form of the Clasp Arm

Flexibility may exist in any form, but it is limited to one direction in the case of the half-round form. The only universally flexible form is the round form, which is practically impossible to obtain by casting and polishing.

Because most cast clasps are essentially half-round in form, they may flex away from the tooth, but edgewise flexing (and edgewise adjustment) is limited. For this reason, cast retentive clasp arms are more acceptable in tooth-supported partial dentures in which they are called on to flex only during placement and removal of the prosthesis. A retentive clasp arm on an abutment adjacent to a distal extension base not only must flex during placement and removal but also must be capable of flexing during functional movement of the distal extension base. It must have universal flexibility to avoid transmission of tipping stresses to the abutment tooth, or it must be capable of disengaging the undercut when vertical forces directed against the denture are toward the residual ridge. A round clasp is the only circumferential clasp form that may be safely used to engage a tooth undercut on the side of an abutment tooth away from the distal extension base. The location of the undercut is perhaps the single most important factor in selection of a clasp for use with distal extension partial dentures.

Material Used for the Clasp Arm

Although all cast alloys used in partial denture construction possess flexibility, their flexibility is proportionate to their bulk. If this were not true, other components of the partial denture could not have the necessary rigidity. A disadvantage of a cast gold partial denture is that its bulk must be increased to obtain needed rigidity at the expense of added weight and increased cost. It cannot be denied that greater rigidity with less bulk is possible through the use of chromium-cobalt alloys.

Although cast gold alloys may have greater resiliency than do cast chromium-cobalt alloys, the fact remains that the structural nature of the cast clasp does not approach the flexibility and adjustable nature of the wrought-wire clasp. Because it was formed by being drawn into a wire, the wrought-wire clasp arm has toughness exceeding that of a cast clasp arm. The tensile strength of a wrought structure is at least 25% greater than that of the cast alloy from which it was made. It may therefore be used in smaller diameters to provide greater flexibility without fatigue and ultimate fracture.

Relative Uniformity of Retention

Now that the factors inherent to a determination of the amount of retention from individual clasps have been reviewed, it is important to consider the coordination of relative retention between various clasps in a single prosthesis.

The size of the angle of convergence will determine how far a given clasp arm should be placed into that angle.

By disregarding—for the time being—variations in clasp flexibility, the relative uniformity of retention will depend on the location of the retentive part of the clasp arm, not in relation to the height of contour, but in relation to the angle of cervical convergence.

The retention on all principal abutments should be as equal as possible. Although esthetic placement of clasp arms is desirable, it may not be possible to place all clasp arms in the same occlusocervical relationship because of variations in tooth contours. However, retentive surfaces may be made similar by altering tooth contours or by using cast restorations with similar contours.

Retentive clasp arms must be located so that they lie in the same approximate degree of undercut on each abutment tooth. In Figure 7-33, this is seen at point x on both teeth—A and B—despite variation in the distance below the height of contour. Should both clasp arms be placed equidistant below the height of contour, the higher location on tooth B would have too little retention, whereas the lower location on tooth A would be too retentive.

Measurement of the degree of undercut by mechanical means with the use of a surveyor is important. However, undercut identification is only one factor that is important to consider when one is providing appropriate retention for a removable partial denture.

Stabilizing-Reciprocal Cast Clasp Arm

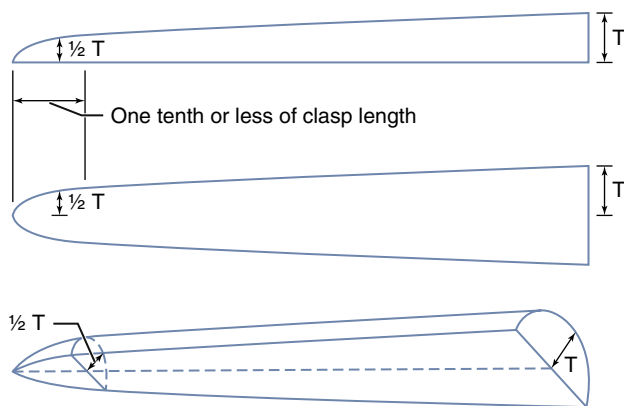
When the direct retainer comes into contact with the tooth, the framework must be stabilized against horizontal movement for the required clasp deformation to occur. This stabilization is derived from cross-arch framework contacts or from a stabilizing or reciprocal clasp in the same clasp assembly. To provide true reciprocation, the reciprocal clasp must be in contact during the entire period of retentive clasp deformation. This is best provided with lingual-palatal, guide-plane surfaces.

A stabilizing (reciprocal) clasp arm should be rigid. Therefore it is shaped somewhat differently than is the cast retentive clasp arm, which must be flexible. Its average diameter must be greater than the average diameter of the opposing retentive arm, to increase desired rigidity. A cast retentive arm is tapered in two dimensions, as illustrated in Figure 7-37, whereas a reciprocal arm should be tapered in one dimension only, as shown in Figure 7-39. Achieving such a form for the arm requires freehand waxing of patterns.

OTHER TYPES OF RETAINERS

Lingual Retention in Conjunction with Internal Rests

The internal rest is covered in Chapter 6. It is emphasized that the internal rest is not used as a retainer, but that its near-vertical walls provide for reciprocation against a lingually placed retentive clasp arm. For this reason, visible clasp arms may be eliminated, thus avoiding one of the principal objections to the extracoronal retainer.



**FIGURE 7-39** The reciprocal arm of the direct retainer assembly should be rigid. An arm tapered both lengthwise and widthwise is more flexible than an arm of the same dimensions tapered only lengthwise. *T*, Clasp thickness.

Such a retentive clasp arm, terminating in an existing or prepared infrabulge area on the abutment tooth, may be of any acceptable design. It is usually a circumferential arm arising from the body of the denture framework at the rest area. It should be wrought because the advantages of adjustability and flexibility make the wrought clasp arm preferable. It may be cast with gold or a low-fusing, chromium-cobalt alloy, or it may be assembled by being soldered to one of the higher-fusing, chromium-cobalt alloys. In any event, future adjustment or repair is facilitated.

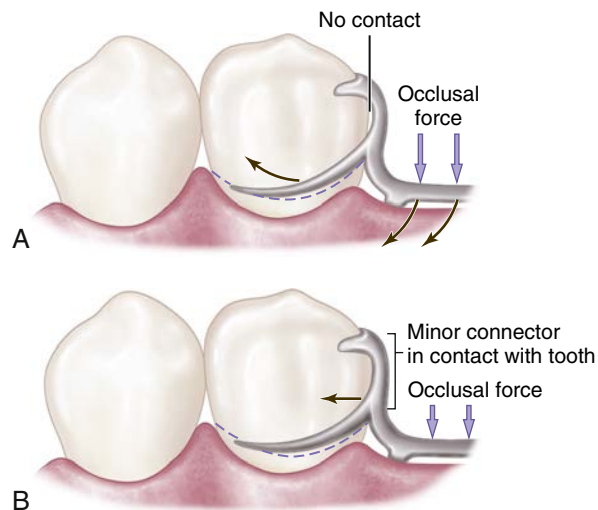
The use of lingual extracoronal retention avoids much of the cost of the internal attachment, yet disposes of a visible clasp arm when esthetics must be considered. Often it is employed with a tooth-supported partial denture only on the anterior abutments, and when esthetics is not a consideration, the posterior abutments are clasped in the conventional manner.

One of the dentist's prime considerations in clasp selection is the control of stress transferred to the abutment teeth when the patient exerts an occluding force on the artificial teeth. The location and design of rests, the clasp arms, and the position of minor connectors as they relate to guiding planes are key factors in controlling transfer of stress to abutments. Errors in the design of a clasp assembly can result in uncontrolled stress to abutment teeth and their supporting tissues. Some common errors and their corrections are illustrated in [Figures 7-40 and 7-41](#).

The choice of clasp design should be based on biological and mechanical principles. The dentist responsible for the treatment being rendered must be able to justify the clasp design used for each abutment tooth in keeping with these principles.

## INTERNAL ATTACHMENTS

The principle of the internal attachment was first formulated by Dr. Herman E.S. Chayes in 1906. One such attachment manufactured commercially still carries his name.



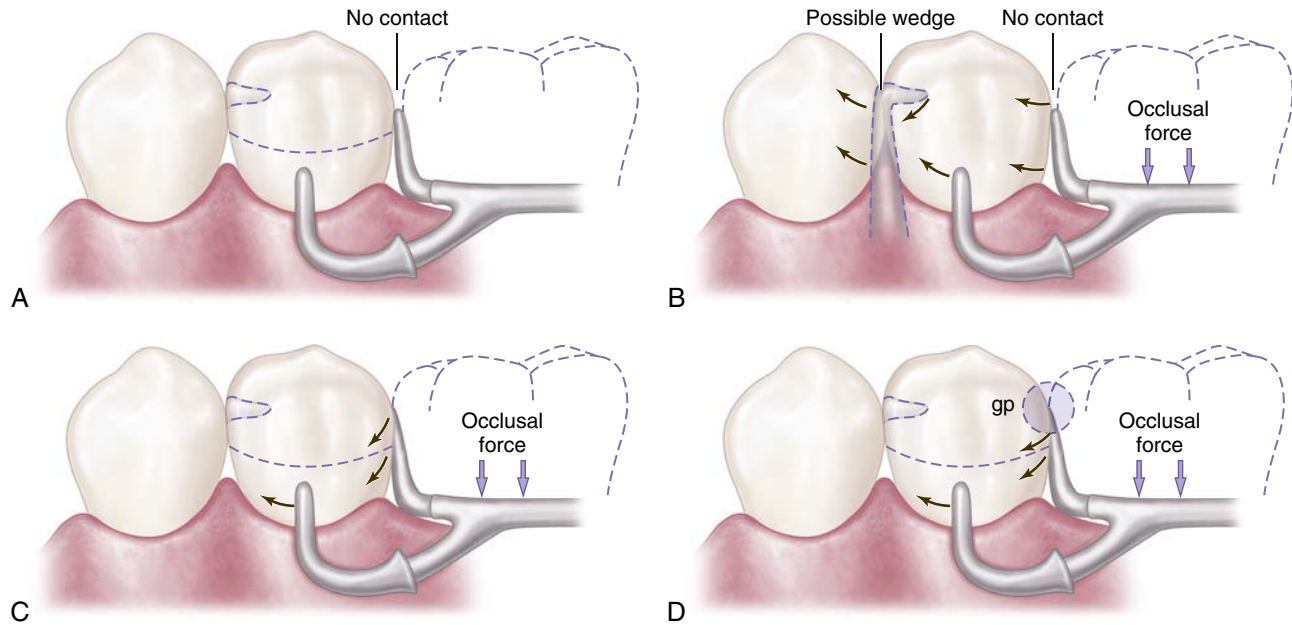
**FIGURE 7-40** **A**, Minor connector supporting the distal rest does not contact the prepared guiding plane, resulting in uncontrolled stress to the abutment tooth. **B**, A minor connector contacts the prepared guiding plane and directs stresses around the arch through the proximal contacts.

Although it may be fabricated by the dental technician as a cast dovetail fitting into a counterpart receptacle in the abutment crown, the alloys used in manufactured attachments and the precision with which they are constructed make the ready-made attachment preferable to any of this type that can be fabricated in the dental laboratory. Much credit is due the manufacturers of metals used in dentistry for continued improvements in the design of internal attachments.

The internal attachment has two major advantages over the extracoronal attachment: (1) elimination of visible retentive and support components and (2) better vertical support through a rest seat located more favorably in relation to the horizontal axis of the abutment tooth. For these reasons, the internal attachment may be preferable in selected situations. It provides horizontal stabilization similar to that of an internal rest. However, additional extracoronal stabilization is usually desirable. It has been claimed that stimulation to the underlying tissue is greater when internal attachments are used because of intermittent vertical massage. This is probably no more than is possible with extracoronal retainers of similar construction.

Some of the disadvantages of internal attachments include the following: (1) they require prepared abutments and castings; (2) they require somewhat complicated clinical and laboratory procedures; (3) they eventually wear, with progressive loss of frictional resistance to denture removal; (4) they are difficult to repair and replace; (5) they are effective in proportion to their length and are therefore least effective on short teeth; (6) they are difficult to place completely within the circumference of an abutment tooth because of the size of the pulp; and (7) they are considered more costly.

Because the principle of the internal attachment does not permit horizontal movement, all horizontal, tipping,



**FIGURE 7-41** A, Clasp assembly designed so that the vertical occlusal force results in movement of the proximal plate cervically and out of contact with the guiding plane, as illustrated in B. This lack of contact may contribute to a possible wedging effect. C, Extending contact of the proximal plate on the prepared guiding plane or, as in D, eliminating space between the artificial tooth and the guiding plane (gp) will help direct stresses around the arch through proximal contacts.

and rotational movements of the prosthesis are transmitted directly to the abutment tooth. The internal attachment therefore should not be used in conjunction with extensive tissue-supported distal extension denture bases unless some form of stress-breaker is used between the movable base and the rigid attachment. Although stress-breakers may be used, they do have some disadvantages—which are discussed later—and their use adds to the cost of the partial denture.

Numerous other types of retainers for partial dentures have been devised that cannot be classified as primarily of the intracoronal or extracoronal type. Neither can they be classified as relying primarily on frictional resistance or placement of an element in an undercut to prevent displacement of the denture. However, all of these use some type of locking device, located intracoronally or extracoronally, for providing retention without visible clasp retention. Although the motivation behind the development of other types of retainers has usually been a desire to eliminate visible clasp retainers, the desire to minimize torque and tipping stresses on the abutment teeth has also been given consideration.

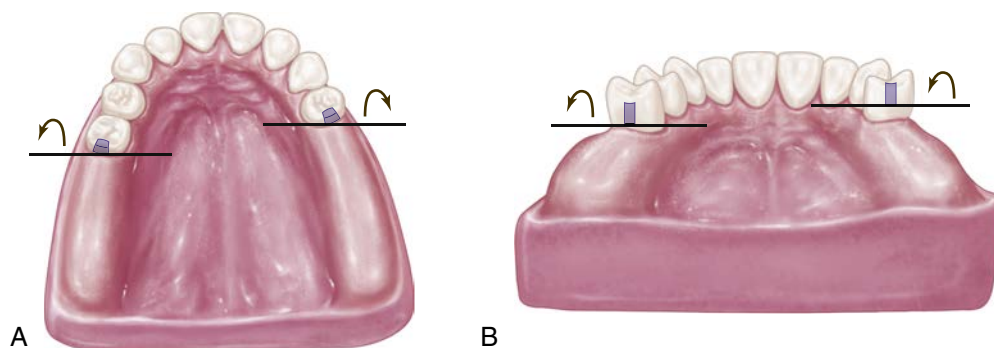
All of the retainers that are discussed herein have merit, and much credit is due to those who have developed specific devices and techniques for the retention of partial dentures. The use of patented retaining devices and other techniques falls in the same limited category as the internal attachment prosthesis and is for economic and technical reasons available to only a small percentage of those patients who need partial denture service.

Internal attachments of the locking or dovetail type unquestionably have many advantages over the

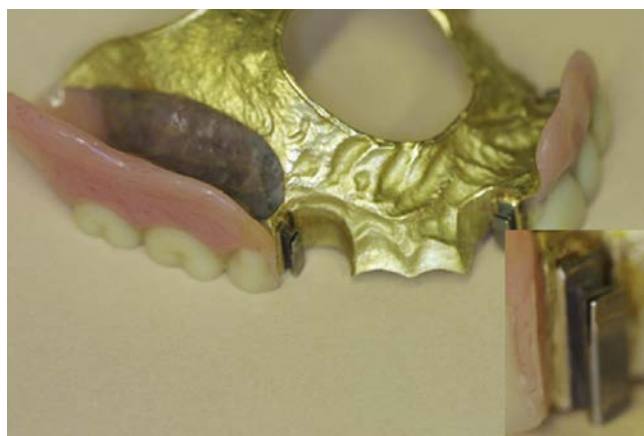clasp-type denture in tooth-supported situations. However, it is questionable whether the locking type of internal attachment is indicated for distal extension removable partial dentures, with or without stress-breakers and with or without splinted abutments, because of inherent excessive leverages most often associated with these attachments.

The nonlocking type of internal attachment, in conjunction with sound prosthodontic principles, can be advantageously used in many instances in Class I and Class II partially edentulous situations. However, unless the cross-arch axis of rotation is common to the bilaterally placed attachments, torque on the abutments may be experienced (Figure 7-42). Excellent textbooks devoted to the use of manufactured intracoronal and extracoronal retainer systems are available. For this reason, this text concerns itself primarily with the extracoronal type of direct retainer assembly (clasps). Numerous well-designed internal attachments are available in the dental market that may be used in situations requiring special retention. Descriptive literature and technique manuals are available from the manufacturers.

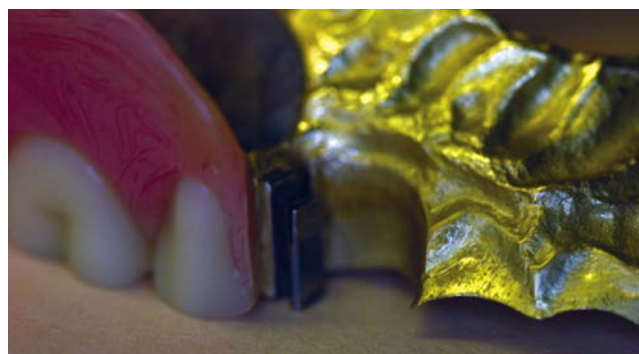
Other conservative treatment of partially edentulous arches with removable partial dentures can be accomplished in a variety of ways. Treatment is still contingent on the location and condition of the remaining teeth and the contour and quality of the residual ridges. Basic principles and concepts of design relative to support and stability must be respected even though a variety of retaining devices can be incorporated. Examples of some of these retaining devices are illustrated in Figures 7-43 through 7-46.




**FIGURE 7-42** A, Axes of rotation, although parallel, are not common because one axis is located anterior to the other axis. B, When one nonlocking internal attachment is elevated farther from the residual ridge than its cross-arch counterpart, the axes of rotation do not fall on a common line; thus some torquing of abutments should be anticipated. However, in many instances, the effect produced by this situation will not exceed physiologic tolerance of the supporting structures of the abutments—all other torquing factors being equal.



**FIGURE 7-43** Classification II, modification 1, maxillary removable partial denture with three internal attachments. Gold framework with soldered attachments that gain retention through activation of the gingival region of the male component (see inset).



**FIGURE 7-44** Same prosthesis as Figure 7-43, showing the attachment position relative to the framework palatal and distal minor connector components.



**FIGURE 7-45** Similar photo as in Figure 7-44, showing the attachment at the anterior modification space. Careful arrangement of the components is required to maximize the esthetic advantage of attachment use in such a region.



**FIGURE 7-46** Prosthesis with three internal attachments shown from the tissue side, depicting the common path for each. Notice the broad ridge coverage and the use of an anterior-posterior palatal strap major connector to help support the prosthesis, minimizing stress to the attachments.

# CHAPTER

# 8

## Indirect Retainers

### CHAPTER OUTLINE

Role of Indirect Retainers in Control of Prosthesis

Movement

Factors Influencing Effectiveness of Indirect Retainers

Auxiliary Functions of Indirect Retainers

Forms of Indirect Retainers

Auxiliary Occlusal Rest

Canine Rests

Canine Extensions from Occlusal Rests

Cingulum Bars (Continuous Bars) and Linguoplates

Modification Areas

Rugae Support

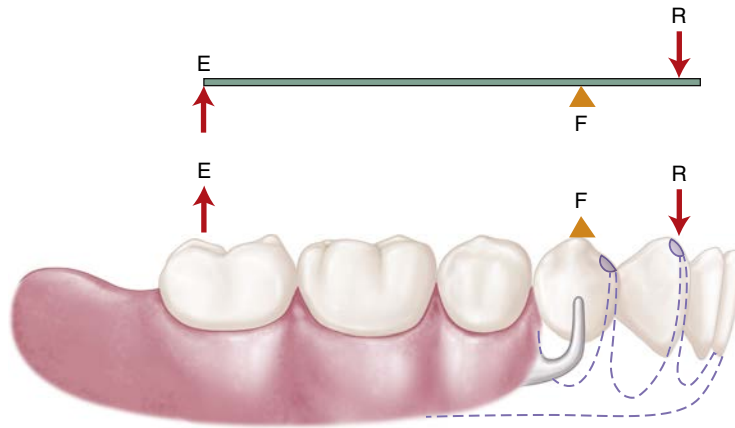
### ROLE OF INDIRECT RETAINERS IN CONTROL OF PROSTHESIS MOVEMENT

As was described in Chapter 4, partial denture movement can exist in three planes. Tooth-supported partial dentures effectively use teeth to control movement away from the tissues. Tooth-tissue-supported partial dentures do not have this capability because one end of the prosthesis is free to move away from the tissue. This may occur because of the effects of gravity in the maxillary arch or adhesive foods in either arch. Attention to the details of design and location of partial denture component parts in control of functional movement is the strategy used in partial denture design.

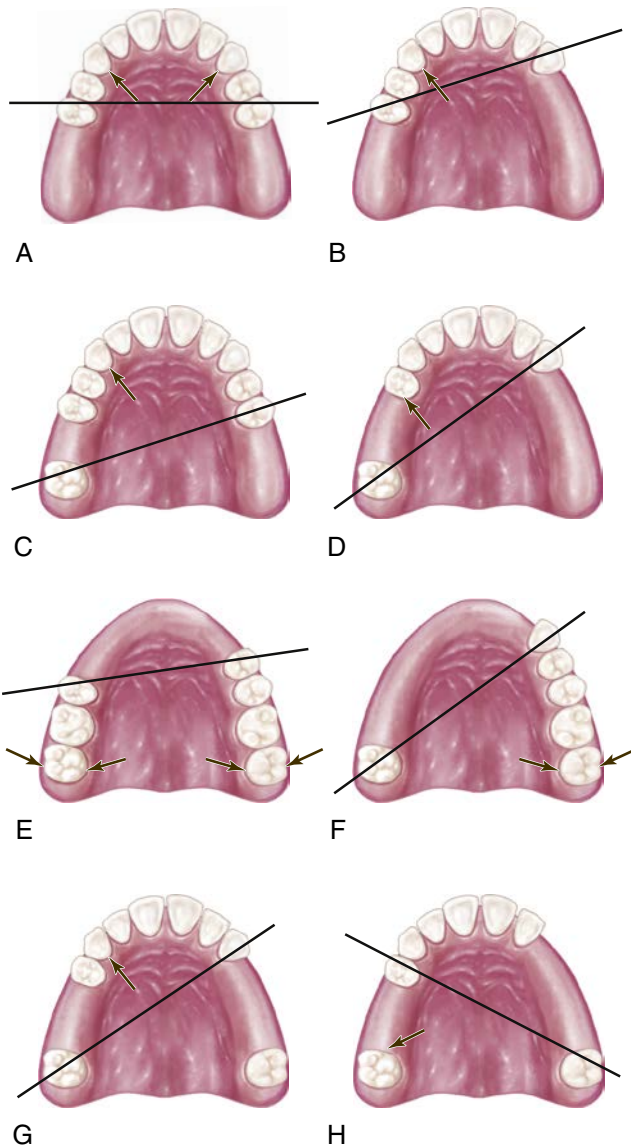
When the distal extension denture base is dislodged from its basal seat, it tends to rotate around the fulcrum lines. Theoretically, this movement away from the tissues can be resisted by activation of the direct retainer, the stabilizing components of the clasp assembly, and the rigid components of the partial denture framework, which are located on definite rests on the opposite side of the fulcrum line away from the distal extension base. These components are referred to as *indirect retainers* (Figures 8-1 and 8-2). Indirect retainer components should be placed as far as possible from the distal extension base, which provides the best leverage advantage against dislodgment (Figure 8-3).

For the sake of clarity in discussion of the location and functions of indirect retainers, fulcrum lines should be considered the axis about which the denture will rotate when the bases move away from the residual ridge.

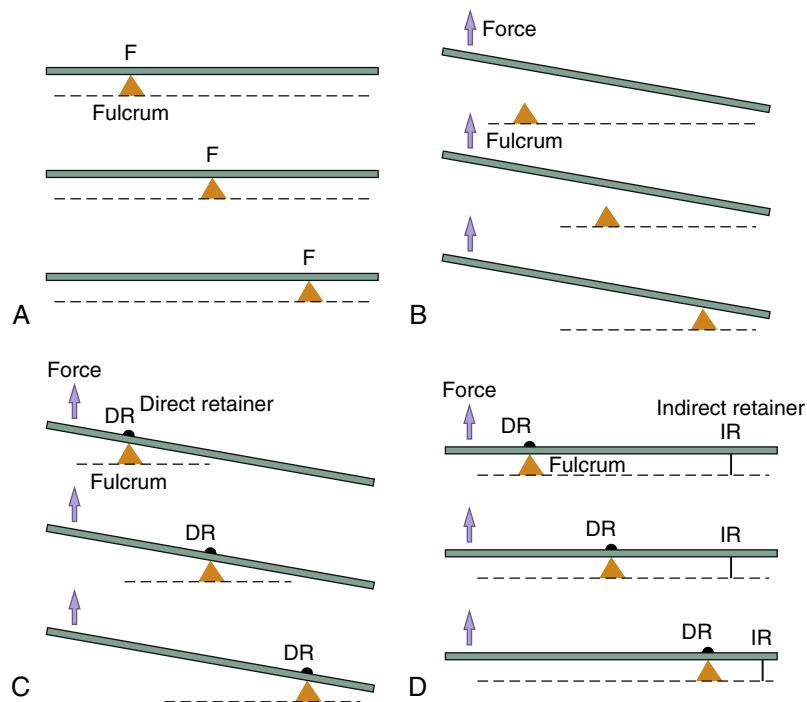
An indirect retainer consists of one or more rests and the supporting minor connectors (Figures 8-4 and 8-5). The proximal plates, adjacent to the edentulous areas, also provide indirect retention. Although it is customary to identify the entire assembly as the indirect retainer, it should be remembered that the rest is actually the indirect retainer united to the major connector by a minor connector. This is noted to avoid interpretation of any contact with tooth inclines as part of the indirect retainer. An indirect retainer should be placed



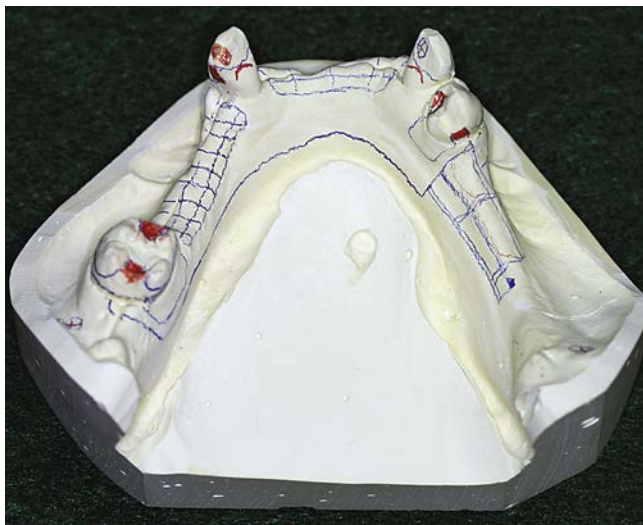
**FIGURE 8-1** Mandibular distal extension removable partial denture showing the distal extension base being lifted from the ridge and the clasp assembly being activated and engaged, with the indirect retainer providing stabilization against dislodgment. *E*, Effort; *F*, fulcrum; *R*, resistance.



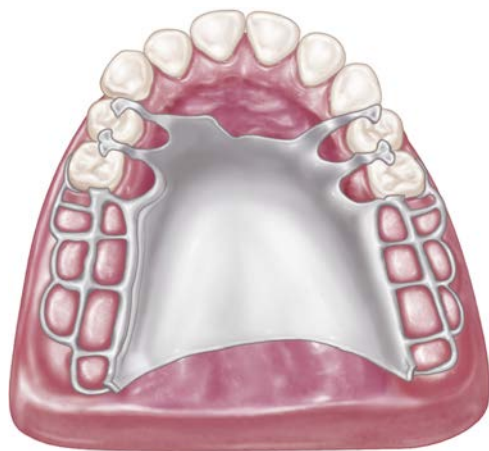**FIGURE 8-2** Fulcrum lines found in various types of partially edentulous arches, around which the denture may rotate when bases are subjected to forces directed toward or away from the residual ridge. Arrows indicate the most advantageous position of indirect retainer(s). **A** and **B**, In a Class I arch, the fulcrum line passes through the most posterior abutments, provided some rigid component of the framework is occlusal to the abutment's heights of contour. **C**, In a Class II arch, the fulcrum line is diagonal, passing through the abutment on the distal extension side and the most posterior abutment on the opposite side. **D**, If the abutment tooth anterior to the modification space lies far enough removed from the fulcrum line, it may be used effectively for support of the indirect retainer. **E** and **F**, In a Class IV arch, the fulcrum line passes through two abutments adjacent to the single edentulous space. **G**, In a Class III arch with a posterior tooth on the right side, which has a poor prognosis and eventually will be lost, the fulcrum line is considered the same as though posterior tooth were not present. Thus its future loss may not necessitate altering the original design of the removable partial denture framework. **H**, In a Class III arch with nonsupporting anterior teeth, the adjacent edentulous area is considered to be the tissue-supported end, with a diagonal fulcrum line passing through the two principal abutments, as in a Class II arch.



**FIGURE 8-3** Indirect retainer principle. **A**, Beams are supported at various points. **B**, A lifting force will displace the entire beam in the absence of retainers. **C**, With direct retainers (DRs) at the fulcrum, the lifting force will depress one end of the beam and elevate the other end. **D**, With both direct and indirect retainers (IRs) functioning, the lifting force will not displace beam. The farther the indirect retainer is from the fulcrum, the more efficiently it should control movement.



**FIGURE 8-4** Planning the location for an indirect retainer for a Class II, modification 2, removable partial denture. The greatest distance from the axis of rotation around most distal rests (fulcrum line) would fall on #22. The decision to use an incisal rest or cingulum rest depends on the patient's concern for the esthetic impact of an incisal rest versus having a crown (for the cingulum rest).



**FIGURE 8-5** Example of indirect retention used in conjunction with a palatal plate-type major connector. Indirect retainers are proximal plates on second premolars and occlusal rests located on first premolars. A secondary function of auxiliary occlusal rest assemblies is to prevent settling of the anterior portion of the major connector and to provide stabilization against horizontal rotation.

as far from the distal extension base as possible in a prepared rest seat on a tooth capable of supporting its function.

Although the most effective location of an indirect retainer is commonly in the vicinity of an incisor tooth, that tooth may not be strong enough to support an indirect retainer and may have steep inclines that cannot be favorably altered to support a rest. In such a situation, the nearest canine tooth or the mesio-occlusal surface of the first premolar may be the best location for the indirect retention, despite the fact that it is not as far removed from the fulcrum line. Whenever possible, two indirect retainers closer to the fulcrum line are used to compensate for the compromise in distance. When a distal extension is judged to be at significant risk for dislodgement away from the denture base, the use of a dental implant as a distal retainer can be considered.

### FACTORS INFLUENCING EFFECTIVENESS OF INDIRECT RETAINERS

The following factors influence the effectiveness of an indirect retainer:

1. The principal occlusal rests on the primary abutment teeth must be reasonably held in their seats by the retentive arms of the direct retainers. If rests are held in their seats, rotation about an axis should occur, which subsequently would activate the indirect retainers. If total displacement of the rests occurs, no rotation about the fulcrum would occur, and the indirect retainers would not be activated.
2. Distance from the fulcrum line. The following three areas must be considered:
  - a. Length of the distal extension base
  - b. Location of the fulcrum line
  - c. How far beyond the fulcrum line the indirect retainer is placed
3. Rigidity of the connectors supporting the indirect retainer. All connectors must be rigid if the indirect retainer is to function as intended.
4. Effectiveness of the supporting tooth surface. The indirect retainer must be placed on a definite rest seat on which slippage or tooth movement will not occur. Tooth inclines and weak teeth should never be used to support indirect retainers.

### AUXILIARY FUNCTIONS OF INDIRECT RETAINERS

In addition to effectively activating the direct retainer to prevent movement of a distal extension base away from the tissues, an indirect retainer may serve the following auxiliary functions:

1. It tends to reduce anteroposterior tilting leverages on the principal abutments. This is particularly important when an isolated tooth is being used as an abutment—a situation that should be avoided whenever possible. Ordinarily, proximal contact with the adjacent tooth prevents

such tilting of an abutment as the base lifts away from the tissues.

2. Contact of its minor connector with axial tooth surfaces aids in stabilization against horizontal movement of the denture. Such tooth surfaces, when made parallel to the path of placement, may also act as auxiliary guiding planes.
3. Anterior teeth supporting indirect retainers are stabilized against lingual movement.
4. It may act as an auxiliary rest to support a portion of the major connector, facilitating stress distribution. For example, a lingual bar may be supported against settling into the tissues by the indirect retainer acting as an auxiliary rest. One must be able to differentiate between an auxiliary rest placed for support for a major connector, one placed for indirect retention, and one serving a dual purpose. Some auxiliary rests are added solely to provide rest support to a segment of the denture and should not be confused with indirect retention.
5. It may provide the first visual indications for the need to re-line an extension base partial denture. Deficiencies in basal seat support are manifested by the dislodgment of indirect retainers from their prepared rest seats when the denture base is depressed and rotation occurs around the fulcrum. These auxiliary functions derived from indirect retainers are important to consider, especially given the reported controversy as to the effectiveness of indirect retainers.

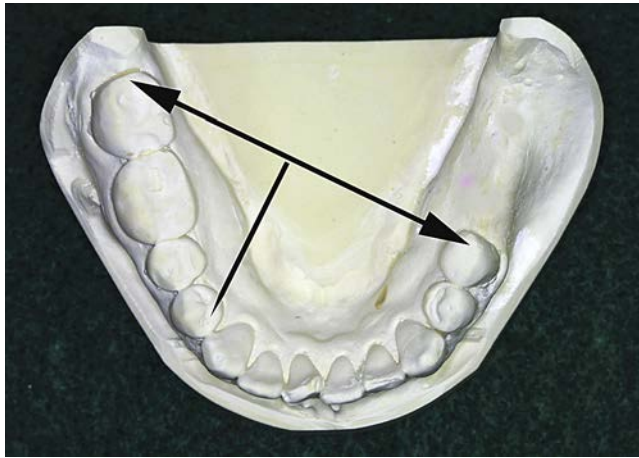
### FORMS OF INDIRECT RETAINERS

The indirect retainer may take any one of several forms. All are effective in proportion to their support and distance from the fulcrum line.

#### Auxiliary Occlusal Rest

The most commonly used indirect retainer is an auxiliary occlusal rest located on an occlusal surface and as far away from the distal extension base as possible. In a mandibular Class I arch, this location is usually on the mesial marginal ridge of the first premolar on each side of the arch (see [Figure 8-4](#)). The ideal position for the indirect retainer perpendicular to the fulcrum line would be in the vicinity of the central incisors, which are too weak and have lingual surfaces that are too perpendicular to support a rest. Bilateral rests on the first premolars are quite effective, even though they are located closer to the axis of rotation.

The same principle applies to any maxillary Class I partial denture when indirect retainers are used. Bilateral rests on the mesial marginal ridge of the first premolars generally are used in preference to rests on incisor teeth (see [Figure 8-5](#)). Not only are they effective without jeopardizing the weaker single-rooted teeth, but interference with the tongue is far less when the minor connector can be placed in the embrasure between canine and premolar rather than anterior to the canine teeth.



**FIGURE 8-6** Mandibular Class II design showing a favorable location for the indirect retainer on the mesio-occlusal of the first premolar #28. This location is at 90 degrees to the fulcrum line between primary rests—disto-occlusal (DO) of #20 and DO of #31—and provides efficient resistance to a denture base lift based on the longest distance to resistant rest support and because the occlusal rest is perpendicular to the load.

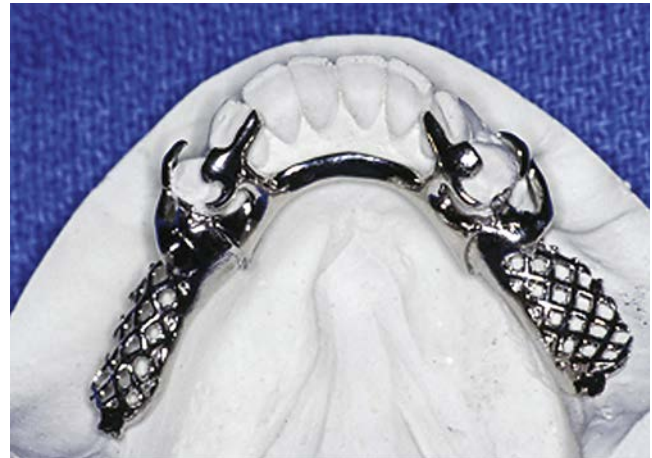Indirect retainers for Class II partial dentures are usually placed on the marginal ridge of the first premolar tooth on the opposite side of the arch from the distal extension base (Figure 8-6). Bilateral rests are seldom indicated except when an auxiliary occlusal rest is needed for support of the major connector, or when the prognosis for the distal abutment is poor and provision is being considered for later conversion to a Class I partial denture.

### Canine Rests

When the mesial marginal ridge of the first premolar is too close to the fulcrum line, or when the teeth are overlapped so that the fulcrum line is not accessible, a rest on the adjacent canine tooth may be used. Such a rest may be made more effective by placing the minor connector in the embrasure anterior to the canine, either curving back onto a prepared lingual rest seat or extending to a mesio-incisal rest. The same types of canine rests as those previously outlined—lingual or incisal rests—may be used (see Chapter 6).

### Canine Extensions from Occlusal Rests

Occasionally, a finger extension from a premolar rest is placed on the prepared lingual slope of the adjacent canine tooth (Figure 8-7). Such an extension is used to effect indirect retention by increasing the distance of a resisting element from the fulcrum line. This method is particularly applicable when a first premolar must serve as a primary abutment. The distance anterior to the fulcrum line is only the distance between the mesio-occlusal rest and the anterior terminal of the finger extension. In this instance, although the extension rests on a prepared surface, it is



**FIGURE 8-7** Mandibular Class I design using canine extensions from occlusal rests as indirect retainers. The canine extension must be placed on prepared rest seats so that resistance will be directed as nearly as possible along the long axis of the canine abutment.

used in conjunction with a terminal rest on the mesial marginal ridge of the premolar tooth. Even when they are not used as indirect retainers, canine extensions, continuous bar retainers, and linguoplates should never be used without terminal rests because of the resultant forces effective when they are placed on inclined planes alone.

### Cingulum Bars (Continuous Bars) and Linguoplates

Technically, cingulum bars (continuous bars) and linguoplates are not indirect retainers because they rest on unprepared lingual inclines of anterior teeth. The indirect retainers are actually the terminal rests at either end that occur in the form of auxiliary occlusal rests or canine rests (see Chapter 5).

In Class I and Class II partial dentures, a cingulum bar or linguoplate may extend the effectiveness of the indirect retainer if it is used with a terminal rest at each end. In tooth-supported partial dentures, a cingulum bar or linguoplate is placed for other reasons but always with terminal rests (see Chapter 5).

In Class I and Class II partial dentures especially, a continuous bar retainer or the superior border of the linguoplate should never be placed above the middle third of the teeth so that orthodontic movement during the rotation of a distal extension denture is avoided. This guideline is not so important when the six anterior teeth are in nearly a straight line, but when the arch is narrow and tapering, a cingulum bar or linguoplate on the anterior teeth extends well beyond the terminal rests, and orthodontic movement of those teeth is more likely. Although these are intended primarily to stabilize weak anterior teeth, they may have the opposite effect if not used with discretion.

### Modification Areas

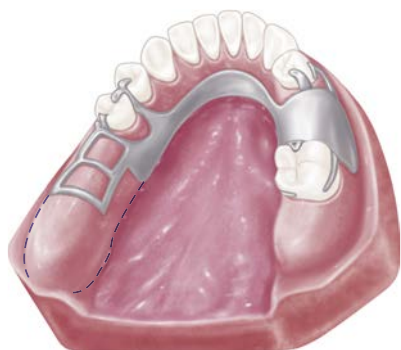
Occasionally, the occlusal rest on a secondary abutment in a Class II partial denture may serve as an indirect retainer. This use will depend on how far from the fulcrum line the secondary abutment is located.

The primary abutments in a Class II, modification 1, partial denture are the abutment adjacent to the distal extension base and the most distal abutment on the tooth-supported side. The fulcrum line is a diagonal axis between the two terminal abutments (Figure 8-8).

The anterior abutment on the tooth-supported side is a secondary abutment, which serves to support and retain one end of the tooth-supported segment and adds horizontal stabilization to the denture. If the modification space were not present, as in an unmodified Class II arch, auxiliary occlusal rests and stabilizing components in the same position would still be essential to the design of the denture (Figure 8-9). However, the presence of a modification space conveniently provides an abutment tooth for support, stabilization, and retention.

If the occlusal rest on the secondary abutment lies far enough from the fulcrum line, it may serve adequately as an indirect retainer. Its dual function then is tooth support for one end of the modification area and support for an indirect retainer. The most typical example is a distal occlusal rest on a first premolar when a second premolar and the first molar are missing and the second molar serves as one of the primary abutments. The longest perpendicular to the fulcrum line falls in the vicinity of the first premolar, making the location of the indirect retainer nearly ideal.

On the other hand, if only one tooth, such as a first molar, is missing on the modification side, the occlusal rest on the second premolar abutment is too close to the fulcrum line to be effective. In such a situation, an auxiliary occlusal rest on the mesial marginal ridge of the first premolar is needed, both for indirect retention and for support for an otherwise unsupported major connector.



**FIGURE 8-8** Class II, modification 1, removable partial denture framework. The fulcrum line, when the denture base is displaced toward the residual ridge, runs from the left second premolar to the right second molar. When forces tend to displace the denture away from its basal seat, the supportive element (distal occlusal rest) of the direct retainer assembly on the right first premolar serves as an indirect retainer.

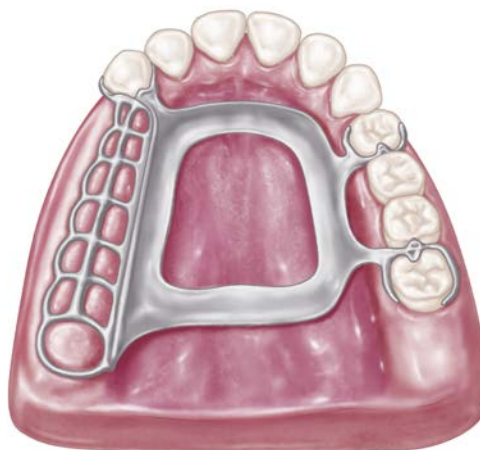Support for a modification area extending anteriorly to a canine abutment is obtained by any one of the accepted canine rest forms, as previously outlined in Chapter 6. In this situation, the canine tooth provides nearly ideal indirect retention and support for the major connector as well.

### Rugae Support

Some clinicians consider coverage of the rugae area of the maxillary arch as a means of indirect retention because the rugae area is firm and usually well situated to provide indirect retention for a Class I removable partial denture. Although it is true that broad coverage over the rugae area can conceivably provide some support, the facts remain that tissue support is less effective than positive tooth support, and that rugae coverage is undesirable if it can be avoided.

The use of rugae support for indirect retention is usually part of a palatal horseshoe design. Because posterior retention is usually inadequate in this situation, the requirements for indirect retention are probably greater than can be satisfied by this type of tissue support alone.

In the mandibular arch, retention from the distal extension base alone is usually inadequate to prevent lifting of the base away from the tissues. In the maxillary arch, where only anterior teeth remain, full palatal coverage is usually necessary. In fact, with any Class I maxillary removable partial denture that extends distally from the first premolar teeth, except when a maxillary torus prevents its use, palatal coverage may be used to advantage. Although complete coverage may be seen in the form of a resin base, the added retention and reduced bulk of a cast metal palate make the latter preferable (see Chapter 5). However, in the absence of full palatal coverage, an indirect retainer should be used with other designs of major palatal connectors for the Class I removable partial denture.



**FIGURE 8-9** Class II maxillary removable partial denture framework design. The fulcrum line runs from the patient's right canine to left second molar. Forces that tend to unseat the denture from its basal seat will be resisted by activation of retentive elements on canine and molar, with the use of supportive elements on the left first premolar as an indirect retainer.

# CHAPTER

# 9

## Denture Base Considerations

### CHAPTER OUTLINE

#### Functions of Denture Bases in Control of Prosthesis

##### Movement

Tooth-Supported Partial Denture Base

Distal Extension Partial Denture Base

#### Methods of Attaching Denture Bases

#### Methods for Incorporating Dental Implants

#### Ideal Denture Base Material

#### Advantages of Metal Bases

Accuracy and Permanence of Form

Comparative Tissue Response

Thermal Conductivity

Weight and Bulk

#### Methods of Attaching Artificial Teeth

Porcelain or Acrylic-Resin Artificial Teeth Attached with Acrylic-Resin

Porcelain or Resin Tube Teeth and Facings Cemented Directly to Metal Bases

Resin Teeth Processed Directly to Metal Bases

Metal Teeth

Chemical Bonding

#### Need for Relining

#### Stress-Breakers (Stress Equalizers)

The preceding chapters described removable partial denture component parts that engaged the remaining teeth (rests, direct retainers, and indirect retainers) and the cross-arch connector of all component parts, the major connector. This chapter describes the portion of the removable partial denture that contains the replacement teeth—the denture base.

### FUNCTIONS OF DENTURE BASES IN CONTROL OF PROSTHESIS MOVEMENT

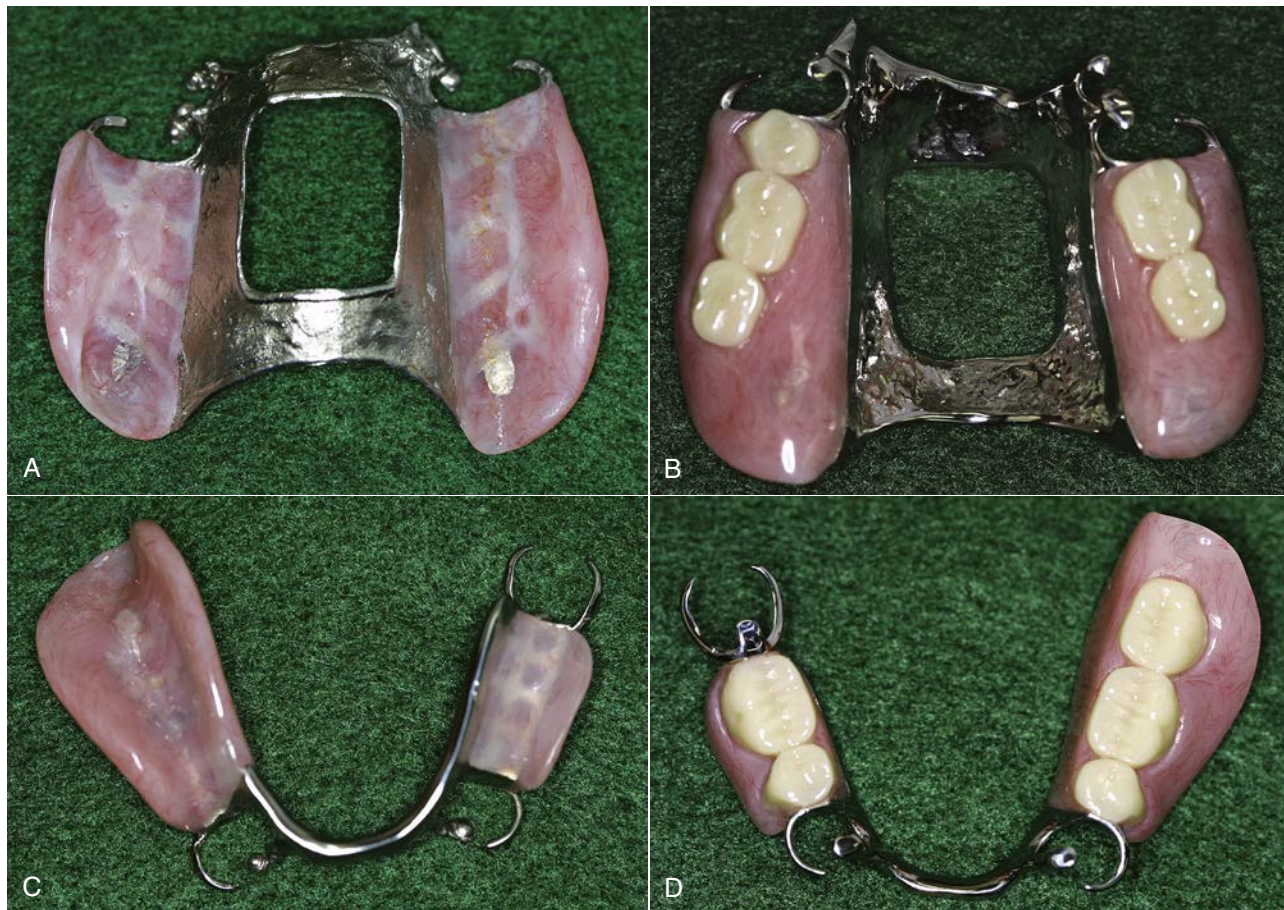
The denture base supports the artificial teeth and consequently receives the functional forces from occlusion and transfers functional forces to supporting oral structures (Figure 9-1). This function is most critical for the distal extension prosthesis, as functional stability and comfort often relate directly to the ability for this transfer of forces to occur without undue movement.

Although its primary purpose is related to masticatory function, the denture base also may add to the cosmetic effect of the replacement, particularly when techniques for tinting and reproducing natural-looking contours are used. Most of the techniques for creating a natural appearance in complete denture bases are applicable equally well to partial denture bases.

Still another function of the denture base is stimulation of the underlying tissues of the residual ridge. Some vertical movement occurs with any denture base, even those supported entirely by abutment teeth, because of the physiologic movement of those teeth under function. It is clearly evident that oral tissues placed under functional stress within their physiologic tolerance maintain their form and tone better than similar tissues suffering from disuse. The term *disuse atrophy* is applicable to both periodontal tissues and the tissues of a residual ridge.

### Tooth-Supported Partial Denture Base

Denture bases differ in functional purpose and may differ in terms of the material of which they are made. In a



**FIGURE 9-1** **A**, Class I maxillary distal extension removable partial denture showing tissue side (intaglio) of denture bases. **B**, Occlusal side of maxillary prosthesis: posterior artificial teeth are attached to the bases. **C**, Class II, modification 1, mandibular distal extension removable partial denture shows intaglio of both extension and modification bases. **D**, Occlusal side of mandibular prosthesis; posterior artificial teeth are attached to the bases. For both prostheses, the bases are extended within the limits of physiologic activity of surrounding oral structures.

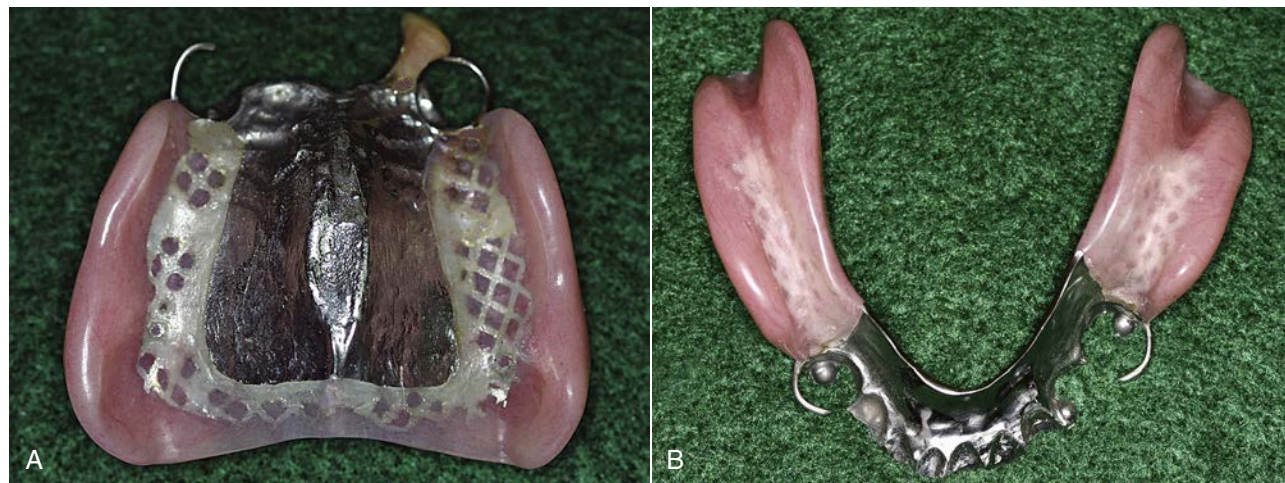tooth-supported prosthesis, the denture base is primarily a span between two abutments supporting artificial teeth. Thus occlusal forces are transferred directly to the abutments through rests. Also, the denture base and the supplied teeth serve to prevent horizontal migration of all abutment teeth in the partially edentulous arch and vertical migration of teeth in the opposing arch.

When only posterior teeth are being replaced, esthetics is usually only a secondary consideration. On the other hand, when anterior teeth are replaced, esthetics may be of primary importance. Theoretically, the tooth-supported partial denture base that replaces anterior teeth must perform the following functions: (1) provide desirable esthetics; (2) support and retain the artificial teeth in such a way that they provide masticatory efficiency and assist in transferring occlusal forces directly to abutment teeth through rests; (3) prevent vertical and horizontal migration of remaining natural teeth; (4) eliminate undesirable food traps (oral cleanliness); and (5) stimulate the underlying tissues.

When an implant is placed in a distal extension segment of a Class I or Class II removable partial denture, the effect is to create a bound span by supporting the segment at both ends. In this situation the requirements of the denture base become more like a tooth-bound base than a distal extension denture base.

### Distal Extension Partial Denture Base

In a distal extension partial denture, denture bases that are not in tooth-supported modifications must contribute to the support of the denture. Such support is critical to the goal of minimizing functional movement and improving stability of the prosthesis. Although the abutment teeth provide support for the distal extension base, as the distance from the abutment increases, support from the underlying ridge tissues becomes increasingly important. Maximum support from the residual ridge may be obtained by using broad, accurate denture bases, which spread the occlusal load equitably over the entire area available for such support. The space available for a denture base is determined by the structures



**FIGURE 9-2** Maxillary and mandibular distal extension removable partial dentures with resin denture bases. Bases are extended buccally within the physiologic tolerance of border structures. **A**, Maxillary denture bases cover both the maxillary tuberosities, extend into the pterygomaxillary notches and provide for adaptation along the posterior border, taking care not to extend beyond the soft palatal flexure. **B**, Mandibular bilateral distal extension removable partial denture bases cover the retromolar pads and extend into the retromylohyoid fossae. The impression procedure used established buccal shelves as primary stress-bearing areas of basal seats.

surrounding the space and by their movement during function. Maximum support for the denture base therefore can be accomplished only by using knowledge of the limiting anatomic structures and of the histologic nature of the basal seat areas, accuracy of the impression, and accuracy of the denture base (Figure 9-2). The first two of these support features relate to the gross size and cellular characteristics of the residual ridge tissues. These are highly variable between patients, and consequently not all residual ridges can provide the same quality of support. Therefore the ability to control functional displacement of the distal extension base is a determination that is unique for individual patients.

The snowshoe principle, which suggests that broad coverage furnishes the best support with the least load per unit area, is the principle of choice for providing maximum support. Therefore support should be the primary consideration in selecting, designing, and fabricating a distal extension partial denture base. Of secondary importance (but to be considered nevertheless) are esthetics, stimulation of the underlying tissues, and oral cleanliness. Methods used to accomplish maximum support of the restoration through its base(s) are presented in Chapters 16 and 17.

In addition to their difference in functional purposes, denture bases vary in material of fabrication. This difference is directly related to their function because of the need for some dentures to be relined.

Because the tooth-supported base has an abutment tooth at each end on which a rest has been placed, future relining or rebasing may not be necessary to reestablish support. Relining is necessary only when tissue changes have occurred beneath the tooth-supported base to the point that poor esthetics or accumulation of debris results. For these reasons alone, tooth-supported bases made soon after

extractions should be of a material that permits later relining. Such materials are the denture resins, the most common of which are copolymer and methyl methacrylate resins.

*Primary retention* for the removable partial denture is accomplished mechanically by placing retaining elements on the abutment teeth. *Secondary retention* is provided by the intimate relationship of denture bases and major connectors (maxillary) with the underlying tissues. The latter is similar to the retention of complete dentures and is proportionate to the accuracy of the impression registration, the accuracy of the fit of the denture bases, and the total area of contact involved.

Retention of denture bases has been described as the result of the following forces: (1) adhesion, which is the attraction of saliva to the denture and tissues; (2) cohesion, which is the attraction of the molecules of saliva to each other; (3) atmospheric pressure, which is dependent on a border seal and results in a partial vacuum beneath the denture base when a dislodging force is applied; (4) physiologic molding of the tissues around the polished surfaces of the denture; and (5) the effects of gravity on the mandibular denture.

Boucher, writing on the subject of complete denture impressions, described these forces as follows:\*

Adhesion and cohesion are effective when there is perfect apposition of the impressed surface of the denture to the mucous membrane surfaces. These forces lose their effectiveness if any horizontal displacement of the dentures breaks the continuity of this contact. Atmospheric pressure is effective primarily as a rescue force when extreme dislodging forces are applied to the denture. It depends on a perfect

\*From Boucher CO: Complete denture impression based upon the anatomy of the mouth, *J Am Dent Assoc* 31:117-1181, 1994.

border seal to keep the pressure applied on only one side of the denture. The presence of air on the impression surface would neutralize the pressure of the air against the polished surface. Because each of these forces is directly proportional to the area covered by the dentures, the dentures should be extended to the limits of the supporting structures.

The molding of the soft tissues around the polished surfaces of denture bases helps to perfect the border seal. Also, it forms a mechanical lock at certain locations on the dentures, provided these surfaces are properly prepared. This lock is developed automatically and without effort by the patient if the impression is made with an understanding of the anatomic possibilities.

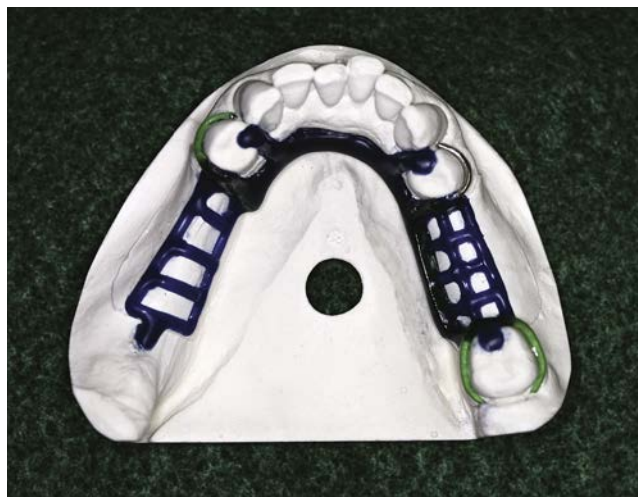Few partial dentures are made without some mechanical retention. Retention from the denture bases may contribute significantly to the overall retention of the partial denture and therefore must not be discounted. Denture bases should be designed and fabricated so that they will contribute as much retention to the partial denture as possible. However, it is questionable whether atmospheric pressure plays as important a role in retention of removable partial dentures because a border seal cannot be obtained as readily as it can be with complete dentures. Therefore adhesion and cohesion gained by excellent apposition of the denture base and soft tissues of the basal seat play an important retentive role.

## METHODS OF ATTACHING DENTURE BASES

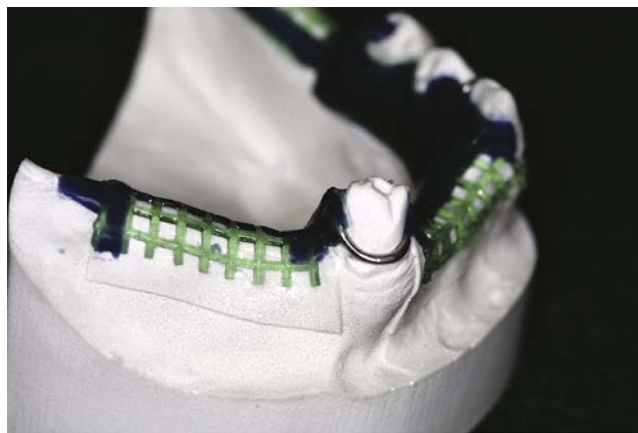Acrylic-resin bases are attached to the partial denture framework by means of a minor connector designed so that a space exists between the framework and the underlying tissues of the residual ridge (Figure 9-3). Relief of at least a 20-gauge thickness over the basal seat areas of the master cast is used to create a raised platform on the investment cast on which the pattern for the retentive frame is formed (Figure 9-4). Thus after casting, the portion of the retentive framework to which the acrylic-resin base will be attached will stand away from the tissue surface sufficiently to permit a flow of acrylic-resin base material beneath its surface.

The retentive framework for the base should be embedded in the base material with sufficient thickness of resin (1.5 mm) to allow for relieving if this becomes necessary during the denture adjustment period or during relining procedures. Thickness is also necessary to avoid weakness and subsequent fracture of the acrylic-resin base material surrounding the metal framework.

The use of plastic mesh patterns in forming the retentive framework is generally less satisfactory than a more open framework (see Figure 9-4). Less weakening of the resin by the embedded framework results from use of the more open form. Pieces of 12- or 14-gauge half-round wax and 18-gauge round wax are used to form a ladderlike framework rather than the finer latticework of the mesh pattern. The precise design of the retentive framework, other than that it should be located both buccally and lingually, is not as important as its effective rigidity and strength when it is embedded in the

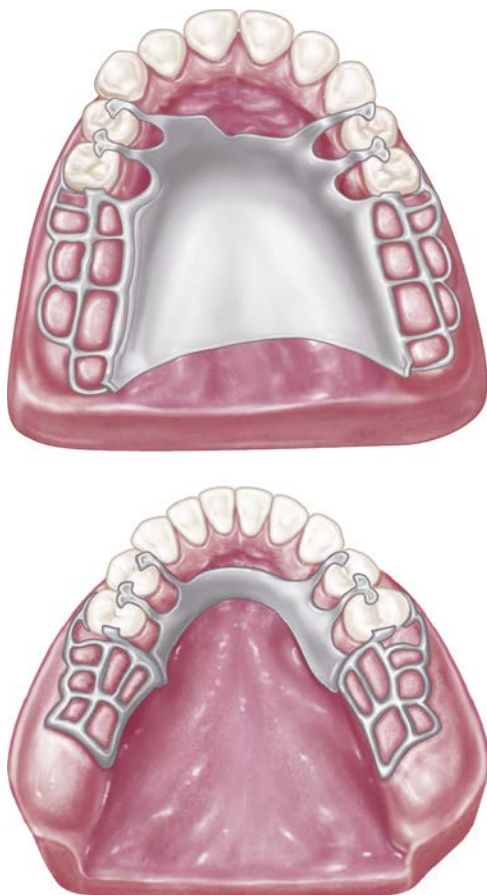

**FIGURE 9-3** Mandibular Class II, modification 1, wax pattern developed on an investment cast. Adequate provision is made for attaching the resin base to the major connector on the edentulous side by way of a ladderlike minor connector and a butt-type joint. A similar minor connector design will be used for modification space. *Note:* Relief space beneath the minor connectors is established by relief wax placed on the original master cast and duplicated in this refractory cast. This allows processed resin to surround the minor connectors in creating the denture base.



**FIGURE 9-4** Unlike the minor connector designs in Figure 9-3, the designs used for this prosthesis have a plastic mesh pattern. Although such designs can be reinforced to be more rigid, the bulk of the connector itself may contribute to weakening of the resin base. A more open type of minor connector seems preferable.

acrylic resin base. It should also be free of interference with future adjustment, should not interfere with arrangement of artificial teeth, and should be open enough to avoid weakening any portion of the attached acrylic-resin. Designing the retentive framework for denture bases by having elements located buccal and lingual to the residual ridge not only will strengthen the acrylic-resin base but also will minimize distortion of the base created by the release of inherent strains in the acrylic-resin base during use or storage of the restoration (Figure 9-5).



**FIGURE 9-5** Note that minor connectors by which resin denture bases will be attached to the framework are open, ladderlike configurations that extend on both buccal and lingual surfaces. This not only provides excellent attachment of the resin bases but minimizes warping of bases resulting from the release of inherent strains in compression-molded resin.

Metal bases are usually cast as integral parts of the partial denture framework. Mandibular metal bases may be assembled and attached to the framework with acrylic-resin (Figure 9-6).

### METHODS FOR INCORPORATING DENTAL IMPLANTS

When dental implants are placed, modifications can be required in the denture base and the specific modification is dependent on how the implants will be engaged.

Implants placed anteriorly, to enhance retention by removing the need for a visible clasp, must take into account retentive device bulk and connection requirements for joining to the prosthesis (i.e., direct to the metallic frame or via embedding within the acrylic resin denture base).

Placement of the implant should consider minimizing palatal/lingual bulk, provision of adequate space for housing,



**FIGURE 9-6** Cast distal extension base of a maxillary removable partial denture. Cast bases are an integral part of the framework and not only provide support to the prosthetic dentition but reinforce framework rigidity.

acrylic resin and denture tooth, and alignment coincident with the insertion path of the prosthesis.

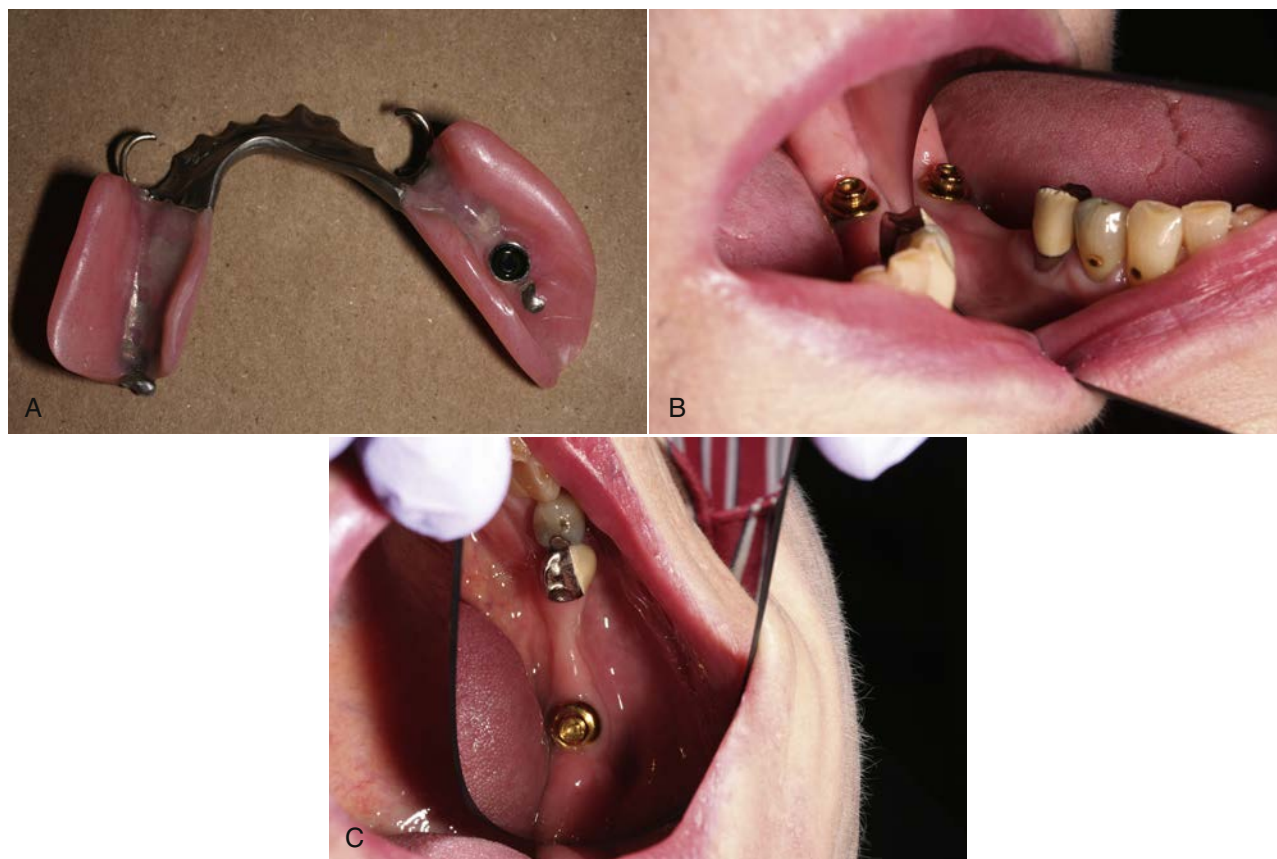
Modifications required for implants placed more distal, for purposes of support, typically require designing space for embedding an attachment housing within the denture base (Figure 9-7).

### IDEAL DENTURE BASE MATERIAL

The requirements for an ideal denture base are as follows:

1. Accuracy of adaptation to the tissues, with minimal volume change
2. Dense, nonirritating surface capable of receiving and maintaining a good finish
3. Thermal conductivity
4. Low specific gravity; lightweight in the mouth
5. Sufficient strength; resistance to fracture or distortion
6. Easily kept clean
7. Esthetic acceptability
8. Potential for future relining
9. Low initial cost

Such an ideal denture base material does not exist, nor is it likely to be developed in the near future. However, any denture base, whether of resin or metal and regardless of the method of fabrication, should come as close to this ideal as possible.



**FIGURES 9-7** A. Intaglio surface view of a Locator retentive element in the posterior aspect of a distal extension base of a mandibular removable partial denture. B. Mirror view of the Locator attachment on an implant in the distal mandible. The attachment will provide support and retention for the distal extension removable partial denture. C. Occlusal view of the locator attachment.

### ADVANTAGES OF METAL BASES

Except for those edentulous ridges with recent extractions, metal can be used for tooth-supported bases and is thought to provide several advantages. Its principal disadvantages are that it is difficult to adjust and relin. A commonly stated advantage is that the stimulation it gives to the underlying tissues is so beneficial that it prevents some alveolar atrophy that would otherwise occur under a resin base and thereby prolongs the health of the tissues that it contacts. Some of the advantages of a metal base are discussed in the following sections.

#### Accuracy and Permanence of Form

Cast metal bases, whether of gold, chrome, or titanium alloys, not only may be cast more accurately than denture resins but also can maintain their accuracy of form without changes in the mouth. Internal strains that may be released later to cause distortion are not present. Although some resins and some processing techniques are superior to others in accuracy and permanence of form, modern cast alloys are generally superior in this respect. Evidence of this fact is that an additional posterior palatal seal may

be eliminated entirely when a cast palate is used for a complete denture, as compared with the need for a definite post-dam when the palate is made of acrylic-resin. Distortion of an acrylic-resin base is manifest in the maxillary denture by a distortion away from the palate in the midline and toward the tuberosities on the buccal flanges. The greater the curvature of the tissues, the greater is this distortion. Similar distortions occur in a mandibular denture but are more difficult to detect. Accurate metal castings are not subject to distortion by the release of internal strains, as are most denture resins.

Because of its accuracy, the metal base provides an intimacy of contact that contributes considerably to the retention of a denture. Sometimes called *interfacial surface tension*, direct retention from a cast denture base is significant in proportion to the area involved. This has been mentioned previously as an important factor in both direct and direct-indirect retention of maxillary restorations. Such intimacy of contact is not possible with acrylic-resin bases.

Permanence of form of the cast base is also ensured because of its resistance to abrasion from denture cleaning agents. Cleanliness of the denture base should be stressed;

however, constant brushing of the tissue side of the acrylic-resin denture base inevitably causes some loss of accuracy by abrasion. Intimacy of contact, which is never as great with an acrylic-resin base as with a metal base, is therefore jeopardized further by cleaning habits. The metal bases, particularly the harder chrome alloys, withstand repeated cleaning without significant changes in surface accuracy.

### Comparative Tissue Response

Clinical observations have demonstrated that the inherent cleanliness of the cast metal base contributes to the health of oral tissues when compared with an acrylic-resin base. Perhaps some of the reasons for this are the greater density and the bacteriostatic activity contributed by ionization and oxidation of the metal base. Acrylic-resin bases tend to accumulate mucinous deposits containing food particles, as well as calcareous deposits. Unfavorable tissue reaction to decomposing food particles and bacterial enzymes and mechanical irritation from calculus may result if the denture is not kept meticulously clean. Although calculus, which must be removed periodically, can precipitate on a cast metal base, other deposits do not accumulate as they do on an acrylic-resin base. For this reason, a metal base is naturally cleaner than an acrylic-resin base.

### Thermal Conductivity

Temperature changes are transmitted through the metal base to the underlying tissues, thereby helping to maintain the health of those tissues. Freedom of interchange of temperature between the tissues covered and the surrounding external influences (temperature of liquids, solid foods, and inspired air) contributes much to the patient's acceptance of a denture and may help avoid the feeling of the presence of a foreign body. Conversely, denture acrylic resins have insulating properties that prevent interchange of temperature between the inside and the outside of the denture base.

### Weight and Bulk

Metal alloy may be cast much thinner than acrylic-resin and still have adequate strength and rigidity. Cast gold must be given slightly more bulk to provide the same amount of rigidity but still may be made with less thickness than acrylic-resin materials. Even less weight and bulk are possible when the denture bases are made of chrome or titanium alloys.

At times, however, both weight and thickness may be used to advantage in denture bases. In the mandibular arch, the weight of the denture may be an asset with regard to retention; and for this reason, a cast gold base may be preferred. On the other hand, extreme loss of residual alveolar bone may make it necessary to add fullness to the denture base to restore normal facial contours and to fill out the buccal vestibule to prevent food from being trapped in the vestibule beneath the denture.



**FIGURE 9-8** Partial metal bases used with a palatal strap and resin denture teeth attached directly to the cast metal bases. If needed, a buccal flange of resin could be added to such a base region; however, for these small spans no such flange was needed.

In such situations, an acrylic-resin base may be preferred to the thinner metal base.

In the maxillary arch, an acrylic-resin base may be preferred to the thinner metal base to provide fullness in the buccal flanges or to fill a maxillary buccal vestibule. Acrylic-resin may also be preferred over the thinner metal base for esthetic reasons. In these instances, the thinness of the metal base may be of no advantage, but in areas where the tongue and cheek need maximum room, thinness may be desirable.

Denture base contours for functional tongue and cheek contact can best be accomplished with acrylic-resin. Metal bases are usually made thin to minimize bulk and weight, whereas acrylic-resin bases may be contoured to provide ideal polished surfaces that contribute to retention of the denture, to restore facial contours, and to avoid the accumulation of food at denture borders. Lingual surfaces usually are made concave except in the distal palatal area. Buccal surfaces are made convex at gingival margins, over root prominences, and at the border to fill the area recorded in the impression. Between the border and the gingival contours, the base can be made convex to aid in retention and to facilitate return of the food bolus to the occlusal table during mastication. Such contours prevent food from being entrapped in the cheek and from working under the denture. This usually cannot be accomplished with metal bases.

However, the advantages of a metal base need not be sacrificed for the sake of esthetics or desirable denture contours when the use of such a base is indicated. Denture bases may be designed to provide almost total metallic coverage, yet they have resin borders to avoid a display of metal and to add buccal fullness when needed (Figure 9-8). The advantages of thermal conductivity are not necessarily lost by covering a portion of the metal base as long as other parts of the denture are exposed to effect temperature changes through conduction.

## METHODS OF ATTACHING ARTIFICIAL TEETH

Selection of artificial teeth for form, color, and material must precede attachment to the denture. Artificial teeth may be attached to denture bases by the several means that follow: with acrylic resin, with cement, processed directly to metal, cast with the framework, and by chemical bonding. Use of acrylic-resin to attach artificial teeth to a denture base is the most common method.

### Porcelain or Acrylic-Resin Artificial Teeth Attached with Acrylic-Resin

Artificial porcelain teeth are mechanically retained. The posterior teeth are retained by acrylic-resin in their diatoric holes. The anterior porcelain teeth are retained by acrylic-resin surrounding their lingually placed retention pins. Artificial resin teeth are retained by a chemical union with the acrylic-resin of the denture base that occurs during laboratory processing procedures.

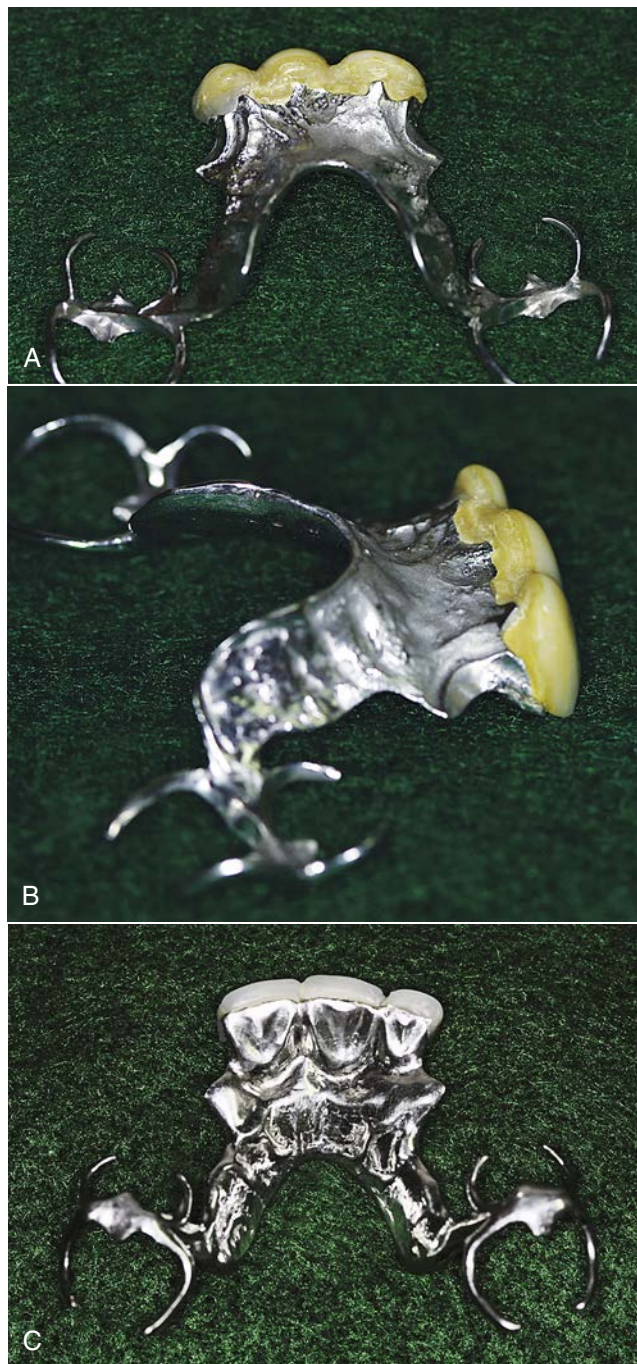
Attachment of acrylic-resin to the metal base may be accomplished by nailhead retention, retention loops, or diagonal spurs placed at random. Attachment mechanisms should be placed so that they will not interfere with placement of the teeth on the metal base.

Any junction of acrylic-resin with metal should occur at an undercut finishing line or should be associated with some retentive undercut. Because only a mechanical attachment exists between metal and acrylic-resin, every attempt should be made to avoid separation and seepage, which result in discoloration and uncleanness. Denture odors are frequently caused by accretions at the junction of the acrylic-resin with metal when only a mechanical union exists. Separation that occurs between the acrylic-resin and the metal can eventually lead to loosening of the acrylic-resin base.

### Porcelain or Resin Tube Teeth and Facings Cemented Directly to Metal Bases

Some disadvantages of this type of attachment are the difficulties involved in obtaining satisfactory occlusion, the lack of adequate contours for functional tongue and cheek contact, and the unesthetic display of metal at gingival margins. The latter is avoided when the tooth is butted directly to the residual ridge, but then the retention for the tooth frequently becomes inadequate.

A modification of this method is the attachment of ready-made acrylic-resin teeth to the metal base with acrylic-resin of the same shade (Figure 9-9). This is called *pressing on a resin tooth* and is not the same as using acrylic-resin for cementation. It is particularly applicable to anterior replacements, because it is desirable to know in advance of making the casting that the shade and contours of the selected tooth will be acceptable. After a labial index of the position of the teeth is made, the lingual portion of the tooth may be cut away or a post-hole prepared in the tooth for retention on the casting. Subsequently, the tooth is attached to the



**FIGURE 9-9** Tissue surface of Class IV removable partial denture in which artificial dentition was added to a metal base. **A**, Teeth were set before completion of the framework to allow the modification space design to incorporate altered teeth. **B**, Anterior teeth were adjusted to the ridge, creating a ridge lap; then the framework was waxed to accommodate a custom tooth position. **C**, Metal reinforcement adds strength to the artificial teeth and protects against dislodgment.

denture with acrylic-resin of the same shade. Because this is done under pressure, the acrylic-resin attachment is comparable with the manufactured tooth in hardness and strength.

Tube or side-groove teeth must be selected in advance of waxing the denture framework (Figure 9-10). However, for best occlusal relationships, jaw relation records always should be made with the denture casting in the mouth. This problem may be solved by selecting tube teeth for width but with occlusal surfaces slightly higher than will be necessary. The teeth are ground to fit the ridge with sufficient clearance beneath, for a thin metal base, and beveled to accommodate a boxing of metal. If an acrylic-resin tube tooth is used, the diatoric hole should be made slightly larger than that provided. The casting is completed and tried in, occlusal relationships are recorded, and then the teeth are ground to harmonious occlusion with the opposing dentition. As is discussed in Chapter 18, artificial posterior teeth on partial dentures can hardly ever be used unaltered but rather should be considered material from which occlusal forms may be created to function harmoniously with the remaining natural occlusion.

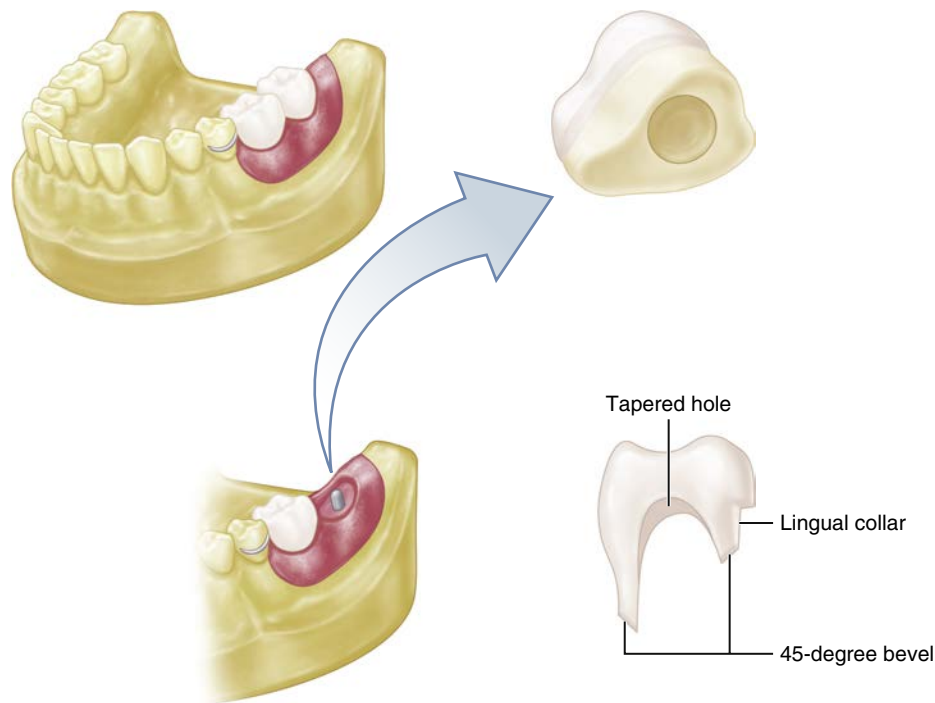
**Resin Teeth Processed Directly to Metal Bases**

Modern cross-linked copolymers enable the dentist or technician to process acrylic-resin teeth that have

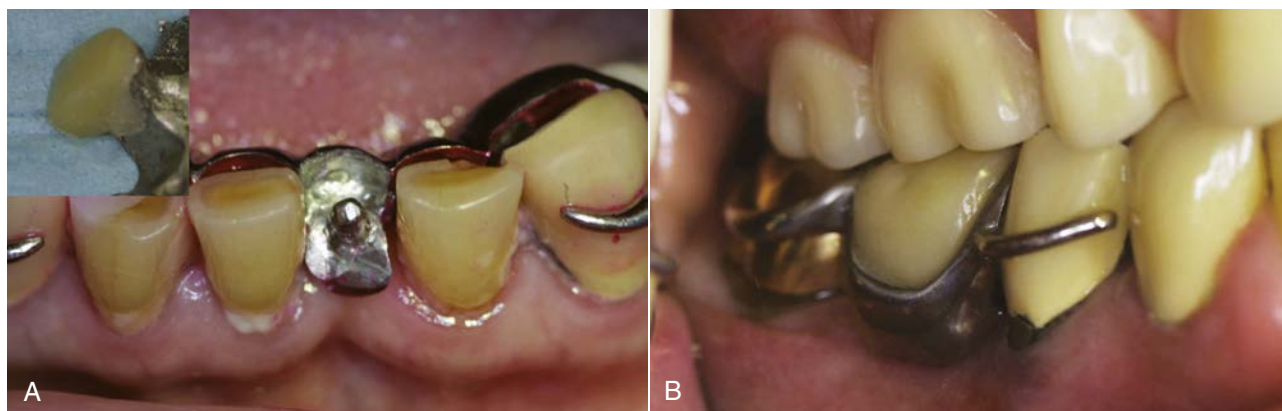
satisfactory hardness and abrasion resistance for many situations. Thus occlusion may be created without resorting to the modification of ready-made artificial teeth (Figure 9-11). Recesses in the denture pattern may be carved by hand or may be created around manufactured teeth that are used only to form the recess in the pattern. Occlusal relationships may be established in the mouth on the denture framework and transferred to an articulator. The teeth can then be carved and processed in acrylic-resin of the proper shade to fit the opposing occlusal record. Better attachment to the metal base than by cementation is thus possible. In addition, unusually long, short, wide, or narrow teeth may be created when necessary to fill spaces not easily filled by the limited selection of commercially-available teeth.

Occlusion on acrylic-resin teeth may be reestablished to compensate for wear or settling by reprocessing new acrylic-resin or using light-activated acrylic-resin when this becomes necessary. A distinction always should be made between the need for relining to reestablish occlusion (on a distal extension partial denture) and the need for rebuilding occlusal surfaces on an otherwise satisfactory base (on a tooth-supported or a tooth- and tissue-supported partial denture).

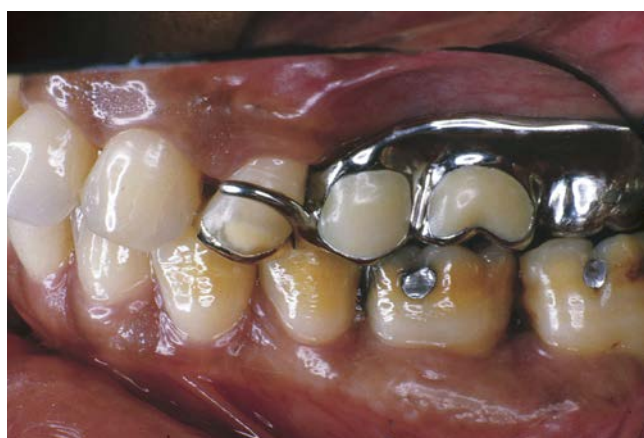Reestablishment of occlusion may also be accomplished by placing cast gold or other suitable cast alloy restorations on existing resin teeth. Although this may



**FIGURE 9-10** Stock porcelain or resin tube tooth, or artificial tooth used as tube tooth, should be ground to accommodate cast coping as illustrated. A hole is drilled from the underside of the tooth, or, if a hole is already present, it is made larger. Then the tooth is ground to fit the ridge with enough clearance for minimum thickness of metal. A 45-degree bevel then is formed around the base of the tooth; finally, a collar is created on the lingual side, extending to the interproximal area. The tooth is then lubricated, and a wax pattern for the denture base is formed around it.



**FIGURE 9-11** Direct attachment of resin teeth to metal bases. **A**, Anterior modification space prepared to receive a denture tooth, which will be reinforced with a post. **B**, Posterior molar attached to a previously waxed base to specifically receive the replacement tooth.



**FIGURE 9-12** Maxillary cast molar designed as an integral part of the framework. Interocclusal space limitation necessitated the use of metal rather than another form of artificial posterior teeth. Note overlays on premolar and molar teeth were used to resist tooth wear. (Courtesy of Dr. C.J. Andres, Indianapolis, IN.)

be done on porcelain teeth as well, it is difficult to cut preparations in porcelain teeth unless air abrasive methods are used. Therefore, if later additions to occlusal surfaces are anticipated, acrylic-resin teeth should be used, thereby facilitating the addition of new resin or cast gold surfaces. A simple technique that can be used to fabricate cast gold occlusal surfaces and attach them to resin teeth is described in Chapter 19.

### Metal Teeth

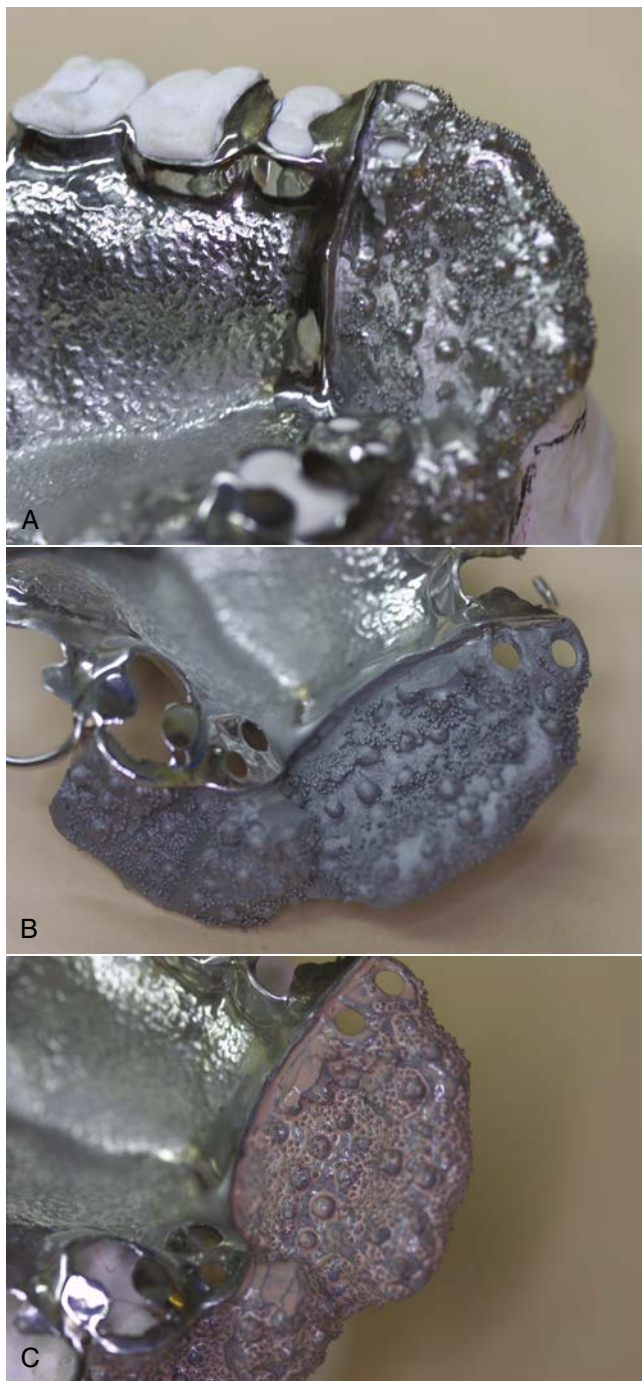
Occasionally, a second molar tooth may be replaced as part of the partial denture casting (Figure 9-12). This is usually done when space is too limited for the attachment of an artificial tooth and yet the addition of a second molar is desirable to prevent extrusion of an opposing second molar. Because the occlusal surface must be waxed before

casting, perfect occlusion is not possible. Because metal, particularly a chrome alloy, is abrasion resistant, the area of occlusal contact should be held to a minimum to avoid damage to the periodontium of the opposing tooth and associated discomfort to the patient. Occlusal adjustment on gold occlusal surfaces is readily accomplished, whereas metal teeth made of chrome alloys are difficult to adjust and are objectionably hard for use as occlusal surfaces. Therefore they should be used only to fill a space and to prevent tooth extrusion.

### Chemical Bonding

Recent developments in resin bonding have provided a means of direct chemical bonding of acrylic-resin to metal frameworks. The investing alveolar and gingival tissue replacement components can be attached without the use of loops, mesh, or surface mechanical locks. Sections of a metal framework that are used to support replacement teeth can be roughened with abrasives and then treated with a vaporized silica coating. On this surface, an acrylic-resin bonding agent is applied, followed by a thin film of acrylic-resin that acts as a substrate for later attachment of replacement acrylic-resin teeth or for processing of acrylic-resin tissue replacements (Figure 9-13).

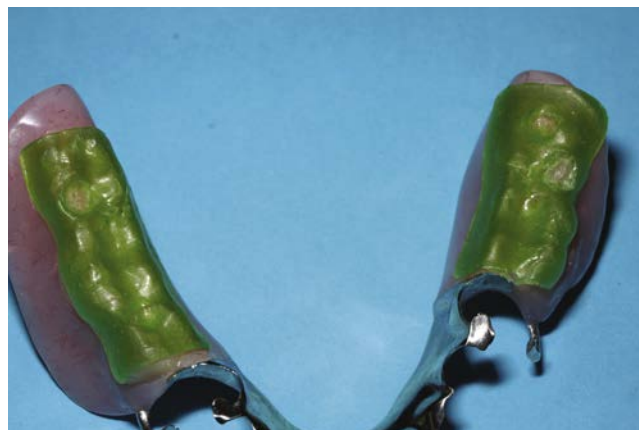A second method of fusing a microscopic layer of ceramic to the metal is accomplished by a process referred to as *tribochemical coating*. This system involves sandblasting the metal framework with a special silica particle material, Rocatec-Plus (3M Espe Dental Products, Irvine, CA). Silica from these particles is attached to the framework by impact. A silane is added to this ceramic-like film to form a chemical bond between the silicate layer and the denture base acrylic-resin. Denture base acrylic-resins formulated with 4-meta are also available and provide a mechanism for bonding acrylic-resin to metal.



**FIGURE 9-13** Coating of metal framework with silica facilitates improved application and seal of resin or composite for denture base regions. Example shows a maxillary minor with beads for added retention of the anterior denture base (A), after air abrasion preparation of the surface (B), and after sili-coating (C).

### NEED FOR RELINING

The distal extension base differs from the tooth-supported base in several respects, one of which is that it must be made of a material that can be relined or rebased when it becomes necessary to reestablish tissue support for the distal extension



**FIGURE 9-14** 28-gauge soft green wax used to identify occlusal contacts between a mandibular Class I distal extension base and an opposing complete denture.

base. Therefore acrylic-resin denture base materials that can be relined are generally used.

Although satisfactory techniques for making distal extension partial denture bases of cast metal are available, the fact that metal bases are difficult if not impossible to reline limits their use to stable ridges that will change little over a long period.

Loss of support for distal extension bases results from changes in residual ridge form over time. These changes may not be readily visible; however, manifestations of this change can be assessed. One of these is loss of occlusion between the distal extension denture base and the opposing dentition, which increases as the distance from the abutment increases (Figure 9-14). This change is proved by having the patient close on strips of 28-gauge green casting wax, or any similar wax, and tapping in centric relation only. Indentations in a wax strip of known thickness are quantitative, whereas marks made with articulating ribbon are only qualitative. In other words, indentations in the wax may be interpreted as light, medium, or heavy, whereas it is difficult if not impossible to interpret a mark made with articulating ribbon as light or heavy. In fact, the heaviest occlusal contact may perforate paper-articulating ribbon and make a lesser mark than areas of lighter contact. Therefore the use of any articulating ribbon is of limited value in checking occlusion intraorally. In making occlusal adjustments, articulating ribbon should be used only to indicate where relief should be provided after the need for relief has been established by using wax strips of known thickness. For this purpose, 28-gauge green or blue casting wax is generally used, although the thinner 30-gauge or the thicker 26-gauge wax may be used for better evaluation of the clearance between areas not in contact.

Loss of support for a distal extension base results in loss of occlusal contact between the prosthetically supplied teeth and the opposing dentition and a return to heavy occlusal contact between the remaining natural teeth. Usually this is an indication that relining is needed to reestablish

the original occlusion by reestablishing supporting contact with the residual ridge. It must be remembered, however, that occlusion on a distal extension base is sometimes maintained at the expense of extrusion of the opposing natural teeth. In such a situation, checking the occlusion alone will not show that settling of the extension base has occurred because changes in the supporting ridge may have also taken place.

A second manifestation of change also must be observable to justify relining. This second manifestation of change in the supporting ridge is evidence of rotation about the fulcrum line with the indirect retainers lifting from their seats as the distal extension base is pressed against the ridge tissues. Originally, if the distal extension base was made to fit the supporting form of the residual ridge, rotation about the fulcrum line is not visible. At the time the denture is initially placed, no anteroposterior rotational movement should occur when alternating finger pressure is applied to the indirect retainer and the distal end of a distal extension base or bases. After changes in the ridge form have occurred, which cause some loss of support, rotation occurs about the fulcrum line when alternating finger pressure is applied. This indicates changes in the supporting ridge that must be compensated for by relining or rebasing.

If occlusal contact has been lost and rotation about the fulcrum line is evident, relining is indicated. On the other hand, if occlusal contact has been lost without any evidence of denture rotation, and if stability of the denture base is otherwise satisfactory, reestablishing the occlusion is the remedy, rather than relining. For the latter, the original denture base may be used in much the same manner as the original trial base was used to record the occlusal relation. Teeth may then be reoriented to an opposing cast or to an occlusal template with the use of light-activated tooth-colored acrylic-resin, tooth-colored composite, cast occlusal surfaces, or new teeth. In any event, a new occlusion should be established on the existing bases. Relining in this instance would be the wrong solution to the problem.

Loss of support may also be assessed clinically by other methods. A layer of rather free-flowing irreversible hydrocolloid, wax, or tissue-conditioning material can be spread on the basal seat portion of the dried denture base(s), and the restoration returned to the patient's mouth. Care is exercised to ensure that the framework is correctly seated (rests and indirect retainers in planned positions). The restoration is removed when the material has set. Significant thicknesses of material remaining under the bases indicate lack of intimate contact of the bases with the residual ridges, suggesting a need for relining.

More often, however, loss of occlusion is accompanied by settling of the denture base to the extent that rotation about the fulcrum line is manifest. Because relining is the only remedy short of making completely new bases, use of an acrylic-resin base originally facilitates later relining. For this reason, acrylic-resin bases are generally preferred for distal extension partial dentures.

The question remains as to when, if ever, metal bases with their several advantages may be used for distal extension partial dentures. It is debatable as to what type of ridge will most likely remain stable under functional loading without apparent change. Certainly the age and general health of the patient will influence the ability of a residual ridge to support function. Minimum and harmonious occlusion and the accuracy with which the base fits the underlying tissues will influence the amount of trauma that will occur under function. The absence of trauma plays a big part in the ability of the ridge to maintain its original form.

The best indication for the use of metal distal extension bases is a ridge that has supported a previous partial denture without having become narrowed or flat or without consisting primarily of easily displaceable tissues. When such changes have occurred under a previous denture, further change may be anticipated because of the possibility that the oral tissues in question are not capable of supporting a denture base without further change. Despite every advantage in their favor, some individuals have ridges that respond unfavorably when called on to support any denture base.

In other instances, such as when a new partial denture is to be made because of the loss of additional teeth, the ridges may still be firm and healthy. Because the ridges have previously supported a denture base and have sustained occlusion, bony trabeculae will have become arranged to best support vertical and horizontal loading, cortical bone may have been formed, and tissues will have become favorable for continued support of a denture base.

In only a relatively few situations is the need for relining a distal extension base not anticipated; metal bases may be considered. However, many instances may be considered borderline. In these cases, metal bases may be used with full understanding on the part of the patient that a new denture may become necessary if unforeseen tissue changes occur. The technique shown in [Figure 9-6](#) permits replacement of metal distal extension bases without the need to remake the entire denture. This method should be seriously considered any time a distal extension partial denture is to be made with a metal base or bases.

For reasons previously outlined, the possibility that tissues will remain healthier beneath a metal base than they will beneath an acrylic-resin base may justify wider use of metal bases for distal extension partial dentures. Through careful treatment planning, better patient education on the problems involved in making a distal extension base partial denture, and greater care taken in the fabrication of denture bases, metal may be used to advantage in some situations in which acrylic-resin bases are ordinarily used.

### STRESS-BREAKERS (STRESS EQUALIZERS)

The previous chapters describing component parts of a partial denture have presumed absolute rigidity of all parts of the partial denture framework except the retentive arm of the direct retainer. All vertical and horizontal

forces applied to the artificial teeth are thus distributed throughout the supporting portions of the dental arch. Broad distribution of stress is accomplished through the rigidity of the major and minor connectors. The effects of the stabilizing components are also made possible by the rigidity of the connectors.

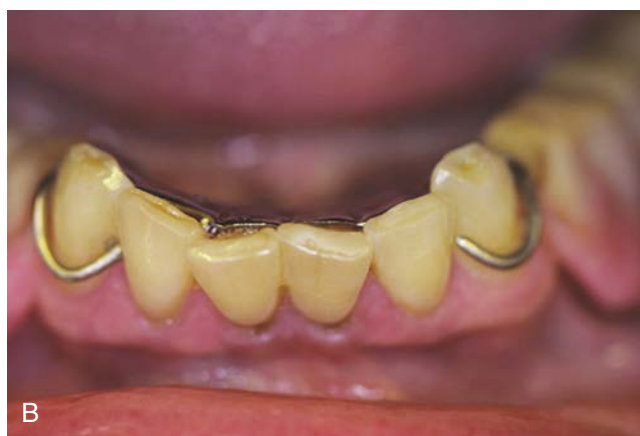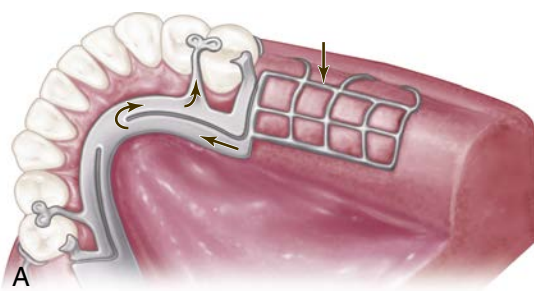
In distal extension situations, the use of a rigid connection between the denture base and supporting teeth must account for base movement without causing tooth or tissue damage. In such situations, stress on the abutment teeth and residual ridge is minimized through the use of functional basing, broad coverage, harmonious occlusion, and correct choice of direct retainers. Generally, two major types of clasp assemblies are used for distal extensions because of their stress-breaking design. Retentive clasp arms may be cast only if they engage undercuts on the abutment teeth in such a manner that tissue-ward movement of the extension base transmits only minimum leverage to the abutment. Otherwise, tapered wrought-wire retentive clasp arms should be used because of their greater flexibility. The tapered, round wrought-wire clasp arm acts somewhat as a stress-breaker between the denture base and the abutment tooth by reducing the effects of denture base movement on the tooth through its flexibility.

Another concept of stress-breaking insists on separating the actions of the retaining elements from the

movement of the denture base by allowing independent movement of the denture base (or its supporting framework) and the direct retainers. This form of stress-breaker, also referred to as a *stress equalizer*, has been used as a means of compensating for inappropriately designed removable partial dentures. Figure 9-15 shows an example of a split bar major connector, which is a commonly used stress breaker.

Regardless of their design, most all stress-breakers effectively dissipate vertical stresses, which is the purpose for which they are used. However, this occurs at the expense of horizontal stability and the harmful effects of reduced horizontal stability (excessive ridge resorption, tissue impingement, inefficient mastication), which far outweigh the benefits of vertical stress-breaking. It is the rigid nature of the more conventional removable partial denture that allows satisfaction of all requirements for support, stability, and retention without overemphasis on only one principle to the detriment of the oral tissues.

The student is referred to two textbooks that describe in detail the use of stress-breakers and articulated partial denture designs: (1) *Precision Attachments in Dentistry*, ed 3, by H.W. Preiskel; and (2) *Theory and Practice of Precision Attachment Removable Partial Dentures*, by J.L. Baker and R.J. Goodkind.



**FIGURE 9-15** With occlusal loading of posterior distal extensions (**A**), the superior edge of the mandibular lingual plate major connector is displaced from the planned contact (**B**). If appropriate contact of the major connector and teeth does not return after release of the distal load, this suggests ridge support is poor and occlusal function is suboptimum. The denture base should be considered for a relined to reestablish occlusion contact, ensuring functional use.

# CHAPTER

# 10

## Principles of Removable Partial Denture Design

### CHAPTER OUTLINE

#### Difference in Prosthesis Support and Influence on Design Differentiation Between Two Main Types of Removable

##### Partial Dentures

Differences in Support

Impression Registration

Differences in Clasp Design

#### Essentials of Partial Denture Design

#### Components of Partial Denture Design

Tooth Support

Ridge Support

Major and Minor Connectors

Direct Retainers for Tooth-Supported Partial Dentures

Direct Retainers for Distal Extension Partial Dentures

Stabilizing Components

Guiding Plane

Indirect Retainers

#### Implant Considerations in Design

#### Examples of Systematic Approach to Design

Required Tooth Modification for Removable Partial Dentures

Implant Considerations

Kennedy Class II Removable Partial Dentures

Class III Removable Partial Denture

Kennedy Class I, Bilateral, Distal Extension Removable Partial Dentures

#### Additional Considerations Influencing Design

Use of a Splint Bar for Denture Support

Internal Clip Attachment

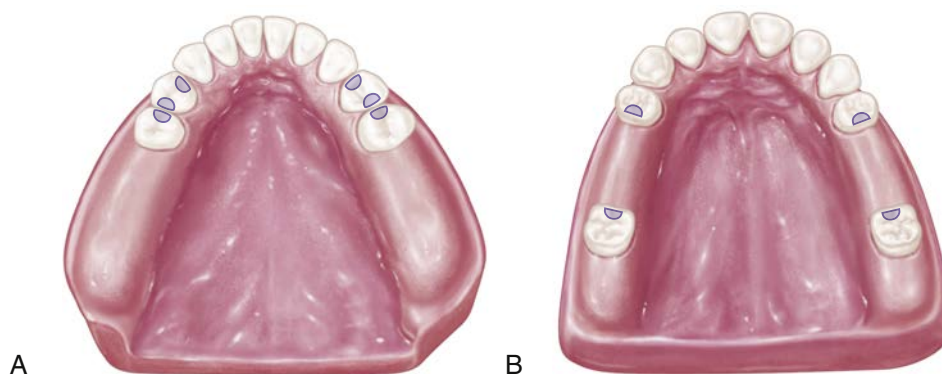
Overlay Abutment as Support for a Denture Base

Use of a Component Partial to Gain Support

### DIFFERENCE IN PROSTHESIS SUPPORT AND INFLUENCE ON DESIGN

Some of the biomechanical considerations of removable partial denture (RPD) design were presented in Chapter 4. The strategy of selecting component parts for a partial denture to help control movement of the prosthesis under functional load has been highlighted as a method to be considered for logical partial denture design. The requirements for movement control are generally functions of whether the prosthesis will be tooth supported or tooth-tissue supported.

For a tooth-supported prosthesis, the movement potential is less because resistance to functional loading is provided by the teeth. Teeth do not vary widely in their ability to provide this support; consequently, designs for prostheses are less variable. This is the case even though the amount of supporting bone, the crown-to-root ratios, the crown and root morphologies, and the tooth number and position in the arch relative to edentulous spaces are well established and may be variable for tooth- and tooth-tissue-supported RPDs. For a tooth-tissue-supported prosthesis, the residual ridge (remaining alveolar bone and overlying connective tissue covered with mucosa) presents with variable potential for support. Not only does the underlying alveolar bone demonstrate a highly variable form following extraction, it continues to change with time. As alveolar bone responds to the loss of teeth, the overlying connective tissue and mucosa undergo change that places the soft tissue at risk for pressure-induced inflammatory changes. This variable tissue support potential adds complexity to design considerations when one is dealing with tooth-tissue-supported prostheses. This occurs because unlike the efficient support provided by teeth, which results in limited prosthesis movement, the reaction of the ridge tissue to functional forces can be highly variable, leading to variable amounts of prosthesis movement. An understanding of the potential



**FIGURE 10-1** A, Kennedy Class I partially edentulous arch. Major support for denture bases must come from residual ridges, tooth support from occlusal rests being effective only at the anterior portion of each base. B, Kennedy Class III, modification 1, partially edentulous arch provides total tooth support for the prosthesis. A removable partial denture (RPD) made for this arch is totally supported by rests on properly prepared occlusal rest seats on four abutment teeth.

sources of functional force from the opposing arch that can have an effect on the movement potential of the prosthesis is helpful.

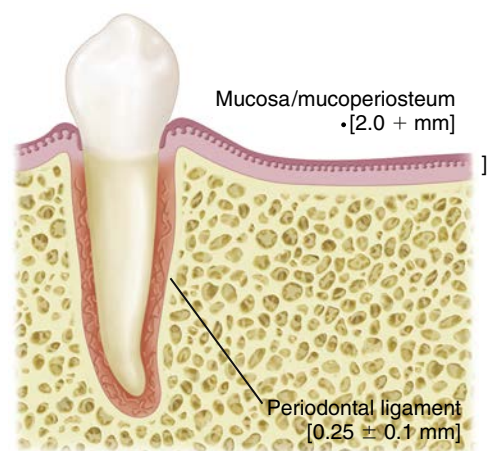
Factors related to the opposing arch tooth position, the existence and nature of prosthesis support in the opposing arch, and the potential for establishing a harmonious occlusion can greatly influence the partial denture design. Opposing tooth positions that apply forces outside the primary support of the prosthesis can introduce leverage forces that act to dislodge the prosthesis. Such an effect is variable and is based on the nature of the opposing occlusion, because the forces of occlusion differ between natural teeth, RPDs, and complete dentures. In general, RPDs opposing natural teeth require greater support and stabilization over time because of the greater functional load demands. Therefore, occlusal relationships at maximum intercuspation should be broadly dissipated to the supporting units.

### DIFFERENTIATION BETWEEN TWO MAIN TYPES OF REMOVABLE PARTIAL DENTURES

On the basis of the previous discussion, it is clear that two distinctly different types of RPDs exist. Certain points of difference are present between Kennedy Class I and Class II types of partial dentures on the one hand and the Class III type of partial denture on the other. The first consideration is the manner in which each is supported. The Class I type and the distal extension side of the Class II type derive their primary support from tissues underlying the base and secondary support from the abutment teeth (Figure 10-1, A, and Figure 10-2). The Class III type derives all of its support from the abutment teeth (see Figure 10-1, B, and Figure 10-2).

Second, for reasons directly related to the manner of support, the method of impression registration and the jaw record required for each type will vary.

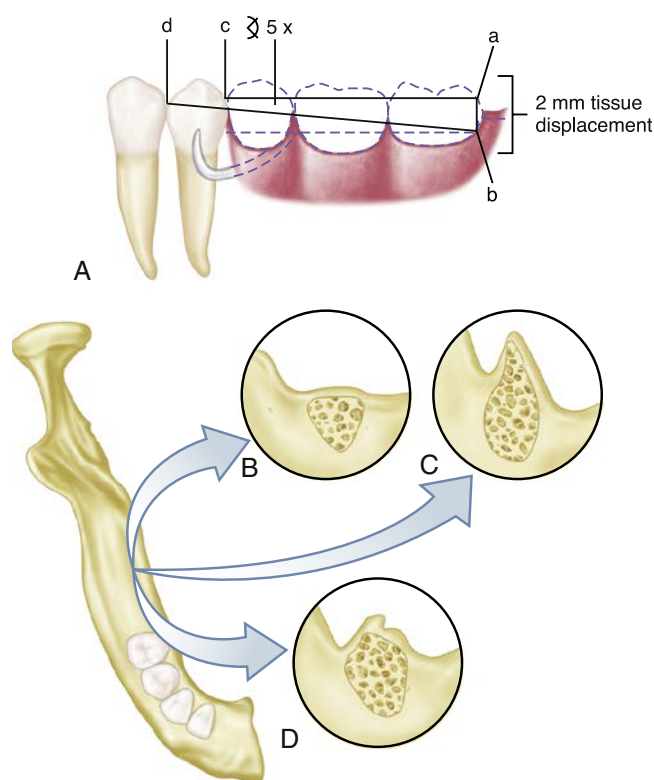
Third, the need for some kind of indirect retention exists in the distal extension type of partial denture, whereas in the



**FIGURE 10-2** Distortion of tissues over the edentulous ridge will be approximately 500  $\mu$ m under 4 newtons of force, whereas abutment teeth will demonstrate approximately 20  $\mu$ m of intrusion under the same load.

tooth-supported, Class III type, no extension base is present to lift away from the supporting tissues because of the action of sticky foods and the movements of tissues of the mouth against the borders of the denture. This is so because each end of each denture base is secured by a direct retainer on an abutment tooth. Therefore the tooth-supported partial denture does not rotate about a fulcrum, as does the distal extension partial denture.

Fourth, the manner in which the distal extension type of partial denture is supported often necessitates the use of a base material that can be relined to compensate for tissue changes. Acrylic-resin is generally used as a base material for distal extension bases. The Class III partial denture, on the other hand, which is entirely tooth supported, does not require relining except when it is advisable to eliminate an unhygienic, unesthetic, or uncomfortable condition resulting from loss of tissue contact. Metal bases therefore



**FIGURE 10-3** A, The longer the edentulous area covered by the denture base, the greater the potential lever action on the abutment teeth. If an extension base area is 30 mm ( $ac$ ) and tissue displacement is 2 mm ( $ab$ ), the amount of movement of the proximal plate on the guiding plane will be approximately 0.25 mm: [ $\alpha = \sqrt{(ab)^2 + (ac)^2}$ ]; arc of the tangent  $ab/ad = x/cd$  ( $2/30 = x/3.75 = 0.25$  mm). B, The flat ridge will provide good support, poor stability. C, The sharp spiny ridge will provide poor support, poor to fair stability. D, Displaceable tissue on the ridge will provide poor support and poor stability.

are more frequently used in tooth-supported restorations, because relining is not as likely to be necessary with them.

### Differences in Support

The distal extension partial denture derives its major support from the residual ridge with its fibrous connective tissue covering. The length and contour of the residual ridge significantly influence the amount of available support and stability (Figure 10-3). Some areas of this residual ridge are firm, with limited displaceability, whereas other areas are displaceable, depending on the thickness and structural character of the tissues overlying the residual alveolar bone. The movement of the base under function determines the occlusal efficiency of the partial denture and also the degree to which the abutment teeth are subjected to torque and tipping stresses. The negative impact of the residual ridge character on the support provided to the occlusion in a specific arch can be addressed through the use of a dental implant, rendering displaceable tissue with movement potential into a more resistant support for occlusion.

### Impression Registration

An impression registration for the fabrication of a partial denture must fulfill the following two requirements:

1. The anatomic form and the relationship of the remaining teeth in the dental arch, as well as the surrounding soft tissues, must be recorded accurately so the denture will not exert pressure on those structures beyond their physiologic limits. A type of impression material that can be removed from undercut areas without permanent distortion must be used to fulfill this requirement. Elastic impression materials such as irreversible hydrocolloid (alginate), mercaptan rubber base (Thiokol), silicone impression materials (both condensation and addition reaction), and the polyethers are best suited for this purpose.
2. The supporting form of the soft tissues underlying the distal extension base of the partial denture should be recorded so firm areas are used as primary stress-bearing areas and readily displaceable tissues are not overloaded. Only in this way can maximum support of the partial denture base be obtained. An impression material capable of displacing tissue sufficiently to register the supporting form of the ridge will fulfill this second requirement. A fluid mouth-temperature wax or any of the readily flowing impression materials (rubber base, the silicones, or the polyethers in an individual, corrected tray) may be employed for registering the supporting form. Zinc oxide-eugenol impression paste can also be used when only the extension base area is being impressed (see Chapter 16).

No single impression material can satisfactorily fulfill both of the previously mentioned requirements. Recording the anatomic form of both teeth and supporting tissues will result in inadequate support for the distal extension base. This is because the cast will not represent the optimum coordinating forms, which require that the ridge be related to the teeth in a supportive form. This coordination of support maximizes the support capacity for the arch and minimizes movement of the partial denture under function.

### Differences in Clasp Design

A fifth point of difference between the two main types of RPDs lies in their requirements for direct retention.

The tooth-supported partial denture, which is totally supported by abutment teeth, is retained and stabilized by a clasp at each end of each edentulous space. Because this type of prosthesis does not move under function (other than within the physiologic limitations of tooth support units), the only requirement for such clasps is that they flex sufficiently during placement and removal of the denture to pass over the height of contour of the teeth in approaching or escaping from an undercut area. While in its terminal position on the tooth, a retentive clasp should be passive and should not flex except when one is engaging the undercut area of the tooth for resisting a vertical dislodging force.

Cast retentive arms are generally used for this purpose. These may be of the circumferential type, arising from the body of the clasp and approaching the undercut from an

occlusal direction, or of the bar type, arising from the base of the denture and approaching the undercut area from a gingival direction. Each of these two types of cast clasps has its advantages and disadvantages.

In the combination tooth- and tissue-supported RPD, because of the anticipated functional movement of the distal extension base, the direct retainer adjacent to the distal extension base must perform still another function, in addition to resisting vertical displacement. Because of the lack of tooth support distally, the denture base will move tissue-ward under function proportionate to the quality (displaceability) of the supporting soft tissues, the accuracy of the denture base, and the total occlusal load applied. Because of this tissue-ward movement, those elements of a clasp that lie in an undercut area mesial to the fulcrum for a distal extension (as is often seen with a distal rest) must be able to flex sufficiently to dissipate stresses that otherwise would be transmitted directly to the abutment tooth as leverage. On the other hand, a clasp used in conjunction with a mesial rest may not transmit as much stress to the abutment tooth because of the reduction in leverage forces that results from a change in the fulcrum position. This serves the purpose of reducing or “breaking” the stress, hence the term *stress-breakers*, and is a strategy that is often incorporated into partial denture designs through various means. Some dentists strongly believe that a stress-breaker is the best means of preventing leverage from being transmitted to the abutment teeth. Others believe just as strongly that a wrought-wire or bar-type retentive arm more effectively accomplishes this purpose with greater simplicity and ease of application. A retentive clasp arm made of wrought wire can flex more readily in all directions than can the cast half-round clasp arm. Thereby, it may more effectively dissipate those stresses that would otherwise be transmitted to the abutment tooth.

Only the retentive arm of the circumferential clasp, however, should be made of wrought metal. Reciprocation and stabilization against lateral and torquing movements must be obtained through use of the rigid cast elements that make up the remainder of the clasp. This is called a *combination clasp* because it is a combination of cast and wrought materials incorporated into one direct retainer. It is frequently used on the terminal abutment for the distal extension partial denture and is indicated where a mesiobuccal but no distobuccal undercut exists, or where a gross tissue undercut, cervical and buccal to the abutment tooth, exists. It must always be remembered that the factors of length and material contribute to the flexibility of clasp arms. From a materials physical property standpoint, a short wrought-wire arm may be a destructive element because of its reduced ability to flex compared with a longer wrought-wire arm. However, in addition to its greater flexibility compared with the cast circumferential clasp, the combination clasp offers the advantages of adjustability, minimum tooth contact, and better esthetics, which justify its occasional use in tooth-supported designs.

The amount of stress transferred to the supporting edentulous ridge(s) and the abutment teeth will depend on: (1) the direction and magnitude of the force; (2) the length of the denture base lever arm(s); (3) the quality of resistance (support from the edentulous ridges and remaining natural teeth); and (4) the design characteristics of the partial denture. As was stated in Chapter 7, the location of the rest, the design of the minor connector as it relates to its corresponding guiding plane, and the location of the retentive arm are all factors that influence how a clasp system functions. The greater the surface area contact of each minor connector to its corresponding guiding plane, the more horizontal the distribution of force (Figure 10-4).

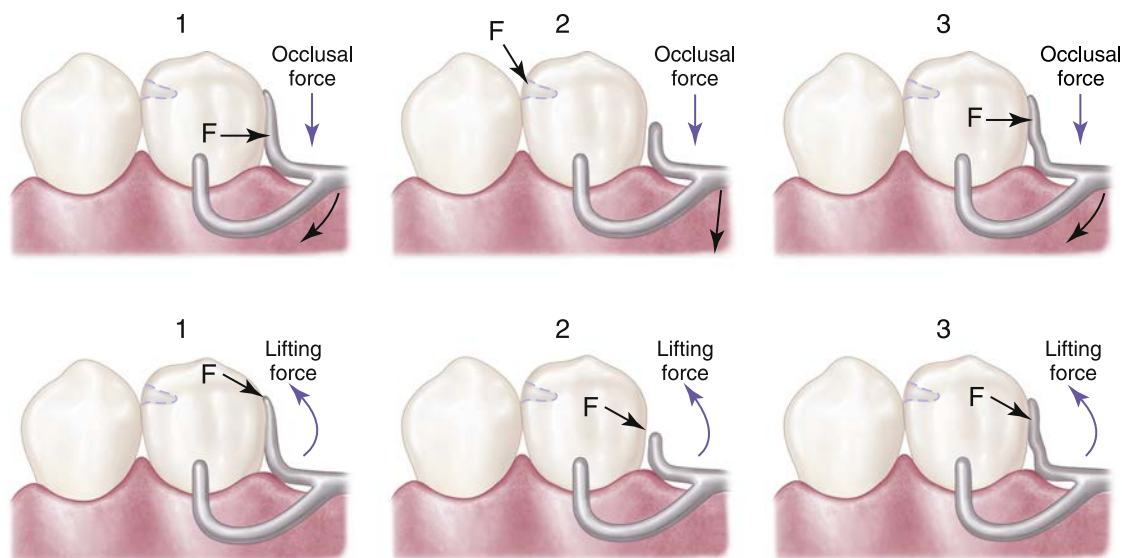
## ESSENTIALS OF PARTIAL DENTURE DESIGN

The design of the partial denture framework should be systematically developed and outlined on an accurate diagnostic cast based on the following prosthesis concepts: where the prosthesis is supported, how the support is connected, how the prosthesis is retained, how the retention and support are connected, and how edentulous base support is connected.

In developing the design, it is first necessary to determine how the partial denture is to be supported. In an entirely tooth-supported partial denture, the most ideal location for the support units (rests) is on prepared rest seats on the occlusal, cingulum, or incisal surface of the abutment adjacent to each edentulous space (see Figure 10-1, B). The type of rest and amount of support required must be based on interpretation of the diagnostic data collected from the patient. In evaluating the potential support that an abutment tooth can provide, consideration should be given to (1) periodontal health; (2) crown and root morphologies; (3) crown-to-root ratio; (4) bone index area (how tooth has responded to previous stress); (5) location of the tooth in the arch; (6) relationship of the tooth to other support units (length of edentulous span); and (7) the opposing dentition. For a more in-depth understanding of these considerations, review Chapters 6 and 13.

In a tooth- and tissue-supported partial denture, attention to these same considerations must be given to the abutment teeth. However, equitable support must come from the edentulous ridge areas. In evaluating the potential support available from edentulous ridge areas, consideration must be given to (1) the quality of the residual ridge, which includes contour and quality of the supporting bone (how the bone has responded to previous stress) and quality of the supporting mucosa; (2) the extent to which the residual ridge will be covered by the denture base; (3) the type and accuracy of the impression registration; (4) the accuracy of the denture base; (5) the design characteristics of the component parts of the partial denture framework; and (6) the anticipated occlusal load. A full explanation of tissue support for extension base partial dentures is found in Chapter 17.

Denture base areas adjacent to abutment teeth are primarily tooth supported. As one proceeds away from the



**FIGURE 10-4** 1, Maximum contact of the proximal plate minor connector with the guiding plane produces a more horizontal distribution of stress to the abutment teeth. 2, Minimum contact or disengagement of the minor connector with the guiding plane allows rotation around the fulcrum located on the mesio-occlusal rest, producing a more vertical distribution of stress to the ridge area. 3, Minor connector contact with the guiding plane from the marginal ridge to the junction of the middle and gingival thirds of the abutment tooth distributes load vertically to the ridge and horizontally to the abutment tooth.  $F$ , The location of the fulcrum of movement for the distal extension base.

abutment teeth, they become more tissue supported. Therefore it is necessary to incorporate characteristics in the partial denture design that will distribute the functional load equitably between the abutment teeth and the supporting tissues of the edentulous ridge. Locating tooth support units (rests) on the principal abutment teeth and designing the minor connectors that are adjacent to the edentulous areas to contact the guiding planes in such a manner that the functional load is dispersed equitably between the available tooth and tissue supporting units will provide designs with controlled distribution of support (see Figure 10-4).

The second step in systematic development of the design for any RPD is to connect the tooth and tissue support units. This connection is facilitated by designing and locating major and minor connectors in compliance with the basic principles and concepts presented in Chapter 5. Major connectors must be rigid so that forces applied to any portion of the denture can be effectively distributed to the supporting structures. Minor connectors arising from the major connector make it possible to transfer functional stress to each abutment tooth through its connection to the corresponding rest and also to transfer the effects of the retainers, rests, and stabilizing components to the remainder of the denture and throughout the dental arch.

The third step is to determine how the RPD is to be retained. The retention must be sufficient to resist reasonable dislodging forces. As was stated in Chapter 7, retention is accomplished by placement of mechanical retaining elements (clasps) on the abutment teeth and by the intimate relationship of the denture bases and major connectors (maxillary) with the underlying tissues. The key to selecting a successful

clasp design for any given situation is to choose one that will (1) avoid direct transmission of tipping or torquing forces to the abutment; (2) accommodate the basic principles of clasp design by definitive location of component parts correctly positioned on abutment tooth surfaces; (3) provide retention against reasonable dislodging forces (with consideration for indirect retention); and (4) be compatible with undercut location, tissue contour, and esthetic desires of the patient. Location of the undercut is the most important single factor in selection of a clasp. Undercut location, however, can be modified by recontouring or restoring the abutment tooth to accommodate a clasp design better suited to satisfy the criteria for clasp selection.

The relative importance of retention is highlighted by the results from a clinical trial investigating prosthesis designs. A 5-year randomized clinical trial of two basic RPD designs—one with rest, proximal plate, and I-bar (RPI) design and one with circumferential clasp design—demonstrated no discernible changes after 60 months in nine periodontal health components of the abutment teeth with either of the two designs. The overall results indicate that the two designs did not differ in terms of success rates, maintenance, or effects on abutment teeth. Therefore, a well-constructed RPD that is supported by favorable abutments and good residual ridges that are properly prepared and maintained in a patient who exhibits good oral hygiene offers the best opportunity for satisfactory treatment.

The fourth step is to connect the retention units to the support units. If direct and indirect retainers are to function as designed, each must be rigidly attached to the major connector. The criteria for selection, location, and design are the

same as those indicated for connecting the tooth and tissue support units.

The fifth and last step in this systematic approach to design is to outline and join the edentulous area to the already established design components. Strict attention to details of the design characteristics outlined in Chapter 9 is necessary to ensure rigidity of the base material without interfering with tooth placement.

## COMPONENTS OF PARTIAL DENTURE DESIGN

All partial dentures have two things in common: (1) they must be supported by oral structures, and (2) they must be retained against reasonable dislodging forces.

In the Kennedy Class III partial denture, three components are necessary: (1) support provided by rests, (2) the connectors (stabilizing components), and (3) the retainers.

The partial denture that does not have the advantage of tooth support at each end of each edentulous space (Kennedy Class I and II) still must be supported, but in this situation, the support comes from both the teeth and the underlying ridge tissues rather than from the teeth alone. This is a composite support, and the prosthesis must be fabricated so that the resilient support provided by the edentulous ridge is coordinated with the more stable support offered by the abutment teeth. The support, connectors, and retainers must take into consideration the movement of tissue-supported denture base areas. In addition, provision must be made for three other factors, as follows:

1. The best possible support must be obtained from the resilient tissues that cover the edentulous ridges. This is accomplished by the impression technique more than by the partial denture design, although the area covered by the partial denture base is a contributing factor in such support.
2. The method of direct retention must take into account the inevitable tissue-ward movement of the distal extension base(s) under the stresses of mastication and occlusion. Direct retainers must be designed so that occlusal loading will result in direct transmission of this load to the long axis of the abutment teeth instead of as leverage.
3. The partial denture, with one or more distal extension denture bases, must be designed so that movement of the extension base away from the tissues will be minimized. This is often referred to as *indirect retention* and is best described in relation to an axis of rotation through the rest areas of the principal abutments (see Chapter 8). However, retention from the RPD base itself frequently can be made to help prevent this movement and, in such instances, may be discussed as direct-indirect retention.

### Tooth Support

Support of the RPD by the abutment teeth is dependent on the alveolar support of those teeth, the crown and root morphology, the rigidity of the partial denture framework, and the design of the occlusal rests. Through clinical and

radiographic interpretation, the dentist may evaluate the abutment teeth and decide whether they will provide adequate support. In some instances, the splinting of two or more teeth, either by using fixed partial dentures or by soldering two or more individual restorations together, is advisable. In other instances, a tooth may be deemed too weak to be used as an abutment, and extraction is indicated in favor of obtaining better support from an adjacent tooth.

Having decided on the abutments, the dentist is responsible for preparation and restoration of the abutment teeth to accommodate the most ideal design of the partial denture. This includes the form of the occlusal rest seats. These modifications may be prepared in sound tooth enamel or in restorative materials that will withstand the functional stress and wear of the component parts of the RPD. The technician cannot be blamed for inadequate abutment tooth preparation, such as occlusal rest support. On the other hand, the technician is solely to blame if he or she extends the casting beyond, or fails to include, the total prepared areas. If the dentist has sufficiently reduced the marginal ridge area of the rest seat to avoid interference from opposing teeth, and if a definite occlusal rest seat is faithfully recorded in the master cast and delineated in the penciled design, then no excuse can be made for poor occlusal rest form on the partial denture.

### Ridge Support

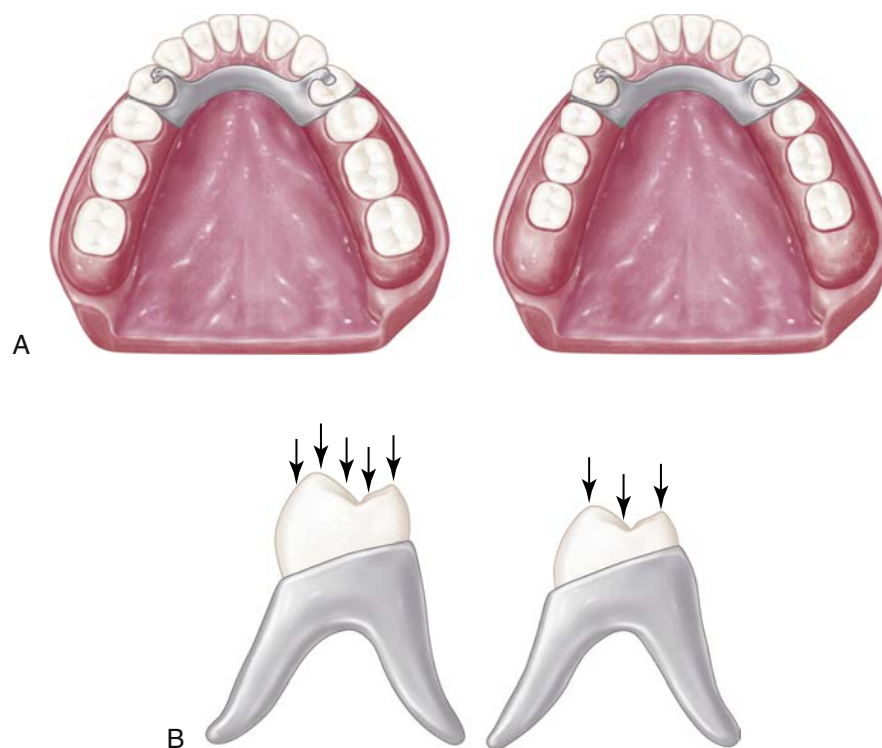
Support for the tooth-supported RPD or the tooth-supported modification space comes entirely from the abutment teeth by means of rests. Support for the distal extension denture base comes primarily from the overlying soft tissues and the residual alveolar bone of the distal extension base area. In the latter, rest support is effective only at the abutment end of the denture base.

The effectiveness of tissue support depends on six things: (1) the quality of the residual ridge; (2) the extent to which the residual ridge will be covered by the denture base; (3) the accuracy and type of impression registration; (4) the accuracy of the denture bases; (5) the design characteristics of component parts of the partial denture framework; and (6) the occlusal load applied.

The quality of the residual ridge cannot be influenced, except that it can be improved by tissue conditioning, or it can be modified by surgical intervention. Such modifications are almost always needed but are not frequently done.

The accuracy of the impression technique is entirely in the hands of the dentist. Maximum tissue coverage for support that encompasses the primary stress-bearing areas should be the primary objective in any partial denture impression technique. The manner in which this is accomplished should be based on biological comprehension of what happens beneath a distal extension denture base when an occlusal load is applied.

The accuracy of the denture base is influenced by the choice of materials and by the exactness of the processing techniques. Inaccurate and warped denture bases adversely



**FIGURE 10-5** **A**, The total occlusal load applied may be reduced by using comparatively smaller posterior teeth represented by the illustration on the *right*. **B**, Less muscular force will be required to penetrate a food bolus with a reduced occlusal table, thereby reducing forces to supporting oral structures.

influence the support of the partial denture. Materials and techniques that will ensure the greatest dimensional stability should be selected.


The total occlusal load applied to the residual ridge may be influenced by reducing the area of occlusal contact. This is done with the use of fewer, narrower, and more effectively shaped artificial teeth (Figure 10-5).

The distal extension RPD is unique in that its support is derived from abutment teeth, which are comparatively unyielding, and from soft tissues overlying bone, which may be comparatively yielding under occlusal forces. Resilient tissues, which are distorted or displaced by occlusal load, are unable to provide support for the denture base comparable with that offered by the abutment teeth. This problem of support is further complicated by the fact that the patient may have natural teeth remaining that can exert far greater occlusal force on the supporting tissues than would result if the patient were completely edentulous. This fact is clearly evident from the damage that often occurs to an edentulous ridge when it is opposed by a few remaining anterior teeth in the opposing arch, and especially when the opposing occlusion of anterior teeth has been arranged so that contact occurs in both centric and eccentric positions. This situation can be best addressed by the use of a dental implant when possible.

Ridge tissues recorded in their resting or nonfunctioning form are incapable of providing the composite support

needed for a denture that derives its support from both hard and soft tissue. Three factors must be considered in the acceptance of an impression technique for distal extension RPDs: (1) the material should record the tissues covering the primary stress-bearing areas in their supporting form; (2) tissues within the basal seat area other than primary stress-bearing areas must be recorded in their anatomic form; and (3) the total area covered by the impression should be sufficient to distribute the load over as large an area as can be tolerated by the border tissues. This is an application of the principle of the snowshoe.

Anyone who has had the opportunity to compare two master casts for the same partially edentulous arch—one cast having the distal extension area recorded in its anatomic or resting form, and the other cast having the distal extension area recorded in its functional form—has been impressed by the differences in topography (Figure 10-6). A denture base processed to the functional form is generally less irregular and provides greater area coverage than does a denture base processed to the anatomic or resting form. Moreover, and of far greater significance, a denture base made to anatomic form exhibits less stability under rotating and/or torquing forces than does a denture base processed to functional form and thus fails to maintain its occlusal relation with opposing teeth. When the patient is asked to close onto strips of soft wax, it is evident that occlusion is maintained at a point of equilibrium over a longer period of time when the denture



**FIGURE 10-6** **A**, Cast of partially edentulous arch representing anatomic form of residual ridges. An impression was made in the stock tray by using irreversible hydrocolloid. **B**, An impression recording the functional or supporting form of residual ridges was made in an individualized impression tray, permitting placement of tissues and definitive border molding.

base has been made to the functional form. In contrast, evidence indicates that rapid “settling” of the denture base occurs when it has been made to the anatomic form, with an early return of the occlusion to natural tooth contact only. Such a denture not only fails to distribute the occlusal load equitably but also allows rotational movement, which is damaging to the abutment teeth and their investing structures.

An implant can efficiently serve to improve ridge support by replacing the tissue compression seen on functional loading with the stiff resistance offered by bone supporting an implant. The benefit for movement control is achieved as if a change was made from a tooth-tissue-borne prosthesis to a tooth-tooth-borne prosthesis.

### Major and Minor Connectors

Major connectors are the units of a partial denture that connect the parts of the prosthesis located on one side of the arch with those on the opposite side. Minor connectors arise from the major connector and join it with other parts of the denture; thus they serve to connect the tooth and tissue support units. A major connector should be properly located in relation to gingival and moving tissues and should be designed to be rigid. Rigidity in a major connector is necessary to provide proper distribution of forces to and from the supporting components.

A lingual bar connector should be tapered superiorly with a half-pear shape in cross section and should be relieved sufficiently but not excessively over the underlying tissues when such relief is indicated. The finished inferior border of a lingual bar or a linguoplate should be gently rounded to avoid irritation to subjacent tissues when the restoration moves even slightly in function.

The use of a linguoplate is indicated when the lower anterior teeth are weakened by periodontal disease. It is also indicated in Kennedy Class I partially edentulous arches when additional resistance to horizontal rotation of the denture is required because of excessively resorbed residual ridges. Still

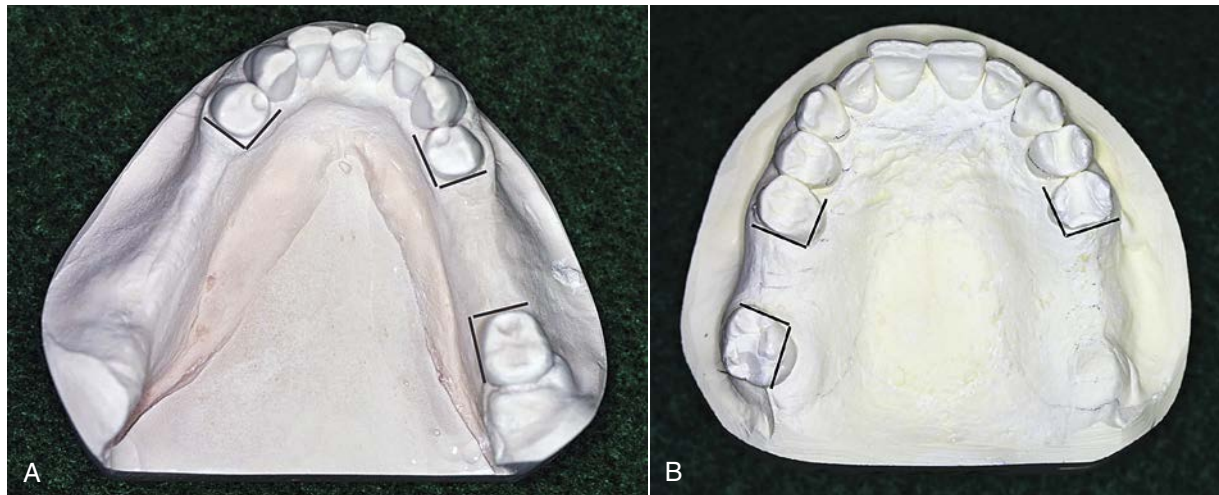
another indication is seen in those situations in which the floor of the mouth so closely approximates the lingual gingiva of anterior teeth that an adequately inflexible lingual bar cannot be positioned without impinging on gingival tissues.

The rigidity of a palatal major connector is just as important and its location and design just as critical as for a lingual bar. A U-shaped palatal connector is rarely justified due to its lack of rigidity, except to avoid an inoperable palatal torus that extends to the junction of the hard and soft palates. Likewise, the routine use of a narrow, single palatal bar can rarely be justified. The combination anterior-posterior palatal strap-type major connector is mechanically and biologically sound if it is located so that it does not impinge on tissues. The broad, anatomic palatal major connector is frequently preferred because of its rigidity, better acceptance by the patient, and greater stability without tissue damage. In addition, this type of connector may provide direct-indirect retention that may sometimes, but rarely, eliminate the need for separate indirect retainers.

### Direct Retainers for Tooth-Supported Partial Dentures

Retainers for tooth-supported partial dentures have only two functions: (1) to retain the prosthesis against reasonable dislodging forces without damage to the abutment teeth and (2) to aid in resisting any tendency of the denture to be displaced in a horizontal plane. The prosthesis cannot move tissue-ward because the retentive components of the clasp assembly are supported by the rest. No movement away from the tissues should occur, and therefore no rotation about a fulcrum, because the retentive component is secured by a direct retainer.

Any type of direct retainer is acceptable as long as the abutment tooth is not jeopardized by its presence. Intracoronal (frictional) retainers are ideal for tooth-supported restorations and offer esthetic advantages that are not possible with extracoronal (clasp) retainers. Nevertheless, circumferential



**FIGURE 10-7** Prospective guiding plane surfaces are indicated by lines located on the respective surfaces of abutment teeth. These surfaces, when used, can be made vertically parallel to the path of placement. However, by including guiding plane surfaces, which are not in the same parallel plane horizontally (*arrows*) but are divergent, cross-arch resistance to horizontal rotation of the denture is enhanced.

and bar-type clasp retainers are mechanically effective and are more economically constructed than are intracoronal retainers. Therefore they are more universally used.

Vulnerable areas on the abutment teeth must be protected by restorations with either type of retainer. The clasp retainer must not impinge on gingival tissues. The clasp must not exert excessive torque on the abutment tooth during placement and removal. It must be located the least distance into the tooth undercut for adequate retention, and it must be designed with a minimum of bulk and tooth contact.

The bar clasp arm should be used only when the area for retention lies close to the gingival margin of the tooth and little tissue blockout is necessary. If the clasp must be placed high, if the vestibule is extremely shallow, or if an objectionable space would exist beneath the bar clasp arm because of blockout of tissue undercuts, the bar clasp arm should not be used. In the event of an excessive tissue undercut, consideration should be given to recontouring the abutment and using some type of circumferential direct retainer.

### Direct Retainers for Distal Extension Partial Dentures

Retainers for distal extension partial dentures, while retaining the prosthesis, must also be able to flex or disengage when the denture base moves tissue-ward under function. Thus the retainer may act as a stress-breaker. Mechanical stress-breakers accomplish the same thing, but they do so at the expense of horizontal stabilization. When some kind of mechanical stress-breaker is used, the denture flange must be able to prevent horizontal movement. Clasp designs that allow flexing of the retentive clasp arm may accomplish the same purpose as that of mechanical stress-breakers, without sacrificing horizontal stabilization and with less complicated techniques.

In evaluating the ability of a clasp arm to act as a stress-breaker, one must realize that flexing in one plane is not

enough. The clasp arm must be freely flexible in any direction, as dictated by the stresses applied. Bulky, half-round clasp arms cannot do this, and neither can a bar clasp engaging an undercut on the side of the tooth away from the denture base. Round, tapered clasp forms offer the advantages of greater and more universal flexibility, less tooth contact, and better esthetics. Either the combination circumferential clasp with its tapered wrought-wire retentive arm or the carefully located and properly designed circumferential or bar clasp can be considered for use on all abutment teeth adjacent to extension denture bases if the abutment teeth have been properly prepared and tissue support effectively achieved, and if the patient exercises good oral hygiene.

### Stabilizing Components

Stabilizing components of the RPD framework are those rigid components that assist in stabilizing the denture against horizontal movement. The purpose of all stabilizing components should be to distribute stresses equally to all supporting teeth without overworking any one tooth. The minor connectors that join the rests and the clasp assemblies to the major connector serve as stabilizing components.

All minor connectors that contact vertical tooth surfaces (and all reciprocal clasp arms) act as stabilizing components. It is necessary that minor connectors have sufficient bulk to be rigid and yet present as little bulk to the tongue as possible. This means that they should be confined to interdental embrasures whenever possible. When minor connectors are located on vertical tooth surfaces, it is best that these surfaces be parallel to the path of placement. When cast restorations are used, these surfaces of the wax patterns should be made parallel on the surveyor before casting.

A modification of minor connector design has been proposed that places the minor connector in the center of the lingual surface of the abutment tooth (*Figure 10-7*). Proponents of this design claim that it reduces the amount of

gingival tissue coverage and provides enhanced bracing and guidance during placement. Disadvantages may include increased encroachment on the tongue space, more obvious borders, and potentially greater space between the connector and the abutment tooth. This proposed variation, however, when combined with thoughtful design principles, may provide some benefit to the periodontal health of the abutment teeth and may be acceptable to some patients.

Reciprocal clasp arms also must be rigid, and they must be placed occlusally to the height of contour of the abutment teeth, where they will be nonretentive. By their rigidity, these clasp arms reciprocate the opposing retentive clasp; they also prevent horizontal movement of the prosthesis under functional stresses. For a reciprocal clasp arm to be placed favorably, some reduction of the tooth surfaces involved is frequently necessary to increase the suprabulge area.

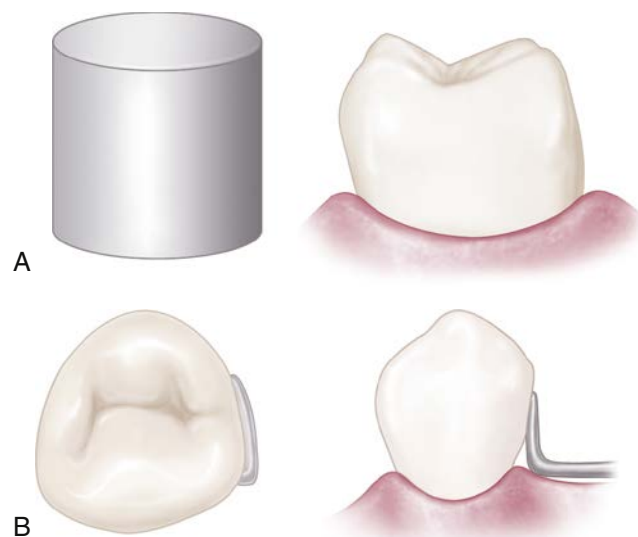When crown restorations are used, a lingual reciprocal clasp arm may be inset into the tooth contour by providing a ledge on the crown on which the clasp arm may rest. This permits the use of a wider clasp arm and restores a more nearly normal tooth contour, at the same time maintaining its strength and rigidity (see Chapter 15).

### Guiding Plane

The term *guiding plane* is defined as two or more parallel, vertical surfaces of abutment teeth, so shaped to direct a prosthesis during placement and removal. After the most favorable path of placement has been ascertained, axial surfaces of abutment teeth are prepared parallel to the path of placement, and therefore become parallel to each other. Guiding planes may be contacted by various components of the partial denture—the body of an extracoronal direct retainer, the stabilizing arm of a direct retainer, the minor connector portion of an indirect retainer—or by a minor connector specifically designed to contact the guiding plane surface.

The functions of guiding plane surfaces are as follows: (1) to provide for one path of placement and removal of the restoration (to eliminate detrimental strain to abutment teeth and framework components during placement and removal); (2) to ensure the intended actions of reciprocal, stabilizing, and retentive components (to provide retention against dislodgment of the restoration when the dislodging force is directed other than parallel to the path of removal and also to provide stabilization against horizontal rotation of the denture); and (3) to eliminate gross food traps between abutment teeth and components of the denture.

Guiding plane surfaces need to be created so that they are as nearly parallel to the long axes of abutment teeth as possible. Establishing guiding planes on several abutment teeth (preferably more than two teeth), located at widely separated positions in the dental arch, provides for more effective use of these surfaces. The effectiveness of guiding plane surfaces is enhanced if these surfaces are prepared on more than one common axial surface of the abutment teeth (see Figure 10-7).



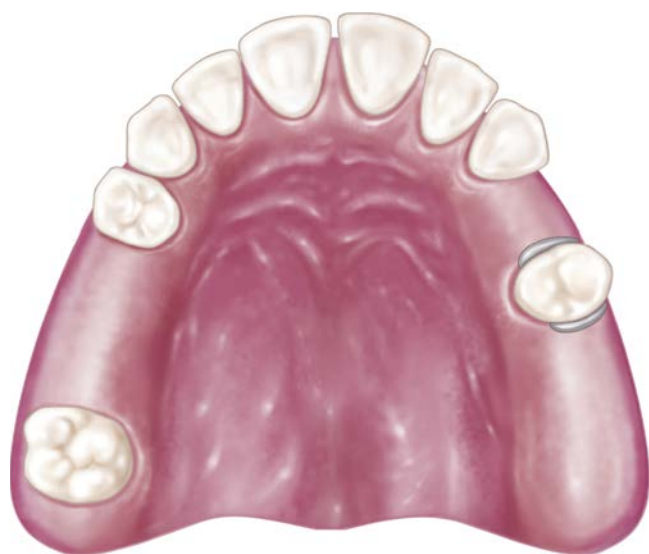**FIGURE 10-8** **A**, The guiding plane surface should be like an area on a cylindrical object. It should be a continuous surface unbounded by even, rounded line angles. **B**, Minor connector contacting the guiding plane surface has the same curvature as that surface. From an occlusal view, it tapers buccally from the thicker lingual portion, thus permitting closer contact of the abutment tooth and the prosthetically supplied tooth. Viewed from the buccal aspect, the minor connector contacts the enamel of the tooth on its proximal surface about two-thirds its length.

As a rule, proximal guiding plane surfaces should be about one-half the width of the distance between the tips of adjacent buccal and lingual cusps, or about one-third the buccal lingual width of the tooth, and should extend vertically about two thirds of the length of the enamel crown portion of the tooth from the marginal ridge cervically. In the preparation of guiding plane surfaces, care must be exercised to avoid creating buccal or lingual line angles (Figure 10-8). If it is assumed that the stabilizing or retentive arm of a direct retainer may originate in the guiding plane region, a line angle preparation would weaken either or both components of the clasp assembly.

A guiding plane should be located on the abutment surface adjacent to an edentulous area. However, excess torquing is inevitable if the guiding planes squarely facing each other on a lone standing abutment adjacent to an extension area are used (Figure 10-9).

### Indirect Retainers

An indirect retainer must be placed as far anterior from the fulcrum line as adequate tooth support permits if it is to function with the direct retainer to restrict movement of a distal extension base away from the basal seat tissues. It must be placed on a rest seat prepared in an abutment tooth that is capable of withstanding the forces placed on it. An indirect retainer cannot function effectively on an inclined tooth surface, nor can a single weak incisor tooth be used for this purpose. A canine or premolar tooth should be used for



**FIGURE 10-9** Guiding planes squarely facing each other should not be prepared on a lone standing abutment. Minor connectors of the framework (*gray areas*) would place undue strain on the abutment when the denture is rotated vertically, either superiorly or inferiorly.

the support of an indirect retainer, and the rest seat must be prepared with as much care as is given any other rest seat. An incisal rest or a lingual rest may be used on an anterior tooth, provided a definite seat can be obtained in sound enamel or on a suitable restoration.

A second purpose that indirect retainers serve in partial denture design is that of support for major connectors. A long lingual bar or an anterior palatal major connector is thereby prevented from settling into the tissues. Even in the absence of a need for indirect retention, provision for such auxiliary support is sometimes indicated.

Contrary to common use, a cingulum bar or a linguo-plate does not in itself act as an indirect retainer. Because these are located on inclined tooth surfaces, they serve more as orthodontic appliances than as support for the partial denture. When a linguo-plate or a cingulum bar is used, terminal rests should always be provided at either end to stabilize the denture and to prevent orthodontic movement of the teeth contacted. Such terminal rests may function as indirect retainers, but they would function equally well in that capacity without the continuous bar retainer or linguo-plate.

## IMPLANT CONSIDERATIONS IN DESIGN

As was mentioned in Chapter 4, the objectives of RPD design are to replace missing teeth with a prosthesis that exhibits limited movement under the influence of functional forces, and to ensure that movement is within physiologic tolerance. Physiologic tolerance would include tissue tolerance as well as a patient's physiologic ability to accommodate to the prosthesis.

The Kennedy Class III tooth-supported RPD presents less of a challenge to oral tissues and patient accommodation than does the Kennedy Class I or II tooth-tissue prosthesis. The challenge is chiefly related to prosthesis movement to an extent allowed by tissue displaceability under an applied force. Use of dental implants to reduce this displacement can significantly benefit tissue tolerability and reduce any challenge to accommodation presented by prosthesis movement. Use of implants can also assist other worthwhile goals such as improved stability and retention when these aspects are needed because of anatomic deficiencies or related factors.

The clinician must consider potential movements of the prosthesis and the ability to control movement given the existing oral tissues, teeth, and occlusion. Selective application of dental implants can provide needed movement control.

## EXAMPLES OF SYSTEMATIC APPROACH TO DESIGN

In [Table 10-1](#) examples are provided as a design baseline for the most common tooth loss distributions—Kennedy Class I, II, and III.

### Required Tooth Modification for Removable Partial Dentures

The required tooth modifications for RPDs are as follows:

- Teeth require modification to accommodate guideplanes, rests, and clasp arms.
- Tooth contour modifications for guideplane and clasp needs are similar to crown reduction of enamel surfaces only (see [Figure 13-18](#)).
- Rest seats are prepared following the guideplane reduction and also are contained in enamel only (see [Figure 13-18](#)).
- Height of contour modifications are required from the guideplane location along two-thirds of the length to the retentive clasp (for both circumferential and combination clasps).

### Implant Considerations

Implants effectively reduce distal extension movement and can enhance support if placed at distal-most tooth position. Such use of an implant changes the mechanics of a Class I distal extension to a Class III as both ends of the edentulous span are supported.

If the implant is placed adjacent to the anterior tooth in an edentulous span, it can be used as a primary abutment for retention. Either location of implant placement that assists the RPD should be placed favorable to assist a subsequent (future) implant placement to provide a fixed prosthesis.

### Kennedy Class II Removable Partial Dentures

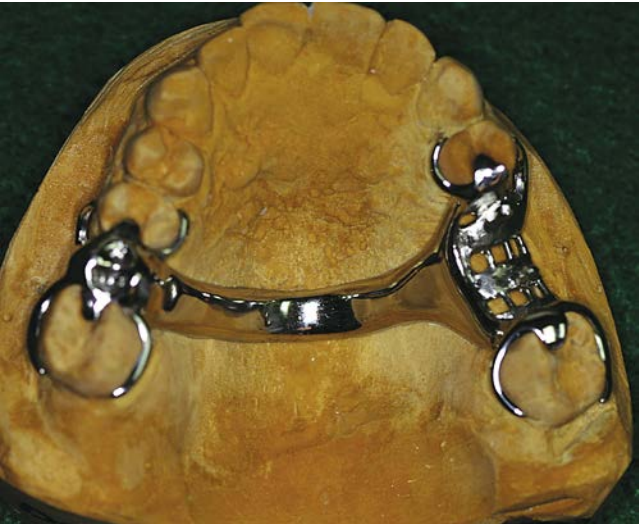The Kennedy Class II partial denture ([Figures 10-12 and 10-13](#)) actually may be a combination of tissue-supported and tooth-supported restorations. The distal extension base must have adequate tissue support, whereas tooth-supported

TABLE 10-1

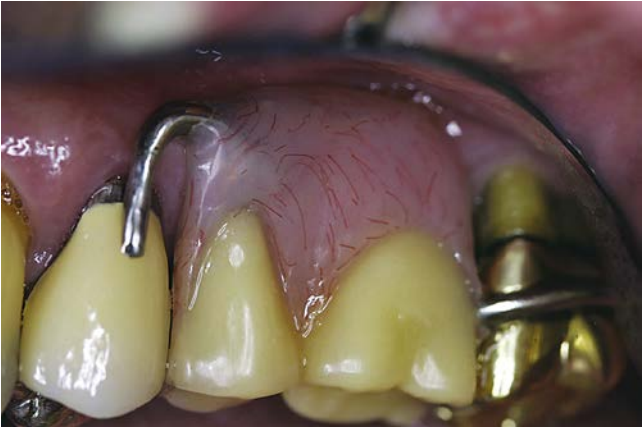Examples of Systematic Approach to Design

	Support	Major connector	Bracing/stability	Retention*
<b>Class I</b>				
Maxilla	Occlusal rest Cingulum rest Denture base palate (as needed)	AP palatal strap Full Palate	Guide planes Indirect retainers Reciprocal clasp Palatal plating	RPI, RPA Combination clasp
Mandible	Occlusal rest Cingulum rest Denture base (Selective Pressure)	Lingual bar Lingual plate	Guide planes Indirect retainers Reciprocal clasp Lingual plating	RPI, RPA Combination clasp
<b>Class II</b>				
Maxilla	Occlusal rest Cingulum rest Denture base palate (uncommon)	AP palatal strap Horseshoe Full Palate (uncommon)	Guide planes Indirect retainer Reciprocal clasp Palatal plating	RPI, RPA (DE side) Combination clasp (DE side) Embrasure clasp (Dentate side) Circumferential clasp (Dentate Side)
Mandible	Occlusal rest Cingulum rest Denture base (Selective Pressure)	Lingual bar Lingual plate	Guide planes Indirect retainers Reciprocal clasp Lingual plating	RPI, RPA Combination clasp
<b>Class III</b>				
Maxilla	Cingulum rest Occlusal rest	Palatal strap Palatal bar	Guide planes Reciprocal clasp	Circumferential clasp I-bar clasp
Mandible	Cingulum rest Occlusal rest	Lingual bar	Guide planes Reciprocal clasp	Circumferential clasp I-bar clasp

RPA, Rest, proximal plate, Akers; RPI, rest, proximal plate, and I-bar.



**FIGURE 10-10** Removable partial denture (RPD) in maxillary Class III arch. The design consists of anterior and posterior palatal bar major connectors, resin-supported artificial teeth, and bar clasp arms throughout.



**FIGURE 10-11** Removable partial denture (RPD) framework in maxillary Class III arch. The design consists of a single palatal strap major connector, bar and circumferential clasp arms, and a means to attach resin-supported artificial teeth.

bases elsewhere in the arch may be made to fit the anatomic form of the underlying ridge. Indirect retention must be provided for; however, occasionally the anterior abutment on the tooth-supported side will satisfy this requirement. If additional indirect retention is needed, provisions must be made for it.

Cast clasps are generally used on the tooth-supported side; however, a clasp design in which wrought wire is used may reduce the application of torque on the abutment tooth adjacent to the distal extension and should be considered. The use of a cast circumferential clasp engaging a mesio-buccal undercut on the anterior abutment of the tooth-supported modification space may result in a Class I lever-like action if the abutment teeth have not been properly prepared, and/or if tissue support from the extension base area is not adequate. It seems rational under these circumstances to minimize these effects through optimum denture base adaptation, to reduce movement or to provide implant support (see Figure 10-13). Should the bar-type retainer be contraindicated because of a severe tissue undercut or the existence of only a mesio-buccal undercut on the anterior abutment, then a combination direct retainer with the retentive arm made of tapered wrought wire should be used. A thorough understanding of the advantages and disadvantages of various clasp designs is necessary in determining the type of direct retainer that is to be used for each abutment tooth.

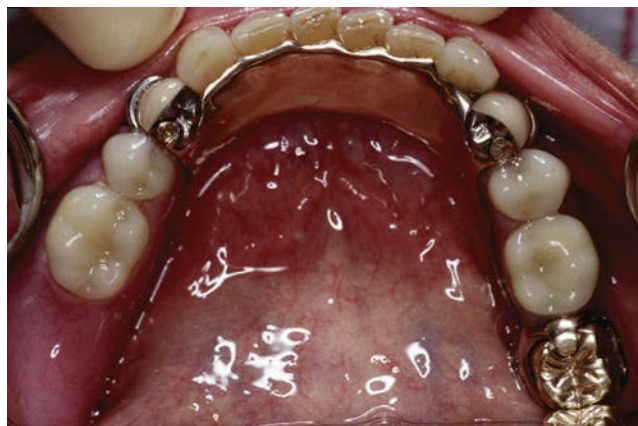Steps included in fabrication of the Class II partial denture closely follow those used with the Class I partial denture, except that the distal extension base is usually made of an acrylic-resin material, whereas the base for any tooth-supported area can be made of metal. This is permissible because the residual ridge beneath tooth-supported bases is not called on to provide support for the denture, and later rebasing is not as likely to be necessary.

### Class III Removable Partial Denture

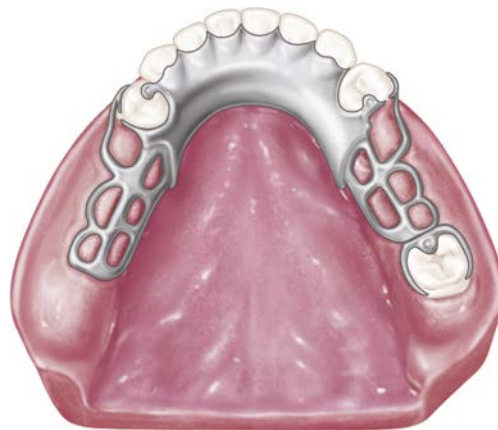The Kennedy Class III RPD (Figures 10-10 and 10-11), entirely tooth supported, may be made to fit the prepared surfaces of the anatomic form of the teeth and surrounding structures. It does not require an impression of the functional form of the ridge tissues, nor does it require indirect retention. Cast clasps of the circumferential variety, the bar type, or the combination clasp may be used, depending on how one can modify the surfaces of the abutment teeth (guiding planes, rests, contours for proper location of clasp arms). Unless the need for later relining is anticipated, as in the situation of recently extracted teeth, the denture base may be made of metal, which offers several advantages. The Class III partial denture can frequently be used as a valuable aid in periodontal treatment because of its stabilizing influence on the remaining teeth.

### Kennedy Class I, Bilateral, Distal Extension Removable Partial Dentures

The Class I, bilateral, distal extension partial denture is as different from the Class III type as any two dental restorations



**FIGURE 10-12** Mandibular Class II removable partial denture (RPD) with distal extension base. Because of tissue undercut cervical to the buccal surface of the right second premolar and lack of distobuccal undercut, a wrought-wire (tapered) retainer arm was used.



**FIGURE 10-13** Mandibular Class II, modification 1, partially edentulous arch. Note that bar-type retentive arms are used on both premolar abutments, engaging distobuccal undercuts at their terminal ends. Lever-like forces may not be as readily imparted to the right premolar, as opposed to the cast circumferential direct retainer engaging the mesio-buccal undercut.

could be (see Figure 10-1). Because it derives its principal support from the tissues underlying its base, a Class I partial denture made to anatomic ridge form cannot provide uniform and adequate support. Yet, unfortunately, many Class I mandibular RPDs are made from a single irreversible hydrocolloid impression. In such situations, both the abutment teeth and the residual ridges suffer because the occlusal load placed on the remaining teeth is increased by the lack of adequate posterior support.

Many dentists, recognizing the need for some type of impression registration that will record the supporting form of the residual ridge, attempt to record this form with a metallic oxide, a rubber base, or one of the silicone impression materials. Such materials actually record only the anatomic

form of the ridge, except when the special design of impression trays permits recording of the primary stress-bearing areas under a simulated load. Others prefer to place a base, made to fit the anatomic form of the ridge, under some pressure at the time that it is related to the remaining teeth, thus obtaining functional support. Still others, who believe that a properly compounded mouth-temperature wax will displace only those tissues that are incapable of providing support to the denture base, use a wax secondary impression to record the supporting, or functional, form of the edentulous ridge. Any impression record will be influenced by the consistency of the impression material and the amount of hydraulic pressure exerted by its confinement within the impression tray.

### ADDITIONAL CONSIDERATIONS INFLUENCING DESIGN

Every effort should be made to gain the greatest support possible for removable prostheses with the use of abutments bounding edentulous spaces. This not only will relieve the residual ridges of some of their obligation for support but also may allow the design of the framework to be greatly simplified. To this end, use of splint bars, internal clip attachments, overlay abutments, overlay attachments, a component partial, and implants should be considered.

#### Use of a Splint Bar for Denture Support

In the Chapter 15 discussion of missing anterior teeth, mention is made of the fact that missing anterior teeth are best replaced with a fixed partial denture. The following is quoted from that chapter: "From a biomechanical standpoint ... a removable partial denture should replace only the missing posterior teeth after the remainder of the arch has been made intact by fixed restorations."

Occasionally, a situation is found in which it is necessary for several missing anterior teeth to be replaced by the RPD rather than by fixed restorations. This may be caused by the length of the edentulous span or by the loss of a large amount of the residual ridge due to resorption, accident, or surgery, or it may result from a situation in which too much vertical space prevents the use of a fixed partial denture, or in which esthetic requirements can better be met through the use of teeth added to the denture framework. In such instances, it is necessary that the best possible support for the replaced anterior teeth be provided. Ordinarily this is done through the placement of occlusal or lingual rests, or both, on the adjacent natural teeth, but when the edentulous span is too large to ensure adequate support from the adjacent teeth, other methods must be used. This is included here only because it influences the design of the major connector that must then be used.

An anterior splint bar may be attached to the adjacent abutment teeth in such a manner that fixed splinting of the abutment teeth results, with a smooth, contoured bar

resting lightly on the gingival tissues to support the RPD. As with any fixed partial denture, the type of abutment retainers and the decision to use multiple abutments will depend on the length of the span and the available support and stability of the teeth being used as abutments. Regardless of the type of abutment retainers used, the connecting bar may be cast of a rigid alloy, or a commercially available bar may be used and cast to the abutments or attached to the abutments by soldering.

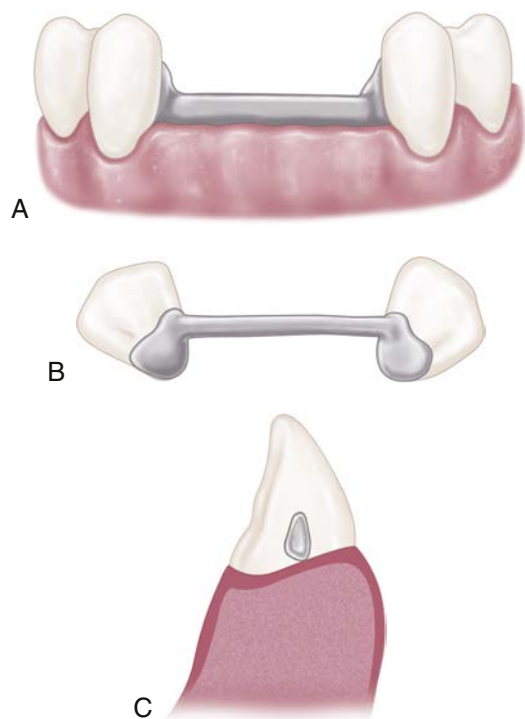
The length of the span influences the size of a splint bar. Long spans require more rigid bars (10-gauge) than short spans (13-gauge). If the bar is to be soldered, it is best that recesses be formed in the proximal surfaces of the abutments and that the connecting bar, which rests lightly on the tissues, be cast or made to fit into these recesses and then attached by soldering.

Because of the greater rigidity of chromium-cobalt alloys, the splint bar is preferably cast in one of these materials and then is attached to the abutments by soldering. The complete assembly (abutments and connecting bar) is then cemented permanently to the abutment teeth, in the same way as for a fixed partial denture. The impression for the partial denture is then made, and a master cast is obtained that accurately reproduces the contours of the abutments and the splint bar. The denture framework then is made to fit the abutments and the bar by extending the major connector or minor connectors to cover and rest upon the splint bar. Retention for the attachment of a resin base, or any other acceptable means of attaching the replaced anterior teeth, is incorporated into the denture design. In those situations wherein the RPD will be tooth supported, the splint bar may be curved to follow the crest of the residual ridge. However, in a distal extension situation, because of the vertical rotation of the denture, caution must be exercised to form the splint bar so that excessive torque will not accrue to its supporting abutments (Figure 10-14). The proximal contours of abutments adjacent to splint bars should be parallel to the path of placement. This serves three purposes: (1) it permits a desirable arrangement of artificial teeth, (2) it aids in resisting horizontal rotation of the restoration, and (3) these components act as guiding planes to direct the partial denture to and from its terminal position.

The splint bar must be positioned anteroposteriorly just lingual to the residual ridge to allow an esthetic arrangement of artificial teeth. The resulting partial denture offers esthetic advantages of removable anterior replacements and positive support, retention, and stability from the underlying splint bar (Figure 10-15).

#### Internal Clip Attachment

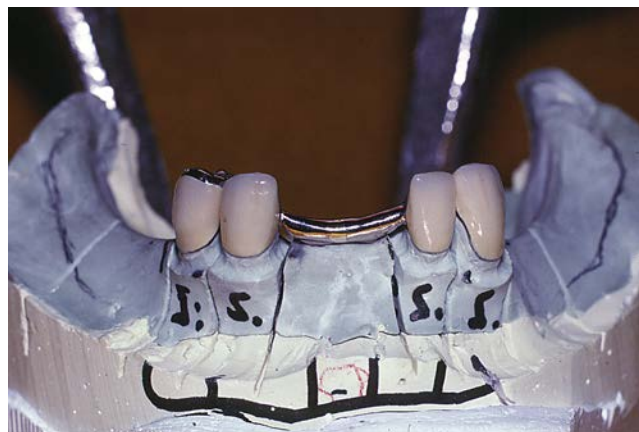The internal clip attachment differs from the splint bar in that the internal clip attachment provides both support and retention from the connecting bar.



**FIGURE 10-14** **A**, Insofar as is possible, the splint bar should be round or ovoid. Provisions must be made in the construction and location of the bar so that dental floss may be threaded underneath the bar to allow proper cleaning by the patient. **B**, As viewed from above, the bar is in a straight line between abutments. This is especially critical for distal extension removable partial dentures (RPDs) to avoid excess torque on abutments as the denture rotates in function. **C**, Sagittal section through the bar demonstrates the rounded form of the bar making point contact with the residual ridge. The entire tissue surface of the bar is easily accessible for cleaning with dental floss. A pear-shaped bar (in cross section) permits rotation of the RPD without appreciable resistance or torque.

Several preformed connecting bars are commercially available in plastic patterns. These can be customized for length and cast in the metal alloy of choice. Internal clip attachments are also commercially available in various metal alloys and durable nylon. When a custom-made connecting bar and clip is fabricated, the bar should be cast from 10- or 13-gauge sprue wax. The cast bar should rest lightly or should be located slightly above the tissues. Retention is provided by one of the commercial preformed metal or nylon clips, which is contoured to fit the bar and is retained in a preformed metal housing or partially embedded by means of retention spurs or loops into the overlying resin denture base.

The internal clip attachment thus provides support, stability, and retention for the anterior modification area and may serve to eliminate both occlusal rests and retentive clasps on adjacent abutment teeth.



**FIGURE 10-15** Lower canines splinted together with a splint bar. The longevity of these teeth is greatly enhanced by splinting. Tissue surfaces are minimally contacted by the rounded form of the lower portion of the bar. Anterior and posterior slopes of the splint bar must be compatible with the path of placement of the denture. Floss will be used by the patient to clean the inferior portion of the splint bar.

### Overlay Abutment as Support for a Denture Base

Every consideration should be directed toward preventing the need for a distal extension RPD. In many instances, it is possible to salvage the roots and a portion of the crown of a badly broken-down molar through endodontic treatment. A periodontally involved molar, otherwise indicated for extraction, sometimes may be salvaged by periodontal and endodontic treatment accompanied by reduction of the clinical crown almost level with the gingival tissues. In another situation, an unopposed molar may have extruded to such an extent that restoring the tooth with a crown is inadequate to develop a harmonious occlusion. Then too, it is not unusual to encounter a molar that is so grossly tipped anteriorly that it cannot serve as an abutment unless the clinical crown is reduced drastically.

Such teeth should be considered for possible support for an otherwise distal extension denture base. Endodontic treatment and preparation of the coronal portion of the tooth as a slightly elevated dome-shaped abutment often offer an alternative to a distal extension base. The student is referred to the Selected Reading Resources section in Appendix B (textbooks; abutment retainers) for sources of information on overdenture abutments and overlay-type prostheses.

### Use of a Component Partial to Gain Support

A component partial is a RPD in which the framework is designed and fabricated in separate parts. The tooth support and tissue-supported components are individually fabricated, and the two are joined with a high-impact acrylic-resin to become a single rigid functioning unit.

# CHAPTER 11

## Surveying

### CHAPTER OUTLINE

#### Description of Dental Surveyor

#### Purposes of the Surveyor

- Surveying the Diagnostic Cast
- Contouring Wax Patterns
- Surveying Ceramic Veneer Crowns
- Placement of Intracoronal Retainers (Internal Attachments)
- Placement of Internal Rest Seats
- Machining Cast Restorations
- Surveying the Master Cast

#### Factors that Determine Path of Placement and Removal

- Guiding Planes
- Retentive Areas
- Interference
- Esthetics

#### Step-by-Step Procedures in Surveying a Diagnostic Cast

- Guiding Planes
- Retentive Areas
- Interference
- Esthetics

#### Final Path of Placement

#### Recording Relation of Cast to Surveyor

#### Surveying the Master Cast

#### Measuring Retention

#### Blocking out the Master Cast

#### Relieving the Master Cast

#### Paralleled Blockout, Shaped Blockout, Arbitrary Blockout, and Relief

When a fixed partial denture (FPD) is prepared, the orientation of the diamond bur is controlled to remove an amount of tooth structure necessary to satisfy the requirements of the path of insertion for the prosthesis. Accomplishment of parallel preparations is ultimately verified by complete seating of the prosthesis but could be verified on the master cast or dies by the use of the surveyor. Once the FPD is fabricated and completely seated, it is ensured full engagement of the entire circumference of and occlusal support from the abutment retainers. If adequate resistance form and fit of the prosthesis are provided, the chance for functional stability equivalent to natural teeth is good. This could not be ensured unless the relationship of the fixed prosthesis and the prepared teeth were carefully controlled.

For a removable prosthesis, the necessity for appropriately planned and executed tooth preparation, followed by verification of a well-fitting prosthesis that engages the teeth as planned, is equally important. As was briefly mentioned in Chapter 7, a dental surveyor is vitally important to the planning, execution, and verification of appropriate mouth modifications for a removable partial denture. Although it does not necessarily affect the occlusal rest preparations on abutment teeth, use of the surveyor is critical for planning the modifications of all tooth surfaces that will be involved in support, stabilization, and retention of the prosthesis. In this role, the use of a surveyor to determine the needed mouth preparation is vitally important in helping to provide stable and comfortable removable prostheses.

A dental surveyor has been defined as an instrument used to determine the relative parallelism of two or more surfaces of the teeth or other parts of the cast of a dental arch. Therefore the primary purpose of surveying is to identify the modifications of oral structures that are necessary to fabricate a removable partial denture that will have a successful prognosis. It is the modification of tooth surfaces to accommodate placement of the component parts of the partial denture in their designated ideal positions on abutment teeth that facilitates this prognosis.

Any one of several moderately priced surveyors on the market will adequately accomplish the procedures necessary to design and construct a partial denture. In addition, these surveyors may be used to parallel internal rests and intra-coronal retainers. With a handpiece holder added, they may be used to machine internal rests and to make the guiding-plane surfaces of abutment restorations parallel.

### DESCRIPTION OF DENTAL SURVEYOR


The most widely used surveyors are the Ney (Figure 11-1) and the Jelenko (Figure 11-2). Both of these are precision-made instruments. They differ principally in that the Jelenko arm swivels, whereas the Ney arm is fixed. The technique for surveying and trimming blockout is therefore somewhat different. Other surveyors also differ in this respect, and the dentist may prefer one over another for this reason.

The principal parts of the Ney surveyor are as follows:

1. Platform on which the base is moved
2. Vertical arm that supports the superstructure
3. Horizontal arm from which the surveying tool suspends
4. Table to which the cast is attached
5. Base on which the table swivels
6. Paralleling tool or guideline marker (This tool contacts the convex surface to be studied in a tangential manner; the relative parallelism of one surface to another may thus be determined; with substitution of a carbon marker, the height of contour may be delineated on the surfaces of the abutment teeth and on areas of interference requiring reduction on blockout.)
7. Mandrel for holding special tools (Figure 11-3)

The principal parts of the Jelenko surveyor are essentially the same as those of the Ney surveyor except that when the nut at the top of the vertical arm is loosened, the horizontal arm may be made to swivel. The objective of this feature, originally designed by Dr. Noble Wills, is to permit freedom of movement of the arm in a horizontal plane rather than to depend entirely on the horizontal movement of the cast. To some, this is confusing because two horizontal movements must be coordinated. For those who prefer to move the cast only in horizontal relationship to a fixed vertical arm, the nut may be tightened and the horizontal arm used in a fixed position.

Another difference between Ney and Jelenko surveyors is that the vertical arm on the Ney surveyor is retained by friction within a fixed bearing. The shaft may be moved up or down within this bearing but remains in a vertical position until again moved. The shaft may be fixed in any vertical position desired by tightening a setscrew. In contrast, the vertical arm of the Jelenko surveyor is spring mounted and returns to the top position when it is released. It must be held down against spring tension while it is in use, which to some is a disadvantage. The spring may be removed, but the friction of the two bearings supporting the arm does not hold it in position as securely as does a bearing designed for that purpose. These minor differences in the two surveyors lead



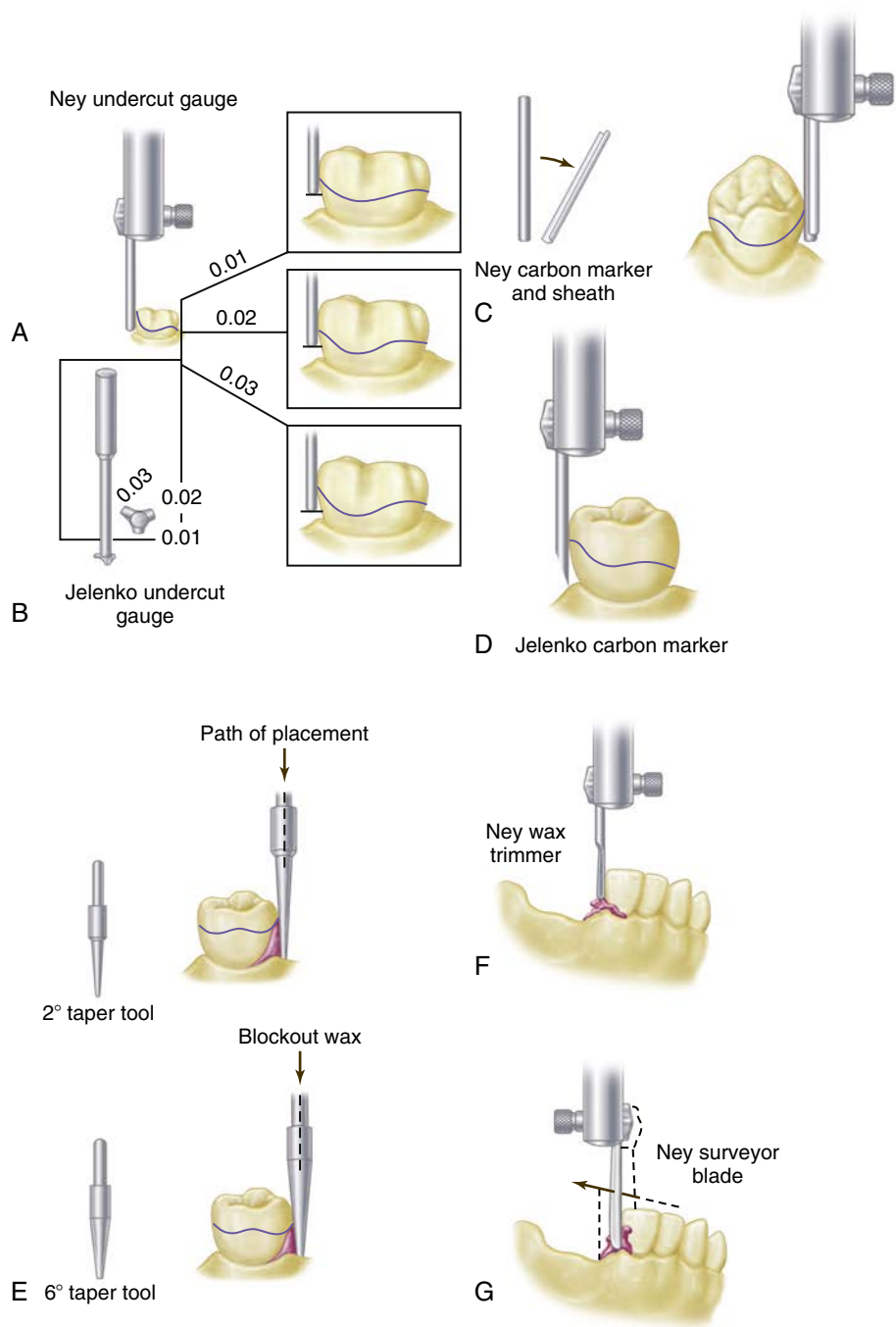
**FIGURE 11-1** The Ney surveyor is widely used because of its simplicity and durability. Dental students should be required to own such a surveyor. By becoming familiar with and dependent on its use, they are more likely to continue using the surveyor in practice as a necessary piece of equipment toward more adequate diagnosis, effective treatment planning, and performance of many other aspects of prosthodontic treatment.



**FIGURE 11-2** The Jelenko Surveyor. Note the spring-mounted paralleling tool and swivel at the top of the vertical arm. The horizontal arm may be fixed in any position by tightening the nut at the top of the vertical arm.

to personal preference but do not detract from the effectiveness of either surveyor when each is properly used.

Because the shaft on the Ney surveyor is stable in any vertical position—yet may be moved vertically with ease—it lends itself well for use as a drill press when a handpiece



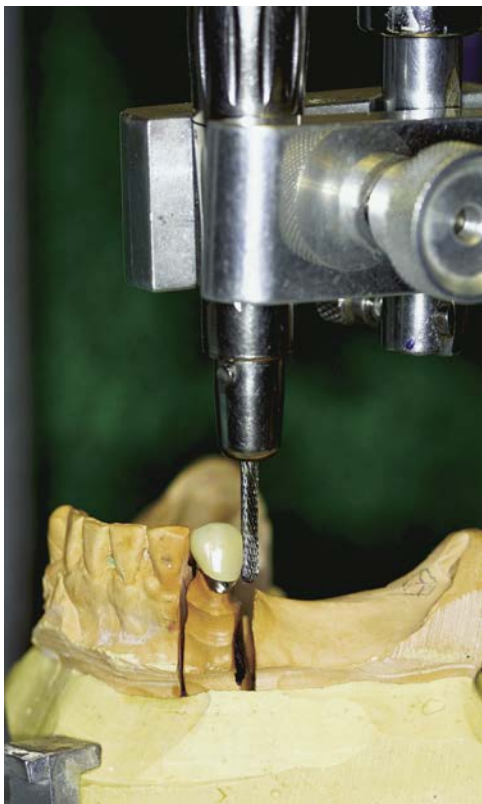**FIGURE 11-3** Various tools that may be used with a dental surveyor. **A**, Ney undercut gauges. **B**, Jelenko undercut gauge. **C**, Ney carbon marker with metal reinforcement sheath. **D**, Jelenko carbon marker. **E**, Tapered tools, 2- and 6-degree, for trimming blockout when some nonparallelism is desired. **F**, Ney wax trimmer for paralleling blockout. **G**, Surveying blade used for trimming blockout.

holder is added (Figure 11-4). The handpiece may thus be used to cut recesses in cast restorations with precision with burs or carborundum points of various sizes in a dental handpiece.

Several other types of surveyors have been designed and are in use today. Many of these are elaborate and costly, yet provide little advantage over simpler types of surveyors.

**PURPOSES OF THE SURVEYOR**

The surveyor may be used for surveying the diagnostic cast, recontouring abutment teeth on the diagnostic cast, contouring wax patterns, measuring a specific depth of undercut, surveying ceramic veneer crowns, placing intracoronal retainers, placing internal rests, machining cast restorations, and surveying and blocking out the master cast.

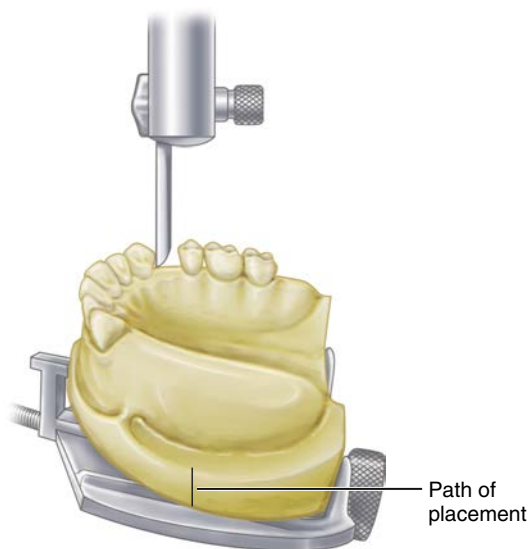


**FIGURE 11-4 Lab Handpiece Clamp.** Handpiece holders attach to the vertical spindle of surveyors and may be used to create and refine any parallel surface on a surveyed crown, as a drill press to prepare internal rests and recesses in patterns and/or castings, and to establish lingual surfaces above the ledge that are parallel to the path of placement in abutment restorations.

### Surveying the Diagnostic Cast

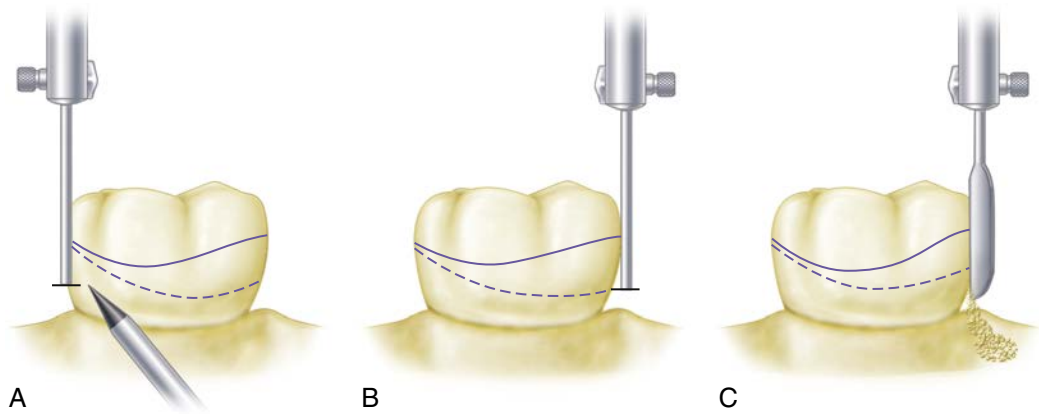
Surveying the diagnostic cast is essential to effective diagnosis and treatment planning. The objectives are as follows:

1. To determine the most desirable path of placement that eliminates or minimizes interference to placement and removal (**Figure 11-5**): The path of placement is the direction in which a restoration moves from the point of initial contact of its rigid parts with the supporting teeth to its terminal resting position, with rests seated and the denture base in contact with the tissues. The path of removal is exactly the reverse, because it is the direction of restoration movement from its terminal resting position to the last contact of its rigid parts with the supporting teeth. When the restoration is properly designed to have positive guiding planes, the patient may place and remove the restoration with ease in only one direction. This is possible only because of the guiding influence of tooth surfaces (guiding planes) made parallel to that path of placement.
2. To identify proximal tooth surfaces that are or need to be made parallel so that they act as guiding planes during placement and removal
3. To locate and measure areas of the teeth that may be used for retention

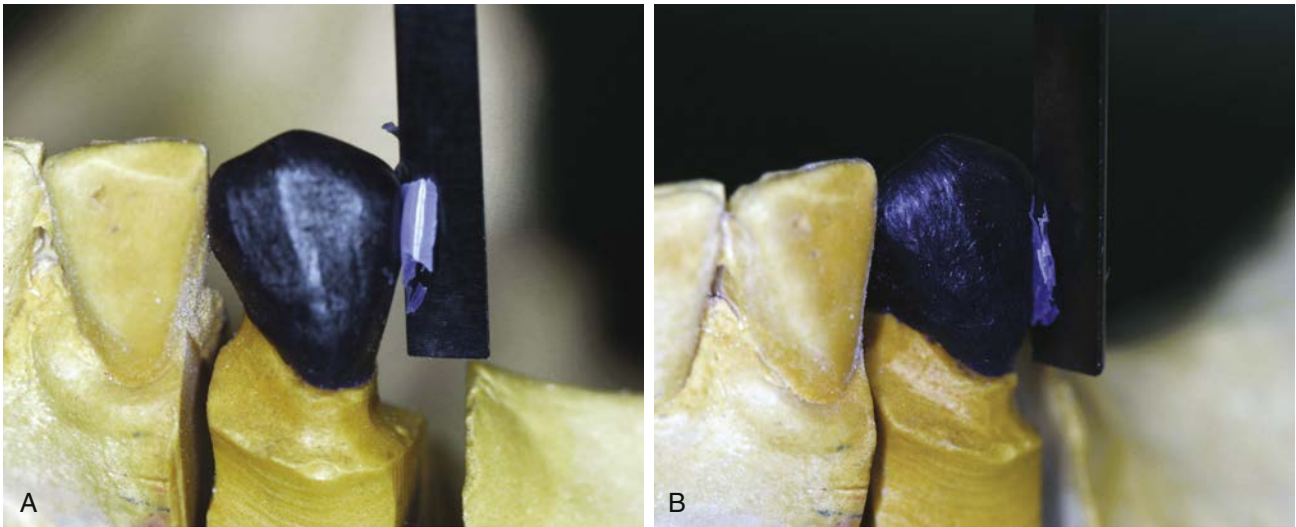


**FIGURE 11-5** Tilt of the cast on the adjustable table of a surveyor in relation to the vertical arm establishes the path of placement and removal that the removable partial denture will take. All mouth preparations must be made to conform to this determined path of placement, which has been recorded by scoring the base of the cast or by tripoding.

4. To determine whether teeth and bony areas of interference need to be eliminated surgically or by selection of a different path of placement
5. To determine the most suitable path of placement that permits locating retainers and artificial teeth to provide the best esthetic advantage
6. To permit accurate charting of the mouth preparations to be made: This includes the preparation of proximal tooth surfaces to provide guiding planes and the reduction of excessive tooth contours to eliminate interference and to permit a more acceptable location of reciprocal and retentive clasp arms. By marking these areas on the diagnostic cast in red, using an undercut gauge to estimate the amount of tooth structure that may safely (without exposing dentin) be removed, and then trimming the marked areas on the stone cast with the surveyor blade, the angulation and extent of tooth reduction may be established before the teeth are prepared in the mouth (**Figure 11-6**). With the diagnostic cast on the surveyor at the time of mouth preparation, reduction of tooth contours may be accomplished with acceptable accuracy.
7. To delineate the height of contour on abutment teeth and to locate areas of undesirable tooth undercut that are to be avoided, eliminated, or blocked out: This includes areas of the teeth to be contacted by rigid connectors, the location of nonretentive reciprocal and stabilizing arms, and the location of retentive clasp terminals.
8. To record the cast position in relation to the selected path of placement for future reference: This may be done by locating three dots or parallel lines on the cast, thus establishing the horizontal plane in relation to the vertical arm of the surveyor (see **Figures 11-6 and 11-16**).



**FIGURE 11-6** **A**, Solid line represents the height of contour on the abutment at selected orientation of the diagnostic cast to the vertical spindle of the surveyor. Dotted line represents the desirable height of the contour for optimally locating components of the direct retainer assembly. A 0.01-inch (0.25-mm) undercut gauge is used to mark the location of the tip of the retentive arm of the direct retainer. **B**, By reducing the axial contour of the tooth by only 0.01 inch, the optimum height of contour can be achieved without exposing the dentin. **C**, Stone tooth is trimmed with a surveyor blade to the desired height of contour. The trimmed area is marked in red pencil and serves as a blueprint for similar recontouring in the mouth. If one can safely assume that the enamel is 1 to 1.5 mm thick in the area of contemplated reduction, only 0.25 mm of enamel needs to be removed to achieve the optimum height of contour.



**FIGURE 11-7** After the cast has been oriented to the surveyor at the predetermined path of placement, designated axial surfaces of the wax pattern are altered with the surveyor blade to meet specific requirements for placement of framework components. **A**, Wax pattern is carved with the surveyor blade to produce a distal guide-plane surface parallel to the selected path of insertion. **B**, The same pattern is modified from the distal guide plane along the buccal surface to align the surface with the height of contour most favorable to the direct retainer specifications.

**Contouring Wax Patterns**

The surveyor blade is used as a wax carver during this phase of mouth preparation so that the proposed path of placement may be maintained throughout the preparation of cast restorations for abutment teeth (Figure 11-7). Guiding planes on all proximal surfaces of wax patterns adjacent to edentulous areas should be made parallel to the previously determined path of placement. Similarly, all other tooth contours that will be contacted by rigid components

should be made parallel. The surfaces of restorations on which reciprocal and stabilizing components will be placed should be contoured to permit their location well below occlusal surfaces and on nonretentive areas. Those surfaces of restorations that are to provide retention for clasp arms should be contoured so that retentive clasps may be placed in the cervical third of the crown and to the best esthetic advantage. Generally, a small amount of undercut from 0.01 to 0.02 inch (0.250 to 0.50 mm) or less is sufficient for retentive purposes.



**FIGURE 11-8** Resultant metal-ceramic surveyed crown from Figure 11-7, which is being refined to maintain the distal guide plane and buccal height of the contour previously designed. Final glaze has not been placed on the veneer crown and required alterations of surfaces to conform to ideal placement of the retainer (*solid line*) can be performed by machining. Final glaze is produced only after necessary recontouring is accomplished.

### Surveying Ceramic Veneer Crowns

Ceramic veneer crowns are often used to restore abutment teeth on which extracoronary direct retainers will be placed. The surveyor is used to contour all areas of the wax pattern for the veneer crown except the buccal or labial surface. It must be remembered that one of the principal goals in using a porcelain veneer restoration is to develop an esthetic replica of a natural tooth. It is unlikely that the ceramic veneer portion can be fabricated exactly to the form required for the planned placement of retentive clasp arms without some reshaping with stones. Before the final glaze is accomplished, the abutment crowns should be returned to the surveyor on a full arch cast to ensure the correct contour of the veneered portions or to locate those areas that need recontouring (Figure 11-8). The final glaze is accomplished only after the crowns have been recontoured.

### Placement of Intracoronary Retainers (Internal Attachments)

In the placement of intracoronary retainers, the surveyor is used as follows:

1. To select a path of placement in relation to the long axes of the abutment teeth that avoids areas of interference elsewhere in the arch
2. To cut recesses in the stone teeth on the diagnostic cast for estimating the proximity of the recess to the pulp (used in conjunction with roentgenographic information to estimate pulp size and location) and to facilitate the fabrication of metal or resin jigs to guide preparations of the recesses in the mouth

3. To carve recesses in wax patterns, to place internal attachment trays in wax patterns, or to cut recesses in castings with the handpiece holder (whichever method is preferred)
4. To place the keyway portion of the attachment in the casting before investing and soldering; each keyway must be located parallel to the other keyways elsewhere in the arch

The student is referred to the Selected Reading Resources in Appendix B for sources of information on intracoronary retainers (internal attachments).

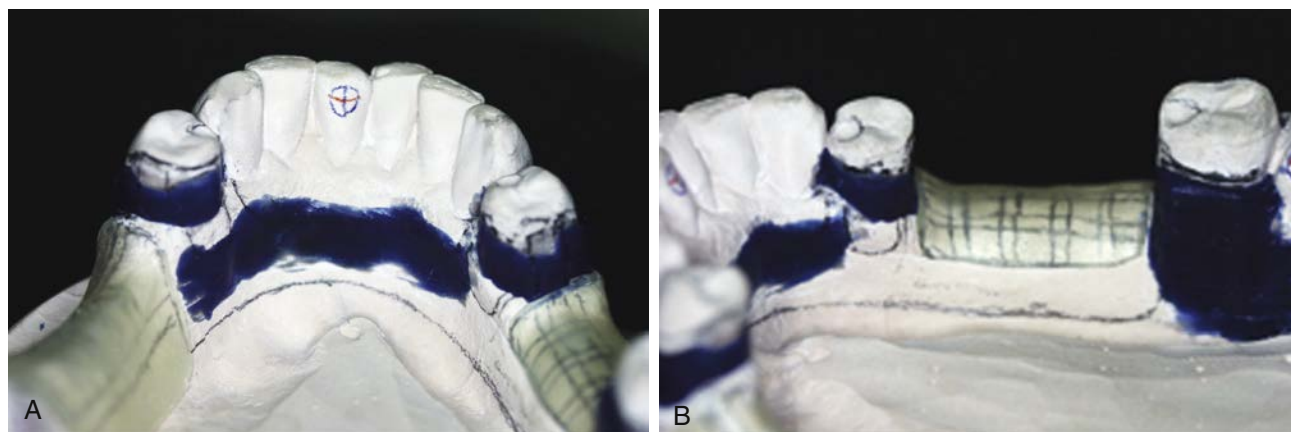
### Placement of Internal Rest Seats

The surveyor may be used as a drill press, with a dental handpiece attached to the vertical arm by a handpiece holder. Internal rest seats may be carved in the wax patterns and further refined with the handpiece after casting, or the entire rest seat may be cut in the cast restoration with the handpiece. It is best to carve the outline form of the rest seat in wax and merely refine the casting with the handpiece.

An internal rest differs from an internal attachment in that some portion of the prosthesis framework is waxed and cast to fit into the rest seat rather than a matched key and keyway attachment used (see Figures 7-42 and 7-43). The former is usually nonretentive but provides a definite seat for a removable partial denture or a cantilever rest for a broken-stress FPD. When they are used with FPDs, nonparallel abutment pieces may be placed separately.

The internal rest in partial denture construction provides a positive occlusal support that is more favorably located in relation to the rotational axis of the abutment tooth than the conventional spoon-shaped occlusal rest. It also provides horizontal stabilization through the parallelism of the vertical walls, thereby serving the same purpose as stabilizing and reciprocal arms placed extracoronally. Because of the movement of a distal extension base, more torque may be applied to the abutment tooth by an interlocking type of rest, and for this reason its use in conjunction with a distal extension partial denture is considered to be contraindicated. The ball-and-socket, spoon-shaped occlusal, or noninterlocking, rest should be used in distal extension partial denture designs. Use of the dovetailed or interlocking internal rest should be limited to tooth-supported removable restorations, except when it is used in conjunction with some kind of stress-breaker between the abutments and the movable base. The use of stress-breakers has been discussed in Chapter 9.

Internal rest seats may be made in the form of a non-retentive box, a retentive box fashioned after the internal attachment, or a semiretentive box. In the latter, the walls are usually parallel and nonretentive, but a recess in the floor of the box prevents proximal movement of the male portion. Internal rest seats are cut with dental burs of various sizes and shapes. Tapered or cylindrical fissure burs are used to form the vertical walls, and small round burs are used to cut recesses in the floor of the rest seat.



**FIGURE 11-9** Master casts are modified by the addition of wax relief to nonbearing regions and by placement of blockout wax parallel to the path of insertion at regions beneath the height of contour where framework contact is not planned (i.e., all areas except retentive clasp tips). **A**, Blockout wax is provided for tooth contours beneath the height of contour on teeth #21 and #28. **B**, Similar blockout was accomplished for mandibular molar #31. Blockout is carved with a straight surveyor blade to ensure parallelism with the identified path of insertion.

### Machining Cast Restorations

With a handpiece holder attached (see Figure 11-4), the axial surfaces of cast and ceramic restorations may be refined by machining with a suitable cylindrical carborundum point. Proximal surfaces of crowns and inlays, which will serve as guiding planes, and vertical surfaces above crown ledges may be improved by machining, but only if the relationship of one crown to another is correct (see Figure 14-9). Unless the seating of removable dies is accurate and they are held in place with additional stone or plaster, cast restorations should first be tried in the mouth and then transferred, by means of a plaster or acrylic-resin index impression, to a reinforced stone cast for machining purposes. The new cast is then positioned on the surveyor, conforming to the path of placement of the partial denture, and vertical surfaces are machined with a true-running cylindrical carborundum point.

Although machined parallelism may be considered ideal and beyond the realm of everyday application, its merits more than justify the additional steps required to accomplish it. When such parallelism is accomplished and reproduced in a master cast, it is essential that subsequent laboratory steps be directed toward the use of these parallel guiding plane surfaces.

### Surveying the Master Cast

Because surveying the master cast follows mouth preparations, the path of placement, the location of retentive areas, and the location of remaining interference must be known before the final design of the denture framework is completed. The objectives of surveying the master cast are as follows:

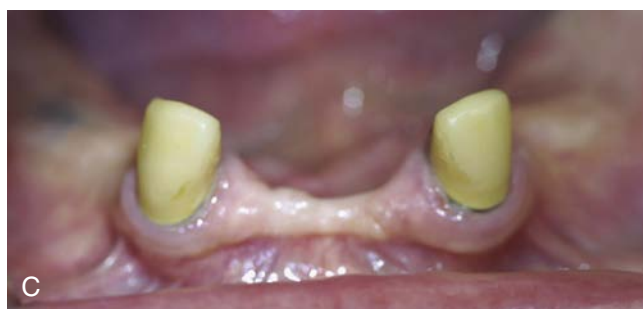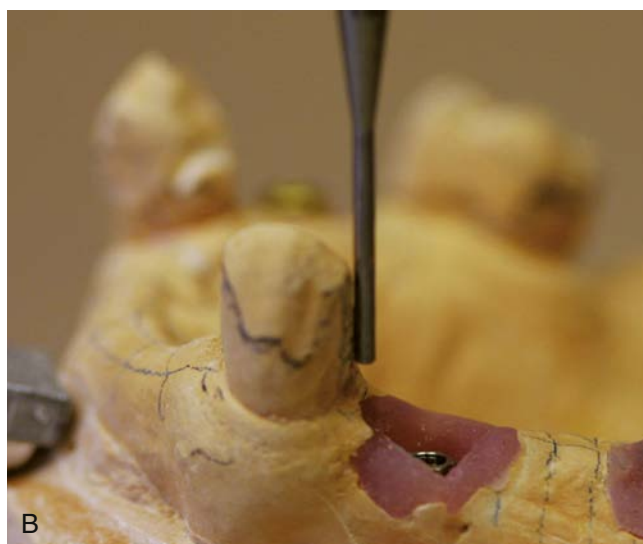
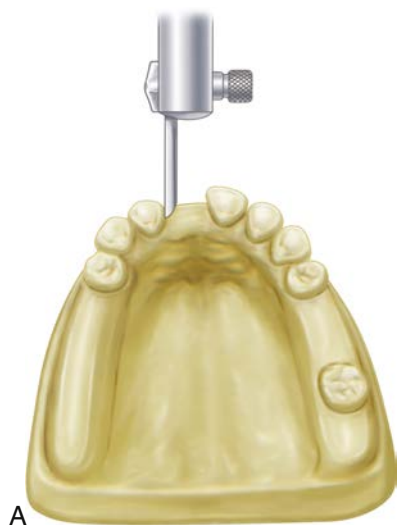1. To select the most suitable path of placement by following mouth preparations that satisfy the requirements of guiding planes, retention, noninterference, and esthetics

2. To permit measurement of retentive areas and to identify the location of clasp terminals in proportion to the flexibility of the clasp arm being used: Flexibility depends on many of the following factors: (a) the alloy used for the clasp, (b) the design and type of clasp, (c) whether its form is round or half-round, (d) whether it is of cast or wrought material, and (e) the length of the clasp arm from its point of origin to its terminal end. Retention depends on (a) the flexibility of the clasp arm, (b) the magnitude of the tooth undercut, and (c) the depth the clasp terminal is placed into this undercut.
3. To locate undesirable undercut areas that will be crossed by rigid parts of the restoration during placement and removal: These must be eliminated by blockout.
4. To trim blockout material parallel to the path of placement before duplication (Figure 11-9)

The partial denture must be designed so that (1) it will not stress abutment teeth beyond their physiologic tolerance, (2) it can be easily placed and removed by the patient, (3) it will be retained against reasonable dislodging forces, and (4) it will not create an unfavorable appearance. It is necessary that the diagnostic cast be surveyed with these principles in mind. Mouth preparation should therefore be planned in accordance with certain factors that will influence the path of placement and removal.

### FACTORS THAT DETERMINE PATH OF PLACEMENT AND REMOVAL

The factors that determine the path of placement and removal are guiding planes, retentive areas, interference, and esthetics. Additionally, if an implant is part of the design its long axis is considered in relation to the path or placement and removal (Figure 11-10, B).



**FIGURE 11-10** **A**, When anterior teeth must be replaced with the removable partial denture, the selected vertical path should consider the junction of the natural tooth and the denture tooth. The path of insertion that requires the least amount of alteration of the natural teeth and the denture tooth (maximizing natural embrasure contours) is desirable. **B**, Distal of canine slightly altered to accommodate the path that optimizes anterior denture tooth placement. **C**, Canine crowns required to satisfy desired contours of the natural tooth and the denture teeth.

### Guiding Planes

Proximal tooth surfaces that bear a parallel relationship to one another must be found or must be created to act as guiding planes during placement and removal of the prosthesis. Guiding planes are necessary to ensure the passage of rigid parts of the prosthesis past existing areas of interference. Thus the denture can be easily placed and removed by the patient without strain on the teeth contacted or on the denture itself and without damage to the underlying soft tissues.

Guiding planes are also necessary to ensure predictable clasp assembly function, including retention and stabilization. For a clasp to be retentive, its retentive arm must be forced to flex. Hence, guiding planes are necessary to give a positive direction to the movement of the restoration to and from its terminal position.

### Retentive Areas

Retentive areas must exist for a given path of placement and must be contacted by retentive clasp arms that are forced to flex over a convex surface during placement and removal. Satisfactory clasp retention is no more than the resistance of metal to deformation. For a clasp to be retentive, its path of escapement must be other than parallel to the path of removal of the denture itself; otherwise it would not be forced to flex and thereby generate the resistance known as retention. Clasp retention therefore depends on the existence of a definite path of placement and removal.

Although desirable, retention at each principal abutment may not be balanced in relation to the tooth on the opposite side of the arch (exactly equal and opposite in magnitude and relative location); however, positive cross-arch reciprocation to retentive elements must be present. Retention should be sufficient only to resist reasonable dislodging forces. In other words, it should be the minimum acceptable for adequate retention against reasonable dislodging forces.

Fairly even retention may be obtained by one of two means. One is to change the path of placement to increase or decrease the angle of cervical convergence of opposing retentive surfaces of abutment teeth. The other is to alter the flexibility of the clasp arm by changing its design, its size and length, or the material of which it is made.

### Interference

The prosthesis must be designed so that it may be placed and removed without encountering tooth or soft tissue interference. A path of placement may be selected that encounters interference only if the interference can be eliminated during mouth preparations or on the master cast by a reasonable amount of blockout. Interference may be eliminated during mouth preparations by surgery, extraction, modification of interfering tooth surfaces, or alteration of tooth contours with restorations.

Generally, interference that cannot be eliminated for one reason or another takes precedence over the factors of retention and guiding planes. Sometimes certain areas can be made noninterfering only by selecting a different path

of placement at the expense of existing retentive areas and guiding planes. These must then be modified with restorations that are in harmony with the path dictated by the existing interference. On the other hand, if areas of interference can be eliminated by various reasonable means, this should be done. When this occurs, the axial contours of existing abutments may frequently be used with little alteration.

### Esthetics

By one path of placement, the most esthetic location of artificial teeth is made possible, and less clasp metal and base material may be displayed.

The location of retentive areas may influence the path of placement selected; therefore retentive areas should always be selected with the most esthetic locations of clasps in mind. When restorations are to be made for other reasons, they should be contoured to permit the least display of clasp metal. Generally, less metal will be displayed if the retentive clasp is placed at a more distogingival area of tooth surface, made possible by the path of placement selected or by the contour of the restorations.

Esthetics also may dictate the choice of path selected when missing anterior teeth must be replaced with the partial denture. In such situations, a more vertical path of placement is often necessary so that neither the artificial teeth nor the adjacent natural teeth will have to be modified excessively (see Figure 11-10). In this instance, esthetics may take precedence over other factors. This necessitates the preparation of abutment teeth to eliminate interferences and to provide guiding planes and retention in harmony with that path of placement dictated by esthetic factors.

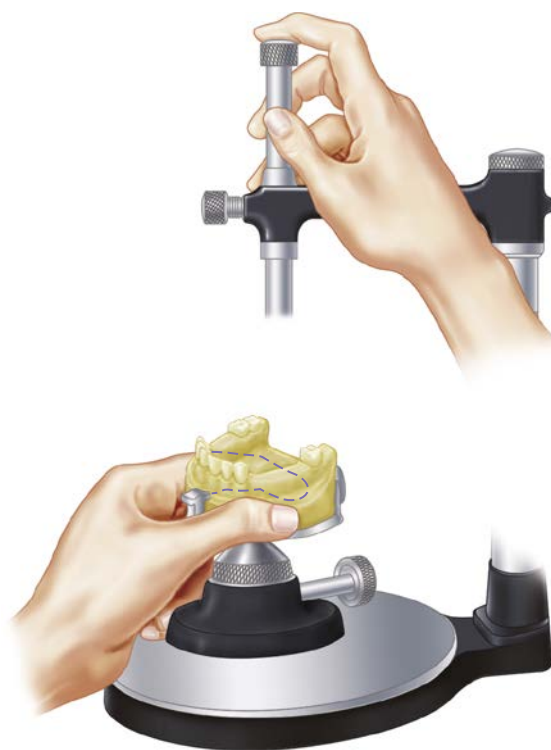
Because the primary consideration should be the preservation of remaining oral tissues, esthetics should not be allowed to jeopardize the success of the partial denture. The replacement of missing anterior teeth therefore should be accomplished by means of FPDs whenever possible, especially if the mechanical and functional effectiveness of the partial denture will require significant tooth preparation.

## STEP-BY-STEP PROCEDURES IN SURVEYING A DIAGNOSTIC CAST

Attach the cast to the adjustable surveyor table by means of the clamp provided. Position the adjustable table so that the occlusal surfaces of the teeth are approximately parallel to the platform (Figure 11-11). Such an orientation is a tentative but practical way to start considering the factors that influence the path of placement and removal.

### Guiding Planes

Determine the relative parallelism of proximal surfaces of all of the potential abutment teeth by contacting the proximal tooth surfaces with the surveyor blade or diagnostic stylus. Alter the cast position anteroposteriorly until these proximal surfaces are in as close to a parallel relation to

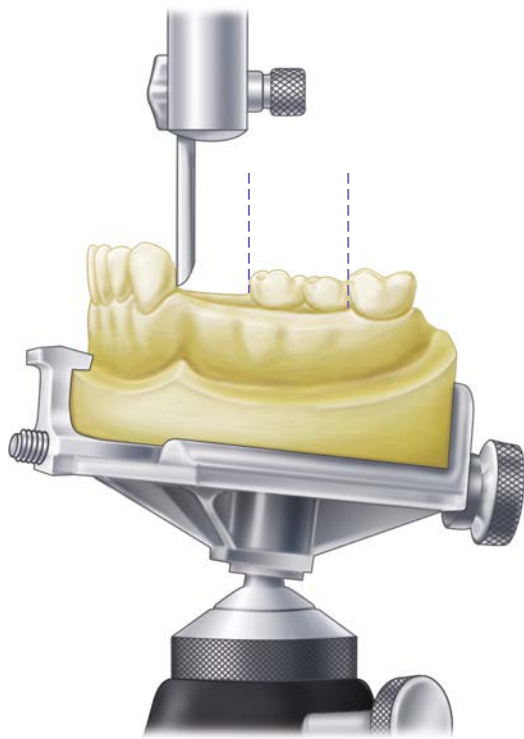


**FIGURE 11-11** Recommended method for manipulating the dental surveyor. The right hand is braced on the horizontal arm of the surveyor, and the fingers are used, as illustrated, to raise and lower the vertical shaft in its spindle. The left hand holding the cast on the adjustable table slides horizontally on the platform in relation to the vertical arm. The right hand must be used to loosen and tighten the tilting mechanism as a suitable anteroposterior and lateral tilt of the cast in relation to the surveyor is being determined.

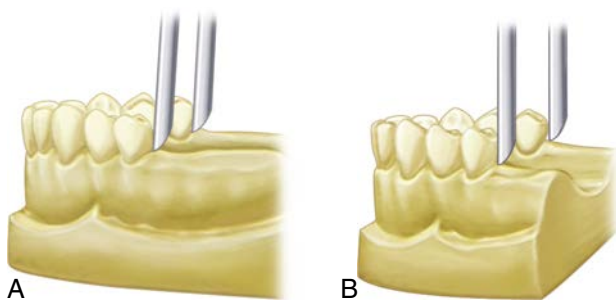
one another as possible, or near enough that they can be made parallel by recontouring. For posterior modification spaces, this determines the anteroposterior tilt of the cast in relation to the vertical arm of the surveyor (Figure 11-12). Although the surveyor table is universally adjustable, it should be thought of as having only two axes, thus allowing only anteroposterior and lateral tilting. If an implant is to be used, the long axis of the implant should be considered in defining the guide plane reduction needs (see Figure 11-10, B).

When a choice is made between having contact with a proximal surface at the cervical area only and contact at the marginal ridge only, the latter is preferred because a plane may then be established by recontouring (Figure 11-13). It is obvious that when only gingival contact exists, a restoration is the only means of establishing a guiding plane. Therefore, if a tilt that does not provide proximal contact is apparent, the proximal surface must be established with some kind of restoration.

The end result of selecting a suitable anteroposterior tilt should be to provide the greatest combined areas of parallel proximal surfaces that may act as guiding planes. Other



**FIGURE 11-12** Relative parallelism of proximal tooth surfaces determines anteroposterior tilt of the cast in relation to the vertical arm of the surveyor.



**FIGURE 11-13** When the most desirable anteroposterior tilt of the cast in relation to the surveyor blade is determined, a choice must be made between positions illustrated in **A** and **B**. In **A**, the distal surface of the left premolar abutment would have to be extended by means of a restoration. In **B**, the right premolar could be altered slightly to provide an acceptably parallel guiding plane. Unless restorations are necessary for other reasons, the tilt shown in **B** is preferred.

axial surfaces of abutment teeth may also be used as guiding planes. This is realized most often by having the stabilizing component of the direct retainer assembly contacting in its entirety the axial surface of the abutment, which has been found or made parallel to the path of placement (see Figure 15-6). Therefore a lateral tilt of the cast to the vertical arm of the surveyor must also be considered, as well as the anteroposterior tilt, when guiding planes are used.

### Retentive Areas

Through contact of buccal and lingual surfaces of abutment teeth with the surveyor blade, the amount of retention existing below their height of convexity may be determined. This is best accomplished by directing a small source of light toward the cast from the side away from the dentist. The angle of cervical convergence is best observed as a triangle of light between the surveyor blade and the apical portion of the tooth surface being studied (see Figure 7-41).

Alter the cast position by tilting it laterally until similar retentive areas exist on the principal abutment teeth. If only two abutment teeth are involved (as in a Kennedy Class I partially edentulous arch), they are both principal abutments. However, if four abutment teeth are involved (as they are in a Kennedy Class III, modification 1 arch), they are all principal abutments, and retentive areas should be located on all four. But if three abutment teeth are involved (as they are in a Kennedy Class II, modification 1 arch), the posterior abutment on the tooth-supported side and the abutment on the distal extension side are considered to be the principal abutments, and retention needs to be equalized accordingly. The third abutment may be considered to be secondary, and less retention is expected from it than from the other two. An exception is when the posterior abutment on the tooth-supported side has a poor prognosis and the denture is designed to ultimately be a Class I. In such a situation, the two stronger abutments are considered to be principal abutments.

When the cast is tilted laterally to establish reasonable uniformity of retention, it is necessary that the table be rotated about an imaginary longitudinal axis without disturbing the anteroposterior tilt previously established. The resulting position is one that provides or makes possible parallel guiding planes and provides for acceptable retention on the abutment teeth. It should be noted that this most desirable position will always require some tooth modification to be achieved. Note that possible interference to this tentative path of placement has not, as yet, been taken into consideration.

### Interference

If a mandibular cast is being surveyed, check the lingual surfaces that will be crossed by a lingual bar major connector during placement and removal. Bony prominences and lingually inclined premolar teeth are the most common causes of interference to a lingual bar connector.

If the interference is bilateral, surgery or recontouring of lingual tooth surfaces, or both, may be unavoidable. If the interference is only unilateral, a change in the lateral tilt may avoid an area of tooth or tissue interference. In changing the path of placement to prevent interference, previously established guiding planes and an ideal location for retentive elements may be lost. Then the decision must be made whether to remove the existing interference by whatever means necessary or to resort to restorations on the abutment

teeth, thereby changing the proximal and retentive areas to conform to the new path of placement.

In a like manner, bony undercuts that offer interference to the seating of denture bases must be evaluated and the decision made to remove them surgically, to change the path of placement at the expense of modifying or restoring teeth to achieve guiding planes and retention, or to design denture bases to avoid such undercut areas. The latter may be done by shortening buccal and labial flanges and distolingual extension of the denture bases. However, it should be remembered that the maximum area available for support of the denture base should be used whenever possible.

Interference to major connectors rarely exists in the maxillary arch. Areas of interference are usually found on buccally inclined posterior teeth and those bony areas on the buccal aspect of edentulous spaces. As with the mandibular cast, the decision must be made whether to eliminate them, to change the path of placement at the expense of modifying or restoring teeth to achieve the required guiding planes and retention, or to design the connectors and bases to avoid them.

Other areas of possible interference to be evaluated are those surfaces of abutment teeth that will support or be crossed by minor connectors and clasp arms. Although interference to vertical minor connectors may be blocked out, doing so may cause discomfort to the patient's tongue and may create objectionable spaces, which could result in the trapping of food. Also it is desirable that tooth surfaces contacted by vertical connectors be used as auxiliary guiding planes whenever possible. Too much relief is perhaps better than too little because of the possibility of irritation to soft tissues. It is always better that the relief be placed with some objective in mind. If possible, a minor connector should pass vertically along a tooth surface that is parallel to the path of placement (which is considered ideal) or tapered occlusally. If tooth undercuts that necessitate the use of an objectionable amount of blockout exist, they may be eliminated or minimized by slight changes in the path of placement and/or eliminated during mouth preparations. The need for such alteration should be indicated on the diagnostic cast in red pencil after final acceptance of a path of placement.

Tooth surfaces on which reciprocal and stabilizing clasp arms will be placed should be studied to see whether sufficient areas exist above the height of convexity for the placement of these components. The addition of a clasp arm to the occlusal third of an abutment tooth adds to its occlusal dimension and therefore to the occlusal loading of that tooth. Nonretentive and stabilizing clasp arms are best located between the middle third and the gingival third of the crown rather than on the occlusal third.

Areas of interference to proper placement of clasp arms can be eliminated by reshaping tooth surfaces during mouth preparations. These areas should be indicated on the diagnostic cast. Areas of interference to the placement of clasps may necessitate minor changes in the path of placement or

changes in the clasp design. For example, a bar clasp arm originating mesially from the major connector to provide reciprocation and stabilization might be substituted for a distally originating circumferential arm.

Areas of interference often overlooked are the distal line angles of premolar abutment teeth and the mesial line angles of molar abutments. These areas frequently offer interference to the origin of circumferential clasp arms. If not detected at the time of initial survey, they are not included in the plan for mouth preparations. When such an undercut exists, the following three alternatives may be considered:

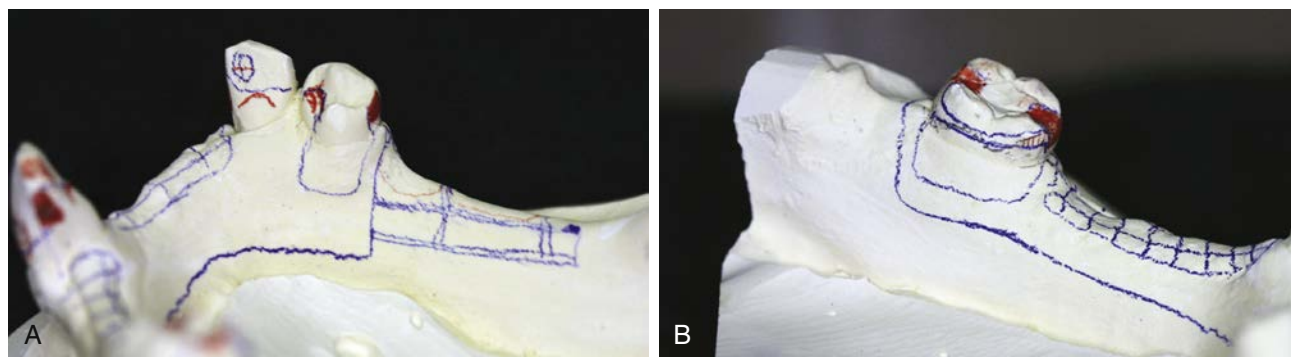
1. They may be blocked out the same as any other area of interference. This is by far the least satisfactory method because the origin of the clasp must then stand away from the tooth in proportion to the amount of blockout used. Although this is perhaps less objectionable than its being placed occlusally, it may be objectionable to the tongue and the cheek and may create a food trap.
2. They may be circumvented by approaching the retentive area from a gingival direction with a bar clasp arm. This is often a satisfactory solution to the problem if other contraindications to the use of a bar clasp arm, such as a severe tissue undercut or a retentive area that is too high on the tooth, are not present.
3. They may be eliminated by reducing the offending tooth contour during mouth preparation. This permits the use of a circumferential clasp arm originating well below the occlusal surface in a satisfactory manner. If the tooth is to be modified during mouth preparations, it should be indicated on the diagnostic cast with a colored pencil.

When the retentive area is located objectionably high on the abutment tooth or the undercut is too severe, interference may also exist on tooth surfaces that support retentive clasps. Such areas of extreme or high convexity must be considered as areas of interference and should be reduced accordingly. These areas are likewise indicated on the diagnostic cast for reduction during mouth preparations.

### Esthetics

The path of placement thus established must still be considered from the standpoint of esthetics, as to both the location of clasps and the arrangement of artificial teeth.

Clasp designs that will provide satisfactory esthetics for any given path of placement usually may be selected. In some instances, gingivally placed bar clasp arms may be used to advantage; in others, circumferential clasp arms located cervically may be used. This is especially true when other abutment teeth located more posteriorly may bear the major responsibility for retention. In still other instances, a tapered wrought-wire retentive clasp arm may be placed to better esthetic advantage than a cast clasp arm. The placement of clasp arms for esthetic reasons does not ordinarily justify altering the path of placement at the expense of mechanical factors. However, it should be considered concurrently with other factors, and if a choice between two paths of insertion of equal merit



**FIGURE 11-14** Diagnostic casts can serve as a visual guide for tooth preparation. **A**, Surveyed cast shows areas requiring tooth reduction in red (mesio-occlusal rest and distal guide plane #28, cingulum rest #27), as well as path of insertion tripod marks. **B**, This mesially tipped molar has been diagnosed to have a ring clasp. Red markings show the necessary mesio-occlusal and disto-occlusal rests required, as well as the mesial guide plane. Also shown is the reduction necessary to lower the lingual height of contour at the mesiolingual line angle. All required axial contour adjustments are determined through the appropriate use of a surveyor.

permits a more esthetic placement of clasp arms by one path than the other, that path should be given preference.

When anterior replacements are involved, the choice of path is limited to a more vertical one for reasons previously stated. In this instance alone, esthetics must be given primary consideration, even at the expense of altering the path of placement and making all other factors conform. This factor should be remembered when the other three factors are considered so that compromises can be made at the time other factors are being considered.

### FINAL PATH OF PLACEMENT

The final path of placement will be the anteroposterior and lateral position of the cast, in relation to the vertical arm of the surveyor that best satisfies all factors: guiding planes, retention, interference, esthetics, and implant long axis.

All proposed mouth changes should be indicated on the diagnostic cast in red pencil, with the exception of restorations to be done. These may also be indicated on an accompanying chart if desired. Extractions and surgery are given priority to allow time for healing. The remaining red marks represent actual modifications of the teeth that remain to be done, which consist of the preparation of proximal surfaces, the reduction of buccal and lingual surfaces, and the preparation of rest seats. Except when they are placed in the wax pattern for a cast restoration, preparation of rest seats should always be deferred until all other mouth preparations have been completed.

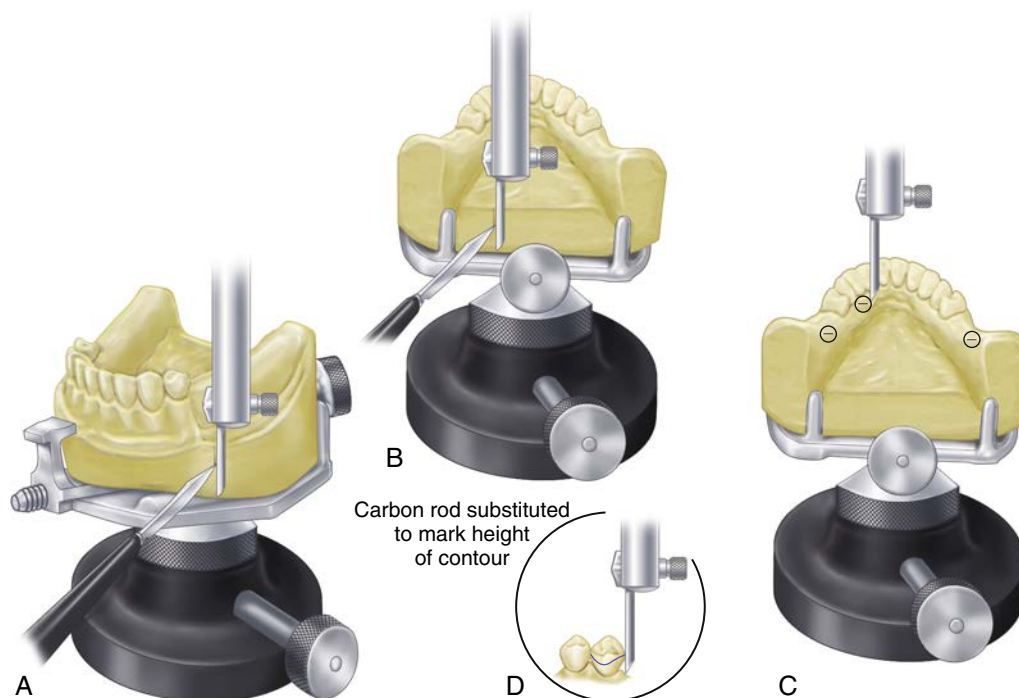
The actual locations of rests will be determined by the proposed design of the denture framework. Therefore the tentative design should be sketched on the diagnostic cast in pencil after the path of placement has been decided. This is done not only to locate rest areas but also to record graphically the plan of treatment before mouth preparations. In the intervening time between patient visits, other partial denture restorations may have been considered. The dentist should have the plan of treatment readily available at each

succeeding appointment to avoid confusion and to keep a reminder about that which is to be done and the sequence that will be required.

The plan for treatment should include (1) the diagnostic cast with the mouth preparations and the denture design marked on it; (2) a chart showing the proposed design and the planned treatment for each abutment; (3) a working chart showing the total treatment involved that will permit a quick review and a check-off of each step as the work progresses; and (4) a record of the fee quoted for each phase of treatment that can be checked off as it is recorded on the patient's permanent record.

Red pencil marks on the diagnostic cast are used to indicate the locations of areas to be modified as well as the locations of rests (Figure 11-14). Although it is not necessary that rest areas be prepared on the diagnostic cast, it is advisable for the beginning student to have done this before proceeding to alter the abutment teeth. This applies equally to crown and inlay preparations on abutment teeth. It is advisable, however, for even the most experienced dentist to have trimmed the stone teeth with the surveyor blade wherever tooth reduction is to be done. This identifies not only the amount to be removed in a given area but also the plane in which the tooth is to be prepared. For example, a proximal surface may need to be recontoured in only the upper third or the middle third to establish a guiding plane that will be parallel to the path of placement. This is not usually parallel to the long axis of the tooth, and if the rotary instrument is laid against the side of the tooth, the existing surface angle will be maintained, thus avoiding the need to establish a new plane that is parallel to the path of placement.

The surveyor blade, which represents the path of placement, may be used to advantage to trim the surface of the abutment tooth whenever a red mark appears. The resulting surface represents the amount of tooth to be removed in the mouth and indicates the angle at which the handpiece must be held. The cut surface on the stone tooth is not marked



**FIGURE 11-15** **A** and **B**, The path of placement is determined, and the base of the cast is scored to record its relation to the surveyor for future repositioning. **C**, An alternate method of recording the relation of the cast to the surveyor is known as *tripoding*. A carbon marker is placed in the vertical arm of the surveyor, and the arm is adjusted to the height by which the cast can be contacted in three divergent locations. The vertical arm is locked in position, and the cast is brought into contact with the tip of the carbon marker. Three resultant marks are encircled with colored lead pencil for ease of identification. Reorientation of the cast to the surveyor is accomplished by tilting the cast until the plane created by three marks is at a right angle to the vertical arm of the surveyor. **D**, Height of contour is then delineated by a carbon marker.

with red pencil again, but it is outlined in red pencil to positively locate the area that is to be prepared.

### RECORDING RELATION OF CAST TO SURVEYOR

Some method of recording the relation of the cast to the vertical arm of the surveyor must be used so that the cast may be returned to the surveyor for future reference, especially during mouth preparations. The same applies to the need for returning any working cast to the surveyor for shaping wax patterns, trimming blockout on the master cast, or locating clasp arms in relation to undercut areas.

Obviously the trimmed base will vary with each cast; therefore recording the position of the surveyor table is of no value. If it were, calibrations could be incorporated on the surveyor table that would allow the same position to be reestablished. Instead, the position of each cast must be established separately, and any positional record applies only to that cast.

Of several methods, two seem to be the most convenient and accurate. One method is to place three widely divergent dots on the tissue surface of the cast with the tip of a carbon marker with the vertical arm of the surveyor in a locked position. Preferably these dots should not be placed

on areas of the cast involved in the framework design. The dots should be encircled with a colored pencil for easy identification. When the cast is returned to the surveyor, it may be tilted until the tip of the surveyor blade or diagnostic stylus again contacts the three dots in the same plane. This approach, which will produce the original position of the cast and therefore the original path of placement, is known as *tripoding the cast* (Figure 11-15). Some dentists prefer to make tiny pits in the cast at the location of the tripoding dots to preserve the orientation of the cast and to transfer this relationship to the refractory cast.

A second method is to score two sides and the dorsal aspect of the base of the cast with a sharp instrument held against the surveyor blade (see Figure 11-15). When the cast is tilted until all three lines are again parallel to the surveyor blade, the original cast position can be reestablished. Fortunately, the scratch lines will be reproduced in any duplication, thereby permitting any duplicate cast to be related to the surveyor in a similar manner. Whereas a diagnostic cast and a master cast cannot be made to be interchangeable, a refractory cast, which is a duplicate of the master cast, can be repositioned on the surveyor at any time. The technician must be cautioned not to trim the sides of the cast on the cast trimmer and thereby lose the reference marks for repositioning.

It must be remembered that repositioning a cast on a surveyor at any time can involve a certain amount of human error. It has been estimated that an error of 0.2 mm can be anticipated when a cast with three reference points on its base is reoriented. This reorientation error can influence the placement of appropriate blockout wax and may result in ineffective placement of direct retainers into prescribed undercuts and improper contacts of minor connectors with guiding planes. Therefore reorientation of the cast to the surveyor by any method must be done with great care.

## SURVEYING THE MASTER CAST


The master cast must be surveyed as a new cast, but the prepared proximal guiding plane surfaces will indicate the correct anteroposterior tilt. Some compromises may be necessary, but the amount of guiding plane surface remaining after blockout should be the maximum for each tooth. Areas above the point of contact with the surveyor blade are not considered as part of the guiding plane area, and neither are gingival undercut areas, which will be blocked out.

The lateral tilt will be the position that provides equal retentive areas on all principal abutments in relation to the planned clasp design. Factors of flexibility, including the need for extra flexibility on distal extension abutments, must be considered when one is deciding what will provide equal retention on all abutment teeth. For example, cast circumferential or cast bar retention on the tooth-supported side of a Class II design should be balanced against the 18-gauge wrought-wire retention on a distal abutment only if the more rigid cast clasp engages a lesser undercut than the wrought-wire clasp arm. Therefore the degree of undercut alone does not ensure relatively equal retention unless clasp arms of equal length, diameter, form, and material are used.

Gross interference will have been eliminated during mouth preparation. Thus for a given path of placement that is providing guiding planes and balanced retention, any remaining interference must be eliminated with blockout. If mouth preparations have been adequately planned and executed, the undercuts remaining to be blocked out should be minimal.

The base of the cast is now scored, or the cast is tripoded as described previously. The surveyor blade or diagnostic stylus then may be replaced with a carbon marker, and the height of convexity of each abutment tooth and soft tissue contours may be delineated. Similarly, any areas of interference to the rigid parts of the framework during seating and removal should be indicated with the carbon marker so areas to be blocked out or relieved can be located.

Carbon markers that become the slightest bit worn from use should be discarded. A worn (tapered) carbon marker will indicate heights of contour more occlusally located than those that actually exist. The carbon marker must be parallel to the vertical spindle of the surveyor (Figure 11-16). The diagnostic stylus should always be checked to ensure that it is not bent or distorted.



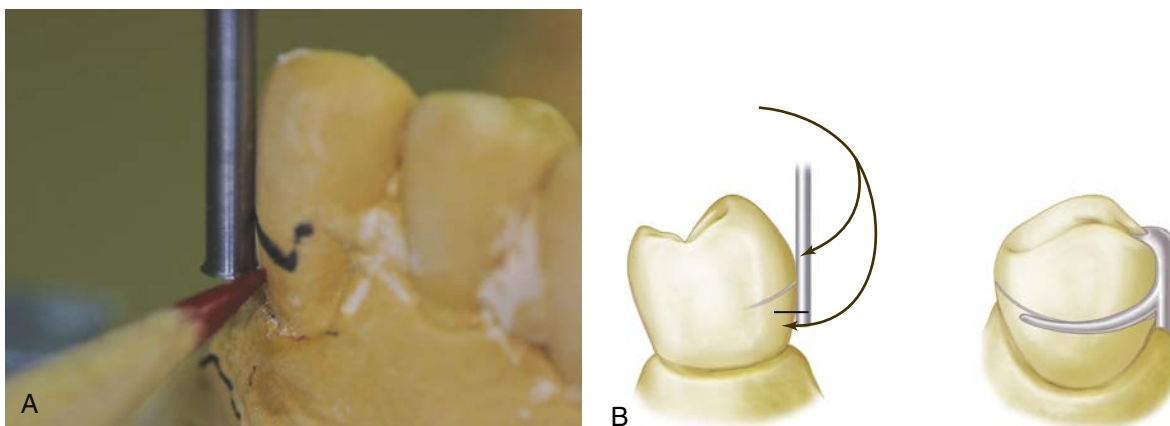
**FIGURE 11-16** A worn carbon marker (*left*) should be discarded because it will invariably misleadingly mark the height of contour for a given orientation of the cast to the vertical spindle of the surveyor. Unworn carbon (*right*) with an angled end is preferable for marking heights of contour on abutment teeth and performing surveys of soft tissue areas.

## MEASURING RETENTION

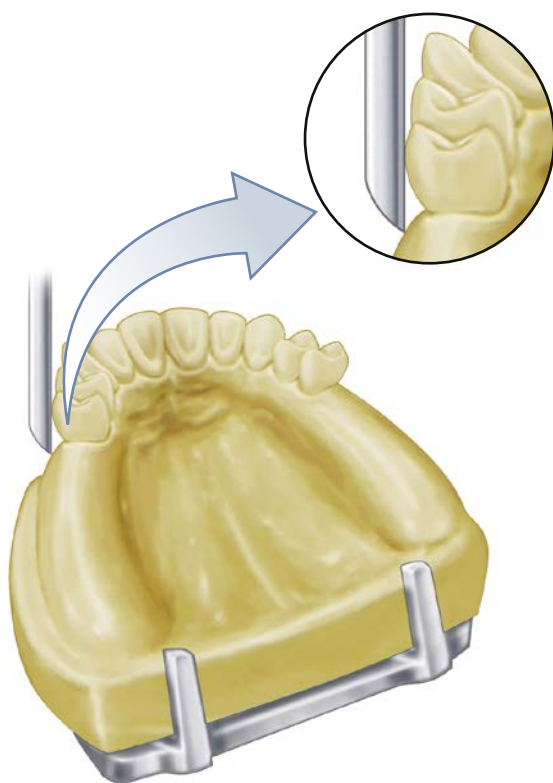
The surveyor is used with the master cast for two purposes: (1) to delineate the height of contour of the abutment teeth both to locate clasp arms and to identify the location and magnitude of retentive undercuts; and (2) to trim blockout of any remaining interference to placement and removal of the denture. The areas involved are those that will be crossed by rigid parts of the denture framework.

The exact undercut that retentive clasp terminals will occupy must be measured and marked on the master cast (Figure 11-17). Undercuts may be measured with an undercut gauge, such as those provided with the Ney and Jelenko surveyors. The amount of undercut is measured in hundredths of an inch, with the gauges allowing measurements up to 0.03 inch. Theoretically the amount of undercut used may vary with the clasp to be used, up to a full 0.03 inch. However, undercuts of 0.01 inch are often adequate for retention by cast retainers. Tapered wrought-wire retention may safely use up to 0.02 inch without inducing undesirable torque on the abutment tooth, provided the wire retentive arm is long enough (at least 8 mm). The use of 0.03 inch is rarely, if ever, justified with any clasp. When greater retention is required, such as when abutment teeth remain on only one side of the arch, multiple abutments should be used, rather than increased retention on any one tooth.

When a source of light is directed toward the tooth being surveyed, a triangle of light is visible. This triangle is bounded by the surface of the abutment tooth on one side and the blade of the surveyor on the other, the apex being the point of contact at the height of convexity and the base of the triangle being the gingival tissues (Figure 11-18). Retention will be determined by (1) the magnitude of the angle of cervical convergence below the point of convexity; (2) the depth at which the clasp terminal is placed in the angle; and (3) the flexibility of the clasp arm. The intelligent application of various clasp designs with their relative flexibility is of greater importance than the ability to measure an undercut with precise accuracy.



**FIGURE 11-17** **A**, Undercut gauge measures the depth of undercut below the height of contour. I-bar direct retainer will contact the tooth from the point of the undercut to the height of contour. The depth to which the retentive clasp arm can be placed depends not only on its length, taper, and diameter and the alloy from which it is made, but also on the type of clasp. A circumferential clasp arm is more flexible than a bar clasp arm of the same length (see Chapter 7). **B**, Specific measurement of the undercut gingiva to the height of contour may be ascertained with the use of an undercut gauge attached to the surveyor. Simultaneous contact of the shank of the undercut gauge at the height of contour and of the lip of a specific undercut gauge on a tooth in the infrabulge area establishes definitively the degree and location of undercut. Therefore the tip of the retentive arm of the direct retainer may be placed at the planned depth of the undercut.



**FIGURE 11-18** Tooth undercut is best viewed against a good source of light passing through the triangle bounded by the surface of the abutment tooth, the surveyor blade, and the gingival tissues.

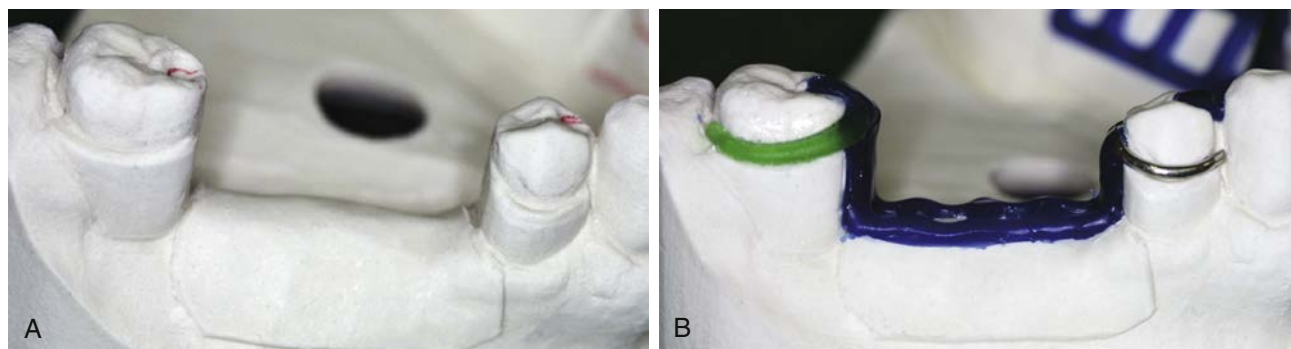
The final design may now be drawn on the master cast with a fine crayon pencil, preferably one that will not come off during duplication. Graphite is usually lifted in duplication, but some crayon pencil marks will withstand duplication without blurring or transfer. Sizing or spraying the master cast to protect such pencil marks is usually not advisable unless it is done with extreme care to avoid obliterating the surface detail.

### BLOCKING OUT THE MASTER CAST

After the path of placement and the location of undercut areas have been established on the master cast, any undercut areas that will be crossed by rigid parts of the denture (which is every part of the denture framework but the retentive clasp terminals) must be eliminated by blockout.

In the broader sense of the term, *blockout* includes not only the areas crossed by the denture framework during seating and removal but also (1) those areas not involved that are blocked out for convenience; (2) ledges on which clasp patterns are to be placed; (3) relief beneath connectors to avoid tissue impingement; and (4) relief to provide for attachment of the denture base to the framework.

Ledges or shelves (shaped blockout) for locating clasp patterns may or may not be used (Figure 11-19). However, this should not be confused with the actual blocking out of undercut areas that would offer interference to the placement of the denture framework. Only the latter is made on the surveyor, with the surveyor blade or diagnostic stylus used as a paralleling device.



**FIGURE 11-19** The wax ledge on the buccal surface of the molar abutment will be duplicated in a refractory cast for exact placement of the clasp pattern. Note that the ledge has been carved slightly below the penciled outline of the clasp arm. This allows the gingival edge of the clasp arm to be polished and still remain in its planned relationship to the tooth when the denture is seated. It should also be noted that the wax ledge definitively establishes planned placement of the direct retainer tip into the measured undercut.

Hard inlay wax may be used satisfactorily as a blockout material. It is easily applied and is easily trimmed with the surveyor blade. Trimming is facilitated by slight warming of the surveyor blade with an alcohol torch. Whereas it is true that any wax will melt more readily than a wax-clay mixture if the temperature of the duplicating material is too high, it should be presumed that the duplicating material will not be used at such an elevated temperature. If the temperature of the duplicating material is high enough to damage a wax blockout, other distortions resulting in an inaccurate duplication will likely occur.

Paralleled blockout is necessary for areas that are cervical to guiding-plane surfaces and over all undercut areas that will be crossed by major or minor connectors. Other areas that are to be blocked out for convenience and for avoidance of difficulties in duplication should be blocked out with hard baseplate wax or oil-base modeling clay (artist's modeling clay). Such areas include the labial surfaces and labial undercuts not involved in the denture design and the sublingual and distolingual areas beyond the limits of the denture design. These are blocked out arbitrarily with hard baseplate wax or clay, but because they have no relation to the path of placement, they do not require the use of the surveyor. Modeling clay that is water soluble should not be used when duplication procedures are involved.

Areas to be crossed by rigid connectors, on the other hand, should be trimmed with the surveyor blade or some other surveyor tool parallel to the path of placement (Figure 11-20). This imposes a considerable responsibility on the technician. If the blockout is not sufficiently trimmed to expose guiding-plane surfaces, the effects of these guiding planes, which were carefully established by the dentist, will be nullified. If, on the other hand, the technician is overzealous in paralleling the blockout, the stone cast may be abraded by heavy contact with the surveyor blade. Although the resulting cast framework would seat back onto the master cast without interference, interference to placement in the mouth would result. This would

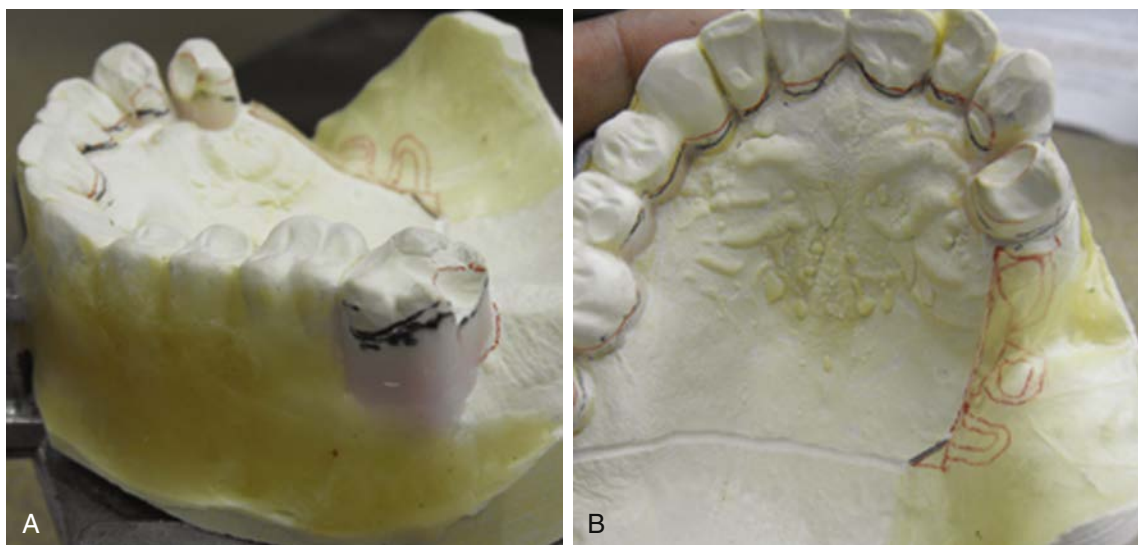


**FIGURE 11-20** All guiding-plane areas must be parallel to the path of placement, and all other areas that will be contacted by rigid parts of the denture framework must be made free of the undercut by parallel blockout. Relief must also be provided for the gingival crevice and gingival margin. *Black regions* designate parallel blockout at proximal guide-plane surfaces and relief along the palatal marginal gingiva.

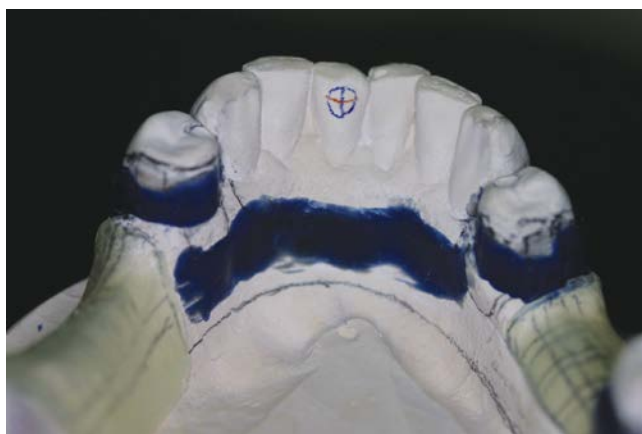necessitate relieving the casting at the chair, which is not only an embarrassing and time-consuming operation but also one that may have the effect of obliterating guiding plane surfaces.

### RELIEVING THE MASTER CAST

Tissue undercuts that must be blocked out are paralleled in much the same manner as tooth undercuts. The difference between blockout and relief must be clearly understood (Figures 11-21 and 11-22). For example, tissue undercuts that would offer interference to the seating of a lingual bar connector are blocked out with blockout wax and trimmed parallel to the path of placement. This does not in itself necessarily afford relief to avoid tissue impingement. In addition to such blockout, a relief of varying thickness must sometimes be used, depending on the location of the connector, the relative slope of the alveolar ridge, and the predictable effect of denture rotation. It must be assumed that indirect retainers, as such, or indirect retention is provided in the design of the denture to prevent rotation of the lingual bar inferiorly. A vertical downward rotation of the denture bases around

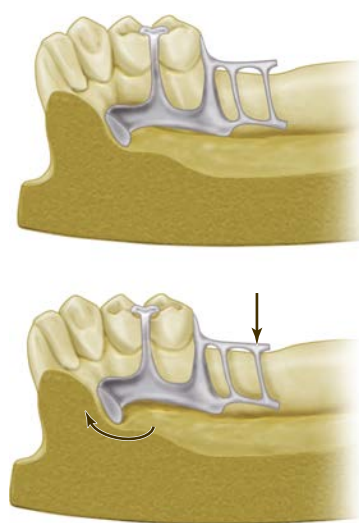


**FIGURE 11-21** Parallel blockout (**A**, labial surfaces of all teeth and gingivae to the retentive clasp on tooth #2) and relief (**B**, marginal gingivae of palatal surfaces of teeth and at distal minor connector) in preparation for framework casting. These spaces allow planned seating of the framework without tissue trauma while accommodating the addition of acrylic-resin beneath the distal extension minor connector for base support without metal contact.



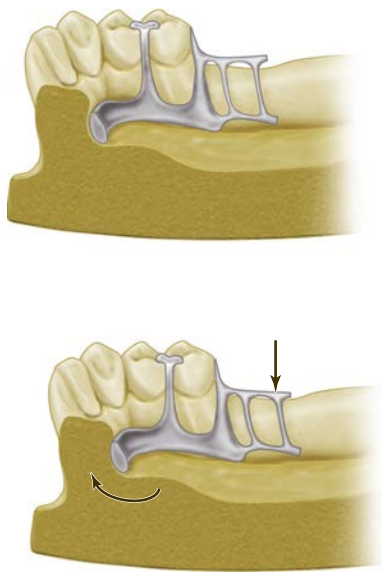
**FIGURE 11-22** Relief and blockout of the master cast before duplication. All undercuts involved in the denture design have been blocked out parallel to the path of placement, except the retentive tips of the retainer clasps. Residual ridges have been provided 20-gauge relief for denture base material.

posterior abutments places the bar increasingly farther from the lingual aspect of the alveolar ridge when this surface slopes inferiorly and posteriorly (Figure 11-23). Adequate relief of soft tissues adjacent to the lingual bar is obtained by the initial finishing and polishing of the framework in these instances. However, excessive upward vertical rotation of a lingual bar will impinge on lingual tissues if the alveolar ridge is nearly vertical or undercut to the path of placement (Figure 11-24). The region of the cast involving proposed placement of the lingual bar should, in this situation, be relieved first by parallel block-out and then by a 32-gauge wax strip. Low-fusing casting



**FIGURE 11-23** Sagittal section of the cast and denture framework. The lingual alveolar ridge slopes inferiorly and posteriorly (*upper figure*). When the force is directed to displace the denture base downward, the lingual bar rotates forward and upward but does not impinge on the soft tissue of the alveolar ridge (*lower figure*). Therefore in such instances, adequate relief to avoid impingement is gained when the tissue side of the lingual bar is highly polished during the finishing process.

wax (such as, Kerr's green casting wax) should not be used for this purpose; it is too easily thinned during adapting and may be affected by the temperature of the duplicating material. Pink casting wax should be used, even though it is difficult to adapt uniformly. A pressure-sensitive, adhesive-coated casting wax is preferred because it adapts



**FIGURE 11-24** An undercut alveolar ridge was blocked out parallel to the path of placement in fabricating the lingual bar (*upper figure*). Application of vertical force to cause rotation of the lingual bar upward can cause impingement of lingual tissue on the alveolar ridge (*lower figure*). To avoid impingement in these instances, not only should the master cast be blocked out parallel to the path of placement, but an additional relief of 32-gauge sheet wax should be used to block out the cast in such undercut areas.

readily and adheres to the cast surface. Any wax, even the adhesive type, should be sealed all around its borders with a hot spatula to prevent its lifting when the cast is moistened before or during duplication.

Horizontal rotational tendencies of mandibular distal extension removable partial dentures account for many of the tissue irritations seen adjacent to a lingual mandibular major connector. These irritations can usually be avoided by blocking out all undercuts adjacent to the bar parallel to the path of placement and then including adequate stabilizing components in the design of the framework to resist horizontal rotation. Judicious relief of the tissue side of the lingual bar with rubber wheels at the site of the irritation most often will correct the discrepancy. Under no circumstances should the rigidity of the major connector be jeopardized by grinding any portion of it.

Still other areas requiring relief are the areas where component parts cross the gingiva and gingival crevices. All gingival areas bridged by the denture framework should be protected from possible impingement resulting from rotation of the denture framework. Hard inlay wax may be used to block out gingival crevices (see [Figure 11-21](#)).

**PARALLELED BLOCKOUT, SHAPED BLOCKOUT, ARBITRARY BLOCKOUT, AND RELIEF**

[Table 11-1](#) differentiates between paralleled blockout, shaped blockout, arbitrary blockout, and relief. The same factors apply to both maxillary and mandibular arches, except that relief is ordinarily not used beneath palatal major connectors, as it is with mandibular lingual bar connectors, except when maxillary tori cannot be circumvented, or when resistive median palatal raphe are encountered.

**TABLE 11-1**

**Differentiation between Parallel Blockout, Shaped Blockout, Arbitrary Blockout, and Relief**

Site	Material	Thickness
<b>Paralleled Blockout</b>		
Proximal tooth surfaces to be used as guiding planes	Hard baseplate wax or blockout material	Only undercut remaining below contact of the surveyor blade with tooth surface
Beneath all minor connectors	Hard baseplate wax or blockout material	Only undercut remaining below contact of the surveyor blade with tooth surface
Tissue undercuts to be crossed by rigid connectors	Hard baseplate wax or blockout material	Only undercut remaining below contact of the surveyor blade with surface of the cast
Tissue undercuts to be crossed by the origin of bar clasps	Hard baseplate wax or blockout material	Only undercut remaining below contact of the surveyor blade with surface of the cast
Deep interproximal spaces to be covered by minor connectors or linguoplates	Hard baseplate wax or blockout material	Only undercut remaining below contact of the surveyor blade with surface of the cast
Beneath bar clasp arms to gingival crevice	Hard baseplate wax or blockout material	Only undercut area involved in attachment of the clasp arm to the minor connector

TABLE 11-1

Differentiation between Parallel Blockout, Shaped Blockout, Arbitrary Blockout, and Relief—cont'd

Site	Material	Thickness
<b>Shaped Blockout</b>		
On buccal and lingual surfaces to locate plastic or wax patterns for clasp arms	Hard baseplate wax	Ledges for location of reciprocal clasp arms to follow height or convexity so that they may be placed as cervical as possible without becoming retentive Ledges for location of retentive clasp arms to be placed as cervical as tooth contour permits; point of origin of clasp to be occlusal or incisal to height of the convexity, crossing the survey line at fourth terminal, and to include undercut area previously selected in keeping with flexibility of the clasp type being used
<b>Arbitrary Blockout</b>		
All gingival crevices	Hard baseplate wax	Enough to just eliminate gingival crevice
Gross tissue undercuts situated below areas involved in the design of denture framework	Hard baseplate wax or oil-based clay	Leveled arbitrarily with a wax spatula
Tissue undercuts distal to the cast framework	Hard baseplate wax or oil-based clay	Smoothed arbitrarily with a wax spatula
Labial and buccal tooth and tissue undercuts not involved in denture design	Hard baseplate wax or oil-based clay	Filled and tapered with spatula to within the upper third or crown
<b>Relief</b>		
Beneath lingual bar connectors or the bar portion of the linguoplates when indicated (see text)	Adhesive wax sealed to the cast; should be wider than the major connector to be placed on it	32-gauge wax if the slope of the lingual alveolar ridge is parallel to the path of placement; 32-gauge wax after parallel blockout of undercuts if the slope of the lingual alveolar ridge is undercut to the path of placement
Areas in which major connectors will contact thin tissue, such as hard areas so frequently found on lingual or mandibular ridges and elevated palatal raphes	Hard baseplate wax	Thin layer flowed on with hot wax spatula; however, if the maxillary torus must be covered, the thickness of the relief must represent the difference in the degree of displacement of the tissues covering the torus and the tissues covering the residual ridges
Beneath framework extensions onto ridge areas for attachment of resin bases	Adhesive wax, well adapted to and sealed to the cast beyond the involved area	20-gauge wax

# CHAPTER

# 12

## Considerations for the Use of Dental Implants with Removable Partial Dentures

### CHAPTER OUTLINE

#### Physiologic Distinction Between Prostheses

#### Replacing Anatomy and Functional Ability

#### Strategically Placed Implants for Removable

#### Partial Denture Stability and Improved Patient Accommodation

#### Movement Control With Selective Implant Placement

#### Placement for Support Versus Retention

#### Anatomic Concerns for Class I and II Arches

#### Benefits of Implant Versus Surveyed Crown

#### Strategically Lost Tooth and Implant Use

#### Use of Abutment for Support and/or Retention

#### Influence of Opposing Occlusion on Implant Location and Implant Abutment Design

#### Treatment Planning

#### Survey Considerations: Path of Insertion for Teeth and Implants

#### Location Influenced by Anatomic and Opposing Occlusal Factors

#### Clasp Assembly Requirements if an Implant Is Used Adjacent to Tooth

#### Clinical Examples

#### Summary

Dental implants are increasingly being used in a variety of ways in the replacement of teeth. Providing implants to support all teeth needing replacement is often preferable if indicated and if the patient can afford to do so. If the patient is unable to pursue an *implant-only* supported prosthesis, this should not keep him or her from considering an implant, because the patient still may benefit from a carefully selected implant used for critical clinical performance advantage when removable partial dentures (RPDs) are pursued. Additionally, implants can be used for RPDs while allowing for future implant-only treatment options.

This chapter presents basic considerations in the selection of implants to improve prosthesis performance by increasing functional stability. Prosthesis instability, a commonly stated problem with removable prostheses, is presented as a potentially confounding and unique component of oral sensory-motor function at issue when patients are challenged with removable prostheses. When all the relevant information necessary to adequately address how best to manage a patient's tooth loss is considered,\* one aspect that should be kept in mind is that *among the various prostheses from which we choose (conventional fixed partial denture, implant-supported partial denture, and removable partial denture), the removable partial denture is the most unique*. Exactly how we describe this uniqueness to our patients is critical to their appropriate prosthesis selection and provides a clue to us as to how dental implants can best be used in conjunction with RPDs.

\* Patient factors—clinical factors (dentition and residual ridge conditions), functional factors, psychological factors; prosthesis factors—implant, fixed, or removable partial dentures.

PHYSIOLOGIC DISTINCTION BETWEEN PROSTHESES

Although physiologic aspects of replacement prostheses have not been adequately researched, the fact that RPDs are less like teeth than fixed prostheses strongly suggests that we should delineate this to our patients. The most obvious difference between treatment options is the manner in which they are supported—conventional fixed partial dentures using teeth with periodontal ligaments versus implant prostheses using osseointegrated implants versus RPDs using teeth, or teeth and mucosa. An additional difference is the rigidity associated with the prosthesis-tooth interface connection—cemented prostheses rigidly connected to teeth versus screw-retained implant prostheses rigidly connected between implants versus clasp/attachment-retained RPD prostheses.

Given this support and rigid connection difference, it is easy to recognize that one distinguishing difference between fixed prostheses (tooth or implant supported) and tooth-tissue-supported RPDs is the potential for *movement under function*. The impact that such movement will have on related oral sensory and oral functional expectations of patients is potentially critical to understand. These patient-specific perspectives are variable because some of our patients are better at distinguishing oral sensory input than others, and some are more functionally capable than others. The importance of sensory-functional considerations is evident when it is realized that the oral cavity is unique from a sensory perception standpoint, because the sensory input from the mouth regions involved in the task of mastication represents one of the largest collections of sensory information processed for a single functional act in the body, rivaled closely by the multifunctional hand (Figure 12-1).

REPLACING ANATOMY AND FUNCTIONAL ABILITY

With this relative importance of oral sensory function associated with mastication in mind, it would be helpful to consider what exactly we are attempting to replace when we discuss with our patients the management of missing teeth. This involves both the physical tools for mastication and the oral ability for precise and stable neuromuscular functions to manipulate a bolus of food. Analysis of chewing studies shows that the oral receptor feedback that guides movement of the mandible comes from various sources. The most sensitive input (i.e., the input that provides the most refined and precisely controlled movement) comes from the periodontal mechanoreceptors (PMRs), with additional input coming from the gingiva, mucosa, periosteum/bone, and temporomandibular joint (TMJ) complex. Loss of teeth leads to loss of guidance precision, which may be caused by the deficit in PMRs. No artificial replacements reestablish the same ability inherent in the PMR guidance. Yet prostheses may vary in their ability to affect the deficit on the basis of sensory-related

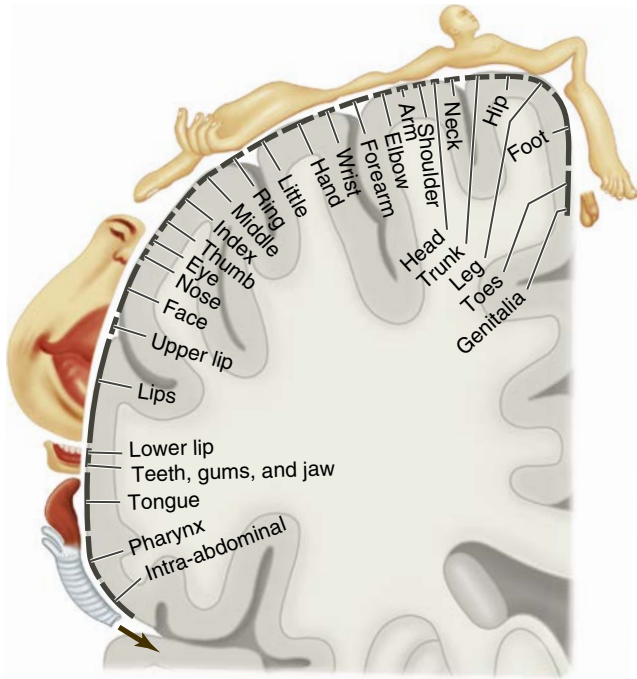


FIGURE 12-1 Somatosensory cortex.

dynamics. This notion of variable prosthesis impact suggests that either the prostheses are not the same or patients may vary in terms of neuromuscular\* ability.

What is meant by the term *neuromuscular ability*? This is the task-specific sensory-motor performance “ability” that a specific patient possesses for the task/act of mastication. It involves multiple factors, including the selection of a prosthesis that may vary in qualitative neuromuscular ability compared with the gold standard—natural teeth. This prosthesis influence can be favorable when replacements are more like teeth (in their neuromuscular sensory input nature), or it can be unfavorable if they are unlike teeth and potentially cause confounding sensory input that diminishes function (e.g., implant fixed partial denture versus denture base). This therapeutic variability suggests that prostheses differ in the influence they have on oral sensory receptors; therefore, this may affect our patient’s perspective on how much we have improved the rehabilitation of oral function (i.e., neurophysiologic ability rehabilitation).

Stability under function is critical for limiting confounding sensory input because instability is a significant confounder of normal function. Whether a prosthesis is stable or unstable influences whether it provides a positive or a negative contribution to an already reduced peripheral receptor influence. This is compounded by the inherent neuromuscular variability seen between patients.

\*In this discussion, *neurophysiologic* and *neuromuscular* both refer to the relationship between oral sensory input and the resultant oral functional movement.

Consequently, in some of our patients, replacement teeth may have less of a “margin” for sensory contribution without creating functional impediments.

### STRATEGICALLY PLACED IMPLANTS FOR REMOVABLE PARTIAL DENTURE STABILITY AND IMPROVED PATIENT ACCOMMODATION

To decide which treatment option is best from a patient accommodation perspective, it must be determined whether this specific patient possesses the ability to meet the challenge posed by the neuromuscular deficit. If the answer is *yes*, then the patient may be an appropriate candidate for an RPD. However, if the answer is *no* and for good reasons an RPD is chosen, the use of *strategically located implants* to assist the patient in meeting the challenge should be discussed.

Stated differently, the success of any prosthesis may be compromised by a significant level of sensory loss. In addition, if the patient also possesses an inherently poor neurophysiologic ability, the choice of a prosthesis that creates an additional sensory “burden” may make the situation too challenging for the patient. The greatest contributing factor to the challenge is instability, and stability is most efficiently improved by the use of dental implants.

### MOVEMENT CONTROL WITH SELECTIVE IMPLANT PLACEMENT

The most beneficial use of an implant with an RPD is to reduce the negative impact of any sensory input resulting from prosthesis movement. The greatest potential for movement is seen with Kennedy Class I and II prostheses. Consequently, the greatest benefits in the use of implants with Class I and II RPDs are to gain stability, control prosthesis movement, and reduce unnatural sensations that are movement-related.

The clinician who is deciding exactly where to place an implant for the greatest benefit should take many factors into consideration. The ultimate decision will likely be influenced by a combination of important clinical issues. Basic considerations include factors associated with support, stability, and retention; residual ridge anatomy; strategic tooth loss; opposing occlusal influence; and the condition of a terminal tooth.

#### Placement for Support Versus Retention

When considering where to place an implant to assist an RPD, we should ask, “What will best serve the patient over time?” Certainly, we want the prostheses to be adequately retained, but as we consider what the retentive need for our RPD is, we should also ask, “Is it the most important issue that patients face?”

Support for prostheses is the characteristic that resists the greatest functional forces—those associated with chewing. A well-supported prosthesis is likely to impart less displacement to the soft tissue; less displacement likely is associated with a more comfortable prosthesis. If the major concern is comfort, then support is more often the best treatment target

for an implant. The most effective location for resisting force would be the posterior occlusal contact position—that position where the forces of occlusion are likely the greatest.

#### Anatomic Concerns for Class I and II Arches

It is clear that placement of implants within the alveolar ridge requires adequate bone volume. Tooth loss commonly leads to residual ridge resorption; the longer from the time of extraction that a patient is seen, the more alveolar resorption is expected.

When this occurs in the posterior jaw, vertical loss of volume at the ridge crest is complicated by the maxillary sinus and inferior alveolar nerve at the apical location. These anatomic boundaries require careful consideration of surgical manipulation and must be considered as potentially more burdensome to the patient (i.e., they increase surgical risk). It is unclear at this time whether shortened implants ( $\leq 8$  mm) in posterior edentulous regions are adequate for the necessary resistance. Certainly, the opposing occlusion contributes to this decision and natural teeth would be expected to generate more forceful occlusal function demanding greater implant resistance, compared with an opposing complete denture prosthesis.

#### Benefits of Implant Versus Surveyed Crown

Surveyed crowns have long been used to maximize support, stability, and retention for RPDs. The ability to control expected movement in the removable prosthesis can be improved by the use of such a carefully contoured crown. The same can be said for an implant, which presents a logical comparison as to which is a better choice for patients.

As an example, if a patient is deciding between a crown on tooth #6 versus an implant at site #5, what should he or she be considering? Both can be used to provide support, stability, and retention. If the crown is designed to accommodate an attachment, it can also be used without a visible clasp. This is a more technically demanding intervention and carries with it more challenging maintenance requirements. Also, the typical consideration regarding caries risk should be discussed. This suggests the need to think about long-term needs when deciding between options.

The implant at site #5 can reduce the need for a clasp, while at the same time providing a reasonably simple maintenance requirement for managing attachment needs. The implant attachment can be easily accommodated within a simple RPD framework that accommodates the #5 replacement tooth and available prosthetic space for attachment needs. Variable retention is available based on the type of attachment selected—an advantage over the use of a clasp, which carries the risk of fracture with repeated adjustment over time.

#### Strategically Lost Tooth and Implant Use

Loss of a canine or molar abutment in an existing removable prosthesis can have a significantly negative impact on the prosthesis. Resistance to movement toward the tissue and across the tissue (aspects of support and stability) is greatly affected. Previous interventions for strategic tooth loss, such as the Swing-Lock prosthesis, have been based on recognition of the need

to use more teeth to meet the demands for comfortable, stable function. Use of an implant in this situation can directly address the loss of a strategic component that controls functional movement and may be able to utilize the existing prosthesis.

**Use of Abutment for Support and/or Retention**

As an implant is placed more distally (in a distal extension), it serves more of a support function than a retention function. In a situation where support and retention are desired, the connecting design (the actual attachment male-female components) must allow adequate resistance to supporting forces without premature deformation of the retentive component and reduction of the retaining properties.

Generally, a component designed to primarily provide retention may not serve a supportive role for the desired period of time before replacement. Use of a more resistant retentive element to better resist supportive forces may provide retention in excess of the patient's ability to comfortably remove the prosthesis for daily hygiene.

**Influence of Opposing Occlusion on Implant Location and Implant Abutment Design**

Distal extension RPDs are significantly influenced by the type and plane of orientation of the opposing dentition. Opposing complete dentures, which exhibit a regular occlusal plane, encourage equal force distribution associated with occlusion, allowing an optimum scenario for comfort.

Irregular occlusal planes created by super-erupted opposing natural teeth make control of functional forces more challenging at the residual alveolar ridge level. Use of implants for such oral conditions may improve prosthesis comfort, especially if support is fully utilized (i.e., no retainer function). In such a scenario, implant abutment design should serve to control movement toward and across the denture bearing area. This places a premium on nonresilient and nonretentive abutment designs. Care should be taken to closely follow such designs during the early postinsertion phase because the potential for excessive occlusal loads could have detrimental effects on abutment connections and implant stability.

**TREATMENT PLANNING**

**Survey Considerations: Path of Insertion for Teeth and Implants**

Engagement of implant abutments requires consideration of the prosthesis path of insertion (POI). An implant placed coincident with the POI allows greater prosthetic flexibility in abutment selection and a more favorable RPD connection (Figure 12-2).

**Location Influenced by Anatomic and Opposing Occlusal Factors**

Implant use requires interocclusal space sufficient for prosthetic materials: denture base with framework minor

connector, attachment housing, and denture tooth. Therefore, the opposing occlusion should be evaluated preoperatively. This becomes even more critical when less residual ridge resorption occurs.

With excessive maxillary residual ridge resorption, the implant location may be more palatal/lingual, requiring consideration of the impact that such a location may have on palatal or lingual contours.

**Clasp Assembly Requirements if an Implant Is Used Adjacent to Tooth**

Engagement of an implant abutment to provide horizontal and vertical resistance supplements the resistance derived from tooth engagement. Consequently, less tooth coverage may be necessary for regions of the arch that have an implant.

If implant use is directed primarily to retention, tooth engagement for maximum resistance remains necessary to improve stability. If this is not achieved, deterioration in retention may be more rapid because of excessive forces directed to the retentive element, which could result in more rapid material deformation.

**CLINICAL EXAMPLES**

Figures 12-3 to 12-6 present clinical examples.

Primary use: Support

Figure 12-3: Kennedy Class I mandibular

Figure 12-4: Kennedy Class II

Combined use: Support and retention

Figure 12-5: Kennedy Class III

Figure 12-6: Kennedy Class II

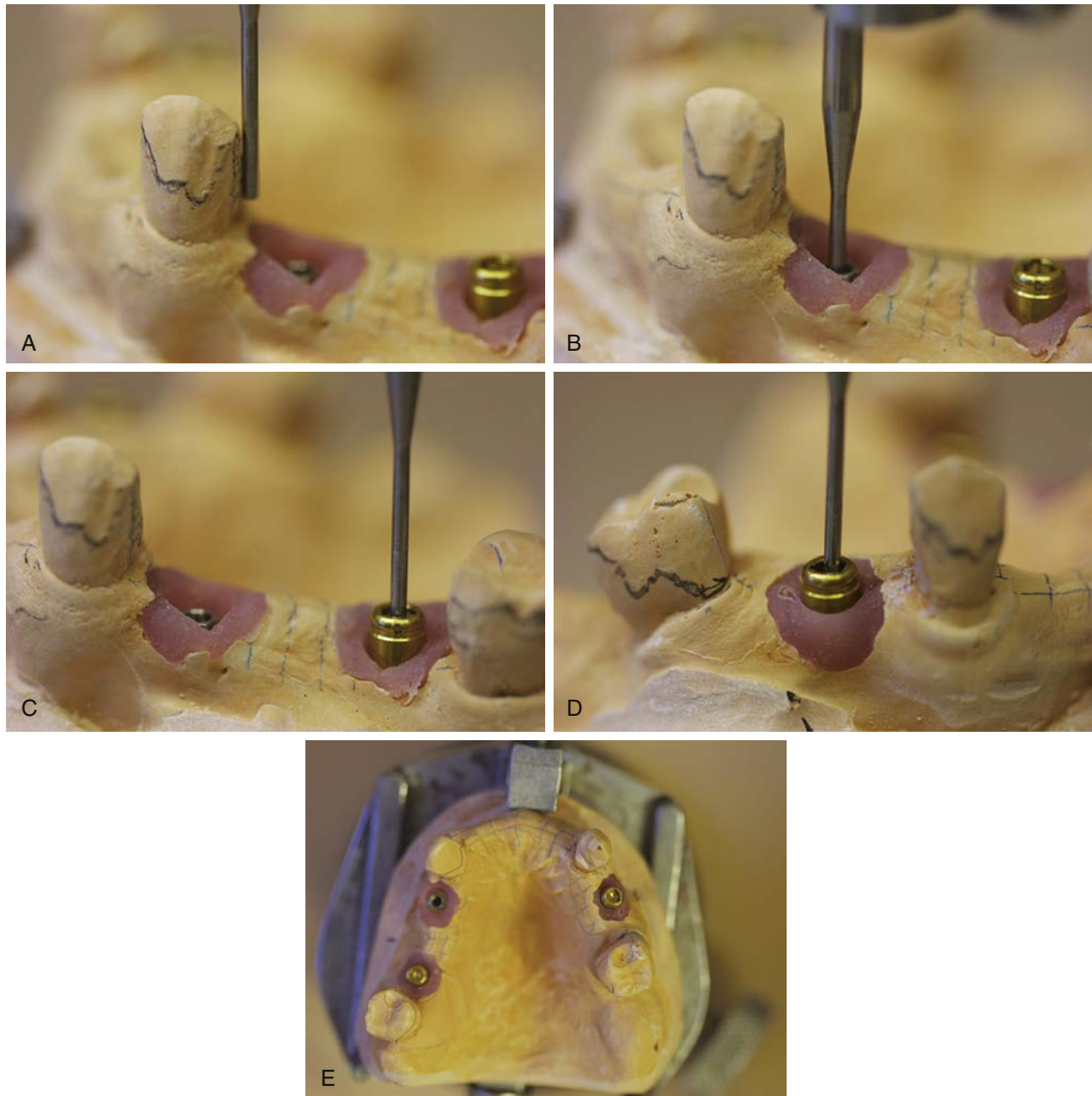
**SUMMARY**

RPDs are unique compared with prostheses supported by natural teeth. Their uniqueness largely relates to their potentially significant negative impact on oral sensory input during function, as well as on the prosthetic bulk required. Because of this, RPDs may present a challenge to accommodation, of which patients should be made aware during the treatment planning stage.

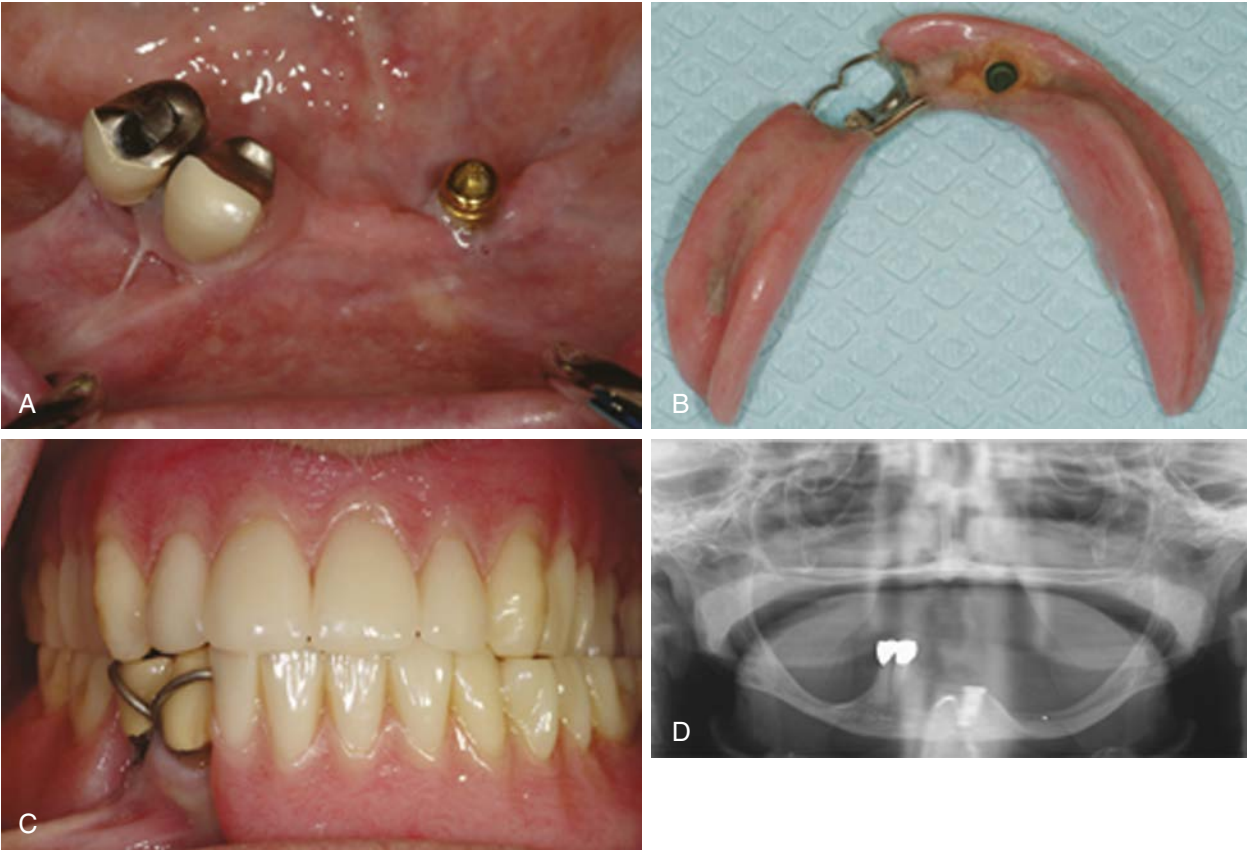Patient sensory perception and neuromuscular variability may influence prosthesis selection. The sensory deficit associated with tooth loss can be complicated by unstable prostheses; for challenging RPDs, the use of implants can significantly contribute to stability.

**ACKNOWLEDGMENT**

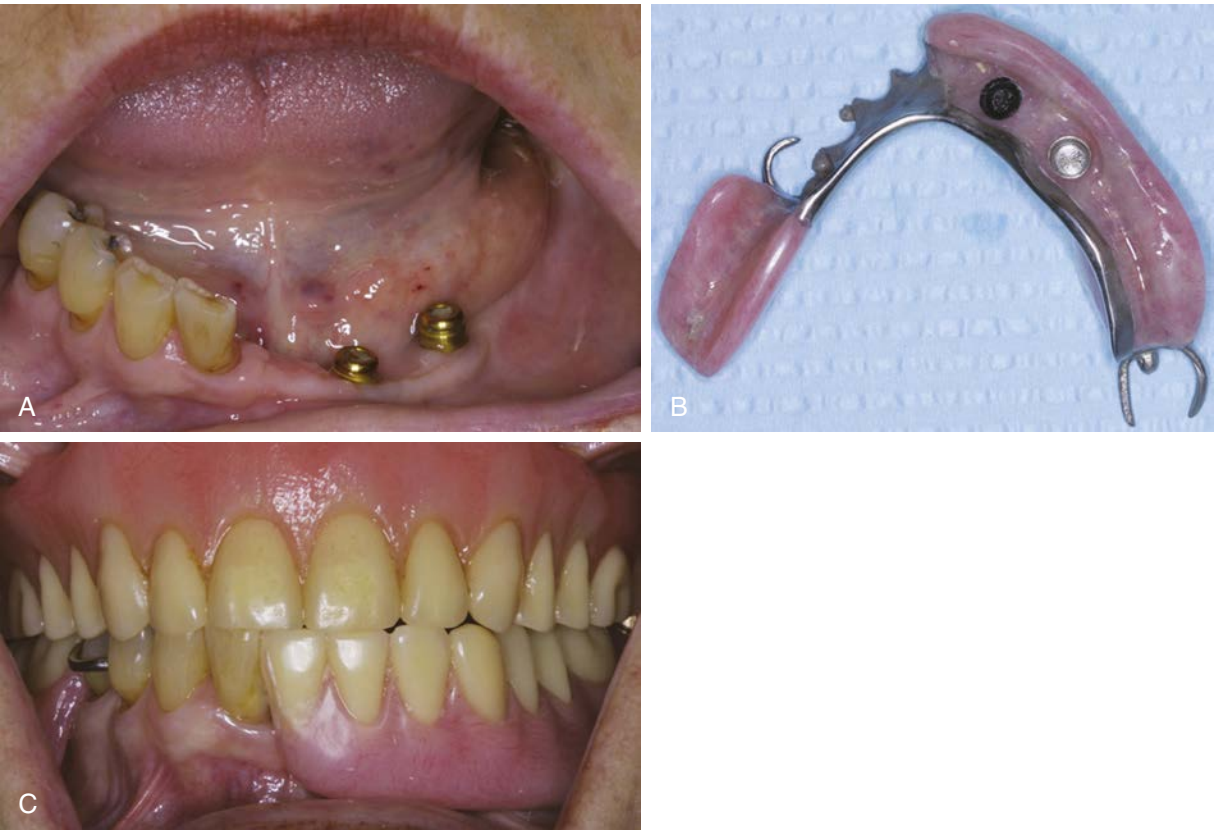The authors would like to acknowledge Dr. Tom Salinas for his helpful input during the writing of this chapter.



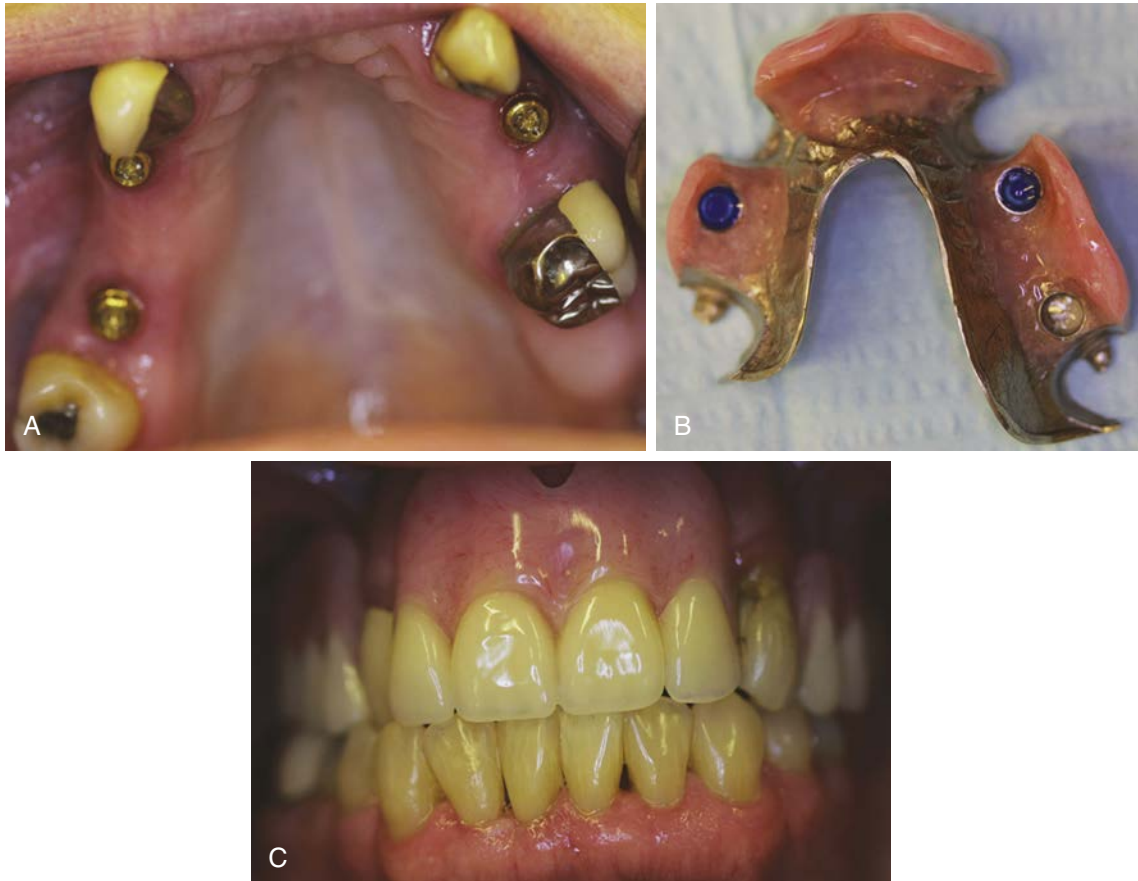
**FIGURE 12-2** Parallel path of insertion established with tooth guide planes (distal of the canines and mesial of the molar) and adjacent implants.



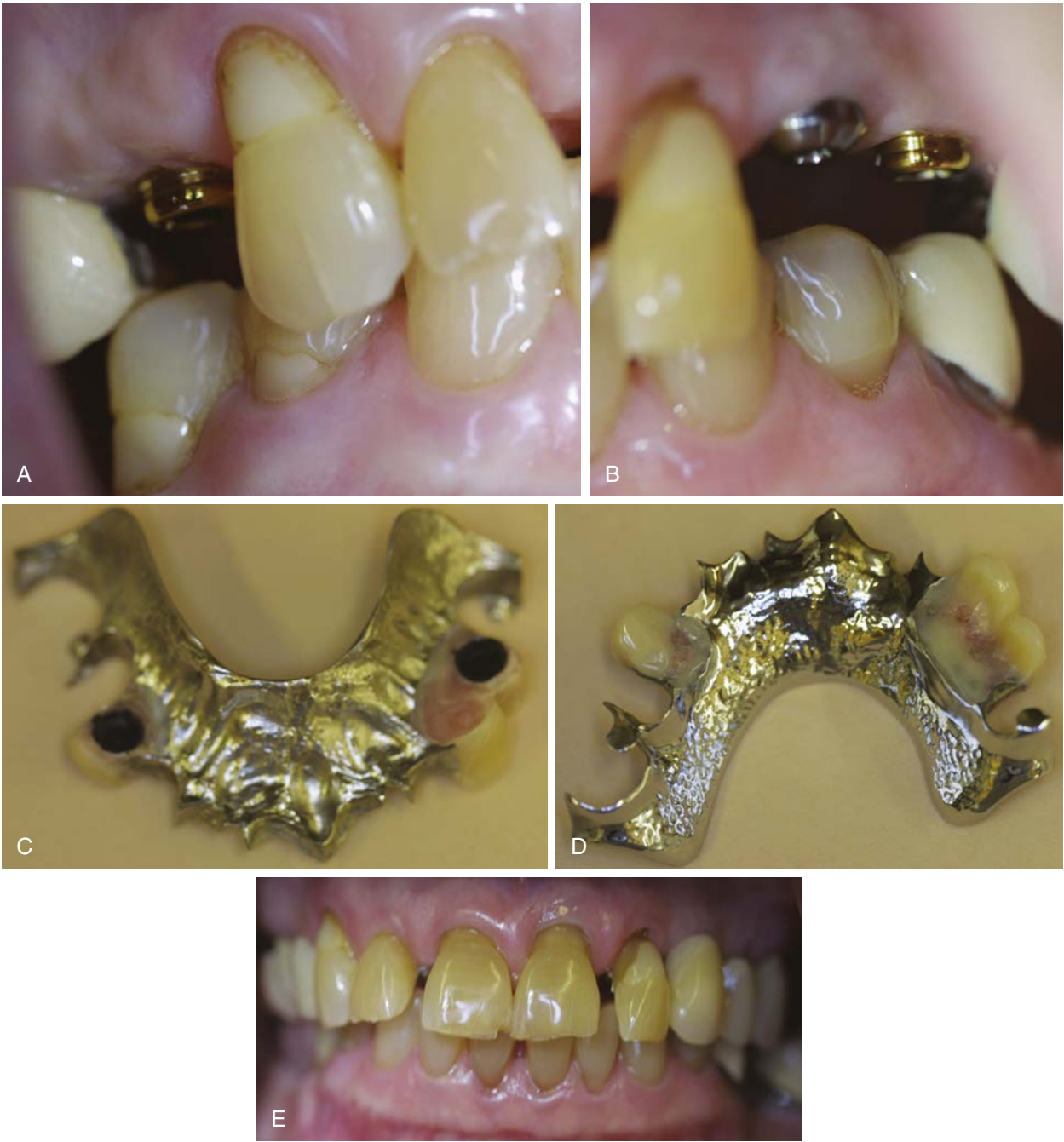**FIGURE 12-3** Significant residual ridge resorption with a strategically missing tooth #22. The implant provided sufficient support to improve functional comfort and occlusal function.



**FIGURE 12-4** A long span modification space across the mandibular midline. The implant provided support and retention improved function and comfort while reducing functional stress on the mandibular incisors.



**FIGURE 12-5** Support provided by the cingulum and mesial-occlusal rests of the teeth and by the implant at site #3. Implants at sites #5 and #12 provide retention. Guide-plane surfaces augment implants for sufficient retention without clasps.



**FIGURE 12-6** An implant-assisted Class III removable partial denture (RPD) with minimum interocclusal space in an elderly patient desiring no prosthesis clasps. Denture teeth were shaped and positioned for optimum esthetics, allowing creation of occlusal contours by acrylic-resin, attaching the teeth to the frame and attachment housings.

P A R T



# CLINICAL AND LABORATORY



# CHAPTER

# 13

## Diagnosis and Treatment Planning

### CHAPTER OUTLINE

Purpose and Uniqueness of Treatment

Patient Interview

Shared Decision Making

Clinical Examination

Objectives of Prosthodontic Treatment

Oral Examination

Sequence of Oral Examination

Diagnostic Casts

Purposes of Diagnostic Casts

Mounting Diagnostic Casts

Sequence for Mounting Maxillary Cast to

Axis-Orbital Plane

Jaw Relationship Records for Diagnostic Casts

Materials and Methods for Recording

Centric Relation

Diagnostic Findings

Interpretation of Examination Data

Radiographic Interpretation

Periodontal Considerations

Caries Risk Assessment Considerations

Evaluation of the Prosthesis Foundation—Teeth  
and Residual Ridge

Surgical Preparation

Analysis of Occlusal Factors

Fixed Restorations

Orthodontic Treatment

Need for Determining Type of Mandibular

Major Connector

Need for Reshaping Remaining Teeth

Infection Control

Differential Diagnosis: Fixed or Removable Partial  
Dentures

Indications for Use of Fixed Restorations

Indications for Removable Partial Dentures

Choice Between Complete Dentures and Removable  
Partial Dentures

Clinical Factors Related to Metal Alloys used for  
Removable Partial Denture Frameworks

Comparative Physical Properties of Gold and  
Chromium-Cobalt

Wrought Wire: Selection and Quality Control

Summary

### PURPOSE AND UNIQUENESS OF TREATMENT

The purpose of dental treatment is to respond to a patient's needs, both the needs perceived by the patient and those demonstrated through a clinical examination and patient interview. Although similarities have been noted between partially edentulous patients (such as classification designations), significant differences exist, making each patient, and the ultimate treatment, unique.

The delineation of each patient's uniqueness occurs through the patient interview and diagnostic clinical examination process. This includes four distinct processes: (1) understanding the patient's desires or chief concerns/complaints regarding his or her condition (including its history) through a systematic interview process; (2) ascertaining the patient's dental needs through a diagnostic clinical examination; (3) developing a treatment plan that reflects the best management of desires and needs (with influences unique to the medical condition or oral environment); and (4) executing appropriately sequenced treatment with planned follow-up. The ultimate treatment is individualized to address disease management and the coordinated restorative and prosthetic needs that are unique to the patient. Provision of the best care for a patient may involve no treatment, limited treatment, or extensive treatment, and the dentist must be prepared to help patients decide the best treatment option given his or her individual circumstances.

### PATIENT INTERVIEW

Although oral health is an important aspect of overall health, it is an elective health pursuit for most individuals.

Consequently, the patient presents for professional evaluation (1) to address some perception of an abnormality that requires correction; or (2) to maintain optimum oral health. In either situation, but especially for the patient presenting with some chief complaint (often with an important history related to that complaint), it is mandatory that the dentist clearly understand what brings the patient to this evaluation. Failure to do so leads to the chance that the patient will be unhappy with the treatment result, because it might not address the very reason he or she came for help. With experience, this subtle point becomes a major component of a clinician's management focus.

A fundamental objective of the patient interview, which accompanies the diagnostic examination, is to gain a clear understanding of why the patient is presenting for evaluation; this involves having the patient describe the history related to the chief complaint. For complicated clinical problems, the interview and diagnostic examination require two appointments to allow complete gathering of all diagnostic information needed to formulate a complete plan of treatment.

The interview, an opportunity to develop rapport with the patient, involves listening to and understanding the patient's chief complaint or concern about his or her oral health. This can include clinical symptoms of pain (provoked or unprovoked), difficulty with function, concern about appearance, problems with an existing prosthesis, or any combination of symptoms related to the teeth, periodontium, jaws, or previous dental treatment. It is important to listen carefully to what the patient has stated is the reason for presenting for evaluation; this is because all subsequent information gathered will be used to discuss these concerns and to relate whether the proposed treatment will affect the patient in any way. Such a discussion at the outset of patient care helps to outline realistic expectations.

Although formats for sequencing the patient interview (and clinical examination) vary, to ensure thoroughness the dentist should follow a sequence that includes:

1. Chief complaint and its history
2. Medical history review
3. Dental history review, especially related to previous prosthetic experience(s)
4. Patient expectations

It is from the aforementioned interaction that patient uniqueness, as mentioned earlier, is best defined. The expectations described by the patient are critical to an understanding of whether a removable partial denture will satisfy the stated treatment goal(s). The fact that removable partial dentures by necessity require material bulk and often use oral soft tissues for support may be hard to comprehend by patients with no such prosthetic history. Helping the patient understand the normal phase of accommodation to such a prosthesis is an important discussion point in selection of a prosthesis. For those patients with a negative past prosthesis experience, it is necessary to determine before treatment is started whether the design, fit, occlusion, or lack of maintenance of the prosthesis can be improved to provide a more positive experience.

## SHARED DECISION MAKING

When helping patients understand their oral health status, comprising both disease and deficit considerations, and the means to address both, we should carefully consider what it is they need to hear from us. For most partially edentulous patients, the discussion may involve fairly complex rehabilitation options for addressing their missing teeth. Because of this complexity, our responsibility is to help them sort through the options in an attempt to help them come to the best decision for them. Using a communication model termed *shared decision making* gives structure to a process where the provider and the patient identify together the best course of care. This process recognizes that there may be complex "trade-offs" in care choice, and it addresses the need to fully inform patients about risks and benefits of care options, as well as ensuring that patient values and preferences play a prominent role in the process. Although it is clear that not all patients desire to participate equally in care decisions, because the options can vary significantly (some are more invasive, have greater risks, are accompanied by higher treatment burden than others; there are often varying maintenance needs between options), we should actively engage them in the process. This is more important given the fact that the tooth replacement is often an elective pursuit, and because of this, there is seldom great urgency involved in making a decision.

## CLINICAL EXAMINATION

### OBJECTIVES OF PROSTHODONTIC TREATMENT

The objectives of any prosthodontic treatment may be stated as follows: (1) the elimination of disease; (2) the preservation, restoration, and maintenance of the health of the remaining teeth and oral tissues (which will enhance the removable partial denture design); and (3) the selected replacement of lost teeth for the purpose of (4) restoration of function in a manner that ensures optimum stability and comfort in an esthetically pleasing manner. Preservation is a principle that protects from decisions that place too high a premium on cosmetic concerns, and it is the dentist's obligation to emphasize the importance of restoring the total mouth to a state of health and of preserving the remaining teeth and surrounding tissues.

Diagnosis and treatment planning for oral rehabilitation of partially edentulous mouths must take into consideration the following: control of caries and periodontal disease, restoration of individual teeth, provision of harmonious occlusal relationships, and the replacement of missing teeth by fixed (using natural teeth and/or implants) or removable prostheses. Because these procedures are integrally related, the appropriate selection and sequencing of treatment should precede all irreversible procedures.

The treatment plan for the removable partial denture, which is often the final step in a lengthy sequence of treatment, should precede all but emergency treatment. This allows abutment teeth and other areas in the mouth to be

properly prepared to support, stabilize, and retain the removable partial denture. This means that diagnostic casts, for designing and planning removable partial denture treatment, must be made before definitive treatment is undertaken. After the major factors that create functional forces are evaluated and those that resist it are understood, the removable partial denture design is drawn on the diagnostic cast, along with a detailed chart of mouth conditions and proposed treatment. This becomes the master plan for the mouth preparations and the design of the removable partial denture to follow.

As pointed out in Chapter 1, failure of removable partial dentures can usually be attributed to factors that result in poor stability. These can result from inadequate diagnosis and failure to properly evaluate the conditions present. This results in failure to prepare the patient and the oral tissues properly before the master cast is fabricated. The importance of the examination, the consideration of favorable and unfavorable aspects relative to movement control, and the importance of planning the elimination of unfavorable influences cannot be overemphasized (see Chapter 2).

As mentioned earlier, for complex treatment, two appointments are often required. The first will likely include a preliminary oral examination (to determine the need for management of acute needs), a prophylaxis, full-mouth radiographs, diagnostic casts, and mounting records if baseplates are not required. The follow-up appointment includes mounting of the diagnostic casts (when baseplates and occlusion rims are needed), a definitive oral examination, review of the radiographs to augment and correlate with clinical findings, and arrangement of additional consultations when required. Following collection and synthesis of all patient and clinical information, including surveying of the casts, a treatment plan (often with options) is presented.

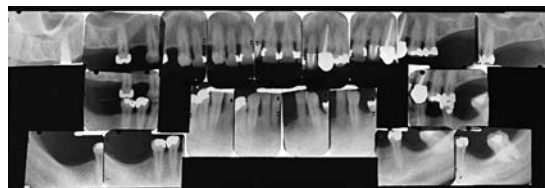
## ORAL EXAMINATION

A complete oral examination should precede any treatment decisions. It should include visual and digital examination of the teeth and surrounding tissues with a mouth mirror, explorer, and periodontal probe, vitality tests of critical teeth, and examination of casts correctly oriented on a suitable articulator. Clinical findings are augmented by and correlated with a complete intraoral radiographic survey.

During the examination, the objective to be kept foremost in mind should be the consideration of possibilities for restoring and maintaining the remaining oral structures in a state of health for the longest period of time. This is best accomplished by an evaluation of factors that generate functional forces and those that resist them. The stability of tooth and prosthesis position is the goal of such an evaluation. The following sequence of examination allows attention to be paid to aspects of each of these critical features of evaluation for removable partial denture service.

### Sequence of Oral Examination

An oral examination should be accomplished in the following sequence: visual examination, pain relief and temporary



**FIGURE 13-1** Complete intraoral radiographic survey of remaining teeth and adjacent edentulous areas reveals much information vital to effective diagnosis and treatment planning. The response of bone to previous stress is of particular value in establishing the prognosis of teeth that are to be used as abutments.

restorations, radiographs, oral prophylaxis, evaluation of teeth and periodontium, vitality tests of individual teeth, determination of the floor of the mouth position, and impressions of each arch.

1. *Relief of pain and discomfort and caries control by placement of temporary restorations.* A preliminary examination is conducted to determine the need for management of acute needs and whether a prophylaxis is required to conduct a thorough oral examination. It is advisable not only to relieve discomfort arising from tooth defects but also to determine as early as possible the extent of caries, and to arrest further caries activity until definitive treatment can be instituted. If tooth contours are restored with temporary restorations, the impression will not be torn on removal from the mouth, and a more accurate diagnostic cast may be obtained.
2. *A thorough and complete oral prophylaxis.* An adequate examination can be accomplished best with the teeth free of accumulated calculus and debris. Also, accurate diagnostic casts of the dental arches can be obtained only if the teeth are clean; otherwise the teeth reproduced on the diagnostic casts are not a true representation of tooth and gingival contours. cursory examination may precede an oral prophylaxis, but a complete oral examination should be deferred until the teeth have been thoroughly cleaned.
3. *Complete intraoral radiographic survey* (Figure 13-1). The objectives of a radiographic examination are (a) to locate areas of infection and other pathosis that may be present; (b) to reveal the presence of root fragments, foreign objects, bone spicules, and irregular ridge formations; (c) to reveal the presence and extent of caries and the relation of carious lesions to the pulp and periodontal attachment; (d) to permit evaluation of existing restorations as to evidence of recurrent caries, marginal leakage, and overhanging gingival margins; (e) to reveal the presence of root canal fillings and to permit their evaluation as to future prognosis (the design of the removable partial denture may hinge on the decision to retain or extract an endodontically treated tooth); (f) to permit evaluation of periodontal conditions present and to establish the need and possibilities for treatment; and (g) to evaluate the alveolar support of abutment teeth, their number, the supporting length and morphology of their roots, the relative amount of alveolar bone loss suffered through pathogenic processes, and the amount of alveolar support remaining.

REMOVABLE PARTIAL PROSTHODONTICS

PATIENT NAME

PATIENT NUMBER

TREATMENT PLAN

LABORATORY INSTRUCTIONS

DESIGN SPECIFICATIONS:

1. RESTS

2. RETENTION

3. RECIPROCATION

4. MAJOR CONNECTOR

5. INDIRECT RETENTION

6. GUIDE PLANES

7. BASE RETENTION

8. AREAS TO BE MODIFIED OR CONTOURED

R

L

1

2

3

4

5

6

7

8

9

10

11

12

13

14

15

16

32

31

30

29

28

27

26

25

24

23

22

21

20

19

18

17

COLOR CODE:

BLUE:--- CAST METAL

RED:--- RESIN BASE AND WROUGHT WIRE

GREEN:-- AREAS TO BE CONTOURED

INSTRUCTOR:

APPROVAL TO SEND TO LABORATORY:

DATE:

A

FIGURE 13-2 A, Diagnosis record for recording pertinent data.

4. Impressions for making accurate diagnostic casts to be mounted for occlusal examination. The casts preferably will be articulated on a suitable instrument. The importance of accurate diagnostic casts and their use will be discussed later in this chapter.

5. Examination of teeth, investing structures, and residual ridges. The teeth, periodontium, and residual ridges can be explored by instrumentation and visual means. Recording of relevant patient history and clinical data on diagnosis charts is important to document features important to clinical presentation. These can be recorded on electronic or paper charts for future reference (Figures 13-2 and 13-3).

Visual examination will reveal many of the signs of dental disease. Consideration of caries susceptibility is of

primary importance. The number of restored teeth present, signs of recurrent caries, and evidence of decalcification should be noted. Only those patients with demonstrated good oral hygiene habits and low caries susceptibility should be considered good risks without resorting to prophylactic measures, such as the restoration of abutment teeth. At the time of the initial examination, periodontal disease, gingival inflammation, the degree of gingival recession, and mucogingival relationships should be observed. Such an examination will not provide sufficient information to allow a definitive diagnosis and treatment plan. For this purpose, complete periodontal charting that includes pocket depths, assessment of attachment levels, furcation involvement, mucogingival problems, and tooth mobility should be performed. The extent of periodontal destruction

Telegram: @uni\_k

PATIENT'S NAME John DoeCHART NO. 383838

STUDENT'S NAME Joe SmithJR. ☒SR. \_\_\_\_\_STUDENT NO. 1234

STARTING DATE 1/14/99INSTRUCTOR SIGNATURE PGreen

COMPLETION DATE \_\_\_\_\_INSTRUCTOR SIGNATURE \_\_\_\_\_

REMOVABLE PARTIAL DENTURE

MAX RPD    MAND. RPD

DIAGNOSIS

1. Are you wearing or have you worn an oral prosthesis? No \_\_\_\_\_ Yes ☒. If so, what type? metal + plastic

2. If a previously worn prosthesis was not entirely satisfactory, what in your opinion were the problems with it? no retention, + teeth badly worn

3. What was the cause of loss of the natural teeth? Perio ☒, Caries ☒, Trauma \_\_\_\_\_

INTRAORAL FINDINGS

1. Oral hygiene Index: Good ☒ Fair \_\_\_\_\_ 2. Caries Index: High \_\_\_\_\_ Moderate \_\_\_\_\_ Low ☒

3. Do centric occlusion and centric relation coincide? Yes ☒ No \_\_\_\_\_

4. Are there frenula or muscle attachments that might interfere with maximum fit and comfort? Yes \_\_\_\_\_ No ☒

5. Is type and quality of saliva normal? Yes ☒ No \_\_\_\_\_ Comments \_\_\_\_\_

6. Examine the following areas for possible interference with optimal fit and comfort.

Mylohyoid Ridge Normal ☒ Other: \_\_\_\_\_Alveolar Ridges Tissues Normal ☒

Tuberosity Normal ☒ Other: \_\_\_\_\_Supporting Alveolar Bone Normal ☒

Tori Present Yes \_\_\_\_\_ No ☒

7. Is any surgical procedure indicated to improve the prognosis? No ☒ Note \_\_\_\_\_

DIAGNOSTIC CAST ANALYSIS

On the Articulator

1. Is there adequate interridge space for the contemplated prosthesis? Yes ☒ No \_\_\_\_\_

2. Is the occlusal plane retrievable? Yes ☒ Doubtful \_\_\_\_\_

3. Is there adequate inter-occlusal space for contemplated rest seats and rests where they will be needed? Yes ☒ Note \_\_\_\_\_

4. Are there anomalies which were not evident intra-orally? No ☒ Note \_\_\_\_\_

On The Surveyor

1. Which teeth are the most suitable abutments? Abutment #1 20 Abutment #2 28 Abutment #3 \_\_\_\_\_ Abutment #4 \_\_\_\_\_ Other: \_\_\_\_\_

2. Do the abutments have adequate retentive undercuts in a favorable location on the tooth? Yes ☒ No \_\_\_\_\_

3. Can suitable guiding planes be developed on the probable abutments? Yes ☒ No \_\_\_\_\_

4. Will tooth alterations be required? No \_\_\_\_\_ Yes ☒

RADIOGRAPHIC INTERPRETATION

1. What is the crown root ratio of each abutment? Abutment #1 1:3 Abutment #2 1:3 Abutment #3 \_\_\_\_\_ Abutment #4 \_\_\_\_\_

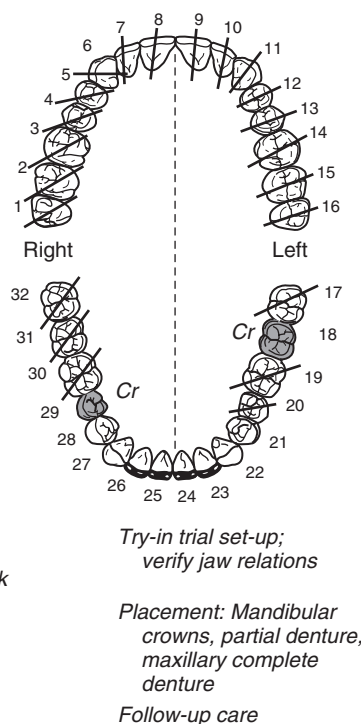
2. Does the supporting bone appear to be of good quality? Yes ☒ No \_\_\_\_\_

QUALITY PRESS, INC.

B

FIGURE 13-2, CONT'D    B, Treatment record chart for recording treatment plan and treatment progress.

Telegram: @uni\_k

Name: *John Doe*Date: *July 1, 1999***Summary Plan:***Maxillary Conventional Complete denture**Mandibular Class II mod. 1 removable partial denture**Porcelain fused to metal abutment Crowns #18, #29***Procedures:***Tissue conditioning maxillary arch**Primary impression-both arches; make impression trays**Preparations. Contour and rest seats #21, #28. Abutment crown preparations #18, #29**Try-in abutment crowns; pick-up for cast for framework casting**Try-in abutment crowns and framework**Fluid wax functional impression: Make altered cast**Jaw relation records; shade and mold selection**Tooth arrangement**Red line each completed unit*

**FIGURE 13-3** Simple Working Chart. Restorations for individual teeth, crowns, and fixed partial dentures to be made may be marked on the chart and checked off as completed during mouth preparations.

must be determined with appropriate radiographs and use of the periodontal probe.

The number of teeth remaining, the location of the edentulous areas, and the quality of the residual ridge will have a definite bearing on the proportionate amount of support that the removable partial denture will receive from the teeth and edentulous ridges. Tissue contours may appear to present a well-formed edentulous residual ridge; however, palpation often indicates that supporting bone has been resorbed and has been replaced by displaceable, fibrous connective tissue. Such a situation is common in maxillary tuberosity regions. The removable partial denture cannot be supported adequately by tissues that are easily displaced. When the mouth is prepared, this tissue should be recontoured or removed surgically, unless otherwise contraindicated. A small but stable residual ridge is preferable to a larger unstable ridge for providing support for the denture. The presence of tori or other bony exostoses must be detected and their presence in relation to framework design must be evaluated. Failure to palpate the tissue over the median palatal raphe to ascertain the difference in its displaceability as compared with the displaceability of the soft tissues covering the residual ridges can lead to a

rocking, unstable, uncomfortable denture and to an unsatisfied patient. Adequate relief of the palatal major connectors must be planned, and the amount of relief required is directly proportionate to the difference in displaceability of the tissues over the midline of the palate and the tissues covering the residual ridges.

During the examination, not only each arch but also its occlusal relationship with the opposing arch must be considered separately. A situation that looks simple when the teeth are apart may be complicated when the teeth are in occlusion. For example, an extreme vertical overlap may complicate the attachment of anterior teeth to a maxillary denture. Extrusion of a tooth or teeth into an opposing edentulous area may complicate the replacement of teeth in the edentulous area or may create occlusal interference, which will complicate the location and design of clasp retainers and occlusal rests. Such findings subsequently will be evaluated further by careful analysis of mounted diagnostic casts.

A breakdown of the fee may be recorded on the back of this chart for easy reference if adjustments or substitutions become necessary because of changes in diagnosis as the work progresses.

6. *Vitality tests of remaining teeth.* Vitality tests should be given particularly to teeth to be used as abutments and those having deep restorations or deep carious lesions. This should be done through both thermal and electronic means.
7. *Determination of the height of the floor of the mouth to locate inferior borders of lingual mandibular major connectors.* Mouth preparation procedures are influenced by the choice of major connectors (see Figure 5-6). This determination must precede altering contours of abutment teeth.

The fee for examination, which should include the cost of the radiographic survey and the examination of articulated diagnostic casts, should be established before the examination is performed and should not be related to the cost of treatment. It should be understood that the fee for examination is based on the time involved and the service rendered, and that the material value of the radiograph and diagnostic casts is incidental to the effectiveness of the examination.

The examination record should always be available in the office for future consultation. If consultation with another dentist is requested, respect for the hazards of unnecessary radiation justifies loaning the dentist the radiograph for this purpose. However, duplicate films should be retained in the dentist's files.

## DIAGNOSTIC CASTS

A diagnostic cast should be an accurate reproduction of all the potential features that aid diagnosis. These include the teeth locations, contours, and occlusal plane relationship; the residual ridge contour, size, and mucosal consistency; and the oral anatomy delineating the prosthesis extensions (vestibules, retromolar pads, pterygomaxillary notch, hard/soft palatal junction, floor of the mouth, and frena). Additional information provided by appropriate cast mounting includes occlusal plane orientation and the impact on the opposing arch, tooth-to-palatal soft tissue relationship, and tooth-to-ridge relationships both vertically and horizontally.

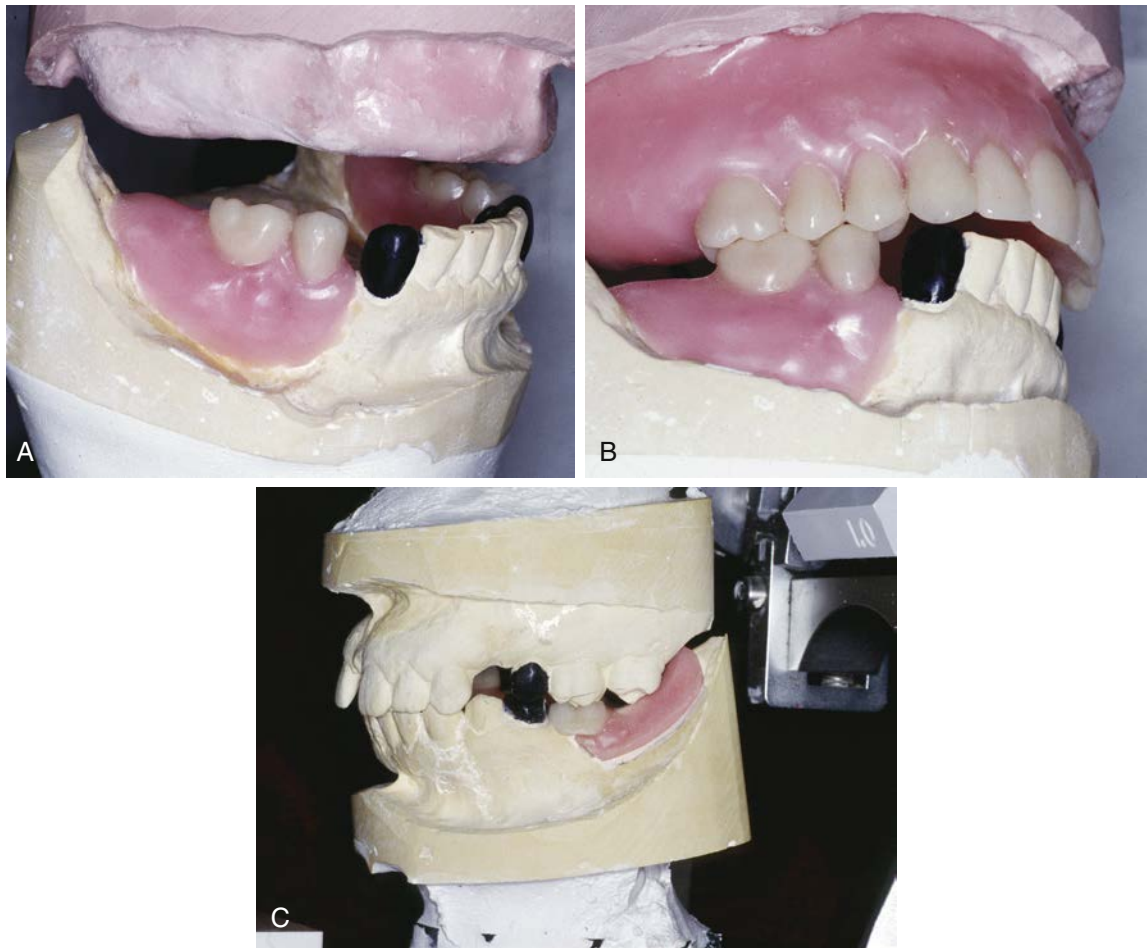
A diagnostic cast is usually made of dental stone because of its strength and the fact that it is less easily abraded than is dental plaster. Generally the improved dental stones (die stones) are not used for diagnostic casts because of their cost. Their greater resistance to abrasion does, however, justify their use for master casts.

The impression for the diagnostic cast is usually made with an irreversible hydrocolloid (alginate) in a stock (perforated or rim lock) impression tray. The size of the arch will determine the size of the tray to be used. The tray should be sufficiently oversized to ensure an optimum thickness of impression material to avoid distortion or tearing on removal from the mouth. The technique for making impressions is covered in more detail in Chapter 16.

## Purposes of Diagnostic Casts

Diagnostic casts serve several purposes as an aid to diagnosis and treatment planning. Some of these are as follows:

1. Diagnostic casts are used to supplement the oral examination by permitting a view of the occlusion from the lingual, as well as from the buccal, aspect. Analysis of the existing occlusion is made possible when opposing casts are occluded, as is a study of the possibilities for improvement by occlusal adjustment, occlusal reconstruction, or both. The degree of overclosure, the amount of interocclusal space available, and the possibilities of interference with the location of rests may also be determined. As stated previously, opportunities for improvement of the occlusal scheme, by occlusal adjustment or occlusal reconstruction, are best evaluated by analysis and modification of mounted diagnostic casts. Such procedures often include diagnostic waxing to determine the possibility of enhancing the occlusion before definitive treatment is begun (Figure 13-4). In other words, diagnostic casts permit the dentist to plan ahead to avoid undesirable compromises in the treatment being given a patient.
2. Diagnostic casts are used to permit a topographic survey of the dental arch that is to be restored by means of a removable partial denture. The cast of the arch in question may be surveyed individually with a cast surveyor to determine the parallelism or lack of parallelism of tooth surfaces involved and to establish their influence on the design of the removable partial denture. The principal considerations in studying the parallelism of tooth and tissue surfaces of each dental arch are to determine the need for mouth preparation: (a) proximal tooth surfaces, which can be made parallel to serve as guiding planes; (b) retentive and nonretentive areas of the abutment teeth; (c) areas of interference with placement and removal; and (d) esthetic effects of the selected path of insertion. From such a survey, a path of placement may be selected that will satisfy requirements for parallelism and retention to the best mechanical, functional, and esthetic advantage. Then mouth preparations may be planned accordingly.
3. Diagnostic casts are used to permit a logical and comprehensive presentation to the patient of present and future restorative needs, as well as of the hazards of future neglect. Occluded and individual diagnostic casts can be used to point out to the patient (a) evidence of tooth migration and the existing results of such migration; (b) effects of further tooth migration; (c) loss of occlusal support and its consequences; (d) hazards of traumatic occlusal contacts; and (e) cariogenic and periodontal implications of further neglect. Treatment planning actually may be accomplished with the patient present so that economic considerations may be discussed. Such use of diagnostic casts permits justification of the proposed fee through the patient's understanding of the problems involved and of the treatment needed. Inasmuch as mouth rehabilitation



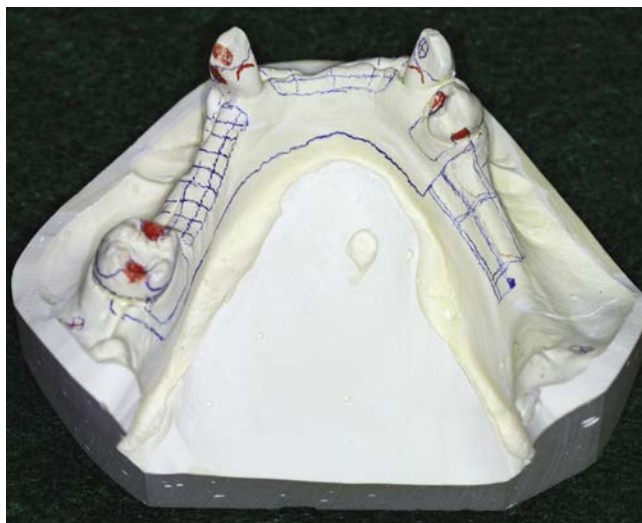
**FIGURE 13-4** **A**, Following mounting of the diagnostic casts, tooth arrangement for the mandibular occlusal plane requirements can be accomplished. **B**, Following placement of the maxillary anterior teeth in an ideal position, diagnostic arrangement of occlusion results in a space posterior to surveyed crown #27. If such a finding were objectionable, alternative arrangements could be investigated. This is not possible unless a diagnostic workup is completed. **C**, Occlusion of the mandibular removable partial denture will be enhanced by improving the maxillary posterior occlusal plane of the super-erupted molars.

procedures are frequently lengthy and often irreversible, there must be complete accord between dentist and patient before extensive treatment is begun, and financial arrangements must be consummated during the planning phase.

4. Individual impression trays may be fabricated on the diagnostic casts, or the diagnostic cast may be used in selecting and fitting a stock impression tray for the final impression. If wax blockout is to be used in the fabrication of individual trays, a duplicate cast made from an irreversible hydrocolloid (alginate) impression of the diagnostic cast should be used for this purpose. The diagnostic cast is too valuable for purposes of future reference to risk damage resulting from the making of an impression tray. On the other hand, if oil-based clay blockout is used, the diagnostic cast may be used without fear of damage.
5. Diagnostic casts may be used as a constant reference as the work progresses. Penciled marks indicating the type of restoration, the areas of tooth surfaces to be modified, the location of rests, and the design of the removable partial

denture framework, as well as the path of placement and removal, all may be recorded on the diagnostic cast for future reference (Figure 13-5). Then these steps may be checked off the worksheet as they are completed. Areas of abutment teeth to be modified may first be changed on the duplicate diagnostic cast by trimming the stone cast with the surveyor blade. A record is thus made of the location and degree of modification to be done in the mouth. This must be done in relation to a definite path of placement. Any mouth preparations to be accomplished with new restorations require that restored teeth be shaped in accordance with a previously determined path of placement. Even so, the shaping of abutment teeth on the duplicate diagnostic cast serves as a guide to the form of the abutment. This is particularly true if the contouring of wax patterns is to be delegated to the technician, as it may be in a busy practice.

6. Unaltered diagnostic casts should become a permanent part of the patient's record because records of conditions



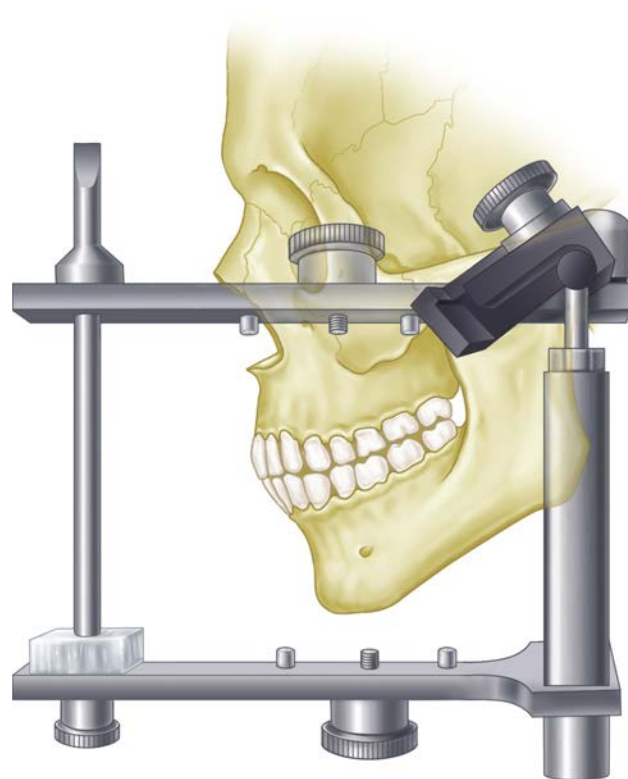
**FIGURE 13-5** Proposed mouth changes and design of the removable partial denture framework are indicated in pencil on the diagnostic cast in relation to the previously determined path of placement. This serves as a means of communicating with the patient and as a chair-side guide to tooth modification.

existing before treatment are just as important as preoperative radiographs. Therefore diagnostic casts should be duplicated, with one cast serving as a permanent record and the duplicate cast used in situations that may require alterations to it.

### Mounting Diagnostic Casts

For diagnostic purposes, casts should be related on an anatomically appropriate articulator to best understand the role occlusion may have in the design and functional stability of the removable partial denture. This becomes increasingly important as the prosthesis replaces more teeth. If the patient presents with a harmonious occlusion and the edentulous span is a tooth-bound space, simple hand articulation is generally all that is required. However, when the natural dentition is not harmonious and/or when the replacement teeth must be positioned within the normal movement patterns of the jaws, the diagnostic casts must be related in an anatomically appropriate manner for diagnosis. This means placement of the maxillary cast in a position relative to the opening axis on the articulator, which is similar to the position of the maxilla in relation to the temporomandibular joint (TMJ) of the patient (Figure 13-6). The mandibular cast is then placed beneath the maxillary cast in a horizontal position dictated by mandibular rotation without tooth contact, at a minimal vertical opening.

*The Glossary of Prosthodontic Terms\** describes an articulator as a mechanical device that represents the TMJs and



**FIGURE 13-6** Use of the facebow makes possible the recording of the spatial relationship of the maxillae to some anatomic reference points and transference of this relationship to an articulator.

jaw members to which maxillary and mandibular casts may be attached. Because the dominant influence on mandibular movement in a partially edentulous mouth is the occlusal plane and the cusps of the remaining teeth, an anatomic reproduction of condylar paths is probably not necessary. Still, movement of the casts in relation to one another as influenced by the occlusal plane and the cusps of the remaining teeth, when mounted at a reasonably accurate distance from the axis of condylar rotation, permits a relatively valid analysis of occlusal relations. This is more anatomically accurate than a simple hinge mounting.

It is better that the casts be mounted in relation to the axis-orbital plane to permit better interpretation of the plane of occlusion in relation to the horizontal plane. Although it is true that an axis-orbital mounting has no functional value on a nonarcon instrument because that plane ceases to exist when opposing casts are separated, the value of such a mounting lies in the orientation of the casts in occlusion. (An arcon articulator is one in which the condyles are attached to the lower member as they are in nature, the term being a derivation coined by Bergström from the words *articulation* and *condyle*. Many of the more widely used articulators such as the Hanau model H series, Dentatus, and improved Gysi have the condyles attached to the upper member and are therefore nonarcon instruments.)

\*The Glossary of Prosthodontic Terms, *J Prosthet Dent*. 94(1):10-92, 2005. Available at: <http://dx.doi.org/10.1016/j.prosdent.2005.03.013>

### Sequence for Mounting Maxillary Cast to Axis-Orbital Plane

The initial steps allow recording of the maxilla-TMJ relationship:

1. Identify the anterior and posterior reference points for the facebow (e.g., external auditory meatus, orbitale).
2. Prepare the bite fork and occlusion rim.
3. Place the bite fork centered to the arch, indexing it to the teeth with wax or elastomer.
4. Place the facebow over the bite fork rod anteriorly.
5. Place the bow evenly into the ears posteriorly.
6. Secure the bow anteriorly.
7. Position the bow anteriorly to the third point of reference (establishes the horizontal plane).
8. Secure the bite fork vertical rod, then the horizontal rod (holding the bow securely to prevent torque).
9. Release the bow anteriorly to allow spread, and disengage from the ears.
10. Remove the fork downward and out of the mouth with the attached bow.
11. Carefully check the security of the attachments.

The next steps allow transfer of the recorded relationship to the articulator:

1. Position the posterior reference points on the articulator (usually a posterior attachment point).
2. Secure the posterior points by securing the bow anteriorly.
3. Vertically relate the secured bow to the articulator anterior reference point.
4. Seat the maxillary cast into the bite fork registration (wax or elastomer).
5. Close the articulator and check clearance for mounting plaster (modify the cast as needed).
6. Mount with low-expansion plaster.

The facebow is a relatively simple device used to obtain a transfer record for orienting a maxillary cast on an articulating instrument. Originally, the facebow was used only to transfer a radius from condyle reference points so that a given point on the cast would be the same distance from the condyle as it is on the patient. The addition of an adjustable infraorbital pointer to the facebow and the addition of an orbital plane indicator to the articulator make possible the transfer of the elevation of the cast in relation to the axis-orbital plane. This permits the maxillary cast to be correctly oriented in the articulator space comparable with the relationship of the maxilla to the axis-orbital plane on the patient. To accommodate this orientation of the maxillary cast and still have room for the mandibular cast, the posts of the conventional articulator must be lengthened. The older Hanau model H articulator usually will not permit a facebow transfer with an infraorbital pointer.

A facebow may be used to transfer a comparable radius from arbitrary reference points, or it may be designed so that the transfer can be made from hinge axis points.

The latter type of transfer requires that a hinge-bow attached to the mandible should be used initially to determine the hinge axis points, to which the facebow is then adjusted for making the hinge axis transfer.

A facebow transfer of the maxillary cast, which is oriented to the axis-orbital plane in a suitable articulator, is an uncomplicated procedure. The Hanau series Wide-View Arcon 183-2, all 96H2-0 models, the Whip Mix articulator (Whip Mix Corporation, Louisville, KY), and the Dentatus model ARH (Dentatus USA, Ltd., New York, NY) will accept this transfer. The Hanau earpiece facebow models 153 and 158, the Hanau fascia facebow 132-2SM, and the Dentatus facebow type AEB incorporate the infraorbital plane to the articulator. None of these are hinge axis bows; they are used instead at an arbitrary point.

The location of the arbitrary point or axis has long been the subject of controversy. Gysi and others have placed it 11 to 13 mm anterior to the upper third of the tragus of the ear on a line extending from the upper margin of the external auditory meatus to the outer canthus of the eye. Others have placed it 13 mm anterior to the posterior margin of the center of the tragus of the ear on a line extending to the corner of the eye. Bergström has located the arbitrary axis 10 mm anterior to the center of a spherical insert for the external auditory meatus and 7 mm below the Frankfort horizontal plane.

In a series of experiments reported by Beck, it was shown that the arbitrary axis suggested by Bergström falls consistently closer to the kinematic axis than do the other two. It is desirable that an arbitrary axis is placed as close as possible to the kinematic axis. Although most authorities agree that any of the three axes will permit transfer of the maxillary cast with reasonable accuracy, it would seem that the Bergström point compares most favorably with the kinematic axis.

The lowest point on the inferior orbital margin is taken as the third point of reference for establishing the axis-orbital plane. Some authorities use the point on the lower margin of the bony orbit in line with the center of the pupil of the eye. For the sake of consistency, the right infraorbital point is generally used and the facebow assembled in this relationship. All three points (right and left axes and infraorbital point) are marked on the face with an ink dot before the transfer is made.

Casts are prepared for mounting on an articulator by placing three index grooves in the base of the casts. Two V-shaped grooves are placed in the posterior section of the cast and one groove in the anterior portion (Figure 13-7).

An occlusion rim properly oriented on a well-fitting record base should be used in facebow procedures involving the transfer of casts representative of the Class I and II partially edentulous situations. Without occlusion rims, such casts cannot be located accurately in the imprints of the wax covering the facebow fork. Tissues covering the residual ridges may be displaced grossly when the patient closes into the wax on the facebow fork. Therefore the wax

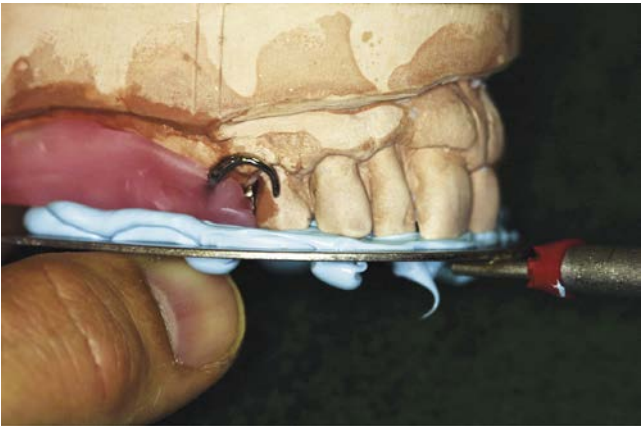


**FIGURE 13-7** The base of the cast has been prepared for mounting by placing three triangular grooves to allow indexing when mounted. The grooves are prepared with a 3-inch stone mounted in a laboratory lathe.

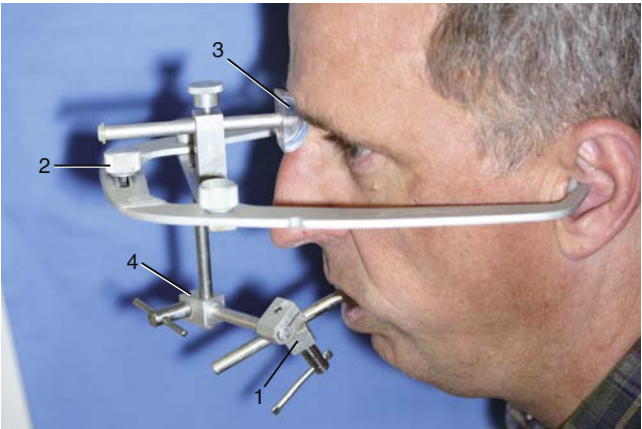
imprints of the soft tissues will not be true negatives of the edentulous regions of the diagnostic casts.

For purposes of illustration, a facebow using the external auditory meatus as the posterior reference point, the Whip Mix Facebow technique (DB 2000, Whip Mix Corporation, Louisville, KY), will be shown. The facebow fork is covered with a polyether, polyvinyl siloxane, or a roll of softened baseplate wax with the material distributed equally on the top and on the underneath side of the facebow fork. Then the fork should be pressed lightly on the diagnostic casts with the midline of the facebow fork corresponding to the midline of the central incisors (Figure 13-8). This will leave imprints of the occlusal and incisal surfaces of the maxillary casts and occlusion rim on the softened baseplate wax and is an aid in correctly orienting the facebow fork in the patient's mouth. The facebow fork is placed in position in the mouth, and the patient is asked to close the lower teeth into the wax to stabilize it in position. It is removed from the mouth and chilled in cold water and then replaced in position in the patient's mouth. An alternative method of stabilizing the facebow fork and recording bases is to enlist the assistance of the patient.

If an earpiece facebow is to be used, the patient should be reminded that the plastic earpieces in the auditory canals will greatly amplify noise. With the facebow fork in position, the facebow toggle is slipped over the anterior projection of the facebow fork (Figure 13-9). The patient can assist in guiding the plastic earpieces into the external auditory meatus. The patient can then hold the arms of the facebow in place with firm pressure while the operator



**FIGURE 13-8** Orienting the facebow fork to the maxillary cast and occlusion rims avoids displacing the occlusion rim in the mouth through patient closure or another uneven force. Polyvinyl siloxane material has been evenly distributed around the facebow fork, and care is exercised to position the fork to be centered at the mid-incisal position without any fork extension posterior to the record base, which could cause discomfort.



**FIGURE 13-9** The horizontal toggle clamp of the Whip Mix earpiece facebow (1) is slid onto the shaft of the facebow fork protruding from the patient's mouth. The patient then helps guide plastic earpieces into the external auditory meatus and holds them in place while the operator tightens three thumb screws (2) and centers the plastic nosepiece (3) securely on the nasion. The horizontal toggle clamp is positioned and secured near (but not touching) the lip. The T screw (4) on the vertical bar is tightened. Note: Extreme care should be exercised not to tilt the facebow out of position when tightening.

secures the bite fork to the facebow. This accomplishes the radius aspect of the facebow transfer.

If an infraorbital pointer is used, it is placed on the extreme right side of the facebow and angled toward the infraorbital point previously identified with an ink dot. It is then locked into position with its tip lightly touching the skin at the dot. This establishes the elevation of the facebow in relation to the axis-orbital plane. Extreme care must be taken to avoid any slip that might injure the patient's eye.



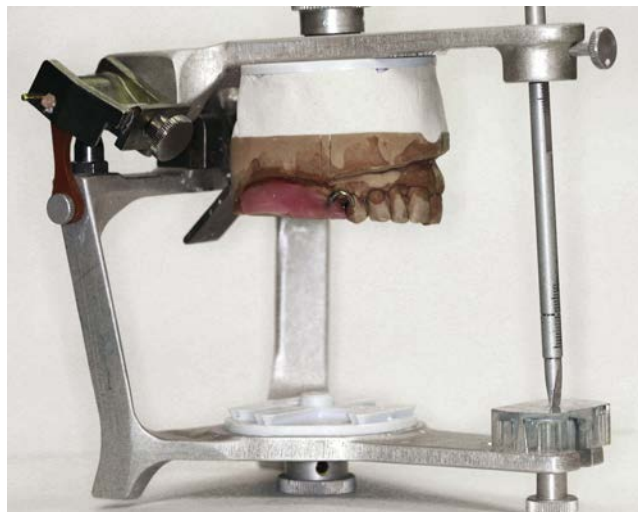**FIGURE 13-10** Facebow fork support used to maintain the fork and cast in position while mounting.

With all elements tightened securely, the patient is asked to open, and the entire assembly is removed intact, rinsed with cold water, and set aside. The facebow records not only the radius from the condyles to the incisal contacts of the upper central incisors, but also the angular relationship of the occlusal plane to the axis-orbital plane.

The facebow must be positioned on the articulator in the same axis-orbital relation as on the patient. If an arbitrary-type facebow is used, the calibrated condyle rods of the facebow ordinarily will not fit the condyle shafts of the articulator unless the width between the condyles just happens to be the same. With a Hanau model 132-25M facebow, the calibrations must be reequalized when in position on the articulator. For example, they have read 74 (mm) on each side of the patient but must be adjusted to read 69 (mm) on each side of the articulator. Some later model articulators have adjustable condyle rods and may be adjusted to fit the facebow. It is necessary that the facebow be centered in either case. Some facebows are self-centering, as is the Hanau Spring-Bow (Whip Mix Corporation, Louisville, KY).

The third point of reference is the orbital plane indicator, which must be swung to the right so that it will be above the tip of the infraorbital pointer. The entire facebow with maxillary cast in place must be raised until the tip of the pointer contacts the orbital plane indicated. The elevation having thus been established, for all practical purposes the orbital plane indicator and the pointer may now be removed because they may interfere with placing the mounting stone.

An auxiliary device called a *cast support* is available; it is used to support the facebow fork and the maxillary cast during the mounting operation (Figure 13-10). With this device, the weight of the cast and the mounting stone are supported separately from the facebow, thus preventing possible downward movement resulting from their combined weight. The cast support is raised to supporting contact with the facebow fork after the facebow height has



**FIGURE 13-11** Facebow mounting is complete. The relationship of the maxillary cast to the articulator condylar components is anatomically similar to that between the patient's maxilla and the bilateral temporomandibular joint (TMJ) complex. Any subsequent tooth arrangement and occlusal contact development represent the mouth more accurately than more arbitrary mountings. The benefits of the anatomic similarity are seen in more accurate occlusion for the finalized prosthesis (i.e., less intraoral adjustment required).

been adjusted to the level of the orbital plane. Use of some type of cast support is highly recommended as an adjunct to facebow mounting.

The keyed and lubricated maxillary cast is now attached to the upper arm of the articulator with the mounting stone, thus completing the facebow transfer (Figure 13-11). Not only will the facebow have permitted the upper cast to be mounted with reasonable accuracy, it also will have served as a convenient means of supporting the cast during mounting. Once mastered, its use becomes a great convenience rather than a time-consuming nuisance.

It is preferable that the maxillary cast be mounted while the patient is still present, thus eliminating a possible reappointment if the facebow record is unacceptable for some reason. Not too infrequently, the facebow record has to be redone with the offset-type facebow fork repositioned to avoid interference with some part of the articulator.

### Jaw Relationship Records for Diagnostic Casts

One of the first critical decisions that must be made in a removable partial denture service involves selection of the horizontal jaw relationship to which the removable partial denture will be fabricated (centric relation or the maximum intercuspal position). All mouth-preparation procedures depend on this analysis. Failure to make this decision correctly may result in poor prosthesis stability, discomfort, and deterioration of the residual ridges and supporting teeth.

It is recommended that deflective occlusal contacts in the maximum intercuspal and eccentric positions be corrected as a preventive measure. Not all dentists agree that centric relation and the maximum intercuspal position must be harmonious in the natural dentition. Many dentitions function satisfactorily with the opposing teeth maximally intercusped in an eccentric position without either diagnosable or subjective indications of TMJ dysfunction, muscle dysfunction, or disease of the supporting structures of the teeth. In many such situations, no attempt should be made to alter the occlusion. It is not a requirement to interfere with an occlusion simply, because it does not completely conform to a relationship that is considered ideal.

If most natural posterior teeth remain and if no evidence of TMJ disturbances, neuromuscular dysfunction, or periodontal disturbances related to occlusal factors exists, the proposed restorations may be fabricated safely with maximum intercuspation of remaining teeth. However, when most natural centric stops are missing, the proposed prosthesis should be fabricated so that the maximum intercuspal position is in harmony with centric relation. By far, the greater majority of removable partial dentures should be fabricated in the horizontal jaw relationship of centric relation. In most instances in which edentulous spaces have not been restored, the remaining posterior teeth will have assumed malaligned positions through drifting, tipping, or extrusion. Correction of the remaining natural occlusion to create a coincidence of centric relation and the maximum intercuspal position is indicated in such situations.

Regardless of the method used in creating a harmonious functional occlusion, an evaluation of the existing relationships of the opposing natural teeth must be made and is accomplished with a diagnostic mounting. This evaluation is performed in addition to, and in conjunction with, other diagnostic procedures that contribute to an adequate diagnosis and treatment plan.

Diagnostic casts provide an opportunity to evaluate the relationships of remaining oral structures when correctly mounted on a semiadjustable articulator with use of a facebow transfer and interocclusal records. Diagnostic casts are mounted in centric relation (most retruded relation of the mandible to the maxillae) so that deflective occlusal contacts can be correlated with those observed in the mouth. Deflective contacts of opposing teeth are usually destructive to the supporting structures involved and should be eliminated. Diagnostic casts demonstrate the presence and location of such interfering tooth contacts and permit visualization of the treatment that would be necessary for their correction. Necessary alteration of teeth to harmonize the occlusion can be performed initially on duplicates of the mounted diagnostic casts to act as guides for similar necessary corrections in the mouth. In many instances the degree of alteration required will indicate the need for crowns or onlays to be fabricated, or for recontouring, repositioning, or elimination of extruded teeth.

As mentioned previously, the maxillary cast is correctly oriented to the opening axis of the articulator by means of the facebow transfer and becomes spatially related to the upper member of the articulator in the same relationship that the maxilla has to the hinge axis and the Frankfort plane. Similarly, when a centric relation record is made at an established vertical dimension, the mandible is in its most retruded relation to the maxilla. Therefore when the maxillary cast is correctly oriented to the axis of the articulator, the mandibular cast automatically becomes correctly oriented to the opening axis, when attached to and mounted with an accurate centric relation record.


Unlike recording the fixed relationship of the maxilla to the mandibular opening axis (using the facebow transfer record), the mandibular position is recorded in space and is not a fixed point. Consequently, it is necessary to prove that the relationship of the mounted casts is correct. This can be done simply by making another interocclusal record, at centric relation, fitting the casts into the record, and checking to see that the condylar elements of the articulator are snug against the condylar housings. If this is not seen, another record is made until duplicate records are produced. Because centric relation is the only jaw position that can be repeated by the patient, mountings in this position can be replicated and verified for correctness.

A straightforward protrusive record is made to adjust the horizontal condylar inclines on the articulator. Lateral eccentric records are made so that the lateral condylar inclinations can be properly adjusted. All interocclusal records should be made as near the vertical relation of occlusion as possible. Opposing teeth or occlusion rims must not be allowed to contact when the records are made. A contact of the inclined planes of opposing teeth will invalidate an interocclusal record.

In some instances, a mounting of a duplicate diagnostic cast in the maximum intercuspal position may also be desirable to definitively study this relationship on the articulator. Because articulators simulate only jaw movements, it is not unreasonable to assume that the relationship of the casts mounted in centric relation may differ minutely from the maximum intercuspal position seen on the articulator and observed in the mouth. When diagnostic casts are hand related by maximum intercuspation for purposes of mounting on an articulator, it is essential that three (preferably four) positive contacts of opposing posterior teeth are present, having widespread molar contacts on each side of the arch. If occlusion rims are necessary to correctly orient casts on an articulator, a centric relation should usually be the horizontal jaw relationship to which the removable partial denture will be constructed.

### Materials and Methods for Recording Centric Relation

Materials available for recording centric relation are numerous. Current materials include polyether materials, polyvinyl silicone materials, dimethacrylate-based materials, metallic



**FIGURE 13-12** A wax interocclusal record made on a cast framework. **A**, The modification spaces first had baseplate wax added; these were adjusted intraorally to provide space at the occlusal vertical dimension for recording wax, the wax was softened using a wax spatula and a hot water bath, the framework was placed in the mouth, and care was exercised to guide the patient to close into a previously verified (and practiced) interocclusal position deemed appropriate (in this instance, centric relation position). The record was recovered from the mouth, excess wax was removed with a warm scalpel, and the wax was chilled and replaced in the mouth to verify the record. If not verified, the wax was resoftened (with additional wax added as needed) and the procedure was repeated. **B**, Immediately after verification, the framework with interocclusal registration was replaced on the mandibular cast and inverted on the maxillary cast for mounting.

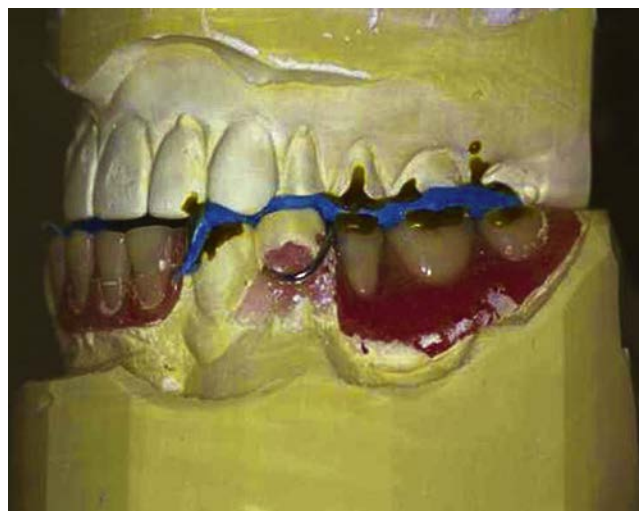oxide paste, and wax. Of these, wax is likely to be least satisfactory unless carefully handled. If not uniformly softened when introduced into the mouth, it can record a position with unequal tissue placement. Also, it does not remain rigid and dimensionally stable after removal unless carefully chilled and handled upon removal (Figure 13-12).

*Metallic oxide bite registration paste* is quite accurate yet is not strong enough to be used alone. To improve strength, it can be supported by a gauze mesh attached to a metal frame or it may be used with occlusion rims.

Elastomeric materials are excellent for recording interocclusal relationships (Figure 13-13). Some are specially formulated for this purpose and have the qualities of extremely low viscosity, minimal resistance to closure, rapid set, low rebound, lack of distortion, and stability after removal from the mouth. Care should be exercised to ensure that no elastic rebound results when the record is used to relate the casts during the mounting procedure.

The mandibular cast should be mounted on the lower arm of the articulator, with the articulator inverted (Figure 13-14, A). The articulator is first locked in centric position, and the incisal pin is adjusted so that the anterior distance between the upper and lower arms of the articulator will be increased 2 to 3 mm greater than the normal parallel relationship of the arms. This is done to compensate for the thickness of the interocclusal record so that the arms of the articulator will again be nearly parallel when the interocclusal record is removed and the opposing casts come into contact.

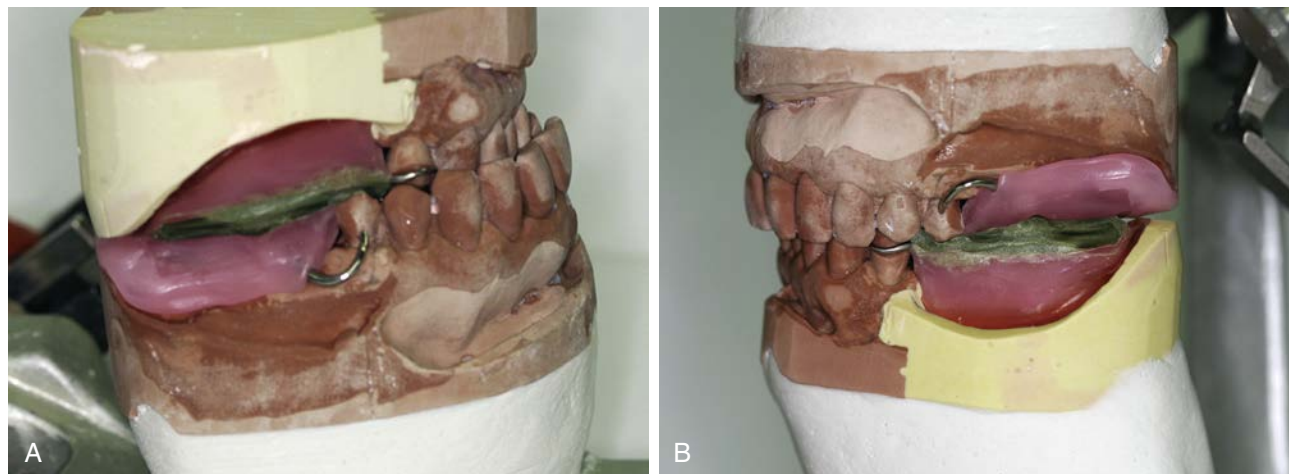
The base of the cast should be keyed and lightly lubricated for future removal. With the diagnostic casts accurately seated and secured in the occlusal record, the mandibular cast is affixed with stone to the lower member of the inverted articulator.



**FIGURE 13-13** Elastomeric interocclusal registration material used to record mandibular position.

An articulator mounting thus made will have related the casts in centric relation (see Figure 13-14, B). The dentist then can proceed to make an occlusal analysis by observing the influence of cusps in relation to one another after the articulator has been adjusted by using eccentric interocclusal records.

After an occlusal analysis has been made, the casts may be removed from their mounting for the purpose of surveying them individually and for other purposes as outlined previously. The indexed mounting ring record also should be retained throughout the course of treatment in the event that further study should be needed. It is advisable that the mounting be identified with the articulator that is used, so that it may always be placed back onto the same articulator.



**FIGURE 13-14** **A**, Mandibular cast inverted on the mounted maxillary cast, making sure that the cast is fully seated into the interocclusal record and stabilized to the opposing cast. It is important to check the posterior occlusion rim contact to ensure that no interfering contact has altered the record. Space should be observed between the opposing record bases (or record base and opposing occlusion). **B**, Mounted casts demonstrating the occlusal plane as found in the mouth. The Frankfort plane of the patient is oriented parallel to the articulator base and the floor. Also, inspection of the posterior rims demonstrates space between the rims, which ensures that the recorded position was registered without influence from rigid contacting components, only from softened wax.

### DIAGNOSTIC FINDINGS

The information gathered in the patient interview and clinical examination provides the basis for establishing whether treatment is indicated, and if so, what specific treatment should be considered. More than one treatment option can be considered, and financial implications need to be considered against long-term expectations if the best decision is to be reached. Provision of a removable partial denture does not often preclude future consideration for other treatments, a fact that is not often the case for alternative treatments. The patient interview can reveal medical considerations that influence the decision to provide any prosthesis. When it is felt that general medical health is being neglected, patients should be strongly encouraged to seek a general medical examination. Alternatively, patients who regularly see their physician may be found to take multiple medications that can contribute to a dry mouth and, potentially, an altered oral microflora with some increased risk for plaque-induced disease. Although such a condition can influence any prosthodontic care, given the unique features of removable partial denture service relative to the need for increased hygiene awareness and care, any factor that places an additional risk for plaque-induced disease should be emphasized with the patient and corrected if possible. Health conditions that negatively affect oral mucosal health (e.g., diabetes mellitus, Sjögren syndrome, lupus, atrophic changes) may pose a risk for patient comfort for a tissue-supported prosthesis and factor into a treatment decision.

For the patient who has had previous experience with some form of prosthesis, the patient interview provides additional information that can influence treatment decisions. Identifying possible reasons (or more importantly, a lack of any reason) for both positive and negative past prosthesis experiences is important for determining whether a patient

can predictably be helped. Although the clinical examination will point out the oral tissue responses to such therapy, the interview will highlight the subjective patient response to therapy and provide significant information that should be pursued. As mentioned previously, a patient complaint regarding the prosthesis needs to be confirmed through evaluation. The patient generally expresses concern about a symptom that can be related to support, stability, retention, and/or appearance. Confirmation of a design feature or oral condition that can explain the symptom is required if one is to have a chance to correct it with a similar prosthesis. If examination does not confirm any such relationship, it would be difficult to proceed without some concern for repeating the patient response to therapy unless a different form of therapy is selected (e.g., replacing a problematic removable partial denture with an implant-supported prosthesis).

### INTERPRETATION OF EXAMINATION DATA

As a result of the oral examination, several diagnoses are made that are related to the various tissues, conditions, and clinical information gathered. The integration of these diagnoses serves as the basis for decisions that will ultimately identify the suggested treatment. The treatment decision reflects a confluence of several aspects of the patient's past, present, and potential oral health status.

It is helpful to consider how the various diagnoses are integrated; consequently, a suggested framework is provided that highlights aspects of disease management, followed by reconstruction considerations for (1) prosthesis support; and (2) prosthesis design-specific aspects.

Disease management takes into account findings from the radiographic examination, periodontal disease and caries assessments, and pathology requiring endodontic

considerations. Reconstruction considerations include diagnoses relative to prosthesis support (teeth and residual ridges) and prosthesis-specific design elements. Prosthesis support related to the remaining teeth requires radiographic examination of alveolar support and root morphology, endodontic evaluation, analysis of occlusal factors, assessment of the benefit for fixed prostheses or orthodontics, and evaluation of the need for extraction. Residual ridge support involves radiographic examination of ridge contours and height, and evaluation of the need for pre-prosthetic surgical intervention. Prosthesis-specific design considerations include determination of anatomic relationships related to mandibular major connector design, the need for tooth modification to facilitate prosthesis function, and analysis of the occlusion. Each of these is considered in the following sections.

### Radiographic Interpretation

Many of the reasons for radiographic interpretation during oral examination are outlined herein and are considered in greater detail in other texts. Aspects of such interpretation that are most pertinent to removable partial denture construction are those relative to the prognosis of remaining teeth that may be used as abutments.

### Disease Validation

It is important to verify by clinical examination disease found through radiographic interpretation. Also, if the clinical examination reveals dental caries and/or periodontal disease, its severity can be confirmed by radiographic interpretation. It would be important to delineate caries severity, in terms of numbers of lesions and dentin/pulpal involvement, to gain insight as to level of disease risk associated with the patient, as well as to identify what therapy is required to maintain teeth. The same is true for periodontal disease risk and severity, as such a diagnosis affects both current and future tooth prognosis for prosthesis support.

Radiographic interpretation allows diagnosis of bone lesions associated with both the jaws and the teeth. The implications for tooth stability and ridge support are important to factor into prosthesis prognosis. Surgical and postoperative management of such lesions can vary significantly with diagnosis (benign versus malignant), and definitive prosthesis treatment is often complicated by resective procedures.

### Tooth Support

The quality of the alveolar support of an abutment tooth is of primary importance because the tooth will have to withstand greater stress loads when supporting a dental prosthesis. Abutment teeth providing total abutment support to the prosthesis, whether fixed or removable, will have to withstand a greater load and especially greater horizontal forces. The latter may be minimized by establishing a harmonious occlusion and by distributing the horizontal forces among several teeth through the use of rigid connectors. Bilateral stabilization against horizontal forces is one of the attributes of a properly designed tooth-supported removable

prosthesis. In many instances, abutment teeth may be aided more than weakened by the presence of a bilaterally rigid removable partial denture.

In contrast, abutment teeth adjacent to distal extension bases are subjected not only to vertical and horizontal forces but to torque as well because of movement of the tissue-supported base. Vertical support and stabilization against horizontal movement with rigid connectors are just as important as they are with a tooth-supported prosthesis, and the removable partial denture must be designed accordingly. In addition, the abutment tooth adjacent to the extension base will be subjected to torque in proportion to the design of the retainers, the size of the denture base, the tissue support received by the base, and the total occlusal load applied. With this in mind, each abutment tooth must be evaluated carefully as to the alveolar bone support present and the past reaction of that bone to occlusal stress.

It is important to judge whether the teeth and their respective periodontium can favorably respond to the demands of a prosthesis. Can radiographic interpretation provide clues to predicting tooth response to increased loading from prostheses? Assessment of regions within the mouth that have been subjected to increased loading can provide some clues as to the predictability of future similar response. An understanding of bone density, index areas, and lamina dura response is helpful for these judgments.

### Bone Density

The quality and quantity of bone in any part of the body are often evaluated by radiographic means. A detailed treatise concerning bone support of the abutment tooth should include many considerations not possible to include in this text because of space limitations. The reader should realize that subclinical variations in bone may exist but may not be observed because of the limitations inherent in technical methods and equipment.

Of importance to the dentist in evaluating the quality and quantity of the alveolar bone are the height and the quality of remaining bone. In estimating bone height, care must be taken to avoid interpretive errors resulting from angulation factors. Technically, when a radiographic exposure is made, the central ray should be directed at right angles to both the tooth and the film. The short-cone technique does not follow this principle; instead the ray is directed through the root of the tooth at a predetermined angle. This technique invariably causes the buccal bone to be projected higher on the crown than the lingual or palatal bone. Therefore in interpreting bone height, it is imperative to follow the line of the lamina dura from the apex toward the crown of the tooth until the opacity of the lamina materially decreases. At this point of opacity change, a less dense bone extends farther toward the tooth crown. This additional amount of bone represents false bone height. Thus, the true height of the bone is ordinarily where the lamina shows a marked decrease in opacity. At this point, the trabecular pattern of bone superimposed on the tooth root is lost. The portion of the root between the

cementoenamel junction and the true bone height has the appearance of being bare or devoid of covering.

Radiographic evaluation of bone quality is hazardous but is often necessary. It is essential to emphasize that changes in bone mineralization up to 25% often cannot be recognized by ordinary radiographic means. Optimum bone qualities are ordinarily expressed by normal-sized interdental trabecular spaces that tend to decrease slightly in size as examination of the bone proceeds from the root apex toward the coronal portion. The normal interproximal crest is ordinarily shown by a relatively thin white line crossing from the lamina dura of one tooth to the lamina dura of the adjacent tooth. Considerable variation in the size of trabecular spaces may exist within normal limits, and the radiographic appearance of crestal alveolar bone may vary considerably, depending on its shape and the direction that the ray takes as it passes through the bone.

Normal bone usually responds favorably to ordinary stresses. Abnormal stresses, however, may create a reduction in the size of the trabecular pattern, particularly in that area of bone directly adjacent to the lamina dura of the affected tooth. This decrease in size of the trabecular pattern (i.e., so-called bone condensation) is often regarded as a favorable bone response, indicative of an improvement in bone quality. This is not necessarily an accurate interpretation. Such bone changes usually indicate stresses that should be relieved, because if the resistance of the patient decreases, the bone may exhibit a progressively less favorable response on future radiographs.

Increased thickness of the periodontal space ordinarily suggests varying degrees of tooth mobility. This should be evaluated clinically. Radiographic evidence coupled with clinical findings may suggest to the dentist the inadvisability of using such a tooth as an abutment. Furthermore, an irregular intercrestal bone surface should make the dentist suspicious of active bone deterioration.

It is essential that the dentist realize that radiographic evidence shows the result of changes that have taken place and may not necessarily represent the present condition. For example, periodontal disease may have progressed beyond the stage visibly demonstrated on the radiograph. As pointed out earlier, radiographic changes are not observed until approximately 25% of the mineral content has been depleted. On the other hand, bone condensation probably does represent the current situation.

Radiographic findings should serve the dentist as an adjunct to clinical observations. Too often the radiographic appearance alone is used to arrive at a diagnosis; therefore radiographic findings should always be confirmed by clinical examination. Radiographic interpretation also serves an important function if used periodically after the prosthesis has been placed. Future bone changes of any type suggest traumatic interference from some source. The nature of such interference should be determined and corrective measures taken.

### Index Areas

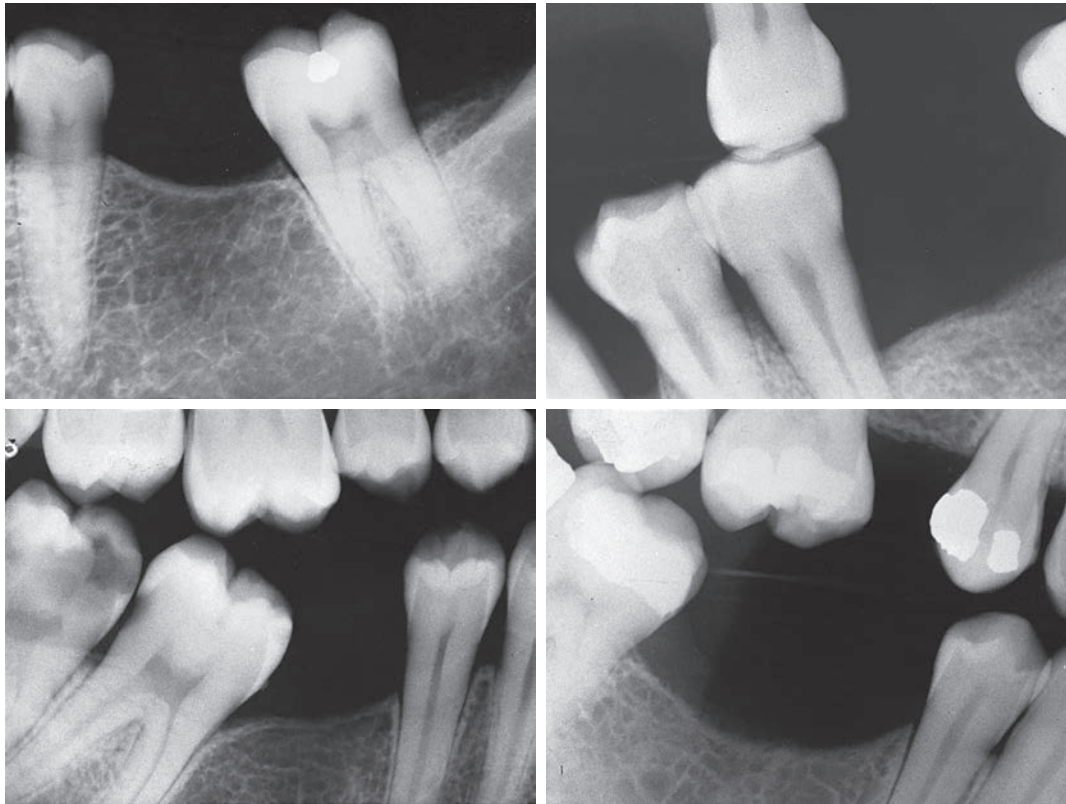
Index areas are those areas of alveolar support that disclose the reaction of bone to additional stress. Favorable reaction to such stress may be taken as an indication of future reaction to an added stress load. Teeth that have been subjected to abnormal loading because of the loss of adjacent teeth or that have withstood tipping forces in addition to occlusal loading may be better risks as abutment teeth than those that have not been called on to carry an extra occlusal load (Figures 13-15 and 13-16). If occlusal harmony can be improved and unfavorable forces minimized by the reshaping of occlusal surfaces and the favorable distribution of occlusal loading, such teeth may be expected to support the prosthesis without difficulty. At the same time, other teeth, although not at present carrying an extra load, may be expected to react favorably because of the favorable reaction of alveolar bone to abnormal loading elsewhere in the same arch.

Other index areas are those around teeth that have been subjected to abnormal occlusal loading; that have been subjected to diagonal occlusal loading caused by tooth migration; and that have reacted to additional loading, such as around existing fixed partial denture abutments. The reaction of the bone to additional stresses in these areas may be either positive or negative, with evidence of a supporting trabecular pattern, a heavy cortical layer, and a dense lamina dura, or the reverse response. With the former, the patient is said to have a positive bone factor, which means the ability to build additional support wherever needed. With the latter, the patient is said to have a negative bone factor, which means the inability to respond favorably to stress.

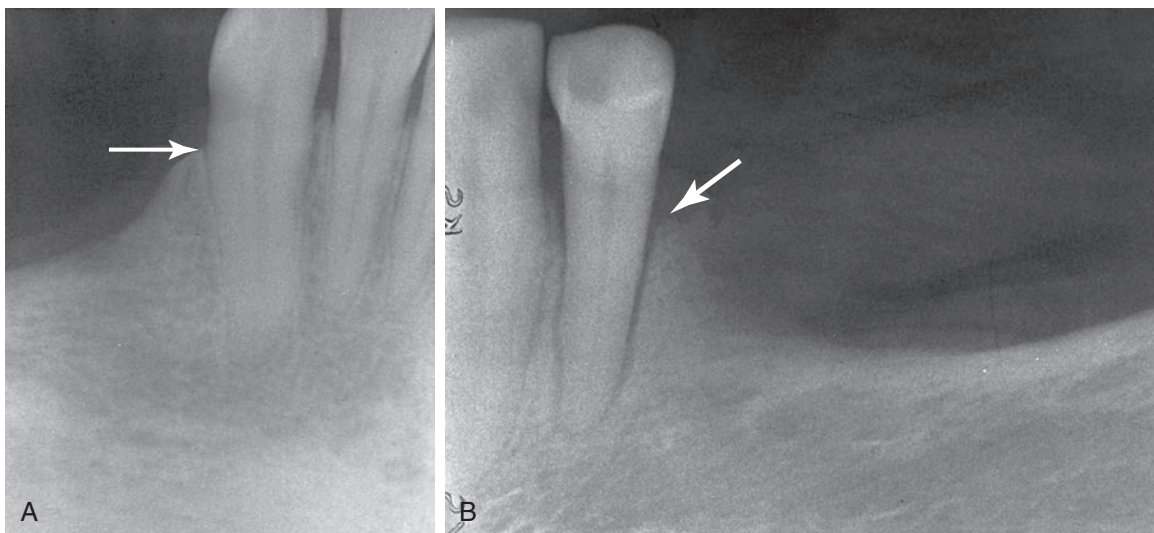
### Alveolar Lamina Dura

The alveolar lamina dura is also considered in a radiographic interpretation of abutment teeth. The lamina dura is the thin layer of hard cortical bone that normally lines the sockets of all teeth. It affords attachment for the fibers of the periodontal membrane, and as with all cortical bone, its function is to withstand mechanical strain. In a roentgenogram, the lamina dura is shown as a radiopaque white line around the radiolucent dark line that represents the periodontal membrane.

When a tooth is in the process of being tipped, the center of rotation is not at the apex of the root but in the apical third. Resorption of bone occurs where there is pressure, and apposition occurs where there is tension. Therefore during the active tipping process, the lamina dura is uneven, with evidence of both pressure and tension on the same side of the root. For example, in a mesially tipping lower molar, the lamina dura will be thinner on the coronal mesial and apicodistal aspects and thicker on the apicomésial and coronal distal aspects because the axis of rotation is not at the root apex but is above it. When the tooth has been tipped into an edentulous space by some change in the occlusion and becomes set



**FIGURE 13-15** The reaction of bone adjacent to teeth that have been subjected to abnormal stress serves as an indication of probable reactions of that bone when such teeth are used as abutments for fixed or removable restorations. Such areas are called *index areas*.



**FIGURE 13-16** **A**, The canine has provided support for the distal extension removable partial denture for 10 years. There has obviously been positive bone response (*arrow*) to increased stress generated by the removable partial denture. **B**, The mandibular first premolar has provided support for the distal extension denture for 3 years. Bone response (*arrow*) to past additional stress has been unfavorable.

in its new position, the effects of leverage are discontinued. The lamina dura on the side to which the tooth is sloping becomes uniformly heavier, which is nature's reinforcement against abnormal stresses. The bone trabeculations are most often arranged at right angles to the heavier lamina dura.

Thus, it is possible to say that for a given individual, nature is able to build support where it is needed, and on this basis to predict future reactions elsewhere in the arch to additional loading of teeth used as abutments. However, because bone is approximately 30% organic and mostly protein and

because the body is not able to store a protein reserve in large amounts, any change in body health may be reflected in the patient's ability to maintain this support permanently. When systemic disease is associated with faulty protein metabolism and when the ability to repair is diminished, bone is resorbed and the lamina dura is disturbed. Therefore the loading of any abutment tooth must be kept to a minimum inasmuch as the patient's future health status and the eventualities of aging are unpredictable.

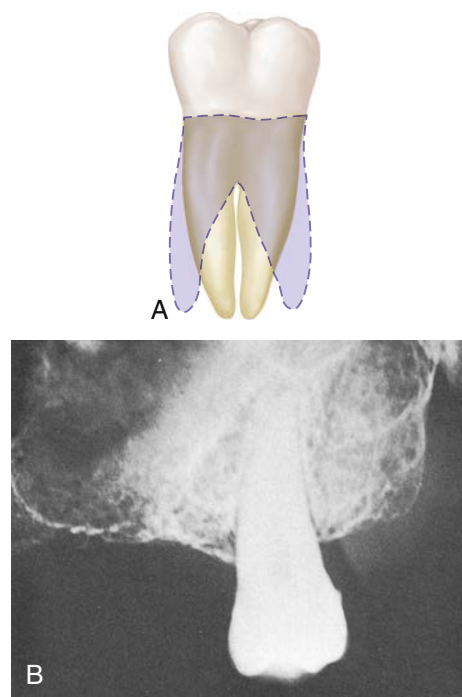
### Root Morphology

The morphologic characteristics of the roots determine to a great extent the ability of prospective abutment teeth to resist successfully additional rotational forces that may be placed on them. Teeth with multiple and divergent roots will resist stresses better than teeth with fused and conical roots, because the resultant forces are distributed through a greater number of periodontal fibers to a larger amount of supporting bone (Figure 13-17).

### Periodontal Considerations

An assessment of the periodontium in general and abutment teeth in particular must be made before prosthetic restoration. One must evaluate the condition of the gingiva, looking for adequate zones of attached gingiva and the presence or absence of periodontal pockets. The ideal periodontal condition is a disease-free periodontium with adequate attached mucosa in regions at or adjacent to removable partial denture component parts that cross the gingival margins to best resist the mechanical challenges posed as the result of function and use. The condition of the supporting bone must be evaluated, with specific attention to reduced bone support and mobility patterns recorded. If mucogingival involvements, osseous defects, or mobility patterns are recorded, the causes and potential treatment must be determined.

Oral hygiene habits of the patient must be determined, and efforts made to educate the patient relative to plaque control. The most decisive evidence of oral hygiene habits is the condition of the mouth before the initial prophylaxis. Good or bad oral hygiene is basic to the patient's nature, and although it may be influenced somewhat by patient education, the long-range view must be taken. It is reasonably fair to assume that the patient will do little more in the long-term future than he has done in the past. In making decisions regarding the method of treatment based on oral hygiene, the future in years, rather than in weeks and months, must be considered. It is probably best not to give the patient the benefit of any doubt as to future oral hygiene habits. Rather, the benefit should come from protective measures where any doubt exists about future oral hygiene habits. Therefore for patients at greatest risk, an oral prophylaxis with continued oral hygiene instructions should be scheduled for 3- to 4-month intervals. In addition, the patient must be advised of the importance of regular maintenance appointments for tissue-supported prostheses to maintain occlusal relationships. When these ongoing observations and prophylactic



**FIGURE 13-17** **A**, The prognosis for abutment service is more favorable for a molar with divergent roots (*shaded*) than for the same tooth if its roots were fused and conical. **B**, Evidence that prospective abutment has conical and fused roots indicates the necessity for formulating a framework design that will minimize additional stresses placed on the tooth by the abutment service.

requirements are described, the patient is faced with the realization that he or she must be willing to share responsibility for maintaining the health of the mouth after restorative and prosthodontic treatment.

The remaining teeth and prosthesis require meticulous plaque control after placement of a removable partial denture. Because of the nature of material coverage of oral tissues, the oral microflora can change with the use of a removable prosthesis. Coupled with this microbial change is the potential for a mechanical challenge to tissue integrity if the appropriate relationship of the prosthesis and soft tissues of the residual ridge, as well as the marginal gingival, is not maintained.

### Caries Risk Assessment Considerations

Caries activity in the mouth, past and present, and the need for protective restorations must be considered. The decision to use full coverage is based on a need to reshape abutment teeth to accommodate the components of the removable partial denture, prevention of restoration breakdown when abutments have large direct restorations, or evidence of recurrent caries risk. Occasionally, three-quarter crowns may be used where buccal or lingual surfaces are completely sound, but intracoronal restorations (inlays) are seldom indicated in any mouth with evidence of past extensive caries or precarious areas of decalcification, erosion, or exposed cementum.

Frequent consumption of sugars can lead to carious involvement of roots, caries around restorations, or caries associated with clasps of removable partial dentures. Intelligent consumption of sweets (smaller amounts and less frequent consumption) and frequent plaque removal are the recommended countermeasures. Excellent protection from caries can be provided by fluoride applications via tooth-pastes, mouth rinses, or (in extreme cases, such as postradiation xerostomia) 1% sodium fluoride (NaF) gels applied daily with plastic trays.

Xerostomia, caused by degeneration of salivary glands (Sjögren syndrome) or various medications, enhances the occurrence and severity of caries, as well as contributes to irritation of the oral mucosa. A possible way to alleviate xerostomia is the use of synthetic saliva, with a carboxymethylcellulose base, which can be enriched with fluoride in an effort to counteract caries. Frequent use provides an excellent means of maintaining high fluoride intraorally for long periods of time, thus enhancing the remineralization of incipient caries. Although providing instructions for improvement of oral hygiene is a duty of the dental team, suspected problems of dietary deficiencies should be referred to a nutritionist.

### Evaluation of the Prosthesis Foundation—Teeth and Residual Ridge

An evaluation of the prosthesis foundation is required to ensure that an appropriately stable base of sound teeth and/or residual ridge(s) is provided to maximize prosthesis function and patient comfort. To that end, the evaluation focuses on the identification of conditions that are inconsistent with sound support and predictably stable function.

### Surgical Preparation

The need for pre-prosthetic surgery or extractions must be evaluated. The same criteria apply to surgical intervention in the partially edentulous arch as in the completely edentulous arch. Grossly displaceable soft tissues covering basal seat areas and hyperplastic tissue should be removed to provide a firm denture foundation. Mandibular tori should be removed if they will interfere with the optimum location of a lingual bar connector or a favorable path of placement. Any other areas of bone prominence that will interfere with the path of placement should be removed also. The path of placement will be dictated primarily by the guiding plane of the abutment teeth. Therefore some areas may present interference to the path of placement of the removable partial denture by reason of the fact that other unalterable factors such as retention and esthetics must take precedence in selecting that path.

Clinical research in pre-prosthetic surgical concepts has contributed significant developments to management of the compromised partially edentulous patient. Bone augmentation and guided bone regeneration procedures have been used with varying degrees of success as an alternative method of improving ridge support for the denture base areas. Skill

and judgment must be exercised in patient selection, procedural planning, and surgical and prosthetic management to optimize clinical results. Use of osseointegrated implants can provide a foundation for developing suitable abutment support for removable partial dentures. As in any surgical procedure, results depend on careful treatment planning and cautious surgical management.

Extraction of teeth may be indicated for one of the following three reasons:

1. If the tooth cannot be restored to a state of health, extraction may be unavoidable. Modern advancements in the treatment of periodontal disease and in restorative procedures, including endodontic therapy, have resulted in the saving of teeth that were once considered untreatable. All reasonable avenues of treatment should be considered from both prognostic and economic standpoints before extraction is recommended.
2. A tooth may be removed if its absence will permit a more serviceable and less complicated removable partial denture design. Teeth in extreme malposition (lingually inclined mandibular teeth, buccally inclined maxillary teeth, and mesially inclined teeth posterior to an edentulous space) may be removed if an adjacent tooth is in good alignment and if good support is available for use as an abutment. Justification for extraction lies in the decision that a suitable restoration, which will provide satisfactory contour and support, cannot be fabricated, or that orthodontic treatment to realign the tooth is not feasible. An exception to the arbitrary removal of a malposed tooth occurs when a distal extension removable partial denture base would have to be made rather than using the more desirable tooth-supported base of the tooth in question. If alveolar support is adequate, a posterior abutment should be retained if at all possible in preference to a tissue-supported extension base. Teeth deemed to have insufficient alveolar support may be extracted if their prognosis is poor and if other adjacent teeth may be used to better advantage as abutments. The decision to extract such a tooth should be based on the degree of mobility and other periodontal considerations and on the number, length, and shape of the roots contributing to its support.
3. A tooth may be extracted if it is so unaesthetically located as to justify its removal to improve appearance. In this situation, a veneer crown should be considered in preference to removal if the crown can satisfy the esthetic needs. If removal is advisable because of unesthetic tooth position, the biomechanical problems involved in replacing anterior teeth with a removable partial denture must be weighed against the problems involved in making an esthetically acceptable fixed restoration. Admittedly, the removable replacement is commonly the more esthetic of the two, despite modern advancements in retainers and pontics. However, the mechanical disadvantage of the removable restoration often makes the fixed replacement of missing anterior teeth preferable.

Another consideration for pre-prosthetic surgery involves the decision between use of a removable partial denture and an implant-supported prosthesis. The following categories of tooth loss are presented with comparative comments germane to such decisions.

### Short Modification Spaces

For short spans ( $\leq 3$  missing teeth), natural tooth- and implant-supported fixed prostheses as well as removable partial dentures can generally be considered. Implant placement requires the decision that ample bone volume exists, or can be provided with minimal morbidity, to adequately house sufficient implants to support prosthetic teeth. Implant prostheses have the advantage of not requiring the use of teeth for support, stability, and retention requirements, and consequently do not increase the functional burden on the natural dentition. Although the predictability of contemporary implant procedures (surgery and prosthodontics) makes them a consideration for short span prostheses, the main advantage is the opportunity to provide replacement teeth without involving adjacent teeth in the reconstruction. Therefore, when the adjacent teeth are in need of restoration, a conventional prosthesis should be considered.

### Longer Modification Spaces

Longer span modification spaces ( $\geq 4$  missing teeth) present a greater challenge for natural tooth-supported fixed prostheses. Consequently, options for treatment include the removable partial denture and the implant-supported prosthesis. An implant prosthesis has the same bone volume requirements as stated earlier and will likely require additional implants for an increased span. Because residual ridge resorption can be greater with longer spans, the need for augmentation may also be greater. Both of these characteristics of longer spans cause implant use to be more costly and can significantly increase the cost difference between treatment options. The increased morbidity associated with augmentation procedures can also limit universal application. Because the removable partial denture remains largely tooth-supported (unless the span includes anterior and posterior segments that may cause it to function similar to a distal extension), the functional stability requirements should be efficiently met through the tooth support.

### Distal Extension Spaces

Without tooth support at each end of the missing teeth, the removable partial denture and the implant-supported prosthesis are the primary treatment considerations (double-abutted cantilevered fixed prostheses opposing maxillary complete dentures have been suggested to be a reasonable option for some patients). It then becomes obvious that when anatomic limitations to implant placement exist and surgical measures cannot be taken to correct this, the removable partial denture is the only option (unless no treatment

is elected). Current surgical options are available to correct most anatomic limitations, yet frequently implant therapy is not elected because of patient medical factors, concerns for the risk of surgical morbidity, increased time required for treatment, and costs. It is important to note that a comparison of long-term maintenance requirements between these two options may demonstrate little cost difference over time. This is related to the effects of continued residual ridge resorption acting on the removable prosthesis and not the implant prosthesis.

### Endodontic Treatment

Abutments for removable partial dentures are required to withstand various forces depending on the classification. The requirement for a distal extension abutment is different than that of a tooth-supported prosthesis in that torsional forces exist in the distal extension situation. For this reason, an abutment for a distal extension that is endodontically treated carries a greater risk for complications than a similar tooth not involved in removable partial denture function.

Because tooth support helps control prosthesis movement, the need for endodontic treatment should include assessment of overdenture abutments for removable partial dentures, especially to control movement of distal extensions.

### Analysis of Occlusal Factors

From the occlusal analysis made by evaluating the mounted diagnostic casts, the dentist must decide whether it is best to accept and maintain the existing occlusion or to attempt to improve on it by means of occlusal adjustment and/or restoration of occlusal surfaces. It must be remembered that the removable partial denture can supplement the occlusion that exists only at the time the prosthesis is constructed. The dominant force that dictates the occlusal pattern will be the cuspal harmony or disharmony of the remaining teeth and their proprioceptive influence on mandibular movement. The goal of artificial tooth placement is to harmonize with the functional parameters of the existing occlusion providing bilateral, simultaneous functional contact.

Chapter 18 identifies schemes of occlusion recommended for partially edentulous configurations. A review of these recommendations will provide a guide for modifying the existing occlusion or developing the appropriate occlusal scheme for each partially edentulous configuration.

Improvements in the natural occlusion must be accomplished before the prosthesis is fabricated, not subsequent to its fabrication. The objective of occlusal reconstruction by any means should be occlusal harmony of the restored dentition in relation to the natural forces already present or established. Therefore one of the earliest decisions in planning reconstructive treatment must be whether to accept or reject the existing vertical dimension of occlusion and the occlusal contact relationships in centric and eccentric positions. If occlusal adjustment is indicated, cuspal analysis

always should precede any corrective procedures in the mouth by selective grinding. On the other hand, if reconstruction is to be the means of correction, the manner and sequence should be outlined as part of the overall treatment plan.

### Fixed Restorations

There may be a need to restore modification spaces with fixed restorations rather than include them in the removable partial denture, especially when dealing with isolated abutment teeth. The advantage of splinting must be weighed against the total cost, with the weight of experience always in favor of using fixed restorations for tooth-bounded spaces unless the space will facilitate simplification of the removable partial denture design without jeopardizing the abutment teeth. One of the least successful removable partial denture designs is seen when multiple tooth-bounded areas are replaced with removable partial dentures in conjunction with isolated abutment teeth and distal extension bases. Biomechanical considerations and the future health of the remaining teeth should be given preference over economic considerations when such a choice is possible.

### Orthodontic Treatment

Occasionally, orthodontic movement of malposed teeth followed by retention through the use of fixed partial dentures makes possible a better removable partial denture design mechanically and esthetically than could otherwise be used. Although adequate anchorage for tooth movement can be a major limitation in partially edentulous arches, carefully placed implants that subsequently can be used for prosthesis support have been used to expand orthodontic applications for this patient group.

### Need for Determining Type of Mandibular Major Connector

As discussed in Chapter 5, one of the criteria used to determine the use of the lingual bar or linguoplate is the height of the floor of the patient's mouth when the tongue is elevated. Because the inferior borders of the lingual bar and the linguoplate are placed at the same vertical level, and because subsequent mouth preparations depend in part on the design of the mandibular major connector, determination of the type of major connector must be made during the oral examination. This determination is facilitated by measuring the height of the elevated floor of the patient's mouth in relation to the lingual gingiva with a periodontal probe and recording the measurement for later transfer to diagnostic and master casts. It is most difficult to make a determination of the type of mandibular major connector to be used solely from a stone cast that may or may not accurately indicate the active range of movement of the floor of the patient's mouth. Too many mandibular major connectors are ruined or made flexible because subsequent grinding of the inferior border is necessary to relieve impingement of the sensitive tissues of the floor of the mouth.

### Need for Reshaping Remaining Teeth

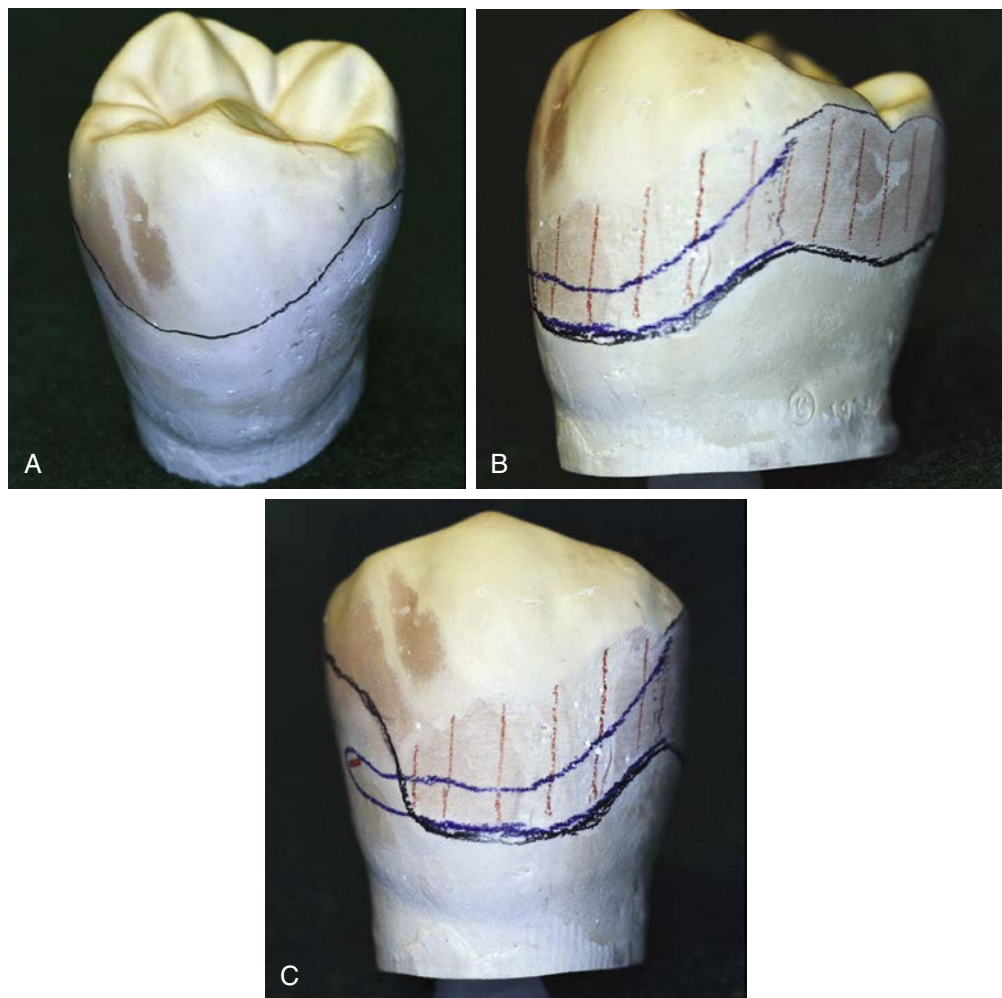
The clinical crown shapes of anterior and posterior teeth are not capable of supporting a removable partial denture framework without appropriate modification. Without the required modifications, the prosthesis does not adequately benefit from the support and stability offered by the teeth and consequently will not be comfortable to the patient. Many failures of removable partial dentures can be attributed to the fact that the teeth were not reshaped properly to establish guiding planes or to receive clasp arms and occlusal rests before the impression for the master cast was made. Of particular importance are the paralleling of proximal tooth surfaces to act as guiding planes, the preparation of adequate rest areas, and the reduction of unfavorable tooth contours (Figure 13-18). To neglect planning such mouth preparations in advance is inexcusable and leads to unsuccessful removable prosthesis service.

The design of clasps is dependent on the location of the retentive, stabilizing, reciprocal, and supporting areas in relation to a definite path of placement and removal. Failure to reshape unfavorably inclined tooth surfaces and, if necessary, to place restorations with suitable contours not only complicates the design and location of clasp retainers but also often leads to failure of the removable partial denture because of poor clasp design.

A malaligned tooth or one that is inclined unfavorably may make it necessary to place certain parts of the clasp so that they interfere with the opposing teeth. Unparallel proximal tooth surfaces not only will fail to provide needed guiding planes during placement and removal but also will result in excessive blockout. This inevitably results in placement of the connectors so far out of contact with tooth surfaces that food traps are created. To pass lingually-inclined lower teeth, clearance for a lingual bar major connector may have to be so great that a food trap will result when the restoration is fully seated. Such a lingual bar will be located so that it will interfere with tongue comfort and function. These are only some of the objectionable consequences of inadequate mouth preparations.

The amount of reduction of tooth contours should be kept to a minimum, and all modified tooth surfaces not only should be repolished after reduction but also should be subjected to fluoride treatment to lessen the incidence of caries. If it is not possible to produce the contour desired without perforating the enamel, then the teeth should be recontoured with an acceptable restorative material. The age of the patient, caries activity evidenced elsewhere in the mouth, and apparent oral hygiene habits must be taken into consideration when one is deciding between reducing the enamel and modifying tooth contours with protective restorations.

Some of the areas that frequently need correction are the lingual surfaces of mandibular premolars, the mesial and lingual surfaces of mandibular molars, the distobuccal line angle of maxillary premolars, and the mesiobuccal line angle of maxillary molars. The actual degree of inclination of teeth in relation to the path of placement and the location



**FIGURE 13-18** **A**, Unmodified buccal surface of the mandibular premolar illustrates a typical height of contour location natural for this tooth (middle and occlusal thirds of the tooth). **B**, Proximal surface modification is required (*hatched region*) to produce a guide-plane surface. **C**, Buccal surface modification is needed to position the height of contour for favorable clasp location. The tooth modification is a continuation of the proximal surface modification onto the buccal surface, and generally requires less than 0.5 mm of tooth removal.

of retentive and supportive areas are not readily interpretable during visual examination. These are established during comprehensive analysis of the diagnostic cast with a surveyor, which should follow the visual examination.

### INFECTION CONTROL

The American Dental Association (ADA) follows the Centers for Disease Control (CDC) recommended infection control procedures for dentistry. The most recent recommendations were made in 2003 and included updates from the previous 1993 guidelines. Most of the updates will be familiar to practitioners and are already largely practiced routinely. They are designed to prevent or reduce the potential for disease transmission from patient to dental health care worker (DHCW), from DHCW to patient, and from patient to patient. The document emphasizes the use of “standard precautions” (which replaces the term “universal precautions”) for the prevention of exposure to and transmission of not only

bloodborne pathogens but also other pathogens encountered in oral health care settings.

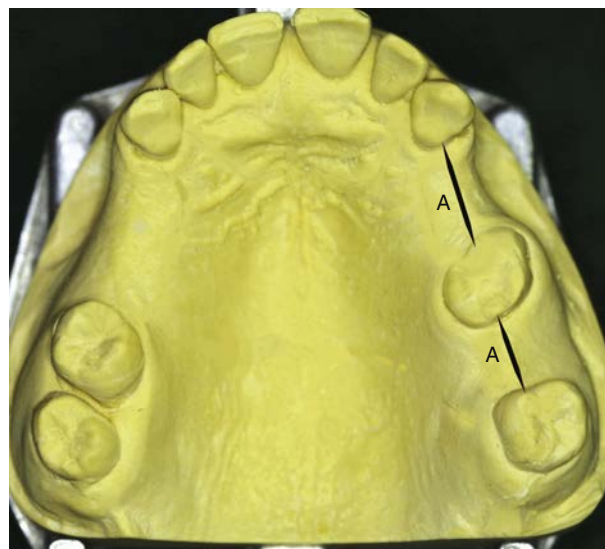
Major updates and additions include application of standard precautions rather than universal precautions, work restrictions for health care personnel infected with, or occupationally exposed to, infectious diseases; management of occupational exposure to bloodborne pathogens, including postexposure prophylaxis for work exposures to hepatitis B virus (HBV), hepatitis C virus (HCV), and human immunodeficiency virus (HIV); selection and use of devices with features designed to prevent sharps injury, contact dermatitis, and latex hypersensitivity; hand hygiene; dental unit waterlines; and biofilm and water quality; special considerations include dental handpieces and other devices attached to air lines and waterlines, saliva ejectors, radiology, parenteral medications, single-use or disposable devices, preprocedural mouth rinses, oral surgical procedures, handling of biopsy specimens and extracted teeth, laser/electrosurgery plumes, *Mycobacterium tuberculosis*, Creutzfeldt-Jakob disease and

other prion diseases, program evaluation, and research considerations. The recommendations provide guidance for measures to be taken that will reduce the risks of disease transmission, among both DHCWs and their patients.

Dental patients and DHCWs potentially may be exposed to a variety of microorganisms. Exposure can occur via blood and/or oral or respiratory secretions. The microorganisms may include viruses and bacteria that infect the upper respiratory tract in general, as well as cytomegalovirus, HBV, HCV, herpes simplex virus types 1 and 2, HIV, *Mycobacterium tuberculosis*, staphylococci, and streptococci. The transmission of infection in the dental operator can occur through several routes. These include direct contact (blood, oral fluids, or other secretions), indirect contact (contaminated instruments, operator equipment, or environmental surfaces), and contact with airborne contaminants present in droplet spatter or in aerosols of oral and respiratory fluids. For infection to occur via any of these routes, the “chain of infection” must be present. This includes a susceptible host, a pathogen with sufficient infectivity and numbers to cause infection, and a portal through which the pathogen may enter the host. For infection control procedures to be effective, one or more of these “links” in the chain must be broken.

Studies from the CDC report that clothing exposed to the acquired immunodeficiency syndrome (AIDS) virus may be safely used after a normal laundry cycle. A high-temperature (140° F to 160° F, 60° C to 70 °C) wash cycle with normal bleach concentrations, followed by machine drying (212° F, 100° C, or higher), is preferable if clothing is visibly soiled with blood or other body fluids. Dry cleaning and steam pressing will also kill the AIDS virus, according to these studies. Patients with oral lesions suggestive of infectious disease and patients with a known history of hepatitis B, AIDS, AIDS-related complex, or other infectious diseases should be referred for appropriate medical care. In addition to environmental surface and equipment disinfection, all instruments, stones, burs, and other reusable items should be disinfected in 2% glutaraldehyde for 10 minutes, cleaned of debris, rinsed, and patted dry before the sterilizing process is initiated. Heat-sensitive items can be sterilized with the use of ethylene oxide (gas).

For items that have been used in the mouth, including laboratory materials (e.g., impressions, bite registrations, fixed and removable prostheses, orthodontic appliances), cleaning and disinfection are required before they are manipulated in the laboratory (whether on site or at a remote location). Any item manipulated in the laboratory should also be cleaned and disinfected before placement in the patient's mouth. Fresh pumice with iodophor should be used for each polishing procedure, and the pumice pan should be washed, rinsed, and dried after each procedure. Because materials are constantly evolving, DHCWs are advised to follow manufacturers' suggested procedures for specific materials relative to disinfection procedures. As a guide, use of a chemical germicide that has at least an intermediate level of activity



**FIGURE 13-19** Class III, modification 2 arch, in which modification spaces on the patient's left (spaces designated at A) will be included in the design of the removable partial denture rather than restored with a long-span fixed partial denture. The design for a removable restoration is greatly simplified, resulting in significantly enhanced stability.

(i.e., “tuberculocidal hospital disinfectant”) is appropriate for such disinfection. Careful communication between dental office and dental laboratory regarding the specific protocol for handling and decontamination of supplies and materials is important to prevent any cross contamination.

### DIFFERENTIAL DIAGNOSIS: FIXED OR REMOVABLE PARTIAL DENTURES

Total oral rehabilitation (disease management, defective tooth restoration, and tooth replacement) is an objective in treating the partially edentulous patient. Although replacement of missing teeth by means of fixed partial dentures, either tooth or implant supported, is generally the method of choice, there are many reasons why a removable partial denture may be the better method of treatment for a specific patient.

The dentist must follow the best procedure for the welfare of the patient, who is always free to seek more than one opinion. Ultimately, the choice of treatment must meet the economic limitations and personal desires of the patient. The exception to this guideline is the Class III arch with a modification space on the opposite side of the arch, which will provide better cross-arch stabilization and a simpler design for the removable partial denture (Figure 13-19).

Although uncommon, unilateral tooth loss is sometimes inappropriately treated with a unilateral removable partial denture in place of a fixed partial denture. This type of prosthesis is not enhanced by cross-arch stabilization and places excessive stress on abutment teeth. Possibly more important, the risk for aspiration is significant if such a prosthesis is

dislodged during use. For these reasons, use of the unilateral removable partial denture is strongly discouraged.

### Indications for Use of Fixed Restorations

#### Tooth-Bounded Edentulous Regions

Generally any unilateral edentulous space bounded by teeth suitable for use as abutments should be restored with a fixed partial denture cemented to one or more abutment teeth at either end. The length of the span and the periodontal support of the abutment teeth will determine the number of abutments required. As mentioned earlier, such a span could be managed with the use of dental implants if deemed feasible and elected by the patient. The fact that implant support does not place additional functional demands on adjacent teeth likely contributes to their preservation, although this has not been universally demonstrated.

For conventional fixed prostheses, lack of parallelism of the abutment teeth may be counteracted with copings or locking connectors to provide parallel sectional placement. Sound abutment teeth make possible the use of more conservative retainers, such as partial-veneer crowns, or resin-bonded-to-metal restorations, rather than full crowns. The age of the patient, evidence of caries activity, oral hygiene habits, and the soundness of remaining tooth structure must be considered in any decision to use less than full coverage for abutment teeth.

Two specific contraindications for the use of unilateral fixed restorations are known. One is a long edentulous span with abutment teeth that would not be able to withstand the trauma of nonaxial occlusal forces. The other is abutment teeth, which exhibit reduced periodontal support due to periodontal disease, which would benefit from cross-arch stabilization. In either situation, a bilateral removable restoration can be used more effectively to replace the missing teeth.

#### Modification Spaces

A removable partial denture for a Class III arch is better supported and stabilized when a modification area on the opposite side of the arch is present. A fixed partial denture need not be used to restore such an edentulous area because its inclusion may simplify the design of the removable partial denture. However, when a modification space is bound by a lone-standing single-rooted abutment, it is better restored by means of a fixed partial denture. This acts to stabilize the at-risk tooth, and the denture is made less complicated by not having to include other abutment teeth for the support and retention of an additional edentulous space or spaces.

When an edentulous space that is a modification of a Class I or Class II arch exists anterior to a lone-standing abutment tooth, this tooth is subjected to trauma by the movements of a distal extension removable partial denture far in excess of its ability to withstand such stresses. The splinting of the lone abutment to the nearest tooth is mandatory. The abutment crowns should be contoured for support and retention of the

removable partial denture; in addition, a means of supporting a stabilizing component on the anterior abutment of the fixed partial denture or on the occlusal surface of the pontic usually should be provided.

#### Anterior Modification Spaces

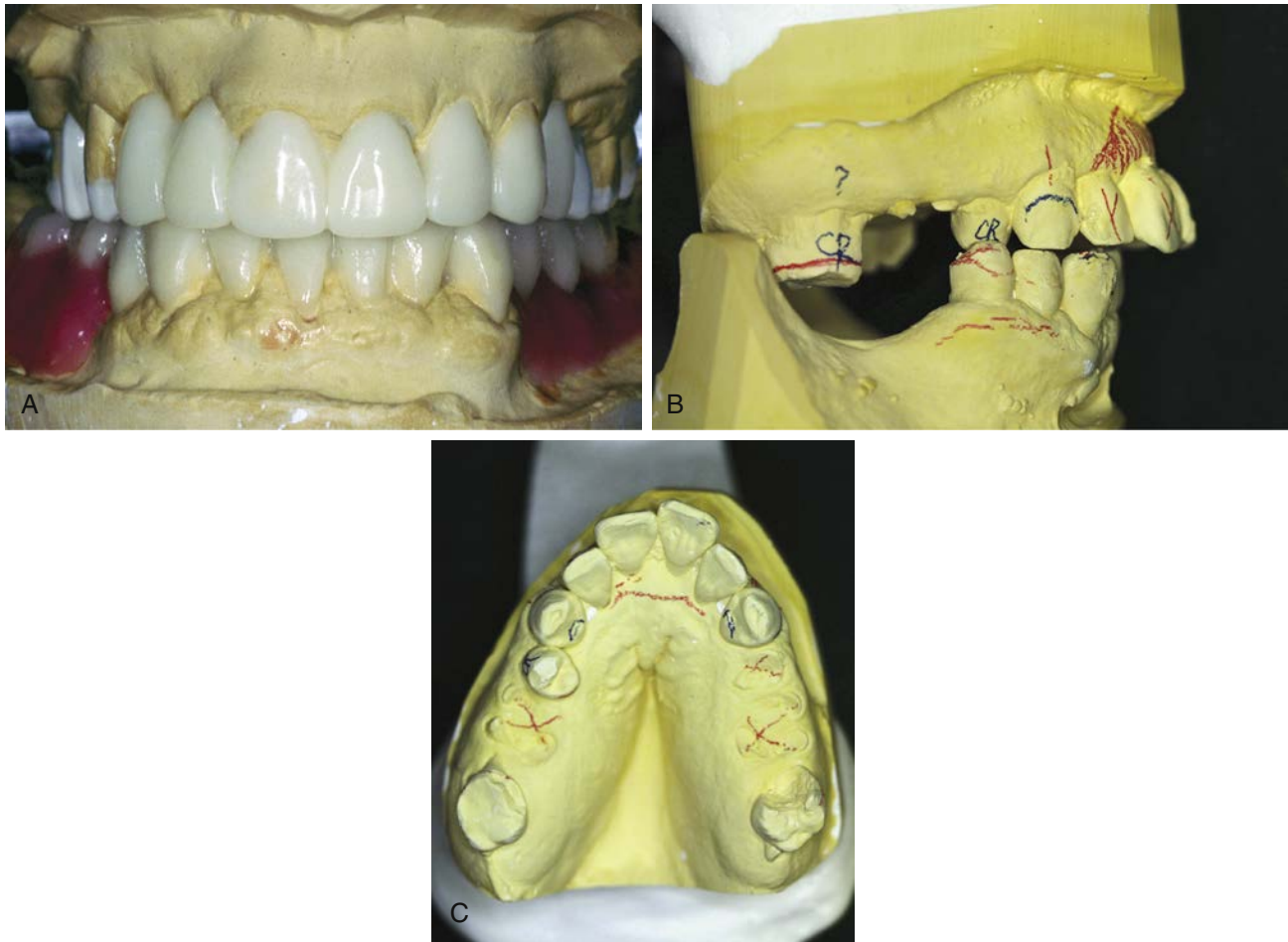
Usually any missing anterior teeth in a partially edentulous arch, except in a Kennedy Class IV arch in which only anterior teeth are missing, are best replaced by means of a fixed restoration. There are exceptions. Sometimes a better esthetic result is obtainable when the anterior replacements are supplied by a removable partial denture, at other times treatment is simplified by inclusion of an anterior modification space into the removable partial denture (Figure 13-20). This is also true when excessive tissue and bone resorption necessitates placement of the pontics in a fixed partial denture too far palatally for good esthetics or for an acceptable relation with the opposing teeth. However, in most instances, from mechanical and biological standpoints, anterior replacements are best accomplished with fixed restorations. The replacement of missing posterior teeth with a removable partial denture is then made much less complicated and gives more satisfactory results.

#### Replacement of Unilaterally Missing Molars (Shortened Dental Arch)

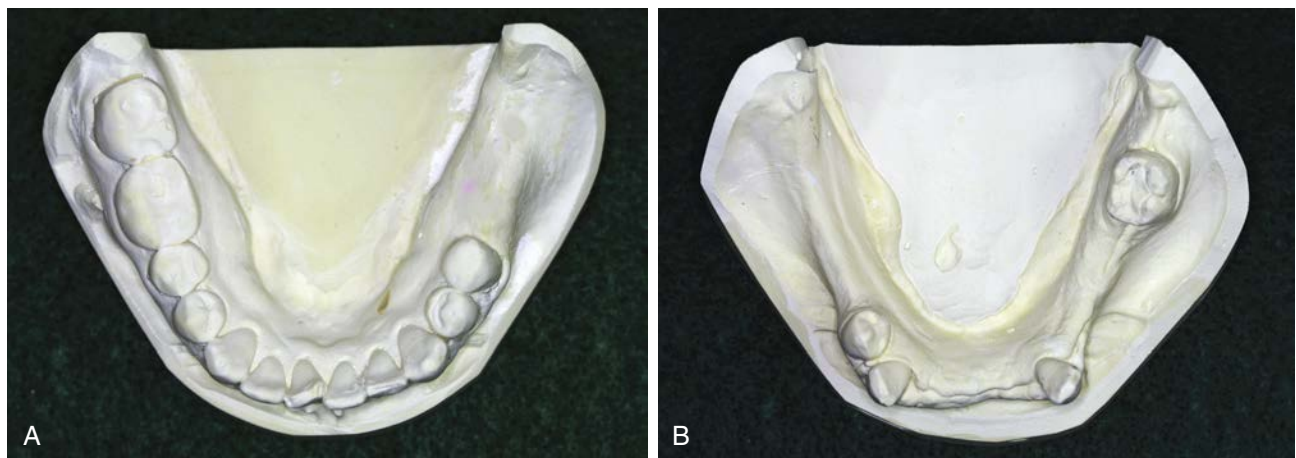
Often the decision must be made to replace unilaterally missing molars (Figure 13-21). The decision must balance the impact of the treatment on the remaining oral structures with the potential benefit to the patient long term. To restore the missing molars with a fixed partial denture would require a cantilever prosthesis or the use of dental implants. A cantilever-fixed prosthesis is most applicable if the second molar is to be ignored, then only first molar occlusion need be supplied with the use of a cantilever-type fixed partial denture. Occlusion need be only minimal to maintain occlusal relations between the natural first molar in the one arch and the prosthetic molar in the opposite arch. The cantilevered pontic should be narrow buccolingually and need not occlude with more than one half to two thirds of the opposing tooth. Often such a restoration is the preferred method of treatment. However, at least two abutments should be used to support a cantilevered molar opposed by a natural molar.

To replace unilaterally missing molars with a removable partial denture necessitates the use of a distal extension prosthesis. This involves the major connector joining the edentulous side to retentive and stabilizing components located on the non-edentulous side of the arch. Leverage factors are frequently unfavorable, and the retainers used on the non-edentulous side are often unsatisfactory. Two factors important to consider in making the decision to provide a unilateral, distal extension removable partial denture include the opposing teeth and the future effect of the maxillary tuberosity.

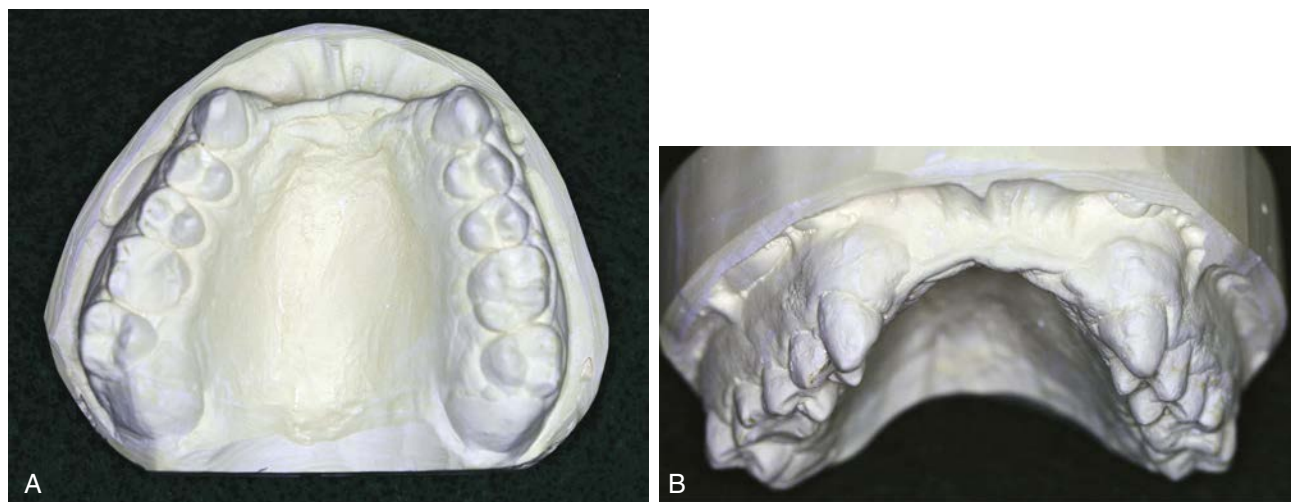
First, the opposing teeth must be considered if it is considered important to prevent extrusion and migration. This



**FIGURE 13-20** A, Diagnostic waxing of this complex case revealed the best means to manage replacement of tooth #6 and tooth #7 was with a fixed prosthesis, especially because the ridge defect was not severe and the adjacent teeth offered good retainer support. B, In contrast, this complex situation requires the maxillary anterior to be repositioned palatally to address an esthetic concern caused by the condition of the maxillary canines and the need to replace the posterior teeth as well. C, The anterior teeth will be more easily managed as part of the removable partial denture. (Courtesy of Dr. M. Alfaro, Columbus, OH.)



**FIGURE 13-21** A, Unilaterally missing molars. If the patient exhibits opposing contacts to the remaining six posterior teeth (bilateral premolars, right first and second molars), functional gain attained by replacing the left molars may be minimal. B, By contrast, the functional gain resulting from replacement of the posterior occlusion in this patient is likely significant.



**FIGURE 13-22** **A**, Occlusal view of the anterior ridge defect (Kennedy Class IV) shows the palatal position of the ridge crest. Incisal edges of opposing dentition require a more labial position, which would create a difficult pontic form. **B**, Labial view of the same cast shows the significance of the vertical bone loss. Replacement of the teeth and ridge anatomy is best accomplished with a removable partial denture.

influences replacement of the missing molars far more than any improvement in masticating efficiency that might result. Replacement of missing molars on one side is seldom necessary for reasons of mastication alone.

Second, the future effect of a maxillary tuberosity must be considered if concern exists for tuberosity enlargement. Often when left uncovered, the tuberosity increases in size, making future occlusal treatment difficult. However, covering the tuberosity with a removable partial denture base, in combination with the stimulating effect of the intermittent occlusion, helps maintain tuberosity size and position. In such an instance, it may be better to make a removable partial denture with cross-arch stabilization and retention than to leave a maxillary tuberosity uncovered.

### Indications for Removable Partial Dentures

Although a removable partial denture should be considered only when a fixed restoration is contraindicated, there are several specific indications for the use of a removable restoration.

#### Distal Extension Situations

Replacement of missing posterior teeth is often best accomplished with a removable partial denture (see [Figure 13-22, B](#)), especially when implant treatment is not feasible for the patient. The exception to this includes situations in which the replacement of missing second (and third) molars is inadvisable or unnecessary, or in which unilateral replacement of a missing first molar can be accomplished by means of a multiple-abutment cantilevered fixed restoration or an implant-supported prosthesis. The most common partially edentulous situations are the Kennedy Class I and Class II. With the latter, an edentulous space on the opposite side of the arch is often conveniently present to aid in required

retention and stabilization of the removable partial denture. If no space is present, selected abutment teeth can be modified to accommodate appropriate clasp assemblies, or intracoronal retainers can be used. As stated previously, all other edentulous areas are best replaced with fixed partial dentures.

#### After Recent Extractions

The replacement of teeth after recent extractions often cannot be accomplished satisfactorily with a fixed restoration. When relining will be required later or when a fixed restoration using natural teeth or implants will be constructed later, a temporary removable partial denture can be used. If an all-resin denture is used rather than a cast framework removable partial denture, the immediate cost to the patient is much less, and the resin denture lends itself best to future temporary modifications, including those required after implant placement and before restoration.

Tissue changes are inevitable following extractions. Tooth-bounded edentulous areas (as a result of extractions) are best initially restored with removable partial dentures. Relining of a tooth-supported resin denture base is then possible. This is usually done to improve esthetics, oral cleanliness, or patient comfort. Support for such a restoration is supplied by occlusal rests on the abutment teeth at each end of the edentulous space.

#### Long Span

A long span may be totally tooth-supported if the abutments and the means of transferring the support to the denture are adequate and if the denture framework is rigid. There is little if any difference between the support afforded a removable partial denture and that afforded a fixed restoration by the adjacent abutment teeth. However, in the absence of

cross-arch stabilization, the torque and leverage on the two abutment teeth would be excessive. Instead, a removable denture that derives retention, support, and stabilization from abutment teeth on the opposite side of the arch is indicated as the logical means of replacing the missing teeth.

### Need for Effect of Bilateral Stabilization

In a mouth weakened by periodontal disease, a fixed restoration may jeopardize the future of the involved abutment teeth unless the splinting effect of multiple abutments is used. The removable partial denture, on the other hand, may act as a periodontal splint through its effective cross-arch stabilizing of teeth weakened by periodontal disease. When abutment teeth throughout the arch are properly prepared and restored, the beneficial effect of a removable partial denture can be far greater than that of a unilateral fixed partial denture.

### Excessive Loss of Residual Bone

The pontic of a fixed partial denture must be correctly related to the residual ridge and in such a manner that the contact with the mucosa is minimal. Whenever excessive resorption has occurred, teeth supported by a denture base may be arranged in a more acceptable buccolingual position than is possible with a fixed partial denture (Figure 13-22).

Unlike a fixed partial denture, the artificial teeth supported by a denture base can be located without regard for the crest of the residual ridge and more nearly in the position of the natural dentition for normal tongue and cheek contacts. This is particularly true of a maxillary denture.

Anteriorly, loss of residual bone occurs from the labial aspect. Often the incisive papilla lies at the crest of the residual ridge. Because the central incisors are normally located anterior to this landmark, any other location of artificial central incisors is unnatural. An anterior fixed partial denture made for such a mouth will have pontics contacting the labial aspect of this resorbed ridge and will be too far lingual to provide desirable lip support. Often the only way the incisal edges of the pontics can be made to occlude with the opposing lower anterior teeth is to use a labial inclination that is excessive and unnatural, and both esthetics and lip support suffer. Because the same condition exists with a removable partial denture in which the anterior teeth are abutted on the residual ridge, a labial flange must be used to permit the teeth to be located closer to their natural position.

The same method of treatment applies to the replacement of missing mandibular anterior teeth. Sometimes a mandibular anterior fixed partial denture is made six or more units in length, in which the remaining space necessitates leaving out one anterior tooth or using the original number of teeth but with all of them too narrow for esthetics. In either instance, the denture is nearly in a straight line because the pontics follow the form of the resorbed ridge. A removable partial denture will permit the location of the replaced teeth in a favorable relation to the lip and

opposing dentition regardless of the shape of the residual ridge. When such a removable prosthesis is made, however, positive support must be obtained from the adjacent abutments.

### Unusually Sound Abutment Teeth

Sometimes the reasoning for making a removable restoration is the desire to see sound teeth preserved in their natural state and not prepared for restorations. As mentioned previously, if this decision is made because it is felt that no tooth modification is necessary for removable partial dentures, then the prosthesis will lack tooth-derived stability and support.

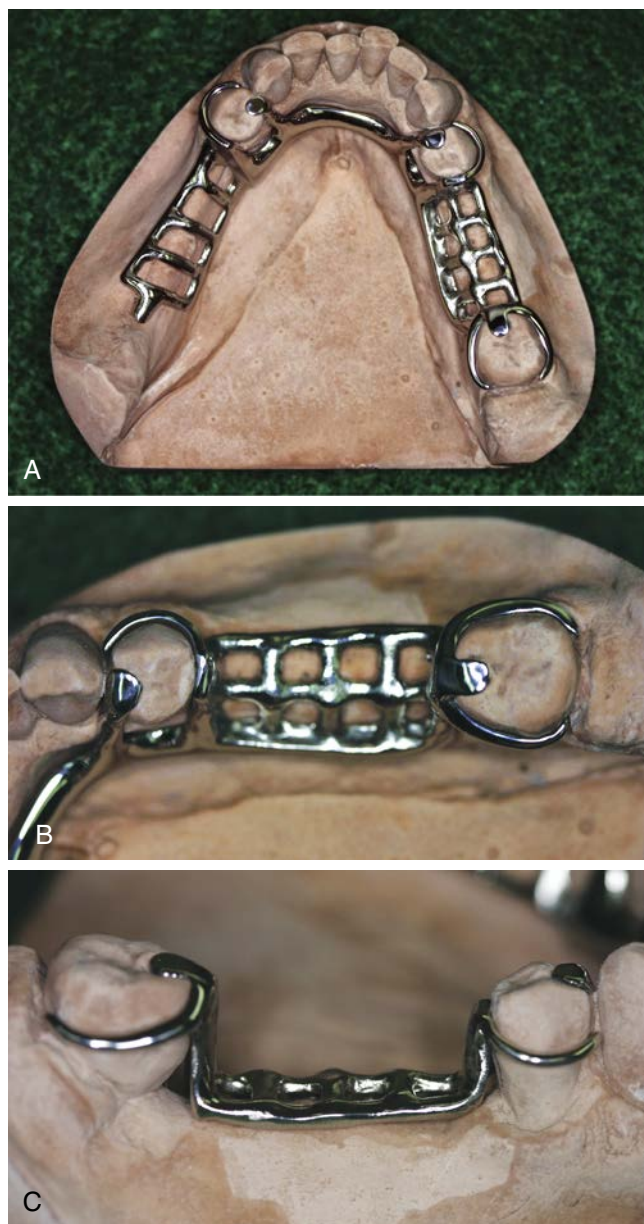When this condition exists, the dentist should not hesitate to reshape and modify existing enamel surfaces to provide proximal guiding planes, occlusal rest areas, optimum retentive areas, and surfaces on which nonretentive stabilizing components may be placed. Continued durability of the natural teeth is best ensured if the modifications that optimize prosthesis function are provided. This is due to the fact that such modifications also ensure the most harmonious use of the natural dentition.

### Abutments with Guarded Prognoses

If the prognosis of an abutment tooth is questionable or if it becomes unfavorable while under treatment, it might be possible to compensate for its impending loss by a change in denture design. The questionable or condemned tooth or teeth may then be included in the original design and, if subsequently lost, the removable partial denture can be modified or remade (Figure 13-23). Most removable partial denture designs do not lend themselves well to later additions, although this eventuality should be considered in the design of the denture.

When the tooth in question will be used as an abutment, every diagnostic aid should be used to determine its prognosis as a prospective abutment. It is usually not as difficult to add a tooth or teeth to a removable partial denture as it is to add a retaining unit when the original abutment is lost and the next adjacent tooth must be used for that purpose.

It is sometimes possible to design a removable partial denture so that a single posterior abutment, about which there is some doubt, can be retained and used at one end of the tooth-supported base. Then if the posterior abutment is lost, it could be replaced by adding an extension base to the existing denture framework. Such an original design must include provisions for future indirect retention, flexible clasping of the future abutment, and provisions for establishing tissue support. Anterior abutments that are considered poor risks may not be so freely used because of the problems involved in adding a new abutment retainer when the original one is lost. It is rational that such questionable teeth should be condemned in favor of more suitable abutments, even though the original treatment plan must be modified accordingly.



**FIGURE 13-23** Kennedy Class II, modification 1, where the molar abutment has a guarded prognosis. **A**, Anterior abutment of the modification space has a clasp assembly that accommodates for potential future loss of the distal molar while currently providing adequate support, stability, and retention. **B**, Premolar clasp assembly comprises a mesial rest, a distal guide plane, and a wrought-wire retainer design, which will accommodate future distal extension movement. **C**, Buccal view shows guide-plane contact and a wrought-wire location that is appropriate for a distal extension.

### Economic Considerations

Economics should not be the sole criterion used to arrive at a method of treatment. When, for economic reasons, complete treatment is out of the question and yet replacement of missing teeth is indicated, the restorative procedures dictated by these considerations must be described clearly to the patient

as a compromise and not as representative of the best that modern dentistry has to offer. A prosthesis that is made to satisfy economic considerations alone may provide only limited success and result in more costly treatment in the future.

### CHOICE BETWEEN COMPLETE DENTURES AND REMOVABLE PARTIAL DENTURES

One of the more difficult decisions to make for the partially edentulous patient involves making the choice of a complete denture over a removable partial denture. Many factors need to be considered when one is making such a decision; these generally fall under the categories of tooth-related factors, factors of comparative functional expectations between prostheses, and patient-specific factors. Because the difference between a tooth-tissue-born prosthesis and a tissue-born prosthesis can be significant, especially because it is difficult for the partially edentulous patient to conceptualize the tissue-born situation, such an irreversible decision is not trivial.

An evaluation of the remaining teeth determines whether any caries or periodontal disease exists. The decision as to whether a tooth is useful for inclusion in a prosthetic treatment plan can be made on the basis of an understanding that with appropriate disease management, the tooth provides a reasonable 5-year prognosis for survival. This takes into account the added functional demand by the prosthesis and a risk assessment for recurrent disease. Because this scenario concerns teeth with disease, the expectation is that tooth structure and/or support is compromised. The added functional burden, along with a potentially increased risk for disease, is an important concern when one is determining the long-term benefit for retaining teeth with a removable partial denture.

If the teeth can be maintained with a reasonable prognosis, the next questions to ask are: “Do they require restoration with surveyed crowns?” and “How much improvement to the prosthesis support, stability, and retention do they provide?” If the expected prognosis for a given tooth is questionable, the costs associated with restoration high, and the added benefit to the prosthesis low, the tooth should likely not be maintained unless the patient strongly desires to maintain all teeth. However, if the same scenario exists and the long-term impact on the support, stability, and retention of the prosthesis is great, the decision strongly favors keeping the tooth.

The question of whether retained teeth offer a significant advantage to the prosthesis from a support, stability, and retention standpoint requires comparative evaluation of potential denture-bearing foundations. If the expectation is that an edentulous arch would have unfavorable physical features (poor ridge form, poor arch configuration, displaceable mucosa, high frena attachments, minimum denture bearing area, and/or an unfavorable jaw relationship), then retention of teeth is likely to provide a more significant benefit. If retention of teeth can help to prevent or delay age-related denture-bearing foundation changes seen with complete denture use, then retention of teeth can be of significant benefit.

When evaluation demonstrates that the remaining teeth have no active disease, then the often-negative impact of disease management on prognosis is not a concern. The decision to maintain teeth is again based on risk assessment, costs for use of the teeth, added benefit to prosthesis functional stability, and comparative functional expectations between a mucosal-borne denture and a removable partial denture that uses teeth for some support, stability, and retention.

The remaining tooth location and distribution can also affect the decision to maintain teeth. It makes a difference whether the remaining teeth are located on only one side of the arch. Having bilateral teeth remaining, especially if they are in similar locations (canines-canines, canines/premolars-canines/premolars), offers advantages for prosthesis design and occlusal development compared with asymmetrical tooth locations. Some teeth may not serve well as a stabilizing component for a removable partial denture and should not be maintained. If the remaining terminal tooth adjacent to a distal extension base is an incisor, the likelihood of long-term support, stability, and retention is poor.

An additional factor for consideration when one is deciding between a complete denture and a removable partial denture is whether there is a strong patient desire to maintain teeth. As mentioned previously, because the change to a complete denture is a significant transformation, sufficient discussion must take place before this decision is made. The dentist must be very clear that the patient understands the functional differences between a mucosal-borne prosthesis for all aspects of function (i.e., chewing, talking, and so on) and the natural dentition or a removable partial denture.

The uniqueness of the patient is again appreciated as these issues are discussed with the patient. One patient may prefer complete dentures rather than complete oral rehabilitation, regardless of ability to pay. Another may be so determined to keep his own teeth that he will make great financial sacrifice if given a reasonable assurance of success of oral rehabilitation. Listening to the patient during the examination and the diagnostic procedures pays off significantly when the treatment options differ so vastly as complete and removable partial dentures often do. During the presentation of pertinent facts, time should be allowed for patients to express themselves freely as to their desires in retaining and restoring their natural teeth. At this time, a treatment plan may be influenced or even drastically changed to conform to the expressed and implied wishes of the patient. For example, there may be a reasonable possibility of saving teeth in both arches through the use of removable partial dentures. With only anterior teeth remaining, a removable partial denture can be made to replace the posterior teeth with the use of good abutment support and, in the maxillary arch, use of full palatal coverage for retention and stability. If patients express a desire to retain their anterior teeth at any cost, and if the remaining teeth are esthetically acceptable and functionally sound, the dentist should make every effort to provide successful treatment. If patients prefer a mandibular removable

partial denture because of fear of difficulty in wearing a mandibular complete denture, then (all factors being acceptable) their wishes should be respected and treatment should be planned accordingly. The professional obligation to present the facts and then do the best that can be done in accordance with the patients' expressed desires still applies.

Other patients may wish to retain remaining teeth for an indefinite but relatively short period of time, with eventual complete dentures a foregone conclusion. In this instance, the professional obligation may be to recommend interim removable partial dentures without extensive mouth preparation. Such dentures will aid in mastication and will provide esthetic replacements, at the same time serving as conditioning restorations, which will make the later transition to complete dentures somewhat easier. Such removable partial dentures should be designed and fabricated with care, but the total cost of removable partial denture service should be considerably less.

An expressed desire on the part of patients to retain only six mandibular anterior teeth must be considered carefully before this is agreed to as the planned treatment. The advantages for patients are obvious: (1) they may retain six esthetically acceptable teeth; (2) they do not become totally edentulous; and (3) they have the advantages of direct retention for the removable partial denture that would not be possible if they were completely edentulous. Retaining even the mandibular canine teeth would accomplish the latter two objectives. Potential disadvantages relate directly to the patient keeping up with prosthesis maintenance procedures. The disadvantages relate to the poor response of the anterior maxilla to functional stress concentrated from the opposing natural dentition. If the functional forces of occlusion are not well distributed, the natural anterior can concentrate stress to the anterior maxillary arch. The possible result of such poorly distributed functional force includes the loss of residual maxillary bone, loosening of the maxillary denture caused by the tripping influence of the natural mandibular teeth, and loss of the basal foundation for the support of future prostheses. However, if the maxillary anterior teeth are arranged to contact in balanced eccentric positions and if patients comply with periodic recall to maintain these relationships, these problems are minimized. Prevention of this sequence of events lies in the maintenance of positive occlusal support posteriorly and the continual elimination of traumatic influence from the remaining anterior teeth. Such support is sometimes impossible to maintain without frequent relining or remaking of the lower removable partial denture base. The presence of inflamed hyperplastic tissue is a frequent sequela to continued loss of support and denture movement.

Although some patients are able to successfully function with a lower removable partial denture supported only by anterior teeth against a complete maxillary denture, it is likely that undesirable consequences will result unless the patient faithfully follows the instructions of the dentist. In no other situation in treatment planning are the general health of the patient and the quality of residual alveolar bone as critical as they are in this situation.

## CLINICAL FACTORS RELATED TO METAL ALLOYS USED FOR REMOVABLE PARTIAL DENTURE FRAMEWORKS

The cast framework offers significant advantages over the all acrylic-resin removable partial denture. In general, the ability to predictably utilize the remaining teeth for support, stability, and retention over time is best assured when the interface between prosthesis and teeth consists of a cast structure and not a polymer. Although the utility of all acrylic-resin prostheses can be extended if wire “rests” are provided, typical polymer properties do not allow for a durable interface, which is required if one is to take advantage of the stabilizing effects of tooth contact. Expectations of how the metal framework improves functional performance are related to the properties of the metal alloy. Various alloys can be considered for use. Following is a discussion of the most common framework alloys in use today.

Practically all cast frameworks for removable partial dentures are made from a chromium-cobalt (Cr-Co) alloy. The popularity of chromium-cobalt alloys has been attributed to their low density (weight), high modulus of elasticity (stiffness), low material cost, and resistance to tarnish. The term *stellite alloy* historically has referred to this class of alloy. Today the more common alloys contain 60% to 63% Co, 29% to 31.5% Cr, and 5% to 6% molybdenum (Mo), with the balance including silicon (Si), manganese (Mn), iron (Fe), nitrogen (N), and carbon (C). The addition of controlled amounts of nitrogen (<0.5%) is reported to improve physical properties. Titanium is also used as a removable partial denture frame material; however, production difficulties continue to hinder its widespread use. The dentist should become familiar with the alloy used by her/his laboratory and should closely monitor fit, density, and rigidity.

The following are comparable characteristics of gold alloys and chromium-cobalt alloys: (1) each is well tolerated by oral tissues; (2) they are equally acceptable esthetically; (3) enamel abrasion by either alloy is insignificant on vertical tooth surfaces; (4) a low-fusing chrome-cobalt alloy or gold alloy can be cast to wrought wire, and wrought-wire components may be soldered to either gold or chrome-cobalt alloys (these characteristics are important in overcoming the objection by some dentists to the increased stiffness of chromium-cobalt alloys for the portions of direct retainers that must engage an undercut of the abutment tooth); (5) the accuracy obtainable in casting either alloy is clinically acceptable under strictly controlled investing and casting procedures; and (6) soldering procedures for the repair of frameworks can be performed on each alloy.

### Comparative Physical Properties of Gold and Chromium-Cobalt

Chromium-cobalt alloys generally have less yield strength when compared with gold alloys used for removable partial dentures. Yield strength is the greatest amount of stress an alloy will withstand and still return to its original shape in an

unweakened condition. Possessing a lower proportional limit, the chromium-cobalt alloys will deform permanently at lower loads than gold alloys. Therefore the dentist must design the chromium-cobalt framework so that the degree of deformation expected in a direct retainer is less than a comparable degree of deformation for a gold component. The *modulus of elasticity* refers to the stiffness of an alloy. Gold alloys have a modulus of elasticity approximately one-half that for chromium-cobalt alloys for similar uses. The greater stiffness of the chromium-cobalt alloy is advantageous but at the same time offers disadvantages. Greater rigidity can be obtained with the chromium-cobalt alloy in reduced sections in which cross-arch stabilization is required, thereby eliminating an appreciable bulk of the framework. Its greater rigidity is also an advantage when the greatest undercut that can be found on an abutment tooth is in the nature of 0.05 inch. A gold retentive element would not be as efficient in retaining the restoration under such conditions as would the chromium-cobalt clasp arm.

High yield strength and low modulus of elasticity produce greater flexibility. The gold alloys are approximately twice as flexible as the chromium-cobalt alloys; in many instances, this provides a distinct advantage in the optimum location of retentive elements of the framework. The greater flexibility of the gold alloys usually permits location of the tips of retainer arms in the gingival third of the abutment tooth. The stiffness of chromium-cobalt alloys can be overcome by including wrought-wire retentive elements in the framework.

The bulk of a retentive clasp arm for a removable partial denture is often reduced for greater flexibility when chromium-cobalt alloys are used as opposed to gold alloys. This, however, is inadvisable because the grain size of chromium-cobalt alloys is usually larger and is associated with a lower proportional limit, and so a decrease in the bulk of chromium-cobalt cast clasps increases the likelihood of fracture or permanent deformation. The retentive clasp arms for both alloys should be approximately the same size, but the depth of undercut used for retention must be reduced by one half when chromium-cobalt is the choice of alloys. Chromium-cobalt alloys are reported to work/harden more rapidly than gold alloys, and this, associated with coarse grain size, may lead to failure in service. When adjustments by bending are necessary, they must be executed with extreme caution and limited optimism.

Chromium-cobalt alloys have a lower density (weight) than gold alloys in comparable sections and therefore are about one half as heavy as gold alloys. The weight of the alloy in most instances is not a valid criterion for selection of one metal over another because after placement of a removable partial denture, the patient seldom notices the weight of the restoration. The comparable lightness of chromium-cobalt alloys, however, is an advantage when full palatal coverage is indicated for the bilateral distal extension removable partial denture. Weight is a factor that must be considered when the force of gravity must be overcome, so that usually passive direct retainers will not be activated constantly to the detriment of abutment teeth.

The hardness of chromium-cobalt alloys presents a disadvantage when a component of the framework, such as a rest, is opposed by a natural tooth or by one that has been restored. We have observed more wear of natural teeth opposed by some of the various chromium-cobalt alloys as contrasted with type IV gold alloys.

It has been observed that gold frameworks for removable partial dentures are more prone to produce uncomfortable galvanic shock to abutment teeth restored with silver amalgam than are frameworks made of chromium-cobalt alloy. This may not be a valid criterion for the selection of a particular alloy when the dentist has complete control over the choice of restorative materials.

Commercially pure (CP) titanium and titanium in alloys containing aluminum and vanadium, or palladium (Ti-O Pd), should be considered potential future materials for removable partial denture frameworks. Their versatility and well-known biocompatibility are promising; however, long-term clinical trials are needed to validate their potential usefulness. Currently, when CP titanium is cast under dental conditions, the material properties change dramatically. During the casting procedure, the high affinity of the liquid metal for elements such as oxygen, nitrogen, and hydrogen results in their incorporation from the atmosphere. As interstitial alloying elements, their deleterious effect on mechanical properties is a problem. Also, reactions between molten titanium metal and the investment refractory produce gases, which cause porosity. With alpha-beta alloys, such as Ti-6Al-4V, a surface skin of alpha titanium can form (alpha-case zone), which has a tremendous effect on electrochemical behavior and mechanical properties. This could be important for small thin structures, such as clasp assemblies and major and minor connectors. The CP grades of titanium have yield strengths that are too low for clinical use as clasps (450 MPa minimum), although the ductility is high. The much higher yield strengths of the Ti-6Al-4V alloys are the same as that of a typical bench-cooled cobalt-chromium alloy but with far superior ductility. The typical Young's modulus of elasticity of titanium alloy is half that of cobalt-chromium and just slightly higher than that of type IV gold alloys. This would require a different approach to clasp design than is used with cobalt-chromium alloys and would present some advantages. Wrought titanium alloy wires are also flexible because of the same low elastic modulus. Beta alloys, which are used in orthodontics, have two-thirds the elastic modulus of CP titanium and Ti-6Al-4V. The joining of titanium by brazing is a problem because like-casting inert atmospheres must be used. The corrosion and fatigue behavior of brazed joints has yet to be tested for long-term corrosion resistance and clinical efficacy. Clinical use has demonstrated reasonable short-term results, but laboratory fabrication difficulties need to be addressed, and long-term advantages over existing alloys must be demonstrated before titanium will gain broad clinical use.

### Wrought Wire: Selection and Quality Control

Wrought-wire direct retainer arms may be attached to the restoration by embedding a portion of the wire in a resin



**FIGURE 13-24** The wrought-wire retainer arm has been contoured to design and incorporated into the wax pattern of this frame where it will become an integral part of the framework. The wire is contoured in two planes and will be mechanically retained in the casting.

denture base, by soldering to the fabricated framework, or by casting the framework to a wire embedded in the wax pattern (Figure 13-24). The physical (mechanical) properties of available wrought wires are most important considerations when a proper wire for the desired method of attachment is selected. These properties include yield strength or proportional limit, percentage elongation, tensile strength, and fusion temperature. After the wire is selected, the procedures to which the wire is subjected in fabricating the restoration become critical. Improper laboratory procedures can diminish certain desirable physical properties of the wrought structure, rendering it relatively useless for its intended purpose. For example, when wrought wire is heated (such as in a cast-to or soldering procedure), its physical properties and microstructure may be considerably altered, depending on temperature, heating time, and cooling operation. All manufacturers of wrought forms for dental applications furnish charts listing their products and the physical properties of each product. The percentage of noble metals is given. In addition, most manufacturers designate wires that may be used in a cast-to procedure. ADA Specification No. 7 addresses itself to wrought gold wire in terms of both content and minimum physical properties (Table 13-1).

The tensile strength of the wrought structure is approximately 25% greater than that of the cast alloy from which it was made. The wrought structure's hardness and strength are also greater. This means that a wrought structure that has a smaller cross section than a cast structure may be used as a retainer arm (retentive) to perform the same function. It has been suggested that minimum yield strength of 60,000 psi is required for the retentive element of a direct retainer. A percentage elongation of less than 6% is indicative that a wrought wire may not be amenable to contouring without attendant undesirable changes in microstructure.

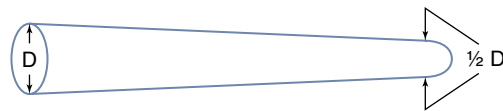
TABLE 13-1

## Comparative Specifications Contained in American Dental Association Specification No. 7

	Type I	Type II
Content of metals of the gold, platinum group (minimum)	75%	65%
Minimum fusion temperature	1742° F	1898° F
Minimum yield point value (hardened or oven cooled)	125,000 psi	95,000 psi
Minimum elongation (hardened)	4%	2%
Minimum elongation (softened)	15%	15%

psi, Pounds per square inch.

Regardless of the method of attaching the wrought-wire retainer that is used (that is, embedding, soldering, or cast-to), tapering the wrought arm seems most rational. A retainer arm is in essence a cantilever that can be made more serviceable and efficient by tapering. Tapering to 0.8 mm permits more uniform distribution of service stresses throughout the length of the arm, being readily demonstrated by photoelastic stress analysis. Uniform tapering of an 18-gauge, round wire arm can be accomplished by rapidly rotating the wire in angled contact with an abrasive disk in the dental lathe. It



**FIGURE 13-25** Round, 18-gauge wrought wire for the retentive component of the direct retainer assembly (clasp) is uniformly tapered to 0.8 mm from its full diameter to its terminus. Tapering should precede contouring of the wire for the retainer arm.

is then polished by rotating the wire in angled contact with a mildly abrasive rubber disk in the dental lathe. The appropriate taper is shown in Figure 13-25.

## SUMMARY

In selecting materials, it must be remembered that fundamentals do not change. These are inviolable. It is only methods, procedures, and substances—by which the dentist affects the best possible end result—that change. The responsibility of the decision still rests with the dentist, who must evaluate all factors in relation to the results desired. In any instance therefore, the dentist must weigh the problems involved, compare and evaluate the characteristics of different potential materials, and then make a decision that leads to delivery of the greatest possible service to the patient.

# سایت کنکور

## WWW.KONKUR.IN

مرجع دانلود رایگان کتب علوم پزشکی و مهندسی  
آرشیو کامل و رایگان کنکورهای ارشد، دکتری و آزمونهای مقاطع و گرایشهای مختلف علوم پزشکی

# CHAPTER

# 14

## Preparation of the Mouth for Removable Partial Dentures

### CHAPTER OUTLINE

#### Pre-Prosthetic Considerations in Partially Edentulous

##### Mouths

- Extractions
- Impacted Teeth
- Malposed Teeth
- Cysts and Odontogenic Tumors
- Exostoses and Tori
- Hyperplastic Tissue
- Muscle Attachments and Frena
- Bony Spines and Knife-Edge Ridges
- Polyps, Papillomas, and Traumatic Hemangiomas
- Hyperkeratoses, Erythroplasia, and Ulcerations
- Dentofacial Deformity
- Dental Implants
- Augmentation of Alveolar Bone

#### Periodontal Preparation

- Objectives of Periodontal Therapy
- Periodontal Diagnosis and Treatment Planning
- Initial Disease Control Therapy (Phase 1)
- Definitive Periodontal Surgery (Phase 2)
- Recall Maintenance (Phase 3)
- Advantages of Periodontal Therapy

#### Optimization of the Foundation for Fitting and Function of the Prosthesis

- Conditioning of Abused and Irritated Tissues
- Use of Tissue Conditioning Materials
- Abutment Restorations
- Contouring Wax Patterns
- Rest Seats

The preparation of the mouth is fundamental to a successful removable partial denture service. Mouth preparation, perhaps more than any other single factor, contributes to the philosophy that the prescribed prosthesis not only must replace what is missing but also must preserve the remaining tissues and structures that will enhance the removable partial denture. Because of the significant and favorable impact dental implants can have on preservation of oral tissues and structures when used with removable partial dentures, it is common to include discussion of dental implants when considering mouth preparation for removable prostheses.

Mouth preparation follows the preliminary diagnosis and the development of a tentative treatment plan. Final treatment planning may be deferred until the response to the preparatory procedures can be ascertained. In general, mouth preparation includes procedures that address conditions that put comfortable prosthetic function at risk and include tooth alteration that are required to for proper tooth stabilization and support of the prosthesis. The objectives of the procedures involved are to create optimum health and eliminate or alter any condition that would be detrimental to the functional success of the removable partial denture.

Naturally, mouth preparation must be accomplished before the impression procedures are performed that will produce the master cast on which the removable partial denture will be fabricated. Oral surgical and periodontal procedures should precede abutment tooth preparation and should be completed far enough in advance to allow the necessary healing period. If at all possible, at least 6 weeks (and preferably 3 to 6 months) should be provided between surgical and restorative dentistry procedures. This depends on the extent of the surgery and its impact on the overall support, stability, and retention of the proposed prosthesis.

## PRE-PROSTHETIC CONSIDERATIONS IN PARTIALLY EDENTULOUS MOUTHS

As a rule, all pre-prosthetic surgical treatment for the removable partial denture patient should be completed as early as possible. When possible, necessary endodontic surgery, periodontal surgery, and oral surgery should be planned so that they can be completed during the same time frame. The longer the interval between the surgery and the impression procedure, the more complete the healing and consequently the more stable the denture-bearing areas.

A variety of oral surgical techniques can prove beneficial to the clinician in preparing the patient for prosthetic replacements. However, it is not the purpose of this section to present the details of surgical correction. Rather, attention is called to some of the more common oral conditions or changes in which surgical intervention is indicated as an aid to removable partial denture design and fabrication and as an aid to the successful function of the restoration. Additional information regarding the techniques used is available in oral surgery texts and journal publications. It is important to emphasize, however, that the dentist who is providing the removable partial denture treatment bears the responsibility for ensuring that the necessary surgical procedures are accomplished in accordance with the treatment plan. Measures to control apprehension, including the use of intravenous and inhalation agents, have made the most extensive surgery acceptable to patients. Whether the dentist chooses to perform these procedures or elects to refer the patient to someone more qualified is immaterial. The important consideration is that the patient should not be deprived of any treatment that would enhance the success of the removable partial denture.

### Extractions

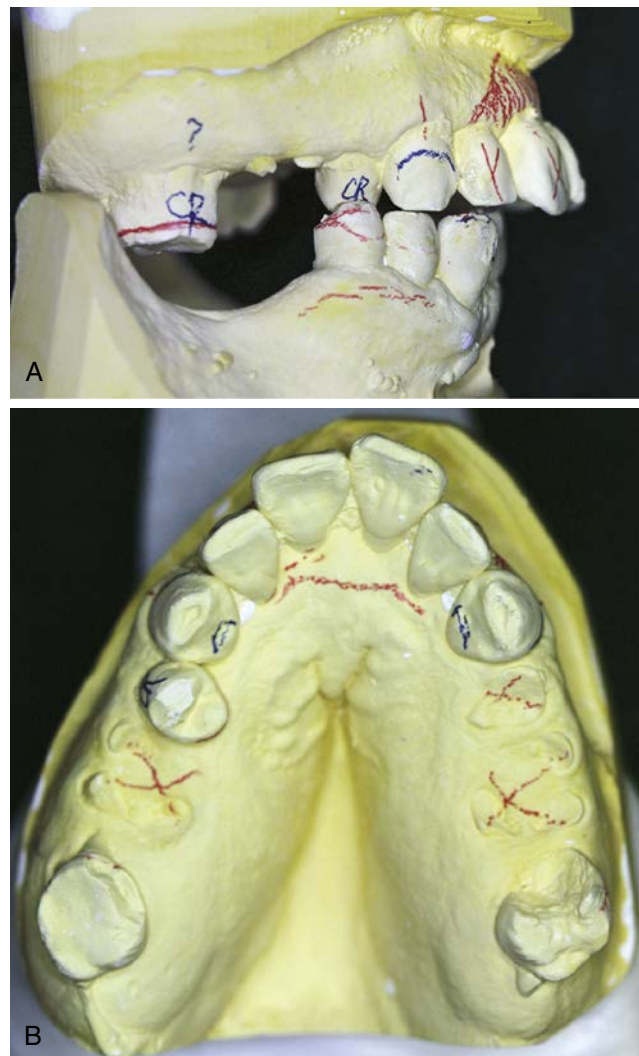
Planned surgical procedures should occur early in the treatment regimen but not before a careful and thorough evaluation of each remaining tooth in the dental arch is completed (Figure 14-1). Regardless of its condition, each tooth must be evaluated in terms of its strategic importance and its potential contribution to the success of the removable partial denture. Extraction of nonstrategic teeth that would present complications or those that may be detrimental to the design of the removable partial denture is a necessary part of the overall treatment plan.

### Impacted Teeth

All impacted teeth, including those in edentulous areas, as well as those adjacent to abutment teeth, should be considered for removal. The periodontal implications of impacted teeth adjacent to abutments are similar to those for retained roots. These teeth are often neglected until serious periodontal implications arise.

### Malposed Teeth

The loss of individual teeth or groups of teeth may lead to extrusion, drifting, or combinations of malpositioning of remaining teeth (Figure 14-2). In most instances, the alveolar



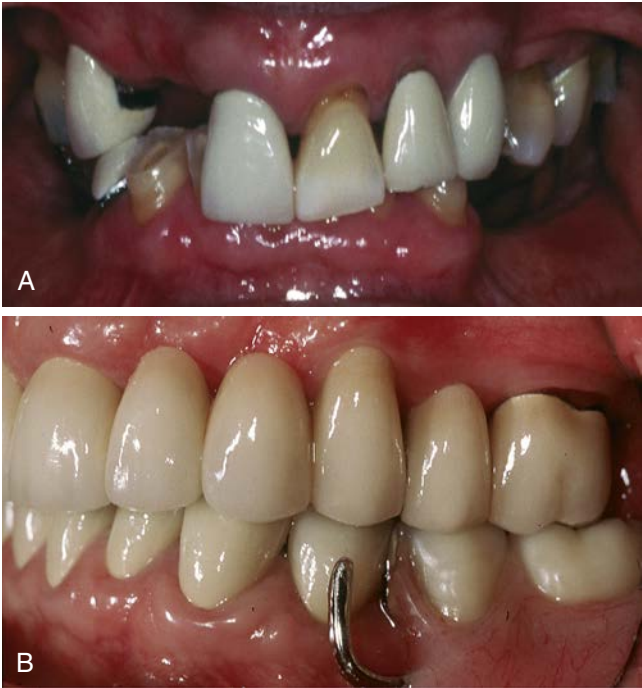**FIGURE 14-1** Diagnostic mounting allows confirmation of the need for extraction after clinical examination. **A**, Anterior tooth position and chronic periodontal disease status require extraction to address the patient's concern of malpositioned and painful teeth. **B**, Root tips require immediate extraction to allow ridge healing to begin. The status of the molar (#15) requires additional workup to determine pulpal involvement of the carious lesion and the extent of occlusal reduction required to optimize the occlusal plane. The decision to maintain this tooth, although potentially costly, must consider the stabilizing effect it will have on the posterior left functional occlusion.

bone supporting extruded teeth will be carried occlusally as the teeth continue to erupt. Orthodontics may be useful in correcting many occlusal discrepancies, but for some patients, such treatment may not be practical because of lack of teeth for anchorage of the orthodontic appliances, cost, time to accomplish the treatment, or for other reasons.

### Cysts and Odontogenic Tumors

Panoramic radiographs of the jaws are recommended to survey the jaws for unsuspected pathologic conditions. When

a suspicious area appears on the survey film, a periapical radiograph should be taken to confirm or deny the presence of a lesion. All radiolucencies or radiopacities observed in the jaws should be investigated. Although the diagnosis may appear obvious from clinical and roentgenographic examinations, the dentist should confirm the diagnosis through appropriate consultation and, if necessary, perform a biopsy of the area and submit the specimens to a pathologist for microscopic study. The patient should be informed of the diagnosis and provided with various options for resolution of the abnormality as confirmed by the pathologist's report.



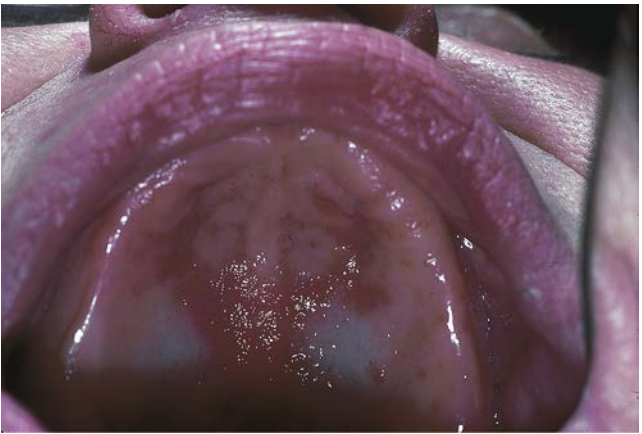**FIGURE 14-2** A, Malpositioned maxillary dentition due to loss of posterior occlusion and excessive wear of opposing mandibular anterior teeth. B, Restored dentition made possible by a combination of endodontics, periodontics, and fixed and removable partial prosthodontics. (Courtesy of Dr. M. Alfaro, Columbus, OH.)

Exostoses and Tori

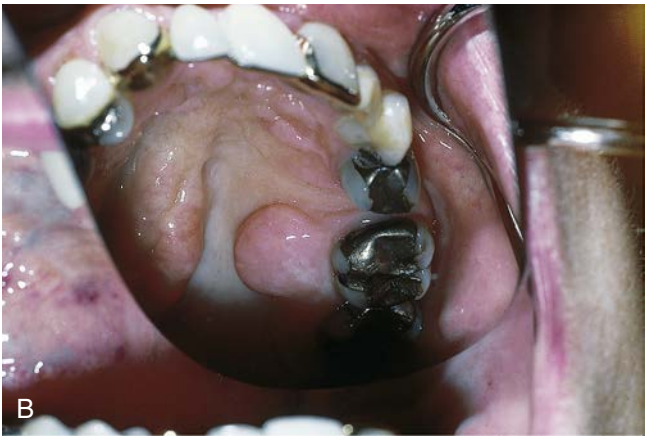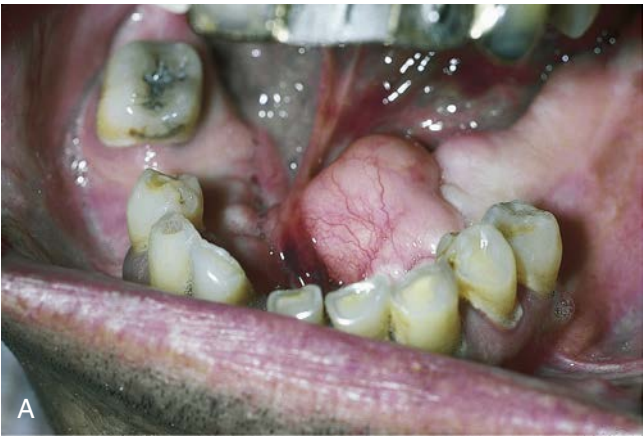The existence of abnormal bony enlargements should not be allowed to compromise the design of the removable partial denture (Figure 14-3). Although modification of denture design can, at times, accommodate for exostoses, more frequently this results in additional stress to the supporting elements and compromised function. The removal of exostoses and tori is not a complex procedure, and the advantages to be realized from such removal are great in contrast to the deleterious effects that their continued presence can create. Ordinarily, the mucosa covering bony protuberances is extremely thin and friable. Removable partial denture components in proximity to this type of tissue may cause irritation and chronic ulceration. Also, exostoses approximating gingival margins may complicate the maintenance of periodontal health and lead to the eventual loss of strategic abutment teeth.

Hyperplastic Tissue

Hyperplastic tissues are seen in the form of fibrous tuberosities, soft flabby ridges, folds of redundant tissue in the vestibule or floor of the mouth, and palatal papillomatosis (Figure 14-4). All these forms of excess tissue should



**FIGURE 14-4** Hyperplasia fibrous tuberosities.



**FIGURE 14-3** Tori and exostoses.

be removed to provide a firm base for the denture. This removal will produce a more stable denture, will reduce stress and strain on the supporting teeth and tissues, and will provide a more favorable orientation of the occlusal plane and arch form for the arrangement of the artificial teeth in many instances. Appropriate surgical approaches should not reduce vestibular depth. Hyperplastic tissue can be removed with any preferred combination of scalpel, curette, electrosurgery, or laser. Some form of surgical stent should always be considered for these patients so that the period of healing is more comfortable. An old removable partial denture that is properly modified can serve as a surgical stent.

### Muscle Attachments and Frena

As a result of the loss of bone height, muscle attachments may insert on or near the residual ridge crest. The mylohyoid, buccinator, mentalis, and genioglossus muscles are most likely to introduce problems of this nature. In addition to the problem of the attachments of the muscles themselves, the mentalis and genioglossus muscles occasionally produce bony protuberances at their attachments that may also interfere with removable partial denture design. Appropriate ridge extension procedures can reposition attachments and remove bony spines, which will enhance the comfort and function of the removable partial denture.

The maxillary labial and mandibular lingual frena are the most common sources of frenum interference with denture design. These can be modified easily through any of several surgical procedures. Under no circumstances should a frenum be allowed to compromise the design or comfort of a removable partial denture.

### Bony Spines and Knife-Edge Ridges

Sharp bony spicules should be removed and knifelike crests gently rounded. These procedures should be carried out with minimum bone loss. However, use of a dental implant can effectively enhance functional comfort in such an instance.

### Polyps, Papillomas, and Traumatic Hemangiomas

All abnormal soft tissue lesions should be excised and submitted for pathologic examination before a removable partial denture is fabricated. Even though the patient may relate a history of the condition having been present for an indefinite period, its removal is indicated. New or additional stimulation to the area introduced by the prosthesis may produce discomfort or undesirable changes in the tumor.

### Hyperkeratoses, Erythroplasia, and Ulcerations

All abnormal white, red, or ulcerative lesions should be investigated, regardless of their relationship to the proposed denture base or framework. A biopsy of areas larger than 5 mm should be completed; and if the lesions are large (over 2 cm in diameter), multiple biopsies should be taken. The biopsy report determines whether the margins of the tissue to be excised can be wide or narrow. The lesions should be

removed and healing accomplished before the removable partial denture is fabricated. On occasion, such as after irradiation treatment or the excoriation of erosive lichen planus, the removable partial denture design will have to be radically modified to avoid areas of possible sensitivity.

### Dentofacial Deformity

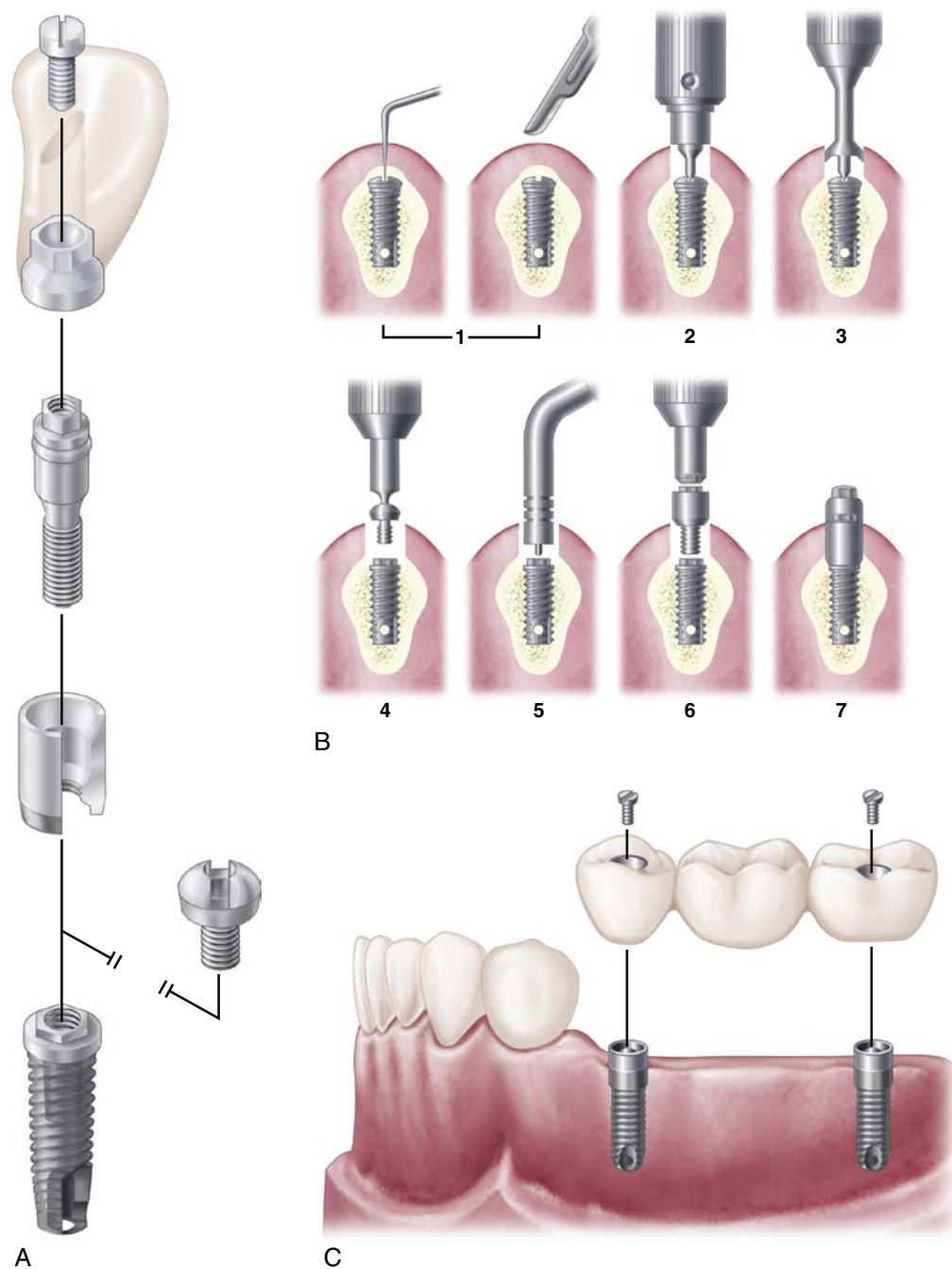
Patients with a dentofacial deformity often have multiple missing teeth as part of their problem. Correction of the jaw deformity can simplify the dental rehabilitation. Before specific problems with the dentition can be corrected, the patient's overall problem must be evaluated thoroughly. Several dental professionals (prosthodontist, oral surgeon, periodontist, orthodontist, and/or general dentist) may play a role in the patient's treatment. These individuals must be involved in producing the diagnostic database and in planning treatment for the patient. Information obtained from a general patient evaluation done to determine the patient's health status, a clinical evaluation directed toward facial esthetics and the status of the teeth and oral soft tissues, and analysis of appropriate diagnostic records can be used to produce a database. From this database, the patient's problems can be enumerated, with the most severe problem being placed at the top of the list. Other identified problems would follow in order of their severity. It is only after this step that input from several dentists can provide a correctly sequenced final treatment plan for the patient.

Surgical correction of a jaw deformity can be made in horizontal, sagittal, or frontal planes. The mandible and maxillae may be positioned anteriorly or posteriorly, and their relationship to the facial planes may be surgically altered to achieve improved appearance. Replacement of missing teeth and development of a harmonious occlusion are almost always major problems in treating these patients.

### Dental Implants

A number of implant devices to support the replacement of teeth have been introduced to the dental profession. These devices offer a significant stabilizing effect on dental prostheses through a rigid connection to living bone. The system that pioneered clinical prosthodontic applications with the use of commercially pure (CP) titanium endosseous implants is that of Brånemark and colleagues (Figure 14-5). This titanium implant was designed to provide a direct titanium-to-bone interface (osseointegrated), with basic laboratory and clinical results supporting the value of this procedure.

Implants are carefully placed using controlled surgical procedures and, in general, bone healing to the device is allowed to occur before a dental prosthesis is fabricated. Long-term clinical research has demonstrated good results for the treatment of complete and partially edentulous dental patients using dental implants. Although research on implant applications with removable partial dentures has been very limited, the inclusion of strategically placed implants can



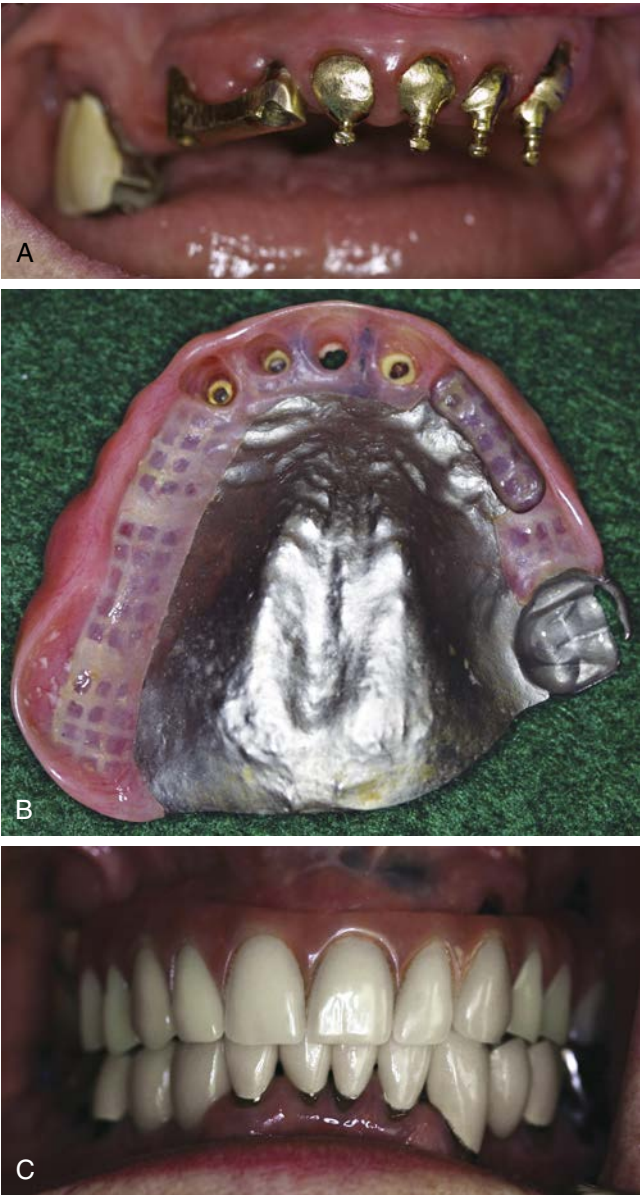
**FIGURE 14-5** A, Brånemark system components. From lower to upper: implant, cover screws, abutment, abutment screw, gold cylinder, and gold screw. B, Basic procedures in second-stage surgery: (1) exploration to locate cover screw; (2) removal of soft tissue; (3) removal of bony tissue; (4) removal of cover screw; (5) use of depth gauge to measure the amount of soft tissue; (6) abutment connection; and (7) placement of healing cap. C, Diagram of freestanding three-unit fixed partial denture supported by two osseointegrated implants that restore the extension base area, which would have been restored with a Class II removable partial denture if implants had not been used. (A and C, Redrawn from Hobo S, Ichida E, Garcia LT: *Osseointegration and occlusal rehabilitation*, Tokyo, 1989, Quintessence Publishing Company.)

significantly control prosthesis movement (see Chapter 12; Figures 14-6 through 14-8).

### Augmentation of Alveolar Bone

Considerable attention has been devoted to ridge augmentation with the use of autogenous and alloplastic materials,

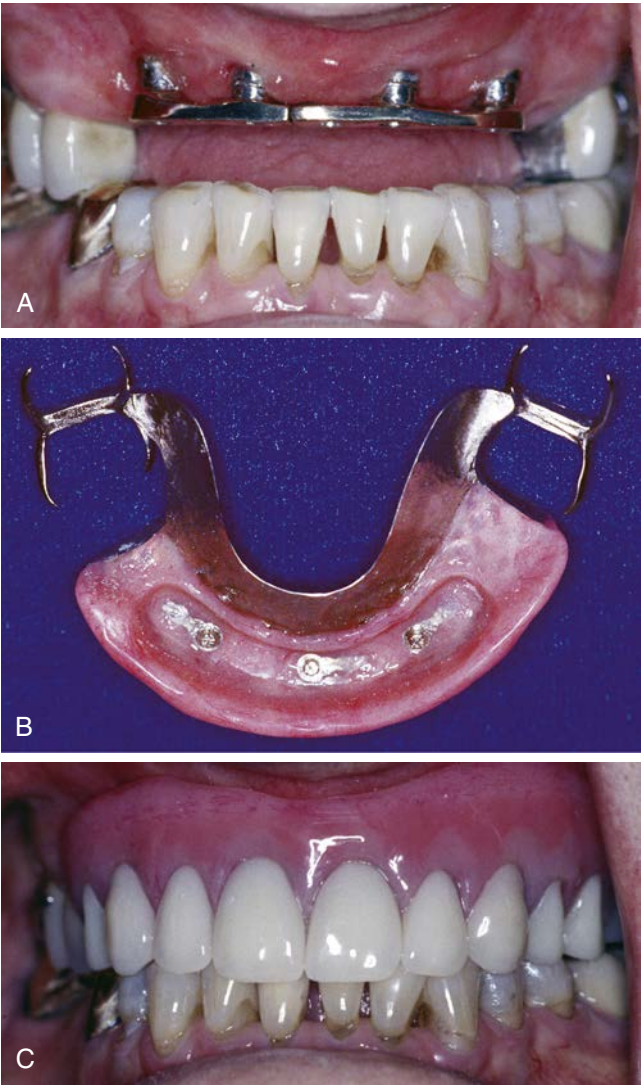
especially in preparation for implant placement. Larger ridge volume gains necessitate consideration of autogenous grafts; however, these procedures are accompanied by concerns for surgical morbidity. Alloplastic materials have displayed short-term success; however, no randomized controlled trials have been conducted to provide evidence of



**FIGURE 14-6** **A**, Implant bar and natural tooth copings used to support and retain this maxillary prosthesis. **B**, Tissue side of prosthesis showing the implant bar space, which when fitted will derive both support and stability from the implants while retention is gained through resilient O-rings on the natural tooth copings. **C**, Maxillary prosthesis seated and in occlusion. (Courtesy of Dr. N. Van Roekel, Monterey, CA.)

long-term increases in ridge width and height for removable prostheses.

Clinical results depend on careful evaluation of the need for augmentation, the projected volume of required material, and the site and method of placement. Considerable emphasis must be placed on a sound clinical understanding that some of the alloplastic materials can migrate or be displaced under occlusal loads if not appropriately supported by underlying bone and contained by buttressing soft tissues.



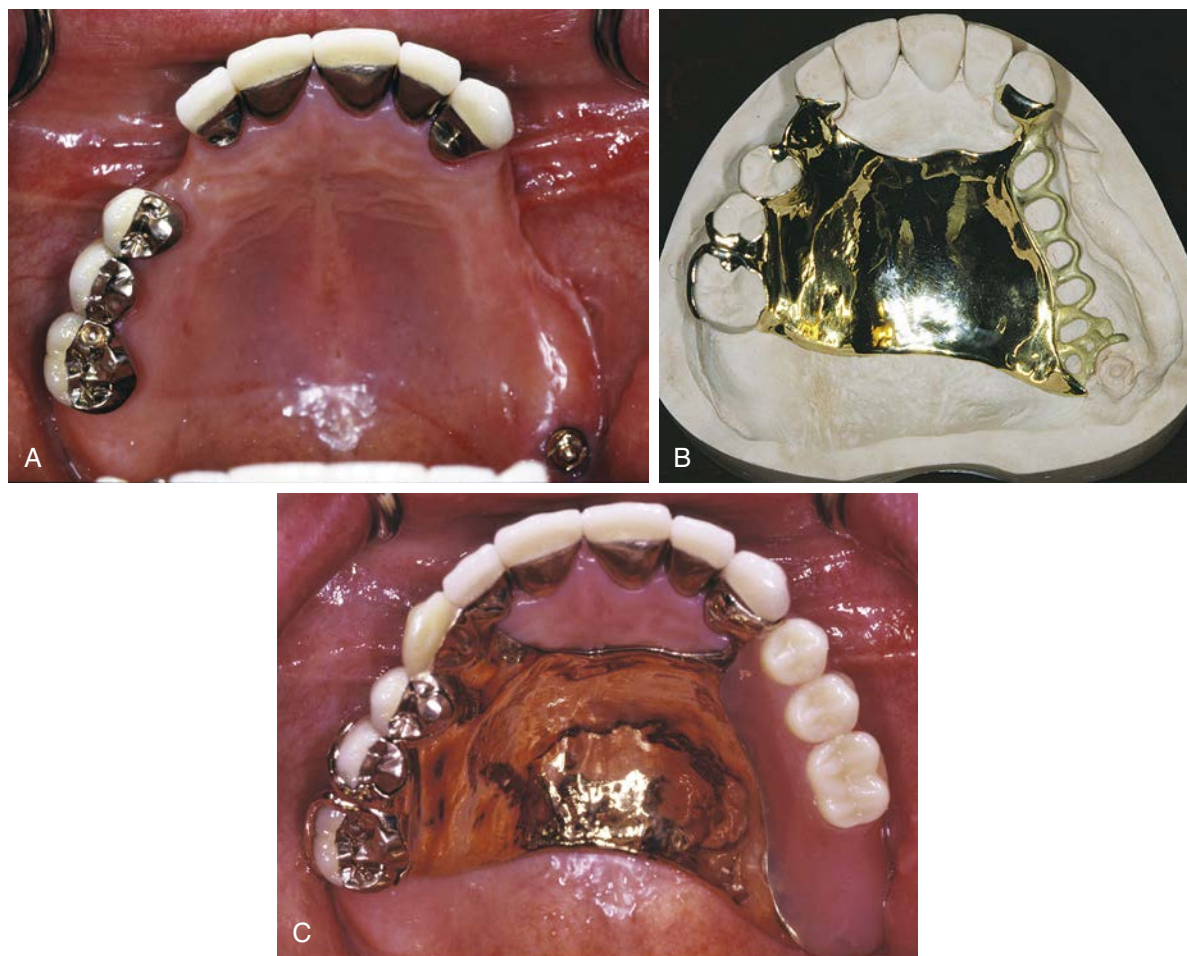
**FIGURE 14-7** **A**, An anterior implant-supported bar demonstrating excellent access for hygiene and a parallel relationship to opposing occlusion. **B**, Prosthesis with implant bar space (housing three retentive male components for retention and a flat surface for bar contact and support) and bilateral posterior embrasure clasps. **C**, Prosthesis seated and in occlusion. (Courtesy of Dr. N. Van Roekel, Monterey, CA.)

Careful clinical judgment with sound surgical and prosthetic principles must be exercised.

**PERIODONTAL PREPARATION\***

Periodontal preparation of the mouth usually follows any oral surgical procedure and is performed simultaneously with tissue conditioning procedures. Ordinarily, tooth extraction and removal of impacted teeth and retained

\* Edited by Vanchit John, DDS, Associate Professor and Chair, Department of Periodontics and Allied Dental Programs, Indiana University School of Dentistry, Indianapolis, Indiana.



**FIGURE 14-8** **A**, A Class II, modification 1, maxillary arch with a posterior implant at the distal location of the extension base. **B**, Maxillary gold framework with broad palatal coverage, maximum stabilization through palatal contacts of multiple maxillary teeth, and implant position at the distal extension base. A single implant should be protected from excessive occlusal forces; consequently the broad palatal coverage and maximum bracing are important features of the overall design. The ball attachment abutment was used for retentive purposes. **C**, Occlusal view of the prosthesis with implant (see **A**), which provides improved retention to the distal extension base. (Courtesy of Dr. James Taylor, Ottawa, Ontario.)

roots or fragments are accomplished before definitive periodontal therapy is provided. However, it is strongly recommended that a gross débridement be performed before tooth extraction when patients present with significant calculus accumulation. This helps limit the possibility of accidentally dislodging a piece of calculus into the extraction socket, which could lead to an infection. Elimination of exostoses, tori, hyperplastic tissue, muscle attachments, and frena, on the other hand, can be incorporated with periodontal surgical techniques. In any situation, periodontal therapy should be completed before restorative dentistry procedures are begun for any dental patient. This is particularly true when a removable partial denture is contemplated, because the ultimate success of this restoration depends directly on the health and integrity of the supporting structures of the remaining teeth. The periodontal health of the remaining teeth, especially those to be used as

abutments, must be evaluated carefully by the dentist and corrective measures instituted before a removable partial denture is fabricated. It has been demonstrated that following periodontal therapy and with a good recall and oral hygiene program, properly designed removable partial dentures will not adversely affect the progression of periodontal disease or carious lesions.

This discussion attempts to demonstrate how periodontal procedures affect diagnosis and treatment planning in a removable partial denture service rather than how the procedures are actually accomplished. For technical details, the reader is referred to any of several excellent textbooks on periodontics.

### Objectives of Periodontal Therapy

The objective of periodontal therapy is the return to health of supporting structures of the teeth, creating an environment

in which the periodontium may be maintained. The specific criteria for satisfying this objective are as follows:

1. Removal and control of all etiologic factors contributing to periodontal disease along with reduction or elimination of bleeding on probing
2. Elimination of, or reduction in, the pocket depth of all pockets with the establishment of healthy gingival sulci whenever possible
3. Establishment of functional atraumatic occlusal relationships and tooth stability
4. Development of a personalized plaque control program and a definitive maintenance schedule

Complete periodontal charting that includes the recording of pocket depths, assessment of attachment levels, and recording of furcation involvements, mucogingival problems, and tooth mobility should be performed. Determining the severity of periodontal disease should also include the use of appropriate radiographs. The dentist who is considering removable partial denture fabrication must be certain that these criteria have been satisfied before continuing with impression procedures for the master cast.

### Periodontal Diagnosis and Treatment Planning

#### Diagnosis

The diagnosis of periodontal diseases is based on a systematic and carefully accomplished examination of the periodontium. It follows the procurement of the health history of the patient and is performed with direct vision, palpation, a periodontal probe, a mouth mirror, and other auxiliary aids, such as curved explorers, furcation probes, diagnostic casts, and appropriate radiographs.

In the examination procedure, nothing is as important as careful exploration of the gingival sulcus and recording of the probing pocket depth and sites that bleed on probing with a suitably designed periodontal probe. Under no circumstances should removable partial denture fabrication begin without an accurate appraisal of sulcus/pocket depth and health. The probe is positioned as close to parallel to the long axis of the tooth as possible and is inserted gently between the gingival margin and the tooth surface, and the depth of the sulcus/pocket is determined circumferentially around each tooth. At least six probing depth readings are recorded on the patient's chart for each tooth. Usually depths are recorded for the distobuccal, buccal, mesiobuccal, distolingual, lingual, and mesiolingual aspects of each tooth. Sulcular health can also be assessed by the presence or absence of bleeding upon probing.

Dental radiographs can be used to supplement the clinical examination but should not be used as a substitute for it. A critical evaluation of the following factors should be made: (1) type, location, and severity of bone loss; (2) location, severity, and distribution of furcation involvements; (3) alterations of the periodontal ligament space; (4) alterations of the lamina dura; (5) the presence of calcified deposits; (6) the location and conformity of restorative margins; (7) evaluation of crown and root morphologies; (8) root proximity;

(9) caries; and (10) evaluation of other associated anatomic features, such as the mandibular canal or sinus proximity. This information serves to substantiate the impression gained from the clinical examination.

Each tooth should be evaluated carefully for mobility. Unfortunately, there is no universally accepted standard for mobility. In general, mobility is graded according to the ease and extent of tooth movement. Normal mobility is in the order of 0.05 to 0.10 mm. Grade I mobility is present when less than 1 mm of movement occurs in a bucco-lingual direction; grade II is present when mobility in the bucco-lingual direction is between 1 and 2 mm; grade III is present when greater than 2 mm of mobility occurs in the bucco-lingual direction and/or the tooth is vertically depressible.

Tooth mobility is an indication of the condition of the supporting structures, namely, the periodontium, and usually is caused by inflammatory changes in the periodontal ligament, traumatic occlusion, loss of attachment, or a combination of the three factors. The degree of mobility present, coupled with a determination of the causative factors responsible, provides additional information that is invaluable in planning for the removable partial denture. If the causative factor can be removed, many grade I and grade II mobile teeth can become stable and may be used successfully to help support, stabilize, and retain the removable partial denture. Mobility in itself is not an indication for extraction unless the mobile tooth cannot aid in support or stability of the removable partial denture, or mobility cannot be reduced. (Grade III usually cannot be reversed and will not provide support or stability.)

#### Treatment Planning

Depending on the extent and severity of the periodontal changes present, a variety of therapeutic procedures ranging from simple to relatively complex may be indicated. As was the situation with the previously discussed oral surgical procedures, it is the responsibility of the dentist rendering the removable partial denture treatment to see that the required periodontal care is accomplished for the patient. Periodontal treatment planning can usually be divided into three phases. The first phase is considered disease control or initial therapy because the objective is to essentially eliminate or reduce local causative factors before any periodontal surgical procedures are accomplished. The procedures that are accomplished as part of the initial preparation phase include oral hygiene instruction, scaling, and root planing and polishing, as well as endodontics, occlusal adjustment, and temporary splinting, if indicated. In many instances, carefully performed scaling and root planing combined with excellent patient compliance may negate the need for periodontal surgery.

During the second, or periodontal, surgical phase, any needed periodontal surgery, such as free gingival grafts, osseous grafts, or pocket reduction, is accomplished. It is advisable to discuss the possible need for these treatment procedures with the patient at the initial examination appointment or during the initial phase of therapy, because

this will likely involve referral of the patient to a periodontist. The maintenance of periodontal health is accomplished in the third phase and is always ongoing. A definitive recall schedule should be established with the patient and is usually kept at 3- to 4-month intervals.

### Initial Disease Control Therapy (Phase 1)

#### Oral Hygiene Instruction

Ordinarily, dental treatment should be introduced to the patient through instruction provided in a carefully devised oral hygiene regimen. The cooperation witnessed by the patient's acceptance and compliance with the prescribed procedure, as evidenced by improved oral hygiene, provides the dentist with a valuable means of evaluating that patient's interest and the long-term prognosis of treatment.

For the oral hygiene routine to be successful, the patient must be convinced to follow the prescribed procedure regularly and conscientiously. The most effective motivation techniques require a good understanding by the patient of his/her periodontal condition. Only then can the benefits of routine treatment become evident. Hence, an explanation of dental/periodontal disease, including its causes, initiation, and progression, is an important component of oral hygiene instruction. After this discussion, the patient should be instructed on the use of disclosing wafers/tablets, a soft/medium-bristle toothbrush, and unwaxed/waxed dental floss. At subsequent appointments, oral hygiene can be evaluated carefully, and other oral hygiene aids (such as, an interdental and or sulcular brushes) can be incorporated as needed. Further treatment should be withheld until a satisfactory level of plaque control has been achieved. This is a particularly critical point for the patient who requires extensive restorative dentistry or a removable partial denture. Without good oral hygiene, any dental procedure, regardless of how well it is performed, is ultimately doomed to failure. The informed dentist insists that acceptable oral hygiene is demonstrated and maintained before embarking on an extensive restorative dentistry treatment plan.

#### Scaling and Root Planing

One of the most important services rendered to the patient is the removal of calculus and plaque deposits from the coronal and root surfaces of the teeth. Careful scaling and root planing are fundamental to the reestablishment of periodontal health. Without meticulous removal of calculus, plaque, and toxic material in the cementum, other forms of periodontal therapy cannot be successful.

The use of ultrasonic instrumentation for calculus removal followed by root planing with sharp periodontal curettes is recommended. The curette is designed specifically for root planing and, when used correctly in combination with ultrasonic instrumentation, results in calculus removal and root surface decontamination. Thorough scaling and root planing should precede definitive surgical periodontal

procedures that may be indicated before removable partial denture fabrication.

#### Elimination of Local Irritating Factors Other Than Calculus

Overhanging restoration margins and open contacts that allow food impaction should be corrected before definitive prosthetic treatment is begun. Although periodontal health predisposes to a much better environment for restorative procedures, it is not always possible or prudent to delay all restorative procedures until complete periodontal therapy and healing have occurred. This is especially true for patients with severe carious lesions in which pulpal involvement is likely. Excavation of these areas and placement of adequate restorations must be incorporated early in treatment. The placement of temporary or treatment fillings must not, in itself, become a local causative factor.

#### Elimination of Gross Occlusal Interferences

Bacterial plaque accumulations and calculus deposits are the primary factors involved in the initiation and progression of inflammatory periodontal disease. However, poor restorative dentistry can contribute to damage of the periodontium, and poor occlusal relationships may act as another factor that contributes to more rapid loss of periodontal attachment. Although occlusal interferences may be eliminated through a variety of techniques, at this stage of treatment, selective grinding is the procedure generally applied. Particular attention is directed to the occlusal relationships of mobile teeth. Traumatic cuspal interferences are removed by a selective grinding procedure. An attempt is made to establish a positive planned intercuspal position that coincides with centric relation. Deflective contacts in the centric path of closure are removed, eliminating mandibular displacement from the closing pattern. After this, the relationship of the teeth in various excursive movements of the mandible is observed, with special attention to cuspal contact, wear, mobility, and roentgenographic changes in the periodontium. The presence of working and nonworking interferences should be evaluated; if present, they should be removed.

The mere presence of occlusal abnormalities, in the absence of demonstrable pathologic change associated with the occlusion, does not necessarily constitute an indication for selective grinding. The indication for occlusal adjustment is based on the presence of a pathologic condition rather than on a preconceived articulation pattern. In the natural dentition, attempts to create bilateral balance, in the prosthetic sense, have no place in the occlusal adjustment procedure. Bilateral balanced occlusion not only is difficult to obtain in a natural dentition but also is apparently unnecessary in view of its absence in most normal healthy mouths. Occlusion on natural teeth needs to be perfected only to the point at which cuspal interference within the patient's functional range of contact is eliminated and normal physiologic function can occur.

### Guide to Occlusal Adjustment

Schuyler\* has provided the following guide to occlusal adjustment by selective grinding:

In the study or evaluation of occlusal disharmony of the natural dentition, accurately mounted diagnostic casts are extremely helpful, if not essential, in determining static cusp-to-fossa contacts of opposing teeth and as a guide in the correction of occlusal anomalies in both centric and eccentric functional relations. Occlusion can be coordinated only by selective spot grinding. Ground tooth surfaces should be subsequently smoothed and polished.

1. A static coordinated occlusal contact of the maximum number of teeth (maximum intercuspal position) when the mandible is in centric relation to the maxilla should be the first objective.
  - a. A prematurely contacting cusp should be reduced only if the cusp point is in premature contact in both centric and eccentric relations. If a cusp point is in premature contact in centric relation only, the opposing sulcus should be deepened.
  - b. When anterior teeth are in premature contact in centric relation, or in both centric and eccentric relations, corrections should be made by grinding the incisal edges of the mandibular teeth. If premature contact occurs only in the eccentric relation, correction must be made by grinding the lingual inclines of the maxillary teeth.
  - c. Usually, premature contacts in centric relation are relieved by grinding the buccal cusps of mandibular teeth, the lingual cusps of maxillary teeth, and the incisal edges of mandibular anterior teeth. Deepening the fossa of a posterior tooth or the lingual contact area in the centric relation of a maxillary anterior tooth changes and increases the steepness of the eccentric guiding inclines of the tooth; although this relieves trauma in centric relation, it may predispose the tooth to trauma in eccentric relations.
2. After establishing a static, even distribution of stress over the maximum number of teeth in centric relation, we are ready to evaluate opposing tooth contact or lack of contact in eccentric functional relations. Our attention is directed first to balancing side contacts. In extreme cases of pathologic balancing contacts, relief may be needed even before corrective procedures in centric relation are performed. Where balancing contacts exist, it is extremely difficult to differentiate the harmless from the destructive because we cannot visualize the influence of these fulcrum contacts on the functional movements of the condyle in the articular fossa. Subluxation, pain, lack of normal functional movement of the joint, or loss of alveolar support of the teeth involved may be evidence of excessive balancing contacts. Balancing side contacts receive less frictional wear than working side contacts, and premature contacts may develop progressively with wear. A reduction in the

steepness of guiding tooth inclines on the working side will increase the proximity of the teeth on the balancing side and may contribute to destructive prematurities. In all corrective grinding to relieve premature or excessive contacts in eccentric relations, care must be exercised to avoid the loss of a static supporting contact in centric relation. This static support in centric relation may exist with the mandibular buccal cusp fitting into the central fossa of the maxillary tooth or with the maxillary lingual cusp fitting into the central fossa of the mandibular tooth, or it may exist in both situations. Although both the maxillary lingual cusp and the mandibular buccal cusp may sometimes have a static centric contact in the sulcus of the opposing tooth, often only one of these cusps has this static contact. In such instances, the contacting cusp must be left untouched to maintain this essential support in the planned intercuspal position, and all corrective grinding to relieve premature contacts in eccentric positions would be done on the opposing tooth inclines. The mandibular buccal cusp is in a static central contact in the maxillary sulcus more often than the maxillary lingual cusp is in a static contact in its opposing mandibular sulcus. Therefore, corrective grinding to relieve premature balancing contacts is more often done on the maxillary lingual cusps.

3. To obtain maximum function and distribution of functional stress in eccentric positions on the working side, necessary grinding must be done on the lingual surfaces of the maxillary anterior teeth. Corrective grinding on the posterior teeth at this time should always be done on the buccal cusp of the maxillary premolars and molars and on the lingual cusp of the mandibular premolars and molars. The grinding of mandibular buccal cusps or maxillary lingual cusps at this time would rob these cusps of their static contact in the opposing central sulci in centric relation.
4. Corrective grinding to relieve premature protrusive contacts of one or more anterior teeth should be accomplished by grinding the lingual surface of the maxillary anterior teeth. Anterior teeth should never be ground to bring the posterior teeth into contact in either protrusive position or on the balancing side. In the elimination of premature protrusive contacts of posterior teeth, neither the maxillary lingual cusps nor the mandibular buccal cusps should be ground. Corrective grinding should be done on the surfaces of the opposing teeth on which these cusps function in the eccentric position, leaving the centric contact undisturbed.
5. Any sharp edges left by grinding should be rounded off.

### Temporary Splinting

Teeth that are mobile at the time of the initial examination frequently present a diagnostic problem for the dentist. The cause of the mobility must be determined and then a decision made for elimination of the causative factors. The response of these teeth to temporary immobilization followed by

\* Courtesy of Dr. C. H. Schuyler, Montclair, NJ.

appropriate treatment may be helpful in establishing a prognosis for them and may lead to a rational decision as to whether they should be retained or sacrificed. Secondary mobility resulting from the presence of an inflammatory lesion may be reversible if the disease process has not destroyed too much of the attachment apparatus. Primary mobility caused by occlusal interference also may disappear after selective grinding. In instances of angular types of osseous defects, one should consider guided tissue regeneration (GTR) as a means of increasing attachment levels. In some situations, however, the teeth must be stabilized because of loss of supporting structure from the periodontal process.

Teeth may be immobilized during periodontal treatment by acid etching teeth with composite resin, with fiber-reinforced resins, with cast removable splints, or with intra-coronal attachments. The latter, an example of which is the A-splint, necessitates cutting tooth surfaces and embedding a ridge connector between adjacent teeth.

After periodontal treatment is performed, splinting may be accomplished with cast removable restorations or cast cemented restorations. The preferred form of permanent splinting uses two or more cast restorations soldered or cast together. They may be cemented with permanent (zinc oxyphosphate or resin) cements or temporary (zinc oxide-eugenol) cements. A properly designed removable partial denture can also stabilize mobile teeth if provision for such immobilization is planned as the denture is designed.

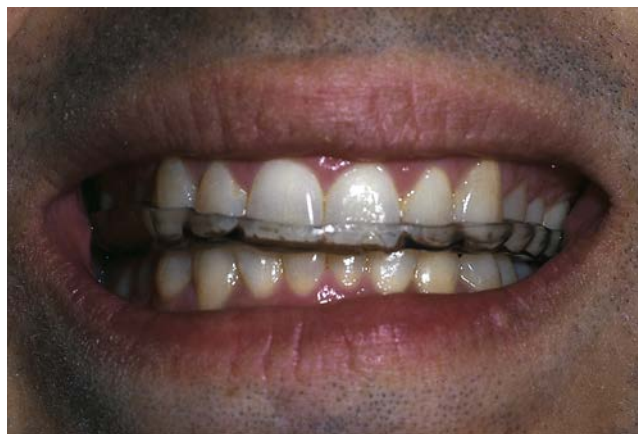### Use of a Nightguard

The removable acrylic-resin splint, originally designed as an aid in eliminating the deleterious effects of nocturnal clenching and grinding, has been used to advantage for the removable partial denture patient. The nightguard may prove helpful as a form of temporary splinting if worn at night when the removable partial denture has been removed. The flat occlusal surface prevents intercuspation of the teeth, which eliminates lateral occlusal forces (Figure 14-9).

The nightguard is particularly useful before fabrication of a removable partial denture when one of the abutment teeth has been unopposed for an extended period. The periodontal ligament of a tooth without an antagonist undergoes changes characterized by loss of orientation of periodontal ligament fibers, loss of supporting bone, and narrowing of the periodontal ligament space. If such a tooth is suddenly returned to full function when it is carrying an increased burden, pain and prolonged sensitivity may result. However, if a nightguard is used to return some functional stimulation to the tooth, the periodontal ligament changes are reversed and an uneventful course can be experienced when the tooth is returned to full function.

### Minor Tooth Movement

The increased use of orthodontic procedures in conjunction with restorative and prosthetic dentistry has contributed to the success of many restorations by altering the periodontal



**FIGURE 14-9** The removable acrylic-resin splint with a flat occlusal plane can be used effectively as a form of temporary stabilization and as a means of eliminating excessive lateral forces created by clenching and grinding habits.

environment in which they are placed. Malposed teeth that were once doomed to extraction should be considered now for repositioning and retention. The additional stability provided for a removable partial denture by uprighting a tilted or drifted tooth may mean much in terms of comfort to the patient. The techniques employed are not difficult to master, and the rewards in terms of a better restorative dentistry service are great.

## Definitive Periodontal Surgery (Phase 2)

### Periodontal Surgery

After initial therapy is completed, the patient is reevaluated for the surgical phase. If oral hygiene is at an optimum level, yet pockets with inflammation and osseous defects are still present, a variety of periodontal surgical techniques should be considered to improve periodontal health. The procedures selected should have the potential to enhance the results obtained during Phase 1 therapy.

Pocket reduction or elimination may be achieved by root planing when the cause of pocket depth is edema caused by gingival inflammation. Apically positioned flap surgery or occasionally a gingivectomy may be considered for reduction of suprabony pockets. Osseous resection or regeneration using a flap approach is a form of surgical therapy that is commonly employed to help with treatment of the diseased periodontium. It must be noted that elimination of the inflammatory disease process and restoration of the periodontal attachment apparatus are the major objectives of periodontal therapy.

**Periodontal Flaps.** Today, use of one of the various flap procedures is the surgical approach that offers the greatest versatility. Periodontal flap surgery involves the elevation of either mucosa alone or both the mucosa and the periosteum. Although there are several indications for flap elevation, the most important goal of flap elevation is to allow access to the bone and the root surfaces for complete

instrumentation. Other goals of the flap approach include access for pocket elimination, caries control, crown lengthening to allow for optimum restorative dental treatment, root amputation or hemisection, as required and access to the furcation of the tooth.

A decision is made before surgery is performed if the aim is resection of osseous tissue to allow for a more physiologic osseous anatomy and subsequently gingival contour, or to regenerate some of the lost periodontal attachment apparatus. However, sometimes changes have to be made during surgery based on the anatomy of defects following the removal of diseased granulation tissue. Osseous resection involves the use of both osteoplasty and ostectomy procedures. Osteoplasty refers to reshaping the bone without removing tooth-supporting bone; ostectomy includes the removal of tooth-supporting bone. Consequently, the flap is widely applied in the treatment of periodontal disease.

**Guided Tissue Regeneration.** GTR has been defined as those procedures that attempt regeneration of lost periodontal structures through differing tissue responses. The rationale for GTR is based on the physiologic healing response of the tissues after periodontal surgery. After periodontal surgery, a race to repopulate the root surface begins among the four tissue types of the periodontium, namely, epithelium, connective tissue, periodontal ligament, and bone. Epithelium, which migrates at a rate of 0.5 mm per day, typically migrates first along the root surface, preventing new attachment. Therefore, to allow the undifferentiated mesenchymal cells from the periodontal ligament and the endosteum of bone to repopulate the root against surfaces, the epithelial cells and the gingival connective tissue cells should be isolated. This isolation during initial healing enables periodontal structures to become reestablished and may lead to better long-term health of the tooth. The GTR procedure commonly involves the use of an osseous graft along with a resorbable membrane (Figure 14-10). This technique has the potential to lead to substantial improvement of the periodontal condition when used around carefully selected two- and three-walled osseous defects and mandibular furcation involvements.

**Periodontal Plastic Surgery.** Periodontal plastic surgery, which was previously referred to as *mucogingival surgery*, is applied to those procedures used to resolve problems involving the interrelationship between the gingiva and the alveolar mucosa. Mucogingival surgery consists of plastic surgical procedures that are used for correction of gingiva–mucous membrane relationships that complicate periodontal disease and may interfere with the success of periodontal treatment. The objectives of periodontal plastic surgery are several and include elimination of pockets that transverse the mucogingival junction, creation of an adequate zone of attached gingiva, correction of gingival recession by root coverage techniques, relief of the pull of frena and muscle attachments on the gingival margin, and correction of deformities of edentulous ridges, done to permit access to the underlying alveolar process and correction of osseous deformities when

there is sufficient or insufficient attached gingiva, to deepen a shallow vestibule, and to assist in orthodontic therapy. Commonly used periodontal plastic surgical procedures include lateral sliding flaps, free gingival grafts, pedicle grafts, coronally positioned grafts, double papilla flaps, semilunar coronally positioned flaps, subepithelial connective tissue grafts, and edentulous ridge augmentation using one of the above techniques. In addition, GTR has been used for periodontal plastic surgical procedures. Recently, use of the commercially-available acellular dermal graft has gained popularity. However, the most commonly used procedure is the subepithelial connective tissue graft (Figure 14-11).

These plastic surgical procedures should be considered whenever an abutment tooth lacks adequate attached keratinized gingiva and requires root coverage to facilitate removable partial denture construction and maintenance.

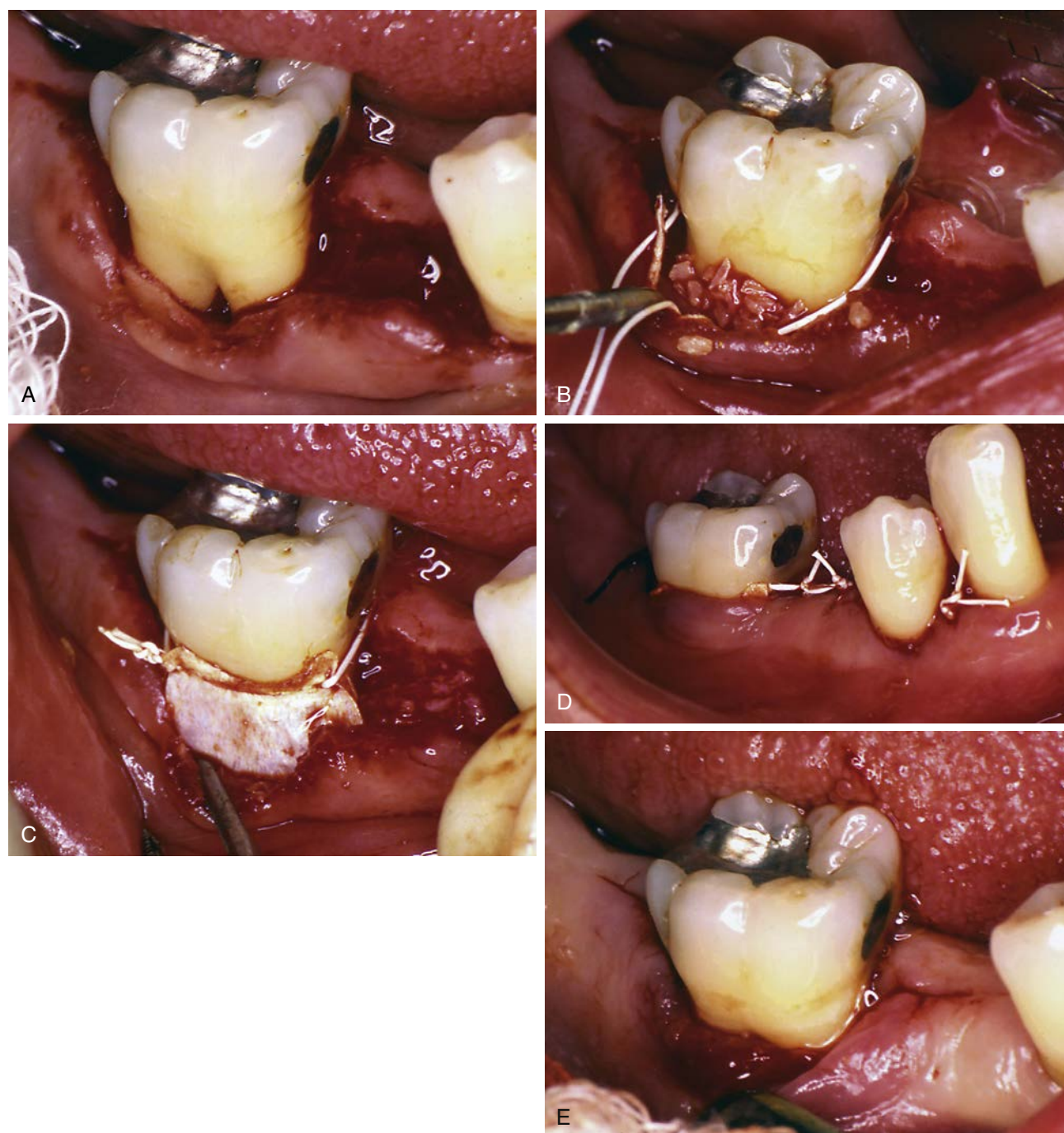
### Recall Maintenance (Phase 3)

Several longitudinal studies have now demonstrated the increasing importance of maintenance for all patients who have undergone any periodontal therapy. This includes not only reinforcement of plaque control measures but also thorough débridement of all root surfaces of supragingival and subgingival calculus and plaque by the dentist or an auxiliary.

The frequency of recall appointments should be customized for the patient, depending on the susceptibility and severity of periodontal disease. It is now understood that patients with a history of moderate to severe periodontitis should be placed on a 3- to 4-month recall system to maintain results achieved by nonsurgical and surgical therapy.

### Advantages of Periodontal Therapy

Periodontal therapy done before a removable prosthesis is fabricated has several advantages. First, the elimination of periodontal disease removes a primary causative factor in tooth loss. The long-term success of dental treatment depends on the maintenance of the remaining oral structures, and periodontal health is mandatory if further loss is to be avoided. Second, a periodontium free of disease presents a much better environment for restorative correction. Elimination of periodontal pockets with the associated return of a physiologic architectural pattern establishes a normal gingival contour at a stable position on the tooth surface. Thus, the optimum position for gingival margins of individual restorations can be established with accuracy. The coronal contours of these restorations can also be developed in correct relationships to the gingival margin, ensuring the proper degree of protection and functional stimulation to gingival tissues. Third, the response of strategic but questionable teeth to periodontal therapy provides an important opportunity for reevaluating their prognosis before the final decision is made to include (or exclude) them in the removable partial denture design. And last, the overall reaction of the patient to periodontal procedures provides the dentist with an excellent indication of the degree of cooperation to be expected in the future.



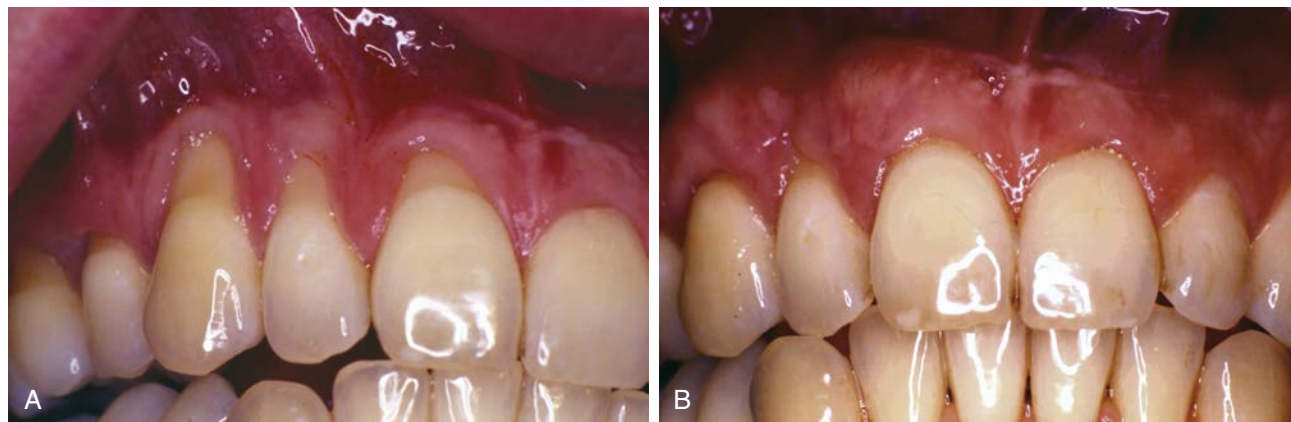
**FIGURE 14-10** Guided tissue regeneration (GTR) procedure performed to address a furcation involvement. **A**, Tooth #30 presented with a Class II furcation involvement with the probe entering 3 mm in a horizontal direction. A GTR procedure using a combination of a bone graft and a nonresorbable membrane was planned. **B**, Following hand and ultrasonic instrumentation, decalcified freeze-dried bone allograft was grafted around the furcation. **C**, A nonresorbable membrane was placed over the bone graft. **D**, The flap was then sutured with a nonresorbable expanded polytetraethylene suture. **E**, Two months following surgery, the membrane was removed. Note the presence of red rubbery tissue filling the previously exposed furcation site. This tissue has the potential to form osseous tissue and close the access to the furcation entrance.

Even in the absence of periodontal disease, certain periodontal procedures may be an invaluable aid in removable partial denture construction. Through periodontal surgical techniques, the environment of potential abutment teeth may be altered to the point of making an otherwise unacceptable tooth a most satisfactory retainer for a removable partial denture.

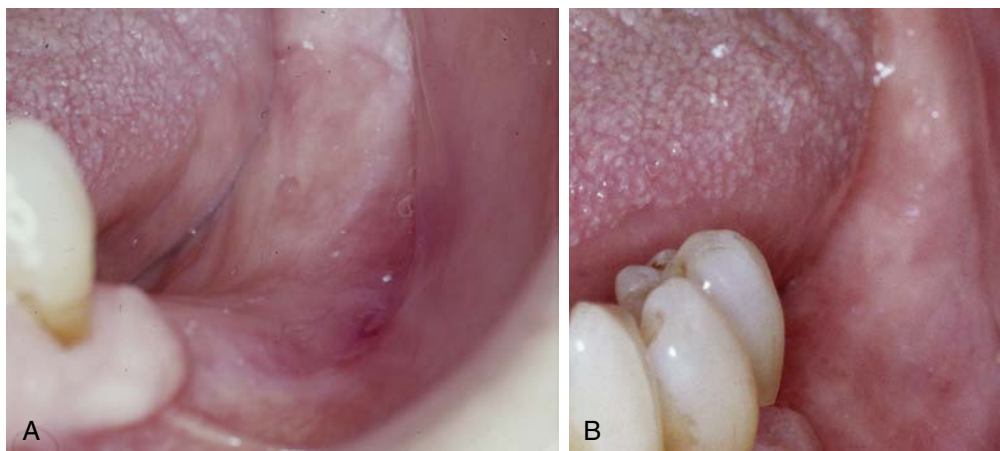
## OPTIMIZATION OF THE FOUNDATION FOR FITTING AND FUNCTION OF THE PROSTHESIS

### Conditioning of Abused and Irritated Tissues

Many removable partial denture patients require some conditioning of supporting tissues in edentulous areas before



**FIGURE 14-11** Gingival recession addressed with subepithelial connective tissue graft procedure. **A**, The patient presents with evidence of severe gingival recession associated with teeth #6, #7, and #8. This was an esthetic problem. The patient also complained of hypersensitivity associated with these teeth. A subepithelial connective tissue graft was planned to help correct the gingival recession. **B**, Clinical appearance 6 months following treatment with a subepithelial connective tissue graft on teeth #6, #7, and #8. The patient was very satisfied with the postoperative appearance, and clinically the symptom of hypersensitivity was no longer significant.



**FIGURE 14-12** **A**, Inflamed and distorted denture bearing mucosa due to an ill-fitting prosthesis that is worn 24 hours a day. **B**, After the tissue abuse is treated via modification of the denture base with a tissue conditioning resilient liner material, the prosthesis is removed for portions of the day, and the abused tissue is massaged, the denture bearing foundation is healthy again.

the final impression phase of treatment begins. Patients who require conditioning treatment often demonstrate the following symptoms:

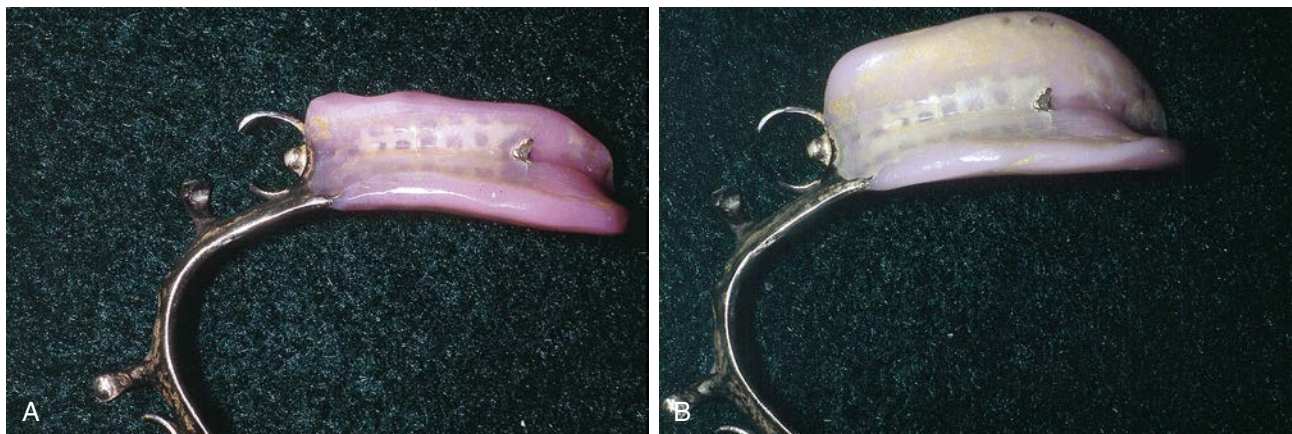- Inflammation and irritation of the mucosa covering denture-bearing areas (Figure 14-12)
- Distortion of normal anatomic structures, such as incisive papillae, rugae, and retromolar pads
- A burning sensation in residual ridge areas, the tongue, and the cheeks and lips

These conditions are usually associated with ill-fitting or poorly occluding removable partial dentures. However, nutritional deficiencies, endocrine imbalances, severe health problems (diabetes or blood dyscrasias), and bruxism must be considered in a differential diagnosis.

If the use of a new removable partial denture or the relining of a present denture is attempted without first correcting these conditions, the chances for successful treatment will be

compromised because the same old problems will be perpetuated. The patient must be made to realize that fabrication of a new prosthesis should be delayed until the oral tissues can be returned to a healthy state. If there are unresolved systemic problems, removable partial denture treatment will usually result in failure or limited success.

The first treatment procedure should consist of immediate institution of a good home care program. A suggested home care program includes rinsing the mouth three times a day with a prescribed saline solution; massaging the residual ridge areas, palate, and tongue with a soft toothbrush; removing the prosthesis at night; and using a prescribed therapeutic multiple vitamin along with a prescribed high-protein, low-carbohydrate diet. Some inflammatory oral conditions caused by ill-fitting dentures can be resolved by removing the dentures for extended periods. However, few patients are willing to undergo such inconveniences.



**FIGURE 14-13** A, Mandibular removable partial denture with underextended bases, which contributed to tissue irritation. B, Denture bases properly extended to enhance support, stability, and retention.

### Use of Tissue Conditioning Materials

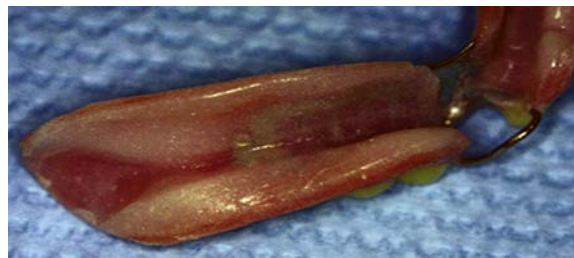The tissue conditioning materials are elastopolymers that continue to flow for an extended period, permitting distorted tissues to rebound and assume their normal form. These soft materials apparently have a massaging effect on irritated mucosa, and because they are soft, occlusal forces are probably more evenly distributed.

Maximum benefit from using tissue conditioning materials may be obtained by (1) eliminating deflective or interfering occlusal contacts of old dentures (by remounting in an articulator if necessary); (2) extending denture bases to proper form to enhance support, retention, and stability (Figure 14-13); (3) relieving the tissue side of denture bases sufficiently (2 mm) to provide space for even thickness and distribution of conditioning material; (4) applying the material in amounts sufficient to provide support and a cushioning effect (Figure 14-14); and (5) following the manufacturer's directions for manipulation and placement of the conditioning material.

The conditioning procedure should be repeated until the supporting tissues display an undistorted and healthy appearance. Many dentists find that intervals of 4 to 7 days between changes of the conditioning material are clinically acceptable. Improvement in irritated and distorted tissues is usually noted within a few visits, and in some patients a dramatic improvement will be seen. Usually three or four changes of the conditioning material are adequate, but in some instances additional changes are required. If positive results are not seen within 3 to 4 weeks, one should suspect more serious health problems and request a consultation from a physician.

### Abutment Restorations

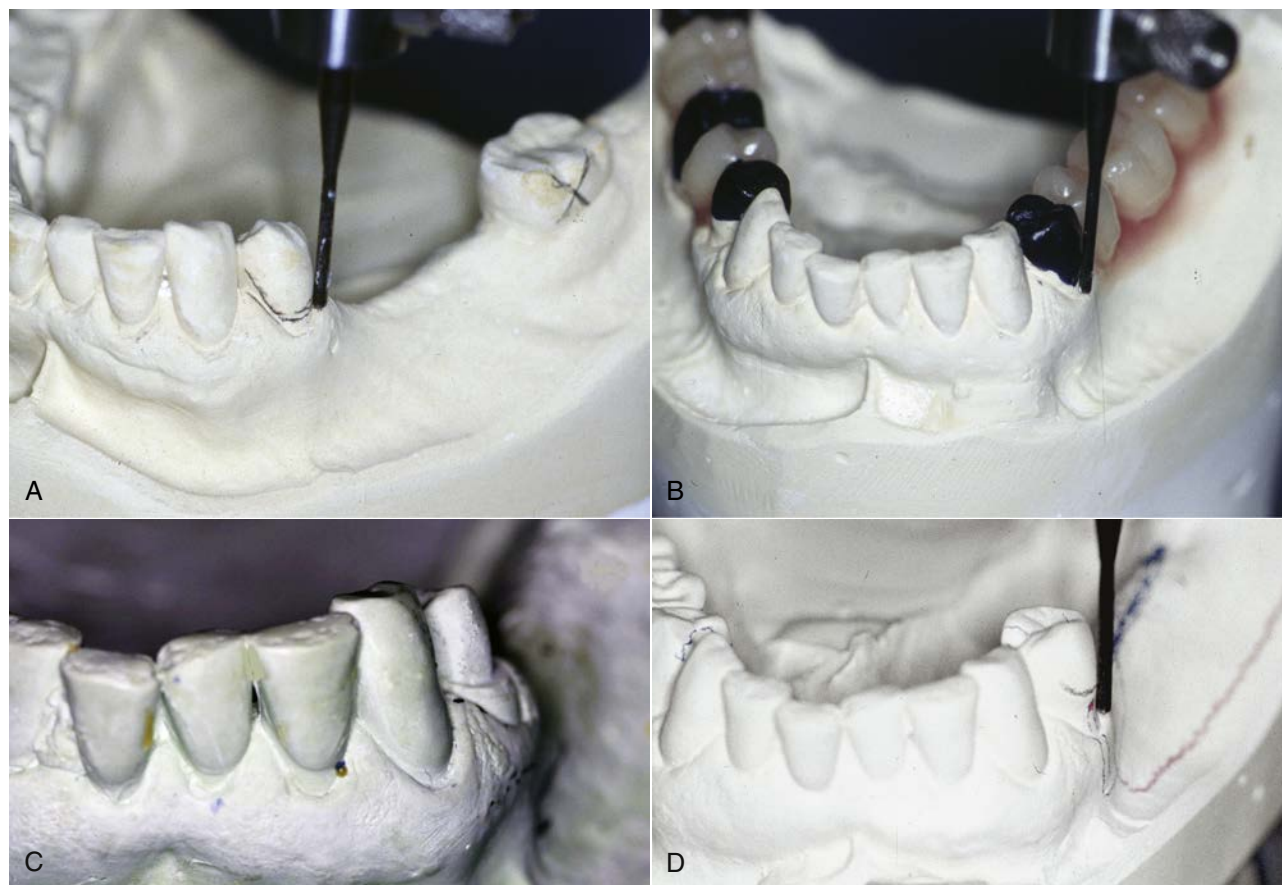
Equipped with the diagnostic casts on which a tentative removable partial denture design has been drawn, the dentist is able to accomplish preparation of abutment teeth with accuracy. The information at hand should include the proposed path of placement, the areas of teeth to be altered and tooth contours to be changed, and the locations of rest seats and guiding planes.



**FIGURE 14-14** Tissue conditioning should be of sufficient thickness to be resilient and not place undue stress on the soft tissue.

During examination and subsequent treatment planning, in conjunction with a survey of diagnostic casts, each abutment tooth is considered individually as to what type of restoration is indicated. Abutment teeth presenting sound enamel surfaces in a mouth in which good oral hygiene habits are evident may be considered a fair risk for use as removable partial denture abutments. One should not be misled, however, by a patient's promise to do better as far as oral hygiene habits are concerned. Good or bad oral hygiene is a habit of long standing and is not likely to be changed appreciably because a removable partial denture is being worn. Therefore, one must be conservative in evaluating the oral hygiene habits of the patient in the future. Remember that clasps as such do not cause teeth to decay; and if the individual will keep the teeth and the removable partial denture clean, one need not condemn clasps from a cariogenic standpoint. On the other hand, more removable partial dentures have been condemned as cariogenic because the dentist did not provide for the protection of abutment teeth rather than because of inadequate care on the part of the patient.

Esthetic veneer types of crowns should be used when a canine or premolar abutment is to be restored or protected. Less frequently, the molar will have to be treated in such a manner, and except for maxillary first molars, the full cast crown is usually acceptable.



**FIGURE 14-15** **A**, Diagnostic cast at an orientation best for all abutments considered. The buccal survey line is too close to the marginal gingival and the distal surface does not lend itself to guide-plane preparation. A surveyed crown is indicated. **B**, Abutment contours appropriate to clasp design (distal guide plane and mid-buccal 0.01 inch undercut) are produced in wax. **C**, Cast of abutment preparation provides buccal surface reduction adequate to replace with metal ceramic material at the required contour. Without careful consideration of survey line placement needs before and during preparation, it is easy to reproduce incorrect contours in finished crowns. **D**, Cast of a seated surveyed crown demonstrates desired contours for the clasp design chosen.

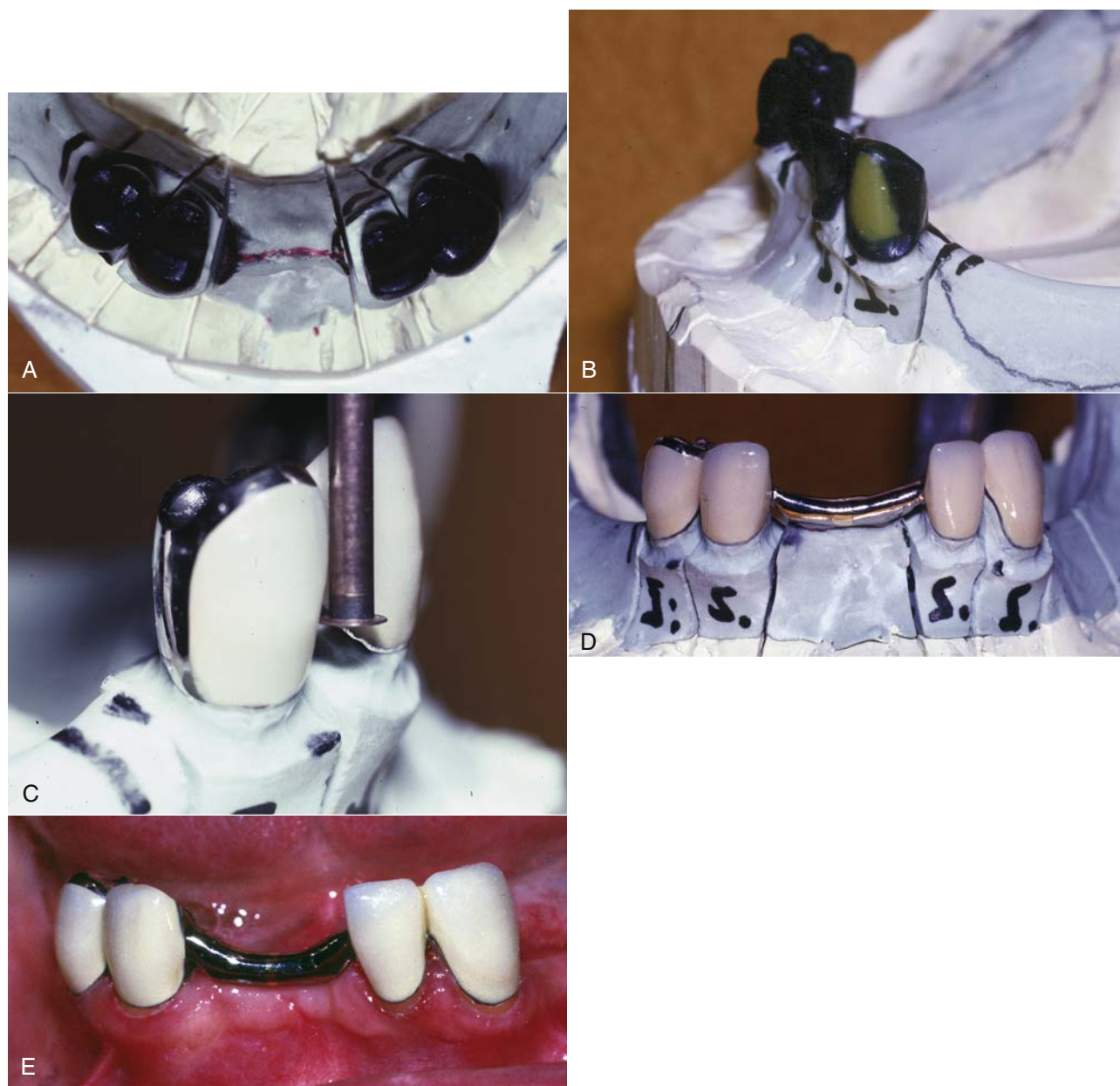
When there is proximal caries on abutment teeth with sound buccal and lingual enamel surfaces, in a mouth exhibiting average oral hygiene and low caries activity, a gold inlay may be indicated. However, silver amalgam or composite for the restoration of those teeth with proximal caries should not be condemned, although one must admit that an inlay cast of a hard type of gold will provide the best possible support for occlusal rests, at the same time giving an esthetically pleasing restoration. However, an amalgam restoration, properly condensed, is capable of supporting an occlusal rest without appreciable flow over a long period.

The most vulnerable area on the abutment tooth is the proximal gingival area, which lies beneath the minor connector of the removable partial denture framework and is therefore subject to accumulation of debris in an area most susceptible to caries. Even when the removable partial denture is removed, these areas are often missed by the toothbrush, which allows bacterial plaque and debris to remain for long periods. Because of this unique removable partial denture concern, special attention should be paid to these

areas during patient education and follow-up. Even when a complete crown restoration is placed in this most vulnerable area, recurrent caries can occur. Caries risk is best managed through effective home care and professional follow-up procedures, rather than through the placement of restorations.

All proximal abutment surfaces that are to serve as guiding planes for the removable partial denture should be prepared so that they will be made as nearly parallel as possible to the path of placement. Preparations may include modifying the contour of existing ceramic restorations, if necessary. This may be accomplished with abrasive stones or diamond finishing stones. A polished surface for the altered ceramic restoration may be restored by using any of several polishing kits supplied by manufacturers.

When preparing abutments that will receive surveyed crowns, it is important to plan for the tooth reduction necessary to allow placement of sufficient restorative material for durability, contour, and esthetics, as well as the contours prescribed for the desired clasp assembly (Figure 14-15). This can be accomplished by first modifying the axial contours



**FIGURE 14-16** **A**, Occlusal view of full contour wax patterns, which will be splinted between crowns and across the midline with a 13-gauge splint bar. Rests are evident on the lingual surfaces of abutment wax patterns. **B**, Wax patterns showing labial cut-back for porcelain. Bilateral guide-plane surfaces will be reproduced in metal and are parallel to the path of insertion. **C**, An abutment veneered crown with an appropriate height of contour and a 0.02-inch undercut for the anticipated wrought-wire retainer. **D**, Completed prosthesis splinted between retainer crowns and across the midline. Splint bar with added vertical support provides indirect retention. **E**, Prosthesis inserted intraorally.

of the abutments to those required of the completed crown, then starting controlled tooth reduction (preparation) to accommodate the thickness of the materials for durability, contour, and esthetics. This ensures that the wax patterns and resultant crowns can be restored to the desired form.

### Contouring Wax Patterns

Modern indirect techniques permit the contouring of wax patterns on the master cast with the aid of the surveyor

blade. All abutment teeth to be restored with castings can be prepared at one time and an impression made that will provide an accurate stone replica of the prepared arch. Wax patterns may then be refined on separated individual dies or removable dies. All abutment surfaces facing edentulous areas should be made parallel to the path of placement by the use of the surveyor blade (Figure 14-16). This technique will provide proximal surfaces that will be parallel without any further alteration in the mouth, will permit the most positive

seating of the removable partial denture along the path of placement, and will provide the least amount of undesirable space beneath minor connectors for the lodgment of debris.

### Rest Seats

After the proximal surfaces of the wax patterns have been made parallel, and buccal and lingual contours have been established to satisfy the requirements of stability and retention with the best possible esthetic placement of clasp arms, the occlusal rest seats should be prepared in the wax pattern rather than in the finished restoration. The placement of occlusal rests should be considered at the time the teeth are prepared to receive cast restorations so that there will be sufficient clearance beneath the floor of the occlusal rest seat. Too many times, a completed cast restoration is cemented in the mouth for a removable partial denture abutment without any provision for the occlusal rest having been made in the wax pattern. The dentist then proceeds to prepare an occlusal rest seat in the cast restoration, while ever conscious of the fact that he or she may perforate the casting during the process of forming the rest seat. The unfortunate result is usually a poorly formed rest seat that is too shallow.

If tooth structure has been removed to provide placement of the occlusal rest seat, it may be ideally placed in the wax pattern by using a No. 8 round bur to lower the marginal ridge and establish the outline form of the rest and then using a No. 6 round bur to slightly deepen the floor of the rest seat inside this lowered marginal ridge. This approach provides an occlusal rest that best satisfies the requirements that it be placed so that any occlusal force will be directed axially and that there will be the least possible interference to occlusion with the opposing teeth.

Perhaps the most important function of a rest is the division of stress loads from the removable partial denture to provide the greatest efficiency with the least damaging effect to the supporting abutment teeth. For a distal extension removable partial denture, the rest must be able to transmit occlusal forces to the abutment teeth in a vertical direction only, thereby permitting the least possible lateral stresses to be transmitted to the abutment teeth.

For this reason, the floor of the rest seat should incline toward the center of the tooth so that the occlusal forces, insofar as possible, are centered over the root apex. Any other form but that of a spoon shape can permit locking of the occlusal rest and the transmission of tipping forces to the abutment tooth. A ball-and-socket type of relationship between occlusal rest and abutment tooth is the most desirable. At the same time, the marginal ridge must be lowered so that the angle

formed by the occlusal rest and the minor connector will stand above the occlusal surface of the abutment tooth as little as possible and avoid interference with the opposing teeth. Simultaneously, sufficient bulk must be provided to prevent weakness in the occlusal rest at the marginal ridge. The marginal ridge must be lowered and yet not be the deepest part of the rest preparation. To permit occlusal stresses to be directed toward the center of the abutment tooth, the angle formed by the floor of the occlusal rest with the minor connector should be less than 90 degrees. In other words, the floor of the occlusal rest should incline slightly from the lowered marginal ridge toward the center of the tooth.

This proper form can be readily accomplished in the wax pattern, if care is taken during crown or inlay preparation to provide the location of the rest. If direct restorations are used, sufficient bulk must be present in this area to allow proper occlusal rest seat form without weakening the restoration. There is insufficient evidence to show that direct restorations used as rest seats perform equally to enamel. When the rest seat is placed in sound enamel, this is best accomplished by the use of round carbide burs (No. 4, 6, and 8 sizes) that leave a smooth enamel surface.

Rest seat preparations in sound enamel (or in existing restorations that are not to be replaced) should always follow the recontouring of proximal tooth surfaces. The preparation of proximal tooth surfaces should be done first because if the occlusal portion of the rest seat is placed first and the proximal tooth surface is altered later, the outline form of the rest seat is sometimes irreparably altered.

Following proximal surface recontouring (guided plane preparation), the larger round bur is used to lower the marginal ridge 1.5 to 2.0 mm while at the same time creating the relative outline form of the rest seat. The result is a rest seat preparation with marginal ridge lowered and gross outline form established but without sufficient deepening of the rest seat preparation toward the center of the tooth. A smaller round bur (a No. 4 or 6) may then be used to deepen the floor of the rest seat to a gradual incline toward the center of the tooth. Enamel rods are then smoothed by the planing action of a round bur revolving with little pressure. Abrasive rubber points are sufficient to complete the polishing of the rest seat preparation.

The success or failure of a removable partial denture depends on how well the mouth preparations were accomplished. It is only through intelligent planning and competent execution of mouth preparations that the denture can satisfactorily restore lost dental functions and contribute to the health of the remaining oral tissues.

# CHAPTER

# 15

## Preparation of Abutment Teeth

### CHAPTER OUTLINE

- Classification of Abutment Teeth
- Sequence of Abutment Preparations on Sound Enamel or Existing Restorations
- Abutment Preparations Using Conservative Restorations
- Abutment Preparations Using Crowns
  - Ledges on Abutment Crowns
  - Spark Erosion
  - Veneer Crowns for Support of Clasp Arms
- Splinting of Abutment Teeth
- Use of Isolated Teeth as Abutments
- Missing Anterior Teeth
- Temporary Crowns when a Removable Partial Denture is Being Worn
  - Cementation of Temporary Crowns
- Fabricating Restorations to Fit Existing Denture Retainers

After surgery, periodontal treatment, endodontic treatment, and tissue conditioning of the arch involved, the abutment teeth may be prepared to provide support, stabilization, reciprocation, and retention for the removable partial denture. Rarely, if ever, is the situation encountered in which alterations of the abutment are not indicated because teeth do not develop with guiding planes, rests, and contours to accommodate clasp assemblies.

A favorable response to any deep restorations, endodontic therapy, and the results of periodontal treatment should be established before the removable partial denture is fabricated. If the prognosis of a tooth under treatment becomes unfavorable, its loss can be compensated for by a change in the removable partial denture design. If teeth are lost after the removable partial denture is fabricated, then the removable partial denture must be added to or replaced. Most removable partial denture designs do not lend themselves well to later additions, although this possibility should be considered in the original design of a denture. Every diagnostic aid should be used to determine which teeth are to be used as abutments or are potential abutments for future designs. When an original abutment is lost, it is extremely difficult to effectively modify the removable partial denture to use the next adjacent tooth as a retaining unit.

It is sometimes possible to design a removable partial denture so that a single posterior abutment that is questionable can be retained and used to support one end of a tooth-supported base. Then, if that posterior abutment was lost, it could be replaced with a distal extension base (see Figure 13-25). Such a design must include provision for future indirect retention, flexible clasping on the remaining terminal abutment, and provision for establishing tissue support by a secondary impression. Anterior abutments, which are considered poor risks, may not be so freely used because of the problems involved in adding a new abutment retainer when the original one is lost. Such questionable teeth should be treatment planned for extraction in favor of a better abutment in the original treatment plan.

## CLASSIFICATION OF ABUTMENT TEETH

All abutment teeth must have contour modifications that are customized to the planned prosthesis design. The subject of abutment preparations may be grouped as follows: (1) those abutment teeth that require only minor modifications to their coronal portions; (2) those that are to have restorations other than complete coverage crowns; and (3) those that are to have crowns (complete coverage).

Abutment teeth that require only minor modifications include teeth with sound enamel, those with small restorations not involved in the removable partial denture design, those with acceptable restorations that will be involved in the removable partial denture design, and those that have existing crown restorations requiring minor modification that will not jeopardize the integrity of the crown. The latter may exist as an individual crown or as the abutment of a fixed partial denture.

The use of unprotected abutments has been discussed previously. Although complete coverage of all abutments may be desirable, it is not always possible or practical. The decision to use unprotected abutments involves certain risks of which the patient must be advised and includes responsibility for maintaining oral hygiene and caries control. Making crown restorations fit existing denture clasps is a difficult task; however, the fact that it is possible to do may influence the decision to use uncrowned but otherwise sound teeth as abutments.

Complete coverage restorations provide the best possible support for occlusal rests. If the patient's economic status or other factors beyond the control of the dentist prevent the use of complete coverage restorations, then an amalgam alloy restoration, if properly condensed, is capable of supporting an occlusal rest without appreciable flow for a long period. Any existing silver amalgam alloy restoration about which there is any doubt should be replaced with new amalgam restorations. This should be done before guiding planes and occlusal rest seats are prepared, to allow the restoration to reach maximum strength and be polished.

Continued improvement in dimensional stability, strength, and wear resistance of composite resin restorations will add another dimension to the preparation and modification of abutment teeth for removable partial dentures that should be less invasive than placement of complete coverage restorations and more economical.

## SEQUENCE OF ABUTMENT PREPARATIONS ON SOUND ENAMEL OR EXISTING RESTORATIONS

Abutment preparations on sound enamel or on existing restorations that have been judged as acceptable should be done in the following order:

1. Proximal surfaces parallel to the path of placement should be prepared to provide guiding planes (Figure 15-1, A).
2. Tooth contours should be modified (see Figure 15-1, B and C), lowering the height of contour so that (a) the

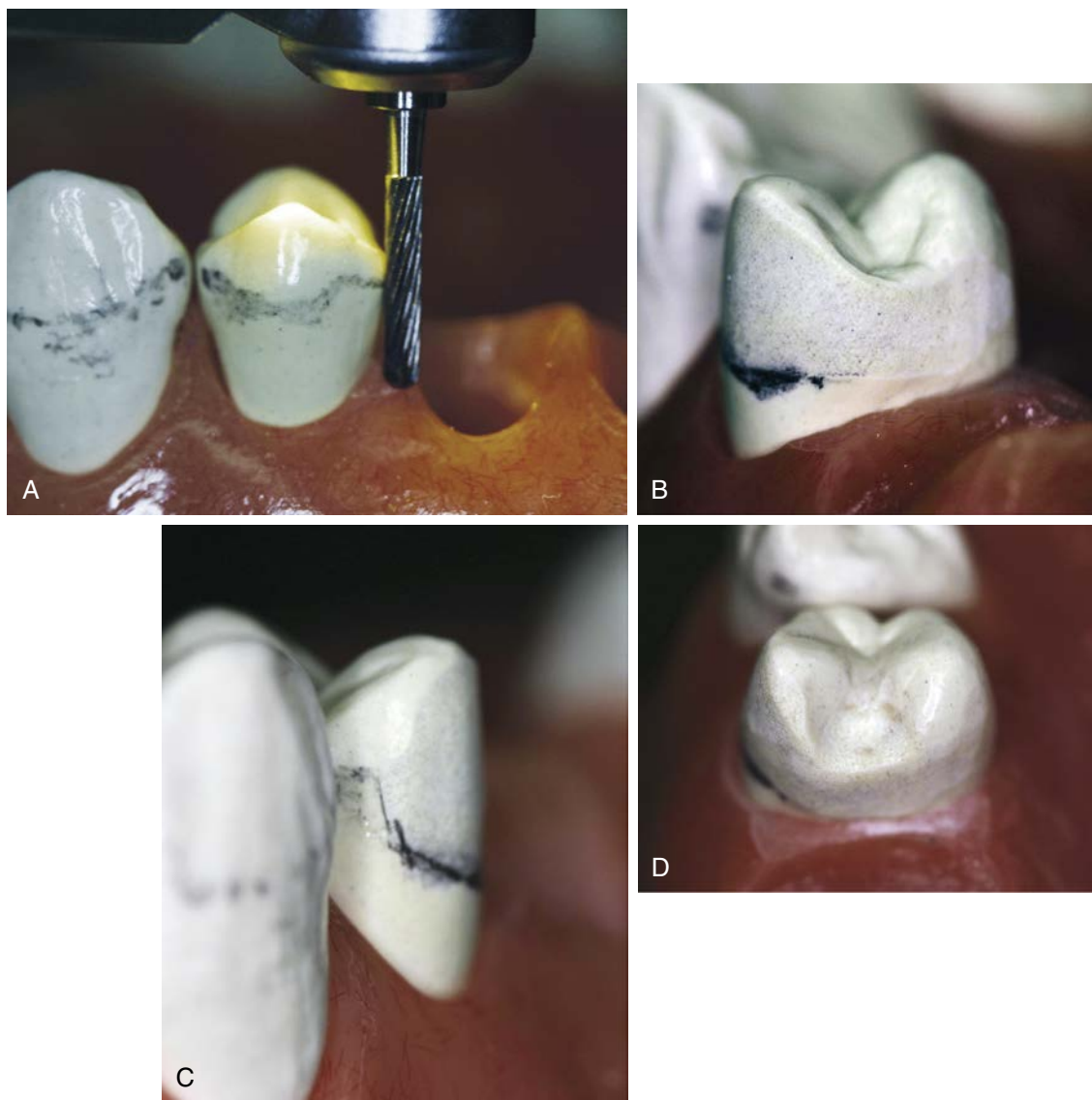
origin of circumferential clasp arms may be placed well below the occlusal surface, preferably at the junction of the middle and gingival thirds; (b) retentive clasp terminals may be placed in the gingival third of the crown for better esthetics and better mechanical advantage; and (c) reciprocal clasp arms may be placed on and above a height of contour that is no higher than the cervical portion of the middle third of the crown of the abutment tooth.

3. After alterations of axial contours are accomplished and before rest seat preparations are instituted, an impression of the arch should be made in irreversible hydrocolloid and a cast formed in a fast-setting stone. This cast can be returned to the surveyor to determine the adequacy of axial alterations before proceeding with rest seat preparations. If axial surfaces require additional axial recontouring, this can be performed during the same appointment and without compromise.
4. Occlusal rest areas should be prepared that will direct occlusal forces along the long axis of the abutment tooth (see Figure 15-1, D). Mouth preparation should follow the removable partial denture design that was outlined on the diagnostic cast at the time the cast was surveyed and the treatment plan confirmed. Proposed changes to abutment teeth should be made on the diagnostic cast and outlined in colored pencil to indicate the area, amount, and angulation of the modification to be done (see Chapter 13). Although occlusal rest seats may also be prepared on the diagnostic cast, indication of their location in colored pencil is usually sufficient for the experienced dentist because rest preparations follow a definite pattern (see Chapter 6).

## ABUTMENT PREPARATIONS USING CONSERVATIVE RESTORATIONS

Conventional inlay preparations are permissible on the proximal surface of a tooth not to be contacted by a minor connector of the removable partial denture. On the other hand, proximal and occlusal surfaces that support minor connectors and occlusal rests require somewhat different treatment. The extent of occlusal coverage (i.e., whether cusps are covered) will be governed by the usual factors, such as the extent of caries, the presence of unsupported enamel walls, and the extent of occlusal abrasion and attrition.

When an inlay is the restoration of choice for an abutment tooth, certain modifications of the outline form are necessary. To prevent the buccal and lingual proximal margins from lying at or near the minor connector or the occlusal rest, these margins must be extended well beyond the line angles of the tooth. This additional extension may be accomplished by widening the conventional box preparation. However, the margin of a cast restoration produced for such a preparation may be quite thin and may be damaged by the clasp during placement or removal of the removable partial denture. This hazard may be avoided by extending the outline of the box beyond the line angle, thus producing a strong restoration-to-tooth junction.

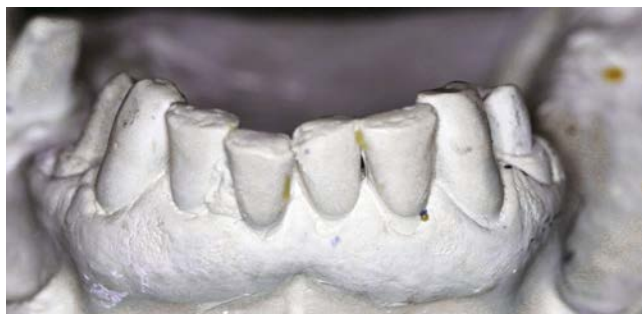

**FIGURE 15-1** Abutment contours should be altered during mouth preparations in the following sequence. **A**, The proximal surface is prepared parallel to the path of placement to create a guiding plane. **B**, Height of contour on the buccal and lingual surfaces is lowered when necessary to permit the retentive clasp terminus to be located within the gingival third of the crown, bracing part of the retentive arm at the junction of the middle and gingival thirds of the crown, and the reciprocal clasp arm on the opposite side of tooth to be placed no higher than the cervical portion of the middle third of the crown. **C**, The area of the tooth at which the retentive clasp arm originates should be altered if necessary to permit a more direct approach to the gingival third of the tooth: (1) incorrect position of retentive clasp arm; (2) area of tooth modified to accommodate better position of retentive clasp arm; (3) more ideal position of retentive clasp arm. **D**, Occlusal rest preparation that will direct occlusal forces along the long axis of the tooth should be the final step in mouth preparations.

In this type of preparation, the pulp is particularly vulnerable unless the axial wall is curved to conform to the external proximal curvature of the tooth. When caries is of minimal depth, the gingival seat should have an axial depth at all points about the width of a No. 559 fissure bur. It is of utmost importance that the gingival seat be placed where it can be easily accessed to maintain good oral hygiene. The proximal contour necessary to produce the proper guiding plane surface and the close proximity of the minor connector render this area particularly vulnerable to future caries. Every effort should be made to provide the restoration with

maximum resistance and retention, as well as with clinically imperceptible margins. The first requisite can be satisfied by preparing opposing cavity walls 5 degrees or less from parallel and producing flat floors and sharp, clean line angles.

It is sometimes necessary to use an inlay on a mandibular first premolar for the support of an indirect retainer. The narrow occlusal width bucco-lingually and the lingual inclination of the occlusal surface of such a tooth often complicate the two-surface inlay preparation. Even the most exacting occlusal cavity preparation often leaves a thin and weak lingual cusp remaining.



**FIGURE 15-2** Solid cast of multiple abutment crowns for a removable partial denture. Wax patterns for crown #21, #28, #30, and #31 can be completed at the same time using the identical cast orientation. This allows control of the path of insertion features on all fitting surfaces of the removable prostheses.

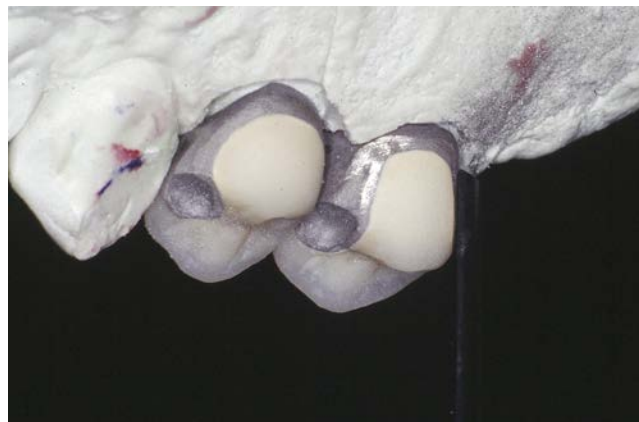### ABUTMENT PREPARATIONS USING CROWNS

When multiple crowns are to be restored as removable partial denture abutments, it is best that all wax patterns be made at the same time. A cast of the arch with removable dies may be used if they are stable and sufficiently keyed for accuracy. If preferred, contouring wax patterns and making them parallel may be done on a solid cast of the arch (Figure 15-2), with individual dies used to refine margins. Modern impression materials and indirect techniques make either method equally satisfactory.

The same sequence for preparing teeth in the mouth applies to the contouring of wax patterns. After the cast has been placed on the surveyor to conform to the selected path of placement and after the wax patterns have been preliminarily carved for occlusion and contact, proximal surfaces that are to act as guiding planes are carved parallel to the path of placement with a surveyor blade. Guiding planes are extended from the marginal ridge to the junction of the middle and gingival thirds of the tooth surface involved. One must be careful not to extend the guiding plane to the gingival margin because the minor connector must be relieved when it crosses the gingivae. A guiding plane that includes the occlusal two thirds or even one third of the proximal area is usually adequate without endangering gingival tissues.

After the guiding planes are parallel and any other contouring to accommodate the removable partial denture design is accomplished, occlusal rest seats are carved in the wax pattern. This method has been outlined in Chapter 6.

It should be emphasized that critical areas prepared in wax should not be destroyed by careless spruing or polishing. The wax pattern should be sprued to preserve paralleled surfaces and rest areas. Polishing should consist of little more than burnishing. Rest seat areas should need only refining with round finishing burs. If some interference by spruing is unavoidable, the casting must be returned to the surveyor for proximal surface refinement. This can be done accurately with the aid of a handpiece holder attached to the vertical spindle of the surveyor or some similar machining device.



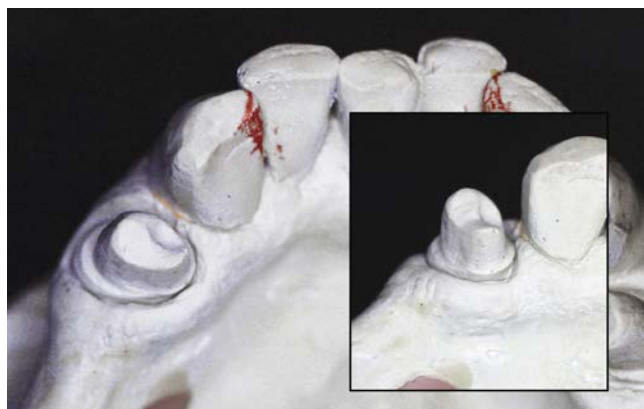
**FIGURE 15-3** Metal ceramic crowns for teeth #4 and #5 demonstrating occlusal rests in metal and evidence of palatal finishing procedures. The distal surface of #4 provides a guide-plane surface that is continued onto a portion of the lingual surface for maximum stabilization.

One of the advantages of making cast restorations for abutment teeth is that mouth preparations that would otherwise have to be done in the mouth may be done on the surveyor with far greater accuracy. It is generally impossible to make several proximal surfaces parallel to one another when preparing them intraorally. The opportunity for contouring wax patterns and making them parallel on the surveyor in relation to a path of placement should be used to its full advantage whenever cast restorations are being made.

The ideal crown restoration for a removable partial denture abutment is the complete coverage crown, which can be carved, cast, and finished to ideally satisfy all requirements for support, stabilization, and retention without compromise for cosmetic reasons (Figure 15-3). Porcelain veneer crowns can be made equally satisfactory but only by the added step of contouring the veneered surface on the surveyor before the final glaze. If this is not done, retentive contours may be excessive or inadequate.

The three-quarter crown does not permit creation of retentive areas as does the complete coverage crown. However, if buccal or labial surfaces are sound and retentive areas are acceptable or can be made so by slight modification of tooth surfaces, the three-quarter crown is a conservative restoration of merit. The same criteria apply in the decision to leave a portion of an abutment unprotected, as in the decision to leave any tooth unprotected that is to serve as a removable partial denture abutment.

Regardless of the type of crown used, preparation should be made to provide the appropriate depth for the occlusal rest seat. This is best accomplished by altering the axial contours of the tooth to the ideal before preparing the tooth and creating a depression in the prepared tooth at the occlusal rest area (Figure 15-4). Because the location of occlusal rests is established during treatment planning, this information will be known in advance of any tooth preparations. If, for example, double occlusal rests are to be used, this will be



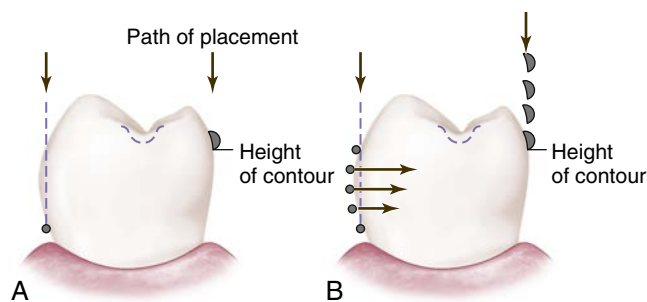
**FIGURE 15-4** Metal-ceramic crown preparation on tooth #21 shows mesial-occlusal rest space provided in the crown preparation at the mesial. The *inset picture* gives a perspective of the vertical height this provides for the rest to be prepared in the wax pattern.

known so that the tooth can be prepared to accommodate the depth of both rests. It is inexcusable when waxing a pattern to find that a rest seat has to be made shallower than is desirable because of post-treatment planning. It can also create serious problems when a rest seat has to be made shallow in an existing crown or inlay because its thickness is not known. The opportunity for creating an ideal rest seat (if it has been properly treatment planned) depends only on the few seconds it takes to create a space for it.

### Ledges on Abutment Crowns

In addition to providing abutment protection, more ideal retentive contours, definite guiding planes, and optimum occlusal rest support, complete coverage restorations on teeth used as removable partial denture abutments offer still another advantage not obtainable on natural teeth. This is the crown ledge or shoulder, which provides effective stabilization and reciprocation.

The functions of the reciprocal clasp arm have been stated in Chapter 6. Briefly, these are reciprocation, stabilization, and auxiliary indirect retention. Any rigid reciprocal arm may provide horizontal stabilization if it is located on axial surfaces parallel to the path of placement. To a large extent, because it is placed at the height of convexity, a rigid reciprocal arm may also act as an auxiliary indirect retainer. However, its function as a reciprocating arm against the action of the retentive clasp arm is limited to stabilization against possible orthodontic movement when the denture framework is in its terminal position. Such reciprocation is needed when the retentive clasp produces an active orthodontic force because of accidental distortion or improper design. Reciprocation, to prevent transient horizontal forces that may be detrimental to abutment stability, is most needed when the restoration is placed or when a dislodging force is applied. Perhaps the term *orthodontic force* is incorrect, because the term signifies a slight



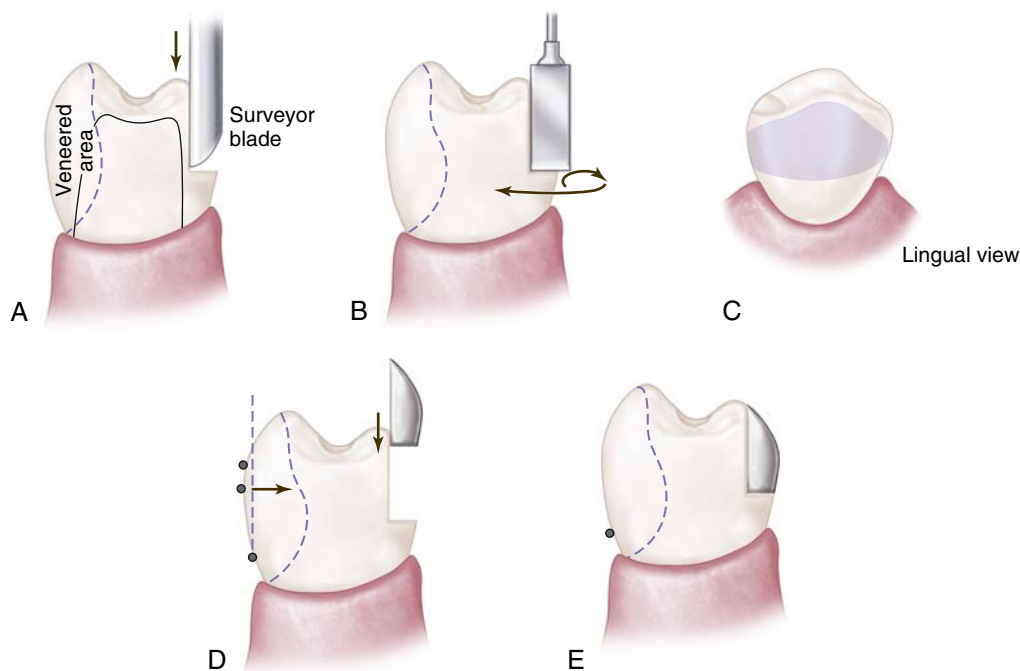
**FIGURE 15-5** **A**, Incorrect relationship of retentive and reciprocal clasp arms to each other when the removable partial denture framework is fully seated. As the retentive clasp arm flexes over the height of contour during placement and removal, the reciprocal clasp arm cannot be effective because it is not in contact with the tooth until the denture framework is fully seated. **B**, Horizontal forces applied to the abutment tooth as the retentive clasp flexes over the height of contour during placement and removal. Open circles at the top and bottom illustrate that the retentive clasp is passive only at its first contact with the tooth during placement and when in its terminal position with the denture fully seated. During placement and removal, a rigid clasp arm placed on the opposite side of the tooth cannot provide resistance against these horizontal forces. See Figure 15-6 for a method to ensure true reciprocation.

but continuous influence that would logically reach equilibrium when the tooth is orthodontically moved. Instead, the transient forces of placement and removal are intermittent but forceful, which can lead to periodontal destruction and eventual instability rather than to orthodontic movement.

True reciprocation is not possible with a clasp arm that is placed on an occlusally inclined tooth surface, because it does not become effective until the prosthesis is fully seated. When a dislodging force is applied, the reciprocal clasp arm, along with the occlusal rest, breaks contact with the supporting tooth surfaces, and they are no longer effective. Thus, as the retentive clasp flexes over the height of contour and exerts a horizontal force on the abutment, reciprocation is nonexistent just when it is needed most (Figure 15-5).

True reciprocation can be obtained only by creating a path of placement for the reciprocal clasp arm that is parallel to other guiding planes. In this manner, the inferior border of the reciprocal clasp makes contact with its guiding surface before the retentive clasp on the other side of the tooth begins to flex (Figure 15-6). Thus, reciprocation exists during the entire path of placement and removal. A ledge on the abutment crown acts as a terminal stop for the reciprocal clasp arm. It also augments the occlusal rest and provides indirect retention for a distal extension removable partial denture.

A ledge on an abutment crown has still another advantage. The usual reciprocal clasp arm is half-round, and therefore convex, and is superimposed on and increases



**FIGURE 15-6** **A**, Preparation of the ledge in a wax pattern with a surveyor blade parallel to the path of placement. **B**, Refinement of the ledge on casting, using a suitable stone or milling device in a handpiece attached to the dental surveyor or a specialized drill press for the same purpose. **C**, Approximate width and depth of the ledge formed on the abutment crown, which will permit the reciprocal clasp arm to be inlaid within the normal contours of the tooth. **D**, True reciprocation throughout the full path of placement and removal is possible when the reciprocal clasp arm is inlaid onto the ledge on the abutment crown. **E**, Direct retainer assembly is fully seated. The reciprocal arm restores the lingual contour of the abutment.

the bulk of an already convex surface. A reciprocal clasp arm built on a crown ledge is actually inlaid into the crown and reproduces more normal crown contours (see [Figure 15-6](#)). The patient's tongue then contacts a continuously convex surface rather than the projection of a clasp arm. Unfortunately, the enamel is not thick enough nor the tooth so shaped that an effective ledge can be created on an unrestored tooth. Narrow enamel shoulders are sometimes used as rest seats on anterior teeth, but these do not provide the parallelism that is essential to reciprocation during placement and removal.

The crown ledge may be used on any complete or three-quarter crown restored surface that is opposite the retentive side of an abutment tooth. It is used most frequently on premolars and molars but also may be used on canine restorations. It is not ordinarily used on buccal surfaces for reciprocation against lingual retention because of the excessive display of metal, but it may be used just as effectively on posterior abutments when esthetics is not a factor.


The fact that a crown ledge is to be used should be known in advance of crown preparation to ensure sufficient removal of tooth structure in this area. Although a shoulder or ledge is not included in the preparation itself, adequate space must be provided so that the ledge may be made sufficiently wide and the surface above it made parallel to the path of placement. The ledge should be

placed at the junction of the gingival and middle thirds of the tooth, curving slightly to follow the curvature of the gingival tissues. On the side of the tooth where the clasp arm will originate, the ledge must be kept low enough to allow the origin of the clasp arm to be wide enough for sufficient strength and rigidity.

In forming the crown ledge, which is usually located on the lingual surface, the wax pattern of the crown is completed except for refinement of the margins before the ledge is carved. After the proximal guiding planes and the occlusal rests and retentive contours are formed, the ledge is carved with the surveyor blade so that the surface above is parallel to the path of placement. Thus, a continuous guiding plane surface will exist from the proximal surface around the lingual surface.

The full effectiveness of the crown ledge can be achieved only when the crown is returned to the surveyor for refinement after casting. To afford true reciprocation, the crown casting must have a surface above the ledge that is parallel to the path of placement. This can be accomplished with precision only by machining the casting parallel to the path of placement with a handpiece holder in the surveyor or some other suitable machining device ([Figure 15-7](#)).

Similarly, the parallelism of proximal guiding planes needs to be perfected after casting and polishing. Although it is possible to approximate parallelism and,



**FIGURE 15-7** A milling machine used to prepare parallel surfaces, internal rest seats, lingual grooves, and ledges in cast restorations. Such a device permits more precise milling than is possible with a dental handpiece attached to the dental surveyor. To be effective, the cast must be positioned on the drill in such a manner that the previously established path of placement is maintained. A movable stage or base therefore should be adjustable until the relation of the cast to the axis of the drill has been made the same as that obtained when the cast was on the dental surveyor.

at the same time, form the crown ledge on the wax pattern with a surveyor blade, some of its accuracy is lost in casting and polishing. The use of suitable burs such as No. 557, 558, and 559 fissure burs and true cylindrical carborundum stones in the handpiece holder permits the paralleling of all guiding planes on the finished casting with the accuracy necessary for the effectiveness of those guiding plane surfaces.

The reciprocal clasp arm is ultimately waxed on the investment cast so that it is continuous with the ledge inferiorly and contoured superiorly to restore the crown contour, including the tip of the cusp. It is obvious that polishing must be controlled so as not to destroy the form of the shoulder that was prepared in wax or the parallelism of the guiding plane surface. It is equally vital that the removable partial denture casting be finished with great care so that the accuracy of the counterpart is not destroyed. Modern investments, casting alloys, and polishing techniques make this degree of accuracy possible.

### Spark Erosion

Spark erosion technology is a highly advanced system for producing the ultimate in precision fit of the reciprocal arm to the ledge on the casting. This technology uses a tool system that permits repositioning of the casting with

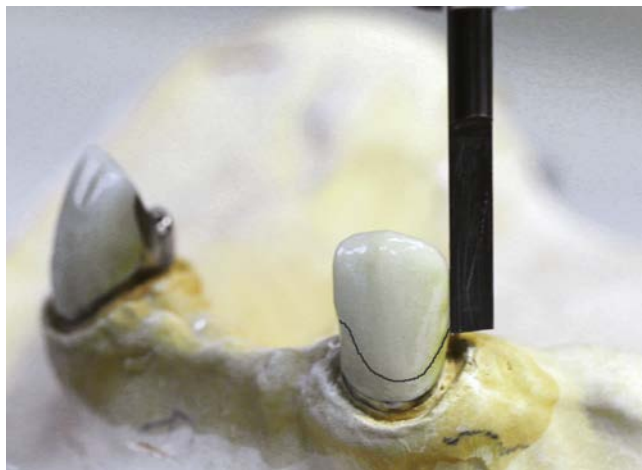
great accuracy and an electric discharge machine that is programmed to erode minute metal particles through periodic spark intervals.

Regardless of the method or technique used, it is imperative that the predetermined cast orientation be maintained to ensure that ledges and proximal guide planes remain parallel.

### Veneer Crowns for Support of Clasp Arms

For cosmetic reasons, resin and porcelain veneer crowns are used on abutment teeth that would otherwise display an objectionable amount of metal. They may be present in the form of porcelain veneers retained by pins and cemented to the crown, porcelain fused directly to a cast metal substructure, porcelain fused to a machined coping, cast porcelain, pressed ceramic crowns, computer-assisted designed and machined ceramic restorations, or acrylic-resin processed directly to a cast crown. The development of abrasion-resistant composites offers materials suitable for veneering that can withstand clasp contact, thereby eliminating an undesirable display of metal.

Veneer crowns must be contoured to provide suitable retention. This means that the veneer must be slightly overcontoured and then shaped to provide the desired undercut for the location of the retentive clasp arm (Figure 15-8).



**FIGURE 15-8** A porcelain veneer crown is resurveyed following adjustment, glazing, and polishing. It is important to survey crowns returned from the laboratory before cementation. The best time to ensure control of all abutment contours for a removable partial denture is when surveyed crowns are used and they are resurveyed before permanent placement.

If the veneer is of porcelain, this procedure must precede glazing, and if it is of resin, it must precede final polishing. If this important step in making veneered abutments is neglected or omitted, excessive or inadequate retentive contours may result.

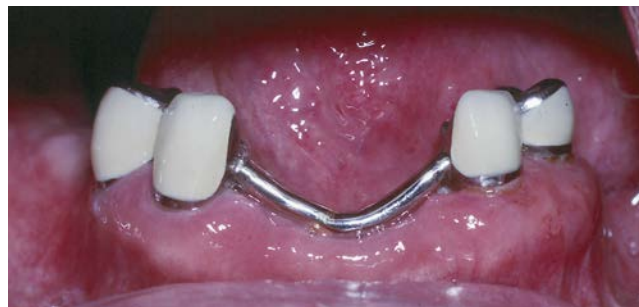In limited clinical trials, porcelain laminates demonstrated resistance to wear of 5-year equivalence. The porcelain, however, resulted in slight wear on the clasps.

The flat underside of the cast clasp makes sufficient contact with the surface of the veneer so that abrasion of a resin veneer may result. Although the underside of the clasp may be polished (with some loss in accuracy of fit), abrasion results from the trapping and holding of food debris against the tooth surface as the clasp moves during function. Therefore, unless the retentive clasp terminal rests on metal, glazed porcelain should be used to ensure the future retentiveness of the veneered surface. Present-day acrylic-resins, which are cross-linked copolymers, will withstand abrasion for considerable time, but not nearly to the same degree as porcelain. Therefore acrylic-resin veneers are best used in conjunction with metal that supports the half-round clasp terminal.

### SPLINTING OF ABUTMENT TEETH

Often, a tooth is considered too weak to use alone as a removable partial denture abutment because of the short length or excessive taper of a single root, or because of bone loss resulting in an unfavorable crown-to-root ratio. In such instances, splinting to the adjacent tooth or teeth can be used as a means of improving abutment support. Thus, two single-rooted teeth serve as a multi-rooted abutment.

Splinting should not be used to retain a tooth that would otherwise be condemned for periodontal reasons. When the



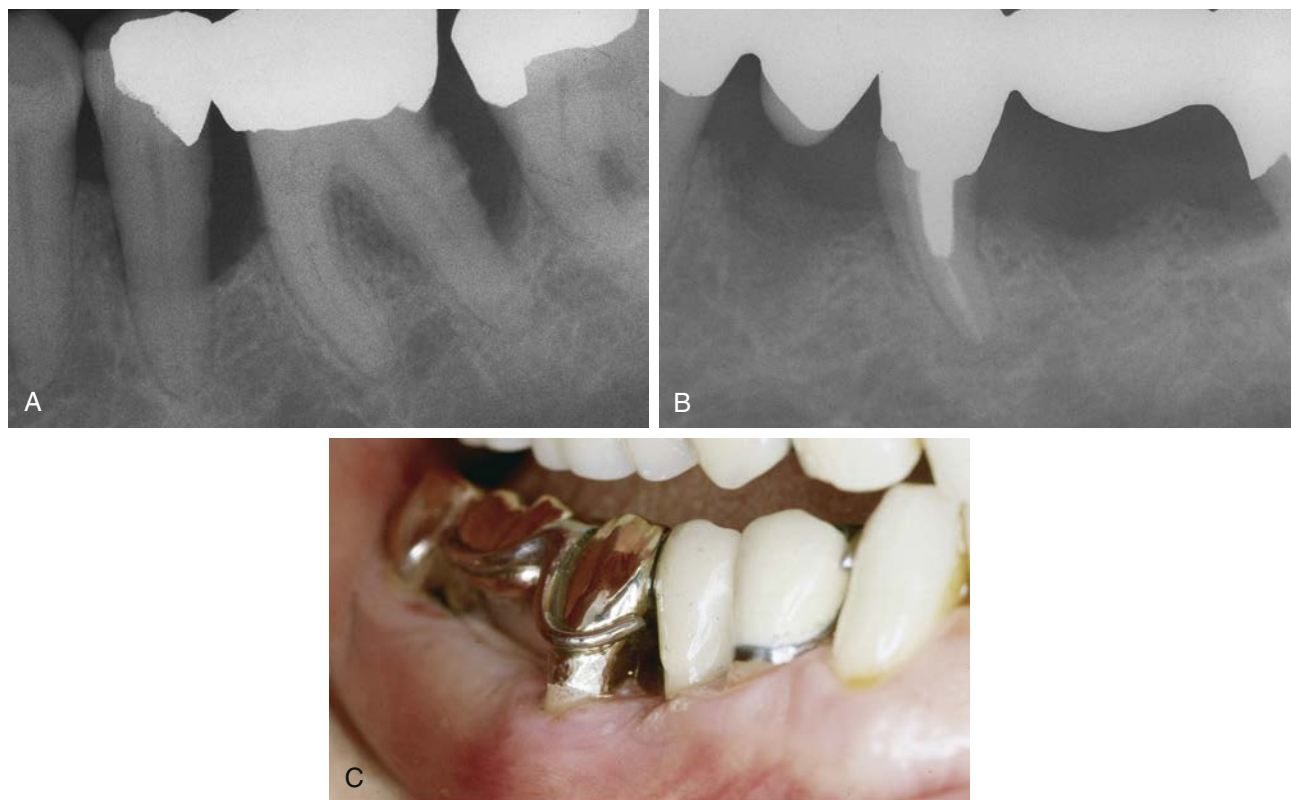
**FIGURE 15-9** First premolars and canines have been splinted in this Class I, modification 1, partially edentulous arch. The splint bar was added to provide cross-arch stabilization for splinted abutments and to support and retain the anterior segment of the removable restoration. The prospective longevity of the abutments has been enhanced.

length of service of a restoration depends on the serviceability of an abutment, any periodontally questionable tooth should be condemned in favor of using an adjacent healthy tooth as the abutment, even though the span is increased one tooth by doing so.

The most common application of the use of multiple abutments is the splinting of two premolars or a first premolar and a canine (Figure 15-9). Mandibular premolars generally have round and tapered roots, which are easily loosened by rotational, as well as by tipping, forces. They are the weakest of the posterior abutments. Maxillary premolars also often have tapered roots, which may make them poor risks as abutments, particularly when they will be called on to resist the leverage of a distal extension base. Such teeth are best splinted by casting or soldering two crowns together. When a first premolar to be used as an abutment has poor root form or support, it is best that it be splinted to the stronger canine.

Anterior teeth on which lingual rests are to be placed often must be splinted together to avoid orthodontic movement of individual teeth. Mandibular anterior teeth are seldom used for support, but if they are, splinting of the teeth involved is advisable. When splinting is impossible, individual lingual rests on cast restorations may be slightly inclined apically to avoid possible tooth displacement, or lingual rests may be used in conjunction with incisal rests, slightly engaging the labial surface of the teeth.

Lingual rests should always be placed as low on the cingulum as possible, and single anterior teeth, other than canines, should not be used for occlusal support. Where lingual rests are used on central and lateral incisors, as many teeth as possible should be included to distribute the load, thereby minimizing the force on any one tooth. Even so, some movement of individual teeth is likely to occur, particularly when they are subjected to the forces of indirect retention or when bone support is compromised. This is best avoided by splinting several teeth with united cast restorations. The condition of the teeth and cosmetic considerations will dictate whether complete crowns, three-quarter crowns, pin ledge inlays,



**FIGURE 15-10** **A**, Periodontal disease required removal of #30 distal and #31 mesial roots. **B**, The first premolar and hemi-sected roots were splinted using a five-unit fixed partial denture. **C**, Fixed prosthesis provided cross-arch support, stability, and retention to a Kennedy Class II removable partial denture.

resin-bonded retainers, or composite restorations will be used for this purpose.

Splinting of molar teeth for multiple abutment support is less frequently used because they are generally multi-rooted. A two- or three-rooted tooth that is not strong enough alone is probably a poor abutment risk. However, there may be notable exceptions when a molar abutment would benefit from the effect of splinting, as in a hemi-sected molar root (Figure 15-10).

### USE OF ISOLATED TEETH AS ABUTMENTS

The average abutment tooth is subjected to some distal tipping, rotation, torquing, and horizontal movement, all of which must be held to a minimum by the quality of tissue support and the design of the removable partial denture. The isolated abutment tooth, however, is subjected also to mesial tipping caused by lack of proximal contact. Despite indirect retention, some lifting of the distal extension base is inevitable, causing torque to the abutment.

In a tooth-supported prosthesis, an isolated tooth may be used as an abutment by including a fifth abutment for additional support. Thus, rotational and horizontal forces are resisted by the additional stabilization obtained from the fifth abutment. When two such isolated abutments exist, a sixth abutment should be included for the same reason.

Thus, the two canines, the two isolated premolars, and two posterior teeth are used as abutments.

In contrast, an isolated anterior abutment adjacent to a distal extension base usually should be splinted to the nearest tooth by means of a fixed partial denture. The effect is twofold: (1) the anterior edentulous segment is eliminated, thereby creating an intact dental arch anterior to the edentulous space; and (2) the isolated tooth is splinted to the other abutment of the fixed partial denture, thereby providing multiple abutment support. Splinting should be used here only to gain multiple abutment support rather than to support an otherwise weak abutment tooth.

Although splinting is advocated for abutment teeth that are considered too weak to risk being used alone, a single abutment standing alone in the dental arch anterior to a distal extension basal seat generally requires the splinting effect of a fixed partial denture (Figures 15-11 and 15-12). Even though the form and length of the root and the supporting bone seem to be adequate for an ordinary abutment, the fact that the tooth lacks proximal contact endangers the tooth when it is used to support a distal extension base removable partial denture.

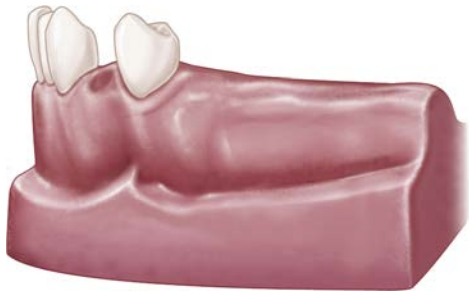A second factor that may influence the decision to use an isolated tooth as an abutment is an esthetic consideration. However, neither esthetics nor economics should deter the dentist from recommending to the patient that an isolated

tooth to be used as a terminal abutment should be given the advantage of splinting by means of a fixed partial denture. If compromises are necessary, the patient must assume responsibility for use of the isolated tooth as an abutment.

The economic aspect of the use of fixed restorations as part of the mouth preparations for a removable partial denture is essentially the same as that for any other splinting procedure—the best design of the fixed partial denture that will ensure the longevity of its service makes the additional procedure and expense necessary. Although it must be recognized that economic considerations, combined with a particularly favorable prognosis of an isolated tooth, may influence the decision to forego the advantages of using a fixed partial denture, the original treatment plan should include this provision, even though the alternative method may be accepted for economic reasons.

MISSING ANTERIOR TEETH

When a removable partial denture is used to replace missing posterior teeth, especially in the absence of distal abutments, any additional missing anterior teeth are best replaced by means of fixed restorations rather than included in the removable partial denture. In any distal extension situation,

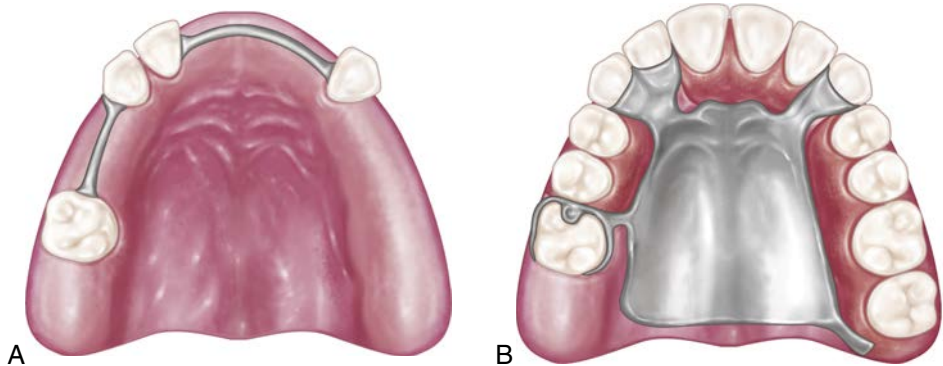


**FIGURE 15-11** Lone-standing premolar should be splinted to the canine with a fixed partial denture. Not only will the design of the removable partial denture be simplified, but the longevity of abutment service by the premolar will be greatly extended.

some anteroposterior rotational action results from the addition of an anterior segment to the denture. The ideal treatment plan, which considers the anterior edentulous space separately, may result in conflict with economic and esthetic realities. Each situation must be treated according to its own merits. Often the best esthetic result can be obtained by replacing missing anterior teeth and tissues with the removable partial denture rather than with a fixed restoration. From a biomechanical standpoint, however, it is generally advisable that a removable partial denture should replace the missing posterior teeth only after the remainder of the anterior arch has been made intact by fixed restorations.

Although the need for compromise is recognized, the decision to include an anterior segment on the denture depends largely on the support available for that part of the removable partial denture. The greater the number of natural anterior teeth remaining, the better is the available support for the edentulous segment. If definite rest seats can be prepared on multiple abutments, the anterior segment may be treated as any other tooth-bounded modification space. Sound principles of rest support apply just as much as elsewhere in the arch. Inclined tooth surfaces should not be used for occlusal support, nor should rests be placed on unprepared lingual surfaces. The best possible support for an anterior segment is multiple support extending, if possible, posteriorly across prepared lingual rest seats on the canine teeth to mesio-occlusal rest seats on the first premolars. Such support would permit the missing anterior teeth to be included in the removable partial denture, often with some cosmetic advantages over fixed restorations.

In some instances, the replacement of anterior teeth by means of a removable partial denture cannot be avoided. However, without adequate tooth support, any such prosthesis lacks the stability that results from replacing only the posterior teeth with the removable partial denture and the anterior teeth with fixed restorations. When anterior teeth have been lost through accident or have been missing for some time, resorption of the anterior residual ridge may have progressed to the point that neither fixed nor removable pontics may be butted to the residual ridge. In such



**FIGURE 15-12** **A**, Isolated abutments have been splinted using splint bars. **B**, The removable partial denture is more adequately supported by the splinting mechanism shown in **A** than could be realized with isolated abutments.

instances, for reasons of esthetics and orofacial tissue support, the missing teeth must be replaced with a denture base supporting teeth that are more nearly in their original position, considerably forward from the residual ridge. Although such teeth may be positioned to better cosmetic advantage, the contouring and coloring of a denture base to be esthetically pleasing require the maximum artistic effort of both the dentist and the technician. Such a removable partial denture, both from an esthetic and a biomechanical standpoint, is one of the most difficult of all prosthetic restorations. However, a splint bar, connected by abutments on both sides of the edentulous space, will provide much-needed support and retention to the anterior segment of the removable partial denture. Because the splint bar will provide vertical support, rest seats on abutments adjacent to the edentulous area need not be prepared, thus simplifying an anterior restoration to some extent.

The concept of a dual path of placement to enhance the esthetic replacement of missing anterior teeth with a removable partial denture is recognized. Sources of information on this concept are made available in the Selected Reading Resources under "Partial Denture Design."

### TEMPORARY CROWNS WHEN A REMOVABLE PARTIAL DENTURE IS BEING WORN

Occasionally, an existing removable partial denture must remain serviceable while the mouth is being prepared for a new prosthesis. In such situations, temporary crowns must be made that will support the old removable partial denture and will not interfere with its placement and removal. Acrylic-resin temporary crowns that duplicate the original form of the abutment teeth must be made.

The technique for making temporary crowns to fit direct retainers is similar to that used for other types of acrylic-resin temporary crowns. The principal difference is that an impression, made with an elastic impression material, must be made of the entire arch with the existing removable partial denture in place. It is necessary that the removable partial denture remain in the impression when it is removed from the mouth. If it remains in the mouth, it must be removed and inserted into the impression in its designated position. The impression with the removable partial denture in place is disinfected, wrapped in a wet paper towel (if irreversible hydrocolloid was used as the impression material) or placed in a plastic bag, and set aside while the tooth or teeth are being prepared for new crowns.

After the preparations are completed and the impressions and jaw relation records have been made, the prepared teeth are dried and lubricated. The original impression is trimmed to eliminate any excess, undercuts, and interproximal projections that would interfere with the replacement of the impression in the mouth.

The methyl methacrylate acrylic-resins, composites, copolymers, and fiber-reinforced resins may serve as excellent materials for temporary crowns in conjunction with removable

partial dentures. Making temporary crowns requires a small mixing cup or dappen dish; a cement spatula; and a small, disposable, plastic syringe. Autopolymerizing acrylic-resin of the appropriate tooth color is placed in the cup or dappen dish, and monomer is added to make a slightly viscous mix. The volume should be slightly in excess of the amount estimated to fabricate the temporary restorations. The mix should be spatulated to a smooth consistency and the mix immediately poured into the barrel of the disposable syringe. A small amount of the mix should be injected over and around the margins of the prepared teeth. The remaining material should be injected into the impression of the prepared teeth. The impression is seated into the mouth, where the dentist holds it in place until sufficient time has elapsed for it to reach a stiff, rubbery stage, or a consistency recommended by the manufacturer. This again must be based on experience with the particular resin used. At this time, the impression is removed. The crowns may remain in the impression. If so, they are stripped out of the impression, all excess is trimmed away with scissors, and the crowns are resealed on the prepared abutments. The removable partial denture is then removed from the impression and resealed in the mouth onto the temporary crowns, which should be in a stiff-rubbery state. The patient may bring the teeth into occlusion to reestablish the former position and occlusal relationship of the existing removable partial denture.

After the resin crown or crowns have polymerized, the removable partial denture is removed and the crowns remain on the teeth. These are then carefully removed, contoured to accommodate oral hygiene access, trimmed, polished, and temporarily cemented. The result is a temporary crown that restores the original abutment contours and allows the removable partial denture to be placed and removed without interference while temporarily providing the same support to the denture that existed before the teeth were prepared.

### Cementation of Temporary Crowns

Cementation of temporary crowns may require slight relief of the internal surface of the crowns to accommodate the temporary cement and to facilitate removal. The temporary cement should be thin and applied only to the inside gingival margin of the crowns to ensure complete seating. As soon as the temporary cement has hardened, the occlusion should be checked and adjusted accordingly. Regardless of the type of temporary cement used, any excess that might irritate the gingivae should be removed.

### FABRICATING RESTORATIONS TO FIT EXISTING DENTURE RETAINERS

It is often necessary that an abutment tooth be restored with a complete crown (or other restoration) that fits the inside of the clasp of an otherwise serviceable removable partial denture. One technique for doing so is simple enough, but it requires that an indirect-direct pattern be made and therefore justifies a fee for service above that required for the usual restoration.

The technique for making a crown to fit the inside of a clasp is as follows: An irreversible hydrocolloid impression of the mouth is made with the removable partial denture in place. This impression, which is used to make the temporary crown, is wrapped in a wet paper towel or placed in a plastic bag and set aside while the tooth is being prepared. Even though several abutment teeth are to be restored, it is usually necessary that each temporary restoration be completed before the next one is begun. This is necessary so that the original support and occlusal relationship of the removable partial denture can be maintained as each new temporary crown is being made. During preparation of the abutment tooth, the removable partial denture is replaced frequently to ascertain that sufficient tooth structure has been removed to allow for the thickness of the casting. When the preparation is completed, an individual impression of the tooth is obtained from which a stone die is made. A temporary crown is then made in the original irreversible hydrocolloid impression, as outlined in the preceding paragraphs. It is trimmed, polished, and temporarily cemented, and the removable partial denture is returned to the mouth. The patient is dismissed after the excess cement has been removed.

On the stone die made from the individual impression, a thin, autopolymerizing resin coping will be formed with a brush technique. The stone die should first be trimmed to the finishing line of the preparation, which is then delineated with a pencil, and the die painted with a tinfoil substitute. A separating material, such as a tinfoil substitute, should be used and will form a thin film on a cold, dry surface. Not all tinfoil substitutes are suitable for this purpose. With autopolymerizing resin powder and liquid in separate dappen dishes and a fine brush, a coping of resin of uniform thickness is painted onto the die. This should extend not quite to the pencil line representing the limit of the crown preparation. After hardening, the resin coping may be removed, inspected, and trimmed if necessary. The thin film of foil substitute should be removed before the coping is resealed onto the die.

The wax pattern buildup on the resin coping is usually not begun until the patient returns. A sequence using a functional chew-in technique for occlusion would be followed establishing proximal contact and contours appropriate for the clasp assembly as outlined in the following paragraphs.

First, the occlusal portion of the wax pattern is established by having the patient close into maximum intercuspation, followed by excursive movements (Figure 15-13, A). The wax pattern is returned to the cast, and additions are made to dull areas as required. The process is repeated until a smooth occlusal registration has been obtained. Except for narrowing of the occlusal surface and carving of grooves and spillways, this will be the occlusal anatomy of the finished restoration.

The second step is the addition of sufficient wax to establish contact relations with the adjacent tooth. At this time, the occlusal relation of the marginal ridges also must be established. Next, wax is added to buccal and lingual surfaces where the clasp arms will contact the crown, and the wax pattern is again resealed in the mouth. The clasp arms, minor connectors, and occlusal rests involved in the removable partial denture are carefully warmed with a needlepoint flame, carefully avoiding any adjacent resin, and the removable partial denture is positioned in the mouth and onto the wax pattern (see Figure 15-13, B). Several attempts may be necessary until the removable partial denture is fully seated and the components of the clasp are clearly recorded in the wax pattern. Each time the removable partial denture is removed, the pattern will draw with it and must be teased out of the clasp.

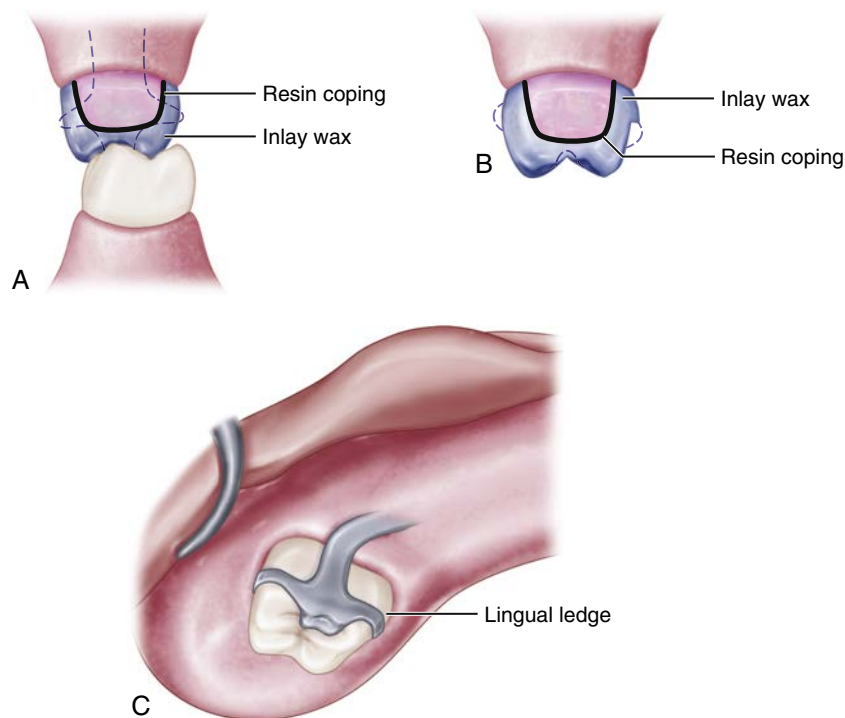
When contact with the clasp arms and the occlusal relation of the removable partial denture have been established satisfactorily, the temporary crown may be replaced and the patient dismissed. The crown pattern is completed on the die by narrowing the occlusal surface bucco-lingually, adding grooves and spillways, and refining the margins. Any wax ledge remaining below the reciprocal clasp arm may be left to provide some of the advantages of a crown ledge that were described earlier in this chapter. Excess wax remaining below the retentive clasp arm, however, must be removed to permit the adding of a retentive undercut later (see Figure 15-13, C).

If a veneer material is to be added, the veneer space must now be carved in the wax pattern. In such situations, the contour of the veneer may be recorded by making a stone matrix of the buccal surface, which can be repositioned on the completed casting to ensure the proper contour of the composite veneer.

The wax pattern must be sprued with care so that essential areas on the pattern are not destroyed. After casting, the crown should be subjected to a minimum of polishing because the exact form of the axial and occlusal surfaces must be maintained.

Because it is impossible to withdraw a clasp arm from a retentive undercut on the wax pattern, the casting must be made without any provision for clasp retention. After the crown has been tried in the mouth with the denture in place, the location of the retentive clasp terminal is identified by scoring the crown with a sharp instrument. Then the crown may be ground and polished slightly in this area to create a retentive undercut. The clasp terminal then may be carefully adapted into this undercut, thereby creating clasp retention on the new crown.

An alternate method for making crowns to fit existing retainers uses mounted casts with the removable prosthesis adapted to the working cast to develop occlusal surfaces for the involved crowns.



**FIGURE 15-13** Making of the cast crown to fit an existing removable partial denture clasp. **A**, Thin acrylic-resin coping is made first on the individual die of a prepared tooth. Inlay wax is then added and coping placed onto the prepared tooth where occlusal surfaces and contact relations are established directly in the mouth. The clasp assembly is warmed with a needlepoint flame only enough to soften the inlay wax, the removable partial denture is placed into the mouth, and it is guided gently into place by the opposing occlusion. This step must be repeated several times and excess wax removed or wax added until full supporting contact with the underside of the clasp assembly has been established, with the denture fully seated. Usually, the wax pattern withdraws with the denture and must be gently teased out of the clasp each time. **B**, The wax pattern is then placed back onto the individual die to complete the occlusal anatomy and refine the margins. Excess wax remaining below the impression of the retentive clasp arm must be removed, but the wax ledge may be left below the reciprocal clasp arm. **C**, Finished casting in the mouth. The terminus of the retentive clasp is then readapted to engage the undercut. It is frequently necessary to remove some interference from casting, as indicated by articulating paper placed between the clasp and the crown, until the clasp is fully seated.

Ideally, all abutment teeth would best be protected with complete crowns before the removable partial denture is fabricated. Except for the possibility of recurrent caries caused by defective crown margins or gingival recession, abutment teeth so protected may be expected to give many years of satisfactory service in support, stabilization, and retention of the removable partial denture. Economically, a policy of insisting on complete coverage for all abutment teeth may well be justified from the long-term viewpoint. It must be recognized, however, that in practice, complete coverage of all abutment teeth is not always possible at the

time of treatment planning. Many factors influence the future health status of an abutment tooth, some of which cannot be foreseen. It is necessary that the dentist be able to treat abutment teeth that later become defective so that their service as abutments may be restored and the serviceability of the removable partial denture maintained. Although not part of the original mouth preparations, this service accomplishes much the same objective by providing support, stability, and retention, and the dentist must be technically capable of providing this removable partial denture service when it becomes necessary.

# CHAPTER

# 16

## Impression Materials and Procedures for Removable Partial Dentures

### CHAPTER OUTLINE

#### Elastic Materials

- Reversible Hydrocolloids
- Irreversible Hydrocolloids
- Mercaptan Rubber–Base Impression Materials
- Polyether Impression Materials
- Silicone Impression Materials

#### Rigid Materials

- Plaster of Paris
- Metallic Oxide Paste

#### Thermoplastic Materials

- Modeling Plastic
- Impression Waxes and Natural Resins

#### Impressions of the Partially Edentulous Arch

- Important Precautions to Be Observed in the Handling of Hydrocolloid Impressions
- Step-by-Step Procedure for Making a Hydrocolloid Impression
- Step-by-Step Procedure for Making a Stone Cast from a Hydrocolloid Impression
- Possible Causes of an Inaccurate and/or a Weak Cast of a Dental Arch

#### Individual Impression Trays

- Technique for Making Individual Acrylic-Resin Impression Trays

Impression materials used in the various phases of partial denture fabrication may be classified as rigid, thermoplastic, or elastic substances. Rigid impression materials are those that set to a rigid consistency. Thermoplastic impression materials are those that become plastic at higher temperatures and resume their original form when cooled. Elastic impression materials are those that remain in an elastic or flexible state after they have set and have been removed from the mouth.

Although rigid impression materials may be capable of recording tooth and tissue details accurately, they cannot be removed from the mouth without fracture and reassembly. Thermoplastic materials cannot record minute details accurately because they undergo permanent distortion during withdrawal from tooth and tissue undercuts. Elastic materials are the only ones that can be withdrawn from tooth and tissue undercuts without permanent deformation and therefore are used generally for making impressions for removable partial dentures, immediate dentures, crowns, and fixed partial dentures when tooth and tissue undercuts and surface detail must be recorded with accuracy.

### ELASTIC MATERIALS\*

#### Reversible Hydrocolloids

Reversible (agar-agar) hydrocolloids, which are fluid at higher temperatures and gel on reduction in temperature, are used primarily as impression materials for fixed restorations. They demonstrate acceptable accuracy when properly used; however, the reversible hydrocolloid impression materials offer few advantages over the irreversible (alginate) hydrocolloids

\*Some of the historical parts of this discussion have been quoted or paraphrased from McCracken WL: Impression materials in prosthetic dentistry, *Dent Clin North Am* 2:671-684, 1958.

when used as a removable partial denture impression material. Present-day irreversible hydrocolloids are sufficiently accurate for making master casts for removable partial dentures. However, control of the border width and length of impressions made with these materials is difficult.

### Irreversible Hydrocolloids

Irreversible hydrocolloids are used for making diagnostic casts, orthodontic treatment casts, and master casts for removable partial denture procedures. Because they are made of colloid materials, neither reversible nor irreversible hydrocolloid impressions can be stored for any length of time but must be poured immediately.

These materials have low tear strength, provide less surface detail than other materials (e.g., mercaptan rubber base) and are not as dimensionally stable as other materials. They can, however, be used in the presence of moisture (saliva); are hydrophilic; pour well with stone; have a pleasant taste and odor; and are nontoxic, nonstaining, and inexpensive. The combination reversible-irreversible hydrocolloids have demonstrated a tendency to separate and should be used with that understanding. The hydrocolloids can be acceptably disinfected with a spray solution of 2% acid glutaraldehyde, stored in 100% humidity, and poured within 1 hour.

### Mercaptan Rubber–Base Impression Materials

The mercaptan rubber–base (Thiokol) impression materials can also be used for removable partial denture impressions and especially for secondary corrected or altered cast impressions. To be accurate, the impression must have a uniform thickness that does not exceed 3 mm ( $\frac{1}{8}$  inch). This necessitates the use of a carefully made individual impression tray of acrylic-resin or some other material possessing adequate rigidity and stability. Those materials that are highly cross-linked (medium and heavy body) do not recover well from deformation and should not be used when large or multiple undercuts are present. For example, when large numbers of teeth with natural tooth contours that display multiple undercuts remain, these materials will be subjected to clinically significant distortion upon withdrawal. The long-term dimensional stability of these materials is poor because of water loss after setting. The material must be held still during the impression-making procedure because it does not have a snap set; it should be allowed to rebound for 7 to 15 minutes after it is removed from the mouth and should then be poured immediately. Many of these materials have an unpleasant odor and can stain clothes. These materials are moderately inexpensive, have high tear strength and long working and setting times (8 to 10 minutes), and can be disinfected in liquid, cold-sterilizing solutions. The accuracy of mercaptan rubber base is acceptable for making impressions for removable partial dentures; however, as with hydrocolloid impression materials, certain precautions must be taken to avoid distortion of the impression. Mercaptan rubber–base impression materials do have an advantage over hydrocolloid

materials in that the surface of an artificial stone poured against them is of a smoother texture and therefore appears to be smoother and harder than one poured against a hydrocolloid material. This is probably so because the rubber material does not have the ability to retard or etch the surface of the setting stone. Despite their accuracy, this has always been a disadvantage of all hydrocolloid impression materials. The fact that a smoother surface results does not, however, preclude the possibility of a grossly inaccurate impression and stone cast resulting from other causes. Rubber-base impression materials possess a longer setting time than the irreversible hydrocolloid materials and lend themselves better to border molding in adequate supporting trays.

### Polyether Impression Materials

Polyether impression material is an elastic-type material, as are the polysulfide and silicone materials. These materials have demonstrated good accuracy in clinical evaluations and are thixotropic, which provides good surface detail and makes them useful as a border molding material. It should be noted, however, that these materials are not compatible with the addition reaction silicone impression materials and should not be used to border mold custom trays when the silicone impression materials are to be used as the final impression material. The polyethers are also hydrophilic, which produces good wettability for easy cast forming.

The polyethers have low to moderate tear strength and much shorter working and setting times, which can limit the usefulness of the material. The flow characteristics and flexibility of the polyether materials are the lowest of any of the elastic materials. These characteristics can limit the use of polyethers in removable partial denture impression procedures. The stiffness of the material can result in cast breakage when removal of the cast from a custom tray is attempted. These materials have a higher permanent deformation than the addition reaction silicones. Some have an unpleasant taste, and because the material will absorb moisture, it cannot be immersed in disinfecting solutions or stored in high humidity for any extended period of time. The materials should be poured within 2 hours; however, manufacturers claim that if the impression is kept dry, clinically acceptable casts can be poured for up to 7 days.

### Silicone Impression Materials

The silicone impression materials are more accurate and easier to use than the other elastic impression materials. The condensation silicones have a moderate (5 to 7 minutes) working time that can be altered by adjusting the amount of the accelerator. They have a pleasant odor, moderately high tear strength, and excellent recovery from deformation. These materials can be used with a compatible putty material to form fit a custom tray. Silicone impression materials are hydrophobic, which can make cast formation a problem. These materials can be disinfected in any of the disinfecting solutions with no alteration in accuracy. Ideally, these materials should be poured within 1 hour.

The addition reaction silicones are the most accurate of the elastic impression materials. They have less polymerization shrinkage, low distortion, fast recovery from deformation, and moderately high tear strength. These materials have a working time of 3 to 5 minutes, which can be easily modified with the use of retardants and temperature controls. They are available in both hydrophilic and hydrophobic forms, have no smell or taste, and also come in putty form, to assist in form fitting the impression tray at chairside. Most of the addition reaction silicones are available in automixing devices, can be poured up to 1 week after impression making with acceptable clinical results, and are stable in most sterilizing solutions. Sulfur in latex gloves and in ferric and aluminum sulfate retraction solution may inhibit polymerization. Many of the hydrophobic types are difficult to pour with stone, and adhesion to acrylic-resin trays is not good. The putties for these materials have a relatively short shelf life, and they are more expensive than the other elastic impression materials.

**RIGID MATERIALS\***

**Plaster of Paris**

One type of rigid impression material is plaster of Paris, which has been used in dentistry for over 200 years. Although all plaster of Paris impression materials are handled in approximately the same manner, the setting and flow characteristics of each manufacturer's product will vary. Some are pure and finely ground with only an accelerator added to expedite setting within reasonable working limits. Others are modified impression plasters to which binders and plasticizers have been added to permit limited border manipulation while the material is setting. These do not set as hard or fracture as cleanly as pure plaster of Paris and therefore cannot be reassembled with as much accuracy if fracture occurs.

Plaster of Paris was once the only material available for removable partial denture impressions, but now elastic materials have completely replaced the impression plasters in this phase of prosthetic dentistry. It can be used for making accurate transfers of abutment castings or copings in the fabrication of fixed restorations and internal attachment dentures and for making rigid indexes and matrices for various purposes in prosthetic dentistry. Modified impression plasters may be used to record maxillomandibular relationships.

**Metallic Oxide Paste**

A second type of rigid impression material is metallic oxide paste, which is usually some form of a zinc oxide–eugenol

combination. A number of these pastes are available; however, they are not used as primary impression materials and should never be used for impressions that include remaining natural teeth. They also are not to be used in stock impression trays.

Metallic oxide pastes are manufactured with a wide variation of consistencies and setting characteristics. For convenience, most of them are dispensed from two tubes; this enables the dentist to dispense and mix the correct proportion from each tube on a mixing slab. The previously prepared tray for the edentulous ridge segments is loaded and positioned in the mouth with or without any attempt at border molding. Border molding with metallic oxide impression pastes is not advisable because wrinkles will occur if movement is permitted at the time the material reaches its setting state.

As with all impression techniques, the accuracy of the primary impression and of the impression tray has a great influence on the final impression. Some metallic oxide pastes remain fluid for a longer period than do others, and some manufacturers claim that border molding is possible. In general, however, all metallic oxide pastes have one thing in common with plaster of Paris impression materials: they all have a setting time during which they should not be disturbed and after which no further border molding is effective.

Metallic oxide pastes, which are rigid substances, can be used as secondary impression materials for complete dentures and for extension base edentulous ridge areas of a removable partial denture if a custom impression tray has been properly designed and attached to the removable partial denture framework (see Chapter 17).

Metallic oxide pastes can also be used as an impression material for relining distal extension denture bases and may be used successfully for this purpose if the original denture base has been relieved sufficiently to allow the material to flow without displacement of the denture or the underlying tissues.

**THERMOPLASTIC MATERIALS\***

**Modeling Plastic**

Like plaster of Paris, modeling plastic is among the oldest impression materials used in prosthetic dentistry. This material is most often used for border correction (border molding) of custom impression trays for Kennedy Class I and Class II removable partial denture bases. It is manufactured in several different colors, each color being an indication of the temperature range at which the material is plastic and workable. A common error in the use of modeling plastic is that it is often subjected to higher temperatures than intended by the manufacturer. It then becomes too soft and loses some of its favorable working characteristics. If a

\*Some of the historical parts of this discussion have been quoted or paraphrased from McCracken WL: Impression materials in prosthetic dentistry, *Dent Clin North Am* 2:671-684, 1958.

\*Some of the historical parts of this discussion have been quoted or paraphrased from McCracken WL: Impression materials in prosthetic dentistry, *Dent Clin North Am* 2:671-684, 1958.

temperature-controlled water bath is not used, a thermometer should be used to maintain the water temperature. If modeling plastic is softened at a temperature above that intended by the manufacturer, the material becomes brittle and unpredictable. Also, there is the ever-present danger of burning the patient when the temperature used in softening the modeling plastic is too high.

The most commonly used modeling plastic for corrected impressions of extension base areas is the red (red-brown) material, in cake form, that softens at about 132° F. It should never be softened at temperatures much above this. Neither it nor any other modeling plastic should be immersed in the water bath for an indefinite period. It should be dipped and kneaded until soft and subjected to no more heat than necessary before the tray is loaded and it is placed in the mouth. Then it may be flamed with an alcohol torch for the purpose of border molding, but it should always be tempered by being dipped back into the water bath before its return to the mouth to avoid burning the patient. The modeling plastic then may be chilled using a water spray before removal from the mouth, although this is not necessary if care is used in removing the impression. During sectional flaming and border molding, the modeling plastic should be chilled in ice water after each removal from the mouth; then it may be trimmed with a sharp knife without danger of fracture or distortion.

Red, gray, and green modeling plastics are obtainable in stick form for use in border molding an impression or an impression tray. The green material is the lowest fusing of the modeling plastics. The red and gray sticks have a higher and broader working range than do the cakes of like color so they may be flamed without harming the material. The gray material in stick form is preferred by some dentists for border molding because of its contrasting lighter color. The choice between the use of green and gray sticks is purely optional and entirely up to the dentist.

Some dentists still prefer to use modeling plastic as a secondary impression material to record edentulous ridges in removable partial denture fabrication. When this is done, it is generally used only as a means of building up the underside of the denture before the tissues are recorded with some secondary impression material (see Chapter 17).

### Impression Waxes and Natural Resins

A second group of thermoplastic impression materials consists of those impression waxes and resins commonly spoken of as mouth-temperature waxes. The most familiar of these have been the Iowa wax (Kerr Co., Romulus, MI) and the Korecta waxes (D-R Miner Dental, Concord, CA), all of which were developed for specific techniques.

Knowledge of the characteristics of mouth-temperature waxes is important if they are to be used correctly.

The Iowa wax was developed for use in recording the functional or supporting form of an edentulous ridge. It may be used as a secondary impression material or as an impression material for relining the finished removable partial denture to obtain support from the underlying tissues.

The mouth-temperature waxes lend themselves well to all relining techniques because they will flow sufficiently in the mouth to avoid displacement of tissues. As with any relining technique, it is necessary that sufficient relief and venting be provided to give the material the opportunity to flow.

The difference between impression wax and modeling plastic is that impression waxes have the ability to flow as long as they are in the mouth and thereby permit equalization of pressure and prevent displacement. The modeling plastics flow only in proportion to the amount of flaming and tempering that can be done outside of the mouth; this does not continue after the plastic has approached mouth temperature. The principal advantage of mouth-temperature waxes is that, given sufficient time, they permit a rebound of those tissues that may have been forcibly displaced.

The impression waxes also may be used to correct the borders of impressions made of more rigid materials, thereby establishing optimum contact at the border of the denture. All mouth-temperature wax impressions have the ability to record border detail accurately and include the correct width of the denture border. They also have the advantage of being correctable.

Mouth-temperature waxes vary in their working characteristics. They are designed primarily for impression techniques that attempt to record the tissues under an occlusal load. In such techniques, the occlusion rim or the arrangement of artificial teeth is completed first. Mouth-temperature wax is then applied to the tissue side of the denture base, and the final impression is made under functional loading by using various movements to simulate functional activity. These mouth-temperature materials also may be used successfully in open-mouth impression techniques. Iowa wax will not distort after removal from the mouth at ordinary room temperatures, but the more resinous waxes must be stored at much lower temperatures to avoid flow when they are out of the mouth. Resinous waxes are not ordinarily used in removable partial denture impression techniques except for secondary impressions.

### IMPRESSIONS OF THE PARTIALLY EDENTULOUS ARCH

An impression of the partially edentulous arch must record accurately the anatomic form of the teeth and surrounding tissues. This is necessary so that the prosthesis may be designed to follow a definite path of placement and removal and so that support, stability, and retention derived from the abutment teeth may be precise and accurate.

Materials that could be permanently deformed by removal from tooth or tissue undercuts should not be used. The thermoplastic impression materials and metallic oxide pastes are therefore excluded for recording the anatomic form of the dental arch. Rubber-base materials that are highly cross-linked should not be used when large or multiple undercuts are present because these materials will be subjected to considerable distortion upon withdrawal. The introduction of hydrocolloids as impression materials was a giant step

forward in dentistry. For the first time, impressions could be made of undercut areas with a material that was elastic enough to be withdrawn from those undercuts without permanent distortion. It permitted the making of a one-piece impression, which did not require the use of a separating medium, and was and still is an acceptably accurate material when handled properly. Irreversible hydrocolloid becomes a gel via a chemical reaction as a result of mixing alginate powder with water. This physical change is irreversible.

All hydrocolloids are dimensionally stable only during a brief period after removal from the mouth. If exposed to the air, they rapidly lose water content, with resulting shrinkage and other dimensional changes. If immersed in water, they imbibe water, with accompanying swelling and dimensional changes. All hydrocolloid impressions should be poured immediately, but if they must be stored for a brief period, they should be in a saturated atmosphere rather than immersed in water. This can be accomplished simply by wrapping the impression in a damp paper towel or sealing it in a plastic bag.

Hydrocolloids also exhibit a phenomenon known as *syneresis*, which is associated with the giving off of a mucinous exudate. This mucinous exudate has a retarding effect on any gypsum material, which results in a soft or chalky cast surface. Sometimes this is detected only by close examination of the impression after removal from the cast. Nevertheless, such a cast surface is inaccurate and ultimately will result in an inaccurate removable partial denture framework. Pouring the cast immediately and using some chemical accelerator, such as potassium sulfate, to counteract the retarding effect of the hydrocolloid can prevent this inaccuracy. All modern irreversible hydrocolloid impression materials have an accelerator incorporated into the powder and no longer need to be treated with a fixing solution.

However, some disadvantages are associated with the use of irreversible hydrocolloid. This material gels by means of a chemical reaction that is accelerated by the warmth of the tissues. In the irreversible hydrocolloid, gelation first takes place next to the tissues, and any movement of the tray during gelation will result in internal stresses that are released on removal of the impression from the mouth. A distorted and therefore inaccurate impression results from an irreversible hydrocolloid impression that is not held immobile during gelation.

Another disadvantage of irreversible hydrocolloid is that it must be introduced into the mouth at approximately 70° F, which results in an immediate increase in the viscosity and surface tension of the material. Air bubbles are therefore harder to dispel.

### Important Precautions to Be Observed in the Handling of Hydrocolloid Impressions

Some important precautions to be observed in the handling of hydrocolloid are as follows:

1. The impression should not be exposed to air because some dehydration will inevitably occur and result in shrinkage.
2. The impression should not be immersed in water or disinfectants because some imbibition will inevitably result, with an accompanying expansion.

3. The impression should be protected from dehydration by placing it in a humid atmosphere or wrapping it in a damp paper towel until a cast can be poured. To avoid volume change, this should be done within 15 minutes after removal of the impression from the mouth.
4. Exudate from the hydrocolloid has a retarding effect on the chemical reaction of gypsum products and results in a chalky cast surface. This can be prevented by pouring the cast immediately or by first immersing the impression in a solution of accelerator if an accelerator is not included in the formula.

### Step-by-Step Procedure for Making a Hydrocolloid Impression

The step-by-step procedure and important points to observe in the making of a hydrocolloid impression are as follows:

1. Select a suitable, sterilized, perforated or rim-lock impression tray that is large enough to provide a 4- to 5-mm thickness of the impression material between the teeth and tissues and the tray.
2. Build up the palatal portion of the maxillary impression tray with wax or modeling plastic to ensure even distribution of the impression material and to prevent the material from slumping away from the palatal surface (Figure 16-1, A). At this time, it is also helpful to pack the palate with gauze that has been sprayed with a topical anesthetic. This serves to anesthetize the minor salivary glands and mucous glands of the palate and thus prevent secretions as a response to smell or taste or to the physical presence of the impression material. If gelation occurs next to the tissues while the deeper portion is still fluid, a distorted impression of the palate may result, which cannot be detected in the finished



**FIGURE 16-1** A, Maxillary impression tray with palatal portion built up with baseplate wax to prevent impression material from sagging away from palatal surface. B, Mandibular impression tray with periphery wax added to lingual flanges to prevent tissues of the floor of the mouth from rising inside the tray. The posterior end of the tray is extended with periphery wax to cover the retromolar pad regions.

impression. This may result in the major connector of the finished casting not being in contact with the underlying tissues. The maxillary tray frequently has to be extended posteriorly to include the tuberosities and the vibrating line region of the palate. Such an extension also aids in correctly orienting the tray in the patient's mouth when the impression is made.

3. The lingual flange of the mandibular tray may need to be lengthened with wax in the retromylohyoid area or to be extended posteriorly, but it rarely ever needs to be lengthened elsewhere. Wax may need to be added inside the distolingual flange to prevent the tissues of the floor of the mouth from rising inside the tray (see [Figure 16-1, B](#)).
4. Place the patient in an upright position, with the arch to be impressed nearly parallel to the floor.
5. When irreversible hydrocolloid is used, place the measured amount of water (at 70° F) in a clean, dry, rubber mixing bowl (600-mL capacity). Add the correct measure of powder. Spatulate rapidly against the side of the bowl with a short, stiff spatula. This should be accomplished in less than 1 minute. The patient should rinse his or her mouth with cool water to eliminate excess saliva while the impression material is being mixed and the tray is being loaded.
6. In placing the material in the tray, avoid entrapping air. Have the first layer of material lock through the perforations of the tray or rim-lock to prevent any possible dislodgment after gelation.
7. After loading the tray, remove the gauze with the topical anesthetic and quickly place (rub) some of the impression material on any critical areas using your finger (areas such as rest preparations and abutment teeth). If a maxillary impression is being made, place the material in the highest aspect of the palate and over the rugae.
8. Use a mouth mirror or index finger to retract the cheek on the side away from you as the tray is rotated into the mouth from the near side.
9. Seat the tray first on the side away from you, next on the anterior area, while reflecting the lip, and then on the near side, with the mouth mirror or finger for cheek retraction. Finally, make sure that the lip is draping naturally over the tray.
10. Be careful not to seat the tray too deeply, leaving room for a thickness of material over the occlusal and incisal surfaces.
11. Hold the tray immobile for 3 minutes with light finger pressure over the left and right premolar areas. To avoid internal stresses in the finished impression, do not allow the tray to move during gelation. Any movement of the tray during gelation will produce an inaccurate impression. If, for example, you allow the patient or the assistant to hold the tray in position at any time during the impression procedure, some movement of the tray will be inevitable during the transfer, and the impression will probably be inaccurate. Do not remove the impression from the mouth until the impression material has completely set.

12. After releasing the surface tension, remove the impression quickly in line with the long axis of the teeth to avoid tearing or other distortion.

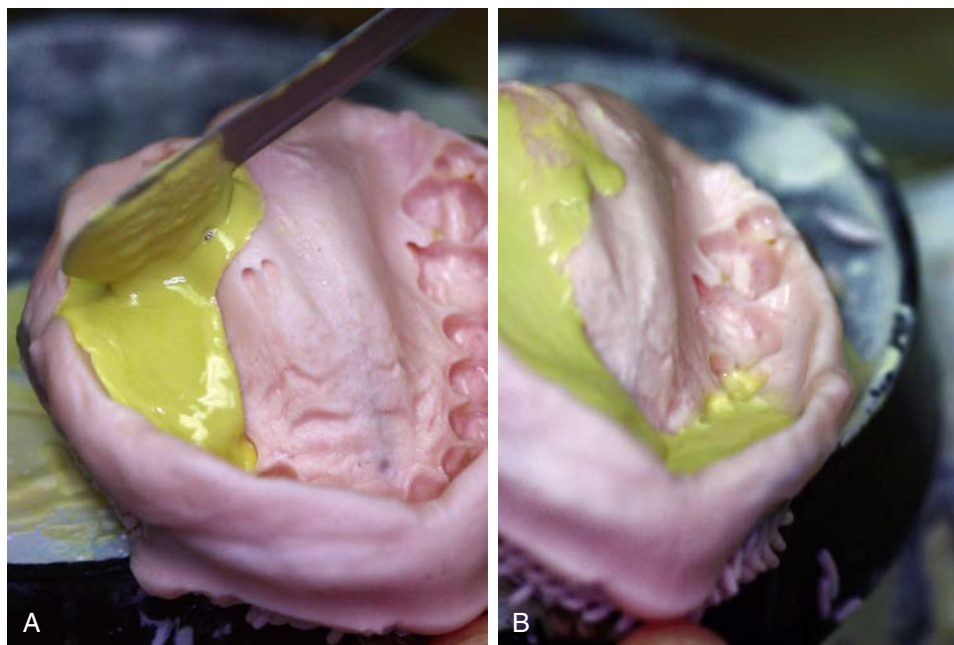
13. Rinse the impression free of saliva with slurry water, or dust it with plaster, and rinse gently; then examine it critically. Spray the impression thoroughly with a suitable disinfectant, and cover it immediately with a damp paper towel.

A cast should be poured immediately into a disinfected hydrocolloid impression to avoid dimensional changes and syneresis. Circumstances often necessitate some delay, but this time lapse should be kept to a minimum. A delay of 15 minutes will satisfy the disinfection requirements and should not be deleterious if the impression is kept in a humid atmosphere.

### Step-by-Step Procedure for Making a Stone Cast from a Hydrocolloid Impression

The step-by-step procedure for making a stone cast from the impression is as follows:

1. A more abrasive-resistant type IV stone should be used to form removable partial denture casts. Have the measured dental stone at hand, along with the designated quantity of room temperature water, as recommended by the manufacturer. A clean 600-mL rubber mixing bowl, a stiff spatula, and a vibrator complete the preparations. A No. 7 spatula also should be within reach.
2. First, pour the measure of water into the mixing bowl, and then add the measure of stone. Spatulate thoroughly for 1 minute, remembering that a weak and porous stone cast may result from insufficient spatulation. Mechanical spatulation under vacuum is preferred. After any spatulation other than in a vacuum, place the mixing bowl on the vibrator and knead the material to permit the escape of any trapped air.
3. After removing the impression from the damp towel, gently shake out surplus moisture and hold the impression over the vibrator, impression side up, with only the handle of the tray contacting the vibrator. The impression material must not be placed in contact with the vibrator because of possible distortion of the impression.
4. With a small spatula, add the first cast material to the distal area away from you. Allow this first material to be vibrated around the arch from tooth to tooth toward the anterior part of the impression ([Figure 16-2](#)). Continue to add small increments of material at this same distal area, with each portion of added stone pushing the mass ahead of it. This avoids the entrapment of air. The weight of the material causes any excess water to be pushed around the arch and to be expelled ultimately at the opposite end of the impression. Discard this fluid material. When the impressions of all teeth have been filled, continue to add artificial stone in larger portions until the impression is completely filled.
5. The filled impression should be placed so that its weight does not distort the hydrocolloid impression material.



**FIGURE 16-2** **A**, Stone is introduced at one posterior region of the impression, with care taken to trace the stone moving into each tooth as it rounds the arch. **B**, Additional stone is not needed until the stone has reached the opposite-most posterior tooth.

The base of the cast can be completed with the same mix of stone. The base of the cast should be 16 to 18 mm ( $\frac{2}{3}$  to  $\frac{3}{4}$  inch) at its thinnest portion and should be extended beyond the borders of the impression so that buccal, labial, and lingual borders will be recorded correctly in the finished cast. A distorted cast may result from an inverted impression.

6. As soon as the cast material has developed sufficient body, trim the excess from the sides of the cast. Wrap the impression and cast in a wet paper towel, or place it in a humidifier, until the initial set of the stone has taken place. The impression is thus prevented from losing water by evaporation, which might deprive the cast material of sufficient water for crystallization. Chalky cast surfaces around the teeth are often the result of the hydrocolloid's acting as a sponge and robbing the cast material of its necessary water for crystallization.
7. After the cast and impression have been in the humid atmosphere for 30 minutes, separate the impression from the cast. Thirty minutes is sufficient for initial setting. Any stone that interferes with separation from the tray must be trimmed away with a knife.
8. Clean the impression tray immediately while the used impression material is still elastic.
9. Trimming of the cast should be deferred until final setting has occurred. The sides of the cast then may be trimmed to be parallel, and any blebs or defects resulting from air bubbles in the impression may be removed. If this is a cast for a permanent record, it may be trimmed to orthodontic specification to present a neat appearance for demonstration purposes. Master casts and other working casts are ordinarily trimmed only to remove excess stone.

### Possible Causes of an Inaccurate and/or a Weak Cast of a Dental Arch

The possible causes of an inaccurate cast are as follows:

1. Distortion of the hydrocolloid impression (a) by use of an impression tray that is not rigid; (b) by partial dislodgment from the tray; (c) by shrinkage caused by dehydration; (d) by expansion caused by imbibition (this will be toward the teeth and will result in an undersized rather than oversized cast); and (e) by attempting to pour the cast with stone that has already begun to set.
2. A ratio of water to powder that is too high. Although this may not cause volumetric changes in the size of the cast, it will result in a weak cast.
3. Improper mixing. This also results in a weak cast or one with a chalky surface.
4. Trapping of air, either in the mix or in pouring, because of insufficient vibration.
5. Soft or chalky cast surface that results from the retarding action of the hydrocolloid or the absorption of necessary water for crystallization by the dehydrating hydrocolloid.
6. Premature separation of the cast from the impression.
7. Failure to separate the cast from the impression for an extended period.

### INDIVIDUAL IMPRESSION TRAYS

This chapter has previously dealt with making an impression in a rigid stock tray of the anatomic form of a dental arch for making a diagnostic cast, a working cast for restorations, or a master cast. There are times, however, when a stock tray is not suitable for making the final anatomic impression of the

dental arch. Most tooth-supported removable partial dentures may be made on a master cast from such an impression. Some maxillary distal extension removable partial dentures with broad palatal coverage, particularly those for a Kennedy Class I arch, may also be made on an anatomic cast, but usually these necessitate the use of an individually made tray.

A stock tray must be sufficiently rigid to avoid distortion during the impression and cast forming procedures and should fit the mouth with about 4 to 5 mm clearance for the impression material without interfering with teeth or bordering tissues; otherwise an individual tray made of some acrylic-resin tray material should be used for the final anatomic impression.

Most stock or disposable removable partial denture trays are of the rim-lock or perforated varieties. Both are made in a limited selection of sizes and shapes. Wide selections of trays are available that can be used for partially edentulous patients, including trays for both bilateral and unilateral edentulous areas.

All of these trays have reinforced borders. Although a complete denture impression tray is, or should be, made of material that permits trimming and shaping to fit the mouth, the existence of a beaded border and the rigidity of a stock removable partial denture tray allow no trimming and little shaping. The resulting impression is often a record of border tissues distorted by an ill-fitting tray rather than an impression of tissues draping naturally over a slightly underextended impression tray.

An individual acrylic-resin tray, on the other hand, can be made with sufficient clearance for the impression material and can be trimmed just short of the vestibular reflections to allow the tissues to drape naturally without distortion. The removable partial denture borders may then be made as accurately as complete denture borders with equal advantages.

Although techniques have been proposed for making individual impression trays that incorporate plastic tubing for water-cooling reversible hydrocolloid impressions, the final anatomic impression usually will be made with irreversible hydrocolloid, mercaptan rubber, or silicone impression materials.

### Technique for Making Individual Acrylic-Resin Impression Trays

The diagnostic cast is often adequate for preparation of the individual tray. However, if extensive surgery or extractions were performed after the diagnostic cast was made, a new impression in a rigid stock tray and a new cast must be made. The procedures for making the new cast are identical to those described previously.

A duplicate of the diagnostic cast, on which the individual tray can be fabricated, should be made because the cast on which an individual tray is made is often damaged or must be mutilated to separate the tray from the cast. Obviously the original diagnostic cast must be retained as a permanent record in the patient's file. Several techniques may be used to make individual impression trays. One technique

for making an individual maxillary tray is described in [Figures 16-3 and 16-4](#). This format could be used for both autopolymerizing acrylic-resin and visible light-cured (VLC) acrylic-resin. The VLC custom tray materials are premixed sheet materials that, when polymerized, provide a highly stable, distortion-free custom impression tray that is ready to use in minutes. These materials are provided by the manufacturers in sheet forms of various sizes, thicknesses, and colors.

A technique for making an individual maxillary tray with light-polymerized resin is as follows:

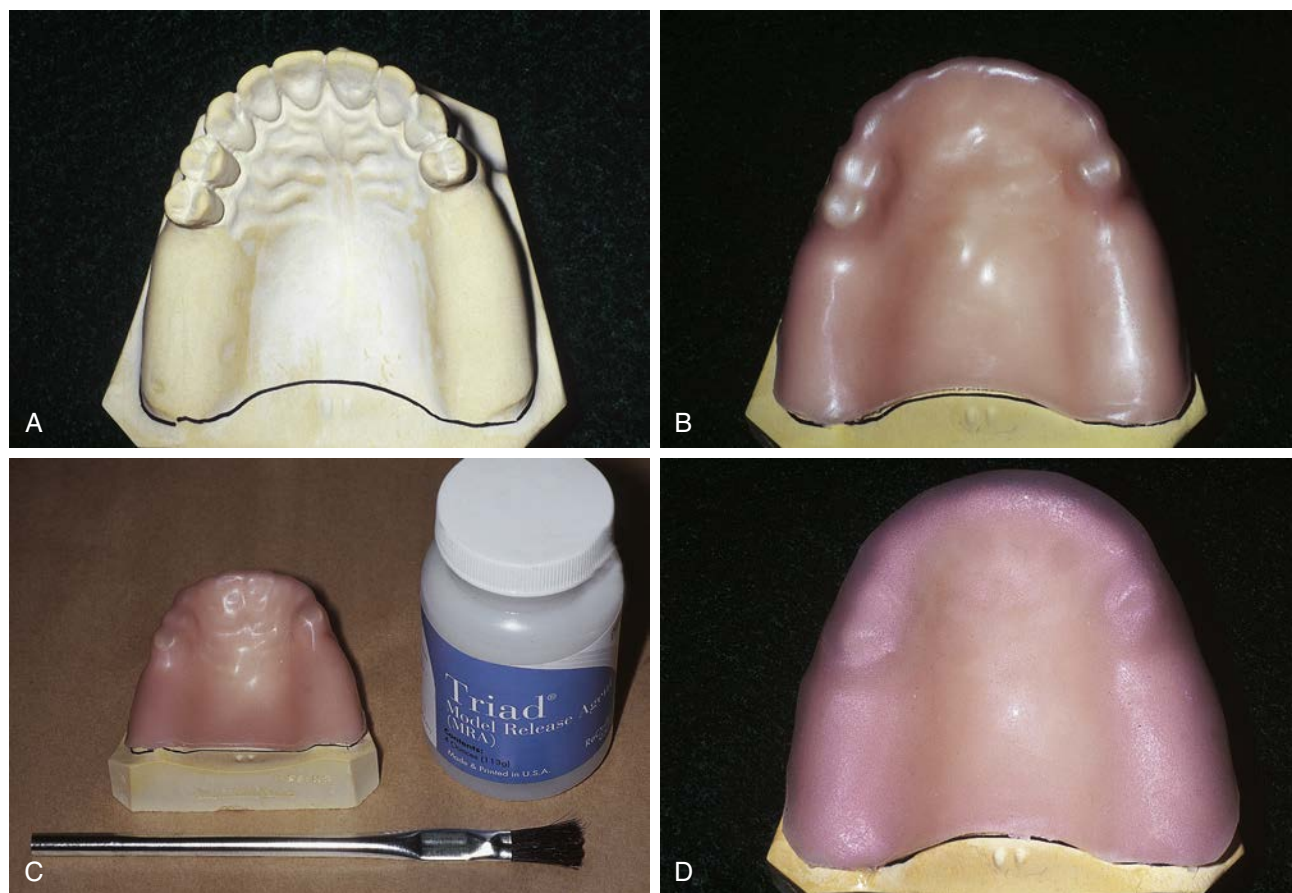1. Outline the extent of the tray on the cast with a pencil. The tray must include all teeth and tissues that will be involved in the removable partial denture.
2. Adapt one layer of baseplate wax over the tissue surfaces and two layers over the teeth of the cast to serve as a spacer for impression material. The wax spacer should be trimmed 2 to 3 mm short of the outline drawn on the diagnostic cast. Wax covering the posterior palatal seal area should be removed so that intimate contact of the tray and tissue in this region may serve as an aid in correctly orienting the tray when the impression is made. Expose portions of the incisal edges of the central incisors to serve as anterior stops when placing the tray in the mouth. Bevel the wax so that the completed tray has a guiding incline that helps position the tray on the anterior stop. Other cast undercuts should be blocked out with wax or modeling compound. Note: Adapt an additional layer of baseplate wax over the teeth if the impression is to be made in irreversible hydrocolloid. This step is not necessary if the choice of impression material is a rubber-base or silicone type of material.
3. Paint the exposed surfaces of the cast that may be contacted by the light-polymerized resin tray material with a model release agent (MRA) to facilitate separation of the polymerized tray from the cast.
4. Remove the VLC tray material from the light-proof pouch and carefully cut the desired length with a knife or scalpel. Adapt the VLC material to the cast, and trim it with a knife. Be sure not to thin the material over the teeth or the posterior border area.
5. Attach a handle by molding excess VLC material into the desired shape, and blend it into the tray material in the cast. With some materials, a paper clip or similar wire may be shaped and used to reinforce the handle. Alternatively, some manufacturers make prefabricated metal custom tray handles that may be easily adapted.
6. Place the cast with the adapted tray in the light polymerizing unit and process according to the manufacturer's directions—usually a maximum of 1 minute.
7. Remove the cast from the unit, and gently remove the tray from the cast. Peel the softened wax out of the tray while the wax is still warm.
8. Paint the entire impression tray with the manufacturer's air barrier coating material, and return the tray to the unit turnstile for additional polymerizing, tissue side up.

9. When the polymerizing cycle is completed, remove the tray from the unit, and clean it with a brush and water.
10. Perfect the borders of the tray with rotary instruments (vulcanite burs, acrylic-resin trimmers, and so on), and slightly polish the external surface of the tray.
11. Place perforations (No. 8 bur size) in the VLC resin tray at 5-mm ( $\frac{3}{16}$ -inch) intervals, with the exception of the alveolar groove areas, if an irreversible hydrocolloid impression material is to be used (see [Figures 16-3 and 16-4](#)).
12. The finished tray must be sanitized and tried in the mouth so that any necessary corrections to the tray can be accomplished before the impression is made.

The technique for making an individual mandibular VLC resin tray follows the same procedures. The buccal shelf regions on the mandibular cast are not covered by the wax spacer because these areas provide the primary support for the mandibular removable partial denture and serve as posterior stops in orienting the tray in the patient's mouth. During impression making, these areas permit selective placement of tissues in the mandibular stress-bearing areas.

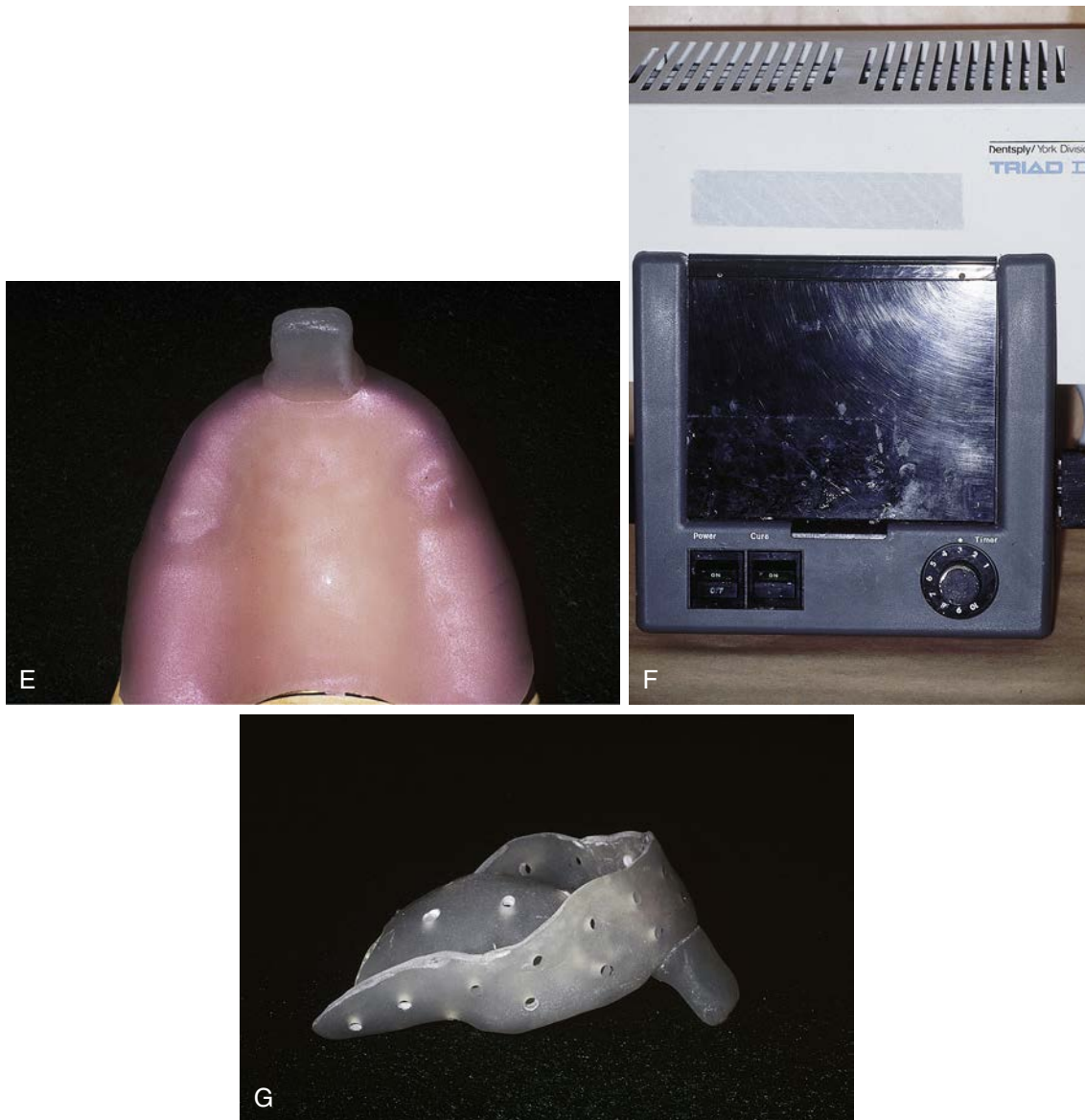
If mercaptan rubber is to be used, perforations are not usually necessary to lock the material in the tray, because the adhesive provided by the manufacturer provides reliable retention, and some confinement of these materials is desirable. However, a series of perforations are necessary in the median palatal raphe and incisive papilla areas of the maxillary tray so that excess impression material will escape through them, thus providing relief of the tissues in this area. For the same reasons, perforations are placed in the alveolar groove of the mandibular tray. With the use of adhesives, the impression material is not easily removed from the tray should a faulty impression have to be remade, but this is an inconvenience common to all newer elastic materials and does not prevent reuse of the impression tray. Opaque elastic impression materials and adhesives can prevent the detection of undesirable pressure areas when an impression is evaluated.

Master casts made from impressions in individual acrylic-resin trays are generally more accurate than those made in rigid stock trays. The use of individual trays should



**FIGURE 16-3** **A**, Desired outline of the tray is drawn on the diagnostic cast. The tray must include all teeth and tissues that will be involved in the removable partial denture. **B**, One thickness of baseplate wax is adapted to the cast and is trimmed to the penciled outline, which is 2 to 3 mm short of the desired border. The posterior palatal seal region is not covered by wax but will be included in finished tray. Two thicknesses of baseplate wax cover the teeth. A window is created in the wax spacer over the incisal edges. **C**, A model release agent (MRA) is painted on the stone surfaces of the cast that will be contacted by the resin. **D**, The visible light-cured (VLC) resin tray material is removed from the light-proof wrap and shaped to the desired outline in a uniform manner.

*Continued*

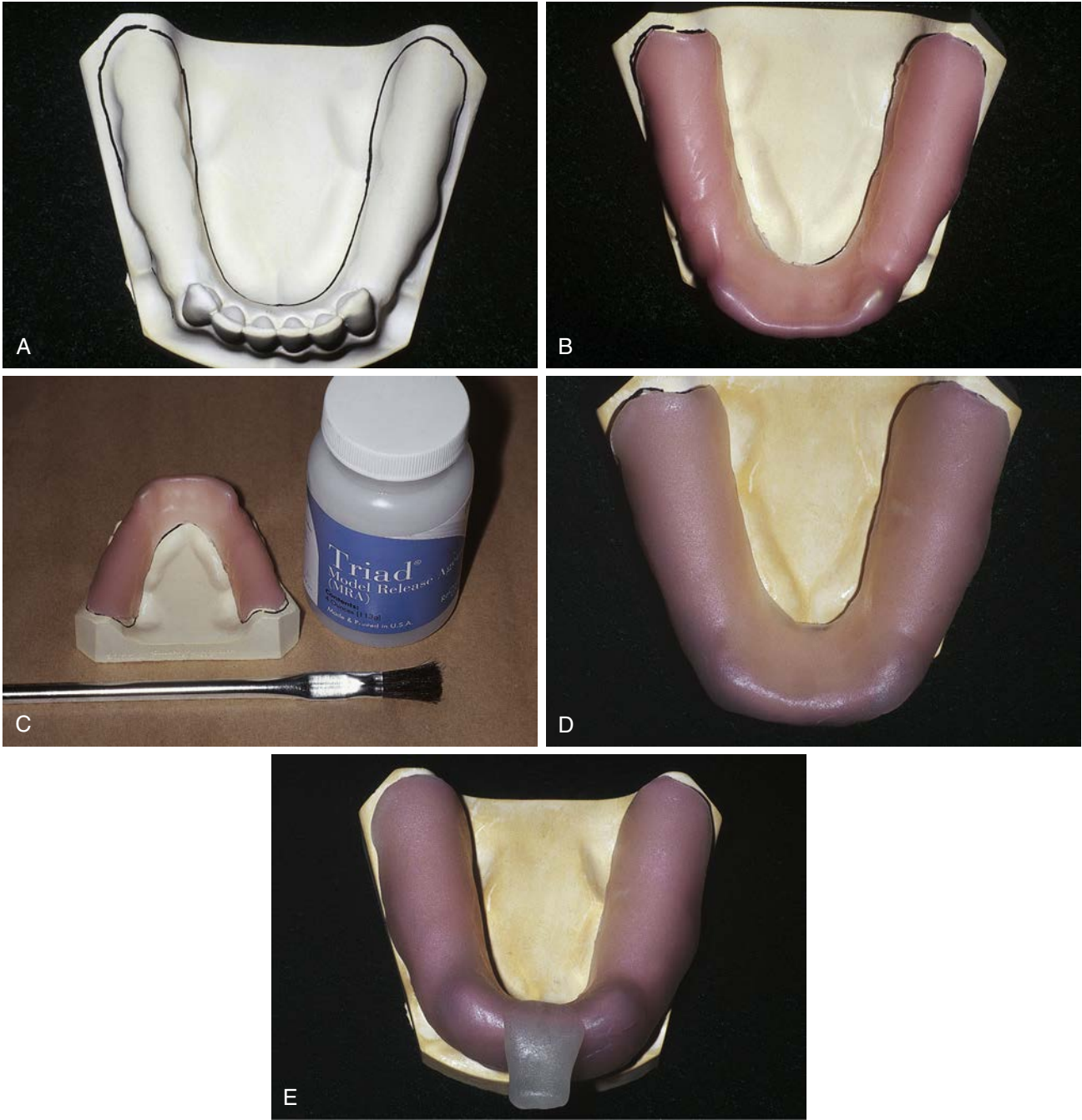


**FIGURE 16-3, CONT'D** **E**, A handle is added to provide a means to place and remove the tray, as well as to pass the tray from assistant to dentist. Its form should consider the lip length and need to manipulate the perioral region. **F**, Before the tray is placed in the curing oven, an air barrier coating is painted on the surface. The tray is then polymerized as per manufacturers' recommendations. **G**, As soon as the tray material has hardened, the tray is removed from the cast, and the wax spacer is removed from the rough tray. An acrylic-resin trimmer in the lathe is used to rough finish the tray. Holes are drilled through the tray, spaced approximately 4.5 mm apart. These holes serve to lock the impression material in the tray. In addition, excess impression material is forced out of the holes when the impression is made, thereby minimally displacement of soft oral tissues. These two features assist in correctly orienting the individualized impression tray in the mouth.

be considered a necessary step in making the majority of removable partial dentures when a secondary impression technique is not to be used. Reasons and methods for making a secondary impression will be considered in Chapter 17.


Final impressions for maxillary tooth-supported removable partial dentures often may be made in carefully selected and recontoured rigid stock impression trays. However, an individual acrylic-resin tray is preferred in those situations

in the mandibular arch when the floor of the mouth closely approximates the lingual gingiva of the remaining anterior teeth. Recording the floor of the mouth at the elevation it assumes when the lips are licked is important in selecting the type of major connector to be used (see Chapter 5). Modification of the borders of an individual tray to fulfill the requirements of an adequate tray is much easier than is the modification of a metal stock tray.

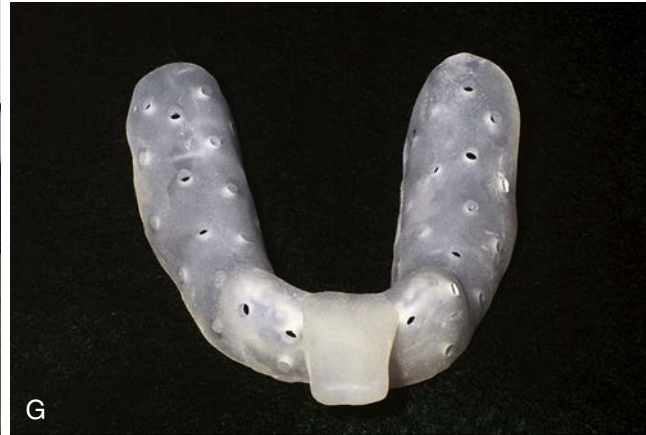

**FIGURE 16-4** A similar technique to the one used for fabrication of the maxillary tray in [Figure 16-3](#) is used for the mandibular tray. **A**, Outline of the tray is penciled on a duplicate mandibular diagnostic cast. **B**, A single sheet of baseplate wax is adapted to the outline of the tray, and another sheet of baseplate wax is adapted over the teeth. A window is cut in the spacer to expose the incisal edges of the lower central incisors to serve as a stop in seating the tray. **C**, A model release agent (MRA) is painted on regions of the cast to be in contact with the resin. **D**, A visible light-cured (VLC) tray material wafer is adapted over the cast and spacer. **E**, A handle is formed with excess tray material, as previously described.

*Continued*



F



G

**FIGURE 16-4, CONT'D** F, An air barrier coating is painted on the tray material and it is processed as described in [Figure 16-3](#).  
G, Following processing, multiple holes are placed throughout the tray.

# CHAPTER

# 17

## Support for the Distal Extension Denture Base

### CHAPTER OUTLINE

#### Distal Extension Removable Partial Denture Factors Influencing the Support of a Distal Extension Base

- Contour and Quality of the Residual Ridge
- Extent of Residual Ridge Coverage by the Denture Base
- Type and Accuracy of the Impression Registration
- Accuracy of the Fit of the Denture Base
- Design of the Removable Partial Denture Framework
- Total Occlusal Load Applied

#### Anatomic form Impression

#### Methods for Obtaining Functional Support for the Distal Extension Base

- Selective Tissue Placement Impression Method
- Framework Fitting
- Functional Impression Technique

In a tooth-supported removable partial denture, a metal base or the framework that supports an acrylic-resin base is connected to and is part of a rigid framework that permits the direct transfer of occlusal forces to the abutment teeth through the occlusal rests. Even though the denture base of the modification space(s) in a Kennedy Class III removable partial denture provides support for the supplied teeth, the residual ridge beneath the base is not called on to aid in the support of the removable partial denture. Therefore the resiliency of the ridge tissues, the ridge configuration, and the type of bone that supports these tissues are not factors in denture support. Regardless of the length of the edentulous spans, if the framework is rigid, the abutment teeth are sound enough to carry the additional load, and the occlusal rests are properly formed, support comes entirely from the abutment teeth at either end of that span. Support may be augmented by splinting and by the use of additional abutments, but in any event the abutments are the sole support of the removable restoration. When a dental implant is used to augment residual ridge support, the implant provides the same role of support as a distal tooth supporting a tooth-borne posterior segment of a removable partial denture.

An impression (and resultant stone cast) records the anatomic form of the teeth (and/or implant) and their surrounding structures and is needed to make a tooth-supported removable partial denture. The impression should also record the moving tissues that will border the denture in an unstrained position so that the relationship of the denture base to those tissues may be as accurate as possible. Although underextension of the denture base in a tooth-supported prosthesis is the lesser of two evils, an underextended base may lead to food entrapment and inadequate facial contours, particularly on the buccal and labial sides. To accurately record the moving tissues of the floor of the mouth, an individual impression tray should be used, rather than an ill-fitting or overextended stock tray. This has been discussed at length in Chapters 5 and 16.

## DISTAL EXTENSION REMOVABLE PARTIAL DENTURE

The distal extension removable partial denture does not have the advantage of total tooth support because one or more bases are extensions covering the residual ridge distal to the last abutment. It therefore is dependent on the residual ridge for a portion of its support.

The distal extension removable partial denture must depend on the residual ridge for some support, stability, and retention. Indirect retention, to prevent the denture from lifting away from the residual ridge, should also be incorporated in the design. The tooth-supported base is secured at either end by the action of a direct retainer and is supported at either end by a rest, whereas this degree of support and direct retention is lacking in the distal extension prosthesis. For this reason, a distal abutment should be preserved whenever possible. In the event of the loss or absence of a distal abutment tooth, the patient must be made aware of the movements to be expected with a distal extension removable partial denture and the limitations imposed on the dentist when the residual ridge must be used for support, stability, and retention for that part of the prosthesis.

## FACTORS INFLUENCING THE SUPPORT OF A DISTAL EXTENSION BASE

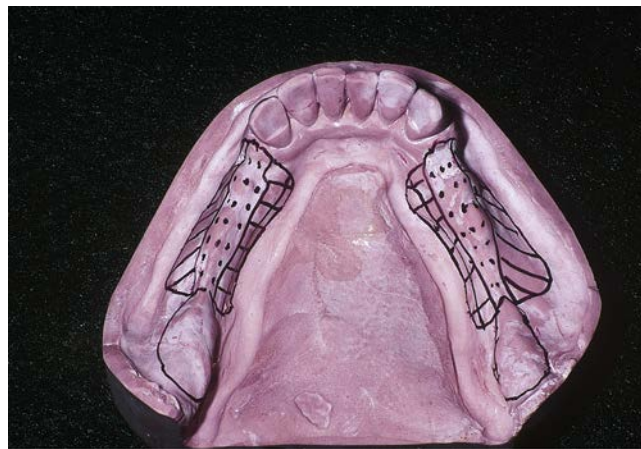
Because one of the stated objectives of prosthodontic treatment is the restoration of function and comfort in an esthetically pleasing manner, maintenance of occlusal contact in distal extension removable partial dentures demands an understanding of the factors that influence residual ridge support. Support from the residual ridge becomes more important as the distance from the last abutment increases and will depend on the following several factors:

- Contour and quality of the residual ridge
- Extent of residual ridge coverage by the denture base
- Type and accuracy of the impression registration
- Accuracy of the fit of the denture base
- Design of the removable partial denture framework
- Total occlusal load applied

Even when ideal residual ridge characteristics that favor support are present, the ridge is less capable of resisting functional loads than either a tooth or implant. Because of this, the impact of a selective implant on the anticipated functional comfort and efficiency of a distal extension removable partial denture should be discussed and considered when indicated based on patient and recipient site factors.

### Contour and Quality of the Residual Ridge

The ideal residual ridge to support a denture base would consist of cortical bone that covers relatively dense cancellous bone, with a broad rounded crest with high vertical slopes, and is covered by firm, dense, fibrous connective tissue. Such a residual ridge would optimally support vertical and horizontal stresses placed on it by denture bases. Unfortunately this ideal is seldom encountered.

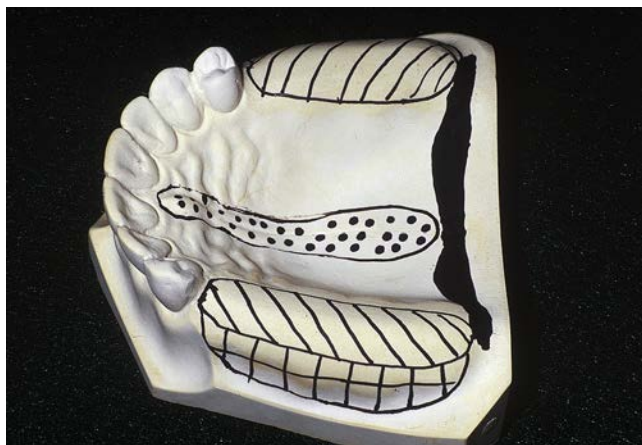

**FIGURE 17-1** The dotted portion outlines the crest of the residual ridge, which should be recorded in its anatomic form in impression procedures. Similarly, retromolar pads should not be displaced by impression. Buccal shelf regions are outlined by a herringbone pattern, and selected additional pressures may be placed on these regions for vertical support of the denture base. Lingual slopes of the residual ridge (cross-hatched) may furnish some vertical support to the restoration; however, these regions principally resist the horizontal rotational tendencies of the denture base and should be recorded by the impression in undisplaced form.

Easily displaceable tissue will not adequately support a denture base, and tissues that are interposed between a sharp, bony residual ridge and a denture base will not remain in a healthy state. Not only must the nature of the bone of the residual ridge be considered in developing optimum support for the denture base but also its positional relationship to the direction of forces that will be placed on it.

The crest of the bony mandibular residual ridge is most often cancellous. Because lining mucosa restricts both the buccal and lingual mucosae adjacent to teeth in the mandible, loss of firm mucosa overlying the residual ridge is common following tooth extraction in the posterior mandible. Pressures placed on tissues overlying the crest of the mandibular residual ridge usually result in irritation of these tissues, accompanied by the sequelae of chronic inflammation. Therefore the crest of the mandibular residual ridge cannot be a primary stress-bearing region. The buccal shelf region (bounded by the external oblique line and the crest of the alveolar ridge) seems to be better suited for a primary stress-bearing role because it is covered by relatively firm, dense, fibrous connective tissue supported by cortical bone. In most instances this region bears more of a horizontal relationship to vertical forces than do other regions of the residual ridge (Figure 17-1). The slopes of the residual ridge then would become the primary stress-bearing region for resistance of horizontal and off-vertical forces.

The immediate crest of the bone of the maxillary residual ridge may consist primarily of cancellous bone. Unlike in the mandible, oral tissues that overlie the maxillary residual alveolar bone are usually of a firm, dense nature (similar to the



**FIGURE 17-2** The crest of the maxillary residual ridge (*herring-bone pattern*) is the primary supporting region for the maxillary distal extension denture base. Buccal and lingual slopes may furnish limited vertical support to the denture base. It seems logical that their primary role is to counteract the horizontal rotational tendencies of the denture base. The *dotted portion* outlines the incisive papilla and the median palatal raphe. Relief must be provided for these regions, especially if tissues covering the palatal raphe are less displaceable than those covering the crest of the residual ridge.

mucosa of the hard palate) or can be surgically prepared to support a denture base. The topography of a partially edentulous maxillary arch imposes a restriction on selection of a primary stress-bearing area. In spite of impression procedures, the crestal area of the residual ridge will become the primary stress-bearing area for vertically directed forces. Some resistance to these forces may be obtained by the immediate buccal and lingual slopes of the ridge. Palatal tissues between the medial palatal raphe and the lingual slope of the posterior edentulous ridge are readily displaceable and cannot be considered as primary stress-bearing sites (Figure 17-2). The tissues covering the crest of the maxillary residual ridge must be less displaceable than the tissues that cover palatal areas, or relief of palatal tissues must be provided in the denture bases or for palatal major connectors.

### Extent of Residual Ridge Coverage by the Denture Base

The broader the residual ridge coverage, the greater is the distribution of the load, which results in less load per unit area (Figure 17-3). A denture base should cover as much of the residual ridge as possible and should be extended the maximum amount within the physiologic tolerance of the limiting border structures or tissues. Knowledge of these border tissues and the structures that influence their movement is paramount to the development of broad coverage denture bases. In a series of experiments, Kaires\* has shown

that “maximum coverage of denture-bearing areas with large, wide denture bases is of the utmost importance in withstanding both vertical and horizontal stresses.”

It is not within the scope of this text to review the anatomic considerations related to denture bases. The student is referred to several articles listed in the “Selected Reading Resources” regarding this subject.

### Type and Accuracy of the Impression Registration

The residual ridge may be said to have two forms: the anatomic form and the functional form (Figure 17-4). The anatomic form is the surface contour of the ridge when it is not supporting an occlusal load. The functional form of the residual ridge is the surface contour of the ridge when it is supporting a functional load.

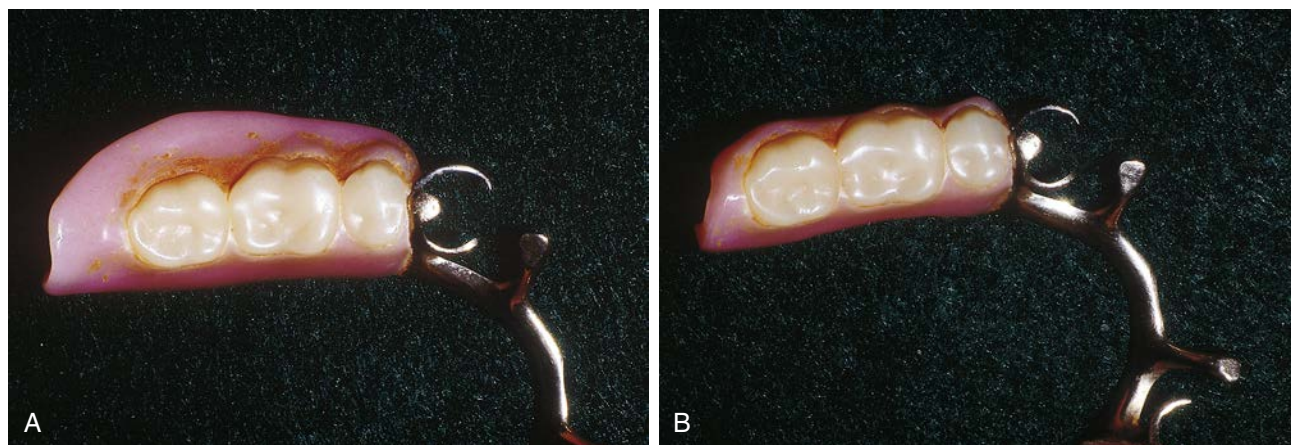
The anatomic form is recorded by a soft impression material, such as a metallic oxide impression paste, if the entire impression tray is uniformly relieved. Depending on the viscosity of the particular impression material used and the rigidity of the impression tray, it is also the form that can be recorded by mercaptan rubber, silicone, and hydrocolloid impression materials. Distortion and tissue displacement by pressure may result from confinement of the impression material within the tray and from insufficient thickness of impression material between the tray and the tissues, as well as from the viscosity of the impression material; however, none of these factors is selective or physiologic in its action. These accidental distortions of the tissues occur because of faulty technique. Use of the anatomic form of the residual ridge in fabricating complete dentures is quite common because of a belief that this is the most physiologic form for support of the dentures.

However, many other dentists believe that certain regions of the residual ridge(s) in a partially edentulous patient are more capable of supporting dentures than other regions. Their impression methods are directed to place more stress on primary stress-bearing regions with specially constructed individual trays and at the same time record the anatomic form of other basal seat tissues, which cannot assume a stress-bearing role. The form of the residual ridge recorded under some loading, whether by occlusal loading, finger loading, specially designed individual trays, or the consistency of the recording medium, is called the *functional form*. This is the surface contour of the ridge when it is supporting a functional load. How much it differs from the anatomic form depends on the thickness and structural characteristics of the soft tissues overlying the residual bone. It will also differ from the anatomic form in proportion to the total load applied to the denture base. Of the two philosophies, the latter seems to be more logical.

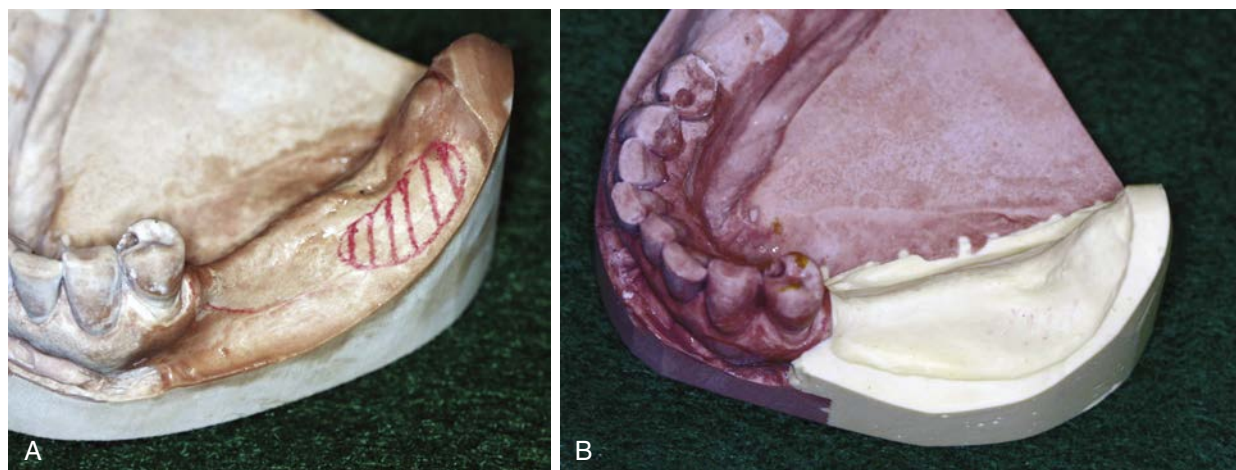
McLean and others recognized the need to record the tissues that support a distal extension removable partial denture base in their functional form, or supporting state, and then relate them to the remainder of the arch by means of a secondary impression. This was called a *functional impression* because it recorded the ridge relation under simulated function.

Any method, whether it records the functional relationship of the ridge to the remainder of the arch, or the functional

\*From Kaires AK: Effect of partial denture design on bilateral force distribution, *J Prosthet Dent* 6:373-389, 1956.



**FIGURE 17-3** Comparison of two removable partial dentures for the same patient. **A**, This is the replacement denture, with properly extended bases. **B**, This denture has severely underextended bases. Occlusal forces are more readily distributed to denture-bearing areas by the replacement denture (**A**).



**FIGURE 17-4** Comparison of anatomic and functional ridge forms. **A**, Original master cast with the edentulous area recorded in its anatomic form, using elastic impression material. **B**, Same cast after the edentulous area has been repoured to its functional form as recorded by the secondary impression.

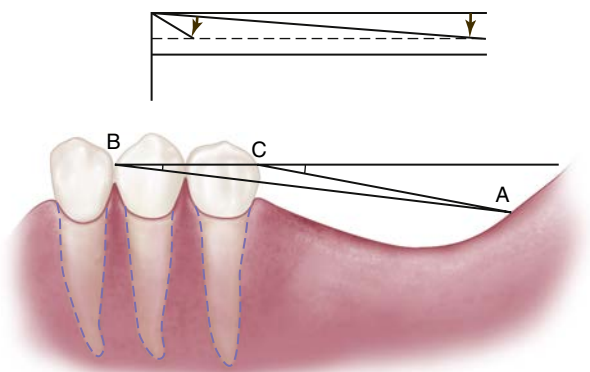
form of the ridge itself, may provide acceptable support for the removable partial denture. On the other hand, those who use the anatomic ridge form for the removable partial denture should seriously consider the need for some mechanical stress-breaker to avoid the possible cantilever action of the distal extension base against the abutment teeth.

Steffel has classified advocates of the various methods for treating the distal extension removable partial denture as follows:

1. Those who believe that ridge and tooth supports can best be equalized by the use of stress-breakers or resilient equalizers.
2. Those who insist on bringing about the equalization of ridge and tooth support by physiologic basing, which is accomplished by a pressure impression or by relining of the denture under functional stresses.
3. Those who uphold the idea of extensive stress distribution for stress reduction at any one point.

It would seem that there is little difference in the philosophy behind methods 2 and 3 as given by Steffel, for both the equalization of tooth and tissue support and stress distribution over the greatest area are objectives of the functional type of impression. Many of the requirements and advantages that are associated with the distributed stress denture apply equally well to the functionally or physiologically based denture. Some of these requirements are (1) positive occlusal rests; (2) an all-rigid, nonflexible framework; (3) indirect retainers to add stability; and (4) well-adapted, broad coverage bases.

Those who do not accept the theory of physiologic basing, for one reason or another, should use some form of stress-breaker between the abutment and the distal extension base.



**FIGURE 17-5** Acute dip of the short denture base is compared with that of the long one in the *top drawing*. In the *bottom drawing*, when the point of rotation is changed from C to B by the loss of more teeth, it can be seen that a proportionally greater area of the residual ridge is used to support the denture base than occurs when the fulcrum line passes through C. The amount of movement is directly related to the quality of tissue support. Line AC represents the length of the denture base. (See also Figure 10-3.)

The advantages and disadvantages of doing so have been given in Chapter 9.

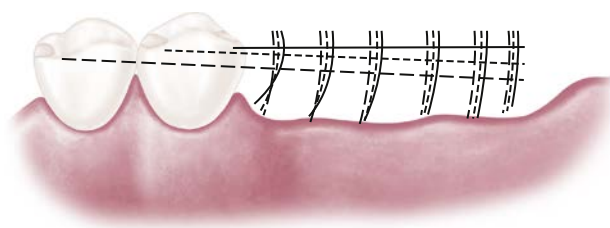
### Accuracy of the Fit of the Denture Base

Support of the distal extension base is enhanced by intimacy of contact of the tissue surface of the base and the tissues that cover the residual ridge. The tissue surface of the denture base must optimally represent a true negative of the basal seat regions of the master cast. Denture bases have been discussed in Chapter 9.

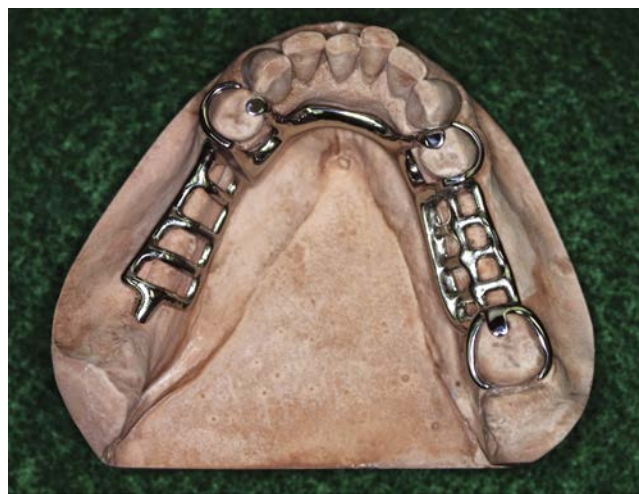In addition, the denture base must be related to the removable partial denture framework in the same manner as the basal seat tissues were related to the abutment teeth when the impression was made. Every precaution must be taken to ensure this relationship when the altered cast technique of making a master cast is used.

### Design of the Removable Partial Denture Framework

Some rotation movement of a distal extension base at the distal abutment is inevitable under functional loading. It must be remembered that the extent to which abutments are subjected to rotational and torquing forces that result from masticatory function is directly related to the position and resistance of the food bolus. The greatest movement takes place at the most posterior extent of the denture base. The retromolar pad region of the mandibular residual ridge and the tuberosity region of the maxillary residual ridge therefore are subjected to the greatest movement of the denture base (Figure 17-5). Steffel and Kratochvil have suggested that as the rotational axis is moved from a disto-occlusal rest to a more anterior location, more of the residual ridge receives vertically directed occlusal forces to support the



**FIGURE 17-6** If rotation of the distal extension base occurs around the nearest rest, as the rest is moved anteriorly more of the residual ridge will be used to resist rotation. Compare the vertical arcs of the *long-dash broken line* with the arcs of the *solid line*. (See also Figure 10-4.)



**FIGURE 17-7** The occlusal rest is placed on the mesio-occlusal surface of the lower first premolar; this will move the point of rotation anterior to the conventionally placed disto-occlusal rest if contact of the proximal minor connector on the distal guiding plane is designed to release under function. The occlusal rest is connected to the lingual bar by a minor connector, which contacts the small mesiolingual prepared guiding plane. Note the vertical extension of the denture base minor connector contacting the distal guiding-plane surface. The lingual guiding plane is prepared to extend from the occlusal surface inferiorly to approximately one third of the height of the lingual surface and is as broad as the contacting minor connector. The distal guiding plane extends from the distal marginal ridge gingivally about two thirds of the height of the distal surface. Such preparations must be designed not to lock the tooth in a viselike grip when the denture base moves toward the residual ridge.

denture base (Figure 17-6). They have suggested that occlusal rests may be moved anteriorly to better use the residual ridge for support without jeopardizing either vertical or horizontal support of the denture by occlusal rests and guiding planes (Figure 17-7).

It is possible, however, that the proximal plate minor connector adjacent to the edentulous area will not disengage from or break contact with the guiding plane. When one considers impression and cast formation variables;

waxing, investing, and casting discrepancies; and finishing and polishing procedures, it may be somewhat philosophical to assume that the minor connector proximal plate will have contact, and if it does, will disengage its contact with the guiding plane, especially if the tissues that support the extension denture base are healthy and demonstrate favorable contour. It is more likely that the abutment tooth will move physiologically to contact the minor connector and that the disengagement will depend on the amount of tissue displacement. Geometrically, the actual amount of tissue displacement in the extension base area under occlusal load may not be enough to cause the minor connector to break contact with the guiding plane.

### Total Occlusal Load Applied

Patients with distal extension removable partial dentures generally orient the food bolus over natural teeth rather than prosthetic teeth. This is likely due to the more stable nature of the natural dentition, the proprioceptive feedback it provides for chewing, and the possible nociceptive feedback from the supporting mucosa. This has an effect on the direction and magnitude of the occlusal load to the removable partial denture and, thus, on the load transferred to the abutments. Given this, the support from the residual ridge should be optimized and shared appropriately with the remaining natural dentition. When the opposing natural teeth are super-erupted, control of eccentric functional contacts and the resultant horizontal loads makes chronic discomfort a clinical challenge. This is best managed by reducing the occlusal plane irregularity and enhancing extension base stability through the use of a dental implant.

The number of artificial teeth, the width of their occlusal surfaces, and their occlusal efficiency influence the total occlusal load applied to the removable partial denture. Kaires\* conducted an investigation under laboratory conditions and concluded that “the reduction of the size of the occlusal table reduces the vertical and horizontal forces that act on the removable partial dentures and lessens the stress on the abutment teeth and supporting tissues.”

### ANATOMIC FORM IMPRESSION

The anatomic form impression is a one-stage impression method using an elastic impression material that will produce a cast that does not represent a functional relationship between the various supporting structures of the partially edentulous mouth. It will represent only the hard and soft tissues at rest. With the removable partial denture in position in the dental arch, the occlusal rest(s) will fit the rest seat(s) of the abutment teeth, whereas the denture base(s) will fit the surface of the mucosa at rest. When a masticatory load is applied to the extension base(s) with a food

bolus, the rest(s) will act as a definite stop, which will limit the part of the base near the abutment tooth from transmitting the load to the underlying anatomic structures. The distal end of the base(s), however, that is able to move more freely, will transmit more of the masticatory load to the underlying extension base tissues and will transmit more torque to the abutment teeth through the rigid removable partial denture framework.

It is obvious that the soft tissues that cover the ridge cannot by themselves carry any load applied to them. They act as a protective padding for the bone, which in the final analysis is the structure that receives and resists the masticatory load. Distribution of this load over a maximum area of bone is a prime requisite in preventing trauma both to the tissues of the extension base areas and to the abutment teeth.

A removable partial denture fabricated from a one-stage impression, which records only the anatomic form of basal seat tissues, places more of the masticatory load on the abutment teeth and that part of the bone that underlies the distal end of the extension base. The balance of the bony ridge will not function in carrying its share of the load. The result will be a traumatic load to the bone underlying the distal end of the base and to the abutment tooth, which in turn can result in bone loss and loosening of the abutment tooth. A properly prepared, individualized impression tray can be used to record the primary stress-bearing areas in a functional form and the non-stress-bearing areas in an anatomic form, just as is often accomplished in making impressions for complete dentures.

Some dentists believe that every removable partial denture should be relined before its final placement in the mouth. Some believe that tissue can be evenly displaced and use impression materials of heavy consistency. This latter practice can introduce traumatic stresses to the underlying tissues. Some dentists use free-flowing pastes that produce an impression of the soft tissues at rest. A removable partial denture made according to this technique will be similar to a removable partial denture fabricated from a one-piece impression. The occlusal rest will act as a stop and prevent an even distribution of the masticatory load by the base to the edentulous ridge.

### METHODS FOR OBTAINING FUNCTIONAL SUPPORT FOR THE DISTAL EXTENSION BASE

The objective of any functional impression technique is to provide maximum support for the removable partial denture bases. This allows for the maintenance of occlusal contact between natural and artificial dentition and, at the same time, minimal movement of the base, which would create leverage on the abutment teeth. Although some tissue-ward movement of the distal extension base is unavoidable and is dependent on the six factors listed previously, it can be minimized by providing the best possible support for the denture base.

A thorough understanding of the characteristics of each of the impression materials and impression methods leads to the conclusion that no single material can record the

\*From Kaires AK: Effect of partial denture design on bilateral force distribution, *J Prosthet Dent* 6:373-389, 1956.

anatomic form of the teeth and tissues in the dental arch and, at the same time, the functional form of the residual ridge. Therefore, some secondary or corrected impression method must be used.

The method selected is greatly influenced by determination of the support potential of the residual ridge mucosa. Mucosa that is firm and minimally displaceable provides a different support potential than mucosa that is more easily displaced. Methods for obtaining functional support for either should satisfy the two requirements for providing adequate support to the distal extension removable partial denture base. These are (1) that it records and relates the supporting soft tissue under some loading; and (2) that it distributes the load over as large an area as possible.

### Selective Tissue Placement Impression Method

Soft tissues that cover basal seat areas may be placed, displaced, or recorded in their resting or anatomic form. Placed and displaced tissues differ in the degree of alteration from their resting form and in their physiologic reaction to the amount of displacement. For example, the palatal tissues in the vicinity of the vibrating line can be slightly displaced to develop a posterior palatal seal for the maxillary complete denture and will remain in a healthy state for extended periods. On the other hand, these tissues develop an immediate inflammatory response when they have been overly displaced in developing the posterior palatal seal.

Oral tissues that have been overly displaced or distorted attempt to regain their anatomic form. When they are not permitted to do this by the denture bases, the tissues become inflamed and their physiologic functions become impaired, accompanied by bone resorption. Tissues that are minimally displaced (placed) by impression procedures for definitive border control respond favorably to the additional pressures placed on them by the resultant denture bases if these pressures are intermittent rather than continuous.

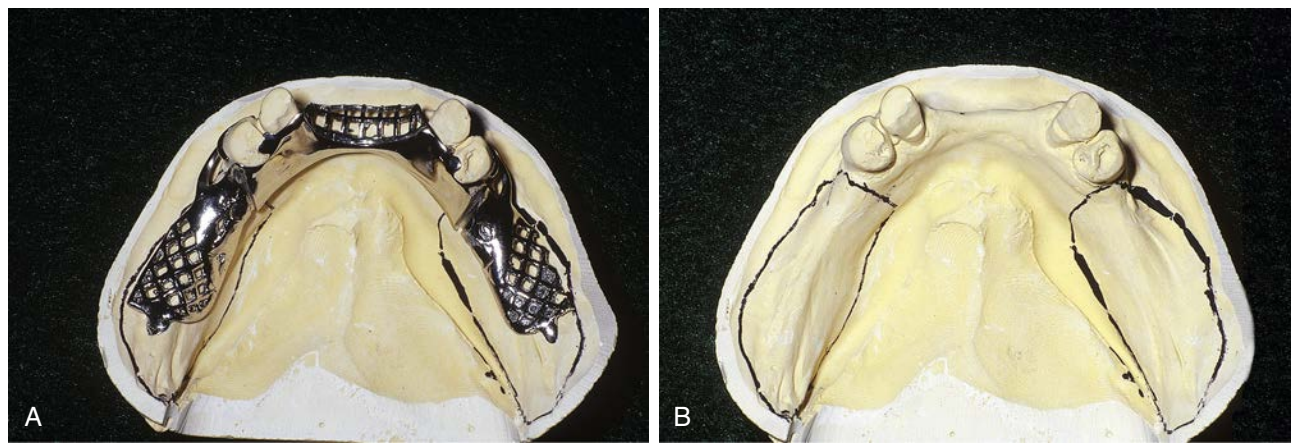
The selective tissue placement impression method is based on these clinical observations, the histologic nature of tissues that cover the residual alveolar bone, the nature of the residual ridge bone, and its positional relationship to the direction of stresses that will be placed on it. It is further believed that by use of specially designed individual trays for impressions, denture bases can be developed that will use those portions of the residual ridge that can withstand additional stress and at the same time relieve the tissues of the residual ridge that cannot withstand functional loading and remain healthy.

There should be no philosophical difference between the requirement of support and coverage by bases of distal extension removable partial dentures and that of complete dentures, either maxillary or mandibular, because the objective of maximum support is the same. The tray is unquestionably the most important part of an impression. However, a tray must be so formed and modified that the impression philosophy of the dentist can be carried out. Making individualized acrylic-resin impression trays is described in Chapter 16, and a method of attaching custom trays to a removable partial denture framework is illustrated in [Figure 17-8](#).

### Framework Fitting

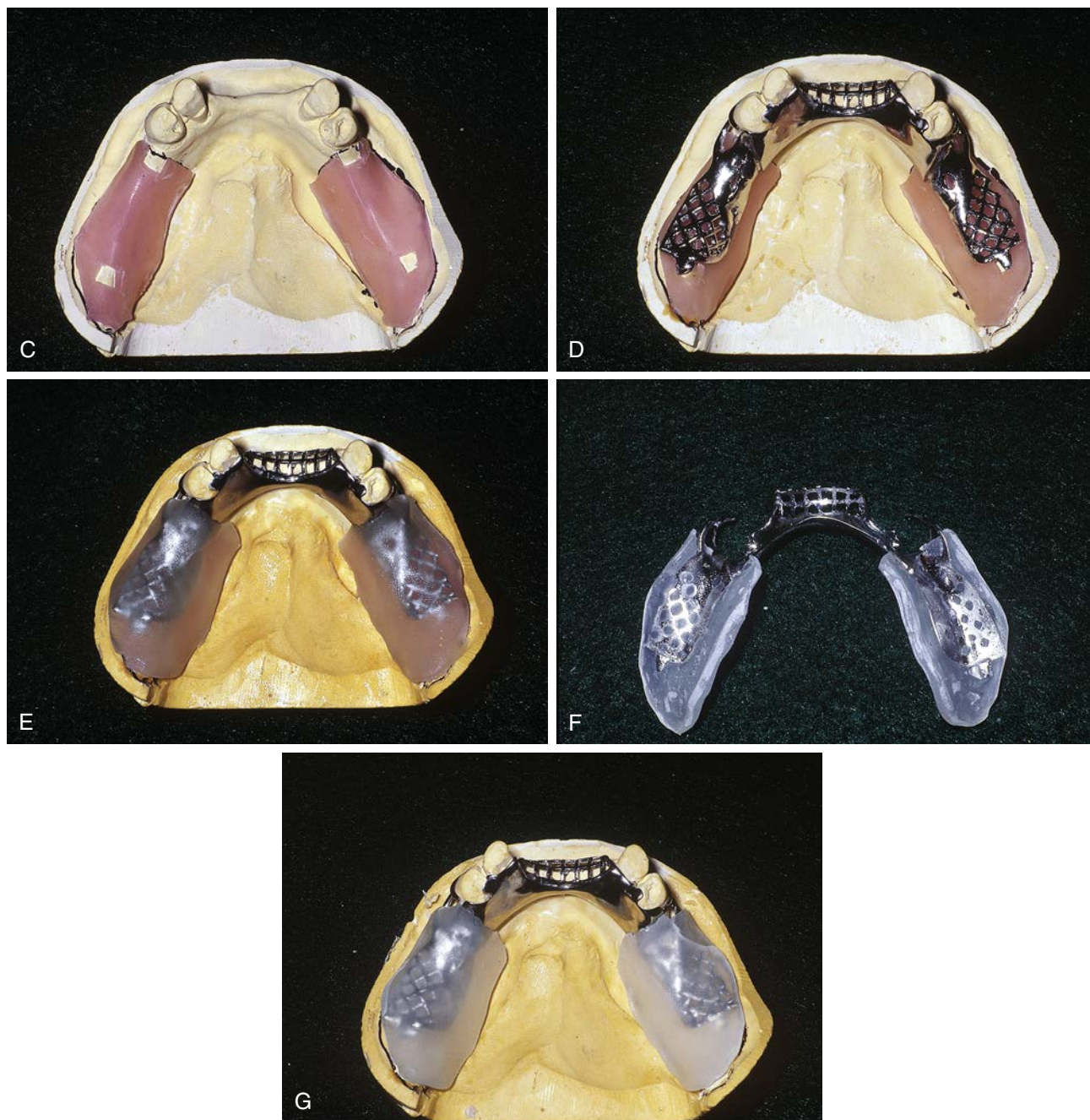Because the goal is to maximize soft tissue support while using the teeth to their supportive advantage, the framework fitted to the teeth while soft tissue support is registered provides a means of coordinating both. This means that before the trays are attached, the framework must be fitted in the mouth as illustrated in [Figure 17-9](#). Fitting the framework involves the following steps:

1. Use of disclosing media to identify interferences to completely seating the removable partial denture framework.
2. Use of disclosing media to identify the appropriate contact(s) of the component parts of the framework during seating of the framework and when the framework is completely seated in its designated terminal position.

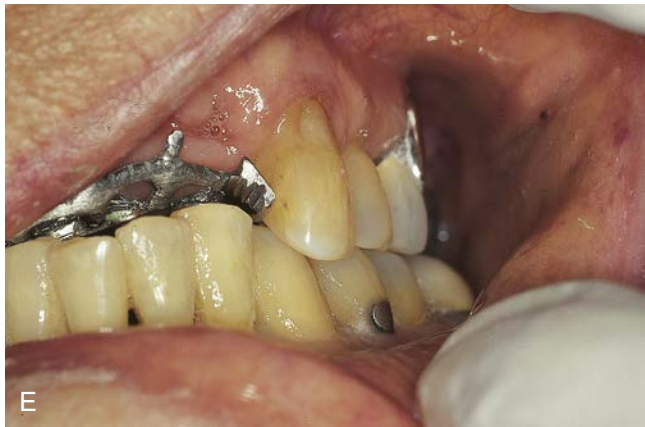
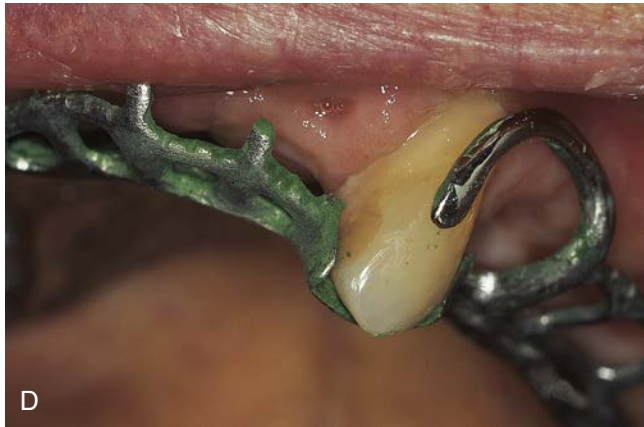
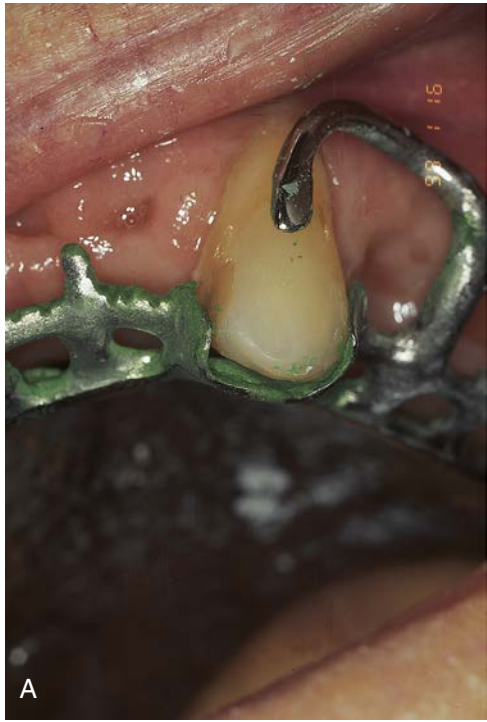**FIGURE 17-8** A secondary impression for the distal extension mandibular removable partial denture is made in individual trays attached to the denture framework. **A**, The framework has been tried in the mouth and fits the mouth and master cast as planned. **B**, The outline of acrylic-resin trays is penciled on the cast.

*Continued*



**FIGURE 17-8, CONT'D** **C**, One thickness of baseplate wax is adapted to outlines to act as spacers so that room for the impression material exists in the finished trays. Windows are cut in the wax spacers corresponding to regions on the cast contacted by minor connectors (tissue stops) for denture bases. **D**, The framework is warmed and pressed to position on the relieved master cast. All regions of the cast that will be contacted by autopolymerizing acrylic-resin or visible light-cured (VLC) resin are painted with tinfoil substitute (Alcote) or model release agent (MRA). **E**, Acrylic-resin material is adapted to the cast and over the framework with finger pressure as described in Chapter 16. Excess material over the borders of the cast is removed with a sharp knife while the material is still soft. **F**, Polymerized acrylic-resin trays and framework are removed from the cast, and trays are trimmed to outline the wax spacer. **G**, Borders of the trays will be adjusted to extend 2 mm short of the tissue reflections. Holes will be placed in the trays corresponding to the crest of the residual ridge and retromolar pads to allow escape of excess impression material when an impression is made.



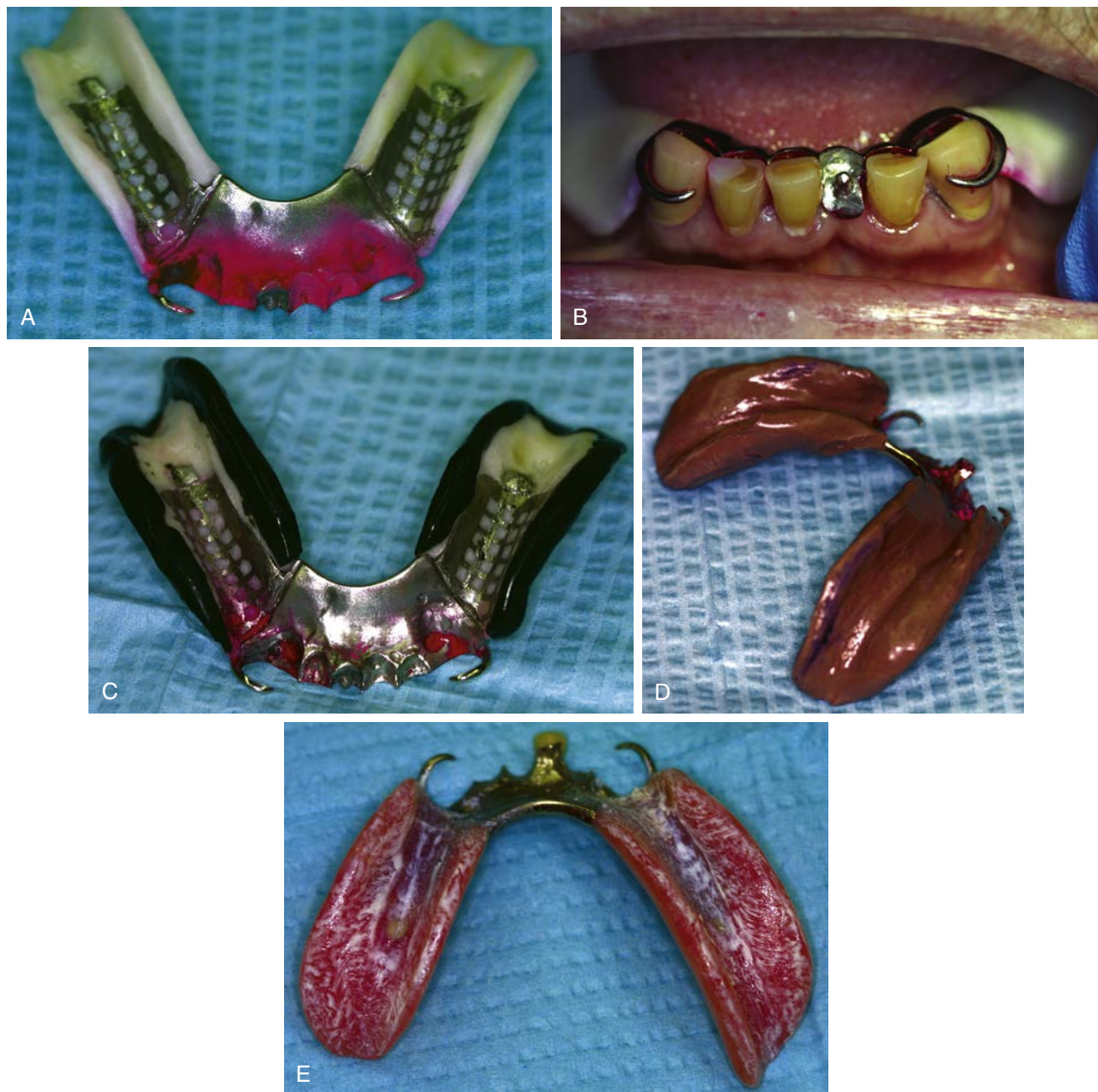**FIGURE 17-9** The framework must be evaluated to assure complete seating, full contact with the remaining dentition for stabilization, support, and retention as planned, and to allow full natural tooth contact. **A**, Several types of disclosing media may be used, such as stencil correction fluid, rouge, and chloroform, and disclosing fluids, pastes, and waxes. Here, a spray disclosing medium has been applied and the framework is placed with mild pressure. Incomplete seating is seen when the framework binds. It is imperative that the framework not be forced to place at this initial seating. **B**, A portion of the proximal plate is preventing complete seating. **C**, The framework is carefully adjusted as over-adjustment can result in a poorly adapted framework. **D**, The framework seats completely after adequate adjustment. This may require repeated disclosing and careful adjustment; however, if improvement is not seen with each framework modification, there should be concern regarding frame accuracy. **E**, Following complete seating and verification of appropriate tooth contacts by component parts (i.e., rests, proximal plates, stabilizing components), the occlusion must be checked and the framework adjusted until natural tooth contacts that exist without the framework seated are achieved with the framework in place. All adjusted regions can be carefully polished with rotary rubber points.

### 3. Adjusting the seated framework to the opposing occlusion.

If there are opposing frameworks, the maxillary framework is removed from the mouth and the mandibular framework is adjusted to the natural maxillary dentition; then the maxillary framework is replaced and it is adjusted to the mandibular dentition with its framework in place. It is important to remember that the metal frameworks must allow all of the natural dentition to maintain the same designed contact relationship with the opposing arch as when the frameworks are out of the mouth. After the framework has been fitted and the custom trays have been attached, selective tissue

placement impression and cast formation can be accomplished as described in [Figure 17-10](#).

The altered cast method of impression making is most commonly used for the mandibular distal extension partially edentulous arch (Kennedy Class I and Class II arch forms). A common clinical finding in these situations is greater variation in tissue mobility and tissue distortion or displaceability, which requires some selective tissue placement to obtain the desired support from these tissues. This variability in tissue mobility is probably related to the pattern of mandibular residual ridge resorption. Altered cast



**FIGURE 17-10** Selective tissue placement impression technique. **A**, Tray attached at the frame try-in, which in **B** is seen incompletely seated. **C**, Completed border molding, which defines the primary bearing areas of the buccal shelves bilaterally. This bearing area and the lingual extension are seen in the final impression (**D**), which can be seen to be in contact with use of the pressure-indicating paste (**E**).

impression methods are seldom used in the maxillary arch because of the nature of the masticatory mucosa and the amount of firm palatal tissue present to provide soft tissue support. These tissues seldom require placement to provide the required support. If excessive tissue mobility is present, it is often best managed by surgical resection, as this is a primary supporting area.

Support is obtained from the primary support areas in the manner by which the flow of the impression material is controlled during the impression-making procedure. Restricting the flow of the material in the primary stress-bearing areas (by minimizing the amount of relief over the area when the custom tray was made) causes greater pressure to be exerted on the tissues in this area (compared with other areas of unrestricted flow where a greater amount of relief or venting of the impression tray was provided). This is often referred to as the “selected pressure” or “dynamic” impression method. By controlling the flow of the impression material with wax relief and venting, one can place or displace the soft tissues over the primary support areas so that they are the primary areas to provide support to the denture base when a removable partial denture is functionally loaded.

An impression for a mandibular distal extension partially edentulous arch may also be adequately made in an individualized, complete arch tray. To do so, not only must the tray be formed to provide proper space for the particular impression materials, but provision must be made so that the functional form of primary stress-bearing areas can be recorded.

Such an impression procedure, properly executed, can be used when metal bases are to be incorporated in the design of the restoration. There is little difference, if any, between recording the basal seats in the partially edentulous arch and recording like areas for complete dentures on an edentulous arch. A secondary impression made in custom trays attached to the framework only makes definitive border control and tissue placement a bit easier, compared with the individualized complete arch tray.

### Functional Impression Technique

When the residual ridge mucosa demonstrates a uniformly firm consistency, an impression technique that involves capturing the tissue form while the patient is in occlusion can be considered. Such a technique records the mucosal position and shape under the influence of a static closure force, similar to functional masticatory forces. The more the mucosa displaces under function, the more rebound there is likely to be. Because the prosthesis will be under occlusal load for only a portion of a day, minimal rebound is desired so as to maintain the clasp assembly–tooth relationship. When such a technique is applied to firm, minimally displaceable mucosa, a minimal rebound effect is seen on the prosthesis position. The selective pressure technique (described earlier) can be applied to all varieties of residual ridges because it is customized to mucosal conditions, whereas the functional impression technique has limited application to a uniformly firm ridge consistency.

# CHAPTER

# 18

## Occlusal Relationships for Removable Partial Dentures

### CHAPTER OUTLINE

#### Desirable Occlusal Contact Relationships for Removable Partial Dentures

#### Methods for Establishing Occlusal Relationships

Direct Apposition of Casts

Interocclusal Records with Posterior Teeth Remaining  
Occlusal Relations Using Occlusion Rims  
on Record Bases

Jaw Relation Records Made Entirely on Occlusion  
Rims

Establishing Occlusion by the Recording  
of Occlusal Pathways

#### Materials for Artificial Posterior Teeth

Arranging Teeth to an Occluding Template

#### Establishing Jaw Relations for a Mandibular

Removable Partial Denture Opposing a Maxillary  
Complete Denture

The fourth phase\* in the treatment of patients with removable partial dentures is the establishment of a functional and harmonious occlusion. Occlusal harmony between a removable partial denture and the remaining natural teeth is a major factor in the preservation of the health of their surrounding structures. In the treatment of patients with complete dentures, the inclination of the condyle path is the only factor not within the control of the dentist. All other factors may be altered to obtain occlusal balance and harmony in eccentric positions to conform to a particular concept and philosophy of occlusion.

Balanced occlusion is desirable with complete dentures because unbalanced occlusal stresses may cause instability of the dentures and trauma to the supporting structures. These stresses can reach a point that causes movement of the denture bases. In removable partial dentures, however, because of the attachment of the removable partial denture to the abutment teeth, occlusal stresses can be transmitted directly to the abutment teeth and other supporting structures, resulting in sustained stresses that may be more damaging than those transient stresses found in complete dentures. Failure to provide and maintain adequate occlusion on the removable partial denture is primarily a result of (1) lack of support for the denture base; (2) the fallacy of establishing occlusion to a single static jaw relation record; and (3) an unacceptable occlusal plane.

In establishing occlusion on a removable partial denture, the influence of the remaining natural teeth is usually such that the occlusal forms of the teeth on the removable partial denture must be made to conform to an already established occlusal pattern. Occlusal adjustment or restoration may have altered this pattern. However, the pattern present at

\*See Chapter 2, under discussion on the phases of removable partial denture service.

the time the removable partial denture is made dictates the occlusion on the removable partial denture. The only exceptions are those in which an opposing complete denture can be made to function harmoniously with the removable partial denture, or in which only anterior teeth remain in both arches and the incisal relationship can be made so that tooth contacts do not disturb denture stability or retention. In these situations, jaw relation records and the arrangement of the teeth may proceed in the same manner as with complete dentures, and the same general principles apply.

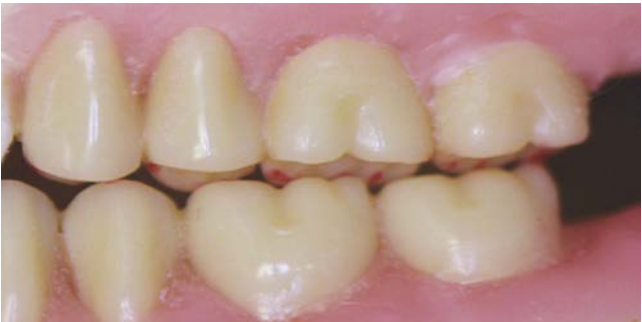With all other types of removable partial dentures, the remaining teeth dictate the occlusion. The dentist should strive for planned contacts in centric occlusion and no interferences in lateral excursions. Although a functional relationship of the removable partial denture to the natural dentition sometimes may be adjusted satisfactorily in the mouth, extraoral adjustment is often easier for both dentist and patient, is more accurate, and can be accomplished in a more comprehensive manner.

Establishment of a satisfactory occlusion for the removable partial denture patient should include the following: (1) analysis of the existing occlusion; (2) correction of existing occlusal disharmony; (3) recording of centric relation or an adjusted centric occlusion; (4) harmonizing of eccentric jaw movements for a functional eccentric occlusion; and (5) correction of occlusal discrepancies created by the fit of the framework and during processing of the removable partial denture.

**DESIRABLE OCCLUSAL CONTACT RELATIONSHIPS FOR REMOVABLE PARTIAL DENTURES**

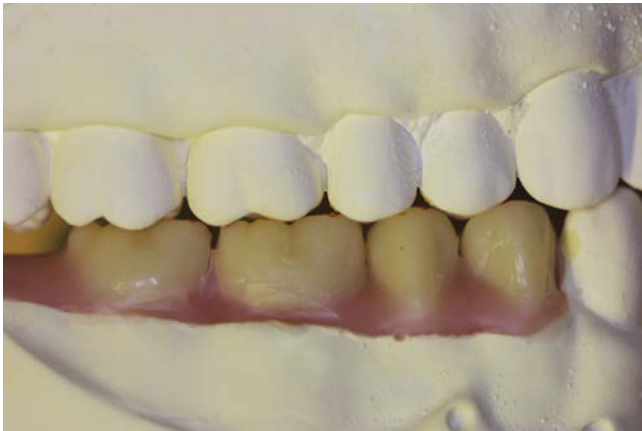The following occlusal arrangements are recommended to develop a harmonious occlusal relationship among removable partial dentures and to enhance stability of the removable partial dentures:

- 1. Simultaneous bilateral contacts of opposing posterior teeth must occur in centric occlusion.
- 2. Occlusion for tooth-supported removable partial dentures may be arranged similarly to the occlusion seen in



**FIGURE 18-1** Posterior occlusion of a maxillary complete denture opposing a Class I mandibular removable partial denture. The stability of the maxillary complete denture can be promoted by developing balanced occlusion as shown.

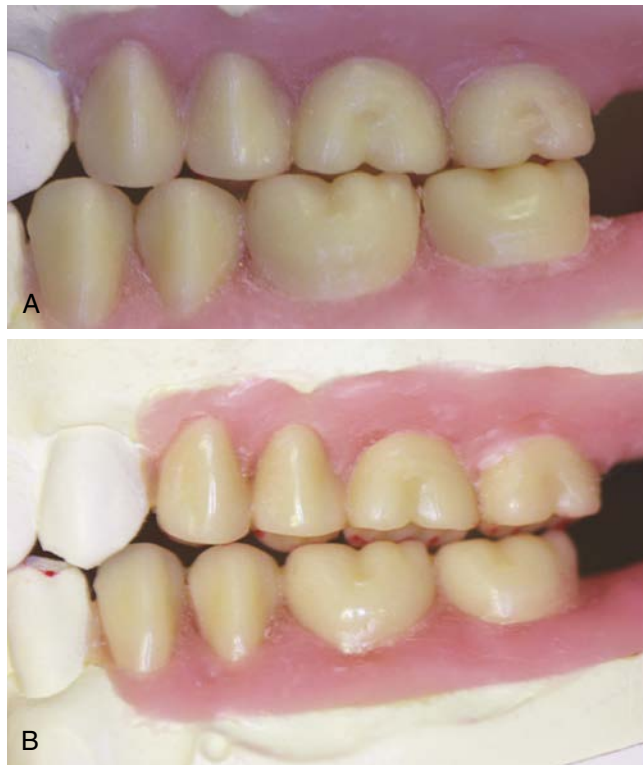- a harmonious natural dentition, because stability of such removable partial dentures results from the effects of direct retainers at both ends of the denture base.
- 3. Bilateral balanced occlusion in eccentric positions should be formulated when a maxillary complete denture (Figure 18-1) opposes the removable partial denture. This is accomplished primarily to promote the stability of the complete denture. However, simultaneous contacts in a protrusive relationship do not receive priority over appearance, phonetics, and/or a favorable occlusal plane.
- 4. Working side contacts should be obtained for the mandibular distal extension denture (Figure 18-2). These contacts should occur simultaneously with working side contacts of the natural teeth to distribute the stress over the greatest possible area. Masticatory function of the denture is improved by such an arrangement.
- 5. Simultaneous working and balancing contacts should be formulated for the maxillary bilateral distal extension removable partial denture whenever possible (Figure 18-3). Such an arrangement will compensate in part for the unfavorable position that the maxillary artificial teeth must occupy in relation to the residual ridge, which is usually lateral to the crest of the ridge. However, this desirable relationship often must be compromised when the patient's anterior teeth have an excessively steep vertical overlap with little or no horizontal overlap. Even in this situation, working side contacts can be obtained without resorting to excessively steep cuspal inclinations.
- 6. Only working contacts need to be formulated for the maxillary or mandibular unilateral distal extension removable partial denture (Figure 18-4). Balancing side contacts would not enhance the stability of the denture because it is entirely tooth supported by the framework on the balancing side.



**FIGURE 18-2** Bilateral distal extension mandibular removable partial denture opposed by natural dentition in the maxillary arch. Working contacts are achieved, balancing contacts are purposefully avoided because they would not enhance the stability of the restoration, and protrusive balance is avoided in favor of an acceptable appearance and a favorable occlusal plane.

7. In the Kennedy Class IV removable partial denture configuration, contact of opposing anterior teeth in the planned intercuspal position is desired to prevent continuous eruption of the opposing natural incisors, unless they are otherwise prevented from extrusion by means of a lingual plate or auxiliary bar, or by splinting. Contact of the opposing anterior teeth in eccentric positions can be developed to enhance incisive function but should be arranged to permit balanced occlusion without excursive interferences.
8. Artificial posterior teeth should not be arranged farther distally than the beginning of a sharp upward incline of the mandibular residual ridge or over the retromolar pad (Figure 18-5). To do so would have the effect of shunting the denture anteriorly.

A harmonious relationship of opposing occlusal and incisal surfaces alone is not adequate to ensure stability of distal extension removable partial dentures. In addition, the relationship of the teeth to the residual ridges must be considered. Bilateral eccentric contact of the mandibular distal extension removable partial denture need not be formulated to stabilize the denture. The buccal cusps, however, must be favorably placed to direct stress toward the buccal shelf, which is the primary support area in the mandibular arch.

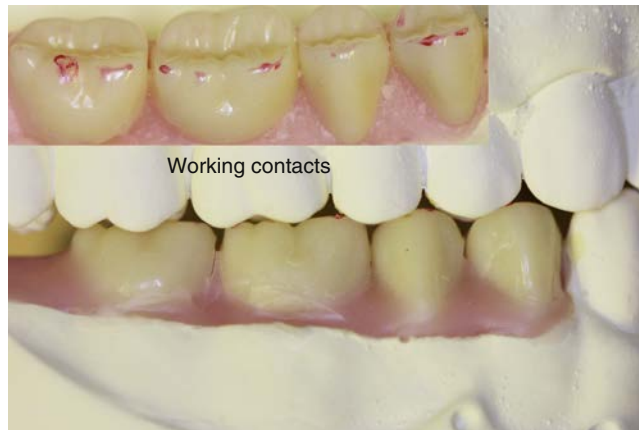


**FIGURE 18-3** Opposing Class I partially edentulous arches arranged to allow working side contacts of opposing posterior teeth (A) with balancing contact (B) arranged to minimize tipping of the maxillary removable partial denture and to broadly distribute forces accruing to its supporting structures (abutments and residual ridges).

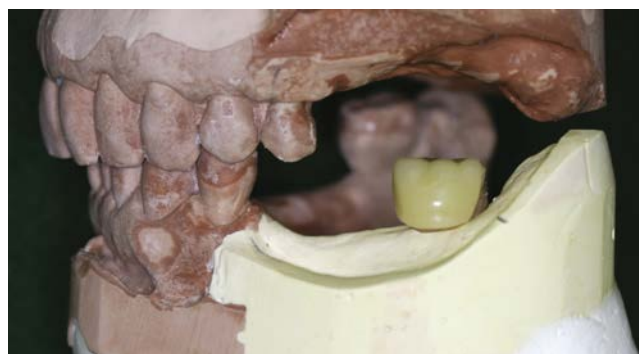In such positions, the denture is not subjected to excessive tilting forces (Figure 18-6). On the other hand, the artificial teeth of the bilateral, distal extension, maxillary removable partial denture often must be placed lateral to the crest of the residual ridge (Figure 18-7). Such an unfavorable position can cause tipping of the denture, which is restrained only by direct retainer action on the balancing side. To enhance the stability of the denture, it seems logical to provide simultaneous working and balancing contacts in these situations if possible.

## METHODS FOR ESTABLISHING OCCLUSAL RELATIONSHIPS

Five methods of establishing interocclusal relations for removable partial dentures will be briefly described. Before any of these is described, it is necessary that the use of a face-bow mounting of the maxillary cast and pertinent factors in



**FIGURE 18-4** When occlusion is developed for a Class II removable partial denture (maxillary or mandibular), only working side contacts are necessary, because the cross-arch framework stability gained from tooth engagement provides resistance to movement. Balancing side contacts do not enhance stability beyond that provided by the contralateral teeth.



**FIGURE 18-5** Mandibular posterior teeth should not be arranged distal to the upward incline (ascending ramus) of the residual ridge. The molar tooth has been placed just anterior to a mark on the cast land area designating the beginning incline.

removable partial denture occlusion be considered. The technique for applying the facebow has been described briefly in Chapter 13.

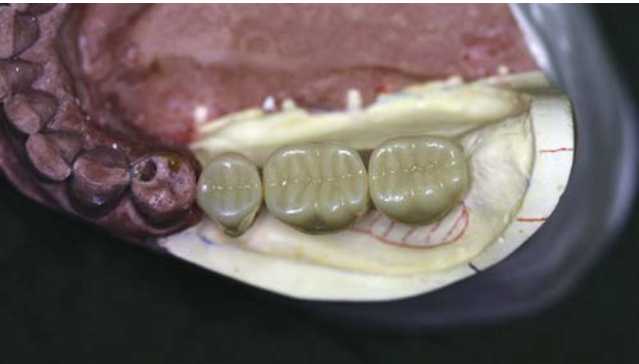
Although a hinge axis mounting may be desirable for complete oral rehabilitation procedures, any of the common types of facebow will facilitate mounting of the maxillary cast in relation to the condylar axis in the articulating instrument with reasonable accuracy and are acceptable for a removable partial denture. As was suggested in Chapter 13, it is still better that the plane of occlusion be related to the axis-orbital plane. Because the dominant factor in removable partial

denture occlusion is the remaining natural teeth and their proprioceptive influence on occlusion, a comparable radius at the oriented plane of occlusion in an acceptable instrument will allow reasonably valid mandibular movements to be reproduced.

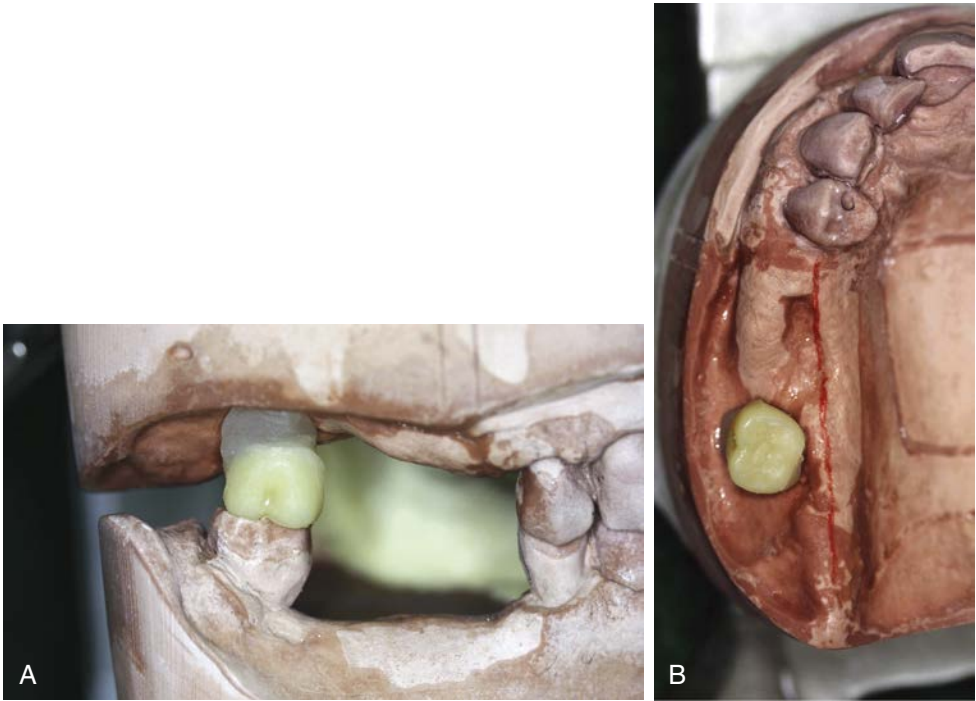
Semiadjustable articulators can simulate but not duplicate jaw movement. Realization of the limitations of a specific instrument and knowledge of the procedures that can overcome these limitations are necessary if an adequate occlusion is to be created.

The recording of occlusal relationships for the partially edentulous arch may vary from the simple apposition of opposing casts (by occluding sufficient remaining natural teeth) to the recording of jaw relations in the same manner as for a completely edentulous patient. As long as some natural teeth remain in contact, however, the cuspal influence that those teeth will have on functional jaw movements dictates the placement of the artificial teeth and the occlusal scheme.

The horizontal jaw relation (planned intercuspal position or centric relation) in which the restoration is to be fabricated should have been determined during diagnosis and treatment planning. Mouth preparations also should have been accomplished in keeping with this determination, including occlusal adjustment of the natural dentition, if such was indicated. Therefore one of the following conditions should exist: (1) centric relation and planned intercuspal position coincide with no evidence of occlusal pathologic conditions; therefore the decision should be to



**FIGURE 18-6** The posterior teeth in this distal extension with a narrower buccal-lingual width than the original teeth have been selected, and they are placed relative to the primary support (buccal shelf) to distribute the functional load to the most anatomically favorable location in a manner that reduces leverage effects.



**FIGURE 18-7** **A**, Maxillary molar occluded in a normal horizontal relationship to the opposing molar. **B**, The resultant position is lateral to the supporting crest of the residual ridge. This position is functionally unfavorable because of the potentially unstable leverage effects; however, stability can be improved by arranging simultaneous working and balancing contacts in the occlusal scheme

fabricate the restoration in centric relation; (2) centric relation and the planned intercuspal position do not coincide, but the planned intercuspal position is clearly defined and the decision has been made to fabricate the restoration in the planned intercuspal position; (3) centric relation and the planned intercuspal position do not coincide and the intercuspal position is not clearly defined; therefore the decision should be made to fabricate the restoration in centric relation; and (4) posterior teeth are not present in one or both arches, and the denture will be fabricated in centric relation.

Occlusal relationships may be established by using the most appropriate of the following methods to fit a particular partially edentulous situation.

### Direct Apposition of Casts

The first method is used when sufficient opposing teeth remain in contact to make the existing jaw relationship obvious, or when only a few teeth are to be replaced on short denture bases and no evidence of occlusal abnormalities is found. With this method, opposing casts may be occluded by hand. The occluded casts should be held in apposition with rigid supports attached with sticky wax to the bases of the casts until they are securely mounted in the articulator.

At best, this method can only perpetuate the existing occlusal vertical dimension and any existing occlusal disharmony present between the natural dentition. Occlusal analysis and the correction of any existing occlusal disharmony should precede the acceptance of such a jaw relation record. The limitations of such a method should be obvious. Yet, such a jaw relation record is better than an inaccurate interocclusal record between the remaining natural teeth. Unless a record is made that does not influence the closing path of the mandible because of its bulk and/or the consistency of the recording medium, direct apposition of opposing casts at least eliminates the possibility that the patient may have a faulty jaw relationship.

### Interocclusal Records with Posterior Teeth Remaining

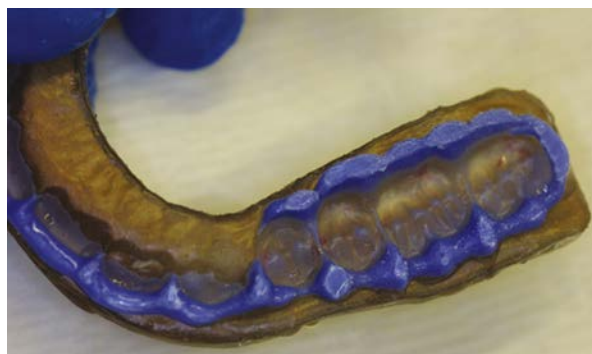A second method, which is a modification of the first, is used when sufficient natural teeth remain to support the removable partial denture (Kennedy Class III or IV) but the relation of opposing natural teeth does not permit the occluding of casts by hand. In such situations, jaw relations must be established as for fixed restorations with some type of interocclusal record.

The least accurate of these methods is the interocclusal wax record. The bulk, consistency, and accuracy of the wax will influence the successful recording of centric relation with an interocclusal wax record after chilling. Excess wax that contacts the mucosal surfaces may distort soft tissue, thereby preventing accurate seating of the wax record onto the stone casts. Distortion of wax during or after removal from the mouth may also interfere with accurate seating.

Therefore, a definite procedure for making interocclusal wax records is given as follows:

- A uniformly softened, metal-reinforced wafer of baseplate or set-up wax is placed between the teeth, and the patient is guided to close in centric relation (Figure 18-8). Correct closure should have been rehearsed before placement of the wax so that the patient will not hesitate or deviate in closing. The wax then is removed and immediately chilled thoroughly in room-temperature water. It should be replaced a second time to correct the distortion that results from chilling and then again chilled after removal.
- All excess wax should now be removed with a sharp knife. It is most important at this time that all wax that contacts mucosal surfaces be trimmed free of contact. The chilled wax record again should be replaced to make sure that no contact with soft tissue occurs.

A wax record can be further corrected with a freely flowing occlusal registration material, such as a metallic oxide paste, which is used as the final recording medium. In making such a corrected wax record, the opposing teeth (and also the patient's lips and the dentist's gloves) should first be lightly coated with petroleum jelly or a silicone preparation. The occlusal registration material then is mixed and applied to both sides of the metal-reinforced wax record. It is quickly placed, and the patient is assisted with closing in the rehearsed path, which will be guided by the previous wax record. After the occlusal registration material has set, the corrected wax record is removed and inspected for accuracy. Any excess projecting beyond the wax matrix should be removed with a sharp knife until only the registration of the cusp tips remains. Such a record should seat on accurate casts without discrepancy or interference and will provide an accurate interocclusal record. When an intact opposing arch is present, use of an opposing cast may not be necessary. Instead, a hard stone may be poured directly into the occlusal registration material record to serve as an opposing cast. However, although this may be an acceptable procedure in the



**FIGURE 18-8** A wax wafer softened in a water bath is used to register interocclusal position. Once removed and cooled, it is corrected with a more rigid and accurate registration material. Before it is used for mounting, the registration is trimmed to allow complete seating of the cast without distortion of the material.

fabrication of a unilateral fixed partial denture, the advantages of having casts properly oriented in a suitable articulator contraindicate the practice. The only exception to this occurs if the maxillary cast on which the removable partial denture is to be fabricated has been mounted previously with the aid of a facebow. In such an instance, an intact mandibular arch may be reproduced in stone by pouring a cast directly into the interocclusal record.

Some of the advantages of using a metallic oxide paste over wax as a recording medium for occlusal records include (1) uniformity of consistency; (2) ease of displacement on closure; (3) accuracy of occlusal surface reproduction; (4) dimensional stability; (5) the possibility of some modification in occlusal relationship after closure, if it is made before the material sets; and (6) reduced likelihood of distortion during mounting procedures.

Three important details to be observed when one uses such a material are as follows:

1. Make sure that the occlusion is satisfactory before making the interocclusal record.
2. Be sure that the casts are accurate reproductions of the teeth being recorded.
3. Trim the record with a sharp knife wherever it engages undercuts, soft tissue, or deep grooves.

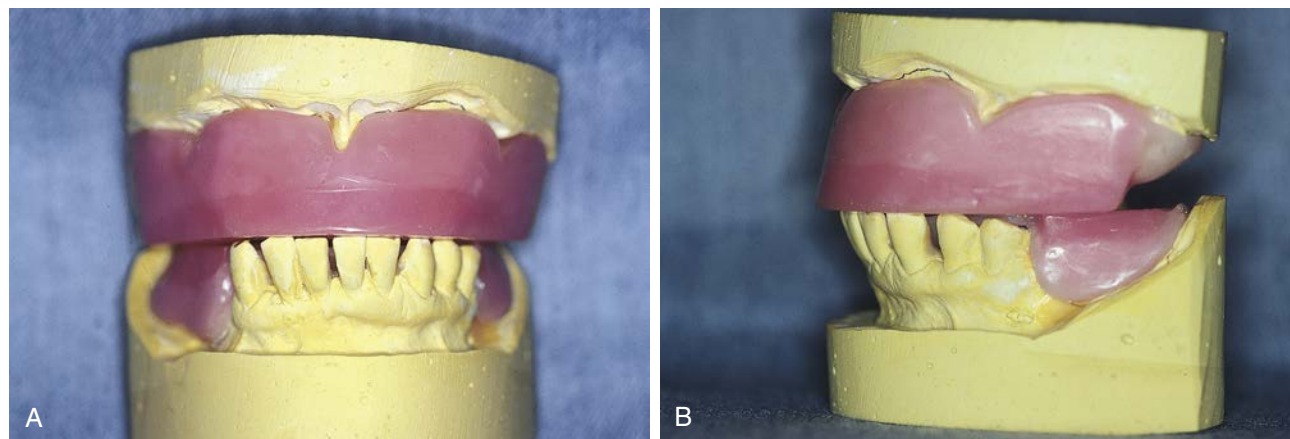
### Occlusal Relations Using Occlusion Rims on Record Bases

A third method is used when one or more distal extension areas are present, when a tooth-supported edentulous space is large, or when opposing teeth do not meet. In these instances, occlusion rims on accurate jaw relation record bases must be used. Simple wax records of edentulous areas are never acceptable. Any wax, however soft, will displace soft tissue. It is impossible to accurately seat such a wax record on a stone cast of the arch.

With this method, the recording proceeds much the same as with the second method, except that occlusion rims are substituted for missing teeth (Figure 18-9). It is essential that accurate bases be used to help support the occlusal relationship. Visible light-cured (VLC) bases may be adapted to the casts through the technique described in Chapter 16 for making impression trays. Utilizing the master cast, block out undesirable undercuts. However, do not add any wax for spacing. Paint a thin layer of the model release agent on the cast and the relief wax to aid in removal of the base from the cast after the designated time of polymerization recommended by the manufacturer. Carefully, adapt the VLC base material to the cast. Do not thin the material, and do not adapt the VLC base material over the remaining teeth. Process the base in the polymerization to set the material, and then separate the record base from the cast and remove any remaining blockout wax. Clean the base, apply the air barrier coating over the entire record base, and process (tissue side up) as directed.

Record bases may also be made entirely of autopolymerizing acrylic-resin. Those materials used in dough form lack sufficient accuracy for this purpose unless they are corrected by relining. An acrylic-resin base may be formed by sprinkling monomer and polymer into a shallow matrix of wax or clay after any undercuts are blocked out. If the matrix and blockout have been formed with care, interference with removal will not occur, and little trimming will be necessary. When the sprinkling method is used and sufficient time is allowed for progressive polymerization to occur, such bases are stable and accurate. Other record bases include the use of cast metal and compression molded or processed acrylic-resin bases for jaw relation records.

Relative to the third method, some mention must be made of the ridge on which the record bases are formed. If the prosthesis is to be tooth-supported or if a distal extension base is to be made on the anatomic ridge form, the bases will



**FIGURE 18-9** Relationship and distribution of remaining teeth for this patient requires that record bases and occlusion rims be used for accurate mounting of casts. **A**, Acrylic-resin record bases and hard baseplate wax occlusion rims for an edentulous maxilla and Kennedy Class I mandibular arch. These record bases are stable and were formed by sprinkling autopolymerizing acrylic-resin. **B**, Occlusion rims substitute for missing posterior teeth and provide an opportunity for posterior support when interocclusal records are made; this is most critical for the longer edentulous span on the mandibular right.

be made to fit that form of the residual ridge. But if a distal extension base is to be supported by the functional form of the residual ridge, it is necessary that the recording of jaw relations be deferred until the master cast has been corrected to that functional form.

Record bases must be as nearly identical as possible to the bases of the finished prosthesis. Jaw relation record bases are useless unless they are made on the same cast or a duplicate cast on which the denture will be processed, or are themselves the final denture bases. The latter may be a cast alloy or a processed acrylic-resin base.

Jaw relation records made by this method accomplish essentially the same purpose as the two previous methods. The fact that record bases are used to support edentulous areas does not alter the effect. In any method, the skill and care used by the dentist in making occlusal adjustments on the finished prosthesis will govern the accuracy of the resulting occlusion.

### Methods for Recording Centric Relation on Record Bases

Centric relation may be recorded in many ways when record bases are used. The least accurate is the use of softened wax occlusion rims. Modeling plastic occlusion rims, on the other hand, may be uniformly softened by flaming and tempering, resulting in a generally acceptable occlusal record. This method is time proved, and when competently done, it is equal in accuracy to any other method.

When wax occlusion rims are used, they should be reduced in height until just out of occlusal contact at the desired vertical dimension of occlusion. A single stop is then added to maintain their terminal position as a jaw relation record is made in some uniformly soft material, which sets to a hard state. Quick-setting impression plaster, bite registration paste, or autopolymerizing resin may be used. With any of these materials, opposing teeth must be lubricated to facilitate easy separation. Whatever the recording medium, it must permit normal closure into centric relation without resistance and must be transferable with accuracy to the casts for mounting purposes.

### Jaw Relation Records Made Entirely on Occlusion Rims

The fourth method is used when no occlusal contact occurs between the remaining natural teeth, such as when an opposing maxillary complete denture is to be made concurrently with a mandibular removable partial denture. It may also be used in those rare situations in which the few remaining teeth do not occlude and will not influence eccentric jaw movements. Jaw relation records are made entirely on occlusion rims when either arch has only anterior teeth present (Figure 18-10).

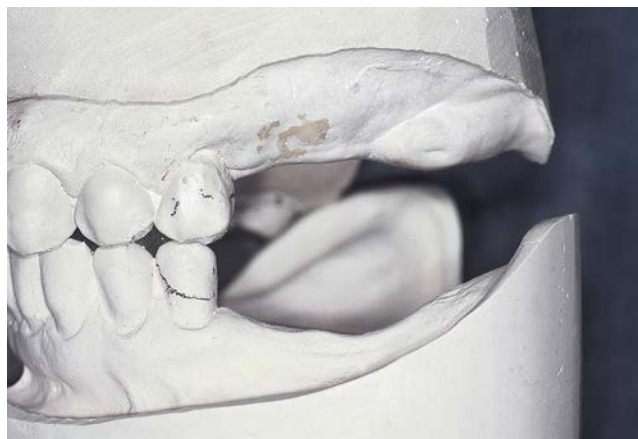In any of these situations, jaw relation records are made entirely on occlusion rims. The occlusion rims must be supported by accurate jaw relation record bases. Here, the choice of method for recording jaw relations is much the same as

that for complete dentures. Either some direct interocclusal method or a stylus tracing may be used. As with complete denture fabrication, the use of a facebow, the choice of articulator, the choice of method for recording jaw relations, and the use of eccentric positional records are optional, based on the training, ability, and desires of the individual dentist.

### Establishing Occlusion by the Recording of Occlusal Pathways

The fifth method of establishing occlusion on the removable partial denture is the registration of occlusal pathways and the use of an occluding template rather than a cast of the opposing arch. When a static jaw relation record is used, with or without eccentric articulatory movements, the prosthetically supplied teeth are arranged to occlude according to a specific concept of occlusion. On the other hand, when a functional occlusal record is used, the teeth are modified to accept every recorded eccentric jaw movement.

These movements are made more complicated by the influence of the remaining natural teeth. Occlusal harmony on complete dentures and in complete mouth rehabilitation may be obtained by the use of several different instruments and techniques. Schuyler has emphasized the importance of establishing first the anterior tooth relation and incisal guidance before proceeding with any complete oral rehabilitation. Others have shown the advantages of establishing canine guidance as a key to functional occlusion before proceeding with any functional registration against an opposing prosthetically restored arch. This is done on the theory that the canine teeth serve to guide the mandible during eccentric movements when the opposing teeth come into functional contact. It also has been pointed out that the canine teeth transmit periodontal proprioceptor impulses to the muscles of mastication and thus have an influence on mandibular movement even



**FIGURE 18-10** Opposing Kennedy Class I dental arches with remaining anterior teeth only. Recording of maxillomandibular relations was accomplished by using stable record bases and occlusion rims.

without actual contact guidance. However, as long as the occlusal surfaces of unrestored natural teeth remain in contact, as in many a partially dentulous mouth, these teeth will always provide the primary influence on mandibular movement. The degree of occlusal harmony that can be obtained on a fixed or removable restoration will depend on the occlusal harmony that exists between these teeth.

Regarding occlusion, Thompson has written, “Observing the occlusion with the teeth in static relations and then moving the mandible into various eccentric positions is not sufficient. A dynamic concept is necessary to produce an occlusion that is in functional harmony with the facial skeleton, the musculature, and the temporomandibular joints.”\* By adding “and with the remaining natural teeth,” the requirements for removable partial denture occlusion are more completely defined.

Some of the methods described previously may be applied to the fabrication of removable partial dentures in both arches simultaneously, whereas the registration of occlusal pathways necessitates that an opposing arch be intact or restored to the extent of planned treatment. A diagnostic wax-up of both maxillary and mandibular arches will facilitate visualization of the proposed mouth preparation and restorative procedures required to accommodate the planned occlusal scheme, correct orientation of the occlusal plane, correct arch form, and complete tooth modifications to accommodate the removable partial denture design—all at the desired vertical dimension of occlusion. If removable partial dentures are planned for both arches, a decision is necessary as to which denture is to be made first and which is to bear a functional occlusal relation to the opposing arch. Generally, the mandibular arch is restored first and the maxillary removable partial denture is occluded to that restored arch. If the maxillary arch is to be restored with a complete denture or a fixed partial denture or crowns, a full diagnostic wax-up must be done before occlusion is established on the opposing removable partial denture. If opposing fixed partial dentures or opposing occluding crowns are to be fabricated, it may be advantageous to develop the occlusion and fabricate them simultaneously to ensure optimal positioning, cuspal relationship, and functional integrity.

Regardless of the method used for recording jaw relations, when one arch is completely restored first, that arch is treated as an intact arch even though it is wholly or partially restored by prosthetic means. The dentist must consider at the time of treatment planning the possible advantages of establishing the final occlusion to an intact arch.

\*From Thompson JR: Temporomandibular disorders: diagnosis and dental treatment in the temporomandibular joint. In Sarnat B, editor: *The temporomandibular joint*, ed 2, Springfield, IL, 1964, Bernard G. Sarnat and Charles C. Thomas, pp 146–184.

### Step-by-Step Procedure for Registering Occlusal Pathways

After the framework has been adjusted to fit the mouth, the technique used for the registration of occlusal pathways is as follows:

1. Support the wax occlusion rim with a denture base that has the same degree of accuracy and stability as the finished denture base. Ideally, this would be the final denture base, which is one of the advantages of making the denture with a metal base. Otherwise, make a temporary base of VLC resin or sprinkled autopolymerizing acrylic-resin (see Figures 19-34 through 19-38), either of which is essentially identical to the final acrylic-resin base. In any distal extension removable partial denture, make this base on a cast that has been corrected to desired functional or supporting forms of the edentulous ridge. Place a film of hard sticky wax on the base before the wax occlusion rim is secured to it. The wax used for the occlusion rim should be hard enough to support biting stress and should be tough enough to resist fracture. Hard inlay wax has proved to be suitable for most patients. However, some individuals with weak musculature or tender mouths may have difficulty in reducing this wax. In such situations, use a slightly less hard wax. Make the occlusion rim wide enough to record all extremes of mandibular movement.
2. Inform the patient that the occlusion rim must be worn for 24 hours or longer. It should be worn constantly, including at nighttime, except for removal during meals. With wearing and biting into a hard wax occlusion rim, a record is made of all extremes of jaw movement. The wax occlusion rim must maintain positive contact with the opposing dentition in all excursions and must be left high enough to ensure that a record of the functional path of each cusp will be carved in wax. This record should include not only voluntary excursive movements but also involuntary movements and changes in jaw movement caused by changes in posture. Extreme jaw positions and habitual movements during sleep should also be recorded.

The occlusal paths, thus recorded, will represent each tooth in its three-dimensional aspect. Although the cast poured against this will resemble the opposing teeth, it will be wider than the teeth that carved it because it represents those teeth in all extremes of movement. The recording of occlusal paths in this manner eliminates entirely the need to reproduce mandibular movement on an instrument.

Instruct the patient in the removal and placement of the removable partial denture that supports the occlusion rim, and explain that by chewing in all directions, the wax will be carved by the opposing teeth. The opposing teeth must be cleaned occasionally of accumulated wax particles. It is necessary that the patient comprehend what is to be accomplished and

understand that both voluntary and involuntary movements must be recorded.

Before dismissing the patient, add or remove wax where indicated to provide continuous contact throughout the chewing range. To accomplish this, repeatedly warm the wax with a hot spatula and have the patient close and chew into the warmed wax rim with the opposing dentition, each time adding to any area that is deficient. Any area left unsupported by its flow under occlusal forces must be reinforced with additional wax. It is important that the wax rim be absolutely dry and free of saliva before additional wax is applied. Each addition of wax must be made homogeneous with the larger mass to prevent separation or fracture of the occlusion rim during the time it is being worn. Leave the wax occlusion rim from 1 to 3 mm high, depending on whether the occlusal vertical dimension is to be increased.

3. After 24 hours, the occlusal surface of the wax rim should show a continuous gloss, which indicates functional contact with the opposing teeth in all extremes of movement. Any areas deficient in contact should be added to at this time. The reasons for maintaining positive occlusal contact throughout the time the occlusion rim is being worn are that (a) all opposing teeth may be placed in function; (b) an opposing denture, if present, will become fully seated; and (c) vertical dimension of occlusion in the molar region will be increased; thus, the head of the mandibular condyle will be repositioned and temporomandibular tissue can return to a normal relationship.

If during this period the wax occlusion rim has not been reduced to natural tooth contact, warm it by directing air from the air syringe through a flame onto the surface of the wax. If the wax rim is held with the fingers during warming, a gradual softening process will result, rather than a melting of the surfaces already established. Repeatedly warm the occlusion rim and replace it in the mouth until the occlusal height has been reduced and lateral excursions have been recorded. At this time, use additional wax to support those areas left unsupported by the flow of wax to the buccal or lingual surfaces. Trim the areas obviously not involved, thus narrowing the occlusion rim as much as possible. Remove those areas projecting above the occlusal surface, which by their presence might limit functional movement.

When seating of the denture and changes in mandibular position have been accomplished by the previous period of wear, it is possible to complete the occlusal registration as an operator procedure. However, if all involuntary movements and those caused by changes in posture are to be recorded, the patient should again wear the occlusion rim for a period of time.

4. After a second 24- to 48-hour period of wear, the registration should be complete and acceptable. The remaining teeth that serve as vertical stops should be in

contact, and the occlusion rim should show an intact glossy surface representing each cusp in all extremes of movement.

Natural teeth formerly in contact will not necessarily be in contact on completion of the occlusal registration. Those teeth that have been depressed over a period of years, and those that have been moved to accommodate overclosure or mandibular rotation may not be in contact upon reestablishment of mandibular equilibrium. Such teeth may possibly return to occlusal contact in the future or may have to be restored to occlusal contact after initial placement of the denture. Because the mandibular position may have been changed during the process of occlusal registration, the cuspal relation of some of the natural teeth may be different from before. This fact must be recognized in determining the correct restored vertical dimension of occlusion.

Occlusion thus established on the removable partial denture will have more complete harmony with the opposing natural or artificial teeth than can be obtained by adjustments in the mouth alone, because occlusal adjustment to accommodate voluntary movement does not necessarily prevent occlusal disharmony in all postural positions or during periods of stress. Furthermore, occlusal adjustment in the mouth without occlusal analysis is limited by the dentist's ability to correctly interpret occlusal markings made intraorally, whether by articulating ribbon or by other means.

The registration of occlusal pathways has additional advantages. It makes obtaining jaw relations possible under actual working conditions, with the denture framework in its terminal position, the opposing teeth in function, and an opposing denture, if present, fully seated. In some instances, it also makes possible the recovery of the lost vertical dimension of occlusion, unilaterally or bilaterally, when overclosure or mandibular rotation has occurred.

The completed registration is now ready for conversion to an occluding template. This is usually done by boxing the occlusal registration with modeling clay after it has been resealed and secured onto the master or processing cast. Only the wax registration and areas for vertical stops are left exposed. It is then filled with a hard die stone to form an occluding template (see Chapter 19).

It is necessary that stone stops are used to maintain the vertical relation rather than relying on some adjustable part of the articulating instrument, which might be changed accidentally. Also, if stone stops are used and both the denture cast and the template are mounted before they are separated, a simple hinge instrument may be used.

## MATERIALS FOR ARTIFICIAL POSTERIOR TEETH

Contemporary acrylic-resin teeth are generally preferred to porcelain teeth, because they are more readily modified and are thought to more nearly resemble enamel in their abrasion potential against opposing teeth. Acrylic-resin teeth

with gold occlusal surfaces are preferably used in opposition to natural teeth restored with gold occlusal surfaces, whereas porcelain teeth are generally used in opposition to other porcelain teeth.

Acrylic-resin tooth surfaces, however, may in time become impregnated with abrasive particles, thereby becoming an abrasive substance themselves. This may explain why acrylic-resin teeth are sometimes capable of wearing opposing gold surfaces. An evaluation of occlusal contact or lack of contact, however, should be meticulously accomplished at each 6-month recall appointment, regardless of the choice of material for posterior tooth forms.

Although some controversy may continue with regard to the use of porcelain or acrylic-resin artificial teeth, there is broad agreement that narrow (reduced bucco-lingual) occlusal surfaces are desirable. Posterior teeth that will satisfy this requirement should be selected, and the use of tooth forms that have excessive bucco-lingual dimension should be avoided.

Acrylic-resin teeth are easily modified and readily lend themselves to construction of cast gold surfaces on their occlusal portions. A simple procedure for fabricating gold occlusal surfaces and attaching them to acrylic-resin teeth is described in Chapter 19 under posterior tooth forms.

### Arranging Teeth to an Occluding Template

The occlusal surface of the artificial teeth, porcelain or resin, must be modified to occlude with the template. With this method, they are actually only raw materials from which an occlusal surface is developed that are in harmony with an existing occlusal pattern. Therefore the teeth must be occluded too high and then modified to fit the template at the established vertical dimension of occlusion.

Teeth arranged to an occluding template ordinarily should be placed in the center of the functional range. Whenever possible, the teeth should be arranged buccolingually in the center of the template. When natural teeth have registered the functional occlusion, this may be considered the normal physiologic position of the artificial dentition, regardless of its relation to the residual ridge. On the other hand, if some artificial occlusion in the opposing arch has been recorded, such as that of an opposing denture, the teeth should be arranged in a favorable relation to their foundation, even if this means arranging them slightly buccally or lingually from the center of the template.

The teeth are usually arranged for intercuspation with the opposing teeth in a normal cuspal relationship. Whenever possible, the mesiobuccal cusp of the maxillary first molar should be located in relation to the buccal groove of the mandibular first molar and all other teeth arranged accordingly. With a functionally generated occlusion, however, it is not absolutely necessary that normal opposing tooth relationships be reestablished. In the first place, the opposing teeth in a dental arch that is not contiguous

may not be in normal alignment, and intercuspation may be difficult to accomplish. In the second place, the occlusal surfaces will need to be modified so that they will function favorably regardless of their anteroposterior position. Because cusps modified to fit an occlusal template will be in harmony with the opposing dentition, it is not necessary that the teeth themselves be arranged to conform to the usual concept of what constitutes a normal anteroposterior relationship.

### ESTABLISHING JAW RELATIONS FOR A MANDIBULAR REMOVABLE PARTIAL DENTURE OPPOSING A MAXILLARY COMPLETE DENTURE

It is common for a mandibular removable partial denture to be made to occlude with an opposing maxillary complete denture. The maxillary denture may already be present, or it may be made concurrently with the opposing removable partial denture. In any event, the establishment of jaw relations in this situation may be accomplished by one of several previously outlined methods.

If an existing maxillary complete denture is satisfactory and the occlusal plane is oriented to an acceptable anatomic, functional, and esthetic position (which rarely occurs), then the complete denture need not be replaced and the opposing arch is treated as an intact arch as though natural teeth were present. A facebow transfer is made of that arch, and the cast is mounted on the articulator. To accomplish this, a facebow record is made with the complete denture in place. After the facebow apparatus has been removed from the patient, the complete denture is removed and an irreversible hydrocolloid impression of the denture is made. When the impression material has set, the denture is removed, cleaned, and returned to the patient. A cast is formed in the impression and then is mounted on the articulator with the facebow record. Maxillomandibular relations may be recorded on accurate record bases attached to the mandibular removable partial denture framework with the use of a suitable recording medium. Centric relation is recorded and is transferred to the articulator. Eccentric records can then be made to program the articulator.

In rare instances, when the mandibular removable partial denture replaces all posterior teeth and the anterior teeth are noninterfering, a central bearing point tracer may be mounted in the palate of the maxillary denture, and centric relation recorded by means of an intraoral stylus tracing against a stable mandibular base. If a stylus jaw relation recording method is used, the stylus must be carefully removed from the denture and attached to the same palatal location of the stone cast that was transferred to the articulator via the facebow. The mandibular cast can then be oriented by way of the horizontal jaw relation record and attached to the articulator.

When an existing complete denture is opposing the arch on which a removable partial denture is fabricated,

a cast of the complete denture may be used during the fabrication procedures. However, when the occlusion is corrected after processing and the removable partial denture is finalized during initial placement, the complete denture should be retrieved and mounted on the articulator with a centric relation record at the desired vertical dimension of occlusion. This will ensure a more accurate cuspal relationship and will prevent abrasion of the cusp contacts that would occur if a stone cast of the denture is used. This procedure is completed when the patient is in the office so as not to deprive the patient of use of the existing complete denture.

If the relationship of the posterior teeth on the maxillary denture to the mandibular ridge is favorable and the complete denture is stable, jaw relations may be established by recording occlusal pathways in the mandibular arch just as for any opposing intact arch. The success of this method depends on the stability of the denture bases, the quality of tissue support, the relation of the opposing teeth to the mandibular ridge, and the interrelation of existing artificial and natural teeth.

More often than not, the existing maxillary complete denture will not be acceptable to use because of poor tooth position. The denture will have been made to occlude with malpositioned mandibular teeth, which have since been lost, or the teeth will have been arranged without consideration for the future occlusal relation with a mandibular removable partial denture. Too often, one sees a maxillary denture with posterior teeth arranged close to the residual ridge without regard for the interarch relationship and with an occlusal plane that is too low. Usually, however, a new maxillary denture must be made concurrently with the mandibular removable partial denture, and jaw relations may be established in one of two ways.

If the mandibular removable partial denture will be tooth supported (a Kennedy Class III arch accommodating a bilateral removable prosthesis), the mandibular arch is restored first. The same applies to a mandibular arch that is restored

with fixed partial dentures. In either situation, the mandibular arch is completely restored first, and jaw relations are established, as they would be to a full complement of opposing teeth. Thus, the maxillary complete denture is made to occlude with an intact arch.

On the other hand, as is more often the situation, the mandibular removable partial denture may have one or more distal extension bases. The situation then necessitates that the occlusion be established on both dentures simultaneously.

All mouth preparations and restorative procedures required to correctly orient the occlusal plane, correct the arch form, accommodate the desired occlusal scheme, and accommodate the removable partial denture design must be accomplished on the remaining natural teeth. In addition, all supporting *tissue* must be in an acceptable state of health before the final impression is made. After final impressions, which include the alter cast impression or the corrected cast impression, are made, the maxillary occlusion rim is contoured, occlusal vertical relation with the remaining lower teeth is established, and a facebow transfer of the maxillary arch is made. The maxillomandibular relations may be recorded by any of the several methods previously outlined and the articulator mounting completed. Occlusion may be established as for complete dentures, with care taken to establish a favorable tooth-to-ridge relationship in both arches, an optimum occlusal plane, and cuspal harmony between all occluding teeth.

After try-in, several methods may be used to complete the restorations. Both dentures may be processed concurrently and remounted for occlusal correction, or the removable partial denture may be processed first. After the dentures are completed and remounted, the teeth—still in wax on the complete denture—are adjusted to any discrepancies that are occurring.

Occlusal discrepancies created during processing must be corrected before the patient is permitted to use the denture(s). Methods by which these discrepancies may be corrected are discussed in Chapter 19.

# CHAPTER

# 19

## Laboratory Procedures

### CHAPTER OUTLINE

#### Duplicating a Stone Cast

- Duplicating Materials and Flasks
- Duplicating Procedure

#### Waxing the Removable Partial Denture Framework

- Forming the Wax Pattern for a Mandibular Class II Removable Partial Denture Framework
- Attaching Wrought-Wire Retainer Arms by Soldering
- Waxing Metal Bases

#### Spruing, Investing, Burnout, Casting, and Finishing of the Removable Partial Denture Framework

- Spruing
- Investing the Sprued Pattern
- Burnout
- Casting
- Removing the Casting from the Investment
- Finishing and Polishing

#### Making Record Bases

- Technique for Making a Sprinkled Acrylic-Resin Record Base

#### Occlusion Rims

#### Making a Stone Occlusal Template from a Functional Occlusal Record

#### Arranging Posterior Teeth to an Opposing Cast or Template

- Posterior Tooth Forms
- Arranging Teeth to an Occluding Surface

#### Types of Anterior Teeth

#### Waxing and Investing the Removable Partial Denture Before Processing Acrylic-Resin Bases

- Waxing the Removable Partial Denture Base
- Investing the Removable Partial Denture

#### Processing the Denture

#### Remounting and Occlusal Correction to an Occlusal Template

- Precautions to Be Taken in Remounting

#### Polishing the Denture


- Denture Borders
- Facial Surfaces

This chapter covers only those phases of dental laboratory procedures that are directly related to removable partial denture fabrication. Familiarity with laboratory procedures relative to making fixed restorations and complete dentures is presumed. Such information is available in numerous textbooks on those subjects and is not duplicated here. For example, the principles and techniques involved in the waxing, casting, and finishing of single inlays, crowns, and fixed partial dentures are adequately covered in lecture material and textbooks and in manuals available to the dental student, the dental laboratory technician, and the practicing dentist. Similarly, knowledge of the principles and techniques for mounting casts, articulating teeth, and waxing, processing, and polishing complete dentures is presumed as a necessary background for the laboratory phases of removable partial denture fabrication. Therefore this chapter is directed specifically toward the laboratory procedures involved in the fabrication of a removable partial denture.

### DUPLICATING A STONE CAST

A stone cast may be duplicated for several purposes. One is the duplication in stone of the original or corrected master cast to preserve the original. One use of such a cast is for fitting a removable partial denture framework without danger of fracture or abrading the surface of the original master cast. Another use might be for processing a temporary prosthesis where wax relief and blockout on the original cast allow production of a duplicate, which following processing will make insertion of the prosthesis easier.

Another purpose of duplicating a cast is to allow an investment cast to be formed for framework fabrication. Careful preparation of the master cast for production of this investment cast involves consideration of the defined path of insertion, heights of contour, and retentive and stabilization areas designed into the mouth preparations. The framework produced should be carefully evaluated on the cast for fit, just as a fixed partial denture is evaluated on a working cast with dies (Figure 19-1).



**FIGURE 19-1** **A**, Framework returned from the laboratory with the master cast. **B**, Replacement on the cast reveals areas of contact that can erode the cast surface. Careful fitting to the cast allows determination of potential framework adjustment regions before fitting in the mouth. If the framework is indiscriminately finished in the laboratory or before intraoral placement, critical tooth contact regions may be lost, resulting in a poorly retained and stabilized prosthesis. Most often, such an overly adjusted framework is poorly stabilized, not poorly retained.

Blockout should be accomplished on the master cast before an investment cast is made. On this investment cast, the wax or plastic pattern is formed. The use of preformed plastic patterns eliminates some of the danger of damaging the surface of the investment cast in the process of forming the pattern. With freehand waxing, considerable care must be taken not to score or abrade the investment cast. The metal framework is ultimately cast against its surface, and the finished casting and the original cast are then returned to the dentist after all fitting has been completed on the duplicating cast.

### Duplicating Materials and Flasks

Duplicating materials include both colloidal and silicone materials. Colloidal materials are made fluid by heating and return to a gel while cooling. The cast to be duplicated must be placed in the bottom of a suitable flask, called a *duplicating flask*. A duplicating flask should contain the fluid material to facilitate its cooling, to support the mold while it is being filled with the cast material, and to facilitate removal of the cast from the mold without permanent deformation or damage to the mold. Numerous duplicating flasks are available on the market.

The technique for duplicating is the same for any cast, whether or not blockout is present. However, if wax or clay blockout is present, the temperature of the duplicating material must not be any higher than that recommended by the manufacturer, to prevent melting and distortion of the blockout material.

Ordinary baseplate wax may be used for paralleled blockout and ledges, but care must be taken that the temperature of the duplicating material is not too high because it will then melt the wax. The use of prepared blockout material, such as Ney blockout wax or Wills undercut material, may be preferred.



**FIGURE 19-2** Duplicating material with a vacuum curing unit in the background, which is used to ensure a dense mold.

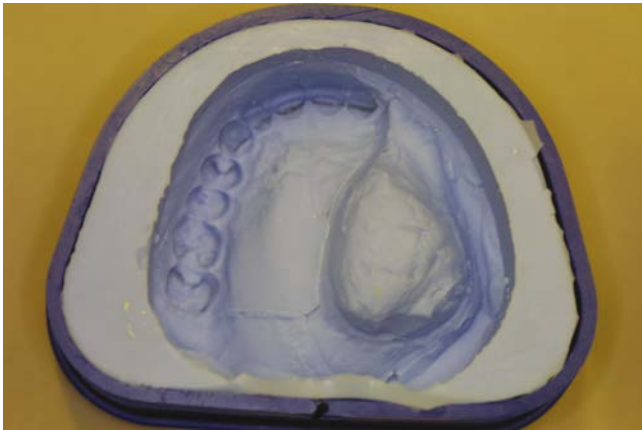### Duplicating Procedure

The equipment needed and the steps required for duplication using a silicone material are described in [Figures 19-2 through 19-6](#).

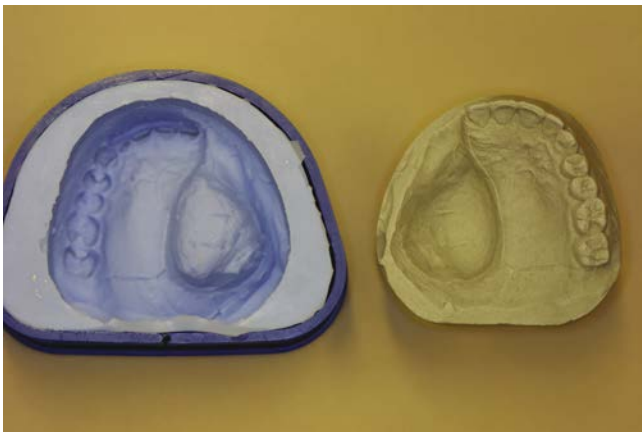## WAXING THE REMOVABLE PARTIAL DENTURE FRAMEWORK

When preformed plastic patterns are used ([Figure 19-7](#)), parts of the denture framework must be waxed freehand to prevent excessive bulk and to create the desired contours for a satisfactory custom-made removable partial denture framework ([Figure 19-8](#)).

Although most dentists do not fabricate their own removable partial denture castings, it is essential that they have an understanding of the dental laboratory procedures involved.



**FIGURE 19-3** Duplicating mold following removal of the relieved and blockout cast.



**FIGURE 19-4** Refractory cast (*right*) following removal from the duplication mold (*left*). This cast incorporates all the features of the relieved and blockout master cast generated from the clinical framework impression.

This enables them to design the removable partial denture framework, complete a laboratory work authorization that communicates the desired design and authorizes its fabrication, and evaluate the quality of the framework (Figure 19-9). Understanding and evaluation of the key features required in a completed removable partial denture framework ensure the patient of a chance to function comfortably with the finished product (Figure 19-10). The contrary is also true.

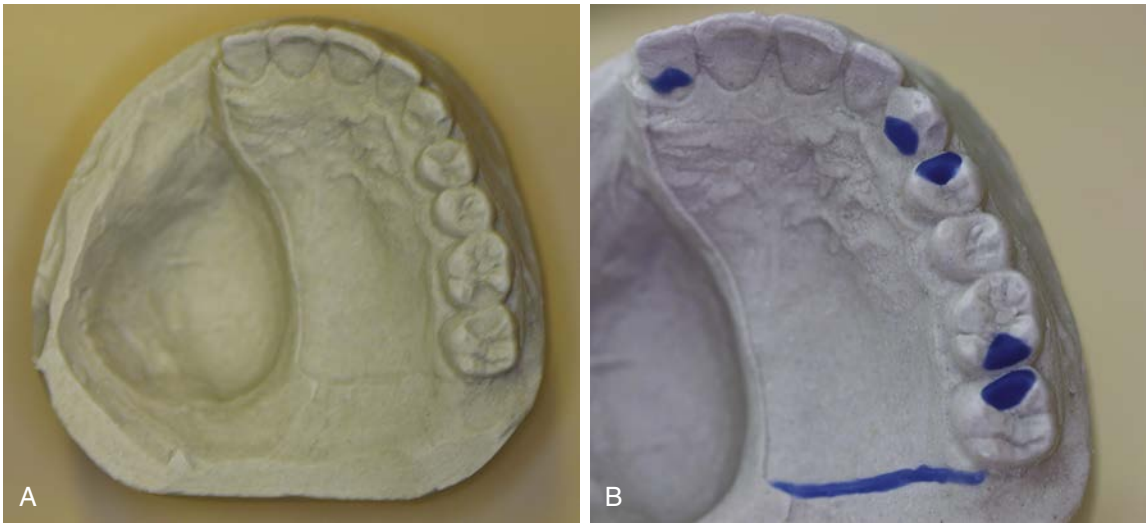
**Forming the Wax Pattern for a Mandibular Class II Removable Partial Denture Framework**

Examples that illustrate many of the essentials of waxing a removable partial denture framework are presented in Figures 19-11 through 19-20. This exercise includes the waxing of three types of direct retainers (circumferential, combination, and bar type), a mandibular lingual bar major connector, a maxillary anterior-posterior palatal strap major connector, both distal extension and tooth-bound modification spaces, and adaptation of round, 18-gauge, wrought-wire retentive arms for combination-type direct retainers.

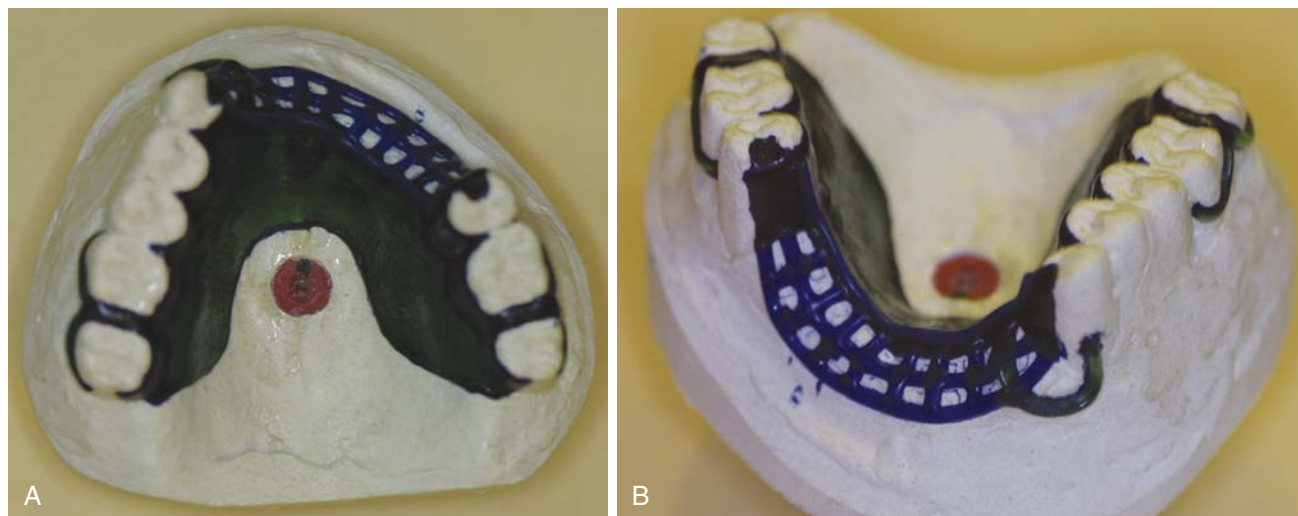
**Attaching Wrought-Wire Retainer Arms by Soldering**

Wrought-wire retainers may be attached to a removable partial denture framework after it has been cast and finished (Figures 19-21 and 19-22). The soldering procedure may be accomplished by electric soldering or by a direct-heat method with an oxygen-gas flame. With either method, care must be taken to use compatible alloys, appropriate solder, and flux in conjunction with the careful application of controlled heat.


Students are encouraged to review the Chapter 13 discussion of the selection of metal alloys to enhance their understanding of the properties of solder, flux, the effects of heat on metal alloys, and the necessity for quality control in soldering procedures.



**FIGURE 19-5** Close up of the refractory cast (A) with initial wax added to rests and the posterior bead line (B).



**FIGURE 19-6** Example of a completed maxillary waxed framework on a refractory cast with the sprue access positioned. **A**, From occlusal. **B**, From anterior.



**FIGURE 19-7** Preformed plastic patterns are available in many shapes and sizes for clasps, for minor connectors connecting to teeth, or for distal extension bases, bars, mesh, and palatal coverage. Because they are made of soft plastic material, they tend to stretch on removal from their backing. Therefore, care must be exercised when one is removing patterns. Their use generally requires that tacky liquid be applied first to the investment cast at their area of placement.

### Waxing Metal Bases

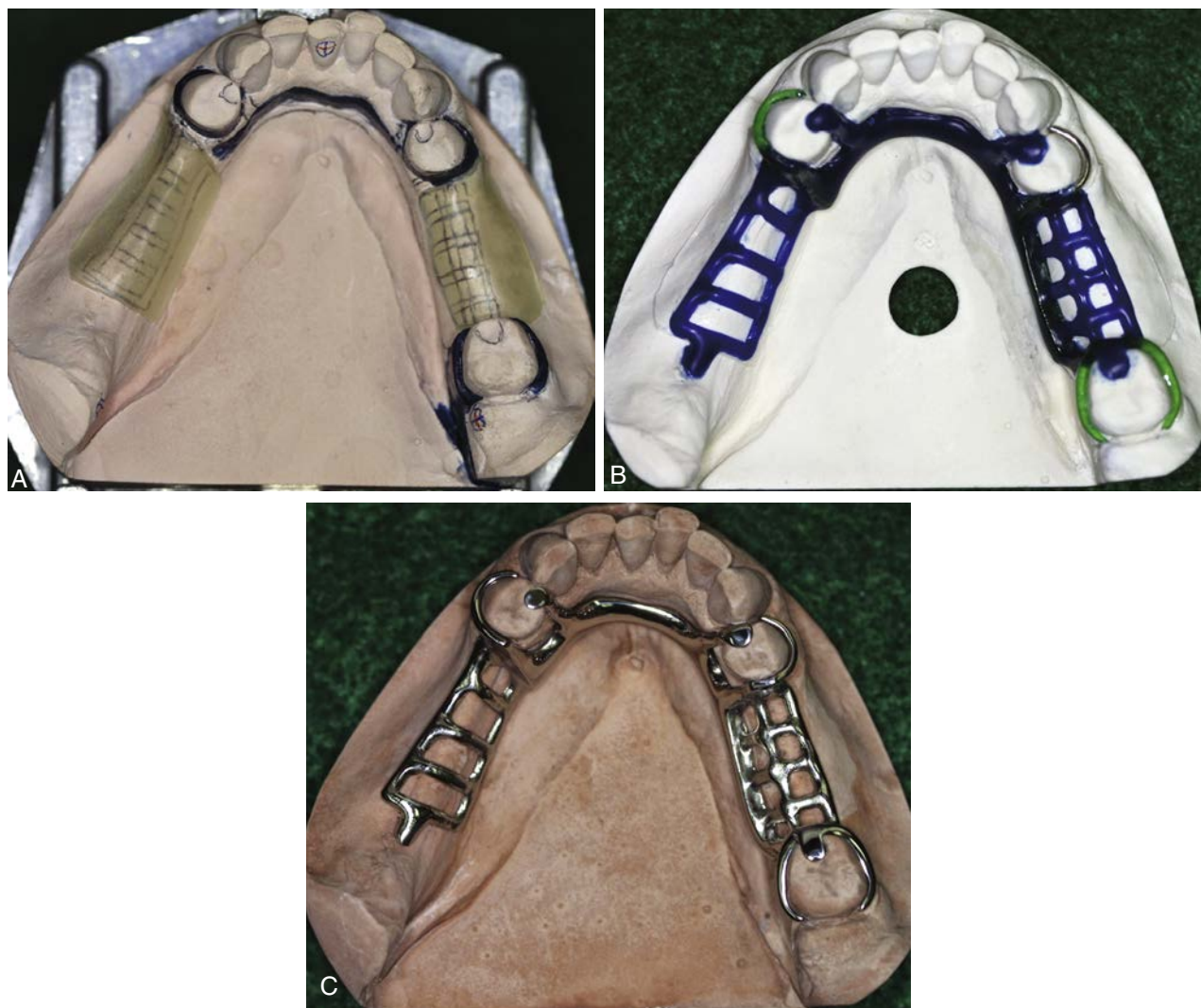A technique for forming the retentive framework for the attachment of acrylic-resin bases has been given. Two basic types of metal bases may be used instead of the resin base. The advantages of cast metal bases in preference to acrylic-resin bases have been discussed in Chapter 9. The type of base to be used must be determined before block-out and duplication so that the relief over each edentulous ridge may be provided or eliminated as required.

For an acrylic-resin base, relief for the retentive frame must be provided. No relief over the residual ridge is used for a complete metal base. For a partial metal base, the

junction between metal and acrylic-resin must be clearly defined by trimming the relief along a definite, previously determined line.

One type of metal base is the complete base with a metal border to which tube teeth, cast copings, or an acrylic-resin superstructure may be attached. If a porcelain or plastic tube or grooved teeth are used, they must be positioned first and the pattern waxed around them to form a coping. The teeth are then attached to the metal base by cementation or, with the use of resin teeth, are attached with additional acrylic-resin under pressure, a so-called pressed-on method of attaching acrylic-resin teeth to a metal base. Another method of attaching teeth is to wax the base to form a coping for each tooth, either by carving recesses in the wax or by waxing around artificial teeth. Rather than attaching a stock tooth, the full tooth may be waxed into occlusion, the base invested, and the wax patterns replaced with heat-polymerized acrylic-resin. This method permits some variation in the dimension and form of the supplied teeth that is not possible with stock teeth. It is particularly applicable to abnormally long or short spaces or when a stock tooth of desired width is not available. With modern cross-linked acrylic-resins, such processed teeth are fairly durable; however, the addition of gold occlusal surfaces is an option.

When artificial teeth are to be arranged to occlude with an opposing cast or an opposing template, the metal base must be formed for attachment of the tissue-colored denture resin supporting the teeth. This is the most common method of attaching teeth to a metal base. The wax pattern for the base is formed from one thickness of 24-gauge casting wax, which is then reinforced at the border and forms the retention of the acrylic-resin superstructure. Because metal borders are more difficult to adjust than acrylic-resin, they are usually made somewhat short of the area normally covered with an acrylic-resin base. Also, because



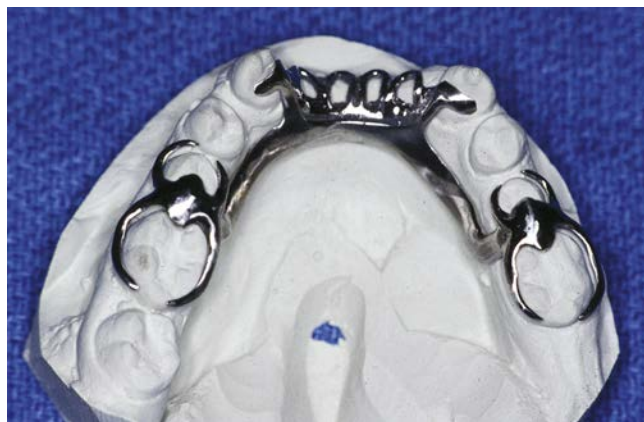**FIGURE 19-8** Three steps are involved in making a denture framework by using relief, blockout ledges, and ready-made pattern forms. **A**, Master cast with relief, blockout of undercuts at posterior right and anterior lingual regions, and shaped blockout ledges for location of retentive and nonretentive clasp arms. **B**, Completed pattern using lingual bar major connector pattern, plastic clasp forms resting on investment ledges, wrought wire, and open retention mesh. **C**, Finished casting returned to master cast.

border thickness adds objectionable weight to the denture, it is made with only a slight border roll. This is one disadvantage of the complete metal base, because the border accuracy of the impression registration cannot be used to fullest advantage, and contouring of facial and lingual surfaces cannot be as effective as with an acrylic-resin base, in which added bulk can sometimes be used to advantage.

The border is first penciled lightly on the investment cast, and then the 24-gauge sheet casting wax is smoothly adapted. Considerable care must be taken not to stretch and thin the sheet wax in adapting it to the cast. To prevent wrinkling, the wax should be adapted in at least two longitudinal pieces and joined and sealed together at the ridge crest. The wax is then trimmed along the penciled outline with a warm, dull instrument to prevent scoring of the investment cast.

A single piece of 14-gauge round wax is now adapted around the border over the sheet wax. With a hot spatula, the round wax must be sealed to the cast along its outer border. Sufficient wax is flowed onto the round wax to blend it smoothly into the sheet wax, thus completing a border roll. The inner half of the round wax form remains untouched. Wax is added when needed to facilitate carving without trimming the original 24-gauge thickness. The result should be a rounded border that blends smoothly into the sheet wax.

The boxing for the resin, which will in turn support the artificial teeth, is now added, again with 14-gauge round wax. The proposed outline for the boxing is identified by lightly scoring the sheet wax. On this scored line, the 14-gauge round wax is adapted, thus forming the outline of the boxing.

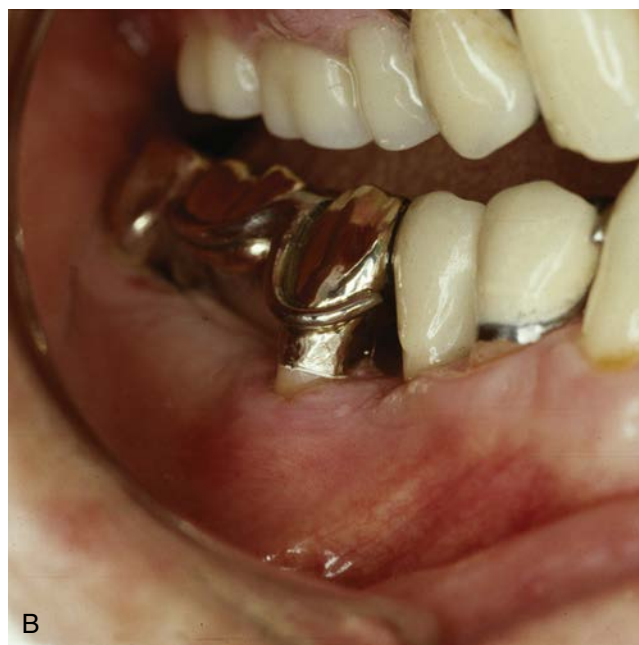
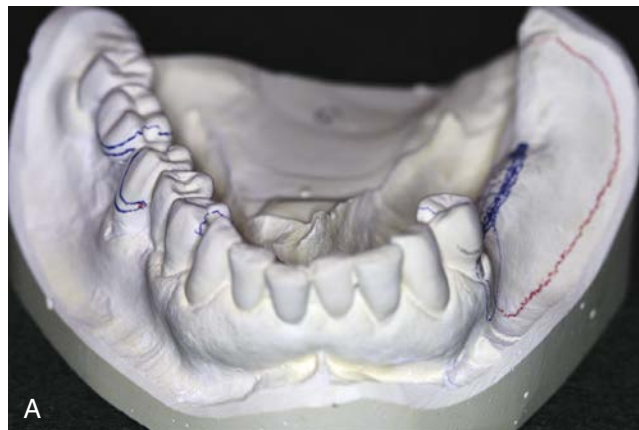
**FIGURE 19-9** Evaluation of the framework by the clinician is as important for removable partial denture frameworks as it is for implant and/or fixed partial denture castings. Careful scrutiny of attention to detail in following the design specifications is necessary, as is evaluation of the fit of the framework to the cast. On this cast, initial seating of the framework reveals interference with complete seating bilaterally from the embrasure clasps. Only minor adjustment should be required to completely seat the framework. If major adjustment is needed, or if after complete seating of the framework the clasp assemblies do not contact the teeth as prescribed, the framework should be remade.

With additional wax, the ditch between the sheet wax and the outer border of the round wax is filled in and blended smoothly onto the sheet wax. This is done in the same manner as the border, with sufficient wax added to allow for smoothing and carving. As was mentioned previously, the pattern should not be flamed or polished with a cloth. Instead the pattern must be smoothed by carving.

The result thus far should be a pattern reinforced at the border and at the boxing and slightly concave in between, with some of the original sheet wax exposed. The inside of the boxing is not sealed to the sheet wax, thus leaving a slight undercut for the attachment of the acrylic-resin. With a sharp blade, the margins of the boxing are then carved to a knife-edge finishing line. With the backside of the large end of the No. 7 wax spatula, this margin may be lifted slightly, further deepening the undercut beneath the finishing line.

In addition to the undercut finishing line, retention spurs, loops, or nailheads are added for retention of the acrylic-resin to be added later. Spurs are usually made of 18-gauge or smaller round wax attached at one end only at random acute angles to the sheet wax. Loops are small-gauge round (wax, resin, or metal) circles attached vertically or horizontally with space beneath for the acrylic-resin attachment. Nailheads are made of short pieces of 18-gauge round wax attached vertically to the sheet wax, with the head flattened by a slightly warmed spatula. Any method of providing retention is acceptable if it permits positive attachment of the acrylic-resin and will not interfere with the placement of artificial teeth.

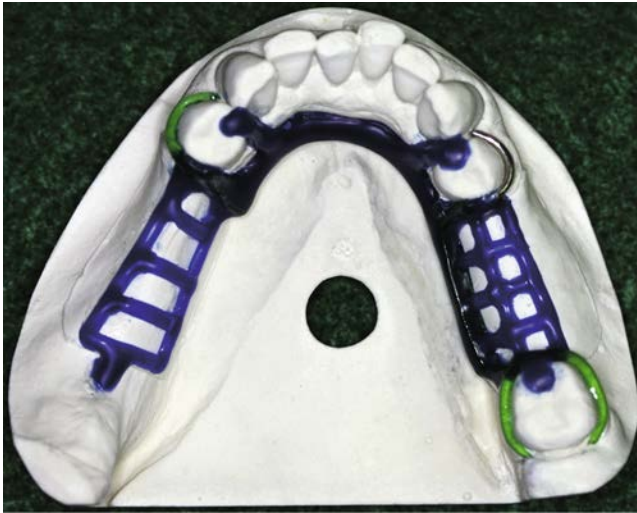

**FIGURE 19-10** **A**, Design of a mandibular removable partial denture framework is outlined on the master cast for the technician to follow in waxing and casting the framework. **B**, Cast framework as returned from the laboratory is evaluated intraorally, revealing sufficiently accurate adaptation and design identical to the embrasure clasp and mesio-occlusal rest #28, as shown on the design cast in **A**.

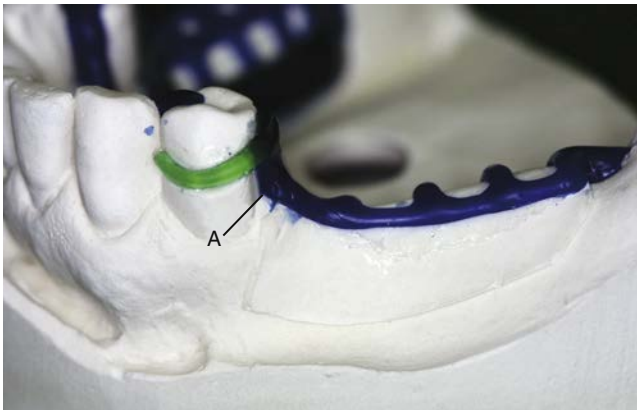A metal base waxed as described provides optimum contours with a minimum of bulk and weight and with adequate provision for the attachment of artificial teeth to the metal base. If properly designed, the more visible portions of the metal base will be covered with the acrylic-resin supporting the supplied teeth.

### SPRUIING, INVESTING, BURNOUT, CASTING, AND FINISHING OF THE REMOVABLE PARTIAL DENTURE FRAMEWORK

Brumfield has listed factors that influence the excellence of a dental casting ([Box 19-1](#)).



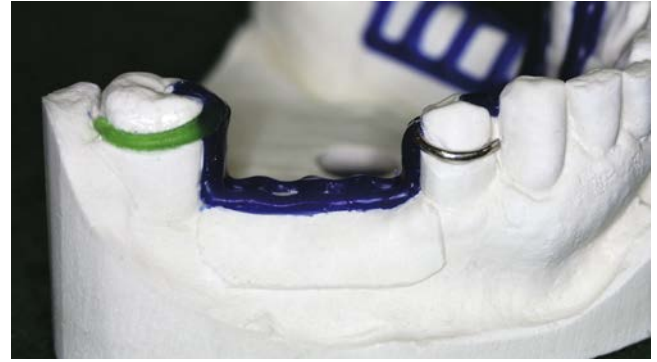**FIGURE 19-11** Occlusal view of mandibular Kennedy Class I, modification 1 wax pattern on a refractory cast. The lingual bar major connector joins three clasp assemblies (rest, proximal plate, and Akers [RPA] clasp, wrought wire, and cast circumferential).



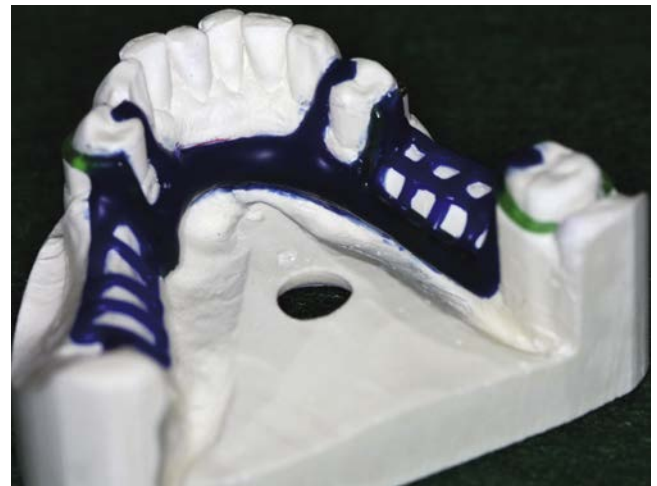**FIGURE 19-12** Buccal view of left side of the pattern shown in Figure 19-11. A tapered retainer clasp pattern is placed on the refractory cast ledge produced by duplication of shaped blockout ledges. The cast illustrates relief provided beneath the minor connector, which retains the denture base resin. The tissue index at the gingival region of the proximal plate will provide an easily identifiable finish line for resin finishing and future trimming of altered cast impression.

### Spruing

Brumfield described the function of sprues as follows: The sprue channel is the opening that leads from the crucible to the cavity in which the framework is to be cast. Sprues have the purpose of leading the molten metal from the crucible into the mold cavity. For this purpose, they should be large enough to accommodate the entering stream and of the proper shape to lead the metal into the mold cavity as quickly as possible but with the least amount of turbulence. Sprues have the further purpose of providing a reservoir of molten metal from which the casting may draw during solidification, thus preventing porosity caused by shrinkage.



**FIGURE 19-13** Buccal view of modification space of the pattern shown in Figure 19-11. A wrought-wire clasp is contoured at the anterior extent of the modification space. Such a retainer will not overly stress the tooth if opposite denture base movement causes rotation across the fulcrum (see Figure 19-11, occlusal rests at #21 and #31). A tapered cast circumferential clasp follows the shaped ledge to a distal buccal 0.01-inch undercut. Both proximal plates have been waxed with sufficient bulk to provide a complete casting. If thickness presents a problem with tooth placement, some finishing can be accomplished at a later time.



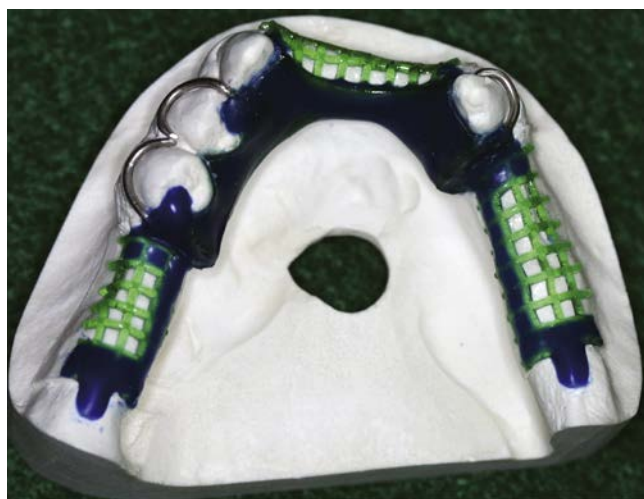**FIGURE 19-14** Lingual view of the pattern shown in Figure 19-11. The lingual bar major connector rigidly connects components cross-arch. The minor connector for resin retention on the left has buccal and lingual struts to allow unimpeded tooth placement. The tapered proximal plate on the right (tooth #28) is thicker on the lingual and thinner on the buccal, to allow close placement of the buccal surface of the denture tooth to #28. The finish line of the modification space is positioned below adjacent tooth gingival margins to allow normal lingual contouring of the resin matrix.

Spruing of the cast may be roughly summarized in the following three general rules:

1. Sprues should be large enough that the molten metal in them will not solidify until after the metal in the casting proper has frozen (8- to 12-gauge round wax is usually used for multiple spruing of removable partial denture castings).

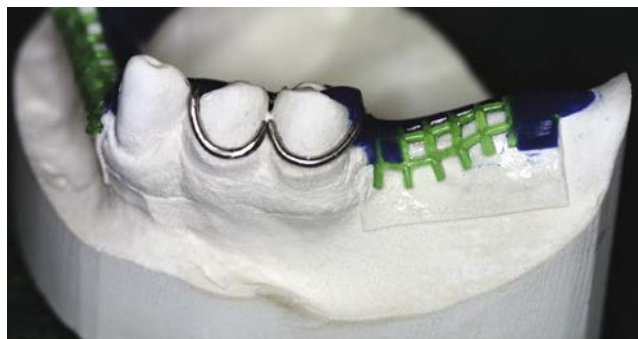

**FIGURE 19-15** Another example of a wax pattern for a mandibular framework. A wrought wire has been adapted to tooth #27. The clasp demonstrates an appropriate circlet shape, allowing maximum length. The circlet shape also allows the undercut to be approached from below; this improves retention—push retention is more efficient than pull retention. Ridge relief is evident beneath the resin minor connector, and the proximal plate housing the wire has been waxed with bulk to facilitate casting. The plate may require adjustment at a later time.



**FIGURE 19-16** Same pattern as shown in Figure 19-15. Includes a lingual plate major connector design. The external finishing line at the anterior modification space is lingual to the anticipated tooth and resin position, allowing a natural contour to be developed in the completed prosthesis. The posterior denture base minor connector patterns have been reinforced with additional wax to add stiffness at the junction with the proximal plate and major connector. Because of the potential for repeated flexure in this region under function, such reinforcement is critical to long-term success with patterns such as this. Because the wrought-wire retainers are not cast, it is important that they be contoured to contact the teeth as accurately as possible, as shown.

2. Sprues should lead into the mold cavity as directly as possible and still permit a configuration that will induce a minimal amount of turbulence in the stream of molten metal.



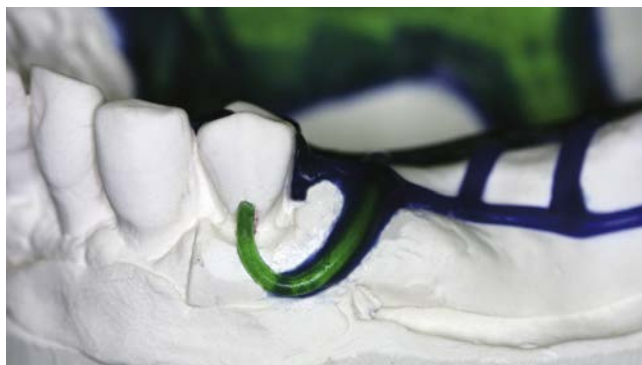**FIGURE 19-17** Buccal view of the pattern shown in Figure 19-16. Double wrought wires are contoured to follow the ledges, the tissue stop at the posterior of the ridge relief is shown, and an occlusal rest distal of #20 will require finishing following completion of casting.



**FIGURE 19-18** Occlusal view of the maxillary refractory cast with a wax pattern. An anatomic replica has been used to develop an anterior-posterior palatal strap major connector with beading evident at the anterior, posterior, and internal edges. Bilateral, tapered I-bar retainers have been waxed as extensions of the resin-retaining minor connectors, and double rests were incorporated into the design on each side.

3. Sprues should leave the crucible from a common point and be attached to the wax pattern at its bulkier sections, that is, no thin sections of casting should intervene between two bulky, unsprued portions.

The configuration of the sprues, from their point of attachment at the crucible until they reach the mold cavity, may be influential in reducing turbulence. One of the more important sources of difficulty in casting is the




**FIGURE 19-19** Buccal view of right I-bar shown in Figure 19-18. The tissue index is demonstrated gingival to the proximal plate, tissue relief is provided beneath the denture base minor connector, and the I-bar shows a taper as it approaches the mid-buccal 0.01-inch undercut.



**FIGURE 19-20** Buccal view of I-bar opposite to that shown in Figure 19-19. Many of the same features seen in Figure 19-19 are evident in this example. The tissue stop distal to the ridge relief is shown and the palatal external finishing line continues distal to the junction of the hard and soft palate (which is the terminus of the posterior palatal strap).

entrapment of gases in the mold cavity before they have a chance to escape. If the sprue channels contain sharp right-angle turns, great turbulence is induced, which is calculated to entrap such gases and so lead to faulty castings. Sprue channels should make long radii and easy turns, and should enter the mold cavity from a direction designed to prevent splashing at this point.

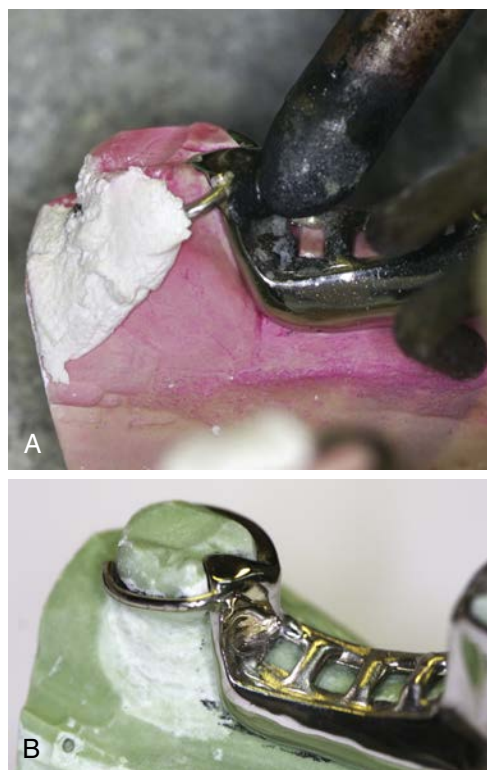
As was previously stated, the sprues should be attached to the bulky points of the mold pattern. If two bulky points exist with a thin section between them, each of the bulky spots should be sprued. The points of attachment should be flared out and local constrictions avoided. If this practice is followed, the sprue, which is bulky enough to freeze after the case framework has frozen, will continue to feed molten metal to the framework until it has entirely solidified. The intent is to provide sound metal in the casting proper with all shrinkage porosity forced into the sprue rod, which is later discarded.



**FIGURE 19-21** Wrought wire can be soldered to cast frameworks as an alternative method to incorporation in the wax pattern and casting procedure. Electric soldering is a common method for soldering and does not require heating of the entire framework. Following preparation of the minor connector where the wire will be soldered, an 18-gauge, round, wrought-wire clasp is carefully adapted and then is secured to the framework and the duplicate stone cast with the use of refractory investment. In this situation, a distolingual molar undercut will be used bilaterally for retention. The flux is placed at the proximal plate, followed by placement of sufficient solder, and the electric heat element tip is placed into contact with the solder while the frame is grounded at another location.

The laboratory procedure for multiple spruing is essentially the same for all mandibular and maxillary castings, except those with a palatal plate. Typical examples are illustrated in Figures 19-23 and 19-24.

Two basic types of sprues are used: multiple and single. Most removable partial denture castings require multiple spruing, with the use of 8- to 12-gauge round wax shapes for main sprues and 12- to 18-gauge round wax shapes for auxiliary sprues. Occasionally, however, a single sprue is preferred for cast palates and cast metal bases for the mandibular arch when these are used as complete denture bases. With removable partial dentures, the use of a single sprue is limited to those maxillary frameworks in which—because of the presence of a palatal plate—it is impossible to locate multiple sprues centrally. In such situations, the single sprue may be used advantageously. A single sprue must be attached to the wax pattern so that the direction of flow of the molten metal will be parallel to the long axis of the single sprue. In some instances, the investment cast may have to be cut away anteriorly to make room for the attachment of the sprue; in others, the sprue may be attached posteriorly. One disadvantage of using a single sprue for large castings is that an extra-long investment ring must be used.



**FIGURE 19-22** **A**, An electric soldering technique has been used to solder the wrought wire. The solder has flowed into the space between the framework and the wire as well as around the wire to ensure its secure attachment to the framework. **B**, Finished and polished wrought-wire retainer.

Some important points to remember in multiple spruing are as follows:

1. Use a few sprues of large diameter rather than several smaller sprues.
2. Keep all sprues as short and direct as possible.
3. Avoid abrupt changes in direction; avoid T-shaped junctions as much as possible.
4. Reinforce all junctions with additional wax to prevent constrictions in the sprue channel and to prevent V-shaped sections of investment that might break away and be carried into the casting.

### Investing the Sprued Pattern

The investment for a removable partial denture casting consists of two parts: the investment cast on which the pattern is formed, and the outer investment surrounding the cast and pattern (see Figure 19-41). The latter is confined within a metal ring, which may or may not be removed after the outer investment has set. If the metal ring is not to be removed, it must be lined with a layer of cellulose, asbestos substitute, or ceramic fiber paper to allow for both setting and thermal expansion of the mold in all directions. The investment must conform accurately to the shape of the pattern and must preserve the configuration of the

### Box 19-1

#### FACTORS THAT INFLUENCE THE EXCELLENCE OF A DENTAL CASTING

1. Care and accuracy with which the cast is reproduced
2. Intelligence with which the framework is designed and proportioned
3. Care and cleanliness in waxing up the cast
4. Consideration of the expansion of the wax caused by temperature
5. Size, length, configuration, points of attachment, and manner of attachment of the sprues
6. Choice of investment
7. Location of the pattern in the mold
8. Mixing water: Amount, temperature, and impurities
9. Spatulation of the investment during mixing
10. Restraint offered to expansion of the investment caused by the investment ring
11. Setting time
12. Burnout temperature and time
13. Method of casting
14. Gases: Adhered, entrapped, and absorbed
15. Force used in throwing the metal into the mold
16. Shrinkage on cooling
17. Removal from the investment after casting
18. Scrubbing, pickling, and so on
19. Polishing and finishing
20. Heat handling



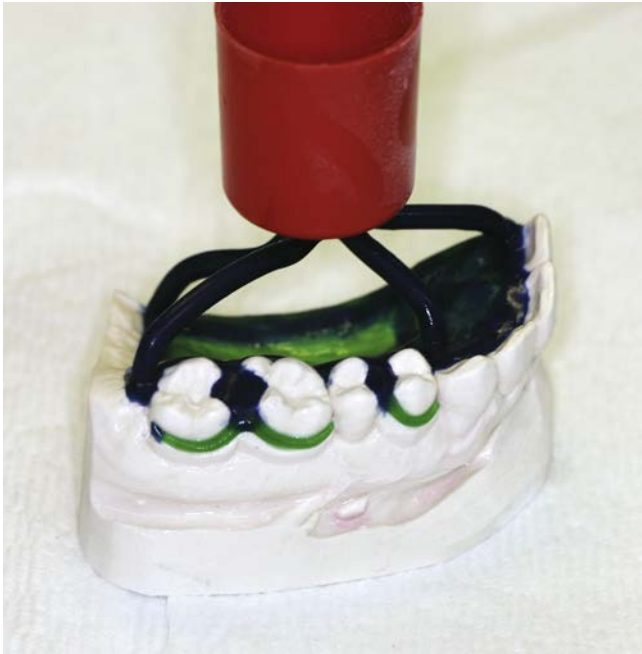**FIGURE 19-23** Mandibular cast framework with sprue intact, showing three 8-gauge sprues attached to the lingual bar. If one is concerned about completely filling distal extension base minor connectors, 12-gauge sprues can be attached to the minor connector.

pattern as a cavity after the pattern itself has been eliminated through vaporization and oxidation. Brumfield has listed the purposes of the investment as follows:

1. It provides the strength necessary to hold the forces exerted by the entering stream of molten metal until this metal has solidified into the form of the pattern.
2. It provides a smooth surface for the mold cavity so that the final casting will require as little finishing as possible; in some situations, a deoxidizing agent is used to keep surfaces bright.



**FIGURE 19-24** For a maxillary framework, multiple 8-gauge sprues or a single main sprue located posteriorly can be used. When a single main sprue is used, additional sprues can feed critical regions for casting completeness.

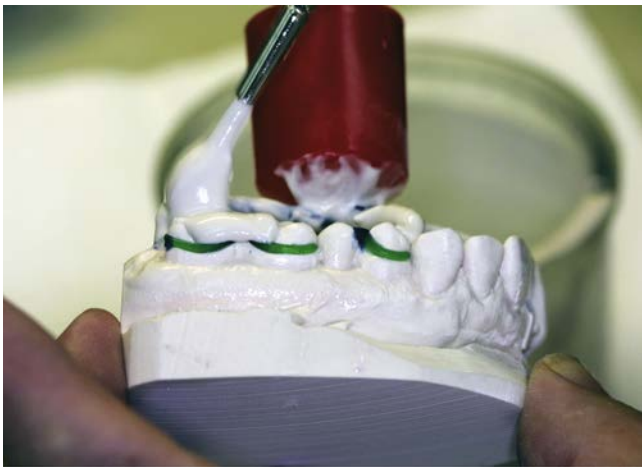

**FIGURE 19-25** Wax pattern sprued and ready to invest.

3. It provides an avenue of escape for most of the gases entrapped in the mold cavity by the entering stream of molten metal.
4. It, together with other factors, provides necessary compensation for the dimensional changes of the alloy\* from the molten to the solid, cold state.

The investment for casting gold alloys is a plaster-bound silica material; compounded in such a way that the total mold expansion will offset the casting shrinkage of the alloy, which varies from 1% to 1.74% (the highest figure being the shrinkage of pure gold). Generally, the higher the percentage of gold in the alloy, the greater is the contraction of the casting on solidifying.

Only one chromium-cobalt alloy has a sufficiently low melting temperature to be cast into a plaster-silica investment mold. According to Peyton, for the other alloys that have a higher melting temperature, an investment that contains quartz powder held together by an ethyl silicate or sodium silicate binder is generally used. Expansion to offset casting shrinkage for chromium-cobalt alloys is accomplished primarily through thermal expansion of the mold and must be sufficient to offset their greater casting shrinkage, which is on the order of 2.3%. For this reason, the casting ring is usually removed after the mold has hardened to allow for the greater mold expansion necessary with these alloys. Because the investments for chromium-cobalt alloys are generally less



**FIGURE 19-26** Applying the investment with a soft moistened brush to ensure complete adaptation of the investment. This helps reduce the number of bubbles and makes for a smoother cast surface.

porous, there is greater danger that gases will be entrapped in the mold cavity by the molten metal. Spruing must be done with greater care, and in some instances, provision for venting the mold is necessary to prevent defective castings.

**Step-by-Step Procedure**

The technique for applying the outer investment is usually referred to as *investing the pattern*. Actually, the cast on which the pattern is formed is part of the investment also. This investment technique is presented in [Figures 19-25 through 19-27](#).

\*Note the substitution of the word alloy, as the same principles apply whether the metal is a precious metal alloy or a chromium-cobalt alloy. In some of the latter alloys, the cobalt is partially replaced by nickel; such alloys are sometimes described as Stellite alloys.



**FIGURE 19-27** Investment mold has been trimmed to prepare the sprue end for burnout and subsequent complete adaptation to the casting machine.

### Burnout

The burnout operation serves three purposes: it drives off moisture in the mold; it vaporizes and thus eliminates the pattern, leaving a cavity in the mold; and it expands the mold to compensate for contraction of the metal on cooling.

For the investment to heat uniformly, it should be moist at the start of the burnout cycle. Steam will then carry the heat into the investment during the early stages of the burnout. Therefore if the investment is not burned out on the same day that it is poured, it should be soaked in water for a few minutes before it is placed in the burnout furnace.

Just before it is placed in the furnace, the mold should be placed in the casting machine to balance the weight against the weight of the mold. At this time, the mold should be properly oriented to the machine and its crucible, and a scratch line should be made at the top for later repositioning of the hot mold.

The mold should be placed in the oven with the sprue hole down and the orientation mark forward. Burnout should be started with a cold oven, or nearly so. Then the temperature of the oven should be increased slowly to a temperature recommended by the manufacturer. This temperature should be maintained for the period recommended by the manufacturer to ensure uniform heat penetration. More time must be allowed for plastic patterns, particularly palatal anatomic replica patterns. It is important that the peak temperature recommended by the manufacturer not be exceeded during the burnout period. (When a high-heat investment is used, follow the manufacturer's instructions as to burnout temperature.)

### Casting

The method of casting varies widely with the alloy and equipment used. All methods use force to quickly inject the

molten metal into the mold cavity. This force may be centrifugal or air pressure; the former is more commonly used. In any case, too much or too little force is undesirable. If too little force is used, the mold is not completely filled before the metal begins to freeze. If too much force is used, excessive turbulence may result in the entrapment of gases in the casting. With centrifugal casting machines, this is regulated by the number of turns put on the actuating spring.

The metal may be melted with a gas-oxygen blowtorch or by an electric muffle surrounding the metal. In some commercial casting procedures and in some dental laboratories, the induction method may be used (Figure 19-28); this provides a rapid and accurate method of melting the metal. Currently available casting machines include those that are electrically controlled to heat alloys to a specified temperature and to release the molten metal at precisely the correct casting temperature. These machines are relatively expensive and are primarily located in commercial laboratories or institutions where casting volume is high.

### Removing the Casting from the Investment

Chromium-cobalt alloys are usually allowed to cool in the mold, are divested (Figure 19-29), and are not cleaned by pickling. Finishing (Figure 19-30) and polishing (Figure 19-31), which are done with special high-speed equipment, require technical skill in the use of bench lathes. Just before they are polished (high-shine), chromium-cobalt castings are electropolished; this is a controlled deplating process (Figure 19-32).

### Finishing and Polishing


Some authorities hold that the sprues should not be removed from the casting until most of the polishing is completed. Although it is true that this policy may prevent accidental distortion, it is difficult to adhere to and is therefore somewhat impractical. Instead, reasonable care should be exercised to prevent any distortion resulting from careless handling. A specific precaution is that a cast clasp arm should not be indiscriminately polished and then bent into place. The waxing should have been done in such a manner that a minimum of finishing is necessary and the intended relationship of the clasp to the abutment is maintained (Figure 19-33).

Actual polishing procedures may vary widely according to personal preference for certain abrasive shapes and sizes. However, the following several rules for finishing the casting are important:


1. *High speeds are preferable to low speeds.* Not only are they effective but in experienced hands there is less danger of the casting being caught and thrown out of the hands by the rotating instrument.
2. *The wheels or points and the speed of their rotation should do the cutting.* Excessive pressure heats the work, crushes the abrasive particles, causes the wheels to clog and glaze, and slows the cutting.

3. A definite sequence for finishing should be adopted and followed for every framework.

4. Clean polishing wheels should be used. If contaminated wheels are used, foreign particles may become embedded in the surface, which will lead to later discoloration.
5. Be sure that each finishing operation completely removes all scratches left by the preceding one. Remember that each successive finishing step uses a finer abrasive and therefore cuts more slowly and requires more time to accomplish.




**FIGURE 19-28**    **A**, An invested pattern is removed from the burnout oven following complete elimination of the wax pattern. **B**, An investment mold is placed into the casting machine. The induction casting process provides consistency to the casting procedure.



**FIGURE 19-29**    **A**, Divesting of the framework involves bulk removal of the investment. **B**, The framework is divested with aluminum oxide.

MAKING RECORD BASES

Bases for jaw relation records should be made of materials that possess accuracy or those that can be relined to provide such accuracy. Relining may be accomplished by seating the previously-adapted base onto the tinfoil or lubricant in the cast with an intervening mix of zinc oxide-eugenol paste or with autopolymerizing acrylic-resin. Some use has been made of mercaptan and silicone impression materials for this purpose, but the wisdom of using an elastic lining material for jaw relation record bases is questionable. When rigid setting materials are used for this purpose, any undercuts on the cast must be blocked out with wax or clay to facilitate their removal without damage to the cast.




**FIGURE 19-30** Gross finishing is accomplished with metal finishing burs, abrasive stones, or sintered diamonds (except at contact areas).

The ideal jaw relation record base is one that is processed (or cast) to the form of the master cast, becoming the permanent base of the completed prosthesis. Cast metal bases for complete or removable partial dentures offer this advantage, as do acrylic-resin bases that are processed directly to the master cast, thus becoming the permanent denture base. When undercuts are present, the master cast will be destroyed during removal of the base. Then existing undercuts must be blocked out inside the denture base before dental stone is poured into it to make a cast for articulator mounting. A second cast, which includes the undercuts, must be poured against the entire base to support it when the overlying acrylic-resin is processed. With both the processed base and the overlying acrylic-resin, some care must be taken to prevent visible junction lines between the original acrylic-resin base and the acrylic-resin that supports the teeth and establishes facial contours.

Some autopolymerizing acrylic-resin materials are sufficiently accurate for use as jaw relation bases. These are used with a sprinkling technique, which, when properly done, permits formation of a base that compares favorably with a



**FIGURE 19-32** Electropolishing unit used for the final surface polish of frameworks in a heated polishing liquid.



**FIGURE 19-31** The framework is finished with a rubber polishing point before final “high-shine” polish in a region adjacent to the teeth (A) and at the periphery of a major connector (B).

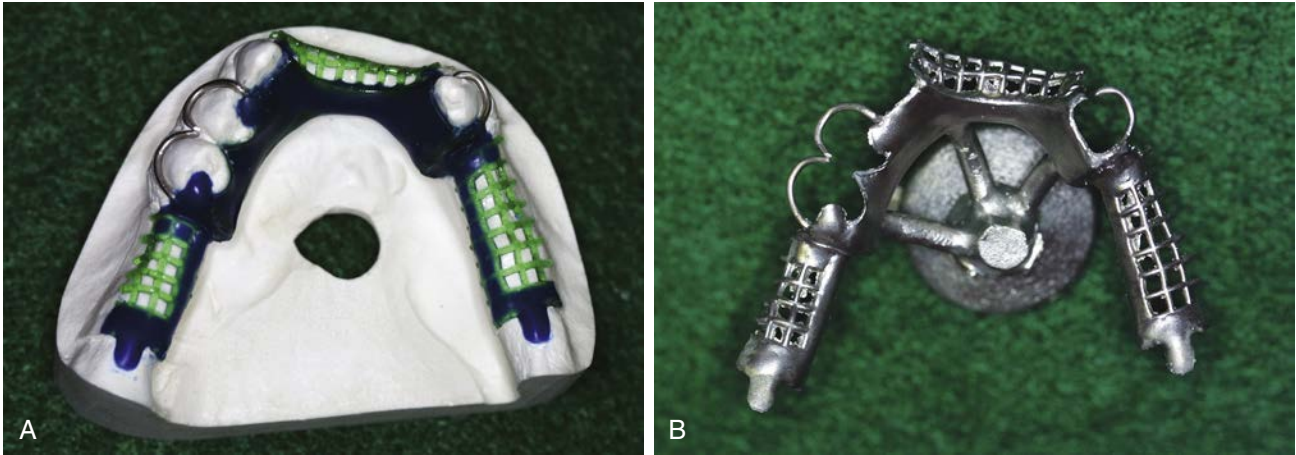
processed base or a visible light polymerized base. A material must be selected that will polymerize in a reasonable time (usually a 12-minute monomer) and will retain its form during the sprinkling process. Because polymerization with typical shrinkage toward the cast begins immediately, alternate addition of monomer and polymer in small increments results in reduced overall shrinkage and greater accuracy. Another option is to use visible light-cured (VLC) denture base materials, which employ a technique similar to that described in Chapter 16 for making custom impression trays.

**Technique for Making a Sprinkled Acrylic-Resin Record Base**

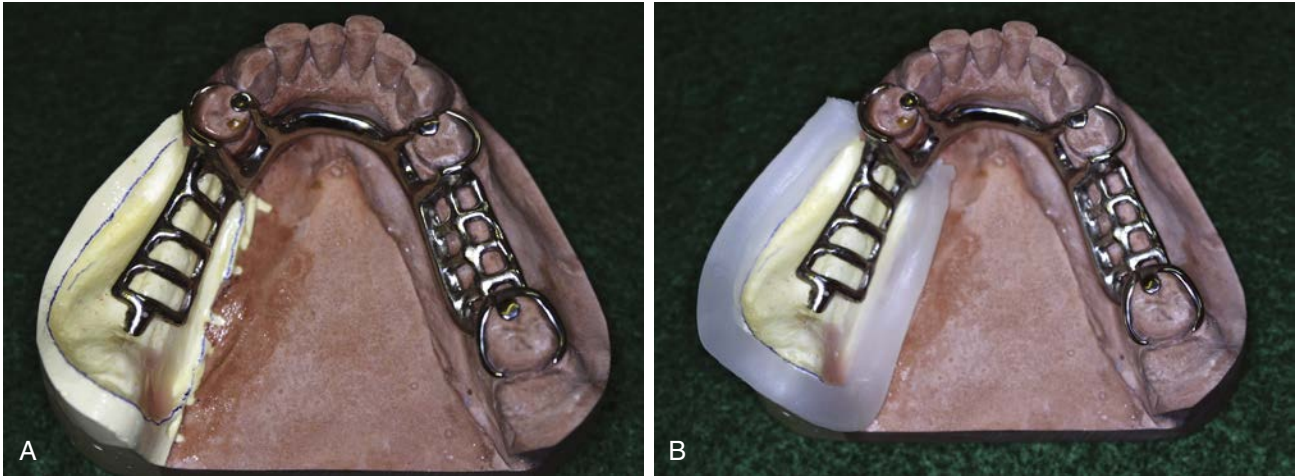
The technique for sprinkling a record base is described here because the techniques used for the VLC impression tray and

record bases were presented in Chapter 16 and elsewhere in this chapter. Some blockout and lubrication of the cast are necessary (Figure 19-34). Relief of undercut areas on the cast is best accomplished with a water-soluble modeling clay or baseplate wax. Modeling clay is easily formed and shaped on the cast and is easily removed from the cast or the base with a natural-bristle toothbrush under warm running water. Wax must be flushed off the cast with hot water and possibly removed from the inside of the base before use.

Bases for jaw relation records must have maximum contact with the supporting tissue. The accuracy of the base will proportionate to the contact provided to the total area of intimate tissue. Those areas are most often undercut and require blockout of the distolingual and retromylohyoid areas of the mandibular cast, the distobuccal and labial aspects of the



**FIGURE 19-33** Attention to detail in forming the wax pattern not only ensures the quality of the framework, it also saves time in finishing and polishing the resultant casting. **A**, Wax pattern of the mandibular framework, which incorporates three wrought-wire retainers. **B**, The same framework following casting shows a smooth casting surface and attention to detail regarding casting completeness and clasp form.



**FIGURE 19-34** **A**, Preparation of Kennedy Class I, modification 1 distal extension for sprinkle-on record base technique. Cast undercuts are blocked out with wax, and the cast is coated with separator. **B**, Peripheral extent of the base (the same as peripheral extent of the prosthesis captured during border molding and an impression-making procedure for this altered cast) is outlined with rope wax to contain resin.

maxillary cast, and, frequently, small multiple undercuts in the palatal rugae. These areas and any others are blocked out with a minimum of clay or wax, to obliterate as little of the surface of the cast as possible. A close-fitting base may then be made that will have the necessary accuracy and stability and yet may be lifted from and returned to the master cast without abrading it.

The cast and the blockout or relief are coated with a separating medium. Following this, the cast is wet with the monomer from a dropper bottle. After the surface has been wetted with the monomer, the polymer is sprinkled or dusted onto the wet surface until all the monomer has been absorbed. Sprinkling is best accomplished with a large-mouthed bottle with a single hole in the lid near the rim. This facilitates placement of the polymer without excess in any one area. A flexible bottle with a suitable applicator tip also may be used. The objective should be to apply polymer uniformly over the entire ridge rather than allowing excess to accumulate at the border to be trimmed later. An autopolymerizing acrylic-resin material must be used that will retain its form during the sprinkling procedure without objectionable flow into low areas (Figures 19-35 and 19-36).

Once the polymer has been sprinkled in slight excess, the monomer is again added. Flooding must be prevented; therefore the monomer must be directed over the entire surface gradually until the polymer has just absorbed the monomer. A few seconds delay before the addition of excess monomer allows the mass to reach a tacky consistency and prevents it from flowing when more monomer is added. Then the monomer may be added in excess and is immediately absorbed by the application of more polymer, as before. This process is repeated selectively until a uniform layer has been built up that is just thick enough so that none of the underlying cast or relief may be seen.

The final step in sprinkling is the addition of monomer sufficient to leave a wet surface. Immediately, the cast should

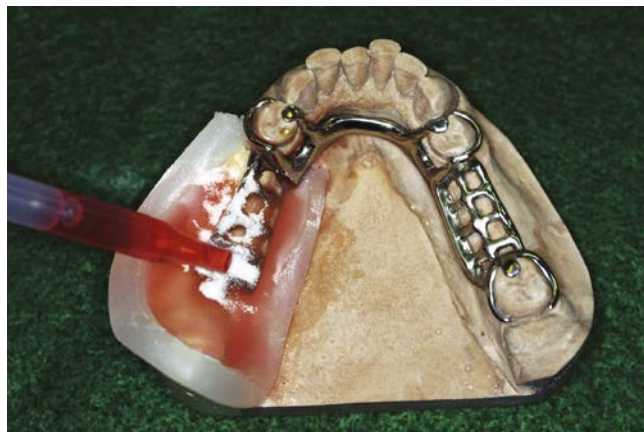be placed in a covered glass dish or covered with an inverted bowl. This permits final polymerization in a saturated atmosphere of monomer and prevents evaporation of surface monomer. The cast should not be placed in water nor any attempt made to accelerate polymerization. Slow polymerization is necessary so that shrinkage toward the cast will occur. Only then will overall shrinkage be negligible and accuracy of fit ensured. This is of little consequence in making an impression tray, but it is most essential in making a sprinkled acrylic-resin base.

Although polymerization will be about 90% complete within an hour and an impression tray may even be lifted within a half-hour, it is critical that a sprinkled denture base should be left overnight before it is separated from the cast. It should be lifted dry or under lukewarm tap water. It should not be immersed in hot water because some warping may occur.

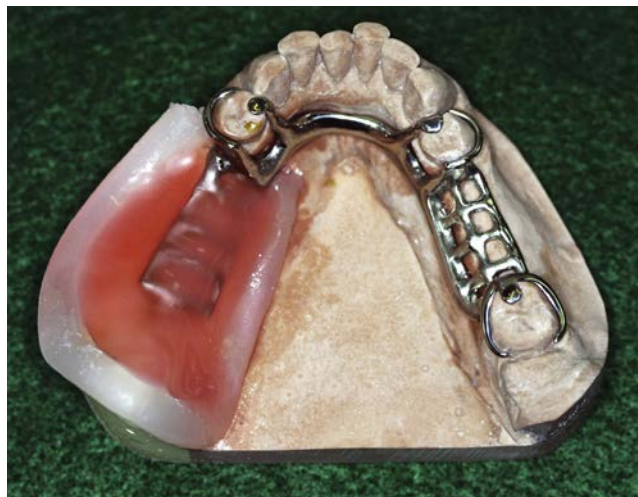A sprinkled acrylic-resin base made with the precautions outlined previously will retain its accuracy for days, or even for an indefinite period, similar to a heat-polymerized resin base (Figure 19-37) or a VLC base.

## OCCCLUSION RIMS

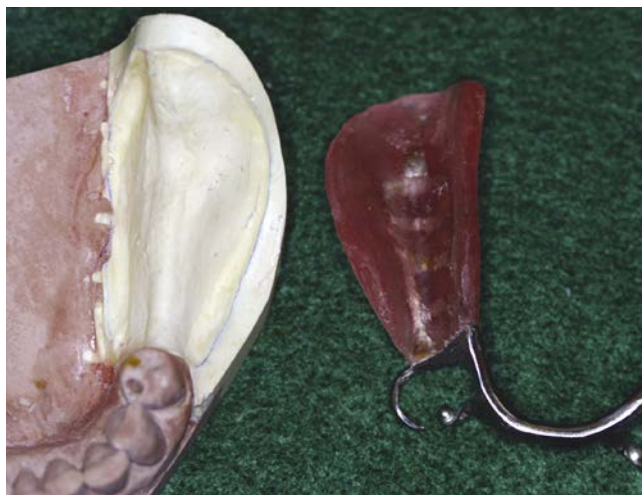It has been explained that jaw relation records for removable partial dentures always should be made on accurate bases that may be part of the denture casting itself or may be attached to it in exactly the same relation as the final denture base will be. Further, it has been stated that although use of the final denture base is best for jaw relation records, a sprinkled or corrected acrylic-resin base may be used satisfactorily. In any case, accuracy of the base supporting a maxillomandibular record must be ensured before the function of occlusion rims is considered.



**FIGURE 19-35** The cast is wetted with monomer, and polymer resin is added in increments to uniformly control thickness. Use of a typical eyedropper may be difficult if the monomer addition cannot be controlled. Use of peripheral rope wax helps in this regard.



**FIGURE 19-36** The record base is complete when a uniform thickness is created that provides strength and accuracy. The completed unpolymerized resin is covered to ensure polymerization without loss of surface monomer.

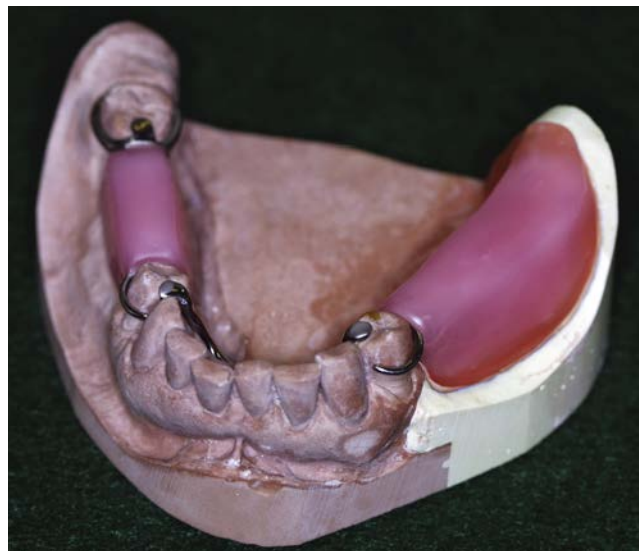

**FIGURE 19-37** Once completely polymerized, the record base and the framework can be removed from the cast, finished, and prepared for addition of the record base. The tissue side of the record base (intaglio) should possess similar accuracy and stability as are seen with the completed prosthesis. Such a record base provides a significant advantage for jaw relation records when minimal teeth remain and ridge configurations along with extensive base areas place a premium on base accuracy and stability.

Occlusion rims may be made of several materials. The material that is most commonly used to establish static occlusal relationships is the hard baseplate wax rim. However, use of a wax occlusion rim can be inaccurate when the occlusal portion of the rim is mishandled. When some soft material that sets to a rigid state, such as impression plaster or bite registration paste, is used in conjunction with wax rims to record static occlusal relations, many of the errors common to wax rims are eliminated—provided some space for the material exists between the occlusion rims, the opposing teeth, or both, at the desired vertical dimension to be recorded. Registration made on wax occlusion rims with the use of a wax registration material must be handled carefully and mounted immediately.

Occlusion rims for static jaw relation records should be so shaped that they represent the lost teeth and their supporting structures (Figure 19-38). An occlusion rim that is too broad and is extended beyond where prosthetic teeth will be located is inexcusable. Such rims will substantially alter the shape of the palatal vault and the arch form of the mandibular arch, will crowd the patient's tongue, will have an unwelcome effect on the patient, and will offer more resistance to jaw relation recording media than will a correctly-shaped occlusion rim.

Modeling plastic (compound) has several advantages and may be used rather than wax for occlusion rims. It may be softened uniformly by flaming, yet when chilled it becomes rigid and sufficiently accurate. It may be trimmed with a sharp knife to expose the tips of the opposing cusps to recheck or position an opposing cast into the record rim. Opposing occlusion rims of modeling plastic may be keyed



**FIGURE 19-38** Occlusion rims are added to allow recording of jaw relation records. Placement of the wax record is dictated by the opposing tooth position and the supporting ridge character. When possible, the occlusion rim should allow recording of the jaw position within the primary bearing area of the ridge.

with greater accuracy than opposing wax rims. Preferably, however, even those should be trimmed short of contact at the vertical dimension of occlusion, and bite registration paste should be interposed for the final record. As with wax rims, an adjustable frame may be used to support the final record.

Occlusion rims made of extra hard baseplate wax or modeling plastic may be used to support intraoral central bearing devices, intraoral tracing devices, or both. Because of its greater stability, modeling plastic is preferable for this purpose when the edentulous situation permits the use of flat plane tracings. An example of such a situation occurs when an opposing complete denture is made concurrently with the removable partial denture. In such a situation, modeling plastic occlusion rims provide greater stability than wax rims, with corresponding improvement in the predictable accuracy of such a jaw relation record. Although sealing opposing occlusion rims or using clips for complete denture jaw relation records may be acceptable, particularly for an initial articulator mounting, the existence of a removable partial denture framework makes this practice hazardous. The framework with attached base should be seated accurately on its cast before the opposing cast is repositioned in occlusion to it, because it is necessary for the dentist to be able to see the removable partial denture framework is in its designed terminal relation to the supporting teeth before articulating the casts.

Occlusion rims for recording functional, or dynamic, occlusion must be made of a hard wax that can be carved by the opposing dentition. This method, outlined in Chapter 18, presumes that the opposing arch is intact or

has been restored. Functional occlusion records cannot be made by this method when both arches are restored simultaneously. Rather, an opposing arch must be as intact as the treatment plan calls for, or it must be restored by whatever prosthetic means the situation dictates. Opposing removable partial dentures or an opposing complete denture may be carried concurrently up to the final occlusal record. One denture is then completed and the functional record is made in opposition to it. Often, this necessitates that all opposing teeth are articulated first in wax to establish optimum ridge relations and the correct occlusal plane. One denture is then carried to completion, and the teeth that remain in wax on the opposing denture are removed while the functional occlusal record is being made.

The laboratory steps required for establishing an occlusion with the use of functional occlusal records were described in Chapter 18; however, more detail is provided in the following section. Some inlay waxes are used for this purpose because they can be carved by the opposing dentition, and because most of them are hard enough to support occlusion over a period of hours or days. A wax for recording functional crown and bridge occlusion, because it is established entirely in the dental office, is selected on the basis of how well it may be carved by the opposing dentition in a relatively short time. Therefore, a softer wax may be used than is required for the recording of occlusal paths over 24 hours or longer. For this latter purpose, hard inlay wax seems to satisfy best the requirements for a wax that is durable yet capable of recording a functional occlusal pattern. This wax is packaged in the form of sticks. A layer of hard, sticky wax is first flowed onto the surface of the denture base. Two sticks of the inlay wax are then laid parallel along the longitudinal center of the denture base and are secured to it with a hot spatula. This is the only preparation needed before the dental appointment. Because neither the height nor the width of the occlusion rim can be known in advance, and because deep warming of a chilled wax rim is difficult, the rim is not completed before the appointment.

With the patient in the chair, a hot spatula is inserted into the crevice between the two sticks of wax, making the center portion fluid between two supporting walls. Some transfer of heat to the supporting walls occurs, resulting uniform softening of the occlusion rims. The patient is asked to close into this wax rim until the natural teeth are in contact; this establishes both the height and the width of the occlusion rim. Wax is added or carved away as indicated, and the patient is asked to make lateral excursions. Any excess wax is then removed, and any unsupported wax is supported by addition. Finally, wax is added to increase the occlusal vertical dimension sufficiently to allow for (1) denture settling, (2) changes in jaw relations brought about by the reestablishment of posterior support, and (3) carving in all mandibular excursions. When sufficient height and width have been established

to accommodate all excursive movements, the patient is given instructions for chewing in the functional record and is then dismissed.

Although this discussion has been included in the chapter on laboratory procedures, the entire procedure of establishing occlusion rims is for the purpose of recording functional occlusion and should be considered a chairside procedure rather than a laboratory procedure. It is necessary that the purpose of a functional occlusal record be clearly understood so that subsequent laboratory steps may be accomplished in such a manner that the effect of the occlusal record may be reproduced on the finished denture.

### MAKING A STONE OCCLUSAL TEMPLATE FROM A FUNCTIONAL OCCLUSAL RECORD

After final acceptance of the occlusal record developed by the patient, the effectiveness of this method for establishing functional occlusion on the removable partial denture depends on how accurately the following procedures are carried out. For this reason, it will be given as a step-by-step procedure. If the base of the master cast (or processing cast) has not been keyed previously, do this before proceeding. Reduce the thickness and width of the base if it is so large that difficulty will be encountered in flasking. The base may not be reduced after removal from the articulator because the mounting record would be lost.

Keying may be done in several ways, but a method whereby the keyed portions are visible on the articulator mounting eliminates some possibility of remounting error. According to the preferred method, form a 45-degree bevel on the base of the cast by hand or with the model trimmer, and then add three V-shaped grooves on the anterior and posterior aspects of the base of the cast at the bevel. The bevel serves to facilitate reseating of the cast on the articulator mounting, and the mounting surfaces are made still more definite by the triangular grooves. Once placed at the beveled margin, the triangular grooves are visible at all times, and any discrepancy may be clearly seen.

Inspect the underside of the cast framework and the denture bases, removing any particles of wax or other debris. Similarly, inspect and clean the master cast of any particles of stone, wax, or blockout material, or any other debris that might prevent the casting from being seated accurately on it.

Now seat the denture framework on the cast in its original terminal position. This is the position that is maintained by securing it with sticky wax with all occlusal rests seated while the trial denture base is made. It is also the position that the casting assumed in the mouth while the occlusal record was being made and that must be duplicated on return of the denture framework to the master cast. While holding the framework in this terminal

position, secure it again with sticky wax. (If a processing cast is used in place of the master cast, the denture base will have been made on that cast, and the same precautions used in returning the framework to its original position apply.)

With the denture framework and the occlusal record in position, form a matrix of clay around the occlusal record to confine the hard stone, which will form the stone occlusal template. The clay matrix is the same for a metal or electroplated surface as for the wax record. The clay matrix should rise at a 45-degree angle from the buccal and lingual limits of the occlusal registration. Then arch the clay or a sheet of wax across from one side to the other, forming a vault that will permit lingual access when the teeth are articulated.

Leave the occlusal surfaces of a processing cast exposed so that they may act as vertical stops. This will serve to maintain the vertical relation in the articulator. Unless such stone-to-stone stops are used, the technician may alter the vertical relation in the articulator, accidentally or otherwise. Any change in vertical relations is incompatible with a concept of dynamic conclusion because the occlusal pattern is directly related to the degree of jaw separation. Although it may be true that occlusal vertical dimension may be changed when casts are mounted in relation to the opening axis of the mandible, as long as natural cusps remain to influence mandibular movement, the occlusal vertical relation established with a functional occlusal record must not be changed in the articulator.

Cover the surfaces of the adjacent abutment teeth left exposed with sodium silicate, microfilm, or some other separating medium to ensure separation of the stone vertical stops. If the wax record has not been electroplated, use a hard dental stone to form the opposing template. This may be an improved stone, but the use of a stone die material is preferred. Only the occluding surface needs to be poured in the harder stone, with a less costly laboratory stone used to back it up. If this is done, add the second layer to the first before the former takes its initial set to prevent any possibility of accidental separation between the two materials.

Vibrate the stone only into the wax registration and against the stone stops. Pile on the rest of the stone, and leave it uneven to facilitate attachment to the mounting stone. Attach the occlusal template to the articulator without provision for removal or remounting because only the working cast needs to be keyed for remounting.

After the stone template has set, attach the occluded casts to both arms of the articulator before separating the casts. The type of articulating instrument used is of little importance because all eccentric positions are recorded on the template, and whatever instrument is used acts purely as a simple hinge or a tripod. Therefore any laboratory articulator or tripod may be used.

Casts should be attached to the articulating instrument with stone rather than with plaster. Mounting stones are

available that have been especially formulated and prepared to minimize the setting expansion inherent in most gypsum products. The least amount of setting expansion of the mounting medium is most desirable to maintain the intended relationship of the opposing casts.

One must remember which arch will be movable as a working cast, and the articulator mounting should be made accordingly. For example, for a mandibular denture, the template is attached to the upper arm of the articulator. For a maxillary denture, the template is mounted upside down on the lower arm. The keyed base of the working cast attached to the opposing arm must be coated with a light coat of microfilm, mineral oil, or petroleum jelly to facilitate its separation from the mounting stone.

After the mounting has been completed, separate the casts and remove the clay. The template, with its mounting, may be removed from the articulator if a mounting ring or mounting stud permits; otherwise, trimming must be done on the articulator. With a pencil, outline the limits of the occlusal registration and any excess stone around its borders. With a knife, trim the vertical stops to a sharp edge on the buccal surface where they contact the working cast.

Remove any overhanging stone, leaving the occluding template and vertical stops clearly visible and accessible. Remove the wax registration before arranging artificial teeth to the occluding template.

### ARRANGING POSTERIOR TEETH TO AN OPPOSING CAST OR TEMPLATE

Whether posterior teeth are to be arranged to occlude with an opposing cast or with an occlusal template, the denture base on which the jaw relation record has been made must first be removed and discarded unless metal bases are part of the denture framework, or heat-polymerized acrylic-resin bases were used. This statement is based on the assumption that where an adjustable articulator has been used to develop the occlusion, the trial dentures have been evaluated, the articulator mounting has been proved, and the articulator has been programmed for eccentric positions. Because record bases that are entirely tissue supported have no place in recording occlusal relations for removable partial dentures, the bases must be attached to the denture framework. Metal bases that are part of the prosthesis present no problem. The teeth may be arranged in wax or replaced on the metal base, depending on the type of posterior tooth used, and these must be occluded directly to the opposing cast or template.

Unless occlusal relations are recorded on final acrylic-resin bases, autopolymerizing acrylic-resin bases attained by the sprinkling method or VLC bases are the most accurate and stable of bases that may be used for this purpose. (An alternate method is relining of the original impression bases, thus accomplishing the same purpose.)

Although static relations may be recorded successfully on corrected bases, functional registrations are best accomplished on new acrylic-resin bases made for that purpose. In either situation, the denture cannot be completed on these bases; neither can the bases be removed conveniently from the retentive framework during the boil out after flasking. Therefore the metal framework must be lifted from the cast, and the original record base removed by flaming its underside. Care must be taken not to allow the acrylic-resin to burn, or the cast framework will become discolored with carbon. The framework is repolished and is then returned to its original position on the master cast and secured there with sticky wax before the artificial teeth are arranged.

### Posterior Tooth Forms

Posterior tooth forms for removable partial dentures should not be selected arbitrarily. One should bear in mind that the objective in removable partial denture occlusion is harmony between natural and artificial dentition. Whether the teeth are arranged to occlude with an opposing cast or to an occlusal template, they should be modified to harmonize with the existing dentition. In this respect, removable partial denture occlusion may differ from complete denture occlusion. In the latter case, posterior teeth may be selected and articulated according to the dentist's concept of what constitutes the most favorable complete denture occlusion, whereas removable partial denture occlusion must be made to harmonize with an existing occlusal pattern. Thus, the occlusal surfaces on the finished removable partial denture may bear little resemblance to the original occlusal surfaces of the teeth as manufactured.

Artificial tooth forms should be selected to restore the space and fulfill the esthetic demands of the missing dentition. Manufactured tooth forms usually require modification to satisfactorily articulate with an opposing dentition. The original occlusal form, therefore, is of little importance in forming the posterior occlusion for the removable partial denture.

The posterior teeth are most often made of resin (including all resin forms—composite, interpolymers, network, cross-link, double cross-link, and so on). An advantage of resin teeth is that they are more easily modified and subsequently reshaped for masticating efficiency by the addition of grooves and spillways. Resin teeth are also more easily narrowed bucco-lingually to reduce the size of the occlusal table without sacrificing strength or esthetics. They may be more easily ground to fit minor connectors and irregular spaces and to avoid retentive elements of the removable partial denture framework. However, when resin teeth are used, the occlusion must be evaluated periodically to make sure that the occlusal surfaces have not worn out of contact. It seems that the best combinations of opposing occlusal surfaces used to maintain the established occlusion and to prevent deleterious abrasion are porcelain-to-porcelain surfaces,

gold surfaces to natural or restored natural teeth, and gold surfaces to gold surfaces.

### Arranging Teeth to an Occluding Surface

The procedure for arranging teeth to a static relationship with an opposing cast is essentially the same as for arranging teeth to an occluding template. On the other hand, articulation of artificial teeth on an adjustable instrument, which reproduces to some extent mandibular movement, will follow more closely the customary pattern for complete denture occlusion. The procedure for arranging posterior teeth to an occluding template was presented in Chapter 18.

## TYPES OF ANTERIOR TEETH

Anterior teeth on removable partial dentures are concerned primarily with esthetics and the function of incising. These are best arranged when the patient is present because an added appointment for try-in would be necessary anyway. They may be arranged arbitrarily on the cast and then tried in, but a stone index of their labial surfaces should be made on the master cast after the final arrangement has been established to preserve the arrangement that the patient saw and approved.

From a purely mechanical standpoint, all missing anterior teeth are best replaced with fixed restorations rather than with the removable partial denture. However, for cosmetic or economic reasons, or in situations in which several missing anterior teeth are involved—such as in a Class IV partially edentulous arch—their replacement with the removable partial denture may be unavoidable.

Some types of anterior teeth used in removable partial dentures are as follows:

1. *Porcelain or resin teeth, attached to the framework with acrylic-resin.*
2. *Ready-made resin teeth processed directly to retentive elements on the metal framework with a matching resin.* This is called a *pressed-on method* and has the advantage of permitting previous selection and evaluation of the anterior teeth, plus the advantage of the use of ready-made resin teeth for labial surfaces. These are then hollowed out on the lingual surface to facilitate their permanent attachment to the denture framework with the resin of the same shade.
3. *Resin teeth processed to a metal framework in the laboratory.* Tooth forms of wax may be carved on the removable partial denture framework and tried in the mouth, adjusted for esthetics and occlusion, and then processed in an acrylic-resin of a suitable shade. There is some question as to whether the shade and durability of such teeth are comparable with those of manufactured resin teeth, but improvements in materials have led to improved quality and appearance of laboratory-made teeth. Moreover, such teeth may often be shaped and characterized to better blend with adjacent natural teeth.

4. *Porcelain or acrylic-resin facings cemented to the denture framework.* These may be tried in the mouth on a baseplate wax base and adjusted for esthetics. Ready-made plastic backings may be used, which become part of the pattern for the removable partial denture framework. The teeth are then ultimately cemented to the framework. Esthetically, these are less satisfactory than other types of anterior teeth, but because the plastic backing is cast as part of the removable partial denture framework, they have the advantage of greater strength and are replaced easily. A record of the mold and shade of each tooth should be kept, and only the ridge lap of the replacement teeth needs to be ground to fit. When replaceability is the main reason for its use, the stock facing should not be beveled or difficulty will be encountered in replacing it. Replacement also may be accomplished by waxing and processing a resin tooth that directly faces the metal backing. Stock tube or side-groove teeth are not ordinarily used for anterior teeth on removable partial dentures because of the horizontal forces that tend to dislodge them.
5. *Anterior resin denture teeth can be modified to be used as resin veneers, the same as for veneer crowns and veneer pontics on fixed partial dentures.* This is most applicable when the removable partial denture framework is to be cast in an alloy. Then labial surfaces may be waxed and the final carving for esthetics done in the mouth. A modification of this method is the waxing of the veneer coping on a previously cast metal base. These then are cast separately and are attached to the framework by soldering. Esthetically, the result is comparable with that obtained with resin veneer crowns. This method is particularly applicable when there is a desire to make the replaced teeth match adjacent veneered abutment crowns.

## WAXING AND INVESTING THE REMOVABLE PARTIAL DENTURE BEFORE PROCESSING ACRYLIC-RESIN BASES

### Waxing the Removable Partial Denture Base

Waxing the removable partial denture base before investing differs little from waxing a complete denture. The only difference is the waxing of and around exposed parts of the metal framework. At the framework–denture base junction, undercut finishing lines should be provided whenever possible. Then the waxing is merely butted to the finishing line with a little excess to allow for finishing. Otherwise, small voids in the wax may become filled with investing plaster, or fine edges of the investment may break off during boil out and packing. In either situation, small pieces of investment may become embedded in the acrylic-resin at the finishing lines. This is prevented by slightly over waxing and then finishing the acrylic-resin back to the metal finishing line with finishing burs. Abrasive wheels and disks should not be used for this purpose, because they will cut into the metal and may burn the acrylic-resin. Pumice and a rag wheel should

be used sparingly for polishing, because they will abrade the acrylic-resin more rapidly than the metal and will leave the finishing line elevated above the adjacent acrylic-resin.

When waxing to polished metal parts that do not possess a finishing line is done, it must be remembered that no attachment will exist, and that over a period of time, some seepage, separation, and discoloration of the acrylic-resin in this area are inevitable. This may be prevented to some extent by roughening the metal whenever possible to effect some mechanical attachment by silicoating the attachment or by using one of the resin adhesives. The wax should be left 1.5 to 2.0 mm thick so that the acrylic-resin will have some bulk at its junction with the polished metal. Thin films of acrylic-resin over metal should be avoided. In finishing, these should be cut back to an area of bulk with finishing burs. Otherwise, any thin acrylic-resin film eventually will separate and become discolored and unclean as a result of marginal seepage.

Gingival forms should be waxed in accordance with modern concepts of esthetics and should be made to prevent entrapment of food particles. Dental students should become familiar with normal gingival architecture as found on diagnostic casts of natural dentitions, beginning in basic technique exercises with the casts of each other's mouths. In this manner, they may acquire a better concept of gingival contours to be reproduced on prosthetic restorations.

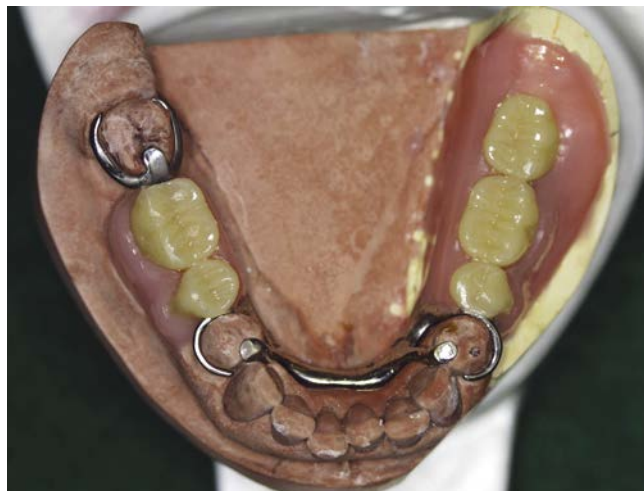Artificial teeth should be uncovered fully to expose the entire anatomic crown and beyond when gingival recession is simulated. Adjacent or contralateral tooth-gingival relationships should be used as a guide to facilitate the harmonious esthetic presentation of the gingival contours. Relatively few prosthodontic patients are in an age bracket in which some gingival recession and exposed cementum would not normally be present; this should be simulated on prosthodontic restorations in proportion to the patient's age. With removable partial dentures, gingival contours around the remaining natural teeth should be used as a guide to the gingival contours to be reproduced on the prosthesis. However, interproximal spaces are almost always filled, particularly between posterior artificial teeth.

Frush has listed the following rules for varying the height of the gingival tissue at the cervical portion of the teeth:

1. Slightly below the high lip line at the central incisors.
2. Lower than the central incisor gingival margin at the lateral incisors.
3. Higher than the central or lateral incisor gingival margin at the canine.
4. Slightly lower than the canine at the premolar and variable for both premolars and molars.\*

The correctly formed papilla should be shaped so that it will be self-cleansing. It should be carved so that it is in harmony with the interpretation of age and will be the

\* From Frush JP: *Dentogenic restorations and dynesthetics*, Los Angeles, 1957, Swissdent Foundation.



**FIGURE 19-39** Waxing of the removable partial denture base should reproduce anatomic contours normal for the specific patient's characteristics. This is especially important for regions where the junction of denture tooth and resin will be visible. Healthy interdental papillae are convex and extend to contact points of the teeth. Root prominence can be carved into wax to create a natural appearance. Stippling is typically accomplished after processing done with the use of an eccentric round bur. All of these features should be considered against the specific oral environment in which the prosthesis will be placed. A finished and polished prosthesis that demonstrates esthetic features not found in the patient's mouth may be considered objectionable.

deciding factor in the visible outline form of the tooth. As Frush has pointed out, even a drop of wax properly placed can change the appearance of a square tooth to a tapering or ovoid appearance. A properly formed papilla further enhances the natural appearance by increasing the color in this area.

The rules for forming the papilla were given by Frush as follows:

1. The papilla must extend to the point of tooth contact for cleanliness.
2. The papillae must be of various lengths.
3. The papilla must be convex in all directions.
4. The papilla must be shaped according to the age of the patient.
5. The papilla must end near the labial face of the tooth and must never slope inward to terminate toward the lingual portion of the interproximal surface.

The denture should be waxed and carved as for a cast restoration, which it actually is, regardless of the material or the method of processing used. The fact that a split-mold technique is used for processing does not alter the fact that the form of the denture base is to be reproduced by a casting procedure. Therefore, the denture pattern should be waxed with care in the same form as that desired for the finished restoration, rather than attempting to shape facial contours on the prosthesis during the polishing phase (Figure 19-39).

Polishing should consist primarily of trimming away the flash, stippling polished surfaces when desired, and polishing lightly with brush wheels and pumice, followed by final polishing with a soft brush wheel and a nonabrasive shining agent, such as whiting. Gross trimming and polishing with pumice should not be necessary if the denture has been properly waxed before investing.

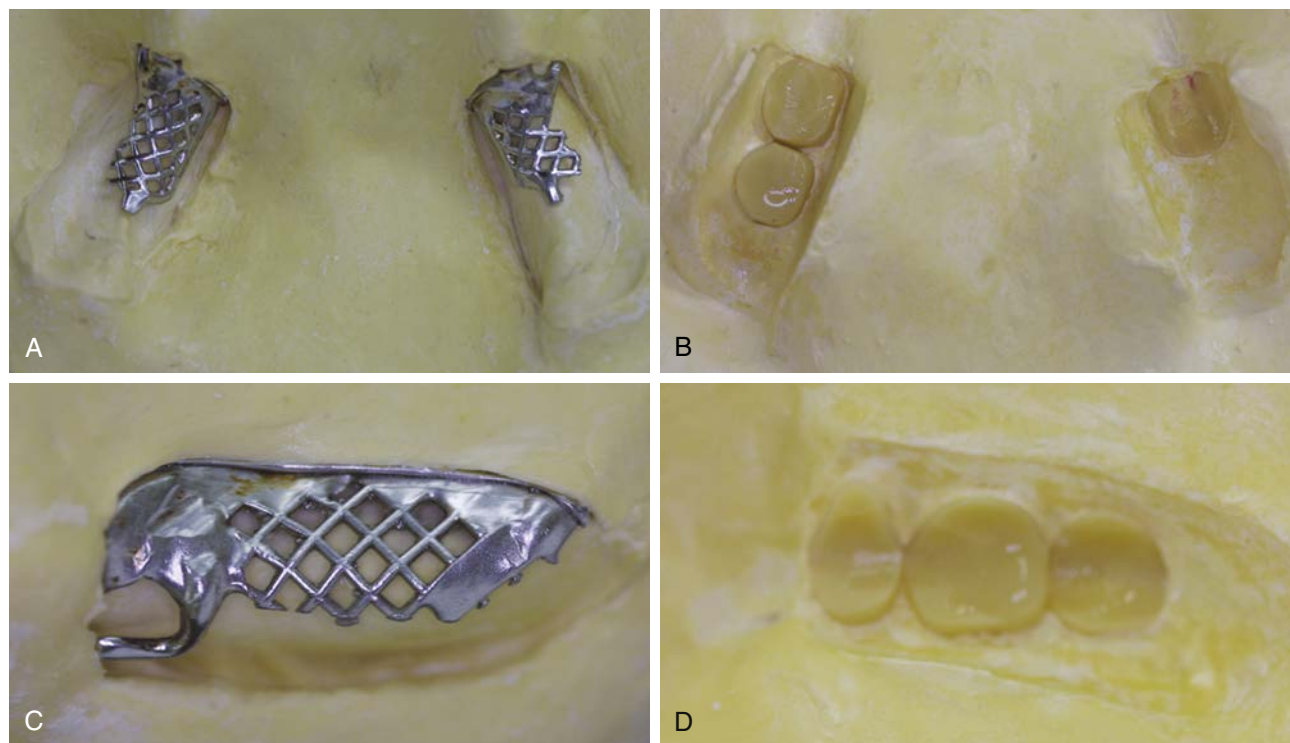
Because the polished surfaces of any denture play an important part in both retention and control of the food bolus, buccal and lingual contours generally should be made concave. In most situations, the border thickness of the denture should be left as recorded in the impression. The only exceptions are the distolingual aspect of the mandibular denture base, to prevent interference with the tongue, and the distobuccal aspect of the maxillary denture base, to prevent interference with the coronoid process of the mandible. These are the only areas that cannot ordinarily be waxed to final contour before investing and may need to be thinned by the dentist at the time of final polishing.

### Investing the Removable Partial Denture

In investing a removable partial denture for processing an acrylic-resin base, it must be remembered that the denture cast must be recovered from the flask intact for remounting. The practice of cutting the teeth off the cast to expose the connectors and retainers, which are then embedded in the upper half of the flask, is permissible only when an existing denture base is being relined and no provision has been made for remounting. (In such a situation, it seems that this practice offers no advantage over investing the denture that is being so relined upside down in the lower half of the flask.) Because in the past some increase in occlusal vertical dimension has been inevitable in any split-mold processing technique, this method results in raising the removable partial denture framework from the supporting teeth by the amount of increase. Occlusal adjustment in the mouth may temporarily reestablish a harmonious occlusal relation with the opposing teeth, whereas the removable partial denture framework will then settle into supporting contact with the abutment teeth at the expense of the underlying ridge.

Changes in occlusal vertical dimension may be held to a minimum by the use of acrylic denture resins that can be placed in the mold in a fluid rather than in a doughy state or those that may be injected in a fluid state into a closed mold. Dimensional changes that occur during relining may also be held to a minimum by the use of autopolymerizing acrylic-resins for this purpose, thus preventing thermal expansion of a mold subjected to elevated temperatures.

When two opposing removable partial dentures are being made concurrently, one is sometimes processed and placed first, and then the final occlusion is established on the second denture to a fully restored arch. In such a situation, when no natural teeth are in opposition, it is not necessary for the first denture to be remounted after processing. In all other situations, remounting to correct for



**FIGURE 19-40** Prostheses invested in processing flasks. **A**, Mandibular Class I master cast with exposed minor connectors of the distal extension bases. **B**, Denture teeth for framework shown in **A**. **C**, Maxillary distal extension minor connector embedded in investing stone. **D**, Opposing flask unit with denture teeth for distal extension shown in **C**.

errors in occlusion is absolutely necessary. Flasking must be accomplished so that the cast may be recovered from the flask undamaged.

Minute voids in the base of the cast will have been reproduced in the stone mounting, and although the obvious larger blebs may be trimmed away, smaller blebs will remain. If the voids in the cast become filled with investing material, the effect is that two particles are trying to occupy the same space. Covering the base with tinfoil substitute before investing can prevent this. Coating the base and sides of the cast with petroleum jelly not only keeps the base of the cast isolated from investing material but also may allow the cast to be more easily recovered from the surrounding investment.

The entire cast, except for the wax and teeth, may then be invested in the lower half of the flask (Figure 19-40). As with a complete denture, only the supplied teeth and wax are left exposed to be invested in the upper half. Also, as with a complete denture, the investment in the lower half must be smooth and free of undercuts and must be coated with a separator to facilitate separation of the two halves of the flask.

An alternate and preferred procedure is to invest the cast only to the top of the tinfoil on the base, smoothing the investment and applying a reliable separator. Then a second layer of investment placed around the anatomic portion of the cast covers the natural teeth and the

exposed parts of the denture framework. This is likewise smoothed and made free of undercuts and coated with a separator before the top half of the flask is poured. Recovery of the cast is thus made easier by having a shell of investment over the anatomic portion of the cast, which may be removed separately.

When the denture base is to be characterized by applying tinted acrylic-resins to the mold, care should be taken not to embed the wax border in the lower half of the flask. Bennett has pointed out the need for investing only to the border of the wax, leaving the entire surface that is to be tinted reproduced in the upper half of the flask. With this precaution, tinting may be carried all the way to the border, and later removal of the flask will not mar the tinted surface. If tinting is not to be done or is to be done only at the cervical margins of the teeth and the papillae, the wax border should be embedded in the lower half, where it may be faithfully reproduced and preserved during polishing.

The use of acrylic-resin materials that require trial packing is complicated by the presence of the retentive framework of the removable partial denture. With their use, trial packing must be done with two sheets of cellophane between two layers of the resin dough; otherwise, the flask could not be opened without pulling the resin away from the teeth in one half of the flask or the metal framework in the other. Acrylic-resin dough is placed in

each half of the flask, the sheets of cellophane are placed between them, and the flask is closed for trial packing. The flask is then opened, the cellophane is removed, and the excess flash is trimmed away. Trial packing should be repeated until no excess is visible. Final closure is accomplished without the intervening sheets of cellophane.

Acrylic-resin materials have been developed that require no trial packing. These are mixed as usual but may be poured into the mold or placed into the mold in a soft state. They offer little or no resistance to closure of the flask, yet the finished product is comparable with acrylic-resin materials packed in a doughy state. They must be used in some excess, with the excess escaping between the halves of the flask. Although they are soft enough to allow the escape of gross excess, the use of a land space is advisable to prevent a thin film from forming on the land area. Any film that exists on the land area after deflasking may be interpreted as an opening of the flask by that amount, hence the need for some provision for an intervening space to accommodate the excess and to facilitate its escape as the flask is closed.

To provide such a land space, the land area on the lower half of the flask may be painted with melted baseplate wax before the top half is poured. After wax elimination, a space then remains to accommodate any excess acrylic-resin remaining after the flask has been completely closed. It is necessary that no plaster or wax is allowed to remain on the rim of the flask, and that the flask makes metal-to-metal contact before the second half is poured. Only in this way is it possible to see that the flask is completely closed before it is placed in the curing unit.

Pouring of the top half of the flask follows the same procedure as that used with a complete denture. Although it is not absolutely necessary for the entire top half to be poured in stone, it is necessary for a stone cap of some type to be used to prevent tooth movement in an occlusal direction. This is so because of the inability of plaster to withstand closing pressures. All plaster remaining on the occlusal surfaces of the teeth should be removed and a separator added before the stone cap is poured to facilitate its removal during deflasking. If the use of stone investment is preferred, a shell of improved stone or die stone may be painted or applied with the fingers onto the wax and teeth and allowed to harden before the remainder of the flask is filled with plaster. If a full stone investment is preferred, some provision should be made for easy separation during deflasking. Not only should a separator stone cap be used, but metal separators or knife cuts radiating out to the walls of the flask should be placed on the partially set stone. Deflasking then is easily accomplished by removing the stone cap and inserting a knife blade between the sections of stone.

Boil out should be deferred until the investing material has set for several hours or preferably overnight. Boil out must effectively eliminate all waxy residue; an adequate source of clean hot water must be available. Immersion

of a flask containing the invested denture in boiling water for 5 minutes will adequately soften the wax supporting the artificial teeth so that flask halves may be separated and the remaining wax flushed out. After wax elimination with boiling water, the invested denture should be flushed with a solution of grease-dissolving detergent and again with clean boiling water.

Immediately after boil out, the warm mold should be painted with a thin film of tinfoil substitute, with care taken to not allow it to collect around the cervical portions of the teeth. No tinfoil substitute should be used on any part of the denture teeth. A second coat should be applied after the first coat has reasonably dried, and packing of the mold should proceed immediately after this film has dried to the touch.

When the master cast for a distal extension removable partial denture has been repoured from a secondary impression, the supporting foot on the retention frame may not necessarily be in contact with the cast. Closing pressure within the flask may distort the unsupported extension of the metal framework, with subsequent rebound on deflasking. The finished denture base will then lack contact with the supporting tissue, resulting in denture rotation about the fulcrum line, similar to that which occurs after tissue resorption. To provide support for the distal extension of the metal framework during flask closure, autopolymerizing acrylic-resin should be sprinkled or painted around the tissue stop at the distal end of the framework and allowed to harden before the denture resin continues to be packed (see Figure 5-38).

## PROCESSING THE DENTURE

Processing follows the same procedure as that used for a complete denture. Denture base characterization tinting may be added just before packing. This is most desirable if denture base material will be visible when in the mouth. Posterior acrylic-resin bases alone ordinarily do not require characterization, but the dentist should select a denture base material that closely resembles the color of the surrounding tissue. The ideal acrylic-resin base material for removable partial dentures therefore is one that (1) may be used without trial packing; (2) possesses a shade that is compatible with surrounding tissue; (3) is dimensionally stable and accurate; (4) is dense and lends itself to polishing; and (5) polymerizes completely.

There has never been any question concerning the merits of placing tinfoil over the denture before investing; this results in a tinfoil-lined matrix and eliminates the need for a separating film. The fact remains, however, that the use of a tinfoil substitute has become universal.

At best, any tinfoil substitute creates an undesirable film at the gingival margins of the teeth, resulting in microscopic separation between the teeth and the

surrounding acrylic-resin. This may be shown by sectioning a finished denture and by observing the marginal discoloration around the cervical portions of the teeth after several months in the mouth. To some extent, injection molding obviates this objection to the use of a tinfoil substitute; this is one of the principal advantages of injection molding over compression molding.

Because the use of compression molding is widespread and is likely to continue, methods are needed that eliminate the use of a tinfoil substitute. The layered silicone rubber method results in more complete adaptation of the acrylic-resin around the cervical portions of porcelain teeth and more complete bonding to acrylic-resin teeth. In addition, denture base tints may be applied directly to the mold without first applying a separating film.

A room-temperature polymerizing silicone rubber that has sufficient body and toughness for the purpose is applied to the wax surface of the denture and over the teeth. To prevent movement of the teeth during processing, the occlusal surfaces should be exposed before the upper half of the flask is poured. The manufacturer's instructions must be followed as to mixing and time elapsed before the outer stone investment is added, to ensure polymerization and bonding to the overlying investment. Boil out then is completed in the usual way.

A further advantage of the layered silicone rubber method is the ease of accomplishing deflasking. If the wax carving of the denture has been completed with care before flasking, denture tints remain unaltered by unnecessary trimming and polishing of the processed denture.

All resin base materials available up to the present time exhibit some dimensional change, both during processing and in the mouth. The fit of the denture is therefore dependent on the accuracy of the denture base material because impression and cast materials in use today are themselves reasonably accurate. In an attempt to minimize dimensional changes in the denture base, materials and techniques are being improved constantly.

Denture base materials that may be poured into the mold or placed into the mold in a soft state are also popular. This technique eliminates trial packing and excessive pressures, which lead to open flasks and altered occlusal vertical dimension as is sometimes experienced with compression molding of acrylic-resin base materials. Activated, or autopolymerizing, acrylic-resins are commonly used to prevent mold expansion at higher temperatures. Materials other than acrylic-resins are used with various techniques, some of which include styrene, vinyl, and experimentally epoxy resins. The main objective behind the development of newer techniques and materials is greater dimensional accuracy and stability, combined with improved strength and better appearance.

The use of injection molding or poured materials to process removable partial denture base materials combines accuracy and efficiency to help create a well-fitting denture base. The Success Injection System (Dentsply

Trubyte, York, PA) combines the accuracy of injection molding with Lucitone 199 (Dentsply Trubyte). The hardware consists of the injection unit, aluminum alloy flasks, and associated system flask components. The flasks are numbered; specifically, they are mated halves that need to be matched for more accurate results. The investment and processing techniques are as follows:

1. *The cast with the completed wax-up is embedded in the designated side "1" of the flask in the usual manner, placing the cast as close as possible to the back of the flask.* After any undercuts on the cast are eliminated, flattened wax sticks (approximately 7 mm in diameter) are used to build the injection sprues. For maxillary removable partial dentures, attach the sprue to the posterior border, ensuring that the sprue is sufficiently wide. For mandibular removable partial dentures, position one sprue for each base extension. Apply a separator to the investment, and place the top half of the flask on the bottom half, ensuring complete intimate metal contact and closure of the halves. Secure the flask brackets to the flask and tighten. Place the flask on the leveler with side "2" up, and complete the investing procedure in the usual manner.
2. *When the investment has set, loosen the bolts and remove the metal flask brackets.* Place the flask in boiling water (8 to 10 minutes) and complete the boil out procedure. Place the metal injection insert into the back of the flask, and slide the plastic injection socket into the metal insert as far as possible. The plastic injection socket lip should rest flush against the trim of the metal injection insert. Close the flask, position the metal flask brackets, and tighten the bolts.
3. *Use the powder/liquid vials to measure sufficient resin for the removable partial denture.* Note that the maximum powder and/or liquid that the injection cartridge can hold is 38 g (56 mL) powder and/or 17.5 mL liquid. Stir the powder and/or liquid for approximately 15 seconds. Do not excessively mix. Cover the mixing jar until the material reaches the "soft pack" stage (approximately 6 minutes). Do not allow the material to reach the "snap set" stage.
4. *Place the resin material into the plastic injection cartridge and insert the blue plastic cartridge plug into the large open end, ribbed side out.* Push the blue cartridge plug in as far as possible to compress the material, and insert the cartridge nozzle into the plastic injection socket until it seats on the injection socket's lip. Place the metal protective sleeve over the cartridge, and place the flask in the injection unit, ensuring that the bolts and the flask brackets face to the operator's right side. Position the open slots on the cartridge sleeve facing out, and then push the sleeve up toward the unit's cross-head, securing the sleeve around the blue rubber O-ring. Tighten the unit's hand wheel to secure the flask.
5. *Complete the injection process, ensuring that the mold is completely filled by viewing the blue cartridge plug*

*through the sleeve slots until the plug stops moving.* When completed, remove the flask from the unit, remove the cartridge sleeve, and pull the plastic cartridge out of the flask with a slight twist. Keep the injection socket in place inside the metal injection insert. Fit the small, blue plastic piston cap onto the end of the pressing device piston. Place the piston of the processing device into the plastic injection socket at the back of the flask, and screw the pressing device onto the metal injection insert until the etched groove is visible on the pin at the top of the pressing device.

6. *Allow the flask to sit for 30 minutes before heat-polymerizing to ensure a good bond between the denture resin and the teeth.* Submerge the closed flask in water at  $163 \pm 2^\circ \text{F}$  for  $1\frac{1}{2}$  hours. Follow with an additional 30-minute boil. An alternate polymerization method is 9 hours in a water bath of  $163 \pm 2^\circ \text{F}$  with no boil. Remove the flask from the polymerization tank and allow to air cool for approximately 30 minutes. Place the flask in a lukewarm water bath to cool completely.
7. *Unscrew the pressing device and loosen the bolts on the flask.* Remove the flask brackets and separate the flask. Remove the investment and divest the removable partial denture and cast. Cut off the injection sprue(s), and finish and polish the removable partial denture in a conventional manner.

The use of VLC denture base materials is claimed to save considerable time in providing a processed base. Manufacturers recommend the use of a light-colored cast to enhance the polymerization of the VLC material. A stone matrix must be fabricated so that the denture teeth can be positively relocated in the same position during the polymerizing process. Once the stone matrix has been completed and verified, the wax and teeth can be removed from the framework, and they can be cleaned and silicoated or coated with the resin bonding agent.

The ideal thickness for the VLC material requires a 1.5-mm space between the edentulous ridge and the retentive component of the framework. The ridge lap of the denture teeth should also be 1.5 mm above the retentive component of the framework, and the tissue side finishing line of the framework should be even with or slightly higher than the palatal side finishing line. If VLC denture base material is to be used, these requirements must be considered at the diagnosis and treatment planning stages.

Without the framework in place, a thin coat of model release agent (MRA) is applied to the denture base areas of the cast, and the VLC material is adapted to the edentulous denture base area and is trimmed to the general outline with a sharp blade. The framework is then seated firmly by being embedded into the uncured VLC material. Make certain that the rests, tissue stops, and other components of the removable partial denture framework are correctly positioned in their designated terminal positions on the cast. Remove any excess material that may

interfere with articulation of the casts or positioning of the teeth, and check to ensure that the VLC material is adapted into the tissue side finishing line of the framework on the cast. This will necessitate returning the cast with the framework to the articulator. Once this has been verified, remove the cast from the articulator and process it in the light-polymerizing unit for 2 minutes.

The denture teeth can then be secured to the stone matrix and related to the cast with the framework and the removable partial denture base. The denture teeth may have to be adjusted before the removable partial denture base can be fitted. To do this, trim the ridge lap areas of the teeth enough to provide the required 1.5 mm of space between the tooth and the denture base material. Remember that thin areas should be avoided between the framework and the cast (minimum of 1.5 mm) and between the framework and the denture teeth (minimum of 1.5 mm).

The denture tooth surfaces that are to be bonded to the VLC denture base must be lightly ground and cleaned. The teeth may then be placed in modeling compound or putty to hold them while the bonding agent is applied to all of the designated surfaces to be bonded to the VLC denture base. These coated surfaces should be allowed to sit for 2 minutes and then are processed in the light polymerization unit for 1 minute.

To secure the teeth into their designated position on the VLC denture base, apply a small piece of VLC material to each tooth with the modeling tool provided by the manufacturer. With the aid of the stone matrix and by using a high-intensity light, tack each individual tooth into position on the VLC denture base.

After tacking the teeth to the VLC denture base, paint a narrow band of bonding agent on the junction line between the teeth and the denture base material. The bonding agent acts as a sealer to prevent leakage and aids bonding of the teeth to the denture base material. Allow the bonding agent to set for 2 minutes, and then process in the light unit for 1 minute. You can now complete the buccal and lingual contouring of the denture base with additional VLC material. Paint all of the exposed surfaces of the VLC denture base material with the air barrier coating material, and process in the light polymerization unit for 2 minutes. After processing, carefully remove the removable partial denture from the cast. Do not attempt to pry it off. Paint the tissue surfaces of the edentulous areas with the air barrier coating material, and place in the light polymerization unit for 6 minutes with the tissue side up. Clean the removable partial denture with water and a brush to remove all traces of the air barrier coating. Trim and polish in a routine manner to complete the removable partial denture.

The study of the history of denture base materials is a most interesting one that has been covered elsewhere in dental literature. The future of denture base materials promises to be just as fascinating a study, but such a discussion cannot be included within the scope of this book. With newer materials, the future of methyl methacrylate as

a denture base material is uncertain despite its acceptance as the best material available since its introduction in 1937. Although it has made possible the simulation of natural tissue color and contours combined with ease of manipulation, the fact remains that it leaves much to be desired as far as accuracy and dimensional stability are concerned. Whether other and newer materials will eventually supplant methyl methacrylate as a denture base material remains to be seen. The fact is that the denture base of the future (1) must be capable of accurately reproducing natural tissue tones faithfully through the use of characterizing stains and customizing procedures; and (2) must not require elaborate processing procedures and equipment, which would make the cost prohibitive for general use.

### REMOUNTING AND OCCLUSAL CORRECTION TO AN OCCLUSAL TEMPLATE

Even with improved denture base materials and processing techniques, some movement of artificial teeth will still occur because of the dimensional instability of the wax in which the artificial teeth were arranged. Until sources of error can be eliminated, remounting will continue to be necessary. How well the occlusion may be perfected by remounting will depend on the manner in which jaw relations were transferred to an instrument and how closely the instrument is capable of reproducing functional occlusion. But even though the articulator is capable of reproducing only a static centric relation, that relation at least should be reestablished before the denture is placed.

Although it is admitted that there are limitations to the perfection of eccentric occlusion in the mouth, some believe that it can be done with more accuracy than on an instrument that is incapable of reproducing eccentric positions. Correction for errors in centric occlusion, however, should not be included in a concept that presumes that centric occlusion may be established satisfactorily by intraoral adjustment, followed then by perfecting of eccentric occlusion. Because of denture instability and the inaccessibility of the occlusion for analysis, accurate intraoral corrections are not possible. Practically, even the occlusal adjustment of natural dentition in which each tooth has its own support can best be done when preceded by an analysis of articulated diagnostic casts.

One cardinal premise must be accepted if prosthetic dentistry is to be anything more than a haphazard procedure. It is possible to transfer centric jaw relation to an instrument with accuracy and to maintain this relation throughout fabrication of the prosthesis. If this is true, then centric occlusion, coinciding with centric jaw relation, with centric occlusion of the remaining natural teeth, or with both, must have been established before initial placement of the prosthesis. This means that occlusal correction to reestablish centric relation by remounting after final processing is an absolute necessity for the success of the restoration. Remounting after

processing is accomplished by returning the cast to a keyed relationship with the articulator mounting.

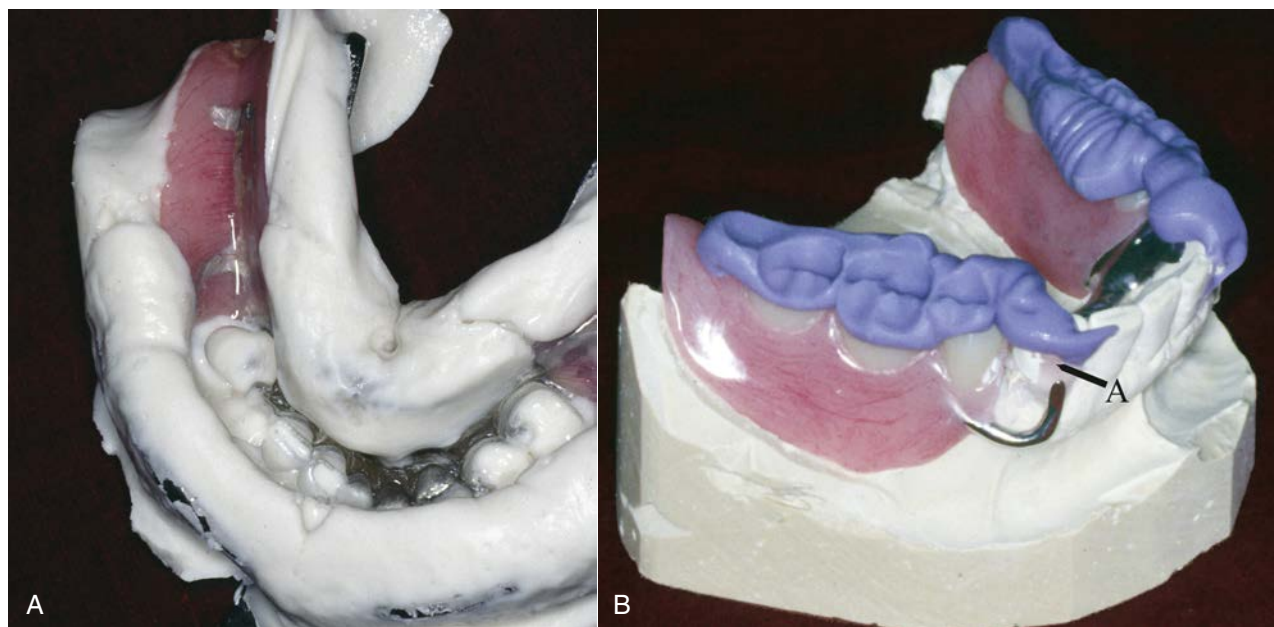
### Precautions to Be Taken in Remounting

The following precautions should be taken to ensure the accuracy of remounting to make final occlusal adjustment before polishing and initial placement of the denture. These apply to all types of occlusal relationship records but are directed particularly at remounting an occlusal template when stone vertical stops are used:

1. Make sure that the base of the cast has been reduced to fit the flask before keying and mounting so that it will not have to be altered later.
2. Bevel the margins of the base of the cast so that it will seat in a definite boxlike manner in the articulator mounting.
3. Notch the posterior and anterior aspects of the base to ensure its return to its original position. Notches at the margins are preferable to depressions within the base because the former permit a visual check of the accuracy of the remounting.
4. Lubricate lightly the base and sides of the cast before it is mounted to facilitate its easy removal from the mounting stone.
5. Add tinfoil or lightly lubricate the base and sides of the cast before flasking it so that traces of investment will not be present to interfere with remounting.
6. When remounting the cast, secure it in the articulator with sticky wax, a hot glue gun, or modeling plastic, followed by stone over both the mounting and the sides of the cast.
7. Before adjusting the occlusion, make certain that no traces of investment remain on the vertical stops.
8. Take care to not abrade the opposing occlusal surface during occlusal adjustment. The use of marking tape or inked ribbon is preferable to articulating paper. The artificial tooth is less likely to cut through and mar the opposing surface, and ink or dye will not build up a false opposing surface, as will wax from articulating paper.
9. Occlusal readjustment to an occlusal template is complete when the stone vertical stops are again in contact. With other types of articulator mountings, readjustment is complete when the vertical pin is again in contact and any valid horizontal excursions are freed of interference.

Occlusal readjustment, as with the original articulation, is done at the expense of the original tooth anatomy. Occlusal surfaces should be reshaped by adding grooves and spillways and by reducing the area of the occlusal table, thus improving the masticating efficiency of the artificial tooth. Although this may be done immediately after occlusal readjustment and before initial placement of the denture, it may be deferred until completion of the final adjustment. In any event, it is a necessary step in the completion of any removable prosthesis.

Porcelain teeth may be reshaped with abrasive or diamond-mounted points. Resin teeth lend themselves better



**FIGURE 19-41** **A**, A stock, perforated tray is used to make an irreversible hydrocolloid (alginate) impression of the denture and dental arch. Blockout of undercuts in the denture base and of tips of direct retainers is necessary, so the denture can be readily removed and replaced on the resultant remounting cast, as illustrated in **B**. **B**, Remounting cast poured in stone with the prosthesis in place and inter-occlusal registration for mounting against a maxillary cast. Wax placed at the retainer tip (**A**) allows the prosthesis to be readily removed and replaced on the cast for occlusal correction procedures that use an articulator.

to reshaping with small burs to restore functional anatomy. Either type should be repolished judiciously to prevent reduction of cuspal contacts. Although cusps may be narrowed, spillways added, and the total area of contact reduced to improve masticating efficiency, critical areas of contact, both vertical and horizontal, must always be preserved.

The term *remounting* is also applied to the mounting of a completed prosthetic restoration back into an instrument by using some kind of interocclusal records. Discrepancies in occlusion resulting from processing of tooth-supported dentures may be corrected by reattaching the indexed processing cast and denture to the same instrument on which the occlusion was formulated. However, because of some instability inherent in distal extension removable partial dentures, such dentures should be retrieved from processing investment, finished, and polished and prepared for performance of occlusal corrections with the use of new intraoral records. The dentist must make a remounting cast before occlusal corrections can be accomplished. This is done simply first by placing the denture in the mouth and making an irreversible hydrocolloid (alginate) impression of the denture and the remaining teeth in the arch (Figure 19-41). When the impression is removed, the denture usually remains in the impression or can be accurately replaced. Undercuts in the denture bases are blocked out, the retentive elements of the framework are covered with a thin layer of molten wax, and a remounting cast is poured in the impression. The remounting casts are then oriented in the articulator by the same type of interocclusal records that were used

to orient the casts to formulate the occlusion. These procedures are covered in Chapter 21 as an integral part of the initial placement appointment.

Occlusal harmony must exist before the patient is given possession of the dentures. Delaying the correction of occlusal discrepancies until the dentures have had a chance to settle is not justifiable.

## POLISHING THE DENTURE

Areas to be considered in the polishing of a removable partial denture are (1) the borders of the denture bases; (2) the facial surfaces; and (3) the teeth and adjacent areas.

The borders on complete metal bases will have been established previously. On partial metal bases and complete acrylic-resin bases, the accuracy with which the border may be finished depends on the accuracy of the impression record and how well this was preserved on the stone cast. Edentulous areas recorded from impressions in stock trays generally lack the accuracy at the borders that is found on casts made from impressions in individualized trays and by secondary impression methods. Border accuracy is determined also by whether or not the impression recorded a functional or a static relationship of the bordering tissue attachments.

### Denture Borders

The principal objectives to be considered in making an impression of edentulous areas of a partially edentulous

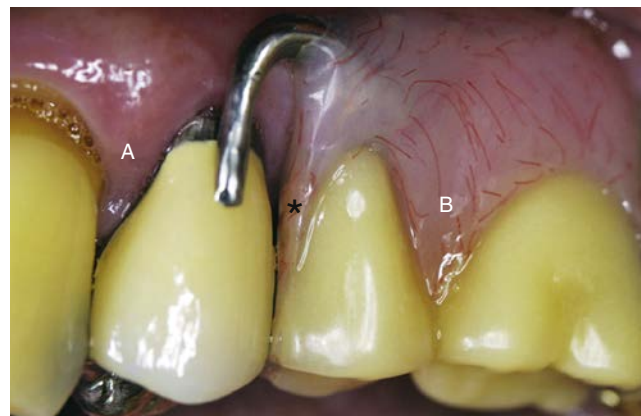
arch include (1) maximal support for the edentulous removable partial denture base; and (2) extension of the borders to obtain maximum coverage compatible with moving tissue. Although this second objective may be met with an adequate individualized impression tray, it is best accomplished with a secondary impression method. Not only the extent of the border, but also its width, should be recorded accurately. Both extent and width as recorded should be preserved on the stone cast. With the exception of certain areas that are arbitrarily thinned by polishing (mentioned previously in this chapter), finishing and polishing the denture borders should consist only of removing any flash and artifact blebs. Otherwise, borders should be left as recorded in the impression.

When the impression is made in a stock tray, the tray itself will have influenced both the extent and the width of the border. Some areas will be left short of the total area available for denture support, whereas others will be extended beyond functional limits by overextension of the tray. Unfortunately, the technician may attempt to interpret the anatomy of the mouth and arbitrarily trim the denture borders. This presumes that the technician has an intimate knowledge of the anatomy of the mouth of the patient for whom the restoration is being made, which is most unlikely. The dentist must correct any overextension remaining after arbitrarily trimming the border from cast landmarks in the mouth. It is preferable for the dentist to finish the borders of dentures, having painstakingly developed them during impression procedures.

### Facial Surfaces

The facial surfaces of the denture base are those polished surfaces lying between the buccal borders and the supplied teeth. Methods have been proposed for making sectional impression records of buccal contours, thereby permitting the denture base to be made to conform to the facial musculature. These have never received wide acceptance and may be considered impractical in removable partial prosthodontics.

Facial surfaces may be established in wax or may be carved into the denture base after processing. Generally, it is desirable that it be done in wax as part of the wax pattern, because it is easier to do so and because contours can best be established at a time when modifications can be made if desired. Buccal surfaces should be contoured to aid in retention of the denture by border molding, to preserve the border roll and thereby prevent food impaction, and to facilitate return of the food bolus back onto the masticating table. Lingual surfaces should be made concave to provide tongue room and to aid in retention of the denture. Polishing of concave surfaces is always more difficult than polishing of flat and convex surfaces. If such contours are established previously in wax, not only is finishing more easily accomplished, but border and gingival areas are less likely to be inadvertently altered.



**FIGURE 19-42** Attention to adjacent tooth-tissue contours can facilitate the production of natural-appearing prostheses. The interproximal papilla at A demonstrates both vertical and horizontal components. In general, the horizontal component increases with age. The prosthetic interproximal papilla at B exhibits only a vertical component and appears artificial. The anterior border (\*) contour is blunted and provides an obvious and abrupt contour change. Contouring the border to bevel into the interproximal region reduces its objectionable appearance.

### Finishing Gingival and Interproximal Areas

The contouring of gingival and interproximal areas after processing is difficult and generally unsatisfactory (Figure 19-42).

Modern cosmetic considerations demand that gingival carving be done around each tooth individually, with variations in the height of the gingival curve and in the length of the papillae. Interproximally, the papillae should be convex rather than concave. The gingival attachment should be free of grooves and ditches that would accumulate debris and stain and should be as free for cleansing as possible. All this precludes gross shaping and trimming of gingival areas after processing. Gingival carving should be done in wax, and investing should be done with care to prevent blebs and artifacts. Finishing should consist only of trimming around the teeth and the papillae with small round burs to create a more natural simulation of living tissue, plus light stippling with an off-center round bur for the same reason. Polishing should consist only of light buffing with brush wheels and pumice, and finally with a soft brush wheel and a nonabrasive polishing agent specially made for this purpose.

Pumicing of gingival areas can only serve to polish the high spots; although it may be done lightly, its use should be limited to light buffing of areas already made as smooth as in the waxing phase. Heavy pumicing of the denture resin not only creates a typical denture look but also alters the delicately carved wax surface and any plastic teeth present. If pumicing must be done, plastic teeth should be protected with adhesive masking tape during the process.

Any polishing operation on a removable partial denture done on a lathe is made hazardous by the presence of direct retainers, which can easily become caught in the polishing

wheel. Although the least damage that might occur is the distortion of a clasp arm, there is a greater possibility that the denture may be thrown forcibly into the lathe pan, with serious damage to the framework or other parts of the denture. The technician must ever be conscious of this possibility and must always cover any projecting clasp with the finger while it is near the polishing wheel. In addition, it is wise to keep a pumice pan well filled with wet pumice to cushion the

shock should an accident occur. Any other lathe pan used in polishing should be lined with a towel or with a resilient material for the same reason. The potential hazard of retainers catching gloved fingers or hands that hold a removable partial denture is always present. Serious injury can result, and extreme caution must be taken to prevent such an occurrence. The risk of infection is increased if the removable partial denture has been in place intraorally.

# CHAPTER 20

## Work Authorizations for Removable Partial Dentures

### CHAPTER OUTLINE

**Work Authorization**

- Content
- Function
- Characteristics

**Definitive Instructions by Work Authorizations**

**Legal Aspects of Work Authorizations**

**Delineation of Responsibilities by Work Authorizations**

### WORK AUTHORIZATION

A work authorization contains the written directions for laboratory procedures to be performed for fabrication of dental restorations. The responsibility of a dentist to the public and to the dental profession to safeguard the quality of prosthodontic services is controlled in part through meaningful work authorizations. If work authorizations are properly completed, they provide a means for increased professional quality assurance and satisfaction in a removable partial denture service.

A work authorization completed by a dentist is similar to granting power of attorney. It grants authority for others to act on the dentist's behalf and specifically prescribes what is authorized.

When properly executed, work authorizations are effective channels of communication. They enhance the quality of the completed restorations by providing instructions for individually and scientifically considered prostheses.

#### Content

Information contained in a work authorization should include the following: (1) the name and address of the dental laboratory; (2) the name and address of the dentist who initiates the work authorization; (3) the identification of the patient; (4) the date of work authorization; (5) the desired completion date of the request; (6) specific instructions; (7) the signature of the dentist; and (8) the registered license number of the dentist. All these requirements can be accommodated in a simply designed form (Figure 20-1).

#### Function

The following four important functions are performed by a work authorization:

1. It furnishes definite instructions for laboratory procedures to be accomplished and implies an expectation of a level of acceptable quality for the services rendered.

## Removable Partial Prosthodontics

Patient name: \_\_\_\_\_

Patient number: \_\_\_\_\_

Student name: \_\_\_\_\_

Student number: \_\_\_\_\_

☐

Treatment plan

☐

Laboratory instructions

Diagram of the maxillary dental arch. Teeth are numbered 1 through 16 from the right (R) to the left (L). The central incisors are 1 and 16, and the second molars are 6 and 11.

Design specifications:

1. Rests

2. Retention

3. Reciprocation

4. Major connector

5. Indirect retention

6. Guide planes

7. Base retention

8. Areas to be modified or contoured

Diagram of the mandibular dental arch. Teeth are numbered 17 through 32 from the right (R) to the left (L). The central incisors are 26 and 23, and the second molars are 29 and 21.

**Color code:**

**Blue: Cast metal**

**Red: Resin base and wrought wire**

**Green: Areas to be contoured**

Instructor: \_\_\_\_\_

Approval to send to laboratory: \_\_\_\_\_ Date: \_\_\_\_\_

**FIGURE 20-1** Work authorization form, designed specifically for removable partial dentures, to furnish detailed information to the laboratory technician. Form used to specifically plan framework design and to designate mouth alterations and preparations.

2. It provides a means of protecting the public from the illegal practice of dentistry.
3. It is a protective legal document for both the dentist and the dental laboratory technician.
4. It completely delineates the responsibilities of the dentist and the dental laboratory technician.

## Characteristics

A work authorization must be legible, clear, concise, and readily understood. It is unreasonable to assume that laboratory technicians are decoding experts. Sufficient information

must be included in a work authorization to enable the technician to understand and execute the request. Many dentists are overly presumptive in assuming that a request can be acceptably fulfilled without proper directions.

It is sound practice to provide the dental laboratory technician with adequate written instructions for each laboratory service required in the fabrication of a restoration. Therefore a new work authorization should accompany the material returned to the laboratory for continuing progress to complete the restoration. In a modern dental practice, it is highly improbable that a one-trip laboratory service

Removable Partial Prosthodontics

Patient name: John Doe

Student name: Joe Smith

Patient number: 158390

Student number: 1234

☐ Treatment plan

7

8

9

10

11

12

13

14

15

16

11

10

9

8

7

6

5

4

3

2

1

R

L

32

31

30

29

28

27

26

25

24

23

22

21

20

19

18

17

R

L

12 ga

18 ga loops

Cast I-bar

18 ga loops

12 ga

Cast I-bar

Copyright Attachments International, Inc.

☐ Laboratory instructions

Design specifications:

1. Rests  
Cingulum rests #22, #27  
MO occlusal rest #20  
MO occlusal rest #28

2. Retention  
I-bar clasp #28  
I-bar clasp #22

3. Reciprocation  
Lingual plate #22, #27, #28

4. Major connector  
Lingual bar

5. Indirect retention  
Cingulum rest #22, #27

6. Guide planes  
Distal #20, #22, #27  
Mesial #20

7. Base retention  
18 ga. loops, 12 ga. inferior border

8. Areas to be modified or  
contoured  
Metal tooth to replace #21

Color code:

Blue: Cast metal

Red: Resin base and wrought wire

Green: Areas to be contoured

Instructor: \_\_\_\_\_

Approval to send to laboratory: \_\_\_\_\_ Date: 2/15/09

**FIGURE 20-2** This work authorization accompanies a master cast on which the dentist has designed and drawn an outline for a removable partial denture framework. It is simple and is not time-consuming to execute, yet it furnishes detailed information so the request can be properly fulfilled.

will be adequate to provide a truly professional removable restoration.

No single work authorization form is adequate to furnish detailed instructions for accomplishing the laboratory phases in the fabrication of removable partial dentures, crowns, and fixed partial dentures, or complete dentures, or for accomplishing orthodontic laboratory procedures. Inherent differences in the many types of restorations themselves and differences in the laboratory phases necessary for their fabrication establish a requirement for individual work authorization forms.

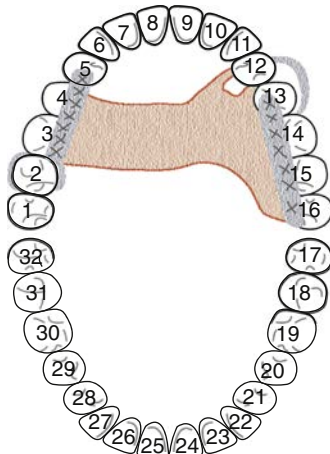
**DEFINITIVE INSTRUCTIONS BY WORK AUTHORIZATIONS**

Work authorization forms may be designed so that only a minimum of writing is necessary to provide thorough instructions (Figure 20-2). The form can contain printed listings of materials and specifications that require either a checkmark or a fill-in for authorization of their use.


Another effective means for communicating, which provides anatomical detail not available when drawing on paper, includes drawing the design on a diagnostic cast. Exact location

Telegram: @uni\_k

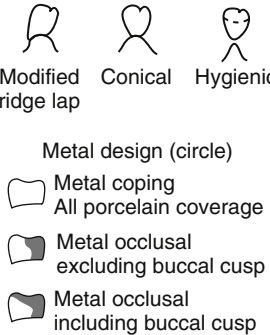
Patient name John Doe Denture identification J. Doe  
 Date submitted 6/1/15 Date required 6/15/15  
 Laboratory name \_\_\_\_\_  
 Laboratory address \_\_\_\_\_  
 Metal type Cr-Co Shade \_\_\_\_\_ Guide \_\_\_\_\_



Indicate characterizations



Pontic design (circle)



Metal design (circle)

WHITE – Department      YELLOW – Lab      PINK – Patient Record

**Rx** Please fabricate max. RPD framework as drawn on design cast

- Rests: No occlusal rests #2, 12  
Do occlusal rest #5
- Retention: I-bar clasp #12  
0.010" mid buccal undercut  
Cast circum clasp #2  
0.010" DB undercut
- Reciprocation: Lingual clasp #2
- Major connector: Palatal strap
- Base retention: Mesh #3-4, #13-15
- Guide planes: Mesial #2  
Distal #5, 12

Thank You!

Signature John Smith

License number 1234

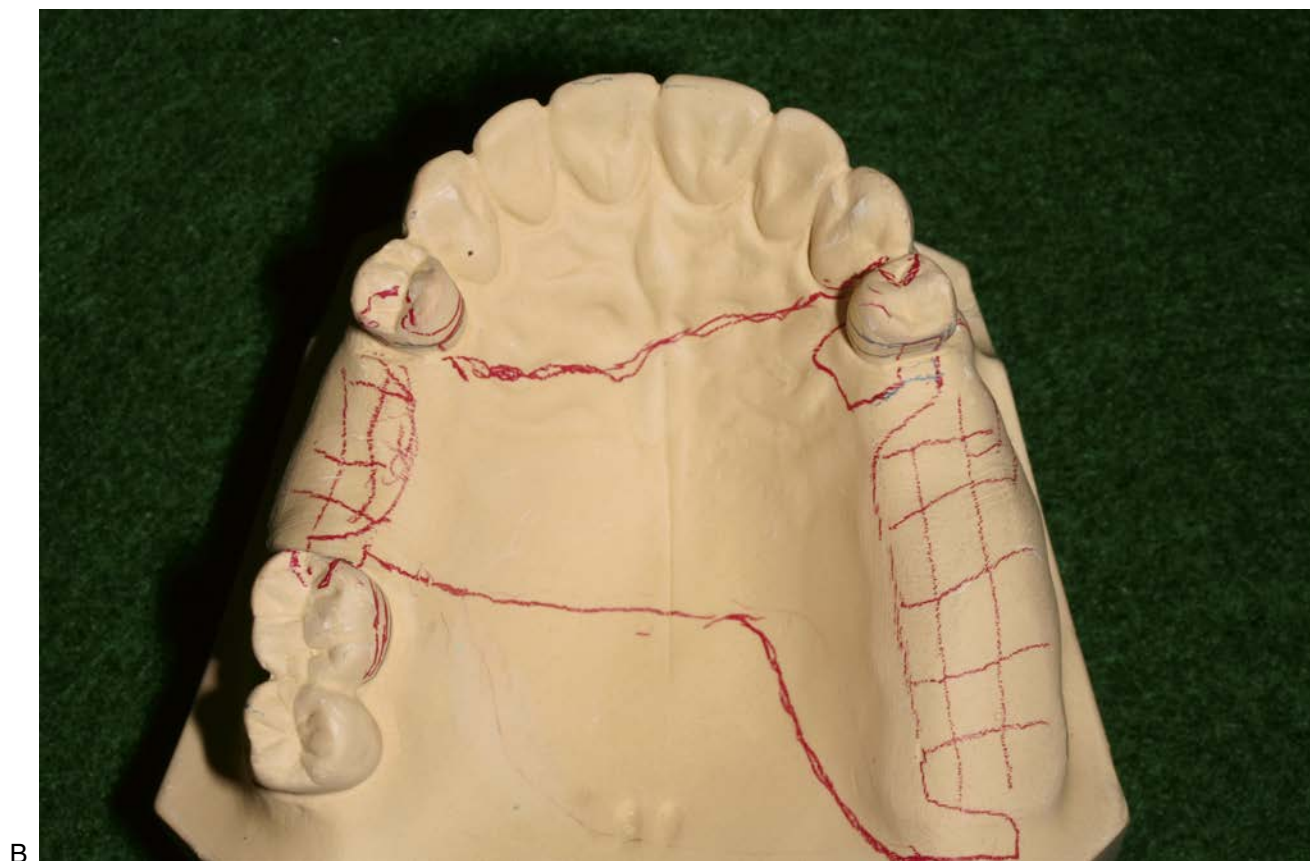
**FIGURE 20-3** A. This work authorization will accompany design and master casts. The dentist will submit a design cast with an outline for the removable partial denture frame. It is simple and is not time consuming, yet it furnishes detailed information so the request can be properly fulfilled.

of rests, proximal plates, major/minor connectors, and clasps augment the written work authorization request (Figure 20-3).

A reminder space is included to designate the choice of metal for the framework. Frameworks for removable partial dentures are usually cast in type IV gold, chromium-cobalt alloy, or a titanium alloy. The nature of the material of the denture base may also be indicated by a checkmark. It is difficult to elicit this information from the markings on master casts.

Space is reserved on the work authorization form to furnish the technician with information on the dentist's selection of teeth. The responsibility for tooth selection must remain with the dentist. The success of the removable partial denture depends in part on the consideration given to the size, number, and placement of the artificial teeth and to the material from which they are made.

A display of courtesy deserved by and a demonstration of respect for the laboratory technician are indicated.



**FIGURE 20-3 CONT'D B.** Occlusal view of the design cast, with the outline of the removable partial denture framework drawn. The path of placement is indicated on the cast, as well as the height of contour and location of retentive clasp undercuts, and location of guide planes, rests, and clasp locations.

The general request is prefaced by “please” and the specific instructions are ended with “thank you.” Do any other three words promote better relations?

A good work authorization form not only ensures clarity but also simplifies correct execution. Figures can be provided on which diagrams may be drawn to enhance written descriptions when necessary. These diagrams may show the occlusal and lingual surfaces of the posterior teeth and the lingual surfaces of the anterior teeth. The palatal region of the maxillary arch and the lingual slopes of the mandibular alveolar ridge can also be included. These features allow a clear, diagrammatic representation of the locations of major connectors, which will complement the outline of the framework on the master cast.

A color-code index can be used to explain the markings on the master cast when it is submitted to the laboratory for the fabrication of a framework. For example, a green pencil can be used to outline the framework; red to designate the desired location of finishing lines on the framework; and black lines to denote the height of contour on teeth and soft tissue created during the survey of the cast. The color code

eliminates confusion in interpreting the markings on the master cast.

Specifications for waxing the framework components for gold, chromium-cobalt, or titanium alloy castings must be furnished for the technician and are an integral part of the work authorization form. Specifications that are adequate for most removable partial denture frameworks may be listed. This feature alone saves time and effort in preparing the work authorization and serves as a handy reference for the laboratory technician. The listing of average specifications does not preclude altering a specification when the situation necessitates other characteristics in a given component.

The specific instructions provided in a work authorization must be so constructed that they will be a constant source of direction and supervision for the laboratory phases of a removable partial denture service. Instructions should leave no doubt about the dentist's requirements in a request for laboratory services. It is foolish to use undercut dimensions of 0.01 or 0.02 inch when a master cast is surveyed, unless written directions are included to incorporate these dimensions into the finished framework.

Work authorization blanks should be available in such a manner that a duplicate can be conveniently made and thus a copy can be supplied for both the dentist and the dental laboratory technician. The original may be a different color than the duplicate for ready identification.

### LEGAL ASPECTS OF WORK AUTHORIZATIONS

Although the National Association of Dental Laboratories (NADL) provides guidelines for statutory regulation, it is the inherent right of each state to implement its own regulation. Fortunately, all states exercise this control. Interpretations of acts that constitute the practice of dentistry are moderately uniform. However, statutory restrictions on dental laboratory operations vary from state to state. Properly executed work authorizations serve to document communication and protect the professional relationship between the dentist and the dental laboratory.

Many states require that work authorizations be made in duplicate and that both the dentist and the dental laboratory technician retain a copy for a specified period from the date of work authorization. Thus, documents are available to substantiate or refute claims and counterclaims that concern the illegal practice of dentistry, or to aid in the settlement of misunderstandings between a dentist and a dental laboratory technician.

### DELINEATION OF RESPONSIBILITIES BY WORK AUTHORIZATIONS

The dentist is responsible for all phases of a removable partial denture service in the strict sense of the word, although the dental laboratory technician may be requested to perform certain technical phases of the service. However, the laboratory technician is responsible only to the dentist and never to the patient. A dentist who relegates the design of a removable partial denture to a less qualified individual accepts the possibility of and responsibility for an inferior removable partial denture service.

A dentist who imposes on auxiliary personnel those responsibilities that legally and morally belong with the dentist does a great injustice to the patients, the technicians, and the dental profession. There is little doubt that the illegal practice of dentistry and the presently existing impasse

between dentist and some dental laboratory technicians are in part a result of many individual dentists who impose unrealistic responsibility on laboratory technicians. Furthermore, this unwelcome relationship may have been caused by the submission of poor impressions, casts, records, and instructions to the laboratory technician, with the demand of impossible quality in the returned restoration under threat of economic boycott.

Most dental laboratory technicians are ethical and earnestly desire to contribute their talents to the dental profession. The dental profession is vitally interested in increasing the number of serious-minded dental auxiliary personnel to share in providing oral health care. However, until the dental profession elevates itself in the eyes of laboratory technicians and also elevates the stature of dental laboratory technology, greater availability of responsible auxiliary personnel is more fancied than real.

The dental laboratory technician is a member of a team whose objectives are the prevention of oral disease and the maintenance of oral health as adjuncts to the physical and mental well-being of the public. A good dental laboratory technician is a valuable team member working with the dentist and contributes much to the team effort in providing oral health care for patients. The degree and quality of the team effort are the responsibility of the dentist and depend on the dentist's knowledge, experience, technical skill, administrative ability, integrity, and ability to communicate effectively.

A dentist may delegate much of the laboratory phase of a removable partial denture service. Work authorizations help fulfill the moral obligation to supervise and direct those technical phases that can be accomplished by dental laboratory technicians. Substantial indications suggest that many members of the dental profession either are not cognizant of the rewards of writing good work authorizations or are not proficient in their execution. It is not a secret that some dentists do not submit instructions when availing themselves of commercial dental laboratory services.

If the practice of prosthodontics is to remain in the control of dentists, each member of the dental profession must avoid delegating responsibility to those who are less qualified to accept the responsibility. Movements to allow denturism are seemingly becoming more prevalent and possibly are related to poor laboratory communication regarding removable prosthodontics.

# CHAPTER

# 21

## Initial Placement, Adjustment, and Servicing of the Removable Partial Denture

### CHAPTER OUTLINE

Adjustments to Bearing Surfaces of Denture Bases  
Occlusal Interference from Denture Framework  
Adjustment of Occlusion in Harmony with Natural and Artificial Dentition  
Instructions to the Patient  
Follow-Up Services

Initial placement of the completed removable partial denture, which is the fifth of six essential phases of removable partial denture service mentioned in Chapter 2, should be a routinely scheduled appointment. All too often the prosthesis is quickly placed and the patient dismissed with instructions to return when soreness or discomfort develops. Patients should not be given possession of removable prostheses until denture bases have been initially adjusted as required, occlusal discrepancies have been eliminated, and patient education procedures have been continued.

Although it is true that some accommodation is a necessary part of adjusting to new dentures, many other factors are also pertinent. Among these are how well the patient has been informed of the mechanical and biological problems involved in the fabrication and wearing of a removable prosthetic restoration, and how much confidence the patient has acquired in the excellence of the finished product. Knowing in advance that every step has been carefully planned and executed with skill and having acquired confidence in both the dentist and the excellence of the prosthesis, the patient is better able to accept the adjustment period as a necessary but transient step in learning to wear the prosthesis. This confidence could be lost if the dentist does not approach the insertion and postinsertion phases as equally important for the success of the treatment.

The term *adjustment* has two connotations, each of which must be considered separately. The first is adjustment of the denture bearing and occlusal surfaces of the denture made by the dentist at the time of initial placement and thereafter. The second is the adjustment or accommodation by the patient, both psychologically and biologically, to the new prosthesis.

After the resin bases have been processed and before dentures are separated from the casts, the occluding teeth must be altered to perfect the occlusal relationship between

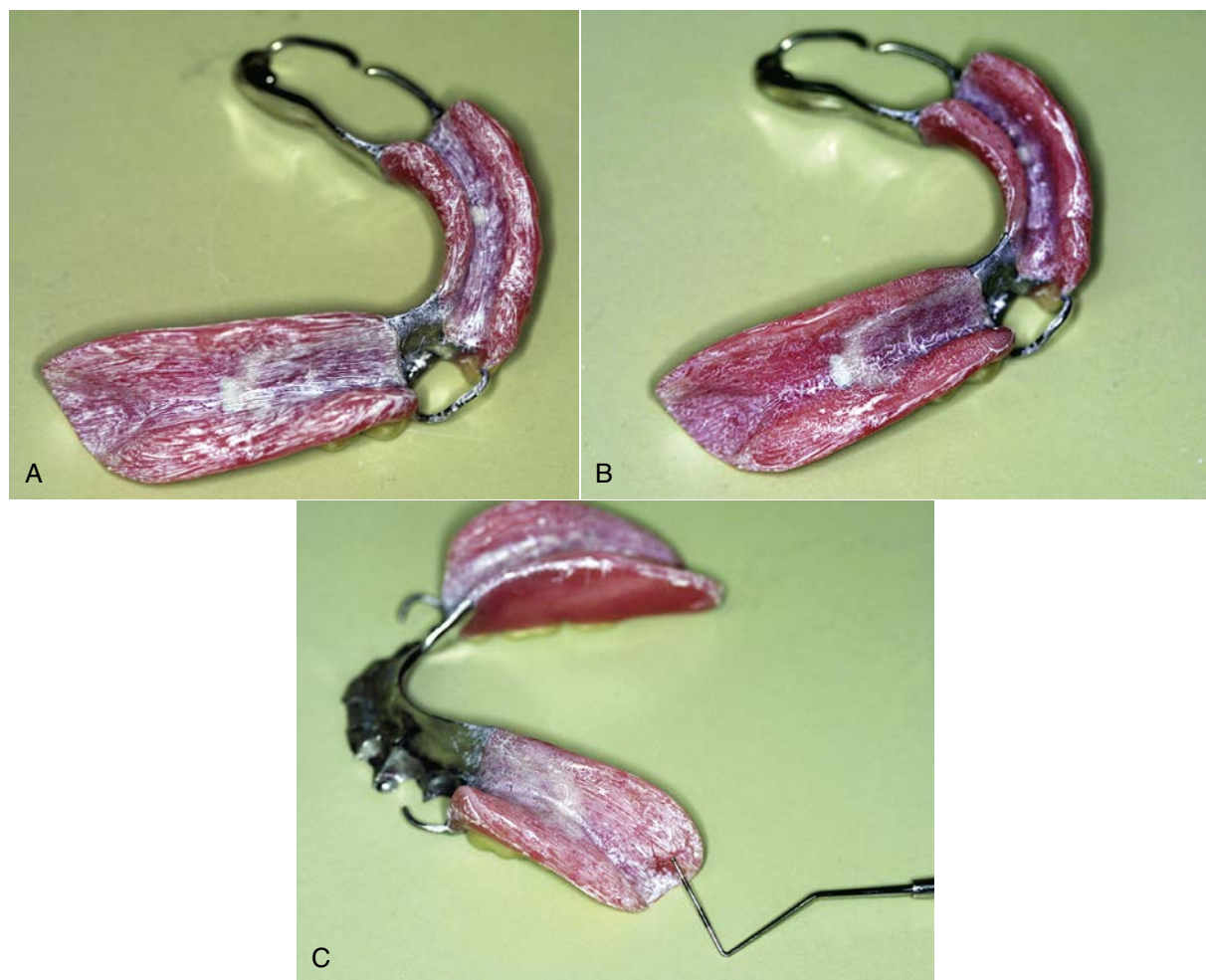
opposing artificial dentition or between artificial dentition and an opposing cast or template. Denture bases must be finished to eliminate excess and perfect the contours of polished surfaces for the best functional and esthetic results. This is made necessary by the inadequacies of casting procedures, because both the metal and resin parts of a prosthetic restoration are produced by casting methods. Unfortunately, such procedures in the laboratory rarely eliminate the need for final adjustment in the mouth to perfect the fit of the restoration to the oral tissue.

Included in this final step in a long sequence of finishing procedures necessary to produce a biologically acceptable prosthetic restoration are the following: (1) adjustment of the

bearing surfaces of the denture bases to be in harmony with the supporting soft tissue; (2) adjustment of the occlusion to accommodate the occlusal rests and other metal parts of the denture; and (3) final adjustment of the occlusion on the artificial dentition to harmonize with natural occlusion in all mandibular positions.

### ADJUSTMENTS TO BEARING SURFACES OF DENTURE BASES

Altering bearing surfaces to perfect the fit of the denture to the supporting tissue should be accomplished with the use of some kind of indicator paste (Figure 21-1). The paste



**FIGURE 21-1** **A**, Tissue side of finished bases of a Kennedy Class I modification 1 removable partial denture, where paste indicates that pressure has been applied. Paste was applied following careful inspection of the tissue surface for irregularities or sharp projections, which must be eliminated before fitting in the mouth. The entire tissue surface of the bases was dried before it was coated with a thin coat of pressure indicator paste using a stiff-bristle brush. Brush marks are evident, and it is the change in the pattern of brush marks that guides adjustment. It is important to avoid thick application of indicator paste, which can hide the presence of significant pressure. **B**, The prosthesis can be dipped in cold water or sprayed with a provided release agent before placement in the patient's mouth, to prevent paste from sticking to oral tissues. After careful seating of the denture, the patient can close firmly on cotton rolls for a few seconds, or the dentist can alternately apply a tissue-ward pressure over the bases to simulate functional movement. The presence of tissue contact is evident in the pattern of the paste, which is different from the brushed pattern. There is no suggestion of excessive pressure in this tissue contact pattern. However, it is not uncommon to relieve the area adjacent to the abutment sparingly. Several placements of the denture with indicator paste are usually necessary for evaluation of the accuracy of the bases. **C**, A different denture base recovered from the mouth after manipulation simulating function. The tissue contact reveals excessive pressure at the region lingual to the retromolar pad.

must be one that will be readily displaced by positive tissue contact and that will not adhere to the tissue of the mouth. Several pressure indicator pastes are commercially available. However, equal parts of a vegetable shortening and USP zinc oxide powder can be combined to make an acceptable paste. The components must be thoroughly spatulated to a homogeneous mixture. A quantity sufficient to fill several small ointment jars may be mixed at one time.

Rather than dismissing the patient with instructions to return when soreness develops and then over-relieving the denture for a traumatized area to restore patient comfort, use a pressure indicator paste with any tissue bearing prosthetic restoration. The paste should be applied by the dentist in a thin layer over the bearing surfaces. The material should be rinsed in water so that it will not stick to the soft tissue, and then digital pressure should be applied to the denture in a tissue-ward direction. The patient cannot be expected to apply a heavy enough force to the new denture bases to register all of the pressure areas present. The dentist should apply both vertical and horizontal forces with the fingers in excess of what might be expected of the patient. The denture is then removed and inspected. Any areas where pressure has been heavy enough to displace a thin film of indicator paste should be relieved and the procedure repeated with a new film of indicator until excessive pressure areas have been eliminated. This is particularly difficult to interpret when patients exhibit xerostomia. An area of the denture base that shows through the film of indicator paste may be erroneously interpreted as a pressure spot, when actually the paste had adhered to the tissue in that area. Therefore, only those areas that show through an intact film of indicator paste should be interpreted as pressure areas and relieved accordingly. The decision to relieve an area of pressure must consider whether the pressure is in a primary, secondary, or nonsupportive denture bearing area. The primary denture bearing areas should be expected to show greater contact than other areas.

Pressure areas most commonly encountered are as follows: in the mandibular arch—(1) the lingual slope of the mandibular ridge in the premolar area; (2) the mylohyoid ridge; (3) the border extension into the retromylohyoid space; and (4) the distobuccal border in the vicinity of the ascending ramus and the external oblique ridge; in the maxillary arch—(1) the inside of the buccal flange of the denture over the tuberosities; (2) the border of the denture lying at the malar prominence; and (3) the point at the pterygomaxillary notch where the denture may impinge on the pterygomandibular raphe or the pterygoid hamulus. In addition, bony spicules or irregularities in the denture base that will require specific relief may be found in either arch.

The amount of relief necessary depends on the accuracy of the impression, the master cast, and the denture base. Despite the accuracy of modern impression and cast materials, many denture base materials leave much to be desired in this regard, and the element of technical error is always present. It is therefore essential that discrepancies in the denture base are detected and corrected before the tissues of the

mouth are subjected to the stress of supporting a prosthetic restoration. One of our major responsibilities to the patient is that trauma should always be held to a minimum. Therefore the appointment time for initial placement of the denture must be adequate to permit such adjustment.

## OCCUSAL INTERFERENCE FROM DENTURE FRAMEWORK

Any occlusal interference from occlusal rests and other parts of the denture framework should have been eliminated before or during the establishment of occlusal relations. The denture framework should have been tried in the mouth before a final jaw relation is established, and any such interference should have been detected and eliminated. Much of this need not occur if mouth preparations and the design of the removable partial denture framework are carried out with a specific treatment plan in mind. In any event, occlusal interference from the framework should not ordinarily require further adjustment at the time the finished denture is initially placed. For the dentist to have sent an impression or casts of the patient's mouth to the laboratory and to receive a finished removable partial denture prosthesis without having tried the cast framework in the mouth is a dereliction of responsibility to the patient and the profession.

## ADJUSTMENT OF OCCLUSION IN HARMONY WITH NATURAL AND ARTIFICIAL DENTITION

The final step in the adjustment of the removable partial denture at the time of initial placement is adjustment of the occlusion to harmonize with the natural occlusion in all mandibular excursions. When opposing removable partial dentures are placed concurrently, the adjustment of the occlusion will parallel to some extent the adjustment of occlusion on complete dentures. This is particularly true when the few remaining natural teeth are out of occlusion. But where one or more natural teeth may occlude in any mandibular position, those teeth will influence mandibular movement to some extent. It is necessary, therefore that the artificial dentition on the removable partial denture be made to harmonize with whatever natural occlusion remains.

Occlusal adjustment of tooth-supported removable partial dentures may be performed accurately by any of several intraoral methods. Occlusal adjustment of distal extension removable partial dentures is accomplished more accurately with the use of an articulator than by any intraoral method. Because distal extension denture bases will exhibit some movement under a closing force, intraoral indications of occlusal discrepancies, whether produced by articulating paper or disclosing waxes, are difficult to interpret. Distal extension dentures positioned on remounting casts can conveniently be related in the articulator with new, nonpressure interocclusal records, and the occlusion can be adjusted accurately at the appointment for initial placement of the dentures (Figure 21-2).

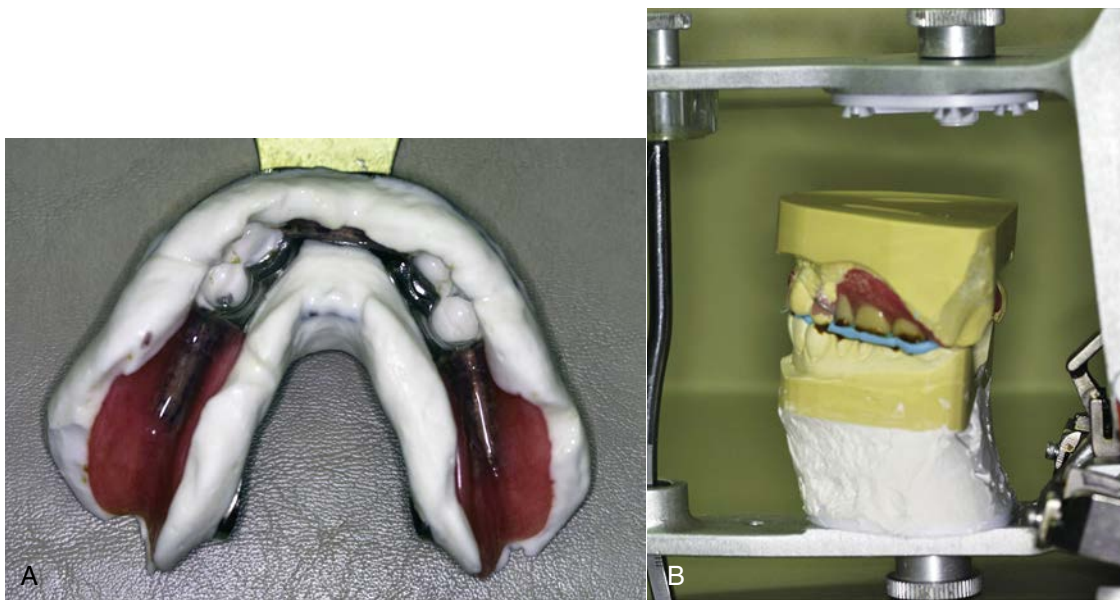
The methods by which occlusal relations may be established and recorded have been discussed in Chapter 18.

In this chapter, the advantages of establishing a functional occlusal relationship with an intact opposing arch have been discussed, along with the limitations that exist to perfecting harmonious occlusion on the finished prosthesis by intraoral adjustment alone. Even when the occlusion on two opposing removable partial dentures is adjusted, it is best that one arch be considered an intact arch and the other one adjusted to it. This is accomplished by first eliminating any occlusal interference with mandibular movement imposed by one denture and adjusting any opposing natural dentition to accommodate the prosthetically supplied teeth. Then the opposing removable partial denture is placed, and occlusal adjustments are made to harmonize with both the natural dentition and the opposing denture, which is now considered part of an intact dental arch. Which removable partial denture is adjusted first, and which is made to occlude with it, is somewhat arbitrary, with the following exceptions: If one removable partial denture is entirely tooth-supported and the other has a tissue-supported base, the tooth-supported denture is adjusted to final occlusion with any opposing natural teeth. That arch is then treated as an intact arch and the opposing denture adjusted to occlude with it. If both removable partial dentures are entirely tooth-supported, the one that occludes with the most natural teeth is adjusted first and the second denture is then adjusted to occlude with an intact arch. Tooth-supported segments of a tooth- and tissue-supported

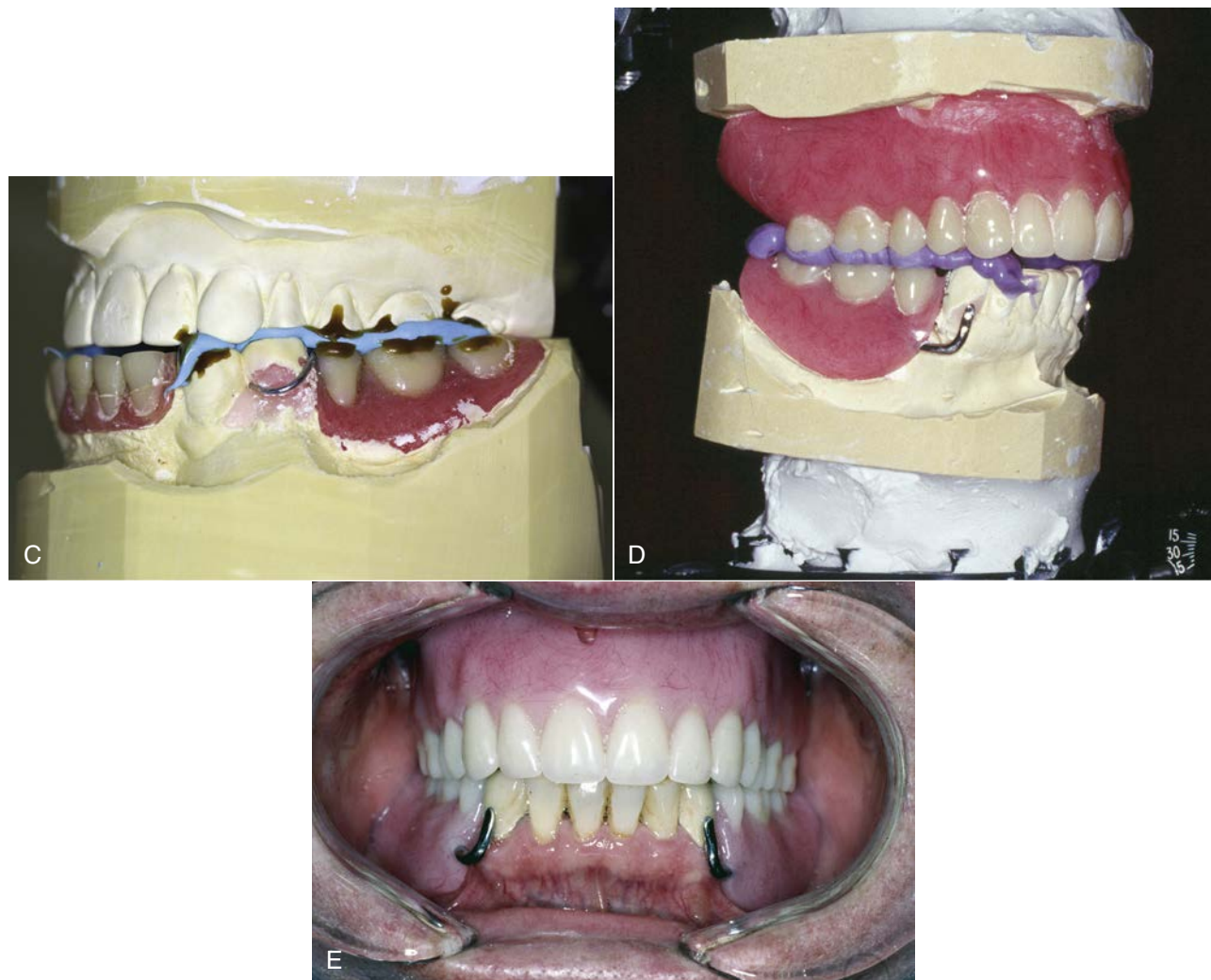
removable partial denture are likewise adjusted first to harmonize with any opposing natural dentition. The final adjustment of occlusion on opposing tissue-supported bases is usually done on the mandibular removable partial denture because this is the moving member, and the occlusion is made to harmonize with the maxillary removable partial denture, which is treated as part of an intact arch.

Intraoral occlusal adjustment is accomplished with the use of some kind of indicator and suitable mounted points and burs. Diamond or other abrasive points must be used to reduce enamel, porcelain, and metal contacts. These also may be used to reduce plastic tooth surfaces, but burs may be used for plastic with greater effectiveness. Articulation paper may be used as an indicator if one recognizes that heavy interocclusal contacts may become perforated, leaving only a light mark. Secondary contacts, which are lighter and frequently sliding, may make a heavier mark. Although articulation ribbon does not become perforated, it is not easy to use in the mouth, and differentiation between primary and secondary contacts is difficult, if not impossible, to ascertain.

In general, occlusal adjustment of multiple contacts between natural and artificial dentition when tooth-supported removable partial dentures are involved follows the same principles as those for natural dentition alone. This is because removable partial dentures are retained by devices attached to the abutment teeth, whereas no mechanical



**FIGURE 21-2** Sequence of laboratory and clinical procedures performed for correction of occlusal discrepancies caused by processing of removable partial dentures. The arch with the prosthesis will require a new cast and record to provide occlusal correction. If it is a maxillary prosthesis, this involves preserving the facebow record by replacing the processed maxillary removable partial denture and cast on the articulator and indexing the occlusal surfaces using a remount jig, or making another facebow record at the try-in appointment. If it is a mandibular prosthesis, the opposing arch can be prepared before insertion. **A**, In this example, the opposing arch is a complete denture that is not to be altered. To produce a cast for use in correcting the occlusion on the articulator, a pick-up impression of the mandibular prosthesis is made. The prosthesis stays within the irreversible hydrocolloid impression; the clasps, proximal plates, and any undercut or parallel surface are carefully blocked out with wax before the remount cast is formed. **B**, The remount cast that is formed is then inverted and positioned with the use of an interocclusal record.




**FIGURE 21-2, CONT'D** **C**, The mounted mandibular cast and the interocclusal record showing that the record was made without tooth contact. This allows the position recorded to not be influenced by the teeth, which could alter the closure path and introduce error. **D**, This example shows a maxillary complete denture that was mounted before the patient visit with the use of a remount index (preserved facebow by indexing before recovery from the processed cast) and the mandibular remount cast and interocclusal record (as in **C**). The record is removed and occlusal correction accomplished to control the post-process occlusion. Use of the completed prostheses provides the best chance to obtain an accurate and reliable interocclusal record, given the fact that the bases are very accurate and stable. **E**, The goal of the remounting procedure is to provide the occlusal position prescribed by the arrangement of prosthesis teeth. It would be inappropriate to allow the patient to attempt to accommodate to a new prosthesis in which the occlusion is not optimized.

retainers are present with complete dentures. The use of more than one color of articulation paper or ribbon to record and differentiate between centric and eccentric contacts is just as helpful in adjusting removable partial denture occlusion as natural occlusion, and this method may be used for the initial adjustment.

For final adjustment, because one denture will be adjusted to occlude with a predetermined arch, the use of an occlusal wax may be necessary to establish points of excessive contact and interference. This cannot be done by articulation paper alone. An occlusal indicating wax (Figure 21-3) that is adhesive on one side, or strips of 28-gauge casting wax or other similar soft wax, may be used. This should always be

done bilaterally, with two strips folded together at the midline. Thus, the patient is not as likely to deviate to one side as when wax is introduced unilaterally.

For centric contacts, the patient is guided to tap into the wax. Then the wax is removed and inspected for perforations under transillumination. Premature contacts or excessive contacts appear as perforated areas and must be adjusted. One of two methods may be used to locate specific areas to be relieved. Articulation ribbon may be used to mark the occlusion; those marks that represent areas of excessive contact are identified by referring to the wax record and are relieved accordingly. A second method is to introduce the wax strips a second time, this time adapting them to the buccal and



**FIGURE 21-3** Occlusal indicator wax. (Courtesy of Kerr Corp., Orange, CA.)

lingual surfaces for retention. After the patient has tapped into the wax, perforated areas are marked with a waterproof pencil. The wax is then stripped off and the penciled areas are relieved.

Whichever method is used, it must be repeated until occlusal balance in the planned intercuspal position has been established and uniform contacts without perforations are evident from a final interocclusal wax record. After adjustment has been completed, any remaining areas of interference are reduced, thus ensuring that there is no interference during the chewing stroke. Adjustments to relieve interference during the chewing stroke should be confined to buccal surfaces of mandibular teeth and lingual surfaces of maxillary teeth. This serves to narrow the cusps so that they will go all the way into the opposing sulci without wedging as they travel into the planned intercuspal contact. Skinner proposed giving a small bite of soft banana to chew rather than expecting the patient to chew without food actually being present. The small bolus of banana promotes normal functional activity of the chewing mechanism, yet by its soft consistency does not in itself cause indentations in the soft wax. Any interfering contacts encountered during the chewing stroke are thus detected as perforations in the wax, which are marked with pencil and relieved accordingly.

After adjustment of the occlusion, the anatomy of the artificial teeth should be restored to maximal efficiency by restoring grooves and spillways (food escapeways) and by narrowing the teeth bucco-lingually to increase the sharpness of the cusps and reduce the width of the food table. Mandibular buccal and maxillary lingual surfaces in particular should be narrowed to ensure that these areas will not interfere with closure into the opposing sulci, because artificial teeth used on removable partial dentures that oppose

natural or restored dentition should always be considered material out of which a harmonious occlusal surface is created. Final adjustment of the occlusion should always be followed by meticulous restoration of the most functional occlusal anatomy possible. Although this may be done after a subsequent occlusal adjustment is made at a later date, the possibility that the patient may fail to return on schedule is always present; in the meantime, broad and inefficient occlusal surfaces may cause overloading of the supporting structures, which would be traumatogenic. Therefore, restoration of an efficient occlusal anatomy is an essential part of the denture adjustment at the time of placement. Again, this necessitates that sufficient time is allotted for initial placement of the removable partial denture to permit accomplishment of all necessary occlusal corrections.

Adjustments to occlusion should be repeated at a reasonable interval after the dentures have reached a point of equilibrium and the musculature has become adjusted to the changes brought about by restoration of occlusal contacts. This second occlusal adjustment usually may be considered sufficient until such time as tissue-supported denture bases no longer support the occlusion, and corrective measures—either reoccluding the teeth or relining the denture—must be used. However, a periodic recheck of occlusion at intervals of 6 months is advisable to prevent traumatic interference resulting from changes in denture support or tooth migration.

## INSTRUCTIONS TO THE PATIENT

Finally, before the patient is dismissed, he or she should be reminded of the chronic nature of the missing tooth condition and of the fact that treatment solutions, such as a removable partial denture, require monitoring to ensure that they continue to provide optimum function without harming the mouth.

Patients should be instructed in the proper placement and removal of the removable partial denture. They should demonstrate that they can place and remove the prosthesis themselves. Clasp breakage can be avoided by instructing patients to remove the removable partial denture by the bases and not by repeated lifting of the clasp arms away from the teeth with the fingernails.

Patients should be advised that some discomfort or minor annoyance might be experienced initially. To some extent, this may be caused by the bulk of the prosthesis to which the tongue must become accustomed.

Patients must be advised of the possibility of the development of soreness despite every attempt on the part of the dentist to prevent its occurrence. Because patients vary widely in their ability to tolerate discomfort, it is best to advise every patient that needed adjustments will be made. On the other hand, the dentist should be aware that some patients are unable to accommodate the presence of a removable prosthesis. Fortunately, these are few in any practice. However, the dentist must avoid any statements that might be interpreted or construed by the patient to be positive assurance tantamount

to a guarantee that the patient will be able to use the prosthesis with comfort and acceptance. Too much depends on the patient's ability to accept a foreign object and to tolerate reasonable pressure to make such assurance possible.

Discussing phonetics with the patient in regard to the new dentures may indicate that this is a unique problem to be overcome because of the influence of the prosthesis on speech. With few exceptions, which usually result from excessive and preventable bulk in the denture design, contour of denture bases, or improper placement of teeth, the average patient will experience little difficulty in wearing the removable partial denture. Most hindrances to normal speech will disappear in a few days.

Similarly, perhaps little or nothing should be said to the patient about the possibility of gagging or the tongue's reaction to a foreign object. Most patients will experience little or no difficulty in this regard, and the tongue will normally accept smooth, nonbulky contours without objection. Contours that are too thick, too bulky, or improperly placed should be avoided in the construction of the denture, but if present, these should be detected and eliminated at the time of placement of the denture. The dentist should palpate the prosthesis in the mouth and reduce excessive bulk accordingly before the patient has an opportunity to object to it. The area that most often needs thinning is the distolingual flange of the mandibular denture. Here, the denture flange should always be thinned during finishing and polishing of the denture base. Sublingually, the denture flange should be reproduced as recorded in the impression, but distal to the second molar the flange should be trimmed somewhat thinner. Then, when the denture is placed, the dentist should palpate this area to ascertain that a minimum of bulk exists that might be encountered by the side and base of the tongue. If this needs further reduction, it should be done and the denture repolished before the patient is dismissed.

The patient should be advised of the need to keep the dentures and the abutment teeth meticulously clean. If cariogenic processes are to be prevented, the accumulation of debris should be avoided as much as possible, particularly around abutment teeth and beneath minor connectors. Furthermore, inflammation of gingival tissue is prevented by removing accumulated debris and substituting toothbrush massage for the normal stimulation of tongue and food contact with areas that will be covered by the denture framework.

The mouth and the removable partial denture should be cleaned after eating and before retiring. Brushing before breakfast also may be effective in reducing the bacterial count, which may help to lessen acid formation after eating in the caries-susceptible individual. A removable partial denture may be effectively cleaned with the use of a small, soft-bristle brush. Debris may be effectively removed through the use of nonabrasive dentifrices, because they contain the essential elements for cleaning. Household cleaners and toothpastes should not be used, because they are too abrasive for use on acrylic-resin surfaces. The patient—the elderly or

handicapped patient in particular—should be advised to clean the denture over a basin partially filled with water so that denture impact will be less if the denture is dropped accidentally during cleaning.

Along with brushing with a dentifrice, additional cleaning may be accomplished with the use of a proprietary denture cleaning solution. The patient should be advised to soak the dentures in the solution for 15 minutes once daily, followed by thorough brushing with a dentifrice. Although hypochlorite solutions are effective denture cleansers, they have a tendency to tarnish chromium-cobalt frameworks and should be avoided.

In some mouths, the precipitation of salivary calculus on the removable partial denture necessitates taking extra measures for its removal. Thorough daily brushing of the denture will prevent deposits of calculus for many patients. However, any buildup of calculus noted by the patient between scheduled recall appointments should be removed in the dental office. This can be quickly and readily accomplished with an ultrasonic cleaner.

Because many patients may dine away from home, the informed patient should provide some means of carrying out midday oral hygiene. Simply rinsing the removable partial denture and the mouth with water after eating is beneficial if brushing is not possible.

Opinion is divided on the question of whether or not a removable partial denture should be worn during sleep. Conditions should determine the advice given the patient, although generally the tissue should be allowed to rest by removal of the denture at night. The denture should be placed in a container and covered with water to prevent its dehydration and subsequent dimensional change. About the only situation that possibly justifies wearing removable partial dentures at night is when stresses generated by bruxism would be more destructive because they would be concentrated on fewer teeth. Broader distribution of the stress load, plus the splinting effect of the removable partial denture, may make wearing the denture at night advisable. However, an individual mouth protector should be worn at night until the cause of the bruxism is eliminated.

Often the question arises whether an opposing complete denture should be worn when a removable partial denture in the other arch is out of the mouth. The answer is that if the removable partial denture is to be removed at night, the opposing complete denture should not be left in the mouth. There is no more certain way of destroying the alveolar ridge, which supports a maxillary complete denture, than to have it occlude with a few remaining anterior mandibular teeth.

The patient with a removable partial denture should not be dismissed as completed without at least one subsequent appointment for evaluation of the response of oral structures to the restorations and minor adjustment if needed. This should be made at an interval of 24 hours after initial placement of the denture. It need not be a lengthy appointment but should be made as a definite

rather than a drop-in appointment. This not only gives the patient assurance that any necessary adjustments will be made and provides the dentist with an opportunity to check on the patient's acceptance of the prosthesis but also avoids giving the patient any idea that the dentist's schedule may be interrupted at will and serves to give notice that an appointment is necessary for future adjustments.

## FOLLOW-UP SERVICES

The patient must understand the sixth and final phase of removable partial denture service (periodic recall) and its rationale. Patients need to understand that the support for a prosthesis (Kennedy Class I and II) may change with time. Patients may experience only limited success with the treatment and prostheses so meticulously accomplished by the dentist, unless they return for periodic oral evaluations.

After all necessary adjustments have been made to the removable partial denture and the patient has been instructed on proper care of the denture, the patient must also be advised as to future care of the mouth to ensure health and longevity of the remaining structures. How often the dentist should examine the mouth and the denture depends on the oral and physical condition of the patient. Patients who are caries-susceptible or who have tendencies toward periodontal disease or alveolar atrophy should be examined more often. Every 6 months should be the rule if conditions are normal.

The need to increase retention on clasp arms to make the denture more secure depends on the type of clasp that has been used. Increasing retention should be accomplished by contouring the clasp arm to engage a deeper part of the retentive undercut rather than by forcing the clasp in toward the tooth. The latter creates only frictional retention, which violates the principle of clasp retention. As an active force, such retention contributes to tooth or restoration movement, or both, in a horizontal direction, disappearing only when the tooth has been moved or the clasp arm has returned to a passive relationship with the abutment tooth. Unfortunately, this is almost the only adjustment that can be made to a half-round cast clasp arm. On the other hand, the round wrought-wire clasp arm may be cervically adjusted and brought into a deeper part of the retentive undercut. Thus, the passivity of the clasp arm in its terminal position is maintained but retention is increased, because it is forced to flex more to withdraw from the deeper undercut. The patient should be advised that the abutment tooth and the clasp will serve longer if the retention is held minimally, which is only that amount necessary to resist reasonable dislodging forces.

The future development of denture rocking or looseness may be the result of a change in the form of the supporting ridges rather than lack of retention. This should be detected as early as possible after it occurs and corrected by relining or rebasing. The loss of tissue support is usually so gradual that the patient may be unable to detect the need for relining. This usually must be determined by the dentist at subsequent

examinations as evidenced by rotation of the distal extension denture about the fulcrum line. If the removable partial denture is opposed by natural dentition, the loss of base support causes loss of occlusal contact, which may be detected by having the patient close on wax or Mylar strips placed bilaterally. If, however, a complete denture or a distal extension removable partial denture opposes the removable partial denture, the interocclusal wax test is not dependable because posterior closure, changes in the temporomandibular joint, or migration of the opposing denture may have maintained occlusal contact. In such cases, evidence of loss of ridge support is determined solely by the indirect retainer leaving its seat as the distal extension denture rotates about the fulcrum.

No assurance can be given to the patient that crowned or uncrowned abutment teeth will not decay at some future time. The patient can be assured, however, that prophylactic measures in the form of meticulous oral hygiene, coupled with routine care by the dentist, will be rewarded by greater health and longevity of the remaining teeth.

The patient should be advised that maximal service may be expected from the removable partial denture if the following rules are observed:

1. *Avoid careless handling of the denture, which may lead to distortion or breakage.* Damage to the removable partial denture occurs while it is out of the mouth as a result of dropping it during cleaning or an accident that occurs when the denture is not worn. Fractured teeth and denture bases and broken clasp arms can be repaired, but a distorted framework can rarely if ever be satisfactorily readapted or repaired.
2. *Protect teeth from caries with proper oral hygiene, proper diet, and frequent dental care.* The teeth will be no less susceptible to caries when a removable partial denture is being worn but may be more so because of the retention of debris. At the same time, the remaining teeth have become all the more important because of oral rehabilitation, and abutment teeth have become even more valuable because of their importance to the success of the removable partial denture. Therefore, a rigid regimen of oral hygiene, diet control, and periodic clinical observation and treatment is essential for the future health of the entire mouth. Also, the patient must be more conscientious about returning periodically for examination and necessary treatment at intervals stated by the dentist.
3. *Prevent periodontal damage to the abutment teeth by maintaining tissue support of any distal extension bases.* As a result of periodic evaluation, this can be detected and corrected by relining or whatever procedure is indicated.
4. *Accept removable partial denture treatment as something that cannot be considered permanent, but partial dentures must receive regular and continuous care by both the patient and the dentist.* The obligations for maintaining caries control and for returning at stated intervals for treatment must be clearly understood, along with the fact that regular charges will be made by the dentist for whatever treatment is rendered.

P A R T



# MAINTENANCE



# CHAPTER

# 22

## Relining and Rebasing the Removable Partial Denture

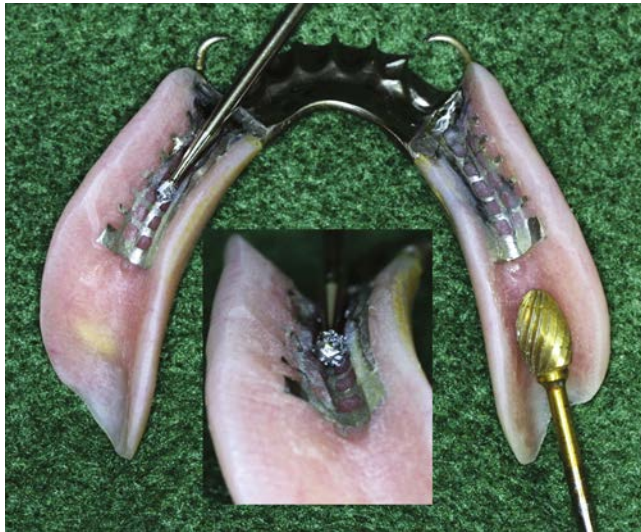### CHAPTER OUTLINE

Relining Tooth-Supported and Tooth Implant-Supported Denture Bases  
Relining Distal Extension Denture Bases  
Methods of Reestablishing Occlusion on a Relined Removable Partial Denture

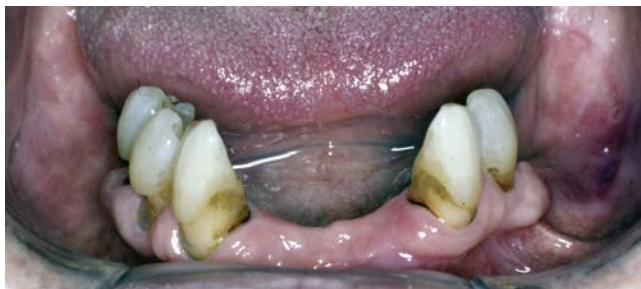Differentiation between relining and rebasing the removable partial denture has been discussed previously in Chapter 1. Briefly, relining is the resurfacing of the tissue of a denture base with new material to make it fit the underlying tissue more accurately. Rebasing is the replacement of the entire denture base with new material. The artificial teeth may also need to be replaced in a rebase procedure. Relining removable partial dentures is a common occurrence in many dental practices; however, rebasing is not done as often.

In either situation, a new impression is necessary and uses the existing denture base after modifications (Figure 22-1) as an impression tray for a closed-mouth or an open-mouth impression procedure. One of several types of impression materials may be used, such as metallic oxide impression paste, rubber-base or silicone elastomers, tissue conditioning materials, or mouth-temperature wax. With a tooth-supported prosthesis, the impression method (open- or closed-mouth) is not as critical. In deciding between a closed-mouth and an open-mouth impression method for relining a distal extension removable partial denture, a major consideration is the resiliency of the mucosa covering the residual ridge. As with secondary impression techniques, a firm mucosal foundation can likely accommodate a closed-mouth functional impression technique or an open-mouth selective pressure technique. However, when the mucosa is easily displaced, the open-mouth selective pressure technique is preferable. Both techniques should guard against framework movement during the impression procedure.

Before relining or rebasing is undertaken, the oral tissue must be returned to an acceptable state of health (Figure 22-2). For more information, refer to the Chapter 14 discussion about conditioning abused and irritated tissue.



**FIGURE 22-1** Use of an existing Kennedy Class I removable partial denture base as a tray during a reline impression. The selective pressure impression philosophy requires space for the impression material that is greater over the ridge crest (secondary stress bearing area) than at the buccal shelf region (primary stress bearing area). A pear-shaped laboratory bur is used to provide general relief (0.5 to 1.0 mm) of the denture base, with additional relief (1.0 mm) obtained over the ridge crest with a #8 round straight shank laboratory bur. Care must be taken to ensure that the tissue surface is relieved of all undercuts that could cause cast fracture when one is recovering the cast from the impression.



**FIGURE 22-2** Kennedy Class I modification 1 arch with a removable partial denture that requires relining. Tissue abuse evident at the left buccal shelf region must be corrected before the reline impression is made. Management requires a period of function without the prosthesis or relief of the prosthesis in the affected region along with placement of a tissue-resilient liner in an effort to reduce the traumatic effects of pressure.

### RELINING TOOTH-SUPPORTED AND TOOTH IMPLANT-SUPPORTED DENTURE BASES

When support is available at each end of a modification space and support for that restoration is derived entirely from the abutment teeth at each end of each edentulous span, reline or rebase is not as routinely needed to maintain occlusion as with a distal extension base. This support may

be effective through the use of occlusal rests, boxlike internal rests, attachments, supporting ledges on abutment restorations, or devices within the acrylic resin base that engage an implant abutment. Except for intrusion of abutment teeth under functional stress, the supporting abutments prevent settling of the restoration toward the tissue of the residual ridge. Tissue changes that occur beneath tooth-supported denture bases do not affect the support of the denture; therefore relining or rebasing is usually done for reasons that include (1) unhygienic conditions and the trapping of debris between the denture base and the residual ridge; (2) an unsightly condition that results from the space that has developed; or (3) patient discomfort associated with lack of tissue contact that arises from open spaces between the denture base and the tissue. Anteriorly, loss of support beneath a denture base may lead to some denture movement, despite occlusal support and direct retainers located posteriorly. Rebasing would be the treatment of choice if the artificial teeth are to be replaced or rearranged, or if the denture base needs to be replaced for esthetic reasons, or because it has become defective.

To accomplish relining or rebasing, the original denture base must have been made of a resin material that can be relined or replaced. Tooth-supported removable partial denture bases made of metal as part of the cast framework generally cannot be satisfactorily relined.

Because the tooth-supported denture base cannot be depressed beyond its terminal position with the occlusal rests seated and the teeth in occlusion, and because it cannot rotate about a fulcrum, a closed-mouth impression method is used. Virtually any impression material may be used, provided sufficient space is allowed beneath the denture base to permit the excess material to flow to the borders—where it may be turned by the bordering tissue, or, as in the palate, may be allowed to escape through venting holes without undue displacement of the underlying tissue. The qualities of each type of impression material must be kept in mind when the material to be used is selected. Ordinarily, an impression material is used that will record the anatomic form of the oral tissue.

A word of caution should be mentioned when a tooth-supported resin base is relined with autopolymerizing resin as an intraoral procedure. When one or more relatively short spans are to be relined, making an impression for relining purposes necessitates that the denture be flasked and processed. The possibilities that the vertical dimension of occlusion may be increased and that the denture may be distorted during laboratory procedures must be weighed against the disadvantages of using a direct-reline material. Fortunately, these materials are constantly improved with greater predictability and color stability. The possibility that the original denture base will become crazed or distorted by the action of the activated monomer is minimal when the base is made of modern cross-linked resin. However, caution should be exercised to ensure that the older types of resin bases are compatible when one is relining with direct-reline resins.

When relining in the mouth with a resin reline material is done with an appropriate technique, the results can be highly satisfactory, with complete bonding to the existing denture base, good color stability, permanence, and accuracy. The procedure for applying a direct reline of an existing resin base is as follows:

1. Generously relieve the tissue side of the denture base. Lightly relieve the borders. This not only provides space for an adequate thickness of new material but also eliminates the possibility of tissue impingement caused by confinement of the material.
2. Apply lubricant or tape over the polished surfaces from the relieved border to the occlusal surfaces of the teeth to prevent new resin from adhering to the preserved bases and teeth.
3. Mix the powder and the liquid in a suitable container according to the proportions recommended by the manufacturer.
4. While the material is reaching the desired consistency, have the patient rinse the mouth with cold water. At the same time, wipe the fresh surfaces of the dried denture base with a cotton pellet or small brush saturated with some of the reline resin monomer. This facilitates bonding and ensures that the surface is free of any contamination.
5. When the material has first begun to thicken, but while it is still quite fluid, apply it to the tissue side of the denture base and over the borders. Immediately place the removable partial denture in the mouth in its terminal position, and have the patient lightly close into occlusion. Be sure that no material flows over the occlusal surfaces or alters the established vertical dimension of occlusion. Then, with the patient's mouth open, manipulate the cheeks to turn the excess at the border and establish harmony with bordering attachments. If a mandibular removable partial denture is being relined, have the patient move the tongue into each cheek and then against the anterior teeth to establish a functional lingual border. It is necessary that the direct retainers be effective to prevent displacement of the denture while molding of the borders is accomplished. Otherwise, the denture must be held in its terminal position with finger pressure on the occlusal surfaces while border molding is in progress.
6. Immediately remove the denture from the mouth and, with fine curved iris scissors, trim away gross excess material and any material that has flowed onto proximal tooth surfaces and other components of the removable partial denture framework. While doing this, have the patient again rinse the mouth with cold water. Then replace the denture in its terminal position to bring the teeth into occlusion. Repeat the border movements with the patient's mouth open. By this time, or soon thereafter, the material will have become firm enough to maintain its form out of the mouth.
7. Remove the denture, quickly rinse it in water, and dry the relined surface with compressed air. Apply a

generous coat of glycerin with a brush or cotton pellet to prevent frosting of the surface caused by evaporation of the monomer. Allow the material to polymerize in a container of cold water. This will eliminate any patient discomfort and tissue damage that could have resulted from exothermic heat or prolonged contact of the tissue with unreacted monomer. Although it is preferable for 20 to 30 minutes to elapse before trimming and polishing, it may be done as soon as the material hardens. Polymerization may be expedited and made denser by placing the denture in warm water in a pressure pot for 15 minutes at 20 psi. The masking tape must be removed before trimming is done but should be replaced over the teeth and polished surfaces below the junction of the new and old materials to protect those surfaces during final polishing.

When properly done, a direct reline is entirely acceptable for most tooth-supported removable partial denture bases made of a resin material, except when some tissue support may be obtained for long spans between abutment teeth. In the latter situation, a reline impression in tissue conditioning material or other suitable elastic impression material may be accomplished. The denture may then be flasked, and a processed reline may be added for optimal tissue contact and support.

### RELINING DISTAL EXTENSION DENTURE BASES

A distal extension removable partial denture, which derives its major support from the tissue of the residual ridge, requires relining much more often than does a tooth-supported denture. Because of this, distal extension bases are usually made of a resin material that can be relined to compensate for loss of support caused by tissue changes. Although tooth-supported areas are relined for other reasons, the primary reason for relining a distal extension base is to reestablish tissue support for that base.

The need for relining a distal extension base is determined by evaluating the stability and occlusion at reasonable intervals after initial placement of the denture. Before initial placement of the denture, the patient must be advised that (1) periodic examination and also relining, when it becomes necessary, are imperative; (2) the success of the removable partial denture and the health of the remaining tissue and abutment teeth depend on periodic examination and servicing of both the denture and the abutment teeth; and (3) a charge will be made for these visits in proportion to the required treatment.

There are two indications of the need for relining a distal extension removable partial denture base. First, loss of occlusal contact between opposing dentures or between the denture and the opposing natural dentition may be evident (see Figures 9-13 and 9-14). This is determined by having the patient close on two strips of 28-gauge, soft green or blue (casting) wax or Mylar matrix strips. If occlusal contact

between artificial dentition is weak or lacking while the remaining natural teeth in opposition are making firm contact, the distal extension denture needs to have occlusion reestablished on the present base by altering the occlusion, thereby reestablishing the original position of the denture framework and base, or sometimes both. In most instances, reestablishing the original relationship of the denture is necessary, and the occlusion will automatically be reestablished.

Second, loss of tissue support that causes rotation and settling of the distal extension base or bases is obvious when alternate finger pressure is applied on either side of the fulcrum line. Although checking for occlusal contact alone may be misleading, such rotation is positive proof that relining is necessary. If occlusal inadequacy is detected without any evidence of denture rotation toward the residual ridge, all that needs to be done is to reestablish occlusal contact by rearranging the teeth or by adding to the occlusal surfaces with resin or cast gold onlays. On the other hand, if occlusal contact is adequate but denture rotation can be demonstrated, this is usually the result of migration or extrusion of opposing teeth or a shift in position of an opposing maxillary denture, thus maintaining occlusal contact at the expense of the stability and tissue support of that denture. This is often the situation when a maxillary complete denture opposes a removable partial denture. It is not unusual for a patient to complain of looseness of the maxillary complete denture and to request relining of that denture when actually it is the removable partial denture that needs relining. Relining and thus repositioning of the removable partial denture result in repositioning of the maxillary complete denture with a return of stability and retention in that denture. Therefore, evidence of rotation of a distal extension removable partial denture about the fulcrum line must be the deciding factor as to whether relining needs to be done.

Rotation tissue-ward about the fulcrum line always results in lifting of the indirect retainer(s). The framework of any distal extension removable partial denture must be in its original terminal position with indirect retainers fully seated during and at the end of any relining procedure. Any possibility of rotation about the fulcrum line caused by occlusal influence must be prevented, and therefore the framework must be held in its original terminal position during the time the impression is being made. This all but eliminates the use of a closed-mouth impression procedure when unilateral or bilateral distal extension bases are relined.

The best way to ensure framework orientation throughout the impression procedure for a distal extension removable partial denture is with an open-mouth procedure done in exactly the same manner as the original secondary impression (see Figure 17-10, *D*). The denture to be relined first is relieved generously on the tissue side (see Figure 22-1) and then is treated in the same way as the original impression base for a functional impression. The step-by-step procedure is the same, with the dentist's three fingers placed on the two principal occlusal rests and at a third point between, preferably at an indirect retainer farthest from the axis of rotation.

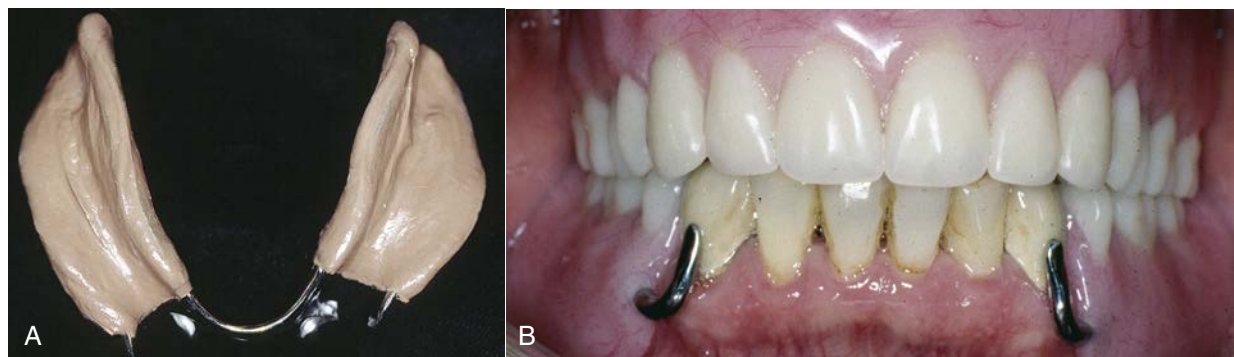
The framework thus is returned to its original terminal position, with all tooth-supported components fully seated. The tissue beneath the distal extension base then is registered in a relationship to the original position of the denture that will ensure that (1) the denture framework will be returned to its intended relationship with the supporting teeth; (2) optimum tissue support will be reestablished for the distal extension base; and (3) the original occlusal relationship with the opposing teeth will be restored.

Although it is true that the teeth are not allowed to come into occlusion during an open-mouth impression procedure, the original position of the denture is positively determined by its relationship with the supporting abutment teeth. Because this is the relationship on which the original occlusion was established, returning the denture to this position should bring about a return to the original occlusal relationship if two conditions are satisfied. The first condition is that laboratory procedures during relining must be done accurately without any increase in the vertical dimension of occlusion. This is essential to any reline procedure, but it is a particular necessity with a removable partial denture because any change in occlusal vertical dimension will prevent occlusal rests from seating and will result in overloading and trauma to the underlying tissue. The second condition is that the opposing teeth have not extruded or migrated, or that the position of an opposing denture has not become altered irreversibly. In the latter situation, some adjustment of the occlusion will be necessary, but this should be deferred until the opposing teeth or denture and the structures associated with the temporomandibular joint have had a chance to return to their original position before denture settling occurs. One of the greatest satisfactions of a job well done is seen in the execution of an open-mouth reline procedure as described in the previous paragraph, which results in the restoration not only of the original denture relationship and of tissue support but also of the original occlusal relationship (Figure 22-3).

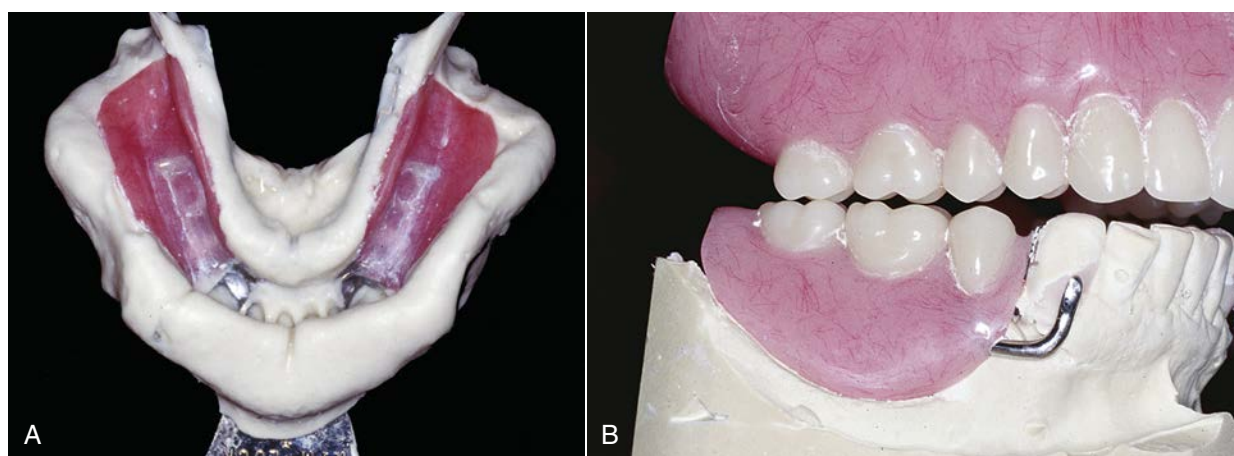
### METHODS OF REESTABLISHING OCCLUSION ON A RELINED REMOVABLE PARTIAL DENTURE

Occlusion on a relined removable partial denture may be reestablished by several methods, depending on whether the relining results in an increase in the vertical dimension of occlusion or in lack of opposing occlusal contacts. In either instance, it is usually necessary to make a remounting cast for the relined removable partial denture so the denture can be correctly related to an opposing cast or prosthesis in an articulator (Figure 22-4).

In rare instances, after a distal extension removable partial denture has been relined by the method previously described, the occlusion is found to be negative rather than positive, or the same as it was before relining. This may be the result of wear of occlusal surfaces over a period of time, a high position of the original occlusion with resulting depression of opposing teeth, or other reasons. In such a situation,



**FIGURE 22-3** **A**, Mandibular reline impression accomplished with an open-mouth impression technique. **B**, Following processing of the reline and occlusal correction with a clinical remount procedure (see Chapter 21), the occlusion is restored to the original relationship.



**FIGURE 22-4** **A**, An irreversible hydrocolloid pick-up impression made following reline of the mandibular removable partial denture. All regions in the framework that are below the height of contour will be coated with a thin layer of baseplate wax to allow recovery of the prosthesis from the remount cast without damage to the cast. This allows replacement of the prosthesis in the mouth for an interocclusal registration. **B**, Mounted mandibular prosthesis against a maxillary complete denture. The maxillary prosthesis was mounted using a remount cast made after finishing and polishing of the prosthesis. It is not uncommon to see a significant occlusal problem when one is relining a mandibular distal extension removable partial denture when the residual ridge resorption has been left unchecked for a long time. The maxillary prosthesis can often assume a more inferior position, and when the mandibular prosthesis is reoriented to the natural dentition, this raises the mandibular occlusal plane, resulting in an occlusal relationship as shown. The best resolution of this requires addressing the maxillary arch at the same time and requires a repositioning of the maxillary occlusal plane.

occlusion on the denture must be restored to reestablish an even distribution of occlusal loading over both natural and artificial dentition. Otherwise, the natural dentition must carry the burden of mastication unaided, and the denture becomes only a space-filling or cosmetic device.

If the artificial teeth to be corrected are resin, the occlusion can be reestablished by adding autopolymerizing or light-activated resin to occlusal surfaces, or by fabricating gold occlusal surfaces, which can be attached to the original replaced teeth. The original teeth may also be removed from the denture base and replaced by new teeth arranged to harmonize with the opposing occlusal surfaces. Baseplate wax may be used to support the teeth as they are arranged. This wax should be carved to restore the lingual anatomy of the teeth and the portion of the denture base that was eliminated

when the original teeth were removed. A stone matrix is made that covers the occlusal and lingual surfaces of the teeth and denture flange. Then wax may be removed from the denture base and teeth and the tissue-bearing surface coated with a bonding agent. Those areas on the stone matrix intimate to the new resin to be added should be painted with a tinfoil substitute or an air barrier coating material if a visible light-cured (VLC) material is to be used. The new teeth are placed in the stone matrix, and the matrix is accurately attached to the denture base with sticky wax or a hot glue gun. VLC material or an autopolymerizing resin is then used to attach the teeth. If an autopolymerizing material is used, it can be conveniently sprinkled on by a buccal approach. The buccal surface of the denture base adjacent to the teeth should be slightly overfilled so that the correct shape may

be restored to this portion of the base during finishing and polishing procedures. Occlusal discrepancies caused by this procedure should be corrected in the articulator by new jaw relation records if the denture has a distal extension base.

A second method involves removing the original teeth and replacing them with a hard inlay wax occlusion rim on which a functional registration of occlusal pathways is then established (see Chapter 18). The original teeth or new teeth may then be arranged to occlude with the template thus

obtained and subsequently attached to the denture base with processed VLC material or autopolymerizing resin. If the latter is used, the need for flasking may be eliminated by securing the teeth to a stone matrix while the resin attachment is applied with a brush technique. Regardless of the method used for reattaching the teeth, the occlusion thus established should require little adjustment in the mouth and should exhibit the occlusal harmony that is possible to attain by this method.

# CHAPTER

# 23

## Repairs and Additions to Removable Partial Dentures

### CHAPTER OUTLINE

Broken Clasp Arms  
 Fractured Occlusal Rests  
 Distortion or Breakage of Other Components—Major and Minor Connectors  
 Loss of a Tooth or Teeth not Involved in Support or Retention of the Restoration  
 Loss of an Abutment Tooth Necessitating its Replacement and Making a New Direct Retainer  
 Other Types of Repairs  
 Repair by Soldering

The need for repairing or adding to a removable partial denture will occasionally arise. However, the frequency of this occurrence should be held to a minimum by careful diagnosis, intelligent treatment planning, adequate mouth preparations, and the carrying out of an effective removable partial denture design with proper fabrication of all component parts. Any need for repairs or additions will then be the result of unforeseen complications that arise in abutment or other teeth in the arch, breakage or distortion of the denture through accident, or careless handling by the patient, rather than faulty design or fabrication.

It is important that the patient is instructed in proper placement and removal of the prosthesis so that undue strain is not placed on clasp arms, on other parts of the denture, or on contacted abutment teeth. The patient also should be advised that care must be given to the prosthesis when it is out of the mouth, and that any distortion may be irreparable. It should be made clear that there can be no guarantee against breakage or distortion from causes other than obvious structural defects.

### BROKEN CLASP ARMS

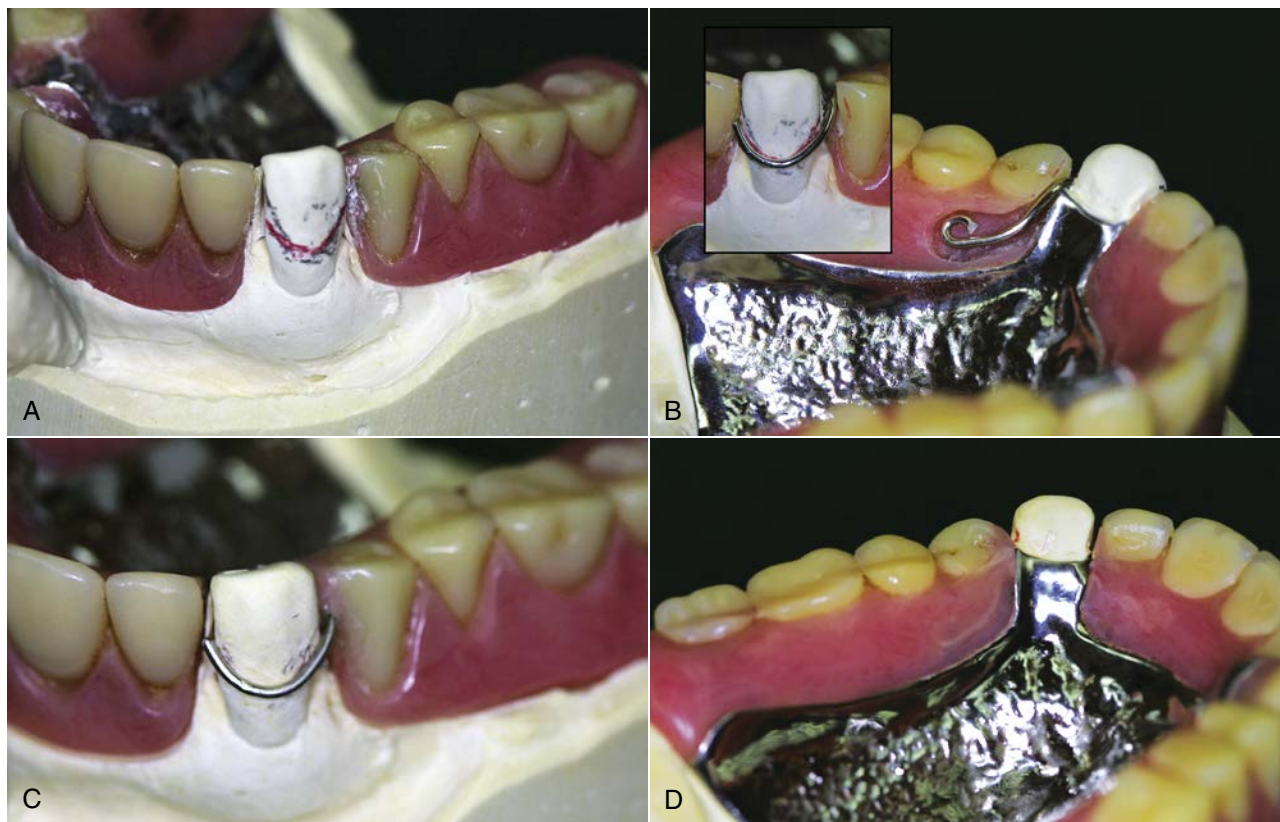
The following are several reasons for breakage of clasp arms:

1. *Breakage may result from repeated flexure into and out of too severe an undercut.* If the periodontal support is greater than the fatigue limit of the clasp arm, failure of the metal occurs first. Otherwise, the abutment tooth is loosened and eventually is lost because of the persistent strain that is placed on it. Locating clasp arms only where an acceptable minimum of retention exists, as determined by an accurate survey of the master cast, can prevent this type of breakage.
2. *Breakage may occur as a result of structural failure of the clasp arm itself.* A cast clasp arm that is not properly formed or is subject to careless finishing and polishing

eventually will break at its weakest point. This can be prevented by providing the appropriate taper to flexible retentive clasp arms and uniform bulk to all rigid nonretentive clasp arms. Wrought-wire clasp arms may eventually fail because of repeated flexure at the region where it exits from the resin base (Figure 23-1), or at a point at which a nick or constriction occurred as a result of careless use of contouring pliers. They also may break at the point of origin from the casting as a result of excessive manipulation during initial adaptation to the tooth or subsequent readaptation. Clasp breakage can best be prevented by cautioning the patient against removing the removable partial denture by sliding the clasp arm away from the tooth with the fingernails. A wrought-wire clasp arm can normally be adjusted several times over a period of years without failure. It is only when the number of adjustments is excessive that breakage is likely to occur. Wrought-wire clasp arms also may break at the point of origin because of recrystallization of the metal. This can be prevented by proper selection of wrought wire, avoidance of burnout

temperatures exceeding 1300° F, and avoidance of excessive casting temperatures when a cast-to method is used. When wrought wire is attached to the framework by soldering, the soldering technique must avoid recrystallization of the wire. For this reason, it is best that soldering be done electrically to prevent the wrought wire from overheating. A low-fusing (1420° F to 1500° F), triple-thick, color-matching gold solder should be used rather than a solder that possesses a higher fusing temperature.

3. *Breakage may occur because of careless handling by the patient.* Any clasp arm will become distorted or will break if subjected to excessive abuse by the patient. The most common cause of failure of a cast clasp arm is distortion caused by accidental dropping of the removable partial denture. A broken retentive clasp arm, regardless of its type, may be replaced with a wrought-wire retentive arm embedded in a resin base (see Figure 23-1, C and D) or attached to a metal base by electric soldering. Often, this avoids the necessity of fabricating an entirely new clasp arm.



**FIGURE 23-1** Fractured direct retainer on canine abutment. The reason for breakage is likely the long-term repeated flexure from movement associated with this 8-year-old distal extension prosthesis. The denture must be evaluated for prospective serviceability if the retainer arm is repaired. Often, the patient will best be served by replacing the denture with a new restoration. **A**, The cast produced from an irreversible hydrocolloid pick-up impression. The height of contour is shown in pencil, with a red line illustrating to the laboratory the location of repair wire (18-gauge). **B**, Clasp adapted to the designated line on the canine and fitted into the resin trough distal to the canine and palatal to the first and second premolars. Note the curvature placed at the end of the wire to prevent movement within the polymerized resin. **C**, Finished and polished wire repair from the buccal. **D**, Palatal view.

### FRACTURED OCCLUSAL RESTS

Breakage of an occlusal rest almost always occurs where it crosses the marginal ridge. Improperly prepared occlusal rest seats are the usual cause of such weakness. An occlusal rest that crosses a marginal ridge that was not lowered sufficiently during mouth preparations may be made too thin or may be thinned by adjustment in the mouth to prevent occlusal interference. Failure of an occlusal rest rarely results from a structural defect in the metal and rarely if ever is caused by accidental distortion. Therefore, the blame for such failure must often be assumed by the dentist for not having provided sufficient space for the rest during mouth preparations.

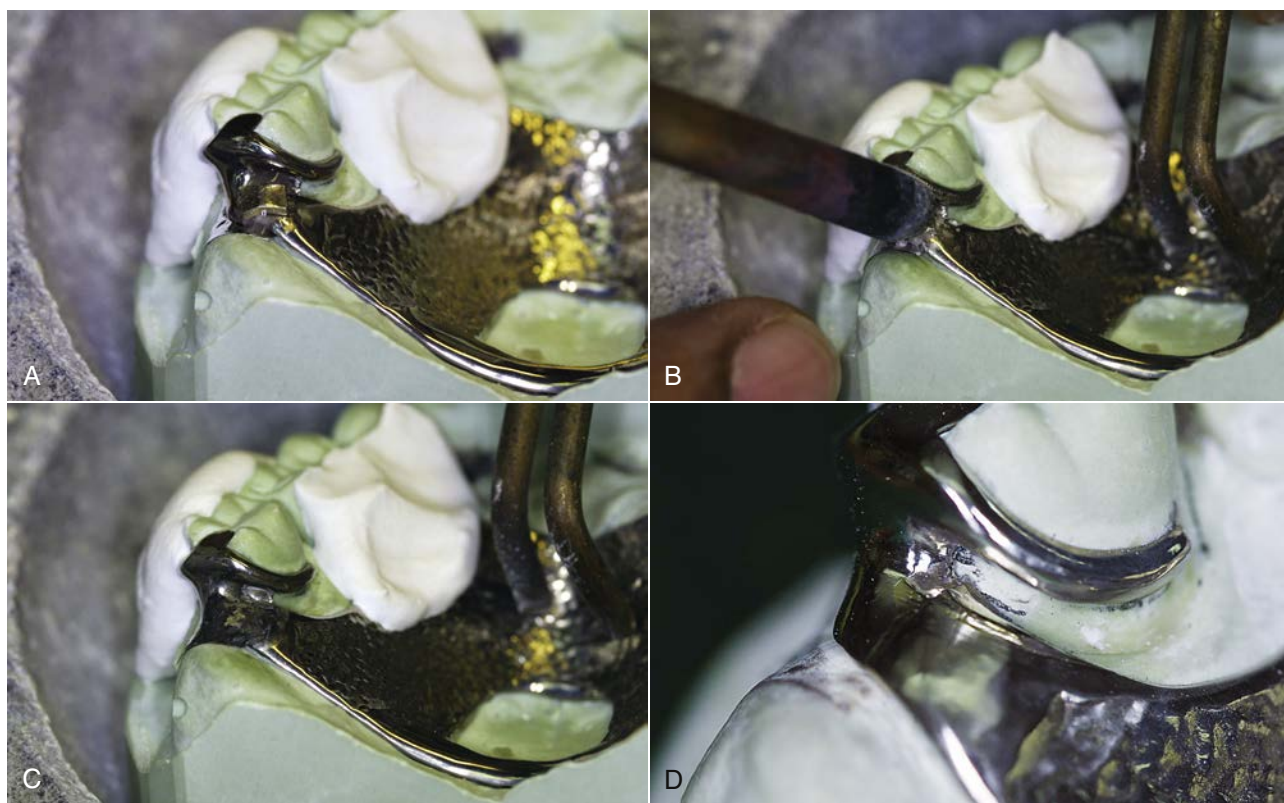
Soldering may repair broken occlusal rests. In preparation for the repair, it may be necessary to alter the rest seat of the broken rest or to relieve occlusal interferences. With the removable partial denture in its terminal position, an impression is made in irreversible hydrocolloid and then is removed, with the removable partial denture remaining in the impression. The dental stone is poured into the impression and is allowed to set. The removable partial denture is removed from the cast, and platinum foil is adapted to the

rest seat and the marginal ridge and overlaps the guiding plane. The removable partial denture is returned to the cast and, with a fluoride flux, gold solder is electrically fused to the platinum foil and the minor connector in sufficient bulk to form an occlusal rest. An alternative solder to use is an industrial brazing alloy, which is higher fusing but responds excellently to electric soldering and does not tarnish.

### DISTORTION OR BREAKAGE OF OTHER COMPONENTS—MAJOR AND MINOR CONNECTORS

Assuming that major and minor connectors were originally made with adequate bulk, distortion usually occurs from abuse by the patient ([Figure 23-2](#)). All such components should be designed and fabricated with sufficient bulk to ensure their rigidity and permanence of form under normal circumstances.

Major and minor connectors occasionally become weakened by adjustment to prevent or eliminate tissue impingement. Such adjustment at the time of initial placement may result from inadequate survey of the master cast or from faulty design or fabrication of the casting. This is inexcusable



**FIGURE 23-2** A, The maxillary juncture between major and minor connectors at the distalmost posterior molar has fractured. Thin platinum foil has been adapted to the cast beneath the fracture, the clasp assembly has been stabilized on the cast with fast-set plaster, the remainder of the prosthesis has been positioned on the cast in full contact with teeth and tissues, and the solder has been positioned for the electric tip to be placed. B, The electric soldering tip and ground are in place. C, Immediately following solder flow, the fracture has been eliminated by the solder connecting the two segments. D, The polished solder repair is ready to be cleaned and returned to the patient. The patient is told that this repair is not as strong as the original, and although it is difficult to know how long it could serve the patient, careful handling of the prosthesis is mandatory.

and reflects on the dentist. Such a restoration should be remade instead of further weakening the restoration by attempting to compensate for its inadequacies by relieving the metal. Similarly, tissue impingement that arises from inadequately relieved components results from faulty planning, and the casting should be remade with enough relief to prevent impingement. Failure of any component that was weakened by adjustment at the time of initial placement is the responsibility of the dentist. However, adjustment made necessary by settling of the restoration because abutment teeth have become intruded under functional loading may be unavoidable. Subsequent failure that results from the weakening effect of such an adjustment may necessitate making a new restoration as a consequence of tissue changes. Commonly, repeated adjustment to a major or minor connector results in loss of rigidity to the point that the connector can no longer function effectively. In such situations, a new restoration must be made, or that part must be replaced by casting a new section and then reassembling the denture by soldering. This occasionally requires disassembly of denture bases and artificial teeth. The cost and probable success must then be weighed against the cost of a new restoration. Generally, the new restoration is advisable.

### LOSS OF A TOOTH OR TEETH NOT INVOLVED IN SUPPORT OR RETENTION OF THE RESTORATION

Additions to a removable partial denture are usually simply made when the bases are made of resin (Figure 23-3). The addition of teeth to metal bases is more complex and necessitates casting a new component and attaching it by soldering or creating retentive elements for the attachment of a resin extension. In most instances when a distal extension denture base is extended, the need should be considered for subsequent relining of the entire base. After the denture base has been extended, a relining procedure for both the new and the old base should be carried out to provide optimum tissue support for the restoration.

### LOSS OF AN ABUTMENT TOOTH NECESSITATING ITS REPLACEMENT AND MAKING A NEW DIRECT RETAINER

In the event of a lost abutment, the next adjacent tooth is usually selected as a retaining abutment, and it generally will require modification or a restoration. Any new restoration should be made to conform to the original path of placement, with proximal guiding plane, rest seat, and suitable retentive area. Otherwise, modifications to the existing tooth should be done the same as during any other mouth preparations, with proximal recontouring, preparation of an adequate occlusal rest seat, and any reduction in tooth contours necessary to accommodate retentive and stabilizing components. A new clasp assembly may be cast for this tooth and the denture reassembled with the new replacement tooth added.

## OTHER TYPES OF REPAIRS

Other types of repairs may include the replacement of a broken or lost prosthetic tooth, the repair of a broken resin base, or the reattachment of a loosened resin base to the metal framework. Breakage is sometimes the result of poor design, faulty fabrication, or use of the wrong material for a given situation. Other times, it results from an accident that will not necessarily repeat itself. If the latter occurs, repair or replacement usually suffices. On the other hand, if fracture has occurred because of structural defects, or if it occurs a second time after the denture has been repaired once before, then some change in the design—by modification of the original denture or with a new denture—may be necessary.

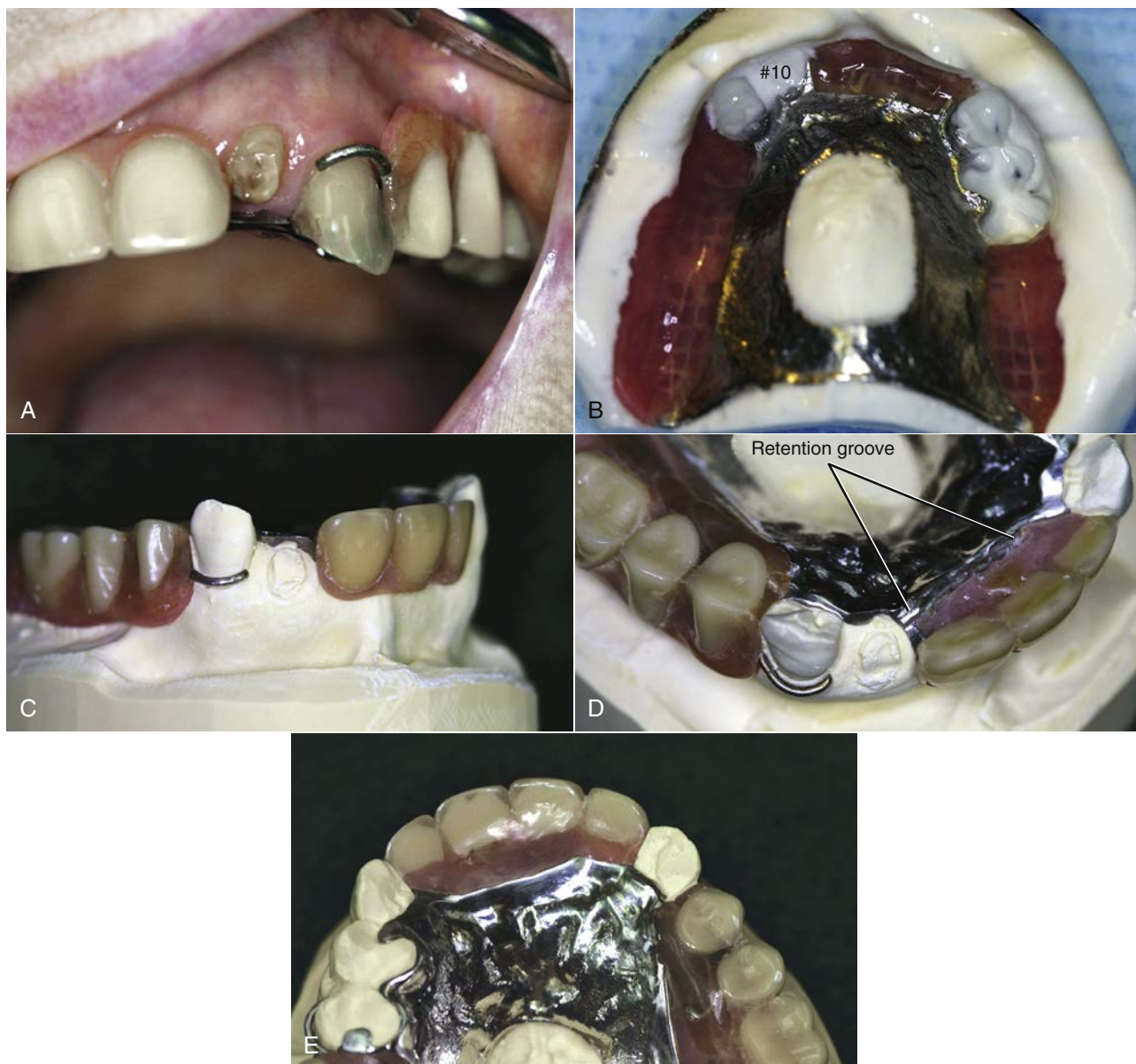## REPAIR BY SOLDERING

Approximately 80% of all soldering in dentistry can be done electrically. Electric soldering units are available for this purpose, and most dental laboratories are so equipped. Electric soldering permits soldering close to a resin base without removing that base because of rapid localization of heat at the electrode. The resin base needs only to be protected with a wet casting ring liner during soldering.

Color-matching gold solder may be used for soldering both gold and chromium-cobalt alloys. A solder for gold alloys that melts at between 1420° F and 1500° F is entirely adequate for soldering gold alloys to chromium-cobalt alloys, thereby lessening the chance of recrystallizing gold wrought wire via excessive and prolonged heat. For electric soldering, triple-thick solder should be used so the additional bulk of the solder will retard melting momentarily, while the carbon electrode conducts heat to the area to be soldered. For soldering chromium-cobalt alloys, a color-matching white 19K gold solder—which melts at about 1676° F—is used. An application of flux is essential for the success of any soldering operation to prevent oxidation of the parts to be joined and the solder itself. A borax-type flux is used when gold alloys are soldered. Fluoride-type flux must be used when chromium-cobalt alloys are soldered. When a gold alloy is to be soldered to a chromium-cobalt alloy, a fluoride-type flux should be chosen.

The following is a procedure for electric soldering:

1. *Roughen both sections to be joined.*
2. *Adapt platinum foil to the master cast beneath the framework to serve as a backing on which the solder will flow.* Lift the edges of the foil to form a trough to confine the flow of the solder.
3. *Seat the pieces to be soldered onto the master cast and secure them temporarily with sticky wax.* Over each piece, add enough soldering investment to secure them after the sticky wax has been eliminated, but leave as much metal exposed as possible.
4. *After flushing off the sticky wax with hot water, secure the cast to the soldering stand.* Cut sufficient solder and place conveniently nearby.



**FIGURE 23-3** This patient presented with an asymptomatic fractured lateral incisor. **A**, Clinical presentation of the fractured tooth and prosthesis. Evaluation of the prosthesis revealed it to be adequately fitting, stable, and retentive. **B**, Pick-up impression of the prosthesis. **C**, Cast formed from the pick-up impression, showing a fully seated prosthesis. **D**, Preparation of the prosthesis included a mechanical means for retention (which was provided by creating a recess in the resin adjacent to the missing tooth) and creating a trough at the external finishing line to repair an area of marginal breakdown. **E**, The finished repair, which will be taken to the mouth and checked for occlusal clearance lingual to the maxillary anterior teeth.

5. *Flux both sections.* Put sufficient triple-thick solder on or in the joint to complete the soldering in one operation, always starting with enough solder to complete the job.
6. *Wet the carbon tip with water to aid conduction of the current, and then touch the carbon tip to the solder (be sure the solder is held firmly in place).* Place the other electrode on any portion of the framework to complete the electric circuit and heat the carbon electrode. Do not push the solder with the carbon tip, but let the heat

alone make the solder flow. Do not remove the carbon tip from the solder while the soldering operation is in progress; this will cause surface pitting due to arcing. After the solder has flowed, remove the electrodes, removing the carbon tip electrode last, and proceed to remove the work from the cast for finishing.

Torch soldering requires an entirely different approach. It is used when the solder joint is long or unusually bulky and when a larger quantity of solder has to be used. Torch soldering cannot be undertaken to repair a removable

partial denture framework that has resin denture bases or artificial teeth supported by resin. The procedure for torch soldering is as follows:

1. Roughen both sections to be joined.
2. Adapt platinum foil to the master cast so it extends under both sections.
3. Seat the sections on the master cast in the correct relationship, and secure them temporarily with sticky wax. Also flow sticky wax into the joint to be soldered.
4. Attach a dental bur or nail over the two sections with a liberal amount of sticky wax. Attach a second and even a third nail or bur across other areas to lend additional support. Never use pieces of wood for this purpose because the wood will swell if it gets wet, thus distorting the relationship of the two sections.
5. Carefully remove the assembled casting from the master cast. Adapt a stock of utility wax directly under each section on either side of the platinum foil. After boil out is done, investment will remain in the center to support the platinum foil.
6. Invest the casting in sufficient soldering investment to secure it, and expose as much of the area to be soldered as possible. When the investment has set, boil out the sticky and utility waxes. Then place the investment in a

drying oven at a temperature not exceeding 200° F until the contained moisture has been eliminated. Do not dry or preheat the investment with a torch because oxides then will be formed that will interfere with the flow of the solder.

7. Use the reducing part of the flame, which is the feathery part just outside the blue inner cone. Flux the joint thoroughly and dry out the flux with the outer part of the flame until it has a powdery appearance. Heat the casting until it is dull red, and then, while holding a strip of solder in the soldering tweezers, dip it into the flux and feed it into the joint, while the casting is being held at a dull-red heat with the torch. Once the soldering operation has begun, do not remove the flame, because any cooling will cause oxides to form. The heat from the casting should be sufficient to melt the solder; therefore, do not put the flame directly on the solder because it will become overheated and pitting will result.
8. After the soldering has been completed, allow the investment to cool slowly before quenching and proceeding with finishing. Remember that any soldering operation that heats the entire casting is in effect a softening heat-treating operation, and heat-hardening of a repaired gold alloy casting is desirable to restore its optimal physical properties.

# CHAPTER

# 24

## Interim Removable Partial Dentures

### CHAPTER OUTLINE

Appearance  
Space Maintenance  
Reestablishing Occlusal Relationships  
Conditioning Teeth and Residual Ridges  
Interim Restoration During Treatment  
Conditioning the Patient for Wearing a Prosthesis  
Clinical Procedure for Placement

Tooth replacement is required for a variety of reasons. Sometimes, replacements may be necessary for shorter periods of time that serve alternative purposes than permanent replacement, such as while tissue is healing or related treatment is being provided. When such applications require the temporary use of removable partial dentures, their fabrication and use must be incorporated into a total prosthodontic treatment plan.

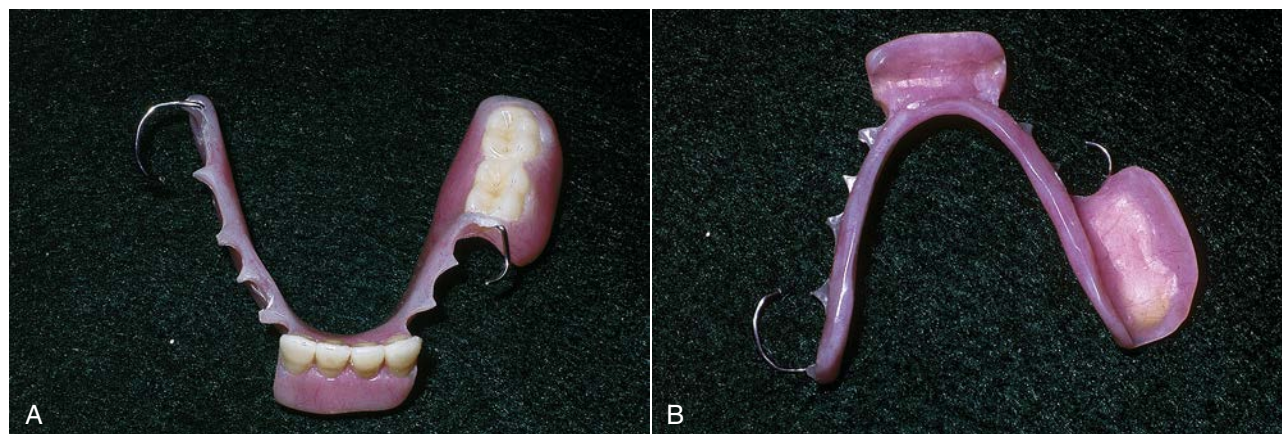
These various uses of interim prostheses for the partially edentulous mouth strive to achieve temporary goals with minimum time and expense. These prostheses are typically resin with wire retention and may include components to provide tooth support. The difficulty in achieving and maintaining strategic tooth support and stability with such prostheses makes it important that patients be made aware that these prostheses are temporary and may jeopardize the integrity of adjacent teeth and the health of supporting tissue if worn for extended periods without supportive care.

Interim prostheses may be indicated as a part of total treatment for the following:

1. Sake of appearance
2. Maintenance of a space
3. Reestablishment of occlusal relationships
4. Conditioning of teeth and residual ridges
5. Interim restoration during treatment
6. Conditioning the patient for wearing a prosthesis

### APPEARANCE

For the sake of appearance, an interim removable partial denture may replace one or more missing anterior teeth, or it may replace several teeth, both anterior and posterior. Such a restoration is usually made of resin, which may be produced by a sprinkling method, by the visible light-cured (VLC) method, or by waxing, flasking, and processing with autopolymerizing or heat polymerizing resin (Figure 24-1). It may be retained by circumferential wrought-wire clasps, Crozat-type clasps, interproximal spurs, or wire loops.



**FIGURE 24-1** **A**, Although loss of mandibular teeth does not always have a significant esthetic impact, this interim removable partial denture was needed because of the visibility of the mandibular incisors. Provision of the mandibular left molars allowed early accommodation of the residual ridge during the temporary prosthesis period. **B**, Tissue surface of the interim prosthesis revealing a rounded lingual flange and a tapered labial flange. The latter was needed to improve lip movement and reduce the feeling of bulk, both of which enhance normal lip activity.

## SPACE MAINTENANCE

When a space results from recent extractions or traumatic loss of teeth, it is usually prudent to maintain the space while the tissue heals. In younger patients, the space should be maintained until the adjacent teeth have reached sufficient maturity to be used as abutments for fixed restorations or so that an implant can be placed. In adult patients, maintenance of the space can prevent undesirable migration and extrusion of adjacent or opposing teeth until definitive treatment can be accomplished (Figure 24-2).

## REESTABLISHING OCCLUSAL RELATIONSHIPS

Interim removable partial dentures are used for the following reasons: (1) to establish a new occlusal relationship or occlusal vertical dimension; and (2) to condition teeth and ridge tissue for optimum support of the definitive removable partial denture that will follow.

Interim removable partial dentures may be used as occlusal splints in much the same manner as cast or resin occlusal splints are used on natural teeth. When total tooth support is available, there is little difference between a fixed and a removable occlusal splint, except that a removable splint is likely to be left out of the mouth unless the patient is actually made more comfortable by its presence. This is usually true when the wearing of an occlusal splint alleviates a temporomandibular joint condition. In other situations, it may be advisable to cement the removable restoration to the teeth until such time as the patient has become accustomed to, and dependent on, the jaw relationship provided by the splint.

Both fixed and removable tooth-supported occlusal splints have much in common. Either of them may be eliminated in sections as restorative treatment is being done, thus maintaining the established jaw relation until all restorative treatment has been completed. The dentist decides whether

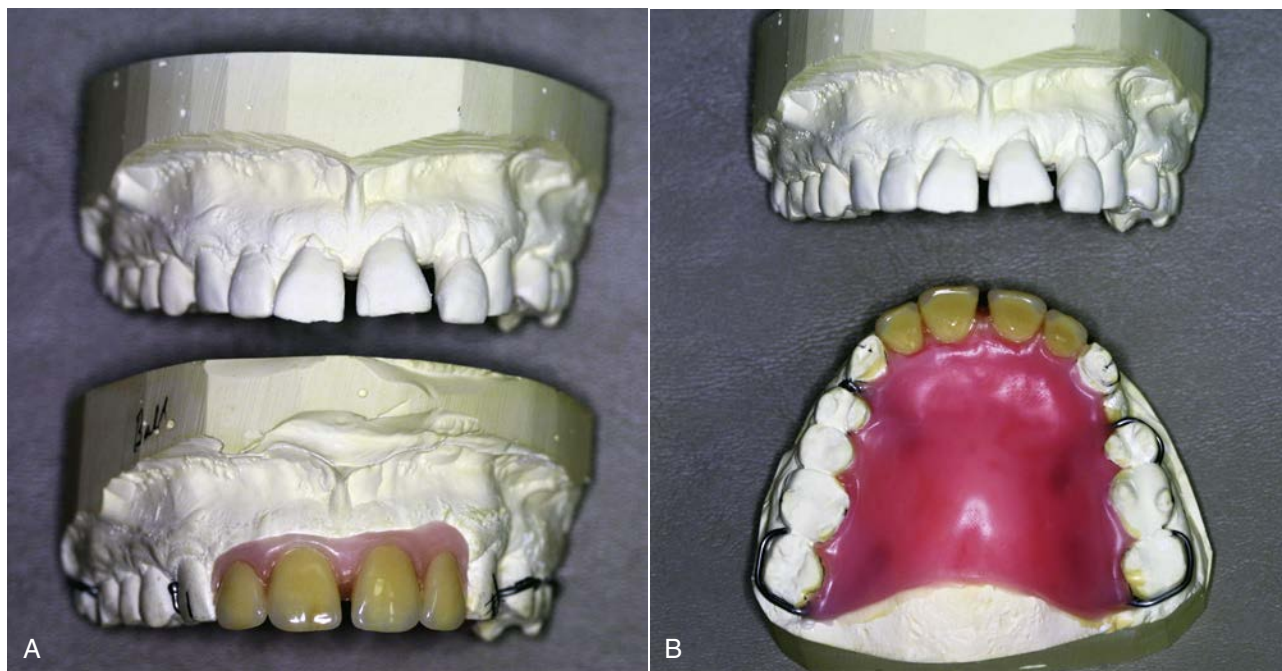
these are to be fixed or removable, and whether they are made of a cast alloy, a composite, or a resin material.

When one or more distal extension bases exist on an occlusal splint, a different situation occurs. The establishment of a new occlusal relation depends on the quality of support and stability the splint receives from the denture support. Both broad coverage and functional basing of tissue-supported bases are desirable, along with some type of occlusal rest on the nearest abutments. Any tissue-supported occlusal splint should be at least relined in the mouth with an autopolymerizing reline resin to afford optimal coverage and support for the distal extension base.

## CONDITIONING TEETH AND RESIDUAL RIDGES

O. C. Applegate, in an article on the choice of partial or complete denture treatment, emphasized the advantages of conditioning edentulous areas to provide stable support for distal extension removable partial dentures. This is accomplished by having the patient wear an interim removable partial denture for a period of time before the final base is fabricated. In the absence of opposing occlusion, stimulating the underlying tissue by applying intermittent finger pressure to the denture base is advised. Whether the stimulation results from occlusal or finger pressure, there seems to be little doubt that the tissues of the residual ridge become more capable of supporting a distal extension removable partial denture when they have been previously conditioned by wearing of a restoration.

Abutment teeth also benefit from wearing of an interim restoration when such a restoration applies an occlusal load to those teeth, either through occlusal coverage or through occlusal rests. Commonly, a tooth that



**FIGURE 24-2** **A**, Malpositioned maxillary anterior teeth require extraction. Following a period of healing, the patient will decide on a definitive treatment option, which may include a removable partial denture or an implant-supported prosthesis. Because the length of time until definitive care will be provided is not known, a temporary interim prosthesis not only replaces esthetically important teeth but provides stabilization of adjacent and opposing dentition as well. **B**, Occlusal view of the interim prosthesis showing clasp placement at the most posterior locations without crossing of the occlusion and anterior positions bilaterally. Full palatal coverage allows less stress to the remaining maxillary dentition and may prevent prosthesis-induced gingival trauma as well as tooth movement.

is to be used as an abutment for a removable partial denture has been out of occlusion for some time. Immediately on applying an occlusal load to that tooth sufficient to support any type of removable prosthesis, some intrusion of the tooth will occur. If such intrusion is allowed to occur after initial placement of the final prosthesis, the occlusal relationship of the prosthesis and its relation to the adjacent gingival tissue will be altered. Perhaps this is one reason for gingival impingement, which occurs after the prosthesis has been worn for some time, even though seemingly adequate relief was provided initially. When an interim removable partial denture is worn, such abutment teeth have an opportunity to become stabilized under the loading of the temporary restoration, and intrusion will have occurred before the impression for the master cast is made. There is sufficient reason to believe that both abutment teeth and supporting ridge tissue are more capable of providing continued support for the removable partial denture when they have been previously conditioned by the wearing of a temporary interim restoration.

### INTERIM RESTORATION DURING TREATMENT

In some instances, an existing removable partial denture can be used with modifications as an interim removable partial denture. Such modifications may include relining and adding

teeth and clasps to an existing denture. In other instances, an existing removable partial denture may be converted to a transitional complete denture for immediate placement while the tissue heals and an opposing arch is prepared to receive a removable partial denture. Sometimes a temporary interim removable partial denture must be made to replace missing anterior teeth in a partially edentulous arch, which are ultimately to be replaced with fixed restorations. On occasion, the anterior portion of the restoration is cut away when the fixed restorations are placed; this leaves the remainder of the denture to be worn while posterior abutment teeth are prepared. Still another type of interim removable partial denture is one in which missing posterior teeth are replaced temporarily with a resin occlusion rim rather than with occluding teeth.

### CONDITIONING THE PATIENT FOR WEARING A PROSTHESIS

A temporary restoration may be made to aid the patient in making a transition to complete dentures when the total loss of teeth is inevitable. Such a removable partial denture also may be considered a valid part of the treatment, because the patient is at the same time being conditioned to wear a removable prosthesis. It should be considered strictly a temporary measure that provides the patient with a restoration for the remaining life of the natural teeth when further

restorative treatment of those teeth is impractical or economically or technically impossible.

This type of a removable partial denture may be worn for prolonged periods, in the meantime undergoing revision, modification to include additional teeth lost, or relining when such becomes necessary or advisable. The dentist should agree to provide such a removable partial denture only under the following conditions: (1) that a definite fee for the treatment is appropriate and that the fee will depend on the servicing necessary; and (2) that when further wearing of the transitional denture is unwise and jeopardizes the health of remaining tissue, the transition to complete dentures will proceed.

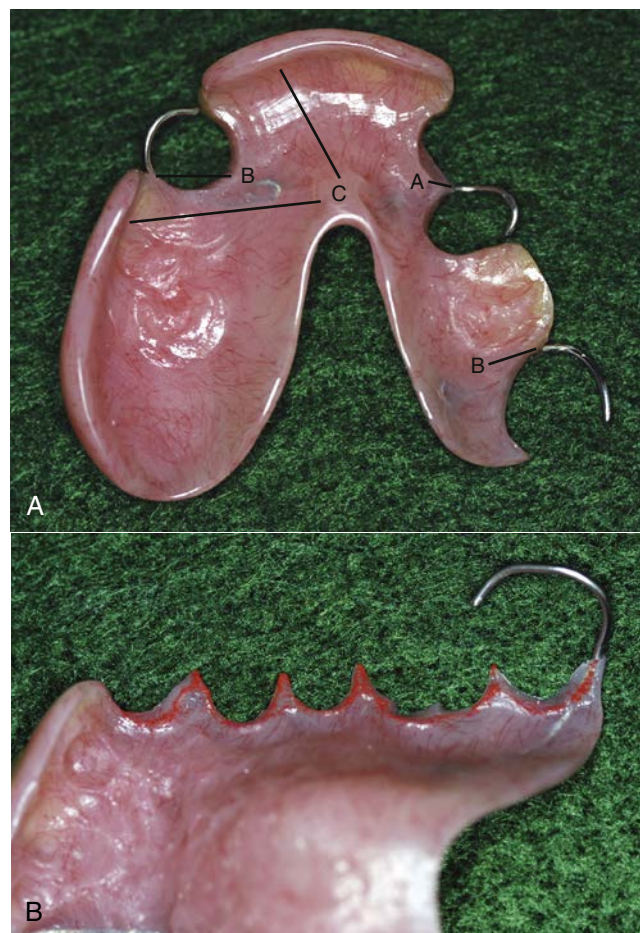
It is imperative that a distinction is made between temporary restorations and a true removable partial denture service, and that the patient is advised of the purposes and limitations of such restorations.

### CLINICAL PROCEDURE FOR PLACEMENT

It is important to consider proper fitting of the prosthesis to ensure comfortable use during the temporary phase of treatment. Careful attention to planned use of the teeth for support, stability, and retention without undue stress from gingival tissue contact or improper occlusal loading will ensure more comfortable use.

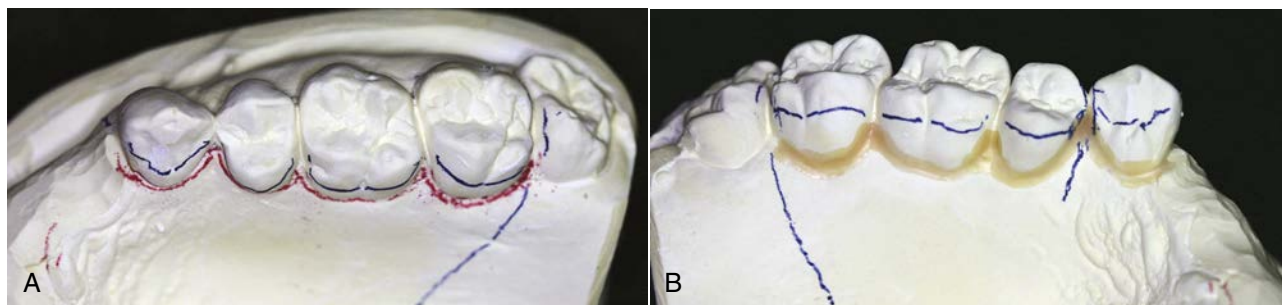
To ensure proper use of the remaining natural teeth, the prosthesis must be completely seated in the arch. Common areas requiring adjustment to ensure complete seating include interproximal extensions, regions where clasps exit from the acrylic-resin base, tissue undercuts (labial undercuts from recent extractions or the lingual/retromylohyoid region), and any portion of the prosthesis that lies inferior to the height of contour, especially if bilaterally opposed (Figure 24-3).

Once seated, it is important to check that no undue pressure to the marginal gingival region is present. To facilitate this step, and to help with the complete seating requirement, it is possible to have the laboratory block out the marginal gingival region and infrabulge regions to reduce seating problems (Figure 24-4). Infrabulge regions may include lingual and palatal tooth surfaces, as well as modification space regions. Because temporary prostheses are generally fabricated on unprepared teeth, these regions often require correction. However, if the blockout is not accomplished carefully, the prosthesis may seat easily, but it may not be as stable as possible because of insufficient tooth contact. Stability and retention are improved when it is possible to have the prosthesis contact portions of the teeth superior to the height of contour because of tooth-dictated control of movement.

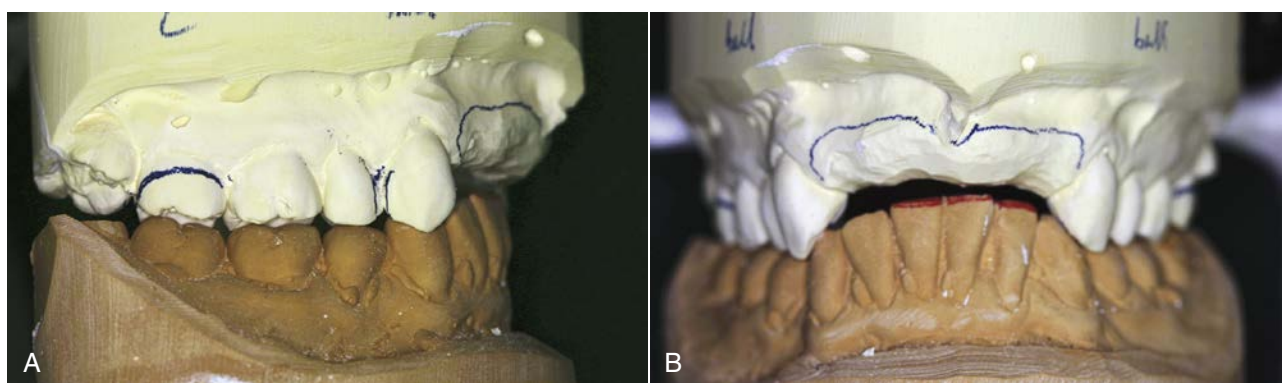


**FIGURE 24-3** **A**, Maxillary interim removable partial denture. Areas that require adjustment commonly include interproximal extensions (**A**), the region where the clasp exits from the resin (**B**), and tissue undercuts of prosthesis extensions (**C**). **B**, Interproximal tooth extensions and regions where marginal gingival is crossed by the prosthesis should be carefully adjusted (*outlined in red*).

It is possible to create occlusal imbalance if the lingual/palatal portion of the prosthesis is too bulky. Consequently, an opposing cast should be provided to allow placement of clasps and acrylic-resin contours that do not cause occlusal interference (Figure 24-5). Once fully seated and relieved appropriately, the occlusion should contribute to the remaining natural dentition (as in a definitive prosthesis) and harmonize with natural tooth-dictated function. Typically, the prosthesis should not be the sole source of occlusal contact. In such situations, the functional forces are concentrated at the acrylic resin-to-tooth junction, and predictably a change in orientation occurs, allowing tissue-ward movement and a change in occlusion with an increase in soft tissue contact.



**FIGURE 24-4** **A**, Maxillary cast with an outline of the prosthesis design and with the region at the marginal gingival crossing outlined. If the cast is not relieved at the marginal gingival, the prosthesis should be corrected before insertion. **B**, Cast showing gingival regions relieved with baseplate wax. A duplicate of this cast will provide the necessary relief for use as a processing cast. If interproximal regions have undercuts, these can also be blocked out to allow easier insertion of a temporary prosthesis.



**FIGURE 24-5** **A**, Evaluation of mounted casts allows determination of the occlusal impact on maxillary temporary prosthesis clasp selection and placement. Interocclusal space allows placement of a ball clasp distal to the canine and a circumferential clasp from the distal of the second molar, both without occlusal interference if the clasps are carefully contoured. **B**, Anterior cast modification in anticipation of postextraction ridge contours for this immediate temporary prosthesis. Diagnosis of the limited space at the anterior region before surgery allows presurgical discussion of the possible need for mandibular incisor modification to improve the interim and final prosthesis occlusion.

# CHAPTER

# 25

## Removable Partial Denture Considerations in Maxillofacial Prosthetics

### CHAPTER OUTLINE

#### Maxillofacial Prosthetics

Maxillofacial Classification

#### Timing of Dental and Maxillofacial Prosthetic Care for Acquired Defects

Preoperative and Intraoperative Care

Interim Care

Potential Complications

Defect and Oral Hygiene

Definitive Care

#### Intraoral Prostheses: Design Considerations

#### Surgical Preservation for Prosthesis Benefit

Maxillary Defects

Mandibular Defects

Mandibular Reconstruction—Bone Grafts

#### Maxillary Prostheses

Obturator Prostheses

Speech Aid Prostheses

Palatal Lift Prostheses

Palatal Augmentation Prostheses

#### Mandibular Prostheses

Evolution of Mandibular Surgical Resection

Type I Resection

Type II Resection

Type III Resection

Type IV Resection

Type V Resection

Mandibular Guide Flange Prosthesis

#### Jaw Relation Records for Mandibular Resection Patients Summary

### MAXILLOFACIAL PROSTHETICS

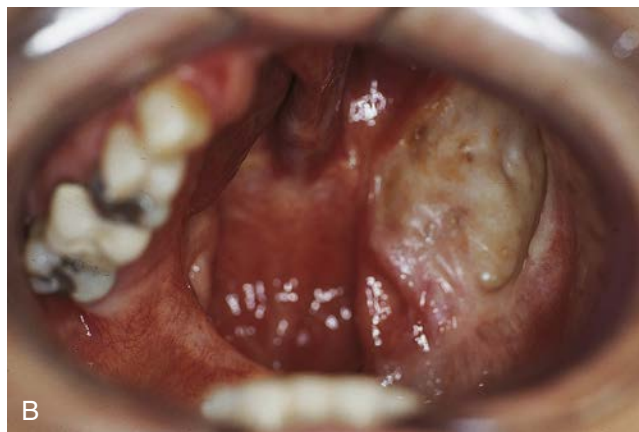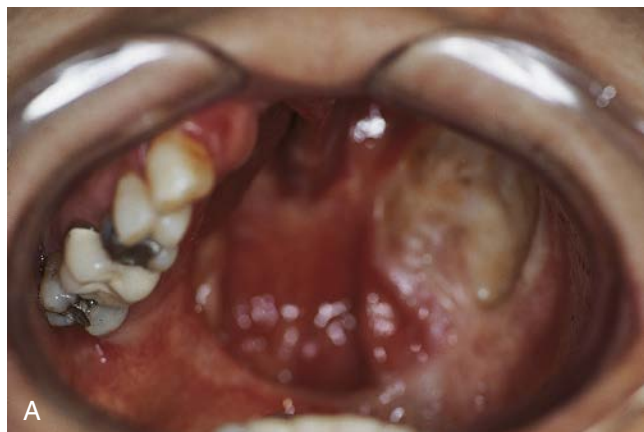The preceding chapters have dealt with prosthesis considerations for partially edentulous individuals. In these patients, the extent of loss includes teeth and a varying degree of residual ridge bone, yet the remaining anatomy of the jaws and adjacent regions is functionally and physically intact. For these patients, the major distinguishing feature that affects removable partial denture design is whether the prosthesis will be tooth-supported or tooth- and tissue-supported.

The maxillofacial patient can experience unique alterations in the normal oral/craniofacial environment; these result from surgical resections ([Figure 25-1](#)), maxillofacial trauma, congenital defects, developmental anomalies, or neuromuscular disease. In contrast to the above, when removable partial dentures are considered for these individuals, not only are tooth and tissue support considerations important, but the design must also take into account what impact the altered environment will have on prosthesis support, stability, and retention. In general, environmental changes reduce the capacity for residual teeth and tissue to provide optimum cross-arch support, stability, and retention.

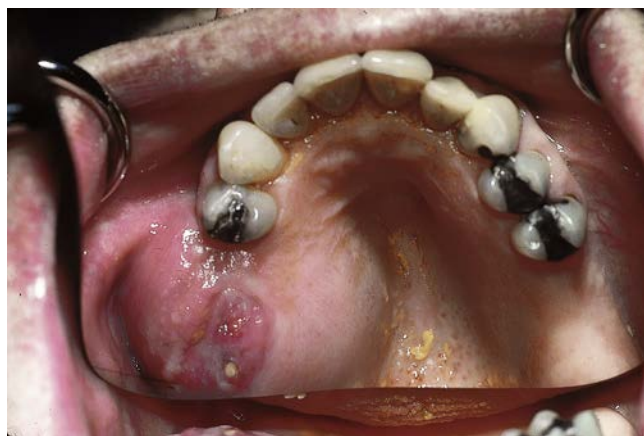As a subspecialty of prosthodontics, maxillofacial prosthetics is concerned with the restoration and/or replacement of the stomatognathic system and associated facial structures with prostheses that may or may not be removed on a regular or elective basis. This chapter discusses important background information related to maxillofacial prostheses and the principals involved in removable partial denture design for the maxillofacial patient.

#### Maxillofacial Classification

Patients can be categorized by maxillofacial defects that are acquired, congenital, or developmental. Acquired defects



**FIGURE 25-1** A unilateral arrangement of maxillary teeth (A), no remaining horizontal hard palate, and a surgical defect, which includes nasal and sinus cavities (B). This unique environment, which is the result of a surgical resection, requires careful application of removable prosthodontic principles modified for maxillofacial needs.



**FIGURE 25-2** Large squamous cell carcinoma involving the maxillary tuberosity region, which will result in an acquired defect following surgical removal.

include those that are the result of trauma or of disease and its treatment. These may include a soft and/or hard palate defect resulting from removal of a squamous cell carcinoma of the region (Figure 25-2). Congenital defects are typically craniofacial defects that are present from birth. The most common of these include cleft defects of the palate that may include the premaxillary alveolus. Developmental defects are those defects that occur because of some genetic predisposition that is expressed during growth and development (Figure 25-3). Such a classification order is helpful as patients within each category share similar characteristics (beyond those features specifically related to the prosthesis design), which become part of the total management plan. For example, prosthetic management of an adult who has experienced a maxillectomy procedure can be quite different from management of a patient with an unrepaired cleft palate.

Another helpful way to classify maxillofacial patients is by the type of prosthesis under consideration. Consequently, prostheses are said to be extraoral (cranial or facial

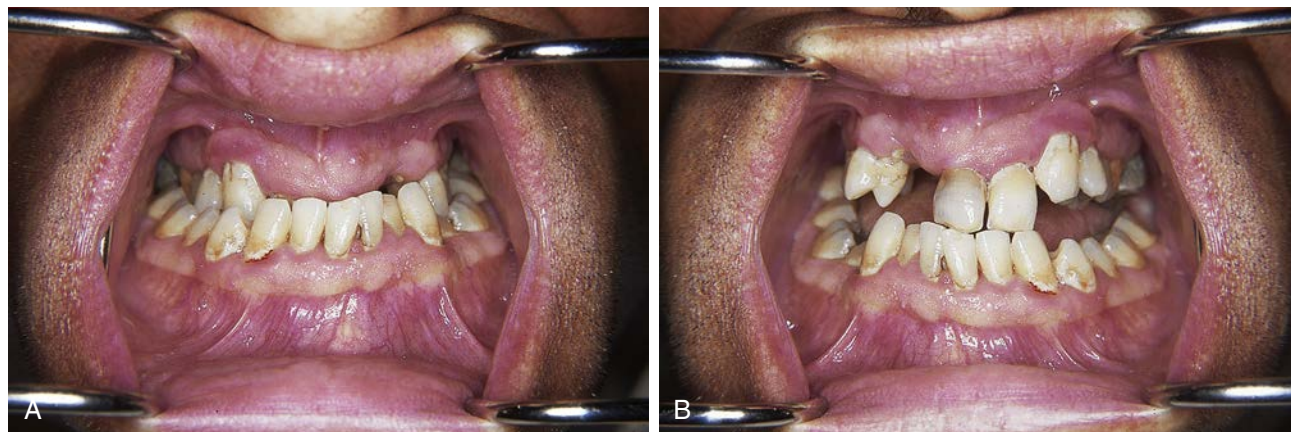
replacement) or intraoral (involving the oral cavity); interim (for short periods of time, often perioperative) or definitive (more permanent); and treatment (used as a component of management, such as a splint or stent) prostheses.

### TIMING OF DENTAL AND MAXILLOFACIAL PROSTHETIC CARE FOR ACQUIRED DEFECTS

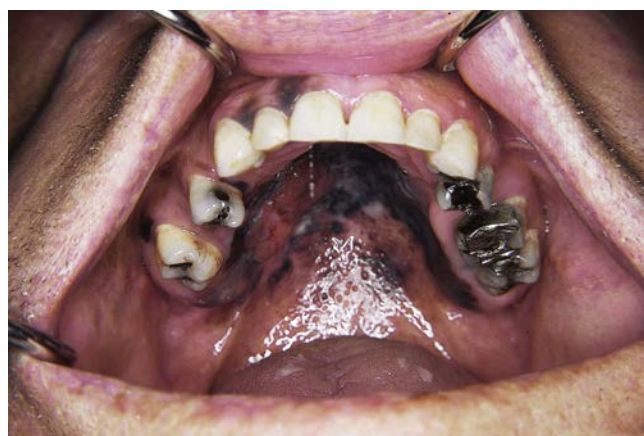Acquired defects are the most common maxillofacial defects managed by using removable prostheses. A conceptual framework for the timing of dental/oral care that best emphasizes the initial important surgical requirements, followed later by the important prosthetic requirements, is helpful to consider regarding the coordination of care for patients with acquired defects. Such a framework considers preoperative and intraoperative interim care and definitive care. Although it may seem unrelated initially, it is included in this discussion of removable partial dentures for maxillofacial applications because of the important impact that decisions made at all stages of management can have on prosthesis function and patient outcomes.

#### Preoperative and Intraoperative Care

The planning of prosthetic treatment for acquired oral defects should begin before surgery. For the patient facing head and neck surgery, consideration should be given to dental needs that will improve the immediate postoperative course. Consequently, the prosthodontist who will help with management of the patient's care should see the patient before surgery (Figure 25-4). The dental objectives of the preoperative and intraoperative care stages are to remove potential dental postoperative complications, to plan for the subsequent prosthetic treatment, and to make recommendations for surgical site preparation that improve structural integrity. Important patient benefits of such a preoperative consultation include the opportunity to develop the patient-clinician relationship, to discuss the functional deficits associated with the anticipated surgical procedure, and to describe how and to what extent the stages of prosthetic



**FIGURE 25-3** A functional jaw position developed because of a combination of tooth loss and growth discrepancy. This developmental defect is illustrated by a protruded and over-closed mandibular position (**A**), which has created a significantly irregular maxillary occlusal plane (**B**).



**FIGURE 25-4** Presurgical presentation of a patient with a maxillary malignant melanoma. The benefits of having such a visit before surgery are both psychological and functional. The psychological benefits include the chance to discuss functional deficits associated with the anticipated surgical procedure and to describe how and to what extent the stages of prosthetic management will address them. The functional benefit from a prosthesis standpoint is that strategically important teeth, for definitive and/or interim prosthesis use, can be discussed with the surgical team and treatment planned for preservation.

management will address them. The benefit from a prosthesis standpoint is that strategically important teeth, for definitive and/or interim prosthesis use, can be discussed with the surgical team and treatment planned for preservation.

The immediate postoperative period will be significantly challenging to the patient. If pre-existing dental disease is severe enough to potentially create symptoms during the immediate postoperative period, treatment should be provided to remove such a complication. Large carious lesions, which could create pain, can be temporarily restored by endodontic therapy if they offer some advantage for postoperative prosthetic function. Teeth exhibiting acute periodontal disease (such as acute necrotizing ulcerative gingivitis)

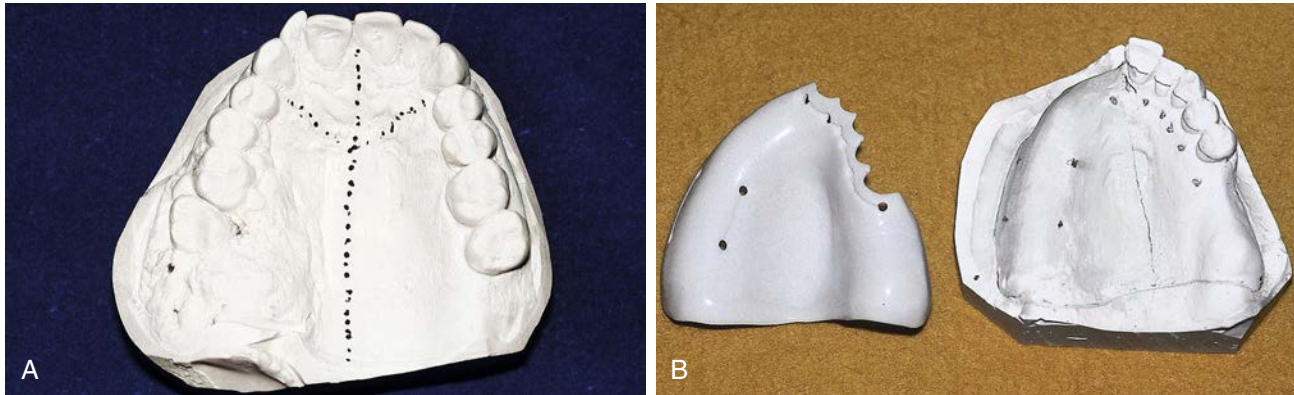
should be treated, as should any periodontal condition that could potentially cause postoperative pain because of excessive mobility or oral infection. Any tooth deemed nonrestorable because of advanced caries or periodontal disease, and not critical for temporary use during the interim care period following temporary treatment, should be removed before, or at the time of, surgical resection. Teeth that may appear to have a limited long-term prognosis may significantly enhance prosthetic service during the initial postsurgical period and should be maintained until the initiation of definitive care.

Impressions are made of the maxillary and mandibular arches to provide a record of existing conditions and occlusion to allow fabrication of immediate or interim prostheses (Figure 25-5) and to assess the need for immediate and delayed modification of the teeth or adjacent structures to optimize prosthetic care. It is important at this stage to begin planning for the definitive prosthesis because the greatest impact on the success of the maxillofacial prosthesis stems from the integrity of the remaining teeth and surrounding structures.

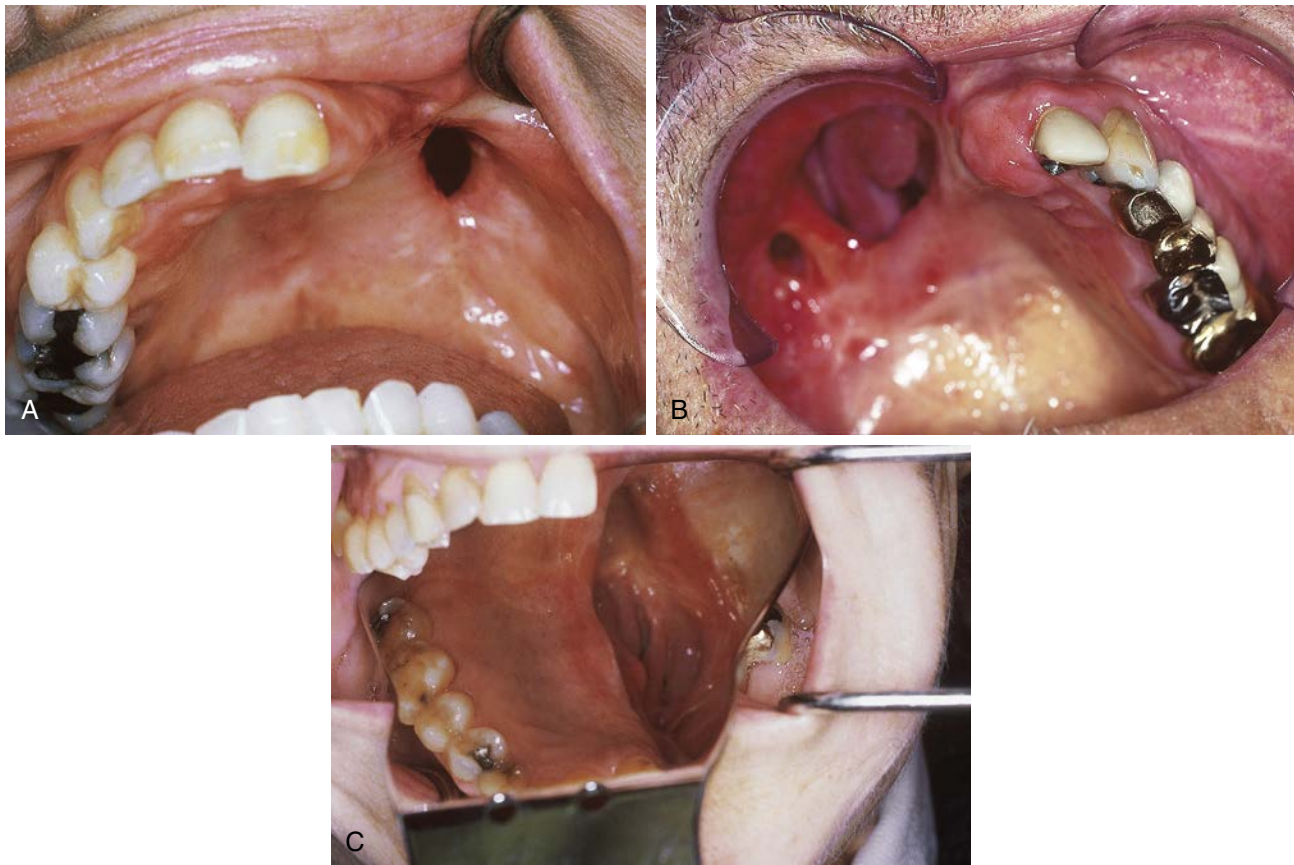
### Interim Care

The major emphasis during this stage of care is the surgical (and adjunctive) management needs of the patient. In today's environment of appropriately aggressive mandibular surgical reconstruction, mandibular discontinuity defects are seldom a surgical outcome. When discontinuity defects in the mandible result following surgery, interim prosthetic care is not indicated and the discussion will be directed to the maxillary defect.

The typical maxillary acquired defect results in oral communication with the nose and/or maxillary sinus, although the composition of the surgical defect may vary widely (Figure 25-6). This creates physiologic and functional deficiencies in mastication, deglutition, and speech. Such defects have a negative impact on the psychological disposition of patients, especially if the defect also affects cosmetic appearance. The major deficiencies directly



**FIGURE 25-5** A, A maxillary cast of the presurgical oral condition, which allows consultation with the surgeon regarding resection margins and the benefits of preservation of teeth. B, Another maxillary cast altered, following consultation with the head and neck surgeon, to allow fabrication of a surgical stent. Perforations are made to allow fixation to the remaining teeth and to superior anatomic regions with the use of wires.



**FIGURE 25-6** Maxillary defects. A, A resection that resulted in a small communication with the sinus, with some hard palate remaining, and adjacent mucosa typical of the oral cavity. B, A resection that did not follow classic maxillectomy technique; however, the midline resection was made through the socket of tooth #9, preserving its alveolar housing. C, A resection along the palatal midline that did not preserve oral mucosa at the resection margin, which allows chronic ulceration at this point of prosthesis fulcrum. Notice the split-thickness skin graft in the superior-lateral region. Engagement of this region can provide support to the obturator extension, minimizing movement with function.

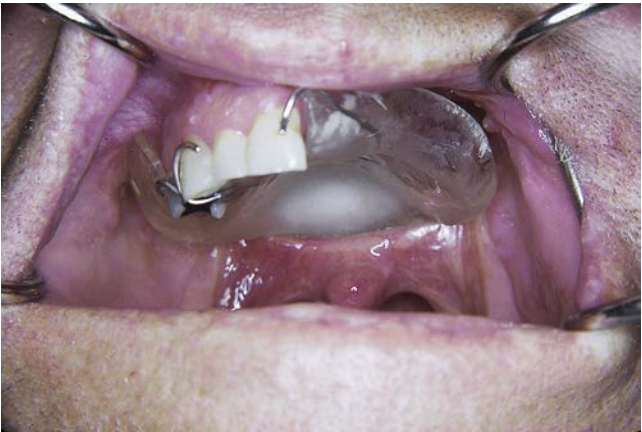addressed by prosthetic management at this interim care time are deglutition and speech. This immediate postsurgical time is very challenging for patients, and it is important that they have been mentally prepared for it during the preoperative period. However, even with preliminary discussion, the impact of the surgery is often very distressing. An initial focus on improvement in swallowing and speech with the interim prosthesis can help boost the rehabilitation process significantly.

The patient is counseled that chewing on the defect side is not allowed because of its effect on prosthesis movement. The objective of this interim obturator prosthesis is to separate the oral and nasal cavities by obturating the communication. Such obturator prostheses most commonly refer to obturation of a hard palatal defect but conceptually can be considered the same for soft palatal defects at this stage of management, because both attempt to artificially block the free transfer of speech sounds and foods/liquids between the oral and nasal cavities. The advantages of having the ability

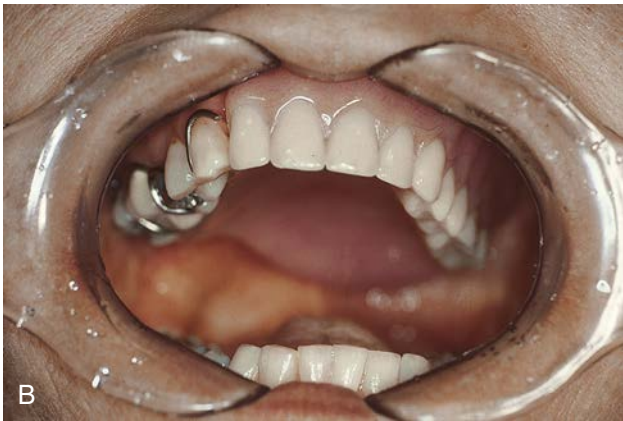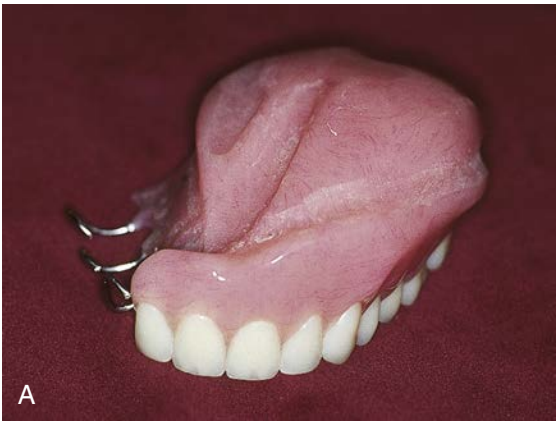
to take nourishment by mouth without nasal reflux (allowing for nasogastric tube removal) and to communicate with family members are a significant component of early prosthetic management. How immediately such care should be provided depends on a number of factors.

A prosthesis can be provided at surgery (see [Figure 25-5, B](#)). Such a surgical obturator prosthesis is placed at the time of surgical access closure and serves to control the surgical dressing and split-thickness skin graft during the immediate postsurgical period. Such prostheses are best stabilized by appropriate wiring to remaining teeth or alveolar bone, or they may be suspended from superior skeletal structures. For some patients who have teeth remaining, such an immediate surgical prosthesis could be retained by wires in the prosthesis that engage undercuts on the teeth and would be removable; however, the ability to control the surgical dressing may be less predictable with such an approach. Immediate placement of a prosthesis has been suggested to improve patient acceptance of the surgical defect, although no measure of this psychological impact has been shown; this method offers greater assurance of adequate nourishment by mouth—potentially precluding the use of a nasogastric tube.

It may be preferable to stabilize the surgical dressing by suturing a sponge bolster to provide stabilization to the split-thickness skin graft. Following the primary healing stage, the sponge with packing (or the immediate prosthesis if used) is removed by the surgeon and an interim obturator prosthesis can be placed ([Figure 25-7](#)). For the patient who has been provided with bolster obturation, the presurgical prosthodontic evaluation is very important to ensure that the patient is prepared for the transition from bolster to prosthesis, and to ensure that plans for the prosthesis are made, especially if an interim prosthesis is to be fabricated. Interim prostheses are wire-retained resin prostheses that generally do not have teeth initially but may be modified with the addition of teeth after an initial period of accommodation ([Figure 25-8](#)).



**FIGURE 25-7** An interim obturator prosthesis fabricated of resin, retained by wires, and provided following surgical pack removal.



**FIGURE 25-8 A-B**, An interim obturator prosthesis fabricated of resin, retained by wires, and including artificial teeth for cosmesis during an extended period of recovery. The superior and lateral surfaces may need modification to improve stability and retention as the surgical site matures and allows more aggressive engagement.

When surgical defects become large, as in a near-total maxillectomy defect, prosthesis support, stability, and retention are not likely to be satisfactory unless extension into the defect can be accomplished. When teeth remain, the impact of the defect size is somewhat lessened. But when the remaining teeth are few or are located unilaterally in a straight line (see Figure 25-1), the mechanical advantage for prosthesis stability is less. The ability of the defect tissue to offer the needed mechanical characteristics to the interim prosthesis is unpredictable at best. It is this patient who benefits the most from a well-planned surgery that preserves oral and defective anatomy to the advantage of the prosthesis.

### Potential Complications

The interim phase of prosthetic management can last for 3 months or more. The primary objective is to allow the patient to pass from an active surgical (and adjunctive treatment) phase to an observational phase of management with minimal complications. During the transition, the patient recovers from the systemic effects of the treatment, deals with the psychological impact of the defect using his or her own coping strategy, and becomes more aware of the functional deficits associated with the surgical defect(s). Minimizing potential complications during the transition, which includes preparing the patient for those anticipated to occur, facilitates the process for the patient and family. Common interim prosthetic complications are related to tissue trauma and the associated discomfort; inadequate retention (looseness) of the maxillary prosthesis; incomplete obturation with leakage of air, food, and liquid around the obturator portion of the prosthesis; and the tissue effects of chemotherapy and radiation therapy.

Discomfort related to the use of interim prostheses can be due to surgical wound healing dynamics, defect conditions, mucosal effects of adjunctive treatment, and/or prosthetic fit. Common areas of surgical wound pain include junctions of the oral and lip/cheek mucosa, especially at the anterior alveolar region for maxillectomy patients. The lateral scar band produced when the skin graft heals to the oral mucosa can be the site of discomfort in some patients. When a split-thickness skin graft is not placed, discomfort caused by the prosthesis fit within the defect can be a consistent and long-term problem. The hard palate surgical margin when not covered with surgically reflected oral mucosa most often will be covered by nasal epithelium, which is also very prone to discomfort. Alveolar bone cuts that have not been rounded will perforate the oral mucosa and will be painful whether or not a prosthesis is worn. This is most frequently a finding for mandibular resection superior alveolar margins when the reconstruction has restored the lower and labial contour to the mandible, but the intraoral mucosa at the superior surface is under tension because of a difference in height.

The prosthesis can create discomfort via excessive static pressure from the internal surfaces or from overextension into the vestibular tissue. The prosthesis can also create discomfort caused by functional movement associated with

swallowing and speech. As was discussed previously, prosthesis movement is dependent on the quality of the supporting structures. Teeth offer the best support, followed by firm edentulous ridges, and lastly, surgical defect structures. The tongue, opposing dentition, and cheek/lips place force on the prosthesis that must be resisted over a large area to prevent movement. Because the defect is least likely to be able to resist movement, the relative size and structural integrity of the defect compared with the remaining teeth and/or edentulous ridge determine the potential prosthesis movement and most affect the discomfort related to such movement.

When teeth are available (and especially if located both close to and far away from the defect), retention is enhanced by engaging them with prosthetic clasps. Clasp retention is the most efficient means of effectively resisting dislodgment. The clasps will require periodic adjustment to maintain their effectiveness, as the movement of the prosthesis flexes the clasps beyond their elastic recovery capacity. For edentulous patients, because the surgical defect allows communication between cavities, the fitting surface of the prosthesis can no longer create a closed environment to develop a seal for resisting dislodgment. Consequently, during the interim phase, when complete engagement of the defect is not possible because of tissue sensitivity, the careful use of denture adhesives is required to facilitate retention. The patient should be instructed that adhesives can alter the prosthesis fit and disrupt the close adaptation of the prosthesis to the remaining tissue. Used adhesive must be removed before new adhesive is reapplied, to maintain fit and hygiene. Also related to retention is the inability to completely place the prosthesis, which for maxillectomy patients can be due to contracture of the scar band. When the maxillary resection leaves the cheek unsupported by bone, the prosthesis provides the necessary support for wound maturation. If the patient removes the interim obturator prosthesis for a period sufficient to allow contraction, the prosthesis will be more difficult to place. Once placed, however, the scar band will relax and subsequent removal and placement will be more easily accomplished. The discomfort associated with this phenomenon is mostly due to patient anxiety and can be effectively addressed by reassuring the patient that this is an easily handled complication.

During the immediate postoperative healing stage, the surgical defect will undergo a change in dimension that affects the prosthesis fit and seal. If space is created with the change, speech will be altered (increase in nasality) and nasal reflux with swallowing will occur. The interim prosthesis is made of easily adjustable material to allow accommodation for such changes. The most common manner of adjustment is through the use of temporary resilient denture lining materials, which offer the ability to mold to the tissue directly and reduce the mechanical effects of movement by virtue of their viscoelastic nature. Leakage can occur quite easily when swallowing unless the patient follows certain instructions. Because the prosthesis cannot offer a watertight seal that matches the presurgical state, patients will be instructed

not to swallow large quantities at one time, and to hold their heads horizontal when swallowing. When the head posture is forward, as when one is taking soup from a spoon, leakage easily occurs around the obturator component of a prosthesis. Another difficult condition that presents difficulty in controlling leakage on swallowing is the midline soft palatal resection. The functional movement of the remaining soft palate is often very difficult to retain with a prosthesis. It is also difficult to provide an adequate seal during the interim prosthesis stage.

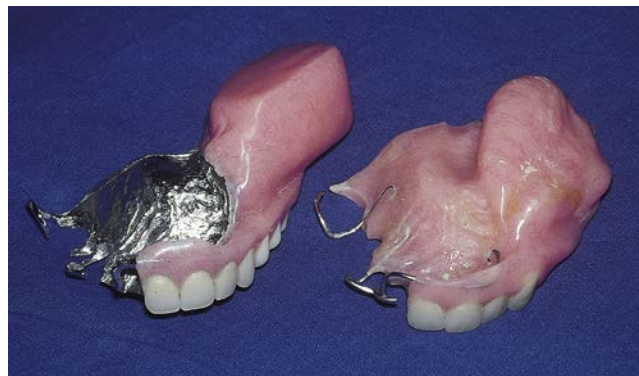When combination treatment is prescribed for the patient, it is commonly provided during the postsurgical phase, when the patient is using an interim prosthesis. The major intraoral complication associated with both radiation therapy and chemotherapy, which affects interim prosthetic service, is mucositis. A careful balance between comfort and adequate fit for speech and swallowing needs must be determined with input from the patient. If prosthesis adjustment can offer relief to ensure completion of treatment and the patient understands the impact adjustment may have on speech and swallowing, then it should be accomplished.

The long-term effects of radiation therapy, especially radiation-induced xerostomia and capillary bed changes (obliterative endarteritis) within the mandible, present a potentially significant threat to any remaining dentition and to the development of osteoradionecrosis. During the interim prosthesis stage, the patient will begin to notice the xerostomic effects, which include development of thick, ropy saliva that makes swallowing more difficult, and an increase in discomfort associated with removable prostheses.

### Defect and Oral Hygiene

Following surgical pack removal, the defect site will mature with time and exposure to the external environment. Initial loss of incompletely consolidated skin graft, mucous secretions mixed with blood, and residual food debris within the cavity are common oral findings for the patient with a maxillary defect. These cause concern for patients who are unprepared and unfamiliar with these new oral findings. As they become more familiar with the surgical defect, patients should be encouraged to clean the defect of food debris and mucous secretions routinely. Defect hygiene will allow quicker healing and will improve the ability to adequately fit a prosthesis. Common defect hygiene practices include (1) lavage procedures, which include rinsing of the defect during normal showering, (2) rinsing of the defect using a bulb syringe or a modified oral irrigating device (modified to provide a multiple orifice “shower” effect), and (3) manual cleaning procedures, such as the use of a sponge-handled cleaning aid. Frequently, dried mucous secretions are difficult to remove and require adequate hydration before mechanical removal.

Following surgical pack removal, the patient may be reluctant to begin oral hygiene practices because of oral discomfort. As patients use the interim prosthesis, which requires daily removal and cleaning at a minimum, they will realize



**FIGURE 25-9** A definitive (*left*) and interim (*right*) obturator prosthesis, contrasting the materials used and the obturator bulb contour. Clasp retention is more stabilizing with the definitive prosthesis because of the cast half-round clasp configuration, the use of embrasure clasps, and the opportunity for guide-plane use. Also, because the surgical site is more mature, prosthesis extension into this region to augment support, stability, and retention when necessary is possible.

the need for and benefit of normal oral hygiene practices because of improved prosthesis fit and tolerance. When teeth are remaining, it is important to the success of long-term prosthesis care to maintain a high level of oral hygiene. This is more critical for patients who exhibit xerostomia and have increased risk of caries. For these patients, daily application of fluoride in custom-formed carriers is prescribed along with frequent professional cleanings. The successful use of maxillofacial prostheses is enhanced greatly by the support provided by natural teeth. Consequently, during the interim prosthetic period, periodontal management procedures are begun in anticipation of the definitive treatment to allow a smooth transition from the interim to definitive prosthetic stages.

### Definitive Care

Surgical reconstruction for maxillofacial defects is an evolving practice for head and neck cancer care. Prosthodontic management for mandibular resection patients most commonly involves implant prostheses supported by a microvascular free flap. The evolution of similar techniques for the surgical reconstruction of maxillary defects resulting in an implant-supported prosthesis is gaining in application.

When the active treatment phase has been completed and no surgical reconstruction has been provided, definitive prosthetic management can be initiated for as long as it takes the defect tissue to mature sufficiently to tolerate more aggressive manipulation and obturation. This phase can be considered a transition for the patient–physician relationship, in which the primary emphasis shifts from active treatment to observation. The primary emphasis from the patient’s standpoint shifts to prosthetic management, and the goals and design of the prosthesis differ from those of the interim prosthesis (Figure 25-9). However, for some patients, more definitive prostheses are delayed because of

general health concerns, questionable tumor prognosis or control, or failure of the patient to reach a level of oral and/or defect hygiene that warrants more sophisticated treatment. Although this phase of management can be considered elective, without definitive prostheses, patients are not afforded the opportunity for complete rehabilitation. It is the extended use of temporary prostheses beyond their serviceable life span that has given a poor impression of prosthetic service to many surgeons and patients. Every opportunity should be provided to the patient for the most complete rehabilitation possible, and this necessitates consideration of more definitive prostheses.

From the previous discussion regarding removable prosthetic physiology, the inability of these static artificial replacements to mimic their natural counterparts results in less than ideal functional measures. Factors related to the structural integrity of the surgical defect and associated reconstructions as they affect this already compromised functional capacity are important considerations, especially when few teeth remain. As was stated previously, the fact that control of removable maxillofacial prostheses has a large skilled performance requirement of patients suggests that oral and defect structures adjacent to the prostheses are important for successful performance. This is crucial to an understanding of the impact that postsurgical defect characteristics and soft tissue reconstructions have on maxillofacial prosthesis management. The reasons for this are twofold: (1) the opportunity for maximal prosthetic benefit necessitates consideration of surgical site characteristics that are separate from classic tumor control approaches; and (2) the ability of the patient to biomechanically control large removable prostheses following surgery may be notably hindered by surgical closure/reconstruction options. Surgical outcomes that can improve prosthetic function without adversely affecting tumor control should be considered and will be described for the more common surgical defects and associated prostheses.

### INTRAORAL PROSTHESES: DESIGN CONSIDERATIONS

Maxillofacial prosthetics is largely a removable prosthetic discipline, with the exception of dental implant-retained prostheses for some applications. For maxillofacial reconstruction with removable partial denture prostheses, typical goals of treatment consist of a well-supported, stable, retentive prosthesis that is acceptable in appearance and exhibits minimal movement under function, thereby preserving the maximum amount of supporting tissue. A strategy for achieving these goals includes maximum coverage of the edentulous ridge within the movement capacity of the muscular attachments, maximum engagement of the remaining teeth to help control retention and movement under function, and placement of artificial teeth to facilitate maintenance of this prescribed tooth-tissue contact during normal functional contacts. Maintaining these basic concepts within an otherwise normal anatomic environment (relative to food control and deglutition) has provided reasonable success for

patients requiring replacement of missing teeth. The challenges faced in doing so for removable maxillofacial prostheses are quite different.

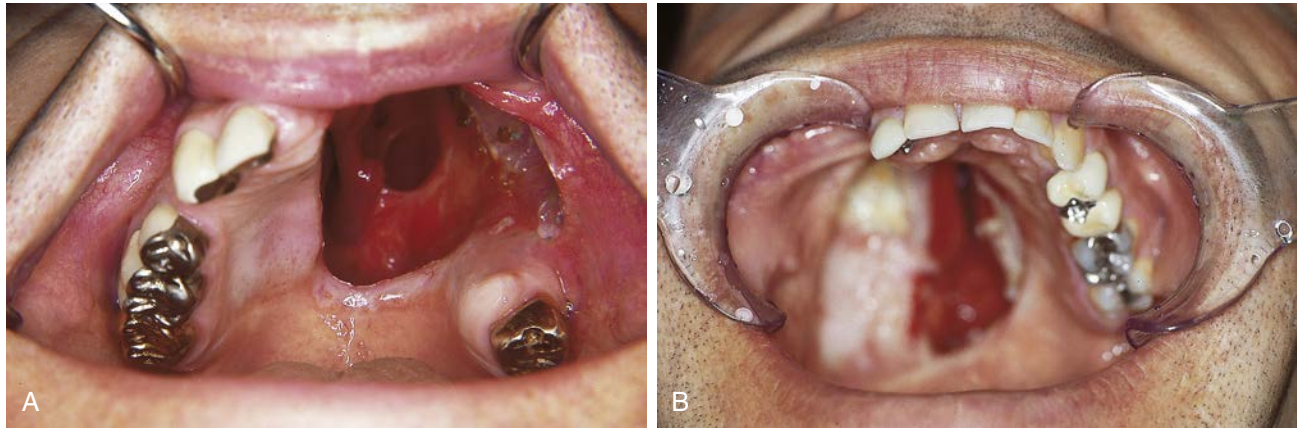
Normal resistance to functional loads is achieved by the highly sophisticated periodontal attachment of the natural dentition, which provides support and stability to teeth. When the dentition is partially depleted and is replaced by prostheses that are tooth-supported, the support and stability of the replacement teeth remain to be provided by the natural attachment. When tooth loss includes several posterior teeth, replacements are placed over the residual edentulous ridge, and the prosthesis receives support and stability from both teeth and mucosa. When all teeth are lost, support and stability are totally provided by the mucosa covering the residual edentulous ridges. Finally, when surgical removal of tumors results in tooth and supporting structure loss, support and stability are provided by combinations of remaining teeth and/or residual ridges and areas within the surgical defect. For partial and complete tissue-supported prostheses, the mechanism of functional load support—as provided by the mucosa—is unsuited to the task from a biological standpoint. Given this understanding, when a maxillofacial prosthesis is required to involve a surgical defect for support and stability, it is obvious that the environment within the surgical defect is even less suited to the task.

### SURGICAL PRESERVATION FOR PROSTHESIS BENEFIT

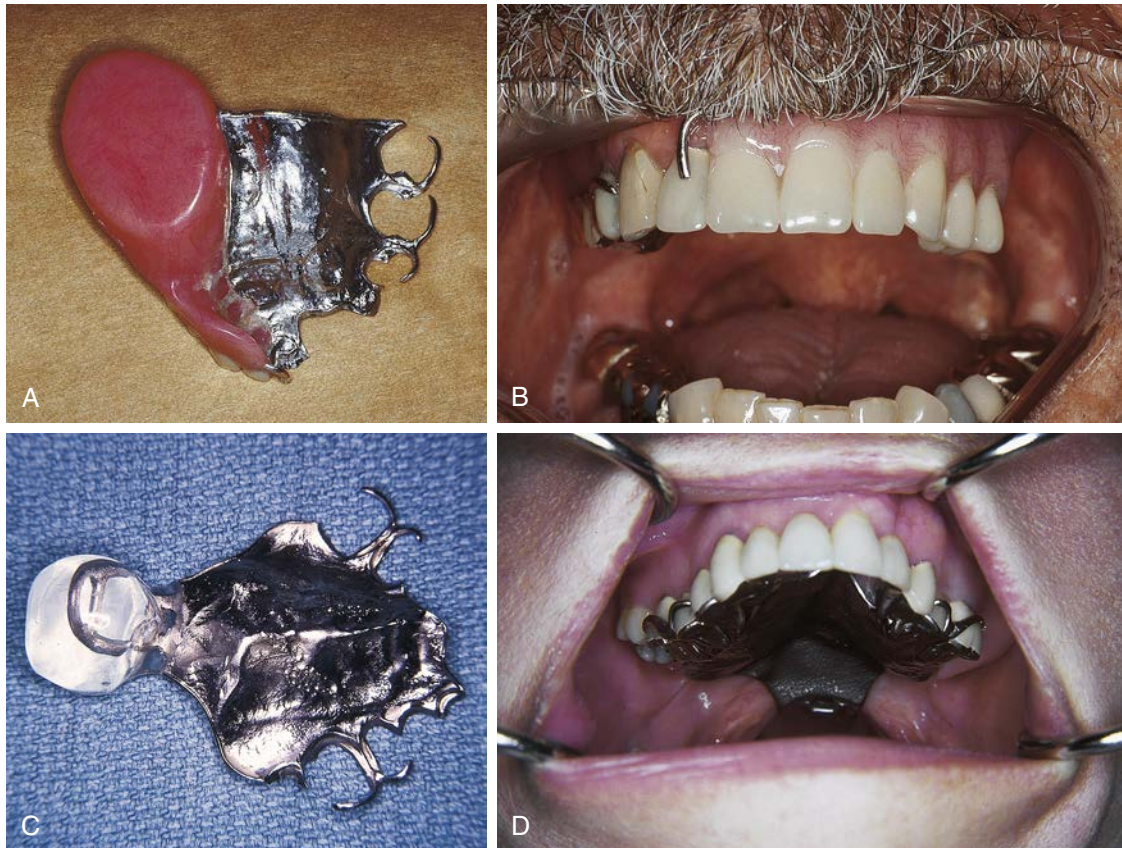#### Maxillary Defects

Surgical outcomes that influence prosthesis success can be considered as those that determine the number of maxillary structures removed ([Figure 25-10](#)) and/or those that affect the structural integrity and quality of the defect. For surgical defects of the hard and/or soft palate, the primary prosthetic objectives include restoration of physical separation of the oral and nasal cavities in a manner that restores mastication, deglutition, speech, and facial contour to as near a normal state as possible. Typical prostheses used to achieve these objectives include the obturator prosthesis ([Figure 25-11, A and B](#)), typically referring to prostheses that obturate defects within the bony palate, and the speech aid prosthesis (see [Figure 25-11, C and D](#)), which typically refers to prostheses that restore palatopharyngeal function for defects of the soft palate.

Current preoperative diagnostic procedures have improved the ability to discern the location and regional bone involvement of tumors of the maxilla and associated paranasal sinuses. Relative to prosthetically important surgical modifications, if it can be determined that tumor control does not require a classic radical maxillectomy approach or that the inferior sinus floor, hard palate, and alveolus are uninvolved, preservation of as much hard palate and alveolar bone and as many teeth as possible should be considered. Tooth preservation has the greatest impact on success because of its stabilizing effect on prosthetic movement. When teeth can be retained in the premaxilla for more



**FIGURE 25-10** **A**, A maxillary defect where a tooth distal to the resection was maintained. The tooth will significantly stabilize the prosthesis by preventing movement of the obturator bulb into the defect at the distal resection margin. **B**, A maxillary defect that demonstrates preservation of the anterior arch curvature, providing enhanced stability through a tripod effect. Also evident is the use of a split-thickness skin graft in the superior-lateral region, which improves the opportunity for useful support.



**FIGURE 25-11** **A**, Superior view of an obturator prosthesis demonstrating the cast framework, three posterior cast half-round clasps and an anterior I-bar clasp, and a superior obturator surface contoured to encourage secretions to flow posteriorly. **B**, The same prosthesis seated intraorally. **C**, A speech aid prosthesis with posterior retention and anterior indirect retention, and a resin speech bulb. **D**, The same prosthesis showing bilateral embrasure clasps and obturation of the palatopharyngeal defect.

posterior tumors or in the posterior molar region for more anterior tumors, control of prosthesis movement is more easily accomplished and prosthetic success can be considerably improved (see [Figure 25-10](#)). Because the classic mid-line maxillectomy defect is significantly more debilitating

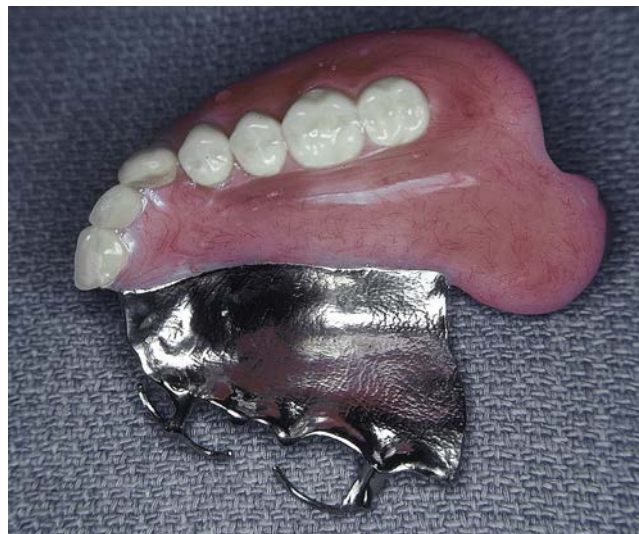for the average patient than a defect whereby preservation of the premaxillary component was accomplished, inclusion of the anterior premaxillary component should be an individual decision based on tumor control, classic resection technique.

For resections in patients with teeth, the tooth adjacent to the defect is subjected to significant force from prosthesis movement. When the surgical alveolar osteotomy cut is planned, the resection should be made through the extraction site of the adjacent tooth to provide the most favorable prognosis for this supportive tooth (see Figure 25-6). This procedure ensures adequate alveolar support for the adjacent tooth, which is a critical tooth for prosthesis success, and improves the tooth's prognosis for long-term survival. The midline of the hard palate is a common area of removable prosthesis pressure because of movement of the prosthesis into the defect under functional forces of swallowing and mastication. To provide the best surgical preparation for this area, when the hard palate is resected, the vertical surface of the bone cut should be covered with an advancement flap of palatal mucosa, to provide a firm and resistant mucosal covering to this region, where the prosthesis can notably act as a fulcrum.

The soft palate owes its normal function to the bilateral sling nature of the musculature, which provides the shape and movement capacity specific for speech and deglutition requirements. When this is altered because of surgery, there appears to be a variable response in the ability to continue to provide palatopharyngeal competence based on the amount of continuous band of posterior tissue remaining. Often, an insufficient band of palatal tissue fails to provide palatopharyngeal competence and hinders prosthetic management of the problem. To serve as a guide for decision making in surgery, it has been suggested that if the required resection leaves less than one third of the posterior aspect of the soft palate, the entire soft palate should be removed. The exception to this would be the edentulous patient who is undergoing a radical maxillectomy. Without teeth to provide the necessary retention for one side of a prosthesis, the patient benefits from the ability to place the prosthesis above the posterior soft tissue band for retention (Figure 25-12).

Preparation of the maxillary surgical site can improve prosthesis tolerance through the use of a split-thickness skin graft (see Figure 25-1). Lining the reflected cheek flap and posterior denuded structures with a graft improves tissue response by decreasing the pain associated with functional contact often seen when this surface is left to heal secondarily. If the posterior structures, pterygoid plates, or anterior temporal bone can provide a firm supportive base for the prosthesis, a skin graft covering is extremely helpful. Laterally, the junction of the skin and oral mucosa creates a scar contracture, which provides a natural retentive region for the obturator portion of the prosthesis. Careful attention is given to this region in fabricating a prosthesis, to maximize support, stability, and retention of the prosthesis.

In general, the need to extend a prosthesis into the defect is greater for edentulous patients than patients with teeth. When teeth remain, they are used to a greater extent to stabilize and retain the obturator component of the prosthesis, and the defect region is not required for such objectives. However, all patients with maxillary defects should have



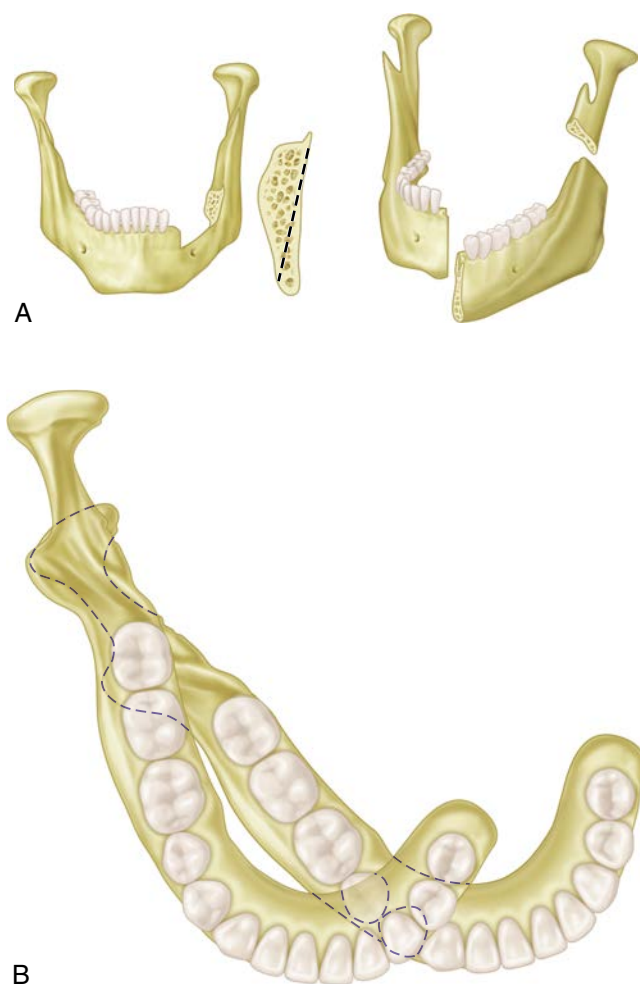
**FIGURE 25-12** A maxillary obturator prosthesis demonstrating a distal extension, which engages a soft palatal remnant for added retention.

sufficient access to the lateral-posterior region of the defect to seal the defect at a minimum. In the edentulous patient, for maximum ability to obturate a maxillary defect, access to the regions superior to the defect opening is required. Nasal turbinates and mucosal connections that do not allow full extension into the necessary retentive and supportive areas of the defect compromise function. The function of turbinates in the newly externalized environment is not beneficial for breathed air humidification or warming and consequently may not warrant preservation.

Surgical reconstruction of maxillary defects should be undertaken when restoration of the functional goals of speech, deglutition, and mastication is better served by such procedures. Surgical reconstruction of a maxillary hard palatal defect in a manner that provides separation of the oral and nasal cavities without consideration for oral space requirements for speech, or for the supportive requirements of replacement teeth, is not only incomplete management but can preclude subsequent prosthetic management. When surgical defects measure 3 cm or less and can be reconstructed to normal contours without compromising adjacent tissue function, surgical management is an appropriate consideration. Larger defects are very difficult to surgically reconstruct and, without careful planning for subsequent functional needs, could create an environment incapable of supporting a prosthesis. For partial soft palatal reconstructions, it is very difficult to provide functional tissue replacement without compromising palatal function. In light of this unpredictability, predictable prosthetic management of such defects is most often the treatment of choice.

### Mandibular Defects

The functions of mastication, deglutition, speech, and oral competence (saliva control) are made possible through



**FIGURE 25-13** A, Marginal (*left*) and segmental (*right*) resections of the mandible. When a segmental resection is not stabilized with a reconstruction bar or bone graft, the continuity of the mandible is lost. Such a defect is a discontinuity defect of the mandible. B, When not stabilized, the discontinuous mandible deviates toward the defect and presents significant problems with mastication restoration.

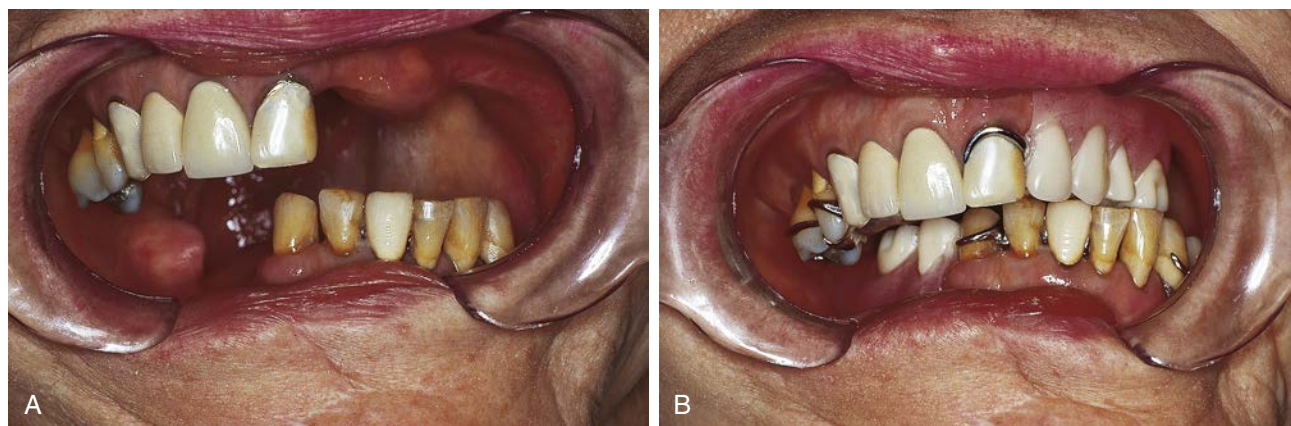
coordinated efforts of separate anatomic regions, which include the oral sphincter, alveololingual and buccal sulci, alveolar ridges, floor of the mouth, mobile tongue, base of the tongue, tonsillar pillars, soft palate, hard palate, and buccal mucosa. The more regions that are involved in a surgical procedure, the greater is the demand on surgical reconstructive efforts. When the mandible is also involved, the complexity of the reconstructive procedure is dependent on the location and amount of mandible to be included in the resection and the decision to maintain continuity with normal mandibular position and contour (Figure 25-13). For disease involving the functional anatomy around the mandible, surgical outcomes that influence prosthesis success are based on decisions to take mandibular portions or segments and decisions regarding reconstruction. The primary prosthetic objectives for mandibular defects are to restore mastication

and cosmesis by the replacement of teeth. Achieving the mastication goal requires an understanding that regardless of the manner of prosthesis support (natural teeth, reconstructed soft tissue, or implants), the impact of the prosthetic device on success is dependent on appropriate surgical management of both soft tissue and bone.

Disease involving soft tissue structures adjacent to and enveloping the mandible necessitates consideration of a mandibular resection to ensure control. When the soft tissue disease is clearly separate from the mandible and does not require bone removal, surgical defects involving these structures should be surgically reconstructed and therefore do not require prosthetic management. The exception to this is the large tongue resection that may require augmentation of the palatal contours to facilitate speech production. Such a palatal augmentation prosthesis is most beneficial when coordinated speech therapy can guide the optimal prosthesis configuration. Other resections may appear to require palatal augmentation for speech, yet the functional problem is tongue immobility secondary to tension created by the reconstructive tissue. Consideration should be given to soft tissue reconstructions that are of sufficient size and mobility, are less prone to contracture tension, and can produce a more normal alveololingual sulcus because these characteristics have been shown to have a significant influence on tongue mobility. Other desirable characteristics, such as sensation and lubrication, are also possible but necessitate a choice of which one is most required given the goals desired.

When tumors are primary to the mandible, as an ameloblastoma is, or when they involve the mandible from adjacent regions, surgical resection of segments of the mandible is required for tumor control. It may be difficult to always predict the functional deficit and the exact plan of reconstruction because the surgeon determines the extent of the resection based on presurgical and surgical findings. However, common anatomically based mandibular resections include the lateral mandibular resection, the anterior mandibular resection, and the hemimandibular resection. From the standpoint of the surviving mandibular resection patient, the most significant decision regarding his or her management is the decision to maintain mandibular continuity, which allows maintenance of position for adjacent intraoral and extraoral soft tissue.

Surgical evolution of procedures that maintain continuity for the mandible has significantly improved the opportunity for functional restoration of mastication, deglutition, and speech. The debilitating effects of the discontinuity defect include a significant cosmetic deformity to the lower third of the face, decreased masticatory function secondary to unilateral closure, compromised coordination of tongue and teeth, altered speech ability, and impaired deglutition (Figure 25-14). Given an appreciation of the decreased performance seen with conventional mucosa-borne denture prostheses, it should be obvious that masticatory rehabilitation for the resection patient without mandibular



**FIGURE 25-14** **A**, A deviated mandibular position following segmental resection without reconstruction. The mandibular midline is left of the maxillary midline by two teeth. **B**, With mandibular and maxillary prostheses in place, the patient closes to a functional position that is unique to the unilateral closure pattern.

continuity is unpredictable at best and is never achieved for most patients. Even for patients with remaining teeth, the altered mandibular position created in time presents a significant functional and cosmetic handicap. From a prosthetic rehabilitation standpoint, the most significantly handicapped postsurgical head and neck condition is the discontinuous mandible. Consequently, such a postsurgical condition should be the rare exception (typically because of reconstruction plate failure) and should not be the planned surgical outcome.

The cosmetic deformity associated with mandibular resection is improved through the use of reconstruction plates to maintain the presurgical contour to the lower jaw. This form of mandibular contour and position maintenance should be considered the minimum standard of care for mandibular resection patients from a functional standpoint. Use of reconstruction plates can maintain cosmetic appearance and preserve the bilateral nature of mandibular movement. However, the use of reconstruction plates alone precludes replacement of teeth in the region of resection. Prosthetic replacement of teeth cannot be provided for regions superior to the reconstruction bar because of the potential for mucosal perforation and exposure of the bar from functional loading of the soft tissue. From a masticatory function standpoint, this may not be a significant negative impact for some patients because of the maintenance of sufficient numbers of occlusal contacts postsurgically.

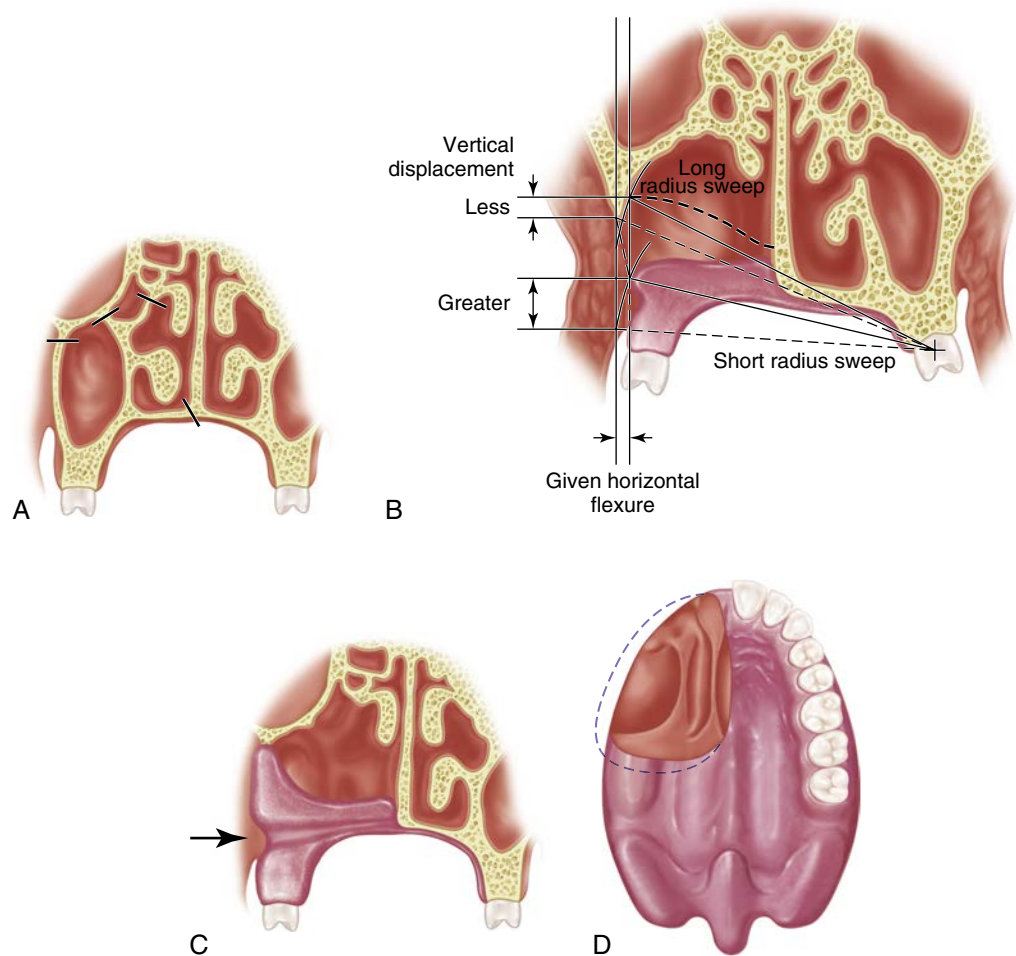
### Mandibular Reconstruction—Bone Grafts

The evolution of head and neck reconstructive surgery has been dramatic over the past three decades. The vascularized tissue options of the forehead and deltopectoral regions gave way to the more popular pedicled myocutaneous flaps from the 1960s to the 1970s. By the 1980s, numerous osteomyocutaneous free-flap donor sites had been identified and were being used for mandibular reconstruction and particulate cancellous bone marrow in formed allogeneic frames.

Equally important to the functional outcome of mastication was the development of the science and the clinical application of the osseointegration phenomenon in the area of dental implants.

The ideal prosthetic characteristics of the replacement mandible include a stable union to proximal and distal segments, restoration of contour to the lower third of the face, a rounded ridge contour with attached mucosa of 2 to 3 mm thickness, and adjacent sulci providing free movement of buccal and lingual soft tissues for food control. Regardless of the type of prosthesis to be used, the appropriate placement of the bone relative to the opposing arch is vital to the intended functional use. If a removable prosthesis is planned and is expected to cover the bone reconstruction, the contour of the developed ridge should provide a surface covered with firm, thin soft tissue, and a rounded superior contour with buccal and lingual slopes approaching parallel to each other and with sufficient vestibular depth to provide horizontal stability. Such a ridge condition is the surgical analog of a minimally resorbed edentulous ridge. With adequate cheek and tongue movement, this should provide a reasonable prognosis for prosthetic success, provided sufficient numbers of teeth remain on the nonresected side. For the optimum chance of prosthetic function, dental implants should be considered, and with sufficient bulk of bone and the same characteristics listed for the removable prosthesis, the prognosis for success is the greatest. To reiterate, the major determining factor for improved function will be the quality of the soft tissue reconstruction.

The major complications seen with mandibular reconstruction are related to the bulk of the soft tissue component and lack of mobility of the tongue. When these factors are controlled for, complications are caused most often by bone placement and size. The common use of free flaps, including bone from other regions of the body that do not possess the native mandibular shape, presents a significant degree of technical difficulty associated with the procedure. The fibula,



**FIGURE 25-15** **A**, Coronal view of proposed maxillary resection. *Bold lines* designate typical area to be resected. **B**, Demonstrates the value of lateral wall height in the design of a removable partial denture obturator. As the defect side of the prosthesis is displaced, the lateral wall of the obturator will engage the scar band and aid in retaining the prosthesis. **C**, Coronal section with surgical obturator in place. With the prosthesis in place, the relation of the scar band (*arrow*) to the lateral portion of the obturator can be seen. A buccal scar band will develop at the height of the previous vestibule where the buccal mucosa and the skin graft in the surgical defect join. **D**, Axial view of the resected area illustrates the defect. *Dotted lines* indicate areas available for intraoral retention.

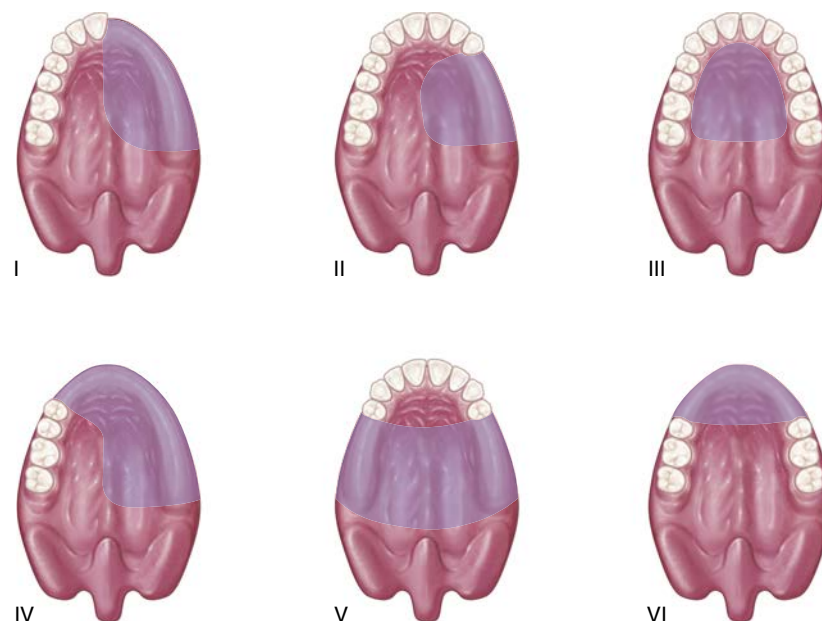
which is a popular choice for mandibular replacement, presents some challenges in meeting the ideal requirements mentioned previously. Because of the straight nature of the bone, it is easy to err in both horizontal and vertical positioning, especially for reconstructions that span to the midline. Lingual positioning requires prosthetic placement at a position that may become functionally unstable over time. Such a location requires implant positions that create a mechanical cantilever that can be detrimental to the long-term success of the implant-supported prosthesis. Posteriorly, the inability to recreate the natural ascending curve of the mandible can restrict placement of teeth and preclude restoration of complete occlusion on the resected side. It is common to have a mismatch in height at the anterior junction of the graft with the resident mandible. For implant-supported prostheses, this area can present significant challenges in terms of adequate hygiene of the implants, and over time, this can compromise implant health. For removable prostheses, this can

become a source of irritation if fulcrum-like action occurs with movement.

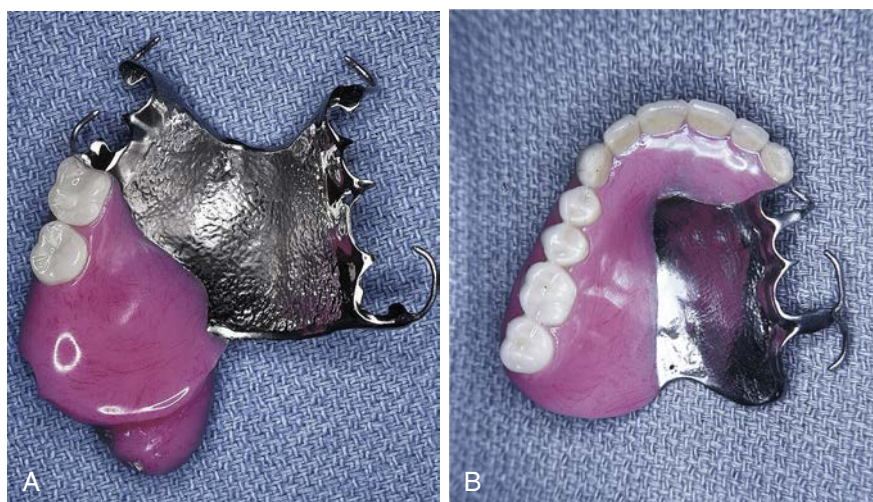## MAXILLARY PROSTHESES

### Obturator Prostheses

The defining characteristic of an obturator prosthesis is that it serves to restore separation of the oral and adjacent cavities following surgical resection of tumors of the nasal and paranasal regions (Figure 25-15). Aramany developed a classification for partially edentulous maxillectomy dental arches (Figure 25-16). The various defects resulting from resection contain and are bounded by anatomic structures and an epithelial lining (either transplanted skin and/or native mucosa) that are quite different from normal partially edentulous arch anatomic features. The expectation for this altered region to contribute significantly to prosthesis support, stability, or retention is infrequently met. Consequently, prosthesis



**FIGURE 25-16** Aramany's classification for partially edentulous maxillectomy dental arches: Class I—midline resection. Class II—unilateral resection. Class III—central resection. Class IV—bilateral anteroposterior resection. Class V—posterior resection. Class VI—anterior resection.



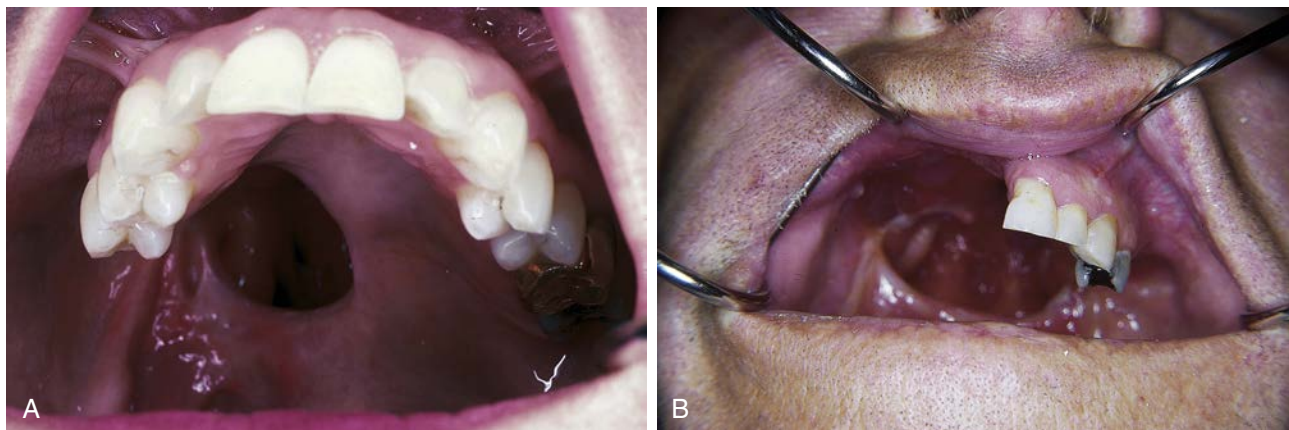
**FIGURE 25-17** **A**, A maxillary obturator prosthesis in which remaining teeth provide significant stabilization to the obturator extension because of their number and location, which allows cross-arch prosthesis engagement. **B**, Another obturator prosthesis, which benefits from teeth in a linear arrangement and therefore does not have any cross-arch tooth stabilization. Obturator movement in **B** is likely to be significantly greater than in **A**. The requirement for using the defect to provide support where possible is therefore greater in **B** than in **A**.

support and stabilization are largely dependent on the ability to aggressively engage the remaining teeth and residual ridge structures.

In comparison with partially edentulous arches, the movement potential for the prosthesis extension into the defect can be significant. When engagement of the distobuccal temporal bone is possible, upward movement of the obturator bulb can be greatly minimized. Movement potential increases as the remaining tooth number decreases and

their arrangement becomes more linear (Figure 25-17). This illustrates the importance of maintaining teeth when possible, which allows for greater prosthesis stabilization through direct tooth engagement and through cross-arch stabilization that increases with nonlinear tooth configurations (Figure 25-18).

To help control potential movement, various suggestions have been made relative to prosthesis design. The basic principle of placing support, stabilization, and retention



**FIGURE 25-18** **A**, Tooth arrangement that offers cross-arch stability (as in [Figure 25-17, A](#)) because of the arch curvature of the remaining tooth distribution and the tripod effect it allows. **B**, More linear arrangement of teeth does not provide cross-arch stability and places greater demand on the defect integrity for prosthesis performance.

immediately adjacent to and as far from the defect as possible acts to distribute the tooth effect on prosthesis performance to the greatest mechanical advantage. Because the teeth adjacent to the anterior resection margin are often incisors, it may be necessary to consider splinting them to improve the long-term prognosis. This region is critical for prosthesis performance, and the requirement for a cingulum rest and labial retention is often difficult to optimize without crowns. Distally, it is often necessary to incorporate an embrasure clasp to provide maximum retention and stabilization. Such a clasp assembly must have sufficient room for occlusal clearance, and it is not uncommon for the opposing occlusion to need adjustment to accommodate such a rest complex. When possible, the palatal surfaces of the maxillary teeth should be surveyed to determine whether guide-plane surfaces can be produced to impart a stabilizing effect. When accomplished, the prosthesis benefits from improved movement resistance, and it does so with more teeth contributing to the effect, thereby distributing the stress more appropriately. Brown described how the vertical height of the lateral portion of the obturator above the buccal scar band can contribute to prosthesis movement control by helping to prevent vertical displacement (see [Figure 25-15](#)).

### Speech Aid Prostheses

The defining characteristics of speech aid prostheses are that they are functionally shaped to the palatopharyngeal musculature to restore or compensate for areas of the soft palate that are deficient because of surgery or congenital anomaly (see [Figure 25-11](#)). Such a prosthesis consists of a palatal component, which contacts the teeth to provide stability and anchorage for retention; a palatal extension, which crosses the residual soft palate; and a pharyngeal component, which fills the palatopharyngeal port during muscular function, serving to restore the speech valve of the palatopharyngeal region.

Because the typical speech aid prosthesis does not provide tooth replacement, the patient should expect only minimum

functional movement. Movement of the pharyngeal extension imposed by the residual palatopharyngeal musculature is generally undesired and is a sign that modification is required. Common reasons for such movement include a low position, causing tongue encroachment; superior extension that does not account for head flexure; or impression procedures that do not accurately record residual soft palatal position or movement.

A pediatric speech aid is a temporary prosthesis used to improve voice quality during the growing years. It is made of materials that are easily modified as growth or orthodontic treatment progresses. Because a speech aid has a significant posterior extension into the pharyngeal region, torque is evident from the long moment arm. A basic principle of posterior retention with anterior indirect retention must be applied to the design of such a maxillary prosthesis. Posterior retention is gained by the use of wrought-wire clasps around the most distal maxillary molars, whereas the anterior extension of the prosthesis onto the hard palate provides indirect retention. If clinical crown length and undercut are adequate to provide retention, orthodontic bands with buccal tie wings can be used in conjunction with the wrought wires. This design facilitates the maintenance of the pharyngeal part of the pediatric speech aid in the proper position in the palatopharyngeal opening.

In the adult whose palatopharyngeal insufficiency is the result of a cleft palate or palatal surgery, an adult speech aid prosthesis can be constructed of more definitive materials because growth changes will not have to be accommodated. If teeth are missing, the prosthesis will incorporate a retentive partial denture framework. The basic design should include posterior retention and anterior indirect retention.

### Palatal Lift Prostheses

The defining characteristic of a palatal lift is that it positions a flaccid soft palate posteriorly and superiorly to narrow the palatopharyngeal opening for the purpose of improving

oral air pressure and therefore speech. Patients who exhibit a structurally normal soft palate and pharyngeal port can demonstrate hypernasal speech caused by paralysis of the regional musculature. This condition is referred to as *palatopharyngeal incompetence* because the failure lies in function, not in anatomic deficiency. The paralysis can result from a variety of neuromuscular conditions (flaccid paralysis of the soft palate from closed head injuries, cerebral palsy, muscular dystrophy, or myasthenia gravis) that have varying clinical courses. The palatal lift prosthesis must physically position the soft palate to redirect air pressure orally. In placing the soft palate, any tissue resistance met acts as a dislodging force on the prosthesis. This dislodging force must be resisted by adequate direct and indirect retention.

To efficiently maintain prosthesis position, the dislodging force is best resisted by bilateral direct retainers placed close to the posterior lift and anteriorly placed indirect retention. Success with a palatal lift prosthesis depends upon the presence of a number of maxillary posterior teeth, which can provide retention for the prosthesis, coupled with an easily placed flaccid soft palate.

### Palatal Augmentation Prostheses

When surgical resection involving the tongue and/or floor of the mouth limits tongue mobility, it affects both speech and deglutition. With tongue mobility limitations, the contour of the palate can be augmented by a prosthesis to modify the space of Donder to allow food manipulation to be more easily transferred posteriorly into the oropharynx.

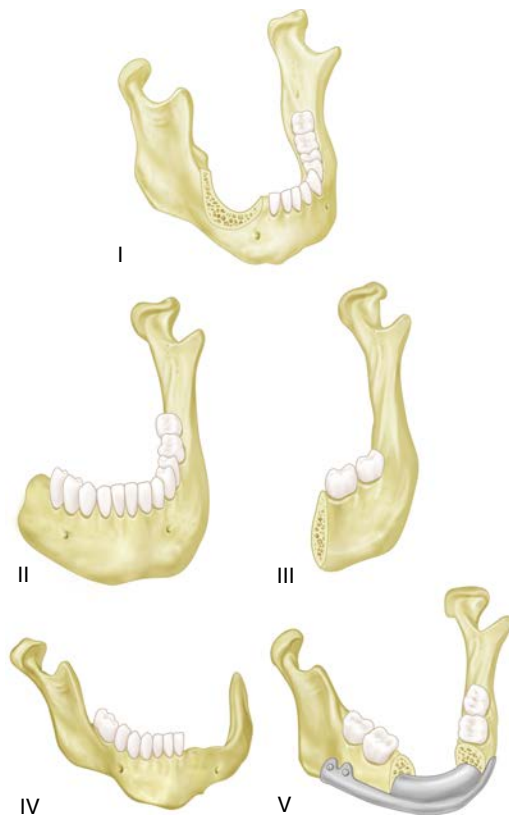
Prosthesis movement potential is low because the functional forces involved are those imparted by the tongue during deglutition and speech, neither of which creates force similar to mastication. It is common to use a diagnostic resin augmentation prosthesis retained with wire clasps to plan the necessary contour needs. Once the appropriate palatal contour has been determined, a definitive augmentation prosthesis can be constructed of cast metal with appropriately placed minor connectors for attaching the resin augmentation. Bilateral rests and direct retainers should be positioned to facilitate the design for the acrylic retention because stability needs related to functional force are not a significant design concern.

## MANDIBULAR PROSTHESES

### Evolution of Mandibular Surgical Resection

When mandibular continuity is preserved, as in a marginal resection (type I mandibular defect, see Figure 25-19), function is least affected and the major prosthesis concern is related to the soft tissue potential for support. With good remaining dental support, near-normal function can often be achieved with prosthodontic rehabilitation.

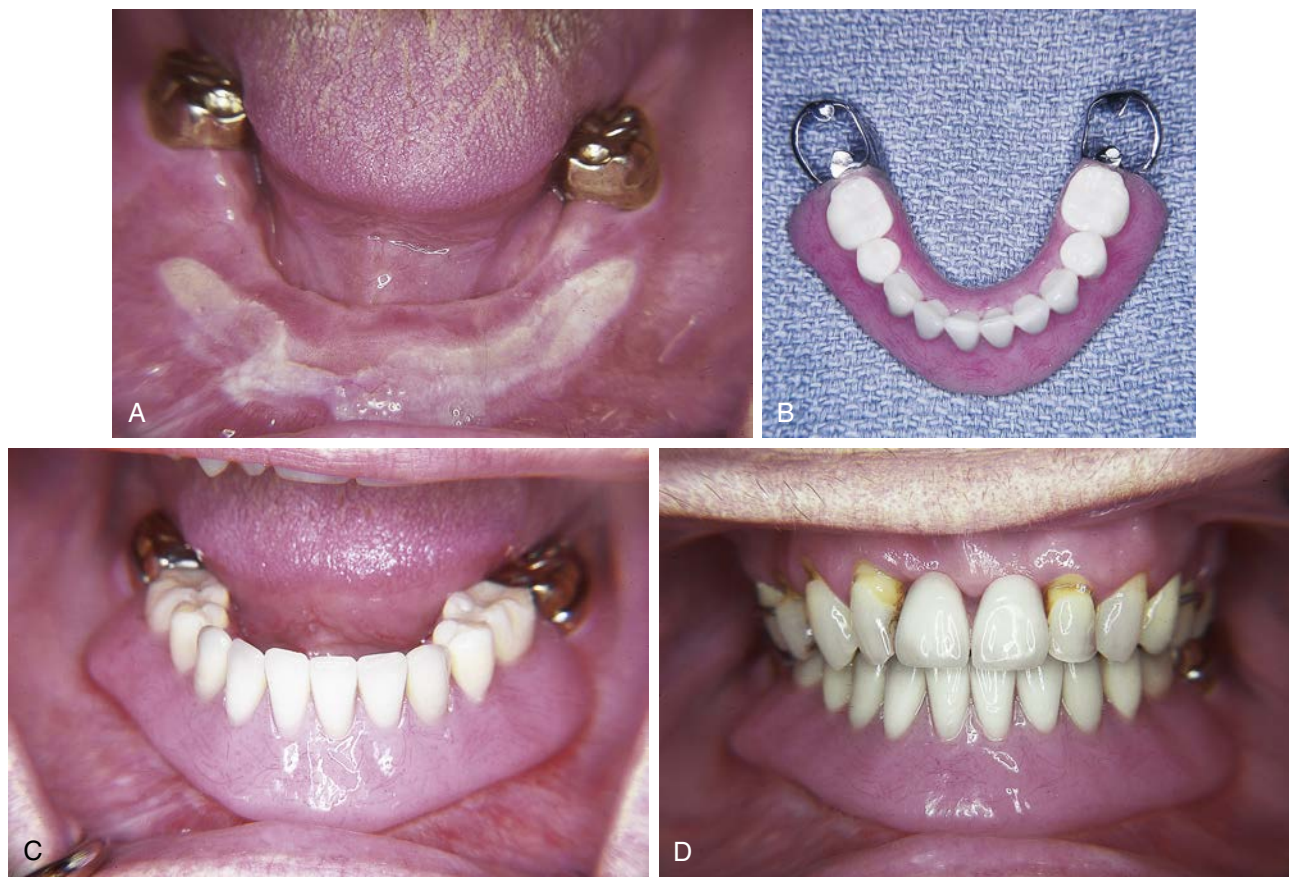
Although it is not as common an outcome as in the past, when continuity of the mandible is lost because of a segmental resection that was not reconstructed, the bilateral joint complex no longer controls the remaining mandibular



**FIGURE 25-19** Cantor and Curtis classification of partial mandibulectomy. (Redrawn from Cantor R, Curtis TA: Prosthetic management of edentulous mandibulectomy patients. I. Anatomic, physiologic, and psychologic considerations, *J Prosthet Dent* 25:446-457, 1971.)

segment. Consequently, the function of the remaining mandibular segment is severely compromised because of loss of coordinated bilateral muscular action functioning across a bilateral joint. The resulting segmental movement is an uncoordinated action dictated by the remaining unilateral muscular activity within a surgical environment that changes with healing dynamics and patient rehabilitation efforts. Successful removable prosthodontic intervention for these situations necessitates a combination of clinician knowledge of the functional movements of the remaining residual mandible and concerted effort and persistence of the patient.

Historically, mandibular stabilization by bone grafts or reconstruction bars was not always a surgical goal. The major exception was the anterior defect (type V), which was recognized to pose significant airway risks if not managed. Currently, most lateral segmental mandibulectomies are also reconstructed surgically. When the mandible is not stabilized following resection and a discontinuity defect results, a mandibular resection prosthesis should be provided to restore mastication within the unique movement capabilities of the residual functioning mandible.



**FIGURE 25-20** A type I resection of the anterior mandible. **A**, Bilateral molars remain to stabilize an anterior extension removable partial denture. A split-thickness skin graft has been used to reconstruct the denture bearing area. **B**, The prosthesis showing cast clasps and the anterior extension base. **C**, The prosthesis in place and covering the skin graft with a configuration produced through a corrective cast impression technique. **D**, The resection prosthesis in occlusion. It is critical to have the remaining natural teeth occlude at the same vertical dimension as the prosthetic teeth to ensure comfortable function.

Resection prostheses are those prostheses provided to patients who have acquired mandibular defects that result in loss of teeth and significant portions of the mandible. Mandibular resection results in defects that may preserve mandibular continuity or may result in discontinuity defects. These are further subclassified by Cantor and Curtis (Figure 25-19) and provide a meaningful foundation for a discussion of removable prosthesis design considerations.

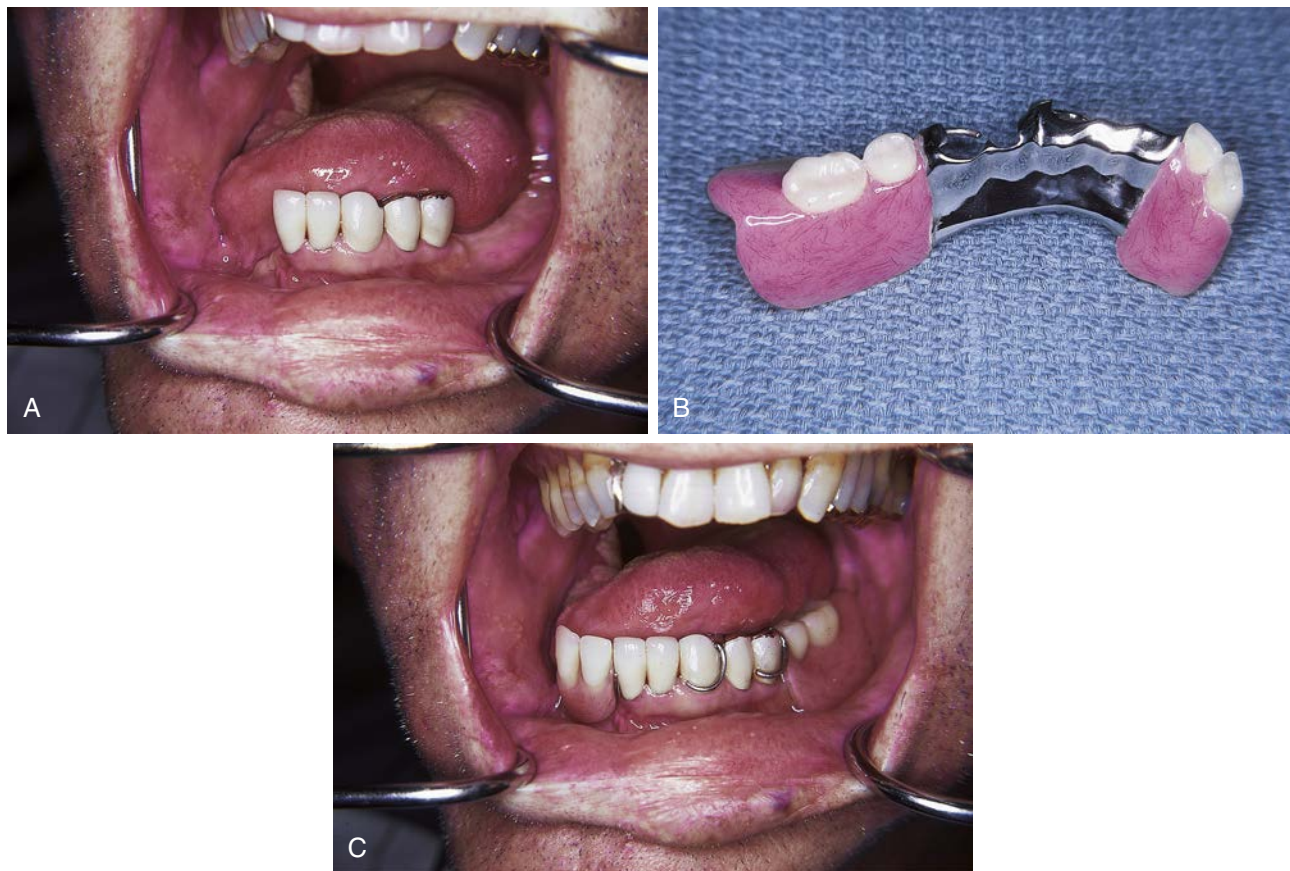
The following discussion highlights design considerations for the major defect classifications outlined. A common feature among all removable resection prostheses is that all framework designs should be dictated by basic prosthodontic principles of design. These include broad stress distribution, cross-arch stabilization with use of a rigid major connector, stabilizing and retaining components at locations within the arch to best minimize dislodging functional forces, and replacement tooth positions that optimize prosthesis stability and functional needs. Modifications to these principles are determined on an individual basis and are greatly influenced

by unique residual tissue characteristics and mandibular movement dynamics.

### Type I Resection

In a type I resection of the mandible, the inferior border is intact and normal movements can be expected to occur. The major difference between this situation and a typical edentulous span is the nature of the soft tissue foundation. For type I resections, the denture-bearing area may be compromised by closure of the defect with the use of adjacent lining mucosa (which can reduce the bucco-lingual width), or by the presence of a split-thickness skin graft.

Ideally, one would like to see a firm, non-movable tissue bed with normal buccal and lingual vestibular extension. If the defect is unilateral and posterior, the framework would be typical of a Kennedy Class II design, taking into account whatever modification spaces may be present. When the marginal resection is in the anterior area, the design may be more typical of a Kennedy Class IV design (Figure 25-20).



**FIGURE 25-21** Type II resection and prosthesis. **A**, Clinical presentation of the mandibular right resection and missing mandibular left molars. **B**, Resection prosthesis with a cast lingual plate major connector and wrought-wire clasps. **C**, Resection prosthesis in place demonstrating the two-tooth extension on the defect side (patient's right). (Courtesy of Dr. Ron Desjardins, Rochester, MN.)

Anterior marginal resections sometimes include part of the anterior tongue and floor of the mouth. With loss of normal tongue function, the remaining teeth are no longer retained in a neutral zone, and as a result, they often collapse lingually because of lip pressure. If this occurs, the use of a labial bar major connector may be necessary.

Corrected cast impression procedures provide a major advantage for fabrication of removable partial dentures in partial mandibulectomy patients. Capture of the unique buccal, lingual, and labial functional contours in the final prosthesis can contribute significantly to stabilization of the prosthesis, especially in discontinuity defects.

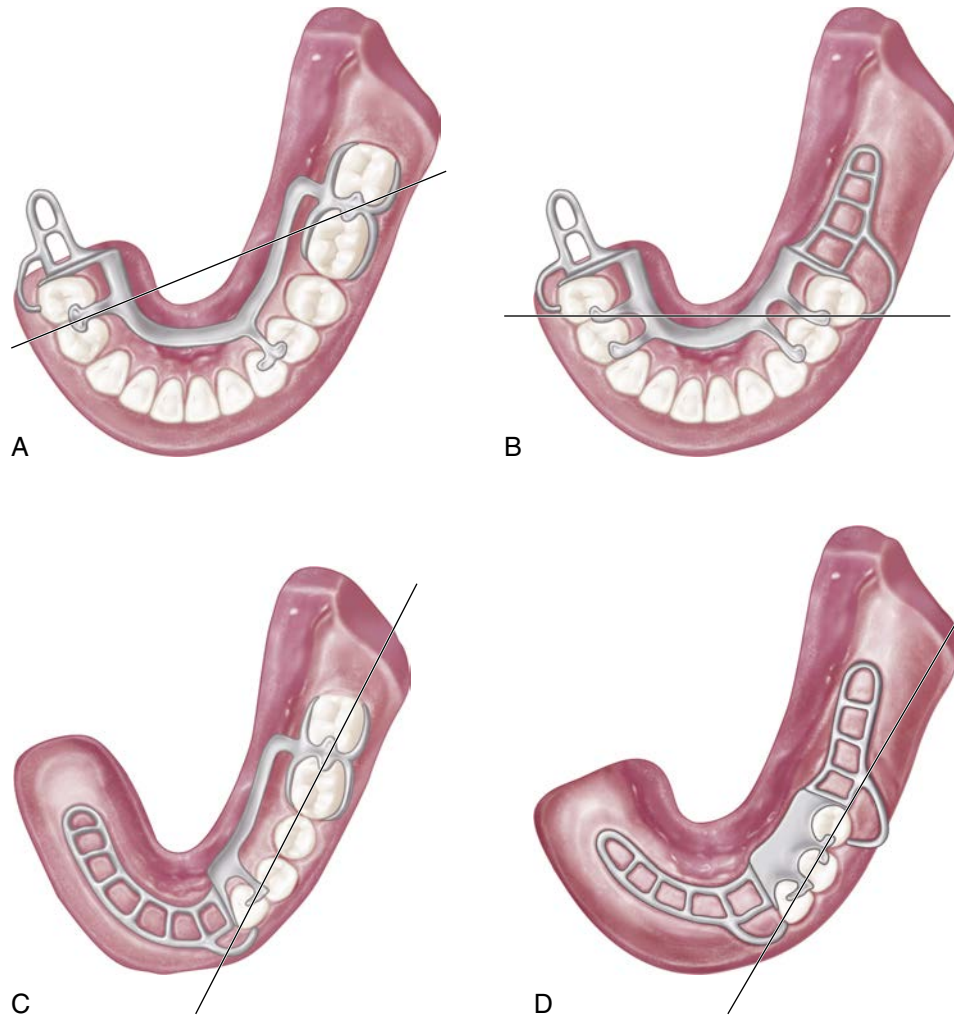
### Type II Resection

In the type II resection, the mandible is often resected in the region of the second premolar and first molar. If no other teeth in the arch are missing, a prosthesis usually is not indicated. In some situations, however, a prosthesis may have to be fabricated to support the buccal tissue and to help fill the space between the tongue and the

cheek to prevent food and saliva from collecting in the region.

Framework design should be similar to a Kennedy Class II design, with extension into the vestibular areas of the resection. This area would be considered nonfunctional and should not be required to support mastication. It must be remembered that extension into the defect area can place significant stress on the remaining abutment teeth; therefore, occlusal rests should be placed near the defect, and an attempt should be made to gain tripod support from remaining teeth and tissue where possible.

An example of a framework design for a type II mandibular resection with missing molars on the nonsurgical side is illustrated in Figure 25-21. The choice of major connector depends on the height of the floor of the mouth as it relates to the position of the attached gingival margins during function. An extension base with artificial teeth can be used on the surgical side if space is available. The extent of this base is determined by a functional impression, and determination should be cautious of the potential for bone exposure at the superior margin of the resection.



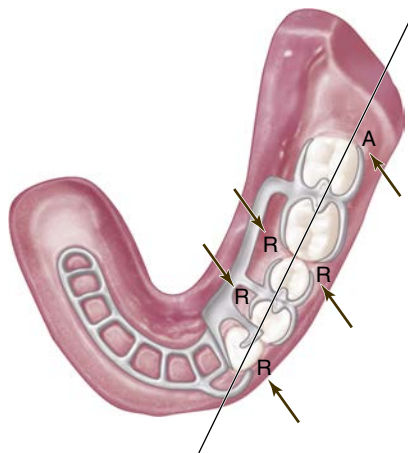
**FIGURE 25-22** A, Frame design for type II resection, no teeth missing on the nonresected side. Note the provision for extension into the resection space between tongue and cheek. B, Type II design with missing posterior teeth on the nonresected side. C, Type II design with missing anterior teeth. D, Type II design with missing anterior and posterior teeth.

Retention can be achieved through the use of various types of clasp assemblies on the distal abutments. Indirect retention can be derived from rests prepared in the mesial fossae of the first premolars and/or the lingual surfaces of the canines. Unlike the result in [Figure 25-21](#), use of an infrabulge retainer on the surgical side may be difficult if a shallow vestibule results from surgical closure. The locations of minor connectors should be physiologically determined to minimize stress on the abutment teeth and to enhance resistance to reasonable dislodging forces. Wrought-wire circumferential retainers are acceptable alternatives.

In a type II mandibular resection, where posterior and anterior teeth are missing on the defect side, the remaining teeth on the intact side of the arch are often present in a straight-line configuration. Embrasure clasps may be used on the posterior teeth, with an infrabulge retainer on the anterior abutment. In some situations, a rotational

path design may be used to engage the natural undercuts on the mesial proximal surfaces of the anterior abutments. Lingual retention with buccal reciprocation on the remaining posterior teeth should be considered. The longitudinal axis of rotation in this design should be considered to be a straight line through the remaining teeth. Depression of the prosthesis on the edentulous side will have less of a chance to dislodge the prosthesis if retention is on the lingual surfaces than if on the buccal. Suggested framework designs for this patient group are illustrated in [Figure 25-22](#).

Physiologic relief of minor connectors is always recommended. When the remaining teeth are in a straight line, a Swing-Lock major connector design (Swing-Lock, Inc., Milford, TX) may be used to take advantage of as many buccal and/or labial undercuts as possible. Because elderly patients often complain of difficulty manipulating Swing-Lock mechanisms, in straight-line situations it



**FIGURE 25-23** Conventional clasping with the use of alternating buccal and lingual retention (arrows).

may be possible to use alternate buccal and lingual retention effectively (Figure 25-23).

In the type II resection with anterior and posterior missing teeth on the resected side and posterior missing teeth on the nonresected side, the prosthesis will have three denture base regions. This prosthesis may have a straight-line longitudinal axis of rotation, as previously discussed. Rests should be placed on as many teeth as possible, minor connectors should be placed to enhance stability, and wrought-wire retainers represent an acceptable alternative to the bar clasps.

### Type III Resection

A type III resection (see Figure 25-19) produces a defect to the midline or farther toward the intact side, leaving half or less of the mandible remaining.

The importance of retaining as many teeth as possible in this situation cannot be overemphasized. The design of a framework for this situation would be similar to the type II resection. The longitudinal axis of rotation is again considered to be a straight line through the remaining teeth. This resection provides a greater chance of prosthesis dislodgment caused by lack of support under the anterior extension.

Alternating buccal and lingual retention in a rigid design or the Swing-Lock design should be considered.

### Type IV Resection

A type IV resection (see Figure 25-19) would use the same design concepts as type II or III resections with the corresponding edentulous areas.

If the graft does not provide an articulation and the soft tissue covering the graft is not firmly attached to the bone graft, the movement potential will be dictated by functional forces of movement coupled with soft tissue supportive capacities.

If a type IV resection extends to the midline with the extension of a graft into the defect area, but does not include temporomandibular joint reconstruction on the surgical side, the design will be similar to the type III resection with an extension base on the surgical side.

If the type IV resection extends beyond the midline, with less than half of the mandible remaining, the design will be similar to the type II resection that has an extension base into the surgical defect area.

### Type V Resection

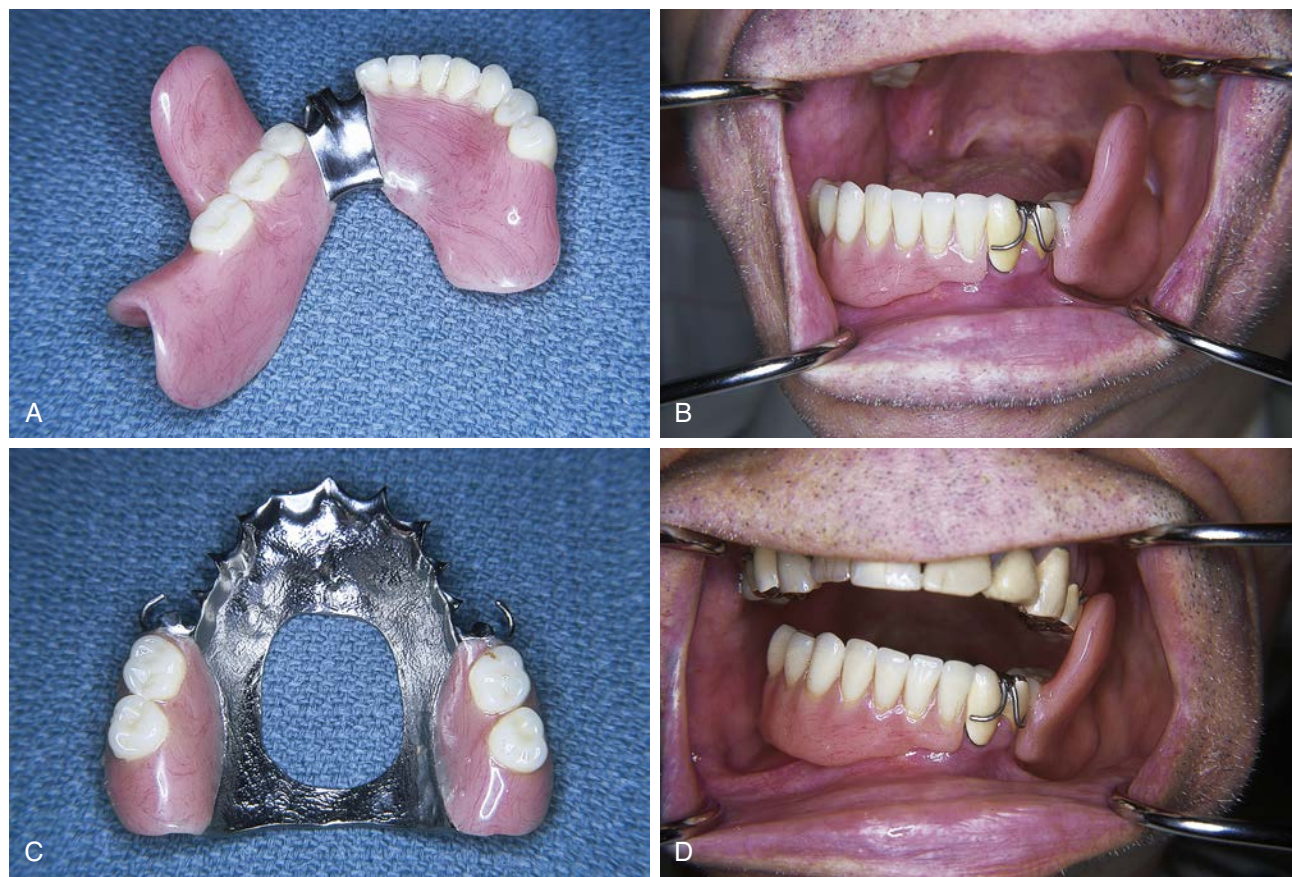
In the type V resected mandible, when the anterior or posterior denture-bearing area of the mandible has been surgically reconstructed, the removable partial denture design is similar to the type I resection design.

The principal difference between a type V resected mandible and the intact mandible with the same tooth loss pattern lies in the management of soft tissue at the graft site. For design purposes, one should consider the residual mandibles of the type I and V resections to be similar to nonsurgical mandibles with the same tooth-loss pattern.

### Mandibular Guide Flange Prosthesis

As was mentioned earlier, in a discontinuity defect, the movement of the residual mandibular segment is an uncoordinated action dictated by two features unique to the specific defect and patient. The first is the remaining unilateral muscular activity that will be specific to the surgical resection and that will have a characteristic resting posture to the defect side with a diagonal movement on “closure.” The second is that the surgical environment will change as healing progresses, and patient efforts to train movement during this healing period will help maintain both position and movement range. To facilitate training of the mandibular segment to maintain a more midline closure pattern, clinicians have used a guide flange prosthesis.

The mandibular guide flange prosthesis is used primarily as an interim training device. When no missing teeth are supplied, it may be considered a training appliance rather than a prosthesis. This appliance is used in dentulous patients with non-reconstructed lateral discontinuity defects who have severe deviation of the mandible toward the surgical side and are unable to achieve unassisted intercuspation on the nonsurgical side (Figure 25-24). Generally these patients have had a significant amount of soft tissue removed along with the resected mandibular segment and have attained surgical closure by suturing of the lateral surface of the tongue to the buccal mucosa, which causes a deviation toward the defect side. Scarring also occurs and is worse for patients who have not been placed on an exercise program during the healing period. The guide flange prosthesis is designed to restrict the patient to vertical opening and



**FIGURE 25-24** A mandibular guide flange prosthesis. **A**, Flange extension is incorporated into a mandibular type II resection prosthesis using a resin extension. **B**, Resection prosthesis inserted. **C**, Opposing maxillary prosthesis designed to engage palatal surfaces of all remaining teeth for maximal stability against flange-induced forces. **D**, Flange extending to the buccal region of the opposing prosthesis and teeth. Upon closure, the flange will guide the mandible to maximum intercuspation, at which time the flange extension will reside in the maxillary left buccal vestibule. (Courtesy of Dr. Ron Desjardins, Rochester, MN.)

closing movements into maximum occlusal contacts. Over time, this guided function should promote scar relaxation, allowing the patient to make unassisted masticatory contact.

The components of the guide flange prosthesis include the major and minor connectors needed to support, stabilize, and retain the prosthesis and the guiding mechanism. This may include a cast buccal guide bar and guide flange, or simply a resin flange, which engages the opposing arch buccal tooth surfaces. In either case, the opposing arch must provide a stable foundation to resist any forces needed to guide the deviated mandibular segment into maximum occlusal contact.

The buccal guide bar is placed as close as possible to the buccal occlusal line angle of the remaining natural teeth to allow maximum opening. The lateral position of the bar must be adequate to prevent the guide from contacting the buccal mucosa of the maxillary alveolus. The length of the bar should overlie the premolars and the first molar where possible. Retention of the maxillary frame should not be problematic because the force directed on the bar is in a palatal direction. The guide flange is attached to

the mandibular major connector by two generous interproximal minor connectors. As with the maxillary frame, significant interproximal tooth structure must be cleared to provide the necessary bulk for the minor connectors. The height of the guide flange is determined by the depth of the buccal vestibule. A small hook is placed at the middle of the top of the guide to prevent disengagement on wide opening. Because the mandibular segment has a constant medial force, the flange acts as a powerful lever with a strong lateral force on the teeth. Therefore, extra rests and additional stabilization and retention on multiple teeth must be considered to prevent oversteering of individual teeth. Retention on the tooth adjacent to the defect is critical for resistance to lifting of the frame. Lingual retention in the premolar area may be considered as an aid in resistance to displacement. When necessary, missing teeth can be added to a guide flange prosthesis. Flange prostheses can be provisionally designed for modification into definitive removable partial dentures after guidance is no longer necessary. This is accomplished by removal of the buccal flange and buccal guide bar components after the patient is able to make occlusal contacts

without use of the guide. However, many patients with mandibular resections have difficulty making repeated occlusal contacts—a fact described in several studies. Occlusal considerations in mandibulectomy patients have been discussed extensively by Desjardins.

Palatal occlusal ramps have been used to guide those patients with less severe deviation than those who require a guide flange into a more stable intercusp contact position. These prostheses incorporate a palatal ramp that simulates the function of the guide flange prosthesis. This inclination of the palatal ramp is determined by the severity of the deviation of the remaining mandible. Some patients have the ability to move laterally into occlusion but have a tendency to close medially and palatally rather than close into an acceptable cuspal relationship. These patients can benefit from a palatal ramp, which can be functionally generated in wax at the try-in stage. This provides a platform for occlusal contact in the entire bucco-lingual range of movement. A supplemental row of prosthetic teeth may be arranged, then removed at the boil out stage, and processed in pink acrylic resin for esthetics. Patients who have experienced both smooth and tooth-form ramps usually prefer the tooth form if the width is adequate.

### JAW RELATION RECORDS FOR MANDIBULAR RESECTION PATIENTS

Interocclusal records must be made using verbal guidance only for resection patients with discontinuity defects. A hands-on approach, like that used for conventional edentulous jaw relation records, will lead to unnatural rotation of the mandible and an inaccurate record. The patient should be instructed to move the mandible toward the nonsurgical side and close into a nonresistant recording

medium at the preestablished occlusal vertical dimension, which will be the occlusal contact position. If the surgical side is significantly deficient, an occlusion rim may have to be extended into the defect area to support the recording medium. Head position is of extreme importance during registration of jaw relation records. If the patient is in a semirecumbent position in the dental chair during the recording procedure, the mandible may be retracted and deviated toward the surgical side, preventing movement toward the intact side. To minimize this problem, the recording should be made with the patient seated in a normal upright postural position.

Most patients with lateral discontinuity defects can make lateral movements toward the nonsurgical side, even without the presence of a lateral pterygoid muscle functioning on the balancing (surgical) side. This is possible because of the compensatory effects of the horizontal fibers of the temporalis and the lateral pterygoid muscle on the normal side, causing a rotational effect on the remaining condyle.

### SUMMARY

Maxillofacial prosthetic treatment of the patient with an oral defect is among the most challenging treatments in dentistry. Defects are highly individual and require the clinician to call upon all knowledge and experience to fabricate a functional prosthesis. The basic principles and concepts described throughout this text will help the clinician to successfully design maxillofacial removable partial dentures. The interested reader is encouraged to pursue maxillofacial texts for more information regarding prosthesis design for this patient group.

## APPENDIX

## A

## Glossary

**abutment** A tooth, a portion of a tooth, or a portion of an implant that serves to support and/or retain a prosthesis.

**acrylic** Formed from acrylic acid (e.g., acrylic resin).

**acrylic resin 1:** Pertaining to polymers of acrylic acid, methacrylic acid, or acrylonitrile; for example, acrylic fibers or acrylic resins. **2:** Any of a group of thermoplastic resins made by polymerizing.

**anatomic ridge form** Surface form of the edentulous ridge when at rest or when not supporting a functional load; often recorded in a soft impression material, such as hydrocolloid or metallic oxide impression paste, and results when an impression tray is uniformly relieved.

**angle of cervical convergence** Angle viewed between a vertical rod contacting an abutment tooth and the axial surface of the abutment cervical to the height of contour.

**appliances** Devices (such as splints, orthodontic appliances, and space maintainers) worn by the patient in the course of treatment.

**balanced occlusion** The simultaneous contacting of maxillary and mandibular teeth on the right and left in the anterior and posterior occlusal areas in centric or any eccentric position within the functional range.

**bar clasp** Type of extracoronal retainer that originates from the denture base or framework, traverses soft tissue, and approaches the tooth undercut area from a gingival direction.

**basal seat** Oral tissues and structures of the residual ridge supporting a denture base. *See also* denture foundation area.

**cast** An accurate and positive reproduction of a maxillary or mandibular dental arch made from an impression of that arch; further designated according to the purpose for which it is made, such as *diagnostic cast*, *master cast*, or

*investment cast*; also may be used as an infinitive (to cast) or as an adjective (cast framework, or cast metal base).

**casting** A metal object shaped by being poured into a mold to harden; used primarily to designate the cast metal framework of a partial denture but also may be used to describe a molded metal denture base that is actually cast into a mold.

**centric jaw relation** *See* centric relation.

**centric occlusion** The occlusion of opposing teeth when the mandible is in centric relation. This may or may not coincide with the maximal intercuspal position.

**centric relation 1:** The maxillomandibular relationship in which the condyles articulate with the thinnest avascular portion of their respective disks with the complex in the anterior-superior position against the shapes of the articular eminences. This position is independent of tooth contact. This position is clinically discernible when the mandible is directed superior and anteriorly. It is restricted to a purely rotary movement about the transverse horizontal axis (GPT-5). **2:** The most retruded physiologic relation of the mandible to the maxillae to and from which the individual can make lateral movements. It is a condition that can exist at various degrees of jaw separation. It occurs around the terminal hinge axis (GPT-3). **3:** The most retruded relation of the mandible to the maxillae when the condyles are in the most posterior unstrained position in the glenoid fossae from which lateral movement can be made at any given degree of jaw separation (GPT-1). **4:** The most posterior relation of the lower to the upper jaw from which lateral movements can be made at a given vertical dimension (Boucher, 1953). **5:** A maxilla-to-mandible relationship in which the condyles and disks are thought to be in the midmost, uppermost position. The position has been difficult to define anatomically but is determined clinically by assessing when the jaw can hinge on a fixed terminal axis (up to 25 mm). It is a clinically determined relationship of the mandible to the maxilla when the condyle disk assemblies are positioned in their most superior position

---

Certain terms in this glossary have been adapted from *The Glossary of Prosthodontic Terms*. Additional terminology can be reviewed in: The glossary of prosthodontic terms, ed. 8. From *The Journal of Prosthetic Dentistry* 94(1):10-92, 2005. Available online: <http://www.sciencedirect.com/science/article/pii/S0022391305001757>.

in the mandibular fossae and against the distal slope of the articular eminence (Ash, 1993). **6:** The relation of the mandible to the maxillae when the condyles are in the uppermost and rearmost position in the glenoid fossae. This position may not be able to be recorded in the presence of dysfunction of the masticatory system. **7:** A clinically determined position of the mandible placing both condyles into their anterior uppermost position. This can be determined in patients without pain or derangement in the temporomandibular joint (TMJ) (Ramsfjord, 1993).

**circumferential clasp** Term used to designate a clasp arm that originates above the height of contour and approaches the tooth undercut from an occlusal direction.

**clasp (or direct retainer)** Component of the clasp assembly that engages a portion of the tooth surface and either enters an undercut for retention or remains entirely above the height of contour to act as a reciprocating element; generally used to stabilize or retain a removable prosthesis.

**clasp assembly** Part of a removable partial denture that acts as a direct retainer and/or stabilizer for a prosthesis by partially encompassing or contacting an abutment.

**complete denture** Dental prosthesis that replaces all of the natural dentition and associated structures of the maxilla or mandible. It is entirely supported by tissues (mucous membrane, connective tissues, and underlying bone).

**dental cast surveyor** Instrument used to determine the relative parallelism of two or more axial surfaces of teeth or other parts of a cast of a dental arch; also used to locate and delineate the contours and relative positions of abutment teeth and associated structures.

**dental stones** Used to form an artificial stone reproduction from an impression, and used as an investment or for mounting purposes; all dental stones are gypsum products.

**denture base** Part of a denture (whether it is metal or is made of a resinous material) that rests on the residual bone covered by soft tissue and to which the teeth are attached.

**denture foundation area** See [basal seat](#).

**direct retainer** Component of a removable partial denture used to retain or prevent dislodgment; consists of a clasp assembly or precision attachment.

**edentulous ridge** See [residual ridge](#).

**functional impression** Impression and resulting cast of the supporting form of the edentulous ridge; artificially created by means of a specially molded (individualized) impression tray or an impression material, or both, that displaces those tissues that can be readily displaced and that would be incapable of rendering support to the denture base when it is supporting functional load.

**functional occlusal registration** Used to designate a dynamic registration of opposing dentition rather than the recording of a static relationship of one jaw to another.

**functional ridge form** See [functional impression](#).

**guiding planes** Two or more vertically parallel surfaces of abutment teeth shaped to direct a prosthesis during placement and removal; surfaces are parallel to the path of the placement and parallel to each other; preferably these surfaces are made parallel to the long axes of abutment teeth.

**height of contour** Line encircling a tooth, designating its greatest circumference at a selected position determined by a dental surveyor.

**incisal rest** A rest placed on the incisal edge of an anterior abutment tooth.

**indirect retainer** Part of a removable partial denture that assists direct retainers in preventing displacement of distal extension denture bases by resisting lever action from the opposite side of the fulcrum line.

**interim denture** Dental prosthesis used for a short time for reasons of esthetics, mastication, occlusal support, or convenience, or for conditioning the patient to accept an artificial substitute for missing natural teeth until a more definite prosthetic dental treatment can be provided.

**internal attachment** See [precision attachment](#).

**investment cast** Cast compounded to withstand high temperatures without disintegrating and, incidentally, to perform certain functions relative to burnout and expansion of the mold.

**lingual bar connector** Component of the partial denture framework located lingual to the dental arch and above the moving tissues of the floor of the mouth but as far below the gingival tissues as possible.

**lingual rest** A rest that occupies a position on the lingual surface of an anterior tooth.

**linguoplate** Designation given when the lingual bar major connector is attached to a thin, contoured apron adjacent to the lingual surfaces of the anterior teeth in the mandible.

**major connector** Part of a removable partial denture that connects the components on one side of the arch to the components on the opposite side of the arch.

**mold** Word used to indicate either the cavity into which a casting is made or the shape of an artificial tooth; use of the term is incorrect when referring to a reproduction of a dental arch or a portion thereof.

**occlusal rest** A rest placed on the occlusal surface of a posterior tooth.

**palatal bar** Thin, broad palatal coverage with a width of less than 8 mm used as a major connector.

**palatal major connector** Any thin, broad palatal coverage that is used as a major connector.

**palatal strap** Proportionally thinner and broader than a palatal bar, although differentiation is somewhat objective.

**plastic** Refers to any of various substances that harden and retain their shape after being molded.

**precision attachment** Refers to an interlocking device, one component of which is fixed to an abutment or abutments,

Boucher CO: Occlusion in prosthodontics, *J Prosthet Dent* 3:633-656, 1953; Ash MM: Personal communication, July 1993; Lang BR, Kelsey CC: International prosthodontic workshop on complete denture occlusion, Ann Arbor, 1973, The University of Michigan School of Dentistry; Ramsfjord SP: Personal communication, July 1993.

while the other is integrated into a removable prosthesis to stabilize and/or retain it.

**prosthesis** A denture, an obturator, a fixed partial denture, or a crown.

**provisional denture** See [interim denture](#).

**rebasing** Process that goes beyond relining and involves refitting a denture by replacing the entire denture base with new material without changing the occlusal relations of the teeth.

**refractory cast** See [investment cast](#).

**refractory investment** Investment material that can withstand the high temperatures of casting or soldering; plaster of Paris and artificial stone may be considered investment if either is used to invest any part of a dental restoration for processing.

**relining** Resurfacing of a denture base with new material to make it fit the underlying tissue.

**removable partial denture (RPD)** Prosthesis that replaces some teeth in a partially dentate arch and can be removed from the mouth and replaced at will.

**residual ridge** Residual bone with its soft tissue that covers the underlying area of the denture base; the exact character of the soft tissue covering may vary, but it includes the mucous membrane and underlying fibrous connective tissue.

**resin** Used broadly for substances named according to their chemical composition, physical structure, and means for activation or curing, such as acrylic resin.

**rest** Any component of the partial denture that is placed on an abutment tooth, ideally in a prepared rest seat, so that

it limits movement of the denture in a gingival direction and transmits functional forces to the tooth.

**retainer** Any type of clasp, attachment, device, and so on used for fixation, stabilization, or retention of a prosthesis; may be intracoronal or extracoronal and can be used as a means of retaining a removable or a fixed restoration.

**retention** Quality inherent in the denture that resists the vertical forces of dislodgment (e.g., the force of gravity, the adhesiveness of foods, the forces associated with opening of the jaws).

**semiprecision rest** Rigid metallic extension of a fixed or removable partial denture that fits into an intracoronal preparation in a cast restoration.

**stability** Quality of a prosthesis of being firm, stable, or constant and resisting displacement by functional, horizontal, or rotational stresses.

**static form** See [anatomic ridge form](#).

**stone** Use of the word in dentistry should be limited to those gypsum materials that are employed for their hardness, accuracy, or abrasion resistance.

**support** Foundation on which a dental prosthesis rests, or to hold up and serve as a foundation.

**undercut** When used in reference to an abutment tooth, that portion of a tooth that lies between the height of contour and the gingiva; when used in reference to other oral structures, the contour or cross section of a residual ridge or dental arch that would prevent placement of a denture.

**wax pattern** Converted to a casting via elimination of the pattern by heat, leaving a mold into which the molten metal is forced by centrifugal force or other means.

## APPENDIX

## B

## Selected Reading Resources

A textbook is rarely found to be all-inclusive in subject matter related to a dental clinical discipline or subdiscipline. Therefore this section, which lists other textbooks and articles from dental periodical literature, may assist in broadening a student's perspective on principles and concepts of removable partial prosthodontics.

Some of the articles have historic significance and are considered classics. Contemporary selections are also included. The serious student of dentistry may extract from this section background information and details related to the progress of removable partial prosthodontics over the years.

We do not imply that sources have been exhausted in compiling these lists of textbooks and articles. We have attempted to correctly classify listed articles for ready reference; however, the length of the "Miscellaneous" section attests to the difficulties encountered.

## TEXTBOOKS

- Alberktsson T, Zarb GA: *The Brånemark osseointegrated implant*, Chicago, 1989, Quintessence.
- Anusavice KJ: *Phillips' science of dental materials*, ed 11, St Louis, 2003, Saunders.
- Applegate OC: *Essentials of removable partial denture prosthesis*, ed 3, Philadelphia, 1965, WB Saunders.
- Babbush CA, et al.: *Dental implants: the art and science*, ed 2, St Louis, 2011, Saunders.
- Beumer J, Curtis TA, Firtell DN: *Maxillofacial prosthetics*, St Louis, 1979, Mosby.
- Block MS: *Color atlas of dental implant surgery*, ed 3, St Louis, 2011, Saunders.
- Brand RW, Isselhard DE: *Anatomy of orofacial structures*, ed 7, St Louis, 2003, Mosby.
- Brewer AA, Morrow RM: *Overdentures*, ed 2, St Louis, 1980, Mosby.
- Brunette DM: *Critical thinking: understanding and evaluating dental research*, ed 2, Chicago, 2007, Quintessence.
- Dawson PE: *Functional occlusion: from TMJ to smile design*, St Louis, 2007, Mosby.
- Dolder EJ, Durrer GT: *The bar-joint denture*, Chicago, 1978, Quintessence.
- Dubrul EL: *Sicher and Dubrul's oral anatomy*, ed 8, St Louis/Tokyo, 1988, Ishiyaku EuroAmerica.
- Dykema RW, Cunningham DM, Johnston JF: *Modern practice in removable partial prosthodontics*, Philadelphia, 1969, WB Saunders.
- Fonseca RJ, Davis WH: *Reconstructive preprosthetic oral and maxillofacial surgery*, ed 2, Philadelphia, 1995, WB Saunders.
- Graber G: *Removable partial dentures*, Stuttgart, Germany, 1988, Thieme Medical.
- Graber DA, Goldstein RE, Feinman RA: *Porcelain laminate veneers*, Chicago, 1988, Quintessence.
- Grasso JE, Miller EL: *Partial prosthodontics*, ed 3, St Louis, 1991, Mosby.
- Hoag PM, Pawlak EA: *Essentials of periodontics*, ed 4, St Louis, 1990, Mosby.
- Johnson DL, Stratton RJ: *Fundamentals of removable prosthodontics*, Chicago, 1980, Quintessence.
- Johnston JF, et al.: *Modern practice in crown and bridge prosthodontics*, ed 4, Philadelphia, 1986, WB Saunders.
- Jordon RE: *Esthetic composite bonding*, ed 2, St Louis, 1993, Mosby.
- Kratochvil FJ: *Partial removable prosthodontics*, Philadelphia, 1988, WB Saunders.
- Krol AJ: *Removable partial denture design outline syllabus*, ed 5, San Francisco, 1999, University of the Pacific School of Dentistry.
- Laney WR, et al.: *Maxillofacial prosthetics*, Littleton, MA, 1979, PSG.
- Laney WR, Gibilisco JA: *Diagnosis and treatment in prosthodontics*, Philadelphia, 1983, Lea & Febiger.
- Little JW, et al.: *Dental management of the medically compromised patient*, ed 7, St Louis, 2008, Mosby.
- Malamed SF: *Medical emergencies in the dental office*, ed 6, St Louis, 2007, Mosby.
- Malone WPF, Koth DC: *Tylman's theory and practice of fixed prosthodontics*, ed 8, Tokyo, 1989, IEA.
- Miller CH, Palenik CJ: *Infection control and management of hazardous materials for the dental team*, ed 4, St Louis, 2010, Mosby.
- Morrow RM, Rudd KD, Rhoads JE: *Dental laboratory procedures: complete dentures*, vol. 1. St Louis, 1985, Mosby.
- Mosby's dental dictionary*, ed 3, St Louis, 2013, Mosby/Elsevier.
- Nelson SJ: *Wheeler's dental anatomy, physiology, and occlusion*, ed 9, St Louis, 2010, Saunders.
- Nevins M, Mellonig JT: *Periodontal therapy: clinical approaches and evidence of success*, vol. 1. Chicago, 1998, Quintessence.
- O'Brien WJ: *Dental materials and their selection*, ed 4, Chicago, 2009, Quintessence.
- Okeson JP: *Management of temporomandibular disorders and occlusion*, ed 6, St Louis, 2008, Mosby.
- Okeson JP: *Orofacial pain: guidelines for assessment, diagnosis, and management*, Chicago, 1996, Quintessence.
- Osborne J: *Osborne and Lammie's partial dentures*, ed 5, Oxford, 1986, Blackwell Scientific.

- Phoenix RD, Cagna DR, DeFreest CF: *Stewart's clinical removable partial prosthodontics*, ed 4, Chicago, 2008, Quintessence.
- Powers JM, Sakaguchi RL: *Craig's restorative dental materials*, ed 12, St Louis, 2006, Mosby.
- Powers JM, Wataha JC: *Dental materials: properties and manipulation*, ed 9, St Louis, 2008, Mosby.
- Preiskel HW: *Precision attachments in prosthodontics*, Chicago, 1996, Quintessence.
- Rahn AO, Ivanhoe JR, Plummer KD: *Textbook of complete dentures*, ed 6, Shelton, CT, 2009, People's Medical Publishing House.
- Ramfjord SP, Ash Jr MM: *Occlusion*, ed 4, Philadelphia, 1995, WB Saunders.
- Renner RP, Boucher LJ: *Removable partial prosthodontics*, Chicago, 1987, Quintessence.
- Rosenstiel SF, Land MF, Fujimoto J: *Contemporary fixed prosthodontics*, ed 4, St Louis, 2006, Mosby.
- Rudd KD, Rhoads JE, Morrow RM: *Dental laboratory procedures*, ed 2, vol. 3, St Louis, 1986, Mosby.
- Sarnat BG, Laskin DM: *The temporomandibular joint: a biological basis for clinical practice*, ed 4, Philadelphia, 1992, WB Saunders.
- Shillingberg HT, et al.: *Fundamentals of fixed prosthodontics*, ed 3, Chicago, 1997, Quintessence.
- Singh P, Cranin AN: *Atlas of oral implantology*, ed 3, St Louis, 2010, Mosby.
- Stratton RP, Wiebelt FJ: *An atlas of removable partial denture design*, Chicago, 1988, Quintessence.
- Watt DM, MacGregor AR: *Designing partial dentures*, Littleton, MA, 1985, PSG.
- Winkler S: *Essentials of complete denture prosthodontics*, ed 2, Littleton, MA, 1988, PSG.
- Wood NK: *Differential diagnosis of oral and maxillofacial lesions*, ed 5, St Louis, 1997, Mosby.
- Wood NK: *Review of diagnosis, oral medicine, radiology, and treatment planning*, ed 4, St Louis, 1999, Mosby.
- Yaliso IL, Dietz Jr JB: *Telescopic prosthetic therapy*, Philadelphia, 1979, George F Stickley.
- Zarb GA: *Temporomandibular joint and masticatory muscle disorders*, St Louis, 1995, Mosby.
- Zarb GA, et al.: *Prosthodontic treatment for edentulous patients: complete dentures and implant-supported prostheses*, ed 12, St Louis, 2004, Mosby.
- Brudvik JS, Morris HF: Stress-relaxation testing. Part III: influence of wire alloys, gauges, and lengths on clasp behavior, *J Prosthet Dent* 46:374, 1981.
- Brudvik JS, Wormley JH: Construction techniques for wrought-wire retentive clasp arms as related to clasp flexibility, *J Prosthet Dent* 30:769-774, 1973.
- Chandler JA, Brudvik JS: Clinical evaluation of patients eight to nine years after placement of removable partial dentures, *J Prosthet Dent* 51:736, 1984.
- Chou TM, et al.: Photoelastic analysis and comparison of force-transmission characteristics of intracoronal attachments with clasp distal-extension removable partial dentures, *J Prosthet Dent* 62:313-319, 1989.
- Chou TM, et al.: Stereophotogrammetric analysis of abutment tooth movement in distal-extension removable partial dentures with intracoronal attachments and clasps, *J Prosthet Dent* 66:343-349, 1991.
- Clayton JA: A stable base precision attachment removable partial denture (PARPD): theories and principles, *Dent Clin North Am* 24:3-29, 1980.
- Cooper H: Practice management related to precision attachment prostheses, *Dent Clin North Am* 24:45-61, 1980.
- DeVan MM: Preserving natural teeth through the use of clasps, *J Prosthet Dent* 5:208-214, 1955.
- Dietz WH: Modified abutments for removable and fixed prosthodontics, *J Prosthet Dent* 11:1112-1116, 1961.
- Dixon DL, et al.: Wear of I-bar clasps and porcelain laminate restorations, *Int J Prosthet* 5:28-33, 1992.
- Dolder EJ: The bar joint mandibular denture, *J Prosthet Dent* 11:689-707, 1961.
- Eliason CM: RPA clasp design for distal-extension removable partial dentures, *J Prosthet Dent* 49:25-27, 1983.
- Frank RP, Brudvik JS, Nicholls JJ: A comparison of the flexibility of wrought-wire and cast circumferential clasps, *J Prosthet Dent* 49:471-476, 1983.
- Getz II: Making a full-coverage restoration on an abutment to fit an existing removable partial denture, *J Prosthet Dent* 54:335-336, 1985.
- Gilson TD: A fixable-removable prosthetic attachment, *J Prosthet Dent* 9:247-255, 1959.
- Gindea AE: A retentive device for removable dentures, *J Prosthet Dent* 27:501-508, 1972.
- Grasso JE: A new removable partial denture clasp assembly, *J Prosthet Dent* 43:618-621, 1980.
- Green JH: The hinge-lock abutment attachment, *J Am Dent Assoc* 47:175-180, 1953.
- Hebel KS, Graser GN, Featherstone JD: Abrasion of enamel and composite resin by removable partial denture clasps, *J Prosthet Dent* 52:389, 1984.
- Highton R, Caputo AA, Matyas J: Retention and stress characteristics for a magnetically retained partial denture, *J Dent Res (IADR abstract 279) 62*(entire issue), 1982.
- Isaacson GO: Telescope crown retainers for removable partial dentures, *J Prosthet Dent* 22:436-448, 1969.
- Ivanhoe JR: Alternative cingulum rest seat, *J Prosthet Dent* 54:395-396, 1985.
- James AG: Self-locking posterior attachment for removable tooth-supported partial dentures, *J Prosthet Dent* 5:200-205, 1955.
- Johnson DL, Stratton RJ, Duncanson Jr MG: The effect of single plane curvature on half-round cast clasps, *J Dent Res* 62:833-836, 1983.
- Johnson JF: The application and construction of the pinledge retainer, *J Prosthet Dent* 3:559-567, 1953.
- Kapur KK, et al.: A randomized clinical trial of two basic removable partial denture designs. Part I: comparisons of five-year success rates and periodontal health, *J Prosthet Dent* 72:268-282, 1994.
- Knodle JM: Experimental overlay and pin partial denture, *J Prosthet Dent* 17:472-478, 1967.
- Knowles LE: A dowel attachment removable partial denture, *J Prosthet Dent* 13:679-687, 1963.

## ABUTMENT RETAINERS: EXTERNAL AND INTERNAL ATTACHMENTS

- Adisman IK: The internal clip attachment in fixed removable partial denture prosthesis, *N Y J Dent* 32:125-129, 1962.
- Ainamo J: Precision removable partial dentures with pontic abutments, *J Prosthet Dent* 23:289-295, 1970.
- Augsburger RH: The Gilmore attachment, *J Prosthet Dent* 16:1090-1102, 1966.
- Becker CM, Campbell MC, Williams DL: The Thompson dowel-rest system modified for chrome-cobalt removable partial denture frameworks, *J Prosthet Dent* 39:384-391, 1978.
- Ben-Ur Z, Aviv I, Cardash HS: A modified direct retainer design for distal extension removable partial dentures, *J Prosthet Dent* 70:342-344, 1988.
- Benson D, Spolsky VW: A clinical evaluation of removable partial dentures with I-bar retainers, Part I *J Prosthet Dent* 41:246, 1979.
- Berg Jr T: I-bar: myth and counter myth, *Dent Clin North Am* 23(1):65-75, 1979.
- Blatterfein L: Design and positional arrangement of clasps for partial dentures, *N Y J Dent* 22:305-306, 1952.
- Blatterfein L: Study of partial denture clasping, *J Am Dent Assoc* 43:169-185, 1951.
- Brodelt RHW: A simple paralleling template for precision attachments, *J Prosthet Dent* 27:285-288, 1972.

- Koper A: Retainer for removable partial dentures: the Thompson dowel, *J Prosthet Dent* 30:759–768, 1973.
- Kotowicz WE: Clinical procedures in precision attachment removable partial denture construction, *Dent Clin North Am* 24:143–164, 1980.
- Kotowicz WE, et al.: The combination clasp and the distal extension removable partial denture, *Dent Clin North Am* 17:651–660, 1973.
- Kratochvil FJ, Davidson PN, Tandarts JG: Five-year study of treatment with removable partial dentures, Part I *J Prosthet Dent* 48:237, 1982.
- Krol AJ: Clasp design for extension base removable partial dentures, *J Prosthet Dent* 29:408–415, 1973.
- Krol AJ: RPI clasp retainer and its modifications, *Dent Clin North Am* 17:631–649, 1973.
- Langer A: Combinations of diverse retainers in removable partial dentures, *J Prosthet Dent* 40:378–384, 1978.
- LaVere AM: Analysis of facial surface undercuts to determine use of RPI or RPA clasps, *J Prosthet Dent* 56:741–743, 1986.
- Leupold RJ, Faraone KL: Etched castings as an adjunct to mouth preparation for removable partial dentures, *J Prosthet Dent* 53:655–658, 1985.
- Lubovich RP, Peterson T: The fabrication of a ceramic-metal crown to fit an existing removable partial denture clasp, *J Prosthet Dent* 37:610–614, 1977.
- Marinello CP, et al.: Resin-bonded etched castings with extracoronal attachments for removable partial dentures, *J Prosthet Dent* 66:52–55, 1991.
- Maroso DJ, Schmidt JR, Blustein R: A preliminary study of wear of porcelain when subjected to functional movements of retentive clasp arms, *J Prosthet Dent* 45:14, 1981.
- McLeod NS: Improved design for the Thompson dowel rest semiprecision intracoronal retainer, *J Prosthet Dent* 40:513–516, 1978.
- McLeod NS: A theoretical analysis of the mechanics of the Thompson dowel semiprecision intracoronal retainer, *J Prosthet Dent* 37:19–27, 1977.
- Mensor Jr MC: Attachment fixation for overdentures, Part I, *J Prosthet Dent* 37:366–373, 1977.
- Mensor Jr MC: Attachment fixation of the overdentures, Part II, *J Prosthet Dent* 39:16–20, 1978.
- Morris HF, et al.: Stress distribution within circumferential clasp arms, *J Oral Rehabil* 3:387–391, 1976.
- Morris HF, et al.: Stress-relaxation testing. Part II. Comparison of bending profiles, microstructures, microhardness, and surface characteristics of several wrought-wires, *J Prosthet Dent* 46:256, 1981.
- Morris HF, et al.: Stress-relaxation testing. Part IV. Clasp pattern dimensions and their influence on clasp behavior, *J Prosthet Dent* 50:319, 1983.
- Morrison ML: Internal precision attachment retainers for partial dentures, *J Am Dent Assoc* 64:209–215, 1962.
- Morrow RM: Tooth-supported complete dentures: an approach to preventive prosthodontics, *J Prosthet Dent* 21:513–522, 1969.
- Odio Jr VJ: The movable-arm clasp for complete passivity in partial denture construction, *J Am Dent Assoc* 74:1009–1015, 1967.
- Plotnik IJ: Internal attachment for fixed removable partial dentures, *J Prosthet Dent* 8:85–93, 1958.
- Pound E: Cross-arch splinting vs. premature extractions, *J Prosthet Dent* 16:1058–1068, 1966.
- Preiskel H: Precision attachments for free-end saddle prostheses, *Br Dent J* 127(462):468, 1969.
- Preiskel H: Screw retained telescopic prosthesis, *Br Dent J* 130:107–112, 1971.
- Prince IB: Conservation of the supportive mechanism, *J Prosthet Dent* 15:327–338, 1965.
- Sato Y, et al.: Effect of friction coefficient on Akers clasp retention, *J Prosthet Dent* 78:22–27, 1997.
- Seto BG, Avera S, Kagawa T: Resin bonded etched cast cingulum rest retainers for removable partial dentures, *Quintessence Int* 16:757–760, 1985.
- Singer F: Improvements in precision: attached removable partial dentures, *J Prosthet Dent* 17:69–72, 1967.
- Smith RA, Rymarz FP: Cast clasp transitional removable partial dentures, *J Prosthet Dent* 22:381–385, 1969.
- Snyder HA, Duncanson MG, Johnson D: Effect of clasp flexure on a 4-meta adhered light-polymerized composite resin, *Int J Prosthodont* 4:364–370, 1991.
- Soderfeldt B, et al.: A multilevel analysis of factors affecting the longevity of fixed partial dentures, retainers and abutments, *J Oral Rehabil* 25:245–252, 1998.
- Spielberger MC, et al.: Effect of retentive clasp design on gingival health: a feasibility study, *J Prosthet Dent* 52:397, 1984.
- Stankewitz CG, Gardner FM, Butler GV: Adjustment of cast clasps for direct retention, *J Prosthet Dent* 45:344, 1981.
- Stansbury BE: A retentive attachment for overdentures, *J Prosthet Dent* 35:228–230, 1976.
- Stern MA, Brudvik JS, Frank RP: Clinical evaluation of removable partial denture rest seat adaptation, *J Prosthet Dent* 53:658–662, 1985.
- Stewart BL, Edwards RO: Retention and wear of precision-type attachments, *J Prosthet Dent* 49:28–34, 1983.
- Strohaber RA, Trovillion HM: Removable partial overdentures, *J Prosthet Dent* 35:624–629, 1976.
- Symposium on semiprecision attachments in removable partial dentures, *Dent Clin North Am* 29:1–237, 1985.
- Tautin FS: Abutment stabilization using a nonresilient gingival bar connector, *J Am Dent Assoc* 99:988–989, 1979.
- Tietge JD, et al.: Wear of composite resins and cast direct retainers, *Int J Prosthet* 5:145–153, 1992.
- Vig RG: Splinting bars and maxillary indirect retainers for removable partial dentures, *J Prosthet Dent* 13:125–129, 1963.
- Walter JD: Anchor attachments used as locking devices in two-part removable prostheses, *J Prosthet Dent* 33:628–632, 1975.
- Waltz ME: Ceka extracoronal attachments, *J Prosthet Dent* 29:167–171, 1973.
- White JT: Visualization of stress and strain related to removable partial denture abutments, *J Prosthet Dent* 40:143–151, 1978.
- Wiebelt FJ, Shillingburg Jr HT: Abutment preparation modifications for removable partial denture rest seats, *Quintessence Dent Technol* 9:449–451, 1985.
- Williams AG: Technique for provisional splint with attachment, *J Prosthet Dent* 21:555–559, 1969.
- Willis LM, Swoope CC: Precision attachment partial dentures. In Clark JW, editor: *Clinical dentistry*, vol. 5. New York, 1976, Harper & Row.
- Wright SM: Use of spring-loaded attachments for retention of removable partial dentures, *J Prosthet Dent* 51:605–610, 1984.
- Zakler JM: Intracoronal precision attachments, *Dent Clin North Am* 24:131–141, 1980.
- Zinner ID, Miller RD, Panno FV: Clinical management of abutments with intracoronal attachments, *J Prosthet Dent* 67:761–767, 1992.
- Zinner ID, Miller RD, Panno FV: Precision attachments, *Dent Clin North Am* 31:395–416, 1987.
- Zinner ID, Miller RD, Panno FV: Semiprecision rest system for distal extension removable partial denture design, *J Prosthet Dent* 42:131–134, 1979.

## ANATOMY

- Bennett NG: A contribution to the study of the movements of the mandible, *J Prosthet Dent* 8:41–54, 1958.
- Boucher CO: Complete denture impressions based upon the anatomy of the mouth, *J Am Dent Assoc* 31:1174–1181, 1944.
- Brodie AG: Anatomy and physiology of head and neck musculature, *Am J Orthod* 36:831–844, 1950.
- Casey DM: Palatopharyngeal anatomy and physiology, *J Prosthet Dent* 49:371–378, 1983.
- Craddock FW: Retromolar region of the mandible, *J Am Dent Assoc* 47:453–455, 1953.
- Haines RW, Barnett SG: The structure of the mouth in the mandibular molar region, *J Prosthet Dent* 9:962–974, 1959.

Martone AL, et al.: Anatomy of the mouth and related structures: I, *J Prosthet Dent* 11:1009–1018, 1961; II, 12:4–27, 1962; III, 12:206–219, 1962; IV, 12:409–419, 1962; V, 12:629–636, 1962; VI, 12:817–834, 1962; VII, 13:4–33, 1963; VIII, 13:204–228, 1963.

Merkeley HJ: The labial and buccal accessory muscles of mastication, *J Prosthet Dent* 4:327–334, 1954.

Merkeley HJ: Mandibular rearmament. I. Anatomic considerations, *J Prosthet Dent* 9:559–566, 1959.

Monteith BD: Management of loading forces on the mandibular extension prosthesis. Part II: Classification for matching modalities to clinical situations, *J Prosthet Dent* 52:832–835, 1984.

Pendleton EC: Anatomy of the face and mouth from the standpoint of the denture prosthodontist, *J Am Dent Assoc* 33:219–234, 1946.

Pendleton EC: Changes in the denture supporting tissues, *J Am Dent Assoc* 42:1–15, 1951.

Pietrokovski J: The bony residual ridge in man, *J Prosthet Dent* 34:456–462, 1975.

Pietrokovski J, Sorin S, Zvia H: The residual ridge in partially edentulous patients, *J Prosthet Dent* 36:150–158, 1976.

Preti G, Bruscajin C, Fava C: Anatomic and statistical study to determine the inclination of the condylar long axis, *J Prosthet Dent* 49:572–575, 1983.

Roche AF: Functional anatomy of the muscles of mastication, *J Prosthet Dent* 13:548–570, 1963.

Silverman SI: Denture prosthesis and the functional anatomy of the maxillofacial structures, *J Prosthet Dent* 6:305–331, 1956.

BIOMECHANICS

Asher ML: Application of the rotational path design concept to a removable partial denture with a distal-extension base, *J Prosthet Dent* 68:641–643, 1992.

Augthun M, et al.: The influence of spruing technique on the development of tension in a cast partial denture framework, *Int J Prosthodont* 7:72–76, 1994.

Avant WE: Factors that influence retention of removable partial dentures, *J Prosthet Dent* 25:265–270, 1971.

Avant WE: Fulcrum and retention lines in planning removable partial dentures, *J Prosthet Dent* 25:162–166, 1971.

Aviv I, Ben-Ur Z, Cardash HS: An analysis of rotational movement of asymmetrical distal-extension removable partial dentures, *J Prosthet Dent* 61:211–214, 1989.

Aydinlik E, Akay HU: Effect of a resilient layer in a removable partial denture base on stress distribution to the mandible, *J Prosthet Dent* 44:17–20, 1980.

Ben-Ur Z, et al.: Designing clasps for the asymmetric distal extension removable partial denture, *Int J Prosthodont* 9:374–378, 1996.

Berg TE, Caputo AA: Comparison of load transfer by maxillary distal extension removable partial dentures with a spring-loaded plunger attachment and I-bar retainer, *J Prosthet Dent* 68:492–499, 1992.

Berg TE, Caputo AA: Load transfer by a maxillary distal-extension removable partial denture with extracoronal attachments, *J Prosthet Dent* 68:784–789, 1992.

Bezzon OL, et al.: Surveying removable partial dentures: the importance of guiding planes and path of insertion for stability, *J Prosthet Dent* 78:412–418, 1997.

Bridgeman JT, et al.: Comparison of titanium and cobalt-chromium removable partial denture clasps, *J Prosthet Dent* 78:187–193, 1997.

Browning JD, Eick JD, McGarrah HE: Abutment tooth movement measured in vivo by using stereophotogrammetry, *J Prosthet Dent* 57:323–328, 1987.

Brudvik JS, Morris HF: Stress-relaxation testing. Part III: Influence of wire alloys, gauges, and lengths on clasp behavior, *J Prosthet Dent* 46:374–379, 1981.

Byron Jr R, Frazer RQ, Herren MC: Rotational path removable partial denture: an esthetic alternative, *Gen Dent* 55:245–250, 2007; quizzes 251, 264.

Cecconi BT: Effect of rest design on transmission of forces to abutment teeth, *J Prosthet Dent* 32:141–151, 1974.

Cecconi BT, Asgar K, Dootz E: Clasp assembly modifications and their effect on abutment tooth movement, *J Prosthet Dent* 27:160–167, 1972.

Cecconi BT, Asgar K, Dootz E: The effect of partial denture clasp design on abutment tooth movement, *J Prosthet Dent* 25:44–56, 1971.

Cecconi BT, Asgar K, Dootz E: Removable partial denture abutment tooth movement as affected by inclination of residual ridges and types of loading, *J Prosthet Dent* 25:375–381, 1971.

Chou TM, et al.: Photoelastic analysis and comparison of force-transmission characteristics of intracoronal attachments with clasp distal-extension removable partial dentures, *J Prosthet Dent* 62:313–319, 1989.

Chou TM, et al.: Stereophotogrammetric analysis of abutment tooth movement in distal-extension removable partial dentures with intracoronal attachments and clasps, *J Prosthet Dent* 66:343–349, 1991.

Clayton JA, Jaslow C: A measurement of clasp forces on teeth, *J Prosthet Dent* 25:21–43, 1971.

Craig RG, Farah JW: Stresses from loading distal extension removable partial dentures, *J Prosthet Dent* 39:274–277, 1978.

DeVan MM: The nature of the partial denture foundation: suggestions for its preservation, *J Prosthet Dent* 2:210–218, 1952.

el Charkawi HG, et al.: The effect of the resilient-layer distal-extension partial denture on movement of the abutment teeth: a new methodology, *J Prosthet Dent* 60:622–630, 1988.

Fisher RL: Factors that influence the base stability of mandibular distal-extension removable partial dentures: a longitudinal study, *J Prosthet Dent* 50:167–171, 1983.

Frank RP, Nicholls JI: A study of the flexibility of wrought-wire clasps, *J Prosthet Dent* 45:259–267, 1981.

Frechette AR: The influence of partial denture design on distribution of force to abutment teeth, *J Prosthet Dent* 6:195–212, 1956.

Goodkind RJ: The effects of removable partial dentures on abutment tooth mobility, *J Prosthet Dent* 30:139–146, 1973.

Goodman JJ, Goodman HW: Balance of force in precision free-end restorations, *J Prosthet Dent* 13:302–308, 1963.

Hall WA: Variations in registering interarch transfers in removable partial denture construction, *J Prosthet Dent* 30:548–553, 1973.

Harrop J, Javid N: Reciprocal arms of direct retainers in removable partial dentures, *J Can Dent Assoc* 4:208–211, 1976.

Henderson D, Seward TE: Design and force distribution with removable partial dentures: a progress report, *J Prosthet Dent* 17:350–364, 1967.

Henriques GE, et al.: Soldering and remelting influence on fatigue strength of cobalt-chromium alloy, *J Prosthet Dent* 78:146–152, 1997.

Hindels GW: Stress analysis in distal extension partial dentures, *J Prosthet Dent* 7:197–205, 1957.

Iwama CY, et al.: Cobalt-chromium-titanium alloy for removable partial dentures, *Int J Prosthodont* 10:309–317, 1997.

Johnson DL, Stratton RJ, Duncanson MGJ: The effect of single plane curvature on half-round cast clasps, *J Dent Res* 62:833–836, 1983.

Kaires AK: Partial denture design and its relation to force distribution and masticatory performance, *J Prosthet Dent* 6:672–683, 1956.

Knowles LE: The biomechanics of removable partial dentures and its relationship to fixed prosthesis, *J Prosthet Dent* 8:426–430, 1958.

Kratochvil FJ: Influence of occlusal rest position and clasp design on movement of abutment teeth, *J Prosthet Dent* 13:114–124, 1963.

Kratochvil FJ, Caputo AA: Photoelastic analysis of pressure on teeth and bone supporting removable partial dentures, *J Prosthet Dent* 3:52, 1975.

Kratochvil FJ, Thompson WD, Caputo AA: Photoelastic analysis of stress patterns on teeth and bone with attachment retainers for removable partial dentures, *J Prosthet Dent* 46:21–28, 1981.

Lofbers PG, Ericson G, Eliasson S: A clinical and radiographic evaluation of removable partial dentures retained by attachments to alveolar bars, *J Prosthet Dent* 47:126–132, 1982.

Lowe RD, Kydd WL, Smith DE: Swallowing and resting forces related to lingual flange thickness in removable partial dentures, *J Prosthet Dent* 23:279–288, 1970.

- MacGregor AR, Miller TPG, Farah JW: Stress analysis of partial dentures, *J Dent* 6:125–132, 1978.
- Marei MK: Measurement (in vitro) of the amount of force required to dislodge specific clasps from different depths of undercut, *J Prosthet Dent* 74:258–263, 1995.
- Maroso DJ, Schmidt JR, Blustein R: A preliminary study of wear of porcelain when subjected to functional movements of retentive clasp arms, *J Prosthet Dent* 45:14–17, 1981.
- Matheson GR, Brudvik JS, Nicholls JI: Behavior of wrought-wire clasps after repeated permanent deformation, *J Prosthet Dent* 55:226–231, 1986.
- Maxfield JB, Nicholls JI, Smith DE: The measurement of forces transmitted to abutment teeth of removable partial dentures, *J Prosthet Dent* 41:134, 1979.
- McCartney JW: Motion vector analysis of an abutment for a distal-extension removable partial denture, *J Prosthet Dent* 43:15–21, 1980.
- McDowell GC: Force transmission by indirect retainers during unilateral loading, *J Prosthet Dent* 39:616–621, 1978.
- McDowell GC, Fisher RL: Force transmission by indirect retainers when a unilateral dislodging force is applied, *J Prosthet Dent* 47:360–365, 1982.
- McLeod NS: An analysis of the rotational axes of semiprecision and precision distal-extension removable partial dentures, *J Prosthet Dent* 48:130–134, 1982.
- Morris HF, Asgar K, Tillitson E: Stress-relaxation testing. I. A new approach to the testing of removable partial denture alloys, wrought-wires, and clasp behavior, *J Prosthet Dent* 46:133–141, 1981.
- Morris HF, Brudvik JS: Influence of polishing on cast clasp properties, *J Prosthet Dent* 55:75–77, 1986.
- Morris HF, et al.: Stress-relaxation testing. IV. Clasp pattern dimensions and their influence on clasp behavior, *J Prosthet Dent* 50:319–326, 1983.
- NaBadalung DP, et al.: Comparison of bond strengths of denture base resins to nickel-chromium-beryllium removable partial denture alloy, *J Prosthet Dent* 78:566–573, 1997.
- NaBadalung DP, et al.: Frictional resistance of removable partial dentures with retrofitted resin composite guide planes, *Int J Prosthodont* 10:116–122, 1997.
- NaBadalung DP, et al.: Laser welding of a cobalt-chromium removable partial denture alloy, *J Prosthet Dent* 79:285–290, 1998.
- Ogata K, Shimigui K: Longitudinal study of forces transmitted from denture base to retainers of free-end saddle dentures with Akers clasps, *J Oral Rehabil* 18:471–480, 1991.
- Plotnick IJ, Beresin VE, Simkins AB: The effects of variations in the opposing dentition on changes in the partially edentulous mandible, *J Prosthet Dent* 133:278–286, 1975; II, 33:403–406, 1975; III, 33:529–534, 1975.
- Sansom BP, et al.: Rest seat designs for inclined posterior abutments: a photoelastic comparison, *J Prosthet Dent* 58:57–62, 1987.
- Shohet H: Relative magnitudes of stress on abutment teeth with different retainers, *J Prosthet Dent* 21:267–282, 1969.
- Smith BH: Changes in occlusal face height with removable partial dentures, *J Prosthet Dent* 34:278–285, 1975.
- Smith BJ, Turner CH: The use of crowns to modify abutment teeth of removable partial dentures, *J Dent* 7:52–56, 1979.
- Smyd ES: Biomechanics of prosthetic dentistry, *J Prosthet Dent* 4:368–383, 1954.
- Stern WJ: Guiding planes in clasp reciprocation and retention, *J Prosthet Dent* 34:408–414, 1975.
- Swoope CC, Frank RP: Stress control and design. In Clark JW, editor: *Clinical dentistry*, vol. 5. New York, 1976, Harper & Row.
- Taylor DT, Pflushoeft FA, McGivney GP: Effect of two clasping assemblies on arch integrity as modified by base adaptation, *J Prosthet Dent* 47:120–125, 1982.
- Tebrock OC, et al.: The effect of various clasping systems on the mobility of abutment teeth for distal-extension removable partial dentures, *J Prosthet Dent* 41:511, 1979.
- Thompson WD, Kratochvil FJ, Caputo AA: Evaluation of photoelastic stress patterns produced by various designs of bilateral distal-extension removable partial dentures, *J Prosthet Dent* 38:261, 1977.
- Toth RW, et al.: Shear strength of lingual rest seats prepared in bonded composite, *J Prosthet Dent* 56:99–104, 1986.
- Vallittu PK: Comparison of the in vitro fatigue resistance of an acrylic resin removable partial denture reinforced with continuous glass fibers or metal wires, *J Prosthodont* 5:115–121, 1996.
- Vallittu PK: Deflection fatigue of cobalt-chromium, titanium, and gold alloy cast denture clasp, *J Prosthet Dent* 74:412–419, 1995.
- Waldmeier MD, et al.: Bend testing of wrought-wire removable partial denture alloys, *J Prosthet Dent* 76:559–565, 1996.
- Wills DJ, Manderson RD: Biomechanical aspects of the support of partial dentures, *J Dent* 5:310–318, 1977.
- Yurkstas A, Fridley HH, Manly RS: A functional evaluation of fixed and removable bridgework, *J Prosthet Dent* 1:570–577, 1951.
- Zoeller GN, Kelly Jr WJ: Block form stability in removable partial prosthodontics, *J Prosthet Dent* 25:515–519, 1971.

## CAD/CAM, RAPID PROTOTYPING OF PARTIAL DENTURES

- Eggbeer D, Bibb R, Williams R: The computer-aided design and rapid prototyping fabrication of removable partial denture frameworks, *Proc Inst Mech Eng H219(3)*:195–202, 2005.
- Lang LA, Tulunoglu I: A critically appraised topic review of computer-aided design/computer-aided machining of removable partial denture frameworks, *Dent Clin North Am* 58(1):247–255, 2014, <http://dx.doi.org/10.1016/j.cden.2013.09.006>.
- Sun J, Zhang FQ: The application of rapid prototyping in prosthodontics, *J Prosthodont* 21(8):641–644, 2012, <http://dx.doi.org/10.1111/j.1532-849X.2012.00888.x>.

## CLASSIFICATION

- Applegate OC: The rationale of partial denture choice, *J Prosthet Dent* 10:891–907, 1960.
- Avant WE: A universal classification for removable partial denture situations, *J Prosthet Dent* 16:533–539, 1966.
- Bailyn M: Tissue support in partial denture construction, *Dent Cosmos* 70:988–997, 1928.
- Beckett LS: The influence of saddle classification on the design of partial removable restoration, *J Prosthet Dent* 3:506–516, 1953.
- Costa E: A simplified system for identifying partially edentulous arches, *J Prosthet Dent* 32:639–645, 1974.
- Cummer WE: Partial denture service. In Anthony LP, editor: *American textbook of prosthetic dentistry*, Philadelphia, 1942, Lea & Febiger.
- Friedman J: The ABC classification of partial denture segments, *J Prosthet Dent* 3:517–524, 1953.
- Godfrey RJ: Classification of removable partial dentures, *J Am Coll Dent* 18:5–13, 1951.
- Kennedy E: Partial denture construction, *Dental Items of Interest* 3–8, 1928.
- Mensor Jr MC: Classification and selection of attachments, *J Prosthet Dent* 29:494–497, 1973.
- Miller EL: Systems for classifying partially dentulous arches, *J Prosthet Dent* 24:25–40, 1970.
- Skinner CN: A classification of removable partial dentures based upon the principles of anatomy and physiology, *J Prosthet Dent* 9:240–246, 1959.

## CLEFT PALATE

- Aram A, Subtelny JD: Velopharyngeal function and cleft palate prostheses, *J Prosthet Dent* 9:149–158, 1959.
- Baden E: Fundamental principles of orofacial prosthetic therapy in congenital cleft palate, *J Prosthet Dent* 4:420–433, 1954.
- Bixler D: Heritability of clefts of the lips and palate, *J Prosthet Dent* 33:100–108, 1975.

Buckner H: Construction of a denture with hollow obturator, lid and soft acrylic lining, *J Prosthet Dent* 31:95–99, 1974.

Calvan J: The error of Gustan Passavant, *Plast Reconstr Surg* 13:275–289, 1954.

Cooper HK: Integration of service in the treatment of cleft lip and cleft palate, *J Am Dent Assoc* 47:27–32, 1953.

Dalston RM: Prosthodontic management of the cleft palate patient: a speech pathologist's view, *J Prosthet Dent* 37:327–329, 1978.

Ettinger RL: Use of teeth with a poor prognosis in cleft palate prosthodontics, *J Am Dent Assoc* 94:910–914, 1977.

Fox A: Prosthetic correction of a severe acquired cleft palate, *J Prosthet Dent* 8:542–546, 1958.

Gibbons P, Bloomer H: A supportive-type prosthetic speech aid, *J Prosthet Dent* 8:362–369, 1958.

Graber TM: Oral and nasal structures in cleft palate speech, *J Am Dent Assoc* 53:693–706, 1956.

Harkins CS: Modern concepts in the prosthetic rehabilitation of cleft palate patients, *J Oral Surg* 10:298–312, 1952.

Harkins CS, Ivy RH: Surgery and prosthesis in the rehabilitation of cleft palate patients, *J South Calif Dent Assoc* 19:16–24, 1951.

Immekus JE, Aramany MA: A fixed-removable partial denture for cleft palate patients, *J Prosthet Dent* 34:286–291, 1975.

Landa JS: The prosthodontist views the rehabilitation of the cleft palate patient, *J Prosthet Dent* 6:421–427, 1956.

Lavelle WE, Zach GE: The tissue bar and Ceka anchor as aids in cleft palate rehabilitation, *J Prosthet Dent* 30:321–325, 1973.

Lloyd RS, Pruzansky S, Subtelny JD: Prosthetic rehabilitation of a cleft palate patient subsequent to multiple surgical and prosthetic failures, *J Prosthet Dent* 7:216–230, 1957.

Merkeley HJ: Cleft palate prosthesis, *J Prosthet Dent* 9:506–513, 1959.

Minsley GE, Warren DW, Hairfield WM: The effect of cleft palate speech aid prostheses on the nasopharyngeal airway and breathing, *J Prosthet Dent* 65:122–126, 1991.

Nidiffer TJ, Shipmon TH: The hollow-bulb obturator for acquired palatal openings, *J Prosthet Dent* 7:126–134, 1957.

Olinger NA: Cleft palate prosthesis rehabilitation, *J Prosthet Dent* 2:117–135, 1952.

Rosen MS: Prosthetics for the cleft palate patient, *J Am Dent Assoc* 60:715–721, 1960.

Rothenberg LIA: Overlay dentures for the cleft-palate patient, *J Prosthet Dent* 37:190–195, 1977.

Schneiderman CR, Maun MB: Air flow and intelligibility of speech of normal speakers and speakers with a prosthodontically repaired cleft palate, *J Prosthet Dent* 39:193–199, 1978.

Sharry JJ: The meatus obturator in cleft palate prosthesis, *Oral Surg* 7:852–855, 1954.

Sharry JJ: Meatus obturator in particular and pharyngeal impressions in general, *J Prosthet Dent* 8:893–896, 1958.

Tautin FS, Schaaf NA: Superiorly based obturator, *J Prosthet Dent* 33:96–99, 1975.

Walter JD: Palatopharyngeal activity in cleft palate subjects, *J Prosthet Dent* 63:187–192, 1990.

## COMPLETE MOUTH AND OCCLUSAL REHABILITATION

Brewer AA, Fenton AH: The overdenture, *Dent Clin North Am* 17:723–746, 1973.

Bronstein BR: Rationale and technique of biomechanical occlusal rehabilitation, *J Prosthet Dent* 4:352–367, 1954.

Cohn LA: Occluso-rehabilitation, principles of diagnosis and treatment planning, *Dent Clin North Am* 6:281, 1962.

Curtis SR: Integrating fixed and removable provisional restorations, *J Prosthet Dent* 70:374–377, 1993.

Dubin NA: Advances in functional occlusal rehabilitation, *J Prosthet Dent* 6:252–258, 1956.

Ferencz JL: Splinting, *Dent Clin North Am* 31:383–393, 1987.

Kazis H: Functional aspects of complete mouth rehabilitation, *J Prosthet Dent* 4:833–841, 1954.

Kornfeld M: The problem of function in restorative dentistry, *J Prosthet Dent* 5:670–676, 1955.

Landa JS: An analysis of current practices in mouth rehabilitation, *J Prosthet Dent* 5:527–537, 1955.

Lang BR: Complete denture occlusion, *Dent Clin North Am* 40:85–101, 1996.

Mann AW, Pankey LD: Oral rehabilitation. I. Use of the P-M instrument in treatment planning and restoring the lower posterior teeth, *J Prosthet Dent* 10:135–150, 1960.

Mann AW, Pankey LD: Oral rehabilitation. II. Reconstruction of the upper teeth using a functionally generated path technique, *J Prosthet Dent* 10:151–162, 1960.

Mann AW, Pankey LD: Oral rehabilitation utilizing the Pankey-Mann instrument and a functional bite technique, *Dent Clin North Am* March 215–230, 1959.

McCartney JW: Occlusal reconstruction and rebase procedure for distal extension removable partial dentures, *J Prosthet Dent* 43:695–698, 1980.

Schuyler CH: An evaluation of incisal guidance and its influence on restorative dentistry, *J Prosthet Dent* 9:374–378, 1959.

Schweitzer JM: Open bite from the prosthetic point of view, *Dent Clin North Am* 1:269–283, 1957.

## CROWNS AND FIXED PARTIAL DENTURES

Alexander PC: Analysis of the cuspid protective occlusion, *J Prosthet Dent* 13:309–317, 1963.

Bader JD, et al.: Effect of crown margins on periodontal conditions in regularly attending patients, *J Prosthet Dent* 65:75–79, 1991.

Beeson PE: The use of acrylic resins as an aid in the development of patterns for two types of crowns, *J Prosthet Dent* 13:493–498, 1963.

Binkley TK, Binkley C: Porcelain-fused-to-metal crowns as replacements for denture teeth in removable partial denture construction, *J Prosthet Dent* 58:124–125, 1987.

Blackman R, Baeg R, Barghi N: Marginal accuracy and geometry of cast titanium copings, *J Prosthet Dent* 67:435–440, 1992.

Budtz-Jorgenson E, Isidor F: A five-year longitudinal study of cantilever fixed partial dentures compared with removable partial dentures in a geriatric population, *J Prosthet Dent* 64:42–47, 1990.

Caplan J: Maintenance of full coverage fixed-abutment bridges, *J Prosthet Dent* 5:852–854, 1955.

Cheug SP, Dimmer A: Management of worn dentition with resin-bonded cast metal lingual veneering, *J Prosthet Dent* 63:122–123, 1990.

Coelho DH: Criteria for the use of fixed prosthesis, *Dent Clin North Am* 1:299–311, 1957.

Cooper TM, et al.: Effect of venting on cast gold full crowns, *J Prosthet Dent* 26:621–626, 1971.

Cowgen GT: Retention, resistance and esthetics of the anterior three-quarter crown, *J Am Dent Assoc* 62:167–171, 1961.

Culpepper WD, Moulton PS: Considerations in fixed prosthodontics, *Dent Clin North Am* 23:21–35, 1979.

Dental technology standards, *J Dent Technol* 14:26–31, 1997.

Eckfeldt A, et al.: Changes of masticatory movement characteristics after prosthodontic rehabilitation of individuals with extensive tooth wear, *Int J Prosthodont* 9(6):539–546, 1996.

Elledge DA, Schorr BL: A provisional and new crown to fit with a clasp of an existing removable partial denture, *J Prosthet Dent* 63:541–544, 1990.

Felton DA, et al.: Effect of in vivo crown margin discrepancies on periodontal health, *J Prosthet Dent* 65:357–364, 1991.

Glantz PO, et al.: The devitalized tooth as an abutment in dentitions with reduced but healthy periodontium, *Periodontol* 2000 4:52–57, 1994.

Goldberg A, Jones RD: Constructing cast crowns to fit existing removable partial denture clasps, *J Prosthet Dent* 36:382–386, 1976.

- Goodacre CJ, et al.: The prosthodontic management of endodontically treated teeth: a literature review. Part I. Success and failure data, treatment concepts, *J Prosthodont* 3:243–250, 1994.
- Guyot SE: Nonrigid subocclusal connector for fixed partial dentures, *J Prosthet Dent* 26:433–436, 1971.
- Hansen CA, Cook PA, Nelson DF: Pin-modified facial inlay to enhance retentive contours on a removable partial denture abutment, *J Prosthet Dent* 55:480–481, 1986.
- Henderson D, et al.: The cantilever type of posterior fixed partial dentures: a laboratory study, *J Prosthet Dent* 24:47–67, 1970.
- Johnson Jr EA: Combination of fixed and removable partial dentures, *J Prosthet Dent* 14:1099–1106, 1964.
- Johnston JF, et al.: Construction and assembly of porcelain veneer gold crowns and pontics, *J Prosthet Dent* 12:1125–1137, 1962.
- Kapur KK, et al.: Veterans Administration Cooperative Dental Implant Study: Comparisons between fixed partial dentures supported by blade-vent implants and removable partial dentures. Part II. Comparison of success rates and periodontal health between two treatment modalities, *J Prosthet Dent* 62:685–703, 1992.
- Kapur KK, et al.: Veterans Administration Cooperation Dental Implant Study: Comparisons between fixed partial dentures supported by blade-vent implants and removable partial dentures. Part IV. Comparisons of patient satisfaction between two treatment modalities, *J Prosthet Dent* 66:517–530, 1991.
- Kunisch WH, Dodd J: A conversion alternative to ceramics in a crown-and-sleeve coping prosthesis, *J Prosthet Dent* 49:581–582, 1983.
- Leff A: New concepts in the preparation of teeth for full coverage, *J Prosthet Dent* 5:392–400, 1955.
- Leff A: Reproduction of tooth anatomy and positional relationship in full cast or veneer crowns, *J Prosthet Dent* 6:550–557, 1956.
- Libby G, et al.: Longevity of fixed partial dentures, *J Prosthet Dent* 78:127–131, 1997.
- Malson TS: Anatomic cast crown reproduction, *J Prosthet Dent* 9: 106–112, 1959.
- Marinello CP, Scharer P: Resin-bonded etched cast extracoronary attachments for removable partial dentures: clinical experiences, *Int J Periodont Res Dent* 7:36–49, 1987.
- McArthur DR: Fabrication of full coverage restorations for existing removable partial dentures, *J Prosthet Dent* 51:574–576, 1984.
- Mojon P, et al.: Relationship between prosthodontic status, caries and periodontal disease in a geriatric population, *Int J Prosthodont* 26:564–571, 1995.
- Morris HF, et al.: Department of Veterans Affairs Cooperative Studies Project No. 242: Quantitative and qualitative evaluation of the marginal fit of cast ceramic, porcelain-shoulder, and cast metal full crown margins, *J Prosthet Dent* 67:198–204, 1992.
- Moulding MB, Holland GA, Sulik WD: An alternative orientation of nonrigid connectors in fixed partial dentures, *J Prosthet Dent* 6:236–238, 1992.
- Muenninghoff LA, Johnson MH: Fixed-removable partial dentures, *J Prosthet Dent* 48:547–550, 1982.
- Palmquist S, et al.: Multivariate analyses of factors influencing the longevity of fixed partial dentures, retainers and abutments, *J Prosthet Dent* 71:245–250, 1994.
- Patur B: The role of occlusion and the periodontium in restorative procedures, *J Prosthet Dent* 21:371–379, 1969.
- Pezzoli M, et al.: Magnetizable abutment crowns for distal-extension removable partial dentures, *J Prosthet Dent* 55:475–480, 1986.
- Phillips RW, Biggs DH: Distortion of wax patterns as influenced by storage time, storage temperature, and temperature of wax manipulation, *J Am Dent Assoc* 41:28–37, 1950.
- Phillips RW, Price RR: Some factors which influence the surface of stone dies poured in alginate impressions, *J Prosthet Dent* 5:72–79, 1955.
- Phillips RW, Swartz ML: A study of adaptation of veneers to cast gold crowns, *J Prosthet Dent* 7:817–822, 1957.
- Pound E: The problem of the lower anterior bridge, *J Prosthet Dent* 5:543–545, 1955.
- Preston JD: Preventing ceramic failures when integrating fixed and removable prostheses, *Dent Clin North Am* 23:37–52, 1979.
- Pruden KC: A hydrocolloid technique for pinledge bridge abutments, *J Prosthet Dent* 6:65–71, 1956.
- Pruden WH: Full coverage, partial coverage, and the role of pins, *J Prosthet Dent* 26:302–306, 1971.
- Rhoads JE: The fixed-removable partial denture, *J Prosthet Dent* 48: 122–129, 1982.
- Rubin MK: Full coverage: the provisional and final restorations made easier, *J Prosthet Dent* 8:664–672, 1958.
- Schorr BL, Peregrina AM, Elledge DA: Alternatives to posterior complete crowns: integrating foundations with cuspal protection, *J Prosthet Dent* 69:165–170, 1993.
- Seals Jr RR, Stratton RJ: Surveyed crowns: a key for integrating fixed and removable prosthodontics, *Quintessence Dent Technol* 11:43–49, 1987.
- Sheets CE: Dowel and core foundations, *J Prosthet Dent* 23:58–65, 1970.
- Shooshan ED: The reverse pin-porcelain facing, *J Prosthet Dent* 9:284–301, 1959.
- Smith GP: The marginal fit of the full cast shoulderless crown, *J Prosthet Dent* 7:231–243, 1957.
- Smith GP: Objectives of a fixed partial denture, *J Prosthet Dent* 11:463–473, 1961.
- Staffanou RS, Thayer KE: Reverse pin-porcelain veneer and pontic technique, *J Prosthet Dent* 12(1138):1145, 1962.
- Thurgood BW, Thayer KE, Lee RE: Complete crowns constructed for an existing partial denture, *J Prosthet Dent* 29:507–512, 1973.
- Treppo KW, Smith FW: A technique for restoring abutments for removable partial dentures, *J Prosthet Dent* 40:398–401, 1978.
- Troxell RR: The polishing of gold castings, *J Prosthet Dent* 9:668–675, 1959.
- Turner KA, Messirlian DM: Restoration of the extremely worn dentition, *J Prosthet Dent* 52:464–474, 1984.
- Wagman SS: Tissue management for full cast veneer crowns, *J Prosthet Dent* 15:106–117, 1965.
- Wagner AW, Burkhart JW, Fayle Jr HE: Contouring abutment teeth with cast gold inlays for removable partial dentures, *J Prosthet Dent* 201:330–334, 1968.
- Wallace FH: Resin transfer copings, *J Prosthet Dent* 8:289–292, 1958.
- Wang CJ, Millstein PL, Nathanson D: Effects of cement, cement space, marginal design, seating aid materials, and seating force on crown cementation, *J Prosthet Dent* 67:786–790, 1992.
- Welsh SL: Complete crown construction for a clasp-bearing abutment, *J Prosthet Dent* 34:320–323, 1975.
- Wheeler RC: Complete crown form and the periodontium, *J Prosthet Dent* 11:722–734, 1961.
- Yalisove IL: Crown and sleeve-coping retainers for removable partial prostheses, *J Prosthet Dent* 16:1069–1085, 1966.

## DENTAL LABORATORY PROCEDURES

- ADA Council on Scientific Affairs and ADA Council on Dental Practice: Infection control recommendations for the dental office and the dental laboratory, *J Am Dent Assoc* 11:395–399, 1996.
- Asgar K, Peyton FA: Casting dental alloys to embedded wires, *J Prosthet Dent* 15:312–321, 1965.
- Becker CM, Smith EE, Nicholls JI: The comparison of denture-base processing techniques. I. Material characteristics, *J Prosthet Dent* 37:330–338, 1977.
- Berg E, et al.: Mechanical properties of laser-welded cast and wrought titanium, *J Prosthet Dent* 74:250–257, 1995.
- Blanchard CH: Filling undercuts on refractory casts with investment, *J Prosthet Dent* 3:417–418, 1953.
- Bolouri A, Hilger TC, Gowrylok MD: Modified flasking technique for removable partial dentures, *J Prosthet Dent* 34:221–223, 1975.

- Brudvik JS, Nicholls JI: Soldering of removable partial dentures, *J Prosthet Dent* 49:762–765, 1983.
- Burnett CA, et al.: Sprue design in removable partial denture casting, *J Dent* 24:99–103, 1996.
- Calverley MJ, Moergeli Jr JR: Effect on the fit of removable partial denture frameworks when master casts are treated with cyanoacrylate resin, *J Prosthet Dent* 58:327–329, 1987.
- Casey DM, Crowther DS, Lauciello FR: Strengthening abutment or isolated teeth on removable partial denture master casts, *J Prosthet Dent* 46:105–106, 1981.
- Dirksen LC, Campagna SJ: Mat surface and rugae reproduction for upper partial denture castings, *J Prosthet Dent* 4:67–72, 1954.
- Dootz ER, Craig RG, Peyton FA: Influence of investments and duplicating procedures on the accuracy of partial denture castings, *J Prosthet Dent* 15:679–690, 1965.
- Dootz ER, Craig RG, Peyton FA: Simplification of the chrome-cobalt partial denture casting procedure, *J Prosthet Dent* 17:464–471, 1967.
- Elbert CA, Ryge G: The effect of heat treatment on hardness of a chrome-cobalt alloy, *J Prosthet Dent* 15:873–879, 1965.
- Elliott RW: The effects of heat on gold partial denture castings, *J Prosthet Dent* 13:688–698, 1963.
- Enright CM: Dentist-dental laboratory harmony, *J Prosthet Dent* 11:393–394, 1961.
- Fiebigler GE, Parr GR, Goldman BM: Remount casts for removable partial dentures, *J Prosthet Dent* 48:106–107, 1982.
- Firtell DN, Muncheryan AM, Green AJ: Laboratory accuracy in casting removable partial denture frameworks, *J Prosthet Dent* 54:856–862, 1985.
- Fowler Jr JA, Kuebker WA, Escobedo JJ: Laboratory procedures for the maintenance of a removable partial overdenture, *J Prosthet Dent* 50:121–126, 1983.
- Garver DG: Updated laboratory procedure for the subpontic clasping system, *J Prosthet Dent* 48:734–735, 1982.
- Gay WD: Laboratory procedures for fitting removable partial denture frameworks, *J Prosthet Dent* 40:227–229, 1978.
- Gilson TD, Asgar K, Peyton FA: The quality of union formed in casting gold to embedded attachment metals, *J Prosthet Dent* 15:464–473, 1965.
- Grunewald AH, Paffenbarger GC, Dickson G: Dentist, dental laboratory, and the patient, *J Prosthet Dent* 8:55–60, 1958.
- Grunewald AH, Paffenbarger GC, Dickson G: The effect of molding processes on some properties of denture resins, *J Am Dent Assoc* 44:269–284, 1952.
- Grunewald AH, Paffenbarger GC, Dickson G: The role of the dental technician in a prosthetic service, *Dent Clin North Am* 4:359–370, 1960.
- Hanson JG, et al.: Effect on dimensional accuracy when reattaching fractured lone standing teeth of a cast, *J Prosthet Dent* 47:488–492, 1982.
- Johnson HB: Technique for packing and staining complete or partial denture bases, *J Prosthet Dent* 6:154–159, 1956.
- Jones DW: Thermal analysis and stability of refractory investments, *J Prosthet Dent* 18:234–241, 1967.
- Jordan RD, Turner KA, Taylor TD: Multiple crowns fabricated for an existing removable partial denture, *J Prosthet Dent* 48:102–105, 1982.
- Kazanoglu A, Smith EH: Replacement technique for a broken occlusal rest, *J Prosthet Dent* 48:621–623, 1982.
- Krand M, et al.: Study on the surface of resins that burn without residues in the lost-wax procedure, *J Prosthodont* 5:259–265, Dec 1996.
- Lanier BR, Rudd KD, Strunk RR: Making chromium-cobalt removable partial dentures: a modified technique, *J Prosthet Dent* 25:197–205, 1971.
- Lauciello FR: Technique for remounting removable partial dentures opposing maxillary complete dentures, *J Prosthet Dent* 45:336–340, 1981.
- Mahler DB, Ady AB: The influence of various factors on the effective setting expansion of casting investments, *J Prosthet Dent* 13:365–373, 1963.
- Maxson BB, et al.: Quality assurance for the laboratory aspects of prosthodontic treatment, *J Prosthodont* 6:204–209, 1997.
- May KB, Razzoog ME: Silane to enhance the bond between polymethyl methacrylate and titanium, *J Prosthet Dent* 73:428–431, 1995.
- McCartney JW: The acrylic resin base maxillary removable partial denture: technical considerations, *J Prosthet Dent* 43:467–468, 1980.
- Mohammed H, et al.: Button versus buttonless castings for removable partial denture frameworks, *J Prosthet Dent* 72:433–444, 1994.
- Moreno de Delgado M, Garcia LT, Rudd KD: Camouflaging partial denture clasps, *J Prosthet Dent* 55:656–660, 1986.
- Mori T, et al.: Titanium for removable dentures. I. Laboratory procedures, *J Oral Rehabil* 24:238–341, 1997.
- Morris HF, et al.: The influence of heat treatments on several types of base-metal removable partial denture alloys, *J Prosthet Dent* 41:388–395, 1979.
- NaBadalung DP, et al.: Comparison of bond strengths of denture base resins to nickel-chromium-beryllium removable partial denture alloy, *J Prosthet Dent* 78:566–573, 1997.
- NaBadalung DP, et al.: Effectiveness of adhesive systems for Co-Cr removable partial denture alloy, *J Prosthet Dent* 7:17–25, Mar 1998.
- Nelson DR, et al.: Expediting the fabrication of a nickel-chromium casting, *J Prosthet Dent* 55:400–403, 1986.
- Nelson DR, von Gonten AS, Kelly Jr TW: The cast round RPA clasp, *J Prosthet Dent* 54:307–309, 1985.
- Palmer BL, Coffey KW: Investing and packing removable partial denture bases to minimize vertical processing error, *J Prosthet Dent* 56:123–124, 1986.
- Parr FR, Gardner LK: The removable partial denture design template, *Compendium* 8 594(596):598–600, 1987.
- Perry CK: Transfer base for removable partial dentures, *J Prosthet Dent* 31:582–584, 1974.
- Peyton FA, Anthony DH: Evaluation of dentures processed by different techniques, *J Prosthet Dent* 13:269–281, 1963.
- Quinlivan JT: Fabrication of a simple ball-socket attachment, *J Prosthet Dent* 32:222–225, 1974.
- Radue JT, Unser JW: Constructing stable record bases for removable partial dentures, *J Prosthet Dent* 46:463, 1981.
- Rantanen T, Eerikainen E: Accuracy of the palatal plate of removable partial dentures, and influence of laboratory handling of the investment on the accuracy, *Dent Mater* 2:28–31, 1986.
- Raskin ER: An indirect technique for fabricating a crown under an existing clasp, *J Prosthet Dent* 50:580–581, 1983.
- Ring M: Rest seats in existing crowns, *Dent Lab Rev* 60:24–25, 1985.
- Ryge G, Kozak SF, Fairhurst CW: Porosities in dental gold castings, *J Am Dent Assoc* 54:746–754, 1957.
- Sarnat AE, Klugman RS: A method to record the path of insertion of a removable partial denture, *J Prosthet Dent* 46:222–223, 1981.
- Scandrett FR, Hanson JG, Unsicker RL: Layered silicone rubber technique for flasking removable partial dentures, *J Prosthet Dent* 40:349–350, 1978.
- Schmidt AH: Repairing chrome-cobalt castings, *J Prosthet Dent* 5:385–387, 1955.
- Schmitt SM, Chance DA, Cronin RJ: Refining cast implant-retained restorations by electrical discharge machining, *J Prosthet Dent* 73:280–283, 1995.
- Schneider R: Metals used to fabricate removable partial denture frameworks, *J Dent Technol* 13:35–42, 1996.
- Schneider RL: Adapting ceramometal restorations to existing removable partial dentures, *J Prosthet Dent* 49:279–281, 1983.
- Schneider RL: Custom metal occlusal surfaces for acrylic resin denture teeth, *J Prosthet Dent* 46:98–101, 1981.
- Schwalm CA, LaSpina FY: Fabricating swinglock removable partial denture frameworks, *J Prosthet Dent* 45:216–220, 1981.
- Schwedhelm ER, et al.: Fracture strength of type IV and type V die stone as a function of time, *J Prosthet Dent* 78:554–559, 1997.
- Shay JS, Mattingly SL: Technique for the immediate repair of removable partial denture facings, *J Prosthet Dent* 47:104–106, 1982.

- Smith GP: The responsibility of the dentist toward laboratory procedures in fixed and removable partial denture prostheses, *J Prosthet Dent* 13:295–301, 1963.
- Smith RA: Clasp repair for removable partial dentures, *J Prosthet Dent* 29:231–234, 1973.
- Stade EH, et al.: Influence of fabrication technique on wrought-wire clasp flexibility, *J Prosthet Dent* 54:538–543, 1985.
- Stankewitz CG: Acrylic resin blockout for interim removable partial dentures, *J Prosthet Dent* 40:470–471, 1978.
- Swoope CC, Frank RP: Fabrication procedures. In Clark JW, editor: *Clinical dentistry*, vol. 5. New York, 1976, Harper & Row.
- Sykora O: A new tripoding technique, *J Prosthet Dent* 44:463–464, 1980.
- Sykora O: Removable partial denture design by Canadian laboratories: a retrospective study, *J Can Dent Assoc* 61:615–621, 1995.
- Tambasco J, et al.: Laser welding in the dental laboratory: an alternative to soldering, *J Dent Technol* 13:23–31, May 1996.
- Teppo KW, Smith FW: A method of immediate clasp repair, *J Prosthet Dent* 30:77–80, 1975.
- Tran CD, Sherraden DR, Curtis TA: A review of techniques of crown fabrication for existing removable partial dentures, *J Prosthet Dent* 55:671–673, 1986.
- Tuccillo JJ, Nielsen JP: Compatibility of alginate impression materials and dental stones, *J Prosthet Dent* 25:556–566, 1971.
- Ulmer FC, Ward JE: Simplified technique for production of a distal-extension removable partial denture remounting cast, *J Prosthet Dent* 41:473–474, 1979.
- von Gonten AS, Nelson DR: Laboratory pitfalls that contribute to embrasure clasp failure, *J Prosthet Dent* 53:136–138, 1985.
- Williams HN, Falkler Jr WA, Hasler JF: Acinetobacter contamination of laboratory dental pumice, *J Dent Res* 62:1073–1075, 1983.
- Zalkind M, Avital R, Rehany A: Fabrication of a replacement for a broken attachment, *J Prosthet Dent* 51:714–716, 1984.
- Payne AGL: Factors influencing the position of artificial upper anterior teeth, *J Prosthet Dent* 26:26–32, 1971.
- Pound E: Applying harmony in selecting and arranging teeth, *Dent Clin North Am* 6:241–258, 1962.
- Pound E: Lost—fine arts in the fallacy of the ridges, *J Prosthet Dent* 4:6–16, 1954.
- Pound E: Recapturing esthetic tooth position in the edentulous patient, *J Am Dent Assoc* 55:181–191, 1957.
- Roraff AR: Instant photographs for developing esthetics, *J Prosthet Dent* 26:21–25, 1971.
- Smith BJ: Esthetic factors in removable partial prosthodontics, *Dent Clin North Am* 23:53–63, 1979.
- Sykora O: Fabrication of a posterior shade guide for removable partial dentures, *J Prosthet Dent* 50:287–288, 1983.
- Tillman EJ: Molding and staining acrylic resin anterior teeth, *J Prosthet Dent* 5:497–507, 1955. *Dent Abstr* 1:111, 1956.
- Van Victor A: The mold guide cast: its significance in denture esthetics, *J Prosthet Dent* 13:406–415, 1963.
- Van Victor A: Positive duplication of anterior teeth for immediate dentures, *J Prosthet Dent* 3:165–177, 1953.
- Vig RG: The denture look, *J Prosthet Dent* 11:9–15, 1961.
- Wallace DH: The use of gold occlusal surfaces in complete and partial dentures, *J Prosthet Dent* 14:326–333, 1964.
- Weiner S, Krause AS, Nicholas W: Esthetic modification of removable partial denture teeth with light-cured composites, *J Prosthet Dent* 57:381–384, 1987.
- Wolfson E: Staining and characterization of acrylic teeth, *Dent Abstr* 1:41, 1956.
- Young HA: Denture esthetics, *J Prosthet Dent* 6:748–755, 1956.
- Zarb GA, MacKay HF: Cosmetics and removable partial dentures: the Class IV partially edentulous patient, *J Prosthet Dent* 46:360–368, 1981.

## DENTURE ESTHETICS: TOOTH SELECTION AND ARRANGEMENT

- Askinas SW: Facings in removable partial dentures, *J Prosthet Dent* 33:633–636, 1975.
- Culpepper WD: A comparative study of shade-matching procedures, *J Prosthet Dent* 24:166–173, 1971.
- DeVan MM: The appearance phase of denture construction, *Dent Clin North Am* 1:255–268, 1957.
- Engelmeier RL: Complete-denture esthetics, *Dent Clin North Am* 40:71–84, 1996.
- Fields Jr H, Birtles JT, Shay J: Combination prosthesis for optimum esthetic appearance, *J Am Dent Assoc* 101:276–279, 1980.
- French FA: The selection and arrangement of the anterior teeth in prosthetic dentures, *J Prosthet Dent* 1:587–593, 1951.
- Frush JP, Fisher RD: How dentogenic restorations interpret the sex factor, *J Prosthet Dent* 6:160–172, 1956.
- Frush JP, Fisher RD: How dentogenics interprets the personality factor, *J Prosthet Dent* 6:441–449, 1956.
- Frush JP, Fisher RD: Introduction to dentogenic restorations, *J Prosthet Dent* 5:586–595, 1955.
- Hughes GA: Facial types and tooth arrangement, *J Prosthet Dent* 1:82–95, 1951.
- Krajicek DD: Natural appearance for the individual denture patient, *J Prosthet Dent* 10:205–214, 1960.
- Lang BR: Complete denture occlusion, *Dent Clin North Am* 40:85–101, 1996.
- Levin EI: Dental esthetics and the golden proportion, *J Prosthet Dent* 40:244–252, 1978.
- Lombardi RE: Factors mediating against excellence in dental esthetics, *J Prosthet Dent* 38:243–248, 1977.
- Myerson RL: The use of porcelain and plastic teeth in opposing complete dentures, *J Prosthet Dent* 7:625–633, 1957.

## DIAGNOSIS AND TREATMENT PLANNING

- Academy of Prosthodontics: Principles, concepts and practices in prosthodontics, *J Prosthet Dent* 73:73–94, 1995.
- Applegate OC: Evaluating oral structures for removable partial dentures, *J Prosthet Dent* 11:882–885, 1961.
- Bartels JC: Diagnosis and treatment planning, *J Prosthet Dent* 7:657–662, 1957.
- Beaumont AJ: An overview of esthetics with removable partial dentures, *Quintessence Int* 33:745–755, 2002.
- Bezzon OL, et al.: Surveying removable partial dentures: the importance of guiding planes and path of insertion for stability, *J Prosthet Dent* 78:412–418, 1997.
- Blatterfein L, Kaufman EG: Prevention of problems with removable partial dentures: Council on Dental Materials, Instruments, and Equipment, *J Am Dent Assoc* 100:919–921, 1980.
- Bolender CL, Swenson RD, Yamane C: Evaluation of treatment of inflammatory papillary hyperplasia of the palate, *J Prosthet Dent* 15:1013–1022, 1965.
- Budtz-Jorgensen E: Restoration of the partially edentulous mouth: a comparison of overdentures, removable partial dentures, fixed partial dentures and implant treatment, *J Dent* 24:237–244, July 1996.
- Casey DM, Lauciello FR: A review of the submerged-root concept, *J Prosthet Dent* 43:128–132, 1980.
- Contino RM, Stallard H: Instruments essential for obtaining data needed in making a functional diagnosis of the human mouth, *J Prosthet Dent* 7:66–77, 1957.
- Dreizen S: Nutritional changes in the oral cavity, *J Prosthet Dent* 16:1144–1150, 1966.
- Dummer PMH, Cidden J: The upper anterior sectional denture, *J Prosthet Dent* 41:146–152, 1979.
- Dunn BW: Treatment planning for removable partial dentures, *J Prosthet Dent* 11:247–255, 1961.

Faine MP: Dietary factors related to preservation of oral and skeletal bone mass in women, *J Prosthet Dent* 73:65–72, 1995.

Foster TD: The use of the face-bow in making permanent study casts, *J Prosthet Dent* 9:717–721, 1959.

Frechette AR: Partial denture planning with special reference to stress distribution, *J Prosthet Dent* 1:700–707, (disc, 208–209), 1951.

Friedman S: Effective use of diagnostic data, *J Prosthet Dent* 9:729–737, 1959.

Garver DC, et al.: Vital root retention in humans: a preliminary report, *J Prosthet Dent* 40:23–28, 1978.

Garver DC, Fenster RK: Vital root retention in humans: a final report, *J Prosthet Dent* 43:368–373, 1980.

Guyer SE: Selectively retained vital roots for partial support of overdentures: a patient report, *J Prosthet Dent* 33:258–263, 1975.

Harvey WL: A transitional prosthetic appliance, *J Prosthet Dent* 14: 60–70, 1964.

Heintz WD: Treatment planning and design: prevention of errors of omission and commission, *Dent Clin North Am* 23:3–12, 1979.

Henderson D, Hickey JC, Wehner PJ: Prevention and preservation: the challenge of removable partial denture service, *Dent Clin North Am* 9:459–473, 1965.

House MM: The relationship of oral examination to dental diagnosis, *J Prosthet Dent* 8:208–219, 1958.

Kabacell JL: Planning for individualized prosthetic treatment, *J Prosthet Dent* 34:405–407, 1975.

Kaldahl WB, Becher CM: Prosthetic contingencies for future tooth loss, *J Prosthet Dent* 54:1–6, 1985.

Kanno T, Carlsson GE: A review of the shortened dental arch concept focusing on the work by the Käyser/Nijmegen group, *J Oral Rehabil* 33:850–862, 2006.

Kayser AF: Limited treatment goals: shortened dental arches, *Periodontol* 2000, 4:7–14, 1994.

Killebrew RF: Crown construction and splinting of mobile partial denture abutments, *J Am Dent Assoc* 70:334–338, 1965.

Krikos AA: Preparing guide planes for removable partial dentures, *J Prosthet Dent* 34:152–155, 1975.

Lambson GO: Papillary hyperplasia of the palate, *J Prosthet Dent* 16:636–645, 1966.

Langer Y, et al.: Modalities of treatment for the combination syndrome, *J Prosthodont* 4:76–81, June 1995.

Lopes I, Norlau LA: Specific mechanics for abutment uprighing, *Aust Dent J* 25:273–278, 1980.

McCracken WL: Differential diagnosis: fixed or removable partial dentures, *J Am Dent Assoc* 63:767–775, 1961.

McGill WJ: Acquiring space for partial dentures, *J Prosthet Dent* 17:163–165, 1967.

Miller EL: Critical factors in selecting removable prosthesis, *J Prosthet Dent* 34:486–490, 1975.

Miller EL: Planning partial denture construction, *Dent Clin North Am* 17:571–584, 1973.

Mopsik ER, et al.: Surgical intervention to reestablish adequate intermaxillary space before fixed or removable prosthodontics, *J Am Dent Assoc* 95:957–960, 1977.

Moulton GH: The importance of centric occlusion in diagnosis and treatment planning, *J Prosthet Dent* 10:921–926, 1960.

Nassif J, Blumenfeld WL: Joint consultation services by the periodontist and prosthodontist, *J Prosthet Dent* 29:55–60, 1973.

Nassif J, Blumenfeld WL, Tarsitano JT: Dialogue—a treatment modality, *J Prosthet Dent* 33:696–700, 1975.

Payne SH: Diagnostic factors which influence the choice of posterior occlusion, *Dent Clin North Am* 1:203–213, 1957.

Rudd KD, Dunn BW: Accurate removable partial dentures, *J Prosthet Dent* 18:559–570, 1967.

Saunders TR, Gillis RE, Desjardins RP: The maxillary complete denture opposing the mandibular bilateral distal-extension partial denture: treatment considerations, *J Prosthet Dent* 41:124–128, 1979.

Sauser CW: Pretreatment evaluation of partially edentulous arches, *J Prosthet Dent* 11:886–893, 1961.

Seiden A: Occlusal rests and rest seats, *J Prosthet Dent* 8:431–440, 1958.

Silverman SI: Differential diagnosis: fixed or removable prosthesis, *Dent Clin North Am* 31:347–362, 1987.

Swoope CC, Frank RP: Removable partial dentures indications and planning. In Clark JE, editor: *Clinical dentistry*, vol. 5. New York, 1976, Harper & Row.

Turner CE, Shaffer FW: Planning the treatment of the complex prosthodontic case, *J Am Dent Assoc* 97:992–993, 1978.

Uccellani EL: Evaluating the mucous membranes of the edentulous mouth, *J Prosthet Dent* 15:295–303, 1965.

Vahidi F: The provisional restoration, *Dent Clin North Am* 31:363–381, 1987.

Wagner AG: Instructions for the use and care of removable partial dentures, *J Prosthet Dent* 26:481–490, 1971.

Waldron CA: Oral leukoplakia, carcinoma, and the prosthodontist, *J Prosthet Dent* 15:367–376, 1965.

Welker WA, Kramer DC: Claspless chrome-cobalt transitional removable partial dentures, *J Am Dent Assoc* 96:814–818, 1978.

Wöstmann B, et al.: Indications for removable partial dentures: a literature review, *Int J Prosthodont* 18:139–145, 2005.

Wright P, Hellyer PH: Gingival recession related to removable partial dentures in older patients, *J Prosthet Dent* 74:602–607, 1995.

Young HA: Diagnostic survey of edentulous patients, *J Prosthet Dent* 5:5–14, 1955.

IMPLANTS AND REMOVABLE PARTIAL DENTURES

Grossmann Y, Levin L, Sadan A: A retrospective case series of implants used to restore partially edentulous patients with implant-supported removable partial dentures: 31-month mean follow-up results, *Quintessence Int* 39:665–671, 2008.

Grossmann Y, Nissan J, Levin L: Clinical effectiveness of implant-supported removable partial dentures: a review of the literature and retrospective case evaluation, *J Oral Maxillofac Surg* 67:1941–1946, 2009.

Kaufmann R, et al.: Removable dentures with implant support in strategic positions followed for up to 8 years, *Int J Prosthodont* 22: 233–241, 2009.

Mijiritsky E: Implants in conjunction with removable partial dentures: a literature review, *Implant Dent* 16:146–154, 2007.

Mijiritsky E, et al.: Implant tooth-supported removable partial denture with at least 15-year long-term follow-up, *Clin Implant Dent Relat Res*, 2013. <http://dx.doi.org/10.1111/cid.12190>.

Strassburger C, Kerschbaum T, Heydecke G: Influence of implant and conventional prostheses on satisfaction and quality of life: a literature review. Part 2. Qualitative analysis and evaluation of the studies, *Int J Prosthodont* 19:339–348, 2006.

IMPRESSION MATERIALS AND METHODS: THE PARTIAL DENTURE BASE

Akerly WB: A combination impression and occlusal registration technique for extension-base removable partial dentures, *J Prosthet Dent* 39:226–229, 1978.

Appleby DC, et al.: The combined reversible hydrocolloid/irreversible hydrocolloid impression system: clinical application, *J Prosthet Dent* 46:48–58, 1981.

Applegate OC: An evaluation of the support for the removable partial denture, *J Prosthet Dent* 10:112–123, 1960.

Applegate OC: The partial denture base, *J Prosthet Dent* 5:636–648, 1955.

Bailey LR: Rubber base impression techniques, *Dent Clin North Am* 1:156–166, 1957.

Bauman R, DeBoer J: A modification of the altered cast technique, *J Prosthet Dent* 47:212–213, 1982.

- Baumont AJ: Sectional impression for maxillary Class I removable partial dentures and maxillary immediate dentures, *J Prosthet Dent* 49:438–441, 1983.
- Berkey D, Berg R: Geriatric oral health issues in the United States, *Int Dent J* 51:254–264, 2001.
- Beyerle MP, et al.: Immersion disinfection of irreversible hydrocolloid impressions. Part I. Microbiology, *Int J Prosthodont* 7:234–238, May 1994.
- Birnbach S: Impression technique for maxillary removable partial dentures, *J Prosthet Dent* 51:286, 1984.
- Blatterfein L, Klein IE, Miglino JC: A loading impression technique for semiprecision and precision removable partial dentures, *J Prosthet Dent* 43:9–14, 1980.
- Boretti G, Bickel M, Geering AH: A review of masticatory ability and efficiency, *J Prosthet Dent* 74:400–403, 1995.
- Carlsson GE: Masticatory efficiency: the effect of age, the loss of teeth and prosthetic rehabilitation, *Int Dent J* 34:93–97, 1984.
- Chaffee NR, et al.: Dimensional accuracy of improved dental stone and epoxy resin die materials. Part I. Single die, *J Prosthet Dent* 77:131–135, 1997.
- Chaffee NR, et al.: Dimensional accuracy of improved dental stone and epoxy resin die materials. Part II. Complete arch form, *J Prosthet Dent* 77:235–238, 1997.
- Chai J, et al.: Clinically relevant mechanical properties of elastomeric impression materials, *Int J Prosthodont* 11:219–223, 1998.
- Chase WW: Adaptation of rubber-base impression materials to removable denture prosthetics, *J Prosthet Dent* 10:1043–1050, 1960.
- Chau VB, et al.: In-depth disinfection of acrylic resin, *J Prosthet Dent* 74:309–313, 1995.
- Chen MS, et al.: An altered-cast impression technique that eliminates conventional cast dissecting and impression boxing, *J Prosthet Dent* 57:471–474, 1987.
- Cho GC, et al.: Tensile bond strength of polyvinyl siloxane impressions bonded to a custom tray as a function of drying time, Part I, *J Prosthet Dent* 73:419–423, 1995.
- Chong MP, et al.: The tear test as a means of evaluating the resistance to rupture of alginate impression materials, *Aust Dent J* 16:145–151, 1971.
- Clark RJ, Phillips RW: Flow studies of certain dental impression materials, *J Prosthet Dent* 7:259–266, 1957.
- Cohen BI, et al.: Dimensional accuracy of three different alginate impression materials, *J Prosthodont* 4:195–199, 1995.
- Corso M, et al.: The effect of temperature changes on the dimensional stability of polyvinyl siloxane and polyether impression materials, *J Prosthet Dent* 79:626–631, 1998.
- Cserna A, et al.: Irreversible hydrocolloids: a comparison of antimicrobial efficacy, *J Prosthet Dent* 71:387–389, 1994.
- Davidson CL, Boere G: Liquid-supported dentures. Part I. Theoretical and technical considerations, *J Prosthet Dent* 68:303–306, 1990.
- Davidson CL, Boere G: Liquid-supported dentures. Part II. Clinical study: a preliminary report, *J Prosthet Dent* 68:434–436, 1990.
- Davis BA, et al.: Effect of immersion disinfection on properties of impression materials, *J Prosthodont* 3:31–34, 1994.
- DeFreitas JF: Potential toxicants in alginate powders, *Aust Dent J* 25:224–228, 1980.
- Dixon DL, Breeding LC, Ekstrand KG: Linear dimensional variability of three denture base resins after processing and in water storage, *J Prosthet Dent* 68:196–200, 1992.
- Dixon DL, Ekstrand KG, Breeding LC: The transverse strengths of three denture base resins, *J Prosthet Dent* 66:510–513, 1991.
- Dootz ER: Fabricating non-precious metal bases, *Dent Clin North Am* 24:113–122, 1980.
- Dootz ER, Craig RG: Comparison of the physical properties of eleven soft denture liners, *J Prosthet Dent* 67:707–712, 1992.
- Douglas CW, Shih A, Ostry L: Will there be a need for complete dentures in the United States in 2020? *J Prosthet Dent* 87:5–8, 2002.
- Douglas CW, Watson AJ: Future needs for fixed and removable partial dentures in the United States, *J Prosthet Dent* 87:9–14, 2002.
- Drennon DG, Johnson GH: The effect of immersion disinfection of elastomeric impressions on the surface detail reproduction of improved gypsum casts, *J Prosthet Dent* 63:233–241, 1990.
- Fitzloff RA: Functional impressions with thermoplastic materials for relining procedures, *J Prosthet Dent* 52:25–27, 1984.
- Frank RP: Analysis of pressures produced during maxillary edentulous impression procedures, *J Prosthet Dent* 22:400–403, 1969.
- Fusayama T, Nakazato M: The design of stock trays and the retention of irreversible hydrocolloid impressions, *J Prosthet Dent* 21:136–142, 1969.
- Gelbard S, et al.: Effect of impression materials and techniques on the marginal fit of metal castings, *J Prosthet Dent* 71:1–6, 1994.
- Gilmore WH, Schnell RJ, Phillips RW: Factors influencing the accuracy of silicone impression materials, *J Prosthet Dent* 9:304–314, 1959.
- Hans S, Gunne J: Masticatory efficiency and dental state: a comparison between two methods, *Acta Odont Scand* 43:139–146, 1985.
- Harris Jr WT: Water temperature and accuracy of alginate impressions, *J Prosthet Dent* 21:613–617, 1969.
- Harrison JD: Prevention of failures in making impressions and dies, *Dent Clin North Am* 23:13–20, 1979.
- Heartwell Jr CM, et al.: Comparison of impressions made in perforated and nonperforated rimlock trays, *J Prosthet Dent* 27:494–500, 1972.
- Helkimo E, Carlsson GE, Helkimo M: Chewing efficiency and state of the dentition, *Acta Odont Scand* 36:33–41, 1978.
- Herfort TW, et al.: Viscosity of elastomeric impression materials, *J Prosthet Dent* 38:396–404, 1977.
- Hesby RM, et al.: Effects of radiofrequency glow discharge on impression material surface wettability, *J Prosthet Dent* 77:414–422, 1997.
- Holmes JB: Influence of impression procedures and occlusal loading on partial denture movement, *J Prosthet Dent* 15:474–481, 1965.
- Hondrum SO, et al.: Effects of long-term storage on properties of an alginate impression material, *J Prosthet Dent* 77:601–606, 1997.
- Hudson WC: Clinical uses of rubber impression materials and electroforming of casts and dies in pure silver, *J Prosthet Dent* 8:107–114, 1958.
- Huggett R, et al.: Dimensional accuracy and stability of acrylic resin denture bases, *J Prosthet Dent* 68:634–640, 1992.
- Iglesias A, et al.: Accuracy of wax, autopolymerized, and light-polymerized resin pattern materials, *J Prosthodont* 5:193–200, 1996.
- Ivanovski S, et al.: Disinfection of dental stone casts: antimicrobial effects and physical property alterations, *Dent Mater* 11:19–23, 1995.
- James JS: A simplified alternative to the altered-cast impression technique for removable partial dentures, *J Prosthet Dent* 53:598, 1985.
- Jasim FA, Brudvik JS, Nicholls JJ: Impression distortion from abutment tooth inclination in removable partial dentures, *J Prosthet Dent* 54:532–538, 1985.
- Johnson GH, et al.: Dimensional stability and detail reproduction of irreversible hydrocolloid and elastomeric impressions disinfected by immersion, *J Prosthet Dent* 79:446–453, 1998.
- Johnston JF, Cunningham DM, Bogan RG: The dentist, the patient, and ridge preservation, *J Prosthet Dent* 10:288–295, 1960.
- Jones RH, et al.: Effect of provisional luting agents on polyvinyl siloxane impression materials, *J Prosthet Dent* 75:360–363, 1996.
- Kawamura Y: Recent concepts of the physiology of mastication, *Adv Oral Biol* 1:77–109, 1964.
- Kawano F, et al.: Comparison of bond strength of six soft denture liners to denture base resin, *J Prosthet Dent* 68:368–371, 1992.
- Koran III A: Impression materials for recording the denture bearing mucosa, *Dent Clin North Am* 24:97–111, 1980.
- Kramer HM: Impression technique for removable partial dentures, *J Prosthet Dent* 11:84–92, 1961.
- Landesman HM, Wright WE: A technique for making impressions on patients requiring complete and removable partial dentures, *CDA J* 14:20–24, 1986.

- Langenwalter EM, Aquilino SA: The dimensional stability of elastomeric impression materials following disinfection, *J Prosthet Dent* 63:270–276, 1990.
- Leach CD, Donovan TE: Impression technique for maxillary removable partial dentures, *J Prosthet Dent* 50:283–286, 1983.
- Leake JL, Hawkins R, Locker D: Social and functional impact of reduced posterior dental units in older adults, *J Oral Rehab* 21:1–10, 1994.
- Lee IK, et al.: Evaluation of factors affecting the accuracy of impressions using quantitative surface analysis, *Oper Dent* 20:246–252, 1995.
- Lee RE: Mucostatics, *Dent Clin North Am* 24:81–96, 1980.
- Lepe X, et al.: Accuracy of polyether and addition silicone after long-term immersion disinfection, *J Prosthet Dent* 78:245–249, 1997.
- Leupold RJ: A comparative study of impression procedures for distal extension removable partial dentures, *J Prosthet Dent* 16:708–720, 1966.
- Leupold RJ, Flinton RJ, Pfeifer DL: Comparison of vertical movement occurring during loading of distal-extension removable partial denture bases made by three impression techniques, *J Prosthet Dent* 68:290–293, 1992.
- Leupold RJ, Kratochvil FJ: An altered-cast procedure to improve support for removable partial dentures, *J Prosthet Dent* 15:672–678, 1965.
- Liedberg B, Spiechowicz E, Owall B: Mastication with and without removable partial dentures: an intraindividual study, *Dysphagia* 10:107–112, 1995.
- Loh PL, et al.: An evaluation of microwave-polymerized resin bases for removable partial dentures, *J Prosthet Dent* 79:389–392, 1998.
- Lucas W, Luke H: The processes of selection and breakage in mastication, *Arch Oral Biol* 28:813–818, 1983.
- Lund PS, Aquilino SA: Prefabricated custom impression trays for the altered cast technique, *J Prosthet Dent* 66:782–783, 1991.
- Manly RS, Vinton P: A survey of the chewing ability of denture wearers, *J Dent Res* 30:314–321, 1951.
- Matís BA, et al.: The effect of the use of dental gloves on mixing vinyl polysiloxane putties, *J Prosthodont* 6:189–192, 1997.
- Millar BJ, et al.: The effect of surface wetting agent on void formation in impressions, *J Prosthet Dent* 77:54–56, 1997.
- Millar BJ, et al.: In vitro study of the number of surface defects in monophasic and two-phase addition silicone impressions, *J Prosthet Dent* 80:32–35, 1998.
- Mitchell JV, Damele JJ: Influence of tray design upon elastic impression materials, *J Prosthet Dent* 23:51–57, 1970.
- Mitchener RW, Omori MD: Putty materials for stable removable partial denture bases, *J Prosthet Dent* 53:435–436, 1985.
- Morrow RM, et al.: Compatibility of alginate impression materials and dental stones, *J Prosthet Dent* 25:556–566, 1971.
- Myers GE: Electroformed die technique for rubber base impressions, *J Prosthet Dent* 8:531–535, 1958.
- Myers GE, Wepfer GG, Peyton FA: The Thiokol rubber base impression materials, *J Prosthet Dent* 8:330–339, 1958.
- Nishigawa G, et al.: Efficacy of tray adhesives for the adhesion of elastomer rubber impression materials to impression modeling plastics for border molding, *J Prosthet Dent* 79:140–144, 1998.
- O'Brien WJ: Base retention, *Dent Clin North Am* 24:123–130, 1980.
- Olin PS, et al.: The effects of sterilization on addition silicone impressions in custom and stock metal trays, *J Prosthet Dent* 71:625–630, 1994.
- Oosterhaven SP, et al.: Social and psychological implications of missing teeth for chewing ability, *Comm Dent Oral Epid* 16:79–82, 1988.
- Parker MH, et al.: Comparison of occlusal contacts in maximum intercuspation for two impression techniques, *J Prosthet Dent* 78:255–259, 1997.
- Pfeiffer KA: Clinical problems in the use of alginate hydrocolloid, *Dent Abstr* 2:82, 1957.
- Phillips RW: Factors affecting the surface of stone dies poured in hydrocolloid impressions, *J Prosthet Dent* 2:390–400, 1952.
- Phillips RW: Factors influencing the accuracy of reversible hydrocolloid impressions, *J Am Dent Assoc* 43:1–17, 1951.
- Phillips RW: Physical properties and manipulation of rubber impression materials, *J Am Dent Assoc* 59:454–458, 1959.
- Pratten DH, Covey DA, Sheats RD: Effect of disinfectant solutions on the wettability of elastomeric impression materials, *J Prosthet Dent* 63:223–227, 1990.
- Prieskel HW: Impression techniques for attachment retained distal extension removable partial dentures, *J Prosthet Dent* 25:620–628, 1971.
- Prinz JF, Lucas PW: Swallow thresholds in human mastication, *Arch Oral Biol* 40:401–403, 1995.
- Rapuano JA: Single tray dual-impression technique for distal extension partial dentures, *J Prosthet Dent* 24:41–46, 1970.
- Redford M, et al.: Denture use and the technical quality of dental prostheses among persons 18–74 years of age: United States, 1988–1991, *J Dent Res* 75:714–725, 1996.
- Render PJ: An impression technique to make a new master cast for an existing removable partial denture, *J Prosthet Dent* 67:488–490, 1992.
- Rudd KD, et al.: Comparison of effects of tap water and slurry water on gypsum casts, *J Prosthet Dent* 24:563–570, 1970.
- Rudd KD, Morrow RM, Bange AA: Accurate casts, *J Prosthet Dent* 21:545–554, 1969.
- Rudd KD, Morrow RM, Strunk RR: Accurate alginate impressions, *J Prosthet Dent* 22:294–300, 1969.
- Samadzadeh A, et al.: Fracture strength of provisional restorations reinforced with plasma-treated woven polyethylene fiber, *J Prosthet Dent* 5:447–450, 1997.
- Scott GK, et al.: Check bite impressions using irreversible alginate/reversible hydrocolloid combination, *J Prosthet Dent* 77:83–85, 1997.
- Sherfudhin H, et al.: Preparation of void-free casts from vinyl polysiloxane impressions, *J Dent* 24:95–98, 1996.
- Silver M: Impressions and silver-plated dies from a rubber impression material, *J Prosthet Dent* 6:543–549, 1956.
- Smith RA: Secondary palatal impressions for major connector adaptation, *J Prosthet Dent* 24:108–110, 1970.
- Steffel VL: Relining removable partial dentures for fit and function, *J Prosthet Dent* 4:496–509, 1954; *J Tenn Dent Assoc* 36:35–43, 1956.
- Taylor TD, Morton Jr TJ: Ulcerative lesions of the palate associated with removable partial denture castings, *J Prosthet Dent* 66:213–221, 1991.
- Thompson GA, et al.: Effects of disinfection of custom tray materials on adhesive properties of several impression material systems, *J Prosthet Dent* 72:651–656, 1994.
- Tjan AH, et al.: Marginal fidelity of crowns fabricated from six proprietary provisional materials, *J Prosthet Dent* 77:482–485, 1997.
- Vahidi F: Vertical displacement of distal-extension ridges by different impression techniques, *J Prosthet Dent* 40:374–377, 1978.
- van Waas M, et al.: Relationship between wearing a removable partial denture and satisfaction in the elderly, *Comm Dent Oral Epid* 22:315–318, 1994.
- Vandewalle KS, et al.: Immersion disinfection of irreversible hydrocolloid impressions with sodium hypochlorite. Part II. Effect on gypsum, *Int J Prosthodont* 7:315–322, 1994.
- Verran J, et al.: Microbiological study of selected risk areas in dental technology laboratories, *J Dent* 24:77–80, 1996.
- Wang HY, et al.: Vertical distortion on distal extension ridges and palatal area of casts made by different techniques, *J Prosthet Dent* 75:302–308, 1996.
- Wang RR, Nguyen T, Boyle AM: The effect of tray material and surface condition on the shear bond strength of impression materials, *J Prosthet Dent* 74:449–454, 1995.
- Wilson JH: Partial dentures: relining the saddle supported by the mucosa and alveolar bone, *J Prosthet Dent* 3:807–813, 1953.
- Young JM: Surface characteristics of dental stone: impression orientation, *J Prosthet Dent* 33:336–341, 1975.
- Yurkstas AA: The masticatory act, *J Prosthet Dent* 15:248–260, 1965.

Zinner ID: Impression procedures for the removable component of a combination fixed and removable prosthesis, *Dent Clin North Am* 31:417–440, 1987.

## MAXILLOFACIAL PROSTHESIS

- Ackerman AJ: Maxillofacial prosthesis, *Oral Surg* 6:176–200, 1953.
- Ackerman AJ: The prosthetic management of oral and facial defects following cancer surgery, *J Prosthet Dent* 5:413–432, 1955.
- Adams D: A cantilevered swinglock removable partial denture design for the treatment of the partial mandibulectomy patient, *J Oral Rehabil* 12:113–118, 1985.
- Brown KE: Fabrication of a hollow-bulb obturator, *J Prosthet Dent* 21:97–103, 1969.
- Brown KE: Reconstruction considerations for severe dental attrition, *J Prosthet Dent* 44:384–388, 1980.
- Cantor R, et al.: Methods for evaluating prosthetic facial materials, *J Prosthet Dent* 21:324–332, 1969.
- Curtis TA, Cantor R: The forgotten patient in maxillofacial prosthetics, *J Prosthet Dent* 31:662–680, 1974.
- Desjardins RP: Prosthodontic management of the cleft palate patient, *J Prosthet Dent* 33:655–665, 1975.
- Firtell DN, Curtis TA: Removable partial denture design for the mandibular resection patient, *J Prosthet Dent* 48:437–443, 1982.
- Firtell DN, Grisius RJ: Retention of obturator: removable partial dentures: a comparison of buccal and lingual retention, *J Prosthet Dent* 43:211–217, 1980.
- Gay WD, King GE: Applying basic prosthodontic principles in the dentulous maxillectomy patient, *J Prosthet Dent* 43:433–435, 1980.
- Goll G: Design for maximal retention of obturator prosthesis for hemimaxillectomy patients (letter), *J Prosthet Dent* 48:108–109, 1982.
- Immekus JE, Aramy M: Adverse effects of resilient denture liners in overlay dentures, *J Prosthet Dent* 32:178–181, 1974.
- Kelley EK: Partial denture design applicable to the maxillofacial patient, *J Prosthet Dent* 15:168–173, 1965.
- King GE, Martin JW: Cast circumferential and wire clasps for obturator retention, *J Prosthet Dent* 49:799–802, 1983.
- Metz HH: Mandibular staple implant for an atrophic mandibular ridge: solving retention difficulties of a denture, *J Prosthet Dent* 32:572–578, 1974.
- Monteith GG: The partially edentulous patient with special problems, *Dent Clin North Am* 23:107–115, 1979.
- Moore DJ: Cervical esophagus prosthesis, *J Prosthet Dent* 30:442–445, 1973.
- Myers RE, Mitchell DL: A photoelastic study of stress induced by framework design in a maxillary resection, *J Prosthet Dent* 61:590–594, 1989.
- Nethery WJ, Delclos L: Prosthetic stent for gold-grain implant to the floor of the mouth, *J Prosthet Dent* 23:81–87, 1970.
- Shifman A, Lepley JB: Prosthodontic management of postsurgical soft tissue deformities associated with marginal mandibulectomy. Part I. Loss of the vestibule, *J Prosthet Dent* 48:178–183, 1982.
- Smith Jr EH: Prosthetic treatment of maxillofacial injuries, *J Prosthet Dent* 5:112–128, 1955.
- Strain JC: A mechanical device for duplicating a mirror image of a cast or mouldage in three dimensions, *J Prosthet Dent* 5:129–132, 1955.
- Toremalm NG: A disposable obturator for maxillary defects, *J Prosthet Dent* 29:94–96, 1973.
- Weintraub GS, Yalisove IL: Prosthodontic therapy for cleidocranial dysostosis: report of case, *J Am Dent Assoc* 96:301–305, 1978.
- Wright SM, Pullen-Warner EA, LeTissier DR: Design for maximal retention of obturator prosthesis for hemimaxillectomy patients, *J Prosthet Dent* 47:88–91, 1982.
- Young JM: The prosthodontist's role in total treatment of patients, *J Prosthet Dent* 27:399–412, 1972.

## MISCELLANEOUS

- Abere DJ: Post-placement care of complete and removable partial dentures, *Dent Clin North Am* 23:143–151, 1979.
- Academy of Denture Prosthetics: Principles, concepts and practices in prosthodontics, *J Prosthet Dent* 61:88–109, 1989.
- Adisman IK: What a prosthodontist should know, *J Prosthet Dent* 21:409–416, 1969.
- American Association of Dental Schools: Curricular guidelines for removable prosthodontics, *J Dent Educ* 44:343–346, 1980.
- Applegate OC: Conditions which may influence the choice of partial or complete denture service, *J Prosthet Dent* 7:182–196, 1957.
- Applegate OC: Factors to be considered in choosing an alloy, *Dent Clin North Am* 4:583–590, 1960.
- Asgar K, Techow BO, Jacobson JM: A new alloy for partial dentures, *J Prosthet Dent* 23:36–43, 1970.
- Atwood DA: Practice of prosthodontics: past, present, and future, *J Prosthet Dent* 21:393–401, 1970.
- Augsburger RH: Evaluating removable partial dentures by mathematical equations, *J Prosthet Dent* 22:528–543, 1969.
- Backenstose WM, Wells JG: Side effects of immersion-type cleansers on the metal components of dentures, *J Prosthet Dent* 37:615–621, 1977.
- Baker CR: Difficulties in evaluating removable partial dentures, *J Prosthet Dent* 17:60–62, 1967.
- Baker CR: Occlusal reactive prosthodontics, *J Prosthet Dent* 17:566–569, 1967.
- Barrett DA, Pilling LO: The restoration of carious clasp-bearing teeth, *J Prosthet Dent* 15:309–311, 1965.
- Bates JF: Studies related to fracture of partial dentures, *Br Dent J* 120:79–83, 1966.
- Beck HO: Alloys for removable partial dentures, *Dent Clin North Am* 4:591–596, 1960.
- Beck HO: A clinical evaluation of the arcon concept of articulation, *J Prosthet Dent* 9:409–421, 1959.
- Beck HO, Morrison WE: Investigation of an arcon articulator, *J Prosthet Dent* 6:359–372, 1956.
- Becker CM, Bolender CL: Designing swinglock partial dentures, *J Prosthet Dent* 46:126–132, 1981.
- Bergman B, Hugoson A, Olsson CO: Caries, periodontal and prosthetic findings in patients with removable partial dentures: a ten-year longitudinal study, *J Prosthet Dent* 48:506–514, 1982.
- Blanco-Dalmau L: The nickel problem, *J Prosthet Dent* 48:99–101, 1982.
- Blatterfein L, Pearce RL, Jackota JT: Minimum acceptable procedures for satisfactory removable partial denture service, *J Prosthet Dent* 27:84–87, 1972.
- Bolender CL, Becker CM: Swinglock removable partial dentures: where and when, *J Prosthet Dent* 45:4–10, 1981.
- Boucher CO: Writing as a means for learning, *J Prosthet Dent* 27:229–234, 1972.
- Budtz-Jorgensen E, Isidor F: Cantilever bridges or removable partial dentures in geriatric patients: a two-year study, *J Oral Rehabil* 14:239–249, 1987.
- Cavalari CJ: Pathologic considerations associated with partial dentures, *Dent Clin North Am* 17:585–600, 1973.
- Chandler JA, Brudvik JS: Clinical evaluation of patients eight to nine years after placement of removable partial dentures, *J Prosthet Dent* 51:736–743, 1984.
- Chen MS, et al.: Simplicity in interim tooth-supported removable partial denture construction, *J Prosthet Dent* 54:740–744, 1985.
- Cotmore JM, et al.: Removable partial denture survey: clinical practice today, *J Prosthet Dent* 49:321–327, 1983.
- Coy RE, Arnold PD: Survey and design of diagnostic casts for removable partial dentures, *J Prosthet Dent* 32:103–106, 1974.
- Cunningham DM: Comparison of base metal alloys and type IV gold alloys for removable partial denture frameworks, *Dent Clin North Am* 17:719–722, 1973.

- Diaz-Arnold AM, Langenwalter EM, Hatch LK: Cast restorations made to existing removable partial dentures, *J Prosthet Dent* 61: 414–417, 1989.
- Dukes BS, Fields Jr H: Comparison of disclosing media used for adjustment of removable partial denture frameworks, *J Prosthet Dent* 45:380–382, 1981.
- Elliot RW: The effects of heat on gold partial denture castings, *J Prosthet Dent* 13:688–698, 1963.
- Ettinger RL: The acrylic removable partial denture, *J Am Dent Assoc* 95:945–949, 1977.
- Ettinger RL, Beck JD, Jakobsen J: Removable prosthodontic treatment needs: a survey, *J Prosthet Dent* 51:419–427, 1984.
- Ewing JE: The construction of accurate full crown restorations for an existing clasp by using a direct metal pattern technique, *J Prosthet Dent* 15:889–899, 1965.
- Farah JW, MacGregor AR, Miller TPG: Stress analysis of disjunct removable partial dentures, *J Prosthet Dent* 42:271–275, 1979.
- Federation of Prosthodontic Organizations: Guidelines for evaluation of completed prosthodontic treatment for removable partial dentures, *J Prosthet Dent* 27:326–328, 1972.
- Fenton AH, Zarb GA, MacKay HF: Overdenture oversights, *Dent Clin North Am* 23:117–130, 1979.
- Fields H, Campfield RW: Removable partial prosthesis partially supported by an endosseous blade implant, *J Prosthet Dent* 31:273–278, 1974.
- Firtell DN, Kouyoumdjian JH, Holmes JB: Attitudes toward abutment preparation for removable partial dentures, *J Prosthet Dent* 55: 131–133, 1986.
- Fish SF: Partial dentures, *Br Dent J* 128:243–246, 289–293, 339–344, 398–402, 446–453, 495–502, 547–551, 590–592, 1970.
- Fisher R: Relation of removable partial denture base stability to sex, age, and other factors, *J Dent Res* (IADR abstract 613) 59:entire issue, 1980.
- Frank RP: Evaluating refractory cast wax-ups for removable partial dentures, *J Prosthet Dent* 35:388–392, 1976.
- Girardot RL: The physiologic aspects of partial denture restorations, *J Prosthet Dent* 3:689–698, 1953.
- Gordon SR: Measurement of oral status and treatment need among subjects with dental prostheses: are the measures less reliable than the prostheses? Part I. Oral status in removable prosthodontics, *J Prosthet Dent* 65:664–668, 1991.
- Harrison WM, Stansbury BE: The effect of joint surface contours on the transverse strength of repaired acrylic resin, *J Prosthet Dent* 23:464–472, 1970.
- Heintz WD: Principles, planning, and practice for prevention, *Dent Clin North Am* 17:705–718, 1973.
- Helel KS, Graser GN, Featherstone JD: Abrasion of enamel and composite resin by removable partial denture clasps, *J Prosthet Dent* 52:389–397, 1984.
- Henderson CW, et al.: Evaluation of the barrier system: an infection control system for the dental laboratory, *J Prosthet Dent* 58:517–521, 1987.
- Izikowitz L: A long-term prognosis for the free-end saddle-bridge, *J Oral Rehabil* 12:247–262, 1985.
- Jankelson BH: Adjustment of dentures at time of insertion and alterations to compensate for tissue changes, *J Am Dent Assoc* 64:521–531, 1962.
- Jones RR: The lower partial denture, *J Prosthet Dent* 2:219–229, 1952.
- Kaaber S: Twelve year changes in mandibular bone level in free end saddle denture wearers, *J Dent Res* (IADR abstract 1367) 60:entire issue, 1981.
- Kaires AK: A study of partial denture design and masticatory pressures in a mandibular bilateral distal extension case, *J Prosthet Dent* 8:340–350, 1958.
- Kelly E: Changes caused by a mandibular removable partial denture opposing a maxillary complete denture, *J Prosthet Dent* 27:140–150, 1972.
- Kelly E: Fatigue failure in denture base polymers, *J Prosthet Dent* 21:257–266, 1969.
- Kelly EK: The physiologic approach to partial denture design, *J Prosthet Dent* 3:699–710, 1953.
- Kessler B: An analysis of the tongue factor and its functioning areas in dental prosthesis, *J Prosthet Dent* 5:629–635, 1955.
- Klein IE, Blatterfein L, Kaufman EG: Minimum clinical procedures for satisfactory complete denture, removable partial denture, and fixed partial denture services, *J Prosthet Dent* 22:4–10, 1969.
- Kratochvil FJ: Maintaining supporting structures with a removable partial prosthesis, *J Prosthet Dent* 25:167–174, 1971.
- Kratochvil FJ, Caputo AA: Photoelastic analysis of pressure on teeth and bone supporting removable partial dentures, *J Prosthet Dent* 32:52–61, 1974.
- Kratochvil FJ, Davidson PN, Guijt J: Five-year survey of treatment with removable partial dentures, Part I, *J Prosthet Dent* 48:237–244, 1982.
- Landa JS: The troublesome transition from a partial lower to a complete lower denture, *J Prosthet Dent* 4:42–51, 1954.
- Lanser A: Tooth-supported telescope restorations, *J Prosthet Dent* 45:515–520, 1981.
- Lechner SK: A longitudinal survey of removable partial dentures. I. Patient assessment of dentures, *Aust Dent J* 30:104–111, 1985.
- Lechner SK: A longitudinal survey of removable partial dentures. II. Clinical evaluation of dentures, *Aust Dent J* 30:194–197, 1985.
- Lechner SK: A longitudinal survey of removable partial dentures. III. Tissue reactions to various denture components, *Aust Dent J* 30: 291–295, 1985.
- Lee MW, et al.: O-ring coping attachments for removable partial dentures, *J Prosthet Dent* 74:235–241, 1995.
- Lewis AJ: Failure of removable partial denture castings during service, *J Prosthet Dent* 39:147–149, 1978.
- Lewis AJ: Radiographic evaluation of porosities in removable partial denture castings, *J Prosthet Dent* 39:278–281, 1978.
- Lopuck SE, Reitz PV, Altadonna J: Hinge for a unilateral maxillary arch prosthesis, *J Prosthet Dent* 45:446–448, 1981.
- Lorton L: A method of stabilizing removable partial denture castings during clinical laboratory procedures, *J Prosthet Dent* 39:344–345, 1978.
- MacEntee MI, Hawbolt EB, Zahel JI: The tensile and shear strength of a base metal weld joint used in dentistry, *J Dent Res* 60:154–158, 1981.
- Maetani T, et al.: Effect of TFE coating on plaque accumulation on dental castings, *J Dent Res* (IADR abstract 1359) 60:entire issue, 1981.
- Maison WG: Instructions to denture patients, *J Prosthet Dent* 9:825–831, 1959.
- Makrauer FL, Davis JS: Gastroscopic removal of a partial denture, *J Am Dent Assoc* 94:904–906, 1977.
- Marcus SE, et al.: The retention and tooth loss in the permanent dentition of adults: United States, 1988–1991, *J Dent Res* 75:684–695, 1996.
- Martone AL: The challenge of the partially edentulous mouth, *J Prosthet Dent* 8:942–954, 1958.
- Martone AL: The fallacy of saving time at the chair, *J Prosthet Dent* 7:416–419, 1957.
- Massler M: Geriatric nutrition: the role of taste and smell in appetite, *J Prosthet Dent* 32:247–250, 1980.
- McCracken WL: Auxiliary uses of cold-curing acrylic resins in prosthetic dentistry, *J Am Dent Assoc* 47:298–304, 1953.
- McCracken WL: A comparison of tooth-borne and tooth-tissue-borne removable partial dentures, *J Prosthet Dent* 3:375–381, 1953.
- McCracken WL: A philosophy of partial denture treatment, *J Prosthet Dent* 13:889–900, 1963.
- Means CR, Flenniken IE: Gagging: a problem in prosthetic dentistry, *J Prosthet Dent* 23:614–620, 1970.
- Mehringer EJ: The saliva as it is related to the wearing of dentures, *J Prosthet Dent* 4:312–318, 1954.
- Michell DL, Wilke ND: Articulators through the years. I. Up to 1940, *J Prosthet Dent* 39:330–338, 1978; II, from 1940, 39:451–458, 1978.
- Miller EL: Clinical management of denture-induced inflammations, *J Prosthet Dent* 38:362–365, 1977.

- Mohamed SE, Schmidt JR, Harrison JD: Articulators in dental education and practice, *J Prosthet Dent* 36:319–325, 1976.
- Morris HF, Asgar K: Physical properties and microstructure of four new commercial partial denture alloys, *J Prosthet Dent* 33:36–46, 1975.
- Neufeld JO: Changes in the trabecular pattern of the mandible following the loss of teeth, *J Prosthet Dent* 8:685–697, 1958.
- Oatlund SG: Saliva and denture retention, *J Prosthet Dent* 10:658–663, 1960.
- Ogle RE, Sorensen SE, Lewis EA: A new visible light-cured resin system applied to removable prosthodontics, *J Prosthet Dent* 56:497–506, 1986.
- Osborne J, Lammie GA: The bilateral free-end saddle lower denture, *J Prosthet Dent* 4:640–652, 1954.
- Overton RG, Bramblett RM: Prosthodontic services: a study of need and availability in the United States, *J Prosthet Dent* 27:329–339, 1972.
- Pascoe DF, Wimmer J: A radiographic technique for the detection of internal defects in dental castings, *J Prosthet Dent* 39:150–157, 1978.
- Phillips RW, Leonard LJ: A study of enamel abrasion as related to partial denture clasps, *J Prosthet Dent* 6:657–671, 1956.
- Plainfield S: Communication distortion: the language of patients and practitioners of dentistry, *J Prosthet Dent* 22:11–19, 1969.
- Prieskel HW: The distal extension prosthesis reappraised, *J Dent* 5:217–230, 1977.
- Ramsey WO: The relation of emotional factors to prosthodontic service, *J Prosthet Dent* 23:4–10, 1970.
- Raybin NH: The polished surface of complete dentures, *J Prosthet Dent* 13:236–239, 1963.
- Removable prosthodontics, *Dent Clin North Am* 28(entire issue), 1984.
- Renggli HH, Allet B, Spanauf AJ: Splinting of teeth with fixed bridges: biological effect, *J Oral Rehabil* 11:535–537, 1984.
- Reynolds JM: Crown construction for abutments of existing removable partial dentures, *J Am Dent Assoc* 69:423–426, 1964.
- Rissen L, et al.: Effect of fixed and removable partial dentures on the alveolar bone of abutment teeth, *J Dent Res* (IADR abstract 1368) 60:entire issue, 1981.
- Rissen L, et al.: Six-year report of the periodontal health of fixed and removable partial denture abutment teeth, *J Prosthet Dent* 54:461–467, 1985.
- Rothman R: Phonetic considerations in denture prosthesis, *J Prosthet Dent* 11:214–223, 1961.
- Rudd KD, Dunn BW: Accurate removable partial dentures, *J Prosthet Dent* 18:559–570, 1967.
- Rushford CB: A technique for precision removable partial denture construction, *J Prosthet Dent* 31:377–383, 1974.
- Ruyter IE, Svendsen SA: Flexural properties of denture base polymers, *J Prosthet Dent* 43:95–104, 1980.
- Sadig W, Fahmi F: The modified swing-lock: a new approach, *J Prosthet Dent* 74:428–431, 1995.
- Savage RD, MacGregor AR: Behavior therapy in prosthodontics, *J Prosthet Dent* 24:126–132, 1970.
- Schabel RW: Dentist-patient communication: a major factor in treatment prognosis, *J Prosthet Dent* 21:3–5, 1969.
- Schabel RW: The psychology of aging, *J Prosthet Dent* 27:569–573, 1972.
- Schmitt SM: Combination syndrome: a treatment approach, *J Prosthet Dent* 54:307–309, 1985.
- Schole ML: Management of the gagging patient, *J Prosthet Dent* 9:578–583, 1959.
- Schopper AF: Loss of vertical dimension: causes and effects: diagnosis and various recommended treatments, *J Prosthet Dent* 9:428–431, 1959.
- Schopper AF: Removable appliances for the preservation of the teeth, *J Prosthet Dent* 4:634–639, 1954.
- Schulte JK, Smith DE: Clinical evaluation of swinglock removable partial dentures, *J Prosthet Dent* 44:595–603, 1980.
- Schuyler CH: Stress distribution as the prime requisite to the success of a partial denture, *J Am Dent Assoc* 20:2148–2154, 1963.
- Schwarz WD, Barsby MJ: Design of partial dentures in dental practice, *J Dent* 6:166–170, 1978.
- Sears VH: Comprehensive denture service, *J Am Dent Assoc* 64:531–552, 1962.
- Skinner EW, Gordon CC: Some experiments on the surface hardness of dental stones, *J Prosthet Dent* 6:94–100, 1956.
- Skinner EW, Jones PM: Dimensional stability of self-curing denture base acrylic resin, *J Am Dent Assoc* 51:426–431, 1955.
- Smith DE: Removable prosthodontics research—quo vadis? *J Prosthet Dent* 62:707–711, 1989.
- Smith FW, Applegate OC: Roentgenographic study of bone changes during exercise stimulation of edentulous areas, *J Prosthet Dent* 11:1086–1097, 1961.
- Stendahl CG, Grob DJ: Detection of binding areas on removable partial denture frameworks, *Dent Clin North Am* 23:101–106, 1979.
- Swoope CC, Frank RP: Insertion and post-insertion care. In Clark J, editor: *Clinical dentistry*, vol. 5. New York, 1976, Harper & Row.
- Sykora O: Definitive immediate cast removable partial dentures, *Can Dent Assoc J* 51:767–769, 1985.
- Sykora O: Extracoronally removable partial denture service in Canada, *J Prosthet Dent* 39:37–41, 1978.
- Tallgren A: Alveolar bone loss in denture wearers as related to facial morphology, *Acta Odontol Scand* 28:251–270, 1970.
- Taylor TD, et al.: Prosthodontic survey. I. Removable prosthodontic laboratory survey, *J Prosthet Dent* 52:598–601, 1984.
- Taylor TD, et al.: Prosthodontic survey. II. Removable prosthodontic curriculum survey, *J Prosthet Dent* 52:747–749, 1984.
- Teppo KW, Smith FW: A method of immediate clasp repair, *J Prosthet Dent* 34:77–80, 1975.
- Trainor JE, Elliott Jr RW: Removable partial dentures designed by dentists before and after graduate level instruction: a comparative study, *J Prosthet Dent* 27:509–514, 1972.
- von Gonten AS, Nelson DR: Laboratory pitfalls that contribute to embrasure clasp failure, *J Prosthet Dent* 53:136–138, 1985.
- von Gonten AS, Palik JF: Tooth preparation guide for embrasure clasp designs, *J Prosthet Dent* 53:281–282, 1985.
- Wagner AG: Maintenance of the partially edentulous mouth and care of the denture, *Dent Clin North Am* 17:755–768, 1973.
- Wagner AG, Fargue EG: A study of four methods of recording the path of insertion of removable partial dentures, *J Prosthet Dent* 35:267–272, 1976.
- Wallace DH: The use of gold occlusal surfaces in complete and partial dentures, *J Prosthet Dent* 14:326–333, 1964.
- Walter JD: Partial denture technique. I. Introduction, *Br Dent J* 147:241–243, 1979; II. The purpose of the denture: choice of material, 147:302–304, 1979; III. Supporting the denture, 148:13–16, 1980; IV. Guide planes, 148:70–72, 1980.
- Weaver RE, Goebel WM: Reactions to acrylic resin dental prostheses, *J Prosthet Dent* 43:138–142, 1980.
- Whitsitt JA, Battle LW, Jarosz CJ: Enhanced retention for the distal extension-base removable partial denture using a heat-cured resilient soft liner, *J Prosthet Dent* 52:447–448, 1984.
- Williams EO, Hartman GE: Instructional aid for teaching removable partial denture design, *J Prosthet Dent* 48:222, 1982.
- Wise HB, Kaiser DA: A radiographic technique for examination of internal defects in metal frameworks, *J Prosthet Dent* 42:594–595, 1979.
- Young HA: Factors contributory to success in prosthodontic practice, *J Prosthet Dent* 5:354–360, 1955.
- Young Jr L: Try-in of the removable partial denture framework, *J Prosthet Dent* 46:579–580, 1981.
- Zach GA: Advantages of mesial rests for removable partial dentures, *J Prosthet Dent* 33:32–35, 1975.
- Zerosi C: A new type of removable splint: its indications and function, *Dent Abstr* 1:451–452, 1956.

Zurasky JE, Duke ES: Improved adhesion of denture acrylic resins to base metal alloys, *J Prosthet Dent* 57:520–524, 1987.

## MOUTH PREPARATIONS

- Alexander JM, Van Sickels JE: Posterior maxillary osteotomies: an aid for a difficult prosthodontic problem, *J Prosthet Dent* 41:614–617, 1979.
- Atwood DA: Reduction of residual ridges in the partially edentulous patient, *Dent Clin North Am* 17:745–754, 1973.
- Axinn S: Preparation of retentive areas for clasps in enamel, *J Prosthet Dent* 34:405–407, 1975.
- Belinfante LS, Abney Jr JM: A teamwork approach to correct a severe prosthodontic problem, *J Am Dent Assoc* 91:357–359, 1975.
- Dixon DL, Breeding LC, Swift EJ: Use of a partial coverage porcelain laminate to enhance clasp retention, *J Prosthet Dent* 63:55–58, 1990.
- Glann GW, Appleby RC: Mouth preparations for removable partial dentures, *J Prosthet Dent* 10:698–706, 1960.
- Johnston JF: Preparation of mouths for fixed and removable partial dentures, *J Prosthet Dent* 11:456–462, 1961.
- Jones RM: Dentin exposed and decay incidence in removable partial denture rest seats, *Int J Prosthodont* 5:227–236, 1992.
- Kahn AE: Partial versus full coverage, *J Prosthet Dent* 10:167–178, 1960.
- Kapur KK, et al.: A randomized clinical trial of two basic removable partial denture designs. Part I. Comparisons of five-year success rates and periodontal health, *J Prosthet Dent* 72:268–282, 1994.
- Laney WR, Desjardins RP: Comparison of base metal alloys and type IV gold alloys for removable partial denture framework, *Dent Clin North Am* 17:611–630, 1973.
- Lorey RE: Abutment considerations, *Dent Clin North Am* 24:63–79, 1980.
- Marquardt GL: Dolder bar joint mandibular overdenture: a technique for nonparallel abutment teeth, *J Prosthet Dent* 36:101–111, 1976.
- McArthur DR, Turvey TA: Maxillary segmental osteotomies for mandibular removable partial denture patients, *J Prosthet Dent* 41:381–387, 1979.
- McCarthy JA, Moser JB: Mechanical properties of tissue conditioners. I. Theoretical considerations, behavioral characteristics and tensile properties, *J Prosthet Dent* 40:89–97, 1978.
- McCarthy JA, Moser JB: Mechanical properties of tissue conditioners. II. Creep characteristics, *J Prosthet Dent* 40:334–342, 1978.
- McCracken WL: Mouth preparations for partial dentures, *J Prosthet Dent* 6:39–52, 1956.
- Mills M: Mouth preparation for removable partial denture, *J Am Dent Assoc* 60:154–159, 1960.
- Mopsik ER, et al.: Surgical intervention to reestablish adequate intermaxillary space before fixed or removable prosthodontics, *J Am Dent Assoc* 95:957–960, 1977.
- Nishimura RD: Etched metal cingulum rest retainer, *J Am Dent Assoc* 112:177–179, 1986.
- Phillips Jr RJ: Design sequence and mouth preparation for the removable partial denture, *J Calif Dent Assoc* 25:363–370, 1997.
- Phillips RW: Report of the Committee on Scientific Investigation of the Academy of Restorative Dentistry, *J Prosthet Dent* 13:515–535, 1963.
- Schorr L, Clayman LH: Reshaping abutment teeth for reception of partial denture clasps, *J Prosthet Dent* 4:625–633, 1954.
- Stamps JT, Tanquist RA: Restoration of removable partial denture rest seats using dental amalgam, *J Prosthet Dent* 41:224–227, 1979.
- Stern WJ: Guiding planes in clasp reciprocation and retention, *J Prosthet Dent* 34:408–414, 1975.
- Swoope CC, Frank RP: Mouth preparation. In Clark JW, editor: *Clinical dentistry*, vol. 5. New York, 1976, Harper & Row.
- Tiege JD, et al.: In vitro investigation of the wear of resin composite materials and cast direct retainers during removable partial denture placement and removal, *Int J Prosthodont* 5:145–153, 1992.
- Tucker KM, Heget HS: The incidence of inflammatory papillary hyperplasia, *J Am Dent Assoc* 93:610–613, 1976.

Wong R, Nicholls JJ, Smith DE: Evaluation of prefabricated lingual rest seats for removable partial dentures, *J Prosthet Dent* 48:521–526, 1982.

## OCCLUSION, JAW RELATION RECORDS, AND TRANSFER METHODS

- Applegate OC: Loss of posterior occlusion, *J Prosthet Dent* 4:197–199, 1954.
- Baraban DJ: Establishing centric relation and vertical dimension in occlusal rehabilitation, *J Prosthet Dent* 12:1157–1165, 1962.
- Bauman R: Minimizing postinsertion problems: a procedure for removable partial denture placement, *J Prosthet Dent* 42:381–385, 1979.
- Beck HO: Choosing the articulator, *J Am Dent Assoc* 64:468–475, 1962.
- Beck HO: A clinical evaluation of the arcon concept of articulation, *J Prosthet Dent* 9:409–421, 1959.
- Beck HO: Selection of an articulator and jaw registration, *J Prosthet Dent* 10:878–886, 1960.
- Beckett LS: Accurate occlusal relations in partial denture construction, *J Prosthet Dent* 4:487–495, 1954.
- Berke JD, Moleres I: A removable appliance for the correction of maxillomandibular disproportion, *J Prosthet Dent* 17:172–177, 1967.
- Berman MH: Accurate interocclusal records, *J Prosthet Dent* 10:620–630, 1960.
- Beyron HL: Characteristics of functionally optimal occlusion and principles of occlusal rehabilitation, *J Am Dent Assoc* 48:648–656, 1954.
- Beyron HL: Occlusal changes in adult dentition, *J Am Dent Assoc* 48:674–686, 1954.
- Beyron HL: Occlusal relationship, *Int Dent J* 2:467–496, 1952.
- Block LS: Preparing and conditioning the patient for intermaxillary relations, *J Prosthet Dent* 2:599–603, 1952.
- Block LS: Tensions and intermaxillary relations, *J Prosthet Dent* 4:204–207, 1954.
- Boos RH: Basic anatomic factors of jaw position, *J Prosthet Dent* 4:200–203, 1954.
- Boos RH: Maxillomandibular relations, occlusion, and the temporomandibular joint, *Dent Clin North Am* 6:19–35, 1962.
- Boos RH: Occlusion from rest position, *J Prosthet Dent* 2:575–588, 1952.
- Borgh O, Posselt U: Hinge axis registration: experiments on the articulator, *J Prosthet Dent* 8:35–40, 1958.
- Boucher CO: Occlusion in prosthodontics, *J Prosthet Dent* 3:633–656, 1953.
- Braly BV: Occlusal analysis and treatment planning for restorative dentistry, *J Prosthet Dent* 27:168–171, 1972.
- Breeding LC, et al.: Accuracy of three interocclusal recording materials used to mount a working cast, *J Prosthet Dent* 71:265–270, 1994.
- Cerveris AR: Vibracentric equilibration of centric occlusion, *J Am Dent Assoc* 63:476–483, 1961.
- Christensen PB: Accurate casts and positional relation records, *J Prosthet Dent* 8:475–482, 1958.
- Clayton JA, Kotowicz WE, Zahler JM: Pantographic tracings of mandibular movements and occlusion, *J Prosthet Dent* 25:389–396, 1971.
- Cohn LA: Factors of dental occlusion pertinent to the restorative and prosthetic problem, *J Prosthet Dent* 9:256–257, 1959.
- Collett HA: Balancing the occlusion of partial dentures, *J Am Dent Assoc* 42:162–168, 1951.
- Colman AJ: Occlusal requirements for removable partial dentures, *J Prosthet Dent* 17:155–162, 1967.
- D'Amico A: Functional occlusion of the natural teeth of man, *J Prosthet Dent* 11:899–915, 1961.
- Draper DH: Forward trends in occlusion, *J Prosthet Dent* 13:724–731, 1963.

- Emmert JH: A method for registering occlusion in semiedentulous mouths, *J Prosthet Dent* 8:94–99, 1958.
- Farmer JB, Connelly ME: Treatment of open occlusions with onlay and overlay removable partial dentures, *J Prosthet Dent* 51:300–303, 1984.
- Fedi PF: Cardinal differences in occlusion of natural teeth and that of artificial teeth, *J Am Dent Assoc* 62:482–485, 1926.
- Fountain HW: Seating the condyles for centric relation records, *J Prosthet Dent* 11:1050–1058, 1961.
- Freilich MA, Altieri JW, Wahle JJ: Principles of selecting interocclusal records for articulation of dentate and partially dentate casts, *J Prosthet Dent* 68:361–367, 1992.
- Gilson TD: Theory of centric correction in natural teeth, *J Prosthet Dent* 8:468–474, 1958.
- Granger ER: The articulator and the patient, *Dent Clin North Am* 4:527–539, 1960.
- Hansen CA, et al.: Simplified procedure for making gold occlusal surfaces on denture teeth, *J Prosthet Dent* 71:413–416, 1994.
- Hausman M: Interceptive and pivotal occlusal contacts, *J Am Dent Assoc* 66:165–171, 1963.
- Henderson D: Occlusion in removable partial prosthodontics, *J Prosthet Dent* 27:151–159, 1971.
- Hindels GW: Occlusion in removable partial denture prosthesis, *Dent Clin North Am* 6:137–146, 1962.
- Hughes GA, Regli CP: What is centric relation? *J Prosthet Dent* 11:16–22, 1961.
- Ivanhoe JR, Vaught RD: Occlusion in the combination fixed removable prosthodontic patient, *Dent Clin North Am* 31:305–322, 1987.
- Jankelson B: Considerations of occlusion on fixed partial dentures, *Dent Clin North Am* 3:187–203, 1959.
- Jeffreys FE, Platner RL: Occlusion in removable partial dentures, *J Prosthet Dent* 10:912–920, 1960.
- Kapur KK, et al.: A randomized clinical trial of two basic removable partial denture designs. Part I. Comparisons of five-year success rates and periodontal health, *J Prosthet Dent* 72:268–282, 1994.
- Lang BR: Complete denture occlusion, *Dent Clin North Am* 40:85–101, 1996.
- Lauritzen AG, Bodner GH: Variations in location of arbitrary and true hinge axis points, *J Prosthet Dent* 11:224–229, 1961.
- Lay LS, et al.: Making the framework try-in, altered cast impression and occlusal registration in one appointment, *J Prosthet Dent* 75:446–448, Apr 1996.
- Lindblom G: Balanced occlusion with partial reconstructions, *Int Dent J* 1:84–98, 1951.
- Lindblom G: The value of bite analysis, *J Am Dent Assoc* 48:657–664, 1954.
- Long Jr JH: Location of the terminal hinge axis by intraoral means, *J Prosthet Dent* 23:11–24, 1970.
- Lucia VO: Centric relation theory and practice, *J Prosthet Dent* 10:849–956, 1960.
- Lucia VO: The gnathological concept of articulation, *Dent Clin North Am* 6:183–197, 1962.
- Lundquist DO, Fiebiger GE: Registration for relating the mandibular cast to the maxillary cast based on Kennedy's classification system, *J Prosthet Dent* 35:371–375, 1976.
- Mann AW, Pankey LD: The PM philosophy of occlusal rehabilitation, *Dent Clin North Am* 7:621–636, 1963.
- McCullum BB: The mandibular hinge axis and a method of locating it, *J Prosthet Dent* 10:428–435, 1960.
- McCracken WL: Functional occlusion in removable partial denture construction, *J Prosthet Dent* 8:955–963, 1958.
- McCracken WL: Occlusion in partial denture prosthesis, *Dent Clin North Am* 6:109–119, 1962.
- Mehta JD, Joglekar AP: Vertical jaw relations as a factor in partial dentures, *J Prosthet Dent* 21:618–625, 1969.
- Meyer FS: The generated path technique in reconstruction dentistry. I and II, *J Prosthet Dent* 9:354–366, 432–440, 1959.
- Millstein PL, Kronman JH, Clark RE: Determination of the accuracy of wax interocclusal registrations, *J Prosthet Dent* 25:189–196, 1971.
- Moore AW: Ideal versus adequate dental occlusion, *J Am Dent Assoc* 55:51–56, 1957.
- Moulton GH: The importance of centric occlusion in diagnosis and treatment planning, *J Prosthet Dent* 10:921–926, 1960.
- Nayyar A, Bill Jr JA, Twiggs SW: Comparison of interocclusal recording materials for mounting a working cast, *J Dent Res* (IADR abstract 1216) 60:entire issue, 1981.
- Nuttall EB: Establishing posterior functional occlusion for fixed partial dentures, *J Am Dent Assoc* 66:341–348, 1963.
- O'Leary TJ, Shanley DB, Drake RB: Tooth mobility in cuspid-protected and group-function occlusions, *J Prosthet Dent* 27:21–25, 1972.
- Olsson A, Posselt U: Relationship of various skull reference lines, *J Prosthet Dent* 11:1045–1049, 1961.
- Reitz PV: Technique for mounting removable partial dentures on an articulator, *J Prosthet Dent* 22:490–494, 1969.
- Reynolds JM: Occlusal wear facets, *J Prosthet Dent* 24:367–372, 1970.
- Ricketts RM: Occlusion: the medium of dentistry, *J Prosthet Dent* 21:39–60, 1969.
- Robinson MJ: Centric position, *J Prosthet Dent* 1:384–386, 1951.
- Scaife Jr RR, Holt JE: Natural occurrence of cuspid guidance, *J Prosthet Dent* 22:225–229, 1969.
- Scandrett FR, Hanson JC: Technique for attaching the master cast to its split mounting index, *J Prosthet Dent* 40:467–469, 1978.
- Schireson S: Grinding teeth for masticatory efficiency and gingival health, *J Prosthet Dent* 13:337–345, 1963.
- Schuyler CH: An evaluation of incisal guidance and its influence in restorative dentistry, *J Prosthet Dent* 9:374–378, 1959.
- Schuyler CH: Factors contributing to traumatic occlusion, *J Prosthet Dent* 11:708–715, 1961.
- Schuyler CH: Factors of occlusion applicable to restorative dentistry, *J Prosthet Dent* 3:772–782, 1953.
- Schuyler CH: Fundamental principles in the correction of occlusal disharmony: natural and artificial (grinding), *J Am Dent Assoc* 22:1193–1202, 1935.
- Sears VH: Centric and eccentric occlusions, *J Prosthet Dent* 10:1029–1036, 1960.
- Sears VH: Occlusal pivots, *J Prosthet Dent* 6:332–338, 1956.
- Sears VH: Mandibular equilibration, *J Am Dent Assoc* 65:45–55, 1962.
- Sears VH: Occlusion: the common meeting ground in dentistry, *J Prosthet Dent* 2:15–21, 1952.
- Shanahan TEJ, Leff A: Interocclusal records, *J Prosthet Dent* 10:842–848, 1960.
- Silverman MM: Determination of vertical dimension by phonetics, *J Prosthet Dent* 6:465–471, 1956. *Dent Abstr* 2:221, 1957.
- Skurnik H: Accurate interocclusal records, *J Prosthet Dent* 21:154–165, 1969.
- Stuart CE: Accuracy in measuring functional dimensions and relations in oral prosthesis, *J Prosthet Dent* 9:220–236, 1959.
- Teteruck WR, Lundeen HC: The accuracy of an ear face-bow, *J Prosthet Dent* 16:1039–1046, 1966.
- Trushkowsky RD, Guiv B: Restoration of occlusal vertical dimension by means of a silica-coated onlay removable partial denture in conjunction with dentin bonding: a clinical report, *J Prosthet Dent* 66:283–286, 1991.
- Wagner AG: A technique to record jaw relations for distally edentulous dental arches, *J Prosthet Dent* 29:405–407, 1973.
- Weinberg LA: Arcon principle in the condylar mechanism of adjustable articulators, *J Prosthet Dent* 13:263–268, 1963.
- Weinberg LA: An evaluation of basic articulators and their concepts. I and II, *J Prosthet Dent* 13:622–863, 1963.
- Weinberg LA: An evaluation of the face-bow mounting, *J Prosthet Dent* 11:32–42, 1961.
- Weinberg LA: The transverse hinge axis: real or imaginary, *J Prosthet Dent* 9:775–787, 1959.

## PARTIAL DENTURE DESIGN

- Akagawa Y, et al.: A new telescopic crown system using a soldered horizontal pin for removable partial dentures, *J Prosthet Dent* 69:228–231, 1993.
- Antos Jr EW, Tenner RP, Foerth D: The swinglock partial denture: an alternative approach to conventional removable partial denture service, *J Prosthet Dent* 40:257–262, 1978.
- Avant EW: Indirect retention in partial denture design, *J Prosthet Dent* 16:1103–1110, 1966.
- Axinn S, O'Connor Jr RP, Kopp EN: Immediate removable partial denture frameworks, *J Am Dent Assoc* 95:583–585, 1977.
- Beaumont Jr AJ, Bianco HJ: Microcomputer-aided removable partial denture design: the next evolution, *J Prosthet Dent* 62:551–556, 1989.
- Becker CW, Bolender CL: Designing swinglock partial dentures, *J Prosthet Dent* 46:126–132, 1981.
- Becker CM, Kaiser DA, Goldfogel MH: Evolution of removable partial denture design, *J Prosthodont* 3:158–166, 1994.
- Ben-Ur Z, et al.: Designing clasps for the asymmetric distal extension removable partial denture, *Int J Prosthodont* 9:374–378, July 1996.
- Ben-Ur Z, et al.: Rigidity of major connectors when subjected to bending and torsion forces, *J Prosthet Dent* 62:557–562, 1989.
- Berg E: Periodontal problems associated with use of distal extension removable partial dentures: a matter of construction? *J Oral Rehabil* 12:369–379, 1985.
- Berg Jr T: I-bar: myth and counter-myth, *Dent Clin North Am* 23:65–75, 1979.
- Berg Jr T, Caputo AA: Anterior rests for maxillary removable partial dentures, *J Prosthet Dent* 39:139–146, 1978.
- Blatterfein L: A systematic method of designing upper partial denture bases, *J Am Dent Assoc* 46:510–525, 1953.
- Blatterfein L: The use of the semiprecision rest in removable partial dentures, *J Prosthet Dent* 22:301–306, 1969.
- Bolouri A: Removable partial denture design for a few remaining natural teeth, *J Prosthet Dent* 39:346–348, 1978.
- Breeding L, Dixon DL: Prosthetic restoration of the anterior edentulous space, *J Prosthet Dent* 67:144–148, 1992.
- Bridgeman JT, et al.: Comparison of titanium and cobalt-chromium removable partial denture clasps, *J Prosthet Dent* 78:187–193, 1997.
- Brown DT, Desjardins RP, Chao EY: Fatigue failure in acrylic resin retaining minor connectors, *J Prosthet Dent* 58:329–335, 1987.
- Browning JD, et al.: Effect of positional loading of three removable partial denture clasp assemblies on movement of abutment teeth, *J Prosthet Dent* 55:347–351, 1986.
- Browning JD, Meadors LW, Eick JD: Movement of three removable partial denture clasp assemblies under occlusal loading, *J Prosthet Dent* 55:69–74, 1986.
- Brudvik J, Reimers D: The tooth-removable partial denture interface, *J Prosthet Dent* 68:924–927, 1992.
- Budtz-Jorgensen E, et al.: Alternate framework designs for removable partial dentures, *J Prosthet Dent* 80:58–66, July 1998.
- Burns DR, Ward JE, Nance GL: Removable partial denture design and fabrication survey of the prosthodontic specialist, *J Prosthet Dent* 62:303–307, 1989.
- Campbell LD: Subjective reactions to major connector designs for removable partial dentures, *J Prosthet Dent* 36:507–516, 1977.
- Campbell SD, Weiner H: The hinged-clasp assembly removable partial denture, *J Prosthet Dent* 63:59–61, 1990.
- Casey DM, Lauciello FR: A method for marking the functional depth of the floor of the mouth, *J Prosthet Dent* 43:108–111, 1980.
- Cecconi BT: Lingual bar design, *J Prosthet Dent* 28:635–639, 1973.
- Cecconi BT, et al.: The component partial: a new RPD construction system, *J Calif Dent Assoc* 25:363–370, 1997.
- Cowles KR: Partial denture design: a simple teaching aid, *J Prosthet Dent* 47:219, 1982.
- Davenport JC, et al.: The acquisition and validation of removable partial denture design knowledge. I. Methodology and overview, *J Oral Rehabil* 23:152–157, 1996.
- Davenport JC, et al.: The acquisition and validation of removable partial denture design knowledge. II. Design rules and expert reaction, *J Oral Rehabil* 23:811–824, 1996.
- Demer WJ: An analysis of mesial rest-I-bar clasps designs, *J Prosthet Dent* 36:243–253, 1976.
- Dunny JA, King GE: Minor connector designs for anterior acrylic resin bases: a preliminary study, *J Prosthet Dent* 34:496–497, 1975.
- Eick JD, et al.: Abutment tooth movement related to fit of a removable partial denture, *J Prosthet Dent* 57:66–72, 1987.
- Ettinger RL: The acrylic removable partial denture, *J Am Dent Assoc* 85:945–949, 1977.
- Farmer JB, et al.: Interim removable partial dentures: a modified technique, *Quintessence Dent Technol* 8:511–516, 1985.
- Feingold FM, Grant AA, Johnson W: The effect of partial denture design on abutment tooth and saddle movement, *J Oral Rehabil* 13:549–557, 1986.
- Firtell DN: Effect of clasp design upon retention of removable partial dentures, *J Prosthet Dent* 20:43–52, 1968.
- Firtell DN, Grisius RJ, Muncheryan AM: Reaction of the anterior abutment of a Kennedy Class II removable partial denture to various clasp arm designs: an in vitro study, *J Prosthet Dent* 53:77–82, 1985.
- Fisher RL, Jaslow C: The efficiency of an indirect retainer, *J Prosthet Dent* 33:24–30, 1975.
- Fisher RL, McDowell GC: Removable partial denture design and potential stress to the periodontium, *Int J Periodont Restor Dent* 4:34–47, 1984.
- Frank RP: Direct retainers for distal-extension removable partial dentures, *J Prosthet Dent* 56:562–567, 1986.
- Frank RP: An investigation of the effectiveness of indirect retainers, *J Prosthet Dent* 38:494–506, 1977.
- Frantz WR: Variations in a removable maxillary partial denture design by dentists, *J Prosthet Dent* 34:625–633, 1975.
- Ghamrawy E: Oral ecologic response caused by removable partial dentures, *J Dent Res* (IADR abstract 2898) 61:entire issue, 1982.
- Ghamrawy E: Plaque formation and crevicular temperature relation to minor connector position, *J Dent Res* (IADR abstract 387) 61:entire issue, 1982.
- Giradot RL: History and development of partial denture design, *J Am Dent Assoc* 28:1399–1408, 1941.
- Hansen CA: Metal minibases in removable prosthodontics, *J Prosthet Dent* 54:442–446, 1985.
- Hansen CA, Campbell DJ: Clinical comparison of two mandibular major connector designs: the sublingual bar and the lingual plate, *J Prosthet Dent* 54:805–809, 1985.
- Henderson D: Major connectors for mandibular removable partial dentures, *J Prosthet Dent* 30:532–548, 1973.
- Henderson D: Major connectors: united it stands, *Dent Clin North Am* 17:661–668, 1973.
- Hero H, et al.: Ductility and structure of some cobalt-base dental casting alloys, *Biomaterials* 5:201–208, 1984.
- Highton R, Caputo AA, Rhodes S: Force transmission and retentive capabilities utilizing labial and palatal I-bar partial dentures, *J Dent Res* (IADR abstract 1214) 60:entire issue, 1981.
- Iwama CY, et al.: Cobalt-chromium-titanium alloy for removable partial dentures, *Int J Prosthodont* 10:309–317, 1997.
- Jacobson TE: Rotational path partial denture design: a 10-year clinical follow-up. Parts I and II, *J Prosthet Dent* 71:271–282, 1994.
- Jacobson TE, Krol AJ: Rotational path removable partial denture design, *J Prosthet Dent* 48:370–376, 1982.
- Jordan LG: Designing removable partial dentures with external attachments (clasps), *J Prosthet Dent* 2:716–722, 1952.

- Kapur KK, et al.: A randomized clinical trial of two basic removable partial denture designs. Part I. Comparisons of five-year success rates and periodontal health, *J Prosthet Dent* 72:268–282, 1994.
- Kelly EK: The physiologic approach to partial denture design, *J Prosthet Dent* 3:699–710, 1953.
- King GE: Dual-path design for removable partial dentures, *J Prosthet Dent* 39:392–395, 1978.
- King GE, Barco MT, Olson RJ: Inconspicuous retention for removable partial dentures, *J Prosthet Dent* 39:505–507, 1978.
- Knodle JM: Experimental overlay and pin partial denture, *J Prosthet Dent* 17:472–478, 1967.
- Ko SH, McDowell GC, Kotowicz WE: Photoelastic stress analysis of mandibular removable partial dentures with mesial and distal occlusal rests, *J Prosthet Dent* 56:454–460, 1986.
- Krikos AA: Artificial undercuts for teeth which have unfavorable shapes for clasping, *J Prosthet Dent* 22:301–306, 1969.
- Lanser A: Telescope retainers for removable partial dentures, *J Prosthet Dent* 45:37–43, 1981.
- Latta GH, et al.: Wear of visible light-cured restorative materials and removable partial denture direct retainers, *J Prosthodont* 6:104–109, 1997.
- LaVere AM, Freda AL: A simplified procedure for survey and design of diagnostic casts, *J Prosthet Dent* 37:680–683, 1977.
- LaVere AM, Krol AJ: Selection of a major connector for the extension base removable partial denture, *J Prosthet Dent* 30:102–105, 1973.
- LaVere AM, Smith RC, Serka RJ: Cross-arch bar splint, *J Prosthet Dent* 67:82–84, 1992.
- Lindquist TJ, et al.: Effectiveness of computer-aided partial denture design, *J Prosthodont* 6:122–127, 1997.
- Lorencki SF: Planning precision attachment restorations, *J Prosthet Dent* 21:506–508, 1969.
- Luk K, et al.: Unilateral rotational path removable partial dentures for tilted mandibular molars, *J Prosthet Dent* 78:102–105, 1997.
- Marxkors R: Mastering the removable partial denture. Part I. Basic reflections about construction, *J Dent Technol* 14:34–39, 1997.
- Marxkors R: Mastering the removable partial denture. Part II. Connection of partial dentures to the abutment teeth, *J Dent Technol* 14:24–30, 1997.
- Maxfield JB, Nicholls JE, Smith DE: The measurement of forces transmitted to abutment teeth of removable partial dentures, *J Prosthet Dent* 41:134–142, 1979.
- McCartney JW: Lingual plating for reciprocation, *J Prosthet Dent* 42:624–625, 1979.
- McCracken WL: Contemporary partial denture designs, *J Prosthet Dent* 8:71–84, 1958.
- McCracken WL: Survey of partial denture designs by commercial dental laboratories, *J Prosthet Dent* 12:1089–1110, 1962.
- McHenry KR, Johansson DE, Christensson LA: The effect of removable partial denture framework design on gingival inflammation: a clinical model, *J Prosthet Dent* 68:799–803, 1992.
- Meeuwissen R, Keltjens HM, Battistuzzi PG: Cingulum bar as a major connector for mandibular removable partial dentures, *J Prosthet Dent* 66:221–223, 1991.
- Monteith BD: Management of loading forces on mandibular distal-extension prostheses. I. Evaluation of concepts for design, *J Prosthet Dent* 52:673–681, 1984.
- Monteith BD: Management of loading forces on mandibular distal-extension prostheses. II. Classification for matching modalities to clinical situations, *J Prosthet Dent* 52:832–836, 1984.
- Myers RE, et al.: A photoelastic study of rests on solitary abutments for distal-extension removable partial dentures, *J Prosthet Dent* 56:702–707, 1986.
- NaBadalung DP, et al.: Frictional resistance of removable partial dentures with retrofitted resin composite guide planes, *Int J Prosthodont* 10:116–122, 1997.
- Naim RI: The problem of free-end denture bases, *J Prosthet Dent* 16:522–532, 1966.
- Navas MTR, del Campo ML: A new free-end removable partial denture design, *J Prosthet Dent* 70:176–179, 1993.
- Pardo-Mindan S, Ruiz-Villandiego JC: A flexible lingual clasp as an esthetic alternative: a clinical report, *J Prosthet Dent* 69:245–246, 1993.
- Perry C: Philosophy of partial denture design, *J Prosthet Dent* 6:775–784, 1956.
- Pienkos TE, et al.: The strength of multiple major connector designs under simulated functional loading, *J Prosthet Dent* 97:299–304, 2007.
- Pipko DJ: Combinations in fixed-removable prostheses, *J Prosthet Dent* 26:481–490, 1971.
- Potter RB, Appleby RC, Adams CD: Removable partial denture design: a review and a challenge, *J Prosthet Dent* 17:63–68, 1967.
- Radford DR, Walter JD: A variation in minor connector design for partial denture, *Int J Prosthet* 6:50–53, 1993.
- Russell MD, Tumer P: A three-part sectional design for an upper removable partial denture with an anterior modification, *Br Dent J* 162:24–26, 1987.
- Rybeck Jr SA: Simplicity in a distal extension partial denture, *J Prosthet Dent* 4:87–92, 1954.
- Schmidt AH: Planning and designing removable partial dentures, *J Prosthet Dent* 3:783–806, 1953.
- Schuyler CH: The partial denture as a means of stabilizing abutment teeth, *J Am Dent Assoc* 28:1121–1125, 1941.
- Schwartz RS, Murchison DG: Design variations of the rotational path removable partial denture, *J Prosthet Dent* 58:336–338, 1987.
- Seals Jr RR, Schwartz IS: Successful integration of fixed and removable prosthodontics, *J Prosthet Dent* 53:763–766, 1985.
- Shifman A: Use of an Adam's clasp for a cast unilateral removable partial denture, *J Prosthet Dent* 61:703–705, 1989.
- Shohet H: Relative magnitudes of stress on abutment teeth with different retainers, *J Prosthet Dent* 21:267–282, 1969.
- Steffel VL: Fundamental principles involved in partial denture design, *J Am Dent Assoc* 42:534–544, 1951.
- Steffel VL: Simplified clasp partial dentures designed for maximum function, *J Am Dent Assoc* 32:1093–1100, 1945.
- Sykora O: Removable partial denture design by Canadian dental laboratories: a retrospective study, *J Can Dent Assoc* 61:615–621, 1995.
- Sykora O, Calikocoglu S: Maxillary removable partial denture designs by commercial dental laboratories, *J Prosthet Dent* 22:633–640, 1970.
- Tautin FS: Abutment stabilization using a nonresilient gingival bar connector, *J Am Dent Assoc* 99:988–998, 1979.
- Thompson WD, Kratochvil FJ, Caputo AA: Evaluation of photoelastic stress patterns produced by various designs of bilateral distal-extension removable partial dentures, *J Prosthet Dent* 38:261–273, 1977.
- Tsao DH: Designing occlusal rests using mathematical principles, *J Prosthet Dent* 23:154–163, 1970.
- Unger JW, Badr SE: Esthetic placement of bar-clasp direct retainers, *J Prosthet Dent* 56:381–382, 1986.
- Vallittu PK: Comparison of the in vitro fatigue resistance of an acrylic resin removable partial denture reinforced with continuous fibers or metal wires, *J Prosthodont* 5:115–121, 1996.
- Vofa M, Kotowicz WE: Plaque retention with lingual bar and lingual plate major connectors, *J Dent Res* (AADR abstract 609) 59:entire issue, 1980.
- Wagner AC, Traweek FC: Comparison of major connectors for removable partial dentures, *J Prosthet Dent* 47:242–245, 1982.
- Waller NI: The root rest and the removable partial denture, *J Prosthet Dent* 33:16–23, 1975.
- Walter JD: Alternative major connectors for mandibular partial dentures, *Restorative Dent* 2 80:82–84, 1986.
- Warren AB, Caputo AA: Load transfer to alveolar bone as influenced by abutment design for tooth supported dentures, *J Prosthet Dent* 33:137–148, 1975.

Weinberg LA: Lateral force in relation to the denture base and clasp design, *J Prosthet Dent* 6:785–800, 1956.

Williams RJ, et al.: Use of a cast flexible plate as a hinge substitute in a hinge-lock design removable partial denture, *J Prosthet Dent* 80:220–223, 1998.

Zach GA: Advantages of mesial rests for removable partial dentures, *J Prosthet Dent* 33:32–35, 1975.

Zoller GN, et al.: Technique to improve surveying in confined areas, *J Prosthet Dent* 73:223–224, 1995.

PERIODONTAL CONSIDERATIONS

Amsterdam M, Fox L: Provisional splinting: principles and technics, *Dent Clin North Am* 3:73–99, 1959.

App GR: Periodontal treatment for the removable partial prosthesis patient: another half century, *Dent Clin North Am* 17:601–610, 1973.

Applegate OC: The interdependence of periodontics and removable partial denture prosthesis, *J Prosthet Dent* 8:269–281, 1958.

Aydinlik E, Dayangac B, Celik E: Effect of splintings on abutment tooth movement, *J Prosthet Dent* 49:477–480, 1983.

Bates JF, Addy M: Partial dentures and plaque accumulation, *J Dent* 6:285–293, 1978.

Bazirgan MK, Bates JF: Effect of clasp design on gingival health, *J Oral Rehabil* 14:271–281, 1987.

Becker CM, Kaldahl WB: Using removable partial dentures to stabilize teeth with secondary occlusal traumatism, *J Prosthet Dent* 47:587–594, 1982.

Berg TE, Caputo AA: Maxillary distal extension removable partial denture abutments with reduced periodontal support, *J Prosthet Dent* 70:245–250, 1993.

Bergman B: Periodontal reactions related to removable partial dentures: a literature review, *J Prosthet Dent* 58:454–458, 1987.

Bergman B, Ericson G: Cross-sectional study of the periodontal status of removable partial denture patients, *J Prosthet Dent* 61:208–211, 1989.

Brill N, et al.: Ecologic changes in the oral cavity caused by removable partial dentures, *J Prosthet Dent* 38:138–148, 1977.

Clarke NG: Treatment planning for fixed and removable partial dentures: a periodontal view, *J Prosthet Dent* 36:44–50, 1976.

Dello Russo NM: Gingival autografts as an adjunct to removable partial dentures, *J Am Dent Assoc* 104:179–181, 1982.

Erperstein H: The role of the prosthodontist in the treatment of periodontal disease, *Int Dent J* 36:18–29, 1986.

Fisher RL, McDowell GC: Removable partial denture design and potential stress to the periodontium, *Int J Periodont Res Dent* 4:34–47, 1984.

Garfield RE: A prosthetic solution to the periodontally compromised/furcation involved abutment tooth, *I, Quintessence Int* 15:805–813, 1984.

Gilson CM: Periodontal considerations, *Dent Clin North Am* 24:31–44, 1980.

Gomes BC, et al.: A clinical study of the periodontal status of abutment teeth supporting swinglock removable partial dentures: a pilot study, *J Prosthet Dent* 46:7–13, 1981.

Gomes BC, Renner RP, Bauer PN: Periodontal considerations in removable partial dentures, *J Am Dent Assoc* 101:496–498, 1980.

Hall WB: Periodontal preparation of the mouth for restoration, *Dent Clin North Am* 24:195–213, 1980.

Hirschfeld Z, et al.: New sustained release dosage form of chlorhexidine for dental use: use for plaque control in partial denture wearers, *J Oral Rehabil* 11:477–482, 1984.

Isidor F, Budtz-Jorgensen E: Periodontal conditions following treatment with cantilever bridges or removable partial dentures in geriatric patients: a 2-year study, *Gerodontology* 3:117–121, 1987.

Ivancie GP: Interrelationship between restorative dentistry and periodontics, *J Prosthet Dent* 8:819–830, 1958.

Jacobson TE: Periodontal considerations in removable partial denture design, *Compendium* 8: 530–534, 536–539, 1987.

Jordan LG: Treatment of advanced periodontal disease by prosthodontic procedures, *J Prosthet Dent* 10:908–911, 1960.

Kimball HD: The role of periodontia in prosthetic dentistry, *J Prosthet Dent* 1:286–294, 1951.

Krogh-Poulsen W: Partial denture design in relation to occlusal trauma in periodontal breakdown, *Int Dent J* 4:847–867, 1954; also *Acad Rev* 3:18–23, 1955.

McKenzie JS: Mutual problems of the periodontist and prosthodontist, *J Prosthet Dent* 5:37–42, 1955.

Morris ML: Artificial crown contours and gingival health, *J Prosthet Dent* 12:1146–1155, 1962.

Nevin RB: Periodontal aspects of partial denture prosthesis, *J Prosthet Dent* 5:215–219, 1955.

Orban BS: Biologic principles in correction of occlusal disharmonies, *J Prosthet Dent* 6:637–641, 1956.

Overby GE: Esthetic splinting of mobile periodontally involved teeth by vertical pinning, *J Prosthet Dent* 11:112–118, 1961.

Perel ML: Periodontal consideration of crown contours, *J Prosthet Dent* 26:627–630, 1971.

Picton DCA, Wills DJ: Viscoelastic properties of the periodontal ligament and mucous membrane, *J Prosthet Dent* 40:263–272, 1978.

Rissin L, et al.: Effect of age and removable partial dentures on gingivitis and periodontal disease, *J Prosthet Dent* 42:217–223, 1979.

Rudd KD, O’Leary TJ: Stabilizing periodontally weakened teeth by using guide plane removable partial dentures: a preliminary report, *J Prosthet Dent* 16:721–727, 1966.

Schuyler CH: The partial denture and a means of stabilizing abutment teeth, *J Am Dent Assoc* 28:1121–1125, 1941.

Schwalm CA, Smith DE, Erickson JD: A clinical study of patients 1 to 2 years after placement of removable partial dentures, *J Prosthet Dent* 38:380–391, 1977.

Seibert JS, Cohen DW: Periodontal considerations in preparation for fixed and removable prosthodontics, *Dent Clin North Am* 31:529–555, 1987.

Spiekermann H: Prosthetic and periodontal considerations of free-end removable partial dentures, *Int J Periodont Restor Dent* 6:148–163, 1986.

Sternlicht HC: Prosthetic treatment planning for the periodontal patient, *Dent Abstr* 2:81–82, 1957.

Stipho HDK, Murphy WM, Adams D: Effect of oral prostheses on plaque accumulation, *Br Dent J* 145:47–50, 1978.

Talkov L: Survey for complete periodontal prosthesis, *J Prosthet Dent* 11:124–131, 1961.

Tebrock OC, et al.: The effect of various clasping systems on the mobility of abutment teeth for distal-extension removable partial dentures, *J Prosthet Dent* 41:511–516, 1979.

Thayer HH, Kratochvil FJ: Periodontal considerations with removable partial dentures, *Dent Clin North Am* 24:195–213, 1980.

Thomas BOA, Gallager JW: Practical management of occlusal dysfunctions in periodontal therapy, *J Am Dent Assoc* 46:18–31, 1953.

Trapozzano VR, Winter CR: Periodontal aspects of partial denture design, *J Prosthet Dent* 2:101–107, 1952.

Waerhaug J: Justification for splinting in periodontal therapy, *J Prosthet Dent* 22:201–208, 1969.

Ward HL, Weinberg LA: An evaluation of periodontal splinting, *J Am Dent Assoc* 63:48–54, 1961.

PHYSIOLOGY: MANDIBULAR MOVEMENT

Brekke CA: Jaw function. I. Hinge rotation, *J Prosthet Dent* 9:600–606, 1959. II. Hinge axis, hinge axes, 9:936–940, 1959; III. Condylar placement and condylar retrusion, 10:78–85, 1960.

Brotman DN: Contemporary concepts of articulation, *J Prosthet Dent* 10:221–230, 1960.

Budtz-Jorgensen E: Restoration of the occlusal face height by removable partial dentures in elderly patients, *Gerodontology* 2:67–71, 1986.

Emig GE: The physiology of the muscles of mastication, *J Prosthet Dent* 1:700–707, 1951.

Fountain HW: The temporomandibular joints: a fulcrum, *J Prosthet Dent* 25:78–84, 1971.

Gibbs CH, et al.: Functional movements of the mandible, *J Prosthet Dent* 26:604–620, 1971.

Jankelson B: Physiology of human dental occlusion, *J Am Dent Assoc* 50:664–680, 1955.

Jemt T, Hedegard B, Wickberg K: Chewing patterns before and after treatment with complete maxillary and bilateral distal-extension mandibular removable partial dentures, *J Prosthet Dent* 50:566–569, 1983.

Kurth LE: Centric relation and mandibular movement, *J Am Dent Assoc* 50:309–315, 1955.

Kurth LE: Mandibular movement and articulator occlusion, *J Am Dent Assoc* 39:37–46, 1949.

McMillen LB: Border movements of the human mandible, *J Prosthet Dent* 27:524–532, 1972.

Messerman T: A concept of jaw function with a related clinical application, *J Prosthet Dent* 13:130–140, 1963.

Naylor JG: Role of the external pterygoid muscles in temporomandibular articulation, *J Prosthet Dent* 10:1037–1042, 1960.

Plotnick IJ, Beresin VE, Simkins AB: The effects of variations in the opposing dentition on changes in the partially edentulous mandible. I. Bone changes observed in serial radiographs, *J Prosthet Dent* 33:278–286, 1975.

Plotnick IJ, Beresin VE, Simkins AB: The effects of variations in the opposing dentition on changes in the partially edentulous mandible. III. Tooth mobility and chewing efficiency with various maxillary dentitions, *J Prosthet Dent* 33:529–534, 1975.

Posselt U: Movement areas of the mandible, *J Prosthet Dent* 7:375–385, 1957.

Posselt U: Studies in the mobility of the human mandible, *Acta Odontol Scand* 10:19–160, 1952.

Posselt U: Terminal hinge movement of the mandible, *J Prosthet Dent* 7:787–797, 1957.

Saizar P: Centric relation and condylar movement, *J Prosthet Dent* 26:581–591, 1971.

Schweitzer JM: Masticatory function in man, *J Prosthet Dent* 11:625–647, 1961.

Shanahan TEJ: Dental physiology for dentures: the direct application of the masticatory cycle to denture occlusion, *J Prosthet Dent* 2:3, 1952.

Shore NA: Educational program for patients with temporomandibular joint dysfunction (ligaments), *J Prosthet Dent* 23:691–695, 1970.

Sicher H: Positions and movements of the mandible, *J Am Dent Assoc* 48:620–625, 1954.

Skinner CN: Physiology of the occlusal coordination of natural teeth, complete dentures, and partial dentures, *J Prosthet Dent* 17:559–565, 1967.

Sostenbo HR: CE Luce's recordings of mandibular movement, *J Prosthet Dent* 11:1068–1073, 1961.

Tallgren A, Mizutani H, Tryda G: A two-year kinesiograph, study of mandibular movement patterns in denture wearers, *J Prosthet Dent* 62:594–600, 1989.

Ulrich J: The human temporomandibular joint: kinematics and actions of the masticatory muscles, *J Prosthet Dent* 9:399–406, 1959.

Vaughan HC: The external pterygoid mechanism, *J Prosthet Dent* 5:80–92, 1955.

## REBASING AND RELINING

Blatterfein L: Rebasing procedures for removable partial dentures, *J Prosthet Dent* 8:441–467, 1958.

Bolouri A, et al.: A procedure for relining a complete or removable partial denture without the use of wax, *J Prosthet Dent* 79:604–606, May 1998.

Breeding LC, Dixon DL, Lund TS: Dimensional changes of processed denture bases after relining with three resins, *J Prosthet Dent* 66:650–656, 1991.

Grady RD: Objective criteria for relining distal-extension removable partial dentures: a preliminary report, *J Prosthet Dent* 49:178–181, 1983.

McGivney GP: A relined technique for extension base removable partial dentures. In Lefkowitz W, editor: *Proceedings of the Second International Prosthodontic Congress*, St Louis, 1979, Mosby.

Steffel VL: Relining removable partial dentures for fit and function, *J Prosthet Dent* 4:496–509, 1954.

Turck MD, Richards MW: Microwave processing for denture relines, repairs, and rebases, *J Prosthet Dent* 69:340–343, 1993.

Wilson JH: Partial dentures: relining the saddle supported by the mucosa and alveolar bone, *J Prosthet Dent* 3:807–813, 1953.

Yasuda N, et al.: New adhesive resin to metal in removable prosthodontics field, *J Dent Res* (IADR abstract 213) 59:entire issue, 1980.

## STRESS-BREAKER DESIGNS

Bartlett AA: Duplication of precision attachment partial dentures, *J Prosthet Dent* 16:1111–1115, 1966.

Bickley RW: Combined splint-stress breaker removable partial denture, *J Prosthet Dent* 21:509–512, 1969.

Cecconi BT, Kaiser C, Rahe A: Stress-breakers and the removable partial denture, *J Prosthet Dent* 34:145–151, 1975.

Hansen CA, Singer MT: The segmented framework removable partial denture, *J Prosthet Dent* 47:765–768, 1987.

Hirschtritt E: Removable partial dentures with stress-broken extension bases, *J Prosthet Dent* 7:318–324, 1957.

James AC: Stress-breakers which automatically return the saddle to rest position following displacement: mandibular distal extension partial dentures, *J Prosthet Dent* 4:73–81, 1954.

Kabcenell JL: Stress-breaking for partial dentures, *J Am Dent Assoc* 63:593–602, 1961.

Kane BE: Buoyant stress equalizer, *J Prosthet Dent* 14:698–704, 1964.

Kane BE: Improved buoyant stress equalizer, *J Prosthet Dent* 17:365–371, 1967.

Levin B: Stress-breakers: a practical approach, *Dent Clin North Am* 23:77–86, 1979.

Levitch HC: Physiologic stress-equalizer, *J Prosthet Dent* 3:232–238, 1953.

MacGregor AR: Stress-breaking in partial dentures, *Aust Prosthodont Soc Bull* 16:65–70, 1986.

Marris FN: The precision dowel rest attachment, *J Prosthet Dent* 5:43–48, 1955.

Neill DJ: The problem of the lower free-end removable partial denture, *J Prosthet Dent* 8:623–634, 1958.

Plotnik IJ: Stress regulator for complete and partial dentures, *J Prosthet Dent* 17:166–171, 1967.

Reitz PV, Caputo AA: A photoelastic study of stress distribution by a mandibular split major connector, *J Prosthet Dent* 54:220–225, 1985.

Reitz PV, Sanders JL, Caputo AA: A photoelastic study of a split palatal major connector, *J Prosthet Dent* 51:19–23, 1984.

Simpson DH: Considerations for abutments, *J Prosthet Dent* 5:375–384, 1955.

Terrell WH: Split bar technique applicable to both precision attachment and clasp cases, *J South Calif Dent Assoc* 9:10–14, 1942.

Zinner ID: A modification of the Thompson Dowel rest for distal-extension removable partial dentures, *J Prosthet Dent* 61:374–378, 1989.

## SURVEYING

Applegate OC: Use of paralleling surveyor in modern partial denture construction, *J Am Dent Assoc* 27:1317–1407, 1940.

Atkinson HF: Partial denture problems: surveyors and surveying, *Aust J Dent* 59:28–31, 1955.

Bezzon OL, et al.: Surveying removable partial dentures: the importance of guiding planes and path of insertion for stability, *J Prosthet Dent* 78:412–418, 1997.

Chestner SC: A methodical approach to the analysis of study cases, *J Prosthet Dent* 4:622–624, 1954.

Hanson JC: Surveying, *J Am Dent Assoc* 91:826–828, 1975.

Katulski EM, Appleyard WN: Biological concepts of the use of the mechanical cast surveyor, *J Prosthet Dent* 7:627–634, 1959.

Knapp JC, Shotwell JL, Kotowicz WE: Technique for recording dental cast-surveyor relations, *J Prosthet Dent* 41:352–354, 1979.

McCarthy MF: An intraoral surveyor, *J Prosthet Dent* 61:462–464, 1989.

Solle W: An improved dental surveyor, *J Am Dent Assoc* 60:727–731, 1960.

Wagner AC, Forque EC: A study of four methods of recording the path of insertion of removable partial dentures, *J Prosthet Dent* 35:267–272, 1976.

Yilmaz C: Optical surveying of casts for removable partial dentures, *J Prosthet Dent* 34:292–296, 1975.

Zoller GN, et al.: Technique to improve surveying in confined areas, *J Prosthet Dent* 73:223–224, Feb 1995.

## WORK AUTHORIZATIONS

Brown ET: The dentist, the laboratory technician, and the prescription law, *J Prosthet Dent* 15:1132–1138, 1965.

Dutton DA: Standard abbreviations (and definitions) for use in dental laboratory work authorizations, *J Prosthet Dent* 27:94–95, 1972.

Gehl DH: Investment in the future, *J Prosthet Dent* 18:190–201, 1968.

Henderson D: Writing work authorizations for removable partial dentures, *J Prosthet Dent* 16:696–707, 1966.

Henderson D, Frazier Q: Communicating with dental laboratory technicians, *Dent Clin North Am* 14:603–615, 1970.

Leeper SH: Dentist and laboratory: a love-hate relationship, *Dent Clin North Am* 23:87–99, 1979.

Quinn L: Status of the dental laboratory work authorization, *J Am Dent Assoc* 79:1189–1190, 1969.

Travaglini EA, Jannetto LB: A work authorization format for removable partial dentures, *J Am Dent Assoc* 6:429–431, 1978.

# Index

- A**
- Abutment teeth**  
 cast restorations for, 209  
 classification of, 207  
 contoured, 28f  
 contouring wax pattern of, 201f, 204–205  
 crowns for, 209–213, 209f–210f  
 damage to, 296  
 decay of, 296  
 with guarded prognoses, 182, 183f  
 isolated, 215f  
 ledges on abutment crowns and, 210–212, 210f–212f  
 lever action on, 114f  
 loss of, 148–149  
 with missing anterior teeth, 215–216  
 modification of natural, 60f  
 occlusal force on, 59f  
 occlusal rests on secondary, 98  
 preparation of, 117, 206–218  
   contouring, 208f  
   in sound enamel, 207, 208f  
 prognosis for service of, 173f  
 protection of, 81  
 rest seats in, 205  
 restorations of, 200f, 202–204  
 retention on terminal, 38f  
 sound, 182  
 spark erosion and, 212  
 splinting of, 213–214, 213f–214f  
 strain on, 10  
 support characteristics of, 23  
 temporary crowns and, 216  
 tipped/tilted  
   cast evaluation of, 59f  
   rest preparation with, 59  
 unprotected, 207  
 use of isolated teeth as, 214–215, 215f  
 using conservative restorations, 207–208  
 veneer crowns on, 212–213, 213f  
 vulnerable area of, 203
- Accuracy of form, of denture bases, 104–105**
- Acquired immunodeficiency syndrome (AIDS) virus, infection control of, 178**
- Acrylic-resin bases, 102, 247, 247f**  
 waxing and investing removable partial denture before processing, 273–276
- Acrylic-resin impression trays, technique for making, 226–228, 227f–230f**
- Acrylic-resin record base, sprinkled, technique for making, 267–268, 267f–269f**
- Acrylic-resin teeth, 250–251**  
 occlusion on, 107
- Acrylic-resin temporary crowns, 216**
- Additions to removable partial dentures, 307, 308f**
- Adhesion forces, 101**
- Adjacent tooth-tissue contours, 281f**
- Adjustments**  
 to bearing surfaces of denture bases, 290–291, 290f  
 final, 290  
 follow-up services for, 296  
 to interim removable partial dentures, 313f  
 to major and minor connectors, 306–307  
 occlusal. *see* Occlusal adjustments  
 of occlusion, with natural and artificial dentition, 291–294, 292f–293f  
 patient instructions for, 294–296  
 of removable partial denture, 289–296  
 to tipped/tilted abutment teeth, 138f
- Agar-agar, 219–220**
- Age, tooth loss and, 4–5**
- Alloplastic materials, 192–193**
- Alloys. *see also* Metal alloys**  
 chromium-cobalt, 263  
 for soldering, 306–307
- Alveolar bone, augmentation of, 192–193**
- Alveolar lamina dura, 171–173**
- Alveolar osteotomy, 324**
- Alveolar ridge, undercut, 142–144, 144f**
- American Dental Association (ADA) specification, No.7, 187t**
- Anatomic consequences, of tooth loss, 5**
- Anatomic form impression, 236**
- Anatomic ridge, 14f**
- Angle of cervical convergence, 84, 84f**
- Anterior ridge defect, 181f**
- Anterior teeth**  
 age and loss of, 4  
 replacement of, 215–216  
 types of, 272–273
- Anterior-posterior palatal strap-type major connector, 40–41, 40f, 54**
- Appearance. *see* Esthetics.**
- Applegate's rules, for applying Kennedy classification, 20**
- Arbitrary blockout, 144, 144t–145t**
- Arbitrary point or axis, 164**
- Arches**  
 Class I, II, III, IV, 94f  
 partially edentulous, classification of, 16–20  
 Applegate's rules for applying Kennedy classification in, 20  
 confusion and disagreement about, 16–17  
 examples of, 17f, 19f  
 requirements for acceptable, 17
- Arm, clasp**  
 assembly parts, function and position of, 84t  
 cross-sectional form of, 89  
 diameter of, 88  
 flexing action of, 68f  
 length of, 88, 88t  
 material used for, 89  
 reciprocal arms, 78f  
   counteraction of reciprocation, 68f  
   functions of, 69–70, 210  
   incorrect relationship of retentive and, 210f  
   rigidity of, 90f  
 retentive arms, 73f, 79f  
   cast clasp, 88f  
   casting of, 111  
   engagement of undercut with, 79f  
   incorrect relationship of reciprocal and, 210f  
   stabilizing-reciprocal cast, 89  
   uniformity of retention, 89
- Arrangements, of tooth, establishment and verification of, 13–14**
- Articulation paper, 292**
- Articulation ribbon, 293–294**
- Articulator, 163, 291**
- Artificial dentition, adjustment of occlusion with, 291–294**
- Artificial teeth**  
 after occlusal adjustment, 294  
 attachment to denture bases, 102, 106–108, 107f  
   with acrylic resin, 106  
   metal, 108  
   with porcelain/acrylic-resin, 106–107  
   with resin, 107–108, 108f  
 esthetics for, 135  
 framework for supporting, 107  
 implants. *see* Implants  
 porcelain, 106  
 ready made, 106–107  
 reattaching, 303  
 reorientation of, 110  
 resin, 302–303  
 torch soldering and, 308–309  
 using smaller, 118f
- Ascending ramus, 244f**
- Atmospheric pressure, 101**
- Atrophy, of tissues, 99**
- Attachments**  
 of artificial teeth to bases. *see under* artificial teeth  
 of facings, 106–107  
 internal. *see* Internal attachments

- Attachments (*Continued*)  
 internal clip, 125–126  
 locking internal, 91  
 muscle, 191  
 position for Classification II, removable  
   partial dentures, 92f  
 of resin denture bases, 102f  
 resin tube teeth, 106–107, 107f  
 rigid, 26f
- Augmentation, of alveolar bone, 192–193
- Authorization, work. *see* Work authorization
- Autopolymerizing resin, 299
- Auxiliary occlusal rest, 95f, 96–97
- Axial surfaces, recontouring of, 62f
- Axis of rotation, 92f, 95f  
 horizontal, 27f  
 longitudinal, 24, 25f  
 vertical, 25f, 26
- Axle, 23, 23f
- B**
- Ball types of rests, 64
- Ball-and-socket relationship, 205
- Bar retainer, 76f
- Bar-type clasp assemblies, 72–78, 74f–76f  
 contraindications for, 77f  
 errors and corrections in, 77f  
 extracoronal, 73f  
 I-bar, 79f  
 indications for, 76–77  
 length of, 88  
 one-half T-type, 79f  
 retentive clasp arms, 79f  
 use of bar clasp arm, 76f
- Bar-type retentive arms, 124f
- Baseplate wax, 302–303  
 thickness of, 237f–238f
- Bases. *see* Denture bases.
- Beading, of maxillary cast, 45, 45f–47f
- Beading line, 46f
- Bearing areas, outline of, 42, 43f
- Bearing surfaces, 290–291
- Bilateral balanced occlusion, 243, 243f
- Bilateral distal extension mandibular removable partial denture, 243f
- Biomechanics  
 of cantilever, 26f  
 considerations for, 22  
 and design solutions, 21–22  
 of impact of implants on movements of partial dentures, 22  
 length of lever and, 26f  
 of possible movements of partial dentures, 24–28  
 of removable partial dentures, 21–28  
 simple machines and, 23–24, 23f
- Blanks, work authorization, 287
- Blockout, 141, 254, 280f  
 paralleled, 144  
 shaped, 144
- Blockout wax, 133f
- Boil out, 276
- Bonding, chemical, 108, 109f
- Bone augmentation, 192–193
- Bone density, 170–171
- Bone grafts, 200f, 326–327
- Bone loss, 181f, 182
- Bony enlargements, exostoses and tori, 190
- Bony mandibular residual ridge, crest of, 232
- Bony ridge, 236
- Bony spines, 191
- Bony undercuts, 137
- Brånemark system, 192f
- Buccal guide bar, 335
- Buccal retention, *versus* lingual, 79
- Buccal surface modification, 177f
- Bulk, feeling of, 311f
- Bulk of denture bases, 105
- Burnout operation, 264, 265f
- C**
- Calculus, 196  
 on acrylic-resin bases, 105  
 removal of, 196  
 salivary, 295
- Canine abutments, 213
- Canine crowns, 134f
- Canine extensions, 97, 97f
- Canine guidance, establishing, 248–249
- Canine rests, 97
- Canines, lingual rests on, 63–65
- Cantilever, 23, 26f
- Cantilever design, 23, 26f
- Carbon markers, 140
- Caries  
 beneath clasp components, 10  
 control of, 156  
 oral hygiene for protection from, 296  
 risk assessment for, 4t  
 susceptibility, 158–160
- Cariou lesions, 196
- Cast metal bases, 104. *see also* Gold/gold alloys; Metal alloys
- Cast molar designs, maxillary, 108f
- Cast restorations, machining, 133
- Cast retentive arms, 114–115
- Cast support, 166
- Casts/casting, 264, 265f. *see also* impression-related entries; Laboratory procedures  
 abutment teeth, diagnostic cast  
   evaluation of, 59f  
 anatomic and functional ridge forms, 234f  
 dental cast surveyor, 12, 13f  
 diagnostic, 162f, 226  
 finished, 47f  
 finishing and polishing of, 264–265, 267f  
 inaccurate and/or weak, 225  
 making of, 218f  
 milling of, 212f  
 mounted maxillary, 169f  
 preparation of base of, 165f  
 reciprocal arms, 78f  
 remounting, 280f  
 removal of, from investment, 264, 265f–266f  
 of residual ridges, 119f  
 solid cast example, 209f  
 tissue side of, 47f  
 trimming of, 225
- Cementation, of temporary crowns, 216
- Centers for Disease Control (CDC), infection control procedures, 177
- Centric relations  
 materials and methods for recording, 167–168, 168f–169f  
 recording of, on record bases, 248
- Ceramic veneer crowns, surveying, 132
- Cervical convergence  
 angle of, 84f  
 size of and distance into angle of, 85–88
- “Chain of infection,” 178
- Chewing stroke, 294
- Chewing studies, 147. *see also* Mastication
- Chrome alloys, 108
- Chromium-cobalt alloys, 125, 263
- Cingulum (continuous) bars, 31f, 33f, 36, 37f, 53  
 functions of, 122  
 linguoplates and, 97
- Circumferential clasps, 71f, 79–81, 80f
- Clasp arm  
 broken, 304–305, 305f  
 relationship of retentive and reciprocal, 210f  
 veneer crowns for support of, 212–213, 213f
- Clasp arm assemblies  
 arm functions, 69–70  
 cross-sectional form of, 89  
 diameter of, 88  
 flexing action of, 68f  
 function and position of, 84t  
 length of arm, 88  
 material used for, 89  
 position of, 57  
 uniformity of retention, 89  
 vertical occlusal forces on, 91f
- Clasp retention, 320, 333  
 amount of, 86f  
 uniformity of, 89
- Clasp-retained partial dentures, reasons for failure of, 14–15
- Clasps/clasp assemblies  
 amount of retention of, 84–89  
 analysis of tooth contours for, 83–84  
 assembly types, 48f  
 bar-type, 68f, 70f, 74f–75f  
 bilateral opposition of retentive clasps, 69f  
 cast, 124  
 circumferential clasps. *see* Circumferential clasps  
 design of  
   to accommodate functional movement, 72–79  
   basic principles of, 68–70  
   criteria for selecting, 71  
 embrasure, 81, 83f  
 fitting crowns inside, 216  
 function and position of, 84t  
 hairpin clasps, 79f  
 placement of, 28f  
 ring, 80–81, 82f  
 RPI, RPA, and bar clasps, 72–78  
 types of, 71–81

- Classification of partially edentulous arches, 16–20  
 Applegate's rules for applying Kennedy classification in, 20  
 confusion and disagreement about, 16–17  
 examples of, 17f, 19f  
 Kennedy method of classification. *see* Kennedy classifications  
 requirements for acceptable, 17  
 Clenching and grinding, 198f  
 Clinical examination, 156–157  
 Clinical procedures, for occlusal adjustment, 292f–293f  
 Cohesion, 101  
 Color-code index, on master cast, 287–288  
 Combination clasps, 78–79, 78f, 115  
 Combination tooth- and tissue-supported removable partial dentures, 115  
 Comfort issues  
   impingement. *see* Impingement problems  
   implants and, 151f  
   relief of pain and discomfort, 157  
   transfer of forces for, 99  
 Commercially pure (CP) titanium, 186  
 Complete coverage restorations, 207  
 Complete palatal coverage major connector, 42f, 54–55  
 Component parts, adding of, 35  
 Composite resins, 216  
 Composite support, 117  
 Conditioning  
   of abused and irritated tissues, 200–201, 202f  
   teeth and residual ridges, 311–312  
 Connectors, major and minor, repairs to, 306–307  
 Conservative restorations, 207–208  
 Continuous bars. *see* Cingulum (continuous) bars  
 Contour height, 83–84, 131f, 139f, 177f  
 Contouring of abutment teeth. *see* Abutment teeth; Recontouring  
 Contouring wax patterns, 131, 131f, 201f, 204–205  
 Contours  
   of denture bases for contact with tongue, 105  
   residual ridge of, 232–233  
   tooth  
     analysis of, 83–84  
     ineffective, 87f  
     unfavorable, 38  
     tooth-tissue, 281f  
 Cosmetic considerations. *see* Esthetics  
 CP (commercially pure) titanium, 186  
 Cross-arch framework, stability of, 244f  
 Cross-arch stability, 29  
 Crown restorations, 121  
   canine crown in, 134f  
   metal-ceramic, 132f  
   surveyed crowns vs. implants, 148  
 Crowns  
   for abutment teeth, 209–213, 209f–210f  
   fitting crowns inside clasps, 216  
   ledges on abutment, 210–212, 210f–212f  
 Crowns (*Continued*)  
   making of cast crown to fit an existing removable partial denture clasp, 218f  
   metal ceramic, 209f–210f  
   restoration of multiple, 209  
   temporary, 216  
   three-quarter, 209  
   veneer  
     esthetic, 202  
     porcelain, 213f  
     for support of clasp arms, 212–213  
 Cysts, 189–190
- D**  
 Decision making  
   for implant use in stability, 148  
   influence of patient interview on, 169  
   position choices for surveying, 136f  
   shared, 9, 156  
   using anterior segment on denture, 215  
   using isolated teeth as abutments, 214–215  
 Deformity, dentofacial, 191  
 Deglutition, 324  
 Dental arch, shortened, 6, 179–181  
 Dental cast surveyor, 12, 13f  
 Dental casting, factors that influence, 262b  
 Dental health care worker (DHCW), 177  
 Dental implants, methods for incorporating, 103, 104f  
 Dental laboratory technicians, 288  
 Dental surveyor, 127. *see also* Surveyors/surveying  
   description of, 128–129  
   errors when repositioning casts on, 140  
   Jelenko, 128, 128f  
   Ney, 128, 128f  
   purposes of, 129–133  
 Dentist-patient relationship, failure of, 15  
 Dentofacial deformity, 191  
 Denture  
   overlay abutments for support of, 126  
   polishing, 280–282  
   processing, 276–279  
 Denture bases  
   accuracy of fit of, 235  
   accuracy of form of, 117–118  
   adjustments to, 290–291  
   attaching artificial teeth to, 106–108  
   considerations, 99–111  
   contours for tongue/cheek contact, 105  
   distal extension. *see* Distal extension denture bases  
   form of, accuracy and permanence of, 104–105  
   functions of, in control of prosthesis movement, 99–102  
   ideal material for, 103  
   methods for incorporating dental implants in, 103, 104f  
   methods of attaching, 102–103  
   need for relining, 109–110  
   partial  
     distal extension, 100–102, 109  
     tooth-supported, 99–100  
   purpose of, 99  
 Denture bases (*Continued*)  
   stress-breakers (stress equalizers), 110–111, 111f  
   support for, 15  
   tissue side of, 202f  
   weight and bulk of, 105, 105f  
 Denture bearing foundation, 201f  
 Denture borders, 280–281  
 Design  
   additional considerations influencing, 125–126  
   biomechanics and, 21–22  
   of clasps, 137–138  
   component partials for support, 126  
   direct retainer assemblies, 60f  
   for distal extension removable partial denture, 26f  
   framework, 331  
   implant considerations in, 122  
   and internal clip attachment, 125–126  
   for intraoral prostheses, 322  
   Kennedy classifications. *see* Kennedy classifications  
   mandibular major connectors, 36, 37f  
   for maxillary connectors, 42–43, 43f  
   for minor connectors, 120–121  
   objectionable, 44f  
   with questionable abutment, 206  
   rationale for, 22  
   systematic approach to, 122–125, 123t  
   and use of splint bar, 125, 126f  
 DHCW. *see* Dental health care worker (DHCW)  
 Diagnosis, 154–187. *see also* Treatment planning  
   for clasp-retained partial dentures, 15  
   clinical examination and, 156–157  
   oral examinations, 157–161  
   prosthodontic treatment objectives for, 156–157  
   diagnostic casts and, 161–168  
     jaw relationship records for, 166–167  
     mounting of, 163, 163f  
     purposes of, 161–163, 162f–163f  
     recording centric relation and, 167–168, 168f–169f  
   differential diagnosis, 178–183, 178f  
     indications for removable partial dentures, 181–183  
     use of fixed restorations, 179–181  
   findings of, 169  
   infection control and, 177–178  
   interpretation of examination data in, 169–177  
     caries risk assessment, 173–174  
     determination of mandibular major connector, 176  
     distal extension spaces, 175  
     endodontic treatment, 175  
     fixed restorations, 176  
     longer modification spaces, 175  
     occlusal factors, 175–176  
     orthodontic treatment, 176  
     periodontal considerations, 173  
     prosthesis foundation, 174  
     radiographic, 170–173

- Diagnosis (*Continued*)  
 reshaping remaining teeth and, 176–177, 177f  
 short modification spaces and, 175  
 surgical preparation and, 174–175  
 of loss of occlusion, 110  
 for oral rehabilitation, 156  
 patient interview in, 155–156  
 periodontal, 195  
 phase, of partial denture service, 12  
 for pulpal involvement, 189f  
 recording pertinent data and, 158f–159f  
 waxing for management of replacement teeth, 180f  
 working chart for, 160f
- Diagnostic casts  
 red pencil marks on, 138, 138f  
 surveying, 130, 130f, 135–138, 135f, 138f–139f
- Diagnostic criteria, for classification of partially edentulous arches, 16
- Diagnostic procedures, preoperative, for maxillary defects, 322–323
- Diatoric holes, 106
- Direct retainers, 3f–4f, 24, 60f, 67–92  
 amount of retention of, 84–89  
 analysis of tooth contours for, 83–84  
 clasp-type. *see* Clasps/clasp assemblies  
 description of, 67  
 design considerations for, 117  
 for distal extension partial dentures, 120  
 extracoronaral, 73f  
 fractured, 305f  
 functions of, 116–117  
 implants as, 81–83  
 internal attachments, 90–91  
 advantages of, 90  
 disadvantages of, 90  
 nonlocking, 92f  
 principle of, 90  
 types of, 91  
 mechanical laws of, 69f  
 reciprocal arm functions and, 69–70  
 replacement and making, 307  
 role in control of prosthesis movement, 67–68  
 selecting a design, 71  
 for tooth-supported prosthesis, 119–120  
 types of, 70–71
- Direction, of force, 22
- Discomfort  
 interim prosthetic complications and, 320  
 relief of pain and, 157
- Discontinuous mandible, 325–326
- Disease management, 169–170
- Disease validation, 170
- Dislodging forces, 24
- Displaceability, of periodontal ligament, 25f
- Displacement, limiting the freedom of, 68
- Display of courtesy, on work authorization, 286
- Distal extension, obturator prosthesis demonstrating, 324f
- Distal extension denture bases, 13, 94f, 100–102, 109  
 acute dip of, 235f  
 extent of residual ridge coverage by, 233  
 factors influencing support of, 232–236  
 horizontal rotational tendencies of, 144  
 methods for obtaining functional support for, 236–241  
 methods for treating, 234  
 relining, 300–301  
 retention from, 98  
 rotation movement of, 235, 235f  
 support for, 100–101, 231–241  
 underextended, 231
- Distal extension partial dentures  
 direct retainers for, 120  
 support for, 117
- Distal extension removable partial denture, 232  
 design of, 26f, 235–236, 235f  
 rotation of, 23–24, 25f
- Distal extension situations, 181, 181f
- Disto-occlusal rest, 26f
- Distortion, of other components, 306–307
- Disuse atrophy, 99
- Divesting of the framework, 265f
- Double occlusal rests, 79f
- Dovetail internal attachments, 91
- Dual path of placement, 216
- Duplication mold, 255f
- Duration, of force, 22
- E**
- Economic considerations, 183, 215
- Edentulous, partially, epidemiology, physiology, and terminology of, 1–7
- Edentulous arches, partially, classification of, 16–20  
 Applegate's rules for applying Kennedy classification in, 20  
 confusion and disagreement about, 16–17  
 examples of, 17f, 19f  
 requirements for acceptable, 17
- Edentulous mouths, pre-prosthetic considerations in, 189–193
- Education, patient. *see* Patient instructions.
- Effort arm, 26f, 72
- Elastic materials, impression, 219–221  
 irreversible hydrocolloids, 220  
 mercaptan rubber-base, 220  
 polyether, 220  
 reversible hydrocolloids, 219–220  
 silicone, 220–221
- Elastomeric interocclusal registration material, 168, 168f
- Electric soldering, 307
- Electropolishing unit, 266f
- Embrasure clasps, 81, 83f
- Embrasure spaces, 47f
- Enamel, sound, 207
- Enamelplasty procedures, 62f
- Endodontic treatment, 175
- Errors  
 in bar clasp designs, 76–77, 77f  
 improper applications of circumferential clasp design, 81f  
 when repositioning casts on surveyors, 140
- Erythroplasia, 191
- Esthetics  
 and artificial teeth, 135  
 of clasps, 10  
 and denture bases, 100  
 impact of tooth loss and, 5  
 interim removable partial dentures for, 311f  
 with metal bases, 105, 105f  
 path of placement considerations for, 137–138  
 of prosthesis, 9  
 veneer crowns for, 202  
 wrought-wire clasp arms, 78
- Evaluations. *see* Diagnosis.
- Examination, clinical. *see* Clinical examination; Diagnosis.
- Exostoses, 160, 190, 190f
- Extended occlusal rest, 59, 59f–60f
- Extension base removable partial dentures, 10
- Extracoronaral clasp-retained partial denture, 11, 11f
- Extracoronaral retainers, 70–71, 73f. *see also* Clasps/clasp assemblies; Direct retainers  
 misuse of, 83  
 types of, 79f
- Extractions, 174, 181, 189, 189f, 206
- Eyedropper, use of, 268f
- F**
- Fabrication, of partial denture, impression registration for, 114
- Facebow, 163f, 164, 251  
 fork support used with, 166f  
 mounting in, 166f  
 positioning of, 165f
- Facial surfaces, 281–282
- Facings, attaching, 106–107
- Failure of removable partial dentures, 157
- Fee, for examinations, 161
- Finger extension, 97
- Finishing index tissue stop, 51f
- Finishing lines, 48f, 50
- First-class lever, 26f–27f
- Fixation, to teeth, 318f
- Fixed partial dentures, 3f  
 Brånemark system and, 192f  
 preparation of, 127
- Fixed restorations, indications for, 179–181  
 anterior modification spaces, 179, 180f  
 modification spaces, 179  
 replacement of unilaterally missing molars, 179–181, 180f  
 tooth-bounded edentulous regions, 179
- Flap procedures, 198–199
- Flask, duplicating, 254
- Flexibilities of clasp arms  
 chromium-cobalt alloys, 88t  
 Type IV gold alloys, 88t
- Floor height, 161
- Floor taper, for rest seats, 63f
- Flux, in soldering, 307
- Follow-up services, 296
- Food bolus, 6
- Food debris, 76–77

- Food entrapment, 37f  
 Food reduction index, 6  
 Forces  
   on adjacent tooth, 324  
   Boucher's description of, 101  
   direction of, 76f  
   dislodging, 87f, 329–330  
   displacement, 67  
   downward, 143f  
   form of occlusal rests and rest seats, 58  
   functional, 10  
   of gravity, 24  
   horizontal, 26  
   lifting, 86f, 116f  
   locations for resisting, 148  
   masticatory, 73f  
   occlusal, 91f, 116f  
   for retention, 101  
   tolerances of supporting structures and, 22  
   transfer of, 99  
 Fork support, 166f  
 Frameworks/framework design  
   for clasp-retained partial dentures, 15  
   design considerations and principles, 235–236, 235f  
   designs, 258f, 331  
   evaluation of, 239f, 258f  
   fitting, 237–241  
   gold, 194f  
   for major connectors, 30f, 45f  
   mandibular, 3f  
   mandibular cast, with sprue, 262f  
   maxillary, 4f  
   occlusal interference from, 291  
   supporting artificial teeth, 107  
   using maxillary teeth, 61f  
   waxing of, 254–258, 257f–258f  
 Frankfort plane, 169f  
 Freedom of displacement, limiting, 68  
 Frena, 191  
 Frequency, of force, 22  
 Frictional resistance, 72f, 80  
 Fulcrum, 23, 24f, 26f  
   change in point of, 27f  
 Fulcrum lines, 24, 93, 94f  
   in Class II, modification 1 framework, 98f  
   location for indirect retainer on, 97f  
   not accessible, 97  
   rotation around, 25f, 110, 301  
 Function, loss of, 5  
 Functional forces, 10  
 Functional form, of residual ridge, 233  
 Functional impression, 233  
   technique, 241  
 Functional loads, 112  
   intraoral prostheses and, 322  
 Functional movement, clasp designs  
   to accommodate, 72–79  
   without accommodating, 79–81  
 Functional restoration, with prostheses, 5–6  
 Functional support, for distal extension  
   denture bases, methods for obtaining, 236–241  
 Furcation entrance, closing, 200f
- G**  
 Gagging, 295  
 Geometry, preparation, 67  
 Gingiva, recession of, 201f  
 Gingival areas, finishing of, 281–282, 281f  
 Gingival carving, 281  
 Gingival forms, 273  
 Gingival tissue, varying height of, rules  
   for, 273  
*Glossary of Prosthodontic Terms*, 2–4, 163  
 Gold solder, 307  
 Gold/gold alloys, 185. *see also* Metal alloys  
   cast gold, 88  
   framework, 194f  
   occlusal adjustments with, 107–108  
   physical properties of, 185–186  
   Type IV, 88t  
 Grafts  
   autogenous, 192–193  
   bone, 200f, 326–327  
   skin, 318f, 323f, 324, 327f, 331, 331f  
 Graphite, 141  
 Gravity, 24  
 Grinding/clenching, 198f  
 GTR. *see* Guided tissue regeneration (GTR).  
 Guided tissue regeneration (GTR), 194f, 199  
 Guiding planes, 3f–4f, 75f, 121  
   contact, 183f  
   facing, 122f  
   functions of, 121  
   locations of, 121  
   opposing, 10  
   parallel to path of placement, 142f  
   parallelism and, 87–88, 211–212  
   and path of placement and removal, 134  
   preparations of, 203  
   surfaces of, 120f–122f  
   and surveying casts, 135–136
- H**  
 Hairpin clasps, 79f  
 Half-round retentive arm, 27f  
 Hand hygiene, 177–178  
 Hard palate  
   defect, 315–316  
   maxillary defects and, 318f  
 Health, major connectors and, 32b  
 Height of contour, 83–84, 85f  
 Height of floor of mouth, 33–34, 34f  
 Hemangiomas, traumatic, 191  
 Hepatitis, control of, 177–178  
 Herringbone pattern, of residual ridge, 232f  
 Hinge, 38f  
 Hinge axis mounting, 245  
 Horizontal forces, 26  
 Horizontal jaw relation, 245–246  
 Human immunodeficiency virus (HIV),  
   infection control of, 177–178  
 Hydrocolloid impression materials  
   irreversible, 119f, 223  
   precautions in handling, 223  
   procedure for making, 223–224, 223f  
   reversible, 219–220  
   stone casts from, 224–225
- Hydrocolloid pick-up impression,  
   irreversible, 302f  
 Hygiene, oral. *see* Oral hygiene.  
 Hyperkeratoses, 191  
 Hyperplasia fibrous tuberosities, 190f  
 Hyperplastic tissue, 190–191, 190f
- I**  
 I-bar, 260f–261f  
 Impacted teeth, 189  
 Impingement problems  
   avoiding, 143f  
   by bar clasp assemblies, 75f  
   by major connectors, 31  
 Implants. *see also* Artificial teeth  
   anatomic concerns for Class I and II  
   arches in, 148  
   bar and natural tooth copings, 193f  
   Brånemark system, 192f  
   clinical examples of, 149, 150f–153f  
   dental, 191–192  
   as direct retainers, 81–83  
   excessive occlusal forces in, 194f  
   impact on movements of partial  
   dentures, 22  
   for improving ridge support, 119  
   influence of opposing occlusion on, 149  
   movement control with selective  
   placement of, 148–149  
   physiologic distinction between  
   prostheses and, 147  
   with removable partial dentures,  
   considerations for, 146–153  
   replacing anatomy and functional ability,  
   147–148  
   as rests, 61  
   strategically lost teeth and, 148–149  
   for support vs. retention, 148  
   surveyed crown vs., 148  
   titanium endosseous, 191  
   treatment planning for, 149  
   clasp assembly requirements for using  
   adjacent tooth with, 149  
   location influenced by anatomic and  
   opposing occlusal factors, 149  
   survey considerations, 149  
   use of abutment for support and/or  
   retention in, 149  
 Impression materials, 236–237. *see also*  
   Casts/casting  
   elastic, 219–221  
   mercaptan rubber-base, 220  
   polyether, 220  
   silicone, 220–221  
   hydrocolloid. *see* Hydrocolloid  
   impression materials  
   partially edentulous arch, 222–225  
   step-by-step procedure for making  
   hydrocolloid impression,  
   223–224  
   stone cast, 224–225  
   for relining tooth-supported denture  
   bases, 299  
   rigid, 221  
   metallic oxide paste, 221  
   plaster of Paris, 221

- Impression materials (*Continued*)  
 thermoplastic, 221–222  
 modeling plastic, 221–222  
 waxes and natural resins, 222
- Impression procedures. *see also* Laboratory procedures  
 for distal extension removable partial denture, 301  
 functional impression technique, 241  
 open-mouth technique, 302f  
 selective tissue placement, 237, 237f–238f, 240f
- Impression trays  
 acrylic-resin, 226–228, 227f–230f  
 individual, 162, 225–228  
 stock, 226
- Impressions  
 anatomic form, 236  
 distorted, 223–224  
 fractured occlusal rests and, 306  
 pick-up  
 for direct retainer, 305f  
 for lateral incisor, 308f  
 registration, 114, 124–125  
 type/accuracy of, 233–235, 234f
- Incisal rest seats, 65–66
- Incisal rests, 65–66
- Incisors, lingual rests on, 63–65
- Inclined plane, 23, 23f
- Index areas, 171, 172f
- Indicator paste, 290–291, 290f
- Indicator wax, 293, 294f
- Indirect retainer principle, 95f
- Indirect retainers, 3f–4f, 24, 93–98, 94f, 121–122  
 auxiliary functions of, 96  
 effectiveness of, 96  
 forms of, 96–98  
 functions of, 116–117, 122  
 with palatal plate-type major connector, 95f  
 placement of components of, 93, 95f, 121–122  
 planning the location of, 95f  
 rests for, 35  
 role of, in control of prosthesis movement, 93–96
- Indirect retention, 117
- Individual impression trays, 162, 225–228  
 acrylic-resin, 226–228
- Infection control, 177–178
- Infrabulge clasp, 78
- Infrabulge region, 85f
- Initial placement  
 procedures, 14  
 of removable partial denture, 289–296
- Inlay, 208
- Insertion paths, 134f
- Instability, of removable partial dentures, 11–12
- Instructions, in work authorization, 285–288, 285f–287f
- Instructions to patient. *see* Patient instructions.
- Intaglio surface of occlusal rests, 60f
- Interdental papillae, healthy, 274f
- Interfacial surface tension, 104
- Interference  
 from frena, 191  
 gross, elimination of, 140  
 and path of placement and removal, 134–135  
 surveying for, 136–137
- Interim obturator prosthesis, 319, 319f, 321f  
 with palatopharyngeal defect, 323f
- Interim removable partial dentures, 310–314  
 adjustment to, 313f  
 for appearance, 310, 311f  
 clinical procedure for placement of, 313, 314f  
 conditioning teeth and residual ridges with, 311–312  
 conditioning the patient with, 312–313  
 design of, 314f  
 indications for, 310  
 reasons for using, 311  
 reestablishing occlusal relationships with, 311  
 restoration during treatment with, 312  
 space maintenance with, 311, 312f  
 type of, 312–313
- Internal attachments  
 direct retainers, 90–91  
 advantages of, 90  
 disadvantages of, 90  
 nonlocking, 92f  
 principle of, 90  
 types of, 91  
 placement of, 132
- Internal clip attachments, 125–126
- Internal occlusal rests, 61, 61f
- Internal rest seats, placement of, 132
- Interocclusal records, 168f, 336
- Interocclusal space, 60f
- Interocclusal wax records, 246
- Interpretation of examination data, 169–177  
 caries risk assessment and, 173–174  
 determination of mandibular major connector, 176  
 distal extension spaces, 175  
 endodontic treatment and, 175  
 fixed restorations, 176  
 longer modification spaces, 175  
 occlusal factors, 175–176  
 orthodontic treatment and, 176  
 periodontal considerations in, 173  
 prosthesis foundation, 174  
 radiographic, 170–173  
 reshaping remaining teeth, 176–177, 177f  
 short modification spaces, 175  
 surgical preparation, 174–175
- Interproximal areas, finishing of, 281–282, 281f
- Interproximal occlusal rest seats, 60–61
- Interproximal ring clasp, 79f
- Interviews, patient. *see* Patient interview.
- Intracoronar retainers, 70, 72f, 119–120.  
*see also* Direct retainers  
 placement of, 132
- Investment  
 applying, 263f  
 for casting gold alloys, 263  
 mold, 264f  
 for removable partial denture casting, 262  
 removing casting from, 264, 265f–266f
- Iowa wax, 222
- Irreversible hydrocolloid (alginate)  
 impression, 280, 280f
- Irreversible hydrocolloid pick-up  
 impression, 302f
- Irreversible hydrocolloids, 119f, 220
- Irritating factors, elimination of, 196
- J**
- Jaw deformity, 191
- Jaw relation records, 166–167, 266, 269f  
 made entirely on occlusion rims, 248, 248f
- Jaw relations, establishing, for mandibular removable partial denture opposing maxillary complete denture, 251–252
- Jelenko surveyors, 128, 128f
- K**
- Kennedy classifications, 16–20, 17f  
 advantages of, 20  
 Applegate's rules for applying, 20  
 application of, rules governing, 19b  
 Class I, 28  
 anatomic concerns for, 148  
 bilateral, distal extension removable partial dentures, 124–125  
 dental arches, opposing, 248f  
 follow-up services for, 296  
 mandibular, 34f  
 maxillary distal extension, 100f  
 modification 1, 299f  
 modification to, 4f  
 partially edentulous arches, 113f  
 for sprinkle-on record base, 267f  
 Class I and II arches, 240–241  
 Class II, 28, 78f, 331–332  
 anatomic concerns for, 148  
 follow-up services for, 296  
 indirect retainers for, 97  
 mandibular, 97f, 124f  
 maxillary, 98f  
 modification 1, 92f, 98f, 100f, 102f, 124f, 183f  
 extended occlusal rests with, 59  
 modification to, 3f  
 removable partial dentures, 122–124, 124f  
 Class III, 28  
 arch, in mandibular removable partial denture, 252  
 components of, 117  
 design of, 123f  
 modification 1, 113f  
 removable partial denture, 123f, 124  
 Class I-IV, 17t  
 Class IV, 28, 244  
 defect of, 181f  
 with examples of modifications, 18f

Key abutments, missing, 37–38

Kinematic axis, 164

Knife-edge ridges, 191

## L

Lab handpiece clamp, 130f

Labial bars, 33f, 36–38, 38f, 53–54

Laboratory procedures, 253–282. *see also*

Casts/casting; impression-related entries; Work authorization

for arranging posterior teeth to an occluding surface, 272 forms for, 272

to opposing cast/template, 271–272

for attaching wrought-wire retainer arms, by soldering, 255, 261f–262f

for burnout, 264, 265f

for casting, 264, 265f

finishing and polishing of, 264–265, 267f

removal of, from investment, 264, 265f–266f

for clasp-retained partial dentures, 15

for forming the wax pattern, for mandibular class II removable partial denture framework, 255, 259f–261f

for investing removable partial denture, 274–276, 275f

for making record bases, 266–268 sprinkled acrylic-resin, technique for, 267–268, 267f–269f

for making stone occlusal template, from functional occlusal record, 270–271

for occlusion rims, 268–270, 269f

for polishing denture, 280–282

borders, 280–281

facial surfaces, 281–282

finishing gingival and interproximal areas, 281–282, 281f

preformed plastic patterns in, 256f

processing the denture, 276–279

for remounting and occlusal correction to occlusal template, 279–280

precautions in, 279–280, 280f

sequence of, 292f–293f

for sprued pattern, investing, 262–263, 280f

step-by-step procedure for, 263, 263f–264f

for spruing, 259–262, 262f–263f

for stone cast, duplicating, 253–254, 254f

materials for, 254, 254f

procedure for, 254, 255f–256f

types of anterior teeth for, 272–273

waxing

of metal bases, 256–258

before processing acrylic-resin bases, 273–276

of removable partial denture base, 273–274, 274f

of removable partial denture framework, 254–258, 257f–258f

Lamina dura, alveolar, 171–173

Land space, 276

Latching mechanism, 38f

Lateral discontinuity defects, 336

Ledges

on abutment crowns, 210–212, 210f–212f

forming the crown ledge, 211

preparation of, 211f

as terminal stop, 210

wax, 141, 142f

Legal aspects, of work authorizations, 288

Lever systems, 78f

Leverage effects, reducing, 245f

Levers, 23, 23f

classes of, 24f

first-class, 26f–27f

length of, 26f

Lifting forces, 116f

Lingual aprons

adapting, 35f

adding, to clasp arms, 71

Lingual bar, 30f–31f, 33f, 37f–38f, 52

location of, 31

Lingual bar connector, 119

Lingual extracoronal retention, 90

Lingual finishing lines, 51f

Lingual rest seat, 63f

Lingual rests

on canines and incisor teeth, 63–65

chromium-cobalt, 65f

Lingual retention, 79

Linguoplates, 31, 33f–36f, 34–36, 42f, 52

cingulum bars and, 97

functions of, 122

use of, 119

Lip movement, 311f

“Load-displacement” character, 22b

Loading, abnormal, 171

Locking internal attachments, 91

Long span, 181–182

Longitudinal axis, rotation about, 24, 25f

Luting agent, 67

## M

Magnitude, of force, 22

Major connectors, 3f–4f, 29–55

anterior-posterior palatal bar-type, 45, 45f

beading of maxillary cast, 45, 45f–47f

characteristics of, 32b

choice of, 332

cingulum (continuous) bars, 31f, 33f, 36, 37f, 53

complete palatal coverage, 42f, 54–55

design considerations for, 119

framework for, 30f, 45f

height of floor of mouth, 34f

interference to, 137

junction of minor connectors and, 50, 51f–52f

labial bar, 33f, 36–38, 38f, 53–54

lingual bar, 30f, 32–34, 33f, 37f–38f, 52

lingual finishing lines, 51f

linguoplate, 33f–36f, 34–36, 42f, 52

mandibular, 32–38, 33f

maxillary, 39–45, 39f

palatal plate-type, 41–42, 41f

palatal strap-type, 40–41, 40f

repairs to, 306–307, 306f

Major connectors (*Continued*)

role in control of prosthesis movement, 30–45

single palatal bar, 44–45

single palatal strap, 40, 40f, 54

sublingual bar-type, 31f, 33f, 36, 52–53

U-shaped palatal, 41, 44, 44f, 55

Malposed teeth, 189

Management

of partial tooth loss, 2

of tooth loss, 8–9

considerations for, 8–15

Mandible resections, 324–325, 325f

Mandibular anterior teeth, replacement of, 182

Mandibular bilateral distal extension

partial dentures, 30f

Mandibular bilateral distal extension

removable partial denture, 3f

Mandibular Class I design, 97f

Mandibular Class II, modification 1,

partially edentulous arches, 124f

Mandibular Class II design, 97f, 124f

Mandibular Class II removable partial denture framework, wax pattern for, 255, 259f–261f

Mandibular defects, 324–326

Cantor and Curtis classification of partial mandibulectomy, 330f

type I resection, 331–332, 331f

type II resection, 332–334, 332f–334f

type III resection, 334

type IV resection, 334

type V resection, 334

Mandibular denture bases, 101f

Mandibular distal extension denture, 243, 243f

Mandibular framework, 3f

Mandibular major connectors, 32–38, 33f

design of, 36, 37f

Mandibular prostheses, 330–336

Mandibular reconstruction, 326–327

Mandibular removable partial denture

bilateral distal extension of, 243f

opposing a maxillary complete denture, jaw relations for, 251–252

Mandibular residual ridge, 244, 244f

Mandibulectomy, classification of, 330f

Marginal ridge, 60f

Master casts, 234f. *see also* Casts/casting;

Laboratory procedures

beading line, 46f

blocking out of, 141–142

color-coded markings on, 287–288

modification of, 133f

relieving, 142–144, 143f

surveying, 133, 140

Mastication

chewing studies for, 5

food reduction and, 6

function of, 5–6

mandibular defects and, 324–325

process of, 5–6

restoration of, 325f

Masticatory efficiency, 6

Masticatory forces, 73f, 241

- Materials**  
 for artificial posterior teeth, 250–251  
 for bone augmentation, 192–193  
 cast metal bases, 104  
 for conditioning of tissue, 198f, 202, 202f  
 deformation of, 149  
 for denture bases, 103  
 for diagnostic casts, 161  
 for duplicating stone cast, 254, 254f  
 elastomeric interocclusal registration, 168f  
 impression. *see* Impression materials  
 for interim removable partial dentures, 311  
 metal  
   advantages of, 104–105  
   attachment to denture bases, 108  
   comparative tissue response to, 105  
   esthetics with, 105  
   used with a palatal strap, 105f  
 for relining tooth-supported denture bases, 299  
 tin foil, 217
- Maxillary arch, edentulism in, 4–5**
- Maxillary casts, 103f**  
 beading of, 45, 45f–47f  
 mounting to axis-orbital plane, 164–166, 165f–166f
- Maxillary Class III arches, 123f**
- Maxillary complete denture, jaw relations**  
 for mandibular removable partial denture opposing, 251–252
- Maxillary defects, 318f, 322–324, 323f–324f**  
 surgical reconstruction of, 324
- Maxillary denture bases, 101f**
- Maxillary framework, 3f**
- Maxillary major connectors, 39–45, 39f**
- Maxillary prostheses, 327–330**  
 obturator, 327–329, 327f, 329f  
 palatal augmentation, 330  
 palatal lift, 329–330  
 speech aid, 329
- Maxillary removable partial dentures, 30f**
- Maxillary residual ridge, crest of, 233f**
- Maxillary teeth, framework design using, 61f**
- Maxillary waxed framework, example of, 256f**
- Maxilla-temporomandibular joint relationship, 164**
- Maxillofacial prosthetics, 315–316**  
 acquired defect following surgical removal, 316f  
 Aramany's classification for, 328f  
 arrangement of maxillary teeth and, 316f  
 classification of defects, 315–316, 317f  
 design considerations, for intraoral prostheses, 322  
 interim obturator prosthesis, 319f, 321f  
   with palatopharyngeal defect, 323f  
 jaw relation records for, 336  
 for mandibular defects, 324–326, 325f–326f  
 mandibular guide flange prosthesis, 334–336, 335f  
 mandibular prostheses, 330–336  
   evolution of mandibular surgical resection, 330–331, 330f
- Maxillofacial prosthetics (Continued)**  
 mandibular reconstruction, bone grafts, 326–327  
 for maxillary defects, 318f, 322–324, 323f–324f  
 maxillary prostheses, 327–330  
   obturator, 327–329, 327f, 329f  
   palatal augmentation, 330  
   palatal lift, 329–330  
   speech aid, 329  
 removable partial denture considerations  
   in, 315–336  
 resections of mandible and, 325f  
 surgical preservation for, 322–327  
 timing of dental care with, for acquired defects, 316–322  
   defect and oral hygiene, 321  
   definitive care, 321–322, 321f  
   interim care, 317–320  
   potential complications in, 320–321  
   preoperative and intraoperative care, 316–317, 317f–318f  
 type I resection, 330–336  
   of anterior mandible, 331f  
 type II resection, 334f  
   frame design for, 333f  
   and prosthesis, 332f  
 type III resection, 334  
 type IV resection, 334  
 type V resection, 334
- Maxillomandibular relations, recording of, 248f**
- Mechanical forces, of direct retainer assemblies, 69f**
- Mechanical locks, 102**
- Mechanical retention, 102**
- Melanoma, maxillary malignant, 317f**
- Mercaptan rubber-base impression material, 220**
- Mesial rest concept, 27f**
- Mesio-occlusal rest seat, 63f**
- Metal alloys, 185–187**  
 cast metal base, 104  
 chrome, 108  
 chromium-cobalt, 125, 185–186  
 gold. *see* Gold/gold alloys  
 titanium, 186
- Metal materials**  
 advantages of, 104–105  
 comparative tissue response to, 105  
 esthetics with, 105  
 metal bases  
   accuracy and permanence of form of, 104–105  
   casting of, 103  
   coating with silica of, 109f  
   for distal extension partial dentures, 110  
   partial, 106f  
   thermal conductivity of, 105  
   waxing of, 256–258  
 metal-ceramic crowns, 132f
- Metal teeth, 108**
- Metal-ceramic crowns, 132f**
- Metallic oxide bite registration paste, 168**
- Metallic oxide paste, 221, 247**
- Methyl methacrylate acrylic-resins, 216**
- Microorganisms, exposure to, 178**
- Milling machines, 212f**
- Minor connectors, 3f–4f, 29–55, 47f**  
 avoiding wedging effects with, 73f  
 clasp assemblies, 46f  
 curvature of, 121f  
 in denture bases, 103f  
 design considerations for, 119  
 design of, 48, 48f  
 embrasure spaces for, 47f  
 finishing lines, 48f, 50  
 form and locations of, 46–49  
 framework for, 30f  
 function and position of, 84t  
 functions of, 45–46  
 junction of major connector and, 50, 51f–52f  
 occlusal forces on, 90f  
 physiologic relief of, 333–334  
 proximal plate, 48f  
 relief spaces under, 102f  
 repairs to, 306–307, 306f  
 as stabilizing components, 120  
 terminal portion of, 50f  
 tissue stops, 49–50, 49f  
 vertical rotation of, 122f
- Modeling plastic, 221–222**
- Modification areas, 98, 98f**  
 Class II partial dentures, 98
- Modification spaces, 179**  
 anterior, 179, 180f
- Molars**  
 maxillary, cast molar designs, 108f  
 splinting of, 214  
 unilaterally missing, 179–181, 180f  
 unstable leverage effects of, 245f
- Mold, duplicating, 255f**
- Molding, of soft tissues, 102**
- Mosby's Dental Dictionary, 2–4, 12**
- Mouth preparation, 12–13**  
 abutment teeth. *see under* Abutment teeth  
 augmentation of alveolar bone in, 192–193  
 bony spines and knife-edge ridges in, 191  
 for clasp-retained partial dentures, 15  
 conditioning of abused and irritated tissues in, 200–201, 202f  
 cysts and odontogenic tumors in, 189–190  
 dental implants in, 191–192  
 dentofacial deformity in, 191  
 exostoses and tori in, 190  
 extractions in, 189, 189f  
 hyperkeratoses, erythroplasia, and ulcerations in, 191  
 hyperplastic tissue in, 190–191, 190f  
 impacted teeth in, 189  
 jaw relationship records and, 166  
 malposed teeth in, 189  
 muscle attachments and frena in, 191  
 osseointegrated, 191  
 periodontal preparation, 193–200  
   advantages of, 199–200  
   diagnosis of periodontal disease, 195  
   initial disease control therapy phases of, 196–198  
   objectives of, 194–195  
   treatment planning, 195–196

- Mouth preparation (*Continued*)  
 polyps, papillomas, and traumatic hemangiomas in, 191  
 for removable partial dentures, 188–205  
 sequencing of, 13  
 Mouth-temperature waxes, 222  
 Movement. *see also* Stability/stabilization  
 jaw, 167  
 minor tooth, 198  
 of prosthesis  
 allowing independent, 111  
 biomechanics of, 24–28  
 calculating amount of, 114f  
 control of, 10  
 distribution of stress for, 110–111  
 under function, 147  
 function of denture base in, 99–102  
 impact of, 147  
 internal attachments and, 90–91  
 planes of, 93  
 of removable partial dentures, 21–22  
 role of indirect retainers in control of, 93–96  
 role of major connectors in, 30–45  
 role of rests in, 56–58  
 in three planes, 28  
 with tooth-supported partial denture, 26–27  
 of tissue, 170  
 tooth mobility, 195  
 Mucosa  
 displacement of, 14f  
 over bony protuberances, 190  
 residual ridge, 10, 241  
 Muscle, repositioning of, 191  
 Muscle attachments, 191
- N**  
 National Association of Dental Laboratories (NADL), 288  
 Natural dentition, adjustment of occlusion with, 291–294  
 Natural teeth  
 modification of, 60f  
 support for prostheses by, 9–10  
 Neuromuscular ability, 147  
 Ney surveyors, 128, 128f  
 Nightguard, 193f, 198  
 Nonbearing areas, outlining, 43, 43f  
 Nonlocking internal attachments, 91, 92f  
 Nonsupporting teeth, 94f
- O**  
 Obturator extension, 318f, 328f  
 Obturator prostheses, 327–329, 327f, 329f  
 Occluding template, arranging teeth to, 251  
 Occlusal adjustments  
 articulation ribbon for, 293–294  
 elimination of interference in, 291–292  
 final, 293  
 with gold alloys, 107–108  
 guide to, 197  
 indicator wax for, 293, 294f  
 intraoral, 292  
 with natural and artificial dentition, 291–294, 292f–293f
- Occlusal contact  
 areas of, 6, 109f  
 loss of, 296  
 Occlusal contours, 153f  
 Occlusal disharmony, 197  
 Occlusal forces, 59f, 91f, 116f, 234f  
 Occlusal function, 151f  
 Occlusal harmony, 15, 171, 291–294, 303  
 Occlusal imbalance, 313  
 Occlusal inadequacy, 301  
 Occlusal indicator wax, 293, 294f  
 Occlusal interferences  
 from denture framework, 291  
 elimination of, 196  
 Occlusal load, 27f, 111f, 171  
 distribution of, 57  
 for interim removable partial dentures, 311–312  
 total applied, 236  
 Occlusal pathways  
 recording of, 248–250  
 registering, step-by-step procedure for, 249–250  
 Occlusal plane, irregular maxillary, 317f  
 Occlusal records, 14  
 Occlusal relations, establishment and verification of, 13–14  
 Occlusal relationships, 160  
 in jaw relation records, made entirely on occlusion rims, 248, 248f  
 maxillomandibular, recording of, 248f  
 methods for establishing, 244–250  
 direct apposition of casts in, 246–247  
 interocclusal records with posterior teeth remaining in, 246, 246f  
 occlusal relations using occlusion rims on record bases in, 247–248, 247f  
 recording centric relation on record bases in, 248–250  
 by recording of occlusal pathways, 248–250  
 of opposing molar, 245f  
 for removable partial dentures, 242–252  
 contact, desirable, 243–244, 243f–245f  
 Occlusal rest seats, interproximal, 60–61  
 Occlusal rests  
 auxiliary, 73f, 95f, 96–97  
 canine extensions from, 97, 97f  
 distal, 98  
 double, 79f  
 extended, 59, 59f–60f  
 form of, 58–59  
 fractured, repairs to, 306  
 internal, 61, 61f  
 preparation of, 58f, 207  
 on secondary abutments, 98  
 Occlusal splints, interim removable partial dentures as, 311  
 Occlusal template, remounting and occlusal correction to, 279–280  
 Occlusal vertical dimension, changes in, 274  
 Occlusion  
 on acrylic-resin teeth, 107  
 and clasp-retained partial dentures, 15  
 enhancing, 162f
- Occlusion (*Continued*)  
 establishing, by recording occlusal pathways, 248–250  
 failure of, 242  
 loss of, 110  
 reestablishment of, 107–108  
 on relined removable partial denture, 301–303  
 Occlusion rims, 268–270, 269f  
 jaw relation records made entirely on, 248, 248f  
 for occlusal relations, 247–248, 247f  
 Odontogenic tumors, 189–190  
 One-half T-type bar clasp, 79f  
 Open-mouth impression procedure, 301, 302f  
 Opposing arch tooth positions, 113  
 Opposing flask unit, 275f  
 Opposing guide planes, 10  
 Oral cavity  
 defects in, 318f  
 forces inherent in, 22  
 interim care for, 319  
 surgical reconstruction for, 324  
 Oral competence, 324–325  
 Oral examinations, 157–161  
 sequence of, 157–161  
 Oral function, measures of, 6  
 Oral hygiene, 202  
 brushing of acrylic-resin dentures, 104–105  
 defect and, 321  
 instruction for, 196  
 patient instructions for, 295  
 for protection from caries, 296  
 Oral prophylaxis, 157  
 Oral receptor feedback, 147  
 Oral rehabilitation, 156  
 Oral structures, preservation of, 12  
 Oral tissues, 237  
 Orthodontic procedures, 198  
 Osseointegrated devices, 191  
 Osseous tissue formation, 200f  
 Osteoplasty, 199  
 Outcomes  
 adverse, clasp assembly-related, 71–72  
 of current removable partial denture, 6  
 patient's expected, 8
- P**  
 Palatal augmentation prostheses, 330  
 Palatal connectors, 123f. *see also* under Major connectors.  
 outline of, 43  
 rigidity of, 119  
 selection of, 43  
 Palatal coverage, absence of full, 98  
 Palatal defect, hard, 324  
 Palatal lift prostheses, 329–330  
 Palatal major connectors, 32f  
 Palatal obturators. *see* Interim obturator prosthesis.  
 Palatal occlusal ramps, 336  
 Palatal plate-type major connectors, 41–42, 41f–42f  
 Palatal strap-type connector, 40–41, 40f  
 Palatopharyngeal competence, 324

- Palatopharyngeal defect, 323f  
 Palatopharyngeal incompetence, 329–330  
 Papillomas, 191  
 Paralleled blackout, 142, 143f, 144, 144t–145t  
 Partial denture service, phases of, 12–14  
 Partially edentulous arches  
   classification of, 16–20  
     Applegate's rules for applying  
       Kennedy classification in, 20  
     confusion and disagreement about, 16–17  
     examples of, 17f, 19f  
     requirements for acceptable, 17  
     impressions of, 222–225  
 Partially edentulous epidemiology, physiology and terminology, 1–7  
 Path of insertion (POI), 134f, 149  
 Path of placement  
   for esthetics, 137  
   factors determining, 133–135, 134f, 139f  
   final, 138–139  
   vertical, 134f  
 Patient  
   cautioning, in broken clasp arms, 304–305  
   conditioning of, for wearing a prosthesis, 312–313  
   guide flange prosthesis for, 334–336  
   rapport with, 156  
   shared decision making, 156  
 Patient instructions, 12  
   for care of dentures, 296  
   for placement and removal of removable partial denture, 294–296  
   rules for handling denture, 296  
 Patient interview, 155–156  
   formats for sequencing of, 156  
   influence on treatment decision from, 169  
   objective of, 156  
 Patient-dentist relationship, failure of, 15  
 Pediatric speech aid, 329  
 Periodic recall, 14  
 Periodontal disease, 214f  
 Periodontal mechanoreceptors (PMRs), 5, 147  
 Periodontal preparation, 193–200  
   advantages of, 199–200  
   diagnosis of periodontal disease, 195  
   initial disease control therapy phases of, 196–198  
   objectives of, 194–195  
   treatment planning, 195–196  
 Periodontal surgery, 198–199  
   guided tissue regeneration, 194f, 199  
   periodontal flaps, 198–199  
   plastic surgery, 199, 201f  
 Peripheral rope wax, use of, 268f  
 Permanence of form, of denture bases, 104–105  
 Phases, of partial denture service, 12–14  
 Phonetics, 295  
 Physiologic basing theory, 234–235  
 Physiologic consequences, of tooth loss, 5  
 Placement, of interim removable partial dentures, 313  
 Placement paths  
   dual, 216  
   recontouring for, 87–88  
   for true reciprocation, 210  
 Plan of treatment, 138  
 Plaque, 196  
 Plaster of Paris, 221  
 Plastic mesh patterns, 102, 102f  
 Pocket depth, 195  
 POI. *see* Path of insertion (POI).  
 Polishing the denture, 280–282  
   denture borders in, 280–281  
   facial surfaces in, 281–282  
   finishing gingival and interproximal areas in, 281–282, 281f  
 Polyethers, 220  
 Polyps, 191  
 Polyvinyl siloxane, 165f  
 Porcelain artificial teeth, attaching, 106  
 Positive vertical support, 64f  
 Posterior teeth  
   age and loss of, 4  
   arranging, to opposing cast/template, 271–272  
   artificial, materials for, 250–251  
   forms of, 272  
   mandibular, ascending ramus, 244f  
   with narrower buccal-lingual width, 245f  
 Preformed plastic patterns, 256f  
 Premolar, splinting of lone-standing, 215f  
 Preparation geometry, 67  
 Pressing on a resin tooth, 106–107  
 Pressure  
   common areas of, 291  
   traumatic effects of, 299f  
 Pressure indicator paste, 290f, 291  
 Primary retention, 68, 101  
 Primary support areas, 241  
 Principle of encirclement, 68  
 Probing, pocket depth, 195  
 Prognoses  
   for abutment service, 173f  
   abutment teeth and, 206  
   abutments with guarded, 182, 183f  
   for service of abutment, 38  
 Prostheses  
   design of, 10  
   desirability of, 9  
   distribution of, 7t  
   functional restoration with, 5–6  
   internal attachment of, 10–11, 11f  
   options for, 9–10  
   patients' understanding of, 9  
   in processing flasks, 275f  
   tooth- and tissue-supported, 10–12  
   tooth-supported, 9–10  
   types of, 3f  
 Prosthodontic treatment, 232  
   objectives of, 2  
 Proximal guiding plane, 121, 121f  
 Proximal plates, 48f, 75, 75f, 93–96, 95f  
 Proximal surface modification, 177f  
 Proximal tooth surfaces, relative parallelism of, 136f  
 Psychological benefits, before surgery, 317f  
 Pulley, 23, 23f  
 Q  
 Quality, of residual ridge, 232–233  
 Quality concerns, for removable partial dentures, 7t  
 Quality control, wrought wire, 186–187  
 R  
 Radiographic interpretation, 170–173  
   alveolar lamina dura, 171–173  
   bone density, 170–171  
   disease validation, 170  
   index areas, 171, 172f  
   root morphology, 173, 173f  
   short-cone technique, 170–171  
   tooth support, 170  
 Radiographic survey, 157  
   bone response to previous stress, 157f, 172f  
 Radiographs, for periodontal diagnosis, 195  
 Rebasings. *see* Relining/rebasing denture bases.  
 Recall maintenance, 199  
 Reciprocal arms, 78f  
   counteraction of reciprocation, 68f  
   functions of, 69–70  
   rigidity of, 90f, 121  
 Reciprocal clasp arm  
   functions of, 210  
   incorrect relationship of retentive and, 210f  
 Reciprocation  
   during placement/removal, 69  
   true, 210  
 Reconstruction considerations, 169–170  
 Recontouring  
   of abutting teeth, burs/points for, 62f  
   for path of placement, 87–88  
 Record bases, 266–268  
   occlusal relations using occlusion rims on, 247–248, 247f  
   recording centric relation on, 248  
   sprinkled acrylic-resin, technique for, 267–268, 267f–269f  
 Recording pertinent data, 158f–159f  
 Refractory casts, 46f, 255f  
 Registration. *see also* Casts/casting;  
   impression-related entries  
   impression, 114  
   type/accuracy of, 233–235  
   materials for  
     elastomeric interocclusal, 168, 168f  
     metallic oxide bite registration paste, 168  
 Relief, 143f, 144, 144t–145t  
   in interim removable partial dentures, 314f  
   physiologic, of minor connectors, 333–334  
   for soft tissue, 31f  
   wax, 133f  
 Relief spaces, 102f  
 Relined removable partial denture, 301–303  
 Relining/rebasing denture bases  
   anticipation of, 124  
   distal extension, 300–301  
   indications for, 110, 300–301

- Relining/rebasing denture bases  
(*Continued*)  
need for, 109–110  
open-mouth technique for, 302f  
preparing for need for, 101  
procedure for, 300  
of removable partial denture, 297–303  
of tooth-supported and tooth implant-  
supported denture bases, 299–300  
using existing denture base, 298, 299f
- Reminder space, 286
- Remounting, 302f  
of cast, 280f  
goal of, 292f–293f  
to occlusal template, and occlusal  
correction, 279–280  
precautions in, 279–280, 280f
- Removable partial dentures  
biomechanics of, 21–28  
Class III, 123f, 124  
current use of, 6–7  
damage to, 296  
design, 112–126  
components of, 117–122  
differentiation of types of, 113–115  
essentials of, 115–117  
implant considerations in, 122  
influence of prosthesis support  
differences in, 112–113  
overlay abutments in, 126  
stabilizing components in, 120–121  
systematic approach to, 122–125,  
123t  
tooth support in, 117  
design process for, 22b  
differentiation of types of  
clasp design in, 114–115  
differences in support in, 114  
impression registration in, 114  
distal extension, 232  
finishing, 258–265  
framework  
design of, 235–236, 235f  
waxing, 254–258, 257f–258f  
impact of, 5  
implant considerations in, 122, 146–153  
impression materials and procedures for,  
219–230  
indications for, 181–183  
abutments with guarded prognoses,  
182, 183f  
after recent extractions, 181  
distal extension situations, 181, 181f  
economic considerations, 183  
excessive loss of residual bone, 182  
long span, 181–182  
need for bilateral stabilization, 182  
unusually sound abutment teeth,  
182  
investing, 274–276, 275f  
Kennedy Class I, bilateral, distal  
extension, 124–125  
Kennedy Class II, 122–124, 124f  
maxillary bilateral distal extension of,  
243, 244f  
mouth preparation for, 188–205  
need for, 7
- Removable partial dentures (*Continued*)  
repairs and additions to, 304–309  
broken clasp arms, 304–305  
direct retainer, 305f, 307  
fractured occlusal rests, 306  
loss of tooth, 307, 308f  
major and minor connectors,  
306–307  
by soldering, 307–309  
types of, 307  
required tooth modification for, 122  
technical quality concerns for, 7t  
tooth-supported, 26–27  
unilateral distal extension of, 243, 244f  
work authorizations for, 283–288  
blanks, 287  
characteristics of, 284–285  
content of, 283  
definitive instructions by, 285–288,  
285f–287f  
delineation of responsibilities by,  
288  
form, 284f–285f  
function of, 283–284  
legal aspects of, 288
- Removal of prostheses, frictional resistance  
to, 72f
- Removal paths, factors determining,  
133–135, 134f
- Resections. *see* Mandible resections;  
Mandibular defects.
- Residual bone, 182
- Residual ridge. *see also* ridge-related entries  
casting of, 119f  
conditioning of, 311–312  
contour and quality of, 232–233  
evaluation of, 174  
mandibular, 244, 244f  
resorption of, 149  
slopes of, 232  
support from, 236  
support quality of, 117, 119f
- Residual ridge crest, 232f
- Residual ridge mucosa, 10
- Resin, interim removable partial dentures,  
310
- Resin denture bases, 30f, 101f  
attachment of, 102f  
caution for, 299
- Resin teeth, pressing on, 106–107
- Resin tube teeth, attaching, 106–107, 107f
- Resistance  
direction of, 97f  
frictional, 72f, 80
- Resistance arm, 26f
- Responsibilities, delineation of, by work  
authorizations, 288
- Rest, proximal plate, Akers (RPA) clasp,  
72–78
- Rest, proximal plate, I-bar (RPI) clasp,  
72–78, 75f
- Rest seats, 56–66, 97f  
form of, 58–59  
incisal, 65–66, 65f–66f  
incline angle of, 58f  
interproximal occlusal, 60–61  
for Kennedy Class I arches, 113f
- Rest seats (*Continued*)  
mesio-occlusal, 63f  
occlusal, 57f, 117  
positive vertical support by, 64f  
preparation of, 58f, 60f, 64f, 66f, 205
- Restorations  
abutment, 202–204  
fabricating for existing denture retainers  
and, 216–218  
sequence of preparation on, 207  
during treatment, with interim  
removable partial dentures, 312
- Rests, 3f–4f, 56–66  
adjacent/joined, 60  
auxiliary occlusal, 95f, 96–97  
bilateral, 96  
canine, 97  
determining locations of, 138  
form of occlusal, 58–59  
function and position of, 84t  
incisal, 65–66  
internal occlusal, 61  
lingual, on canines and incisor teeth,  
63–65  
occlusal, 73f  
auxiliary, 95f, 96–97  
canine extensions from, 97, 97f  
double, 79f  
intaglio surface, 60f  
internal, 61  
preparation of, 58f–59f  
on secondary abutments, 98  
shape of, 58f  
preparations, 10  
role in movement control of, 56–58  
support for, 61–63, 113f  
terminal, 97
- Retainers  
direct. *see* Direct retainers  
indirect. *see* Indirect retainers
- Retention  
amount of, 86f  
causes of, 101  
in clasp, 333  
design considerations for, 117  
implant use for, 149  
importance of, 67  
indirect, 117  
measuring, 140–141, 141f  
mechanical, 102  
primary, 68, 101  
secondary, 68, 101  
on terminal abutments, 38f  
weight/bulk and, 105, 105f
- Retentive areas, 87f  
and path of placement and removal,  
134  
and surveying, 136
- Retentive arms, 78f–79f
- Retentive terminals, 86f
- Retromolar pads, 101f, 232f
- Reversible hydrocolloids, 219–220
- Ridge  
anatomic, 14f  
knife-edge, 191  
residual. *see* Residual ridge
- Ridge crest, shortening of, 148

Ridge forms, anatomic and functional, 234f  
Ridge mucosa, residual, 50f  
Ridge support  
  design considerations for, 117–119  
  implants for improving, 119  
Ridge volume, 5  
Rigid clasp arm, 210f  
Rigid connections, 111  
Rigid materials, 221  
  metallic oxide paste, 221  
  plaster of Paris, 221  
Rigidity, of major connectors, 36  
Ring clasps, 80–81, 82f  
Roach clasp arm, 75  
Root morphology, 173  
Root planing, 196  
Root tips, extraction of, 189f  
Rotation around fulcrum lines, 110  
RPA (rest, proximal plate, Akers) clasp, 72–78, 76f  
RPI (rest, proximal plate, I-bar) clasp, 72–78, 76f  
Rugae support, for indirect retainers, 98

**S**  
Saliva control, 324–325  
Salivary calculus, 295  
Scaling, 196  
Screw, 23, 23f  
Seating  
  of denture, 290f  
  of interim removable partial dentures, 313  
Secondary retention, 68, 101  
Selective pressure technique, 240f, 241  
Selective tissue placement impression  
  method, 237, 237f–238f, 240f  
Sensory-functional considerations, 147  
Sequencing, of mouth preparation, 12–13  
Servicing, of removable partial denture, 289–296  
Settling, of denture base, 118–119  
Shaped blockout, 144, 144t–145t  
Shared decision making, 156  
Shortened dental arch, 179–181  
Side-groove teeth, 107  
Silicone, 220  
Simple machines, 23–24, 23f  
Sjögren syndrome, 174  
Skin graft, 318f, 323f, 324, 327f, 331, 331f  
Sleep, wearing removable partial denture during, 295  
Slippage, prevention of, 73f  
Snowshoe principle, 101  
Soft palate  
  normal function of, 324  
  speech aid prosthesis and, 329  
Soft tissue  
  contours, unfavorable, 38  
  cover basal seat areas, 237  
  disease involving, 325  
  in mandibular reconstruction, 326–327  
  relief for, 31f

Soldering, 307–309  
  of broken clasp arms, 304–305  
  of fractured occlusal rests, 306  
  of major and minor connectors, 306–307  
  of wrought-wire retainer arms, 255, 261f–262f  
Somatosensory cortex, 147f  
Sound, of abutment teeth, 182  
Sound enamel, abutment preparations on, 207  
Space, on work authorization form, 286  
Space maintenance, 311, 312f  
Spark erosion technology, 212  
Spatial relationship, of maxillae, 163f  
Specifications  
  ADA No.7, 187t  
  on work authorization form, 287  
Speech, 295, 319–320, 324–325, 330  
Speech aid prostheses, 329  
Spicules, 191  
Splint bars, 125  
  for cross-arch stabilization, 213f  
  shape of, 126f  
  for tooth longevity, 126f  
Splinting  
  of abutment teeth, 213–214, 213f–214f  
  of lone-standing premolar, 215f  
  temporary, 197–198  
Splints, interim removable partial dentures as, 311  
Sprinkling method, 310  
Sprued pattern, investing, 262–263, 280f  
  step-by-step procedure for, 263, 263f–264f  
Spruing, 259–262, 262f–263f  
Squamous cell carcinoma, 315–316, 316f  
Stability/stabilization, 9, 38f. *see also*  
  Movement; Reciprocal arms  
  absence of mandibular canine, 38f  
  by auxiliary occlusal rests, 95f  
  design of stabilizing components, 120  
  under function, 147–148  
  implant use for, 148  
  need for bilateral, 182  
  poor, 157  
  of weak anterior teeth, 97  
Stabilizing components, 28f  
Standard precautions, 177  
Stock tray, 34f  
Stone casts, 224–225, 225f. *see also* Casts/  
  casting; Laboratory procedures  
  duplicating, 253–254, 254f  
  materials for, 254, 254f  
  procedure for, 254, 255f–256f  
  from hydrocolloid impression materials, 224–225  
Stone die, 217  
Stone matrix, 302–303  
Stone occlusal template, from functional  
  occlusal record, 270–271  
Strategic tooth loss, 148–149  
Stress equalizer, 111  
Stress-bearing areas, 14f  
  primary, 241  
Stress-breakers, 115  
  mechanical, 120  
  use of, 11

Stresses  
  horizontal, 69  
  horizontal distribution of, 116f  
  transfer of, 115  
Sublingual bar-type major connectors, 33f, 36, 52–53  
Success Injection System, 277  
Support  
  for clasp-retained partial dentures, 15  
  component partials for gaining, 126  
  design considerations for, 115, 117  
  differences in, 114  
  for/from distal extension denture bases.  
    *see* Distal extension denture bases  
  with maxillary defects, 324  
  overlay abutments for, 126  
  positive vertical, 64f  
  for rests, 37, 38f, 61–63  
  ridge, 117–119  
  splint bars for, 125, 126f  
  tooth, 117  
Suprabulge region, 85f  
Surgery, for interim removable partial  
  dentures, 314f  
Surgical preparation, on maxillary defects, 324  
Surgical procedures, extractions in, 189, 189f  
Surveyor blade, 138–139, 142  
Surveyors/surveying, 83, 84f, 127–145  
  ceramic veneer crowns, 132  
  contouring wax patterns with, 131, 131f  
  dental cast, 12, 13f  
  determining path of placement and  
    removal with, 133–135, 134f  
  diagnostic casts, 130, 130f, 135–138, 135f, 138f–139f, 161  
  final path of placement and, 138–139  
  guiding planes, 135–136  
  for interference, 136–137  
  machining cast restorations with, 133  
  master cast, 133, 140  
  measuring retention and, 140–141, 141f  
  method for manipulating, 134f  
  paralleled blockout, shaped blockout,  
    arbitrary blockout, and relief, 144, 144t–145t  
  position choices for, 136f  
  relation of cast to surveyor, 139–140  
  and retentive areas, 136  
  surveyed crowns vs. implants, 148  
  tools used with, 128f–130f, 140f  
  for treatment planning, 149  
Swallowing, 320–321, 324  
Swallowing threshold, 6  
Swing-Lock design, 36–37, 38f, 333–334  
Syneresis, 223

**T**  
Tapered wrought-wire retentive arm, 27f  
Temperature, freedom of interchange of, 105  
Temporary crowns, 216  
Temporary restorations, 157  
  removable partial dentures and, 311–313  
Temporomandibular joint (TMJ), 163  
Tensile strength, of wrought structure, 187

- Terminal portion of minor connector, 50f
  - Terminal rests, 97
  - Terminology, prosthodontic, 2–4, 3f–4f
  - Thermal conductivity, of denture bases, 105
  - Thermoplastic impression materials, 219
    - modeling plastic, 221–222
    - waxes and natural resins, 222
  - Three-quarter crown, 209
  - Tinfoil, 217, 276
  - Tipped/tilted abutment teeth
    - cast evaluation of, 59f
    - rest preparation with, 59
  - Tipping forces, 28f, 171
  - Tissue conditioning, 202f
    - abused and irritated, 200–201, 202f
  - Tissue contact, 290f
  - Tissue graft, 201f
  - Tissue molding, 102
  - Tissue stops, 49–50, 49f
  - Tissue support
    - from extension base, 27f
    - loss of, 296, 301
  - Tissues
    - abuse to, management of, 299f
    - changes to, 299
    - conditioning of abused and irritated, 200–201, 202f
    - damage to, from major connectors, 31
    - distortion of, 113f, 233
    - reaction to metallic coverage by, 50–52, 105
    - stimulation of, 99
    - types of bases and health of, 111
  - Tissue-supported prostheses, tooth and, 10–12
  - Titanium, 186
  - Titanium endosseous implants, 191
  - Tongue
    - contours of denture bases for contact with, 105
    - encroachment, speech aid prostheses and, 329
    - functional movement of, 34f
    - maxillary defects and, 324–325
    - palatal augmentation prostheses and, 330
    - reconstruction and, 326
  - Tools used for surveying, 128f–130f, 140f
  - Tooth (teeth)
    - conditioning of, 311–312
    - evaluation of, 174
  - Tooth arrangement, cross-arch stability with, 329f
  - Tooth contours
    - analysis of, for retentive clasps, 83–84
    - unfavorable, 38
  - Tooth implant-supported denture bases, relining of, 299–300
  - Tooth loss, 307, 308f
    - and age, 4–5
    - consequences of, 5
    - current management of partial, 2, 3f
    - partial, considerations for managing, 8–15
  - Tooth mobility, 171, 195
  - Tooth replacements, patient's perspectives on, 8–9
  - Tooth-supported denture bases, relining of, 299–300
  - Tooth-supported partial denture
    - clasps of, 114
    - movement with, 26–27
  - Tooth-supported prostheses, 9–10
    - design considerations for, 112–113
    - direct retainers for, 119–120
    - and tissue-supported, 10–12
  - Torch soldering, 308–309
  - Tori, 160, 190, 190f
  - Total occlusal load, 118, 118f
  - Trabecular pattern, 170–171
  - Trauma, to teeth, 87–88
  - Traumatic effects, of pressure, 299f
  - Traumatic hemangiomas, 191
  - Trays. *see* Impression trays.
  - Treatment
    - limitations of, 12
    - objectives of, 156–157
    - purpose and uniqueness of, 155
  - Treatment planning, 154–187. *see also*
    - Diagnosis
      - choosing between complete and removable partial dentures in, 183–185
      - for clasp-retained partial dentures, 15
      - clinical factors with metal alloys, 185–187
      - gold and chromium-cobalt, 185–186
      - wrought wire selection and quality control, 186–187, 186f–187f, 187t
    - extraction and, 206
    - periodontal preparation and, 195–196
    - proposed mouth changes and, 163f
  - Treatment planning phase, of partial denture service, 12–13
  - Treatment sequencing phase, of partial denture service, 12–13
  - Tribochemical coating, 108
  - Tripoding the cast, 139, 139f
  - True reciprocation, 210
  - Tube teeth, 107, 107f
  - Tumors, 189–190
  - Type I resection, 331–332, 331f
  - Type II resection, 332–334, 332f–334f
  - Type III resection, 334
  - Type IV resection, 334
  - Type V resection, 334
- U**
- Ulcerations, 191
  - Undercut gauges, 130, 140, 141f
  - Undercuts
    - approach to, 88
    - depth of, 88
    - as limiting factors, 72–74
  - Unification, 43
  - Unilateral tooth loss, 178–179
  - Unilaterally missing molars, 179–181, 180f
  - U-shaped palatal major connectors, 41, 44, 44f, 55
- V**
- Veneer crowns, 202
    - porcelain, 213f
    - for support of clasp arms, 212–213
  - Veneers, resin, 273
  - Vertical axis, rotation around, 25f, 26
  - Vertical path selection, 134f
  - Vertical stresses, 111
  - Vertical support, 57f. *see also* Rest seats; Rests
  - Visible light-cured (VLC) bases, for occlusal relations, 247
  - Visible light-cured (VLC) custom trays, 226
  - Visible light-cured (VLC) denture base materials
    - for making record bases, 266–267
    - for processing denture, 278
  - Visible light-cured (VLC) material, for artificial teeth, 302–303
  - Visible light-cured (VLC) methods, 310
  - Vitality tests, of remaining teeth, 161
  - Voids, in cast, 275
  - V-shaped groove, 45f
- W**
- Wax
    - hard inlay, 142
    - for registering interocclusal position, 246f
  - Wax blackout, 133f
  - Wax indicators, for occlusal adjustment, 293, 294f
  - Wax interocclusal record, 168f
  - Wax ledges, 142f
  - Wax patterns
    - contouring, 131, 131f, 201f, 204–205
    - for mandibular class II removable partial denture framework, 255, 259f–261f
    - veneer spaces in, 217
  - Wax reliefs, 133f
  - Waxes and natural resins, 222
  - Waxing
    - for management of replacement teeth, 180f
    - of metal bases, 256–258
    - before processing acrylic-resin bases, 273–276
    - of removable partial denture base, 273–274, 274f
    - of removable partial denture framework, 254–258, 257f–258f
  - Wedge, 23, 23f
  - Wedging effects, prevention of, 60, 73f
  - Weight, of denture bases, 105
  - Well-being, major connectors and, 32b
  - Wheel, 23, 23f
  - Whip Mix Facebow, 165, 165f
  - Work authorization, 283–285. *see also*
    - Laboratory procedures
    - blanks, 287
    - characteristics of, 284–285
    - content of, 283
    - definitive instructions by, 285–288, 285f–287f
    - delineation of responsibilities by, 288
    - form, 284f–285f
    - function of, 283–284
    - legal aspects of, 288

Working chart, 160f

Wrought wire, 186–187, 186f–187f, 187t

Wrought-wire clasp arms

breakage of, 304–305

distortion of, 79

tensile strength of, 89

Wrought-wire retainer arms,

79f

soldering of, 255, 261f–262f

X

Xerostomia, 174

Y

Young's modulus of elasticity of titanium alloy, 186

Z

Zinc oxide-eugenol impression paste, 114

سایت کنکور

WWW.KONKUR.IN

مرجع دانلود رایگان کتب علوم پزشکی و مهندسی

آرشیو کامل و رایگان کنکورهای ارشد، دکتری و آزمونهای مقاطع و گرایشهای مختلف علوم پزشکی

This page intentionally left blank